

MINDMAPS in OPHTHALMOLOGY



ABHISHEK SHARMA

Contents

1	Overview	1
2	Cataract and Refractive Surgery	5
3	Cornea and External Eye	27
4	Glaucoma	57
5	Neuro-Ophthalmology	79
6	Oncology	141
7	Orbit, Oculoplastics, and Lacrimal System	157
8	Pediatric Ophthalmology	193
9	Retina and Vitreous	245
10	Trauma	285
11	Uveitis and Inflammatory Eye Disease	301

Abbreviations

5FU: 5-fluorouracil	BD: twice a day (Latin: <i>bis die</i>)
A/W: associated with	BDUMP: bilateral diffuse uveal melanocytic proliferation
AACG: acute angle closure glaucoma	BLRR: bilateral lateral rectus recession
AAION: arteritic anterior ischemic optic neuropathy	BM: basement membrane
AAU: acute anterior uveitis	BM: body mass index
ABx: antibiotics	BP: blood pressure
AC/A Ratio: (accommodative convergence)/(accommodation)	BPES: blepharophimosis epicanthus inversus syndrome
ACA: anterior cerebral artery	BRAO: branch retinal artery occlusion
ACC: adenoid cystic carcinoma	BRVO: branch retinal vein occlusion
ACD: anterior chamber depth	BSL: blood sugar level
ACE: angiotensin-converting enzyme	BSS: balanced salt solution
ACG: angle closure glaucoma	BSV: binocular single vision
ACH: acetylcholine	BUN: blood urea nitrogen
ACIOL: anterior chamber intraocular lens	C3F8 gas: octafluoropropane
ACPIOL: anterior chamber phakic intraocular lens	Ca: carcinoma
AD: autosomal dominant	CAR: cancer-associated retinopathy
AF: atrial fibrillation	CCA: common carotid artery
AHP: abnormal head posture	CCF: carotid–cavernous fistula
AIDS: acquired immunodeficiency syndrome	CCT: central corneal thickness
AION: anterior ischemic optic neuropathy	CDR: cup–disc ratio
aka: also known as	cf.: (Latin) compare with
AKC: atopic keratoconjunctivitis	CFEOM: congenital fibrosis of the extraocular muscles
ALL: acute lymphoblastic leukemia/lymphoma	CFF: critical fusion frequency
AML: acute myelogenous leukemia	CHED: congenital hereditary endothelial dystrophy
ANA: antinuclear antibodies	CHRPE: congenital hypertrophy of the retinal pigment epithelium
ANCA: antineutrophil cytoplasmic antibody	CIN: conjunctival/corneal intraepithelial neoplasia
Anti-TPO: antithyroid peroxidase	CLE: clear lens exchange
Anti-TSH: antithyroid stimulating hormone	CLL: chronic lymphocytic leukemia
Anti-VEGF: antivascular endothelial growth factor	CME: cystoid macular edema
APMPPE: acute posterior multifocal placoid pigment epitheliopathy	CML: chronic myeloid leukemia
AR: autosomal recessive	CMN: congenital motor nystagmus
ARC: abnormal retinal correspondence	CMV: cytomegalovirus
ARMD/AMD: age-related macular degeneration	CN: cranial nerve
ARN: acute retinal necrosis	CNS: central nervous system
ARPE: acute retinal pigment epithelitis	CNV/CNVM: choroidal neovascularization/choroidal neovascular membrane
ASCRS: American Society of Cataract and Refractive Surgery	CPEO: chronic progressive external ophthalmoplegia
AVM: arteriovenous malformation	CRAO: central retinal artery occlusion
AZOO: acute zonal occult outer retinopathy	CRP: C-reactive protein
BARN: bilateral acute retinal necrosis	CRVO: central retinal vein occlusion
BCC: basal cell carcinoma	CSF: cerebrospinal fluid
BCG vaccine: Bacillus Calmette–Guérin vaccine	CSME: clinically significant macular edema
BCL: bandage contact lens	CSNB: congenital stationary night blindness
BCVA: best corrected visual acuity	CSR: central serous retinopathy

- CT:** connective tissue
CT scan: computed tomography scan
CTA: CT angiogram
CVA: cerebrovascular accident
CVF: confrontational visual field
CWS: cotton wool spot
CXR: chest x-ray
D: diopter
DALK: deep anterior lamellar keratoplasty
DCR: dacryocystorhinostomy
DD: disc diameter
DDx: differential diagnoses
DIDMOAD: diabetes insipidus, diabetes mellitus, optic atrophy, and deafness
DLK: diffuse lamellar keratitis
DM: diabetes mellitus
DNA: deoxyribonucleic acid
DSAEK: Descemet's stripping automated endothelial keratoplasty
dsDNA: double-stranded deoxyribonucleic acid
DVD: dissociated vertical deviation
EBMD: epithelial basement membrane dystrophy
EBV: Epstein–Barr virus
ECA: external carotid artery
ECCE: extracapsular cataract extraction
EDTA: ethylenediaminetetraacetic acid
EKC: epidemic keratoconjunctivitis
ELISA: enzyme-linked immunosorbent assay
EMG: electromyogram/electromyography
ENT: ear, nose & throat
EOG: electro-oculogram
EOM: extraocular muscles
EPG/iEPG: electrophoretogram, hyperviscosity screen
EPO: erythropoietin
ERG: electroretinogram
ERM: epiretinal membrane
ESR: erythrocyte sedimentation rate
ET: esotropia
ETT: endotracheal tube
EUA: examination under anesthesia
EVP: episcleral venous pressure
EW nucleus: Edinger–Westphal nucleus
FAP: familial adenomatous polyposis
FAZ: foveal avascular zone
FB: foreign body
FBC/FBE: full blood count/full blood examination
FDT: frequency doubling technology
FEF: frontal eye fields
FEVR: familial exudative vitreoretinopathy
FFA: fundus fluorescein angiography
FISH: fluorescence in-situ hybridization
FK syndrome: Foster–Kennedy syndrome
FLAIR MRI: fluid attenuated inversion recovery magnetic resonance imaging
FTA-ABS: fluorescent treponemal antibody absorbed
FTMH: full-thickness macular hole
G6PD: glucose-6-phosphate dehydrogenase
GA: general anesthetic
GAGs: glycosaminoglycans
GCA: giant cell arteritis
GDx: glaucoma diagnosis (nerve fiber analyzer from Laser Diagnostic Technologies Inc).
GIT: gastrointestinal tract
GON: glaucomatous optic neuropathy
GP: general physician/general practitioner
GRT: giant retinal tear
GU: genitourinary
GVHD: graft-versus-host disease
HAART: highly active antiretroviral therapy
HIV: human immunodeficiency virus
HSV: herpes simplex virus
HTN: hypertension
HVF: Humphrey visual field
HZO: herpes zoster ophthalmicus
IBD: inflammatory bowel disease
ICA: internal carotid artery
ICE syndrome: iridocorneal endothelial syndrome
ICG: indocyanine green
ICL: implantable collamer lens
ICP: intracranial pressure
ICRB: International Classification of Retinoblastoma
IFN: interferon
IIH: idiopathic intracranial hypertension
IK: interstitial keratitis
ILM: internal limiting membrane
INO: internuclear ophthalmoplegia
IO: inferior oblique
IOFB: intraocular foreign body
IOID: idiopathic orbital inflammatory disease
IOL: intraocular lens
IOOA: inferior oblique over action
IOP: intraocular pressure
IQ: intelligence quotient
IR: inferior rectus
IRMA: intraretinal microvascular abnormalities
IRVAN: idiopathic retinitis, vasculitis, aneurysms, and neuroretinitis
ITC: iridotrabecular contact
IV: intravenous
IVDU: intravenous drug use
IVTA: intravitreal triamcinolone acetonide
JFT: juxtafoveal telangiectasia
JIA: juvenile idiopathic arthritis
JXG: juvenile xanthogranuloma
KPs: keratic precipitates
LA: local anesthetic
LASEK: laser epithelial keratomileusis
LASIK: laser-assisted in situ keratomileusis
LCA: Leber's congenital amaurosis
LFT: liver function test
LG: lacrimal gland
LGV: lymphogranuloma venereum

LL: lower lid	OCD: obsessive compulsive disorder
LMN: lower motor neurons	OCP: ocular cicatricial pemphigoid
LOC: loss of consciousness	OCT: optical coherence tomography
LogMAR: logarithm of the minimum angle of resolution (visual acuity chart)	OHS: ocular histoplasmosis syndrome
LP: lumbar puncture	OHT: ocular hypertension
LPS: levator palpebrae superioris	OIS: ocular ischemic syndrome
LR: lateral rectus	ONH: optic nerve head
LRI: limbal relaxing incision	OPA1: optic atrophy 1 gene
LTS: lateral tarsal strip	OSSN: ocular surface squamous neoplasia
M/C/S: microscopy/cultures/sensitivity	PAC: primary angle closure
MALT: mucosa-associated lymphoid tissue	PACG: primary angle closure glaucoma
MAR: melanoma-associated retinopathy	PACS: primary angle closure suspect
MAs: microaneurysms	PAM: primary acquired melanosis
MELAS: mitochondrial encephalomyopathy, lactic acidosis, stroke	PAN: polyarteritis nodosa
Mentor B-VAT tester: Mentor Baylor Video Acuity Tester (for stereoacuity)	PAS: peripheral anterior synechiae
MEWDS: multiple evanescent white dot syndrome	PC: posterior capsule
MFC: multifocal choroiditis	PCA: posterior cerebral artery
mfERG: multifocal electroretinography	PCIOL: posterior chamber intraocular lens
MG: myasthenia gravis	PCNSL: primary CNS lymphoma
MGJW: Marcus–Gunn jaw-winking	PCR: polymerase chain reaction
MGUS: monoclonal gammopathy of undetermined significance	PCRV: polycythemia rubra vera (hyperviscosity cause)
MK: microbial keratitis	PD: prism diopters
MLF: medial longitudinal fasciculus	PDG: pigmentary dispersion glaucoma
MMC: mitomycin C	PDR: proliferative diabetic retinopathy
MR: medial rectus	PDS: pigment dispersion syndrome
MRD: margin reflex distance	PDT: photodynamic therapy
MRI: magnetic resonance imaging	PED: pigment epithelial detachment
MRV: magnetic resonance venogram	PERT: pre-enucleation radiotherapy
MS: multiple sclerosis	PESS: postenucleation socket syndrome
mtDNA: mitochondrial DNA	PET: positron emission tomography
MuSK: muscle-specific kinase (myasthenia due to autoantibodies)	PF: palpebral fissure
NaCl: sodium chloride	PHACE syndrome: posterior fossa brain malformations, hemangiomas, cardiovascular anomalies
NAD: noradrenaline	PHMB: polyhexamethylene biguanide
NAI: non-accidental injury	PHPV: persistent hyperplastic primary vitreous
NAION: non-arteritic ischemic optic neuropathy	PI: peripheral iridotomy
NF: neurofibromatosis	PIC: punctate inner choroiditis
NFL: nerve fiber layer	PIOL: primary intraocular lymphoma
NL: nasolacrimal	PION: posterior ischemic optic neuropathy
NLDO: nasolacrimal drainage obstruction	PK: penetrating keratoplasty
NMJ: neuromuscular junction	PLGF: placental growth factor
NMO: neuromyelitis optica	PML: progressive multifocal leukoencephalopathy
NPDR: nonproliferative diabetic retinopathy	POAG: primary open angle glaucoma
NSAID: non-steroidal anti-inflammatory drug	POHS: presumed ocular histoplasmosis syndrome
NTG: normotension glaucoma	PORN: progressive outer retinal necrosis
NV: neovascularization	PPD: purified protein derivative (tuberculosis test)
NVA: neovascularization angle	PPMD: posterior polymorphous corneal dystrophy
NVD: neovascularization disc	PPRF: paramedian pontine reticular formation
NVE: neovascularization elsewhere	PRK: photorefractive keratectomy
NVI: neovascularization iris (rubeosis iridis)	PRP: panretinal photocoagulation
OB/GYN: obstetrics/gynecology	PSCC: posterior subcapsular cataract
OAG: open angle glaucoma	PSD: pattern standard deviation
	PSP: progressive supranuclear palsy
	PTK: phototherapeutic keratectomy
	PUD: peptic ulcer disease
	PUK: peripheral ulcerative keratitis

PVD: posterior vitreous detachment
PVR: proliferative vitreoretinopathy
PXF: pseudoexfoliation syndrome
QID: four times a day (Latin: *quater in die*)
RA: rheumatoid arthritis
RAPD: relative afferent pupillary defect
RBC: red blood cells
RE: refractive error
REES: recurrent epithelial erosion syndrome
RF: rheumatoid factor
riMLF: rostral interstitial nucleus of medial longitudinal fasciculus
RNA: ribonucleic acid
RNFL: retinal nerve fiber layer
ROP: retinopathy of prematurity
RP: retinitis pigmentosa
RPE: retinal pigment epithelium
RRD: rhegmatogenous retinal detachment
Rx: treatment
SALT: sequential aggressive local therapy
SCC: squamous cell carcinoma
SCI: subcutaneous injection
SF6: sulfur hexafluoride gas
SGC: sebaceous gland carcinoma
SITA: Swedish interactive threshold algorithm
SLE: systemic lupus erythematosus
SLK: superior limbic keratoconjunctivitis
SLT: selective laser trabeculoplasty
SNP: single nucleotide polymorphism
SO: superior oblique
SOAL: secondary ocular adnexal lymphoma
SPK: superficial punctate keratitis
SR: superior rectus
SRF: subretinal fluid
SRK: Sanders, Retzlaff & Kraft IOL formula
SS antibodies: Sjögren syndrome antibodies
SSPE: subacute sclerosing panencephalitis virus
SSRI: selective serotonin reuptake inhibitor
STD: sexually transmitted disease
SWAP: short wavelength automated perimetry
SXR: skull x-ray
TASS: toxic anterior segment syndrome
TB: tuberculosis
TCA: tricyclic antidepressant
TDS: three times daily (Latin: *ter die sumendus*)
TED: thyroid eye disease
TEE: transesophageal echocardiogram
TFBUT: tear film break-up time
TIA: transient ischemic attack
TM: trabecular meshwork
tPA: tissue plasminogen activator
Trab: trabeculectomy
TSH: thyroid stimulating hormone
TVO: transient visual obscuration
UBM: ultrasound biomicroscopy
UEC: urea, electrolytes, creatinine

UGH syndrome: uveitis–glaucoma–hyphema syndrome
UL: upper lid
URTI: upper respiratory tract infection
USS: ultrasound scan
UV: ultraviolet
VA: visual acuity
VDRL/RPR: venereal disease research laboratory / rapid plasma reagin
VEGF: vascular endothelial growth factor
VEP: visual evoked potential
VF: visual field
VHL: von Hippel–Lindau disease
VKC: vernal keratoconjunctivitis
VKH syndrome: Vogt–Koyanagi–Harada syndrome
VOR: vestibulocochlear reflex
VZV: varicella-zoster virus
WAGR syndrome: Wilms tumor, aniridia, genitourinary, retardation
WBC: white blood cells
WCC: white cell count
WEBINO: wide-eyed bilateral internuclear ophthalmoplegia
WHO: World Health Organization
XT: exotropia

Studies

ACCORD: Action to Control Cardiovascular Risk in Diabetes
ADVANCE: Action in Diabetes and Vascular Disease: Preterax and Diamicron MR Controlled Evaluation (evaluation of the effects of a fixed combination of perindopril and indapamide on macrovascular and microvascular outcomes in patients with type 2 diabetes mellitus)
AGIS: Advanced Glaucoma Intervention Study
ANCHOR: Anti-VEGF antibody for the treatment of predominantly classic choroidal neovascularisation in AMD
AREDS: Age-Related Eye Disease Study
BEAT-ROP: Bevacizumab Eliminates the Angiogenic Threat of Retinopathy of Prematurity
BENEFIT: Betaferon®/Betaseron® in Newly Emerging Multiple Sclerosis for Initial Treatment
BOLT: A two-year prospective randomized controlled trial of intravitreal Bevacizumab or Laser Therapy (BOLT) in the management of diabetic macular edema
BRAVO: A Study of the Efficacy and Safety of Ranibizumab Injection in Patients with Macular Edema Secondary to Branch Retinal Vein Occlusion
BVOS: Branch Vein Occlusion Study
CATT: Comparison of Age-Related Macular Degeneration Treatments Trials
CHAMPS: The Controlled High Risk Avonex® Multiple Sclerosis Trial
CIGTS: Collaborative Initial Glaucoma Treatment Study

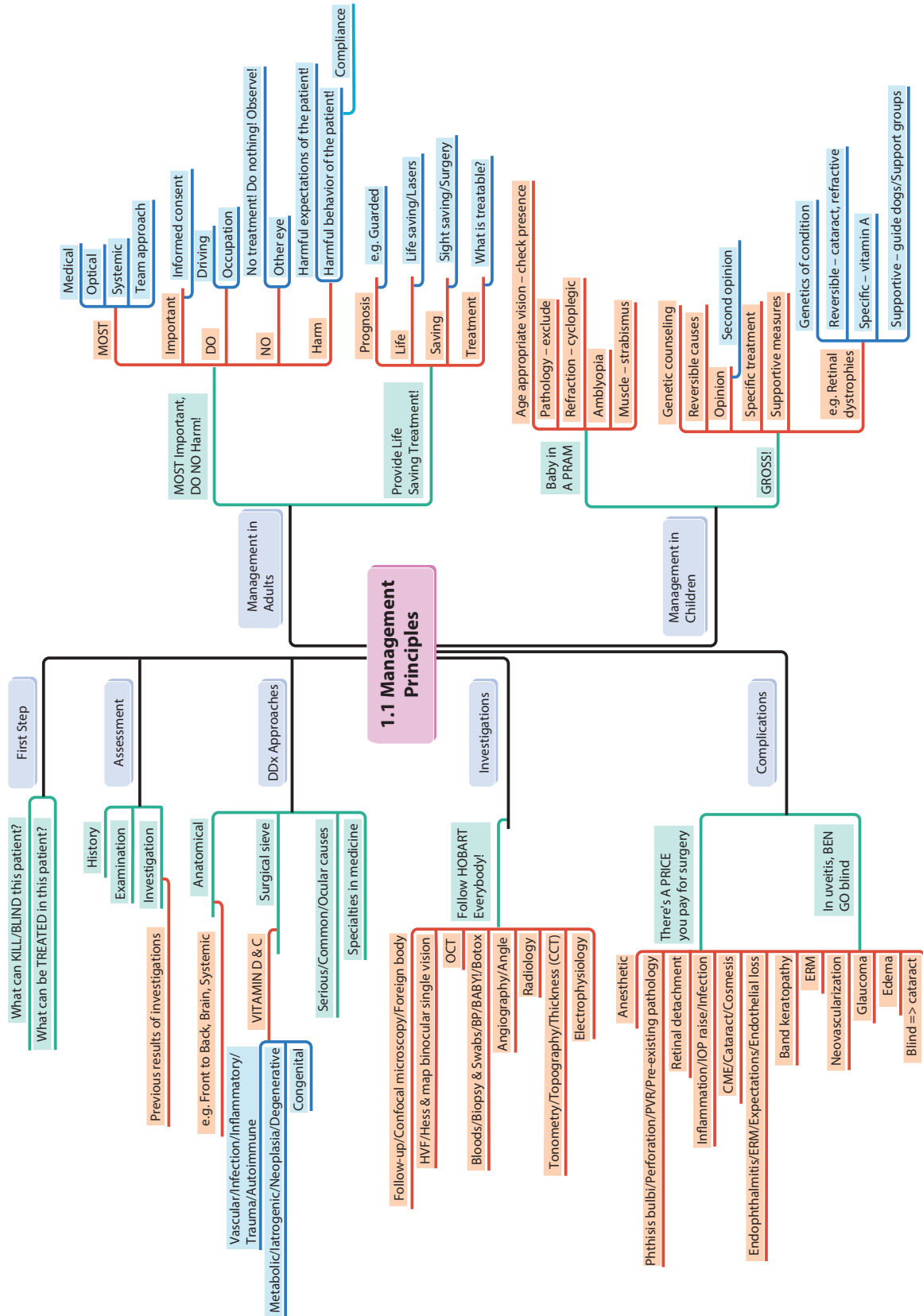
- CNTGS:** Collaborative Normal Tension Glaucoma Study
COMS: Collaborative Ocular Melanoma Study
CRASH: Corticosteroid Randomisation after Significant Head Injury
CRUISE: A Study of the Efficacy and Safety of Ranibizumab Injection in Patients with Macular Edema Secondary to Central Retinal Vein Occlusion
CRYO-ROP: Cryotherapy for Retinopathy of Prematurity
CVOS: Central Vein Occlusion Study
DCCT: Diabetes Control and Complications Trial
DIRECT: Diabetic REtinopathy Candesartan Trials
DRCR.net: The Diabetic Retinopathy Clinical Research Network
DRS: Diabetic Retinopathy Study
DRVS: Diabetic Retinopathy Vitrectomy Study
EGPS: European Glaucoma Prevention Study
EMGT: Early Manifest Glaucoma Treatment Study
ESCRS: European Society of Cataract & Refractive Surgeons Study (prophylaxis of postoperative endophthalmitis after cataract surgery)
ETDRS: Early Treatment of Diabetic Retinopathy Study
ETOMS: Early Treatment of Multiple Sclerosis Study
ETROP: Early Treatment for Retinopathy of Prematurity
EUGOGO: European Group on Graves' Orbitopathy
EVEREST: Efficacy and safety of verteporfin photodynamic therapy in combination with ranibizumab or alone versus ranibizumab monotherapy in patients with symptomatic macular polypoidal choroidal vasculopathy
EVS: Endophthalmitis Vitrectomy Study
FFSS: Fluorouracil Filtering Surgery Study
FIELD: Fenofibrate Intervention and Event Lowering in Diabetes
GLT: Glaucoma Laser Trial
IATSG: Infant Aphakia Treatment Study Group
IONTS: International Optic Nerve Trauma Study
MARINA: The Minimally Classic/Occult Trial of Anti-VEGF Antibody Ranibizumab in the Treatment of Neovascular AMD
MOTAS: Monitored Occlusion Treatment of Amblyopia Study
MPS: Macular Photocoagulation Study
NASCET: North American Symptomatic Carotid Endarterectomy Trial
NASCIS: National Acute Spinal Cord Injury Study
OHTS: Ocular Hypertension Treatment Study
ONTT: Optic Neuritis Treatment Trial
PEDIG: Pediatric Eye Disease Investigator Group – Amblyopia Studies
PIER: Portland Identification and Early Referral (randomized, double-masked, sham-controlled trial of ranibizumab for neovascular ARM)
PRONTO: Prospective Optical coherence tomography imaging of patients with Neovascular AMD Treated with intra-Ocular ranibizumab
RASS: Renin-Angiotensin System Study
READ: Ranibizumab for Edema of the mAcula in Diabetes study
RESOLVE: Safety & Efficacy of Ranibizumab in Diabetic Macular Edema
RESTORE Study: Ranibizumab monotherapy or combined with laser versus laser monotherapy for diabetic macular edema
RISE and RIDE Studies: Prospective, double-masked, phase 3 trials, compared the use of monthly ranibizumab to sham injections in patients with vision loss and diabetic macular edema
SAILOR: Safety Assessment of Intravitreal Lucentis for AMD
SCORE: Standard Care vs. Corticosteroid for Retinal Vein Occlusion
STOP-ROP: Supplemental Therapeutic Oxygen for Prethreshold Retinopathy of Prematurity
UKPDS: The United Kingdom Prospective Diabetes Study
VIEW: VEGF Trap-Eye: Investigation of Efficacy and Safety in Wet Age-Related Macular Degeneration
WESDR: Wisconsin Epidemiologic Study of Diabetic Retinopathy

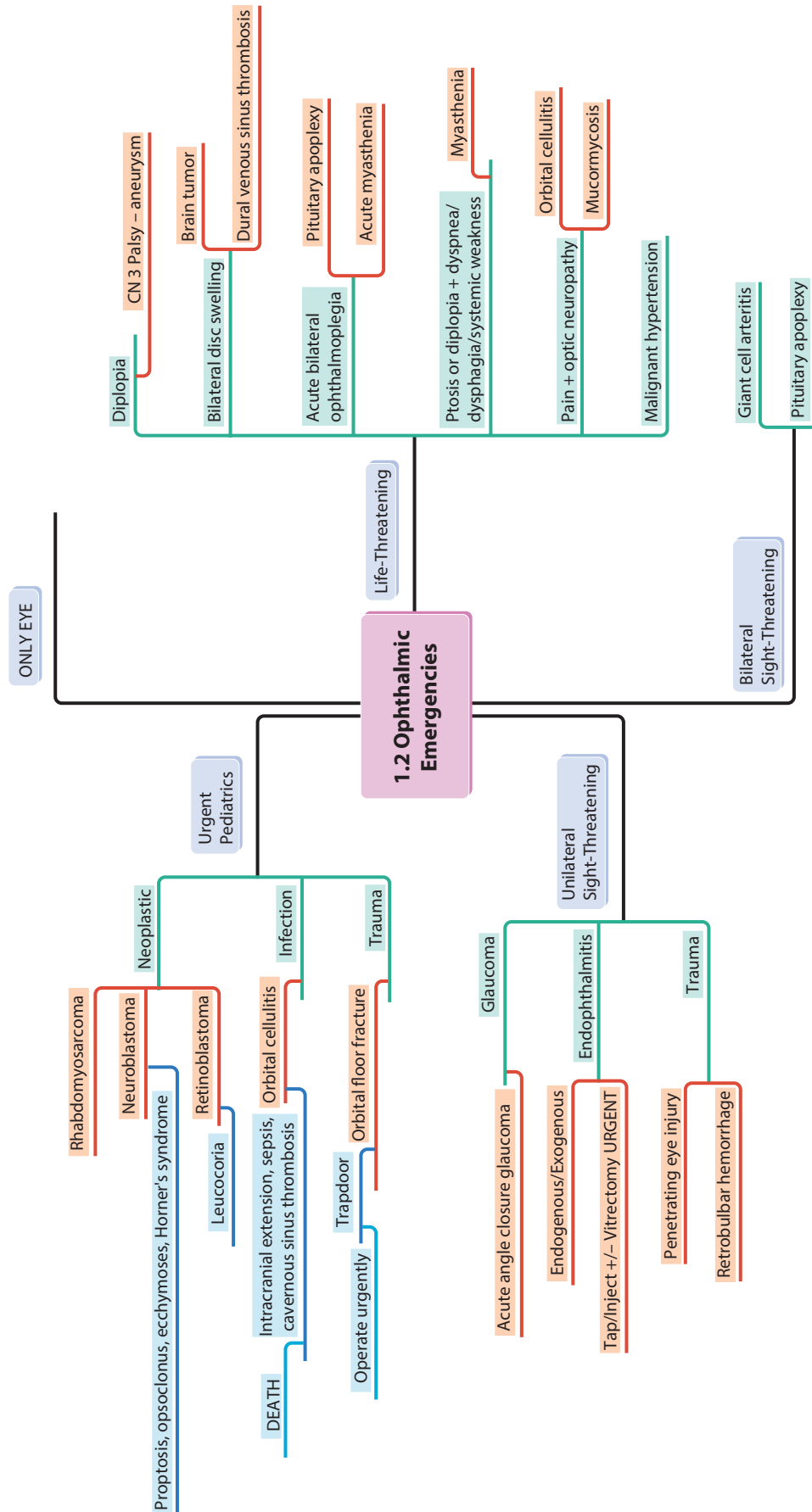
1 Overview

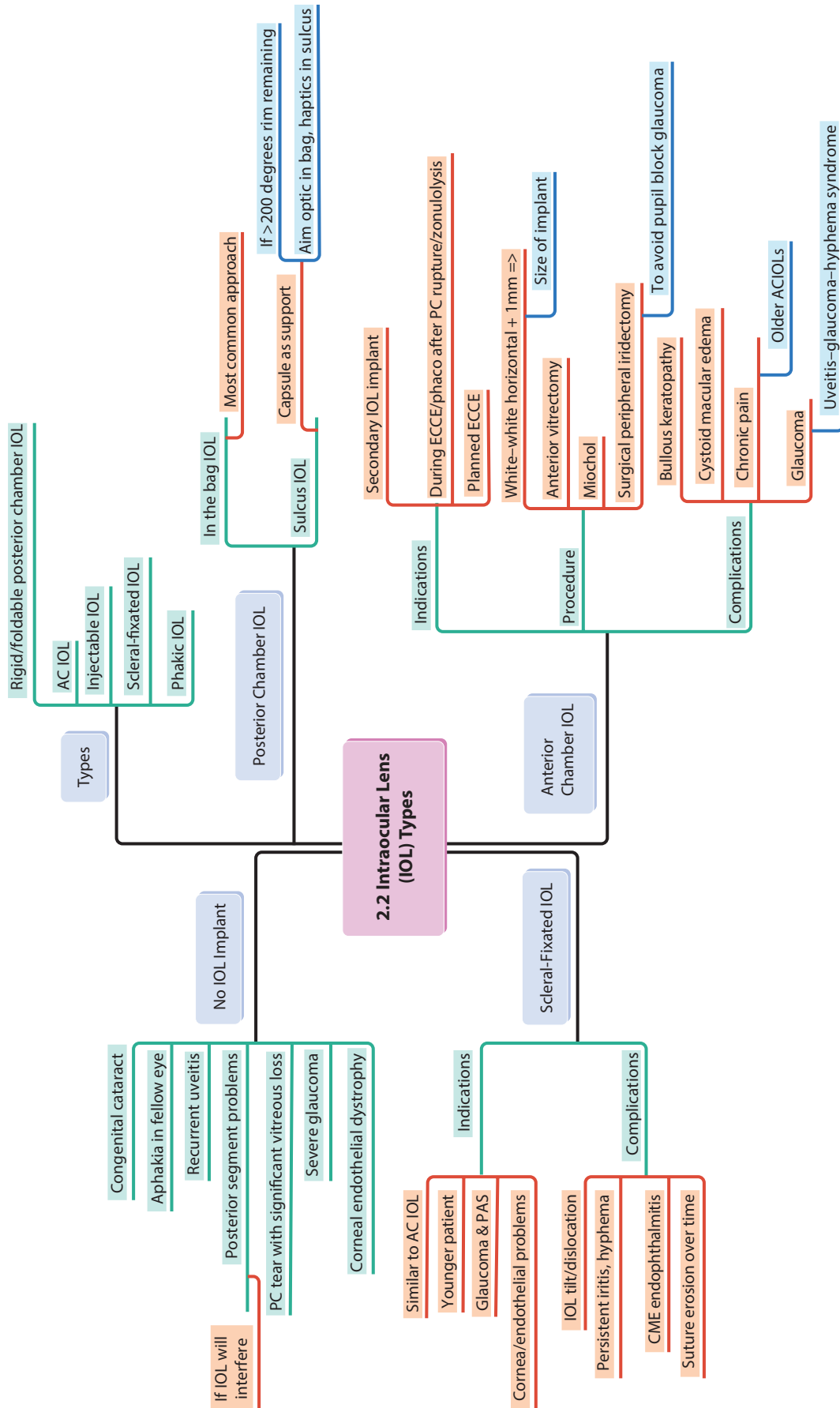
Overview

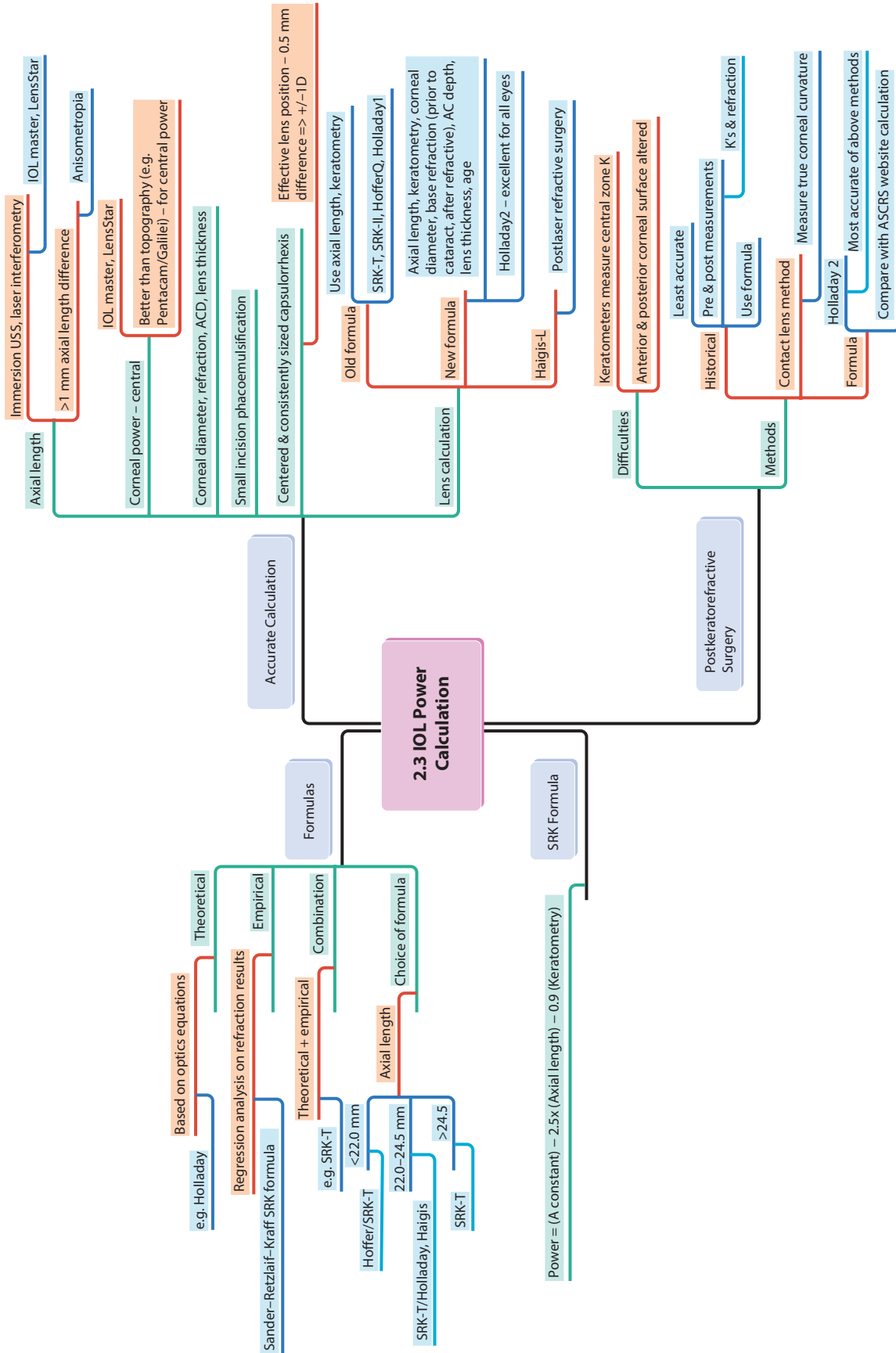
1.1 Management Principles

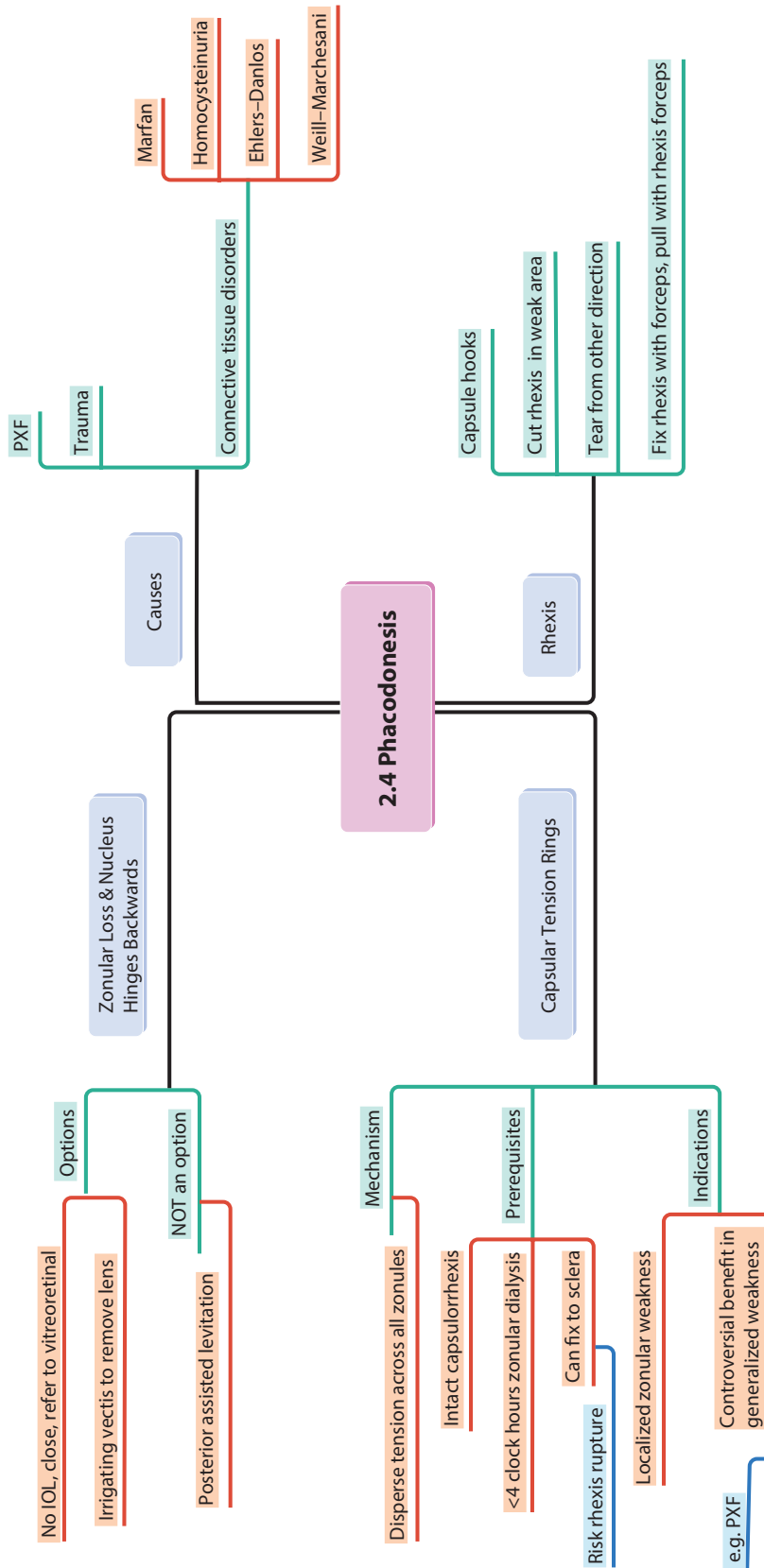
1.2 Ophthalmic Emergencies

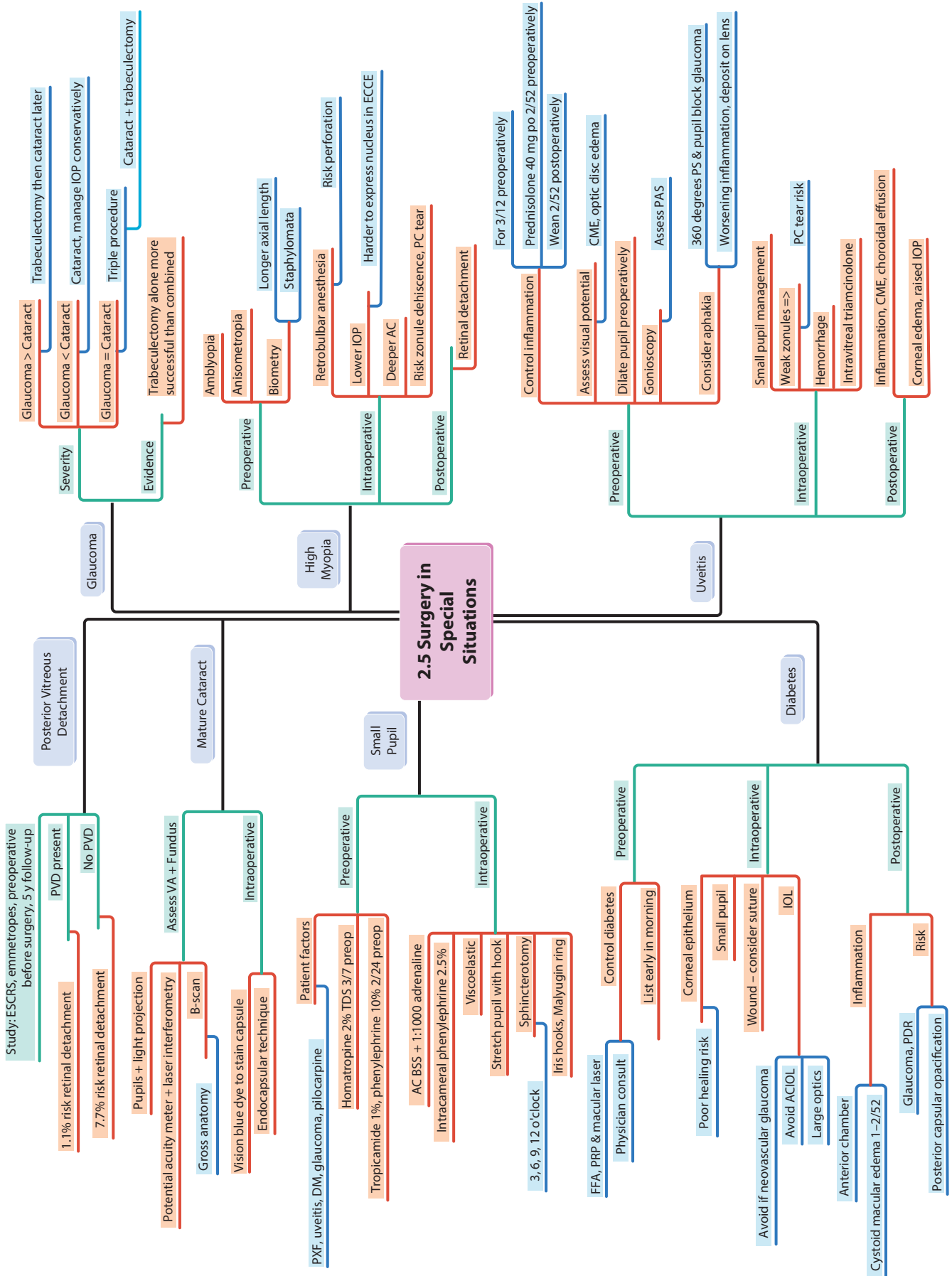


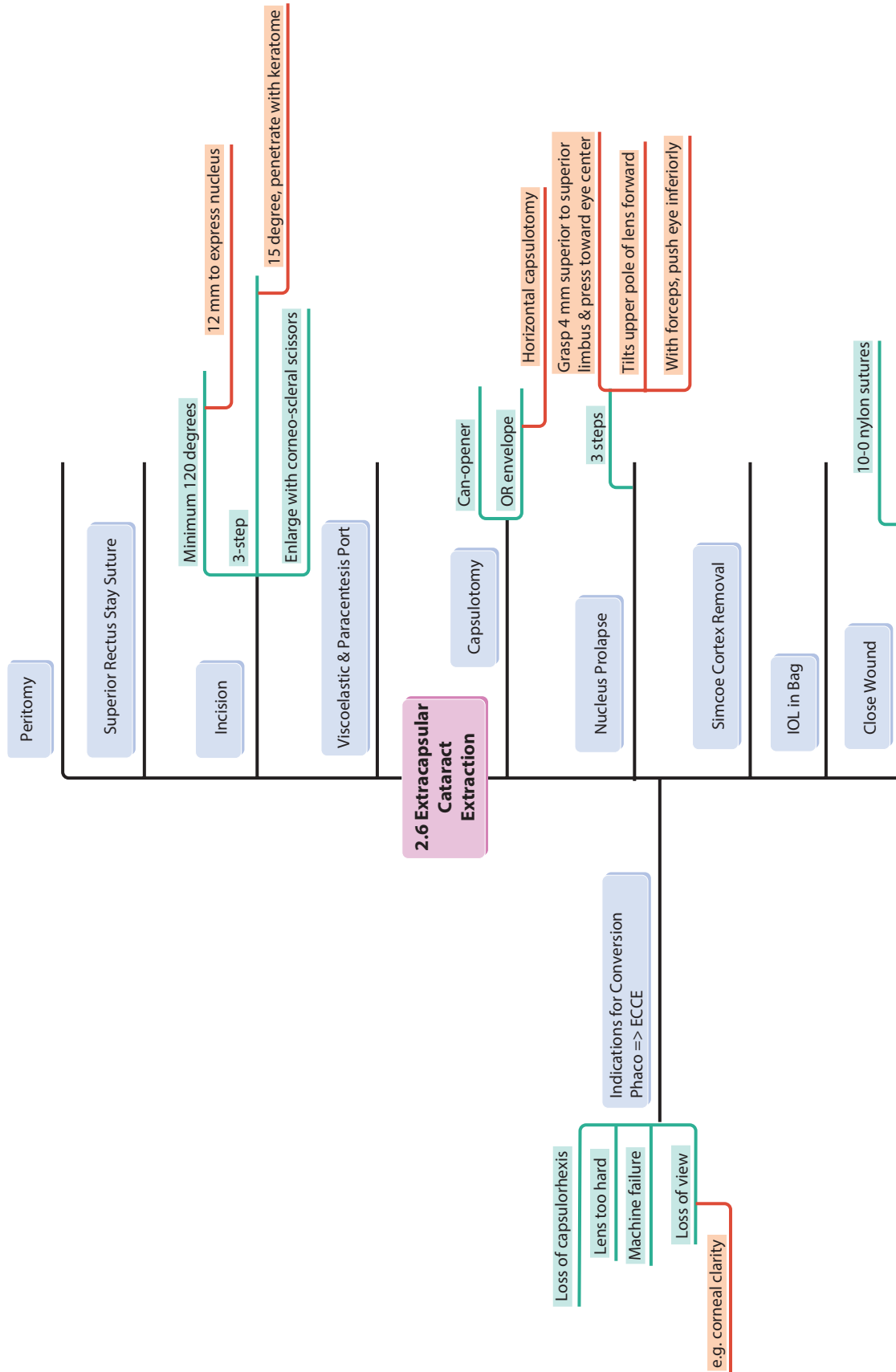


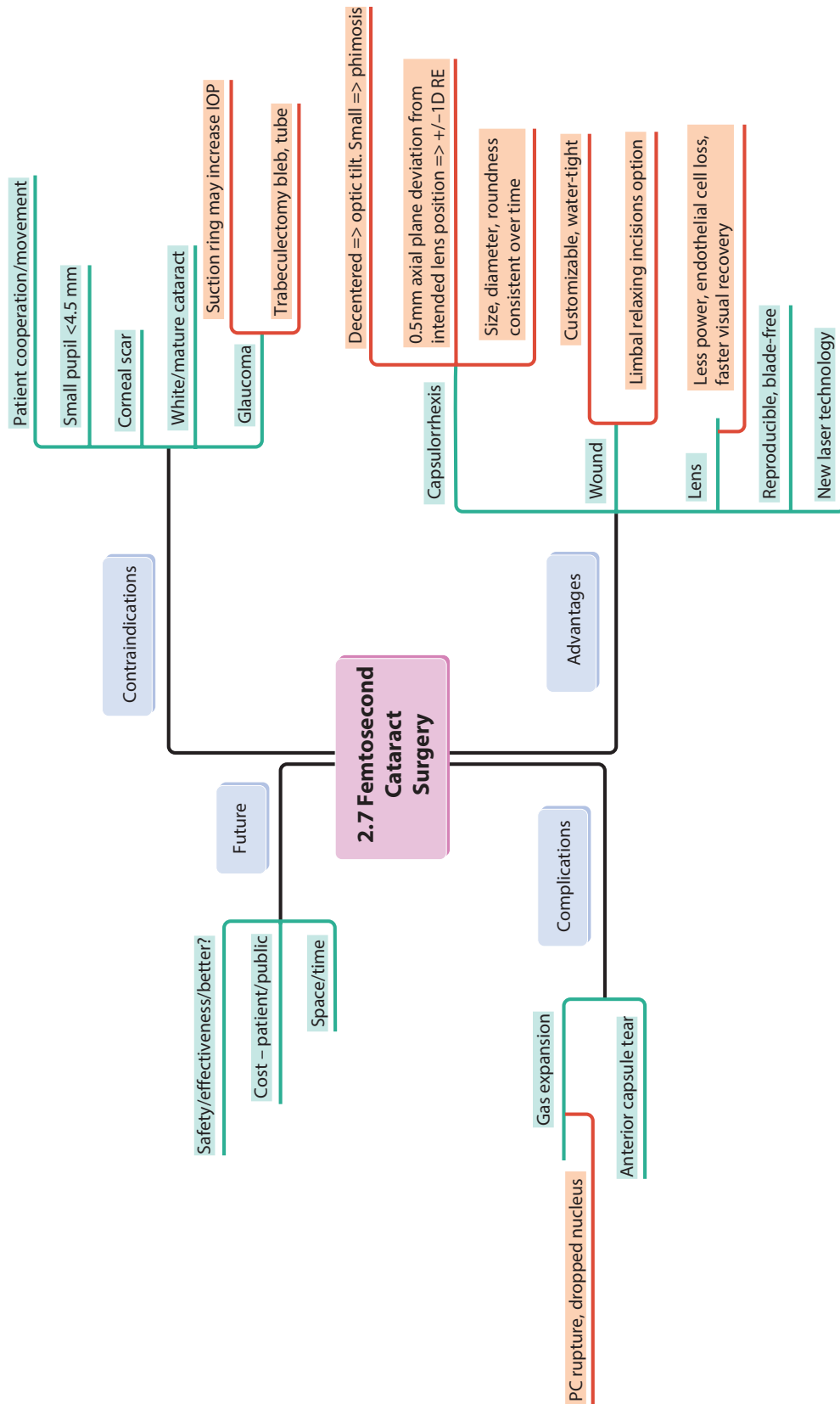


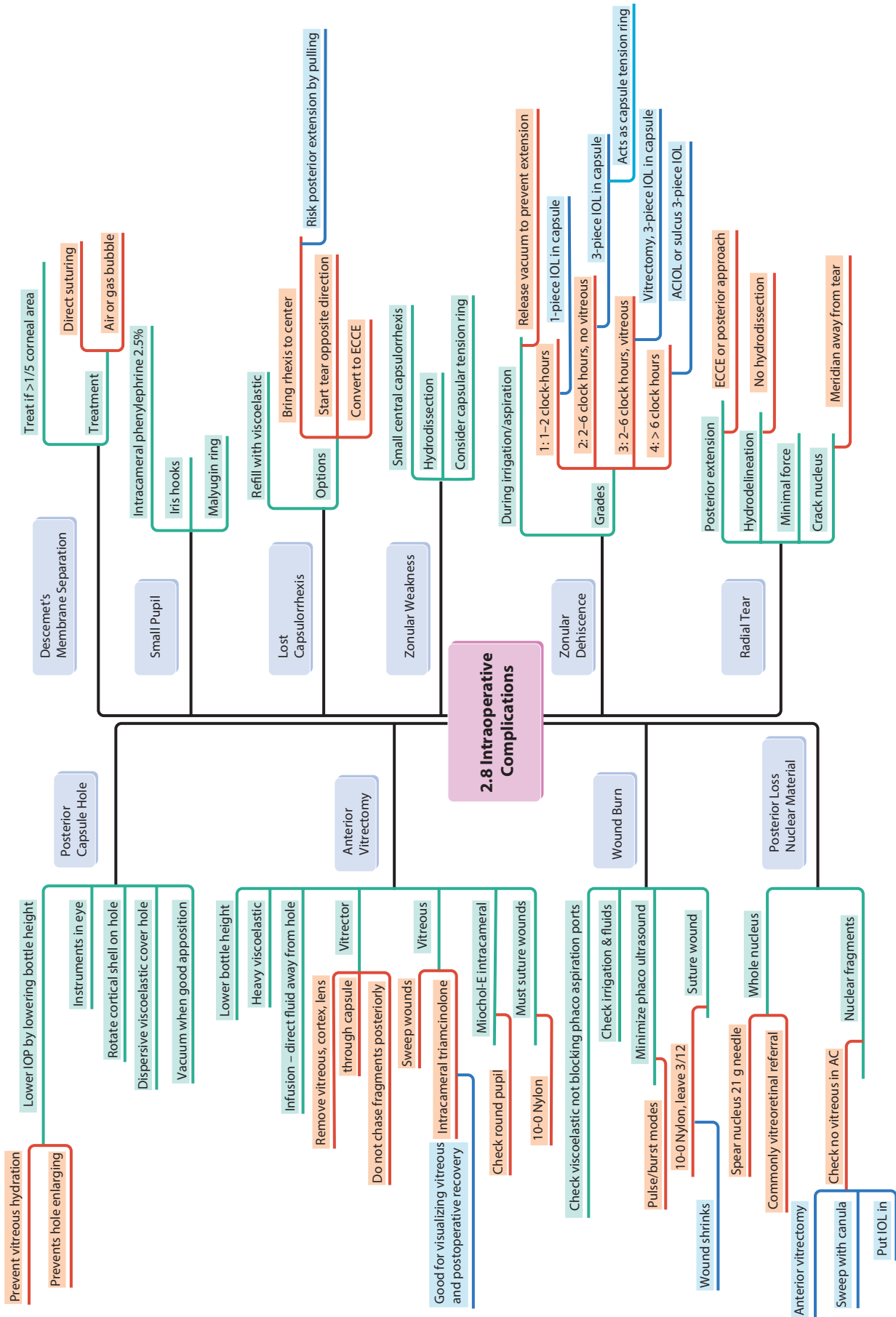


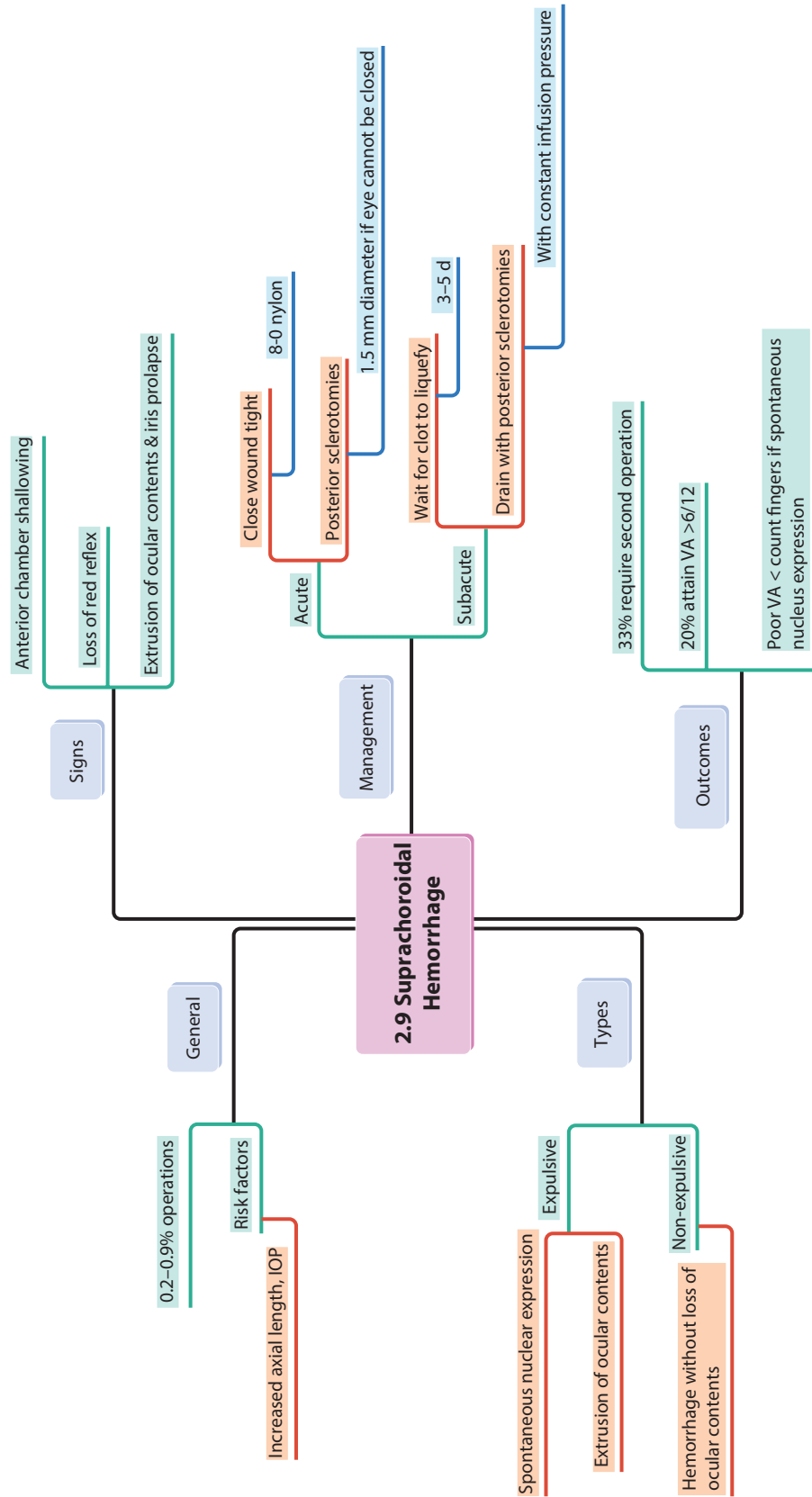


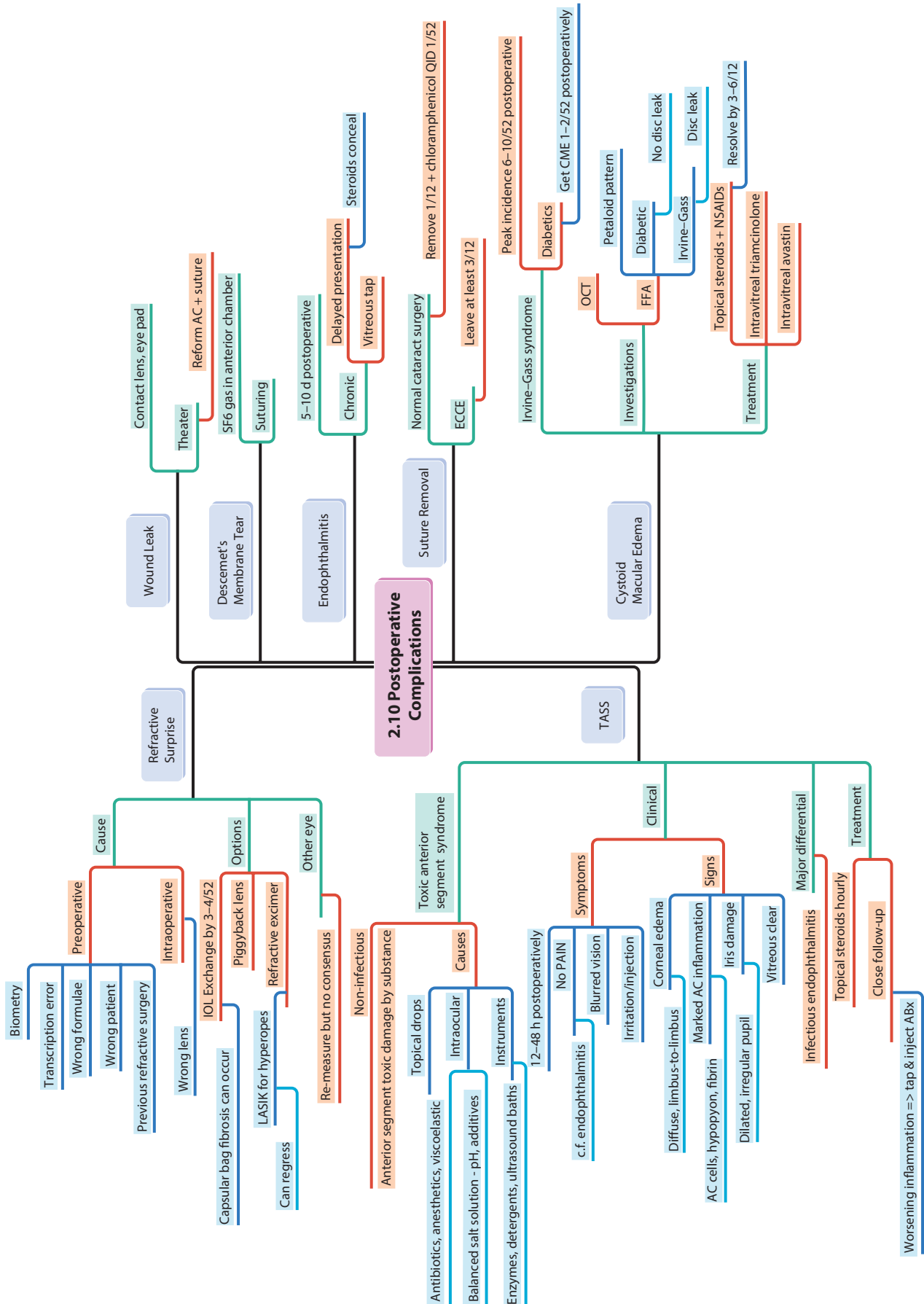


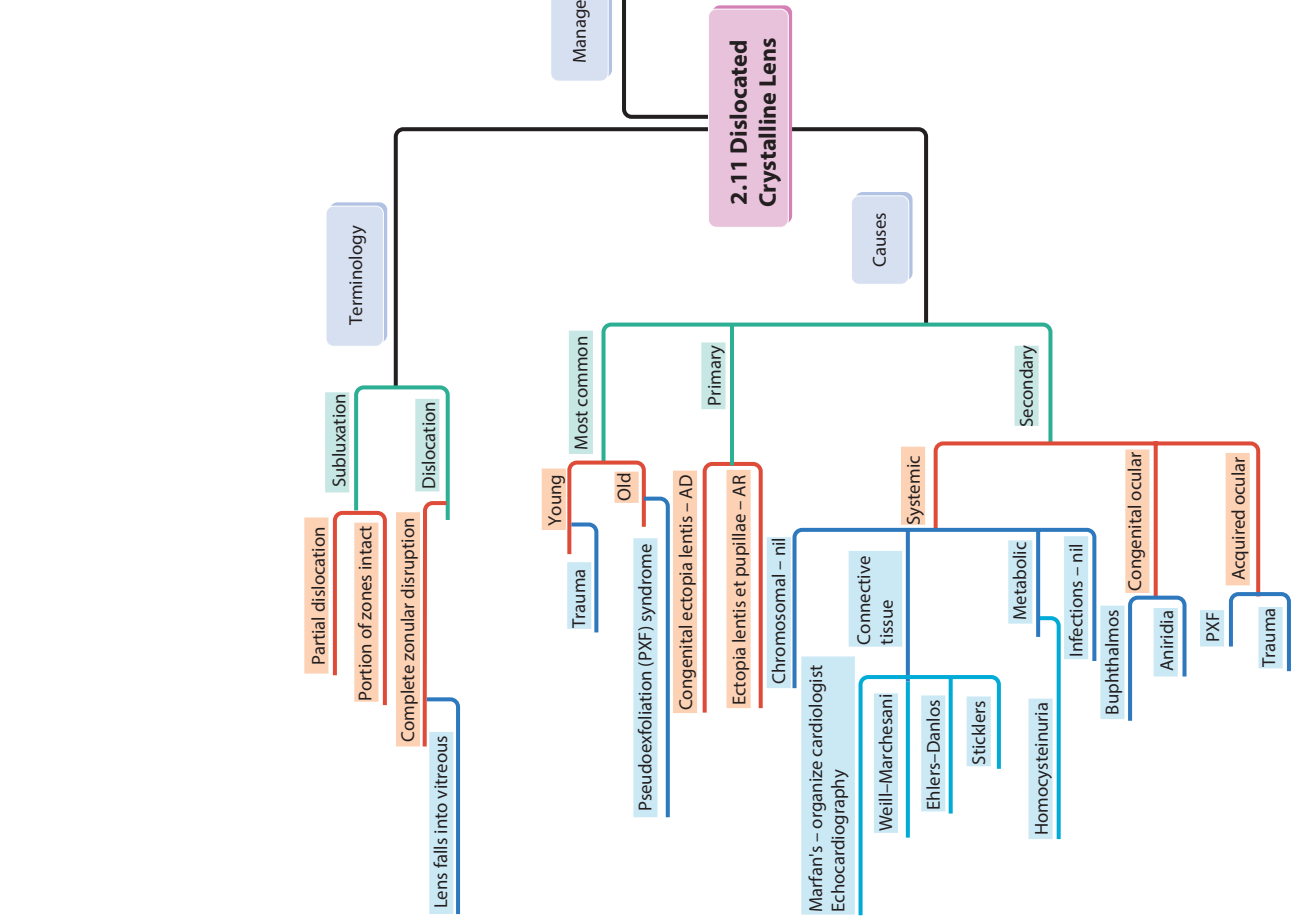
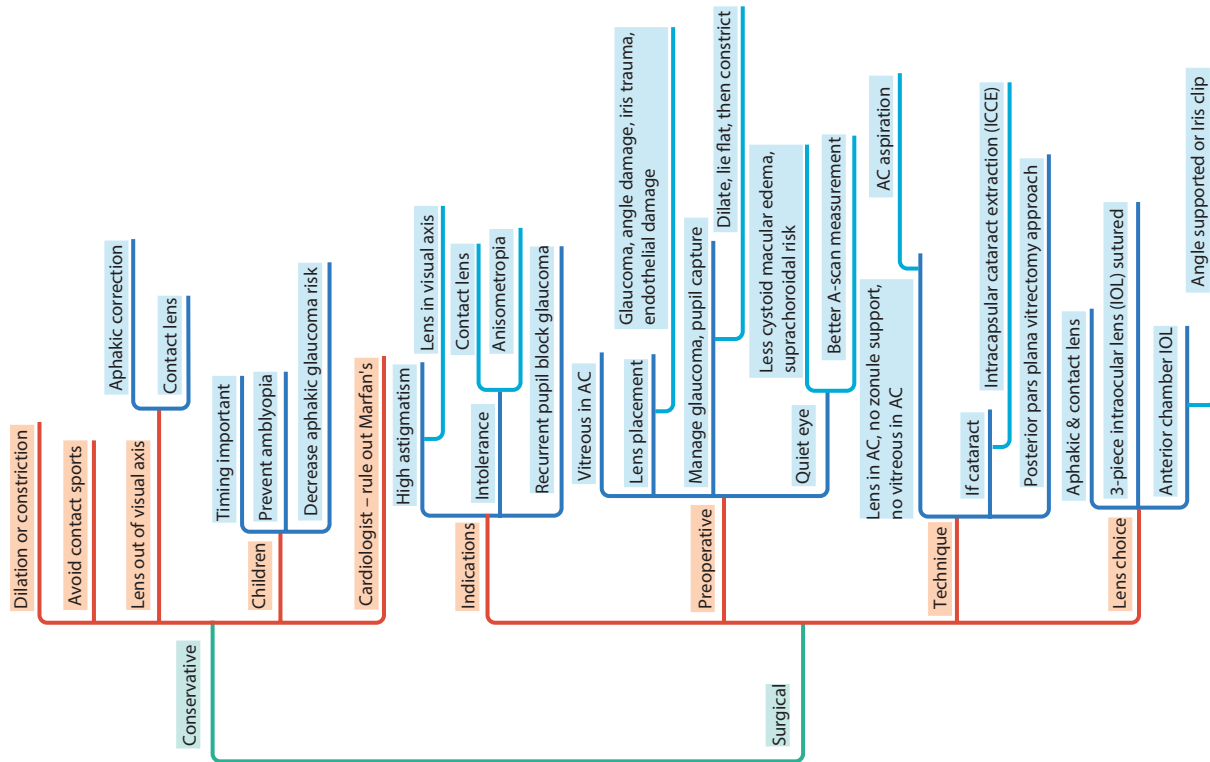


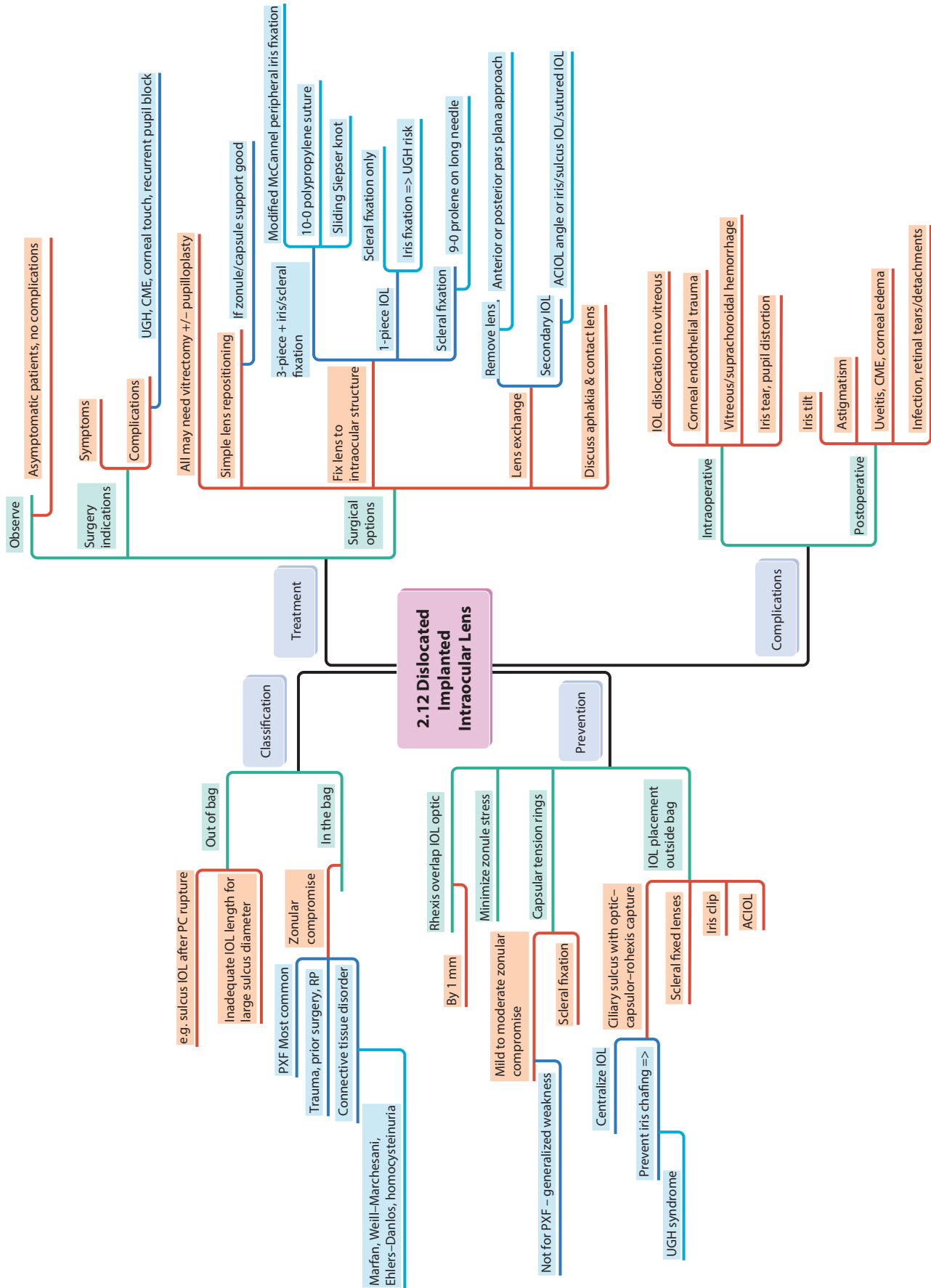


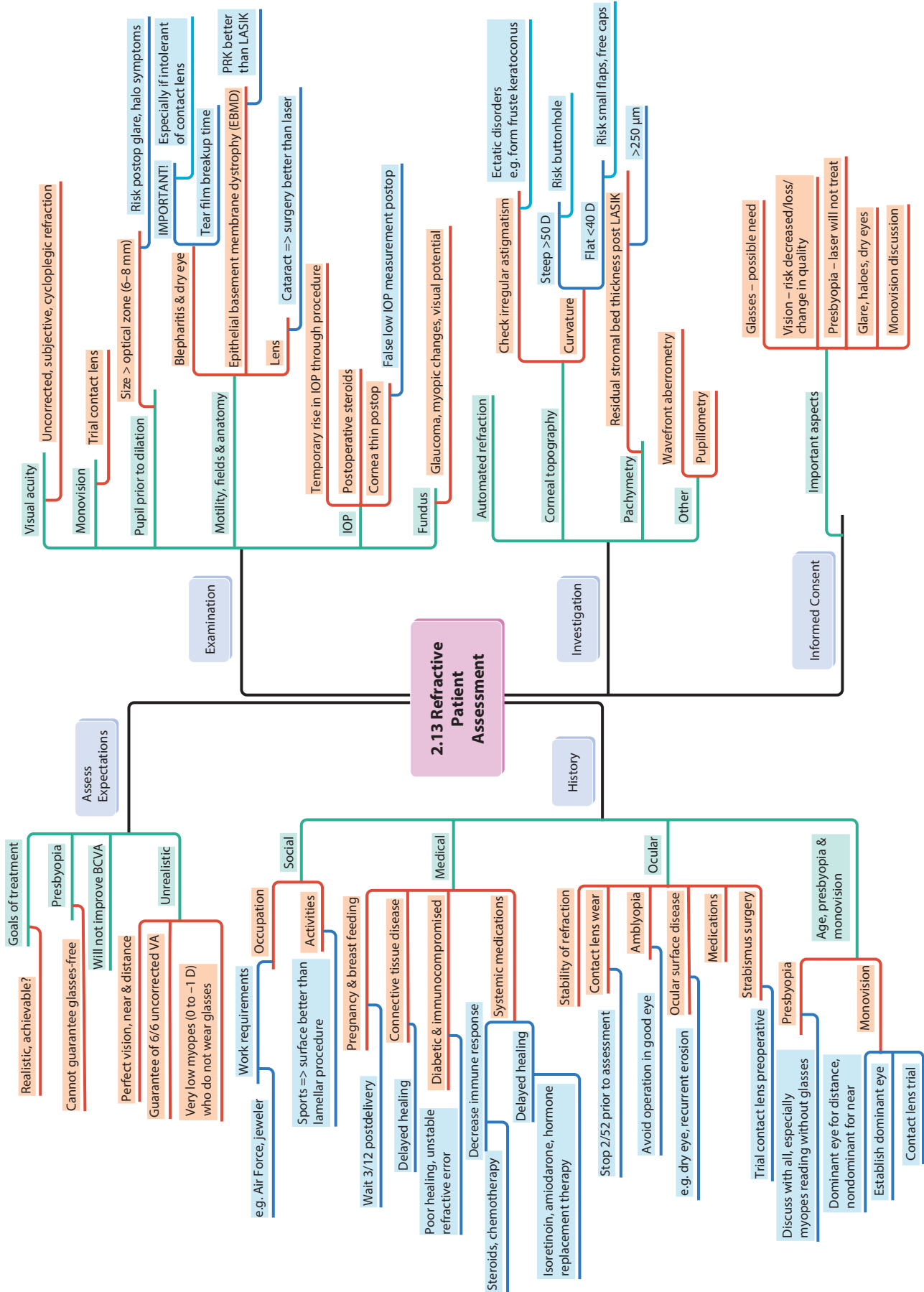


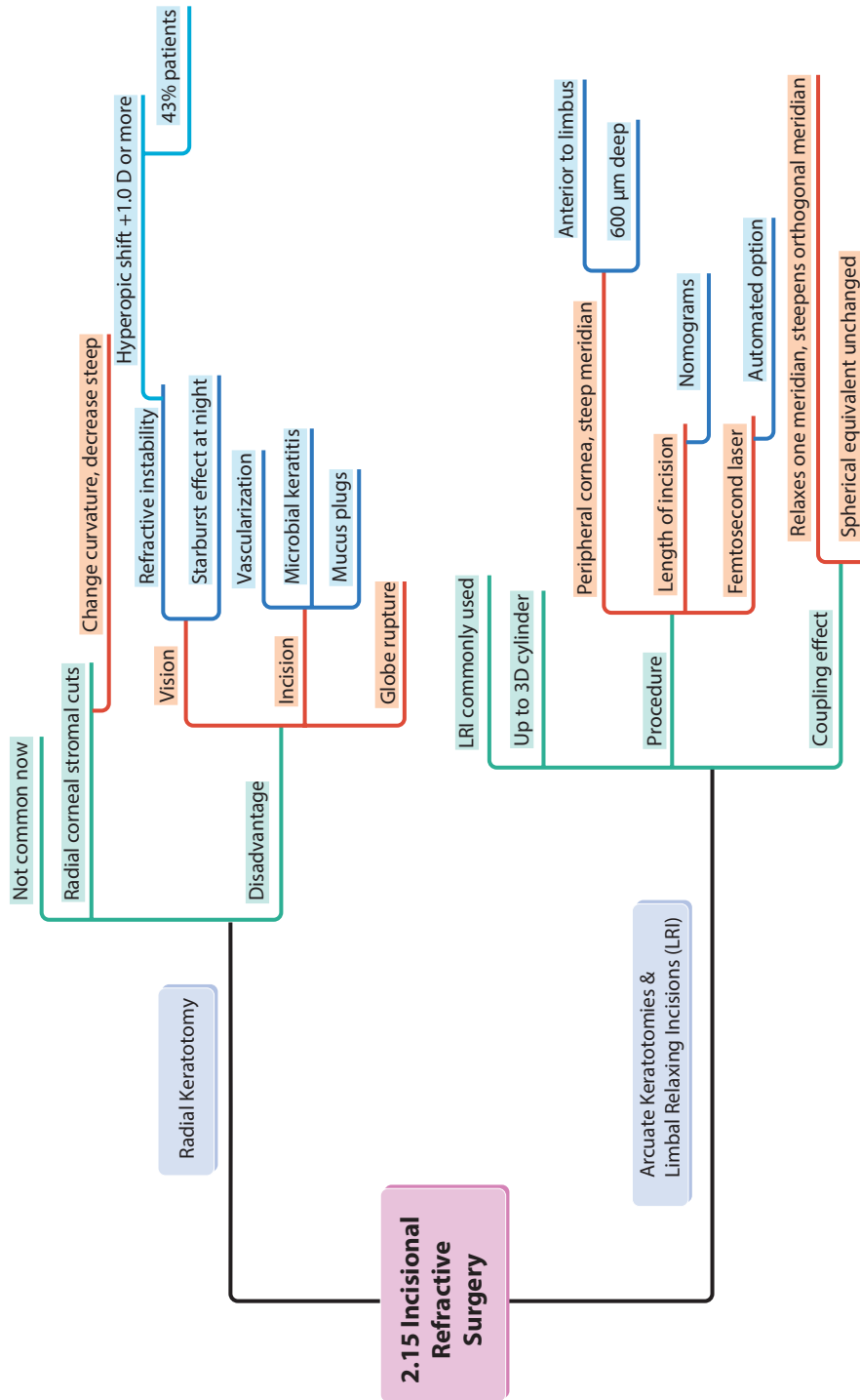


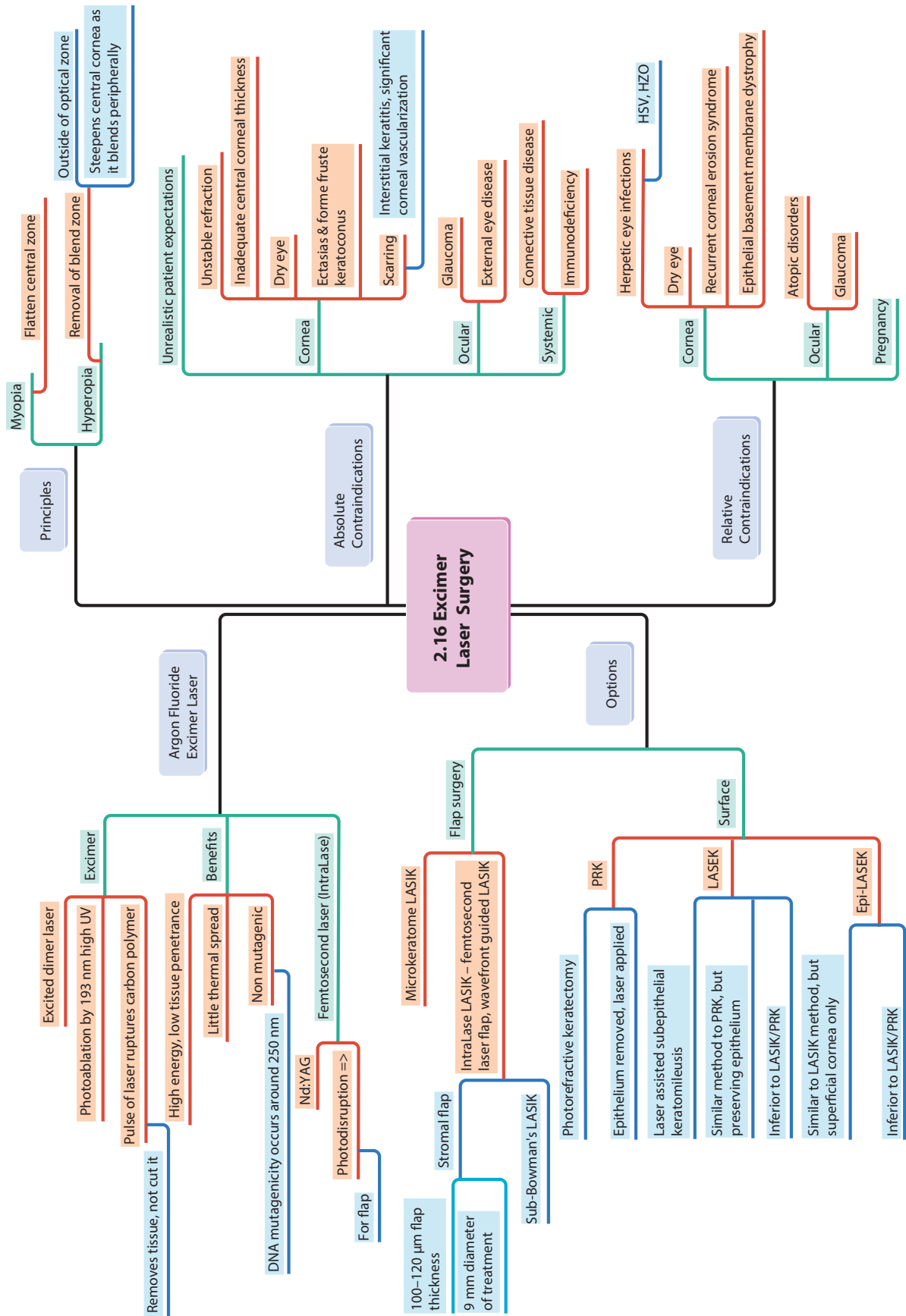


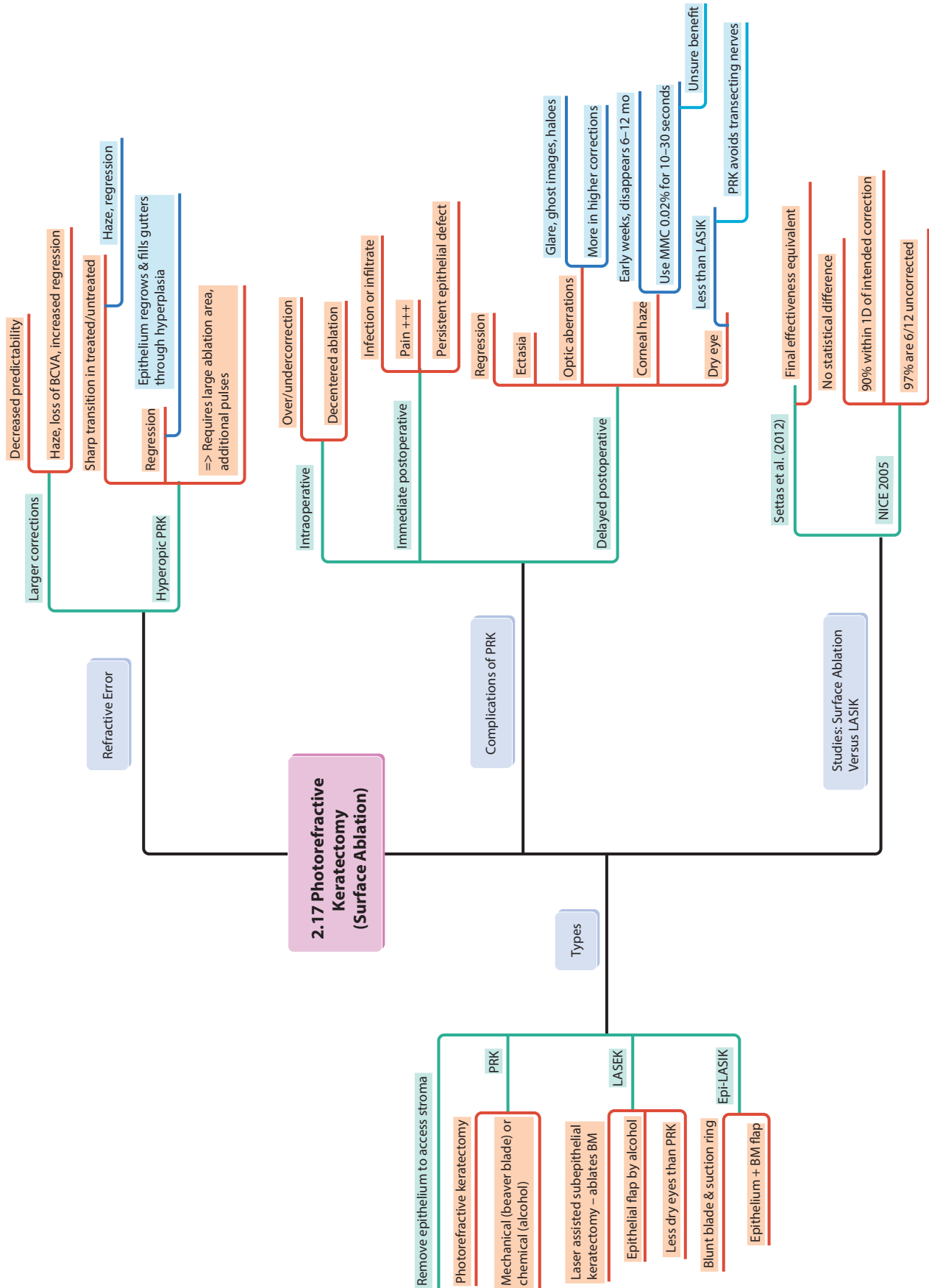


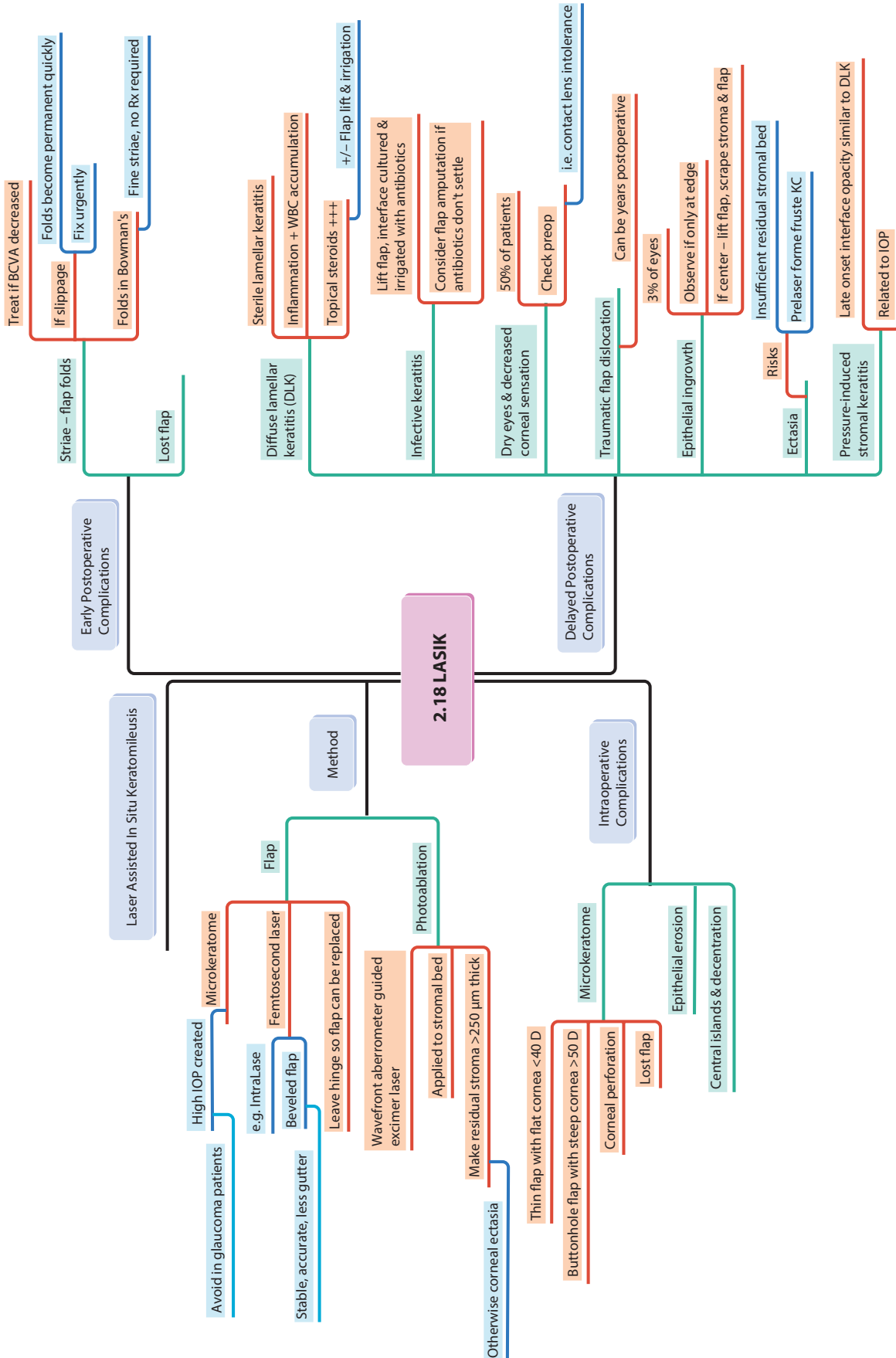


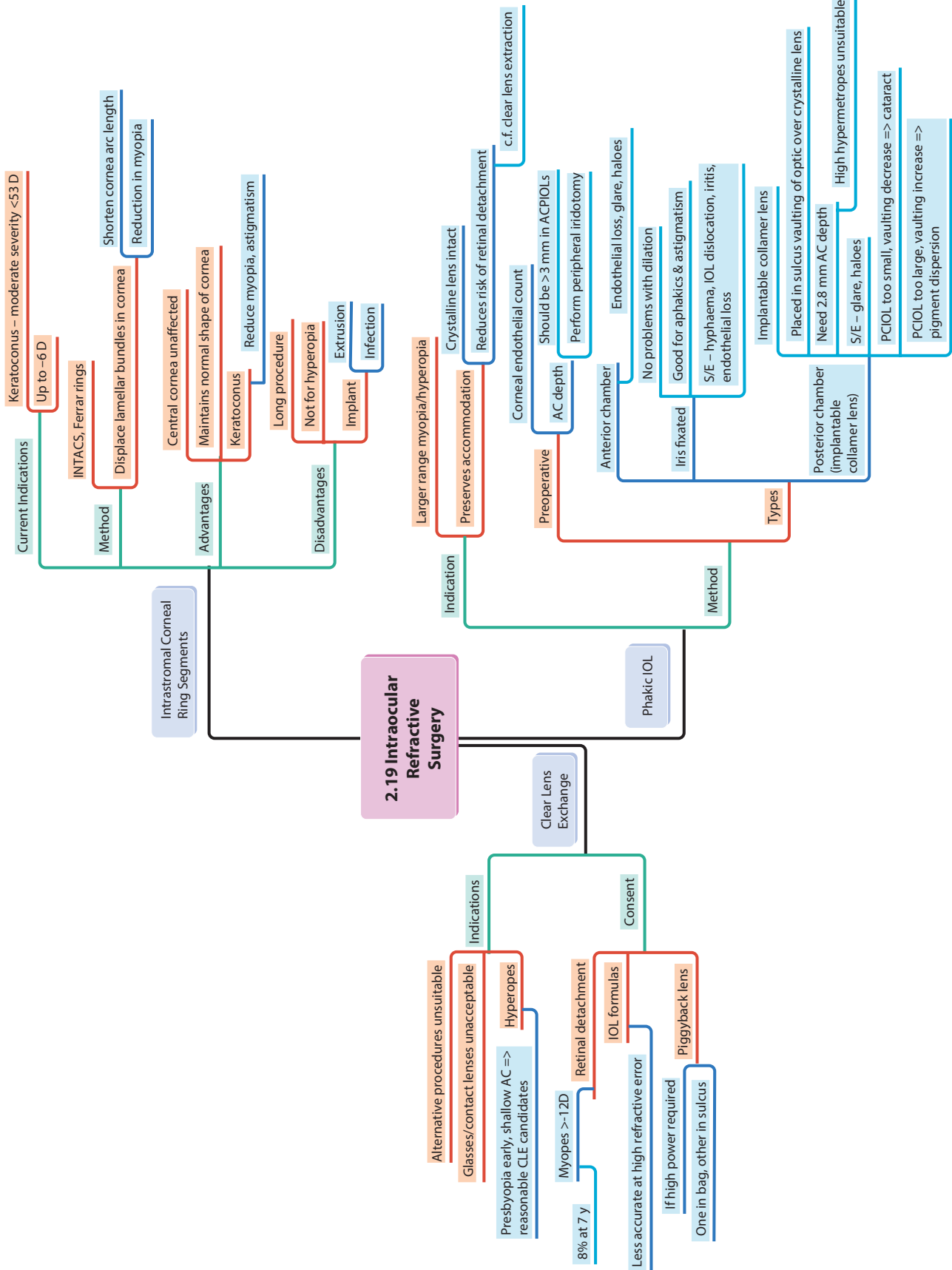


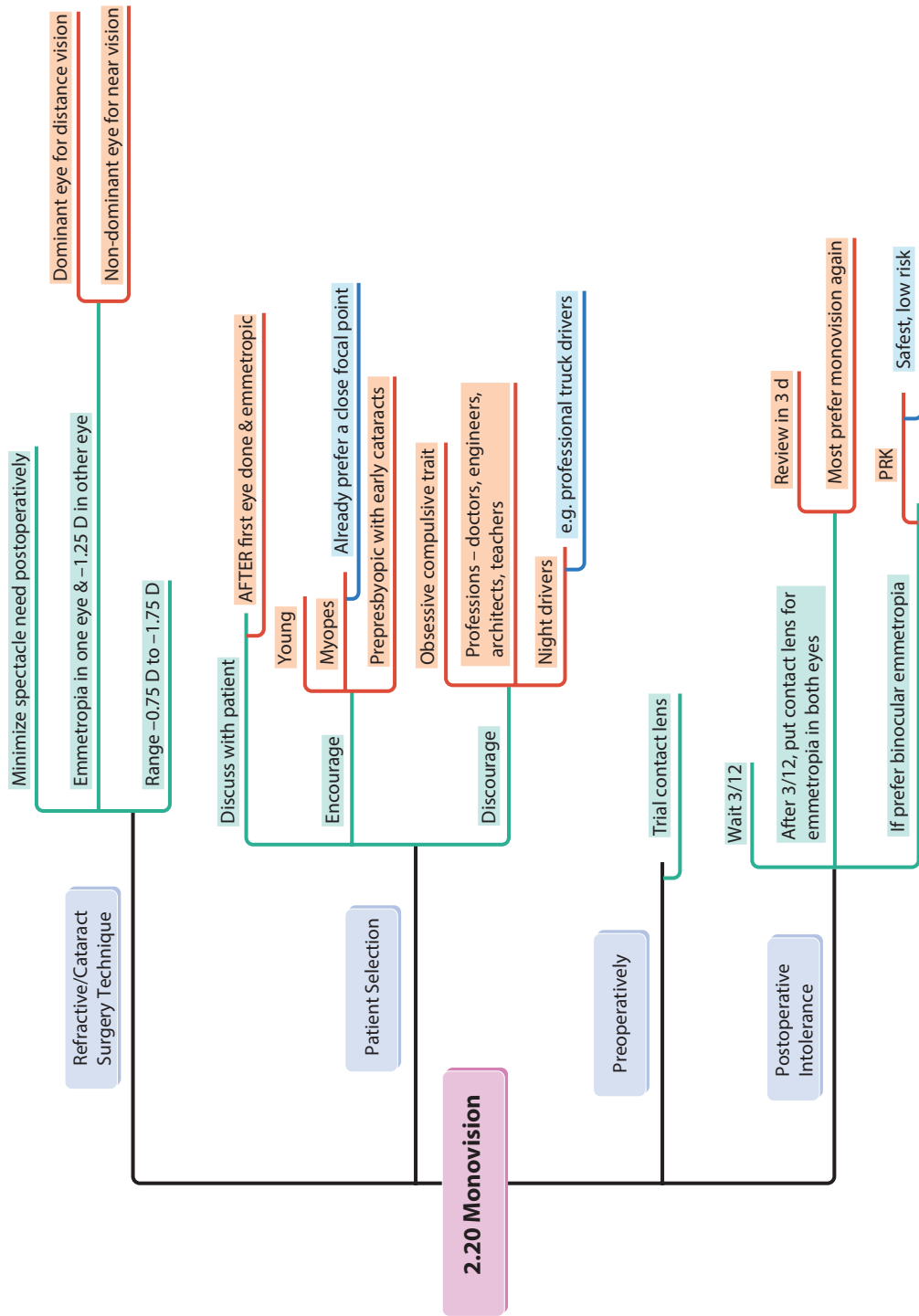


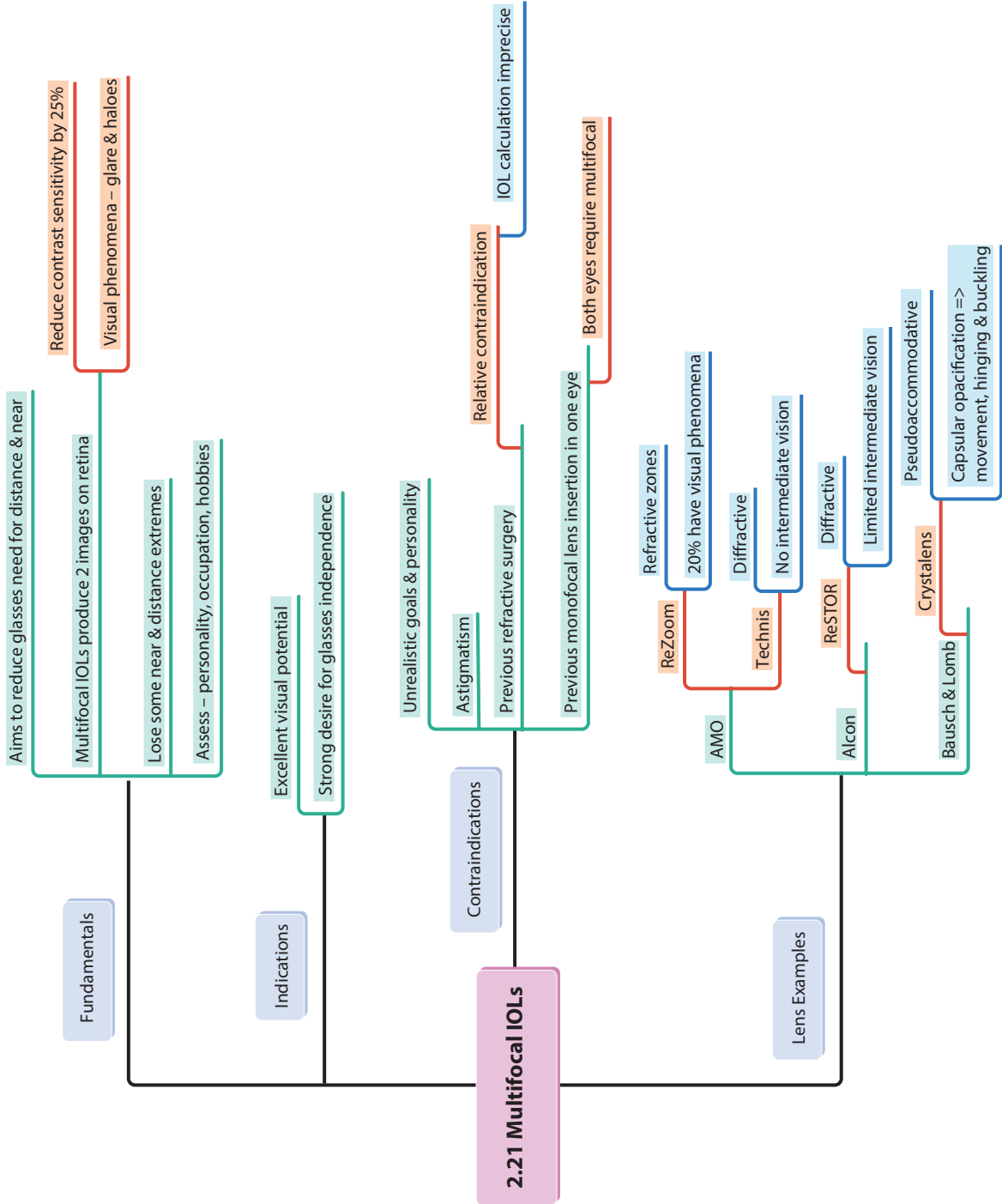




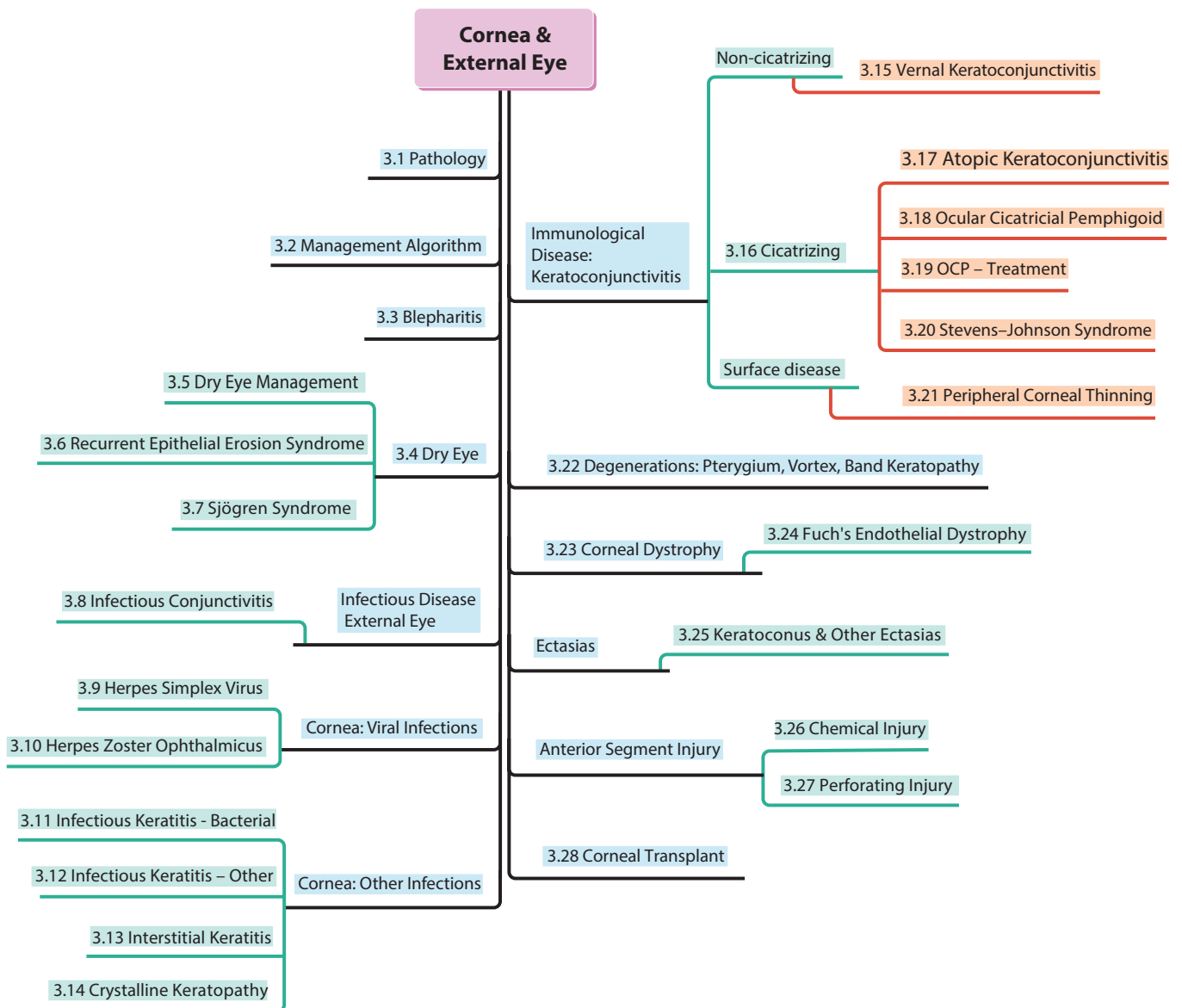


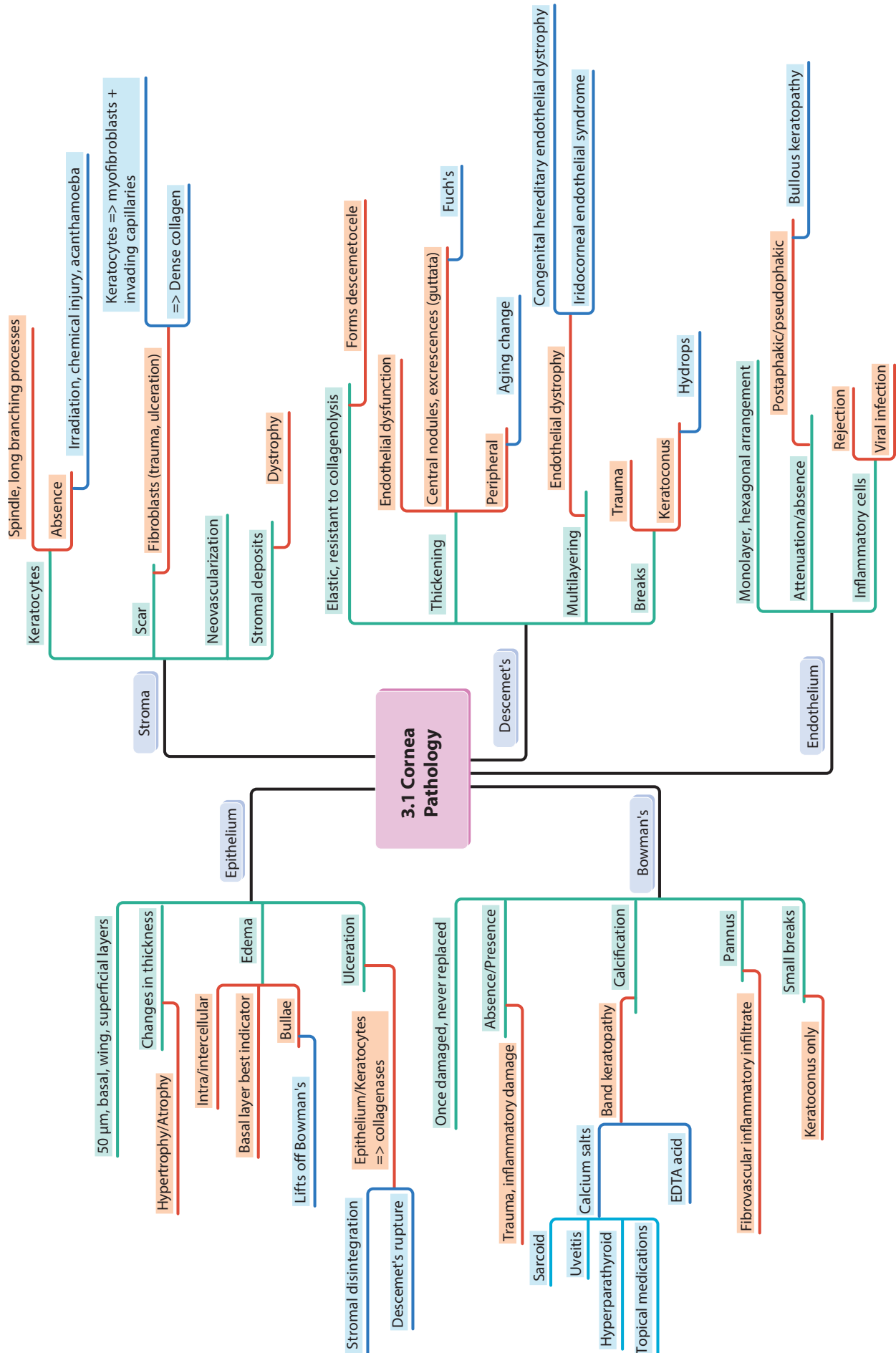


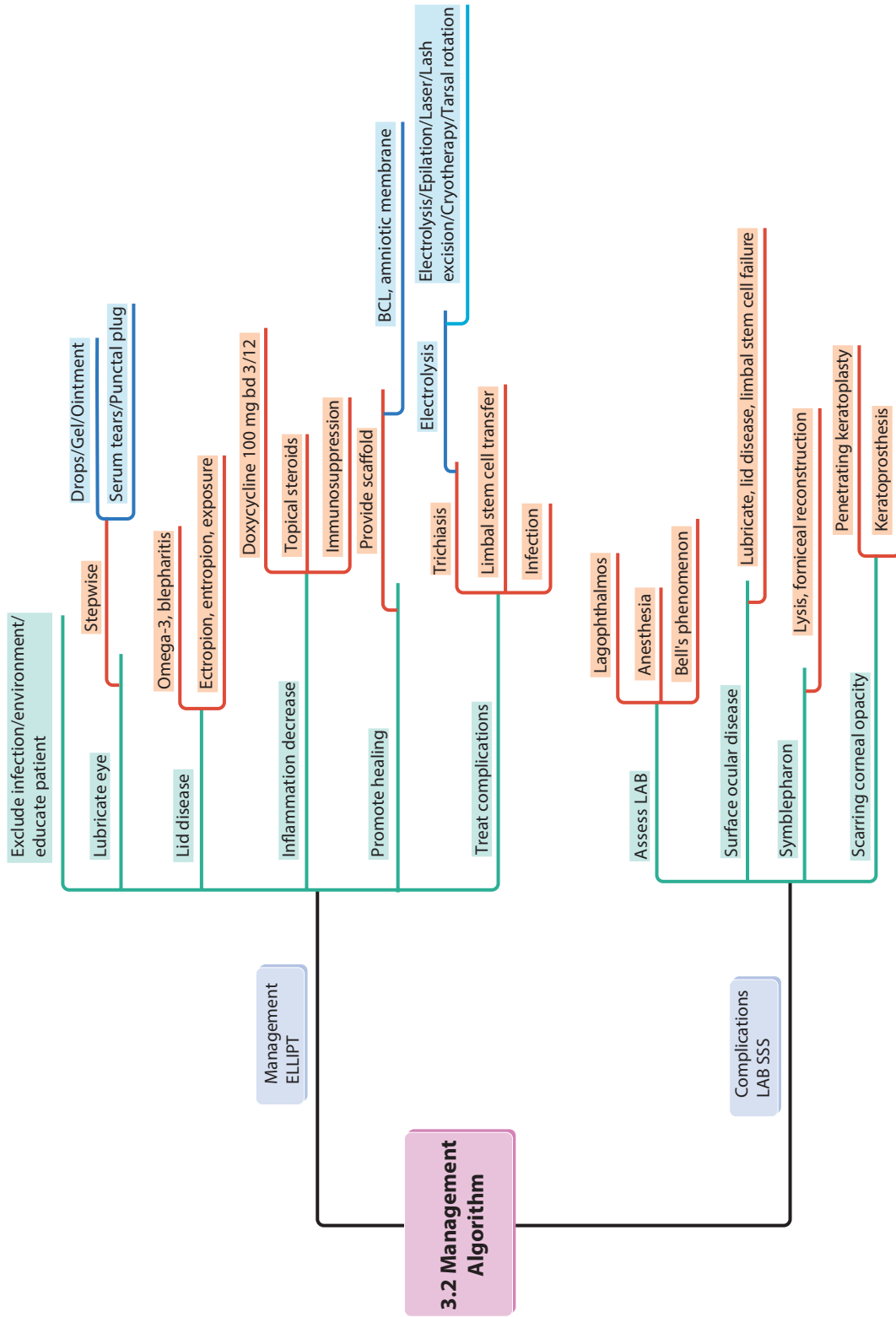


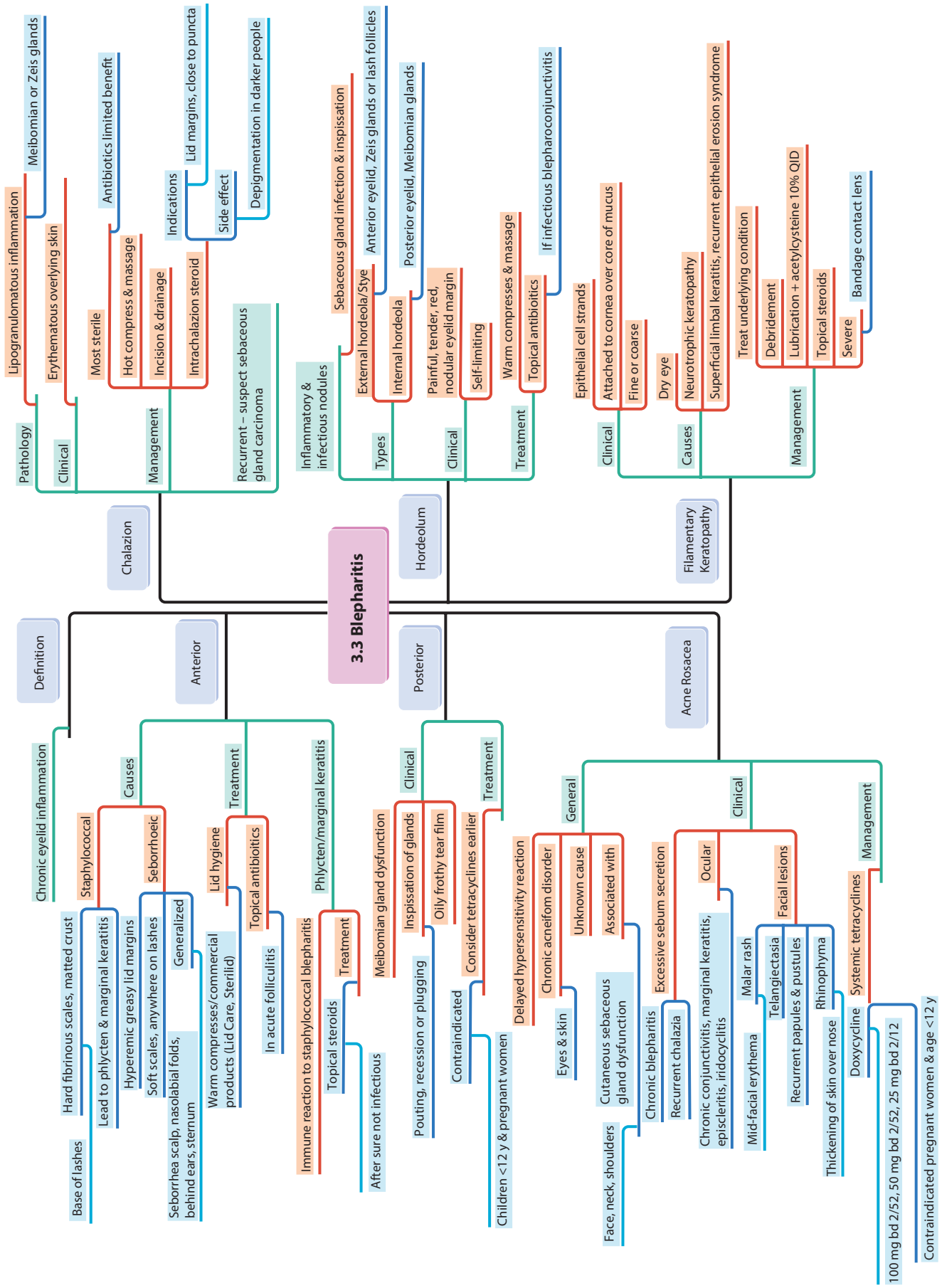


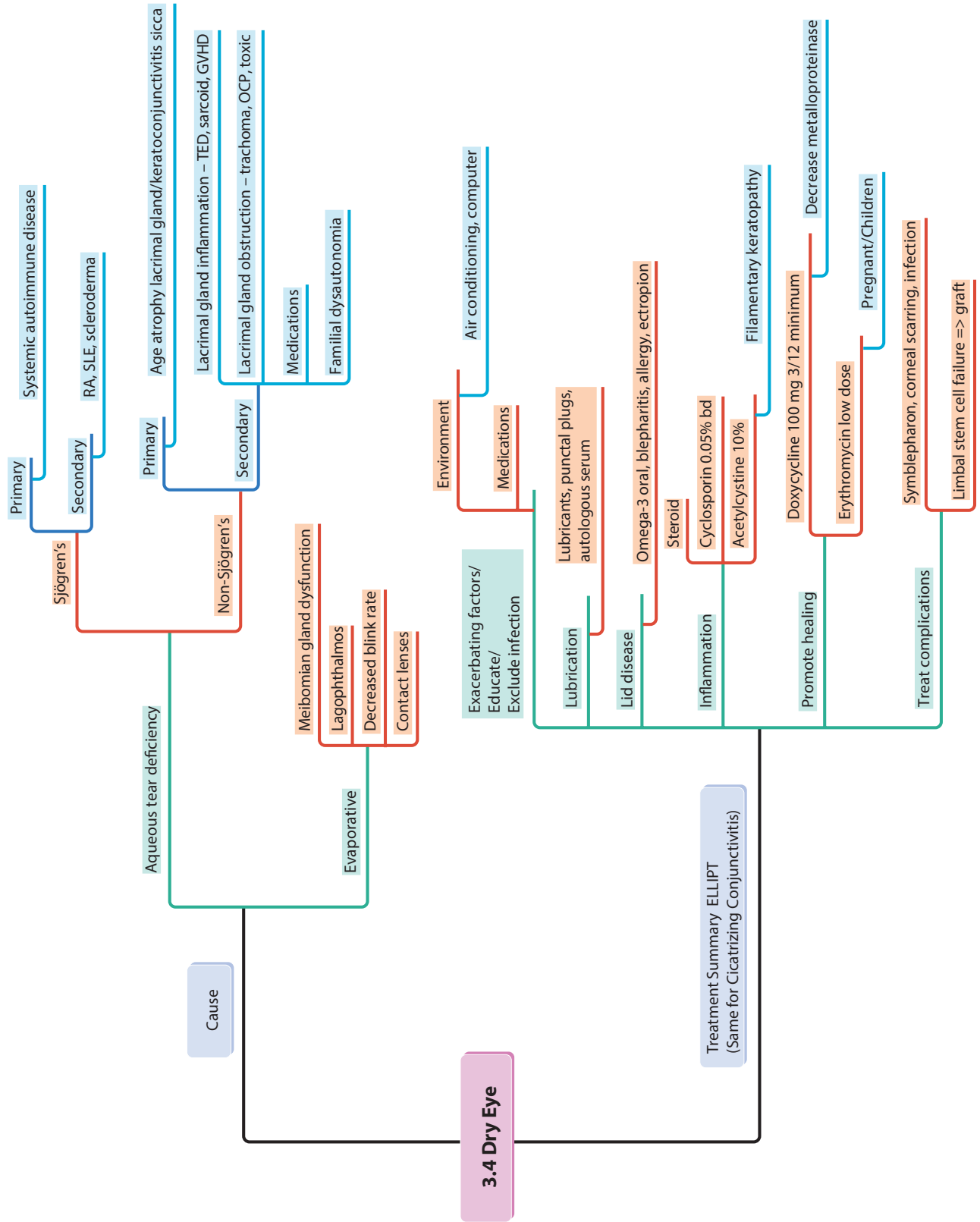
3 Cornea and External Eye

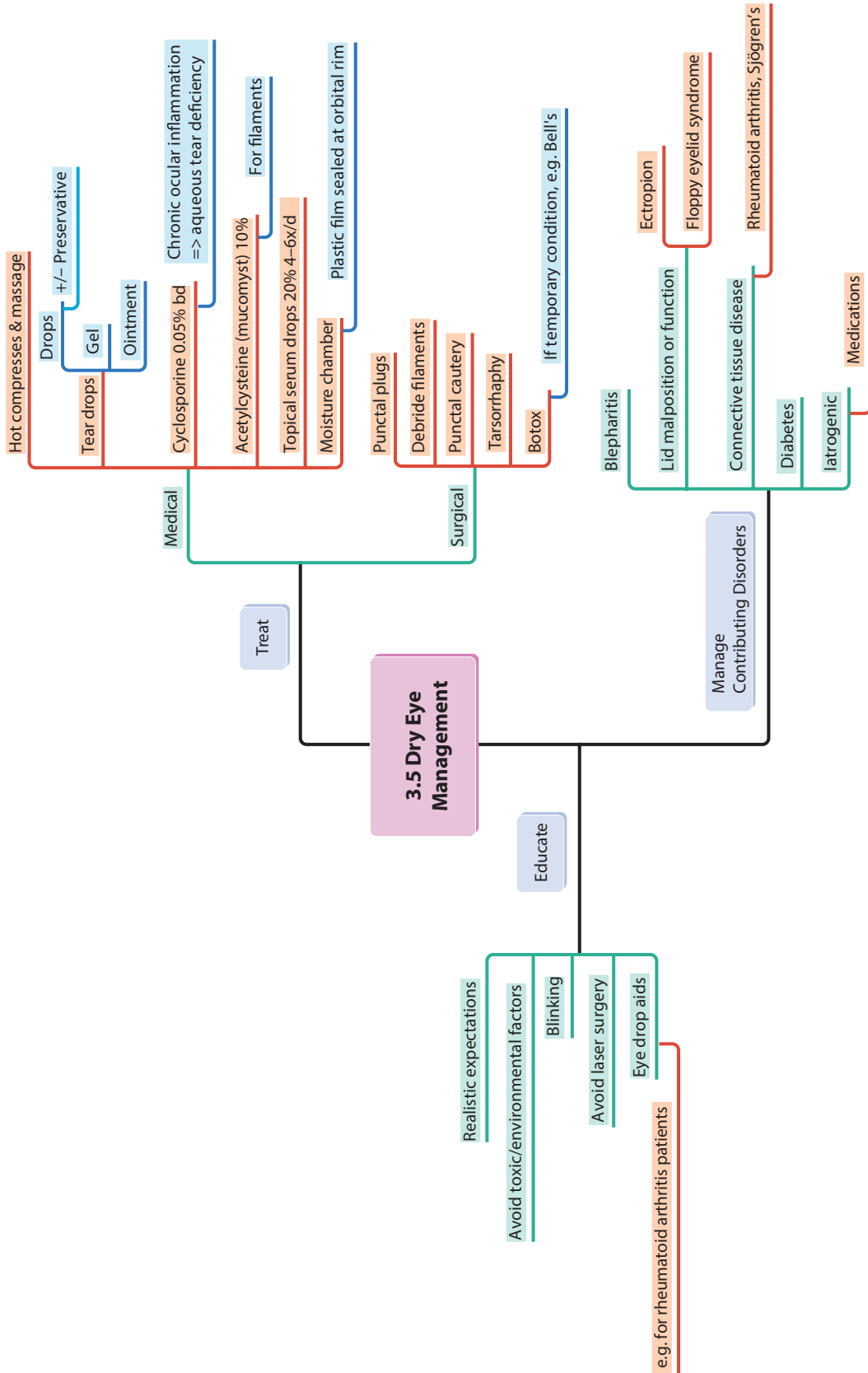


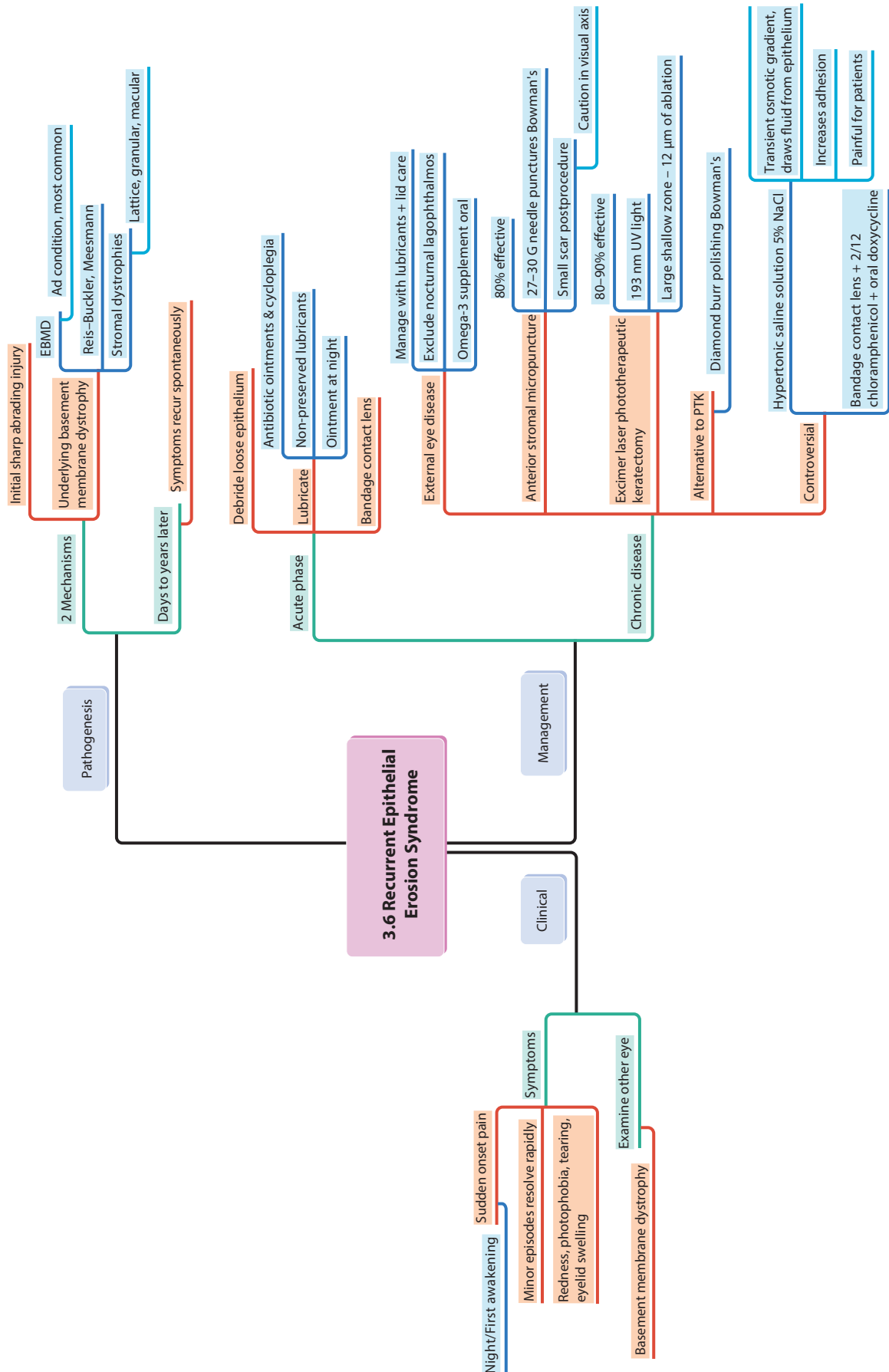


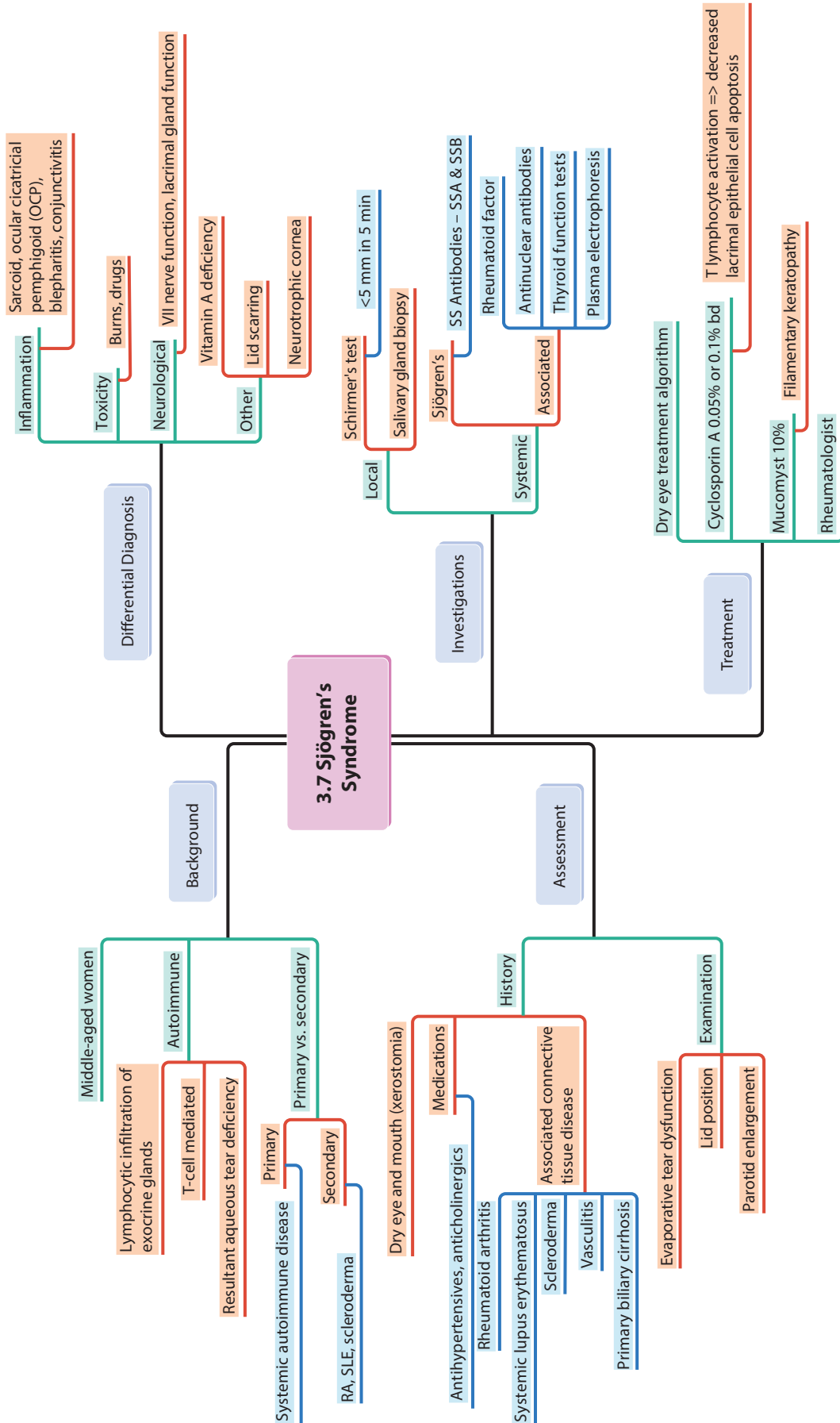


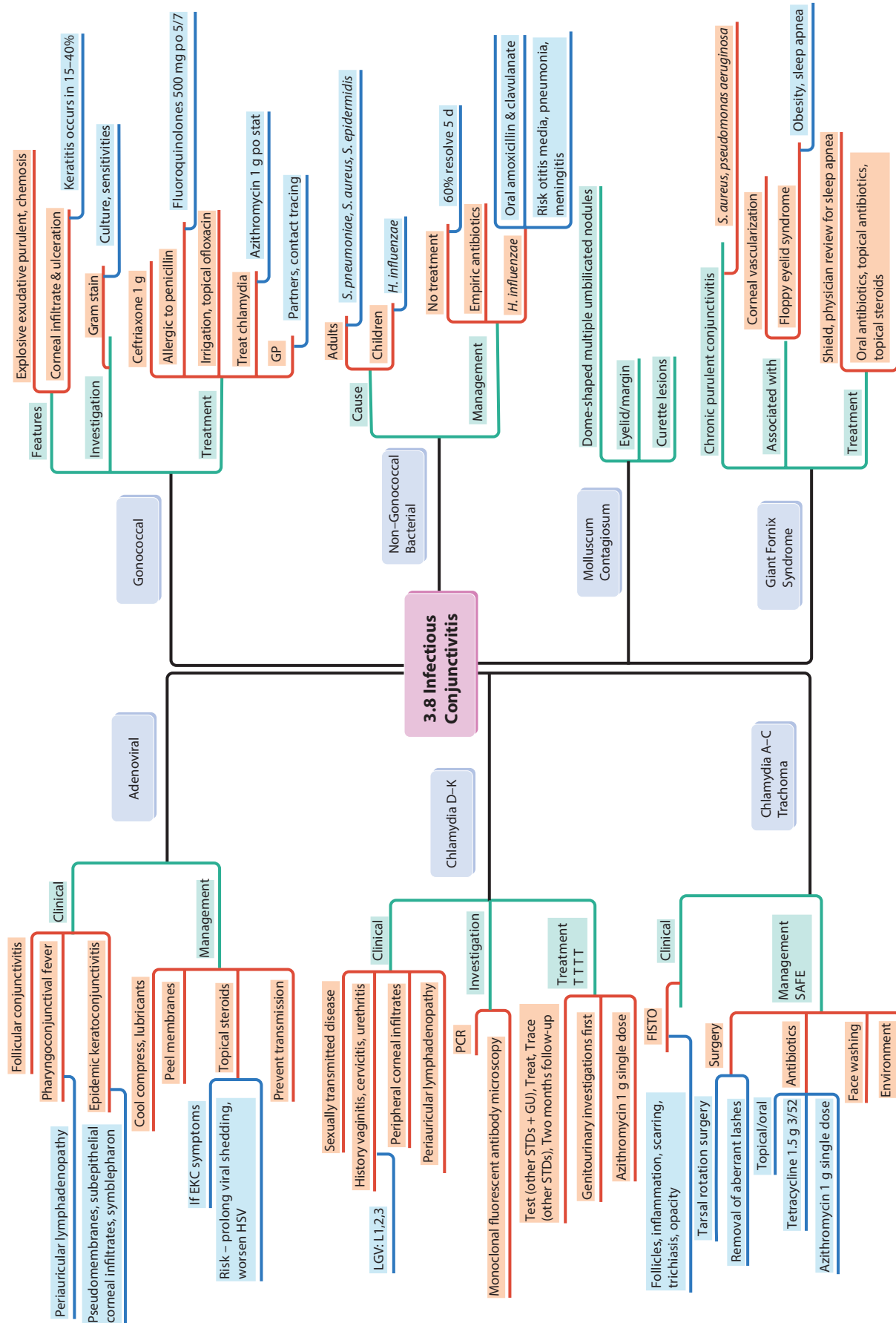


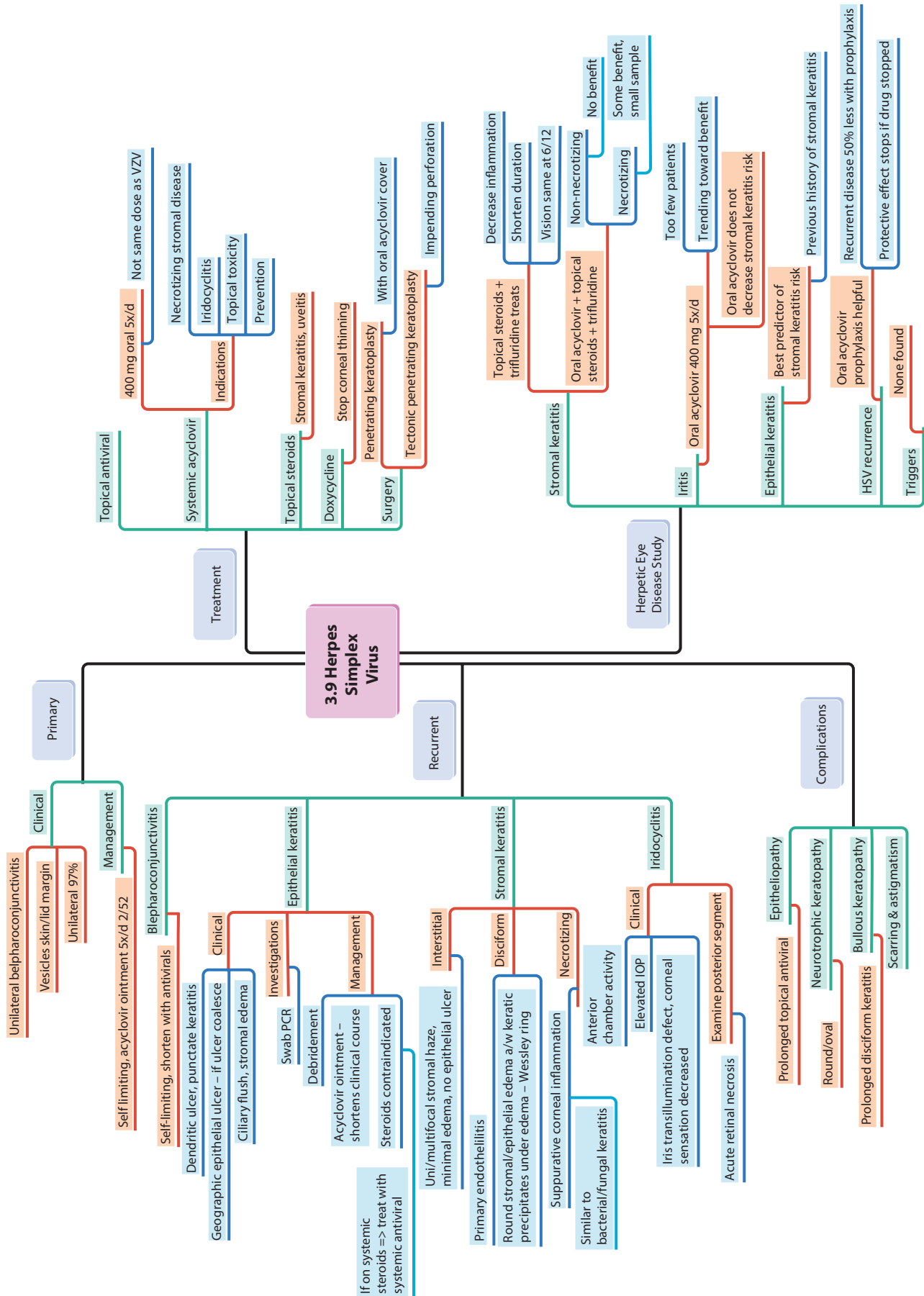


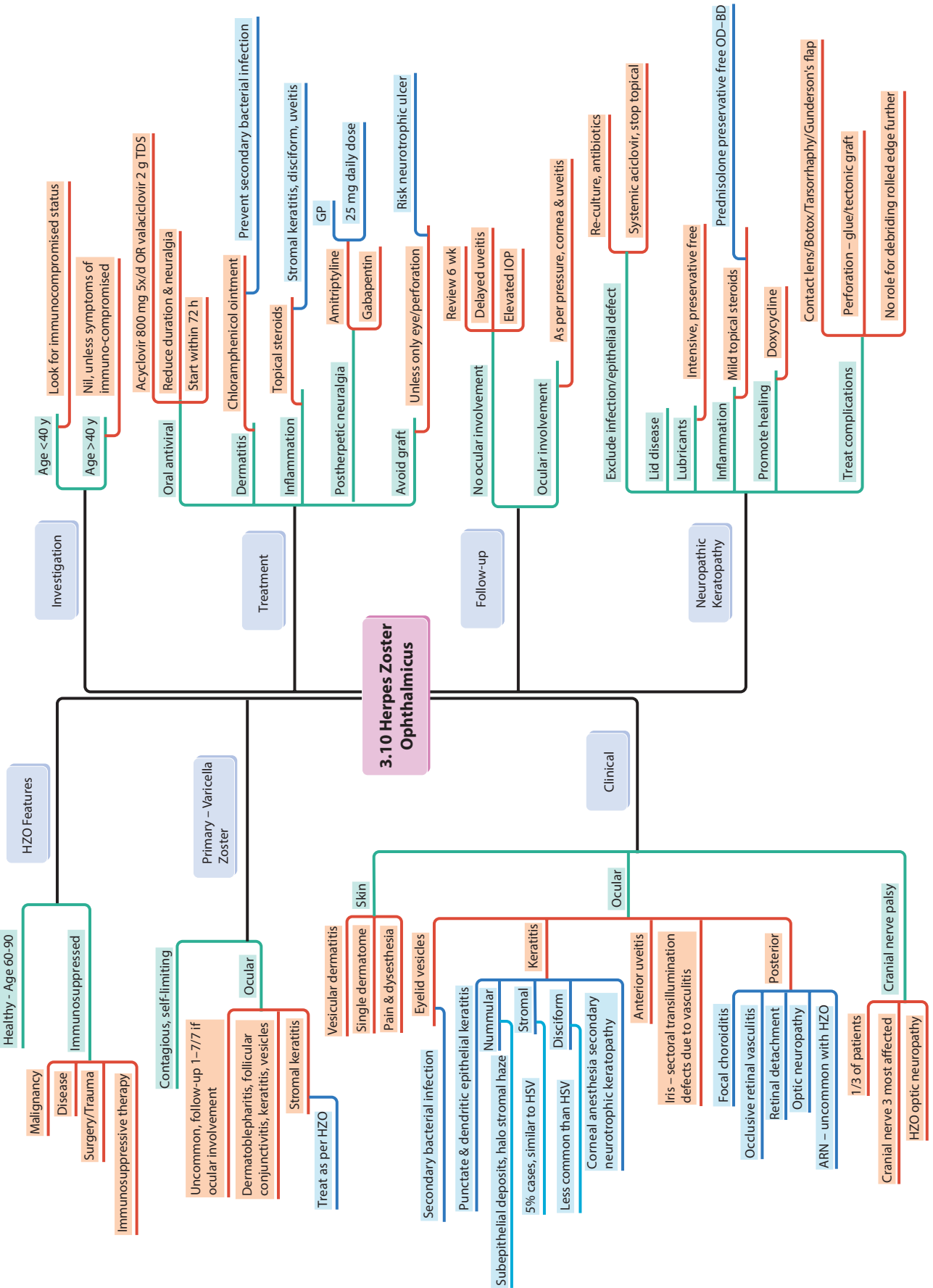


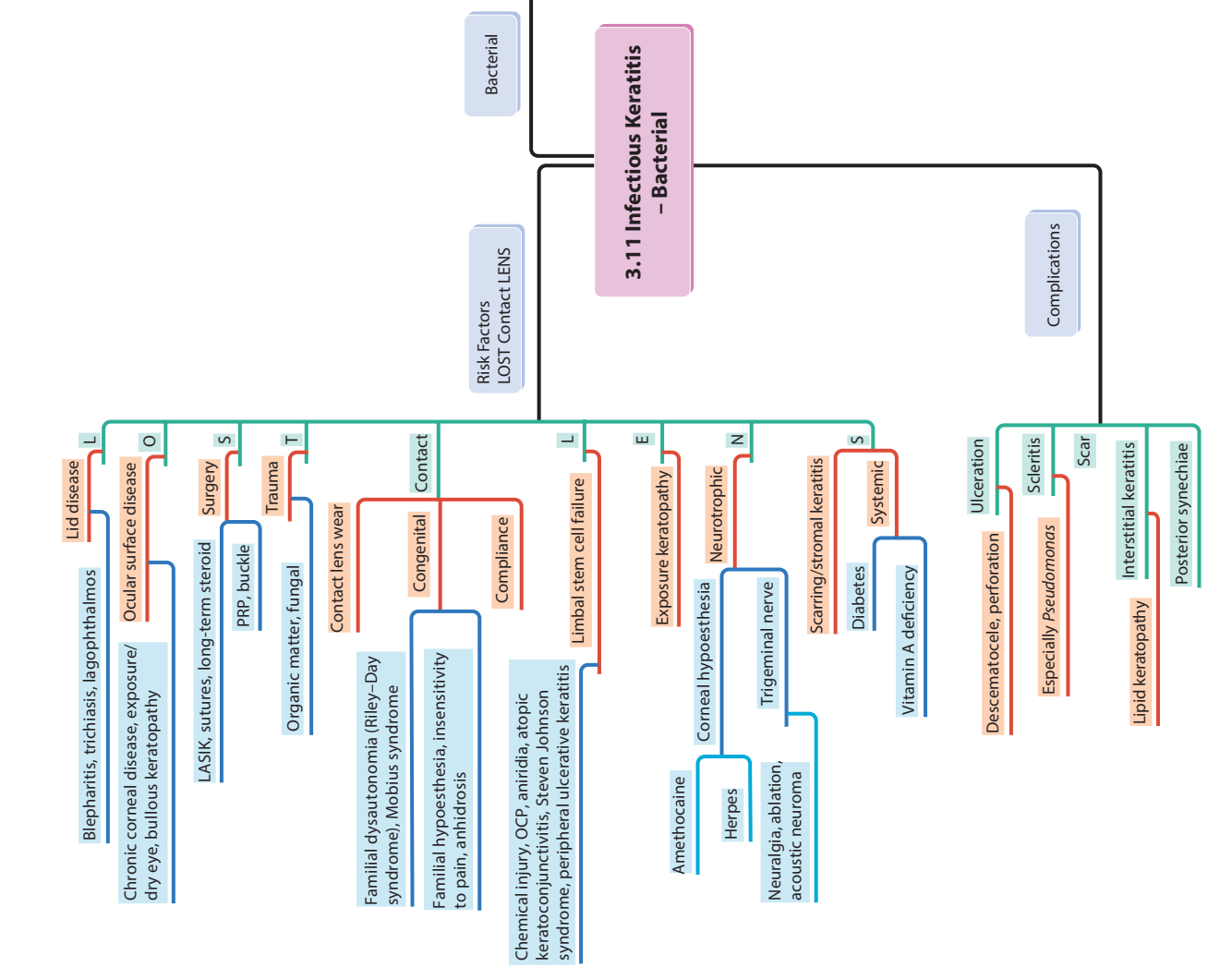
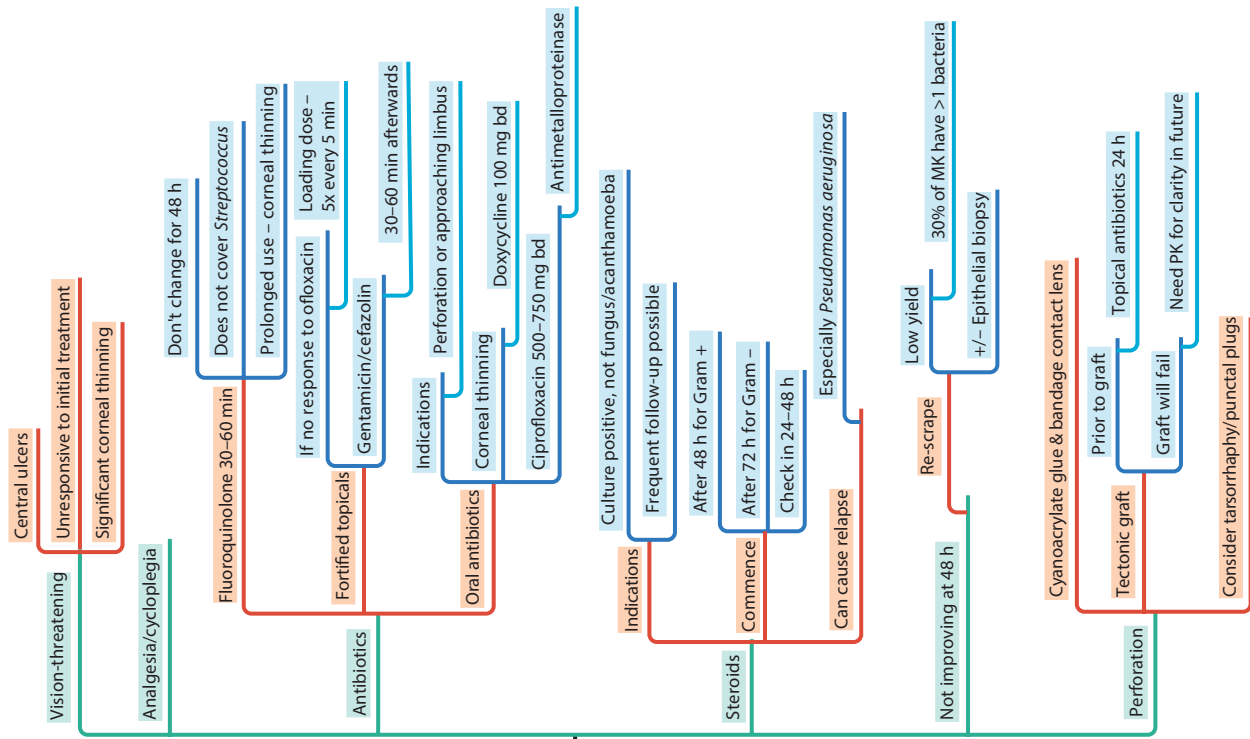


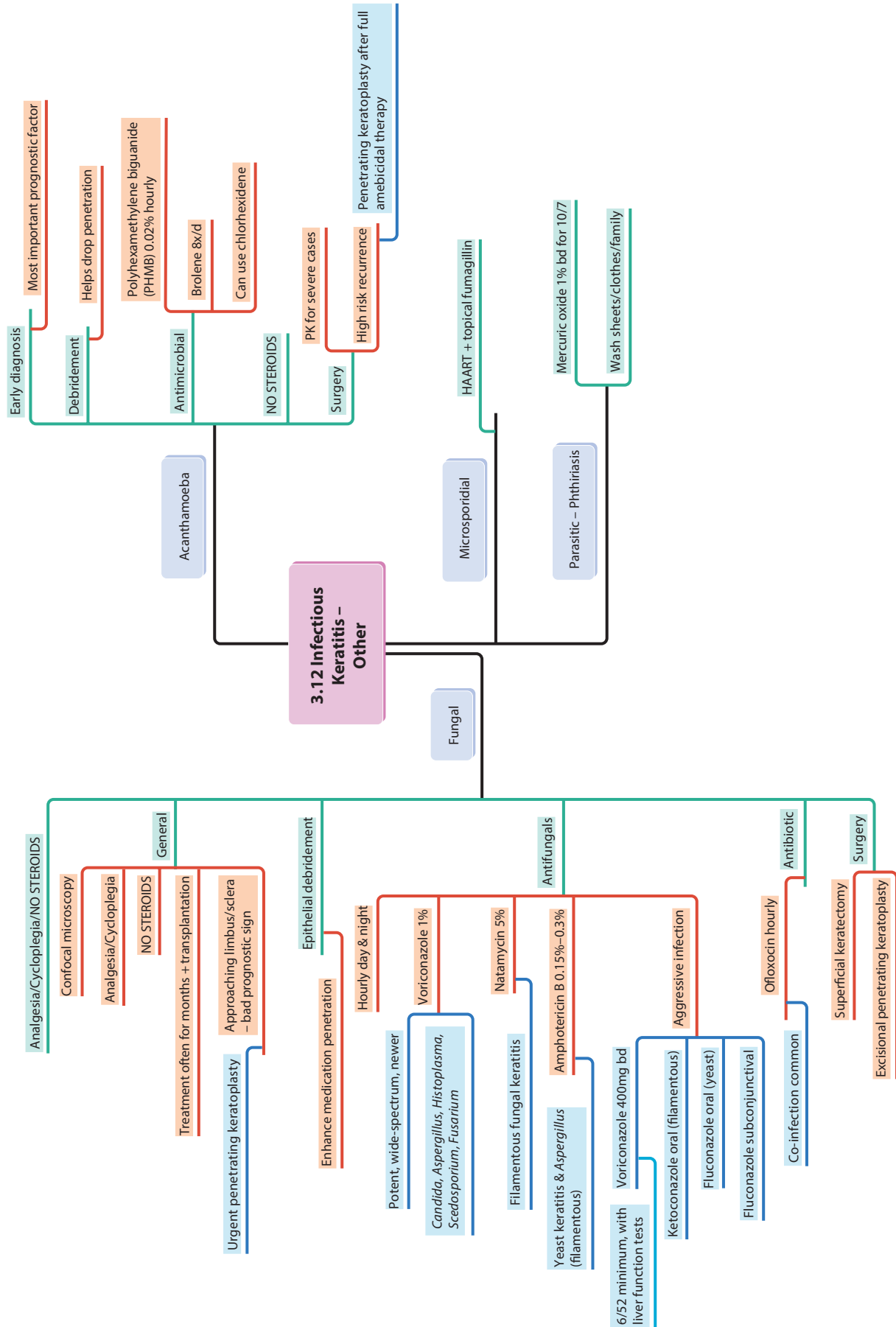


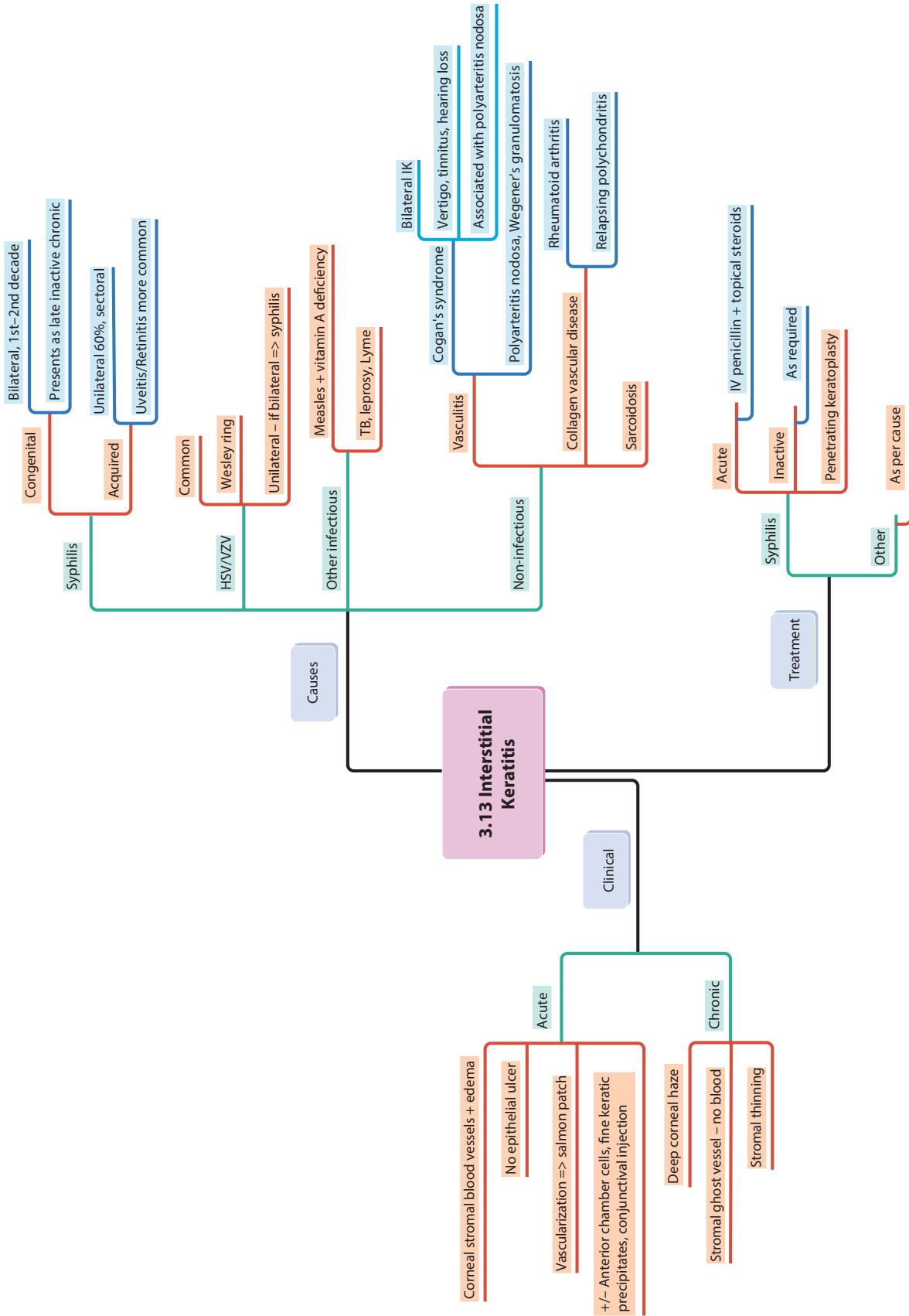


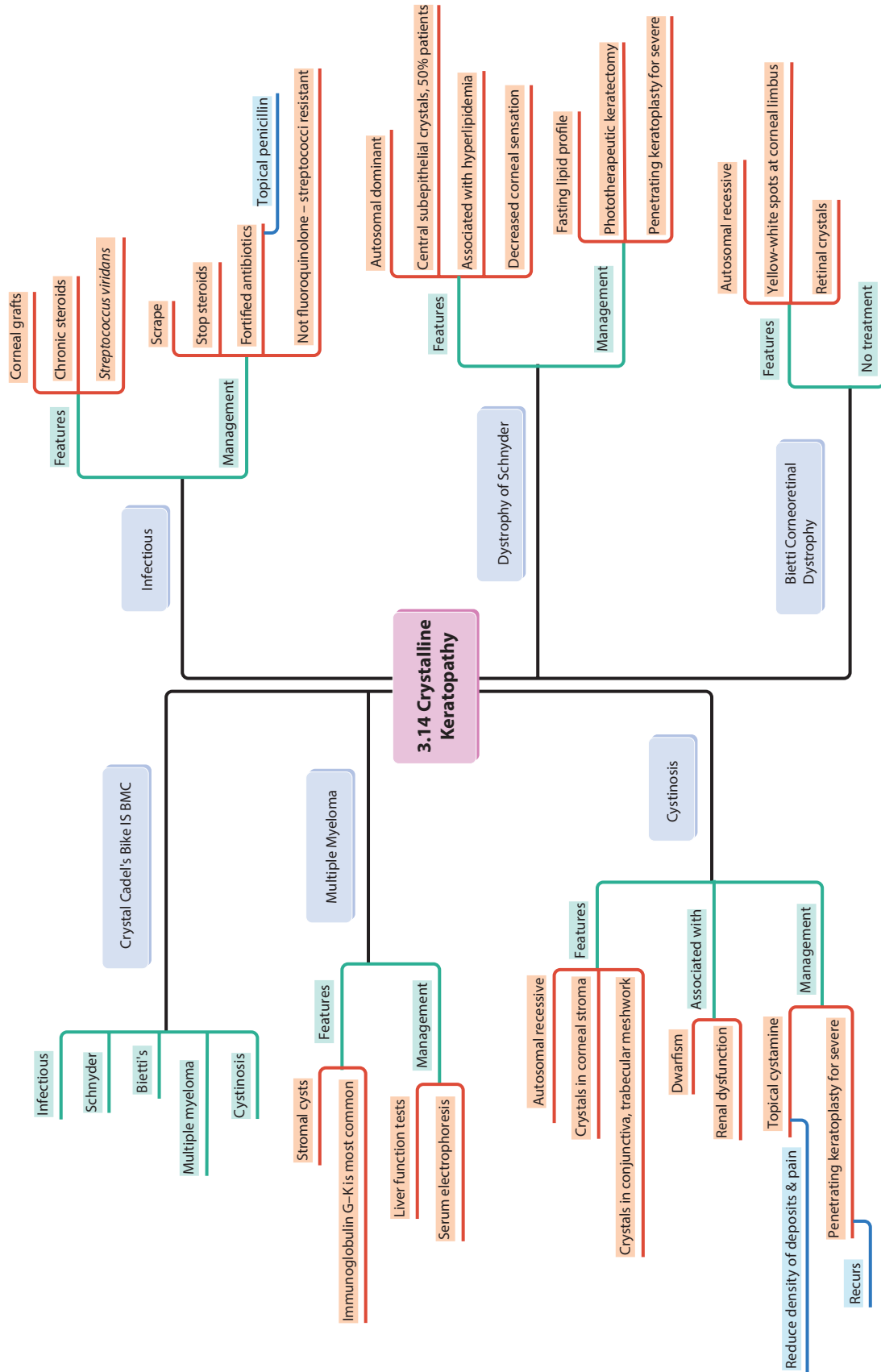


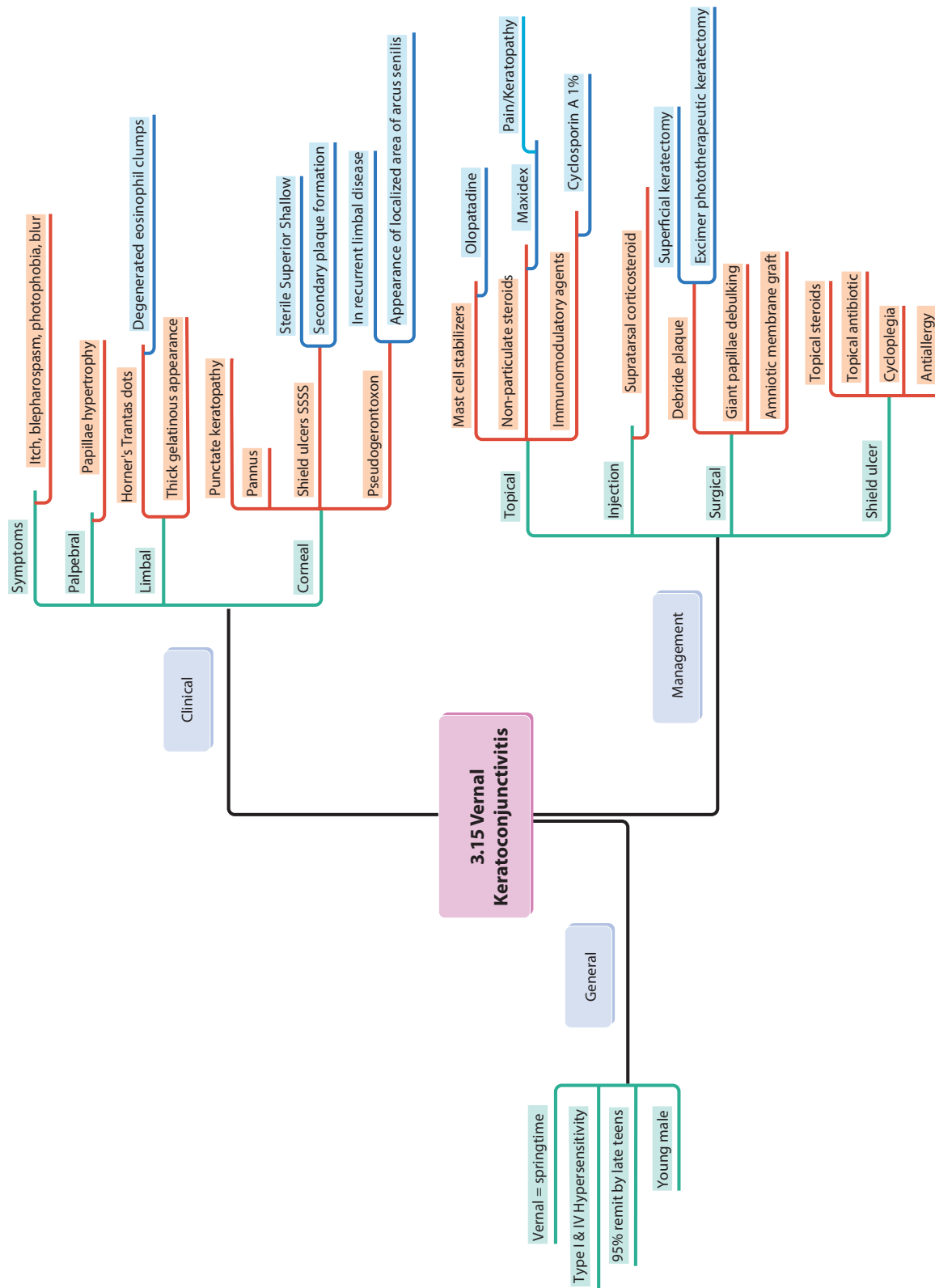


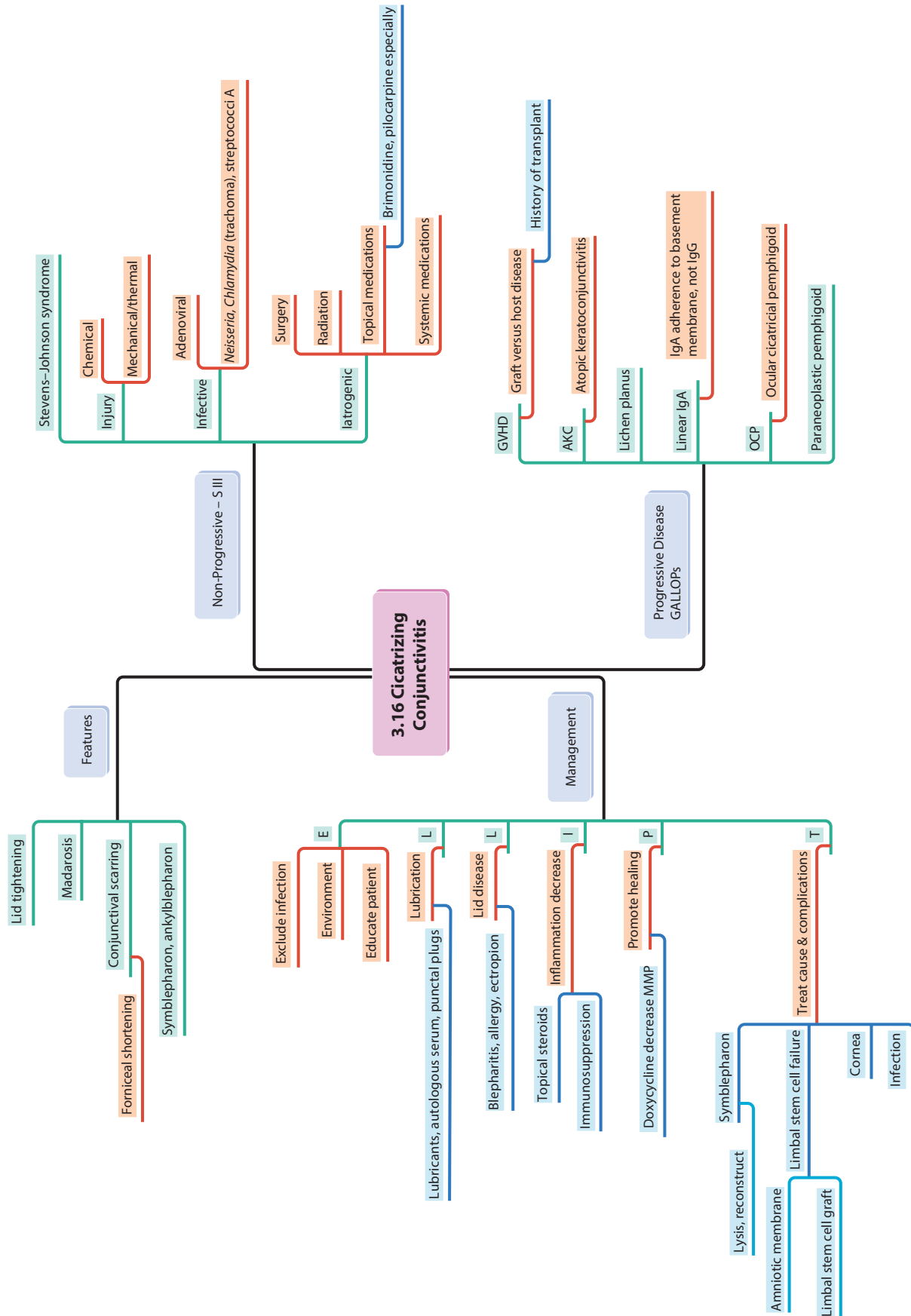


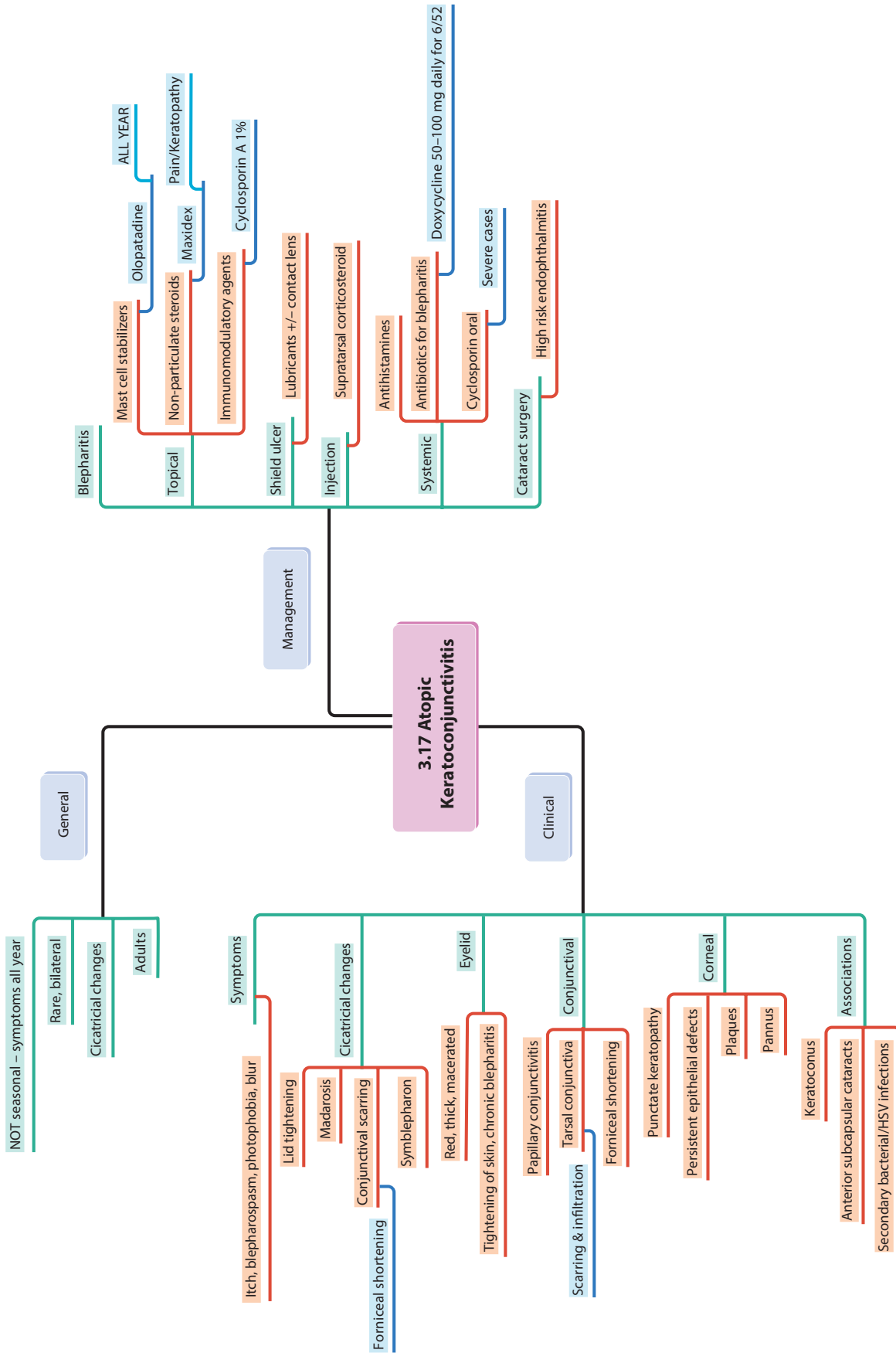


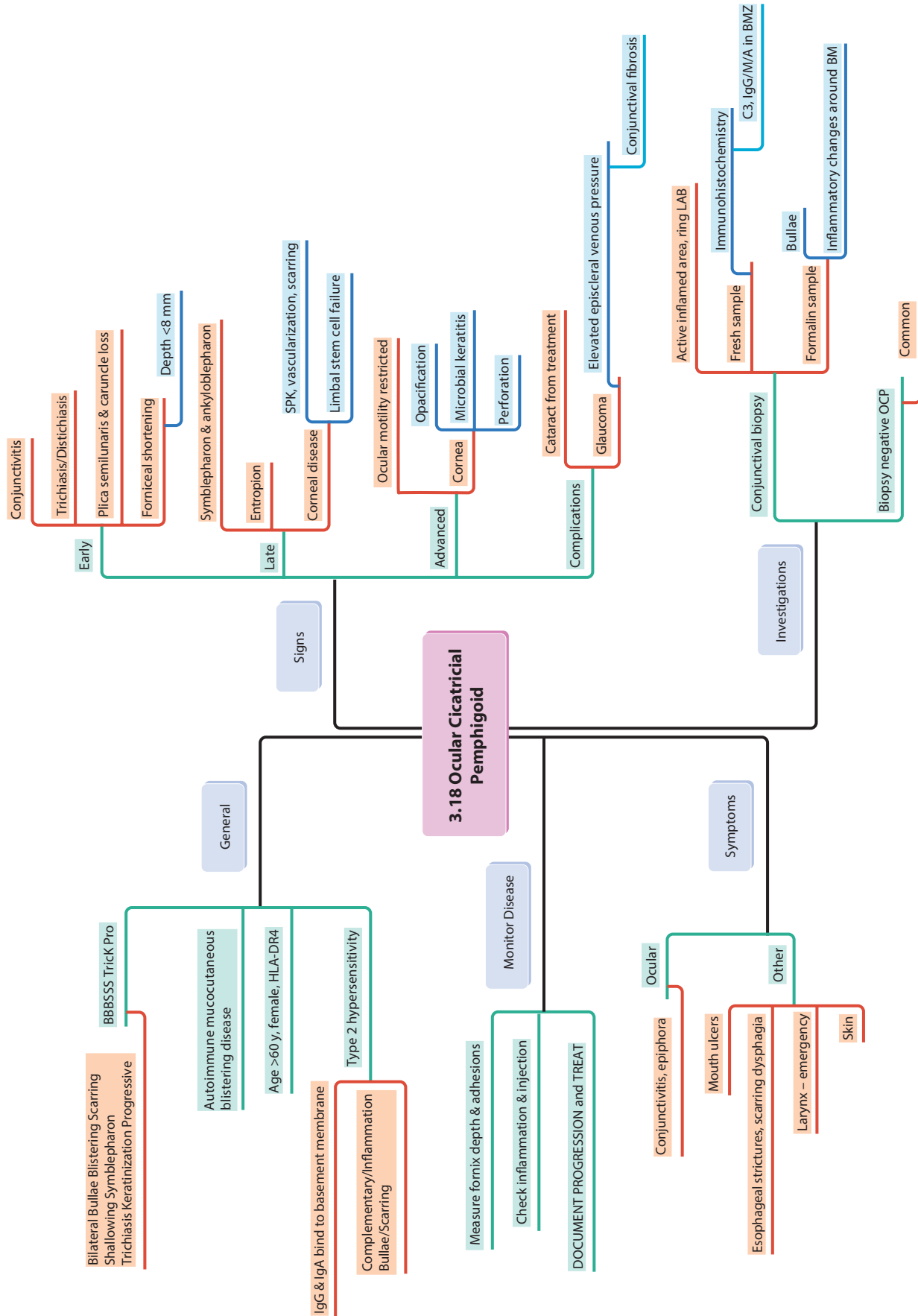


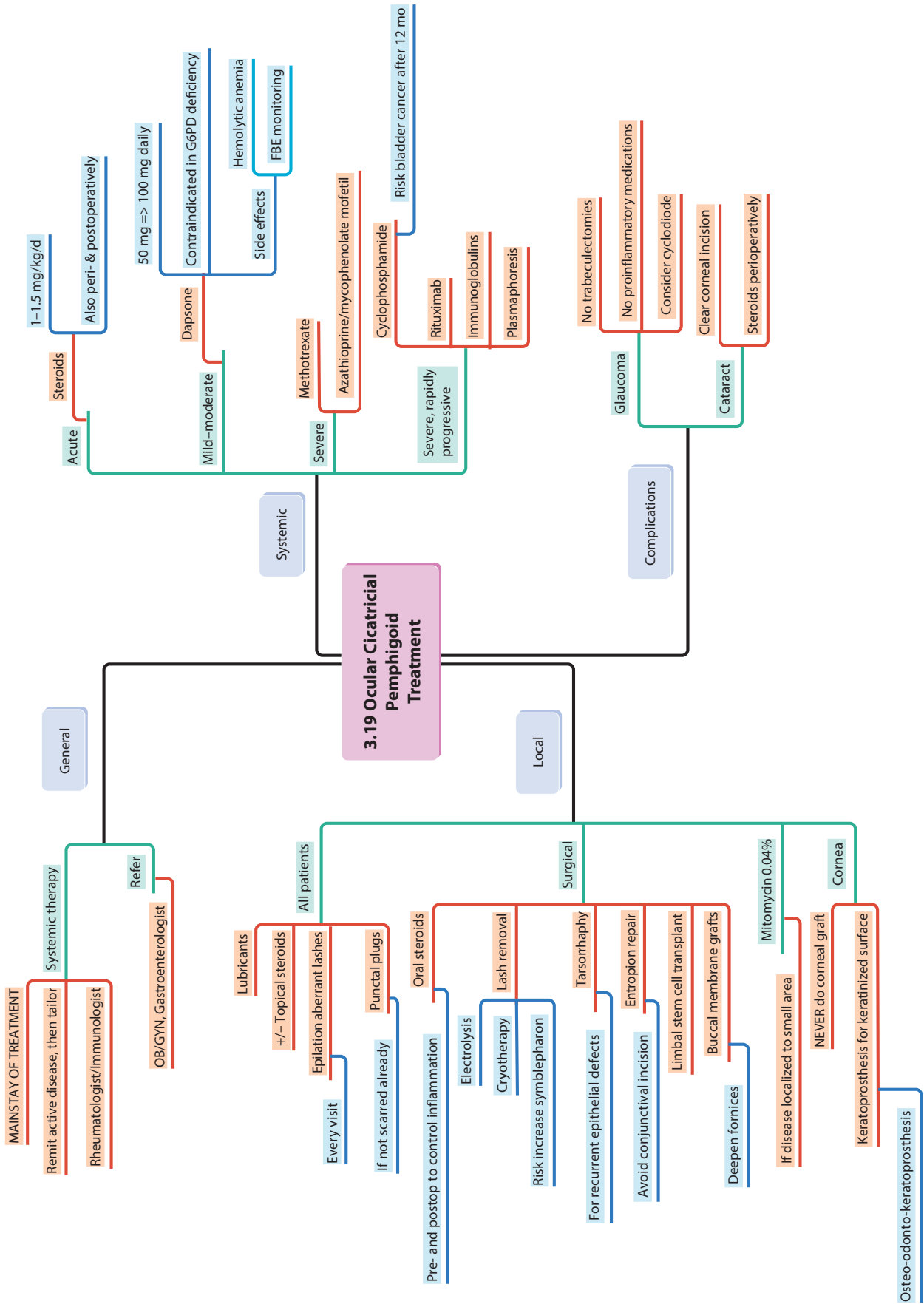


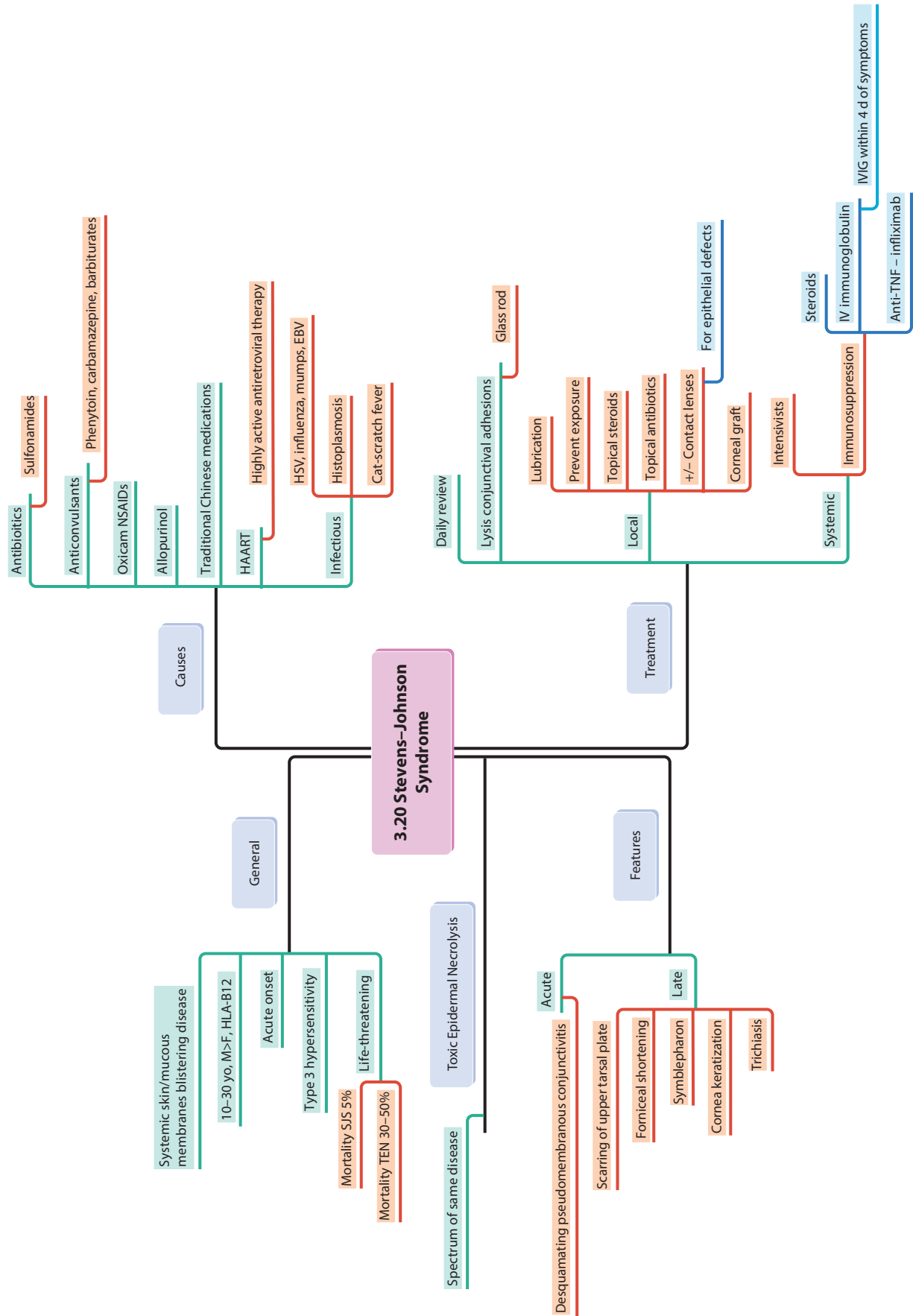


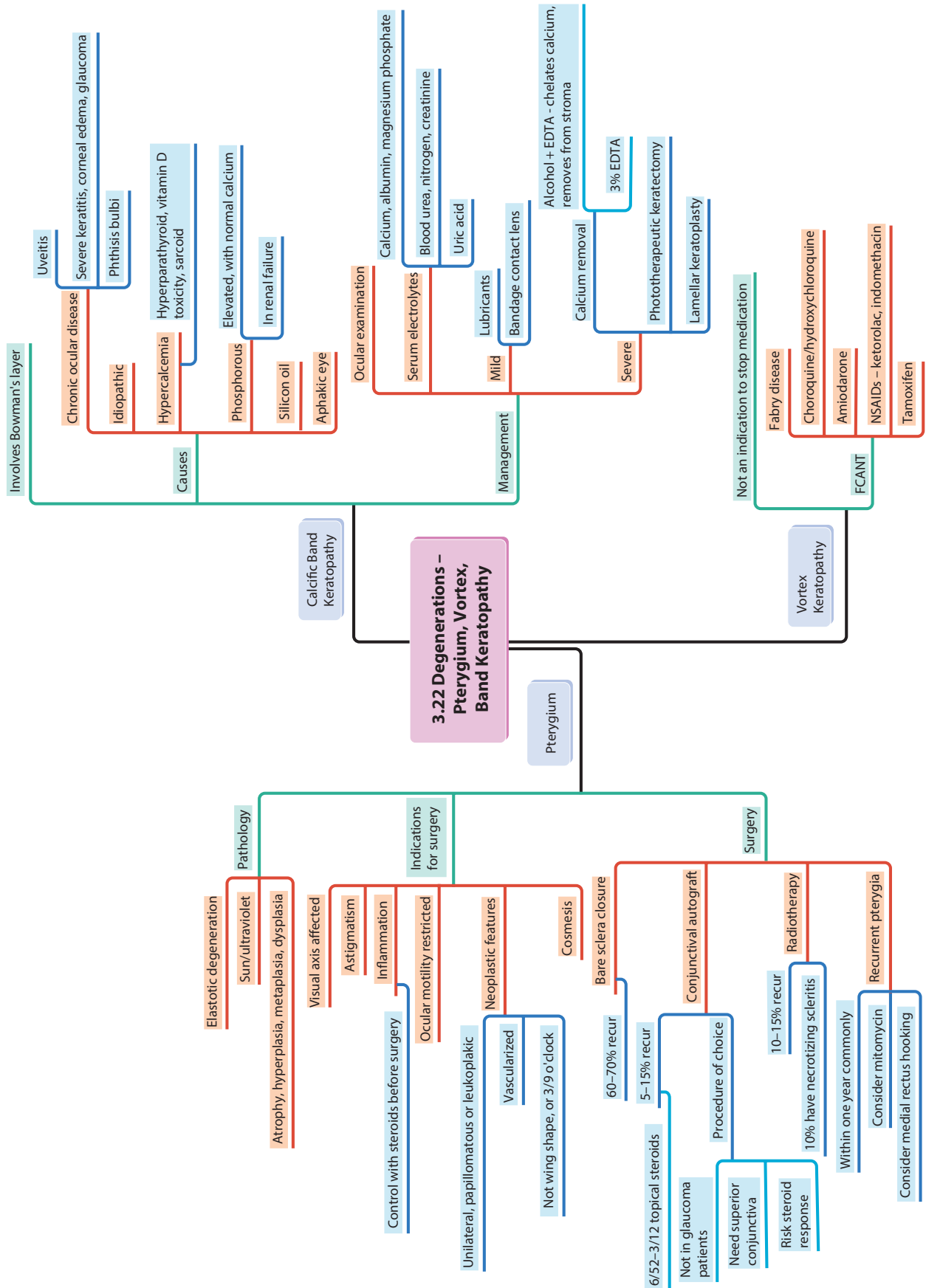


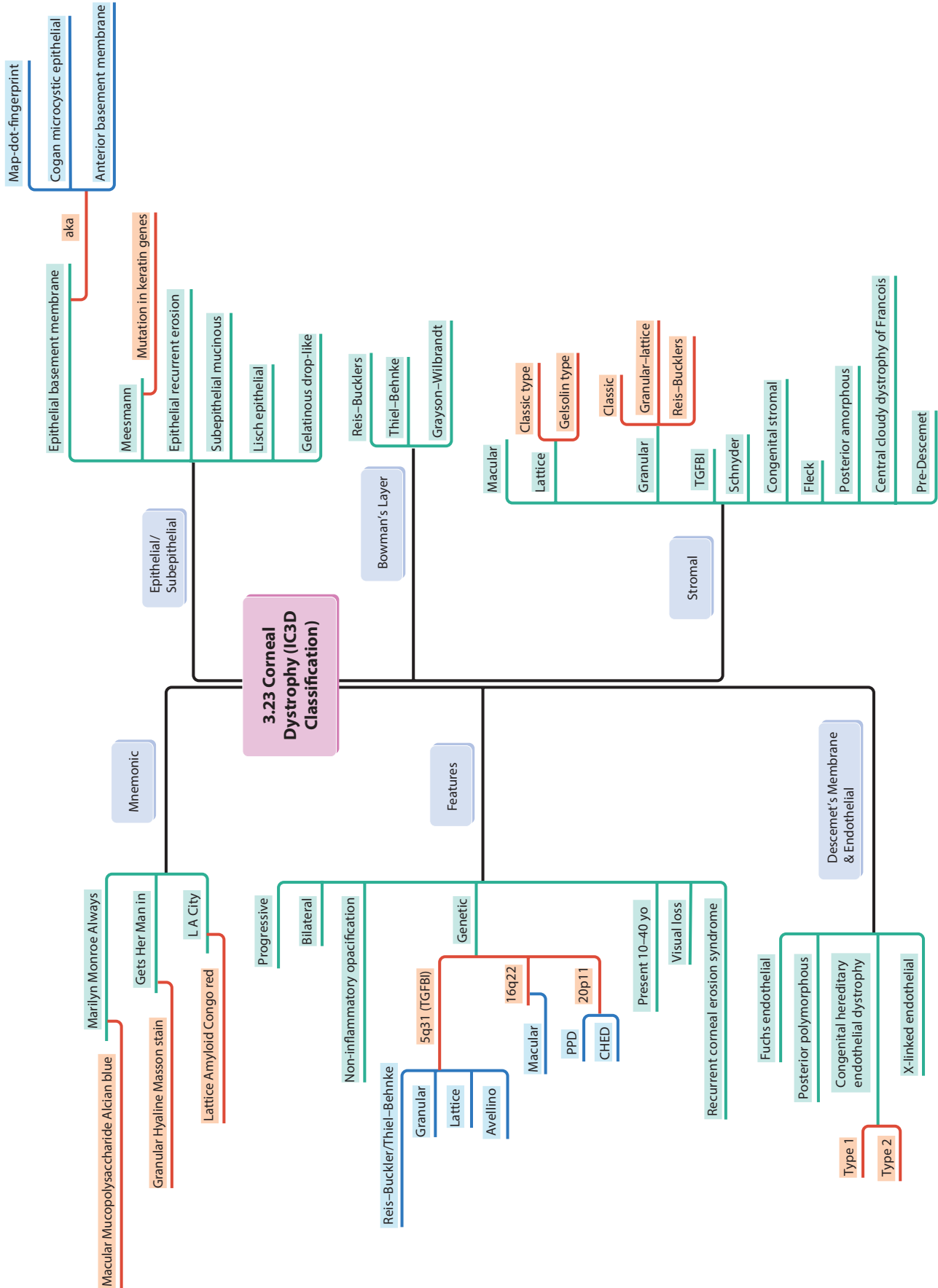


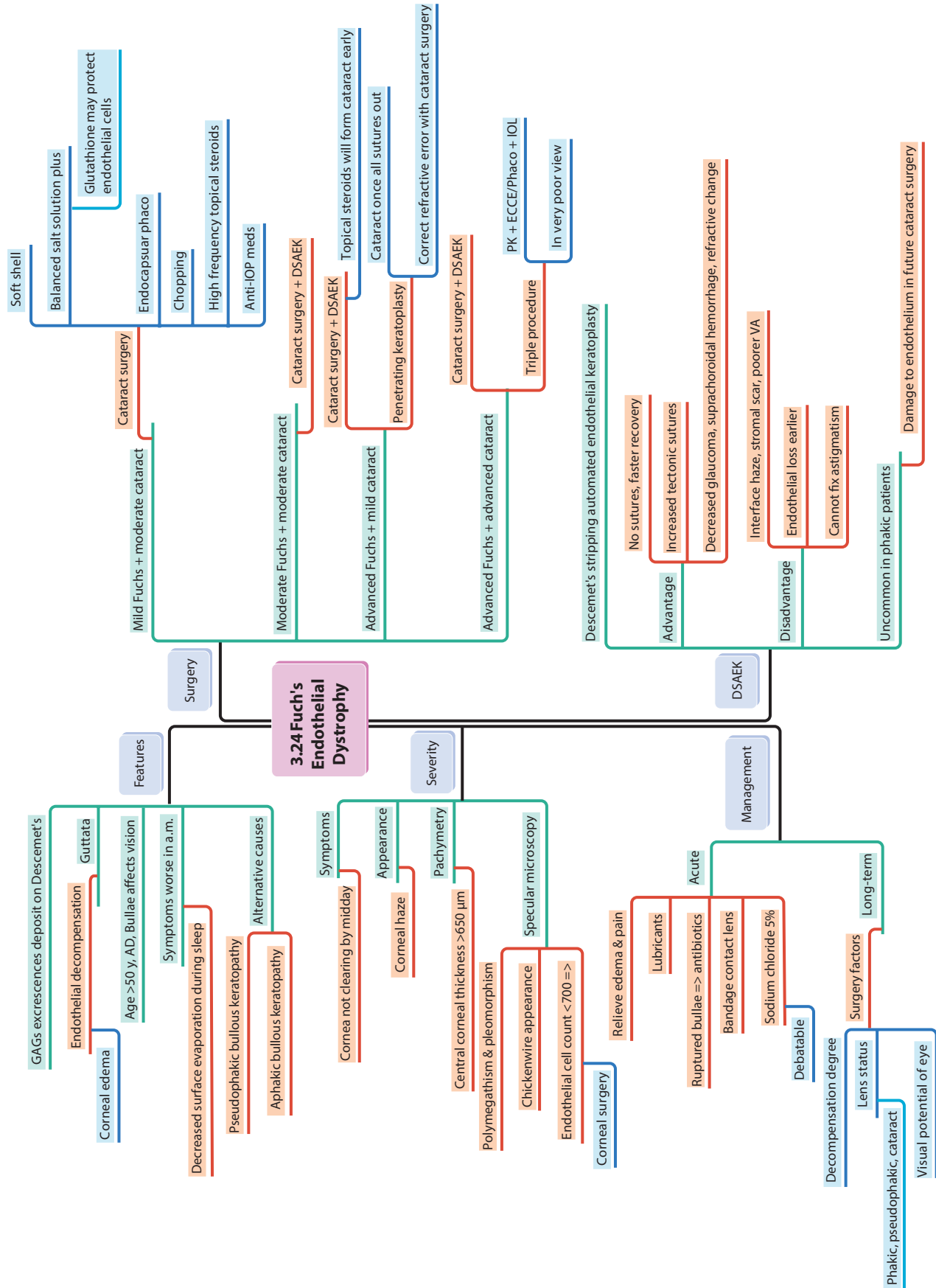


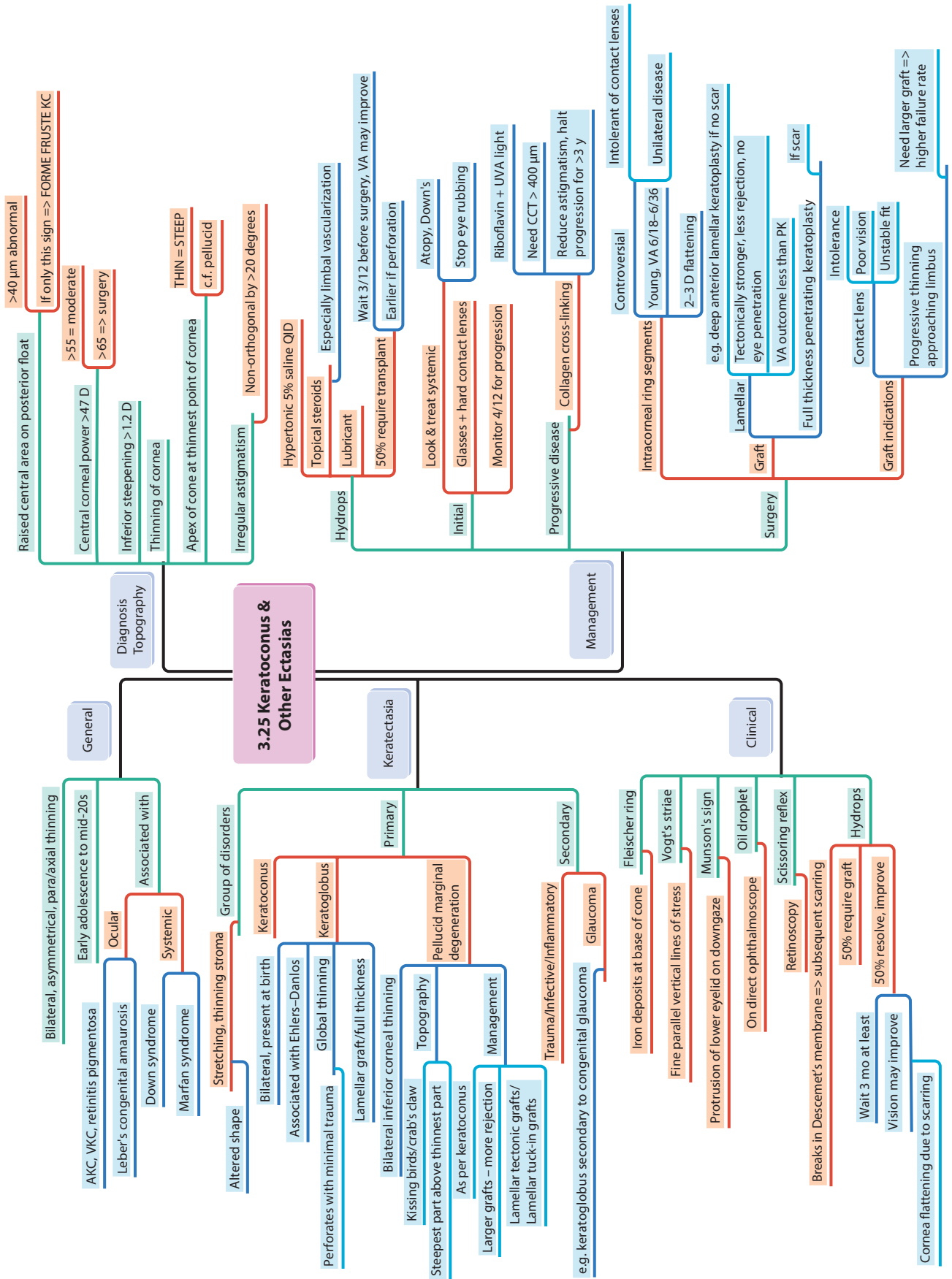


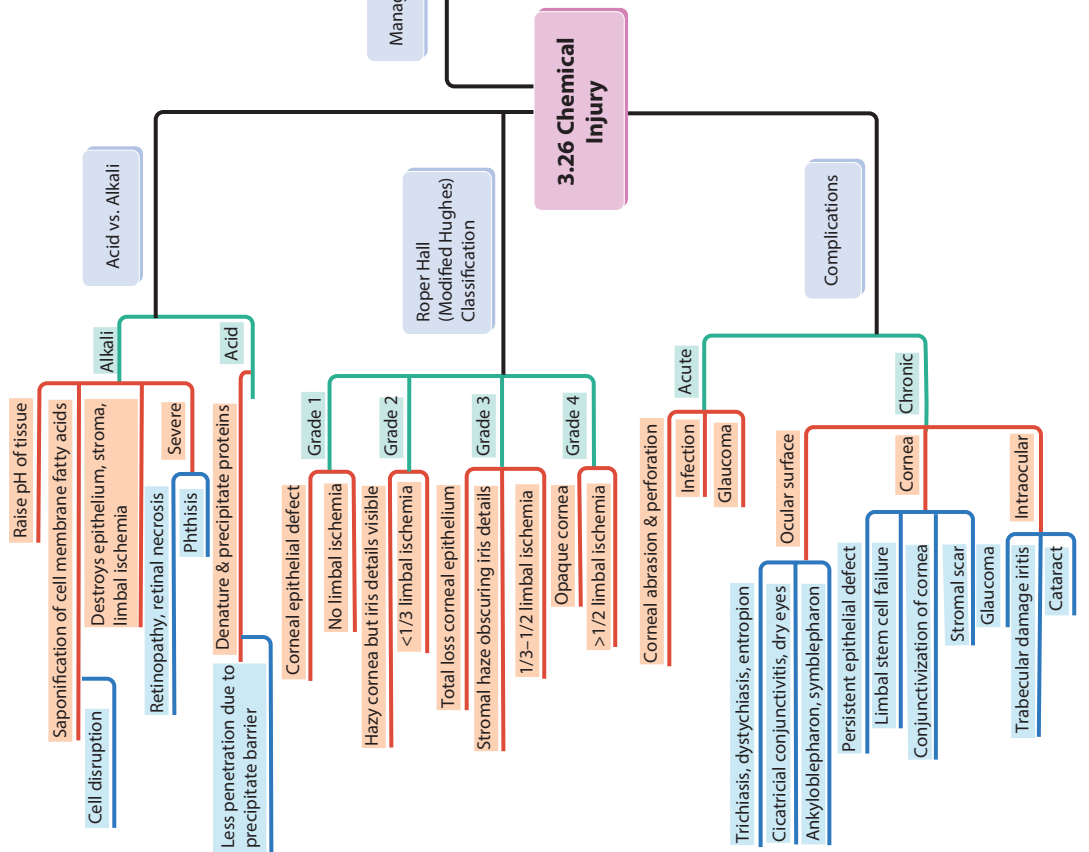
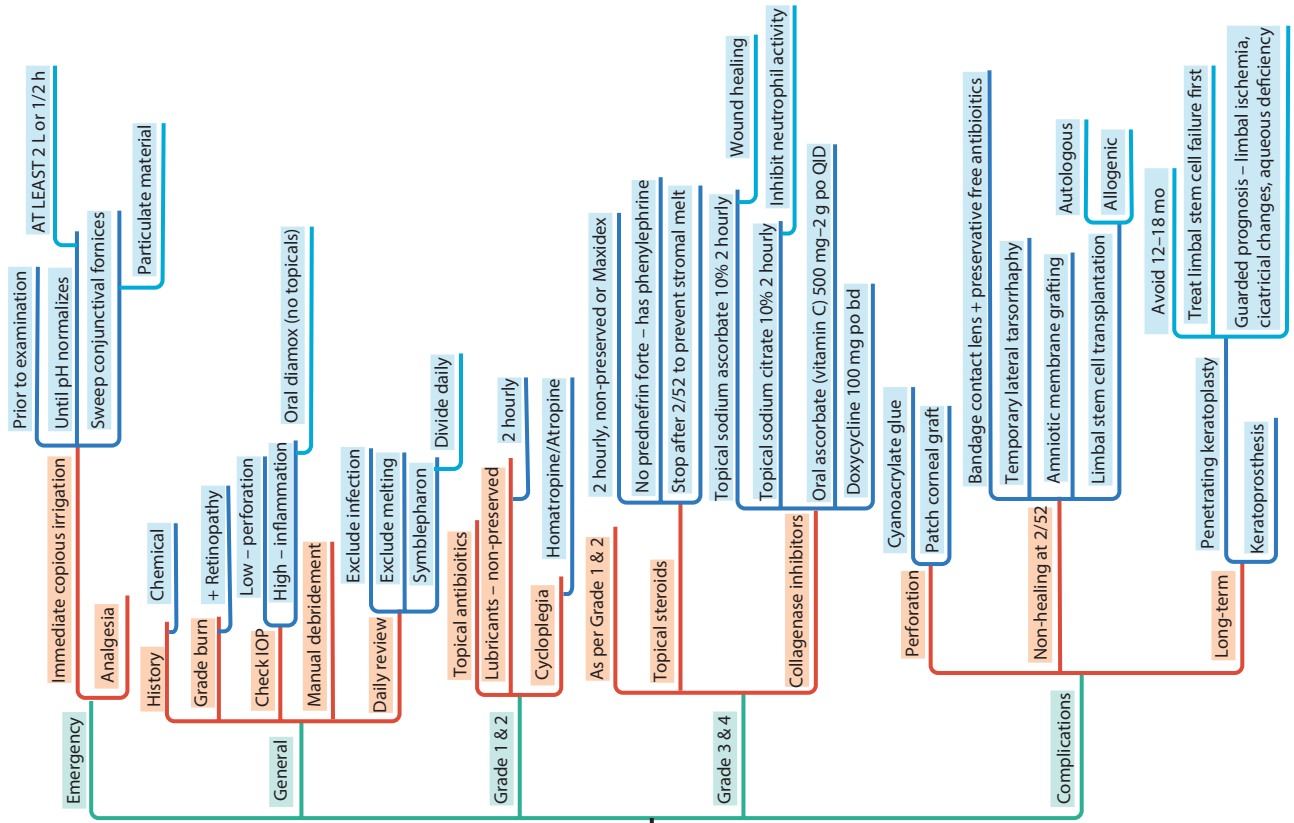


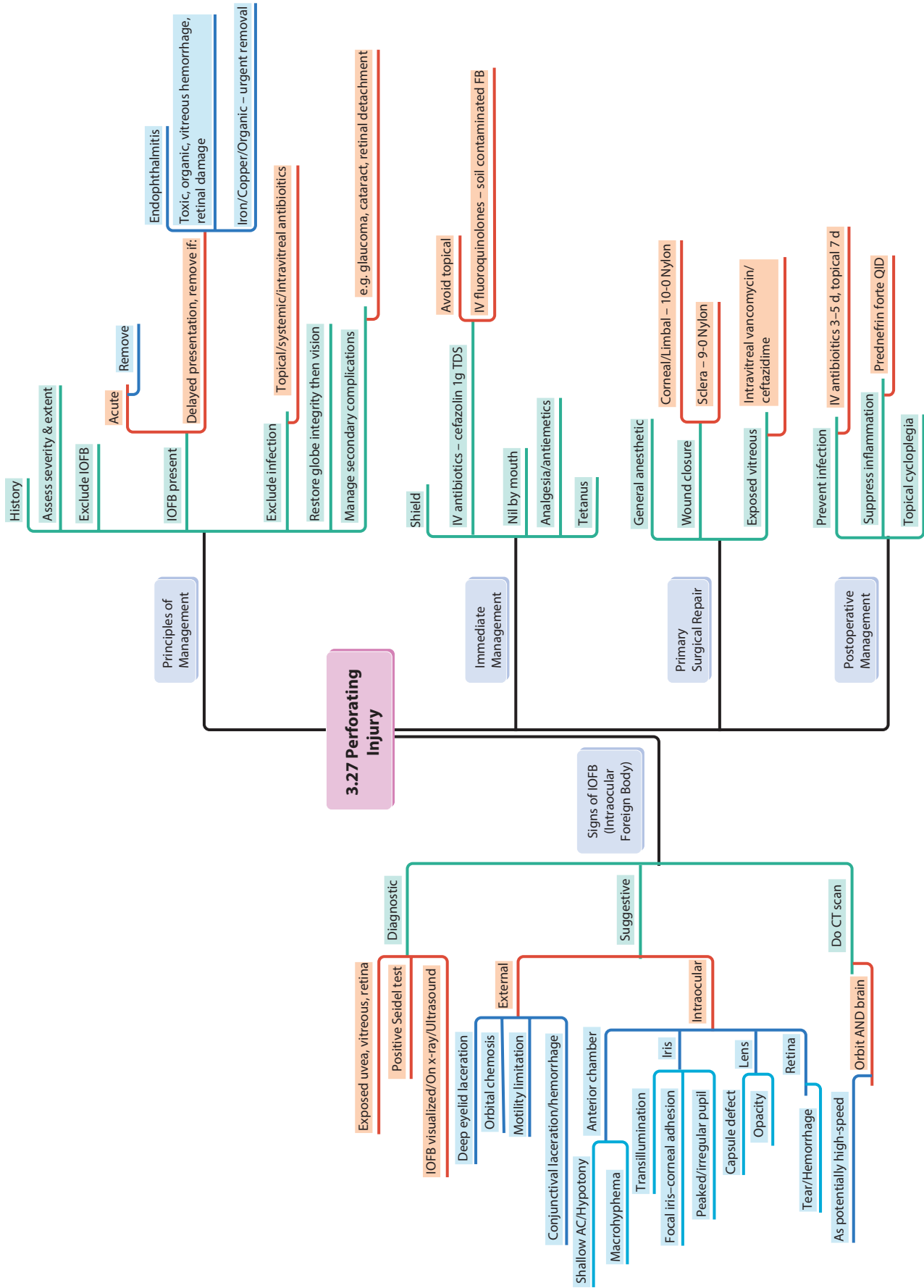


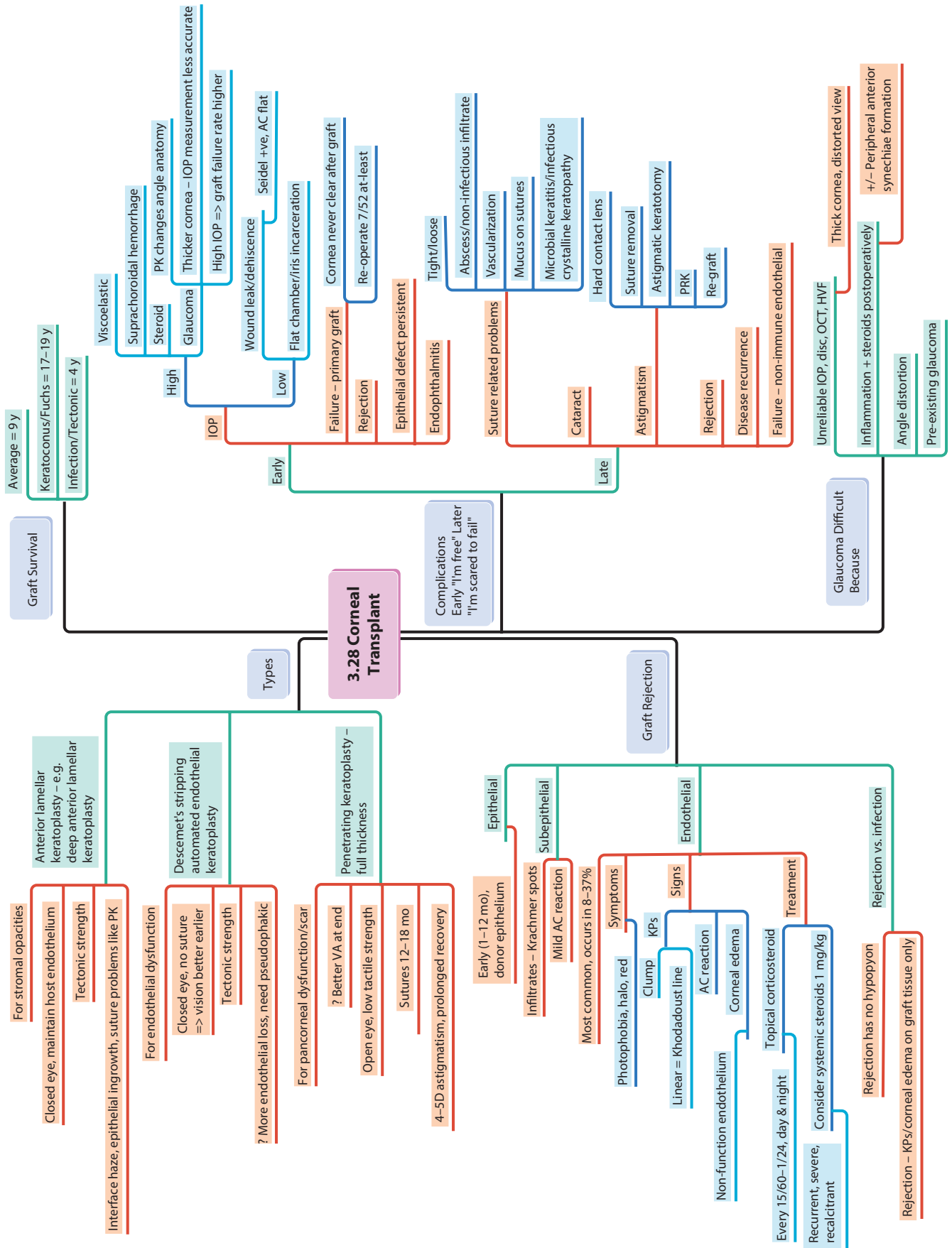




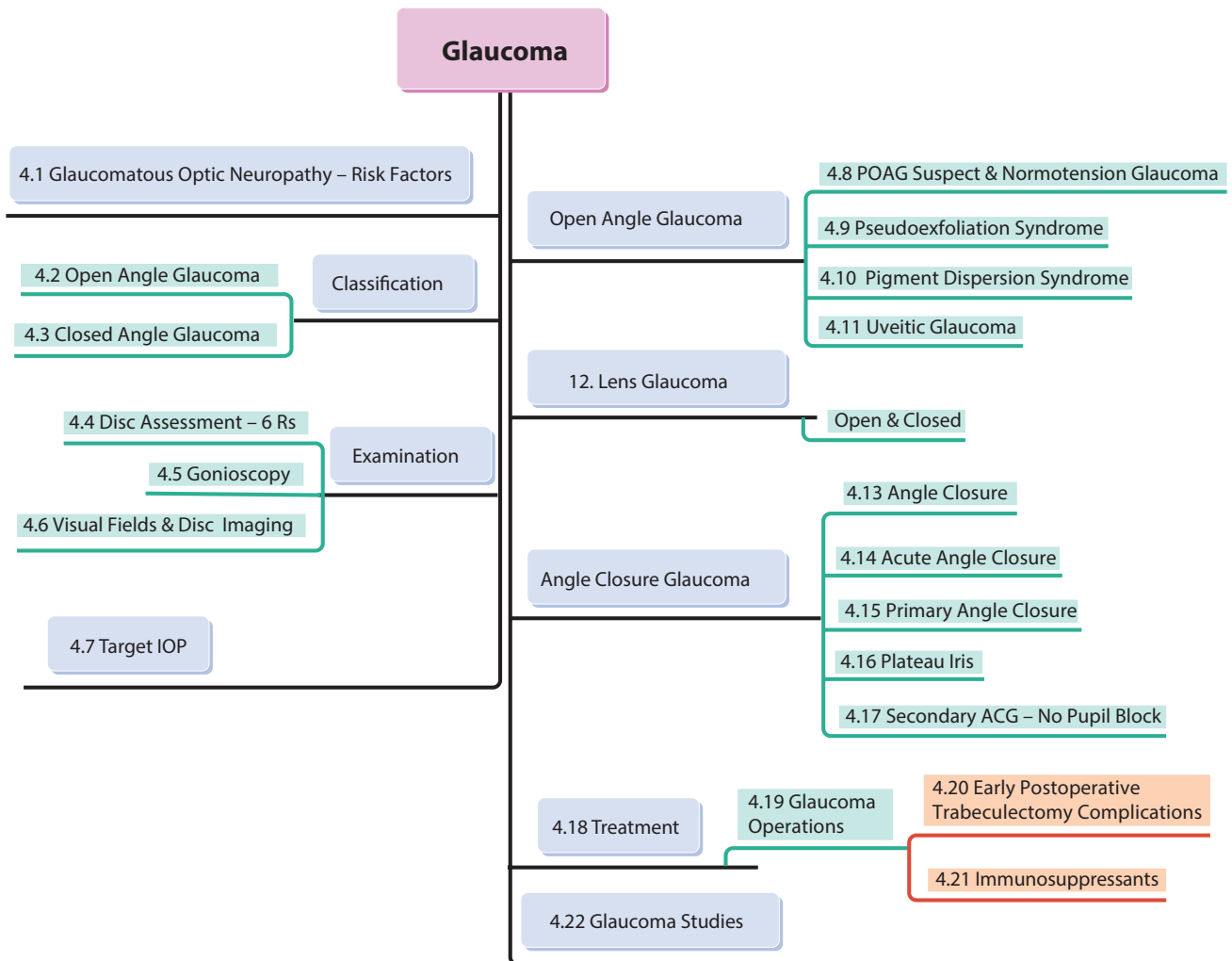


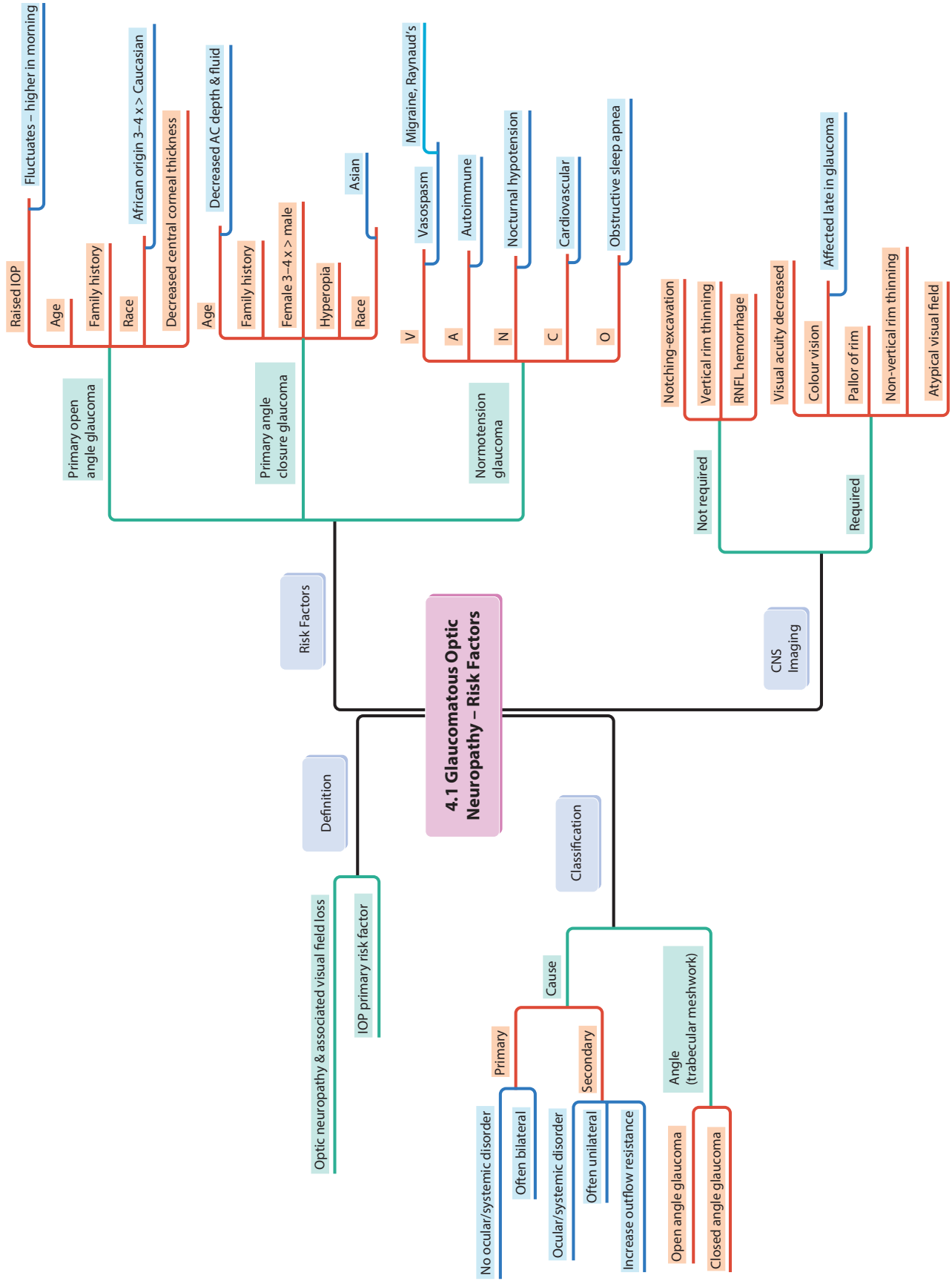


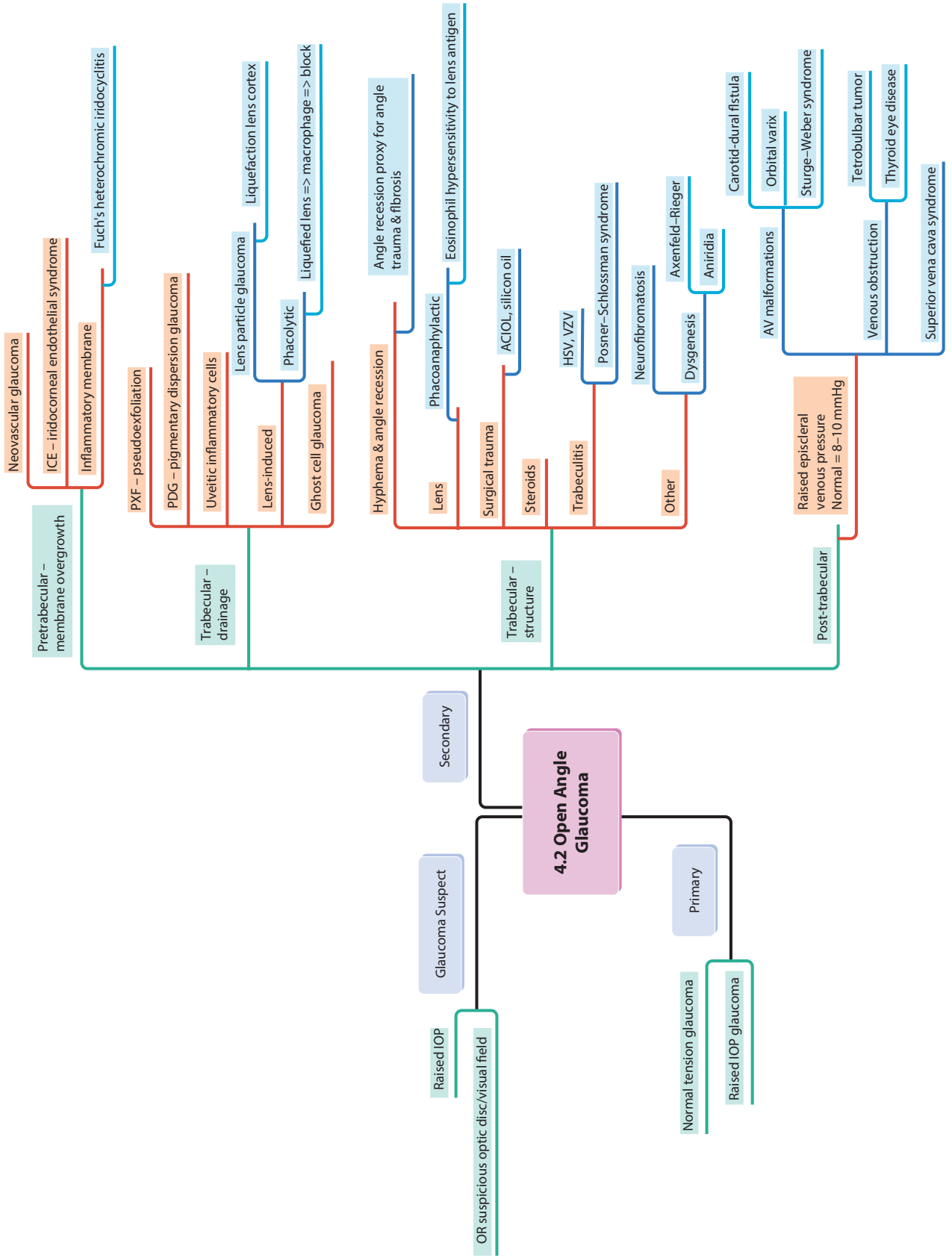


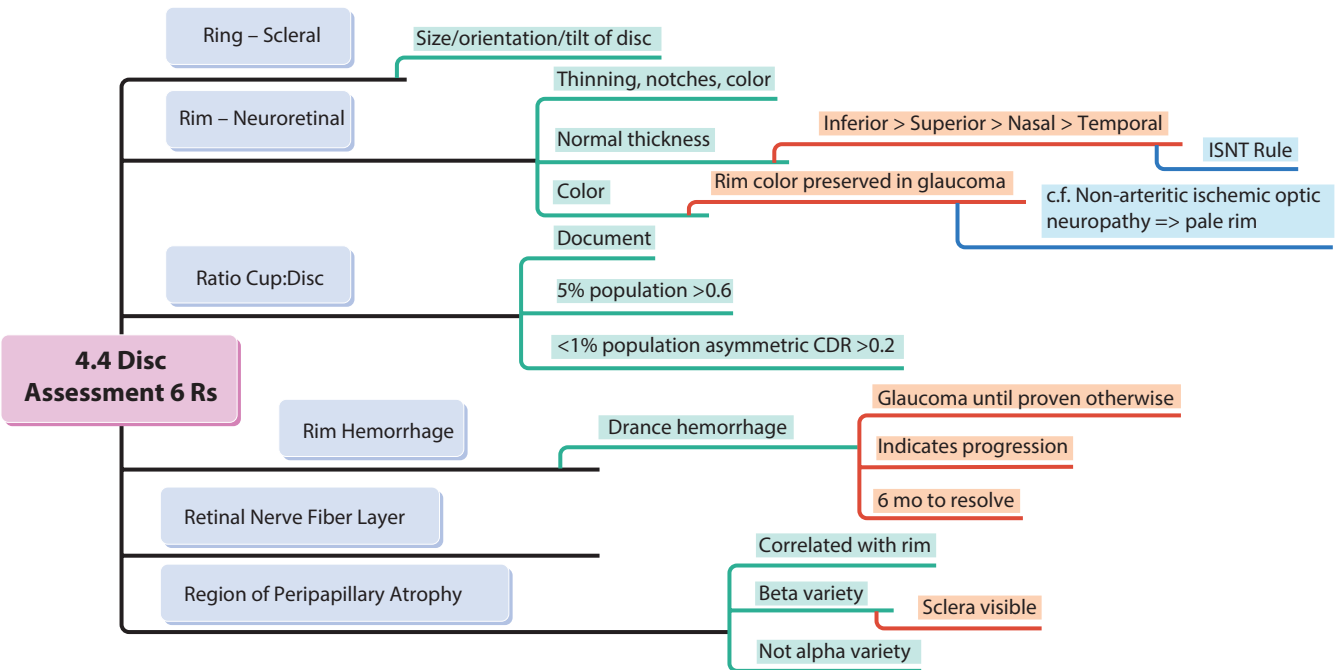
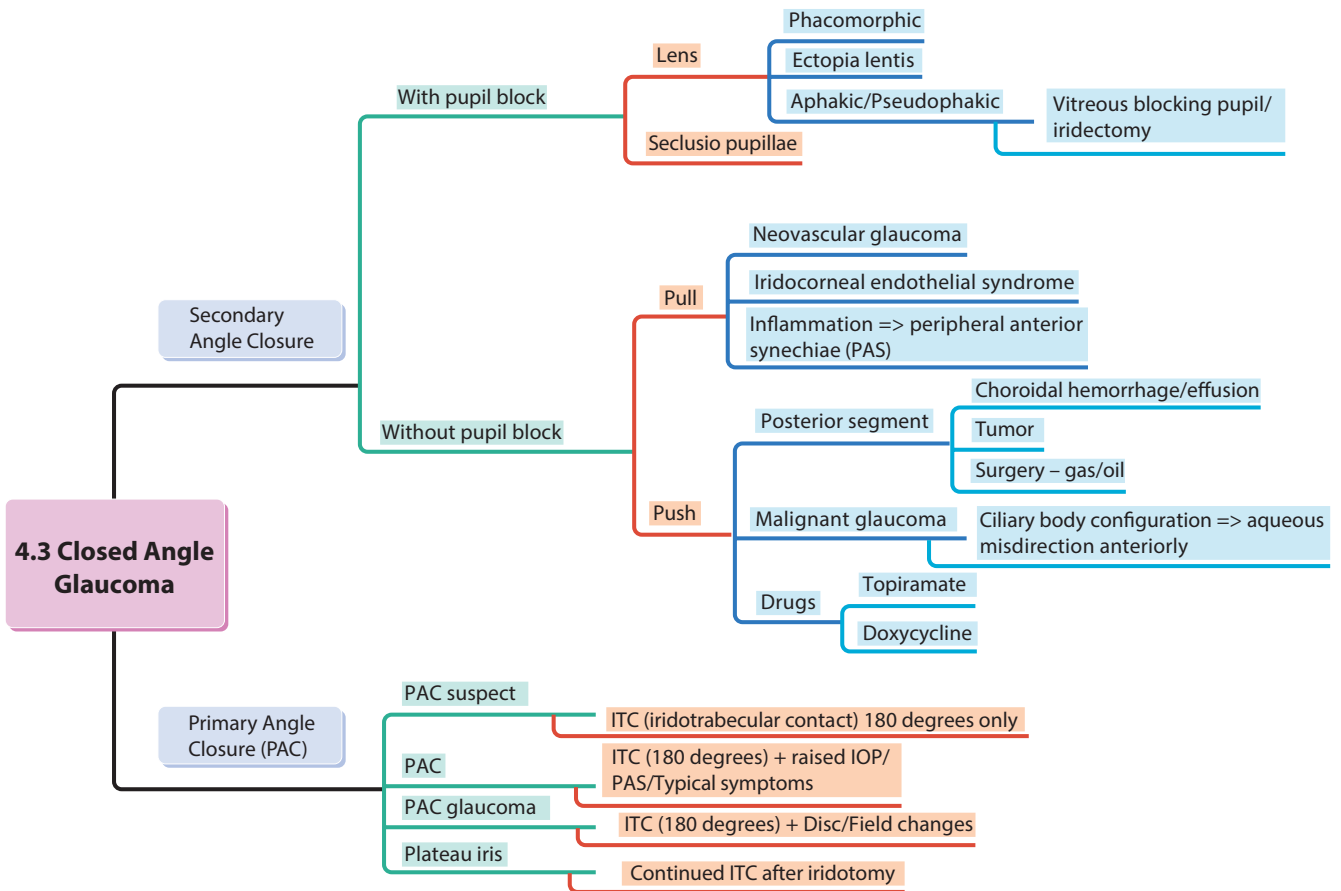


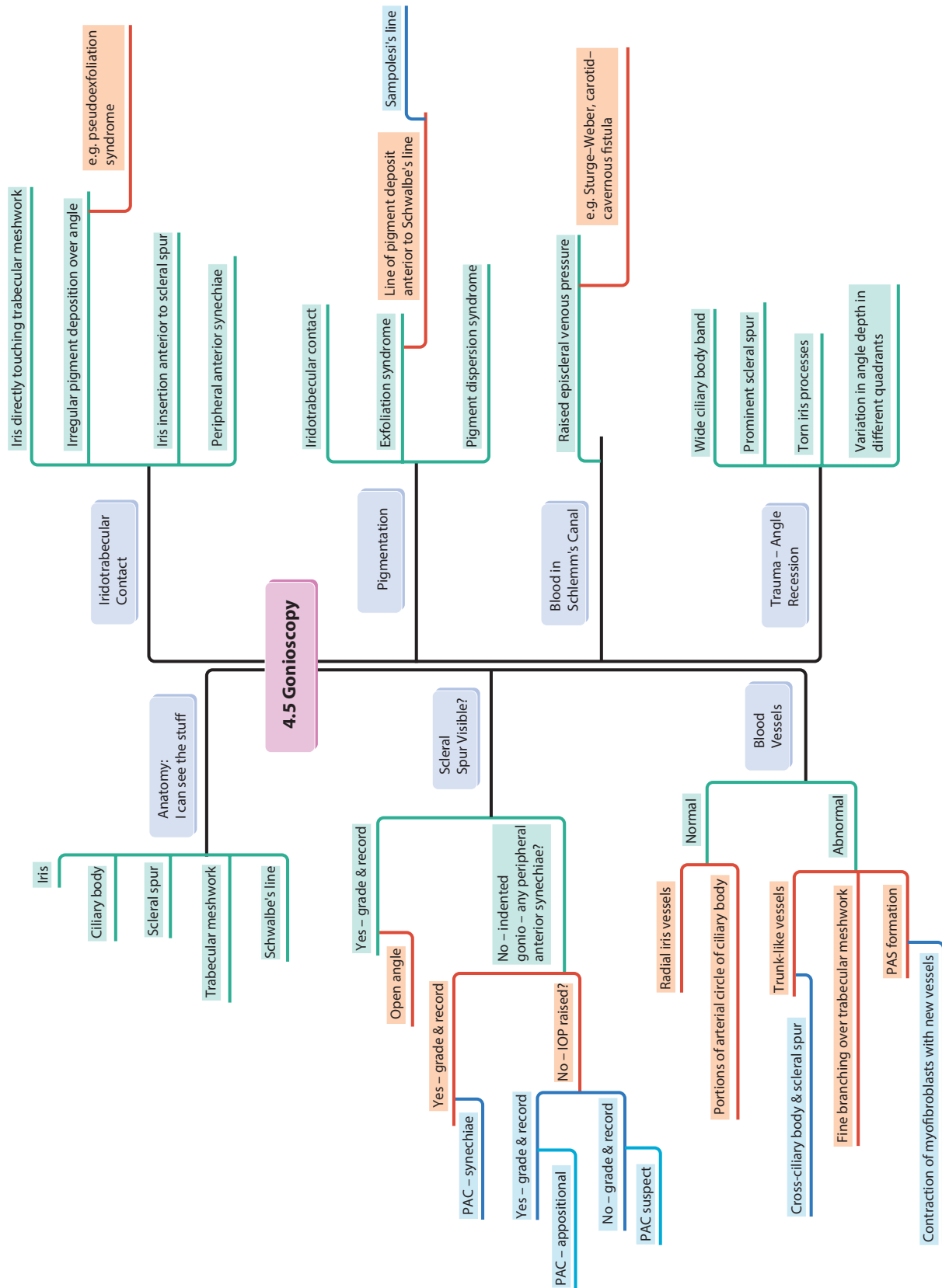
4 Glaucoma

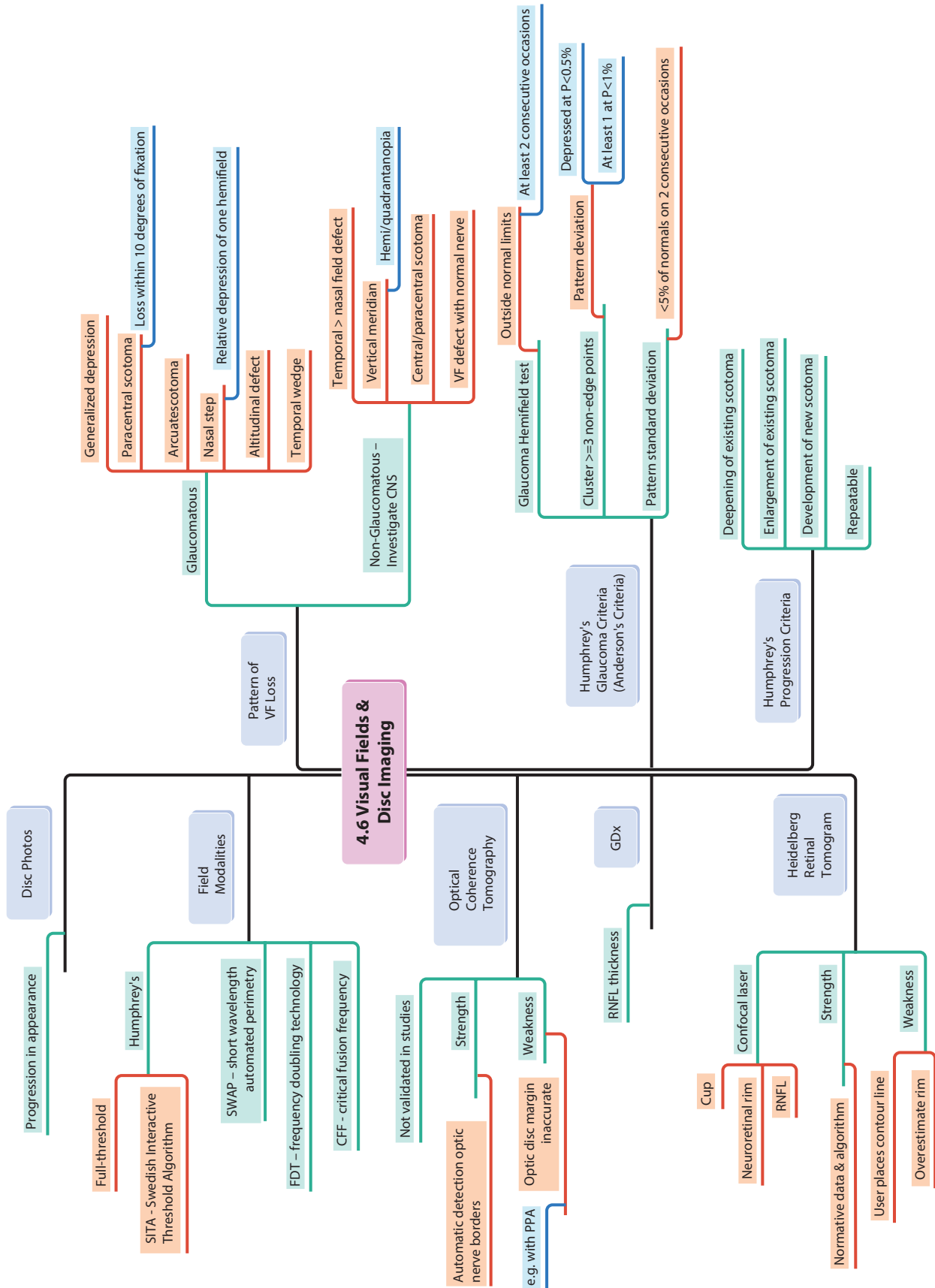


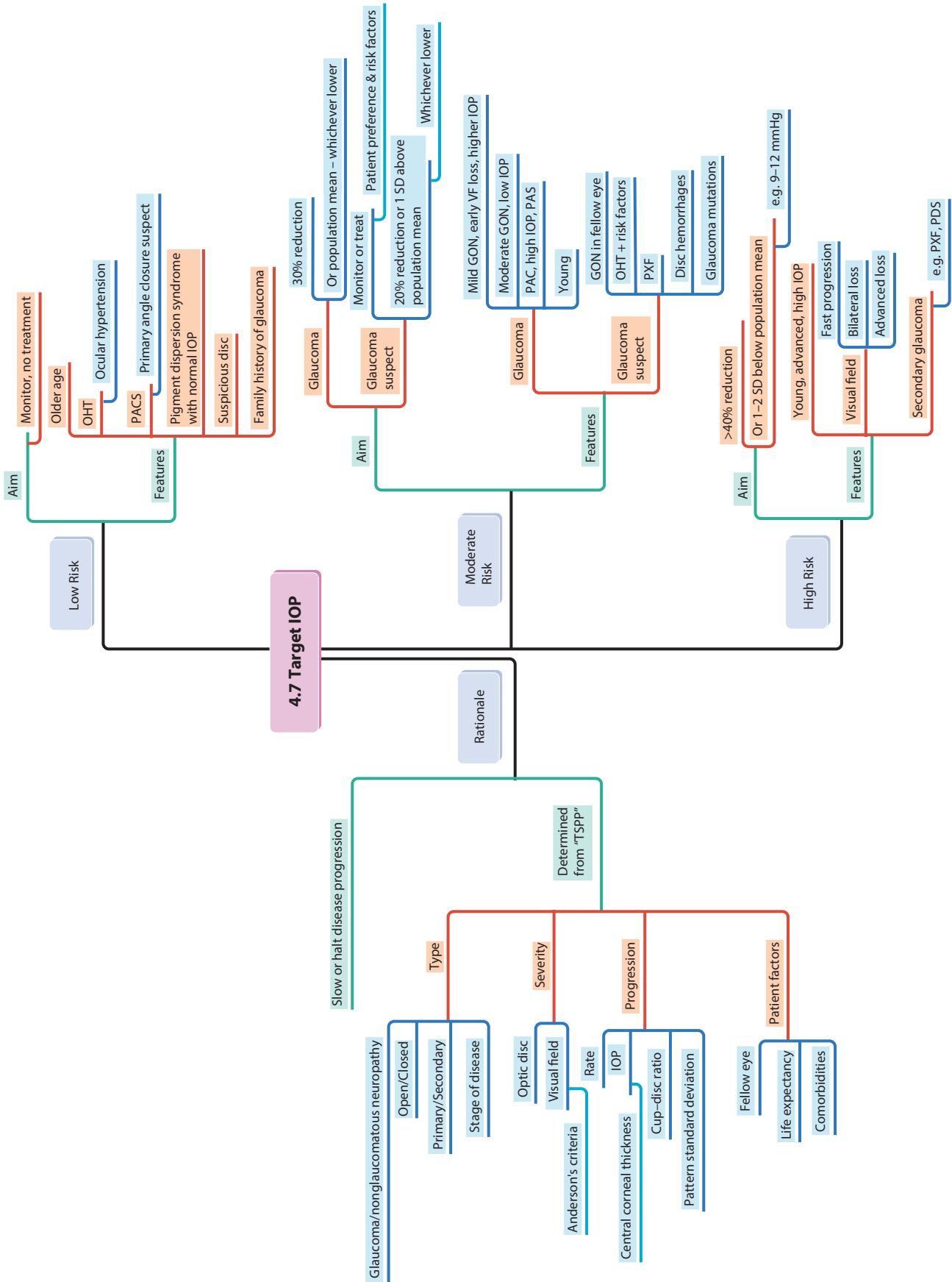


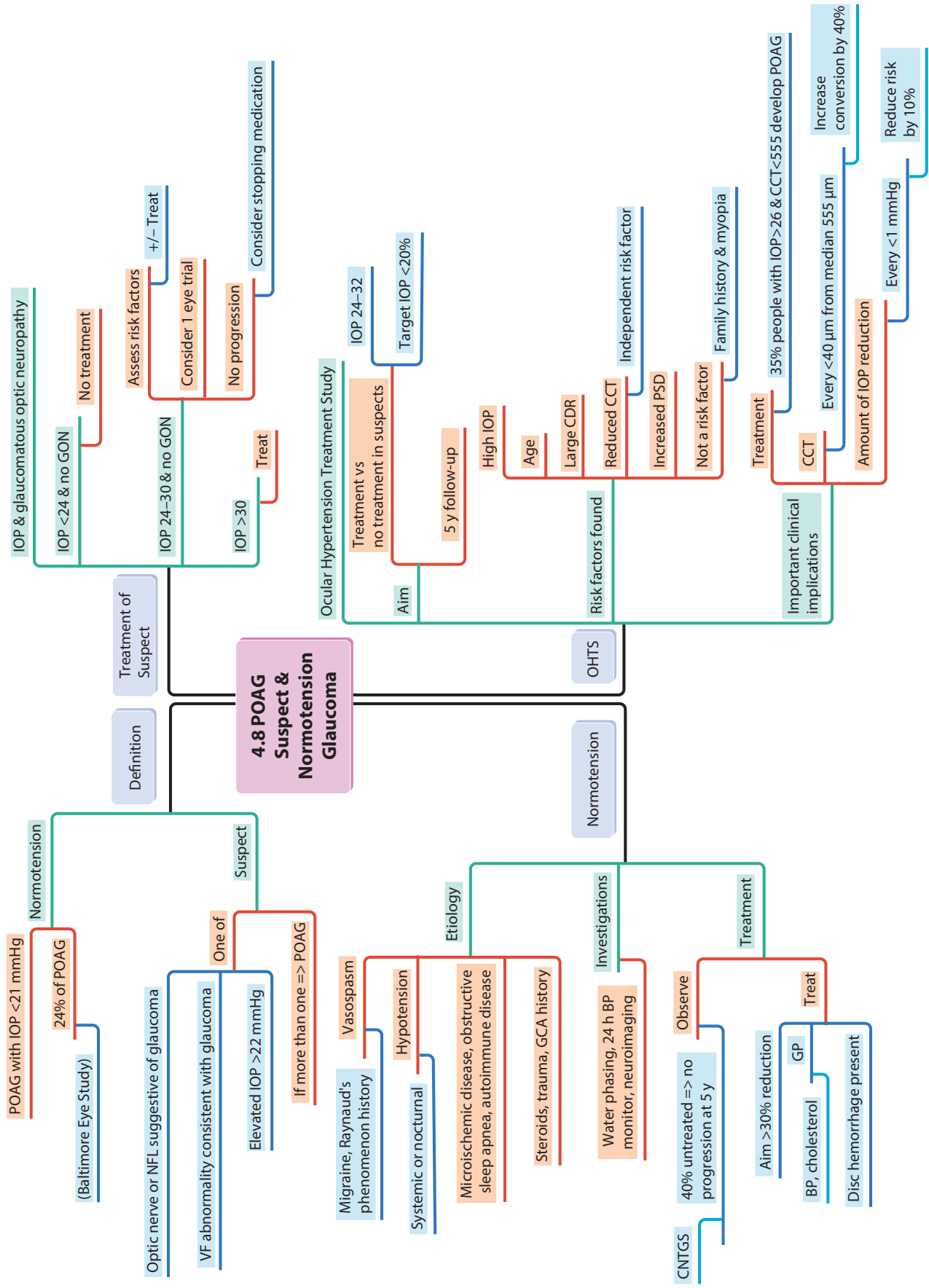


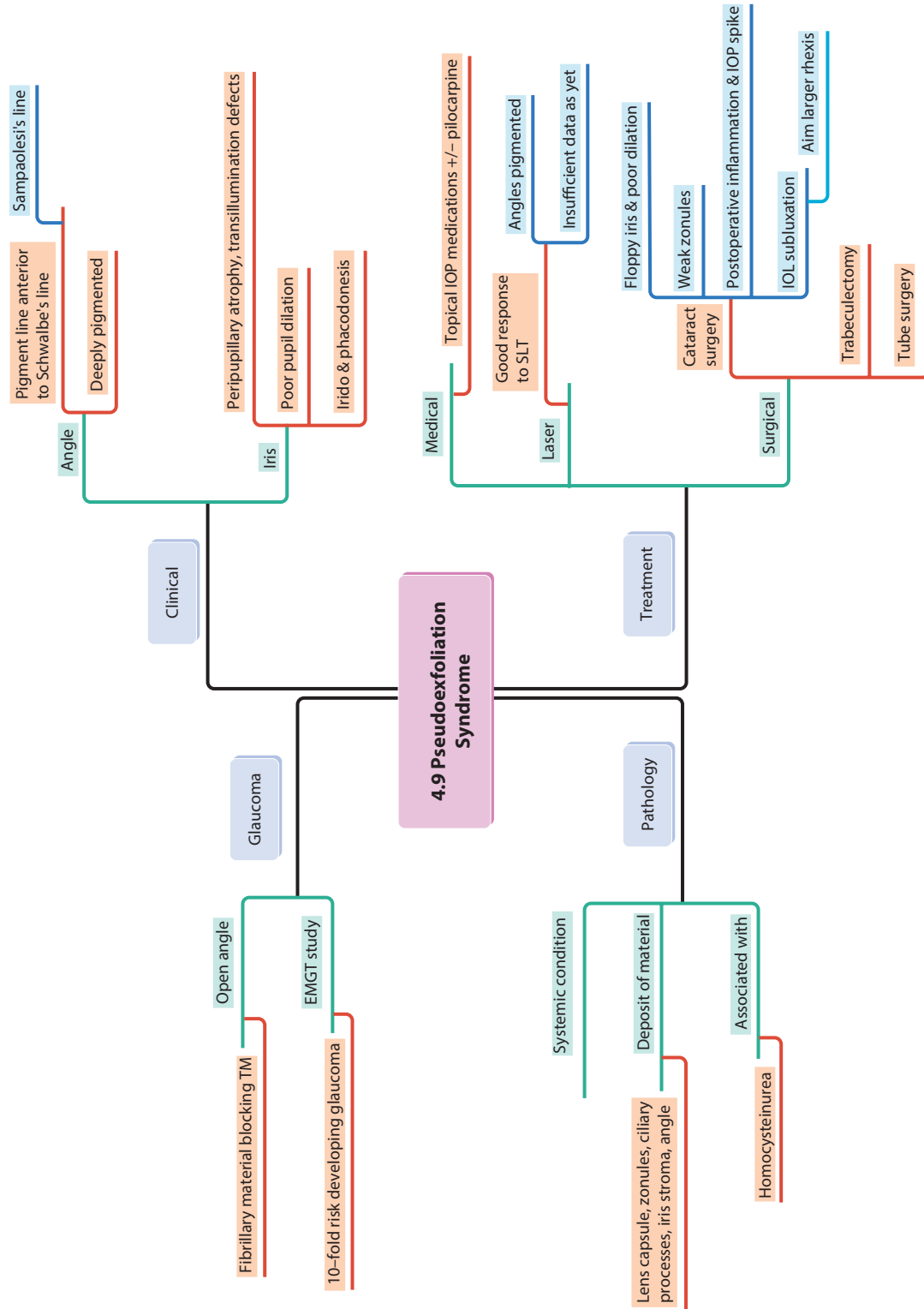


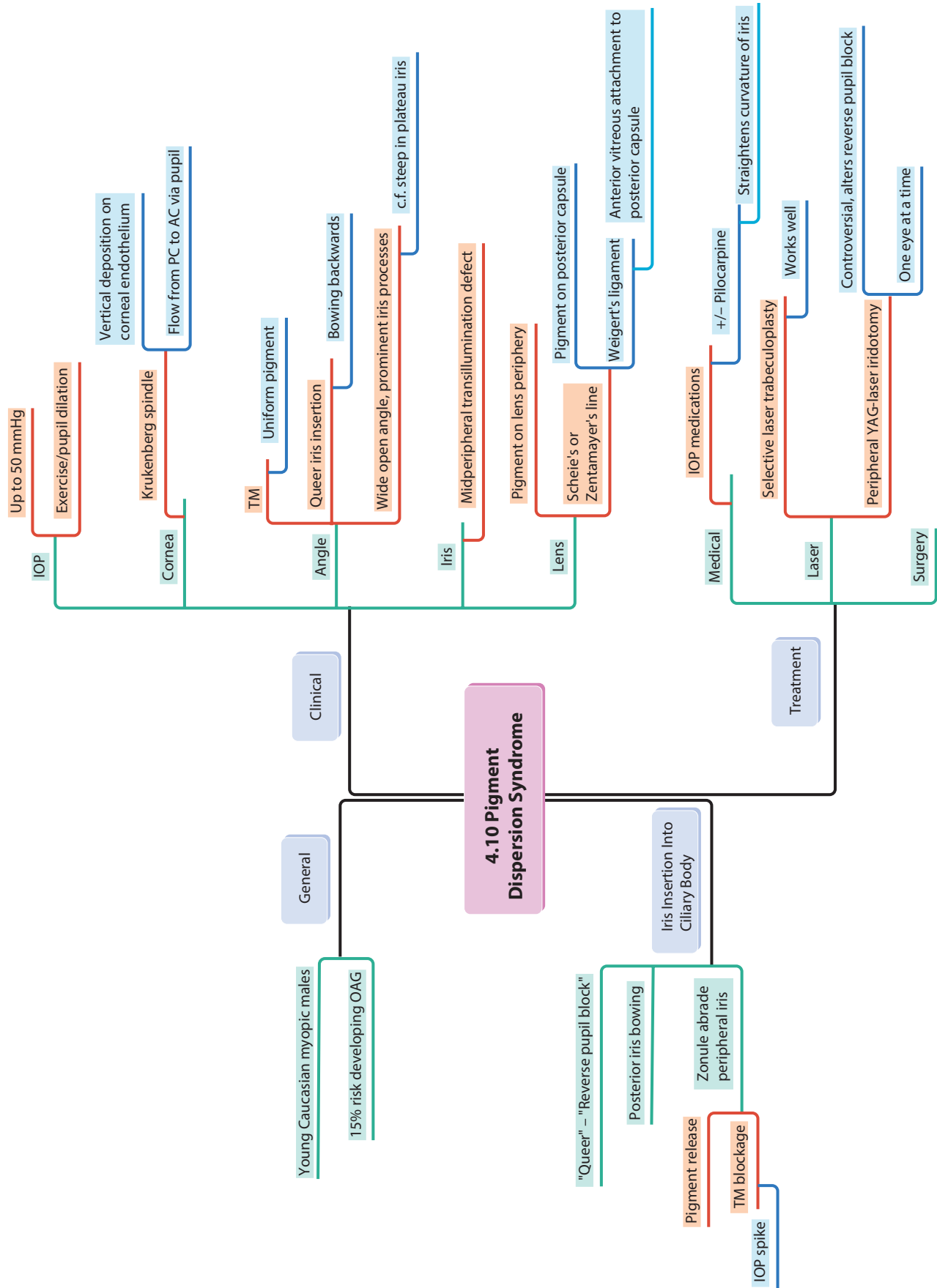












Young Caucasian myopic males

15% risk developing OAG

"Queer" – "Reverse pupil block"

Posterior iris bowing

Pigment release

TM blockage

IOP spike

Zonule abrade peripheral iris

Iris Insertion Into Ciliary Body

General

Clinical

4.10 Pigment Dispersion Syndrome

Treatment

IOP

Cornea

Angle

Iris

Lens

Medical

Laser

Surgery

Up to 50 mmHg

Exercise/pupil dilation

Vertical deposition on corneal endothelium

Flow from PC to AC via pupil

Krukenberg spindle

TM

Uniform pigment

Queer iris insertion

Bowing backwards

Wide open angle, prominent iris processes

c.f. steep in plateau iris

Midperipheral transillumination defect

Pigment on lens periphery

Scheie's or Zentmayer's line

Pigment on posterior capsule

Weigert's ligament

Anterior vitreous attachment to posterior capsule

IOP medications

+/- Pilocarpine

Straightens curvature of iris

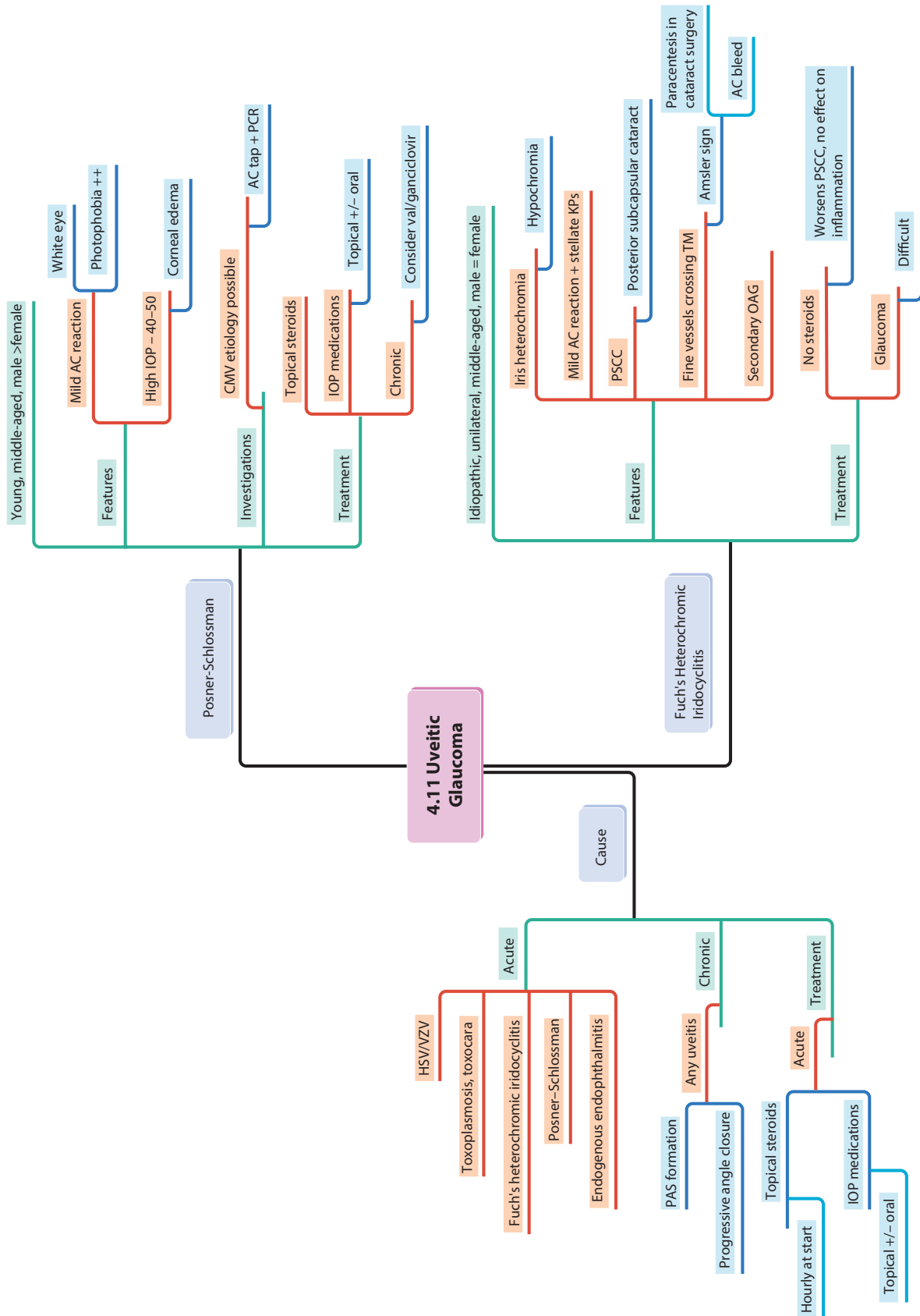
Selective laser trabeculoplasty

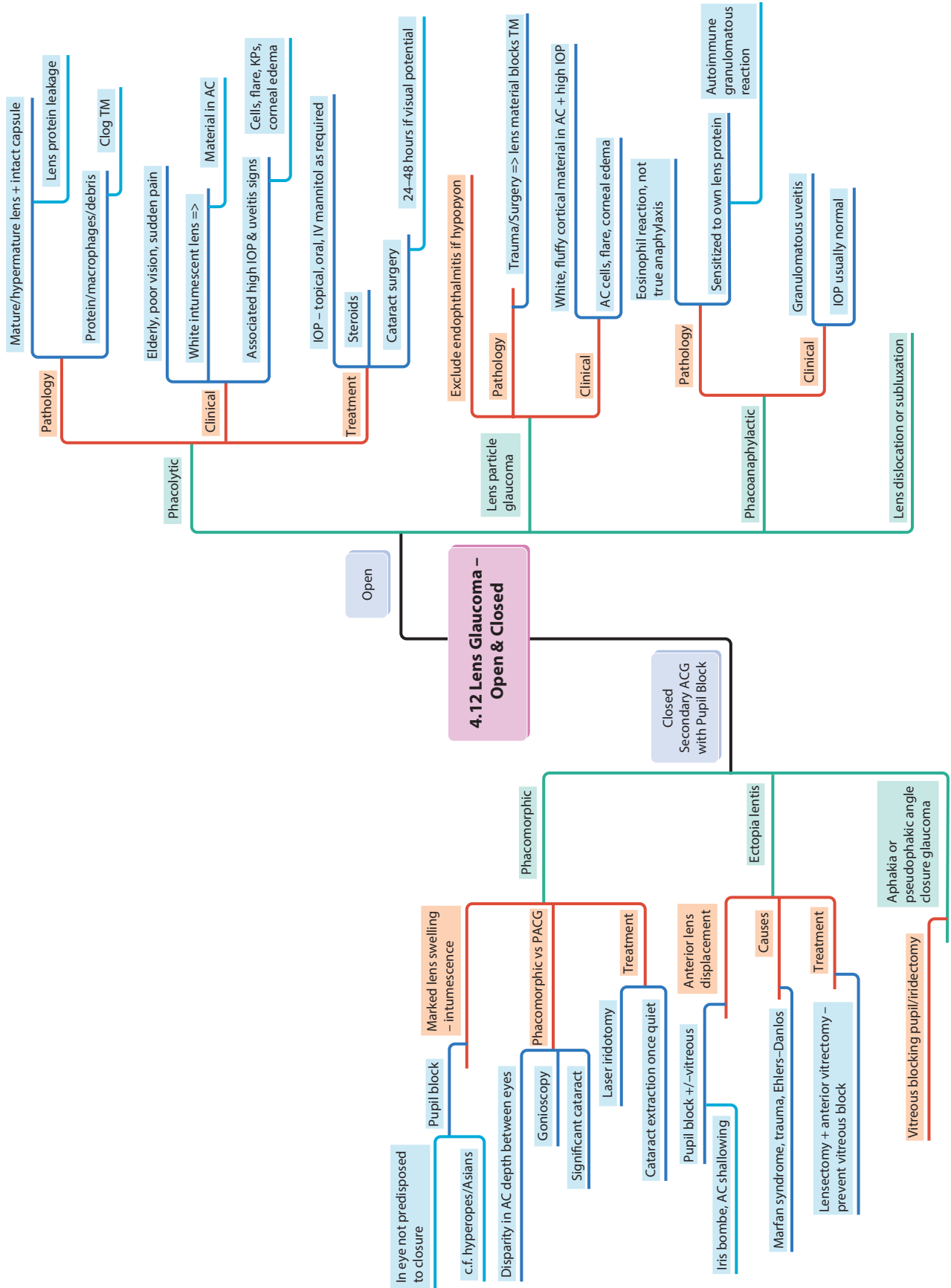
Works well

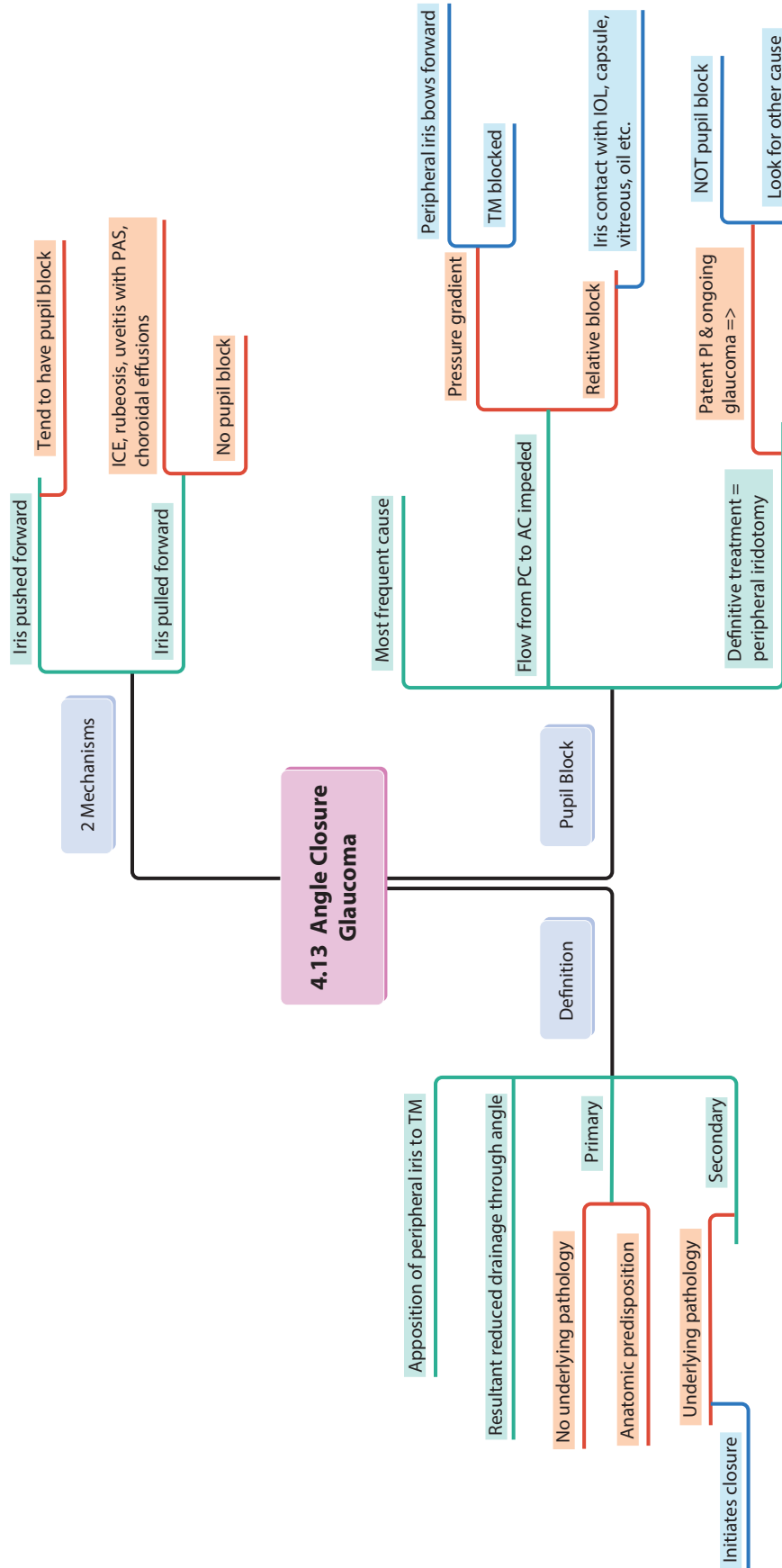
Peripheral YAG-laser iridotomy

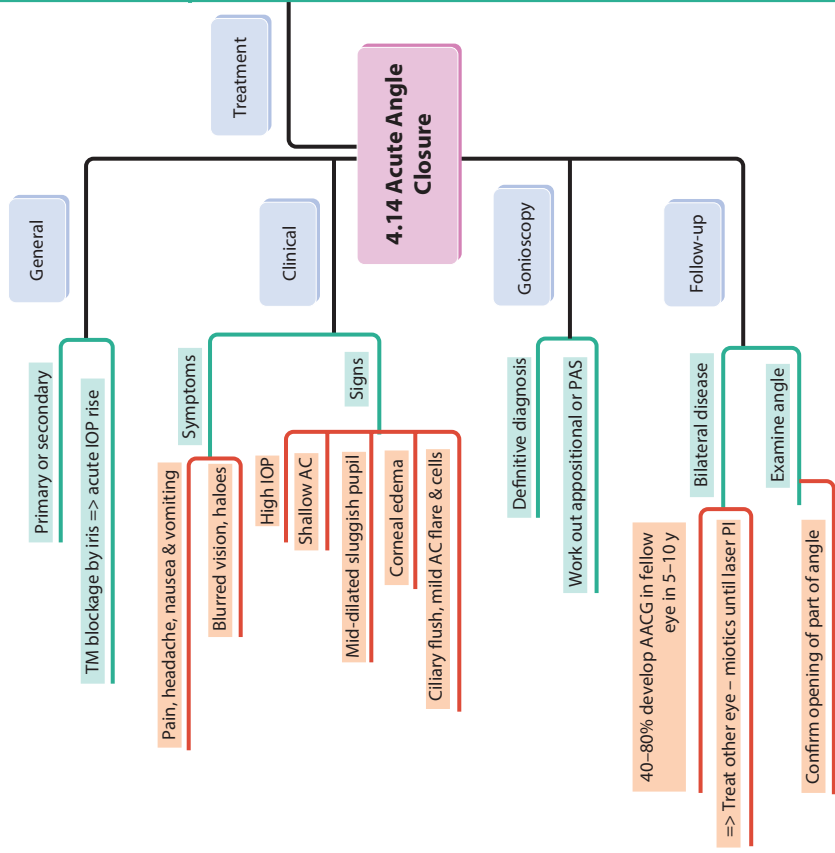
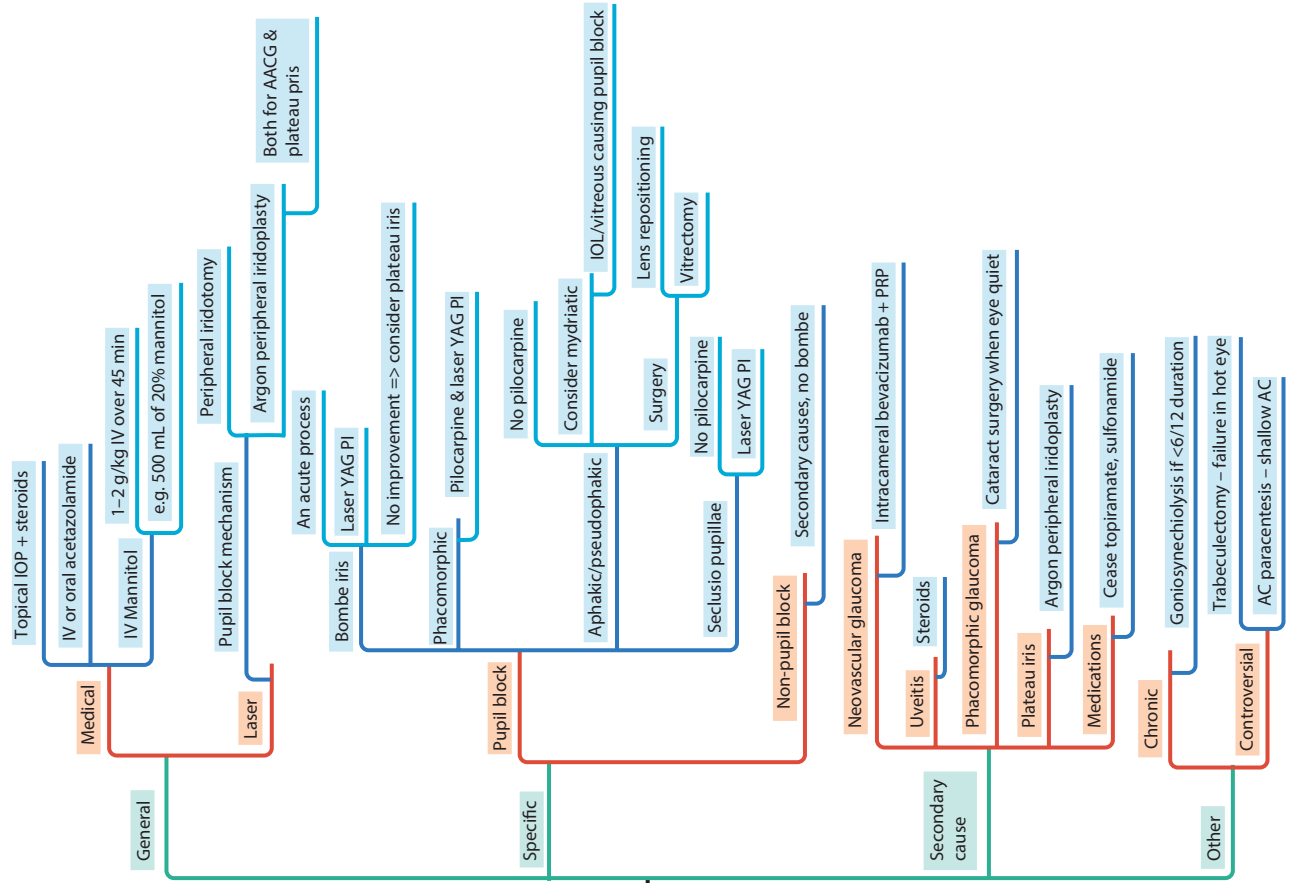
Controversial, alters reverse pupil block

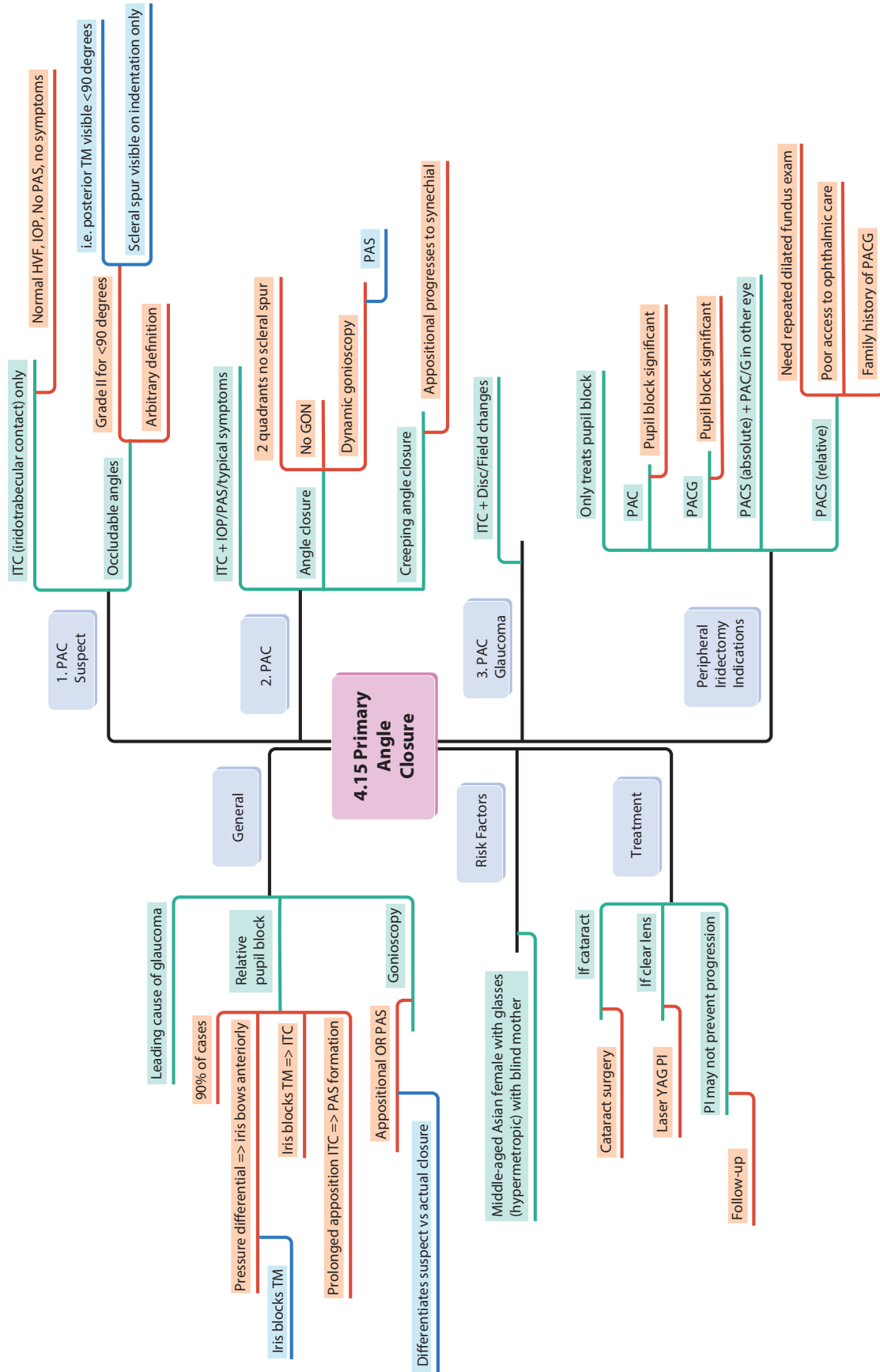
One eye at a time

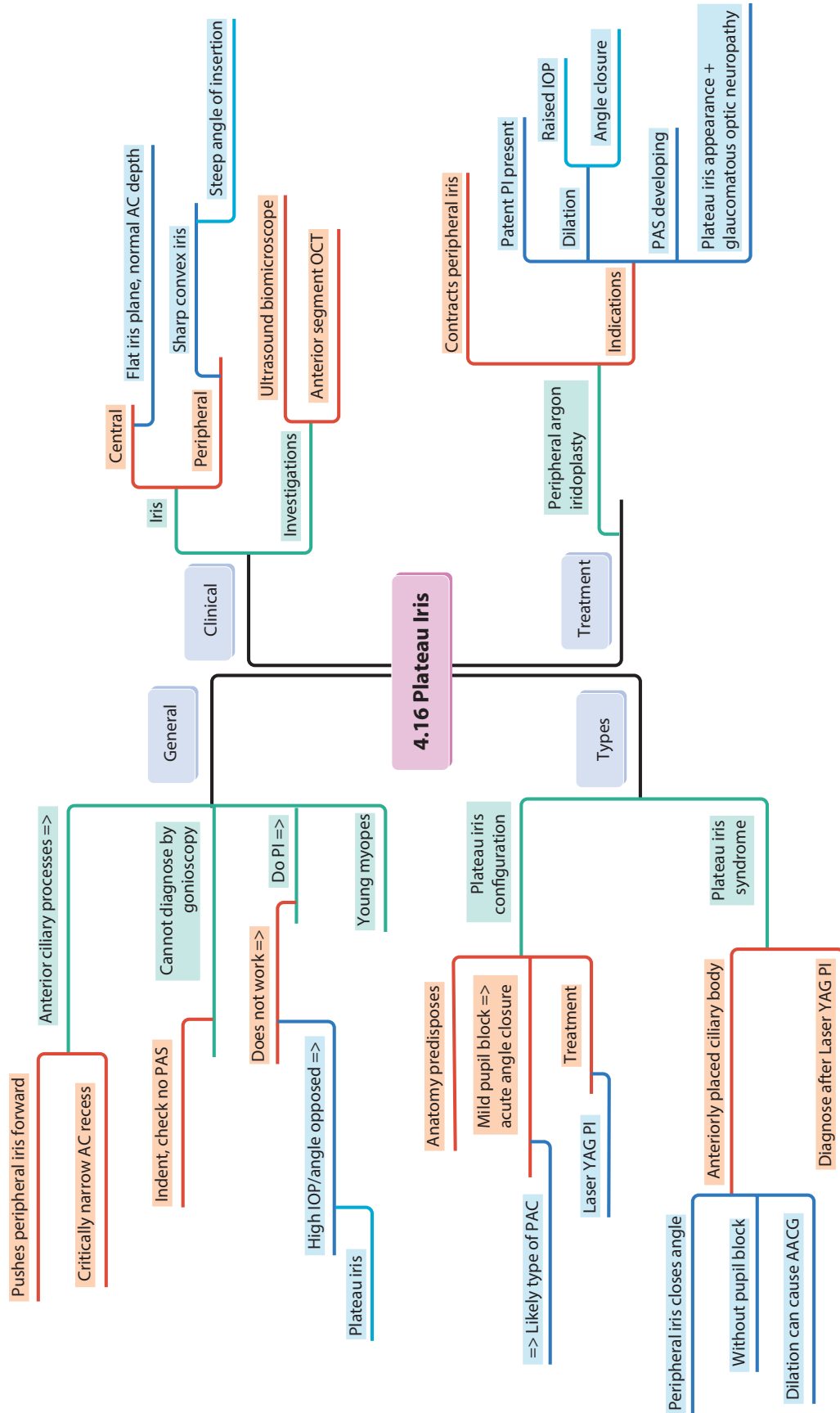


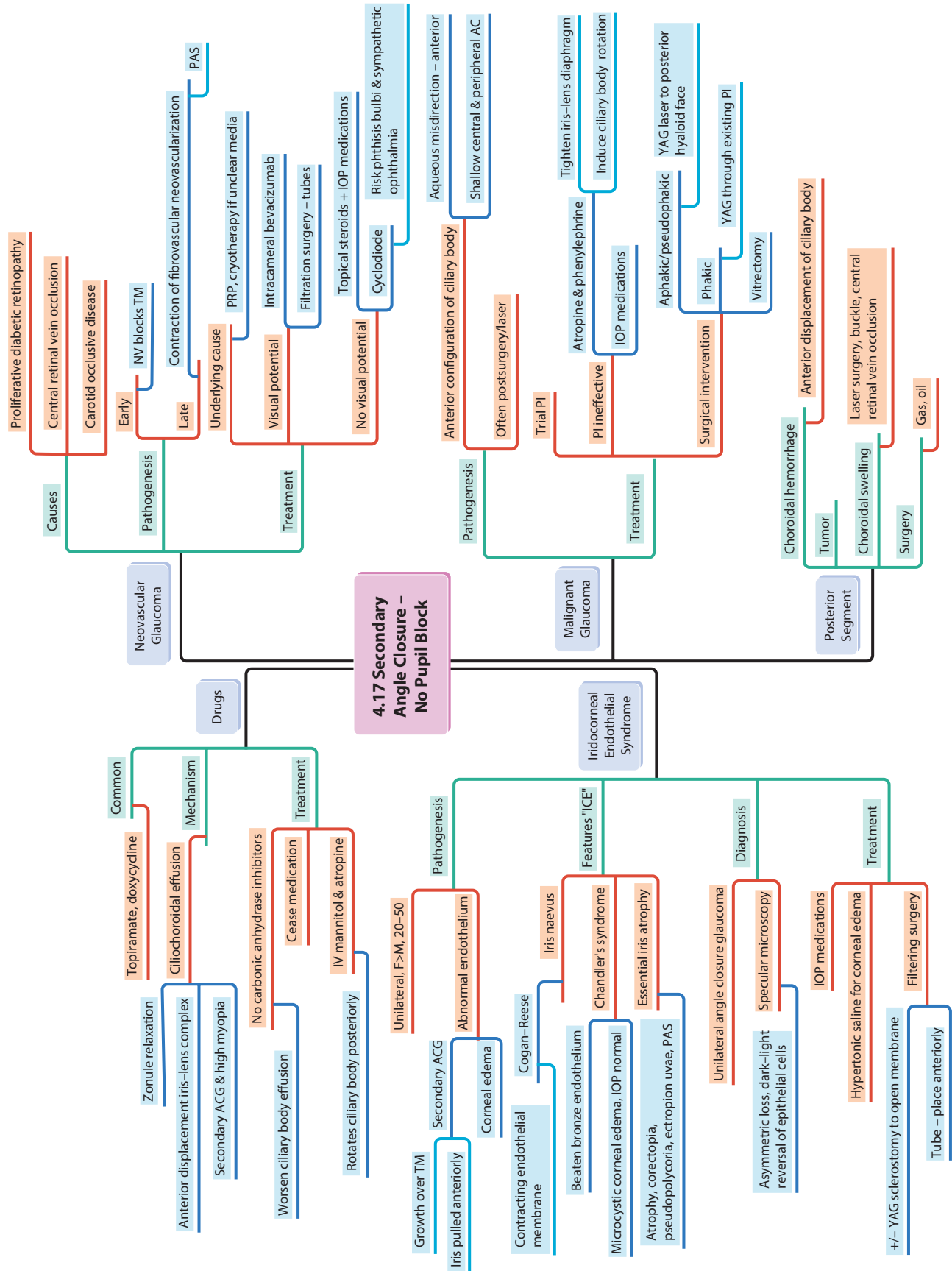












4.17 Secondary Angle Closure - No Pupil Block

Proliferative diabetic retinopathy

Central retinal vein occlusion

Carotid occlusive disease

Early

NV blocks TM

Contraction of fibrovascular neovascularization

PAS

Underlying cause

PRP, cryotherapy if unclear media

Visual potential

Intracameral bevacizumab

Filtration surgery - tubes

No visual potential

Topical steroids + IOP medications

Cyclo diode

Risk phtisis bulbi & sympathetic ophthalmia

Aqueous misdirection - anterior

Shallow central & peripheral AC

Anterior configuration of ciliary body

Often postsurgery/laser

Trial PI

Atropine & phenylephrine

Tighten iris-lens diaphragm

IOP medications

Induce ciliary body rotation

Surgical intervention

Aphakic/pseudophakic

Phakic

Vitrectomy

YAG laser to posterior hyaloid face

YAG through existing PI

Anterior displacement of ciliary body

Laser surgery, buckle, central retinal vein occlusion

Gas, oil

Causes

Pathogenesis

Treatment

Neovascular Glaucoma

4.17 Secondary Angle Closure - No Pupil Block

Malignant Glaucoma

Posterior Segment

Common

Topiramate, doxycycline

Zonule relaxation

Anterior displacement iris-lens complex

Secondary ACG & high myopia

Ciliochoroidal effusion

No carbonic anhydrase inhibitors

Worsen ciliary body effusion

Cease medication

IV mannitol & atropine

Rotates ciliary body posteriorly

Unilateral, F>M, 20-50

Secondary ACG

Abnormal endothelium

Corneal edema

Contracting endothelial membrane

Cogan-Reese

Beaten bronze endothelium

Microcystic corneal edema, IOP normal

Atrophy, corectopia, pseudopolyopia, ectropion uvae, PAS

Essential iris atrophy

Unilateral angle closure glaucoma

Asymmetric loss, dark-light reversal of epithelial cells

Specular microscopy

IOP medications

Hypertonic saline for corneal edema

+/- YAG sclerostomy to open membrane

Filtering surgery

Tube - place anteriorly

Growth over TM

Iris pulled anteriorly

Contracting endothelial membrane

Beaten bronze endothelium

Microcystic corneal edema, IOP normal

Atrophy, corectopia, pseudopolyopia, ectropion uvae, PAS

Essential iris atrophy

Unilateral angle closure glaucoma

Asymmetric loss, dark-light reversal of epithelial cells

Specular microscopy

IOP medications

Hypertonic saline for corneal edema

+/- YAG sclerostomy to open membrane

Filtering surgery

Tube - place anteriorly

Pathogenesis

Features: "ICE"

Diagnosis

Treatment

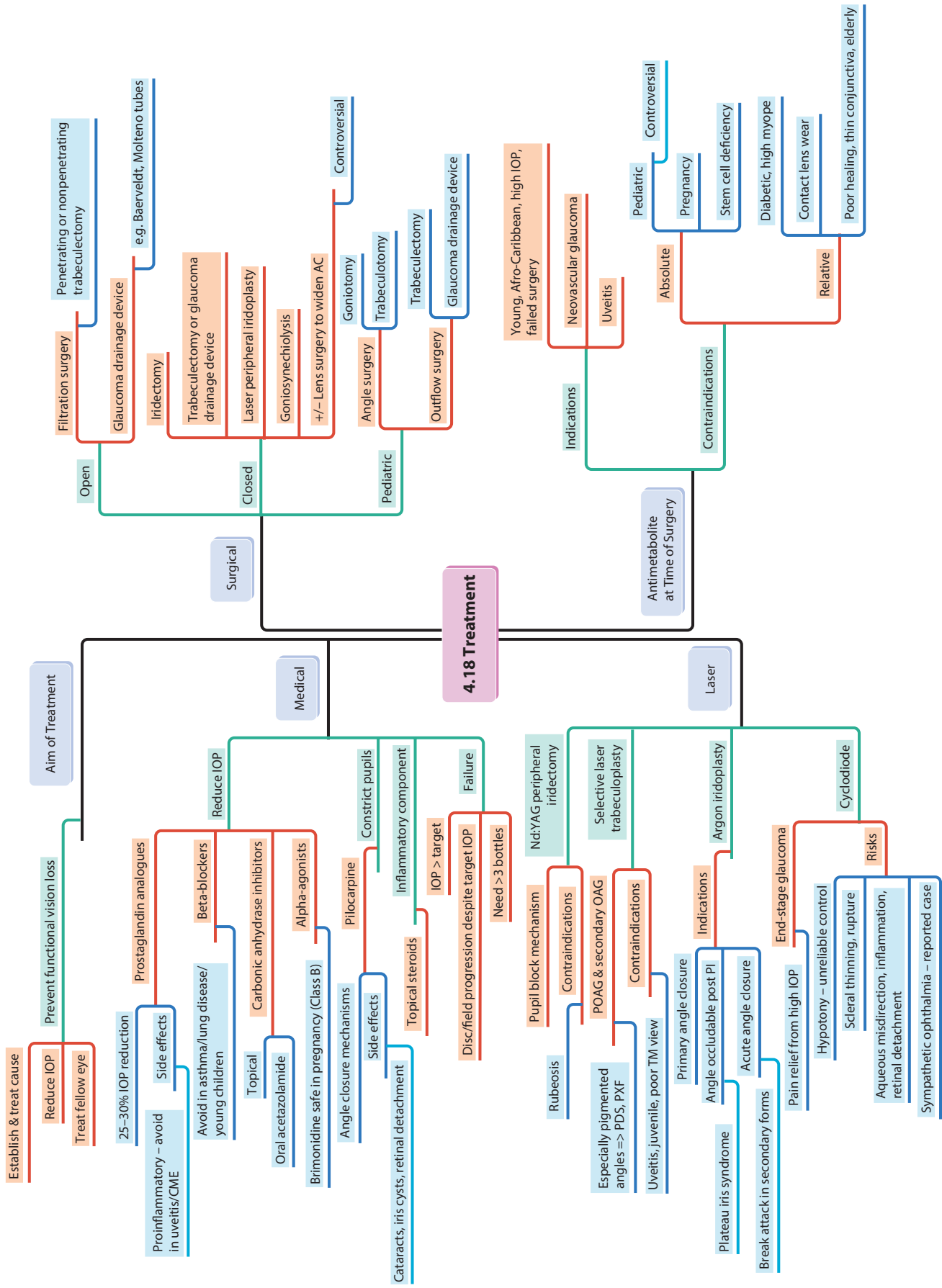
Iridocorneal Endothelial Syndrome

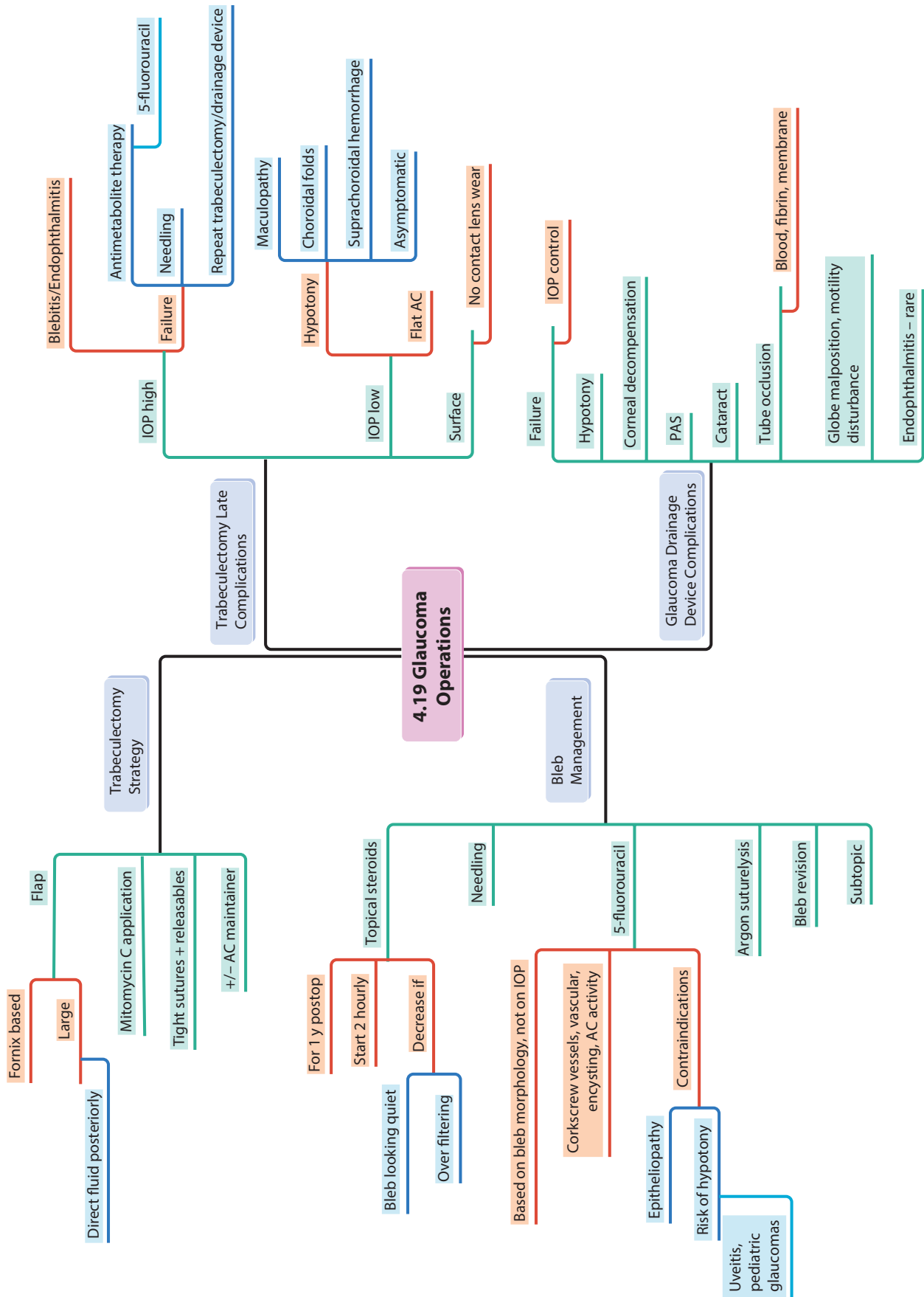
Choroidal hemorrhage

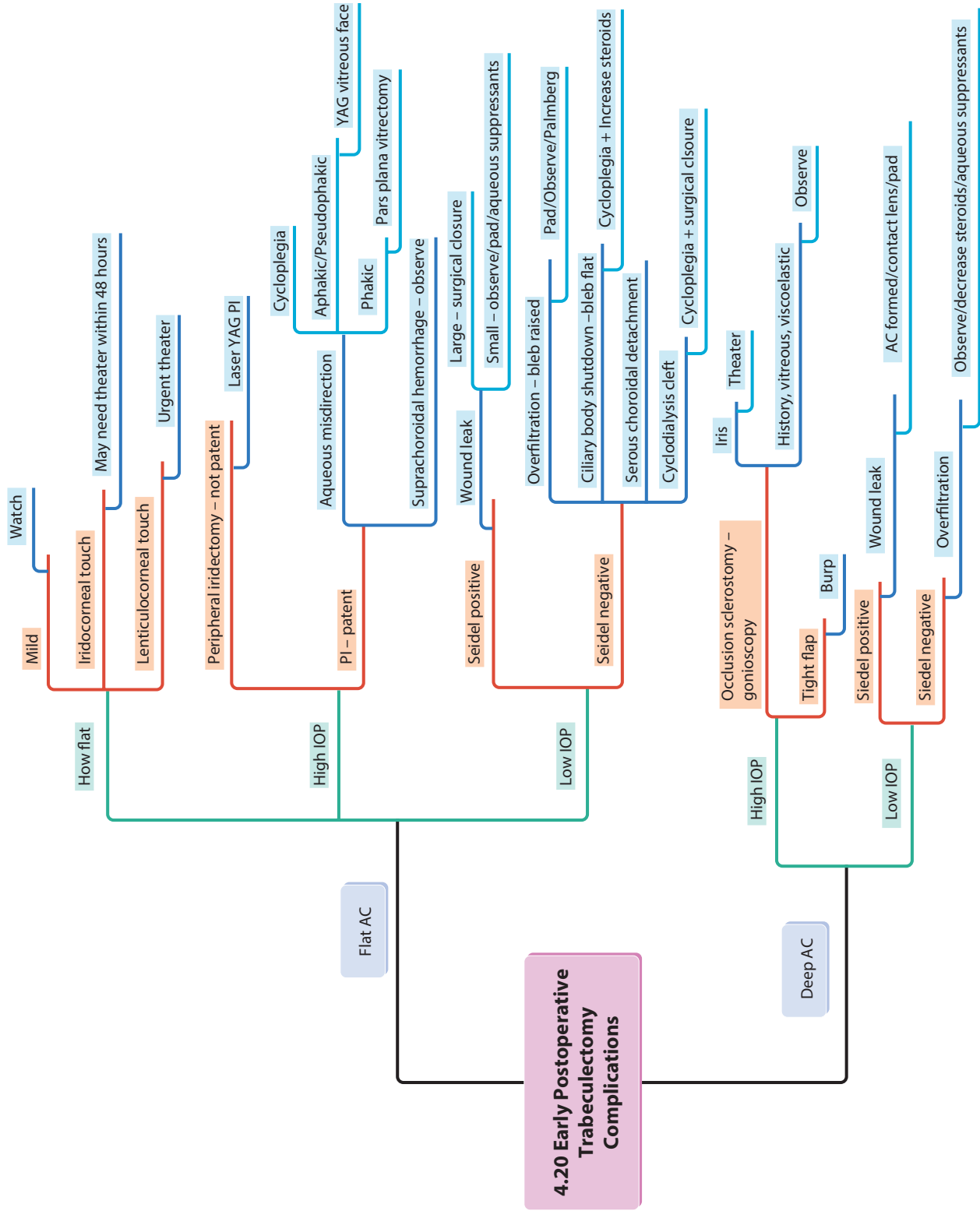
Tumor

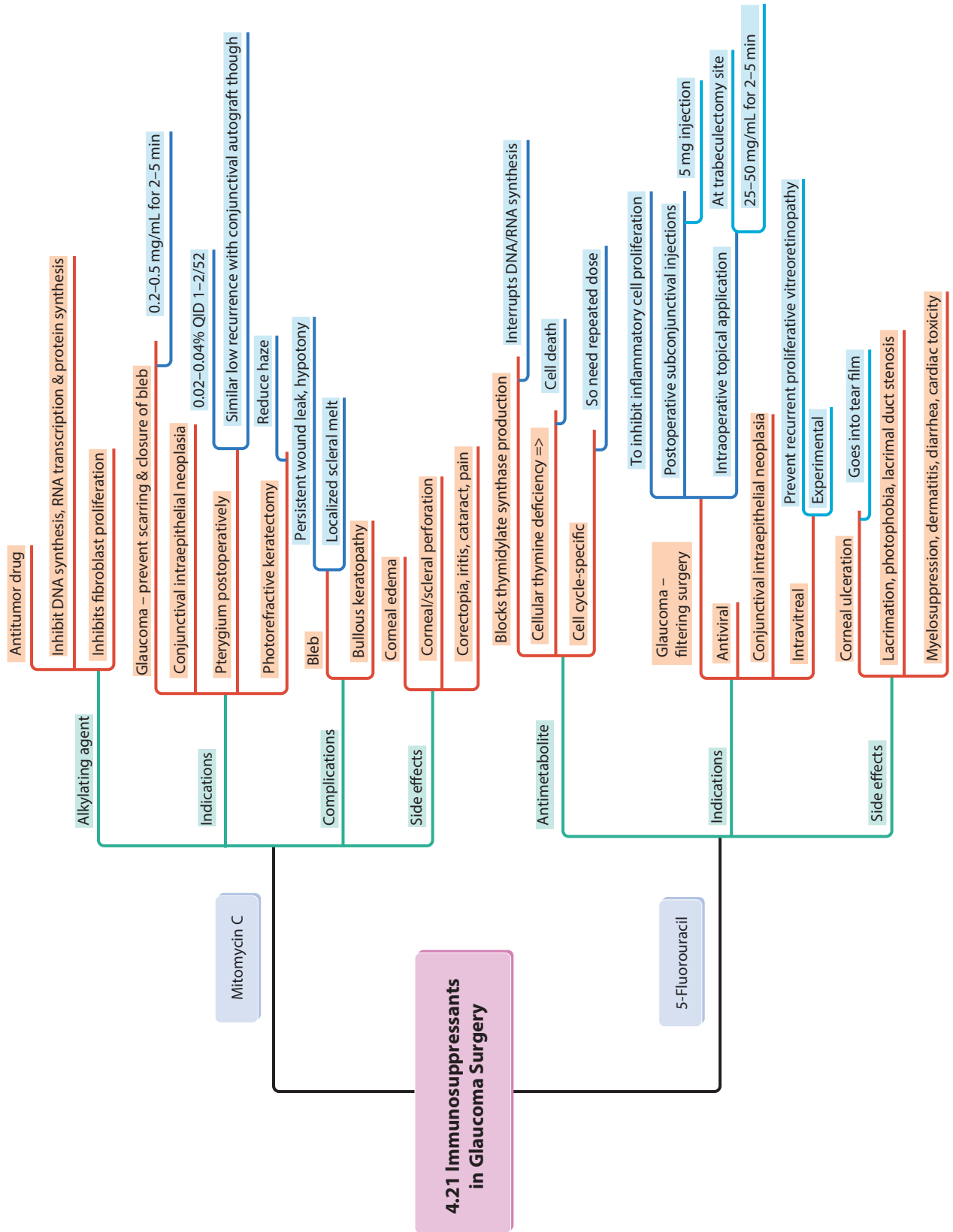
Choroidal swelling

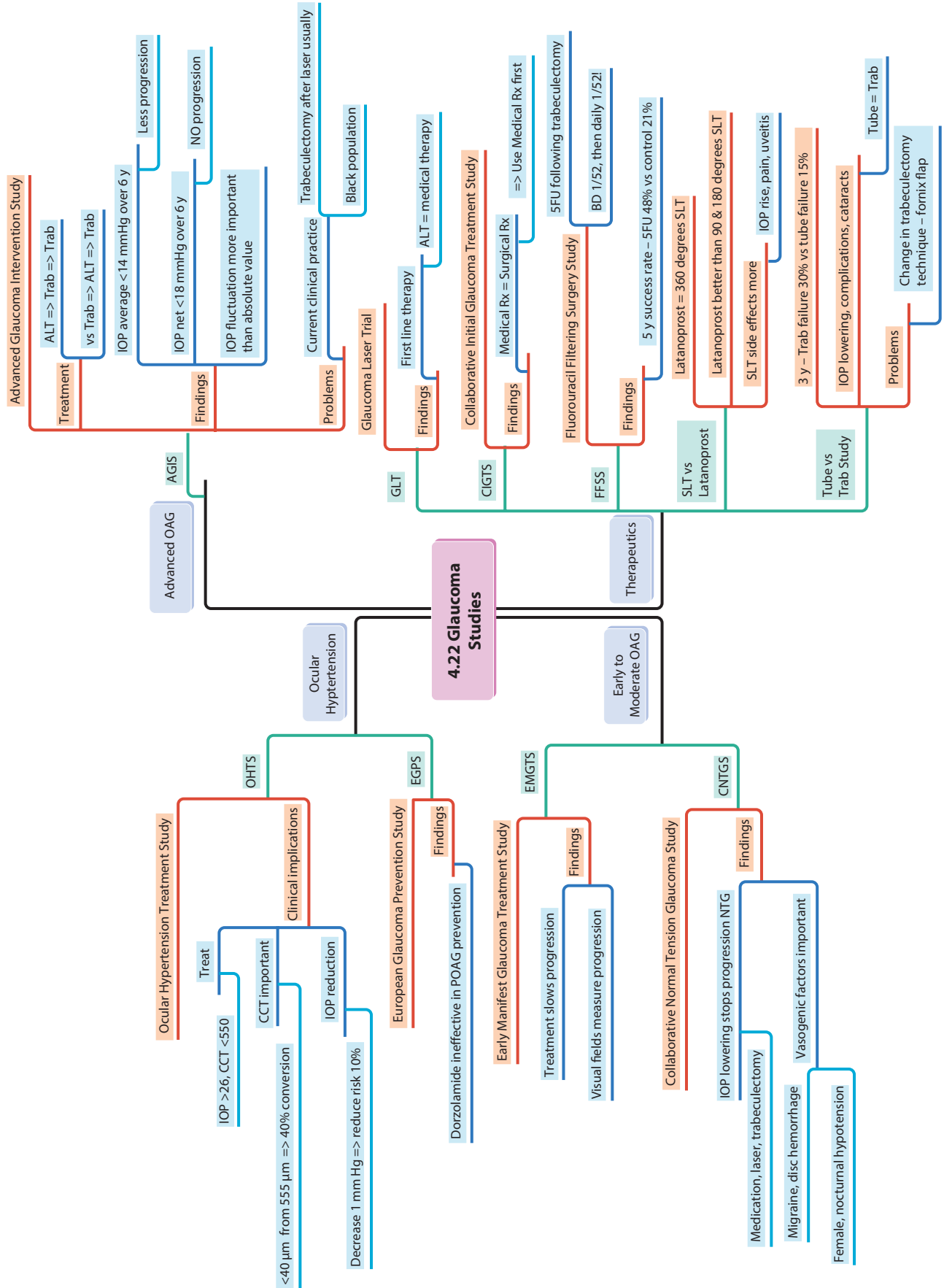
Surgery



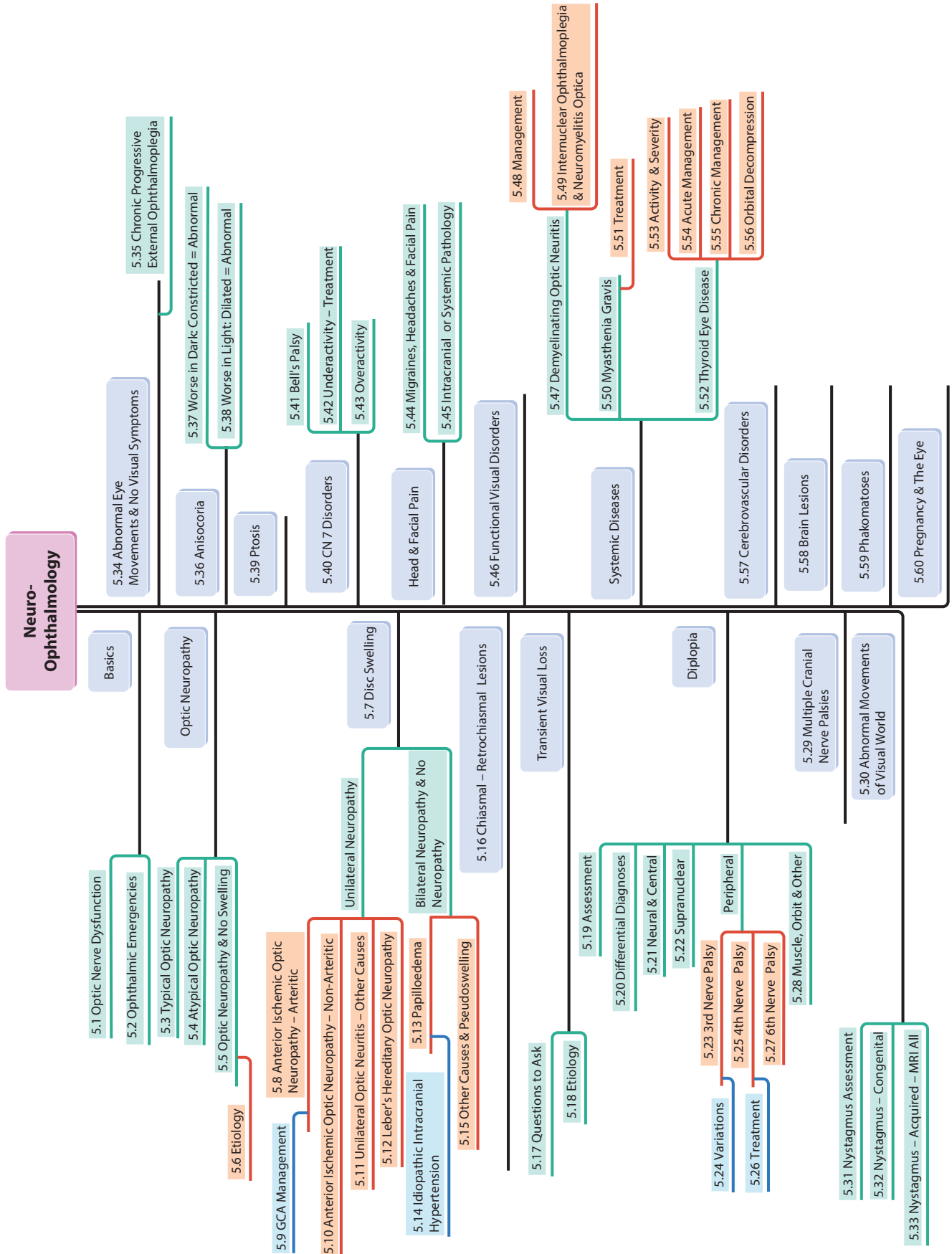


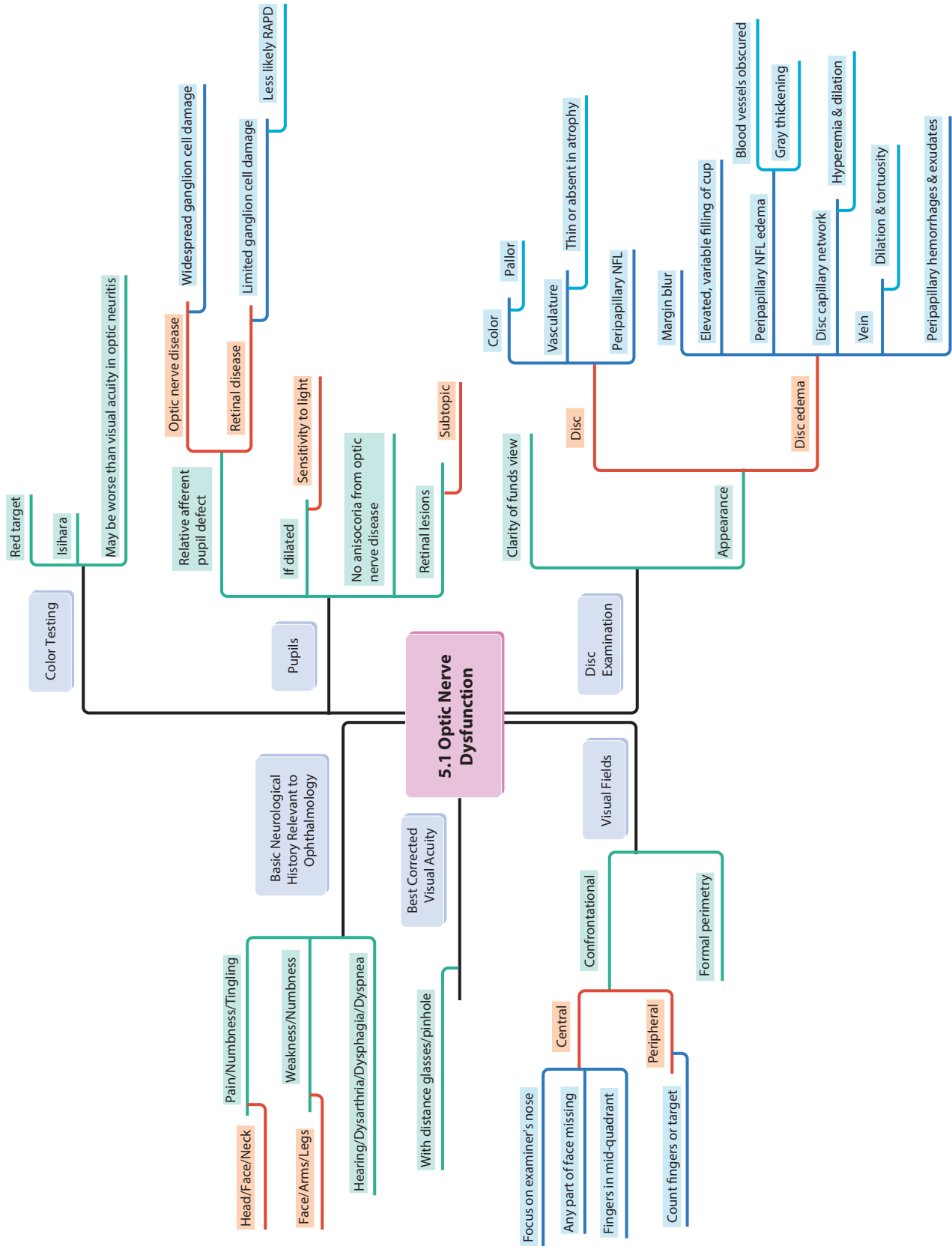


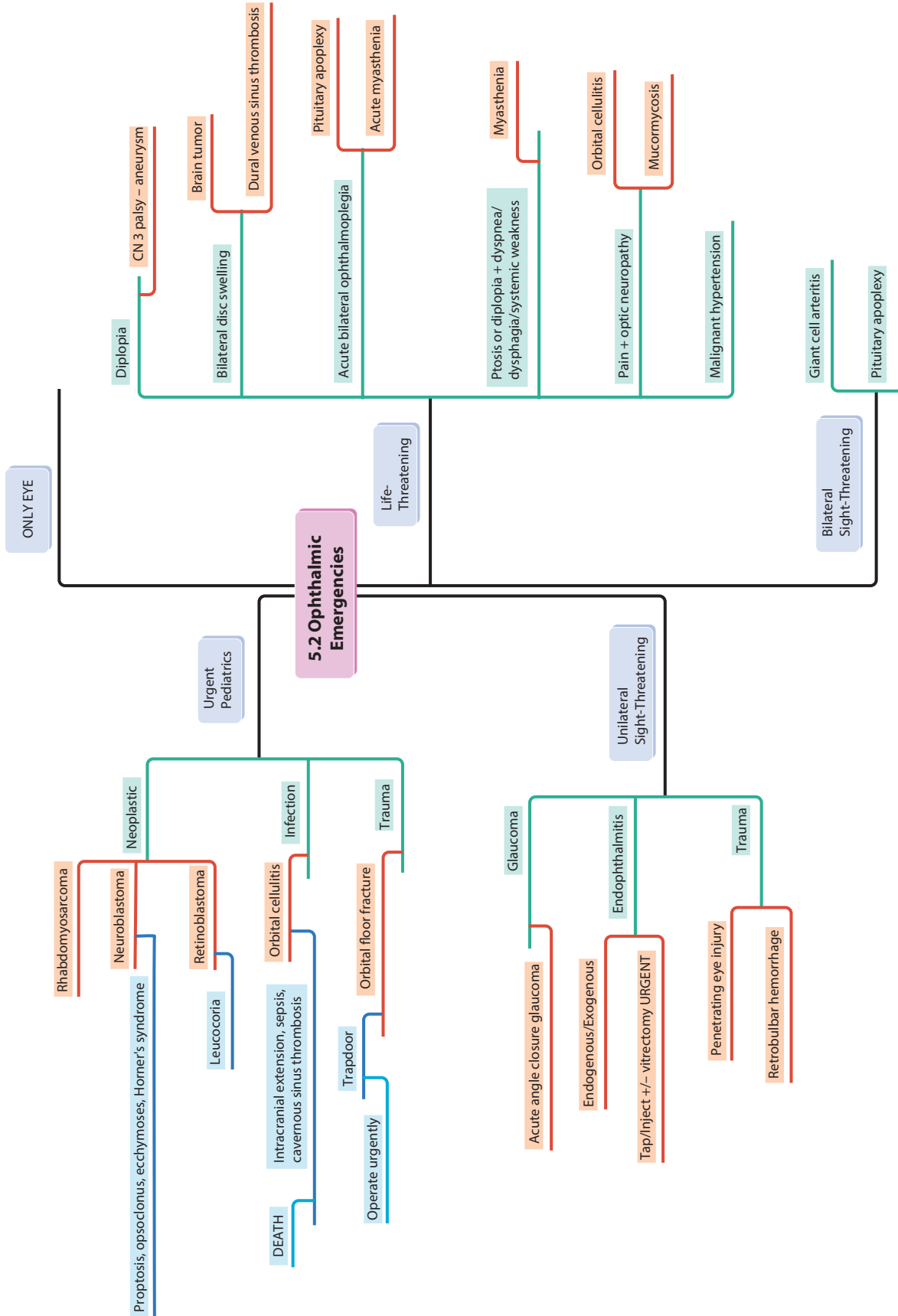


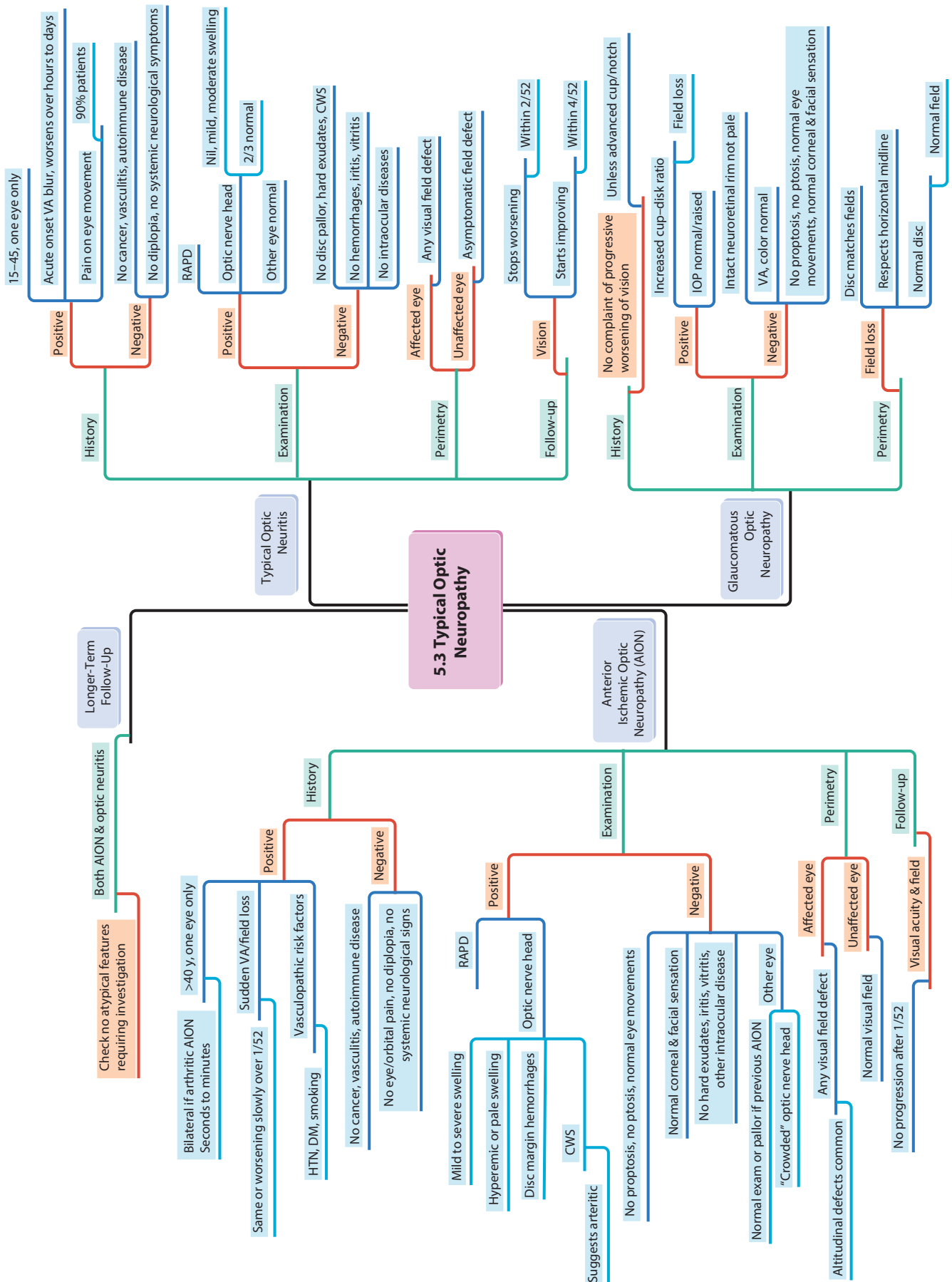


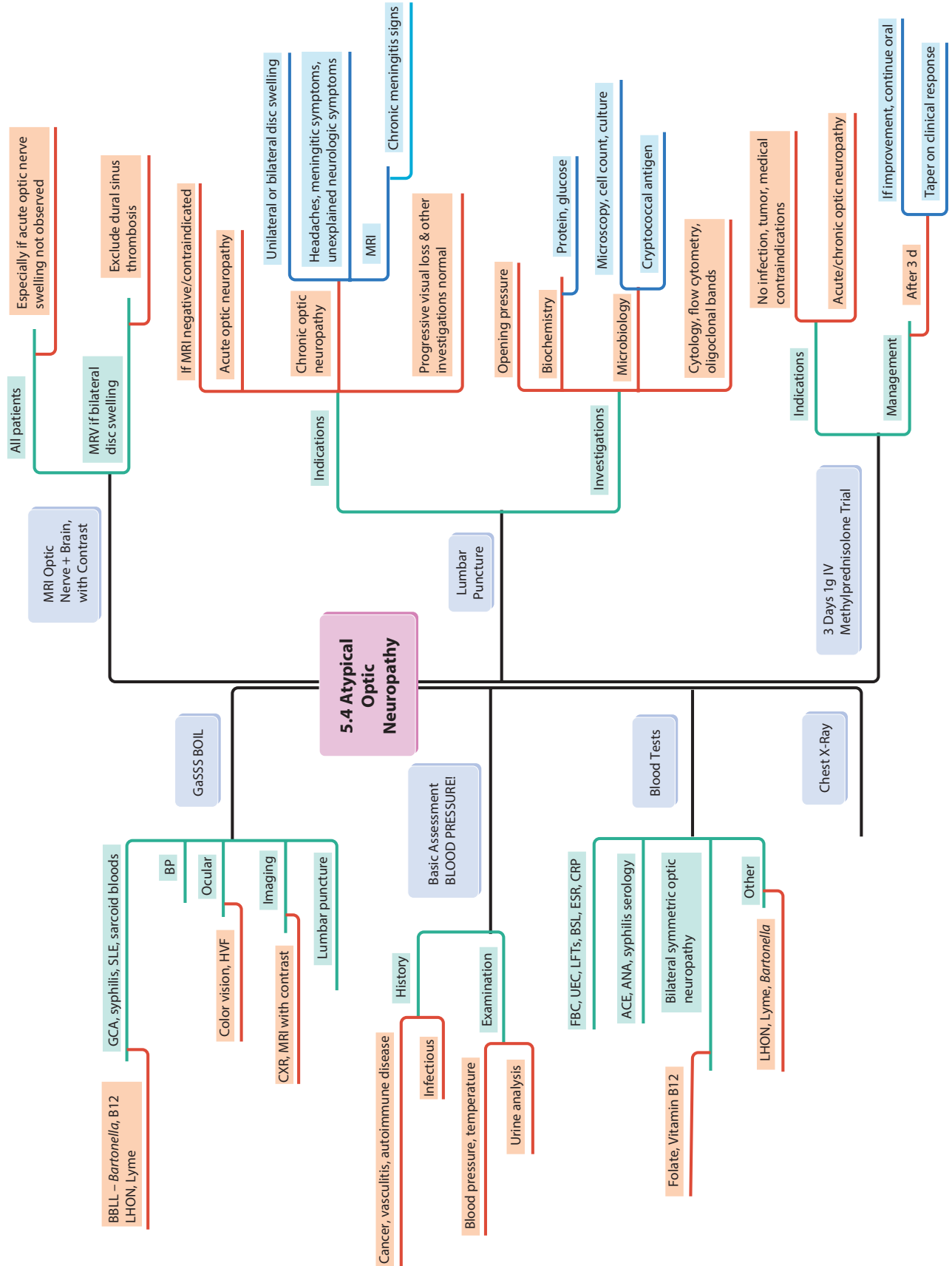
5 Neuro-Ophthalmology

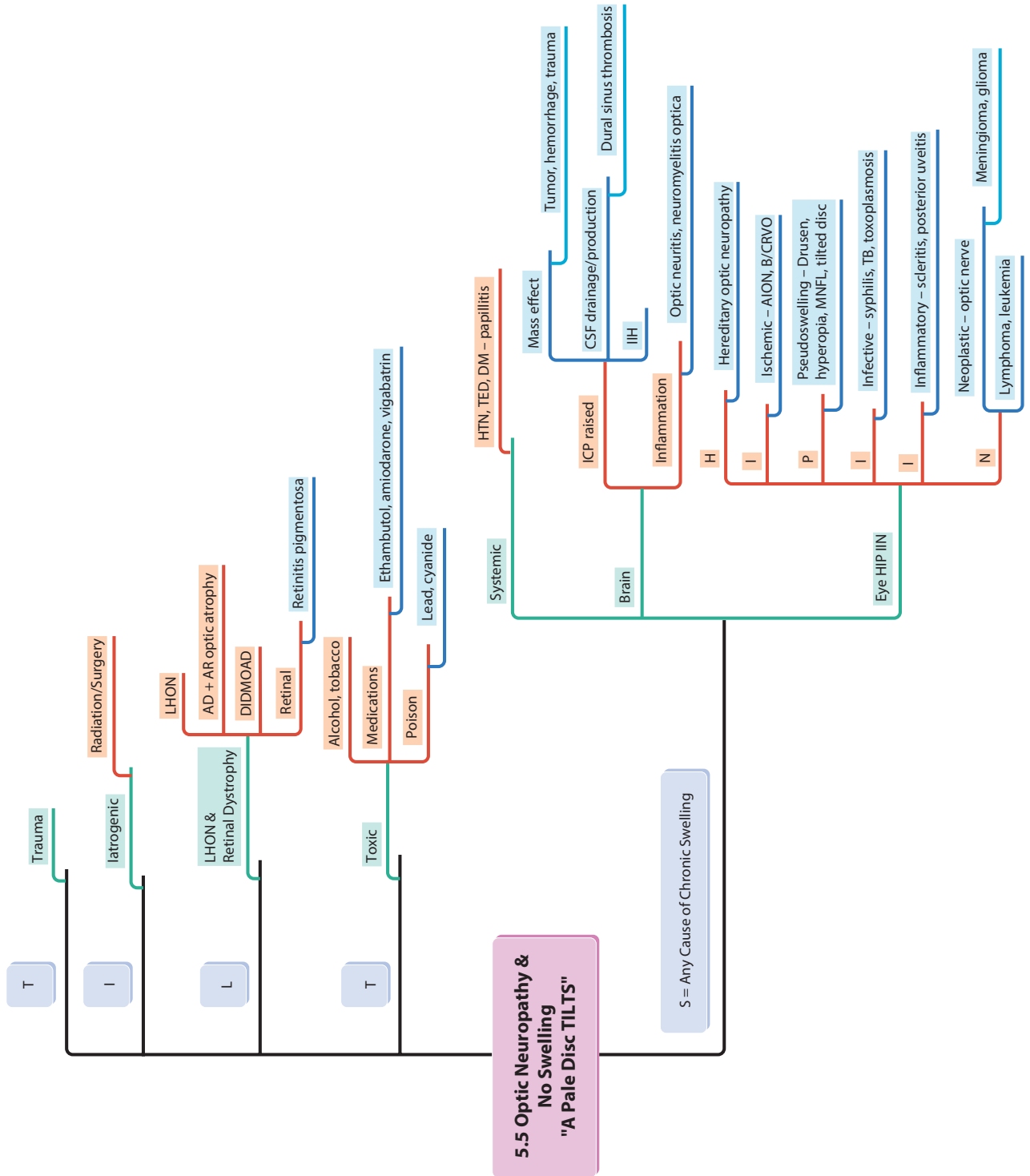


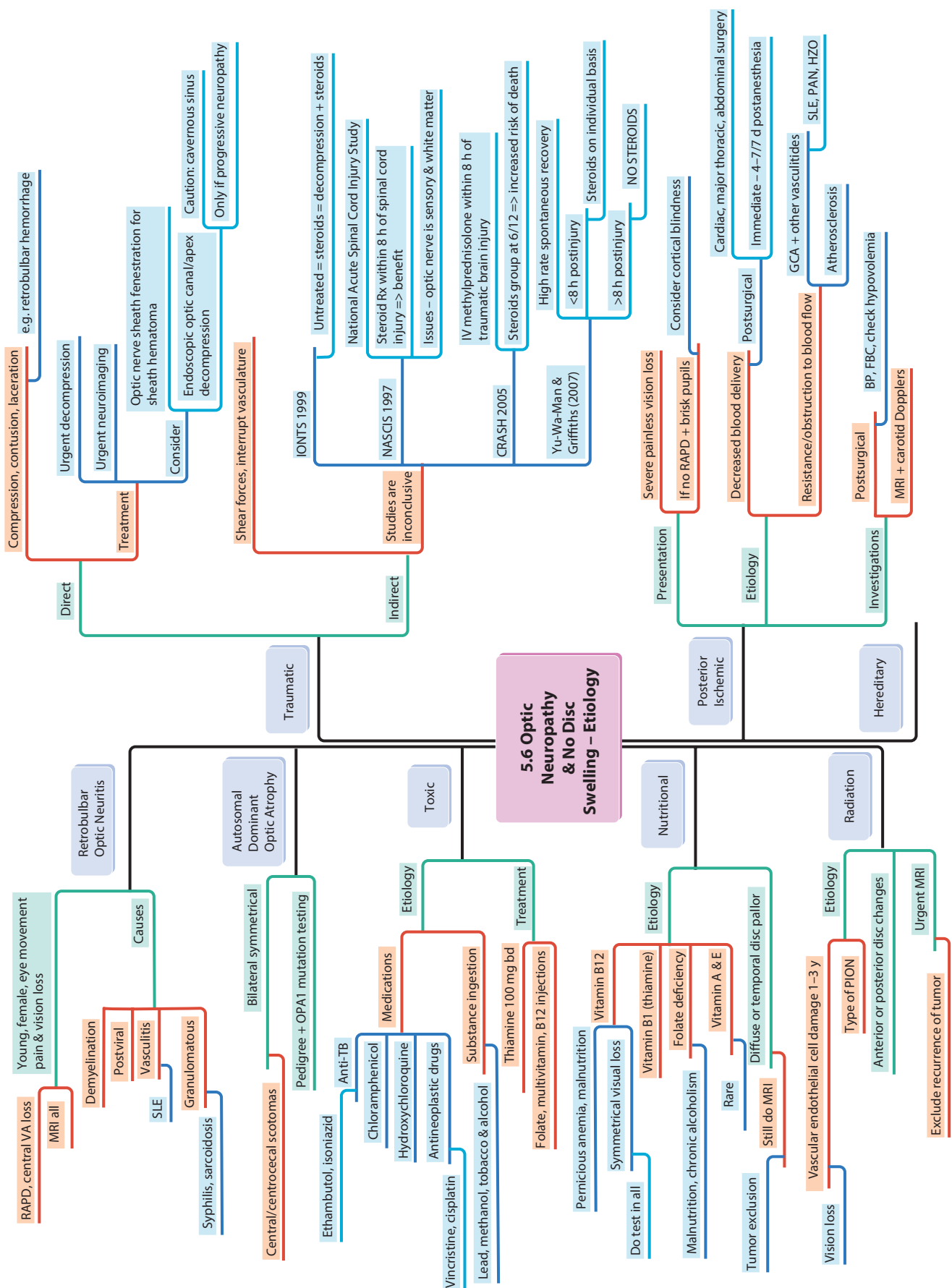


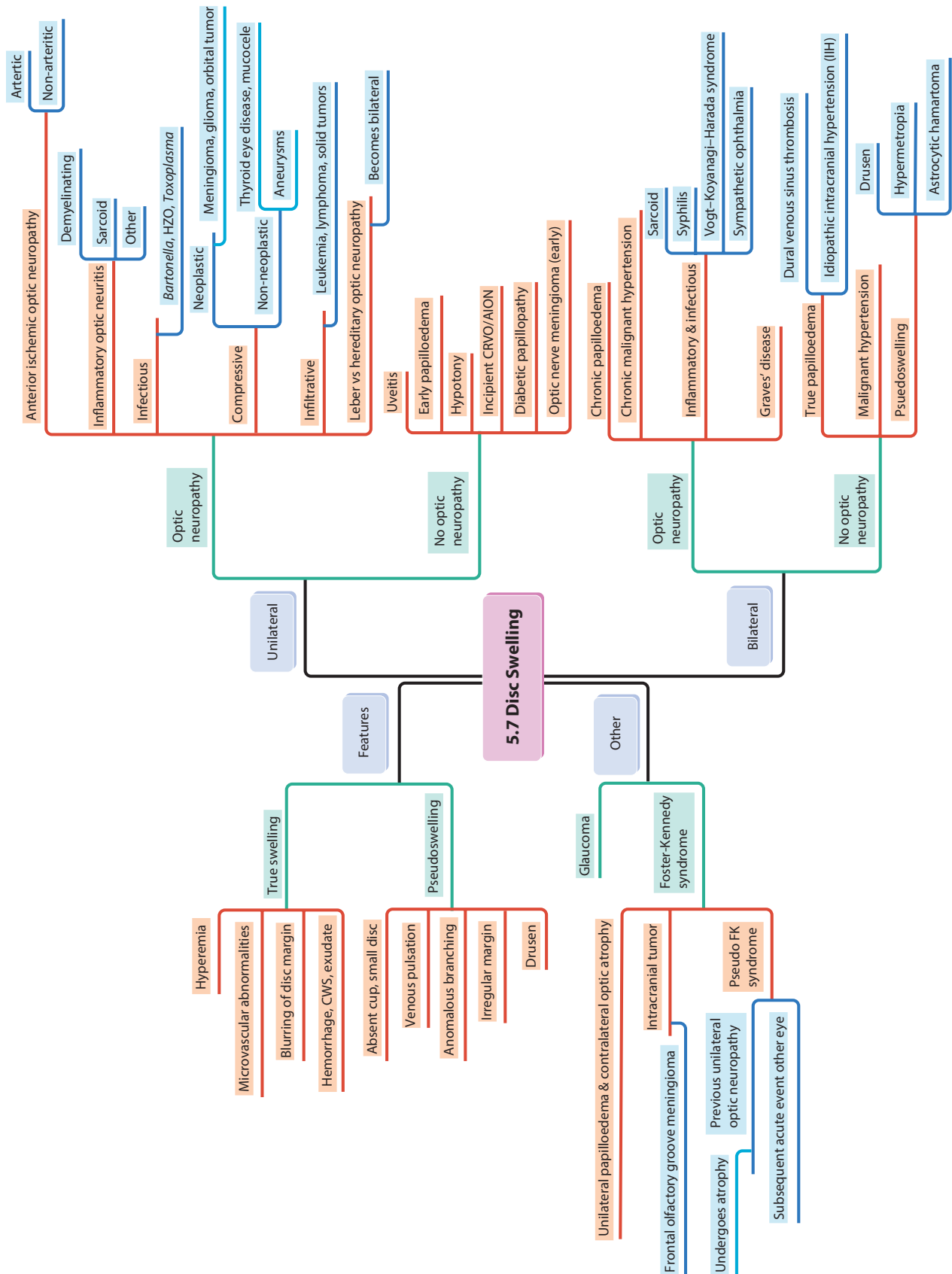


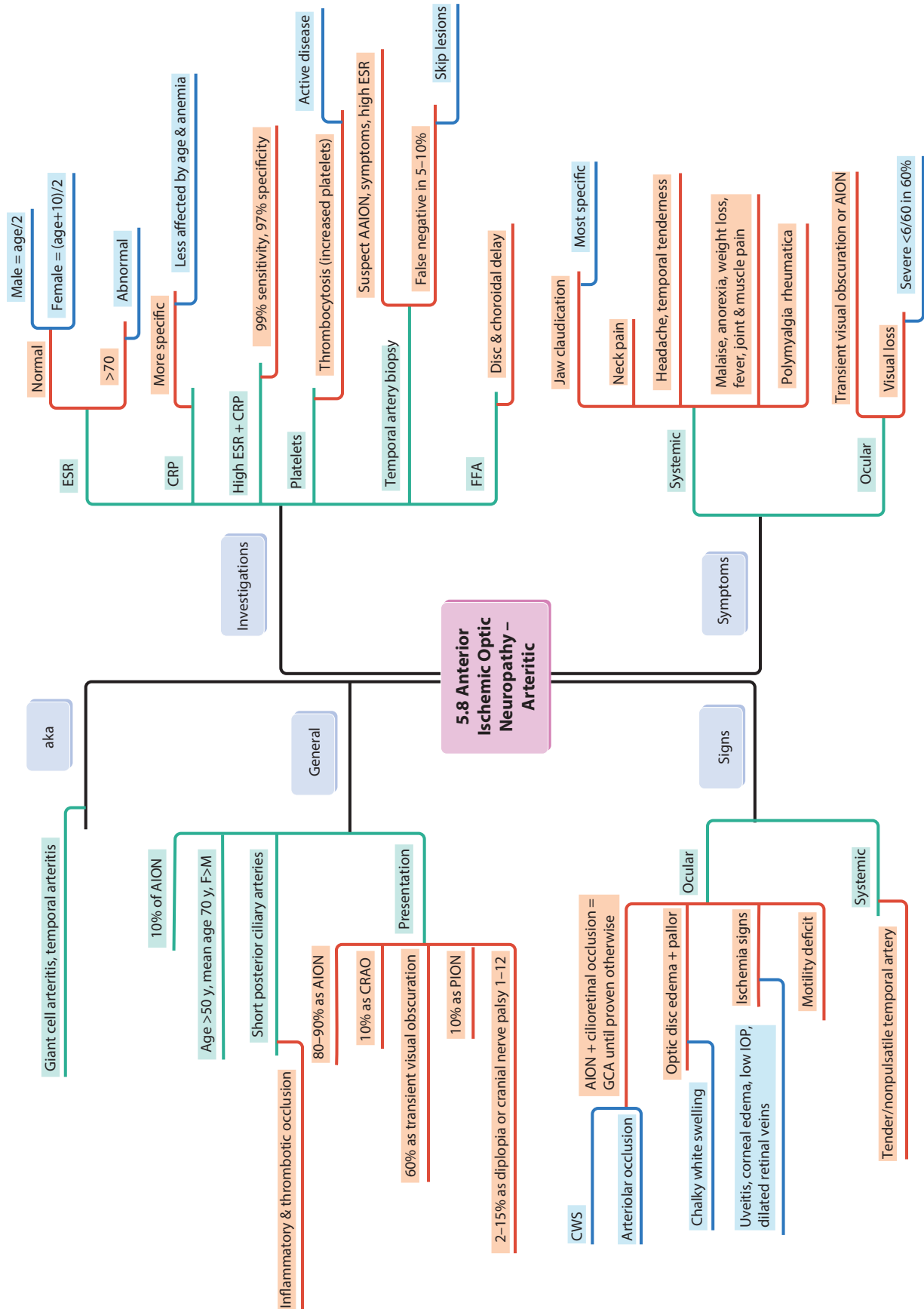


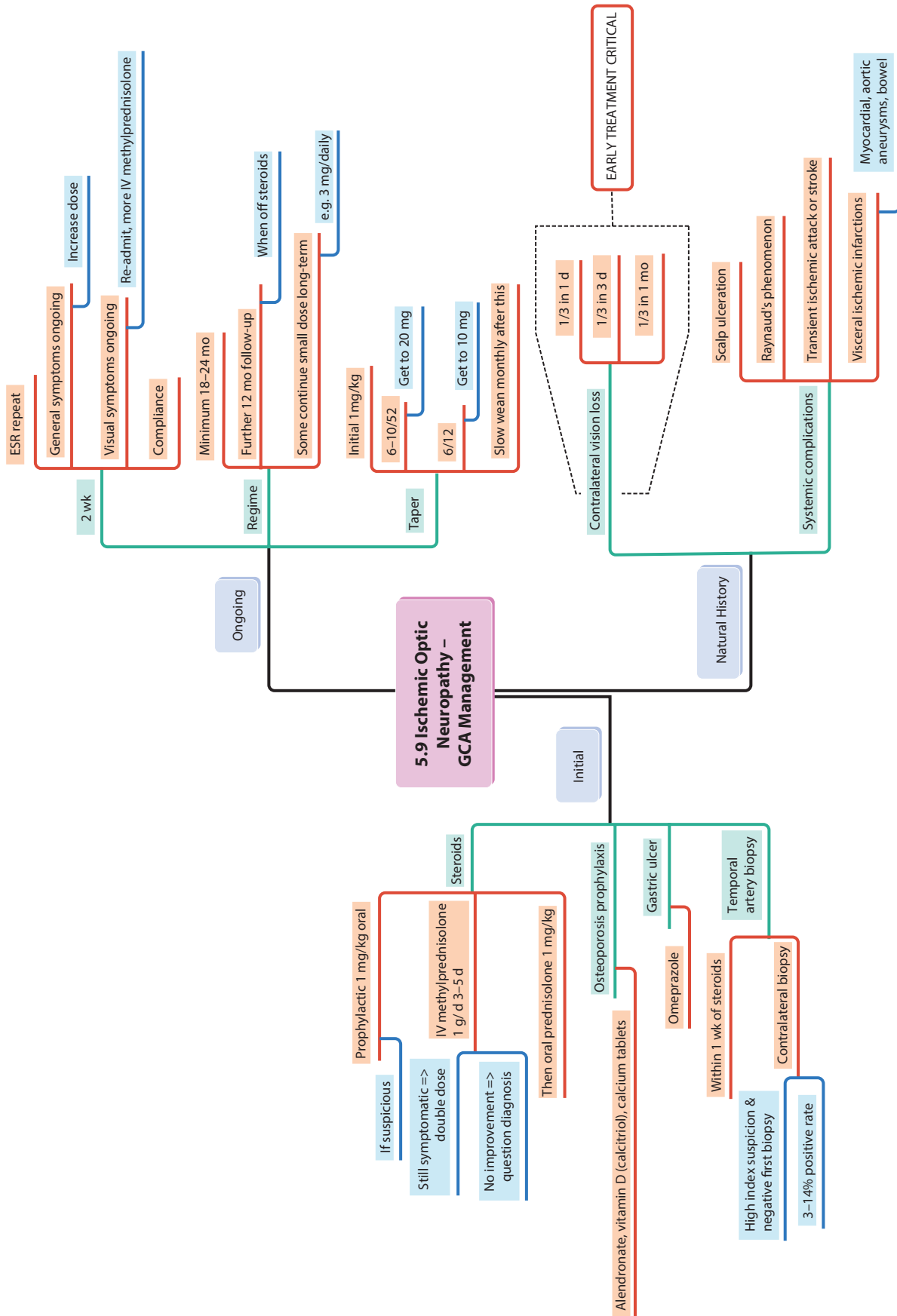


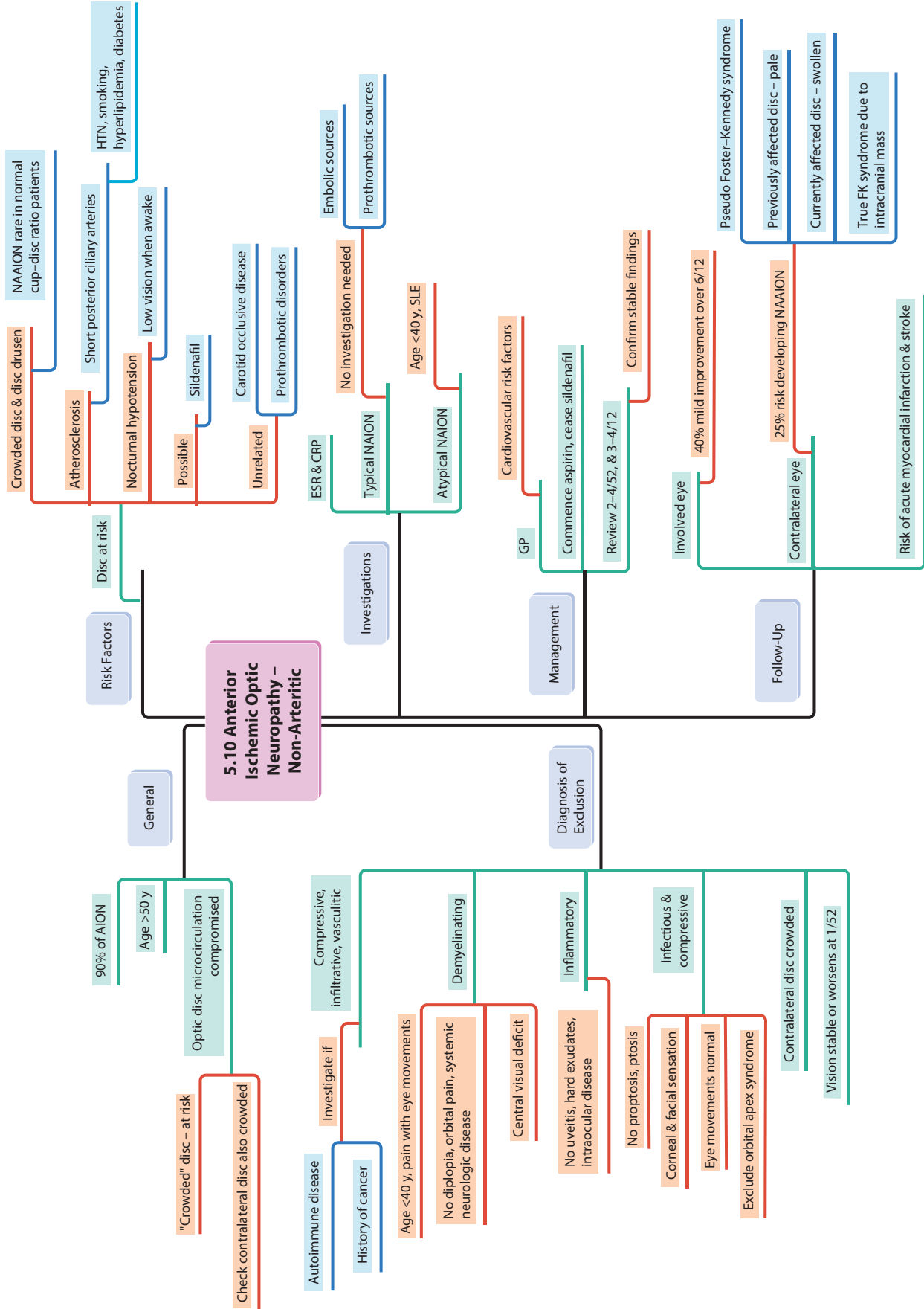


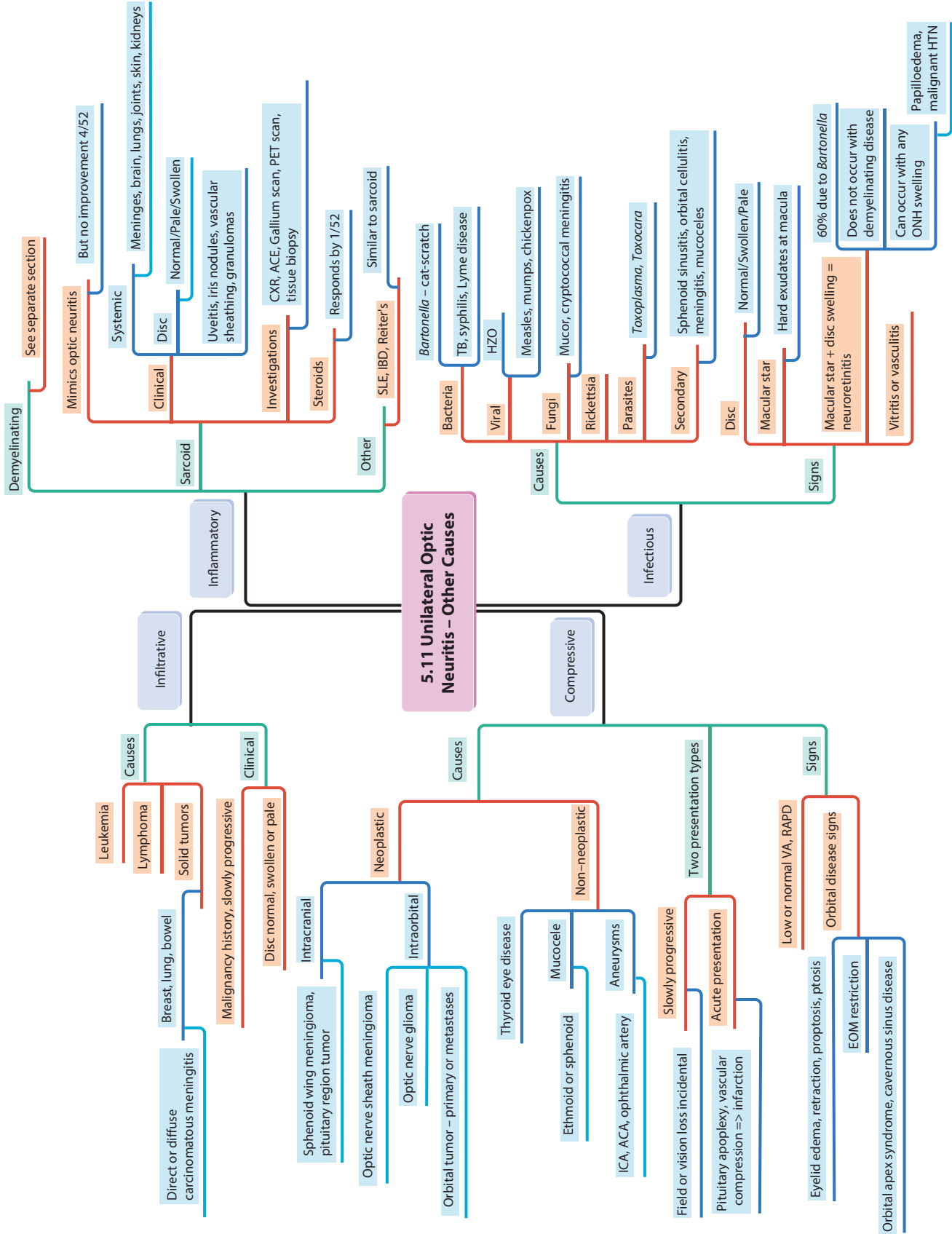


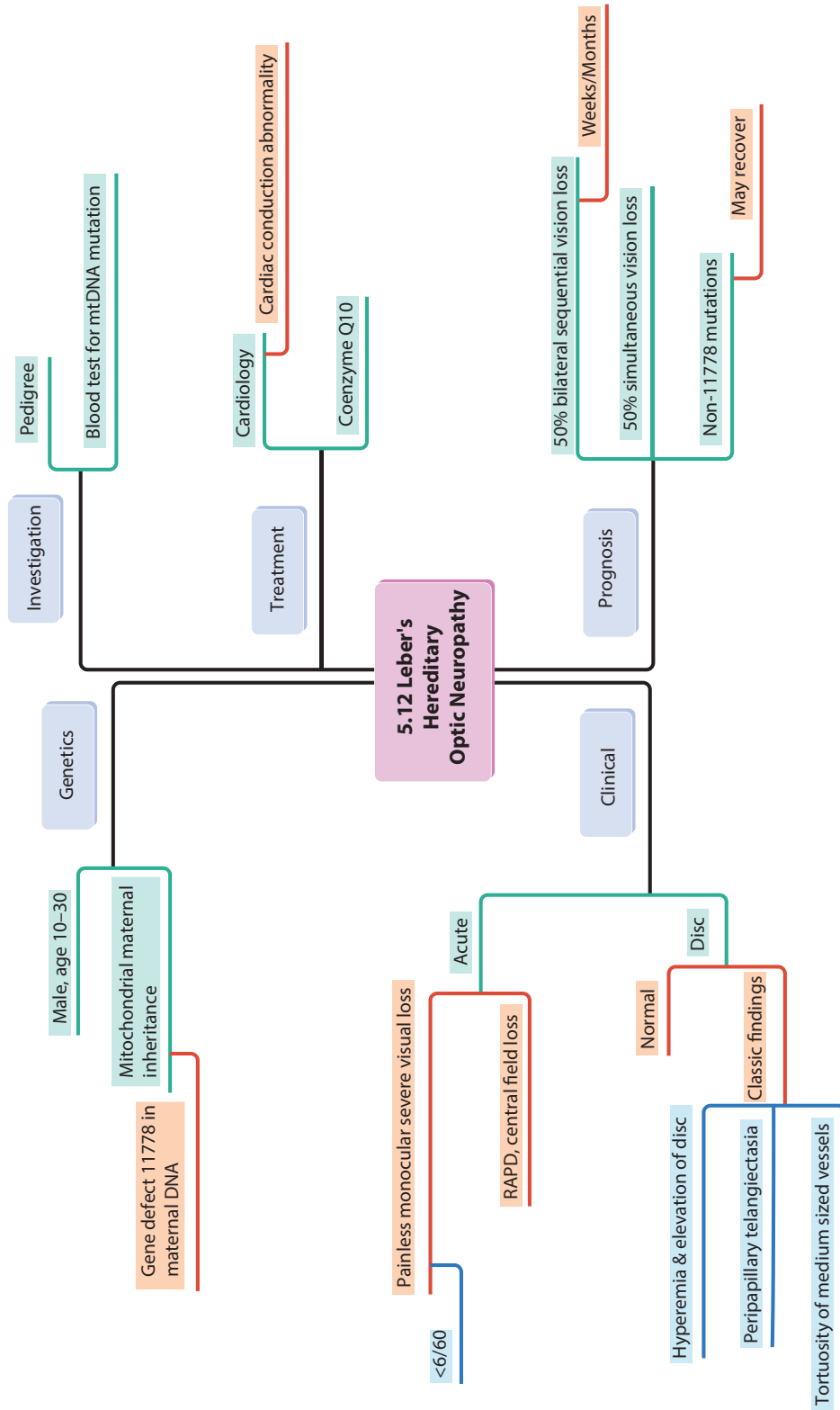


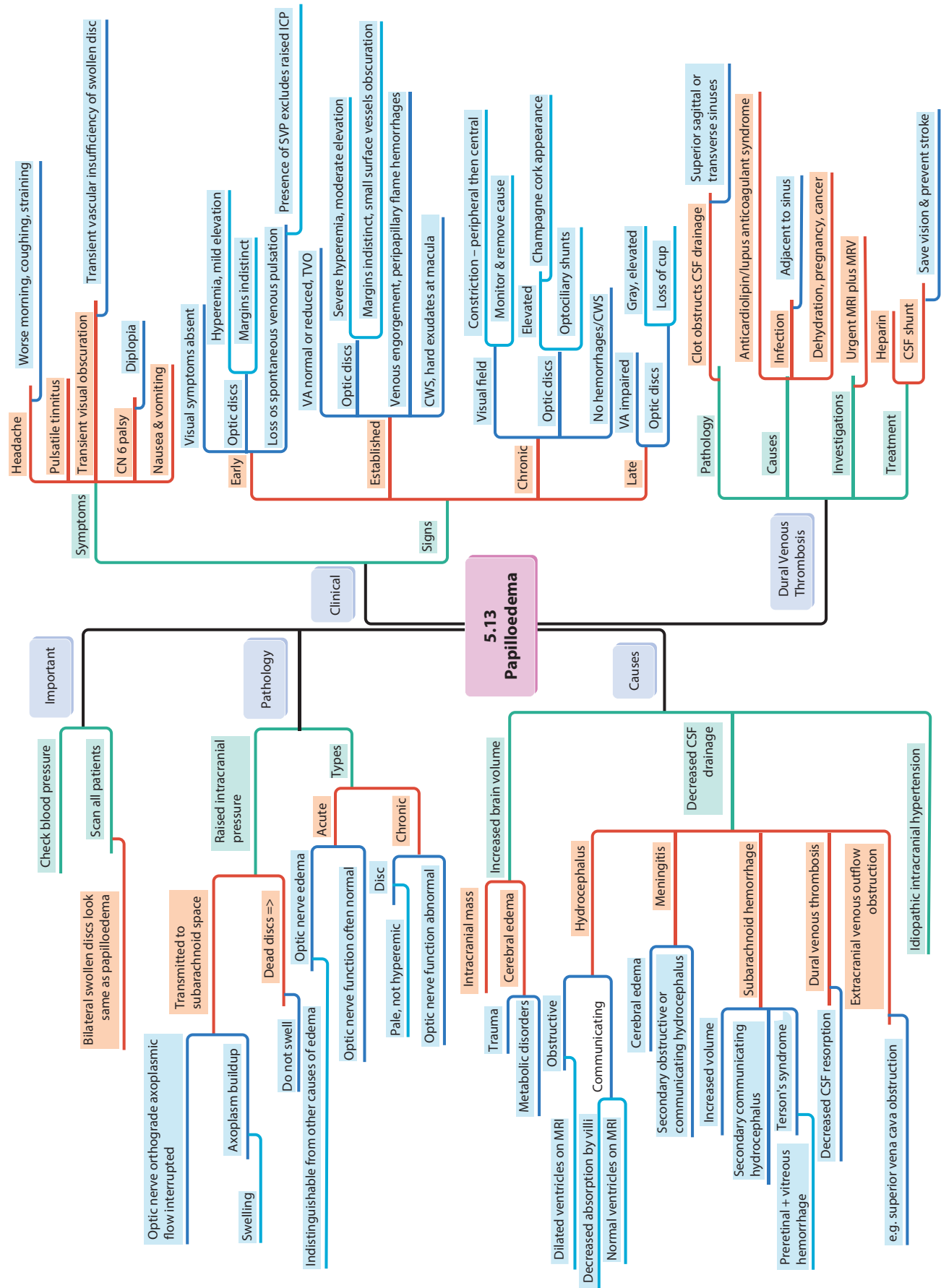


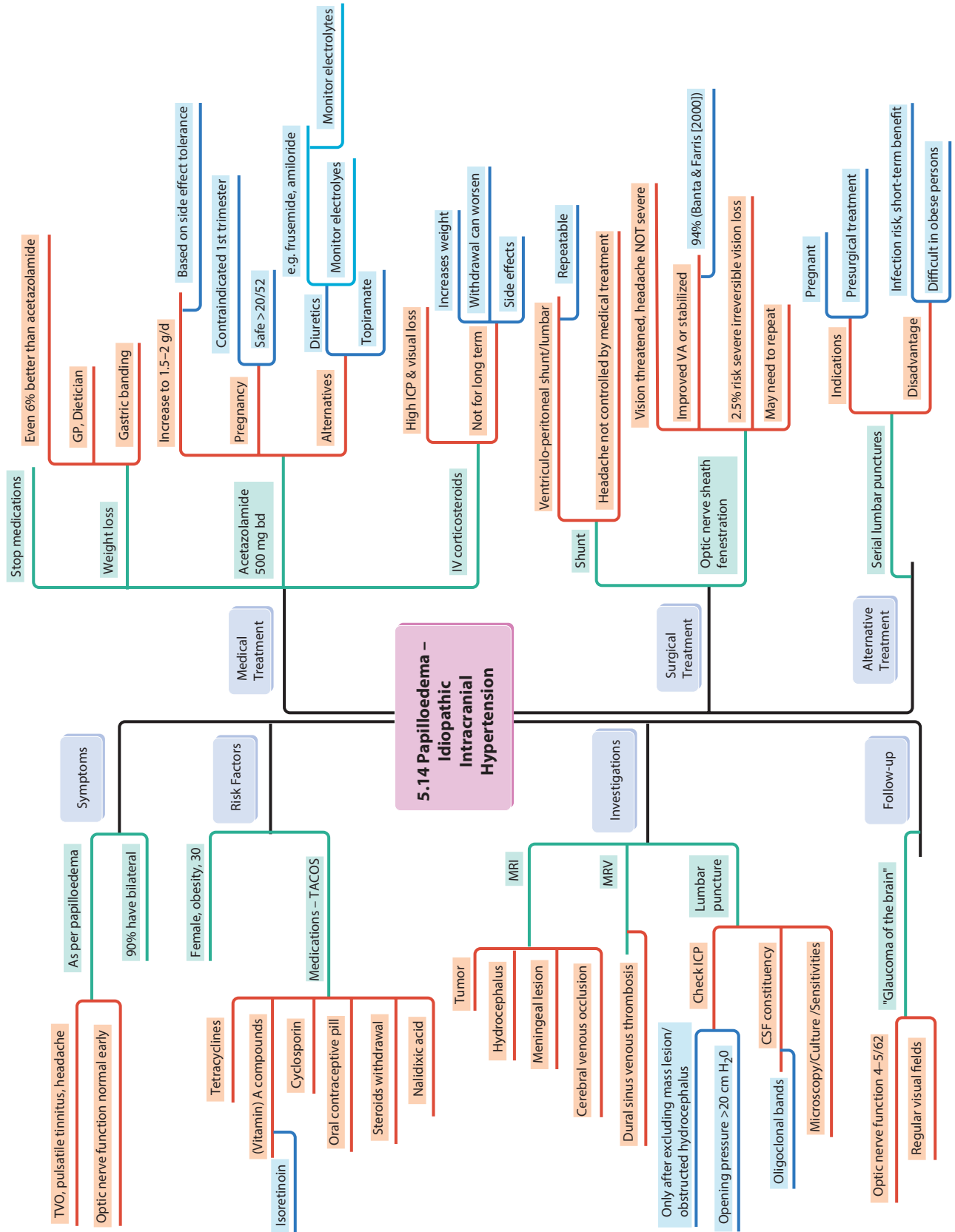


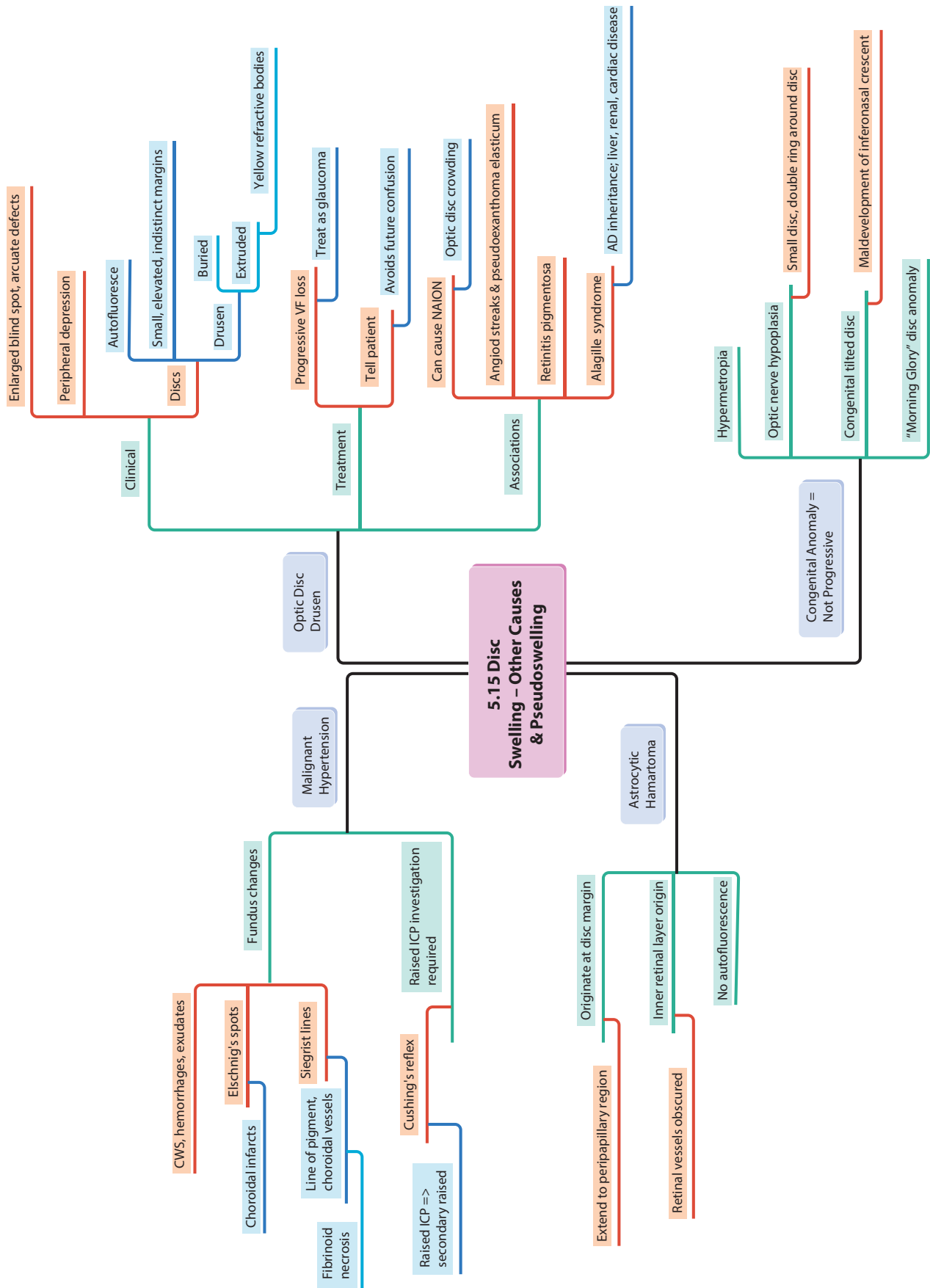


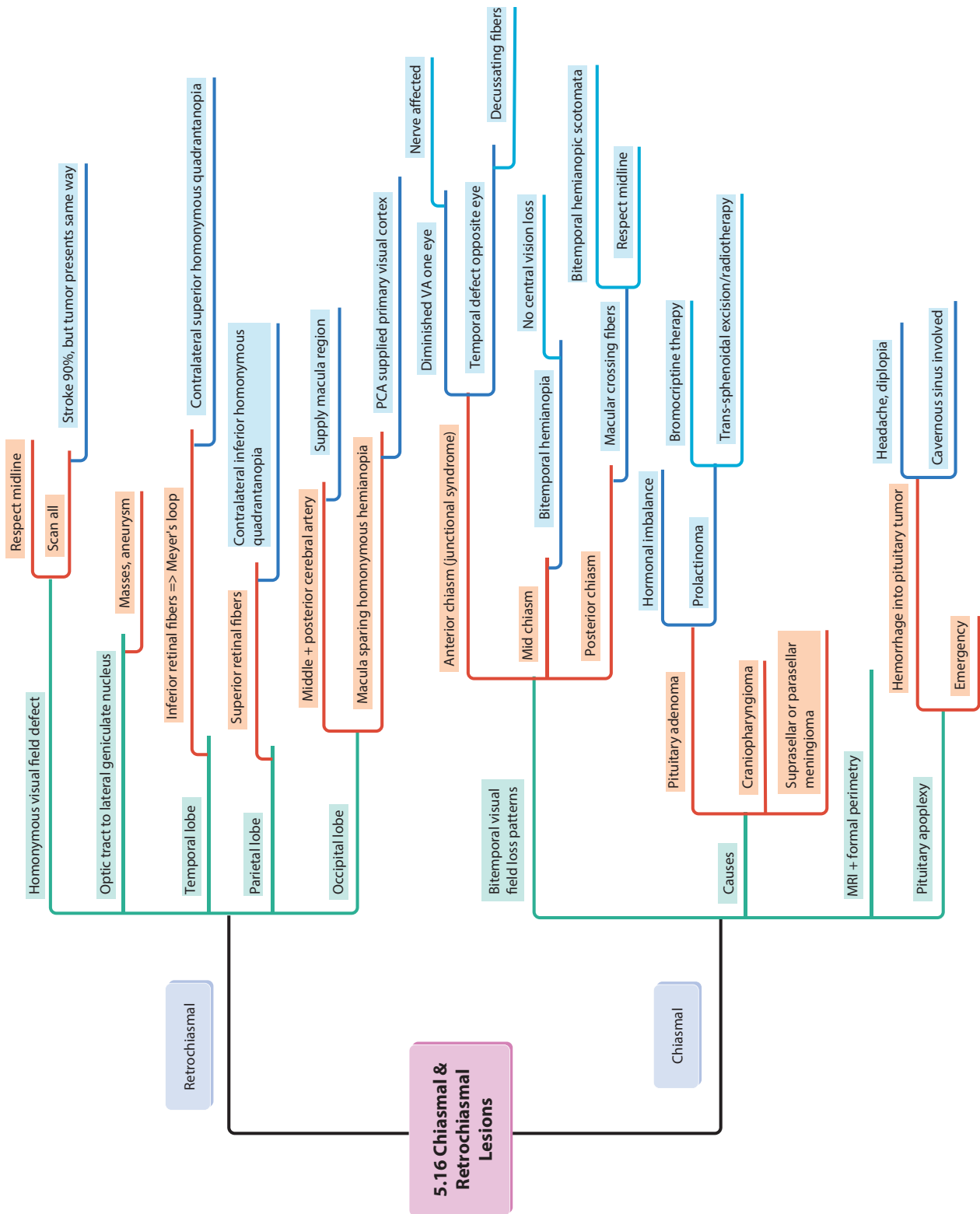


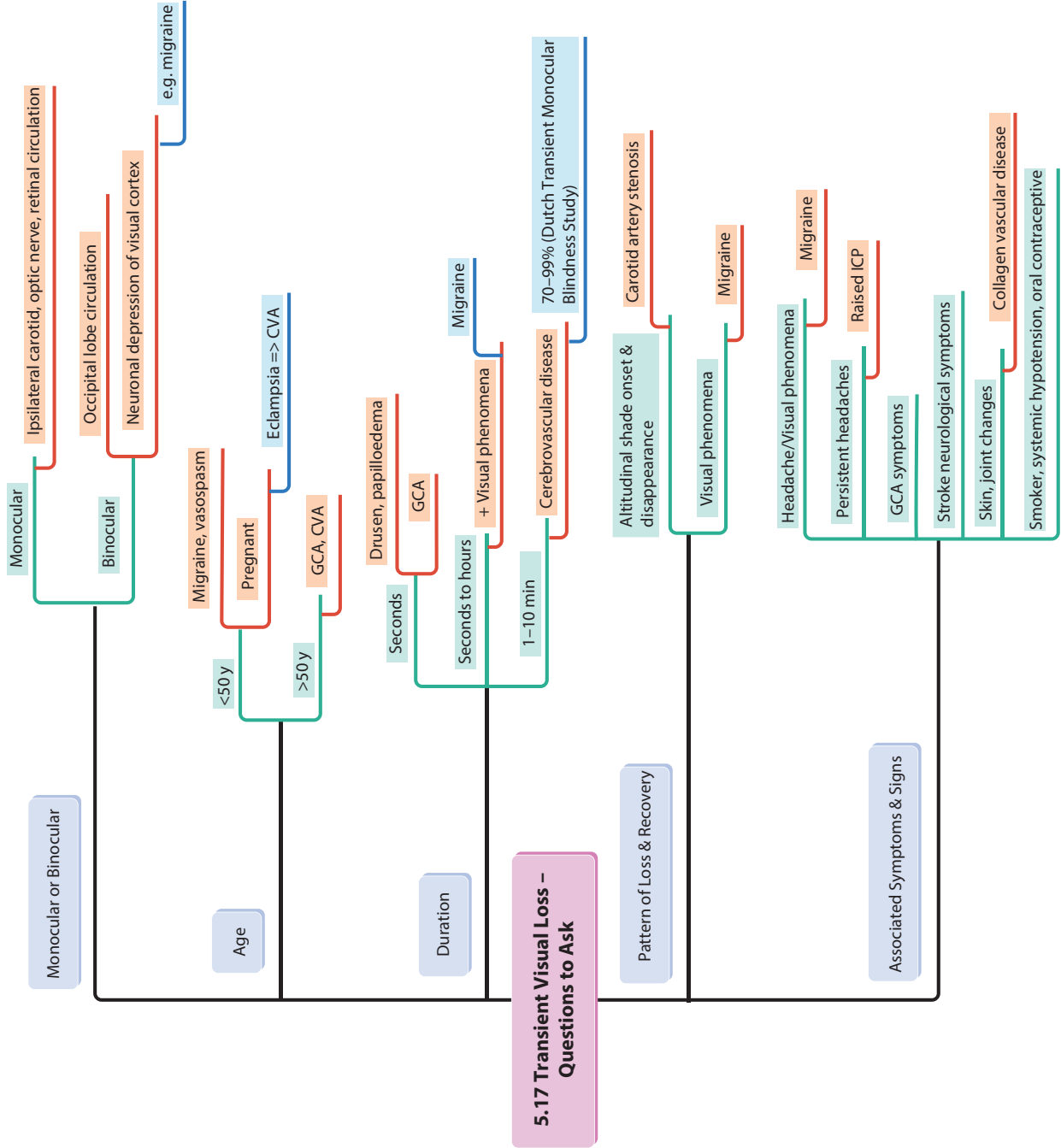


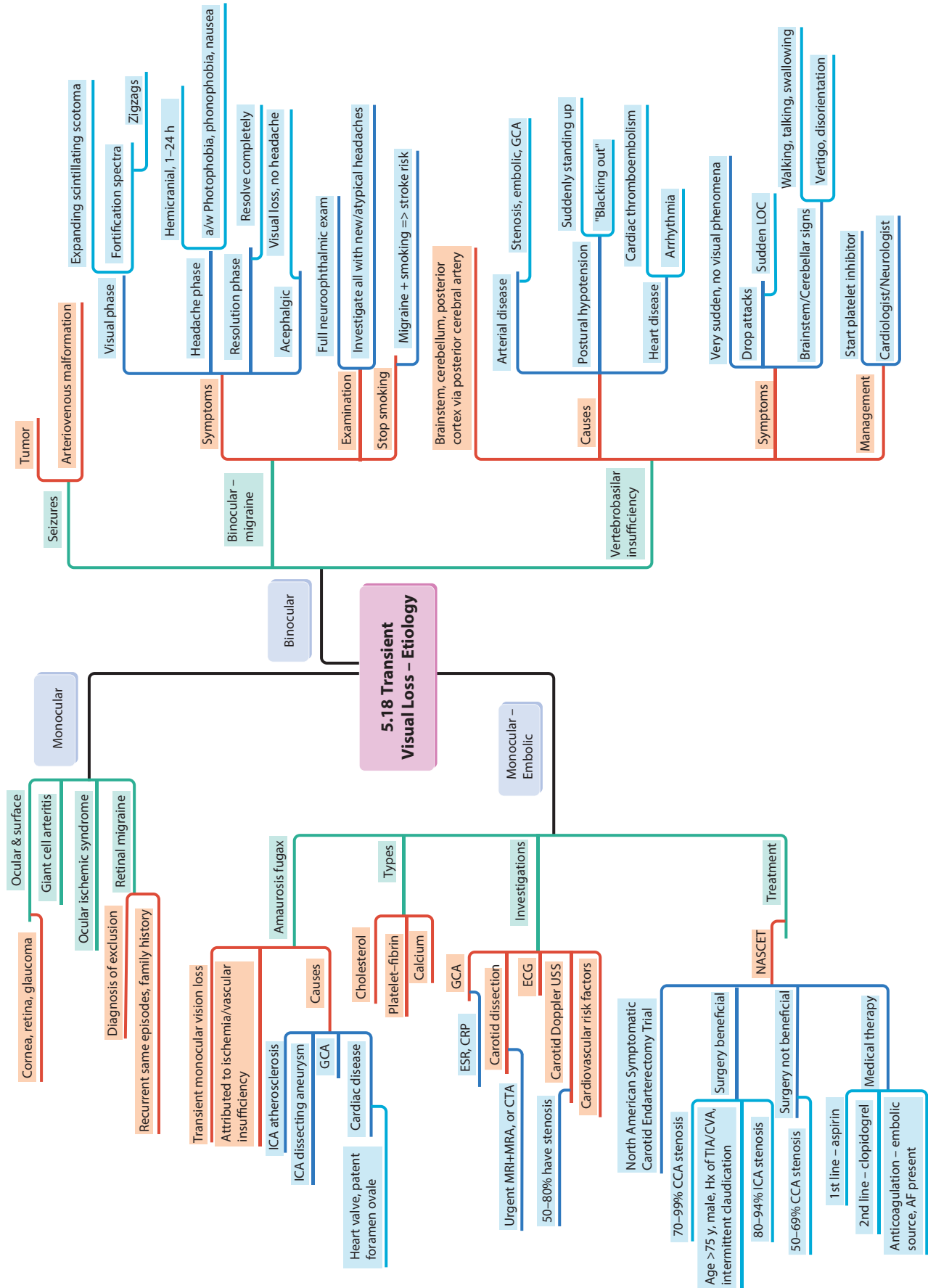


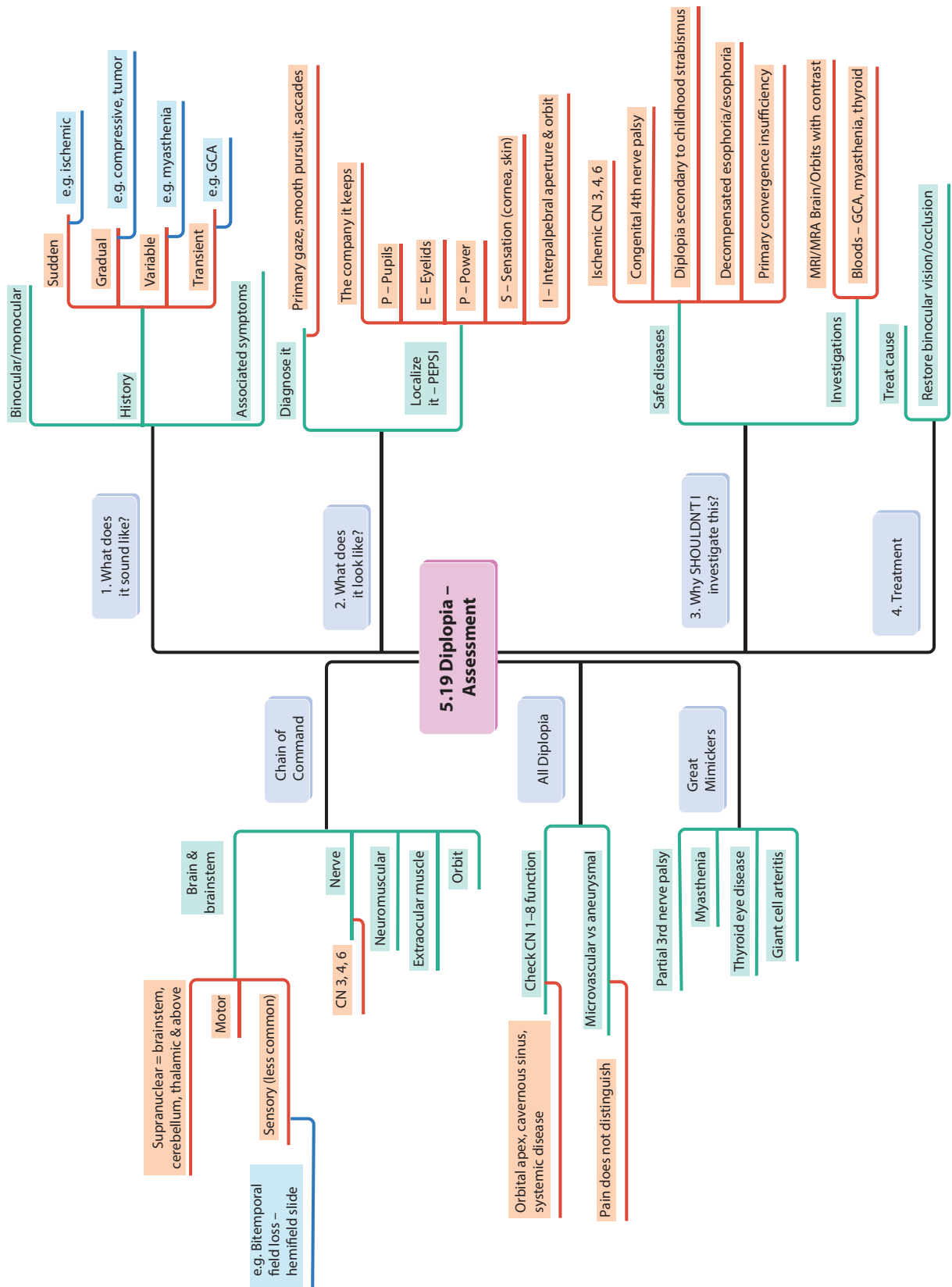


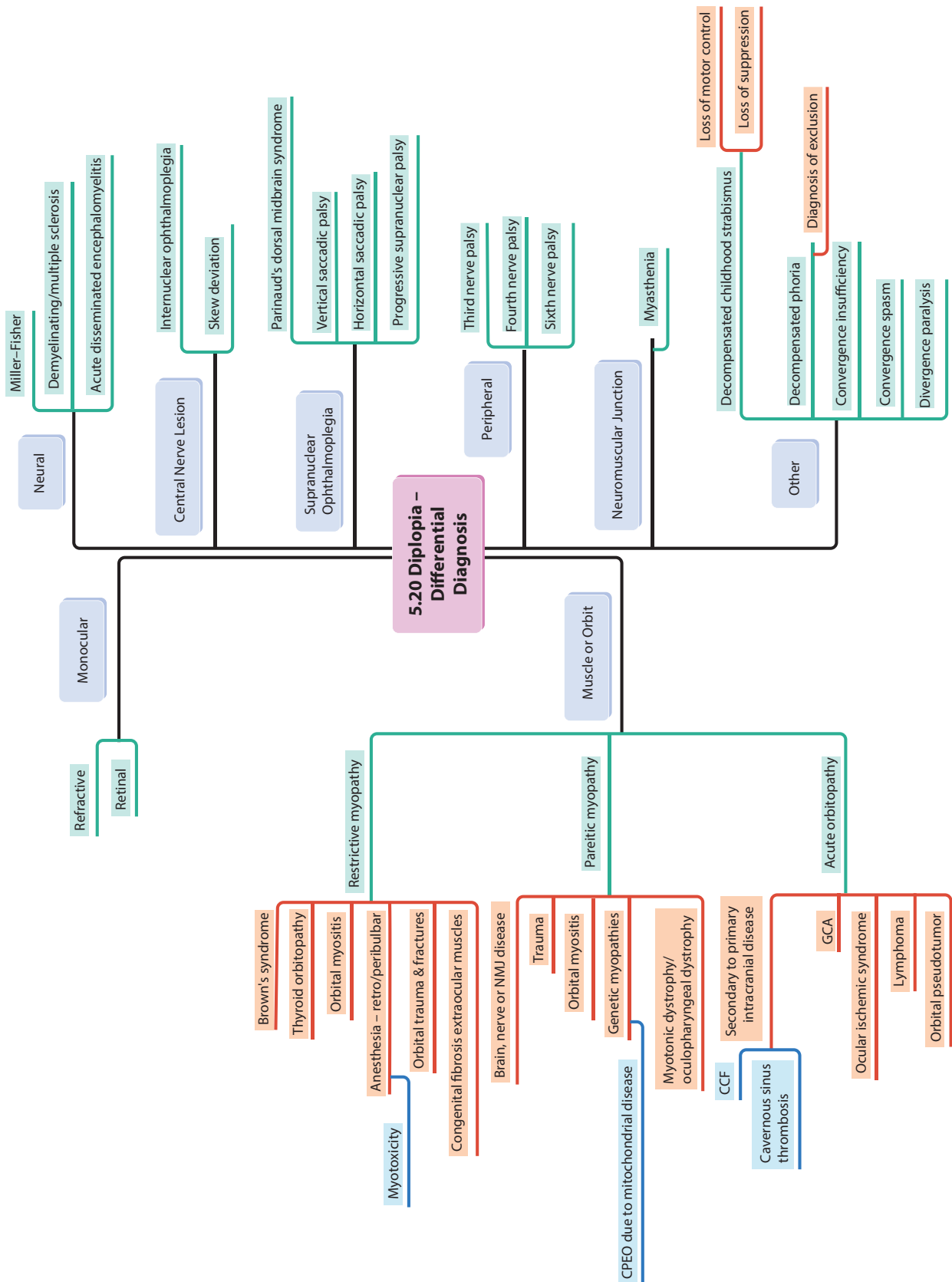


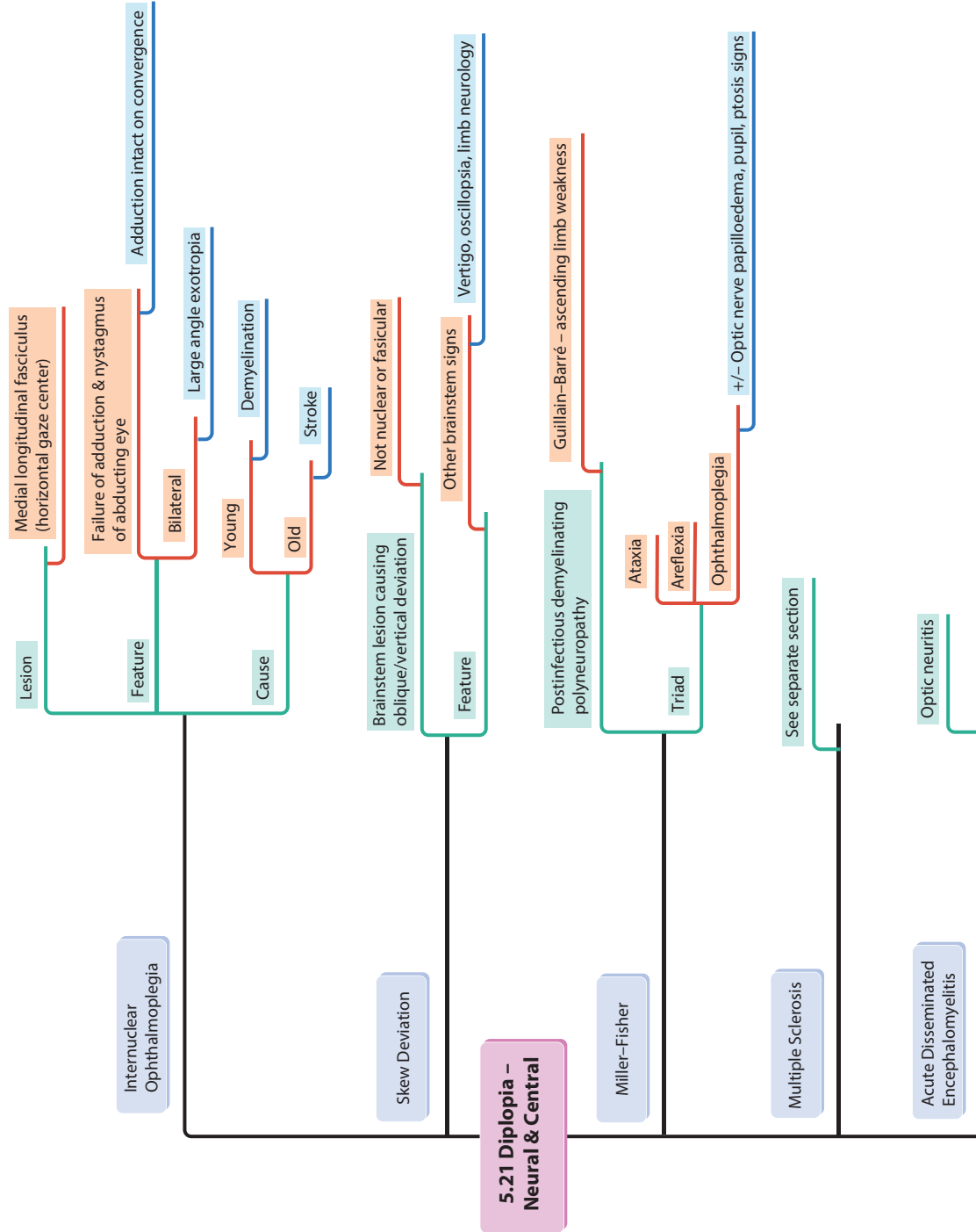


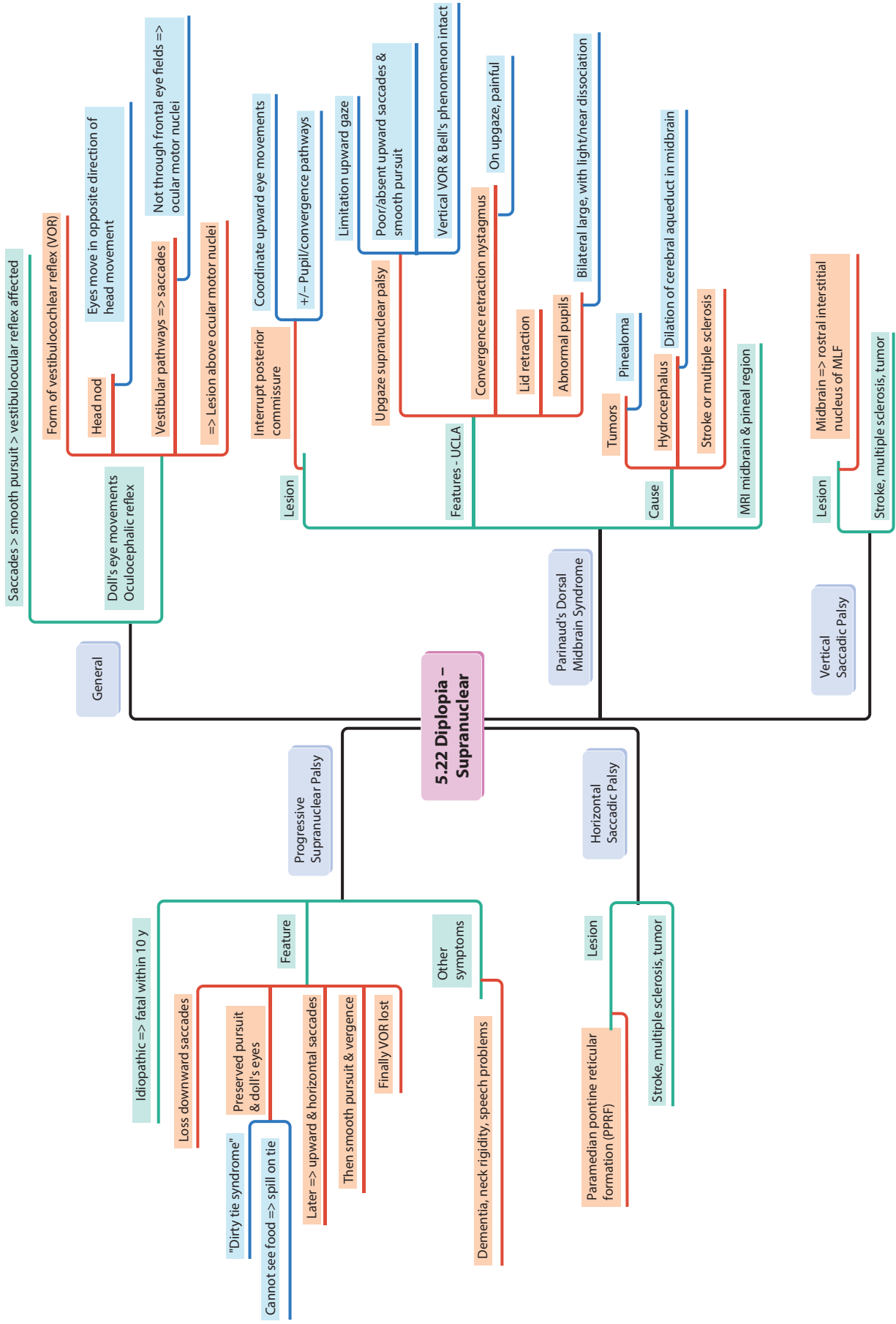


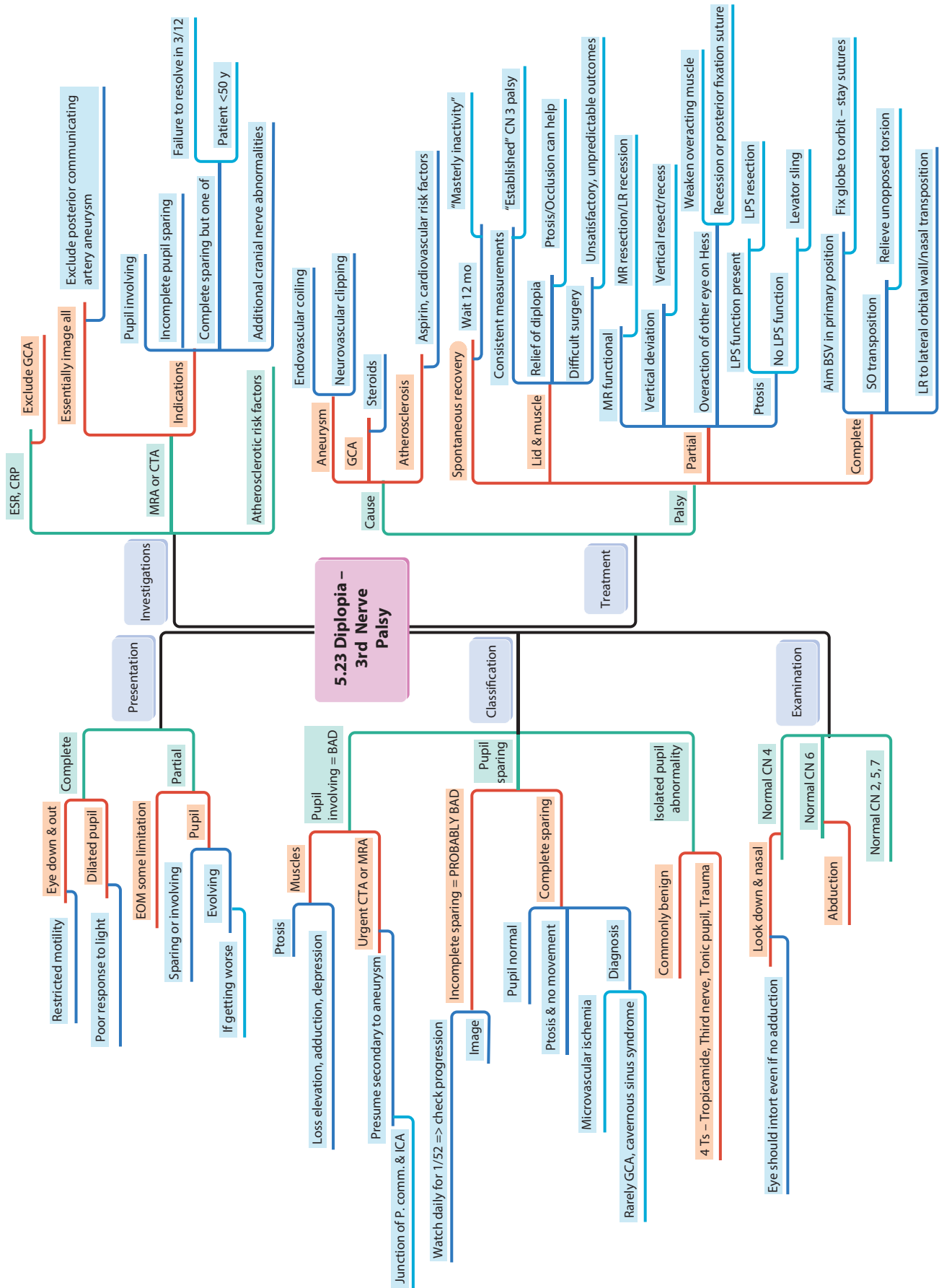


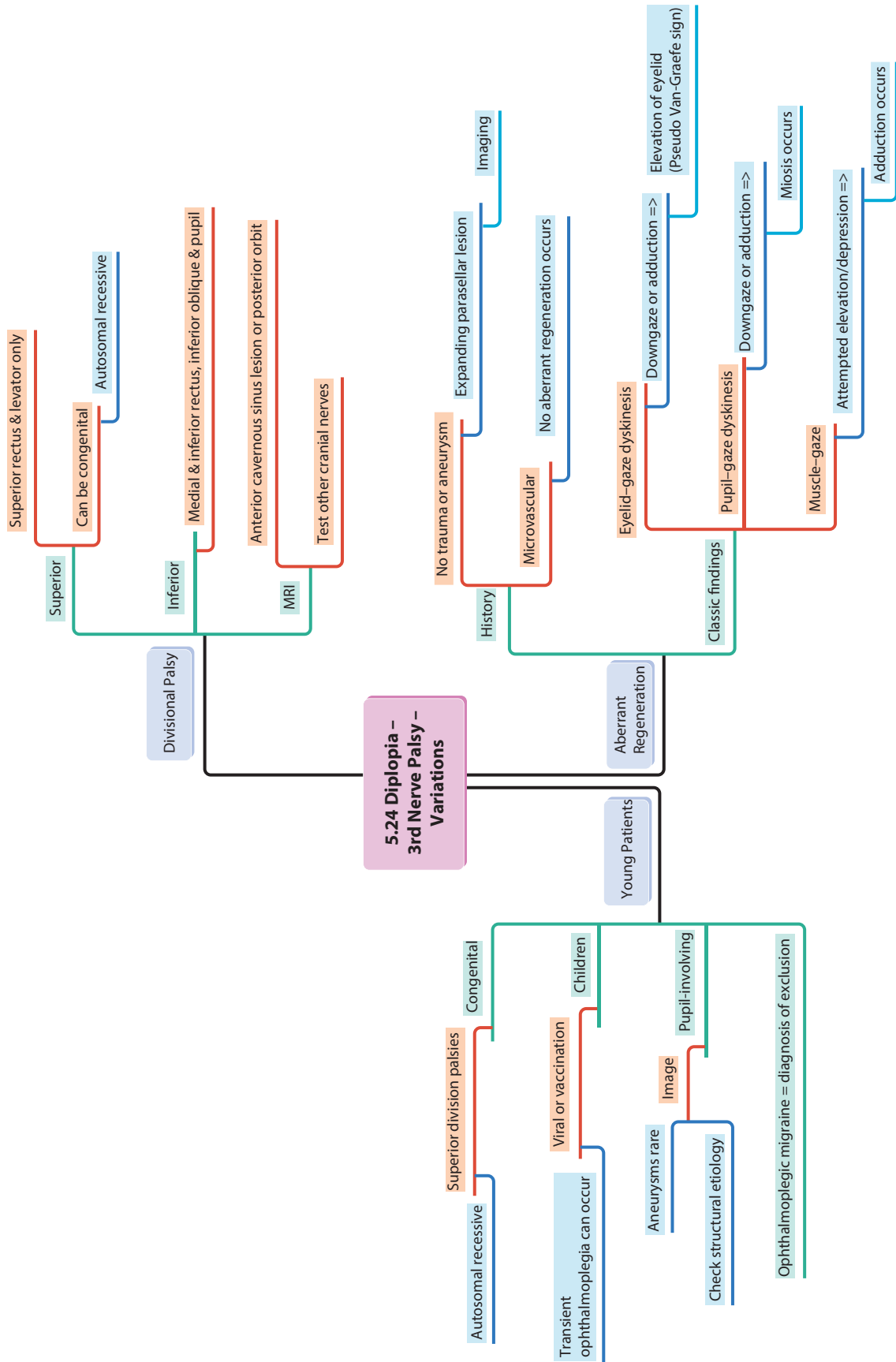


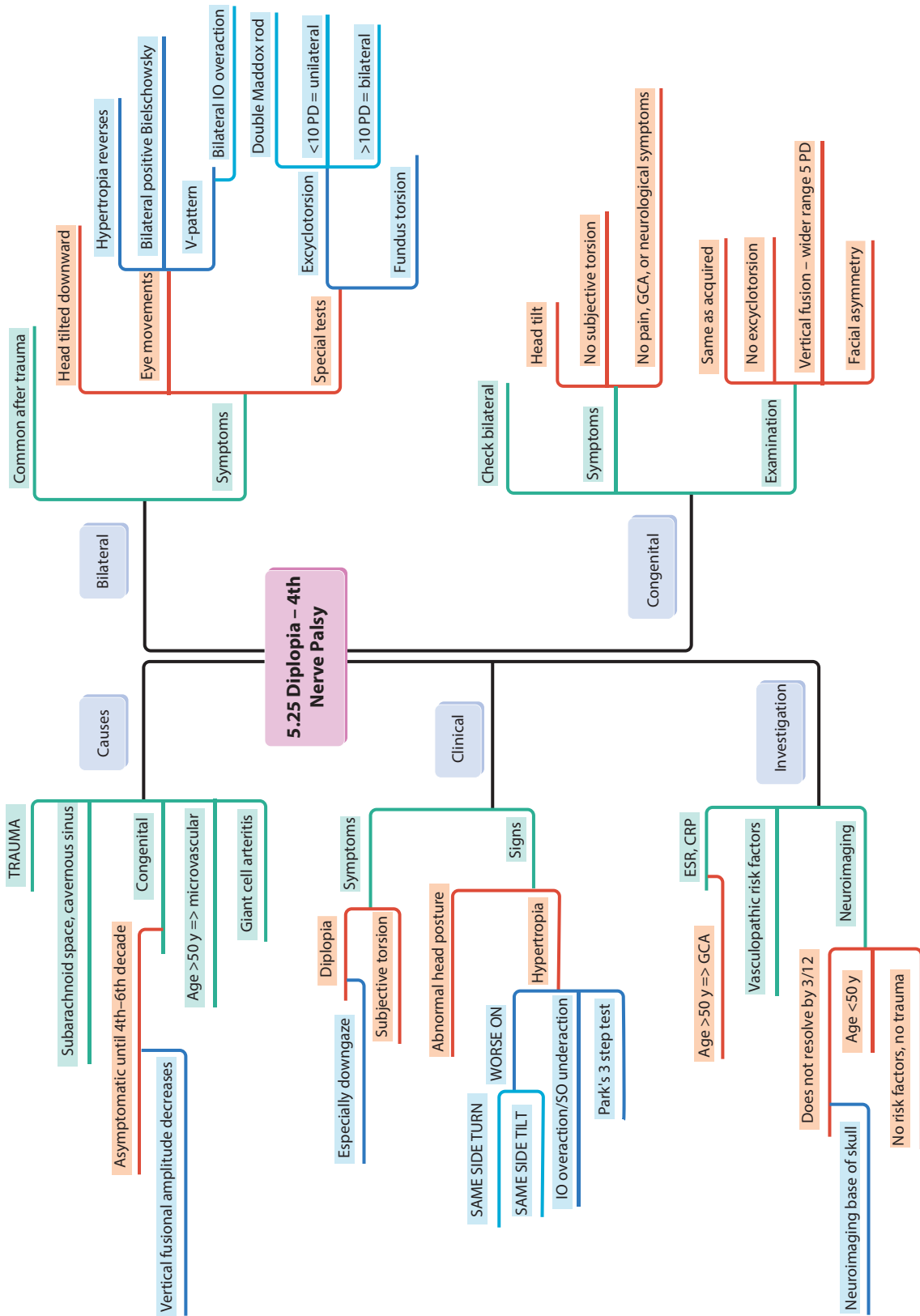


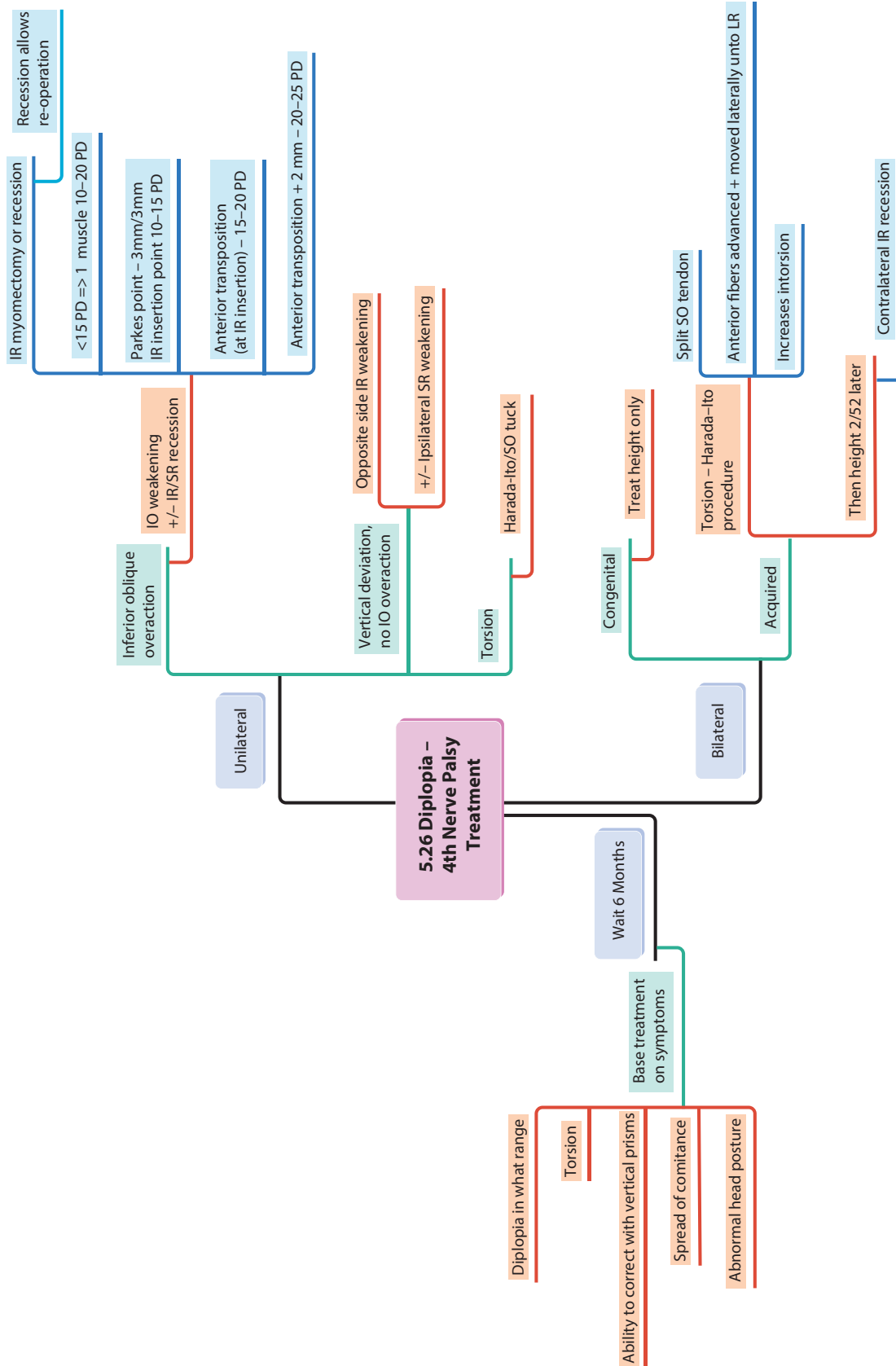


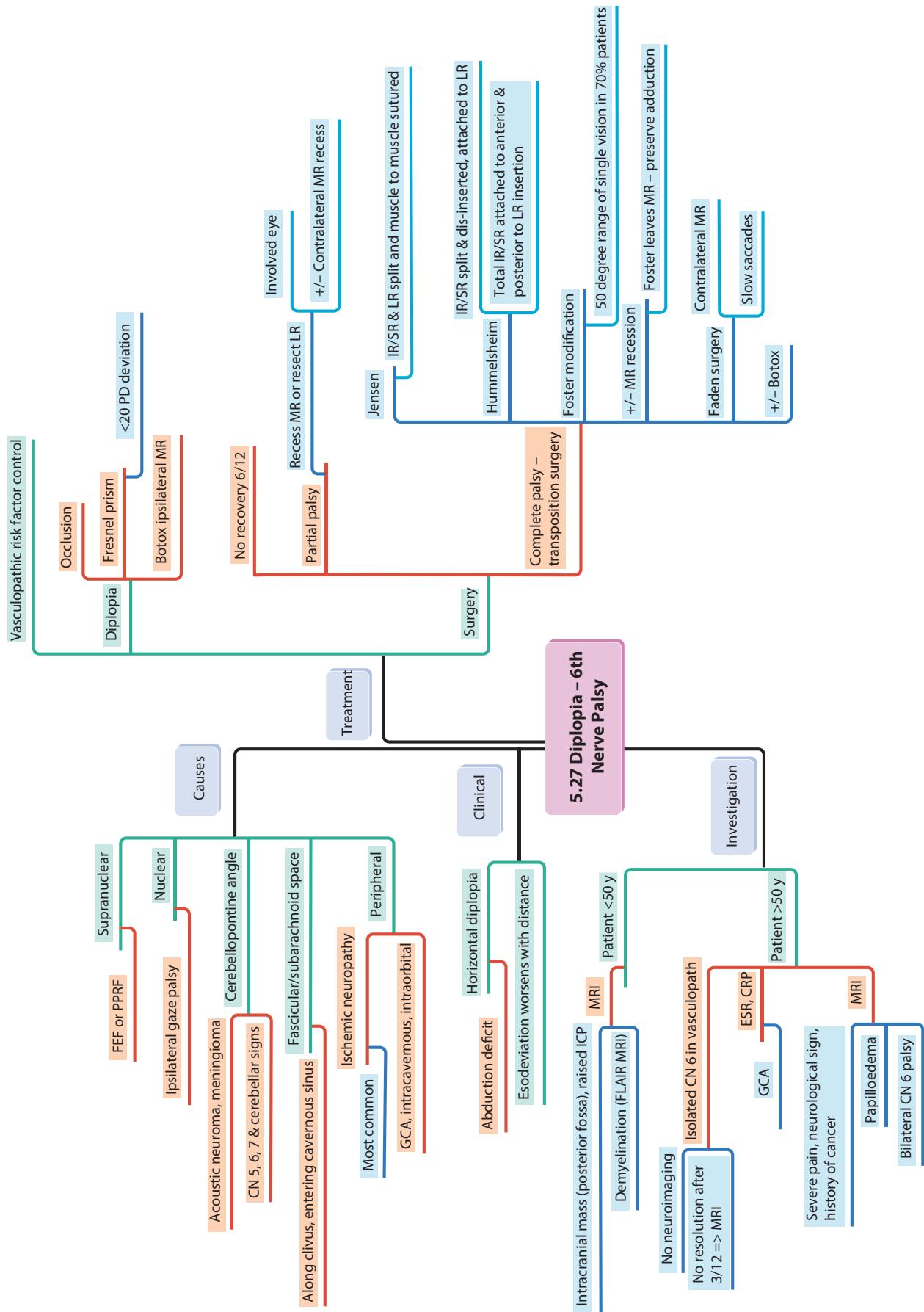


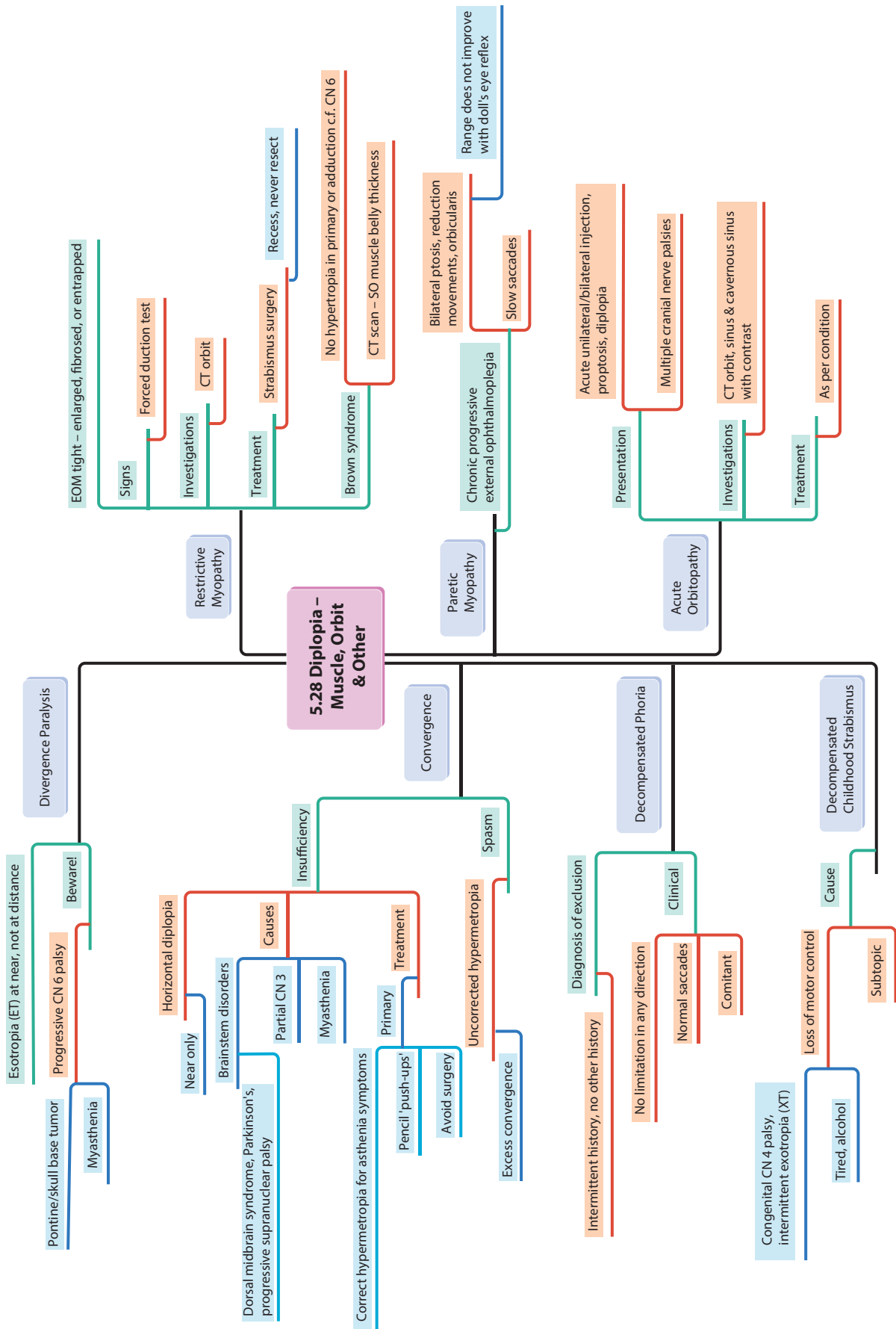


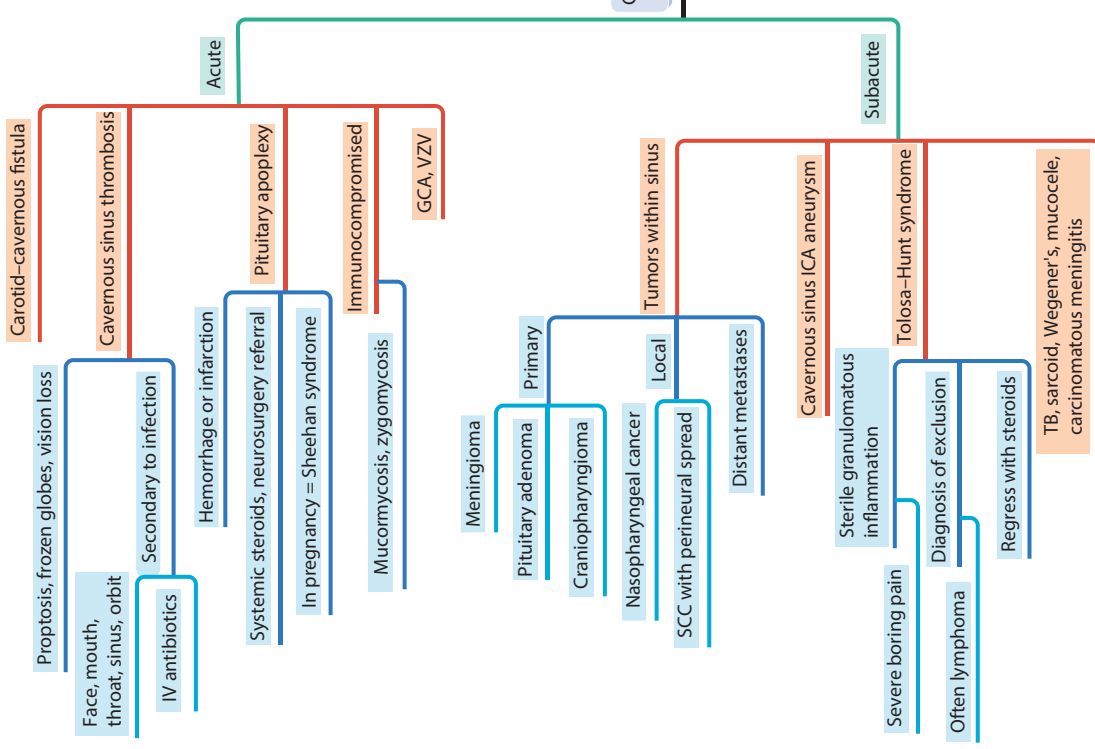
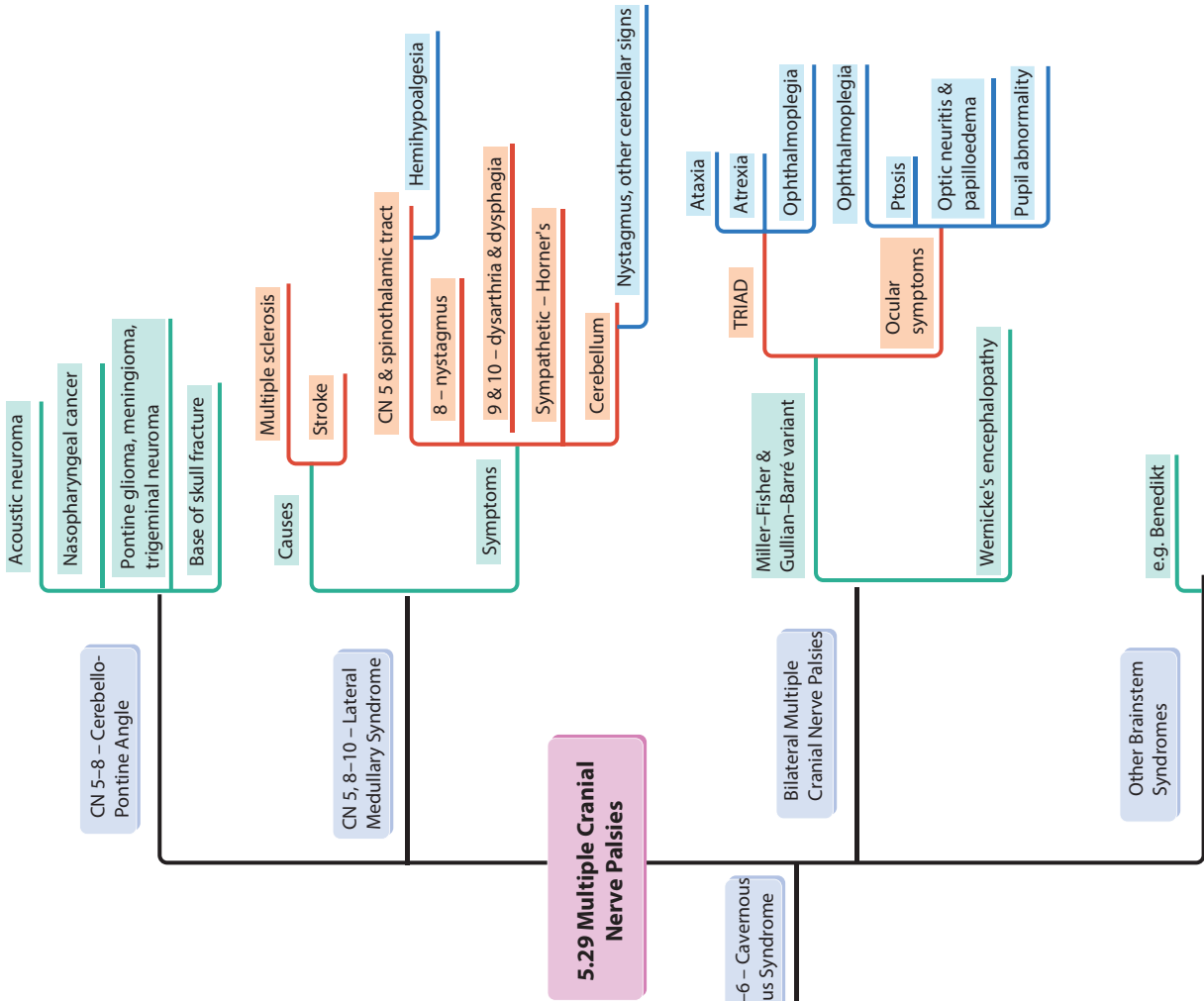


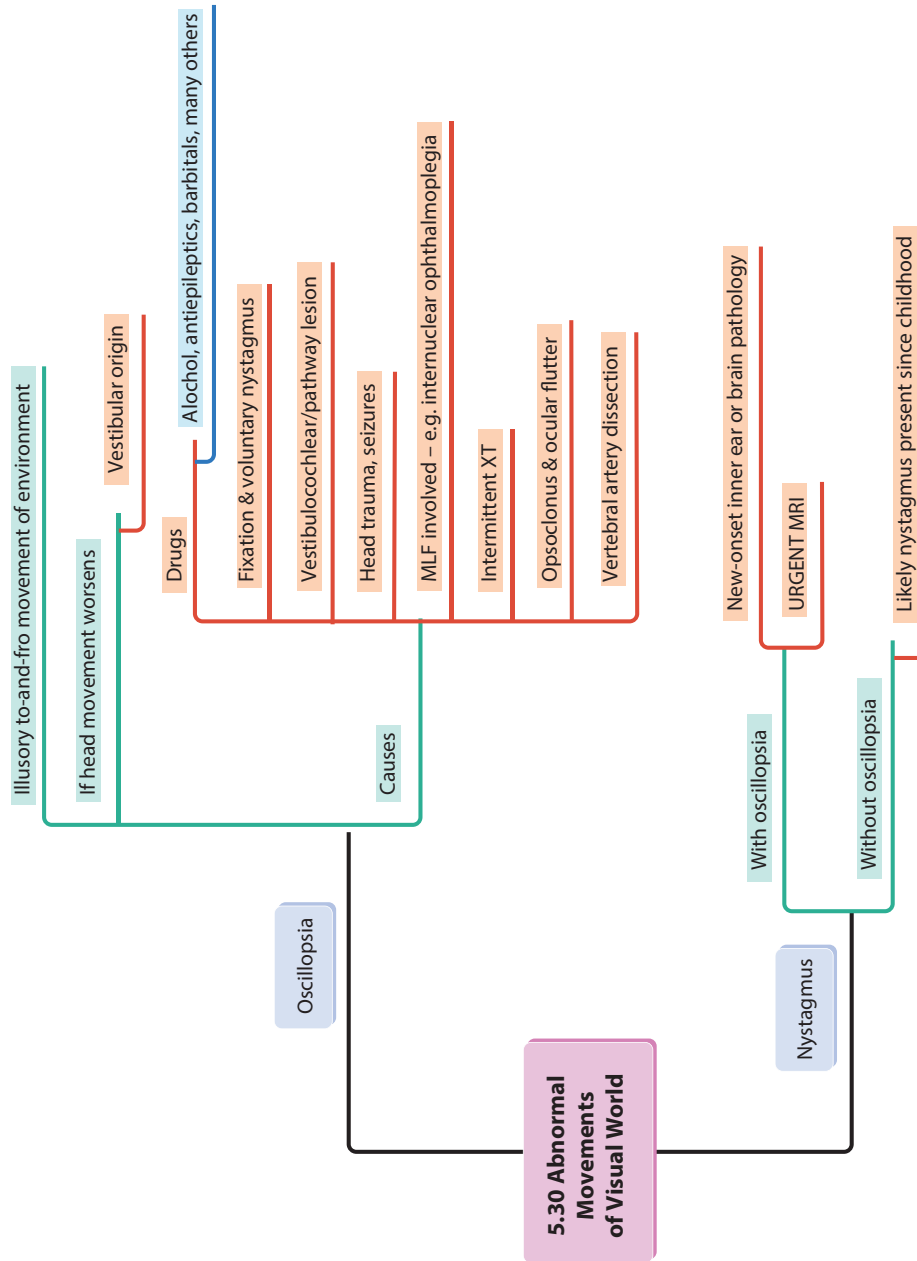


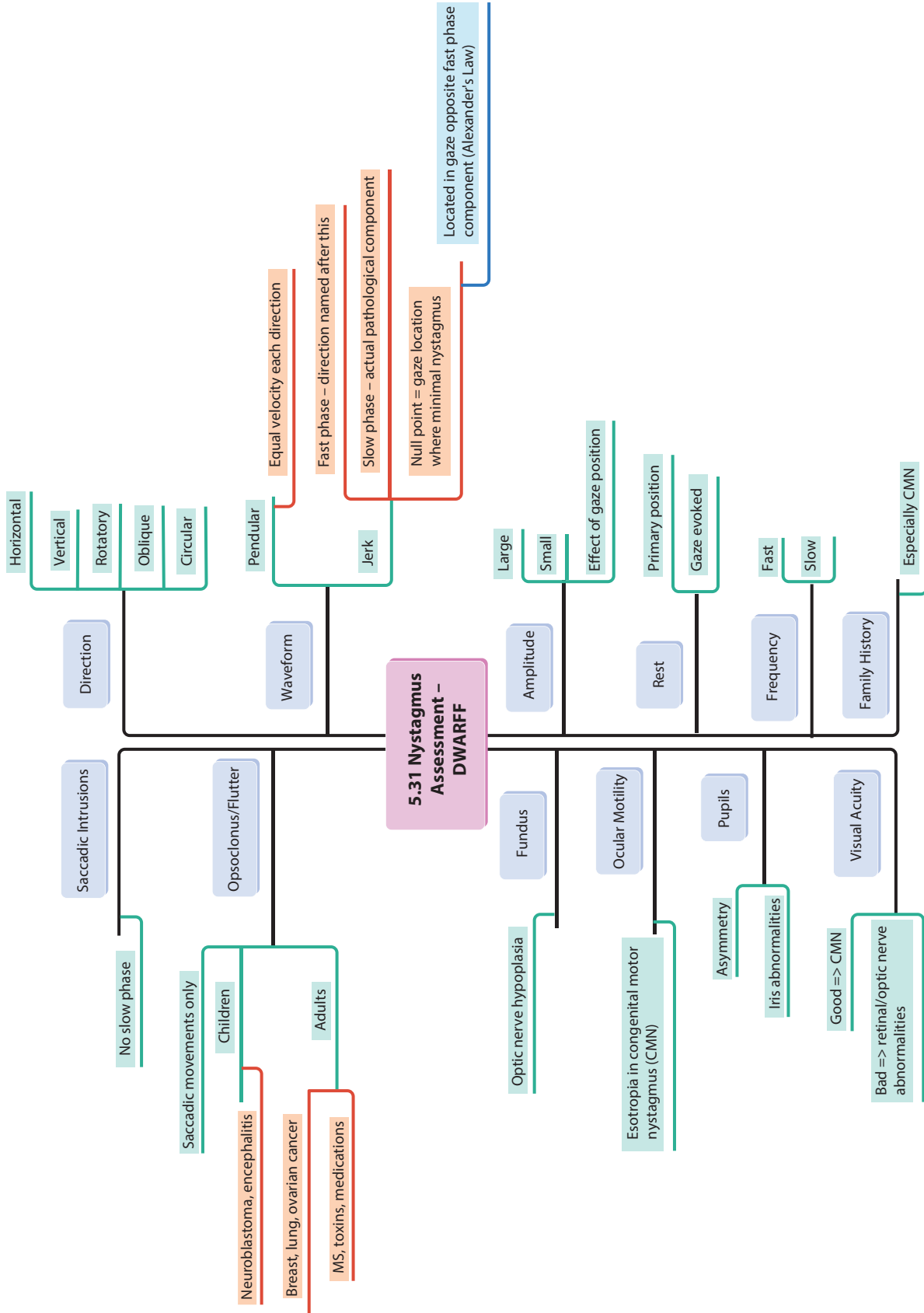


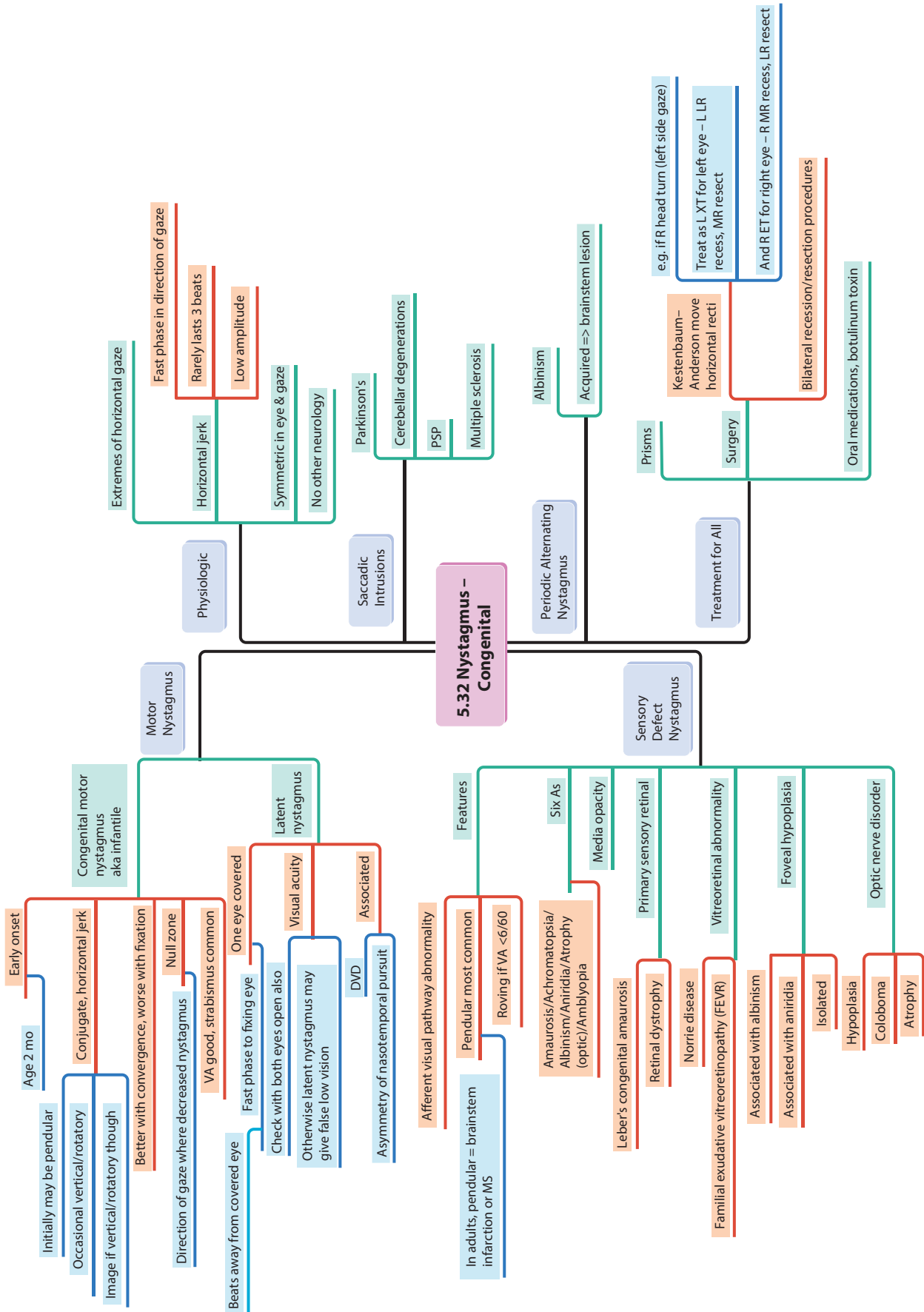


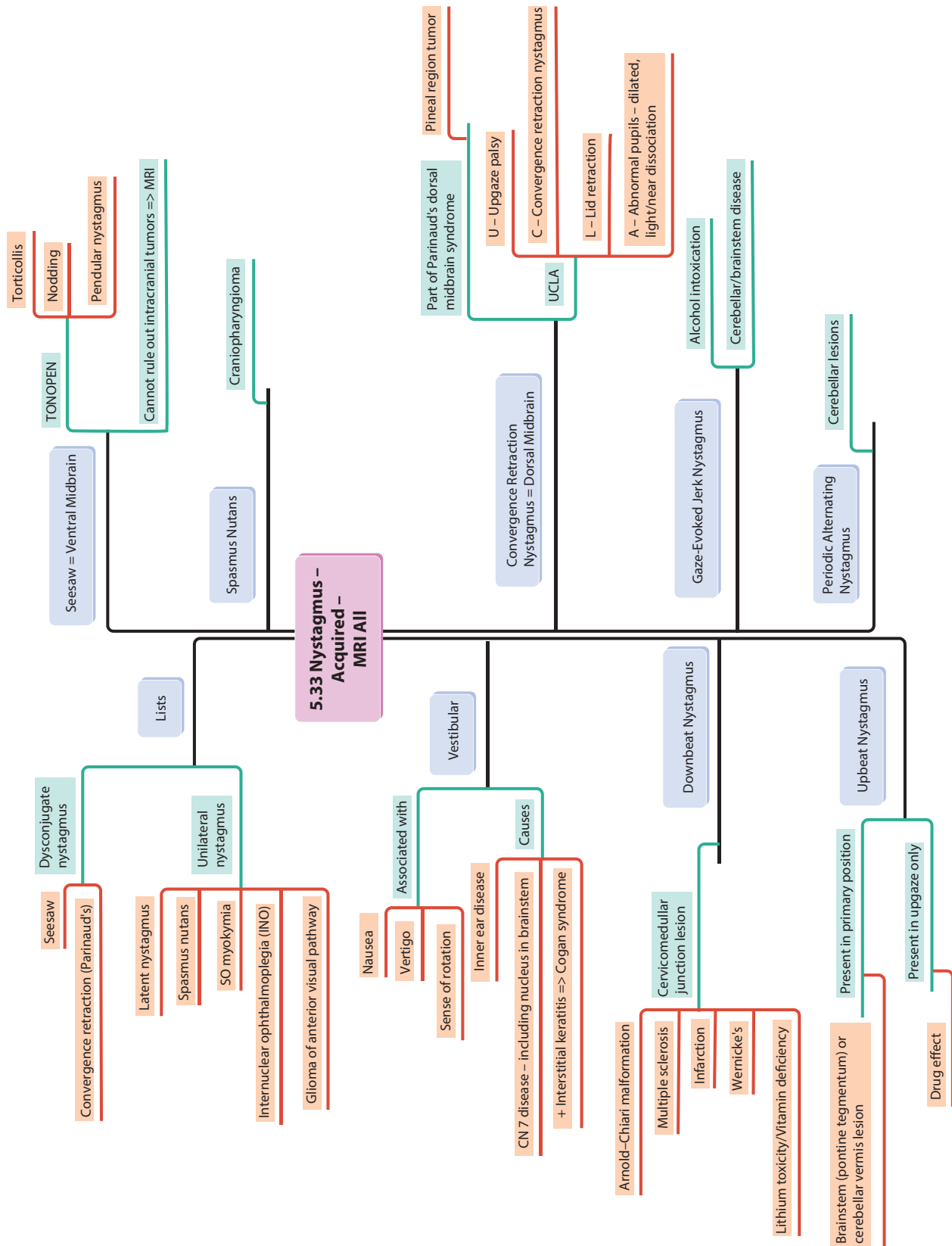


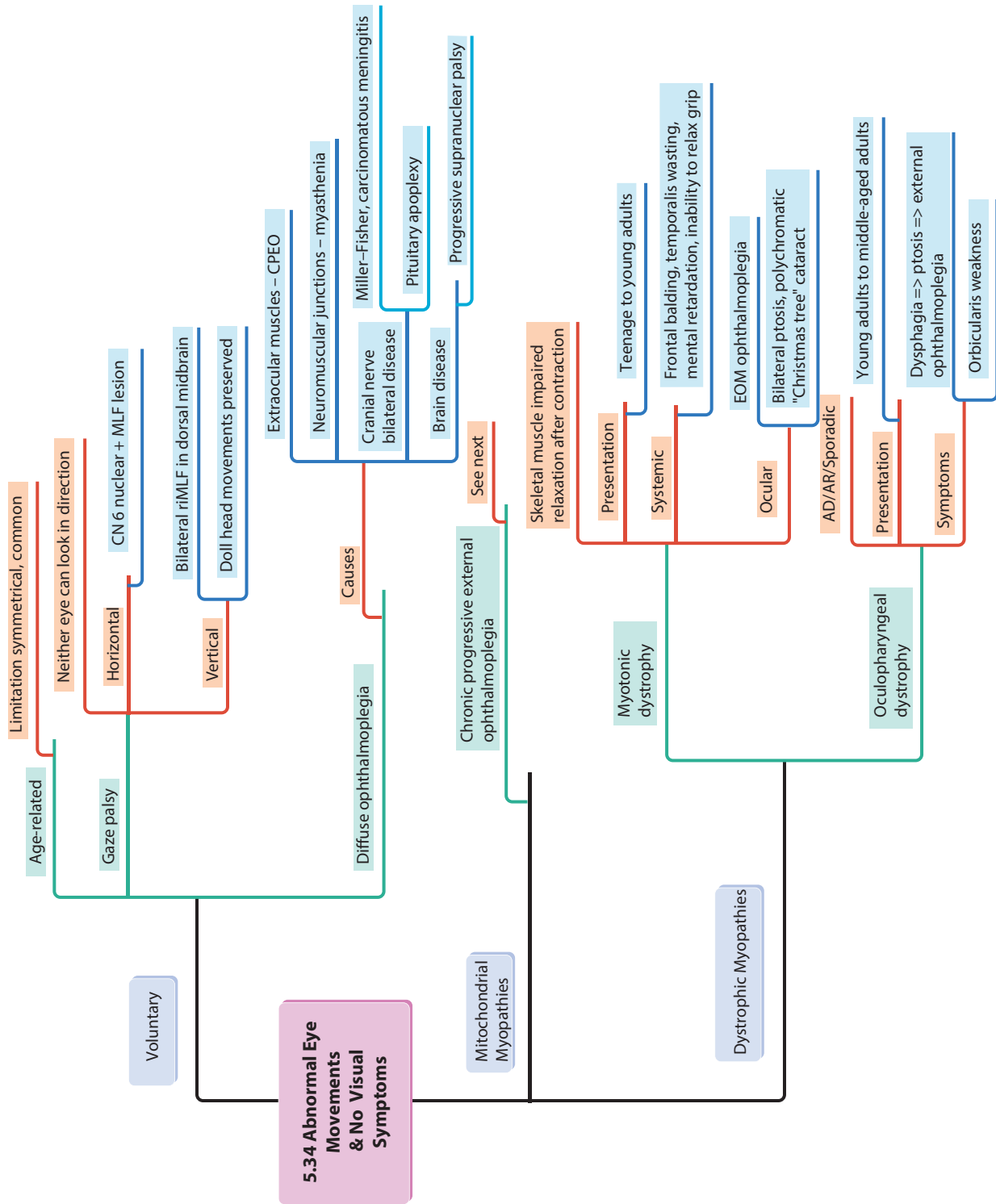


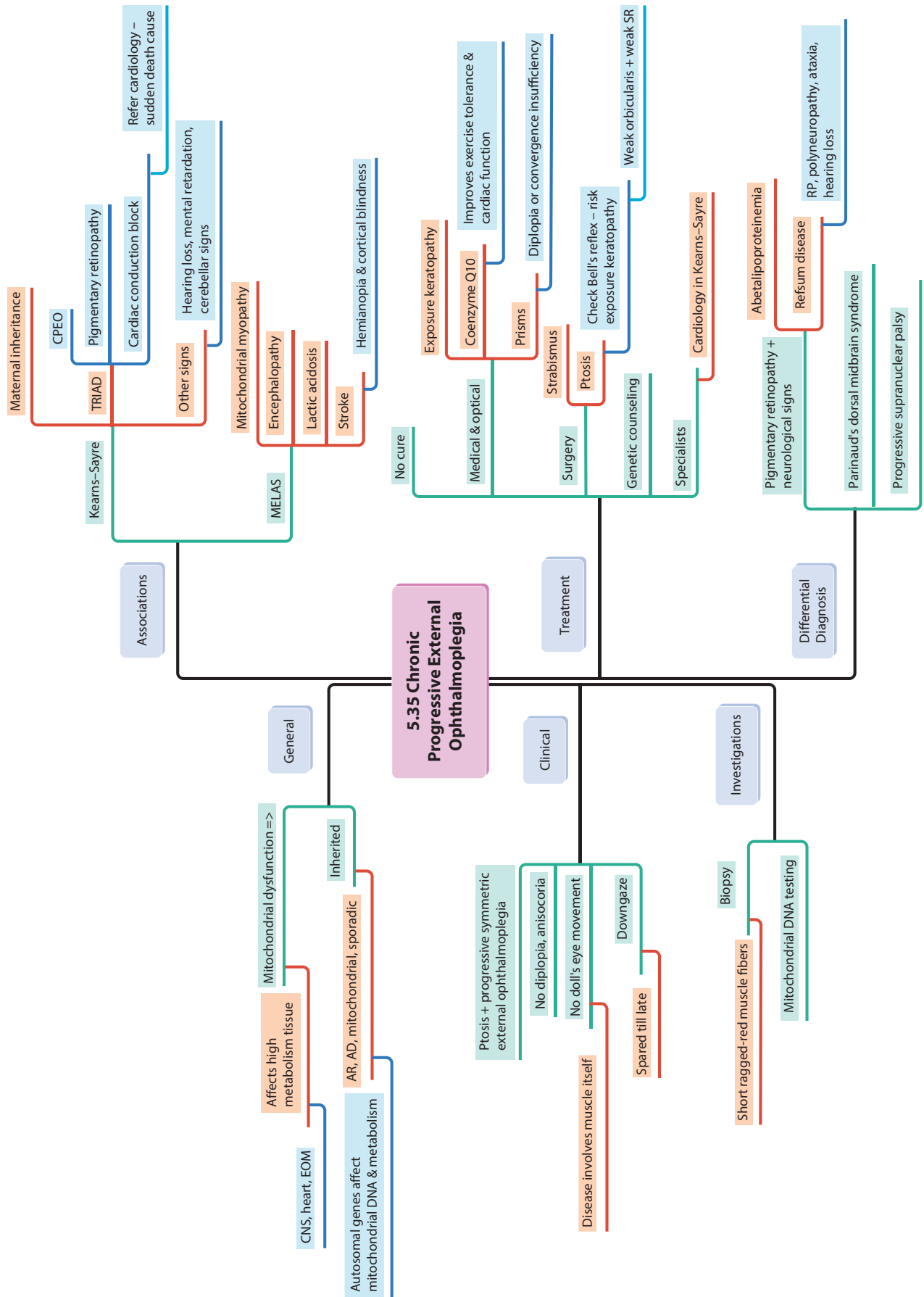


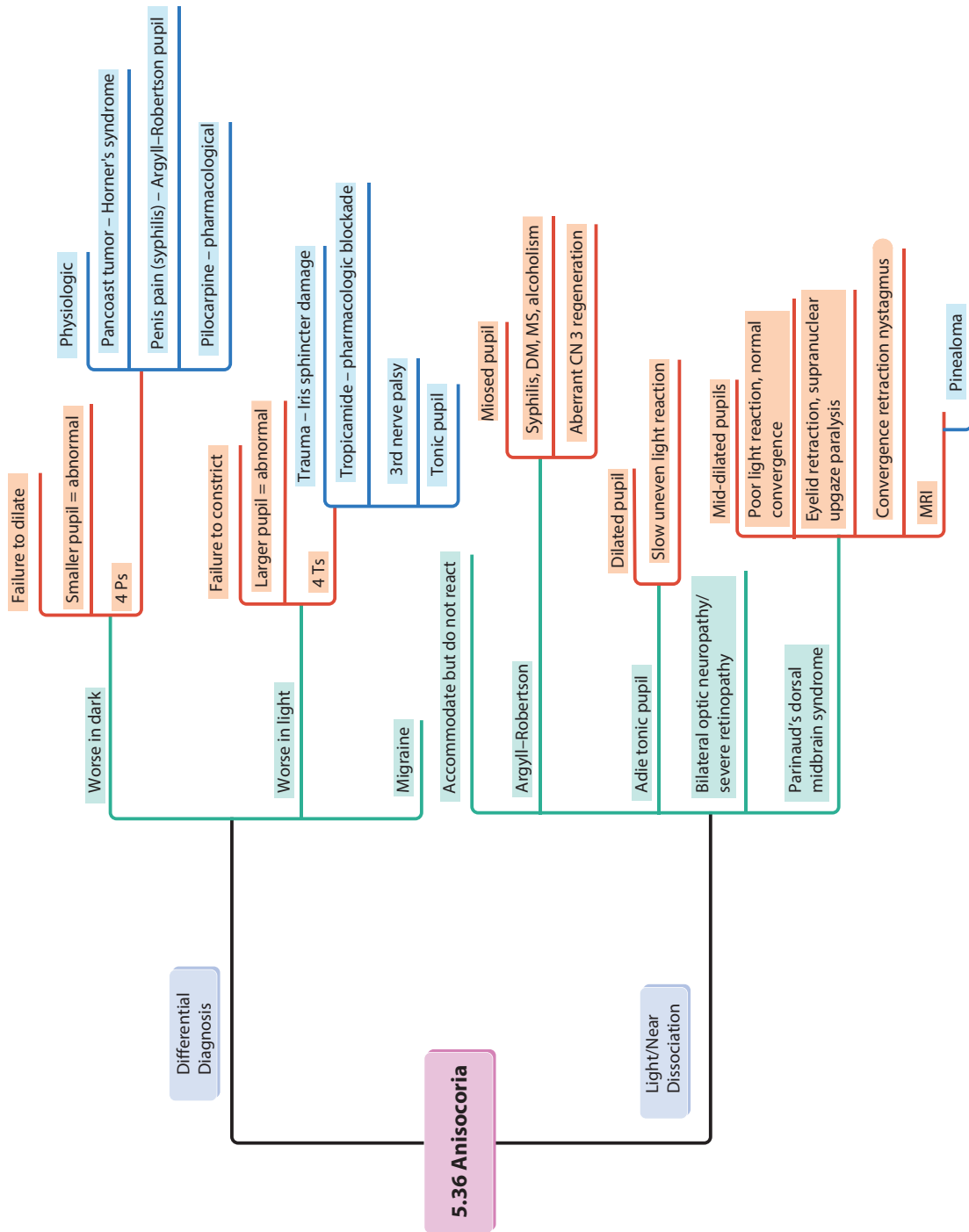


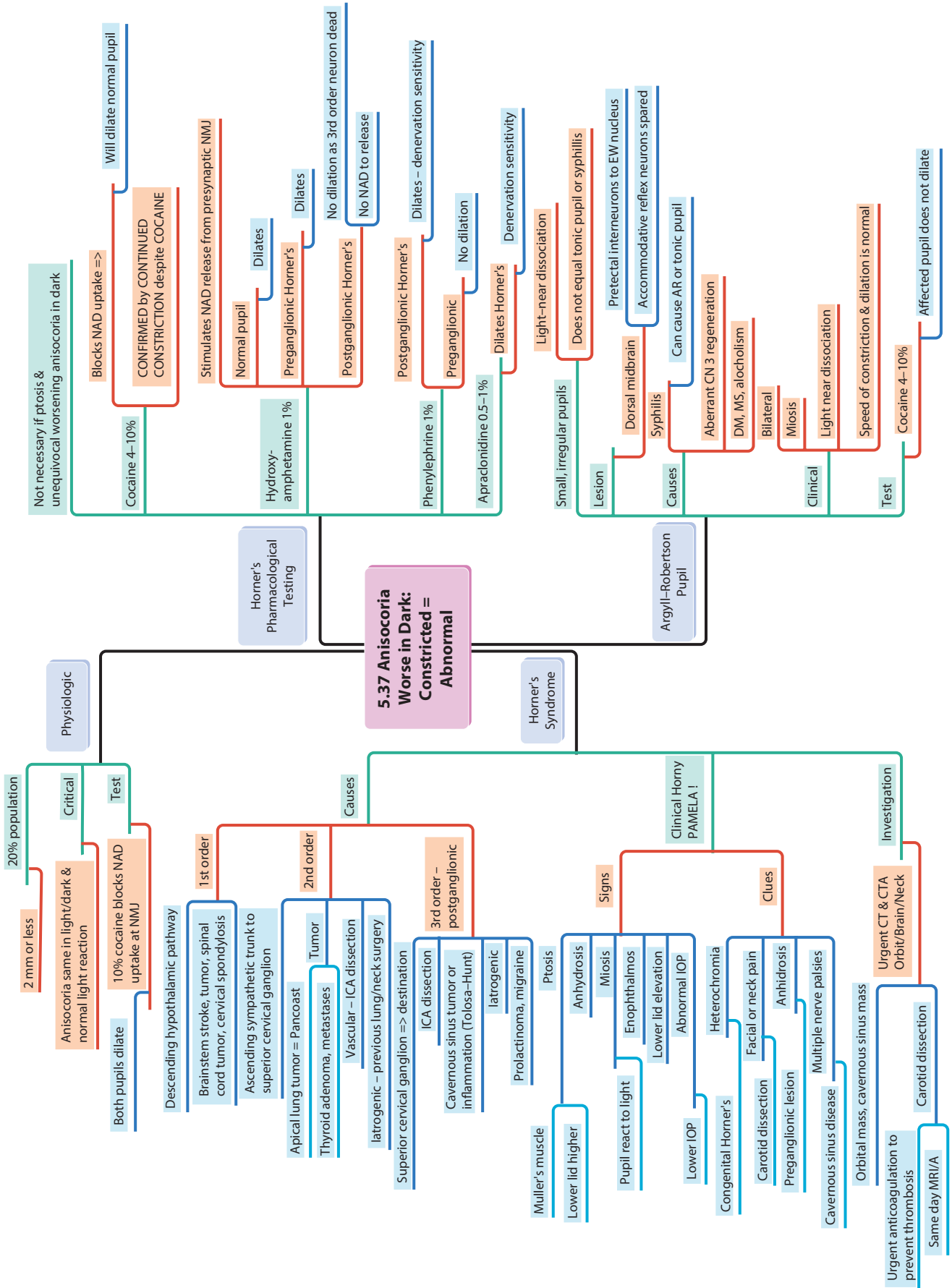


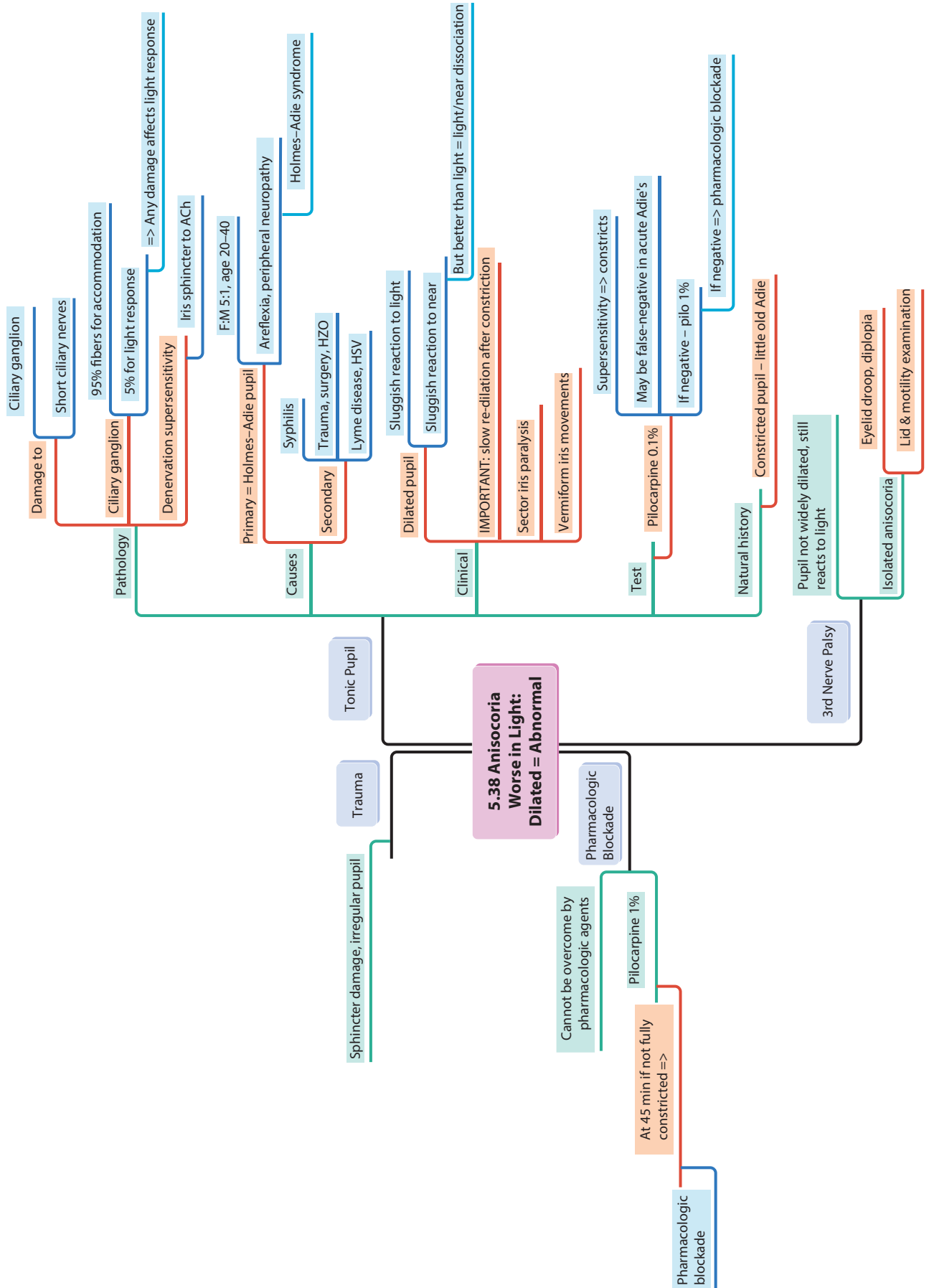


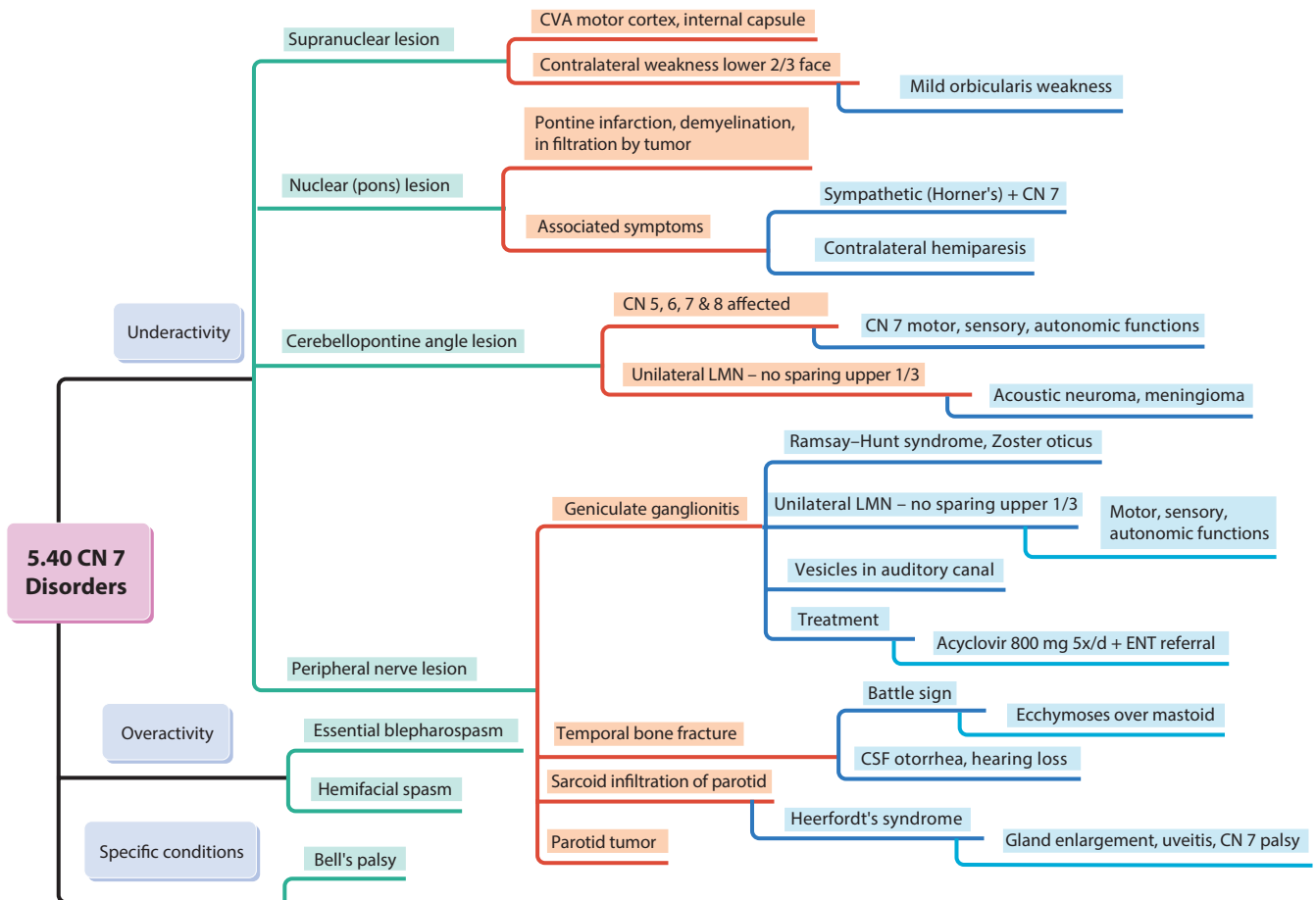
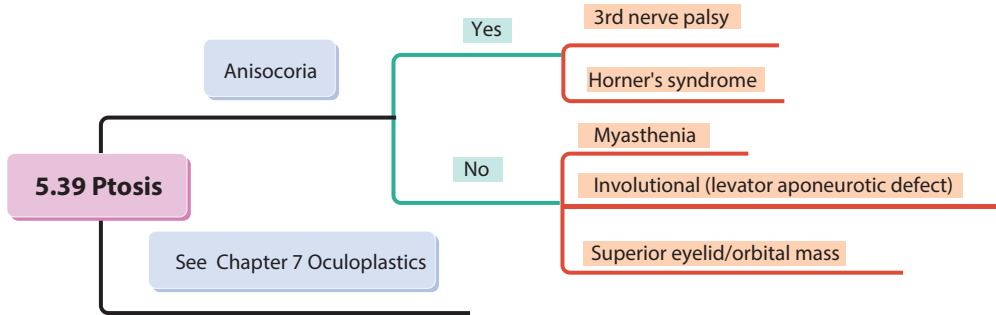


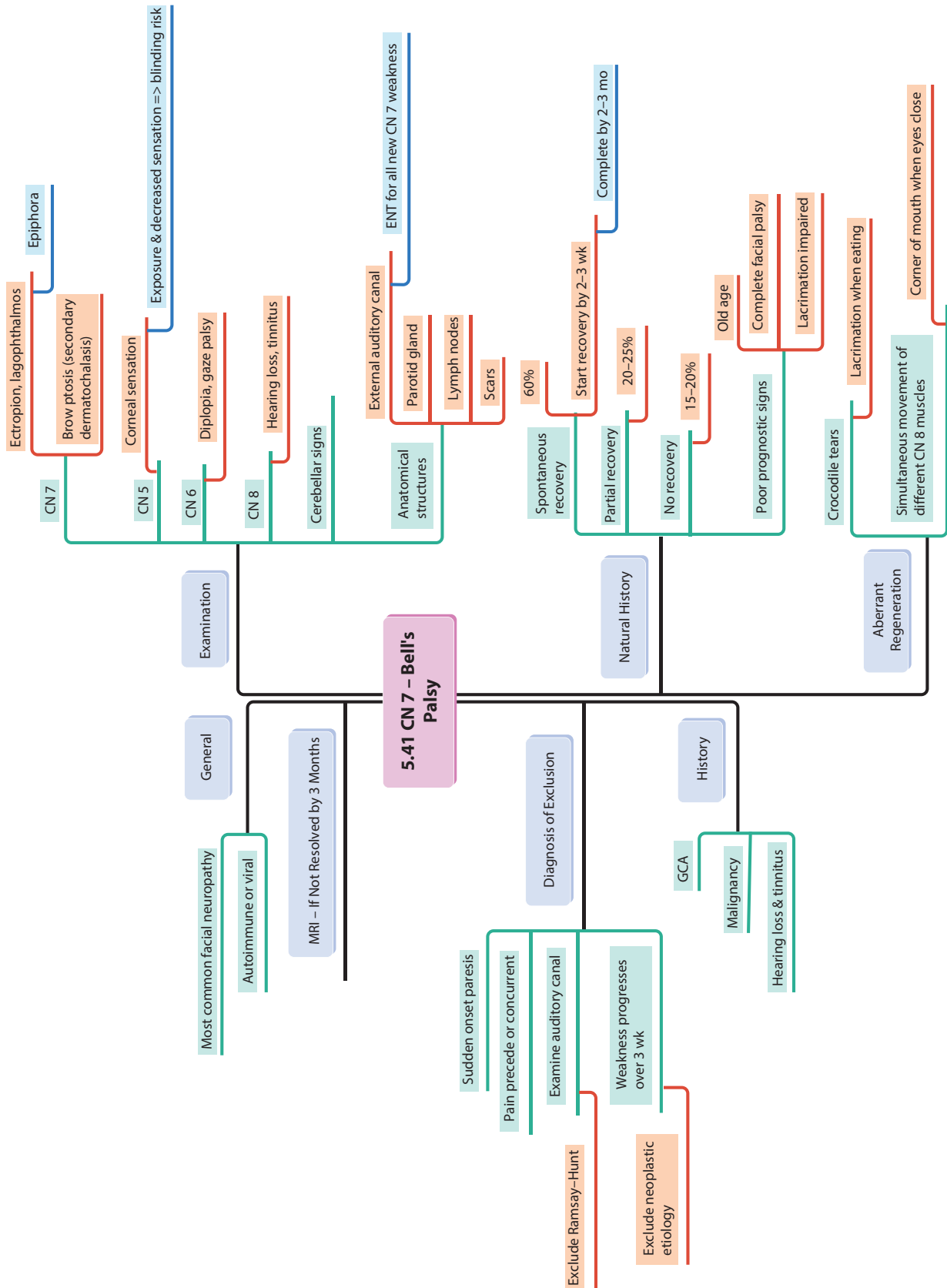


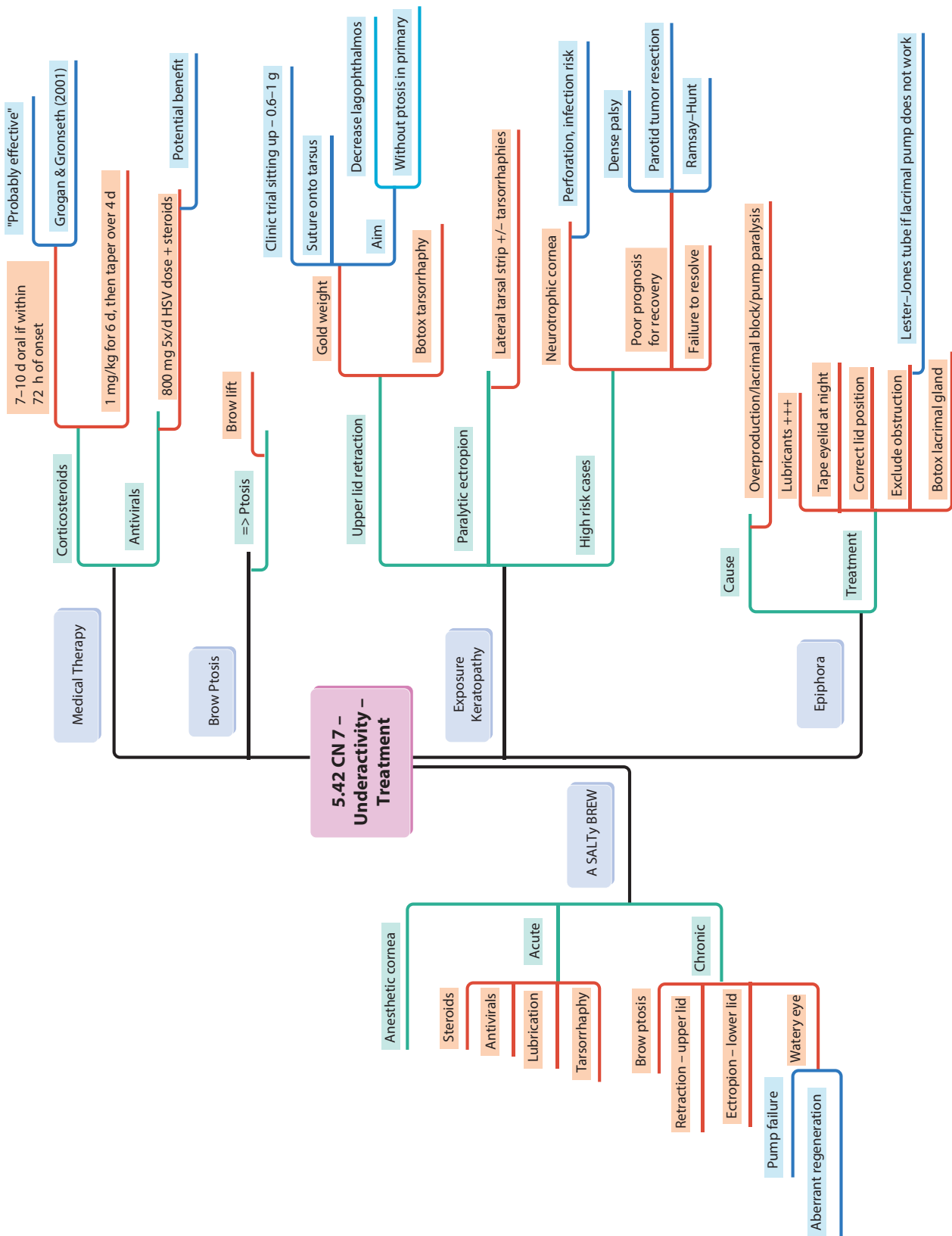


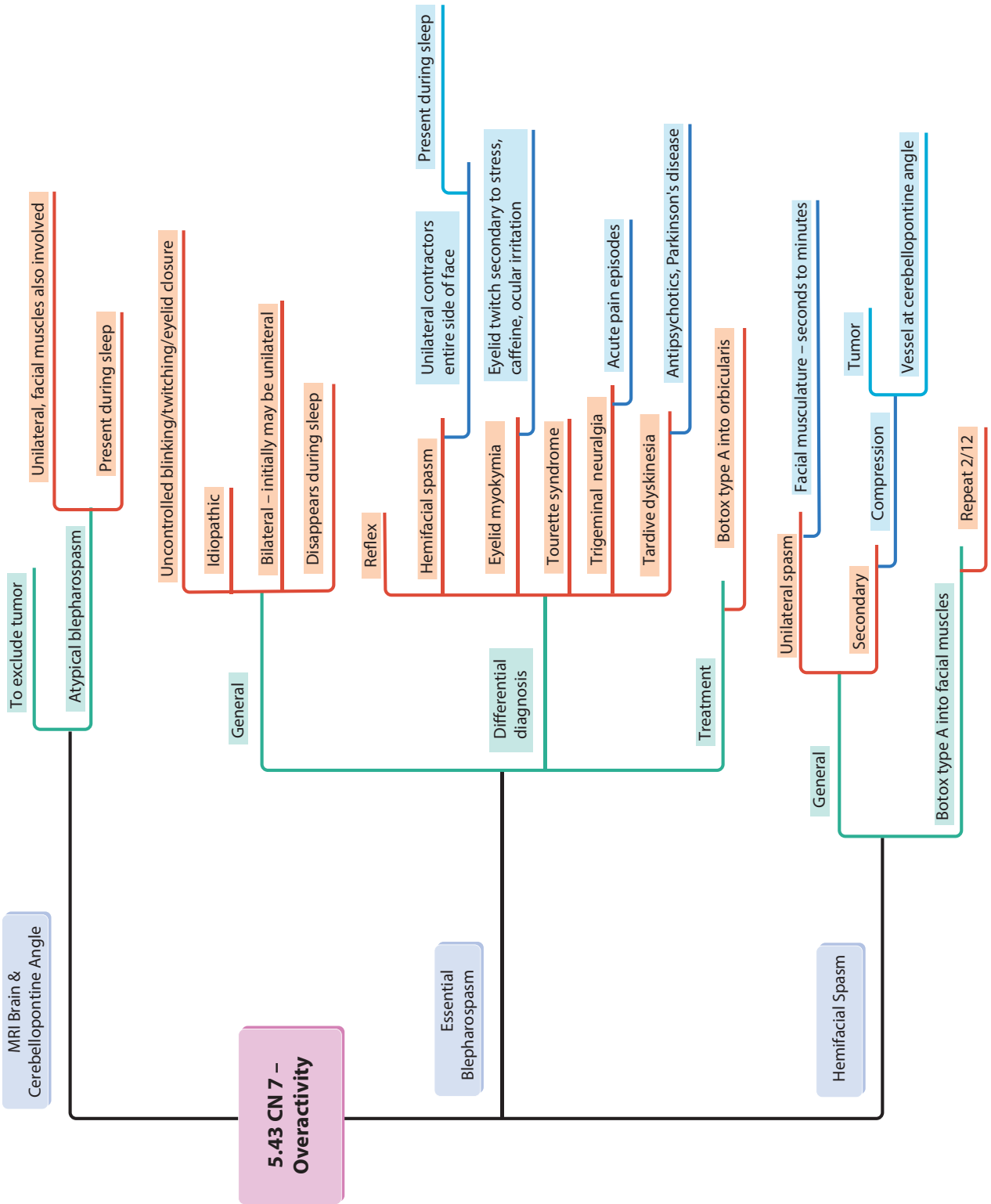


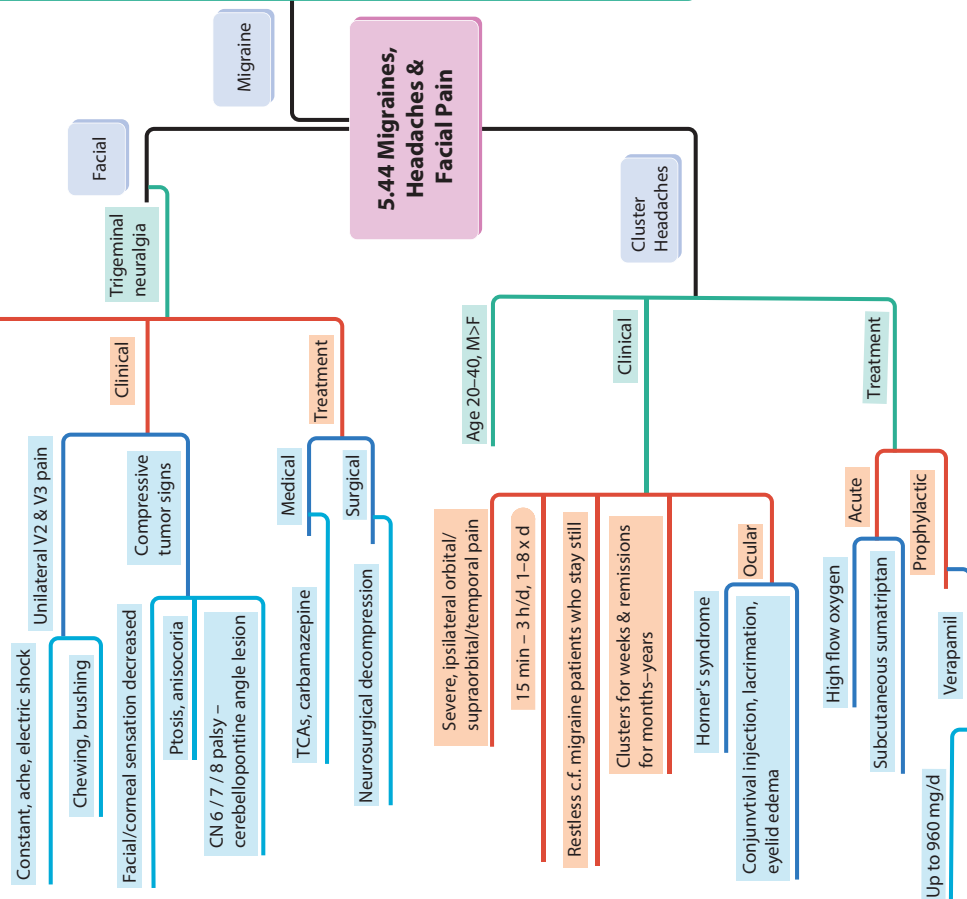
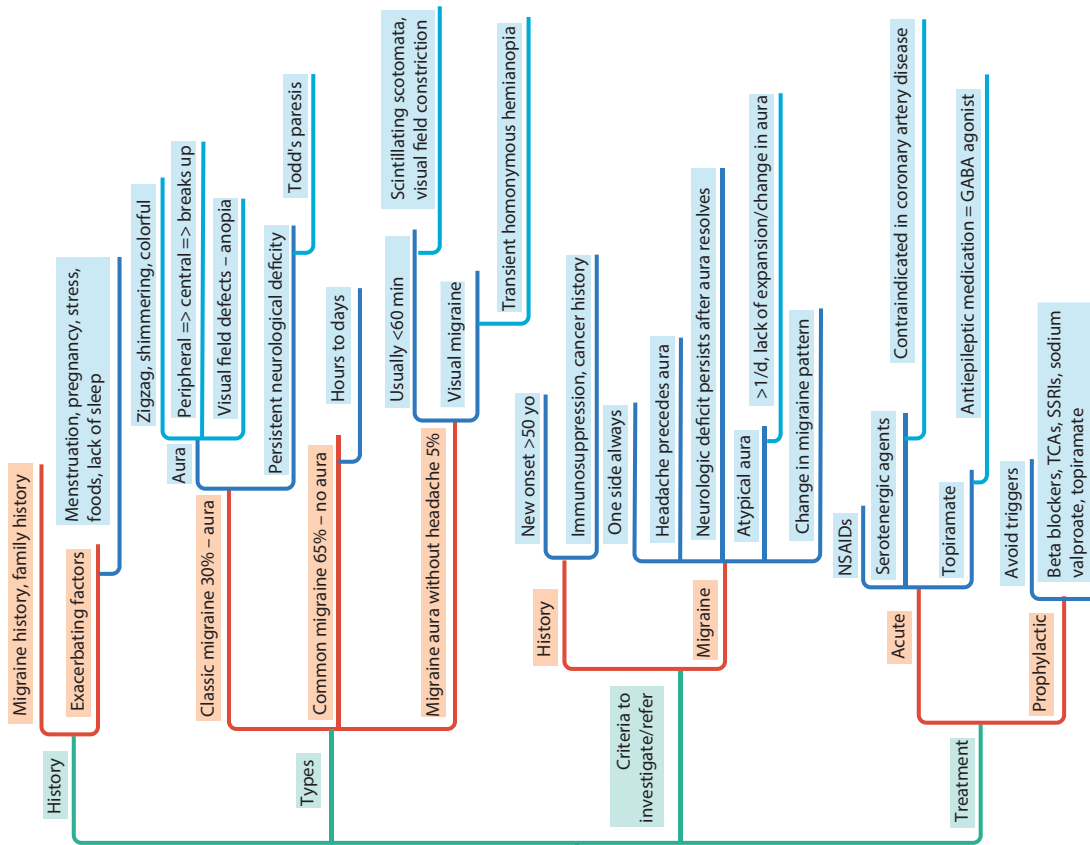


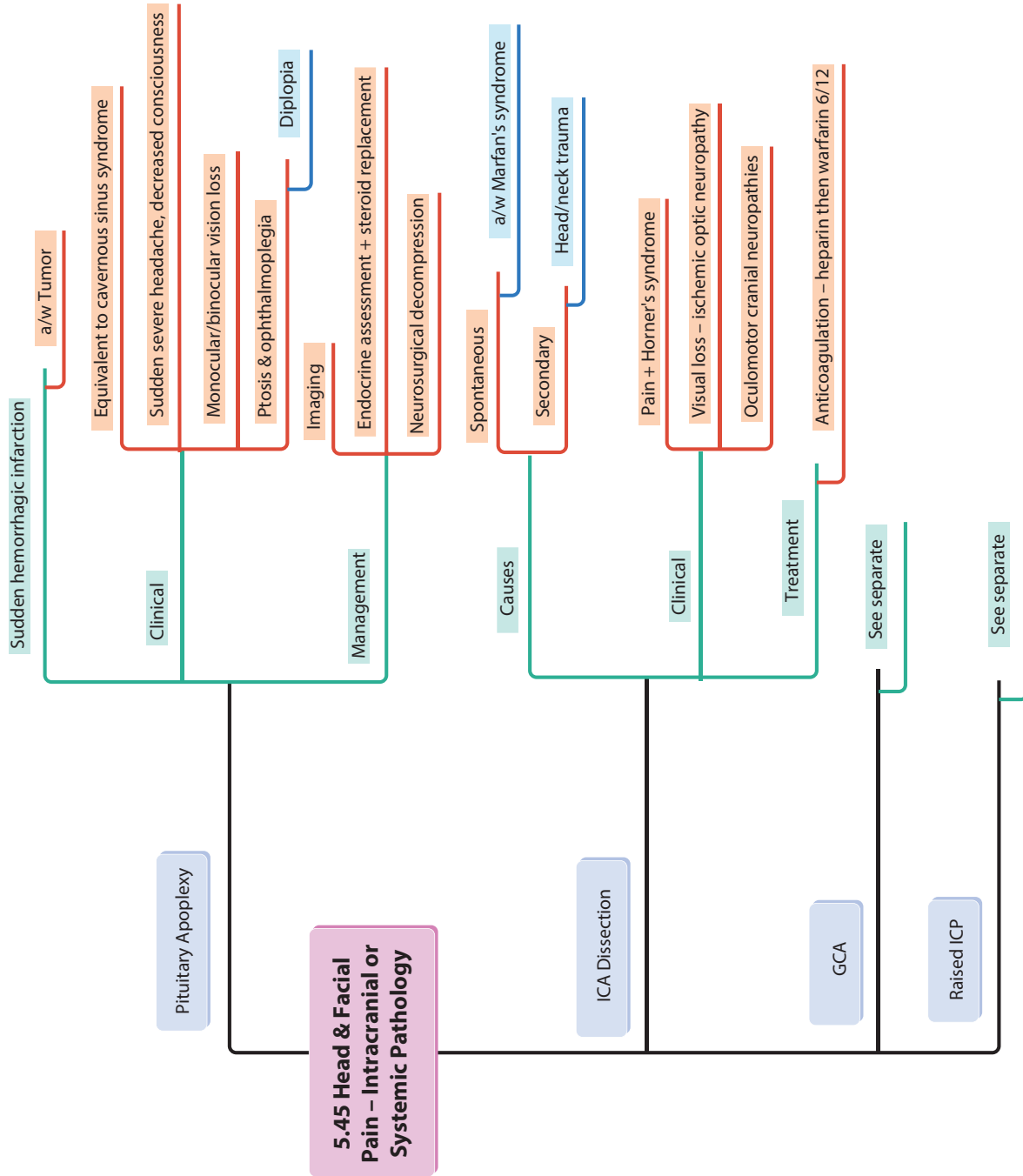


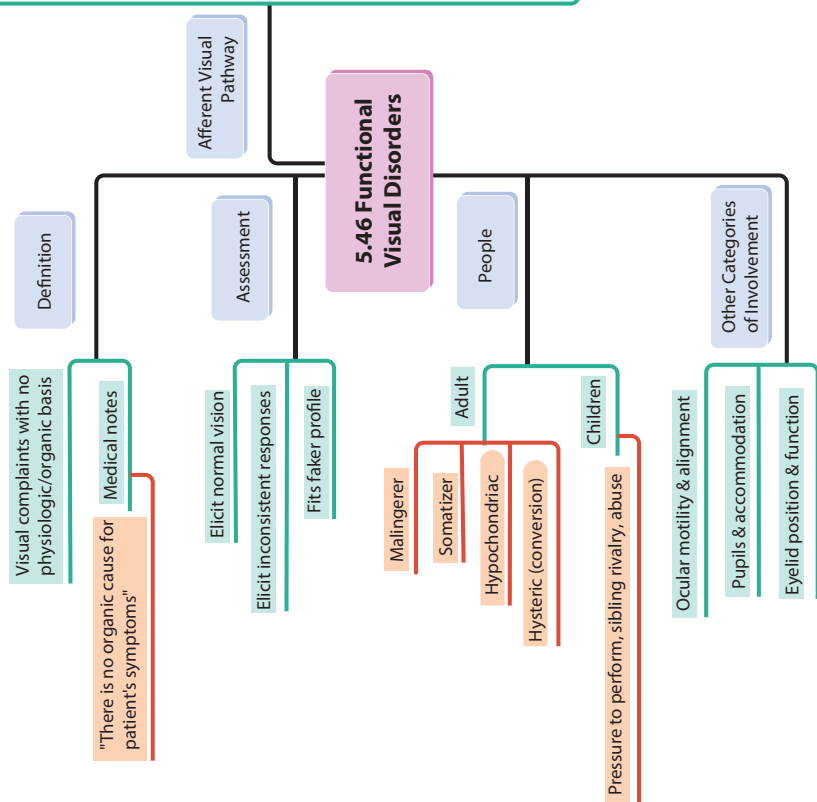
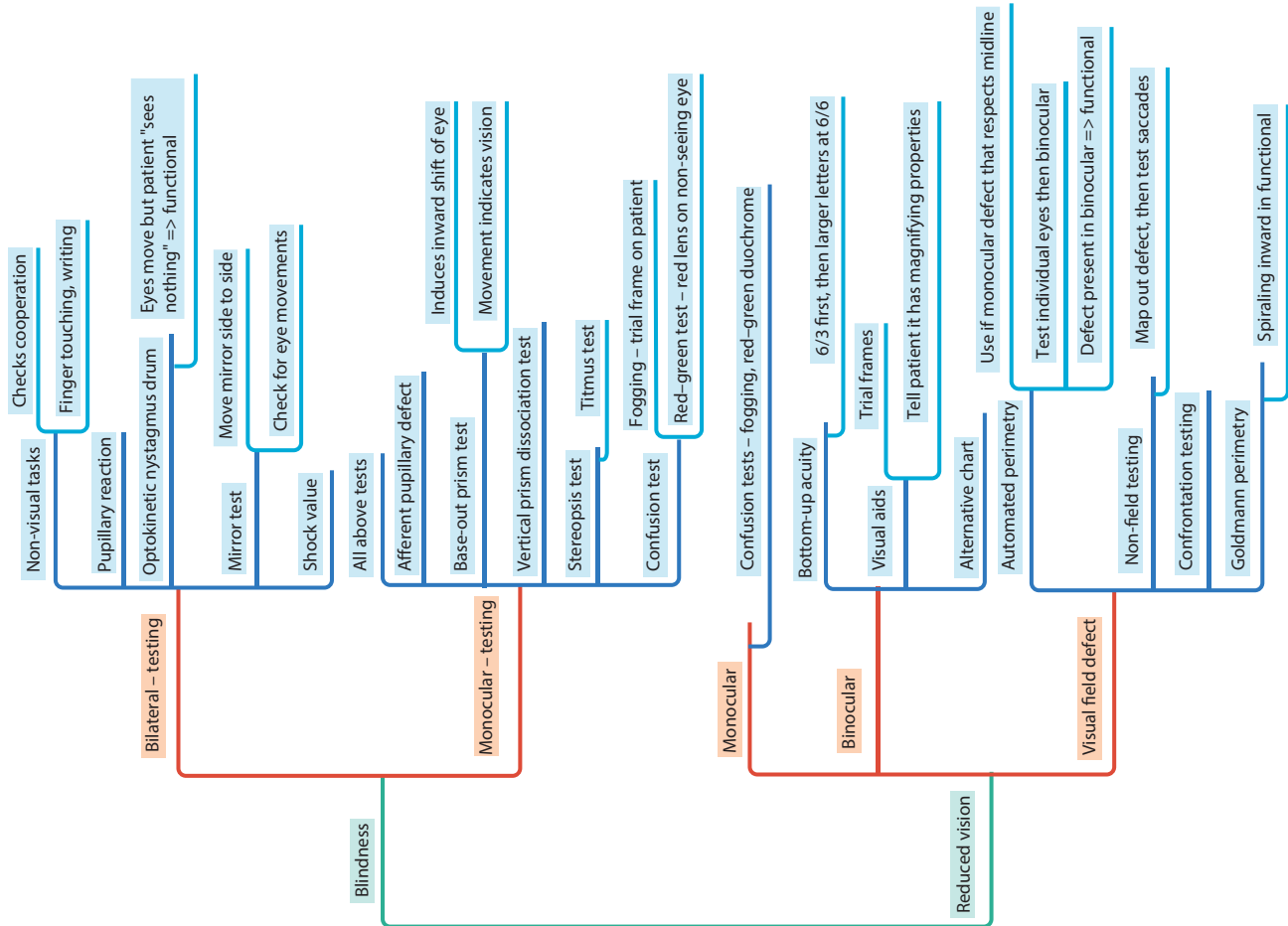


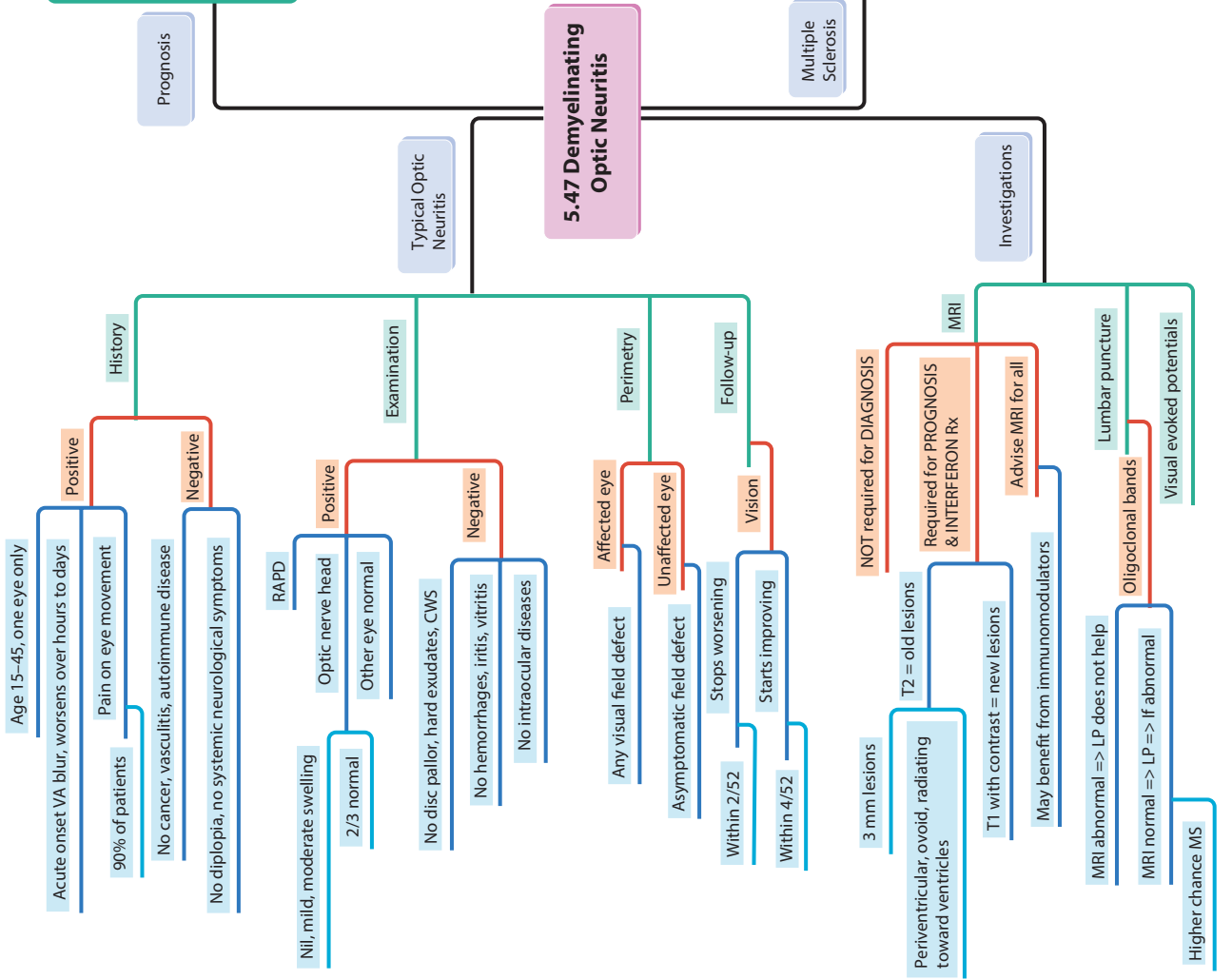
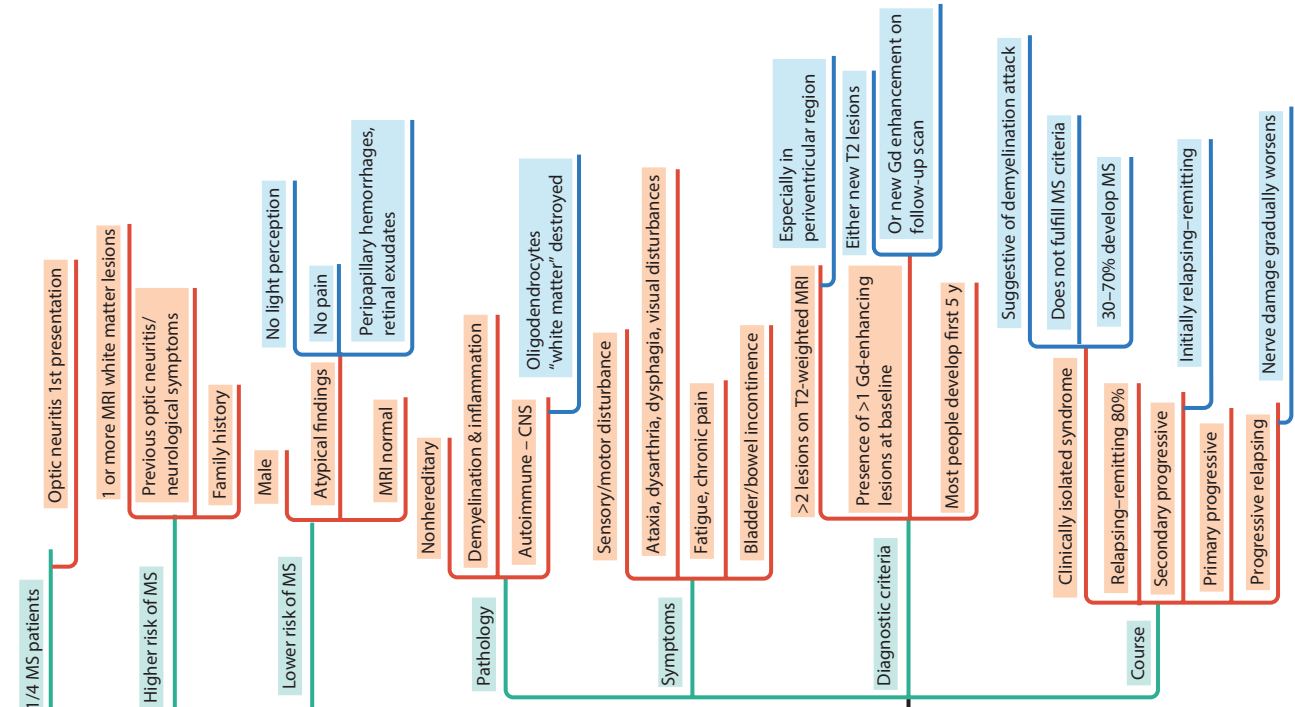


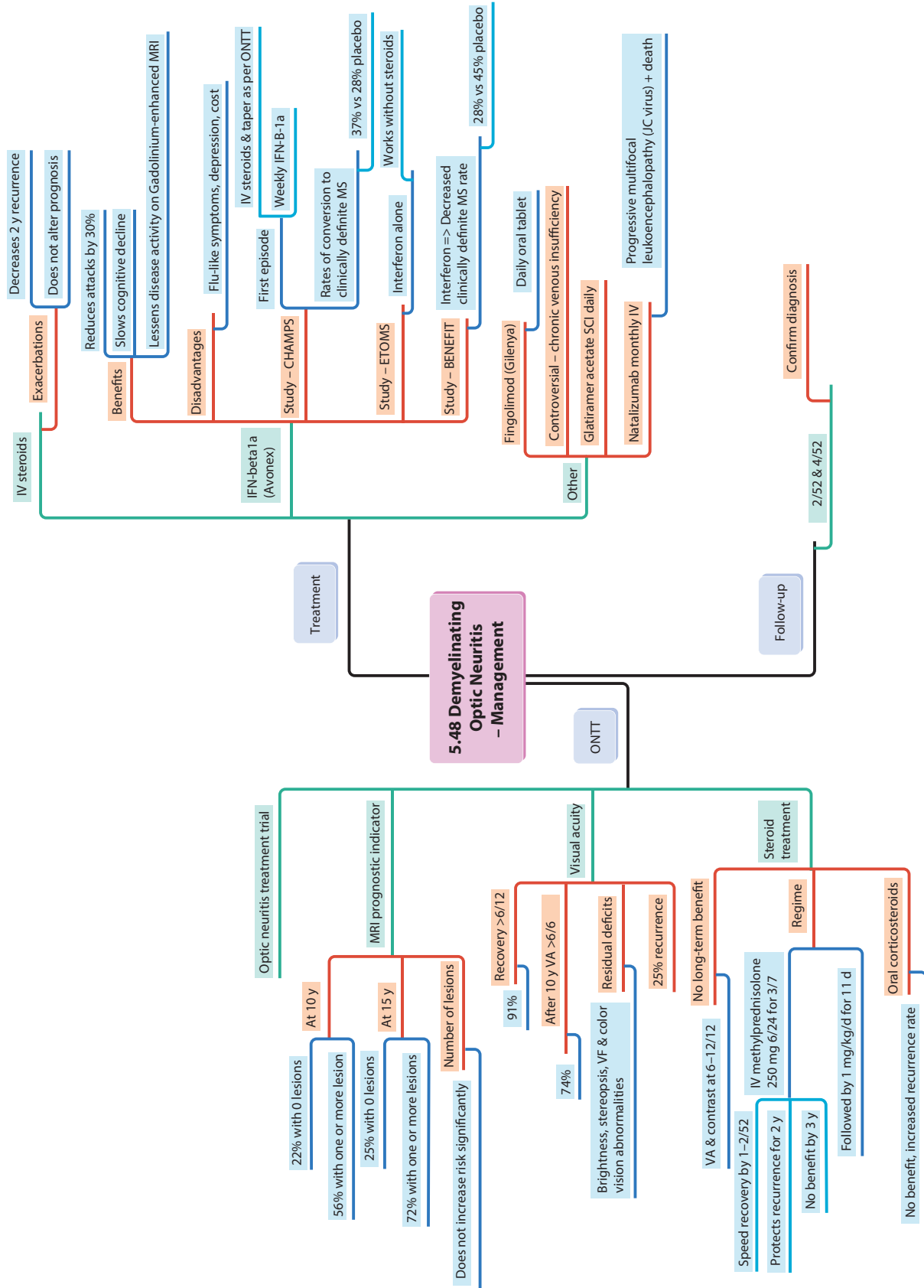


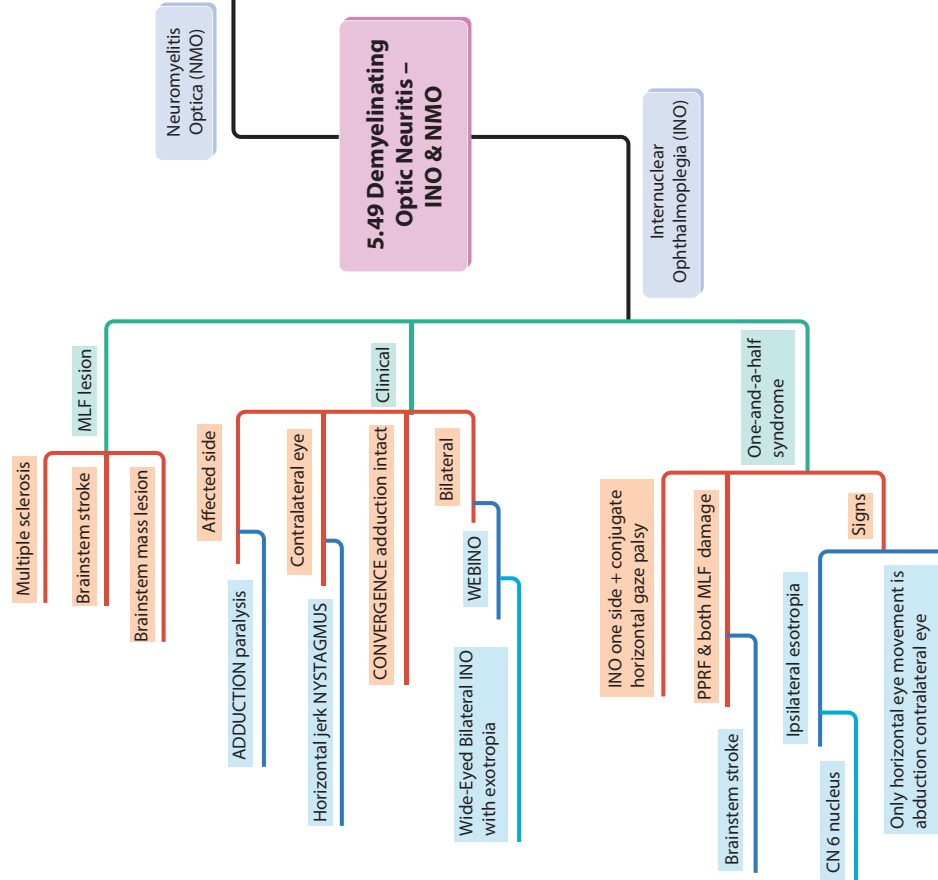
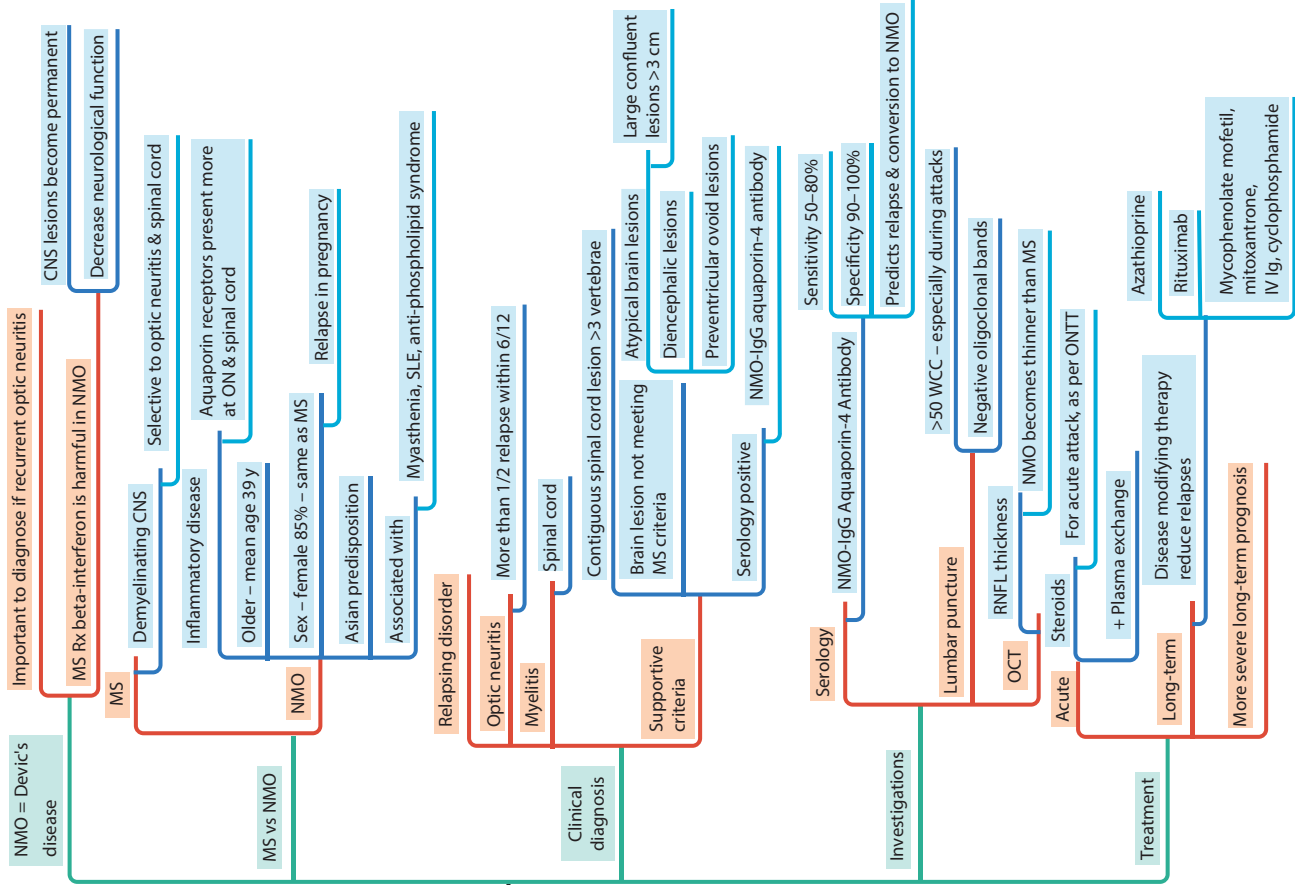


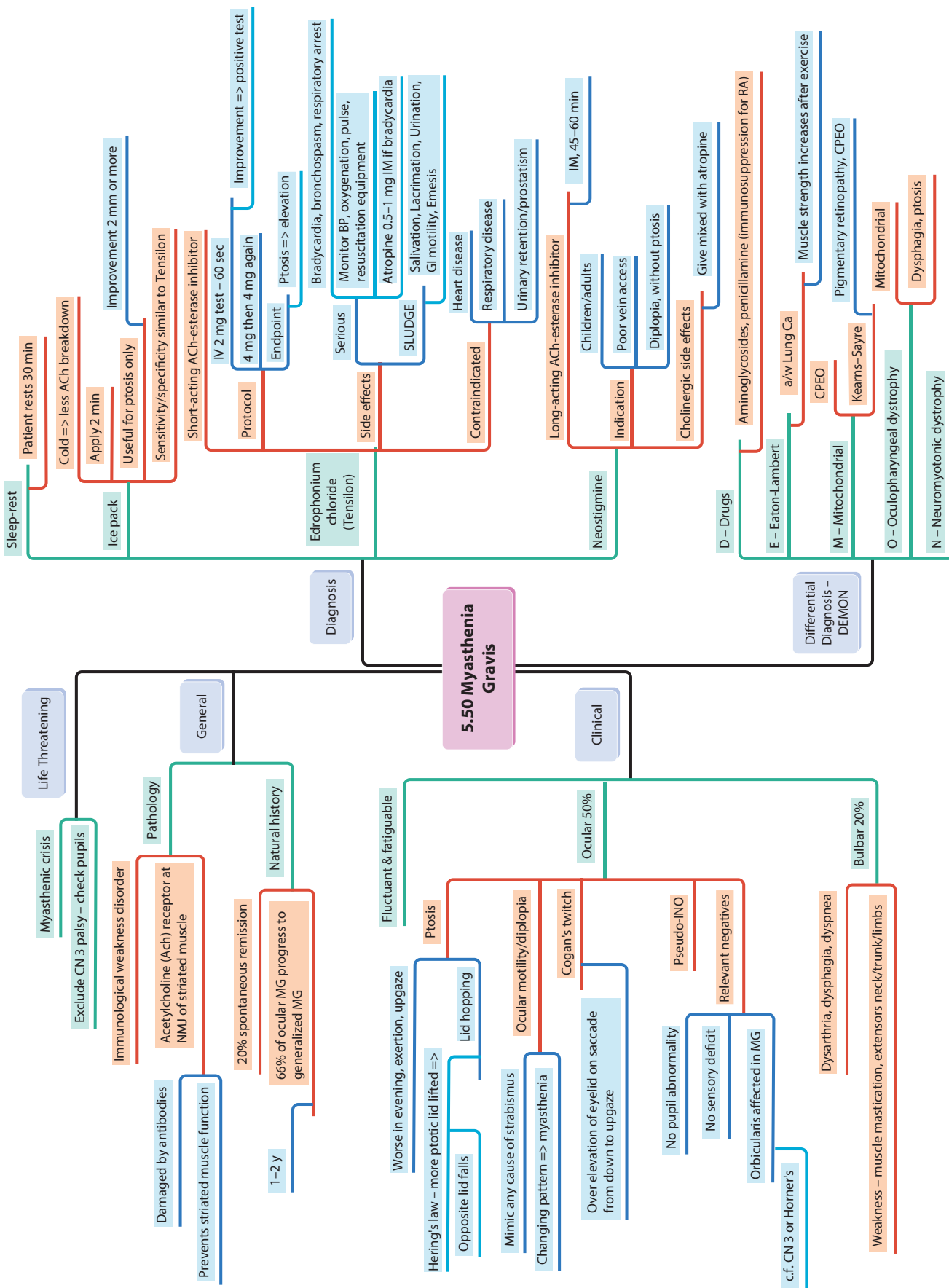


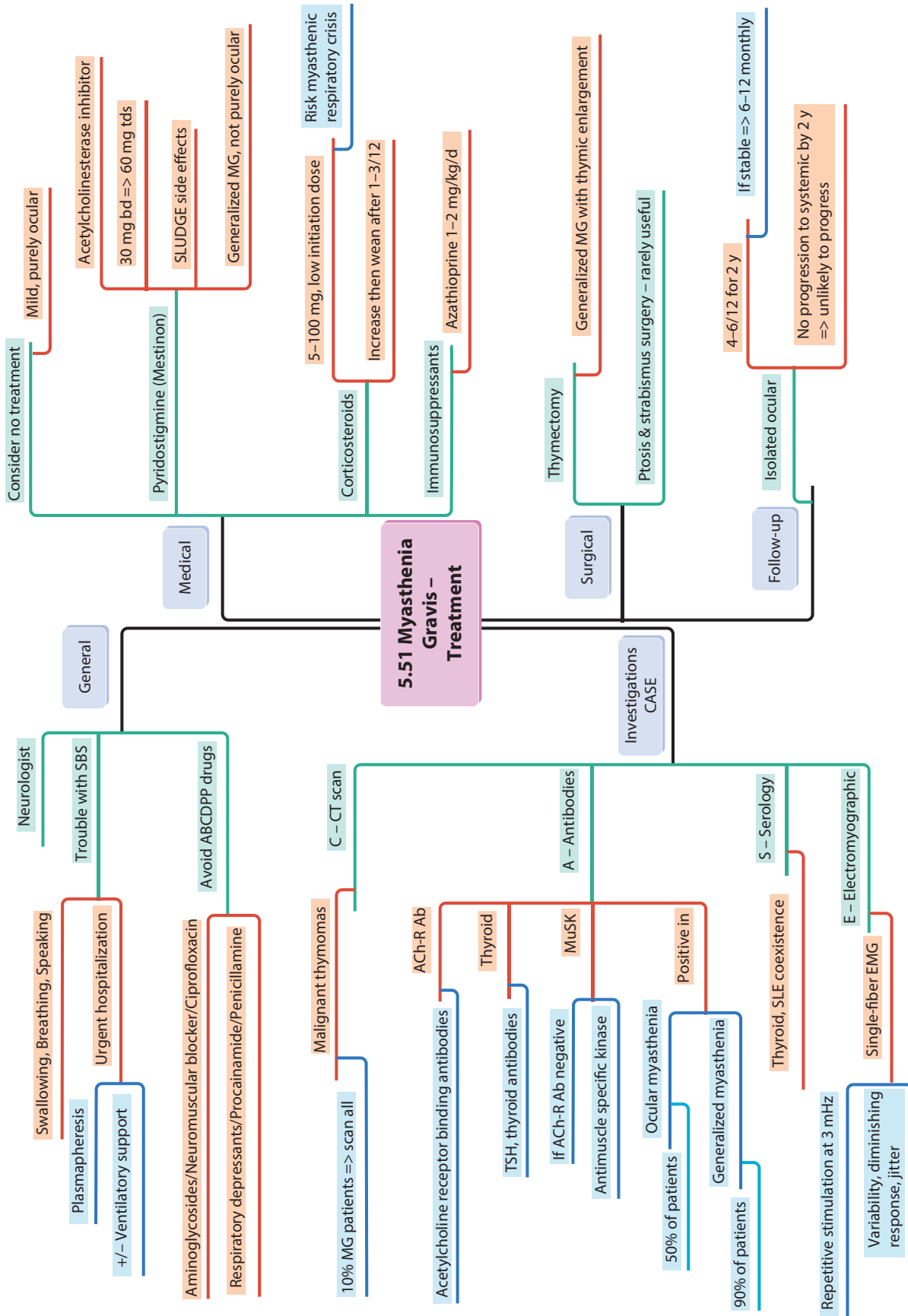


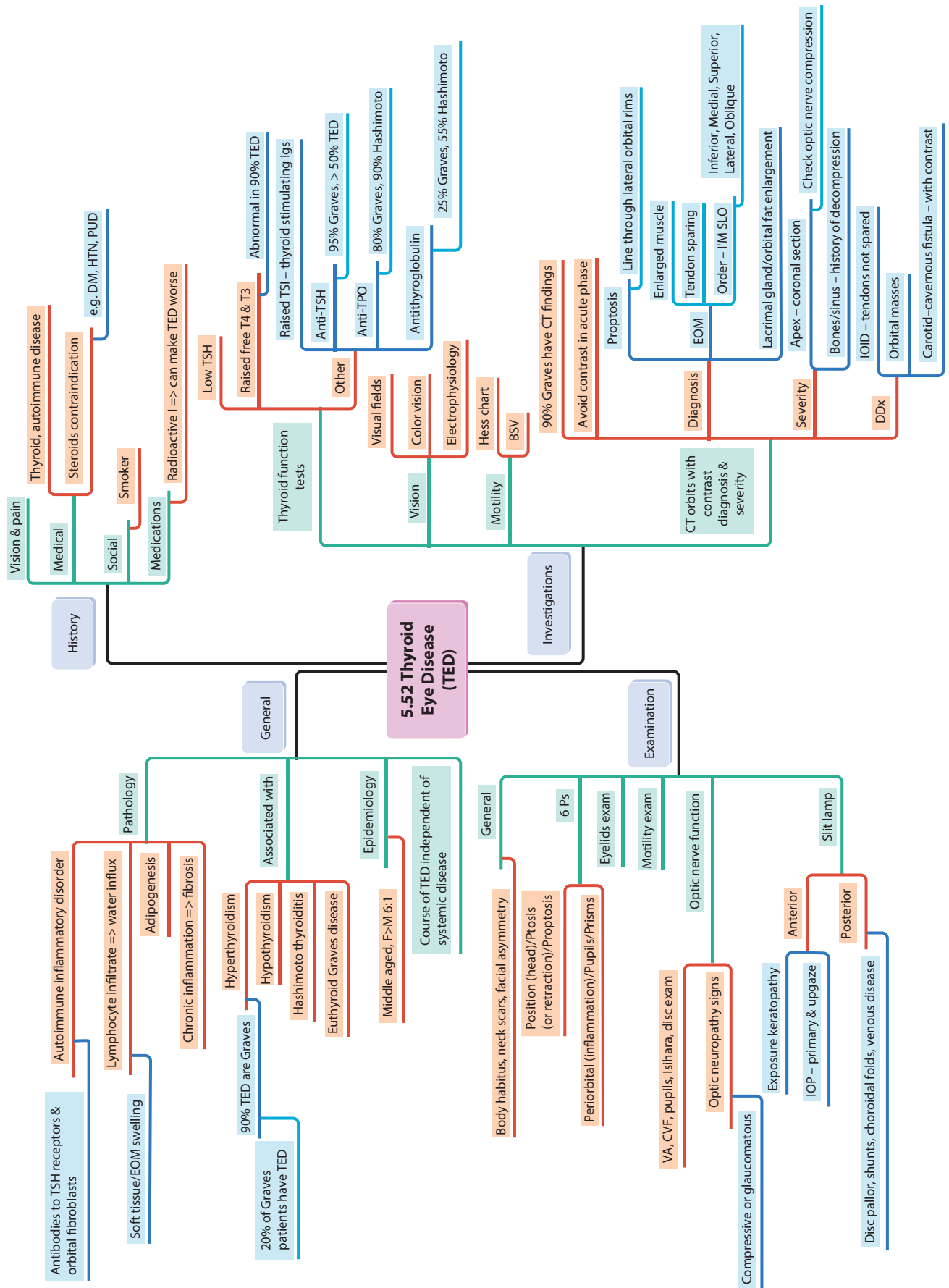


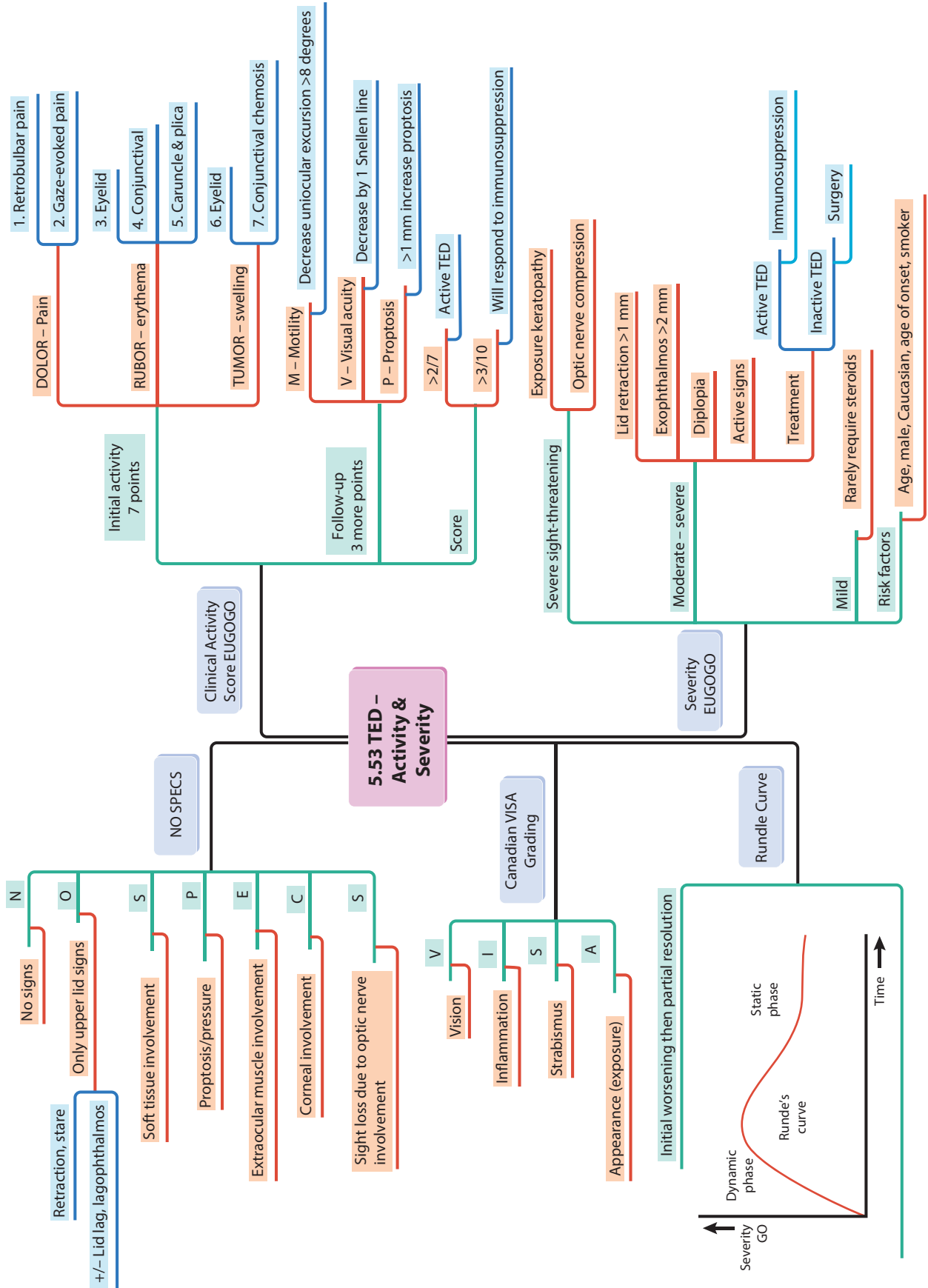


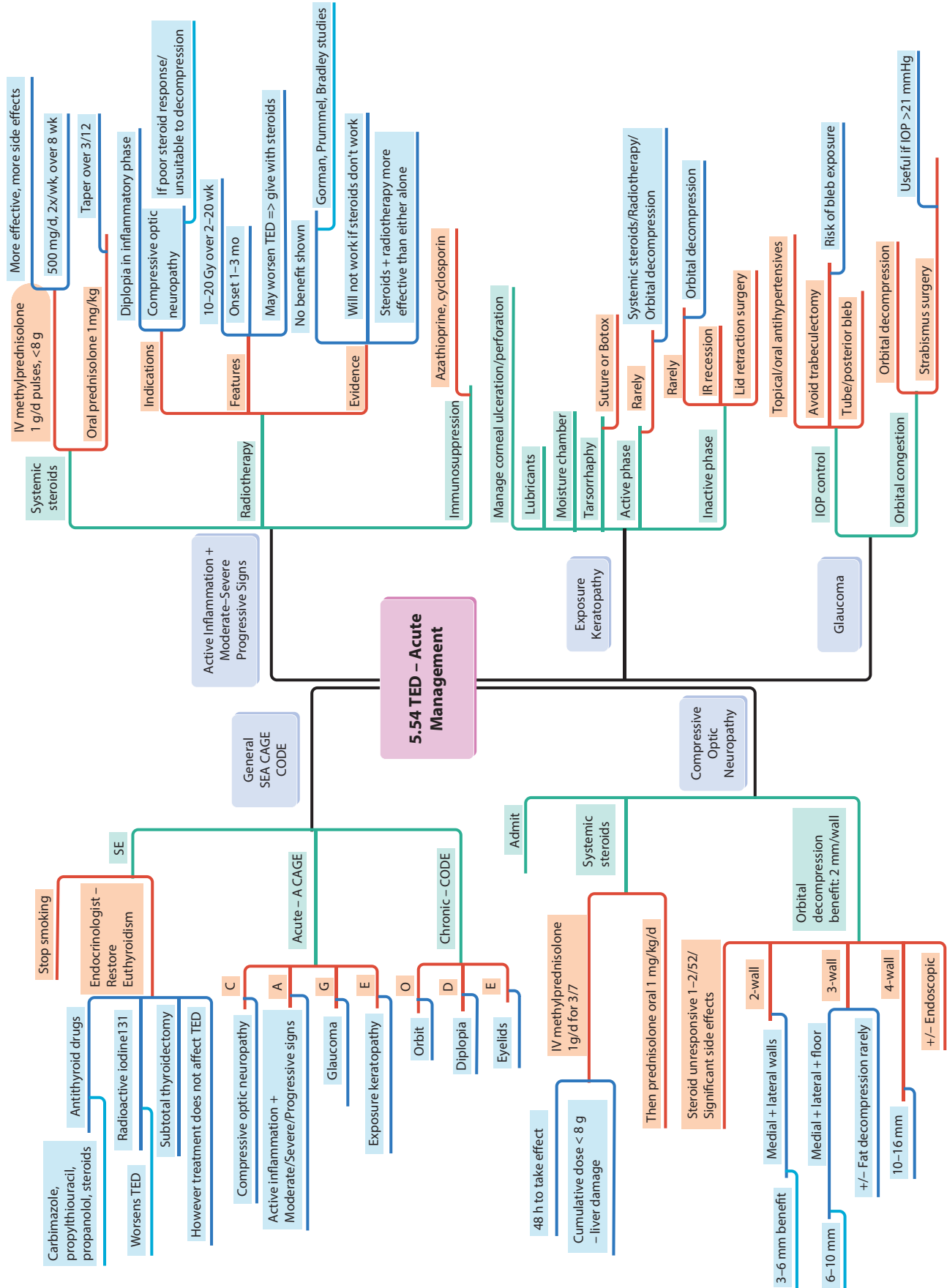


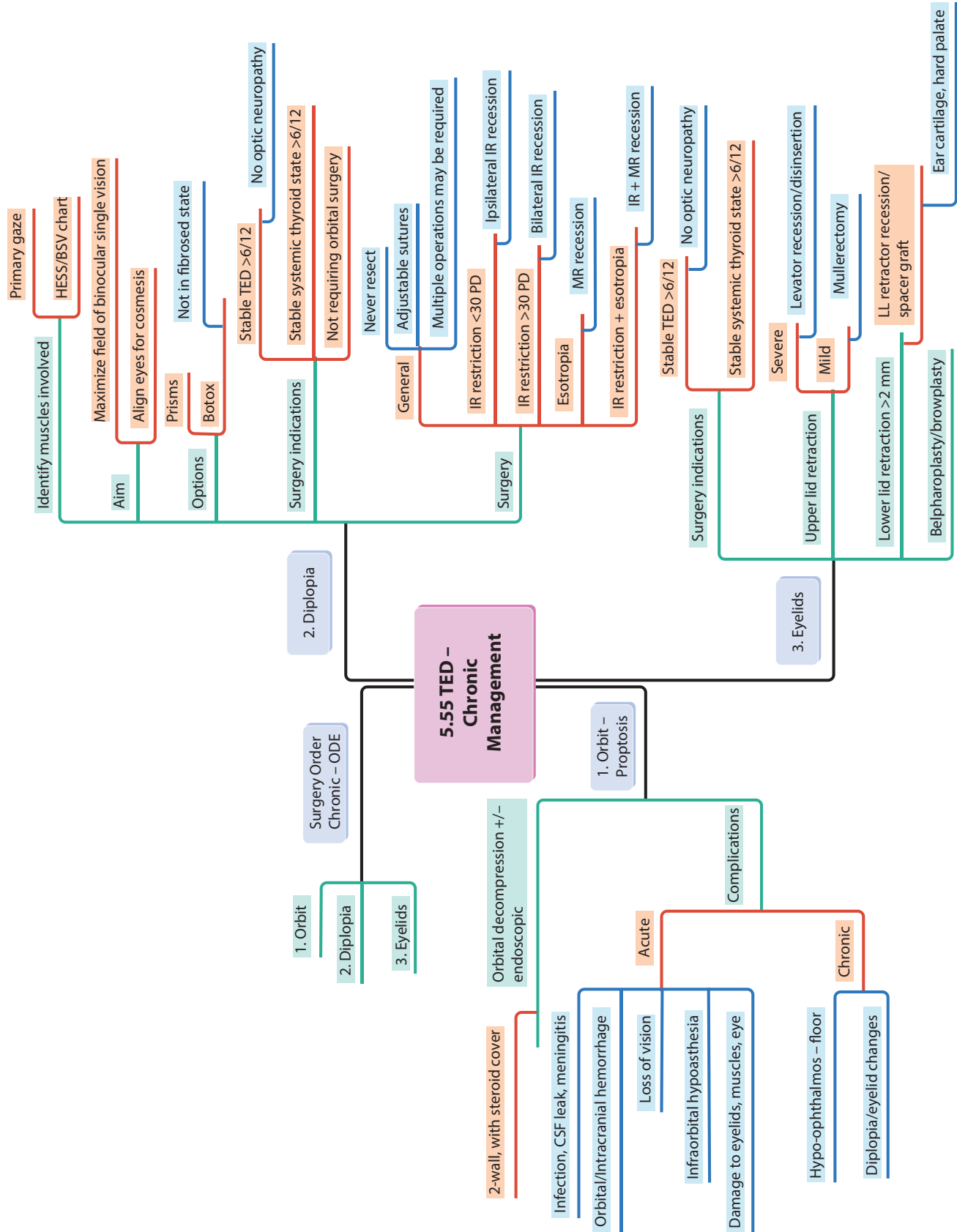


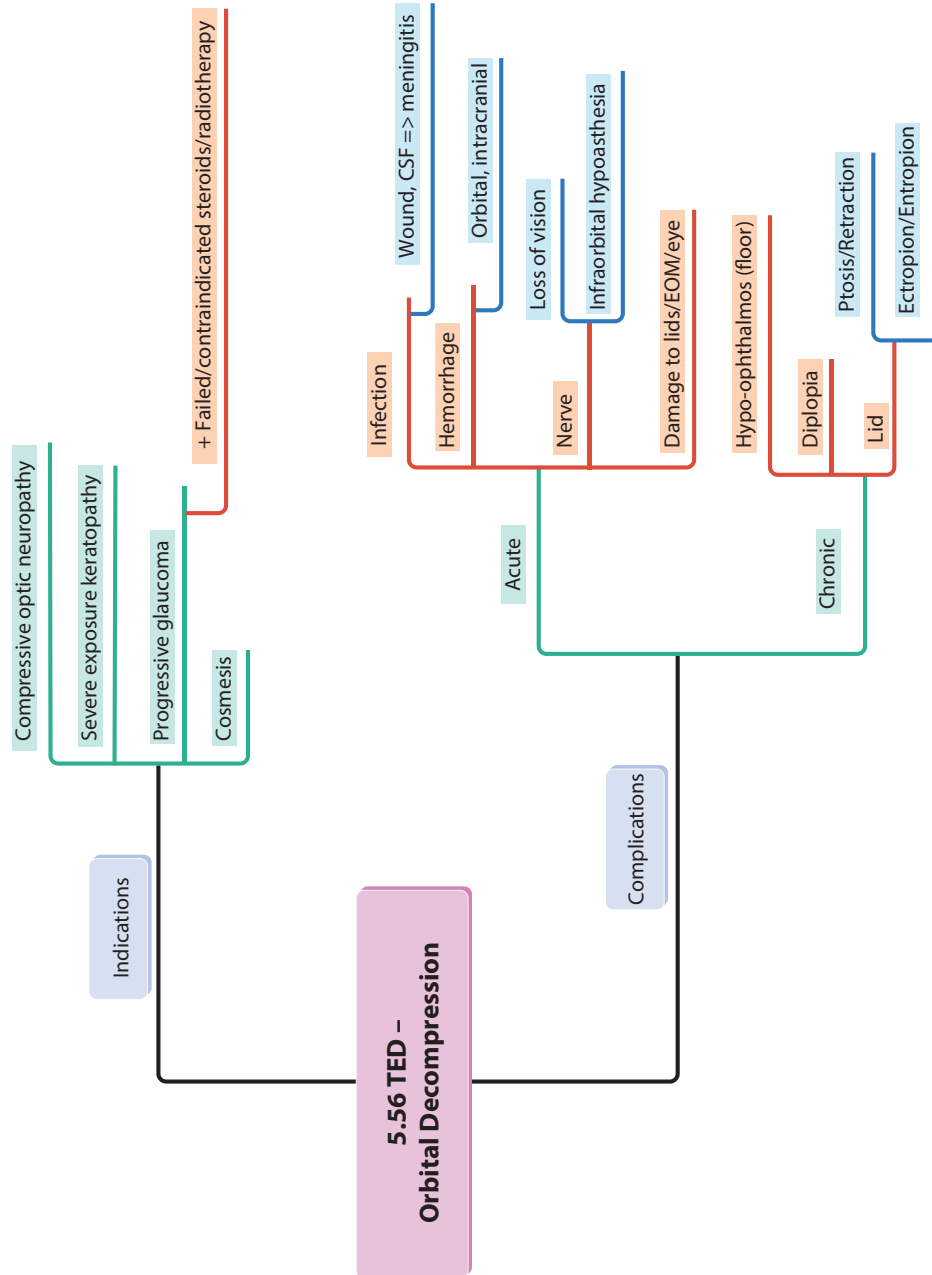


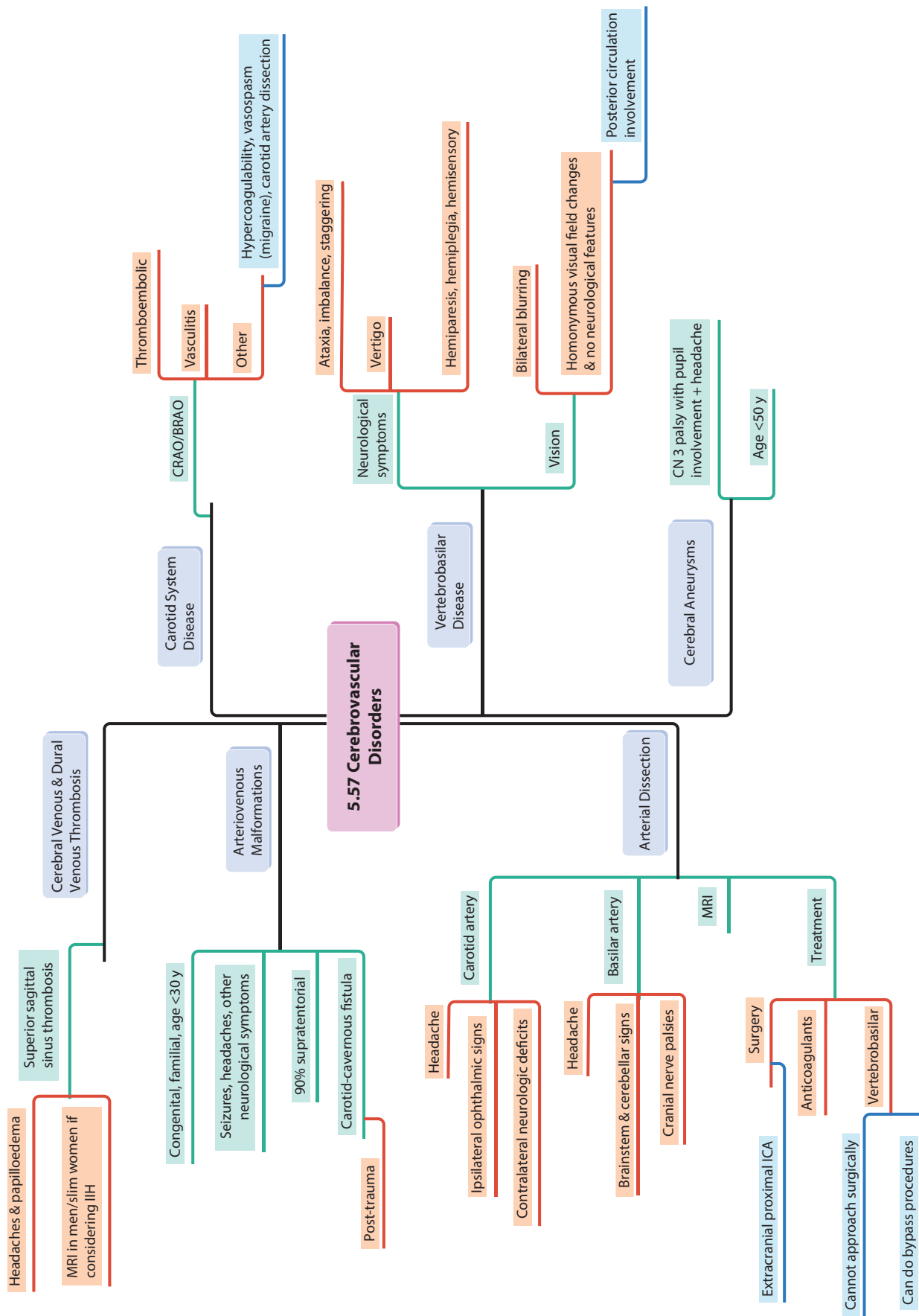


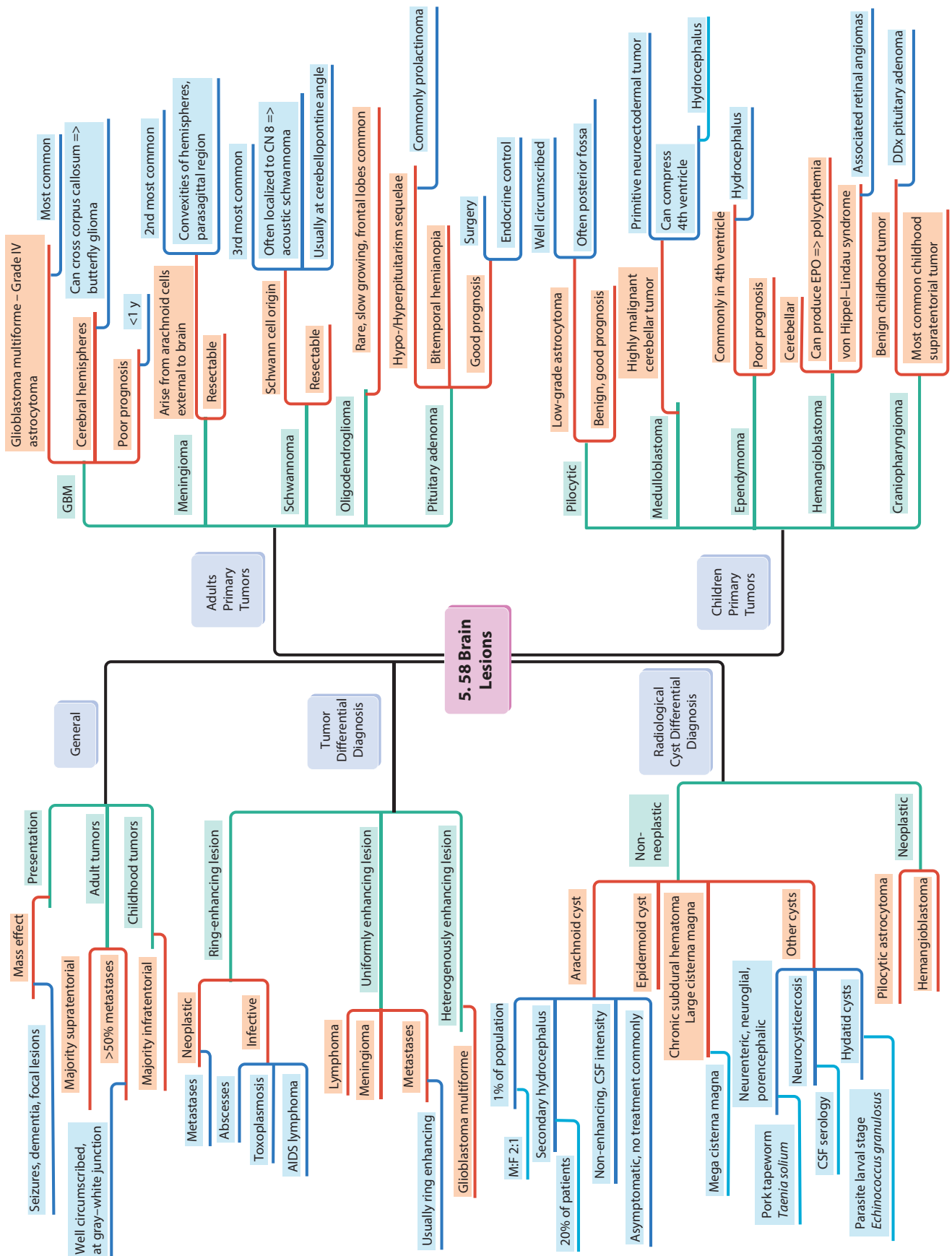


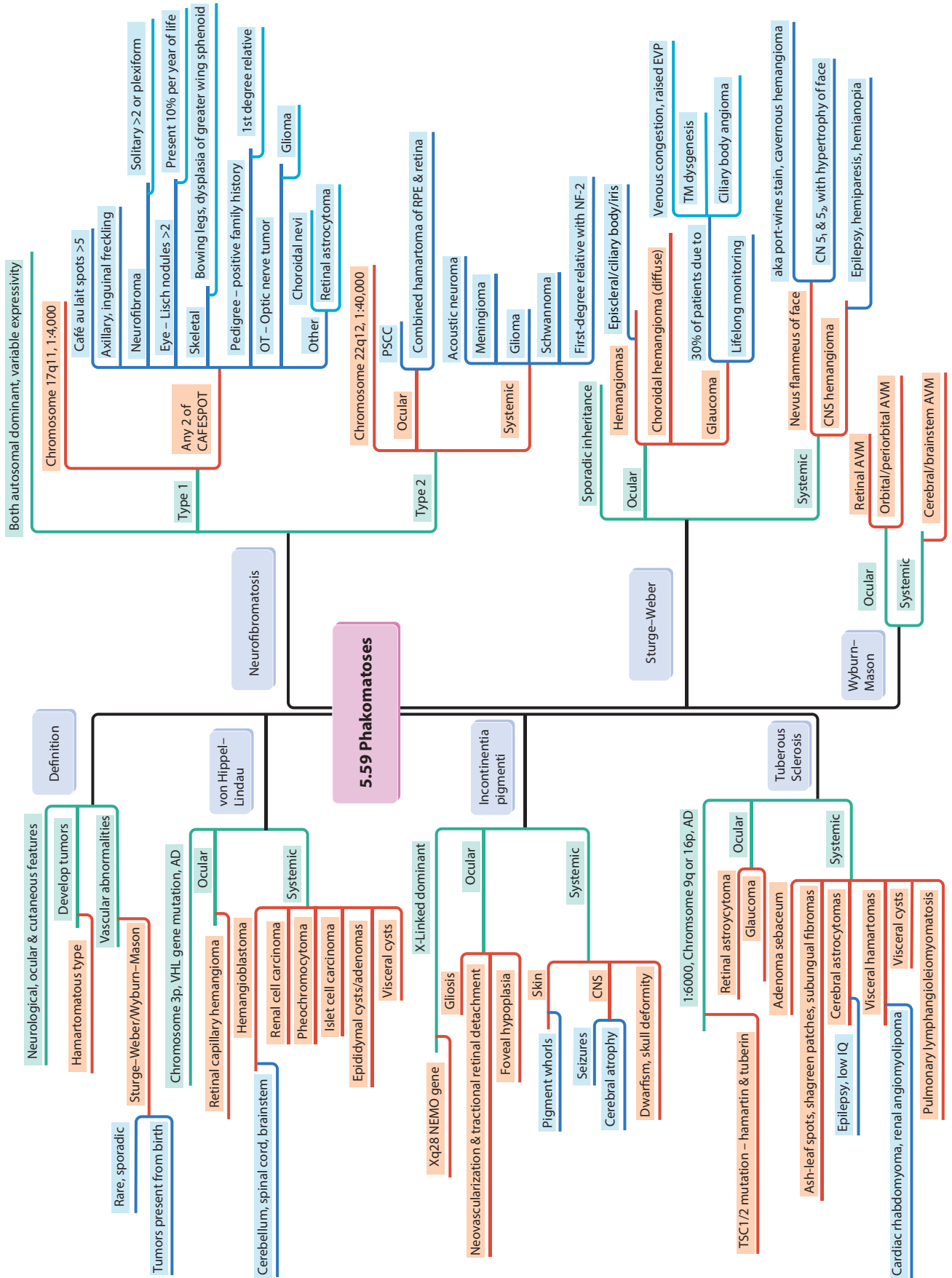


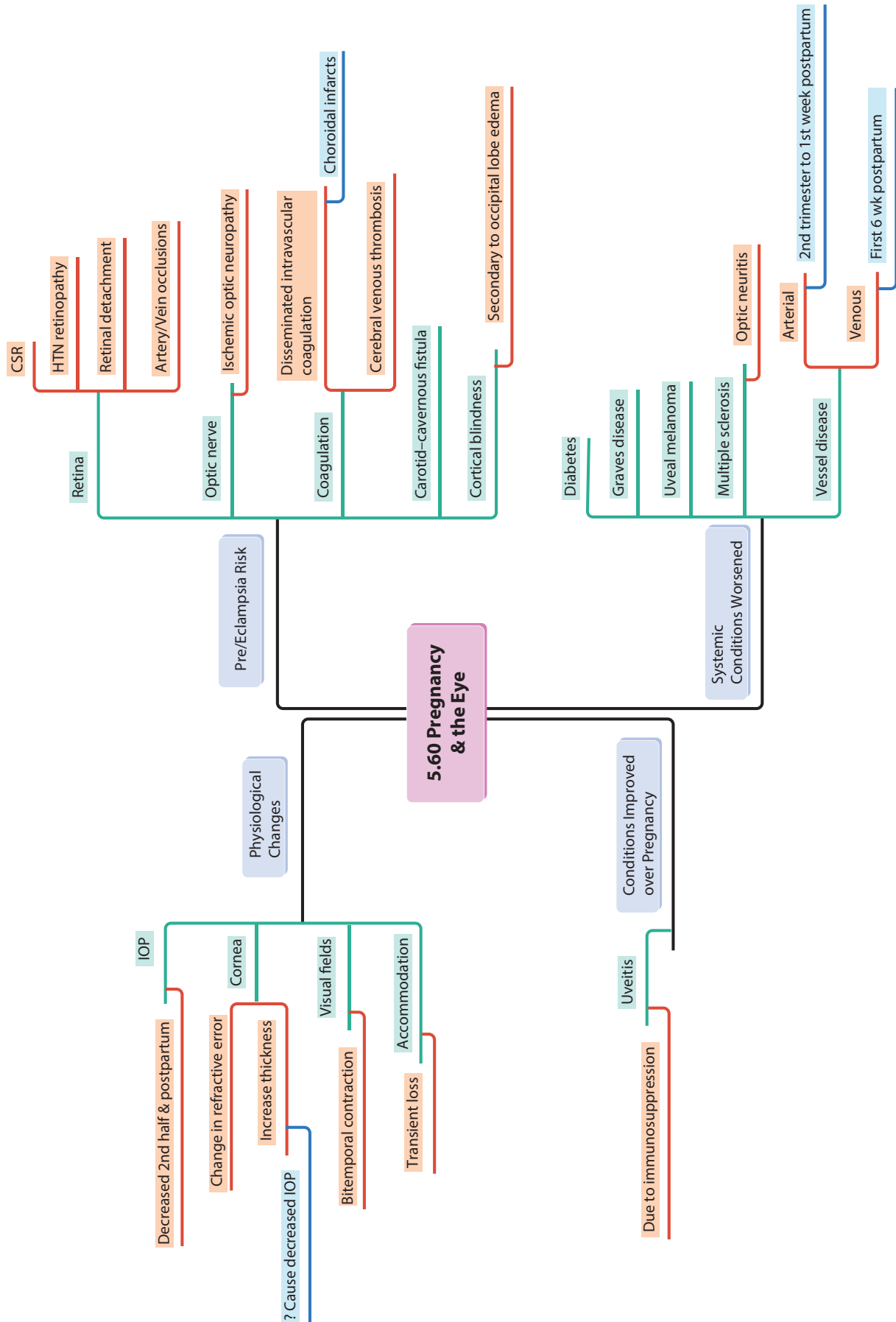




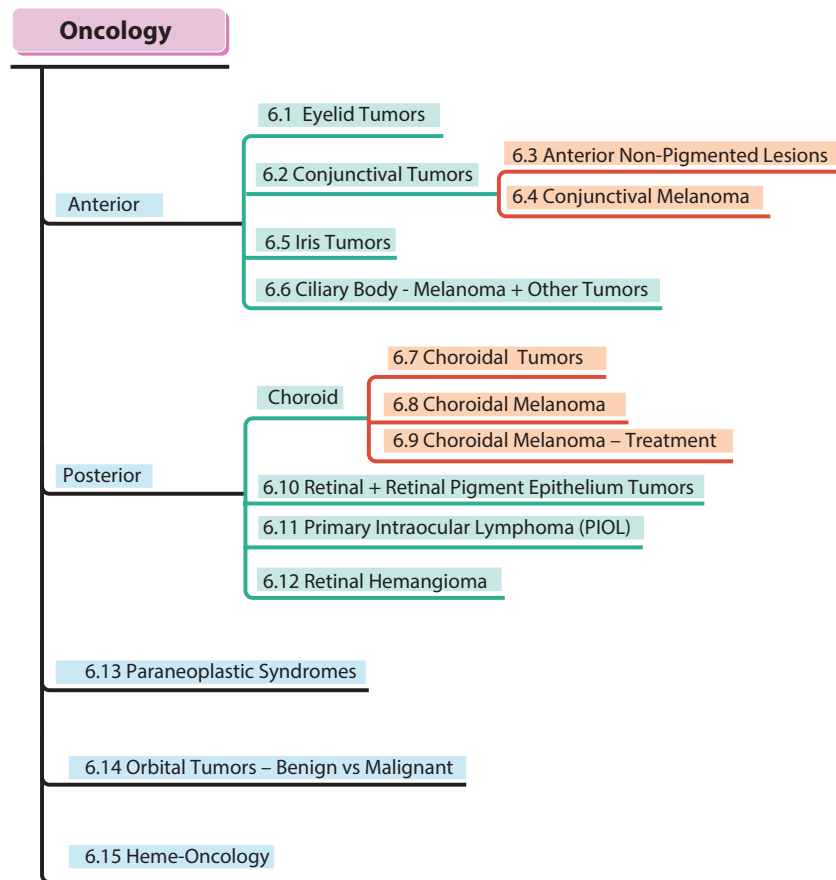


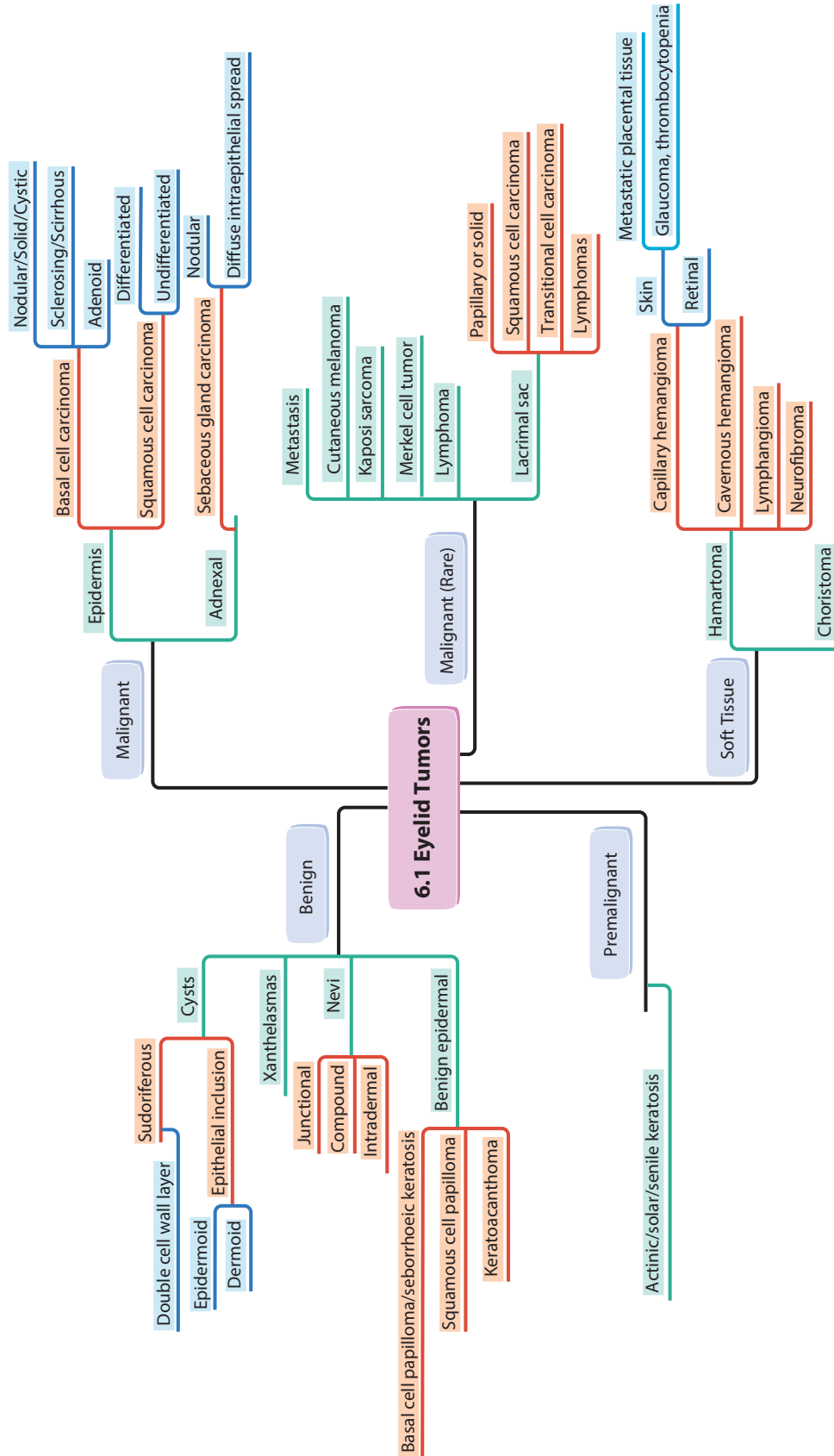


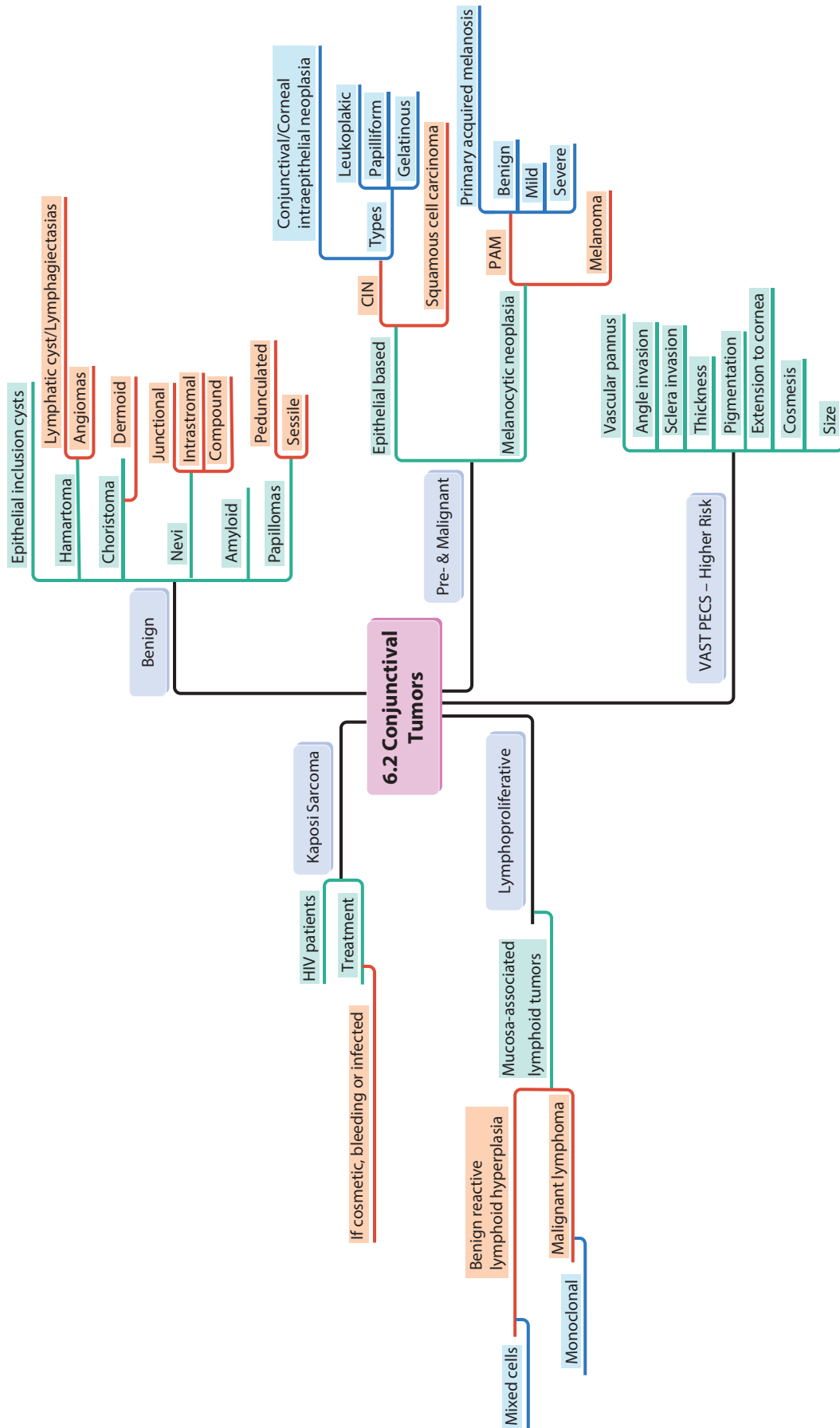


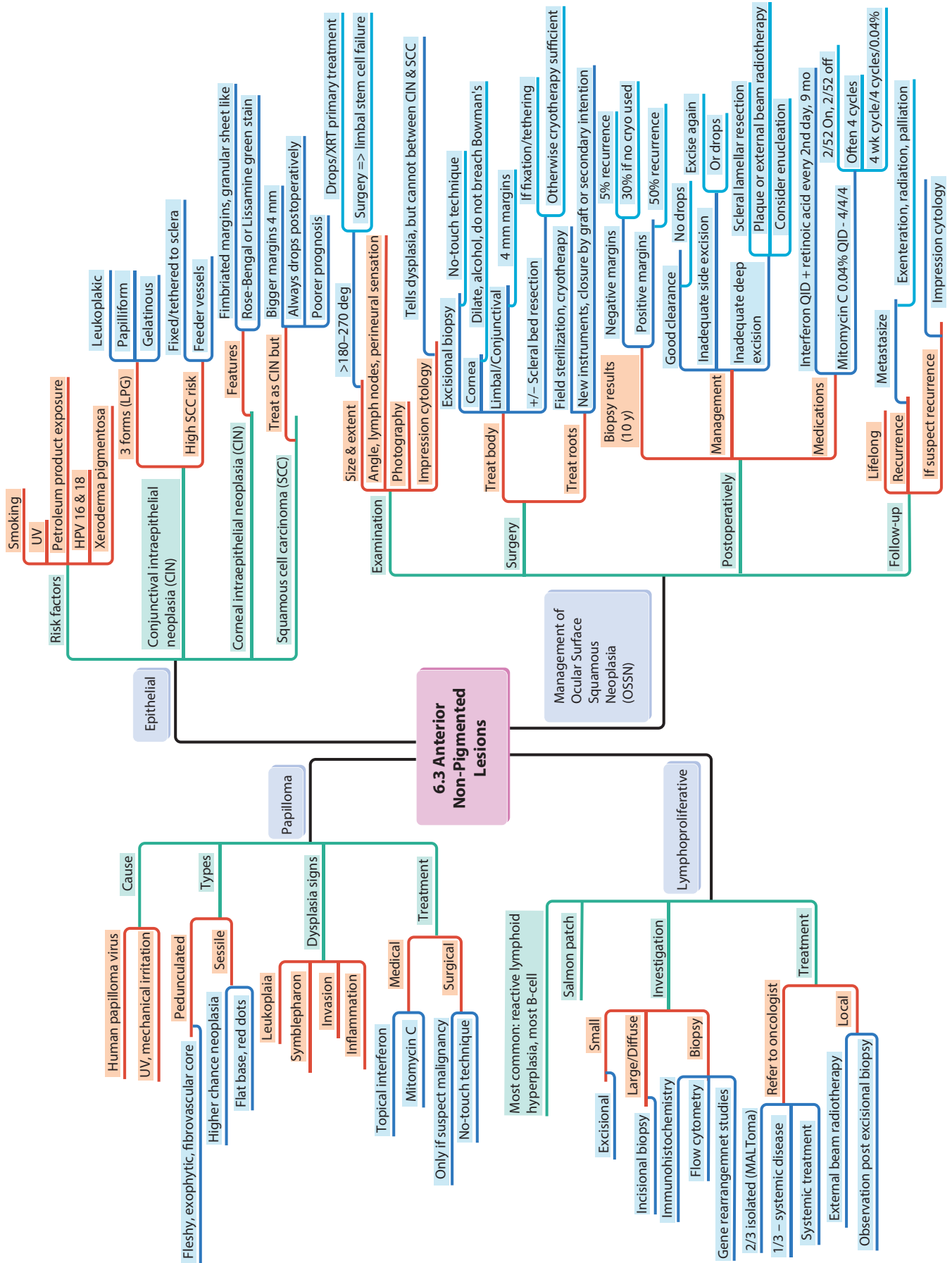


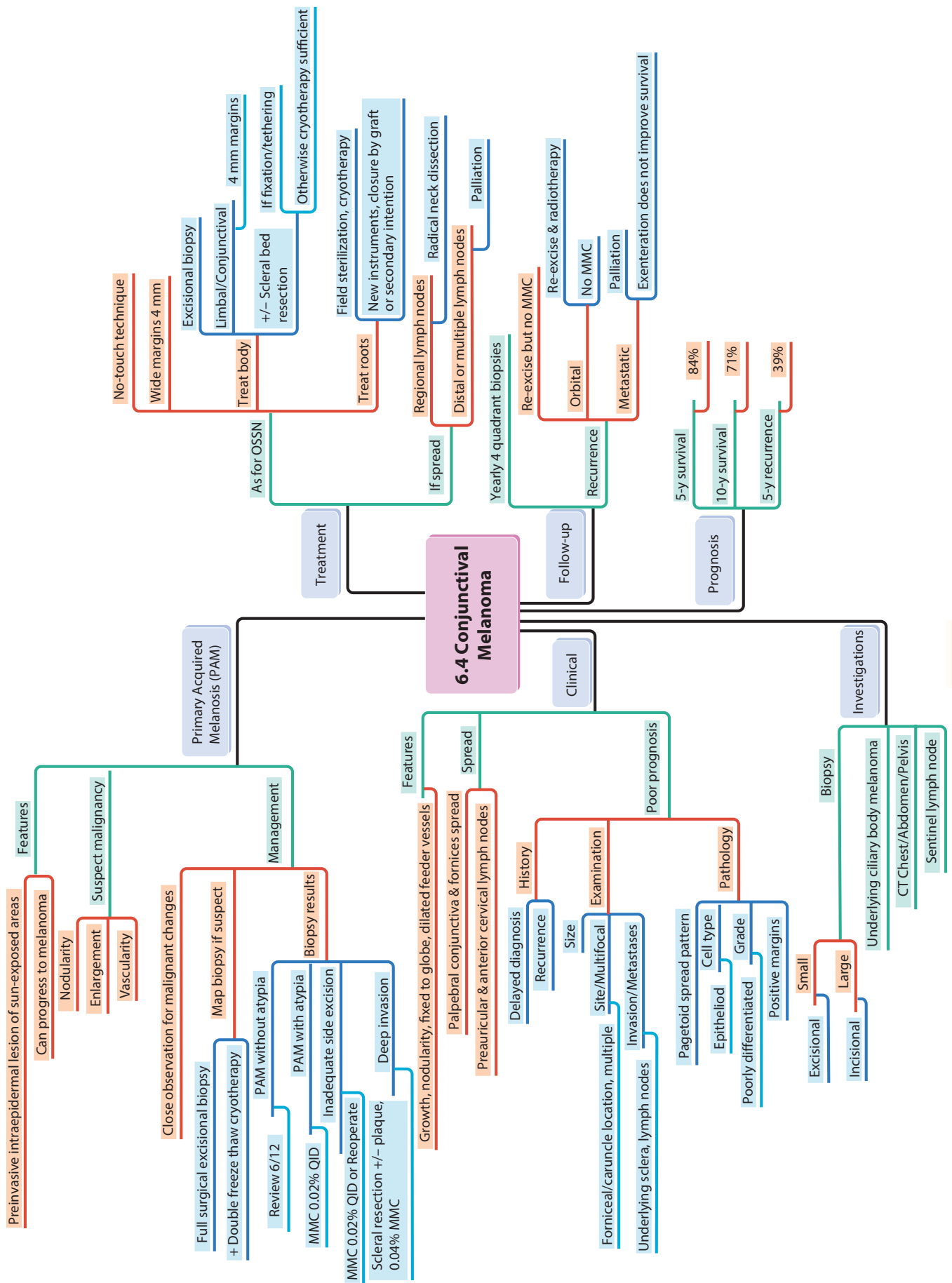
6 Oncology

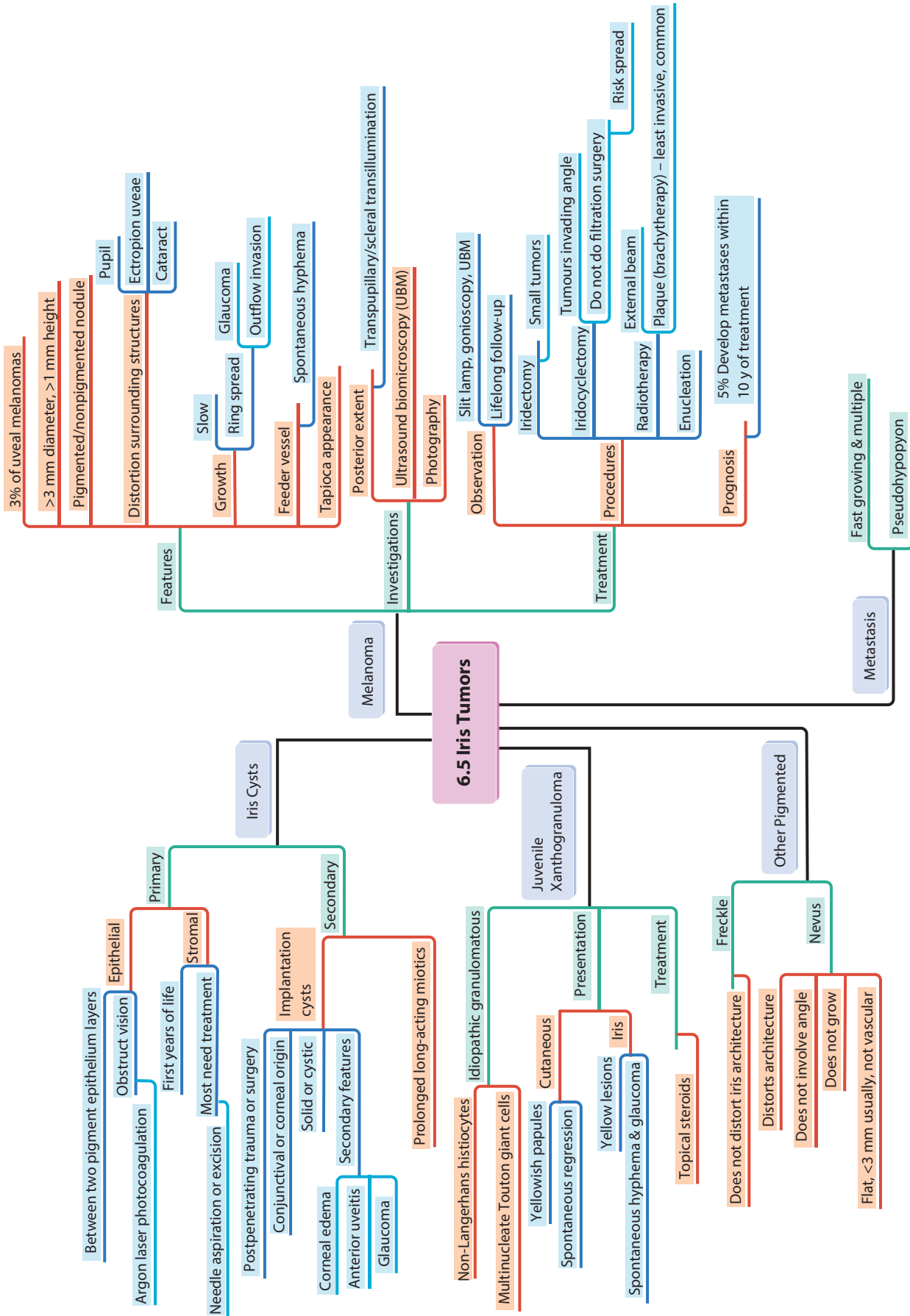


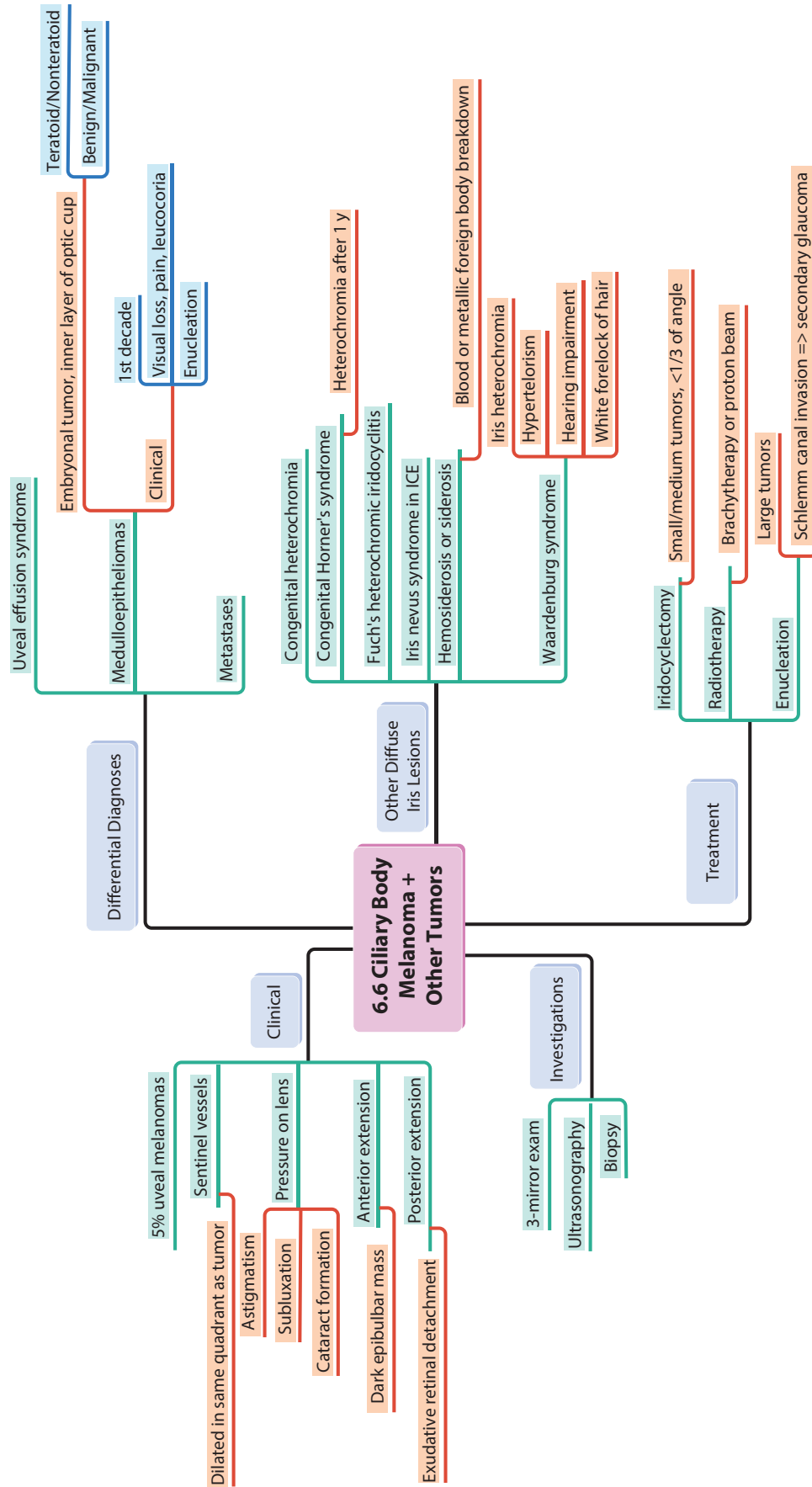


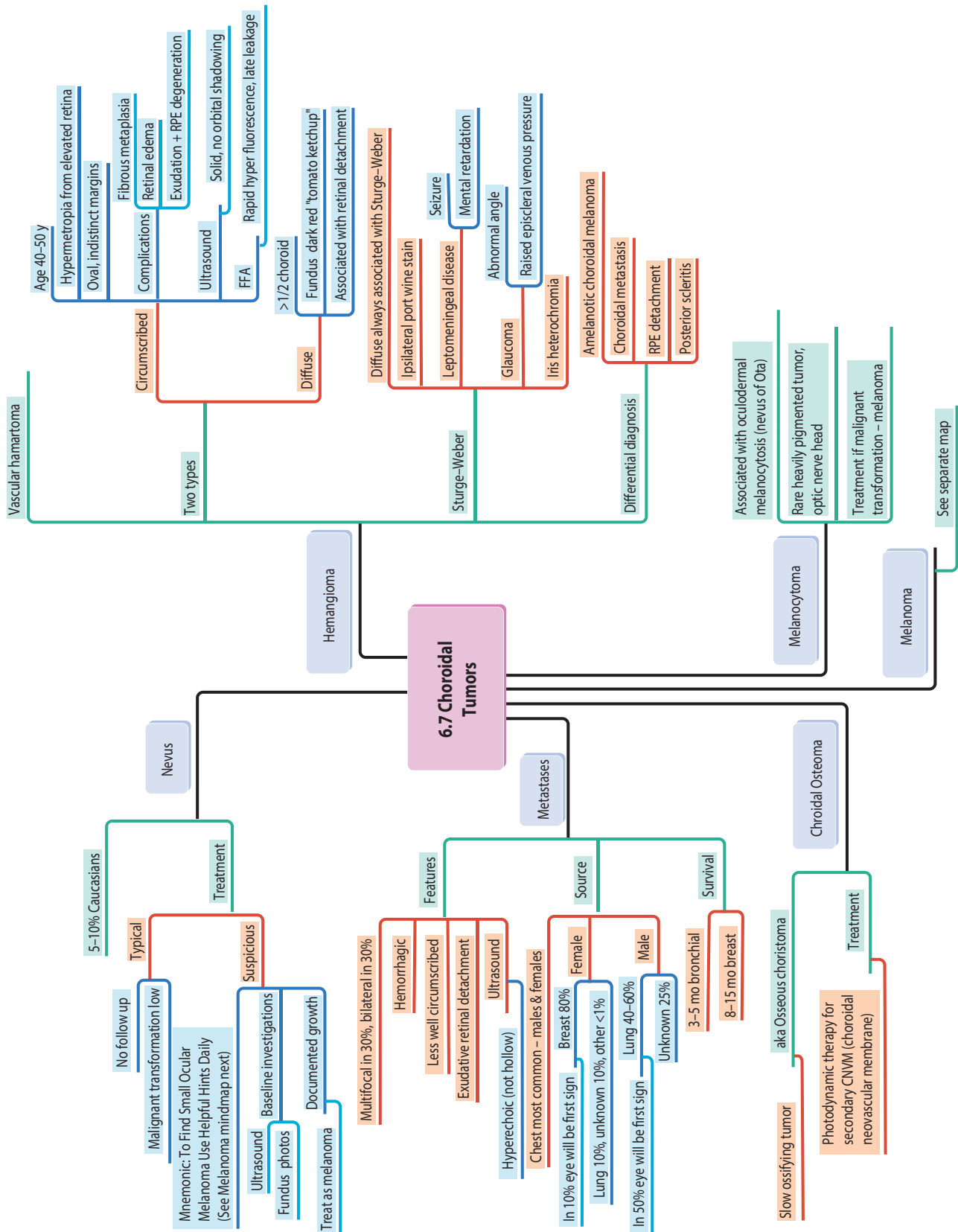


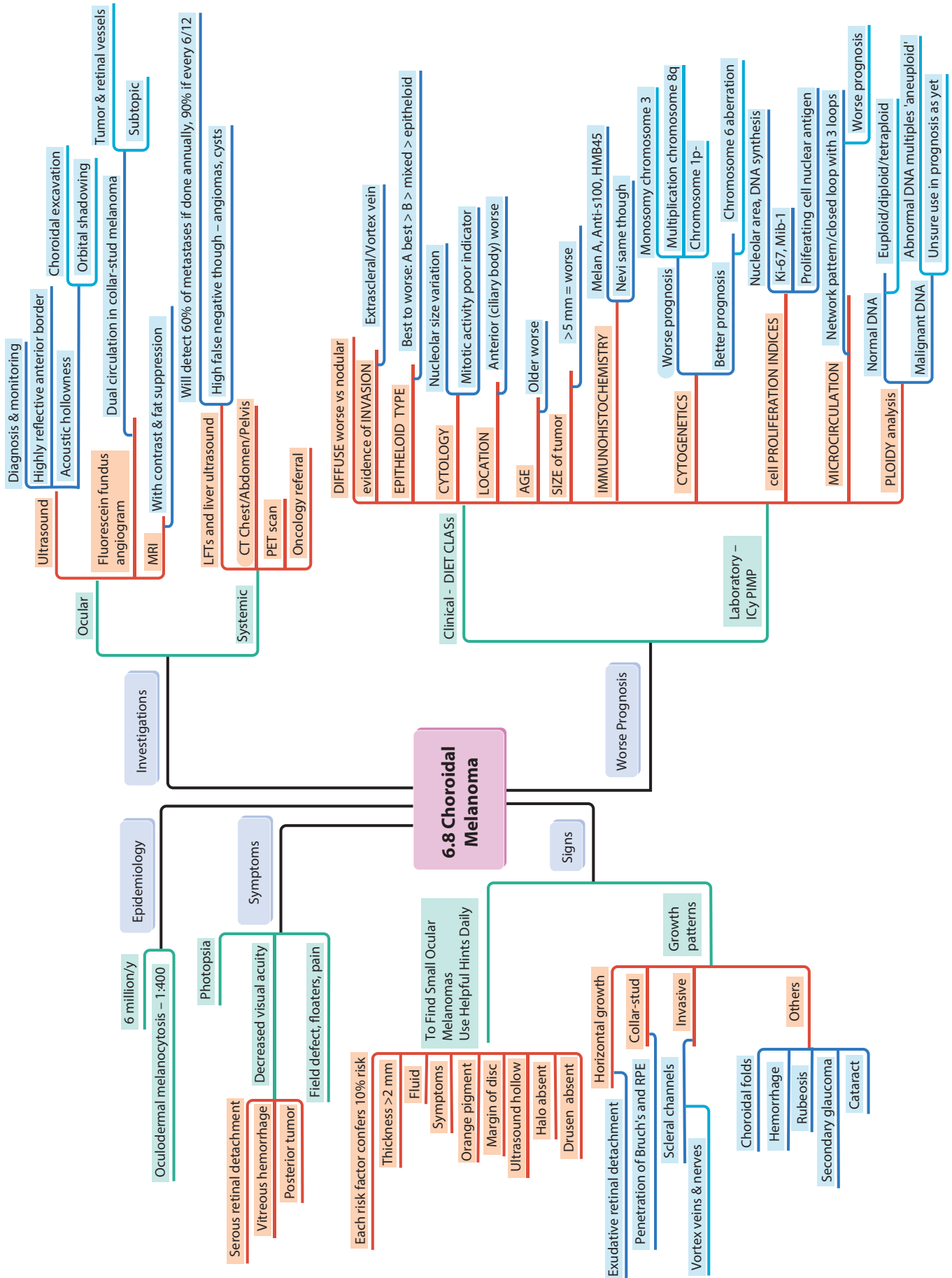


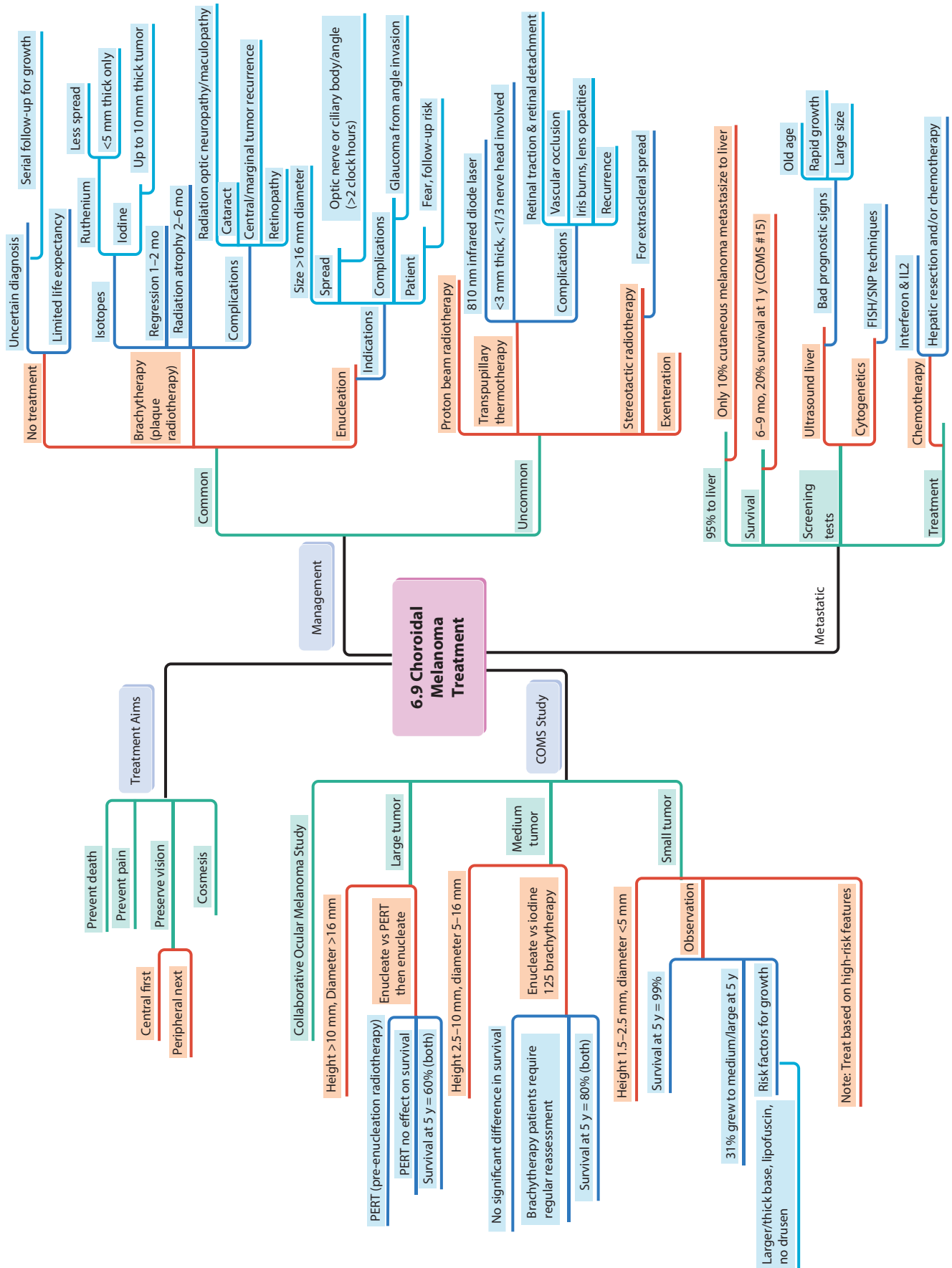


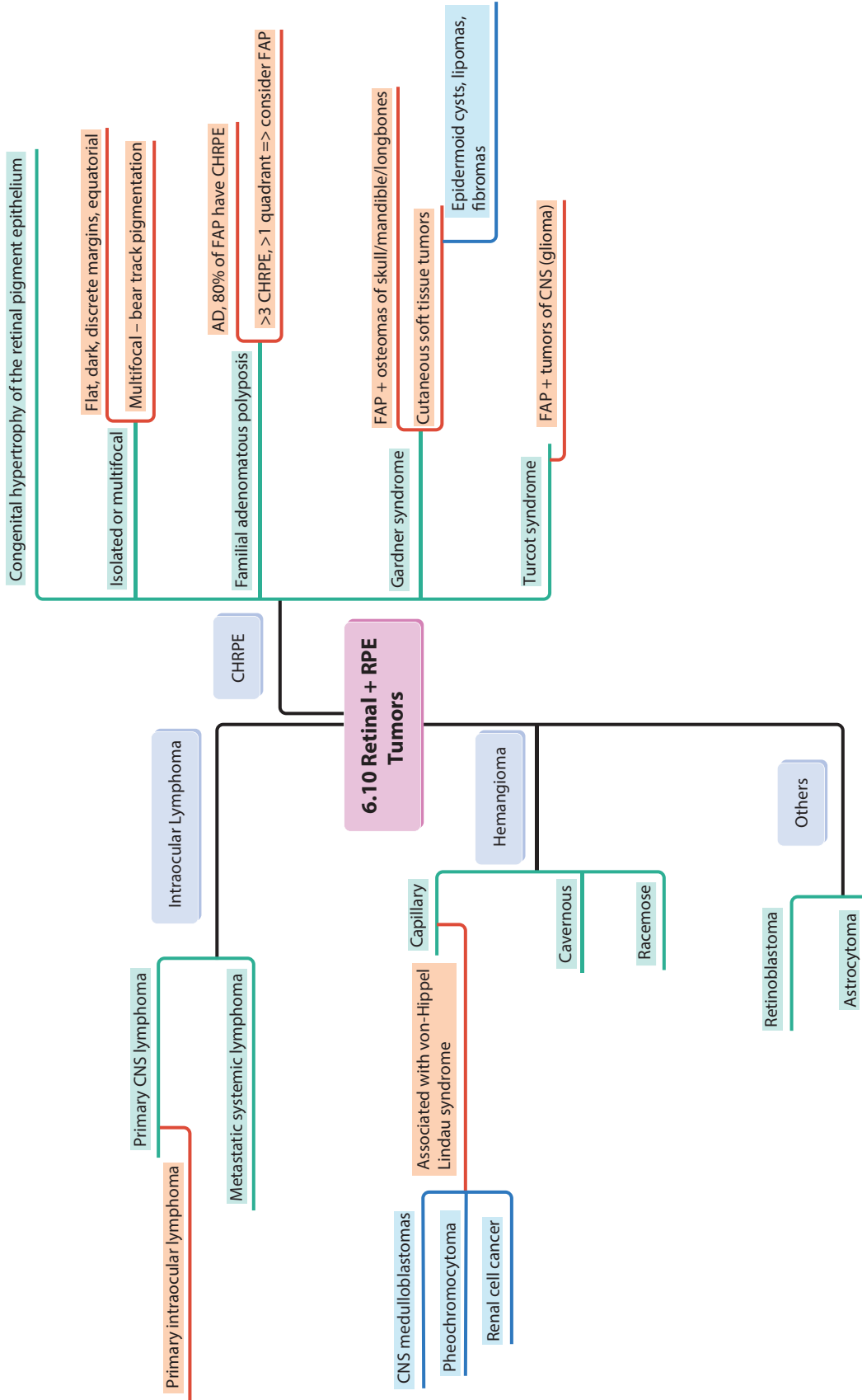












6.10 Retinal + RPE Tumors

Intraocular Lymphoma

CHRPE

Primary CNS lymphoma

Metastatic systemic lymphoma

Primary intraocular lymphoma

CNS medulloblastomas

Pheochromocytoma

Renal cell cancer

Associated with von-Hippel Lindau syndrome

Capillary

Hemangioma

Cavernous

Racemose

Retinoblastoma

Astrocytoma

Others

Congenital hypertrophy of the retinal pigment epithelium

Isolated or multifocal

Flat, dark, discrete margins, equatorial

Multifocal - bear track pigmentation

Familial adenomatous polyposis

AD, 80% of FAP have CHRPE

>3 CHRPE, >1 quadrant => consider FAP

Gardner syndrome

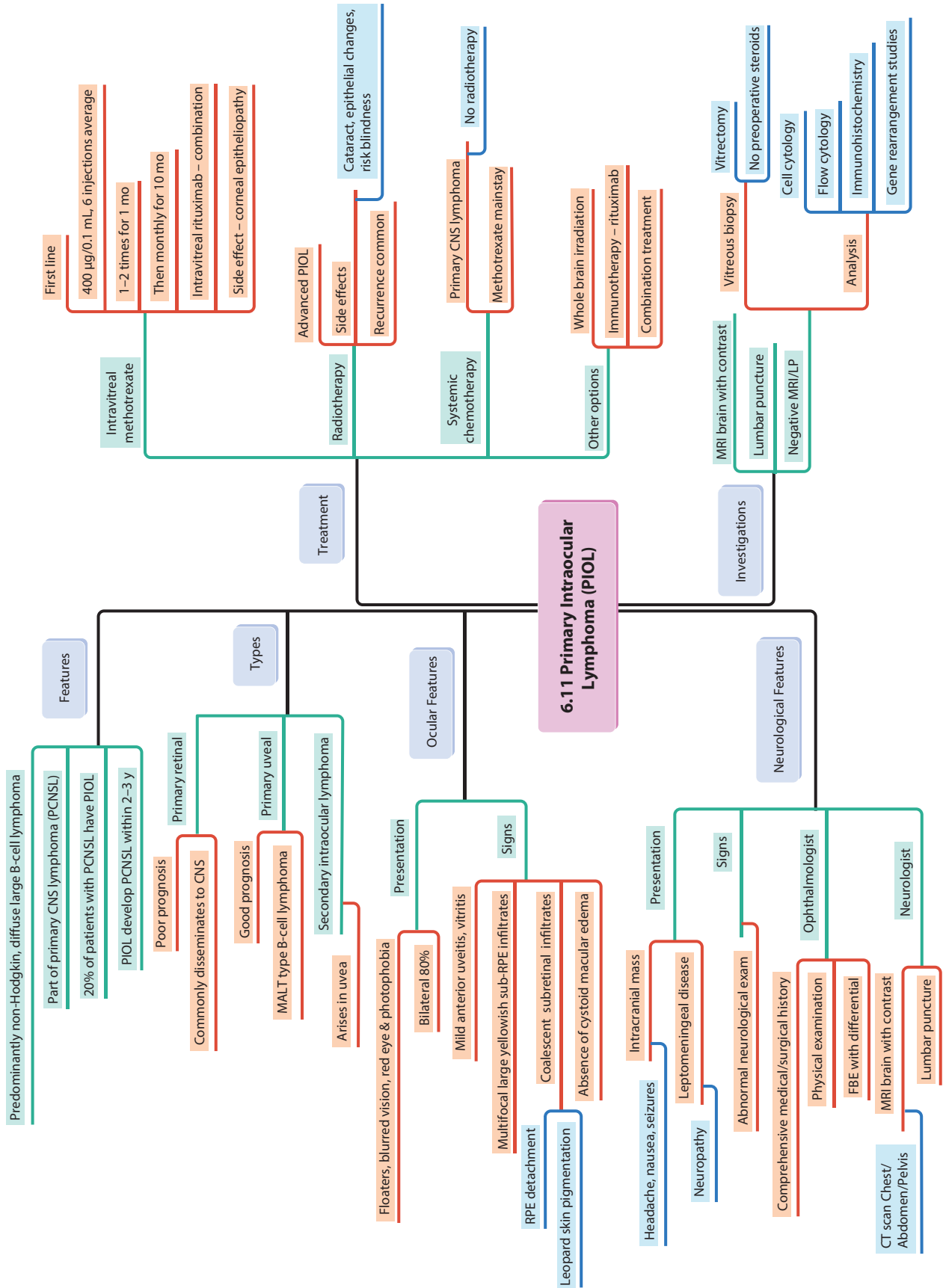
FAP + osteomas of skull/mandible/longbones

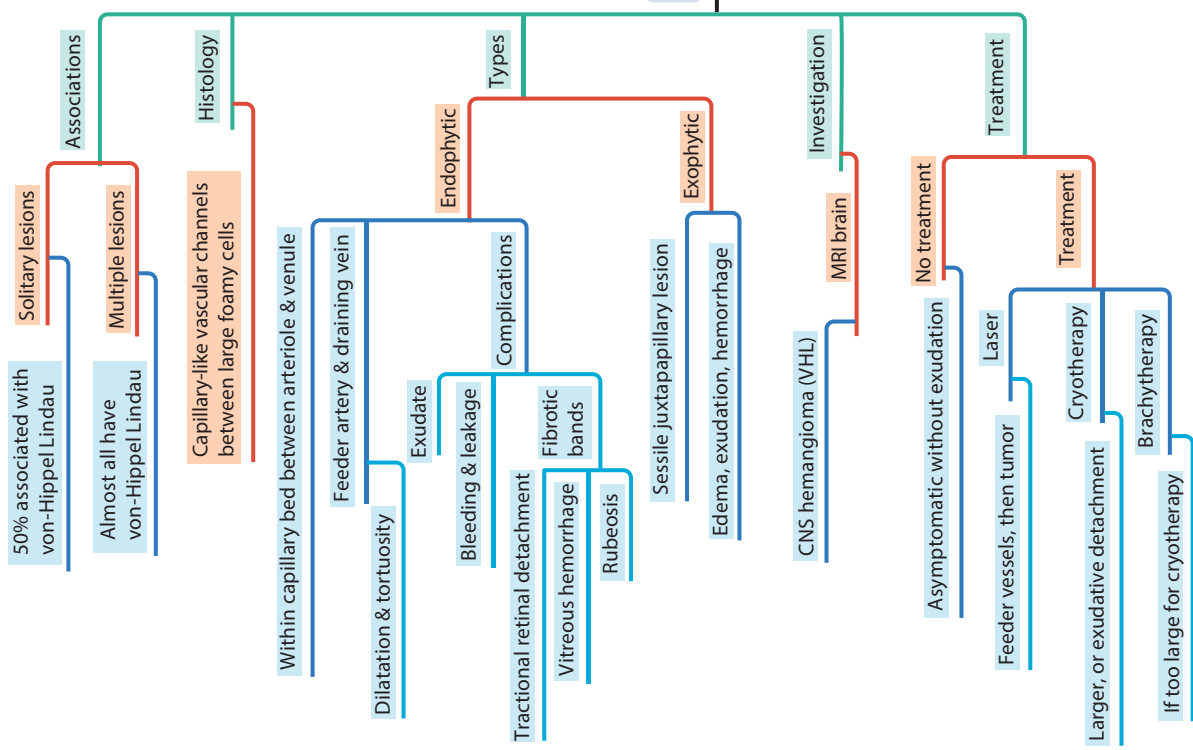
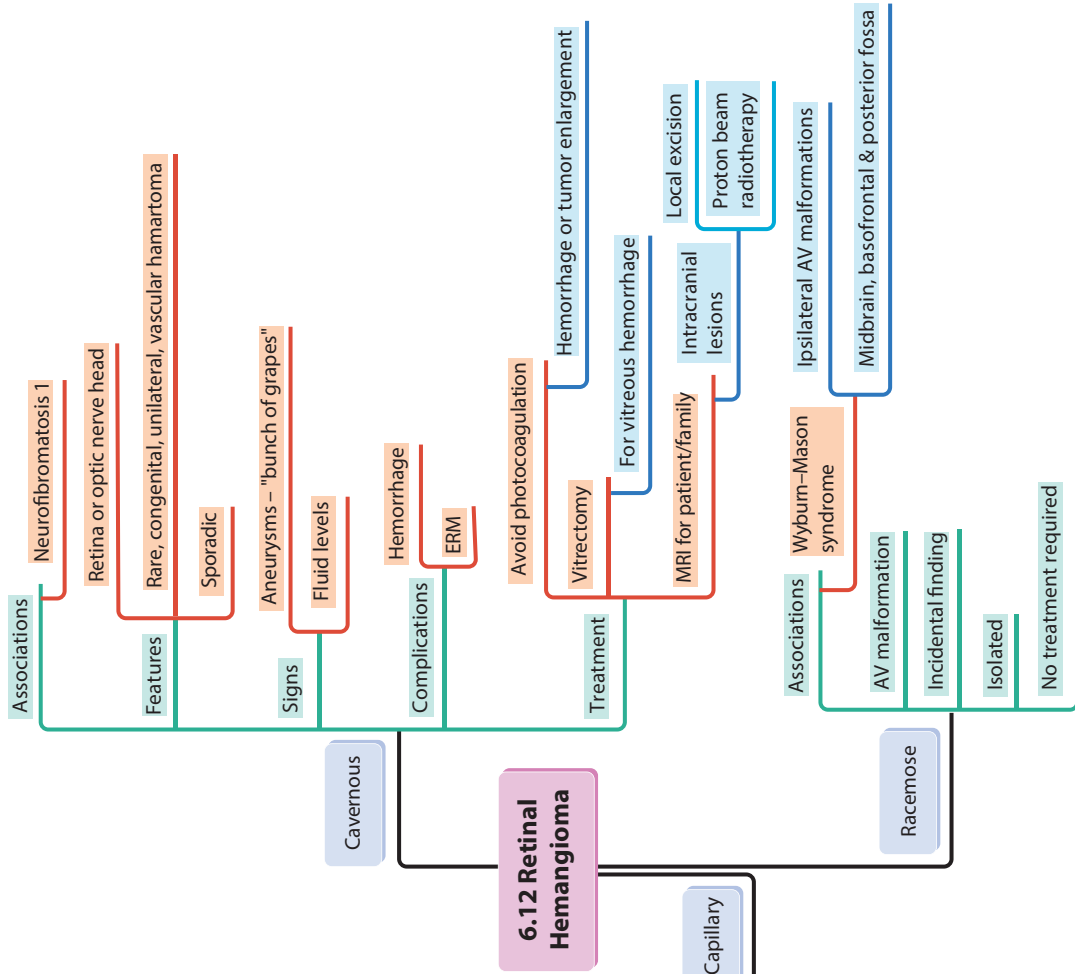
Cutaneous soft tissue tumors

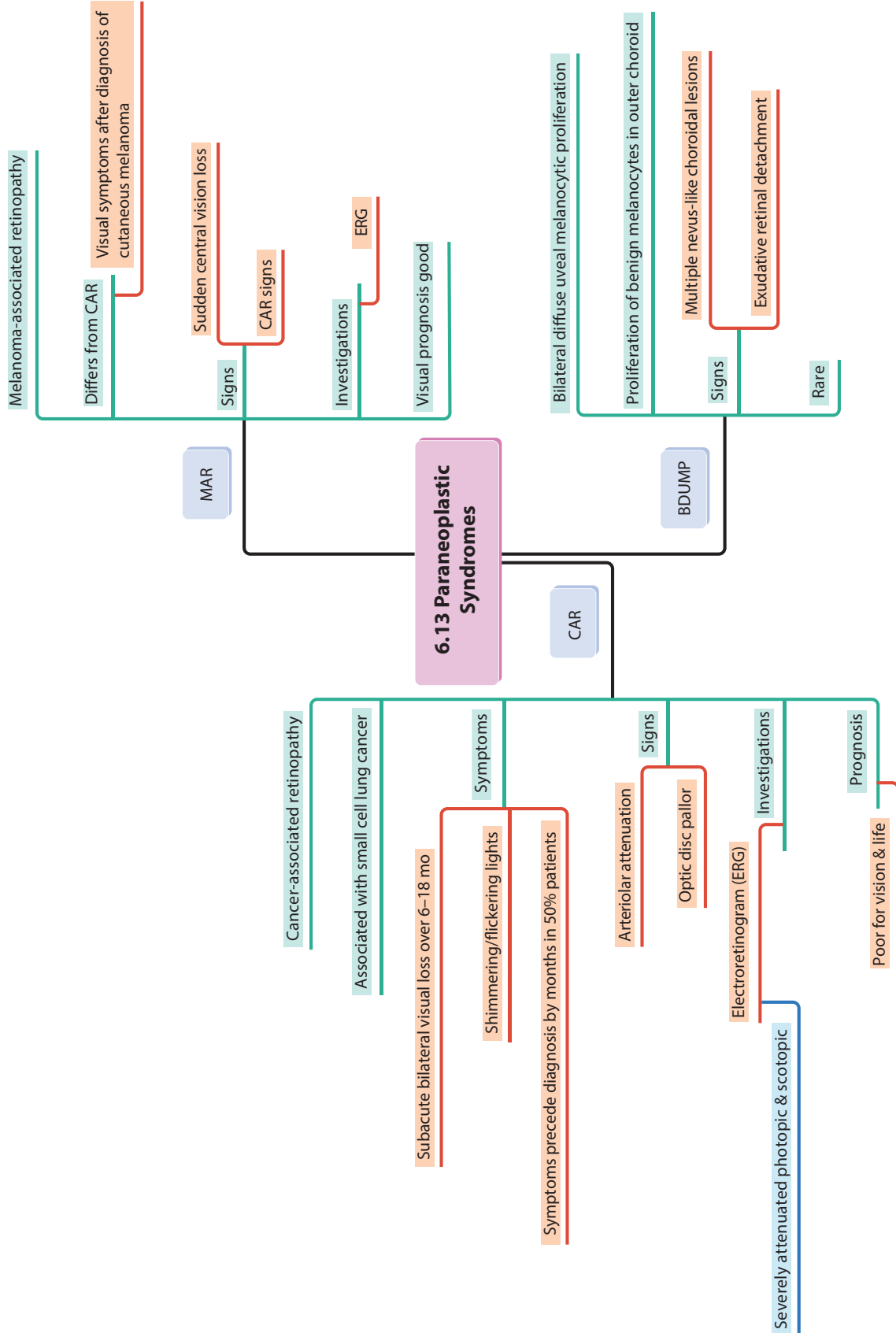
Epidermoid cysts, lipomas, fibromas

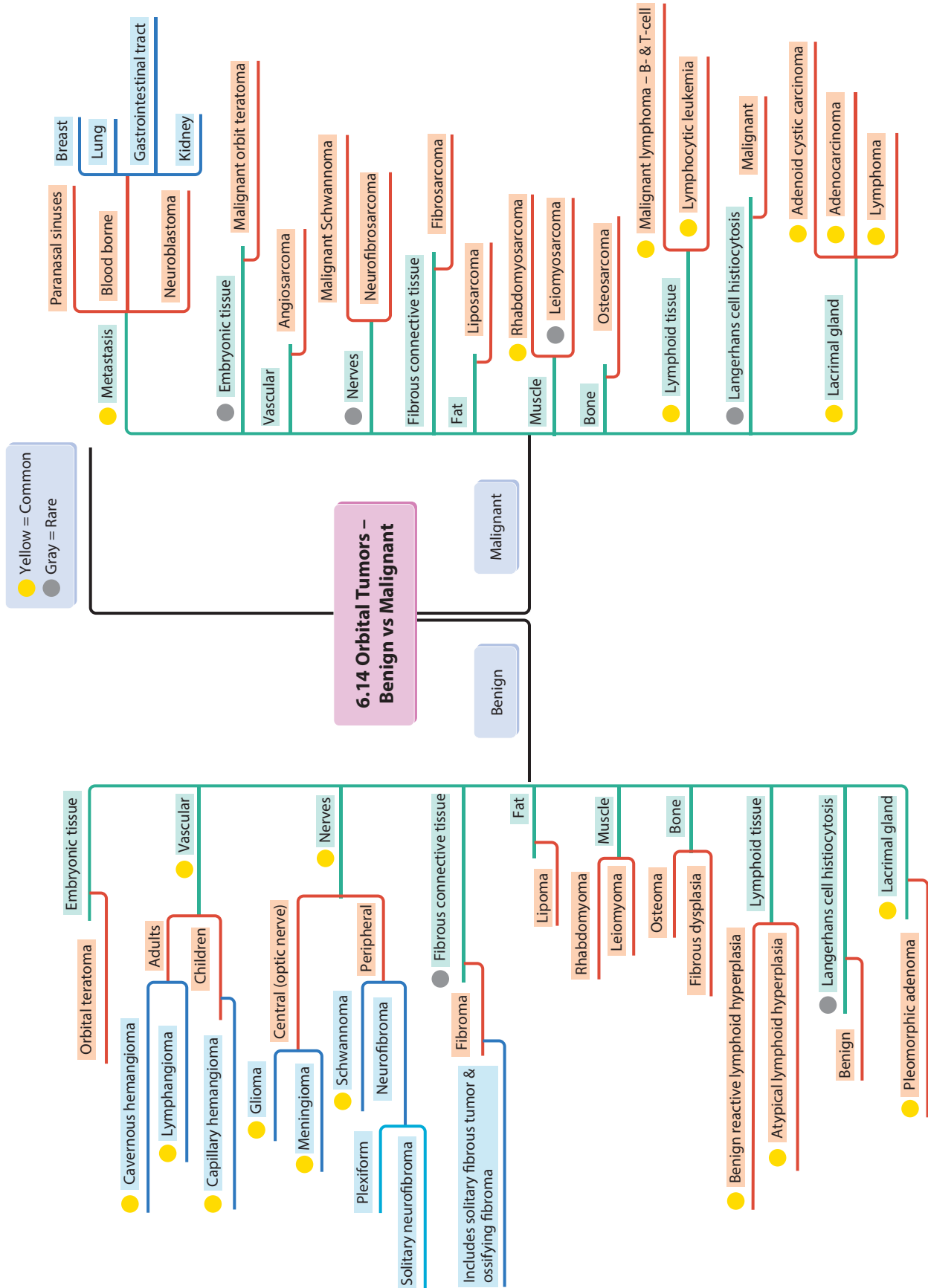
Turcot syndrome

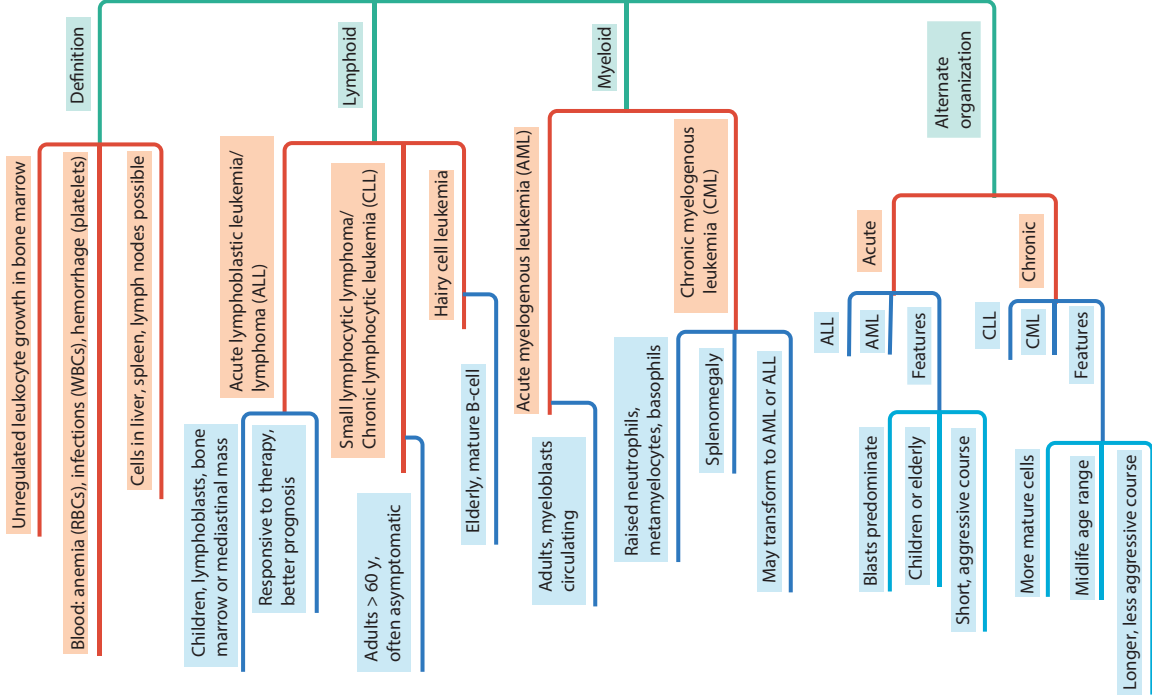
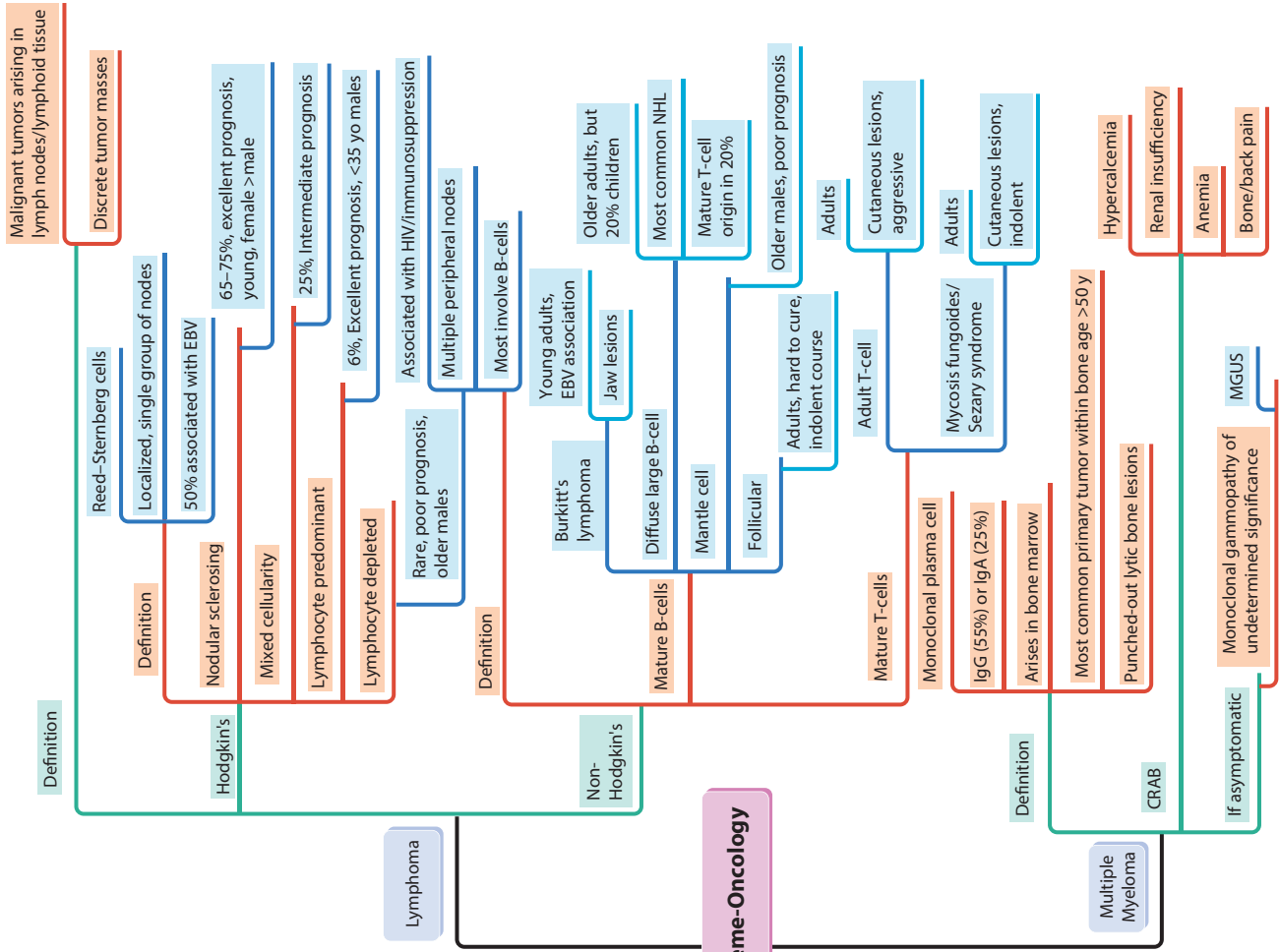
FAP + tumors of CNS (glioma)



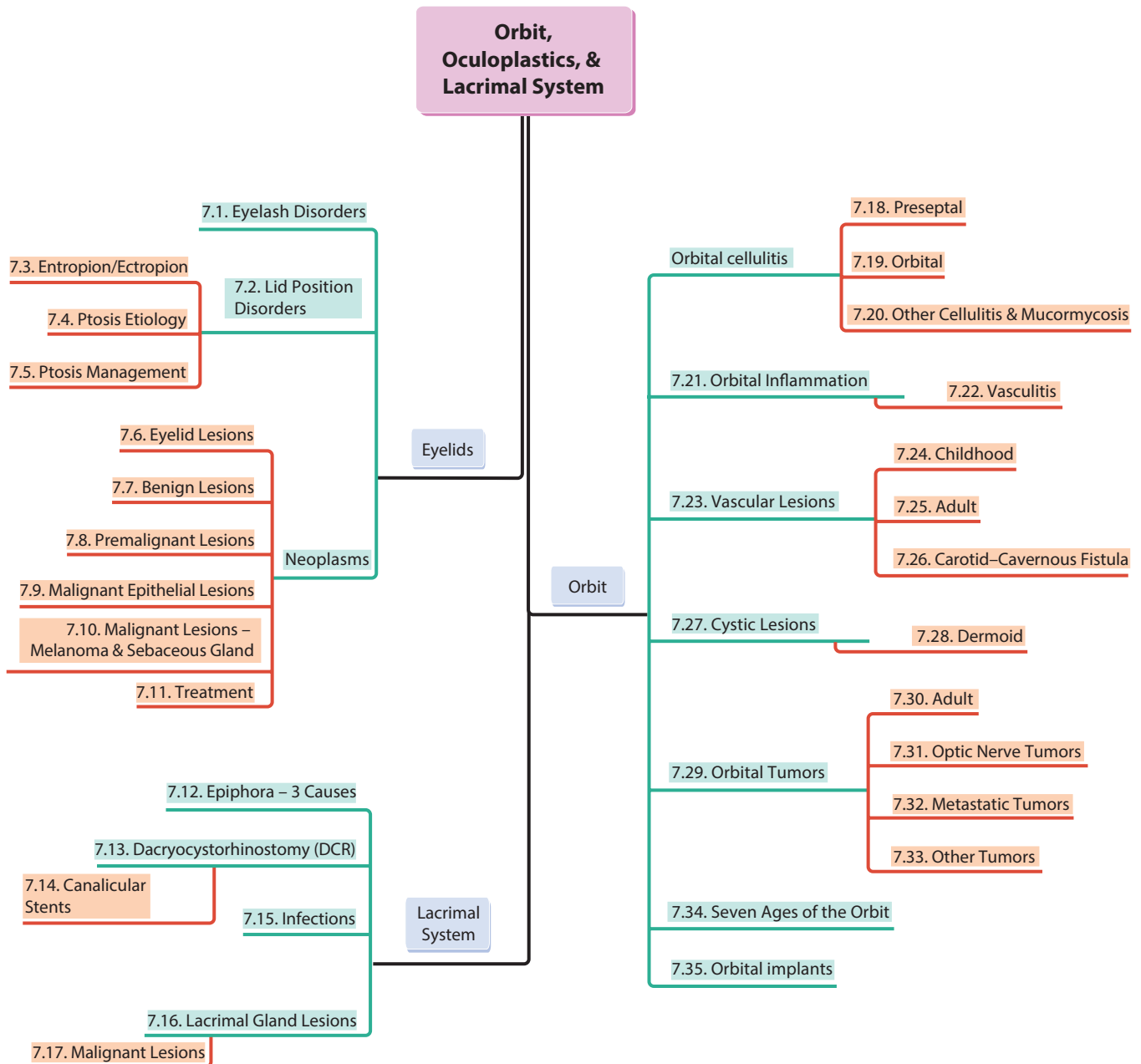


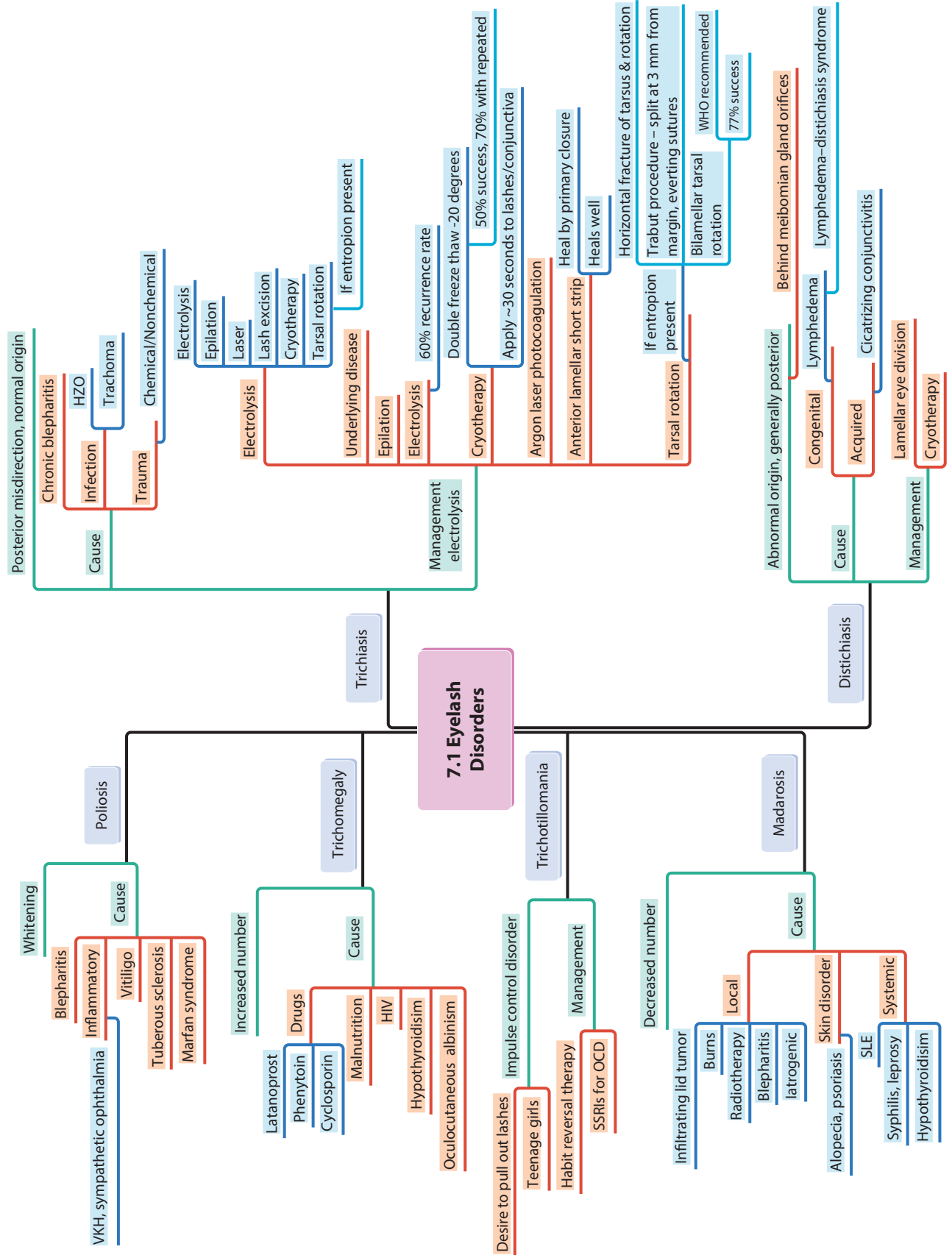


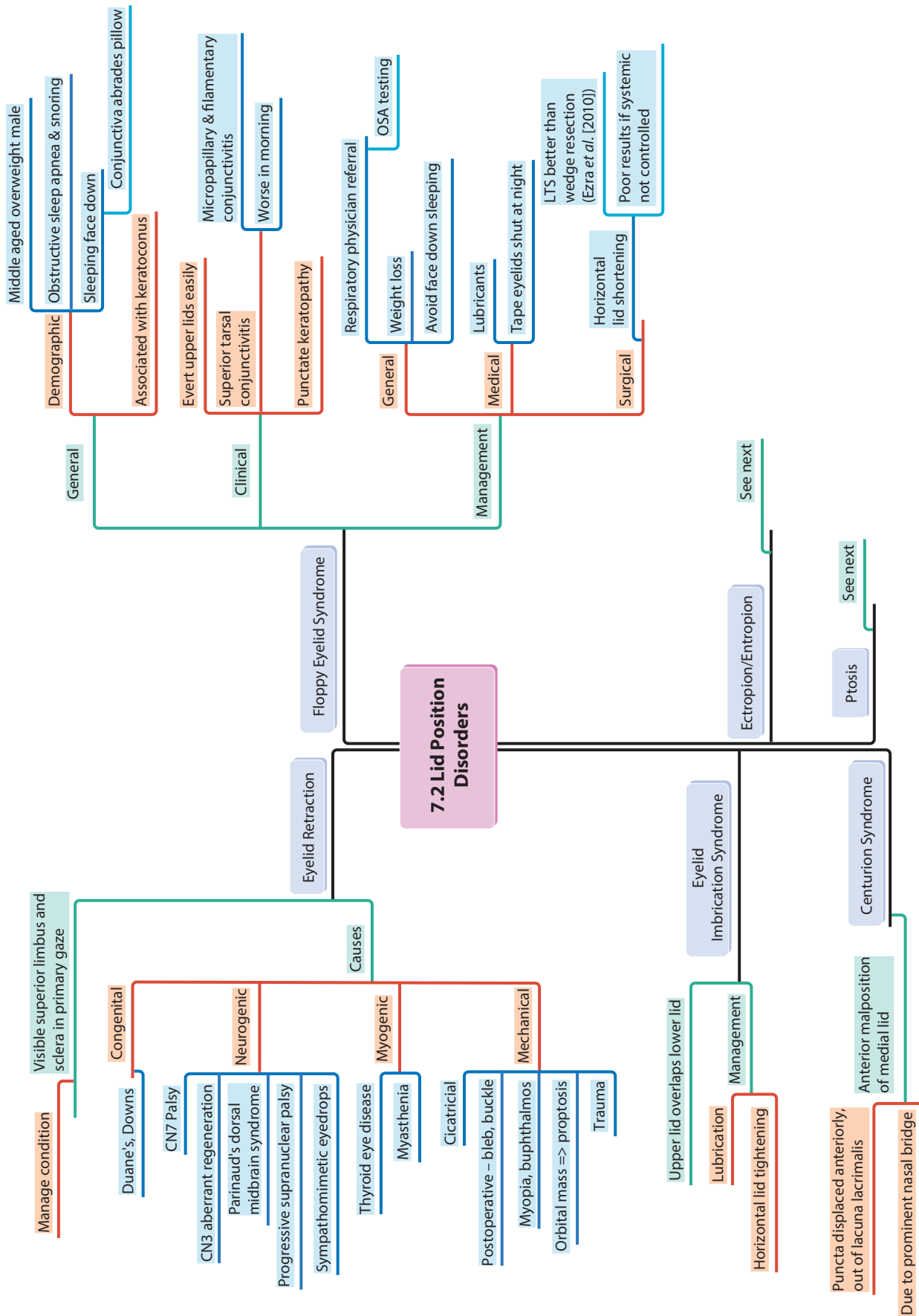




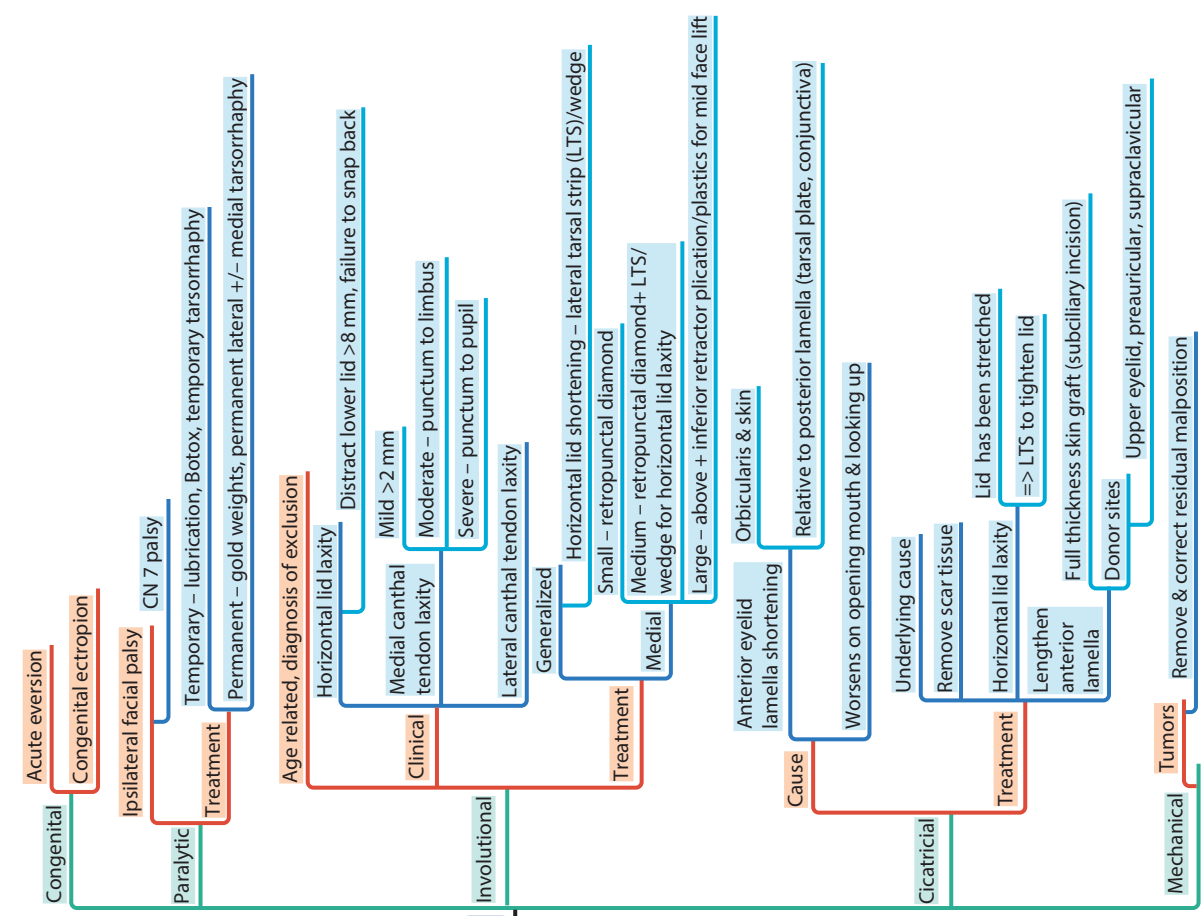
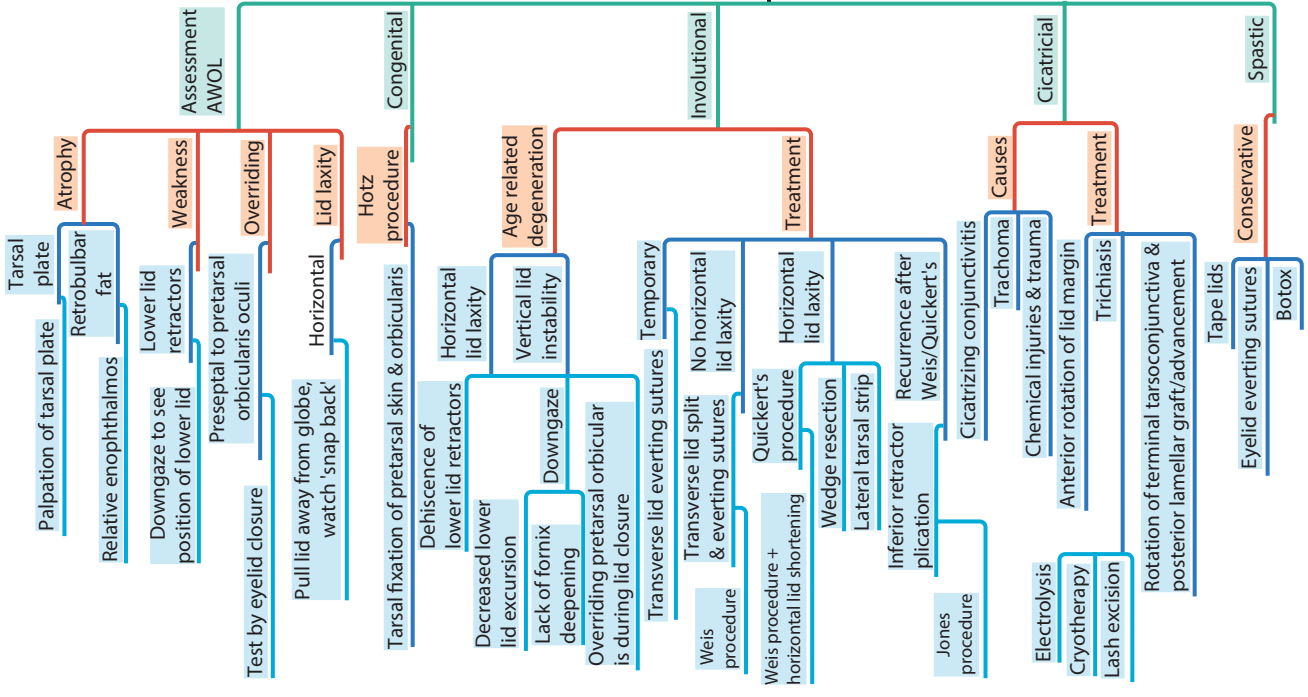
7 Orbit, Oculoplastics, and Lacrimal System

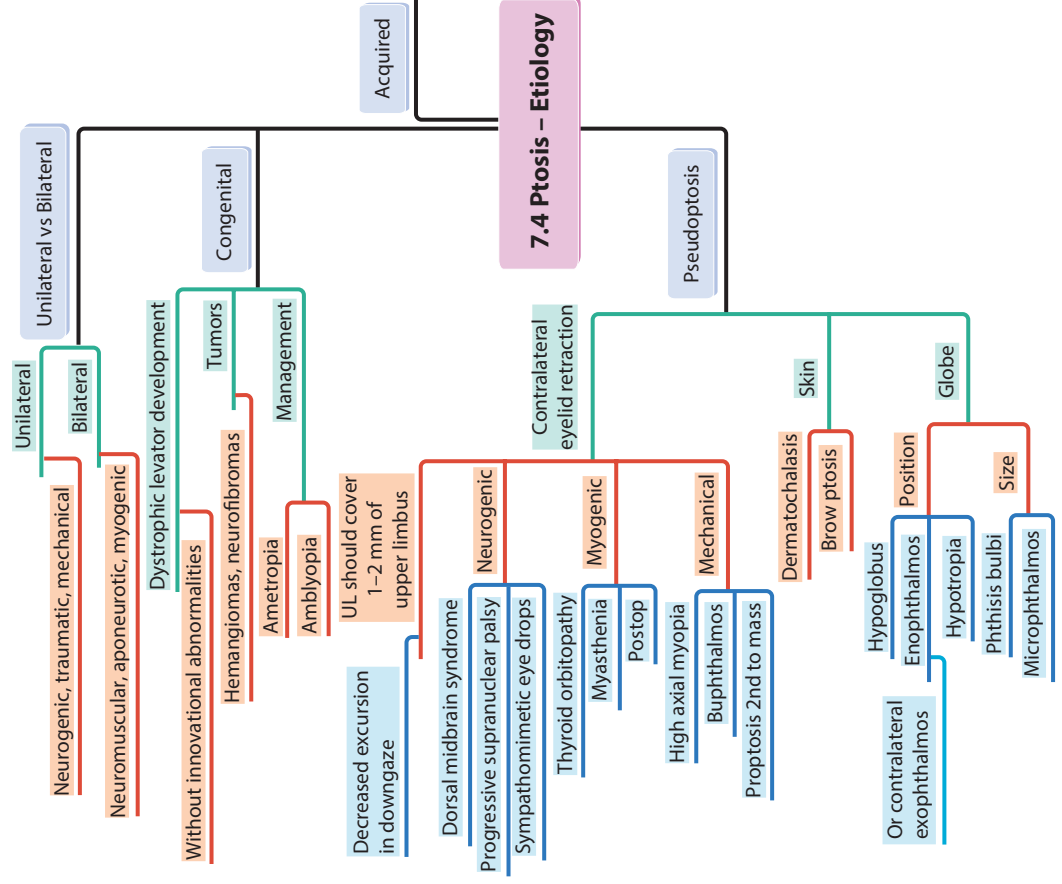
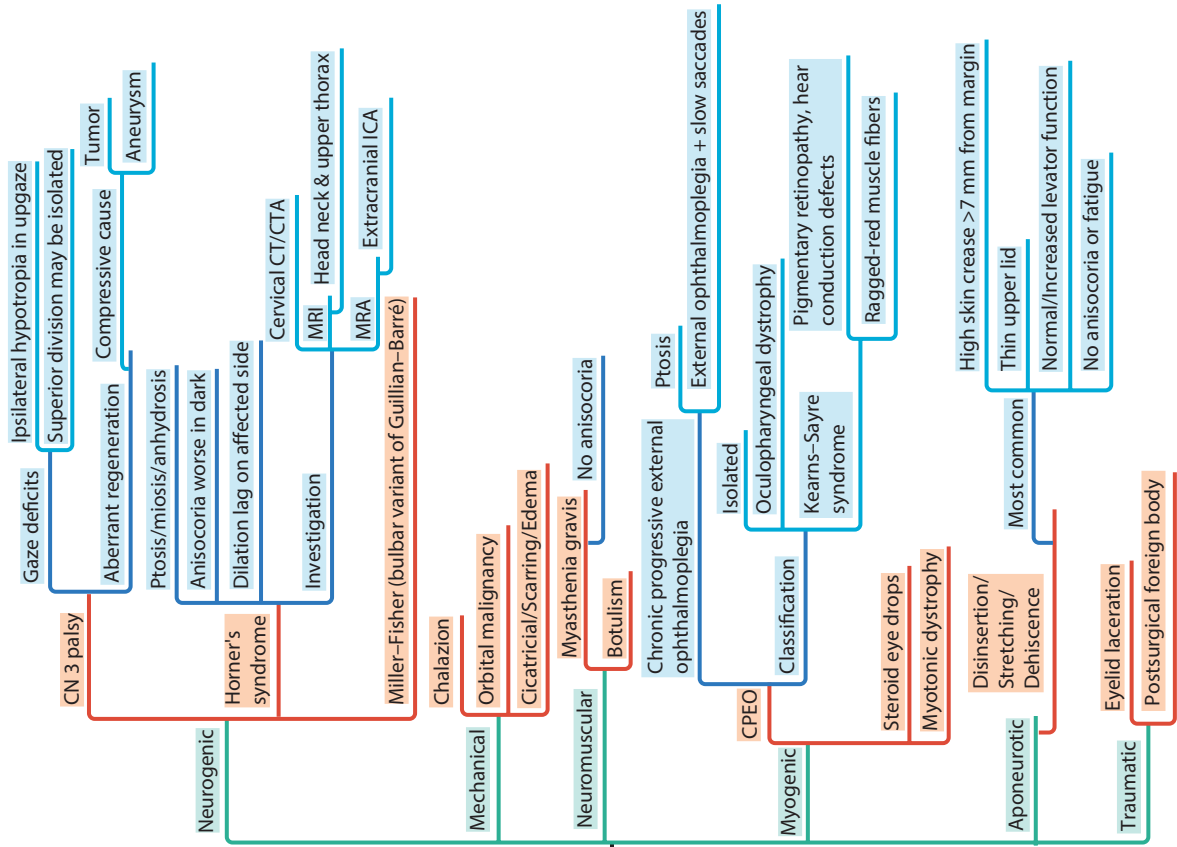


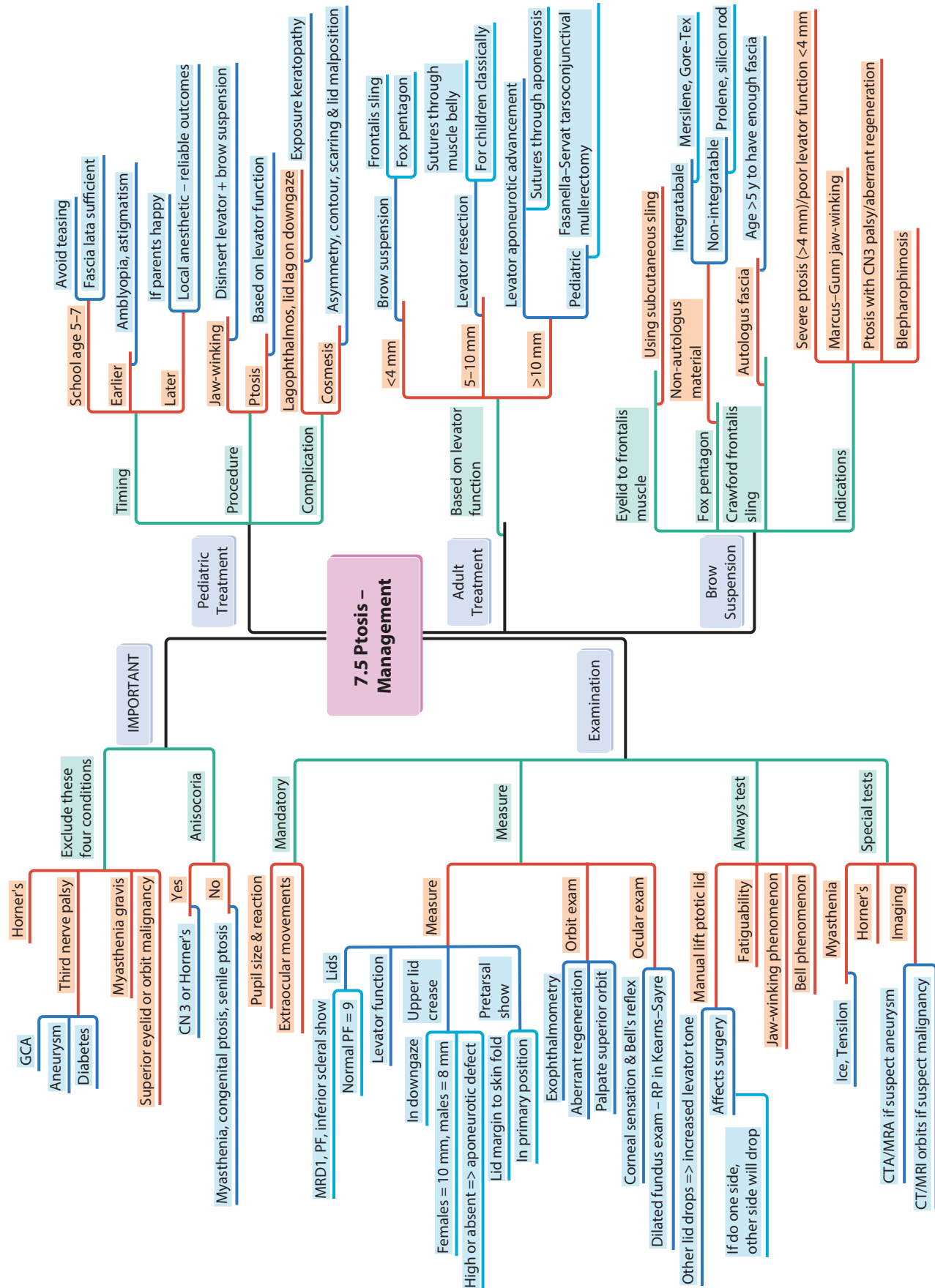


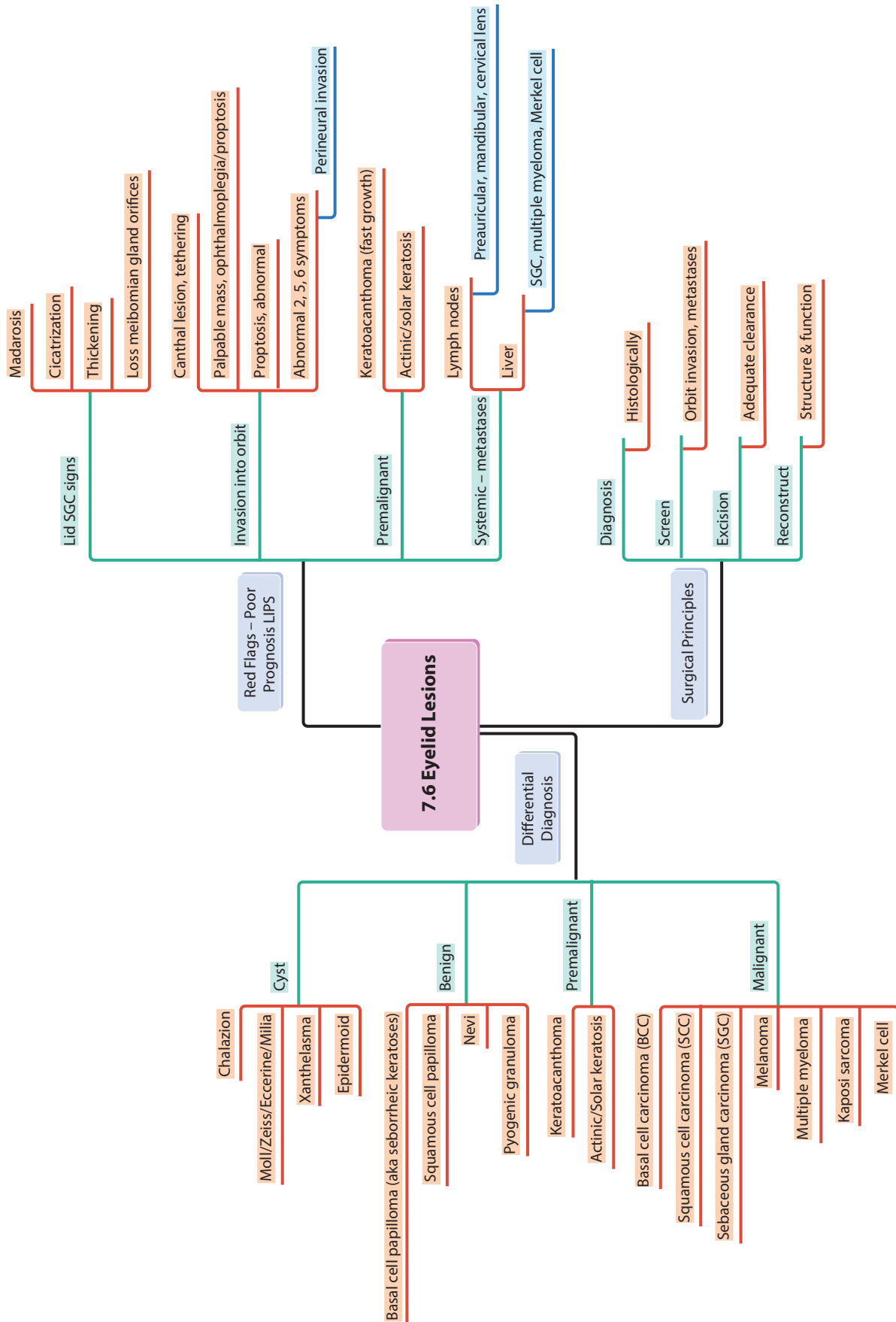


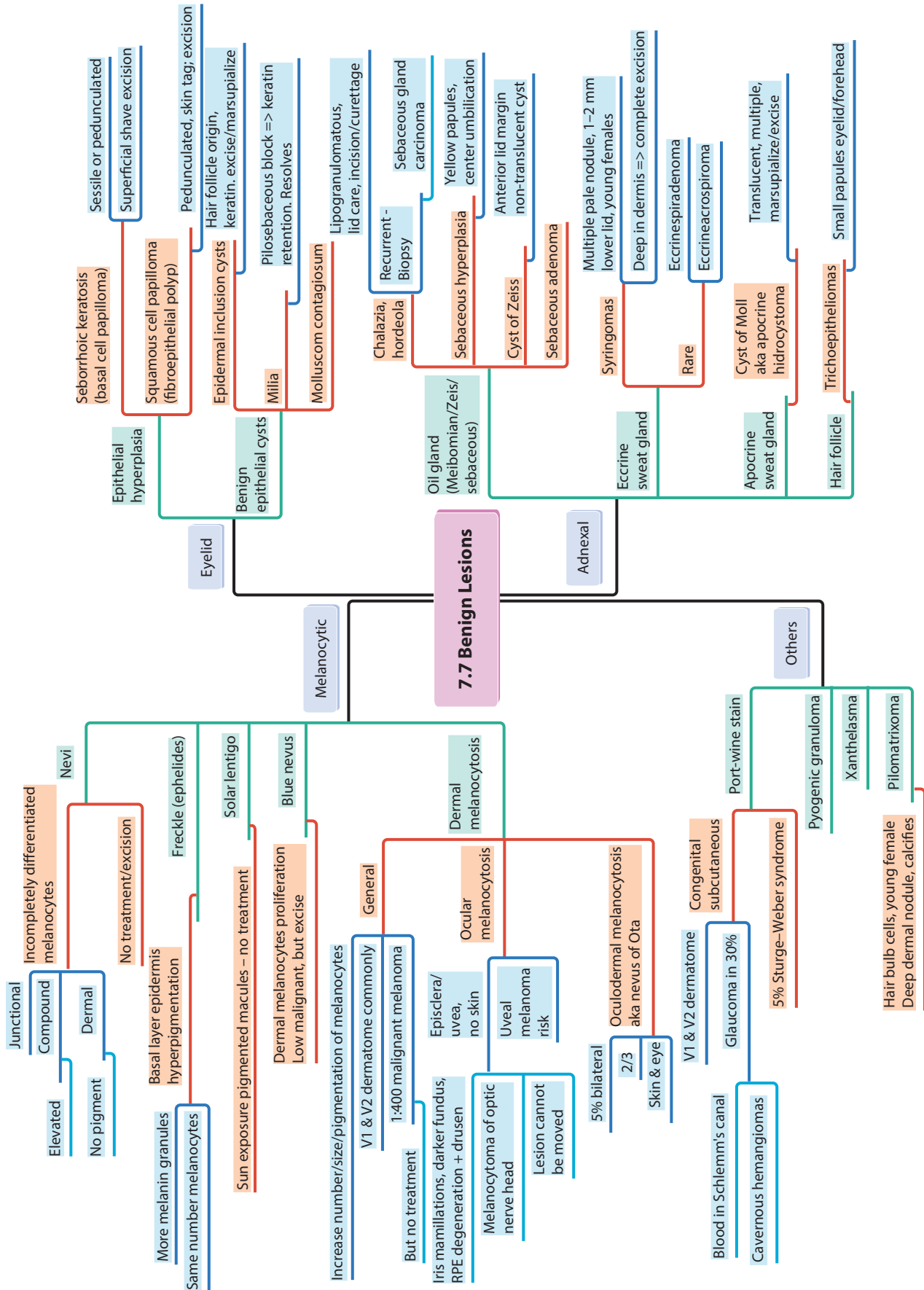
7.3 Lid Position Disorders – Entropion/ Ectropion

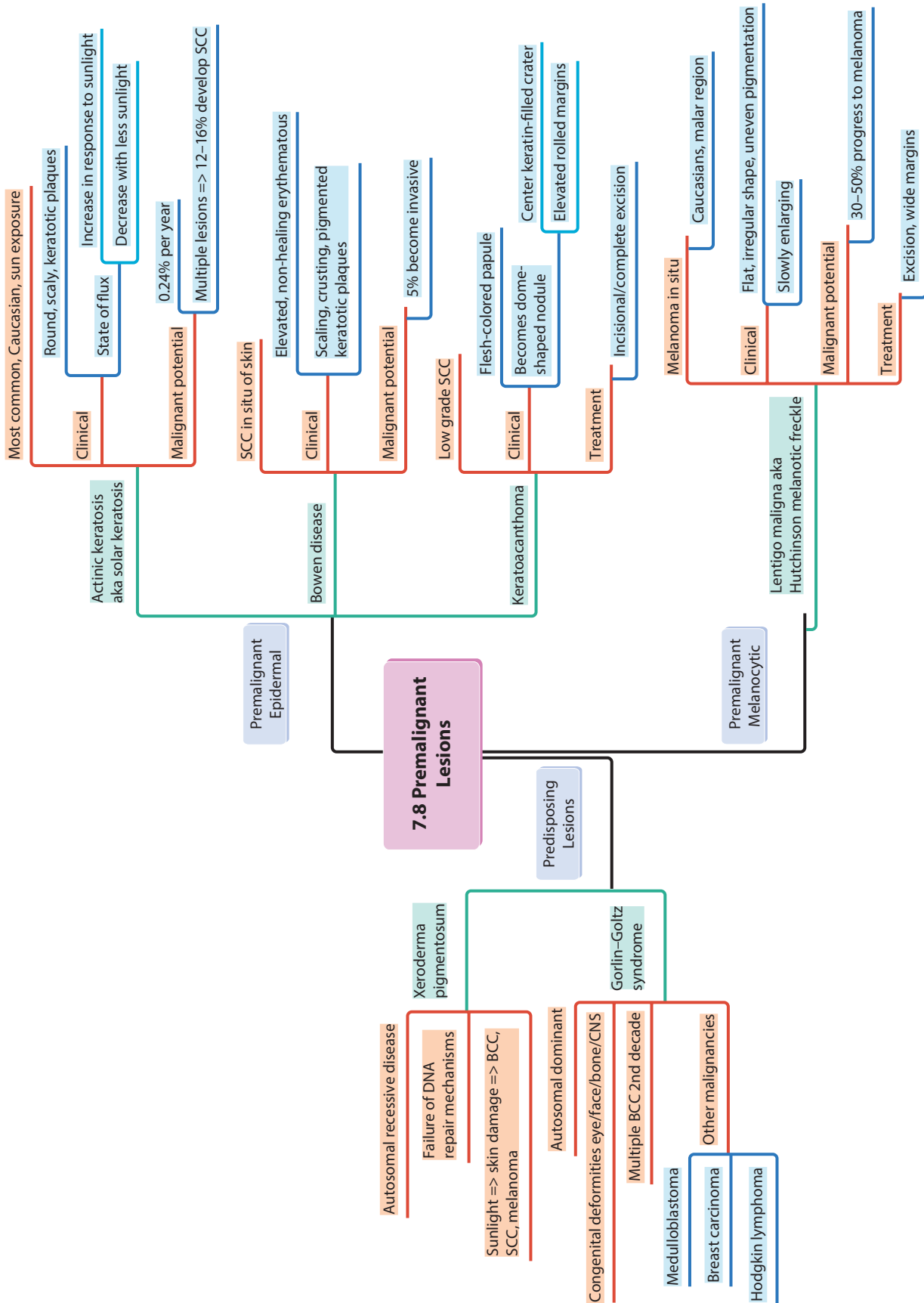


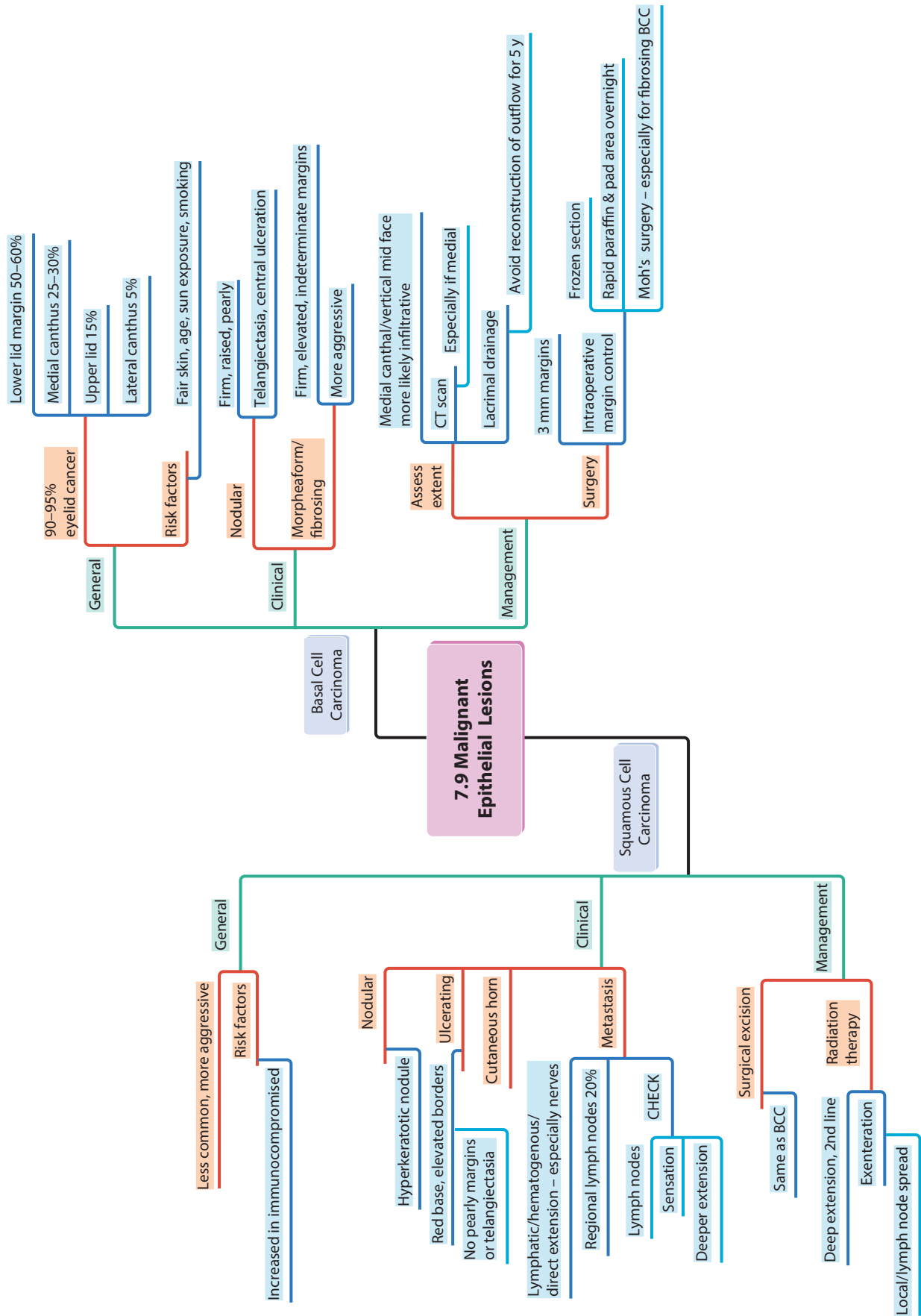


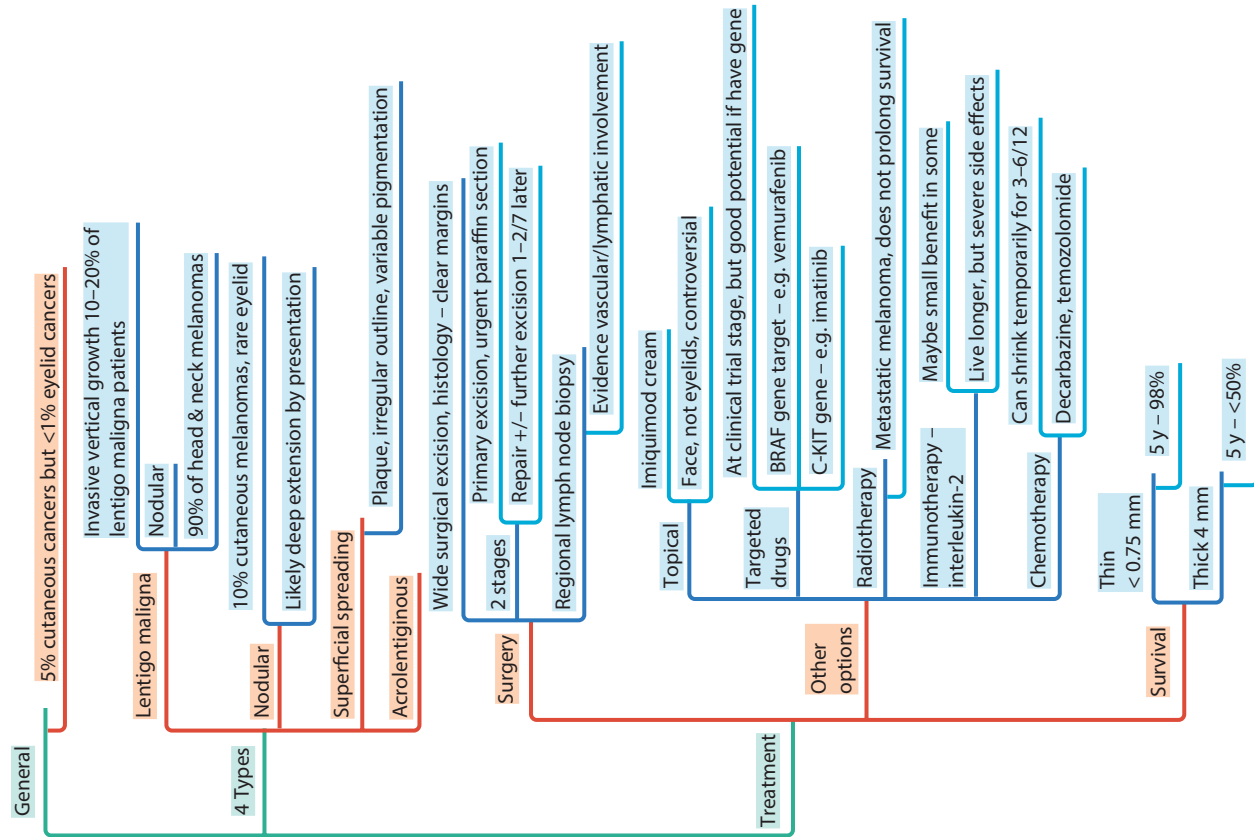




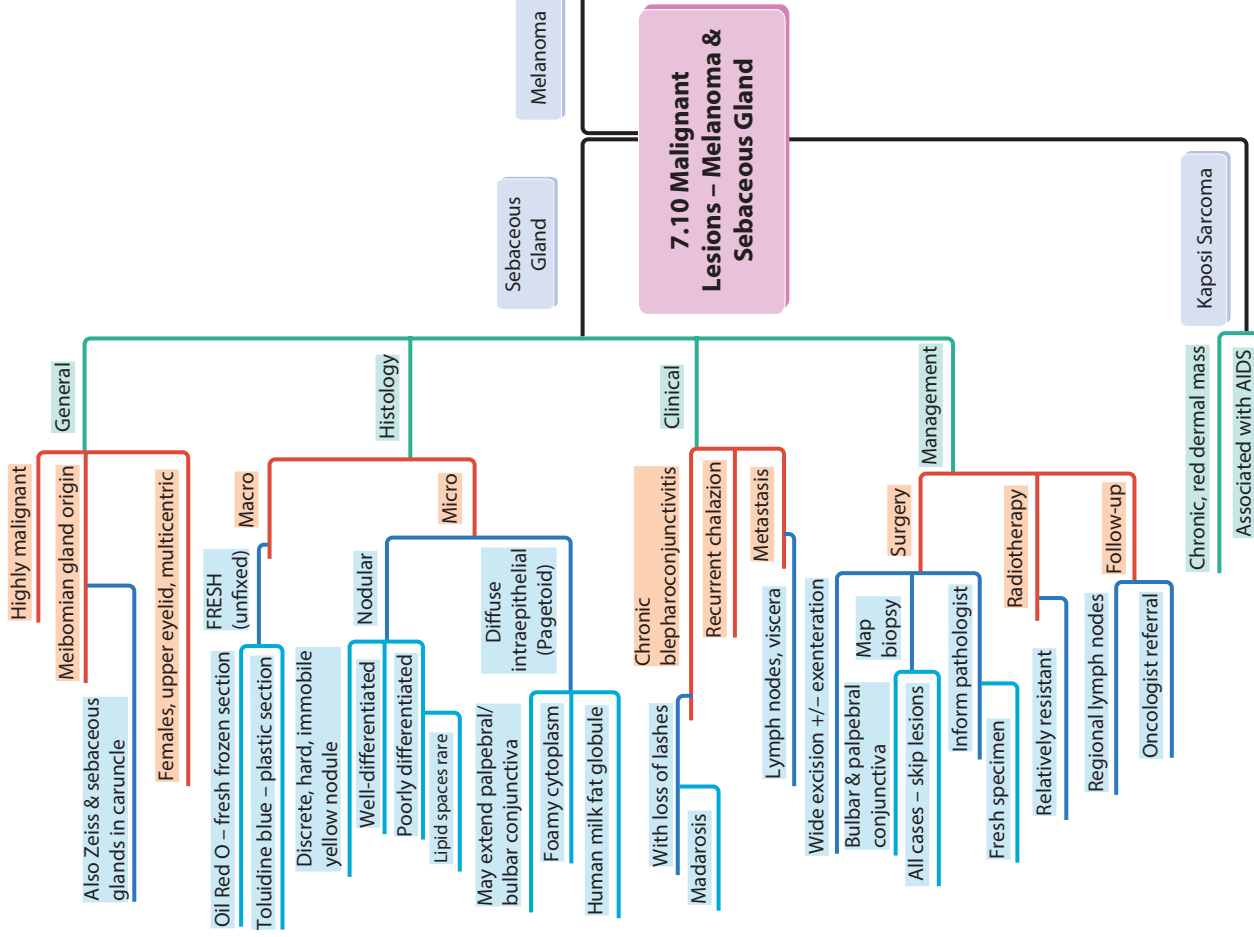


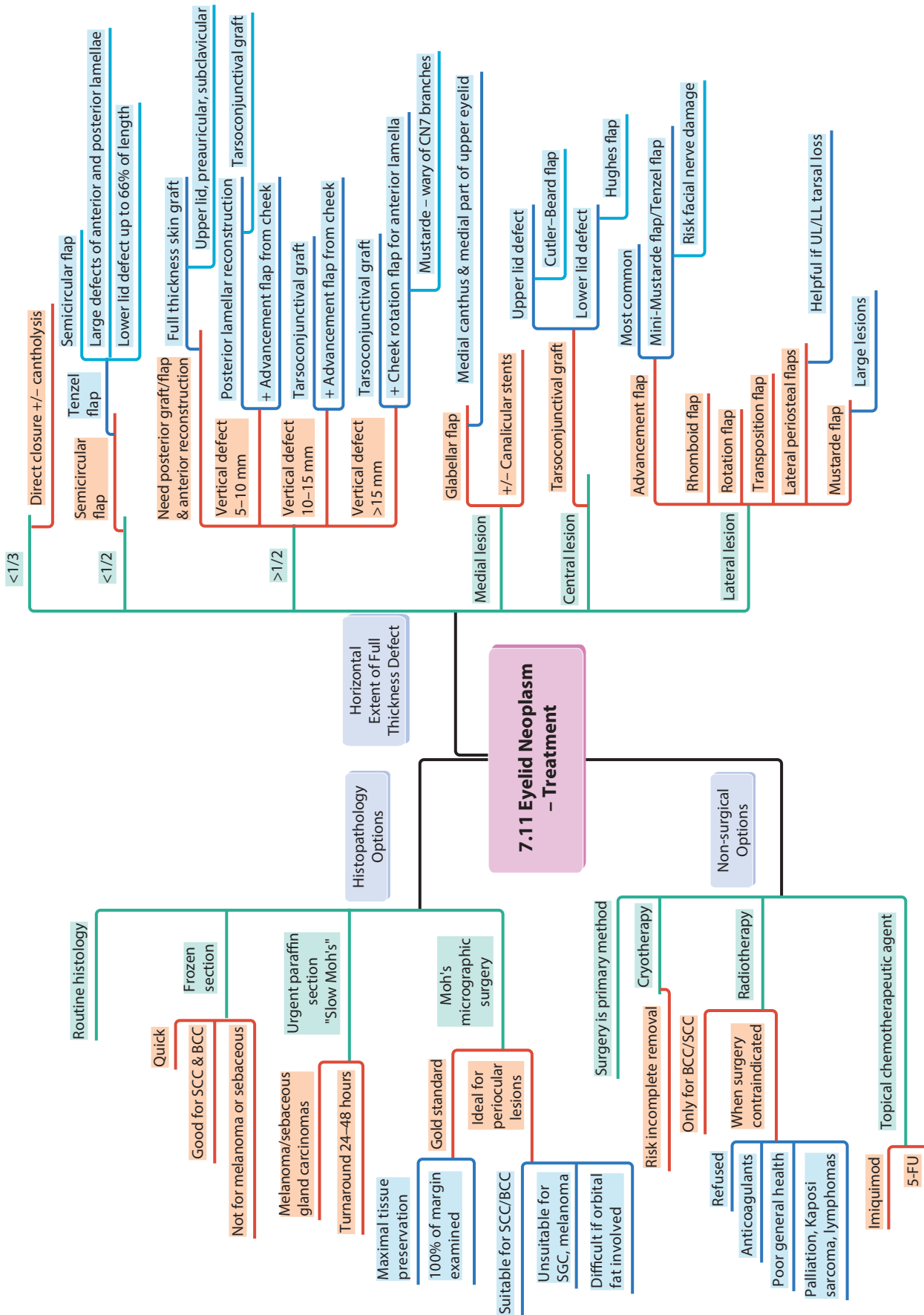


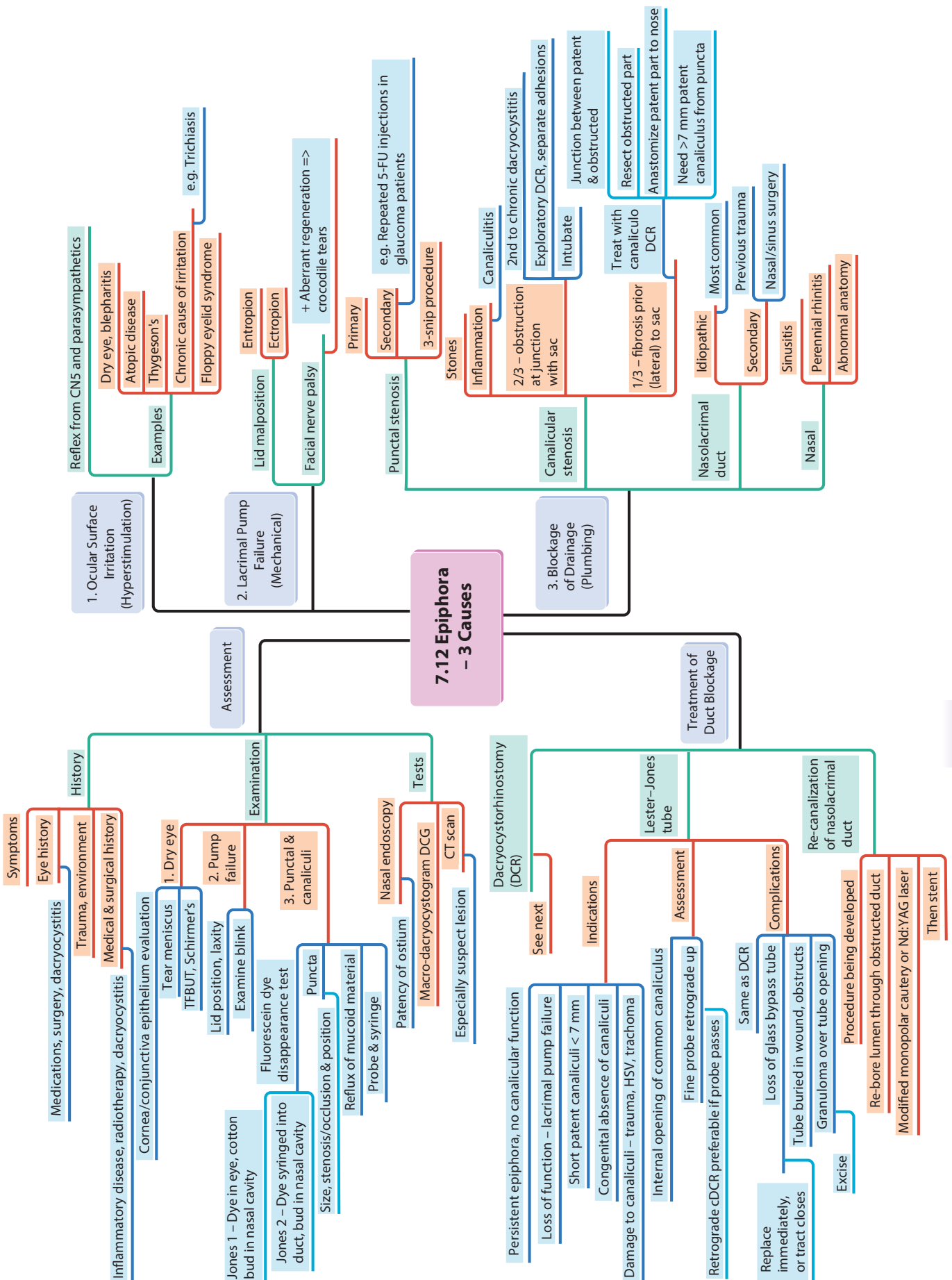


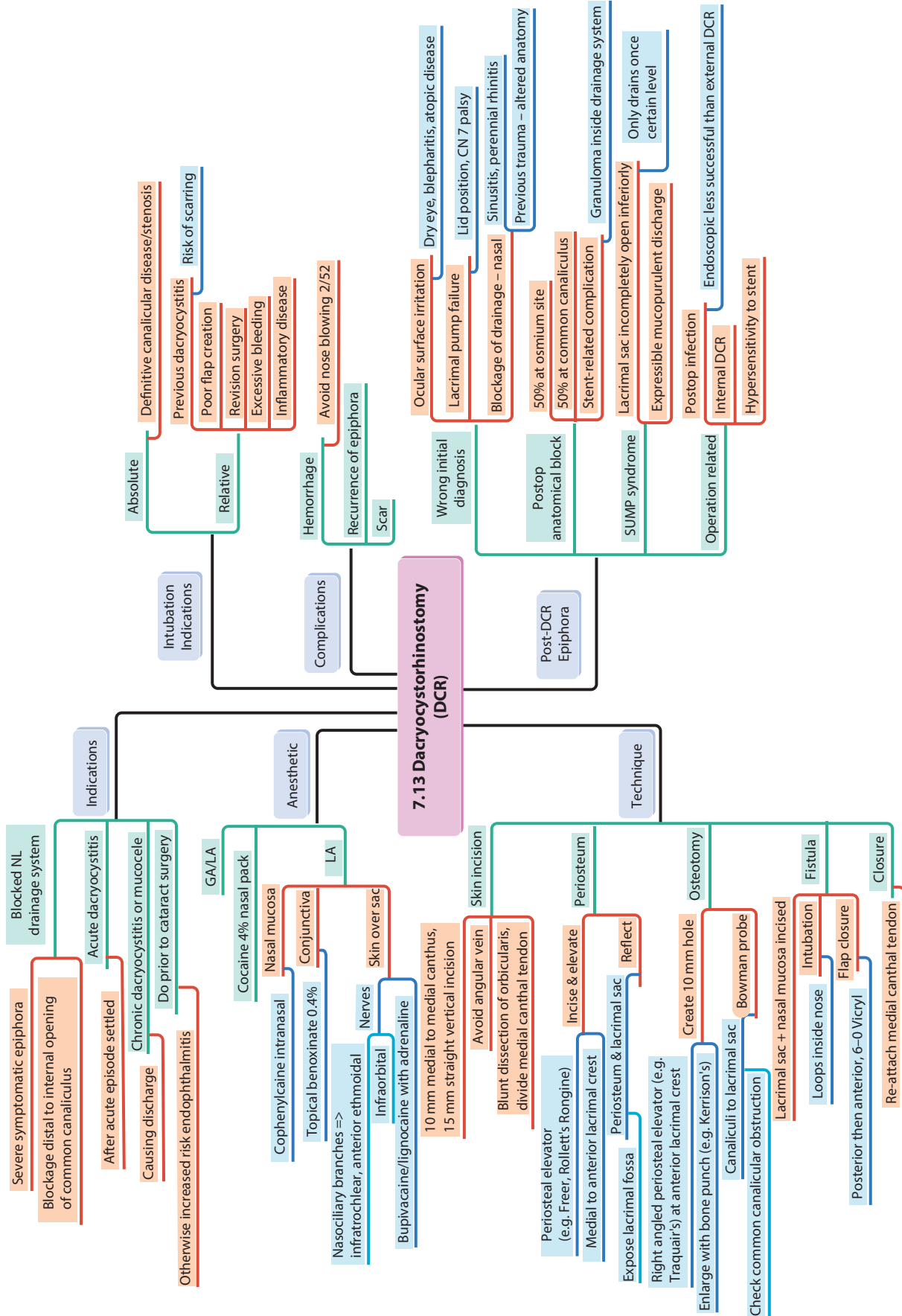


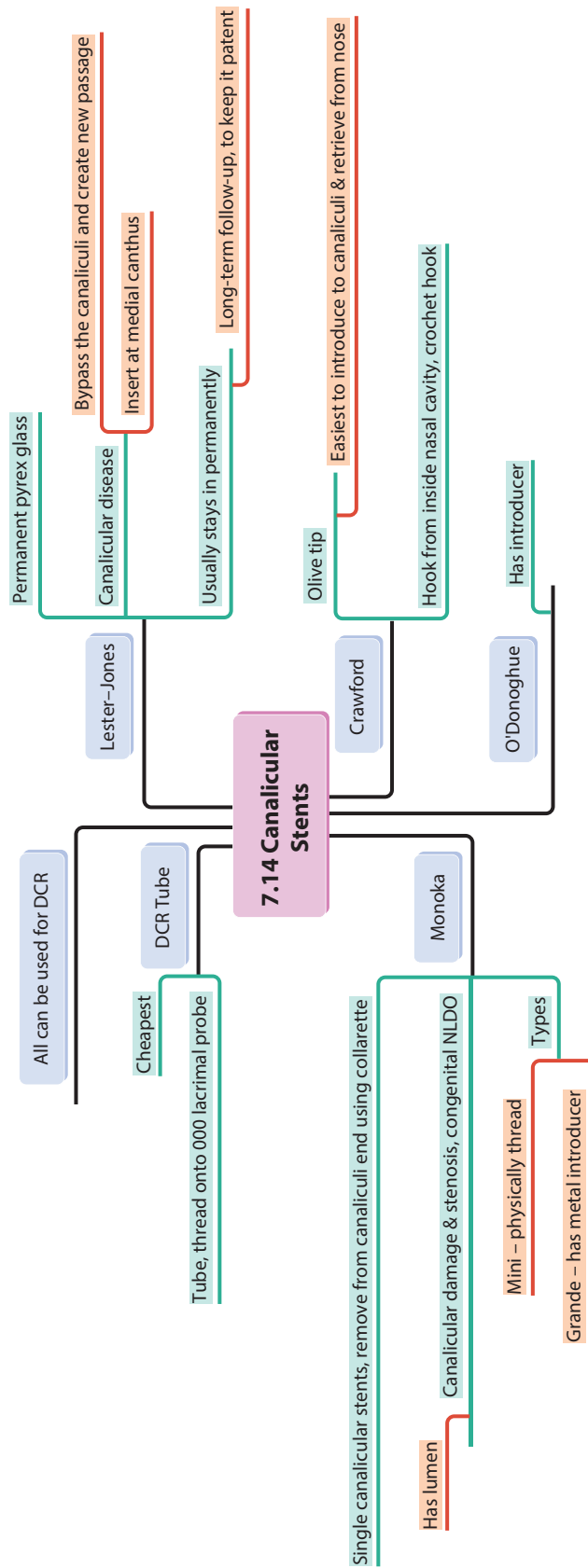
7.10 Malignant Lesions – Melanoma & Sebaceous Gland

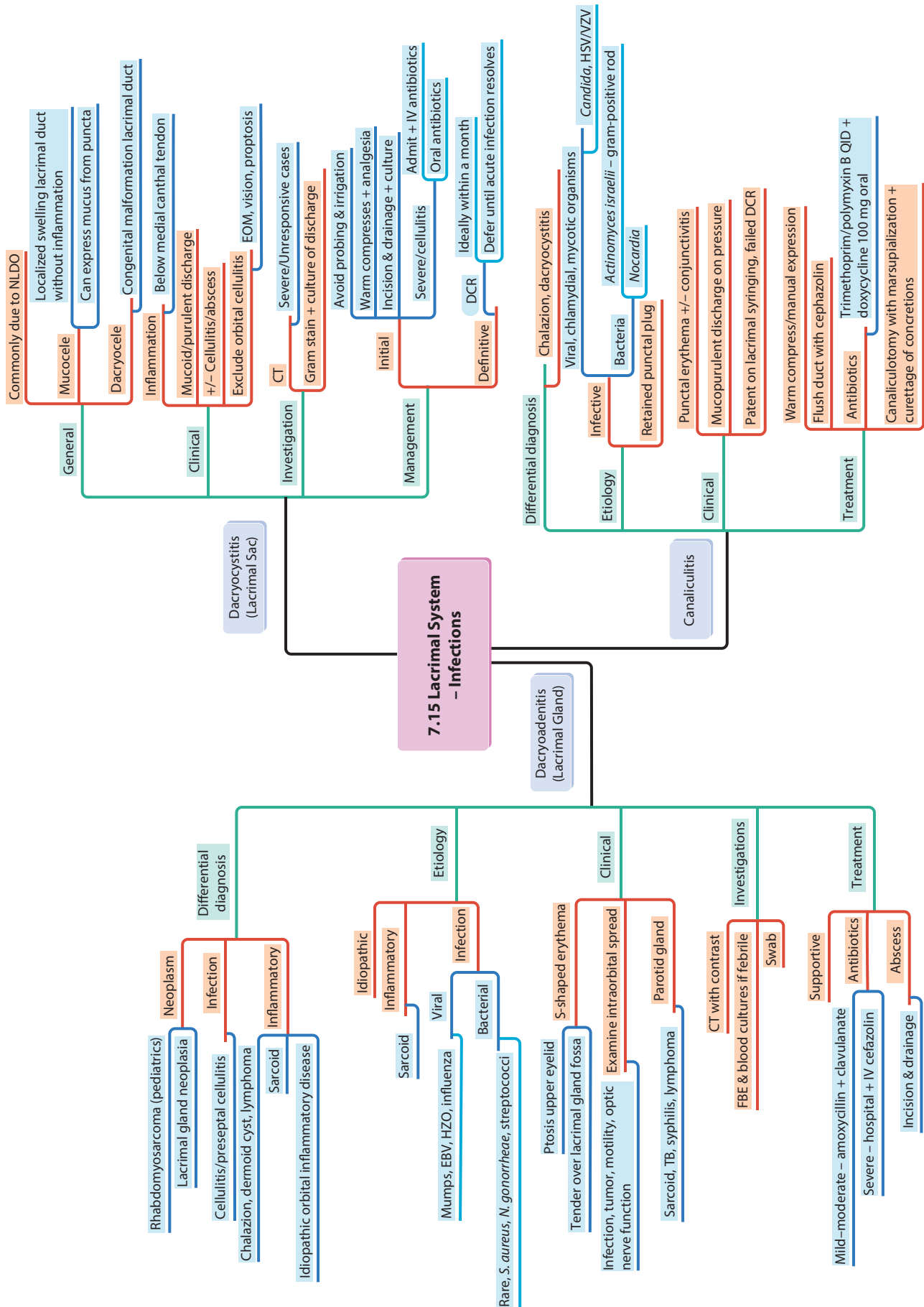


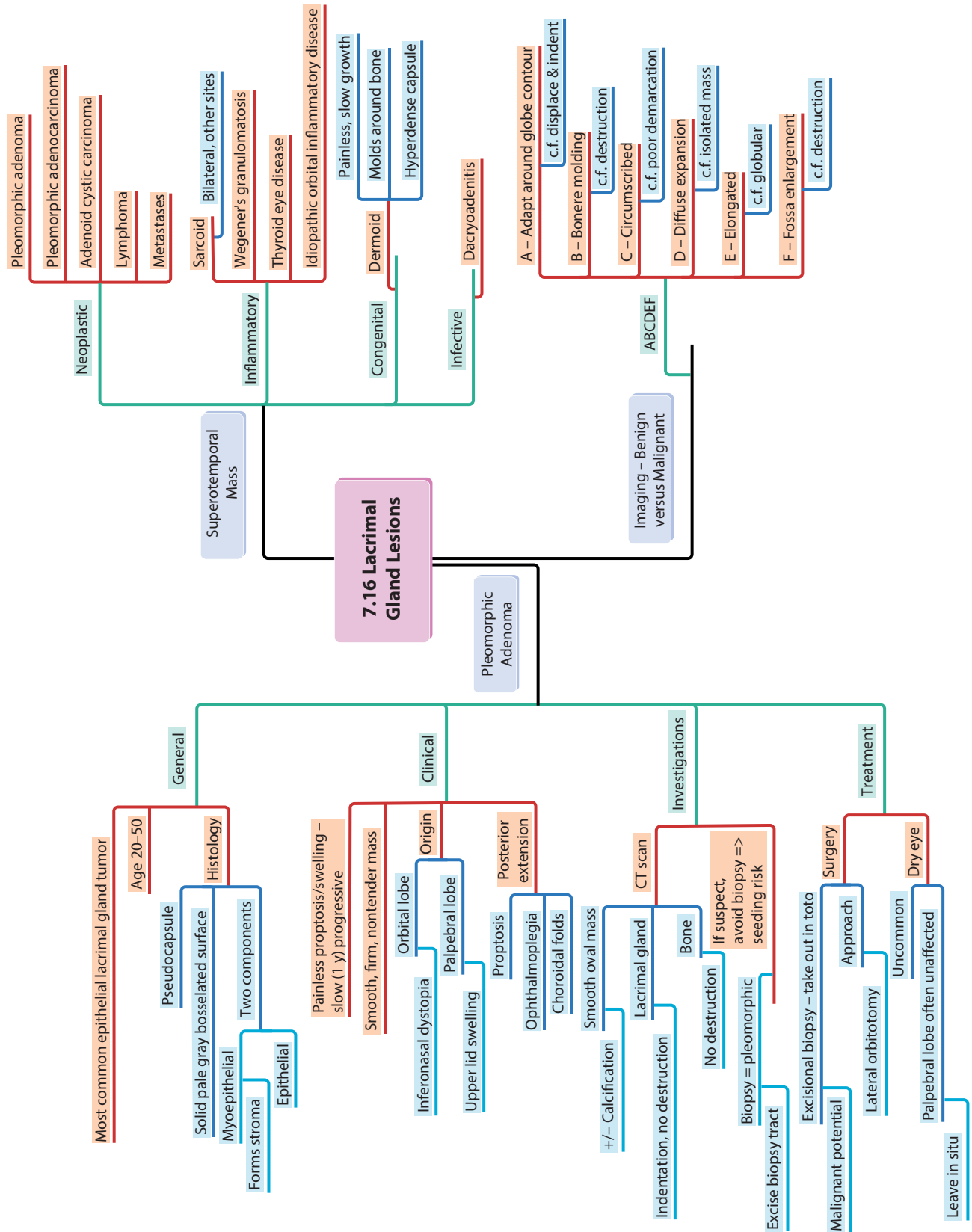


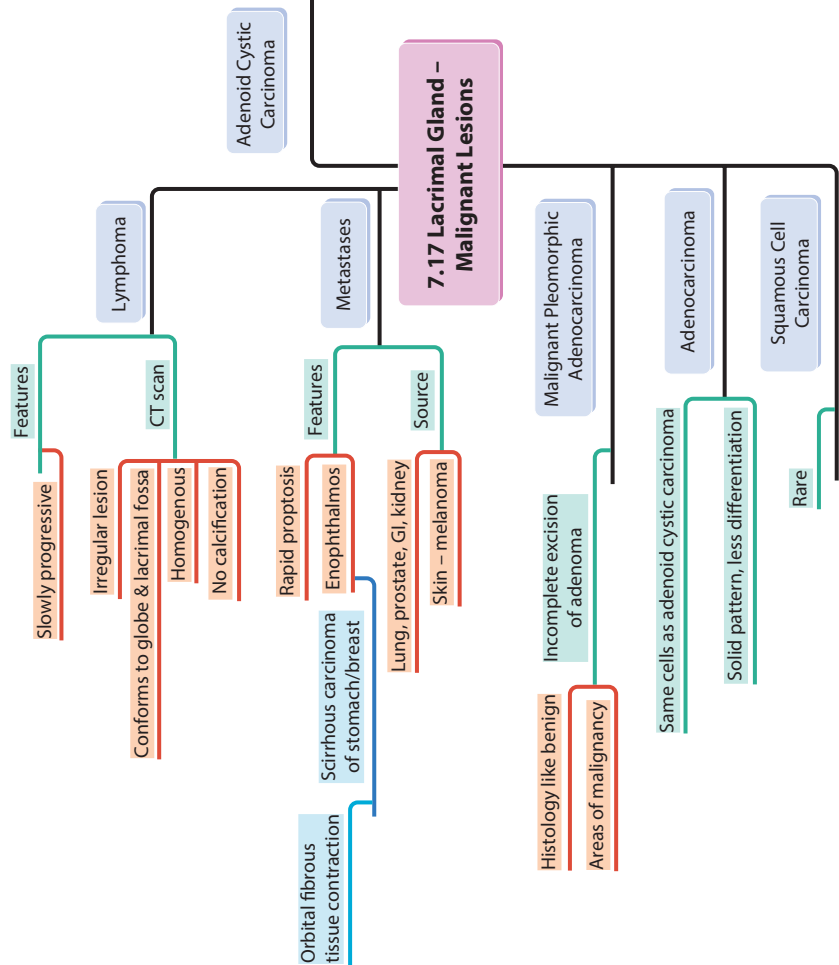
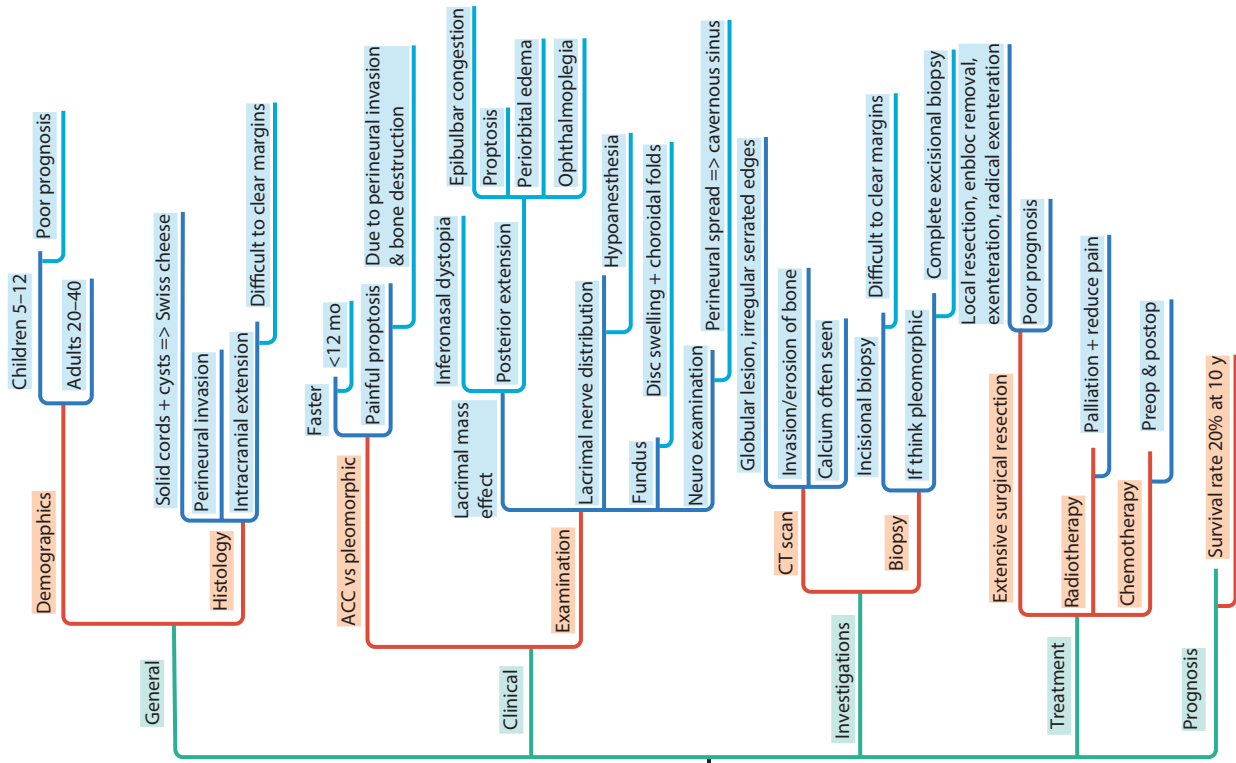


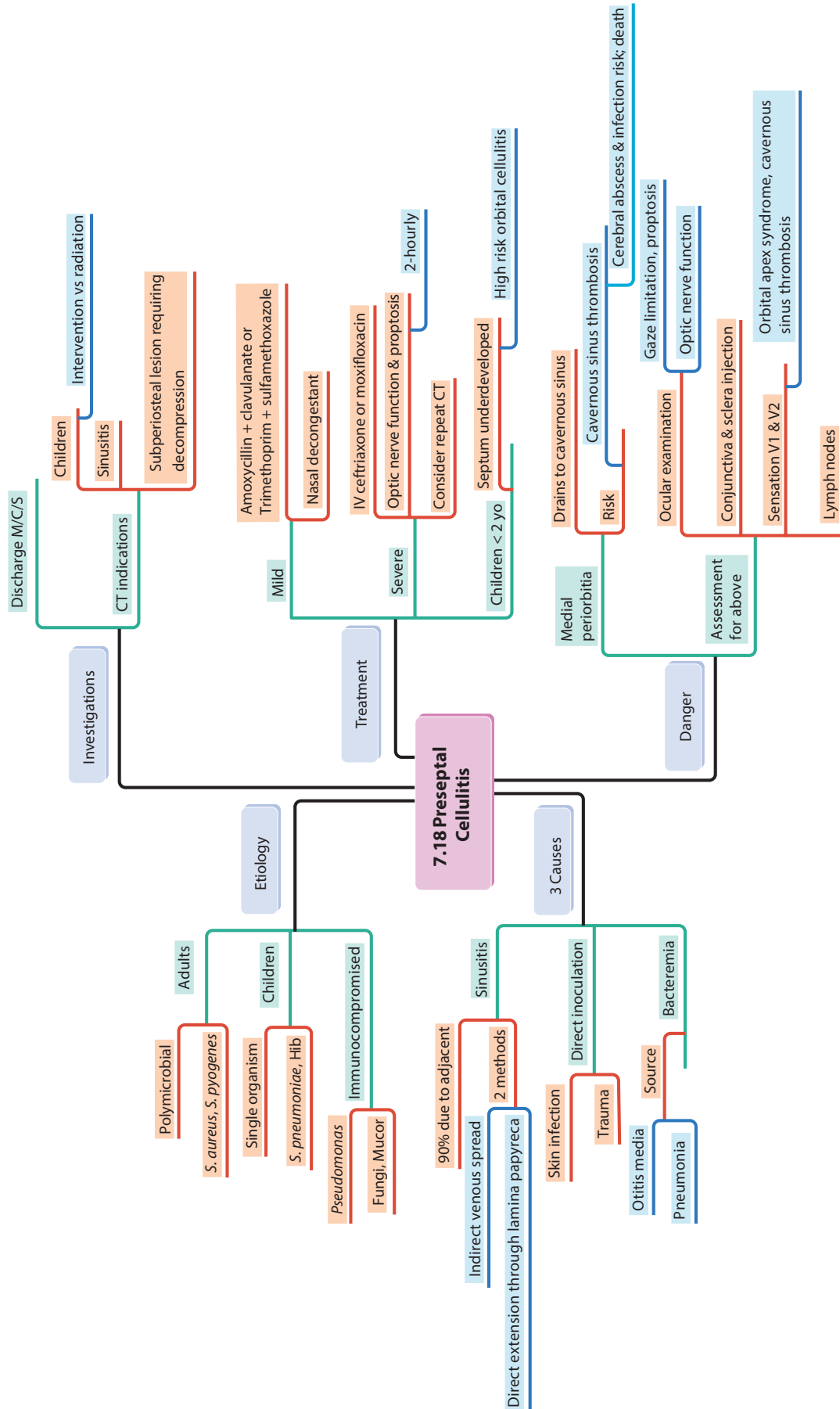


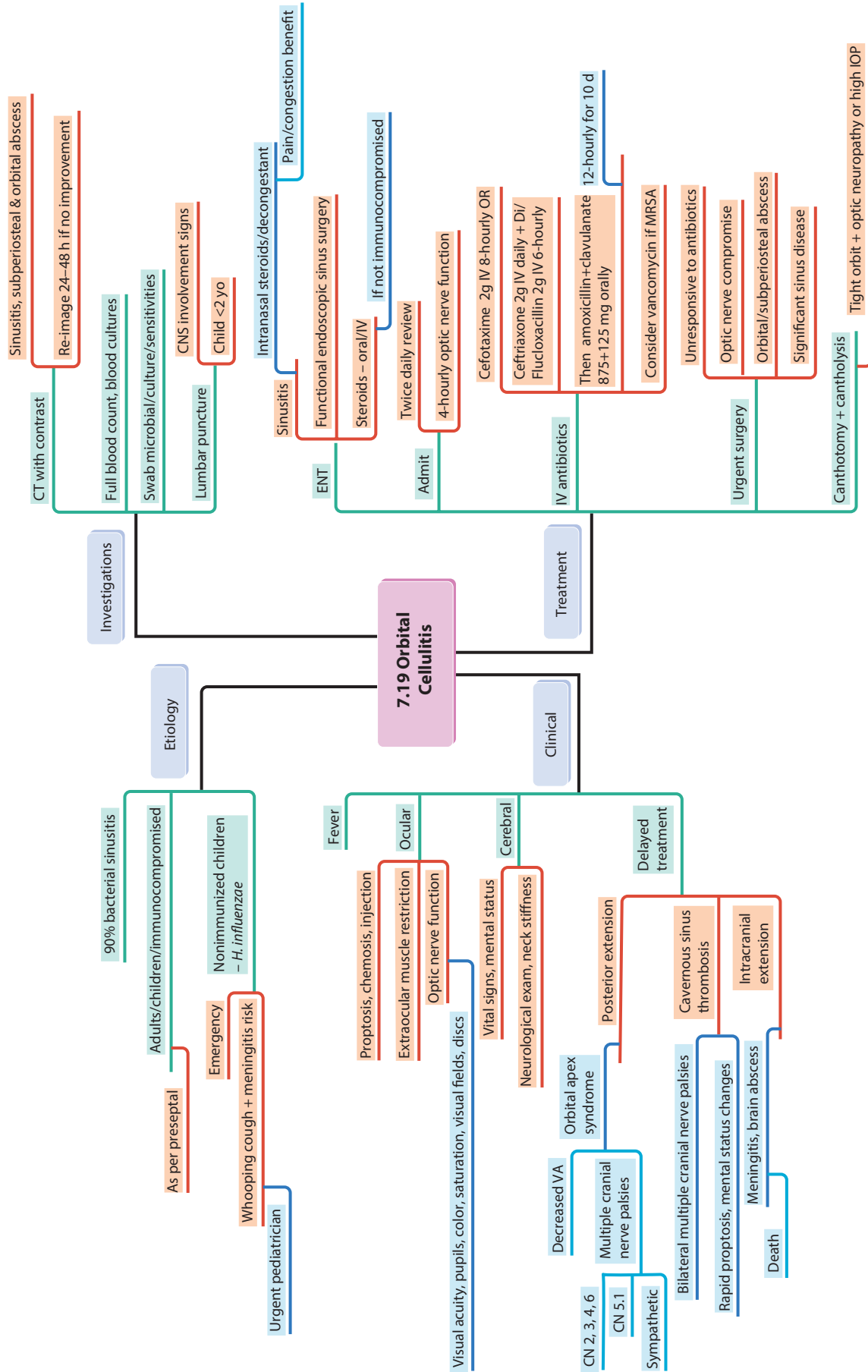


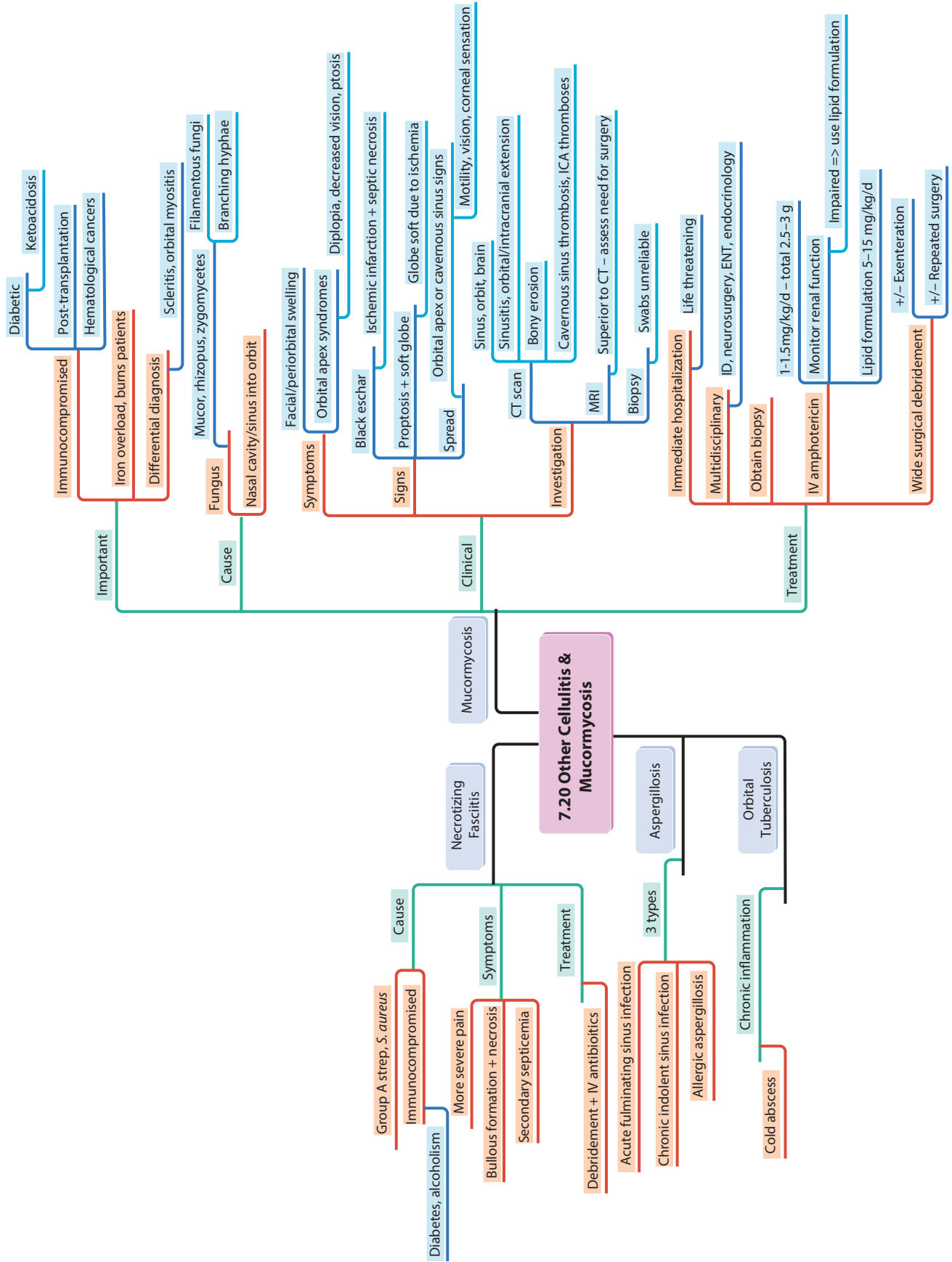


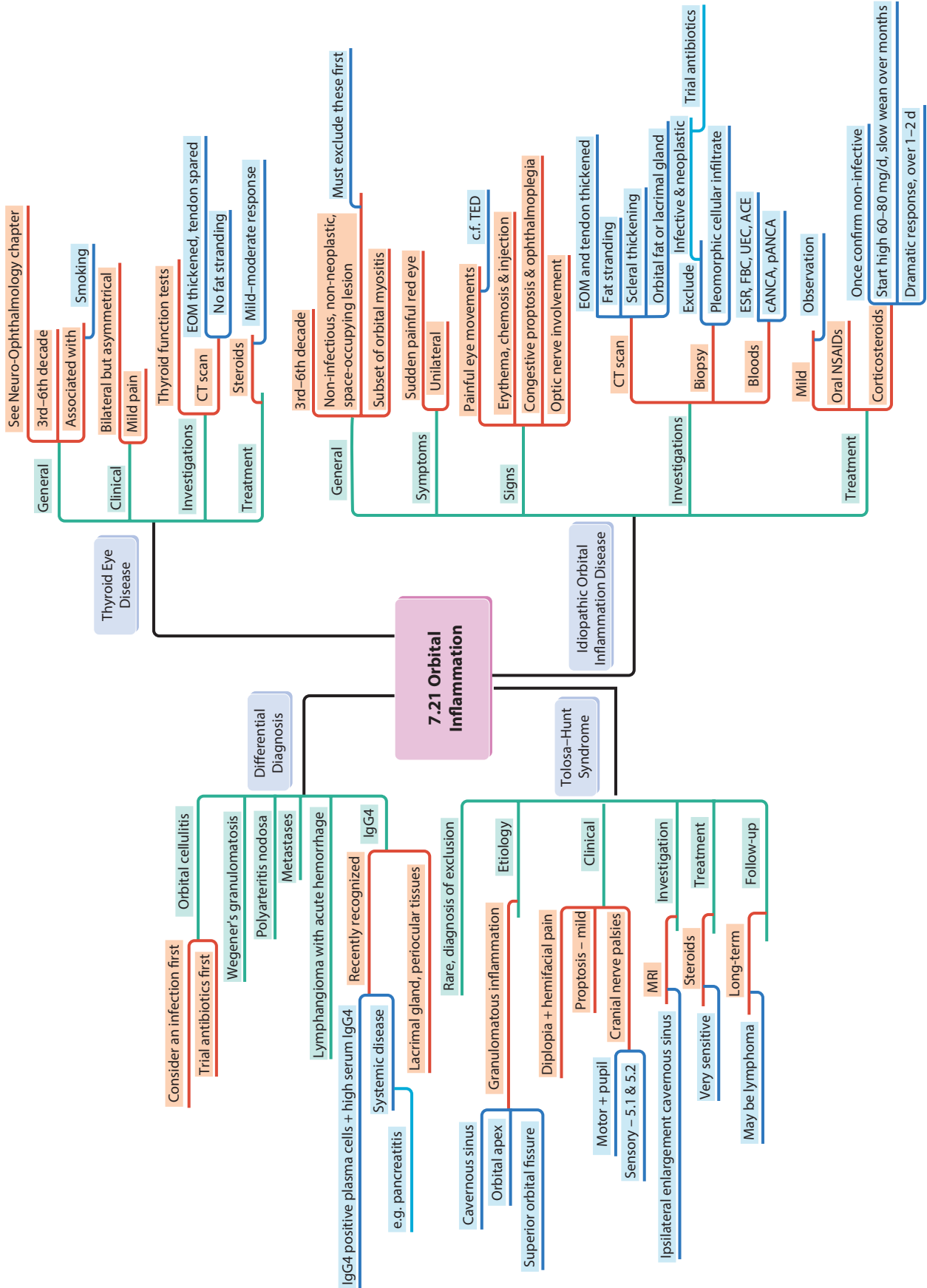


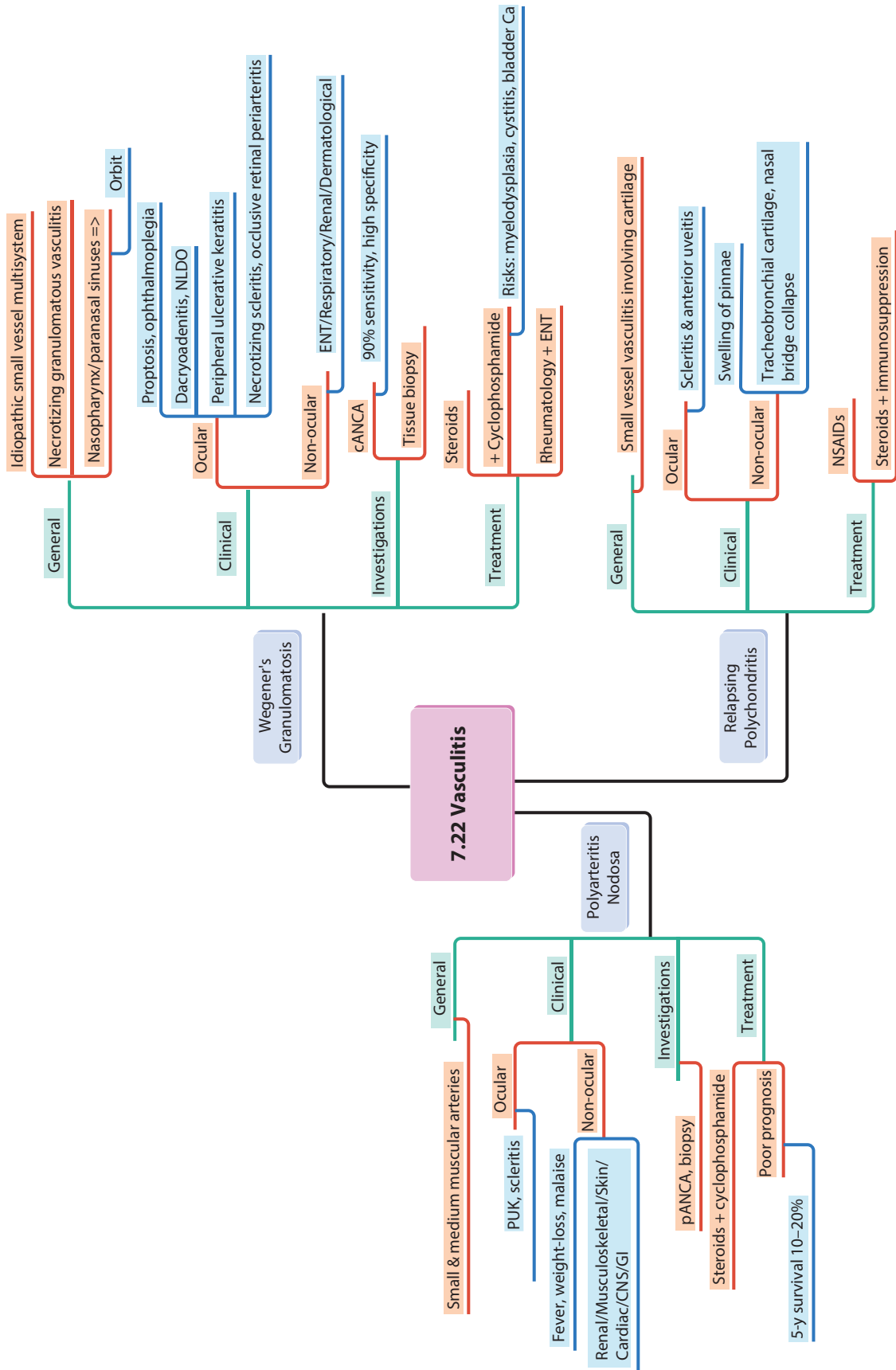


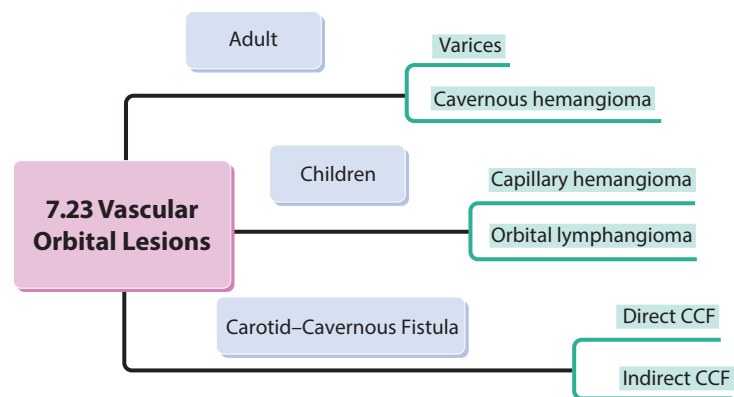


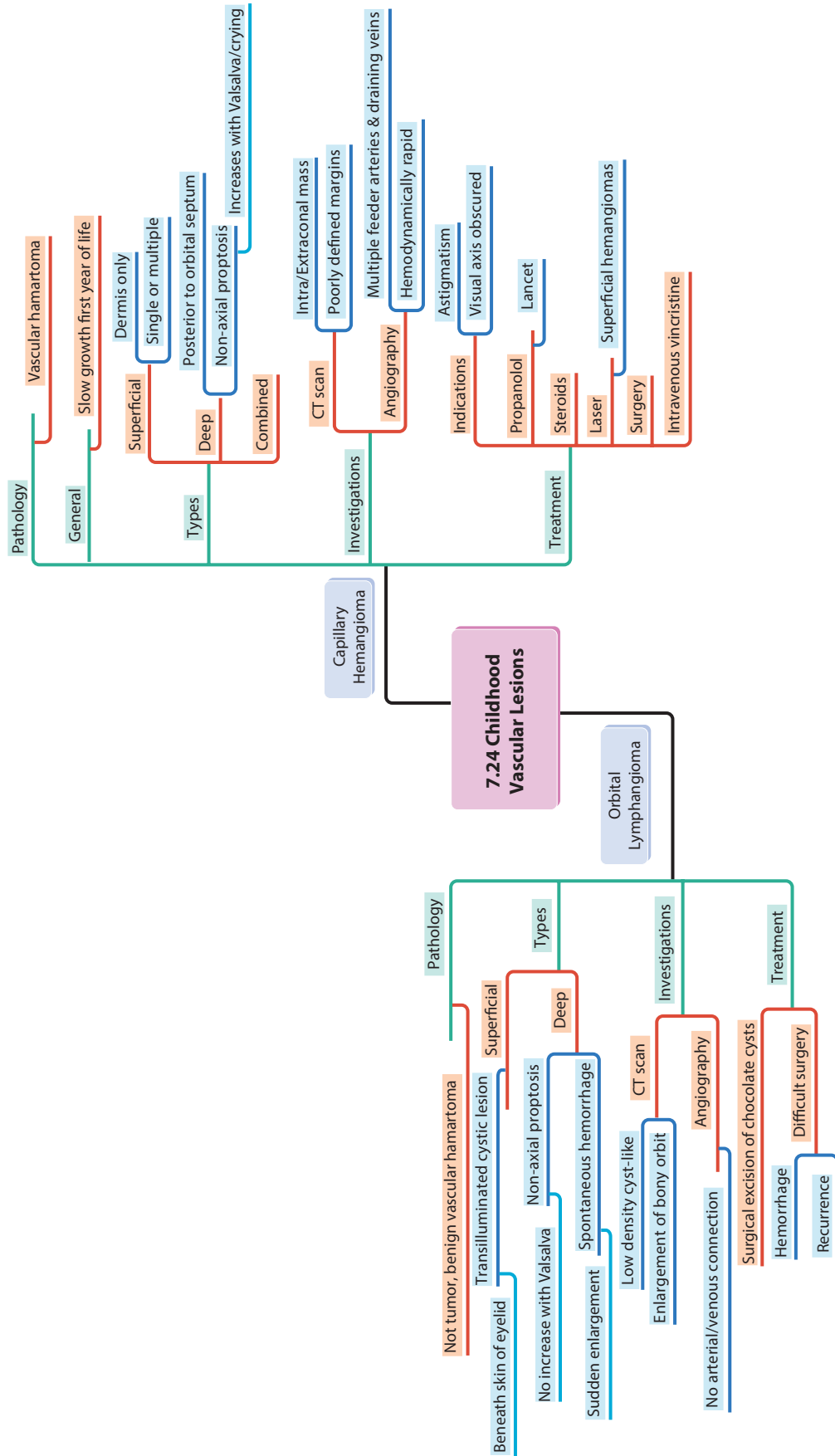


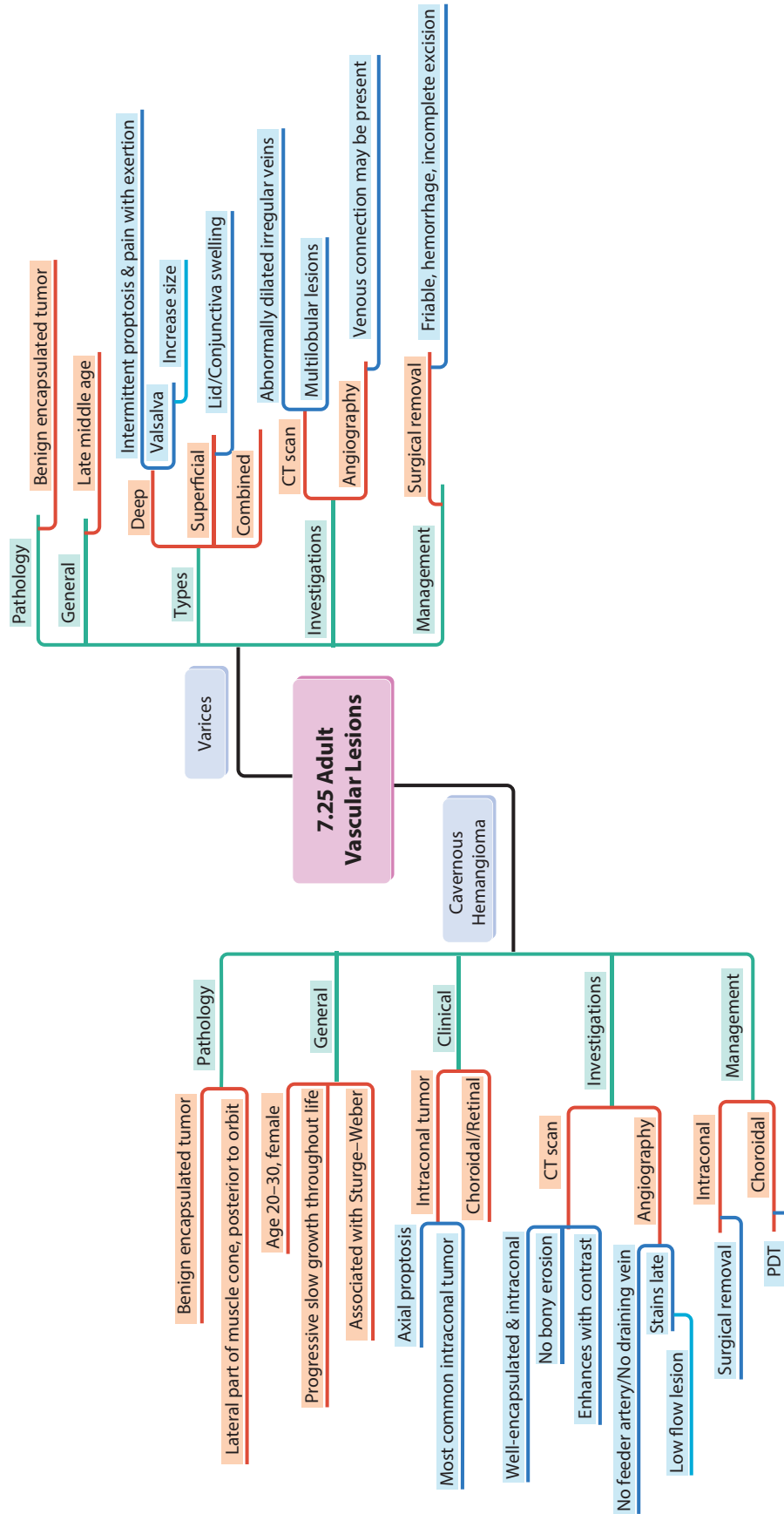


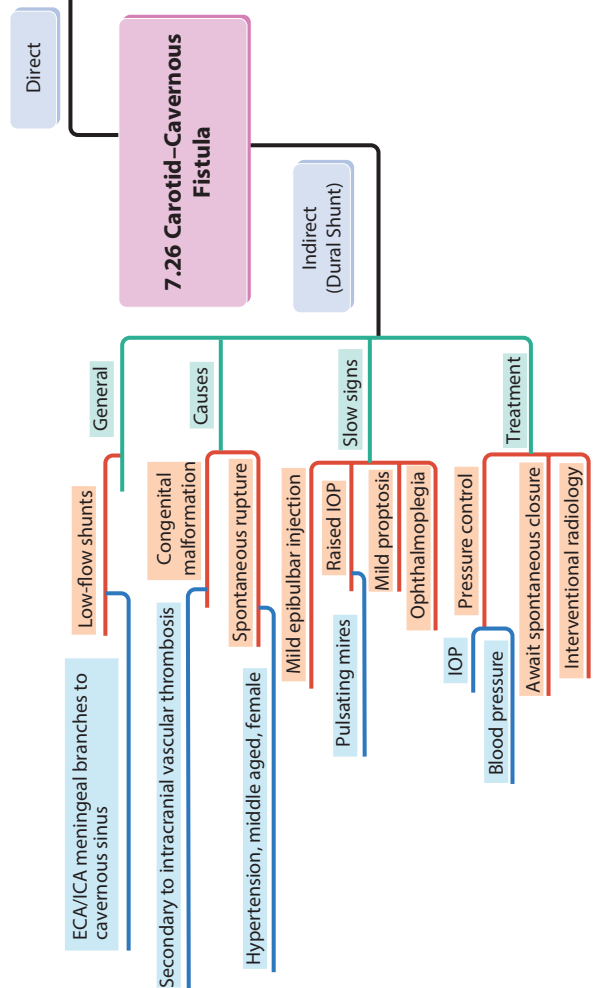
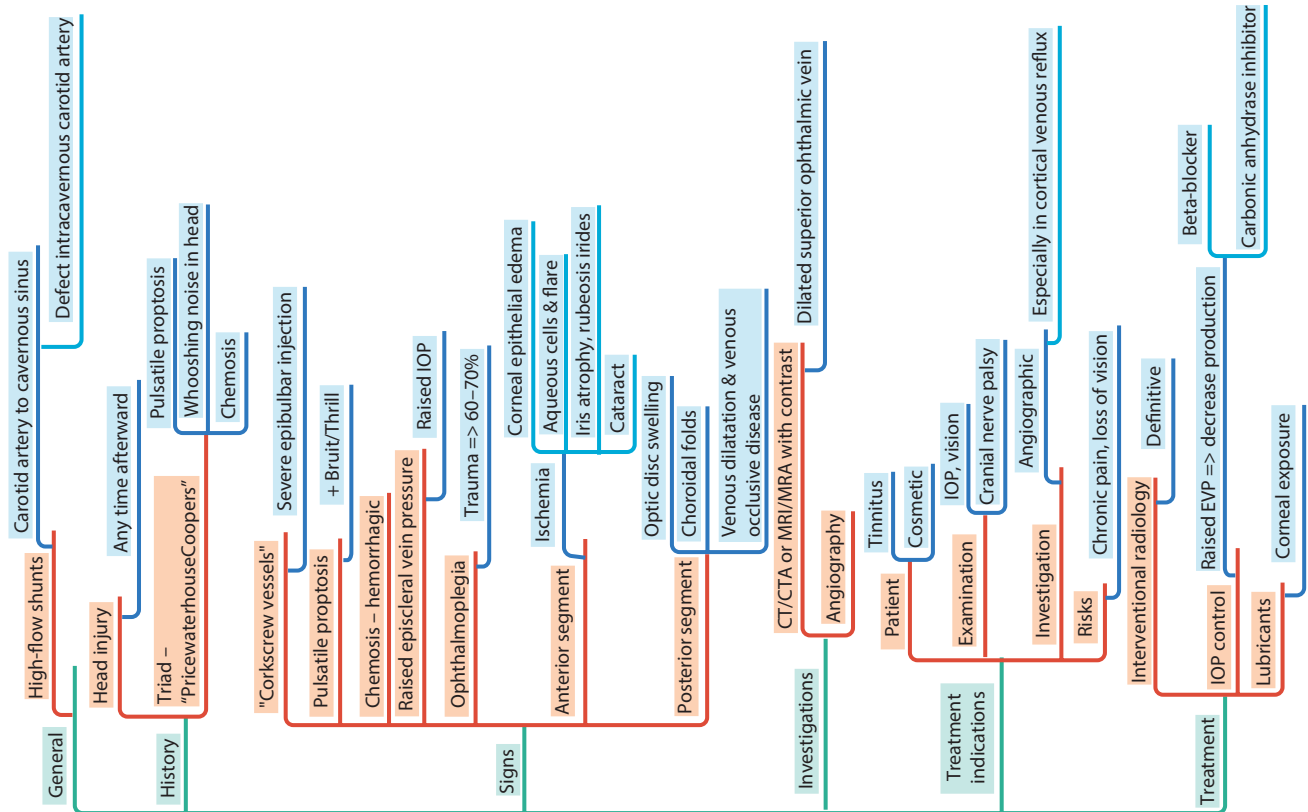


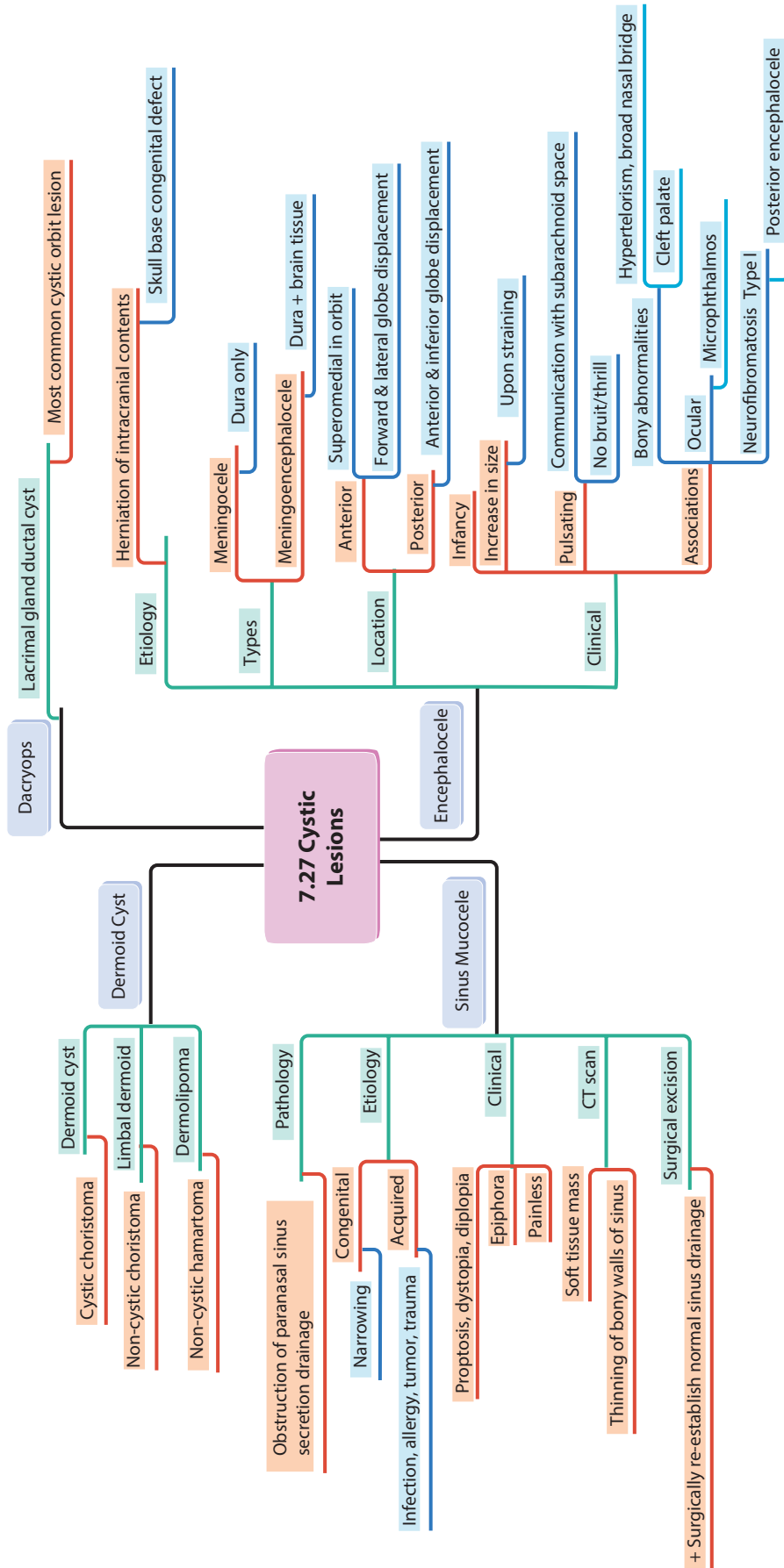


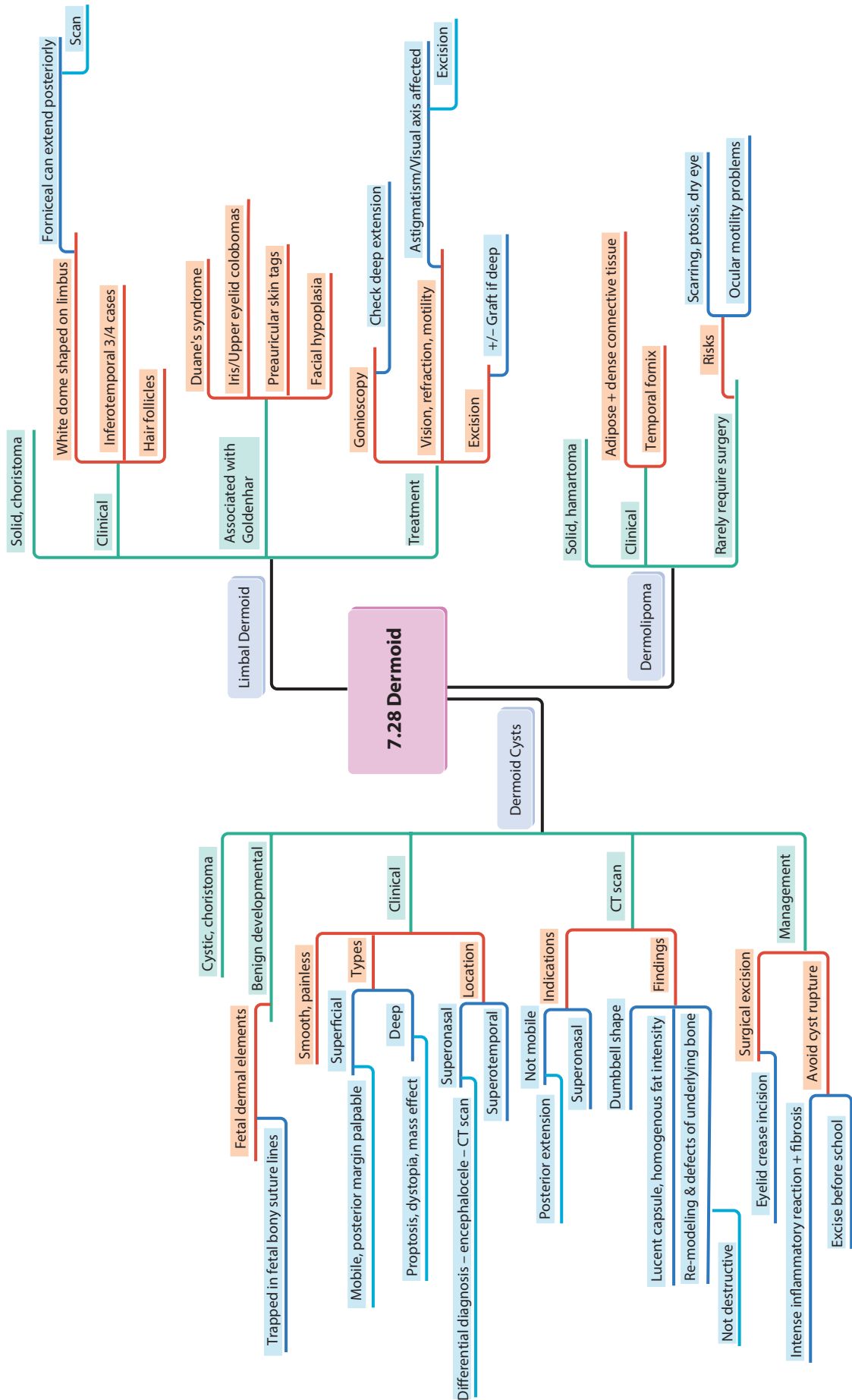


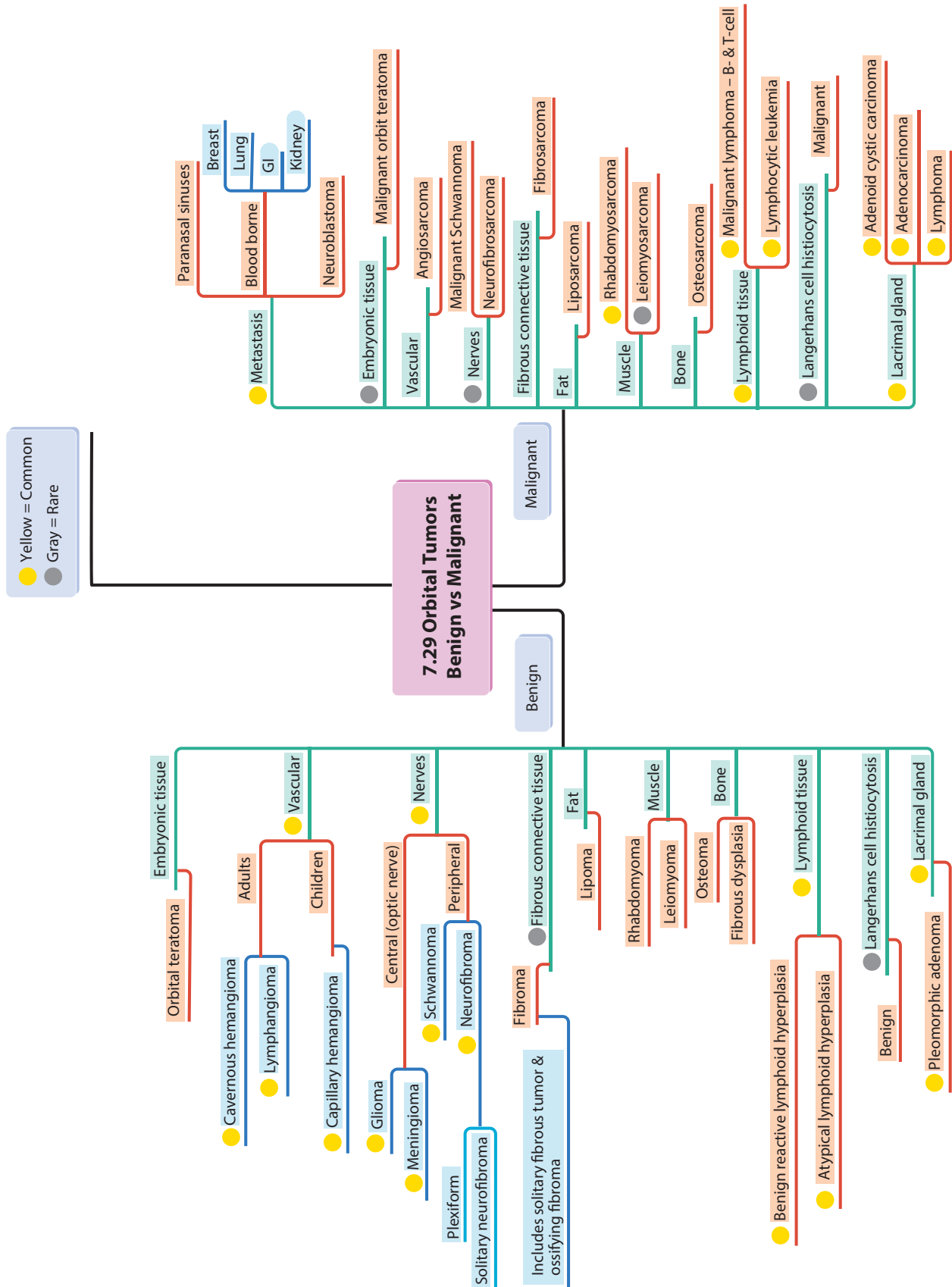


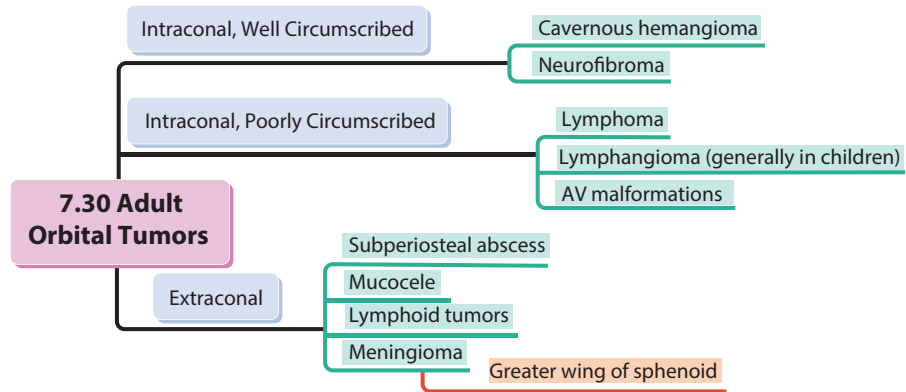


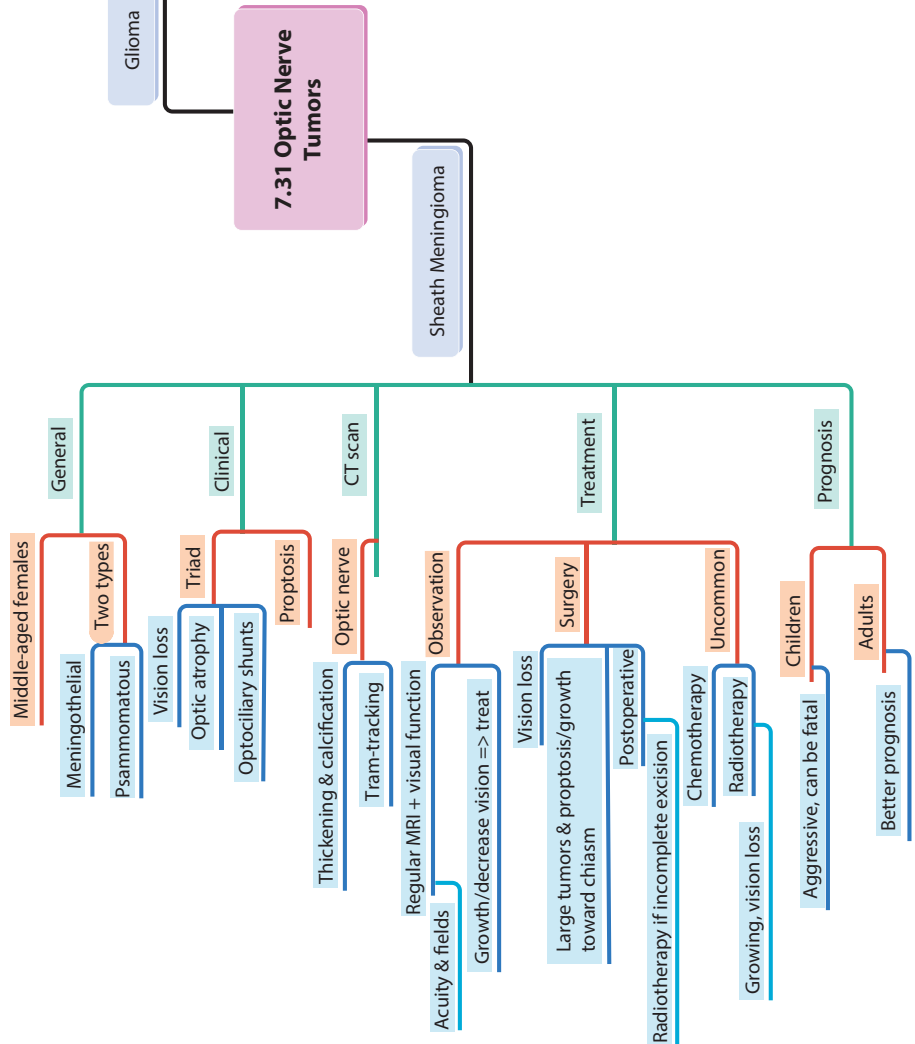
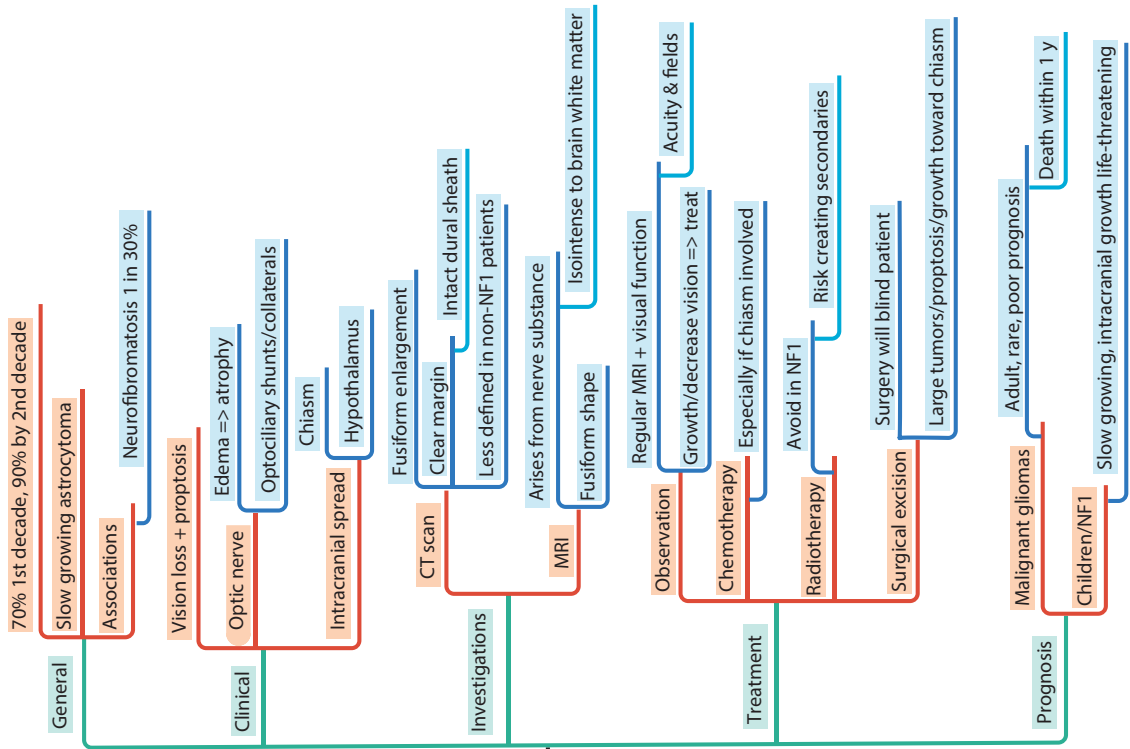


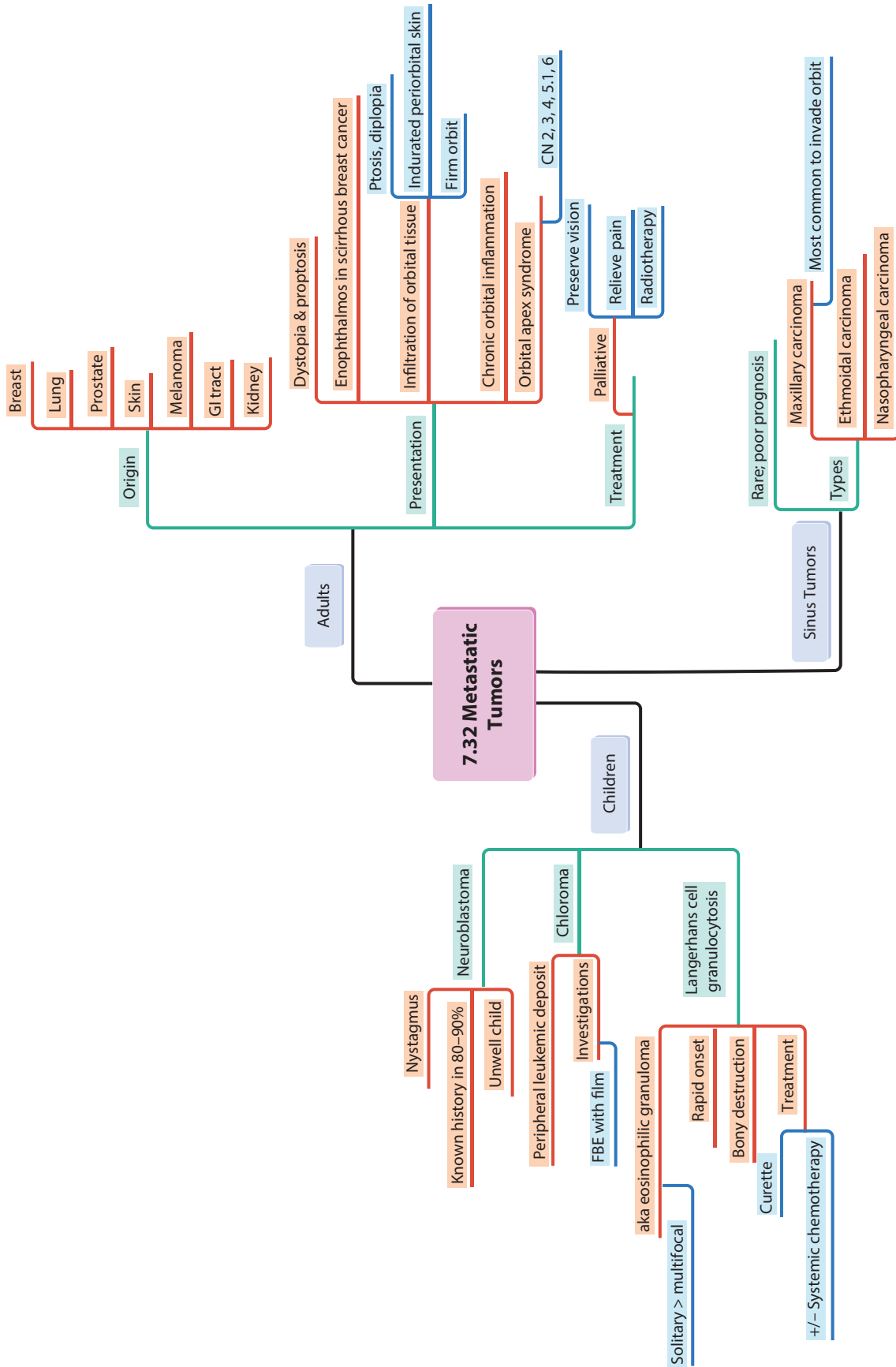


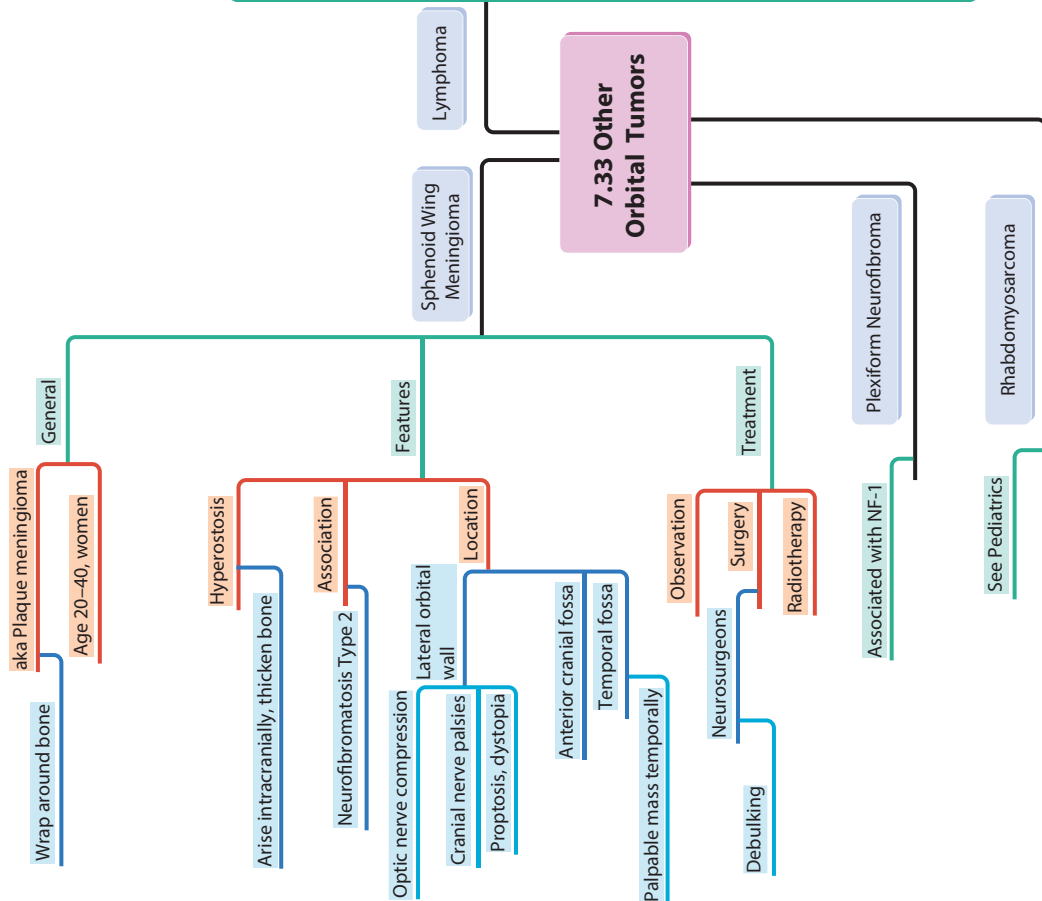
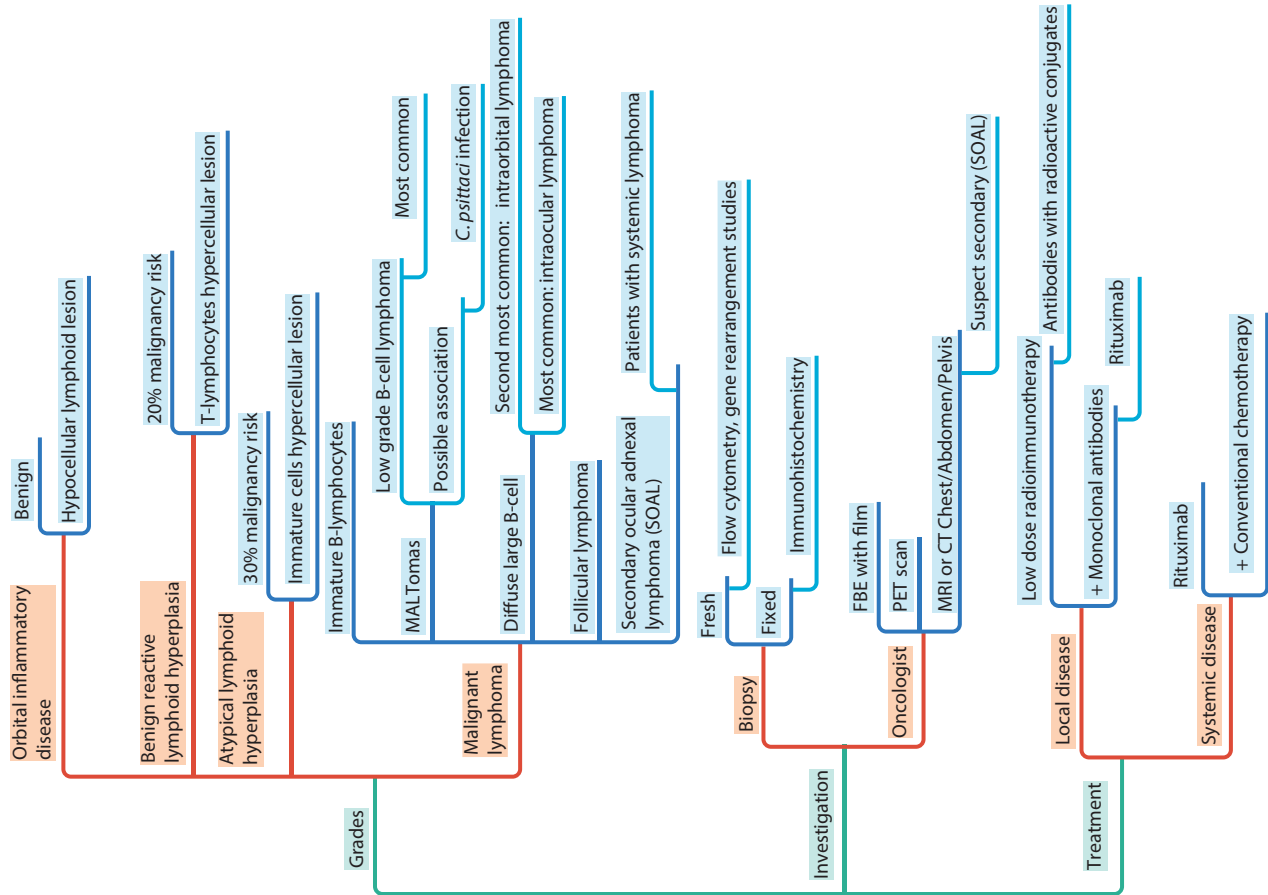


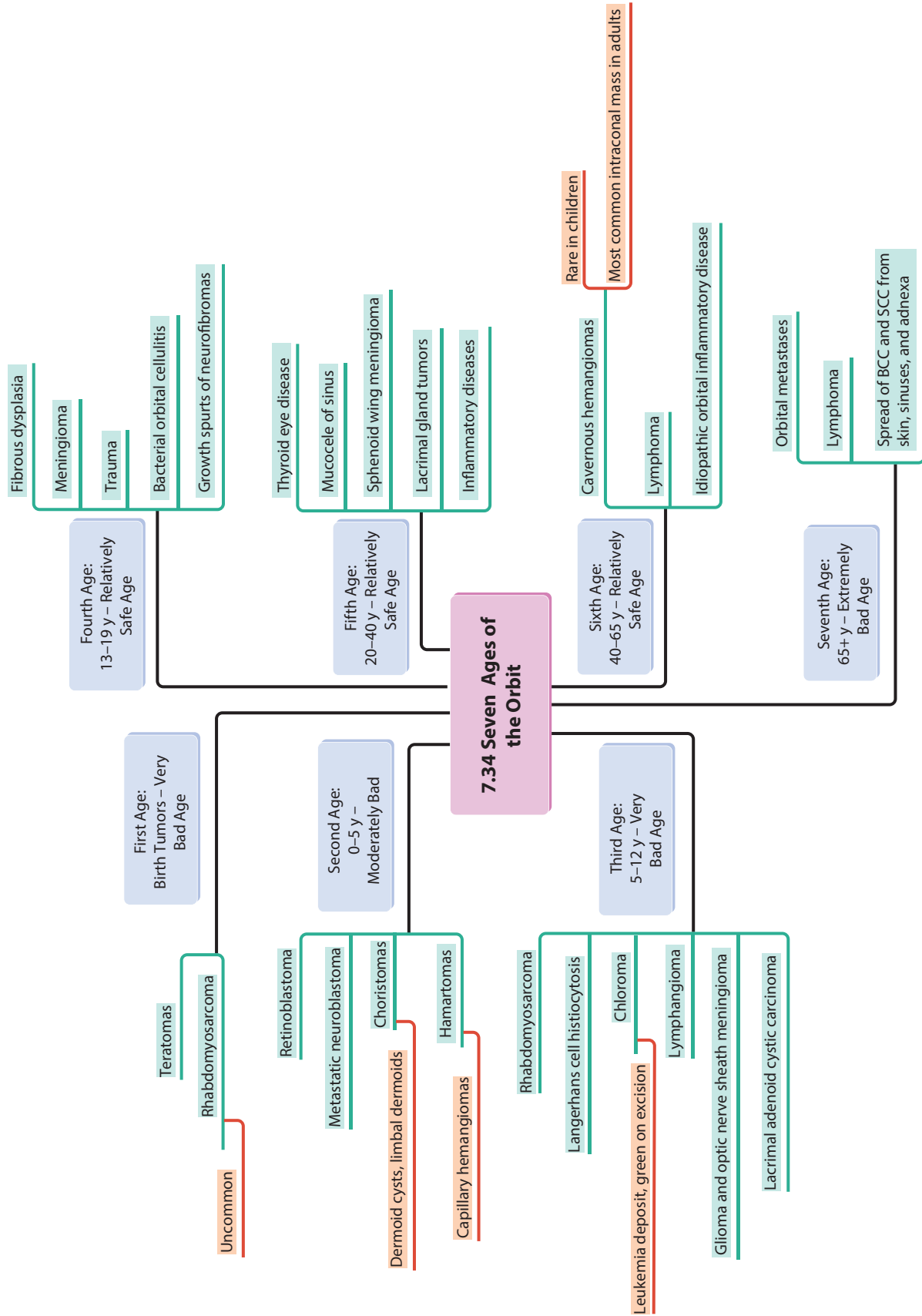


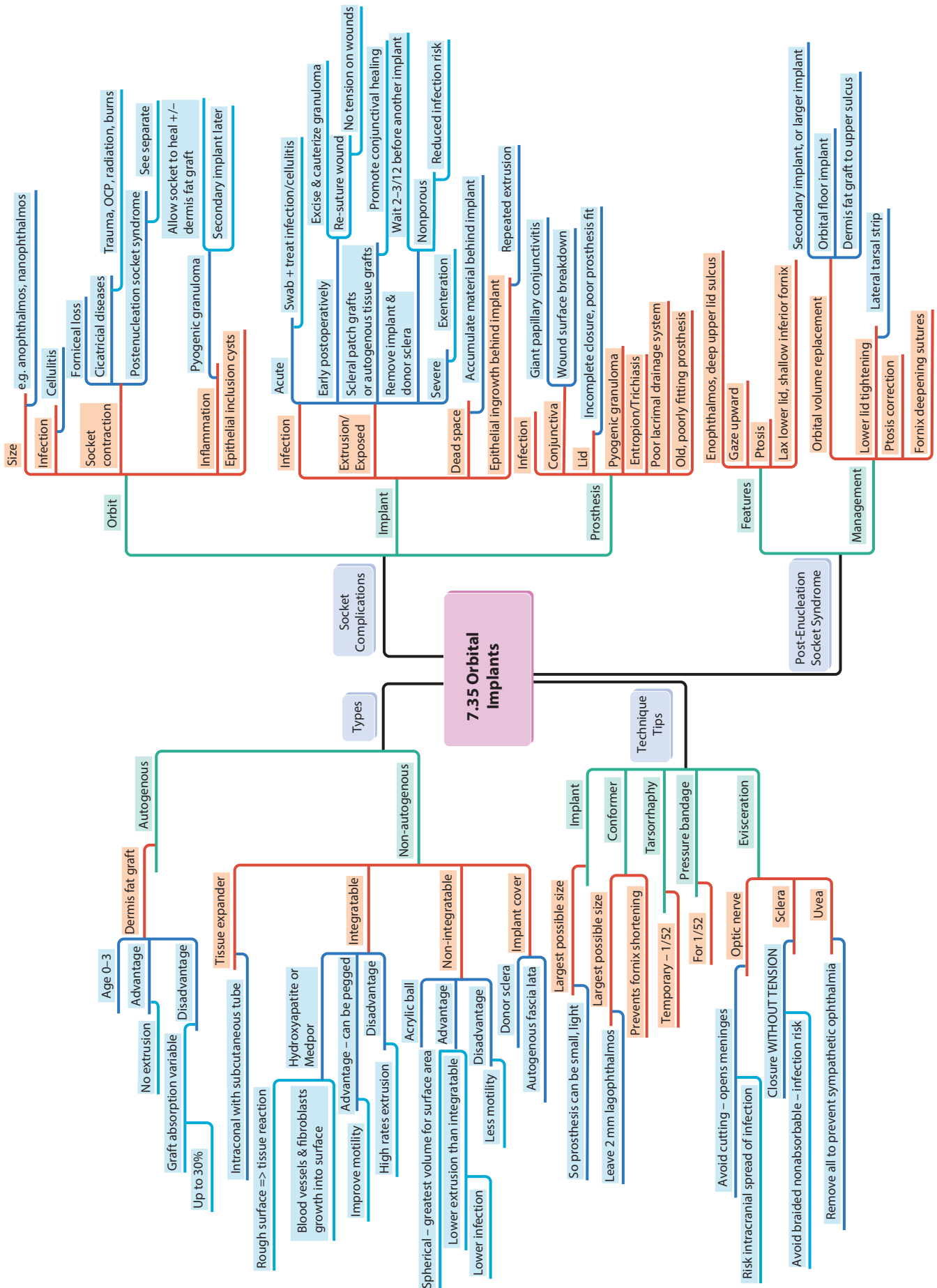




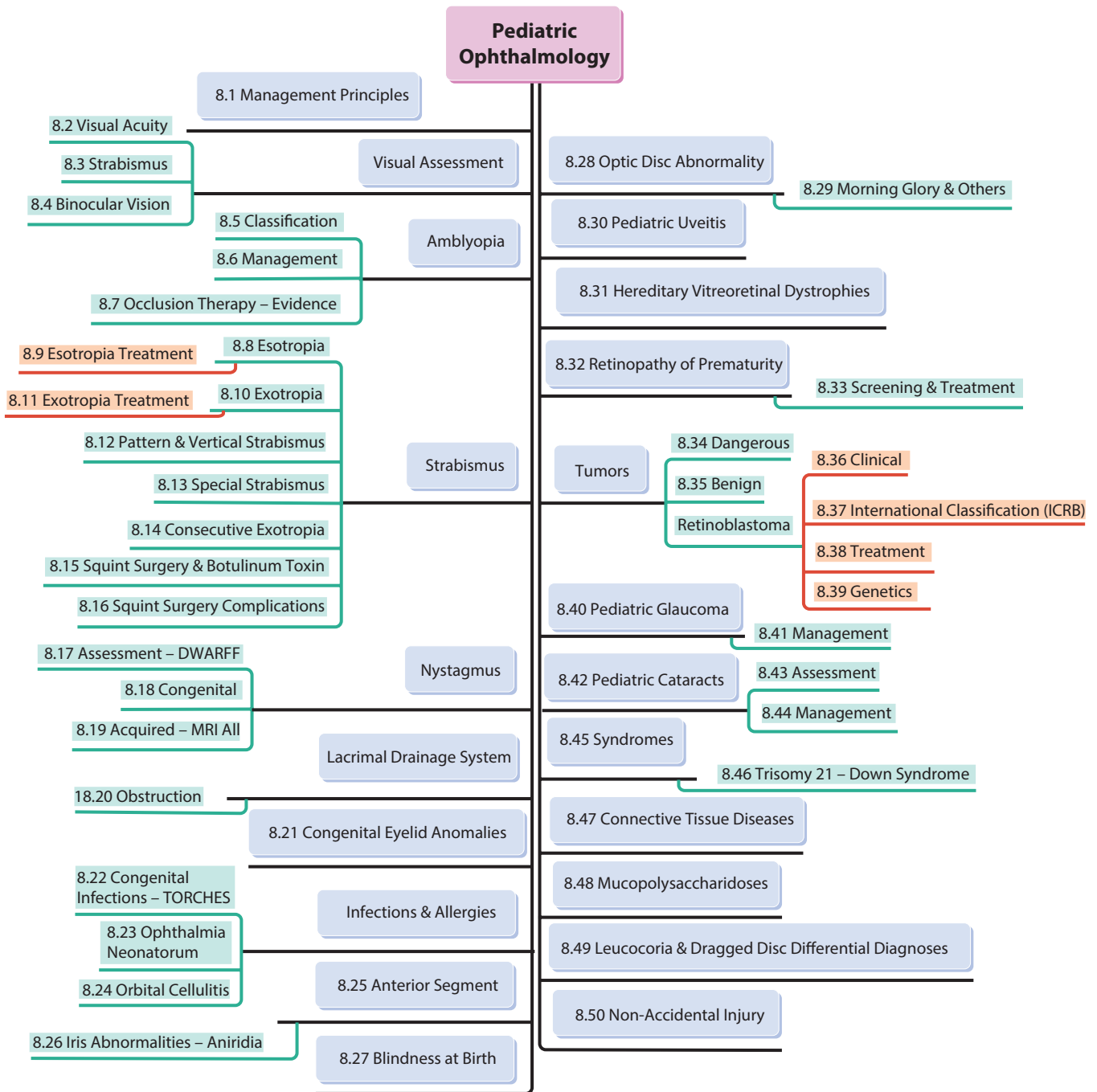


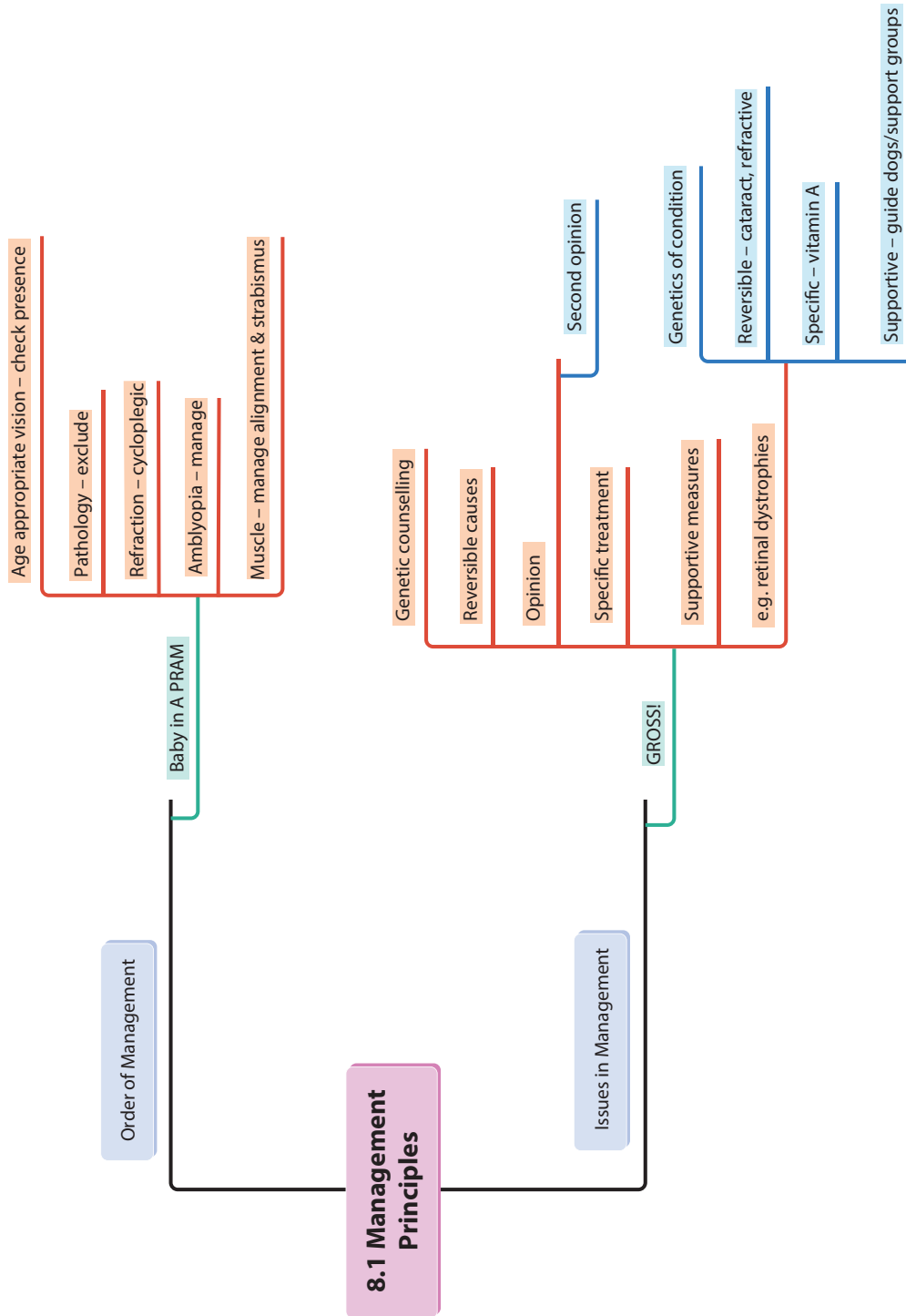


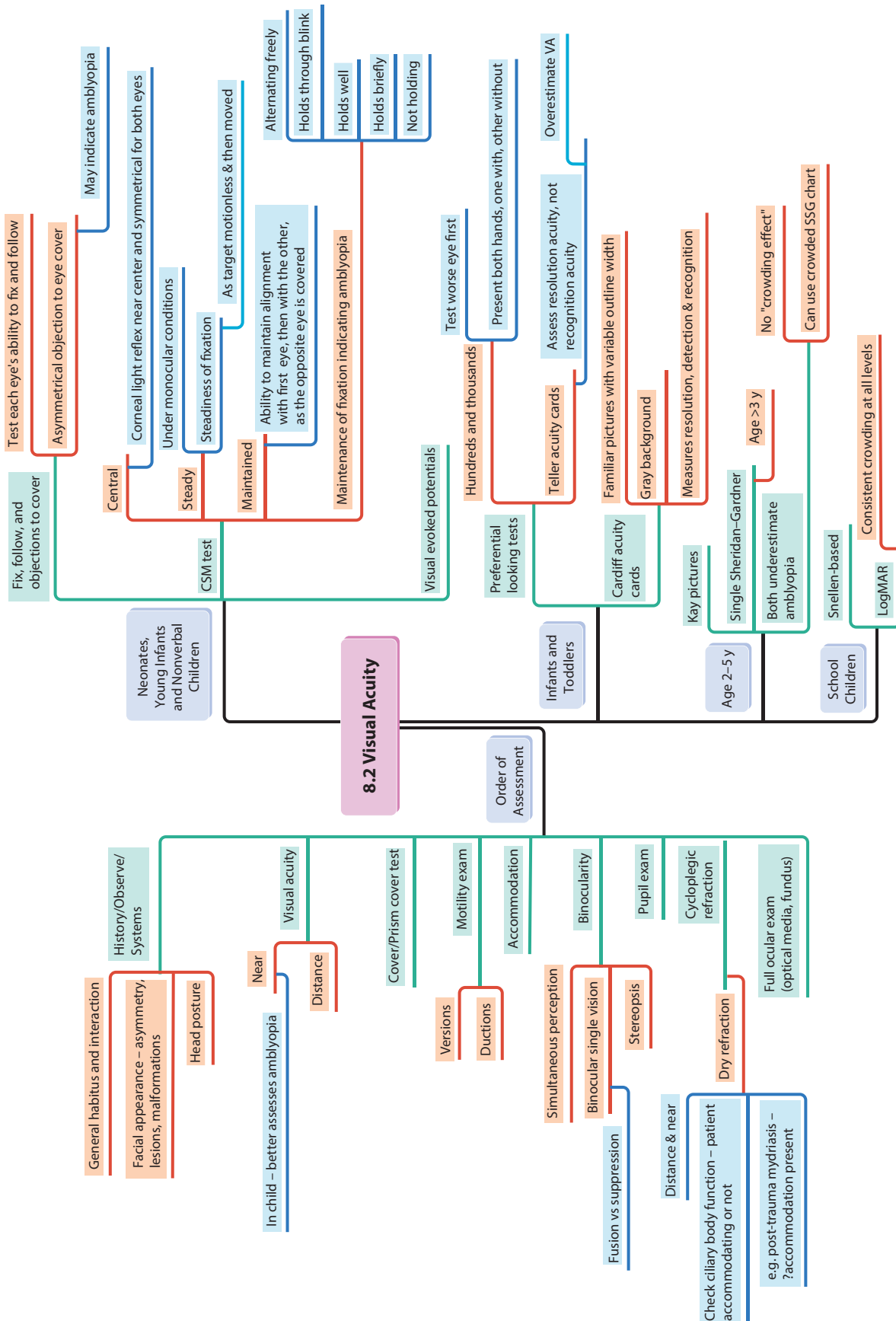


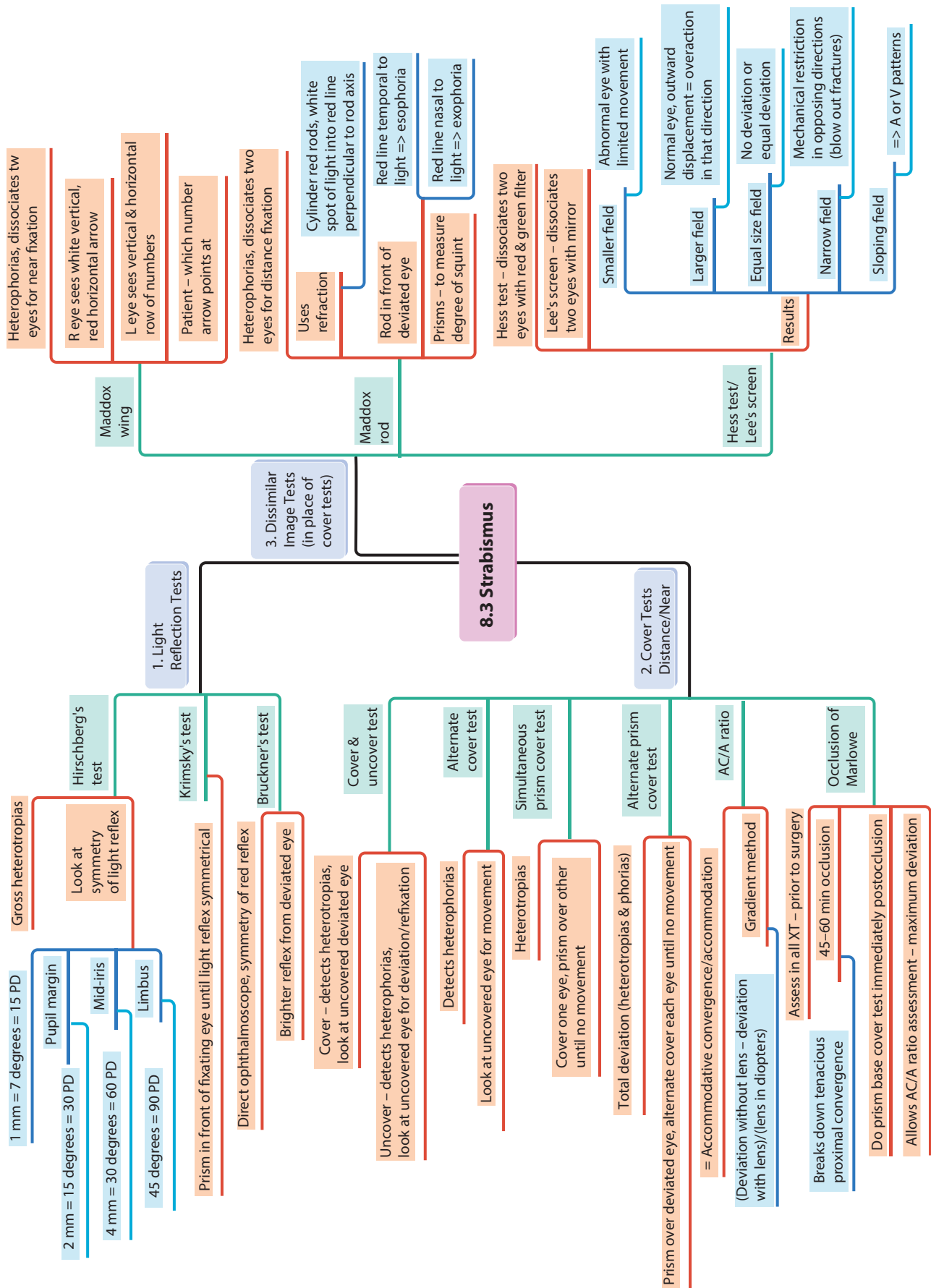


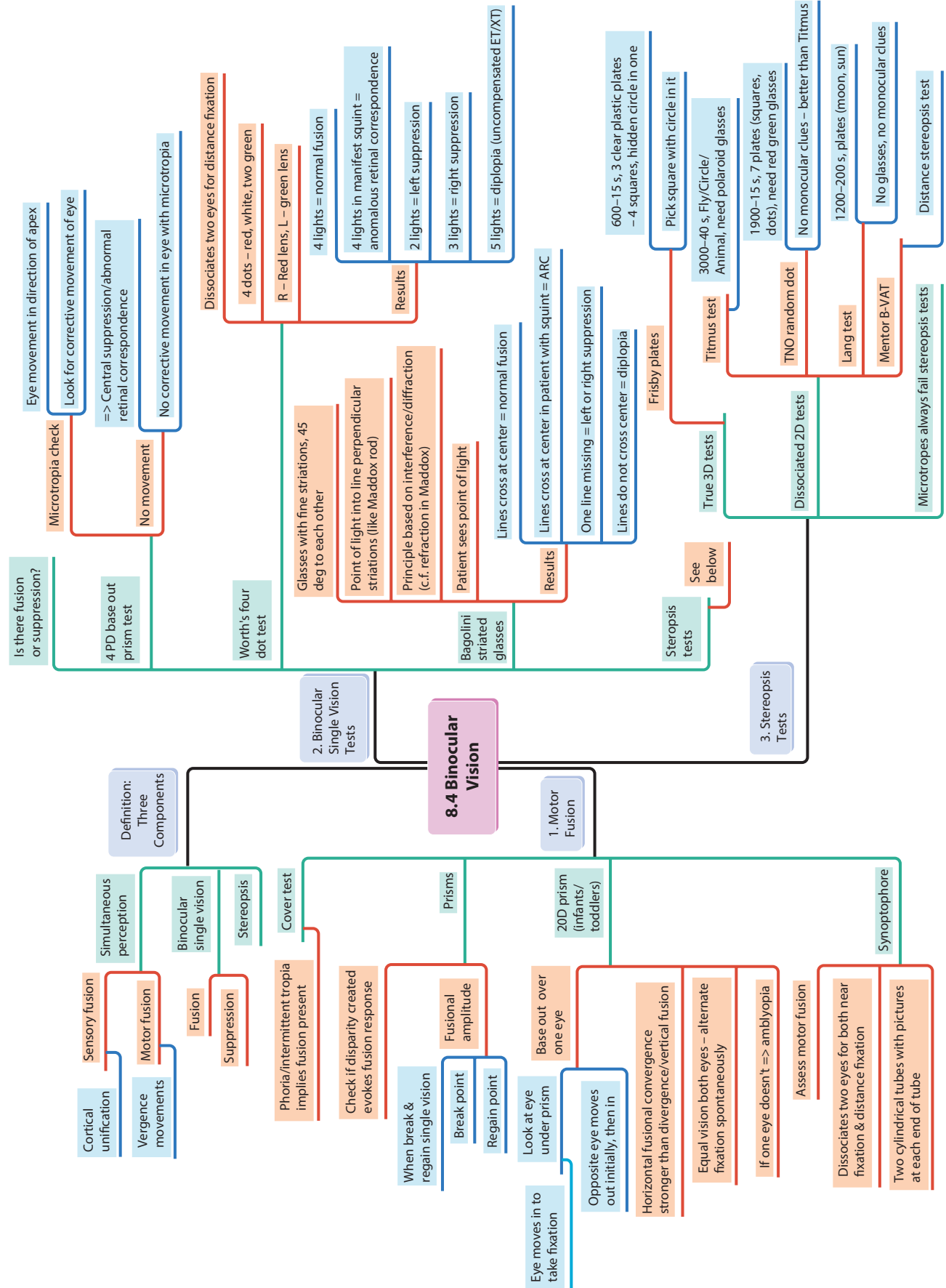
8 Pediatric Ophthalmology

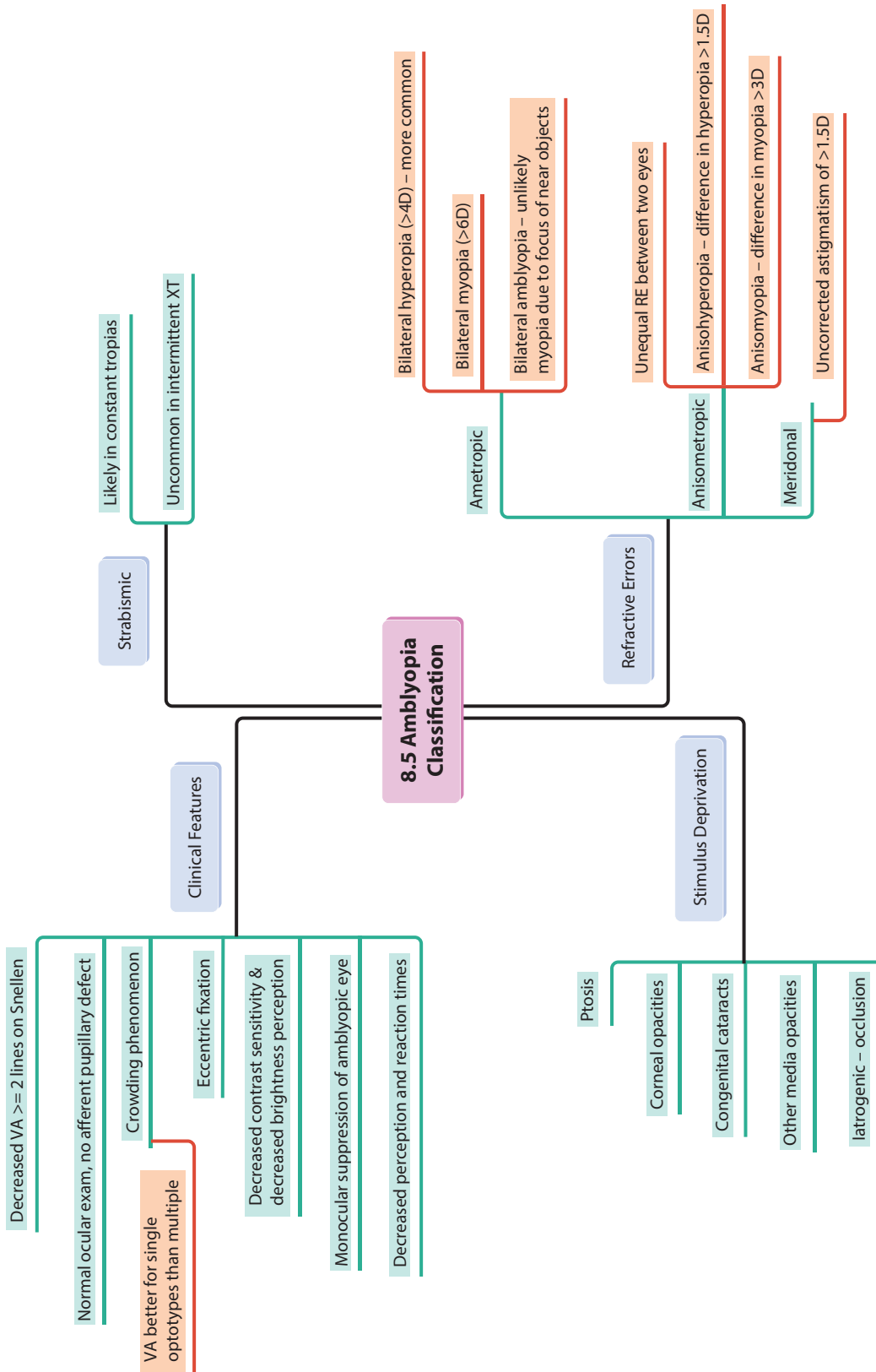


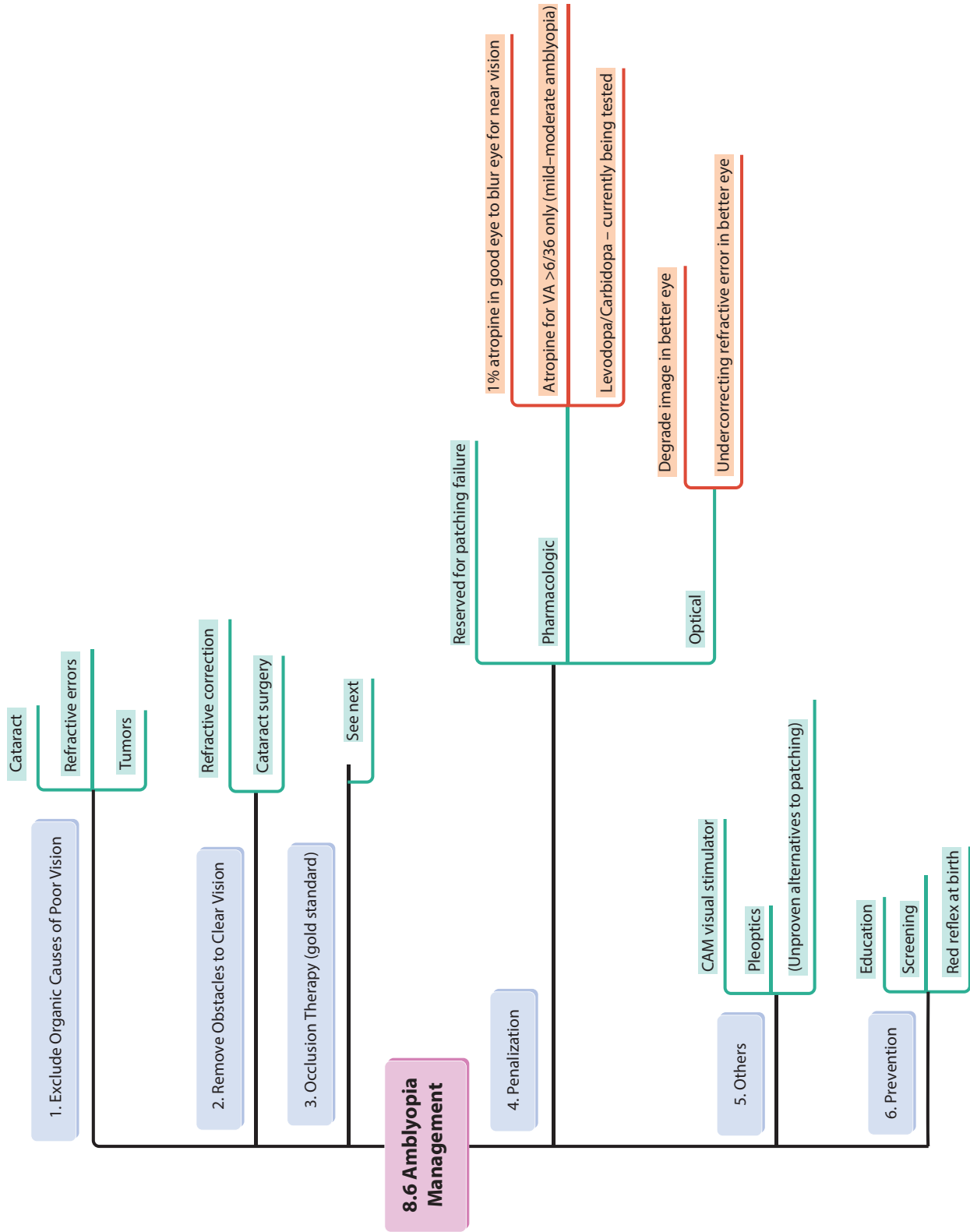


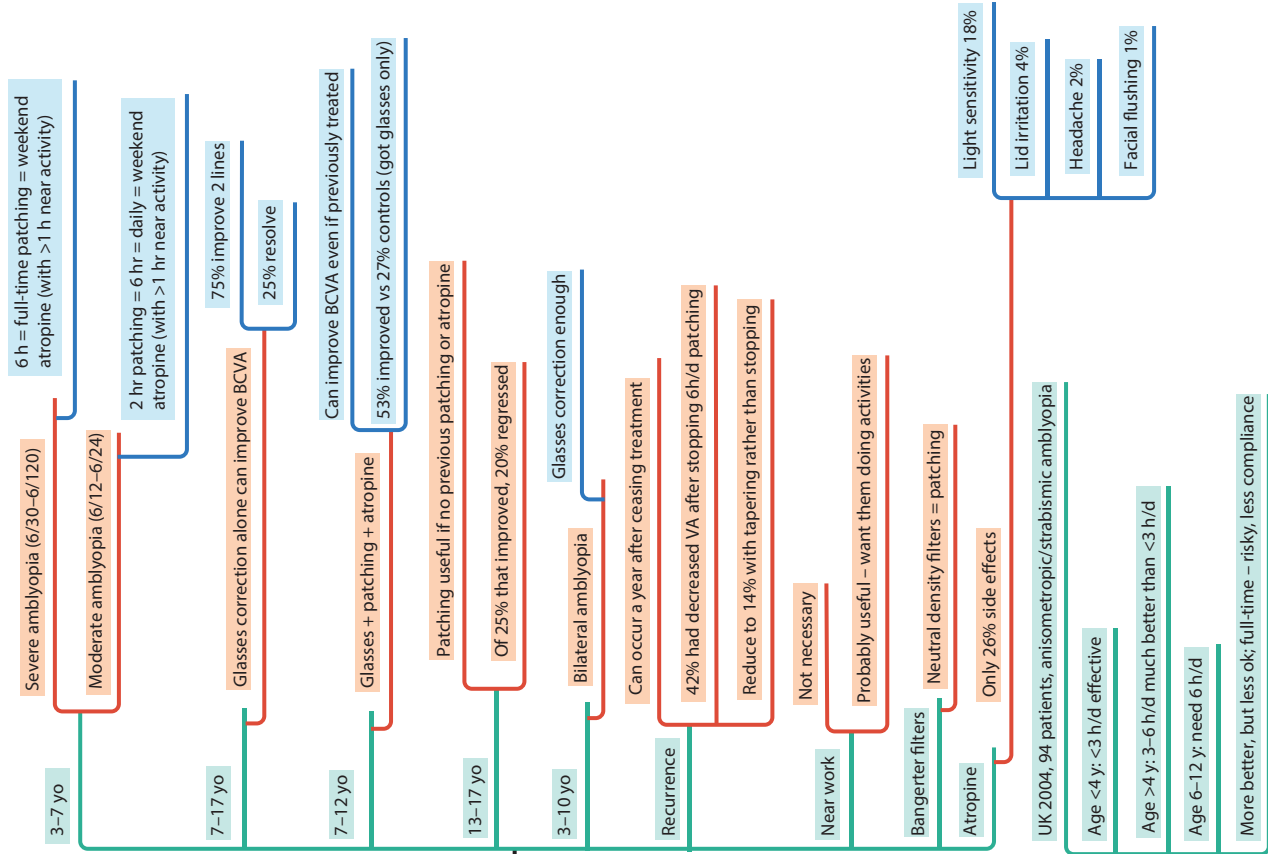












8.7 Amblyopia - Occlusion Therapy - Evidence

Practicalities

- Age, cause, severity determine amount
- Risk - can break down fusion, manifest strabismus
- Start patching when detect amblyopia
- Adhesive patches
- Full-time occlusion should not be >1wk/year of age
- Continue until VA stable for 3-6 mo
- Maintenance patching until age 9 may be required
- 4 reviews per year sufficient
- Consider failure
- Wrong diagnosis
- Noncompliance
- Uncorrected refractive error
- Failure to prescribe sufficient treatment
- Irreversible amblyopia

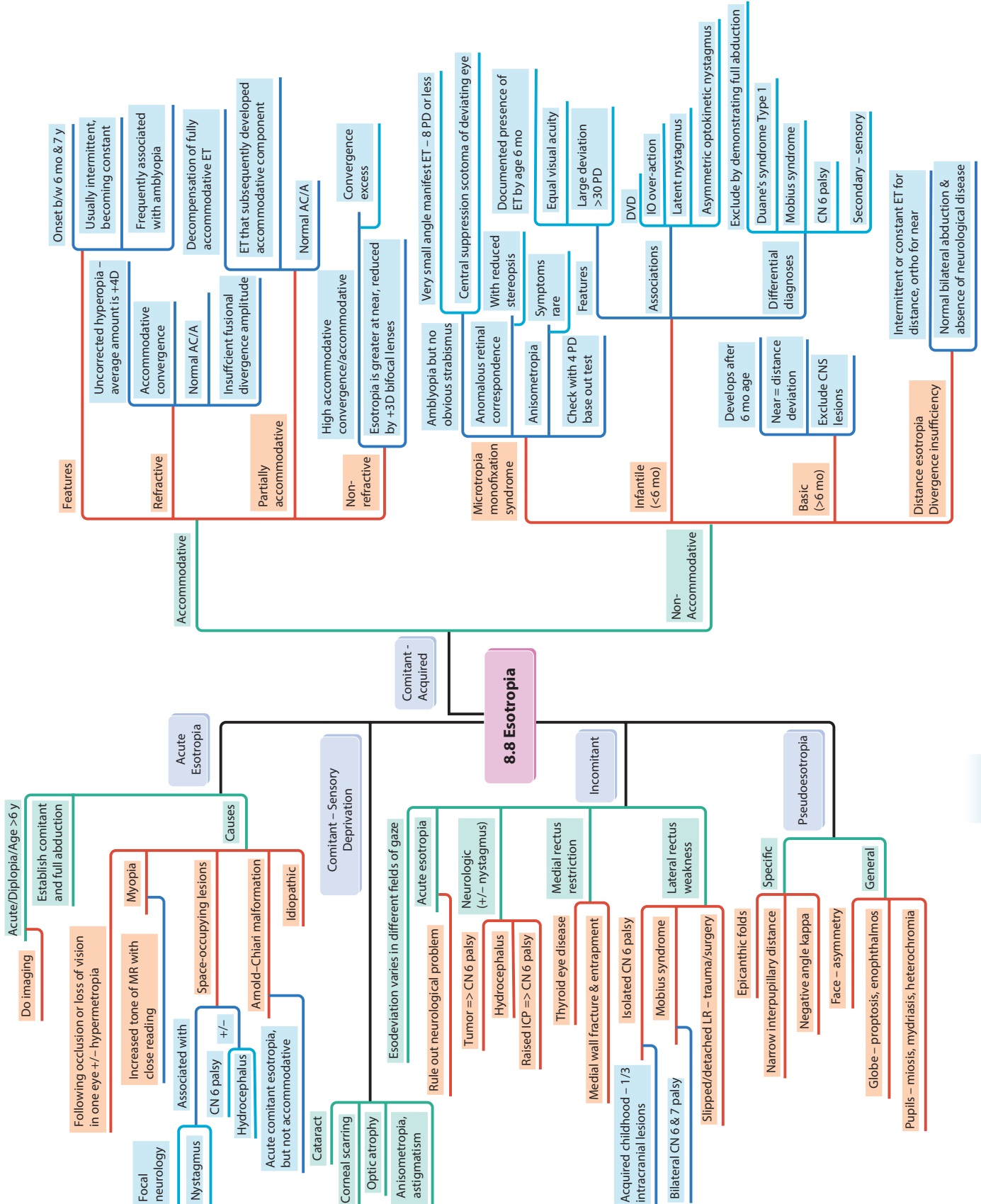
PEDIG Amblyopia Studies

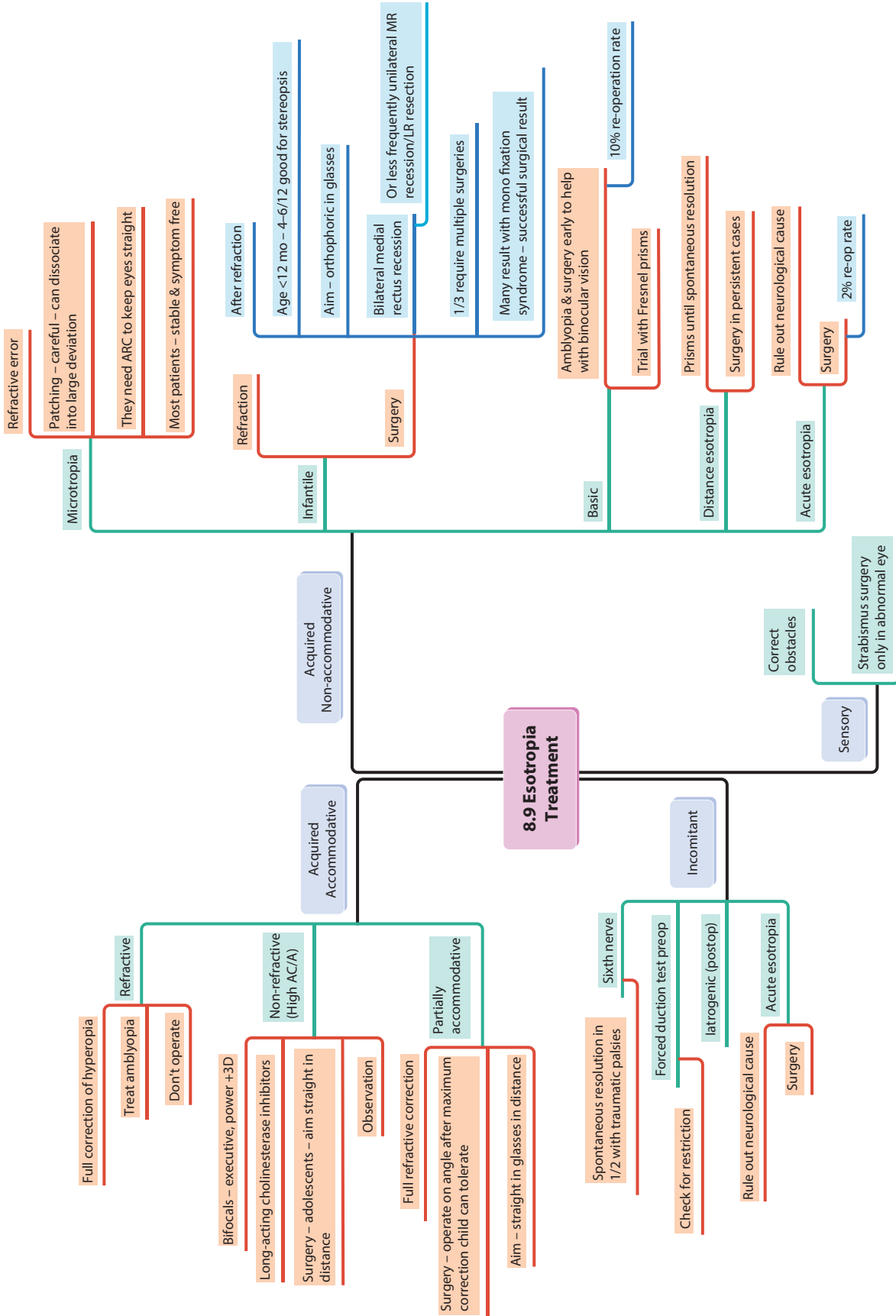
- 3-7 yo
 - Severe amblyopia (6/30-6/120)
 - 6 h = full-time patching = weekend atropine (with >1 h near activity)
 - Moderate amblyopia (6/12-6/24)
 - 2 hr patching = 6 hr = daily = weekend atropine (with >1 hr near activity)
- 7-17 yo
 - Glasses correction alone can improve BCVA
 - 75% improve 2 lines
 - 25% resolve
- 7-12 yo
 - Glasses + patching + atropine
 - Can improve BCVA even if previously treated
 - 53% improved vs 27% controls (got glasses only)
- 13-17 yo
 - Patching useful if no previous patching or atropine
 - Of 25% that improved, 20% regressed
- 3-10 yo
 - Bilateral amblyopia
 - Glasses correction enough
- Recurrence
 - Can occur a year after ceasing treatment
 - 42% had decreased VA after stopping 6h/d patching
 - Reduce to 14% with tapering rather than stopping
- Near work
 - Not necessary
 - Probably useful - want them doing activities
- Bangerter filters
 - Neutral density filters = patching
- Atropine
 - Only 26% side effects

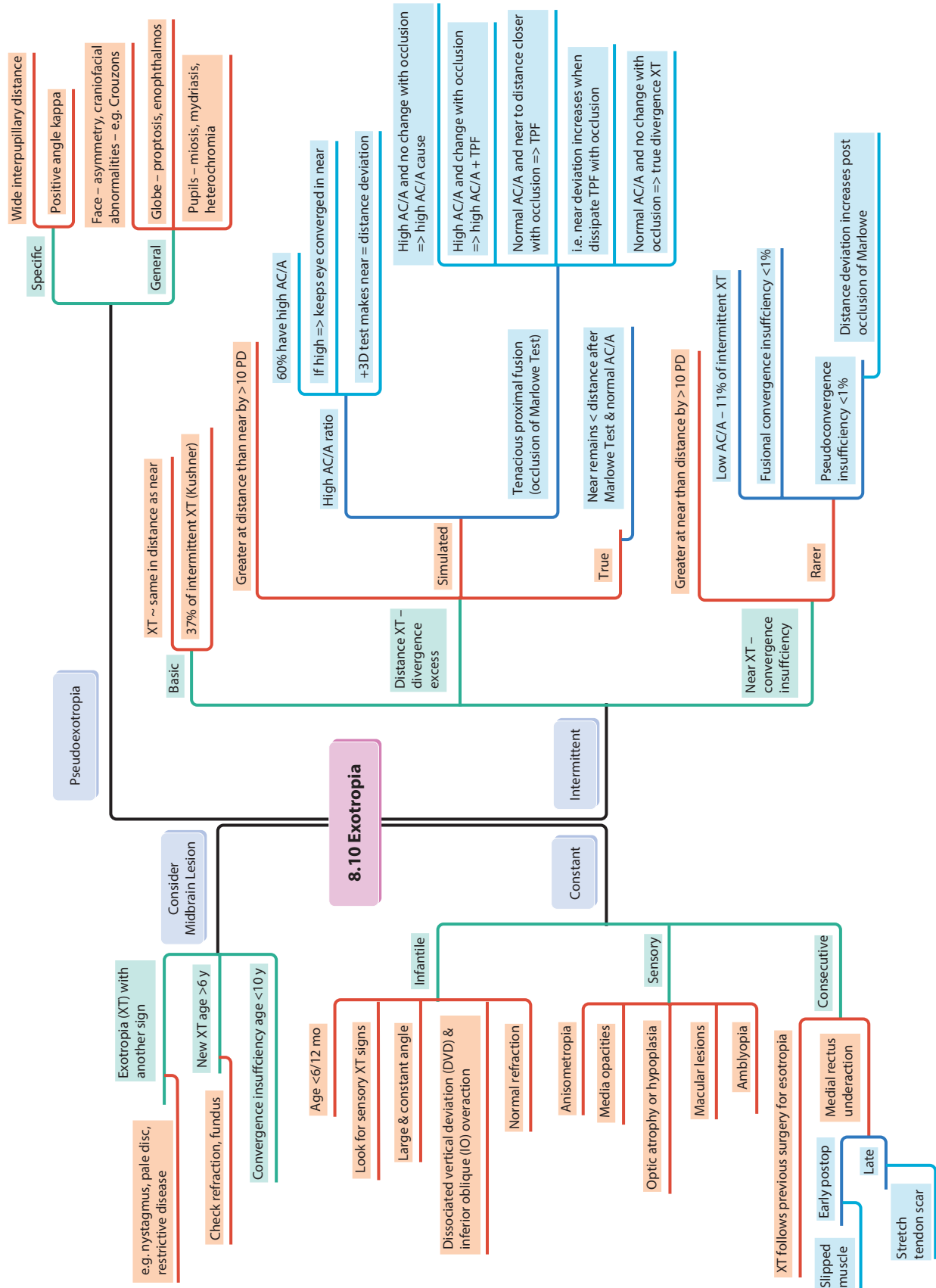
MOTAS Studies

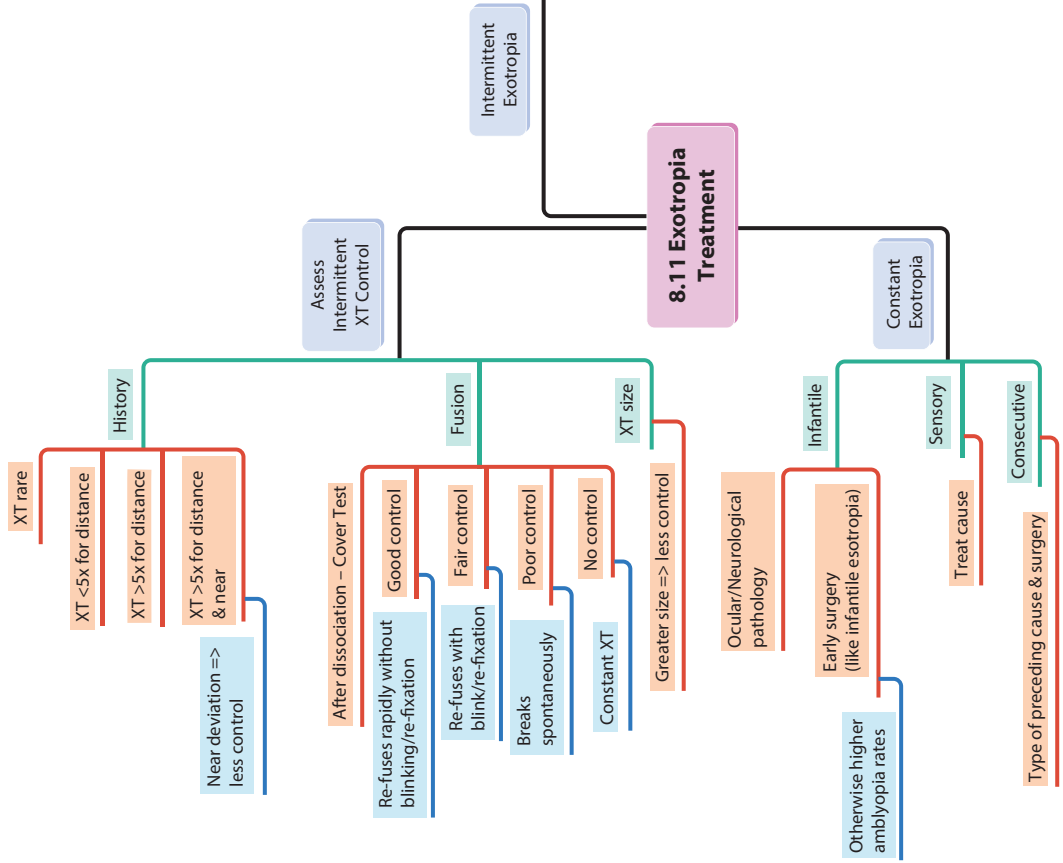
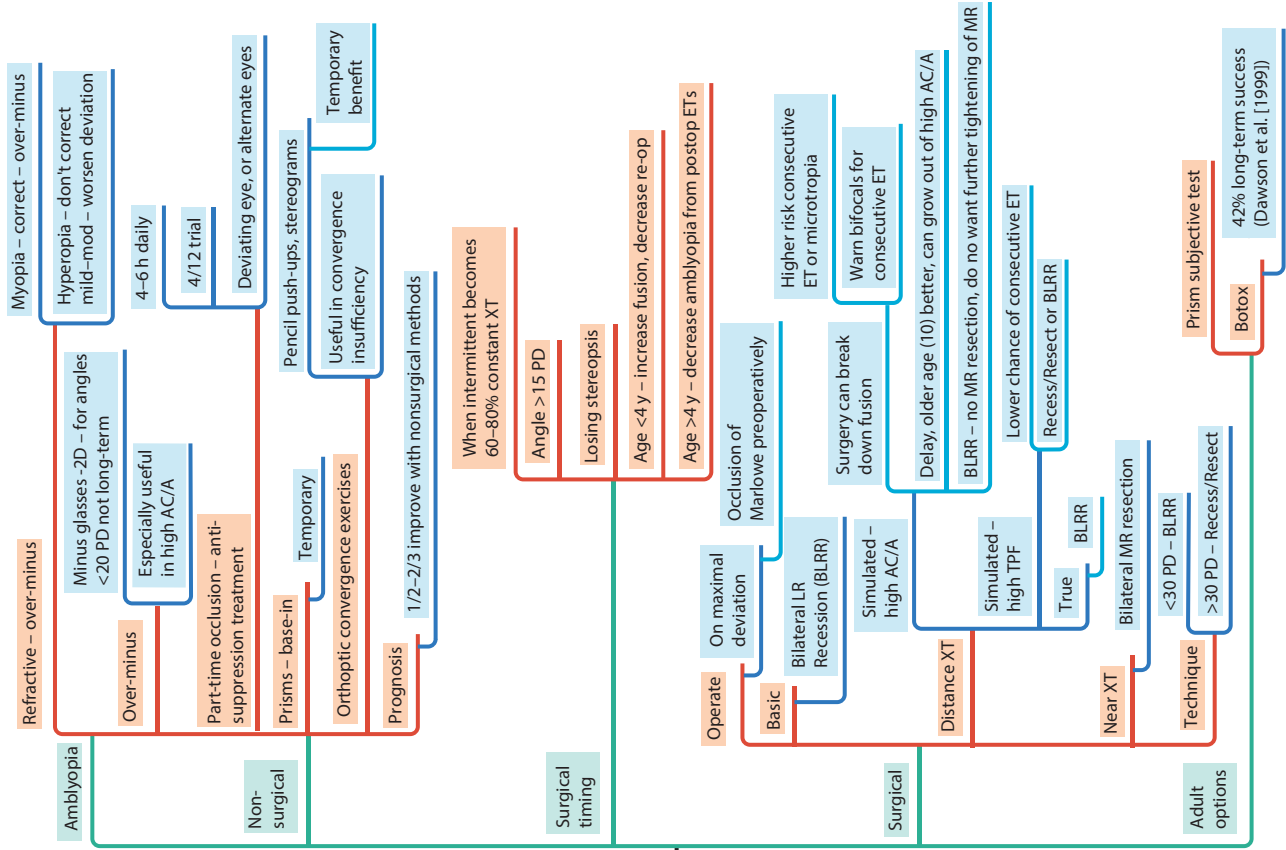
- UK 2004, 94 patients, anisometropic/strabismic amblyopia
- Age <4y: <3 h/d effective
- Age >4y: 3-6 h/d much better than <3 h/d
- Age 6-12 y: need 6 h/d
- More better, but less ok; full-time - risky, less compliance

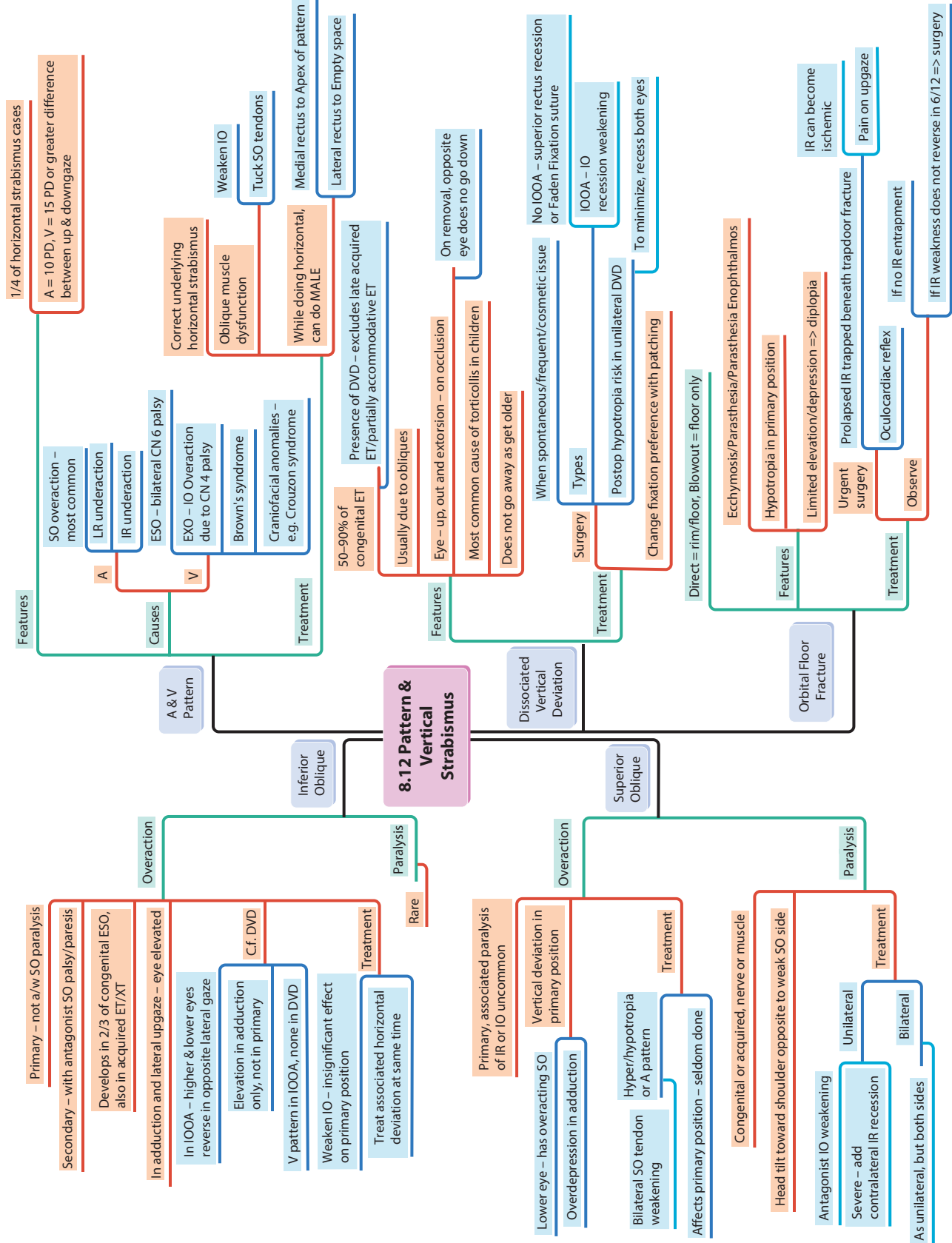
- Light sensitivity 18%
- Lid irritation 4%
- Headache 2%
- Facial flushing 1%

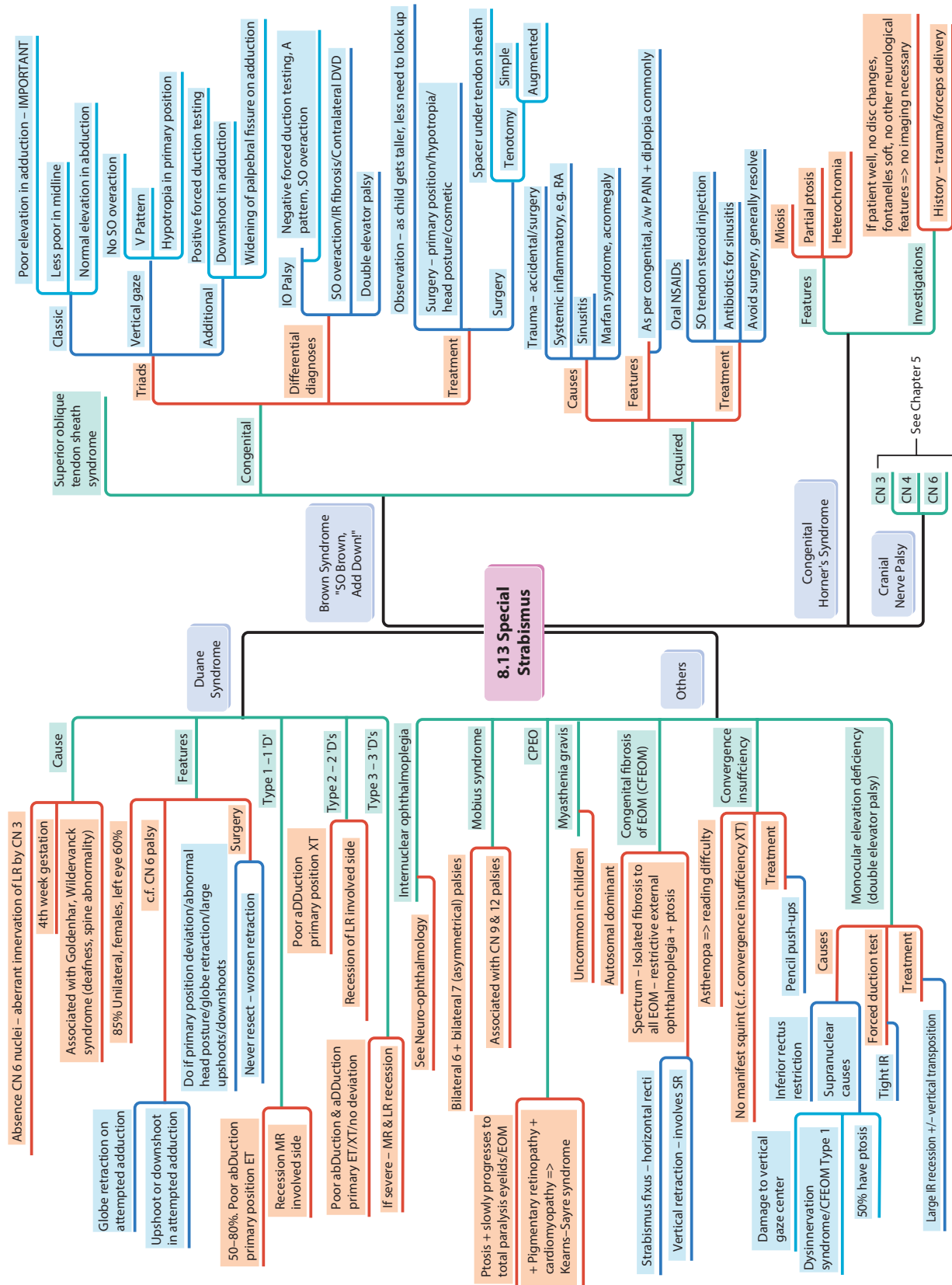


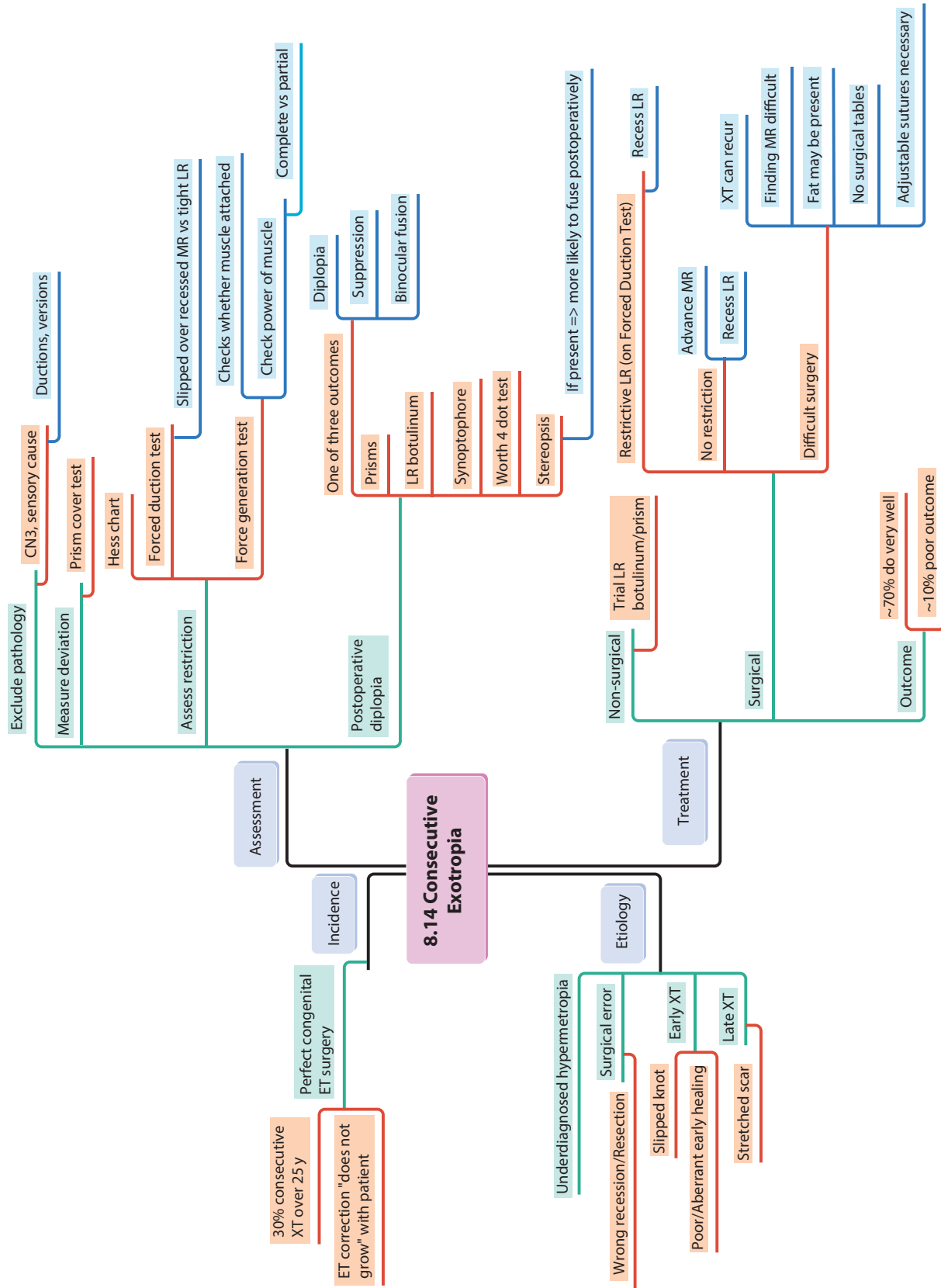


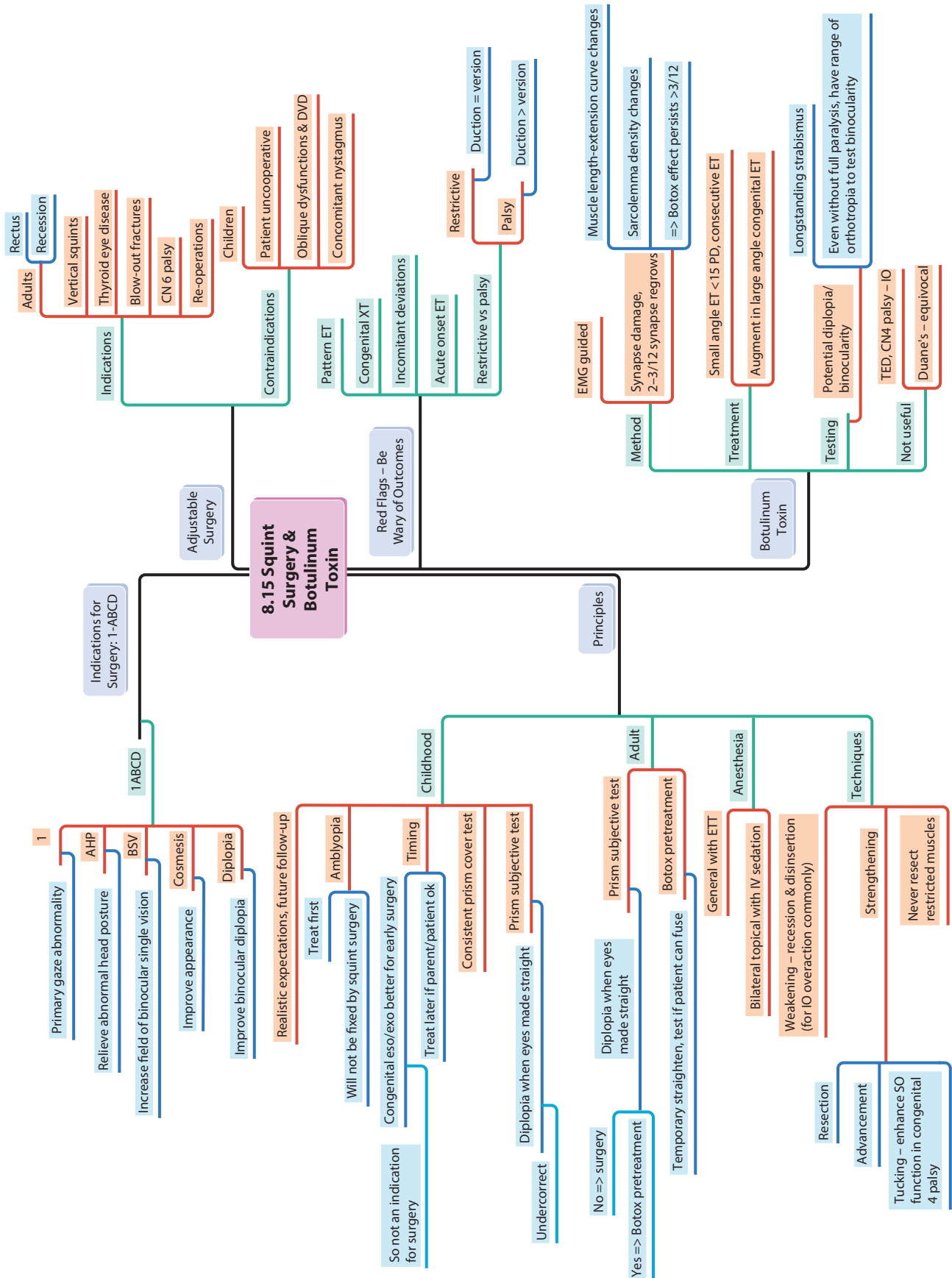


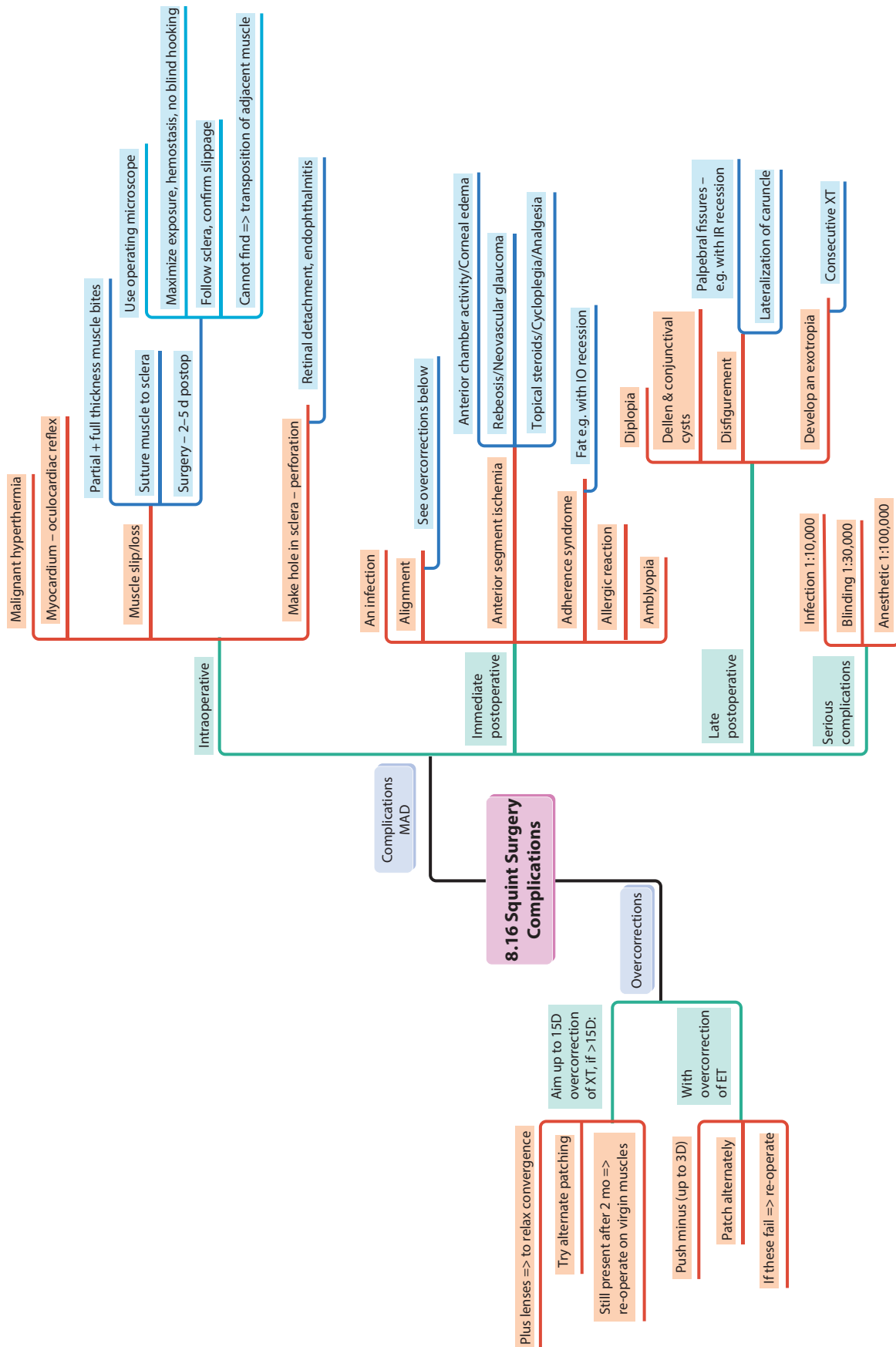


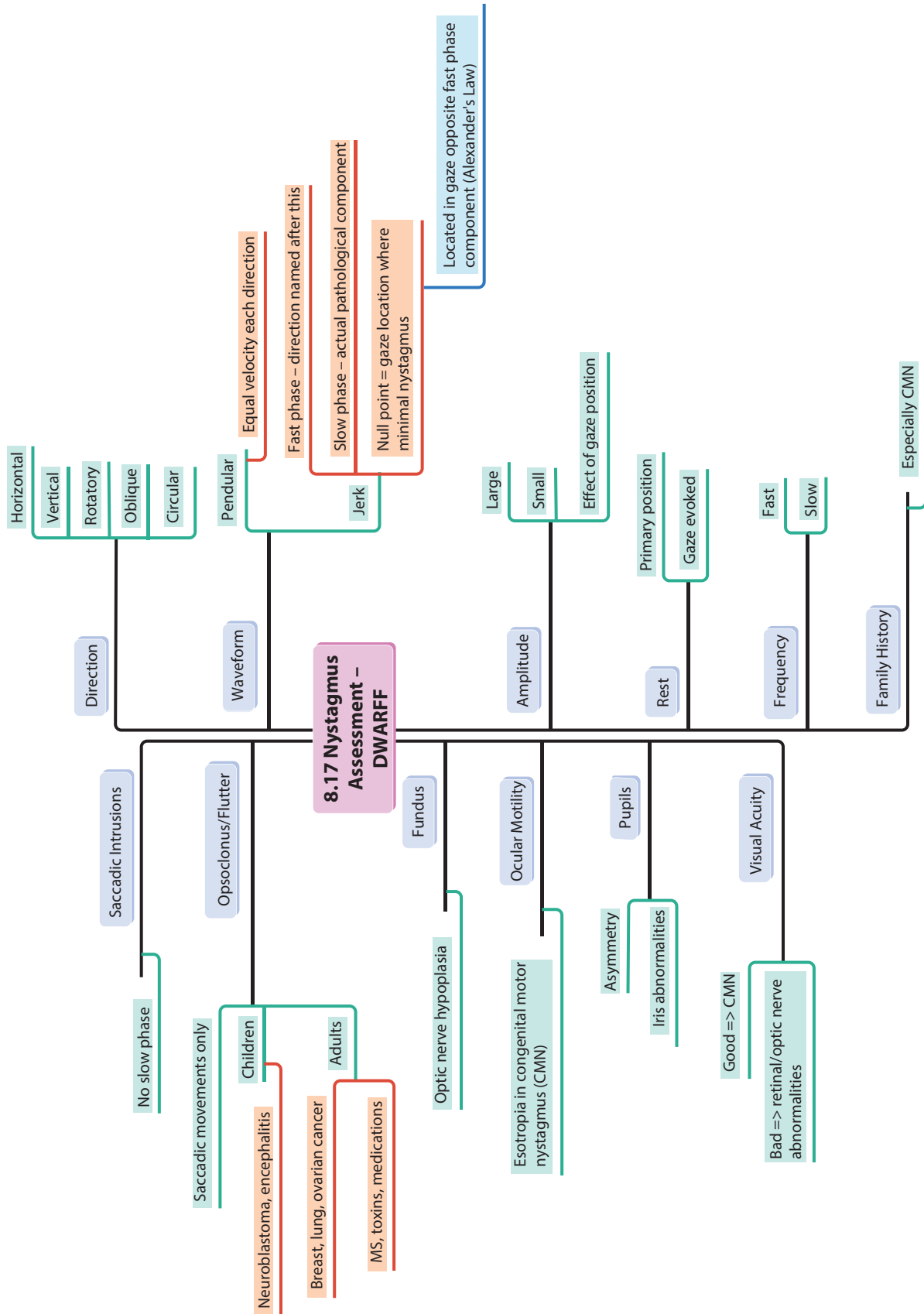


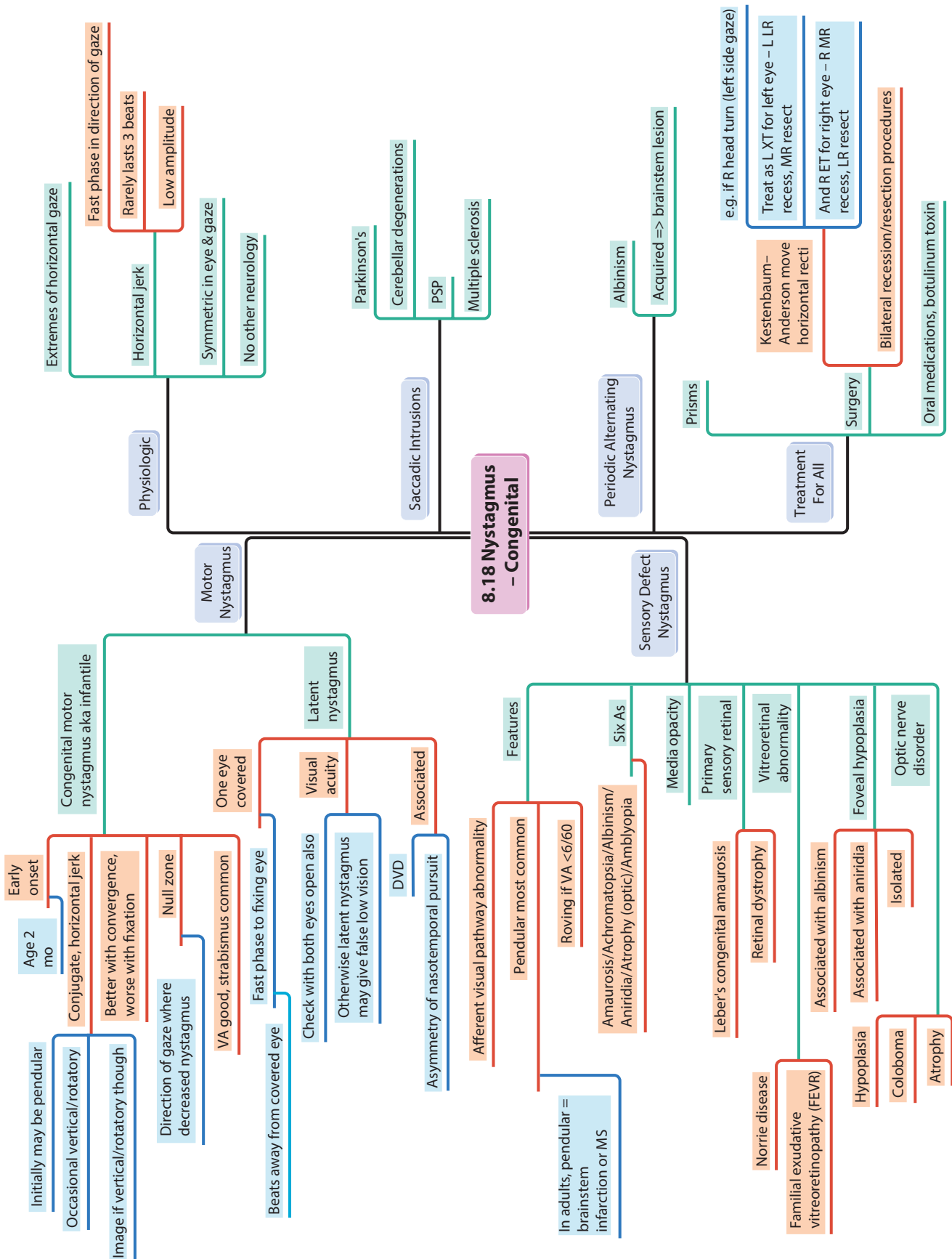


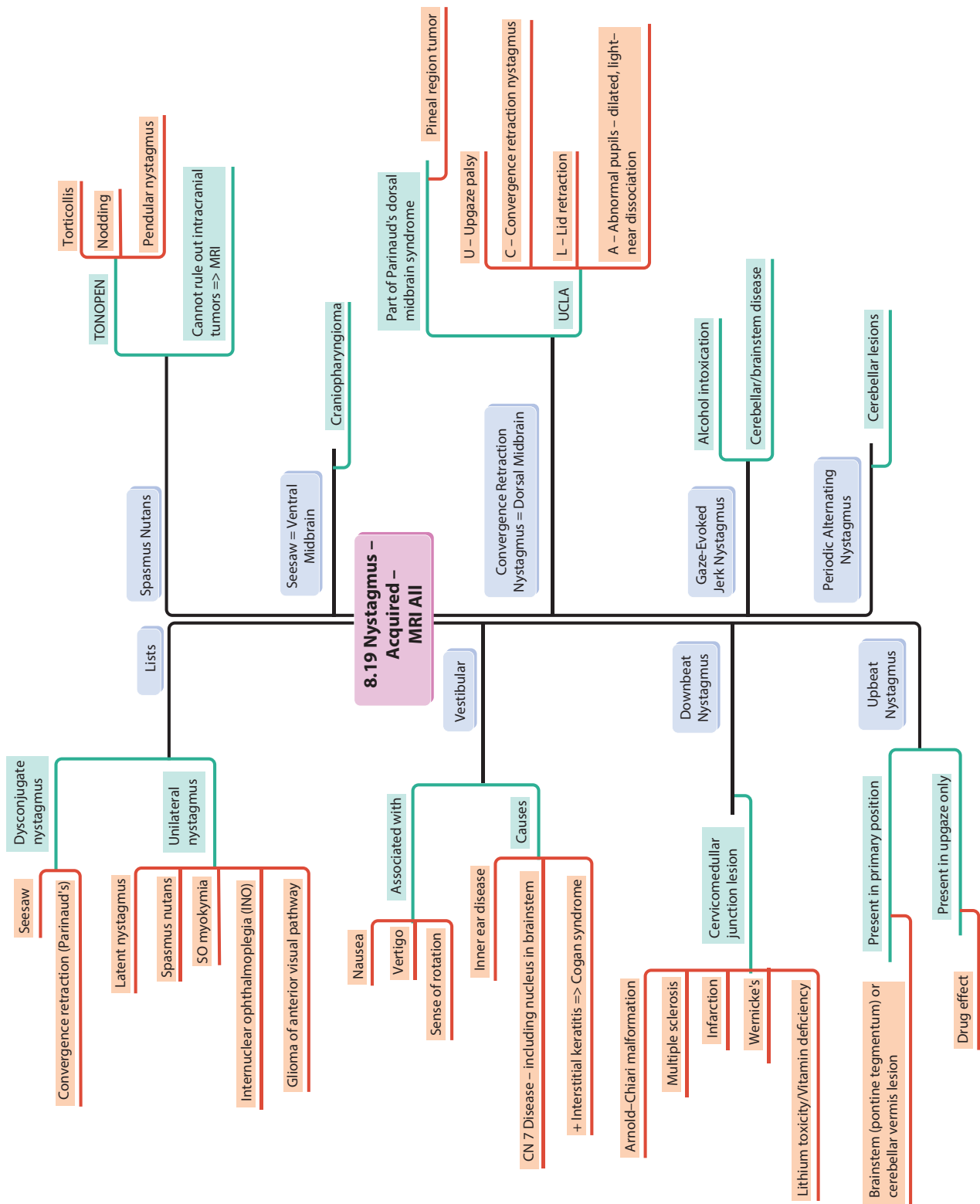


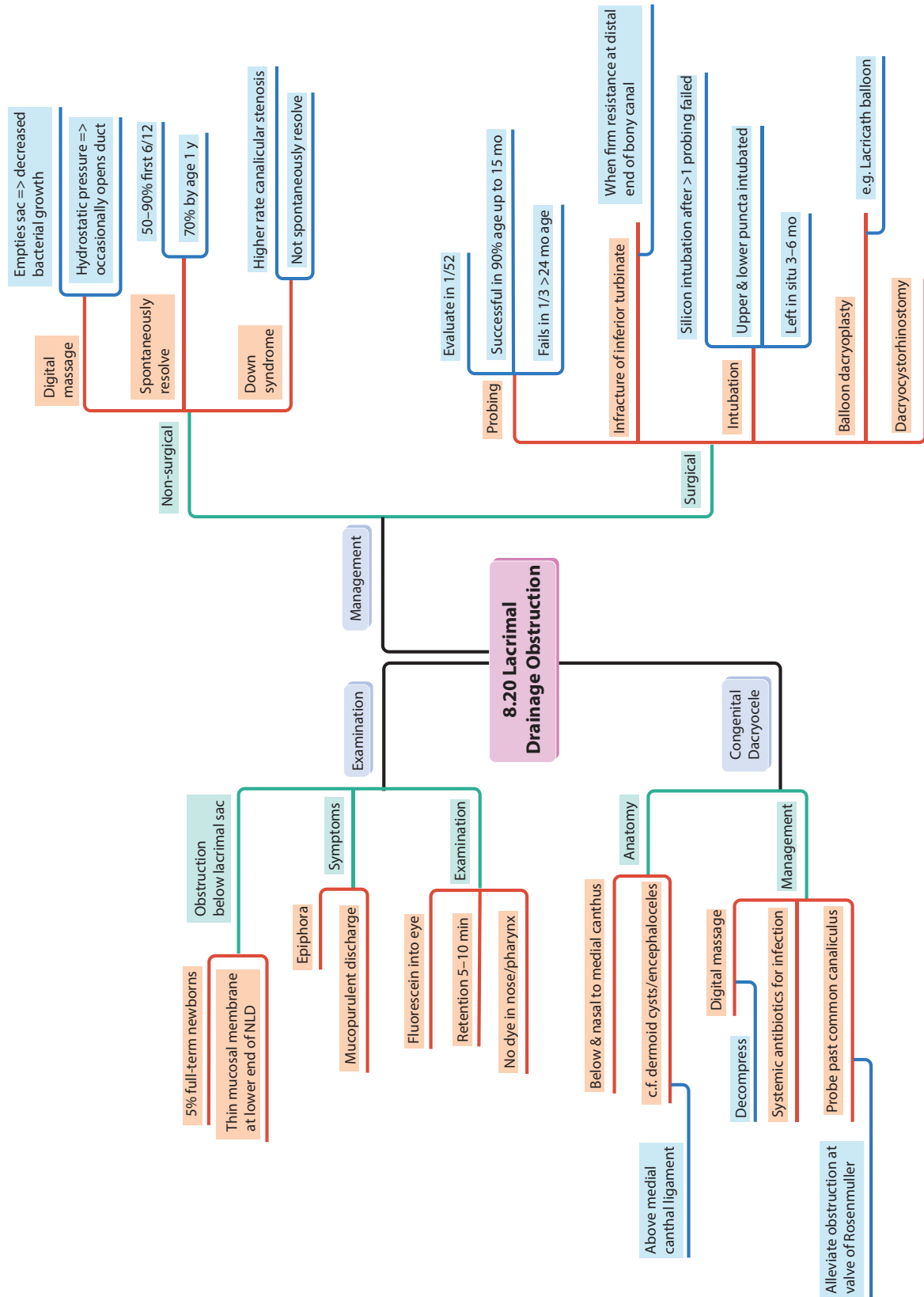


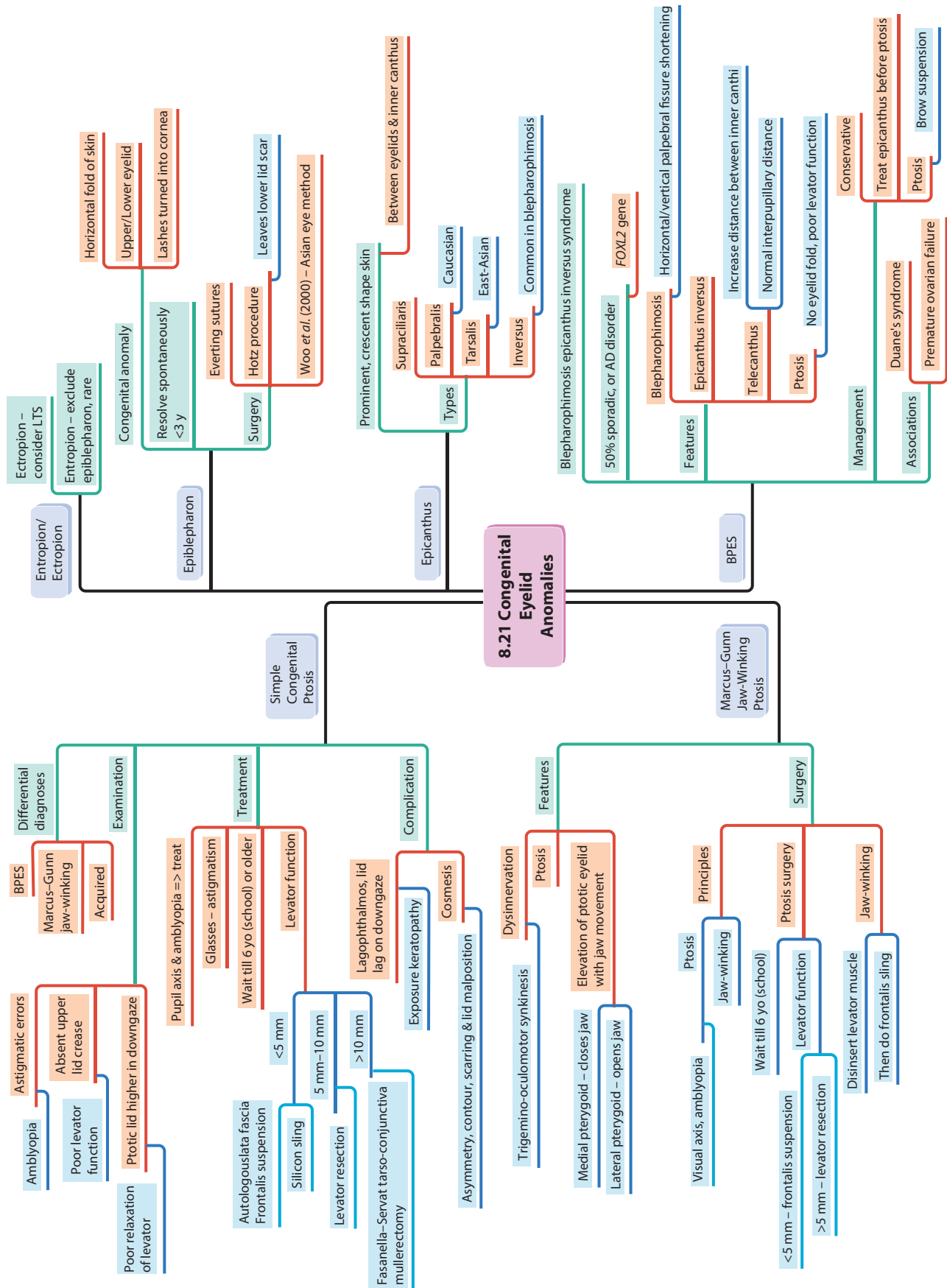


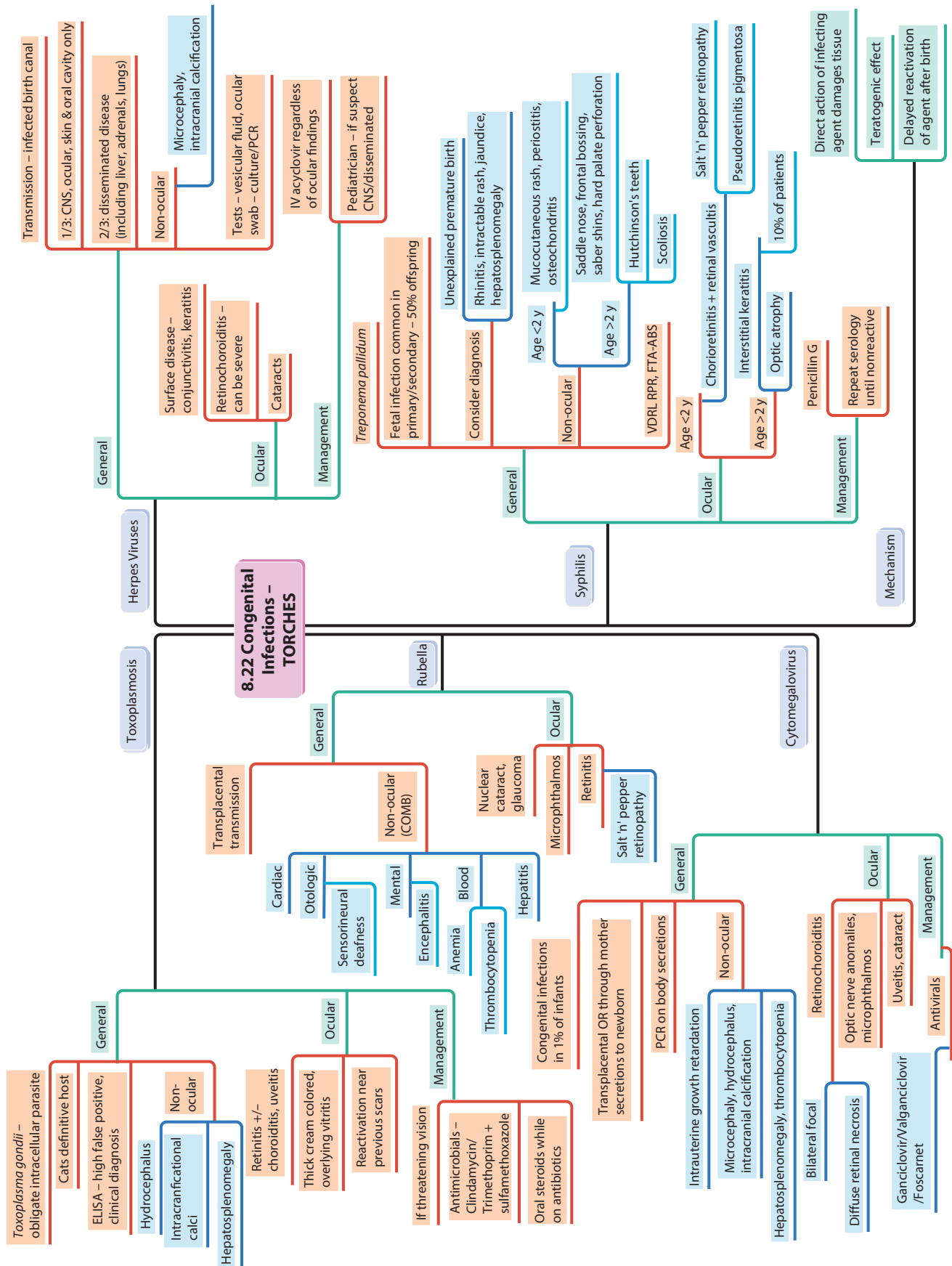


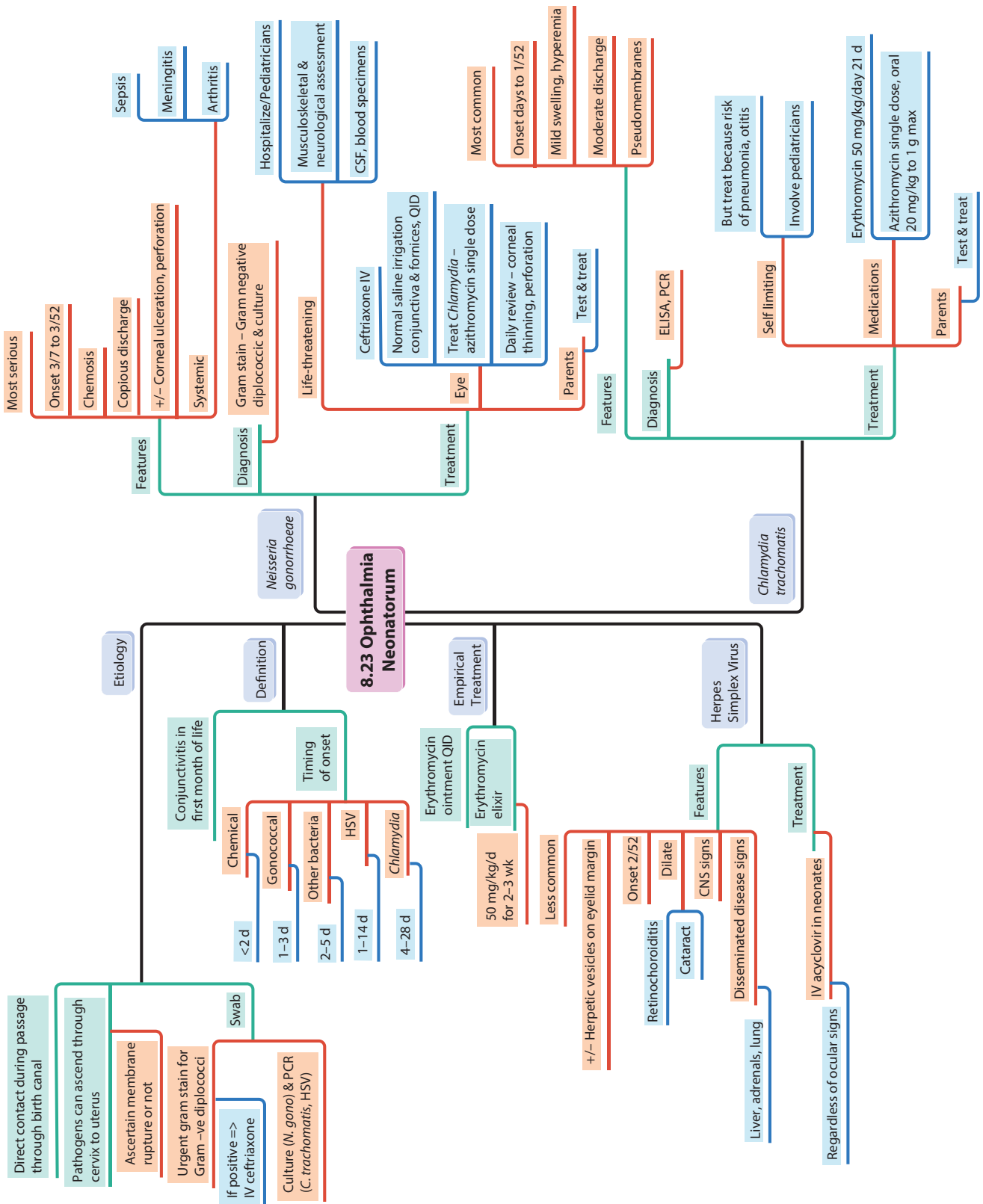


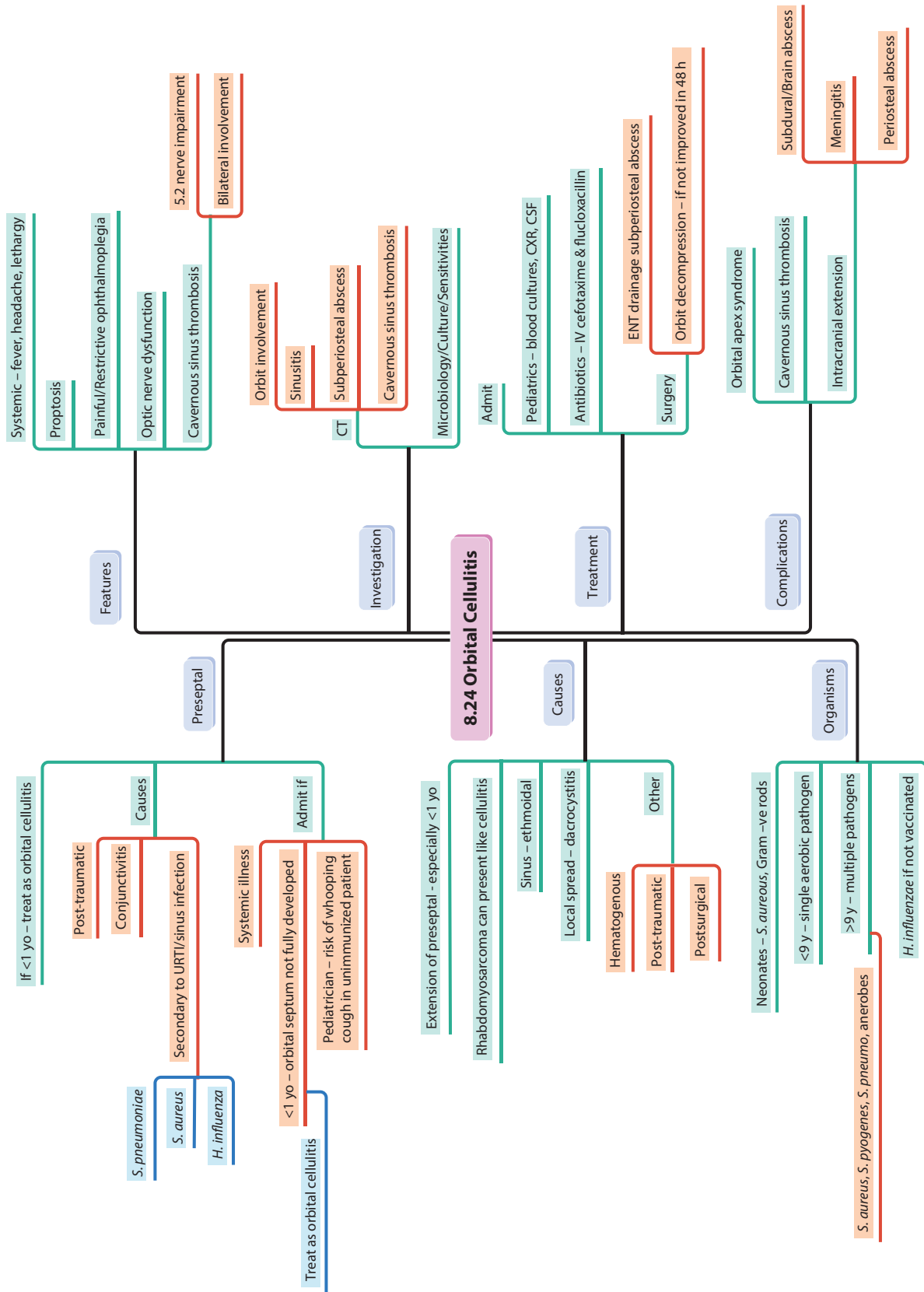


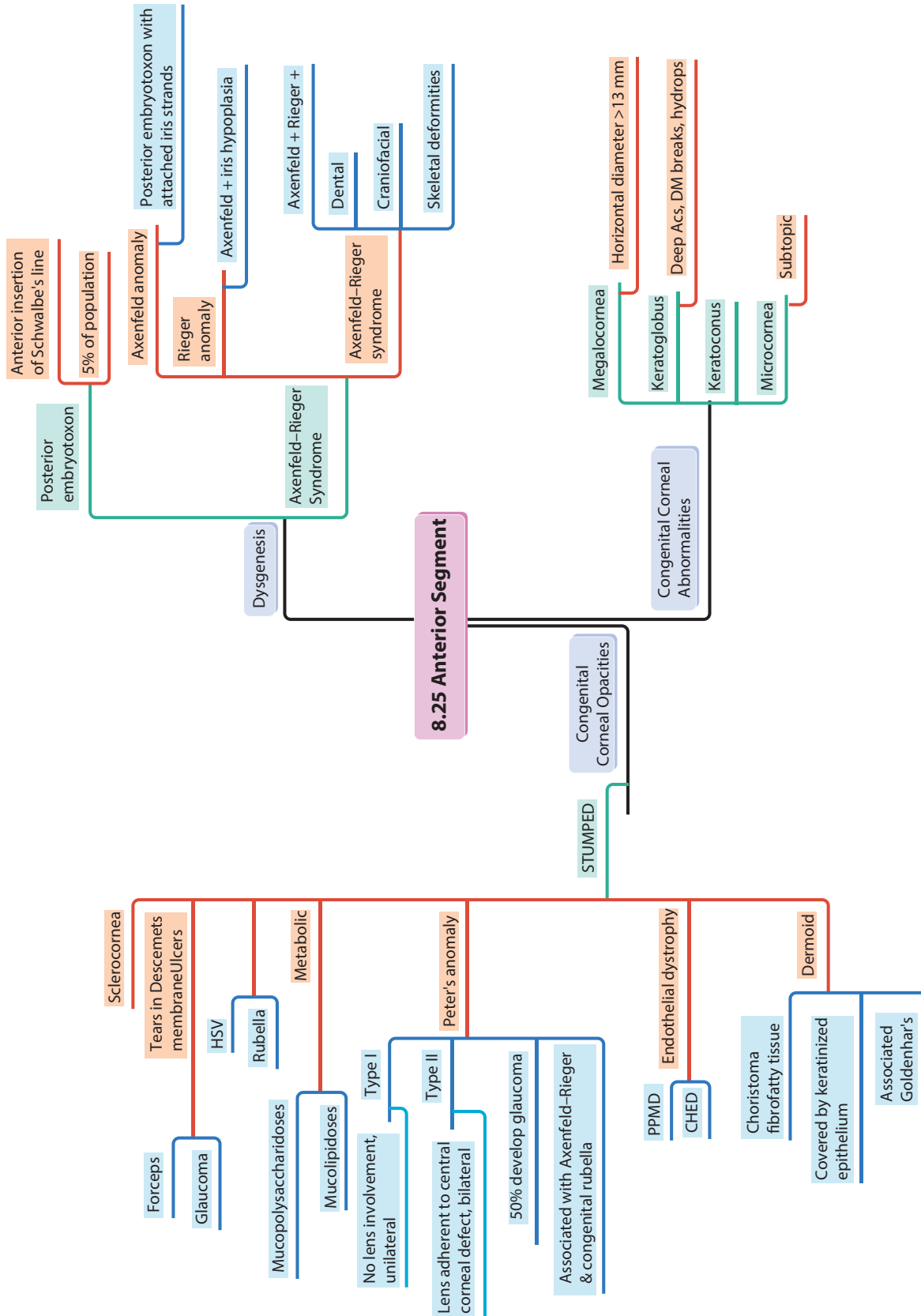


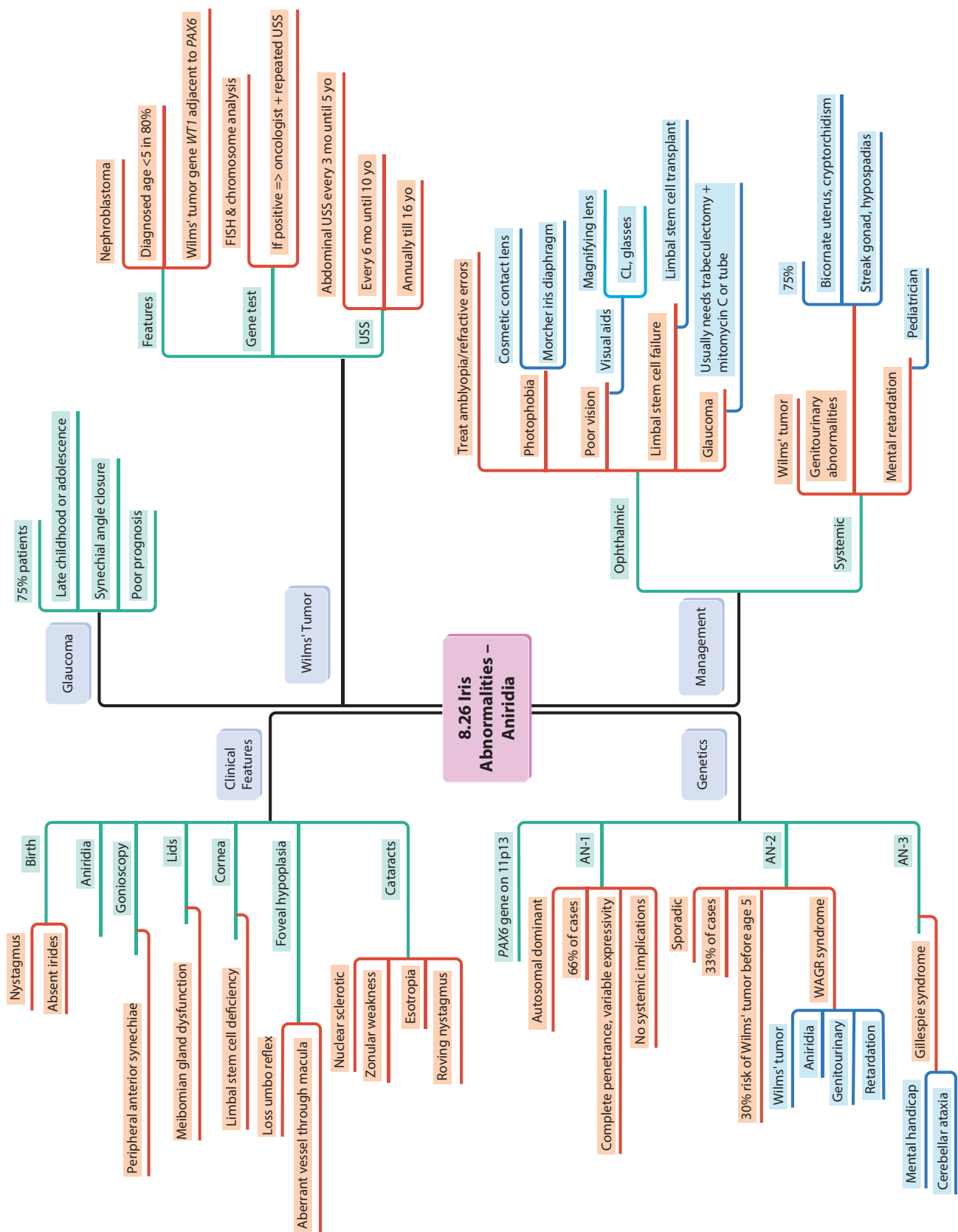


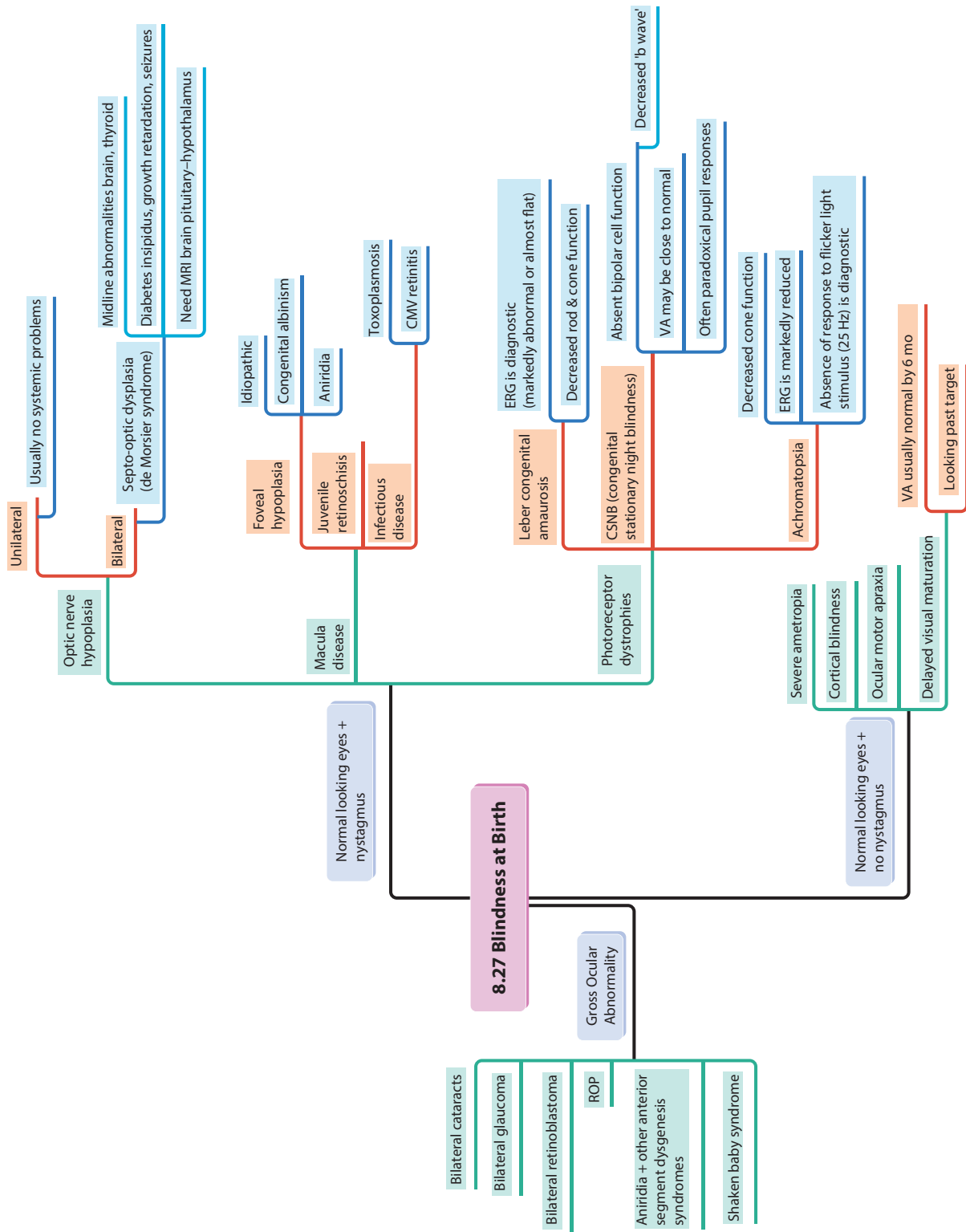


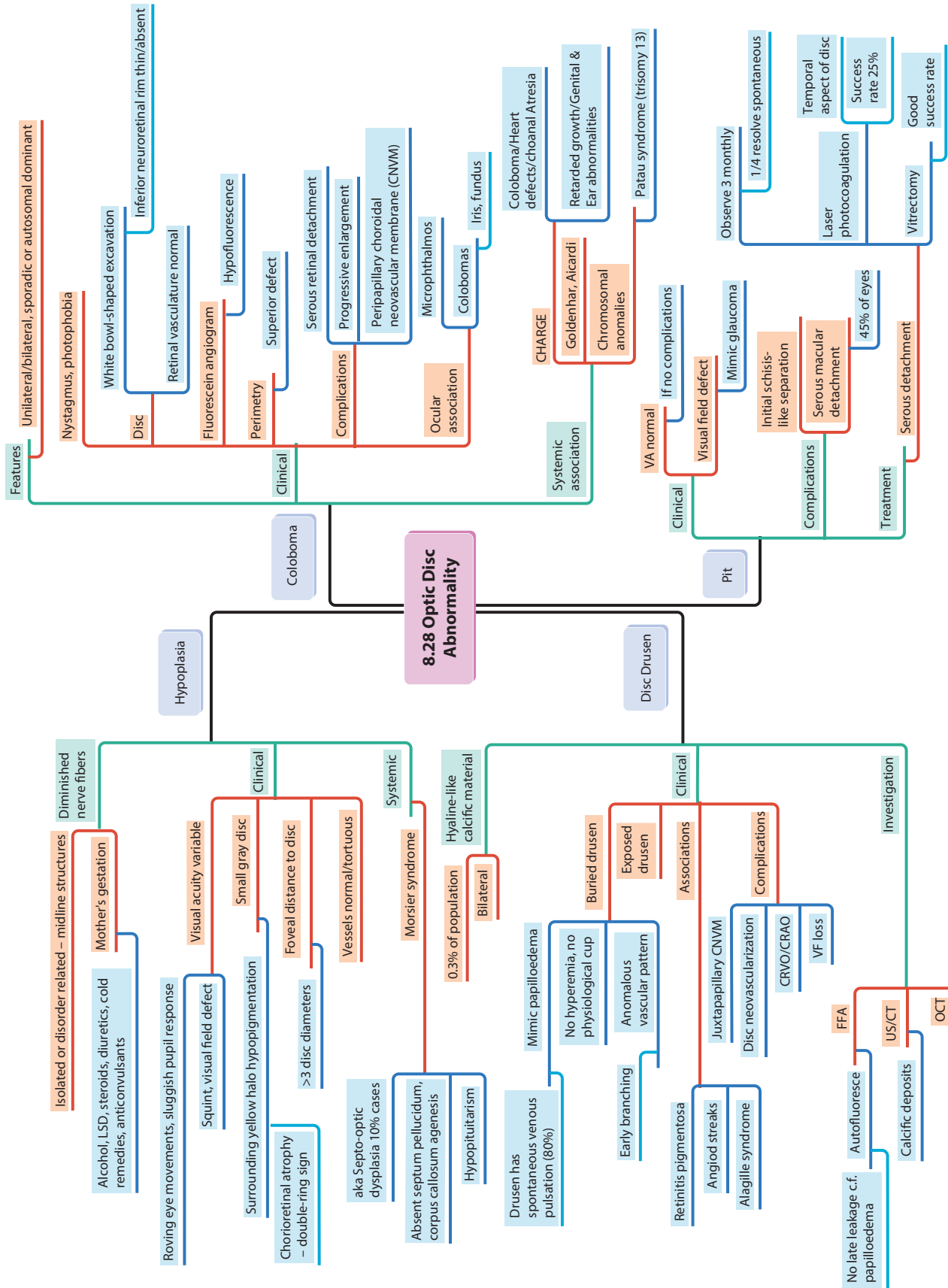


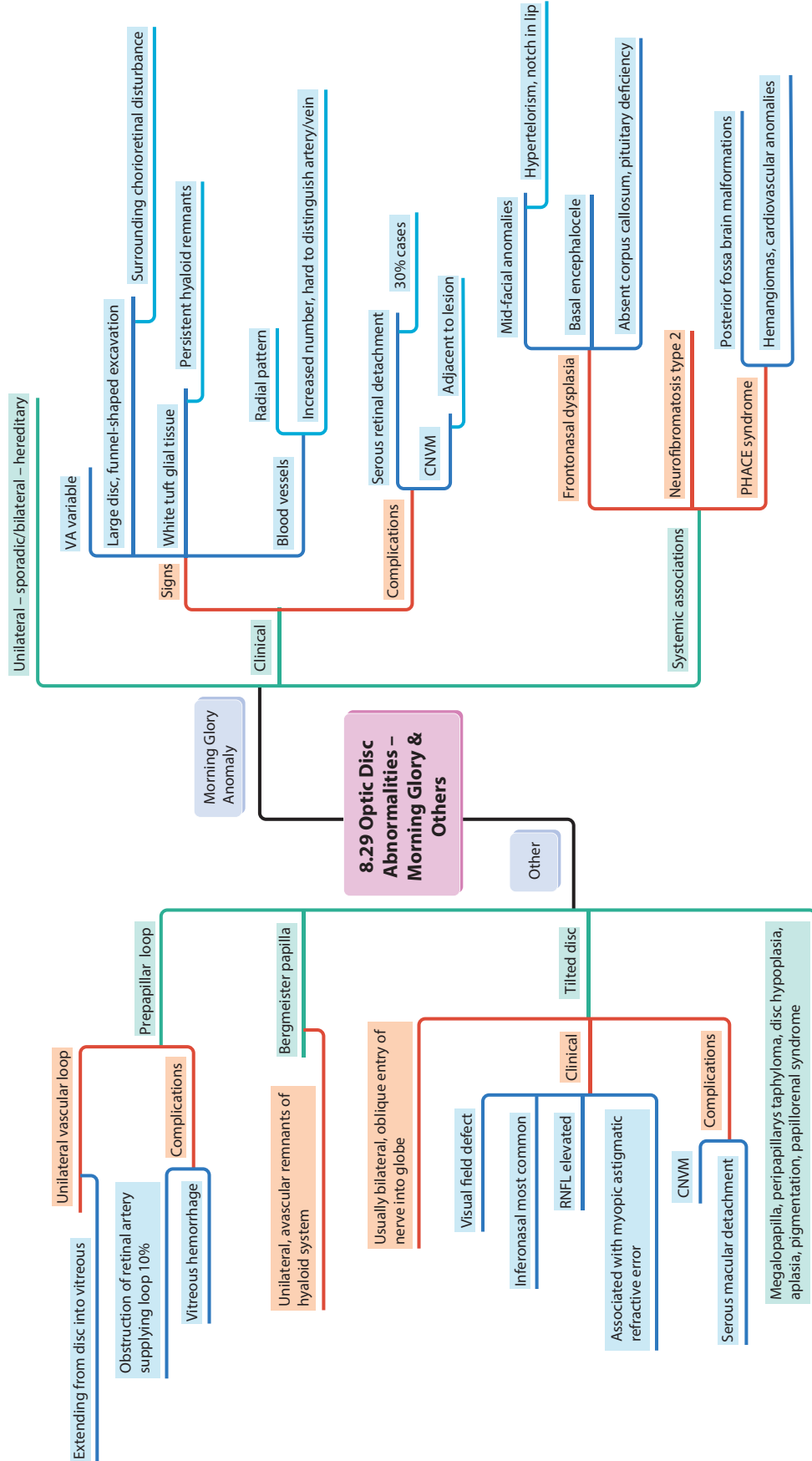


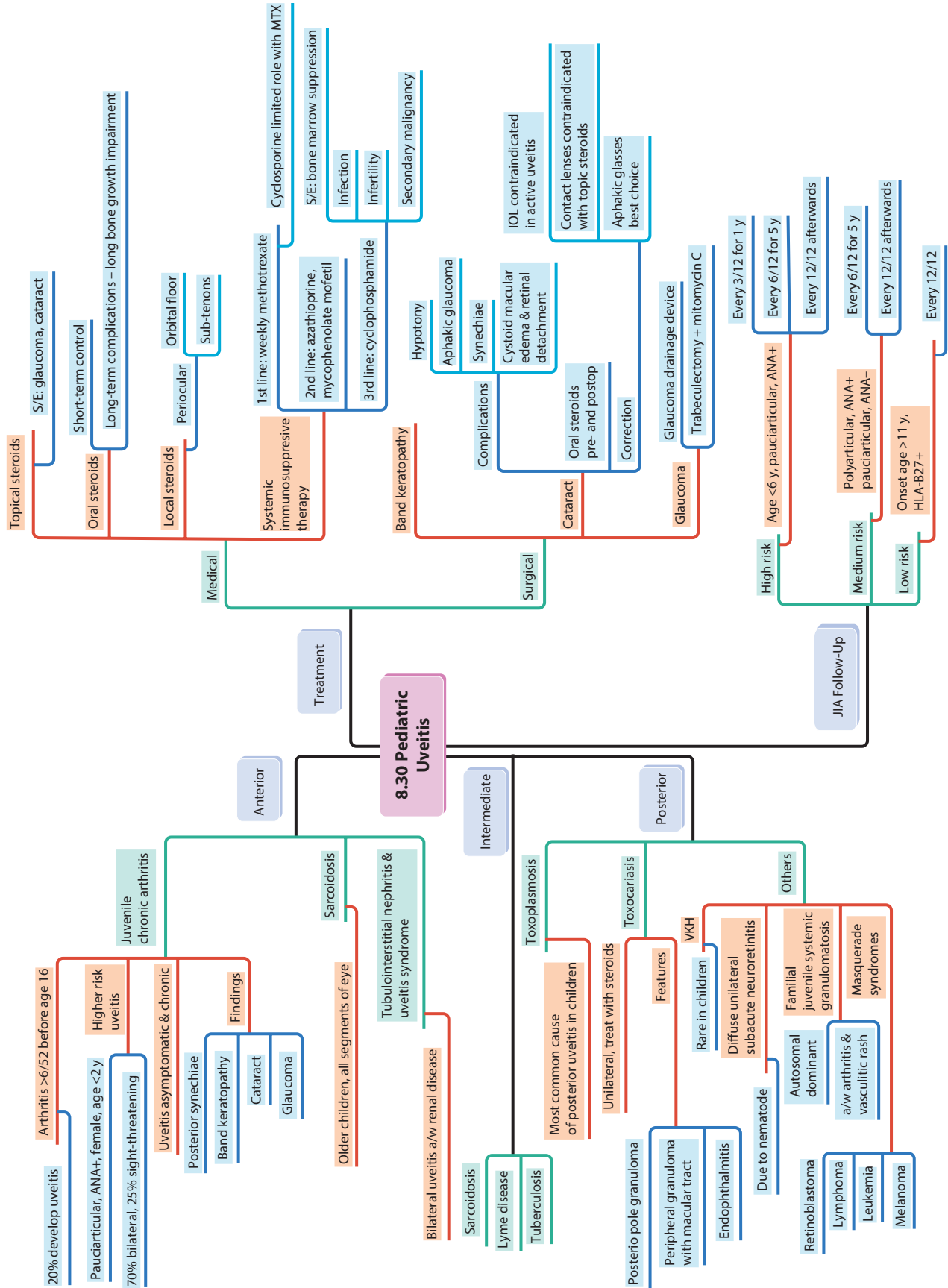


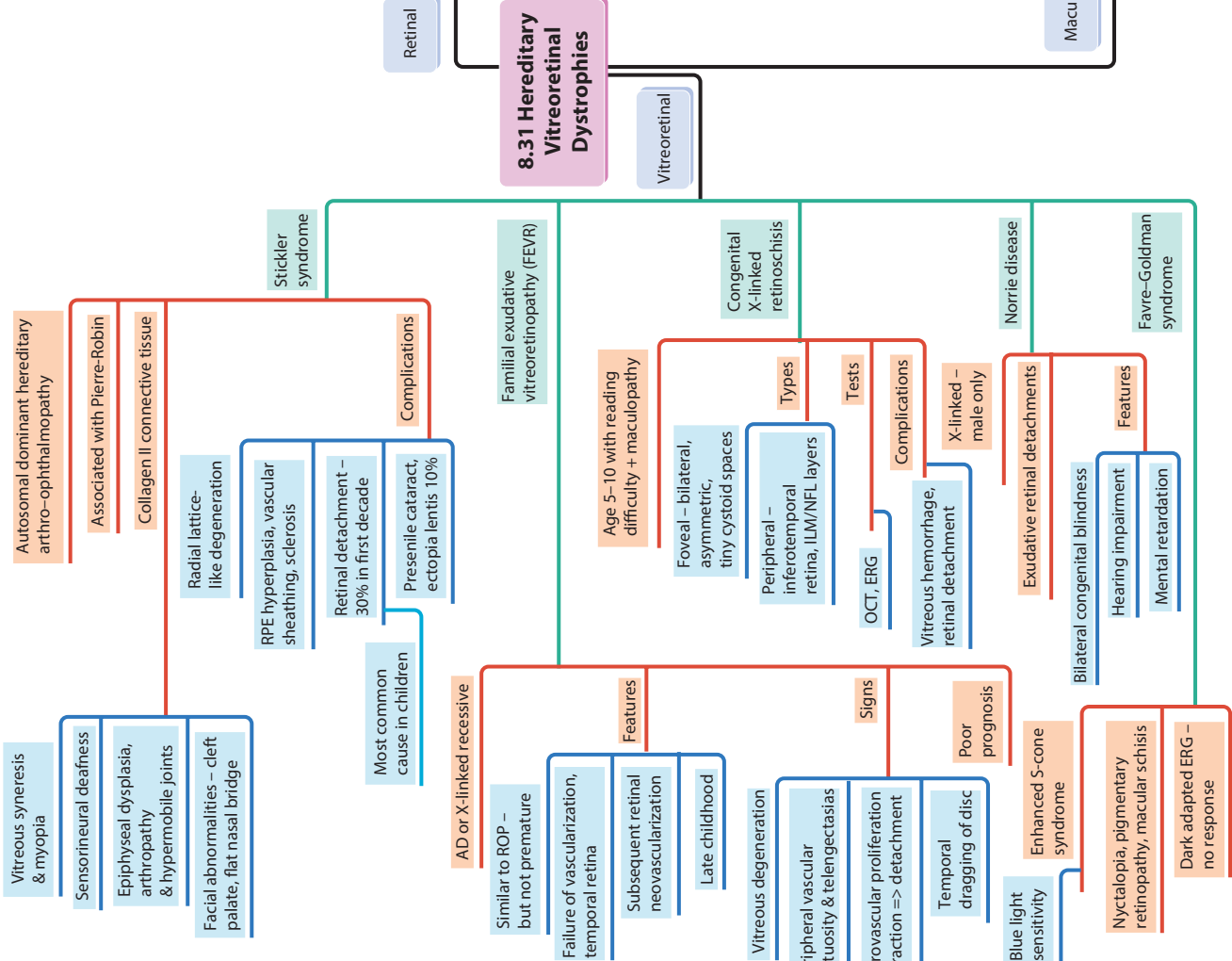
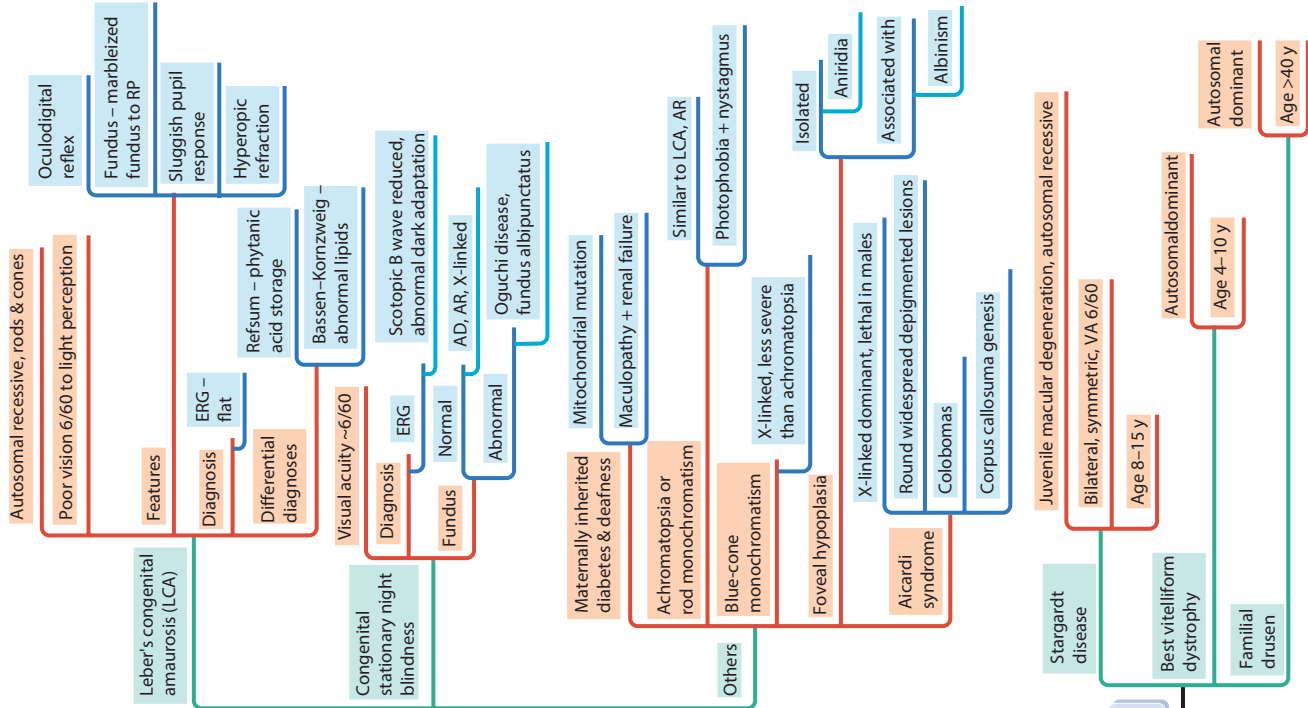


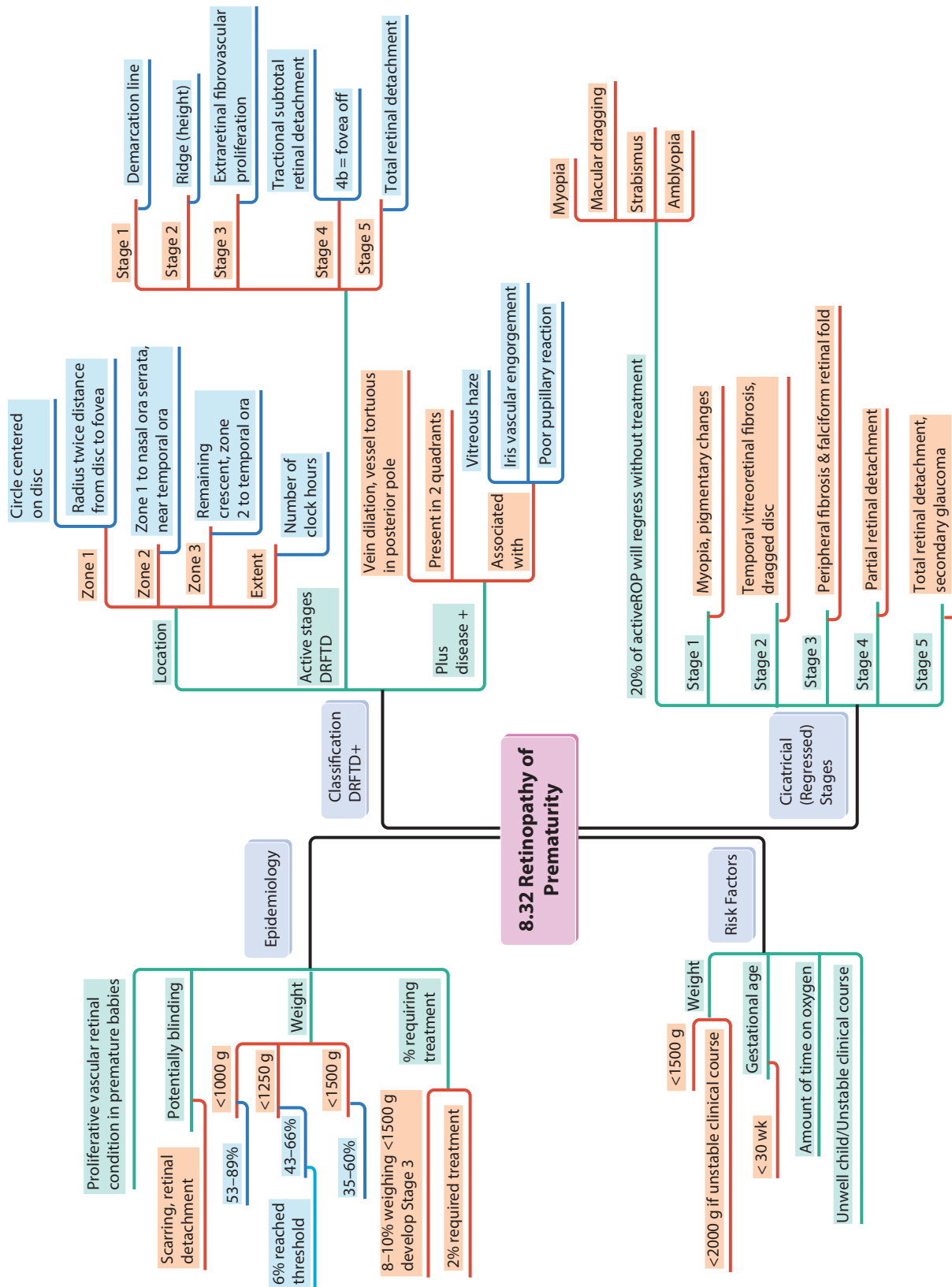


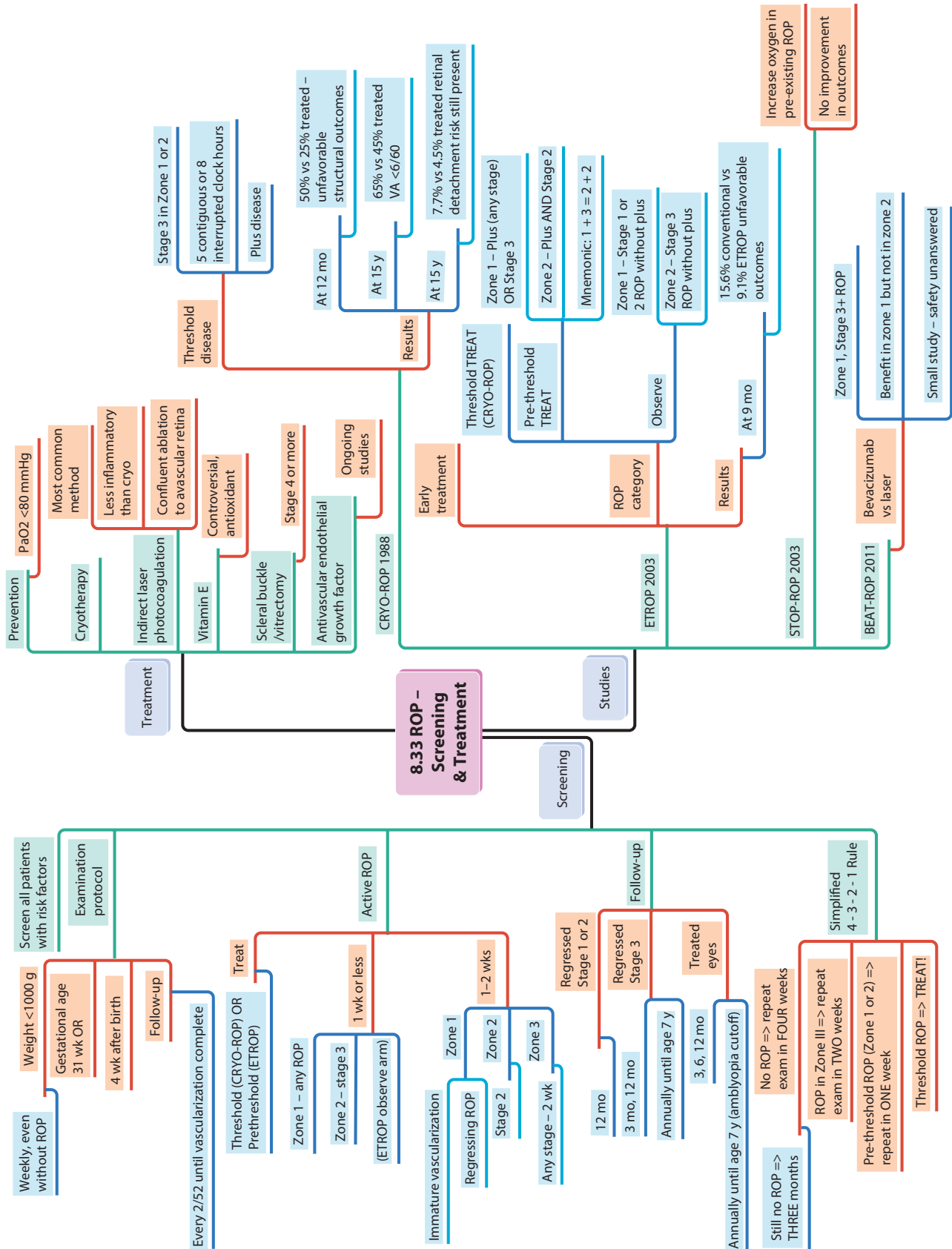


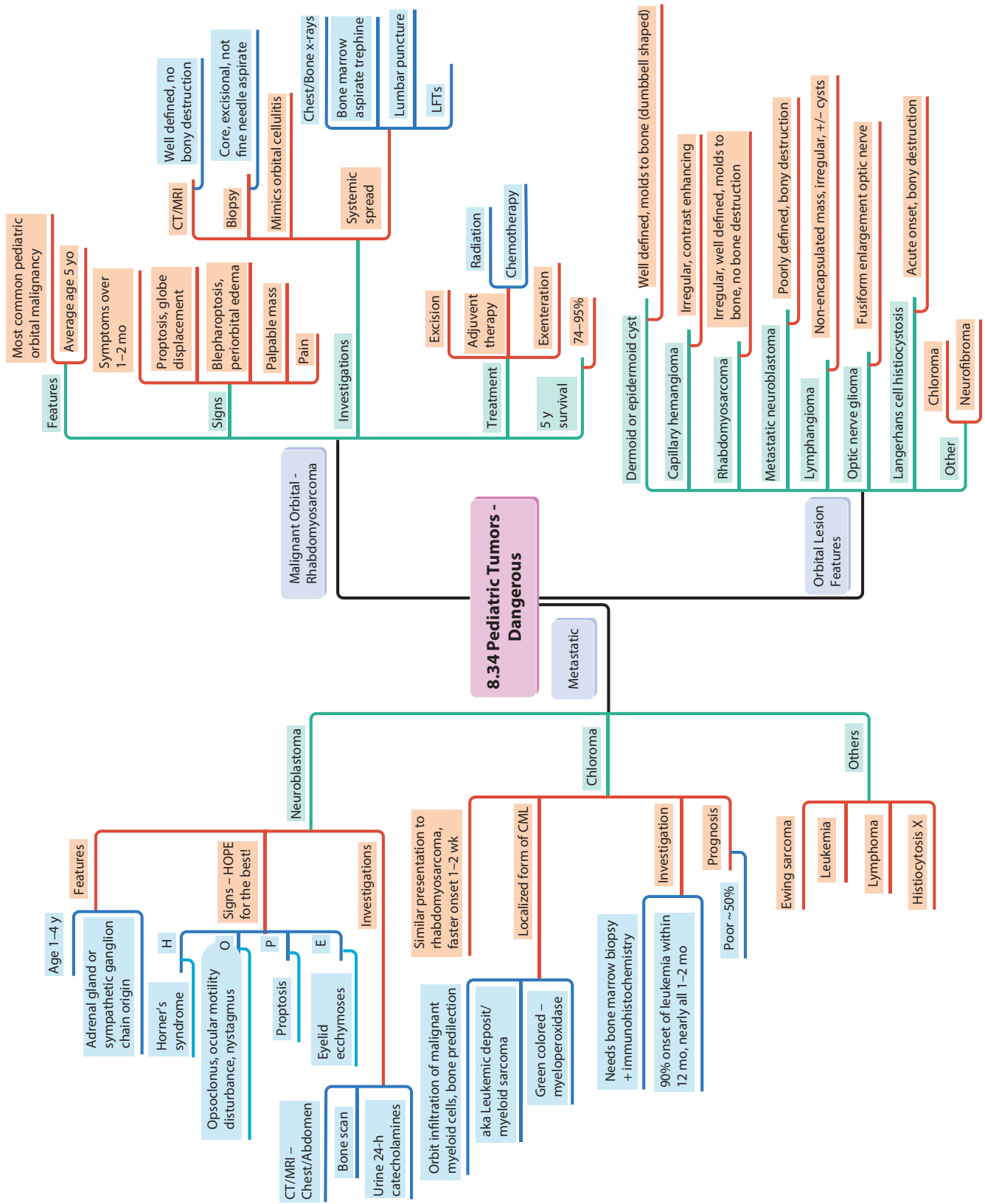


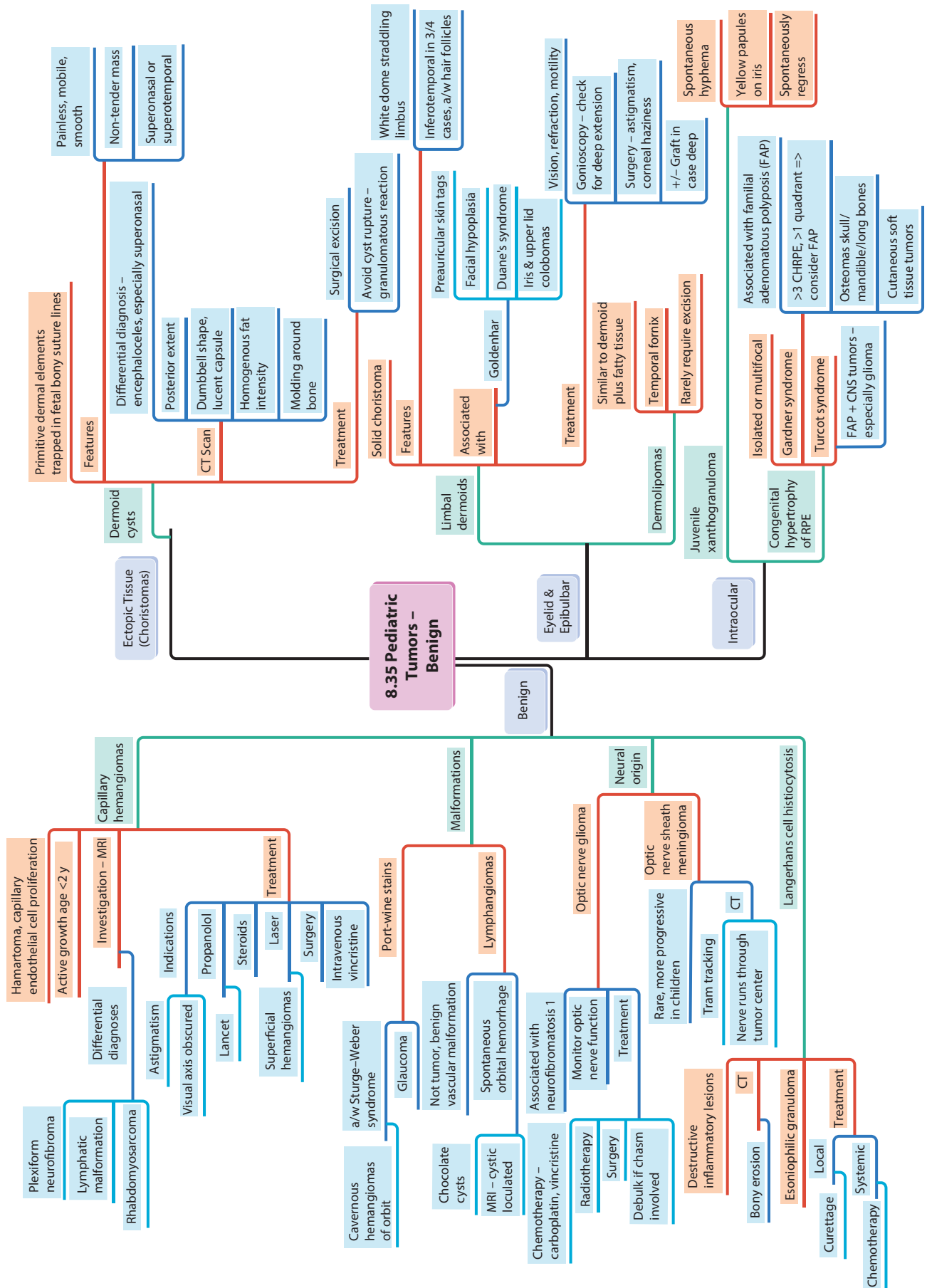


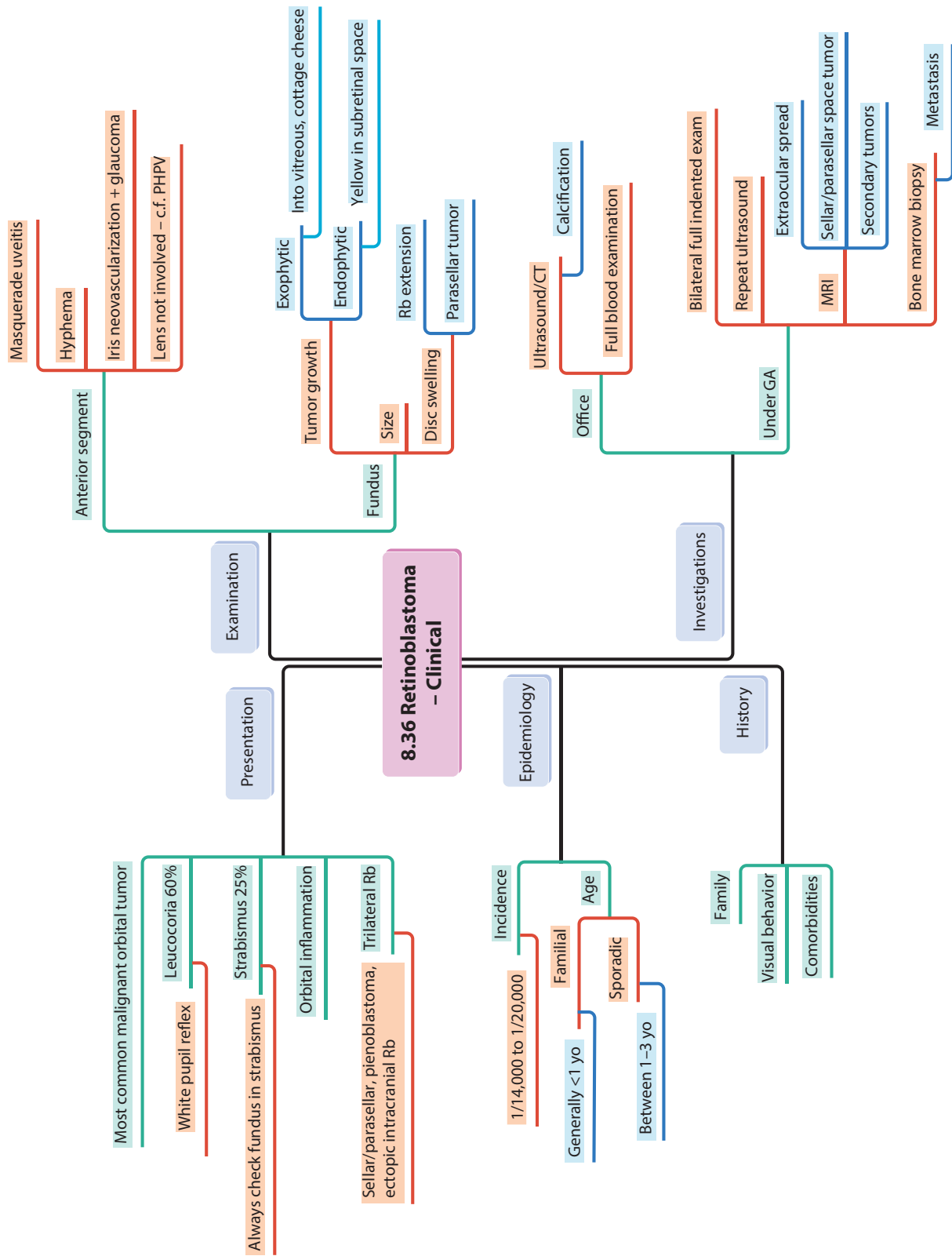


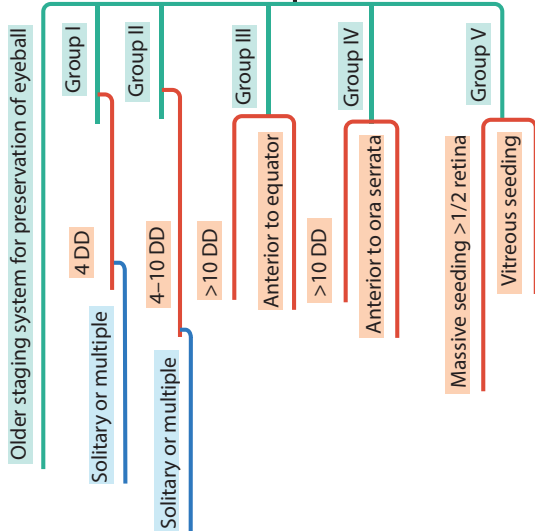
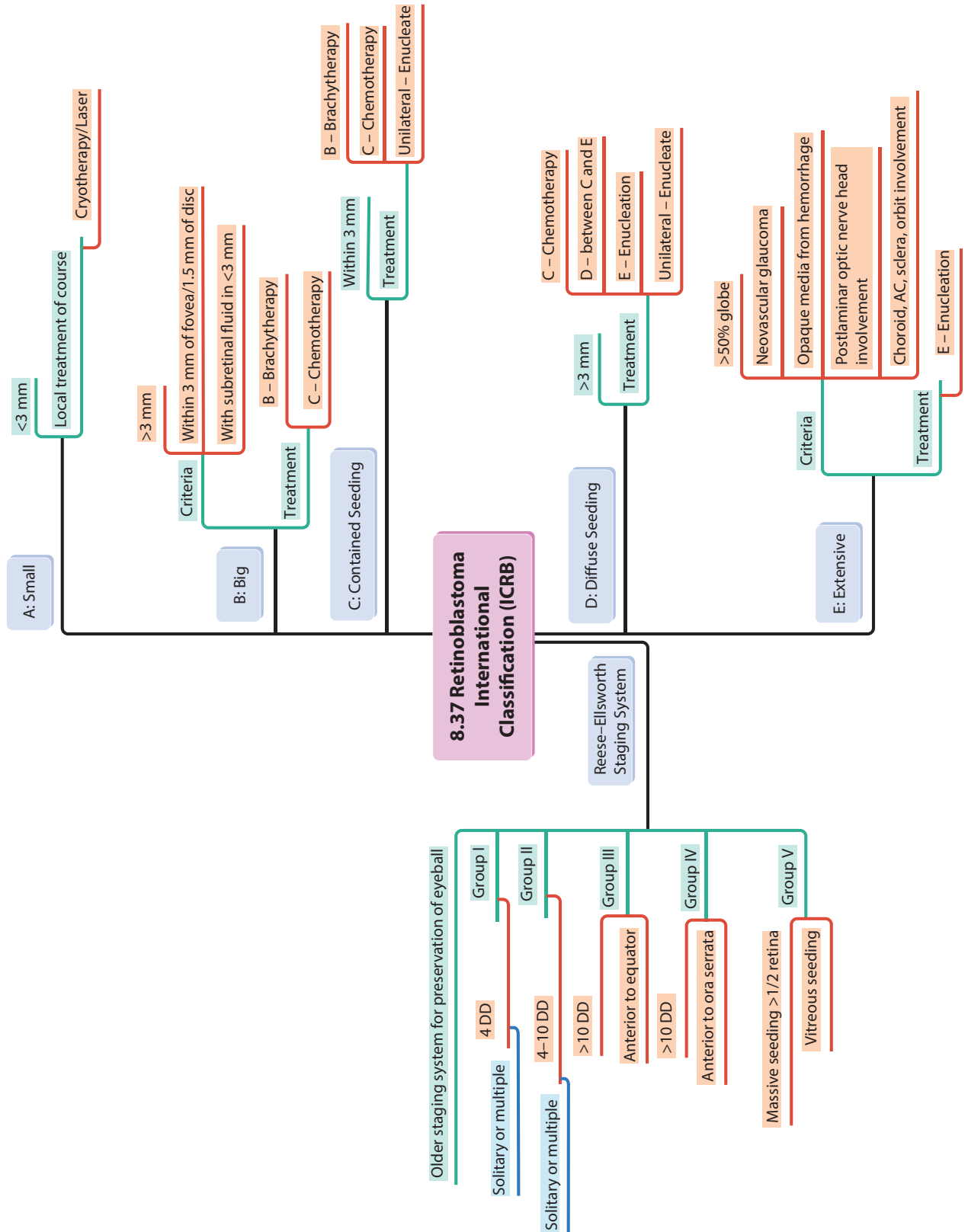




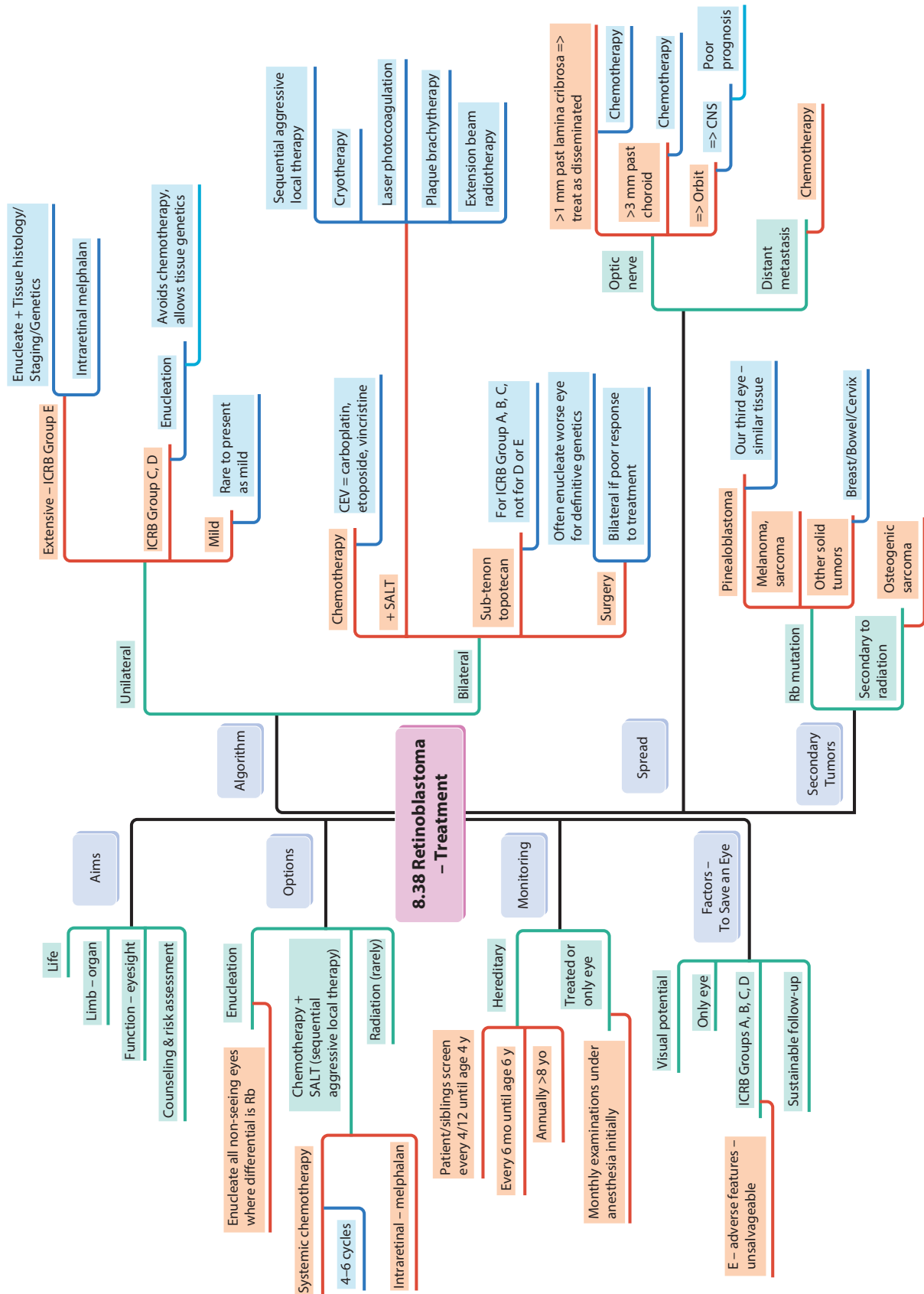


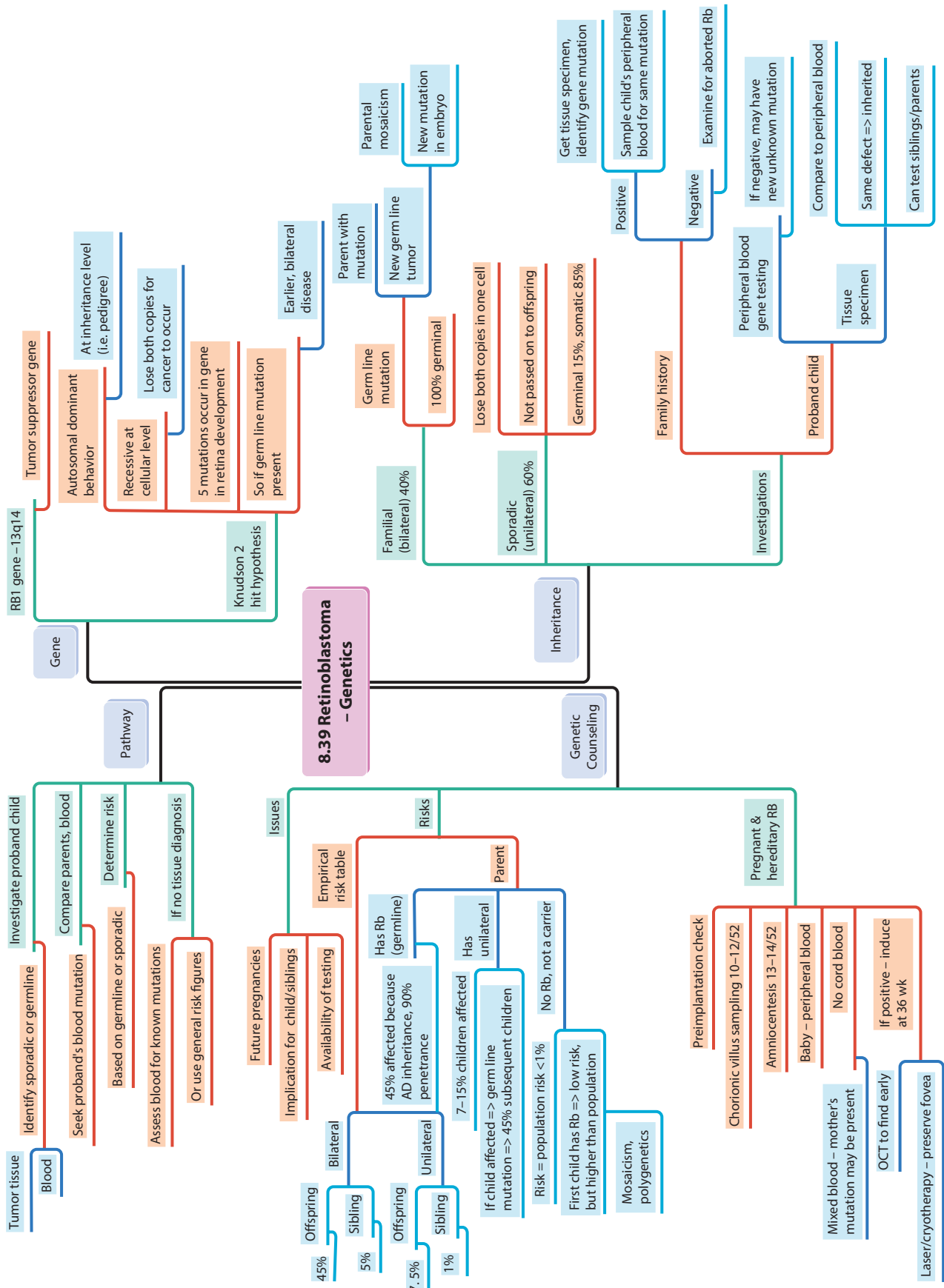


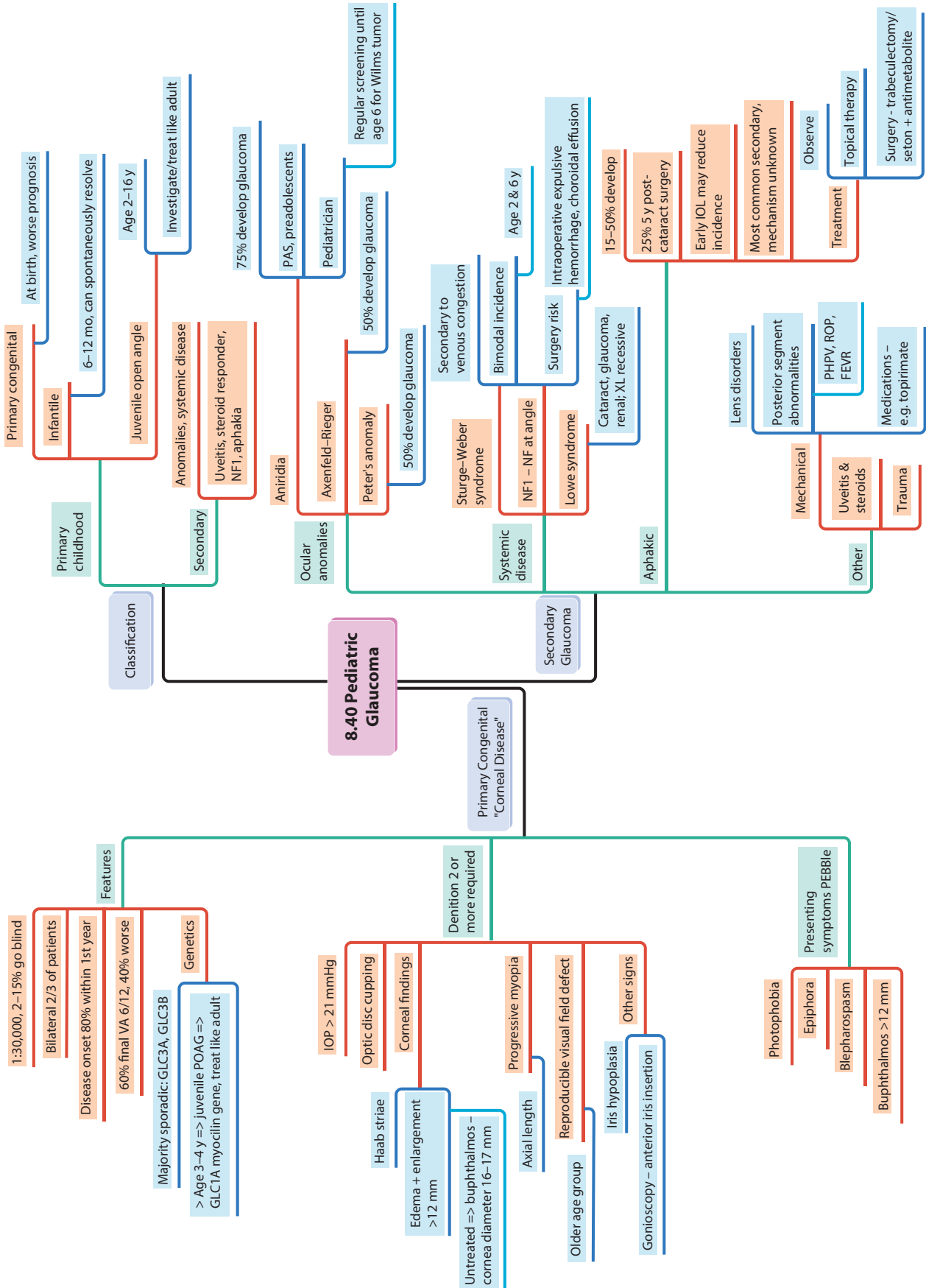


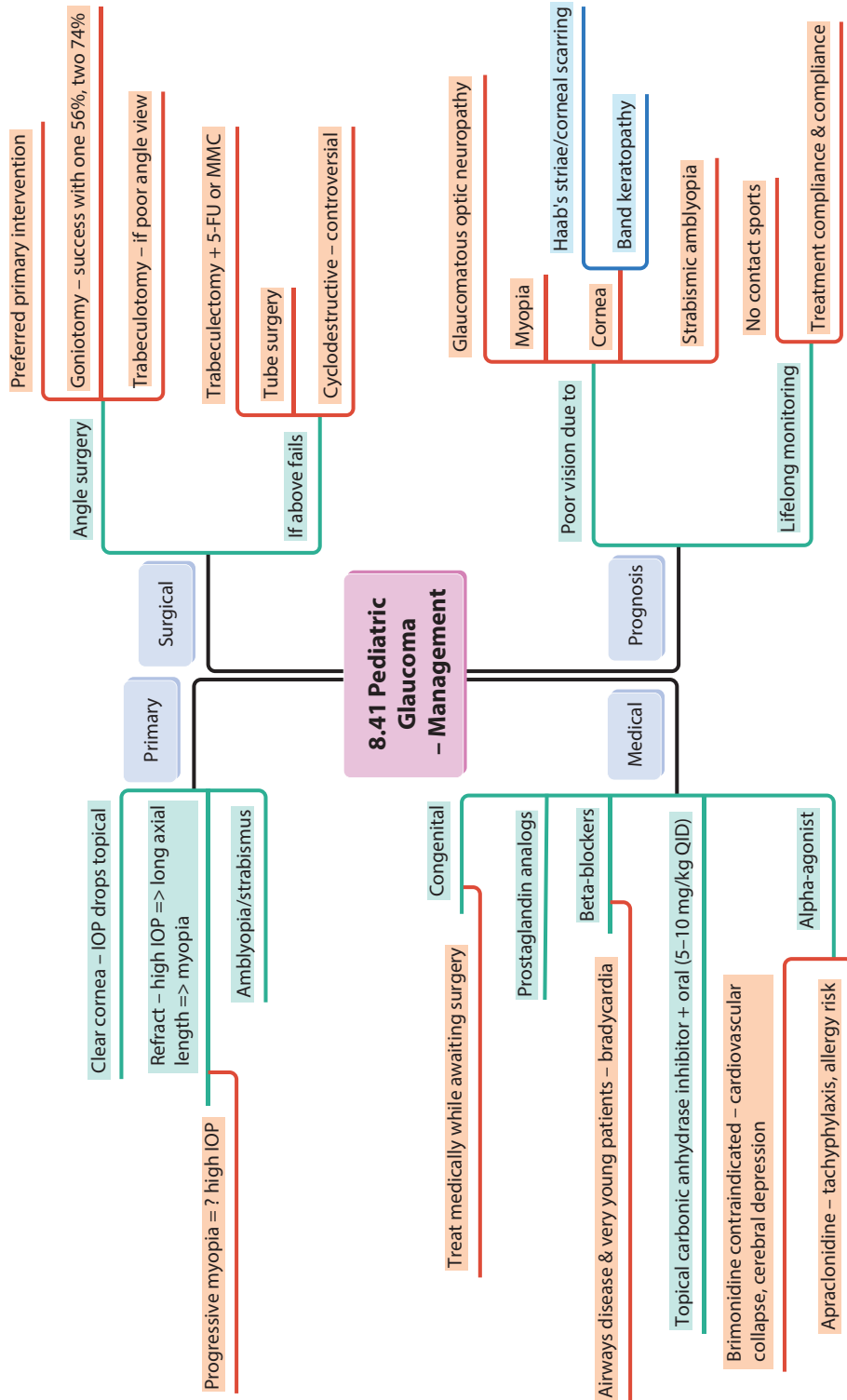


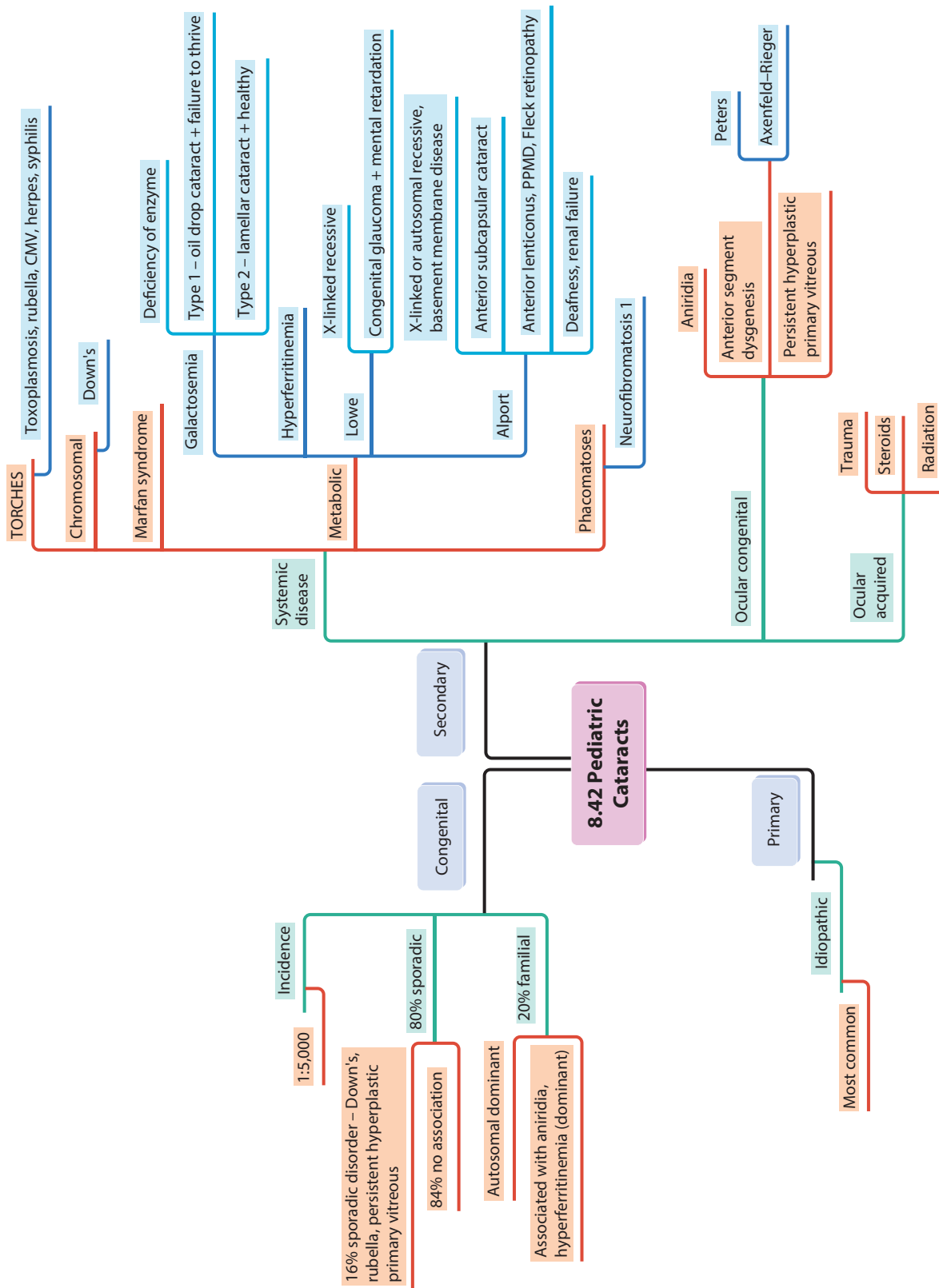
Reese-Ellsworth Staging System

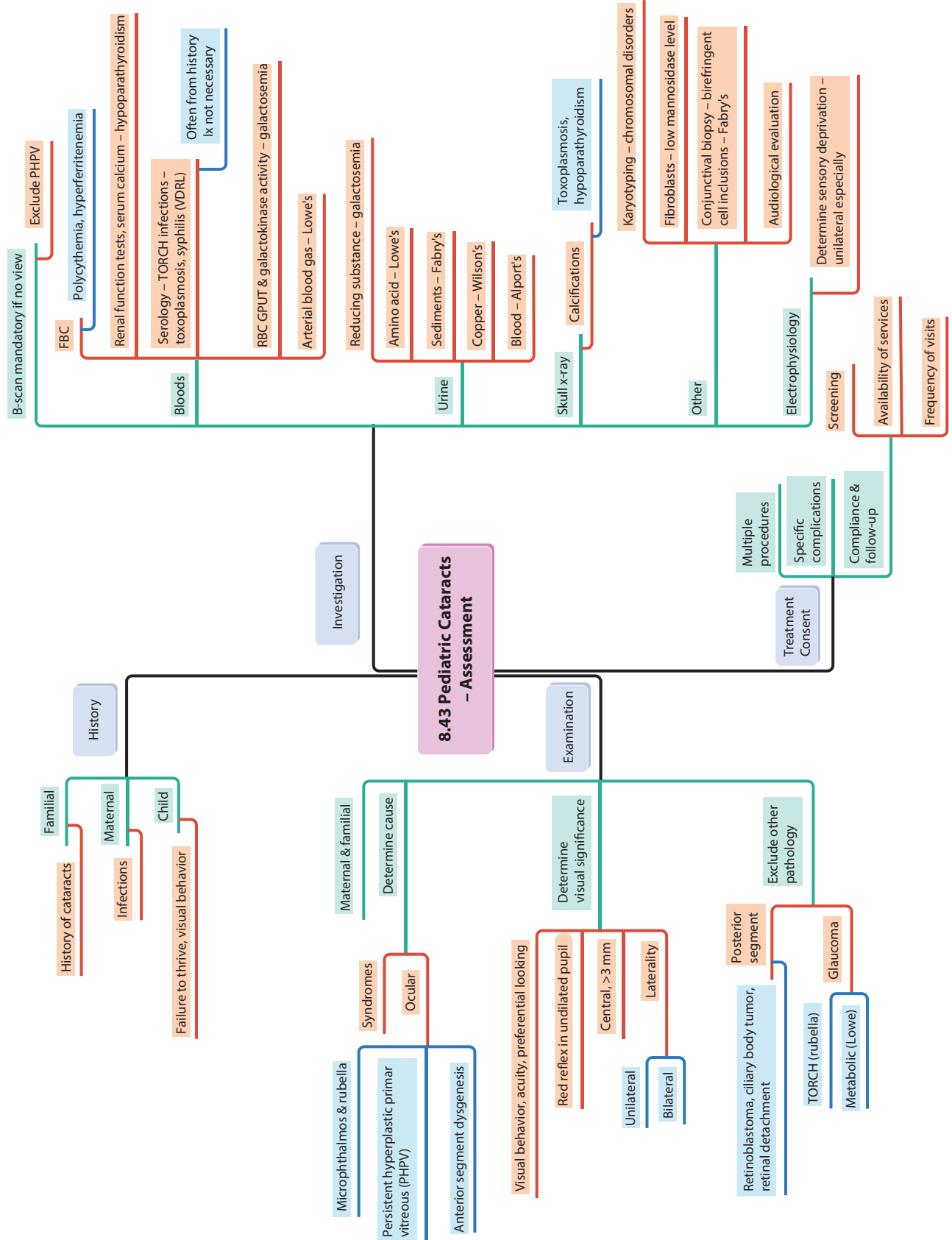


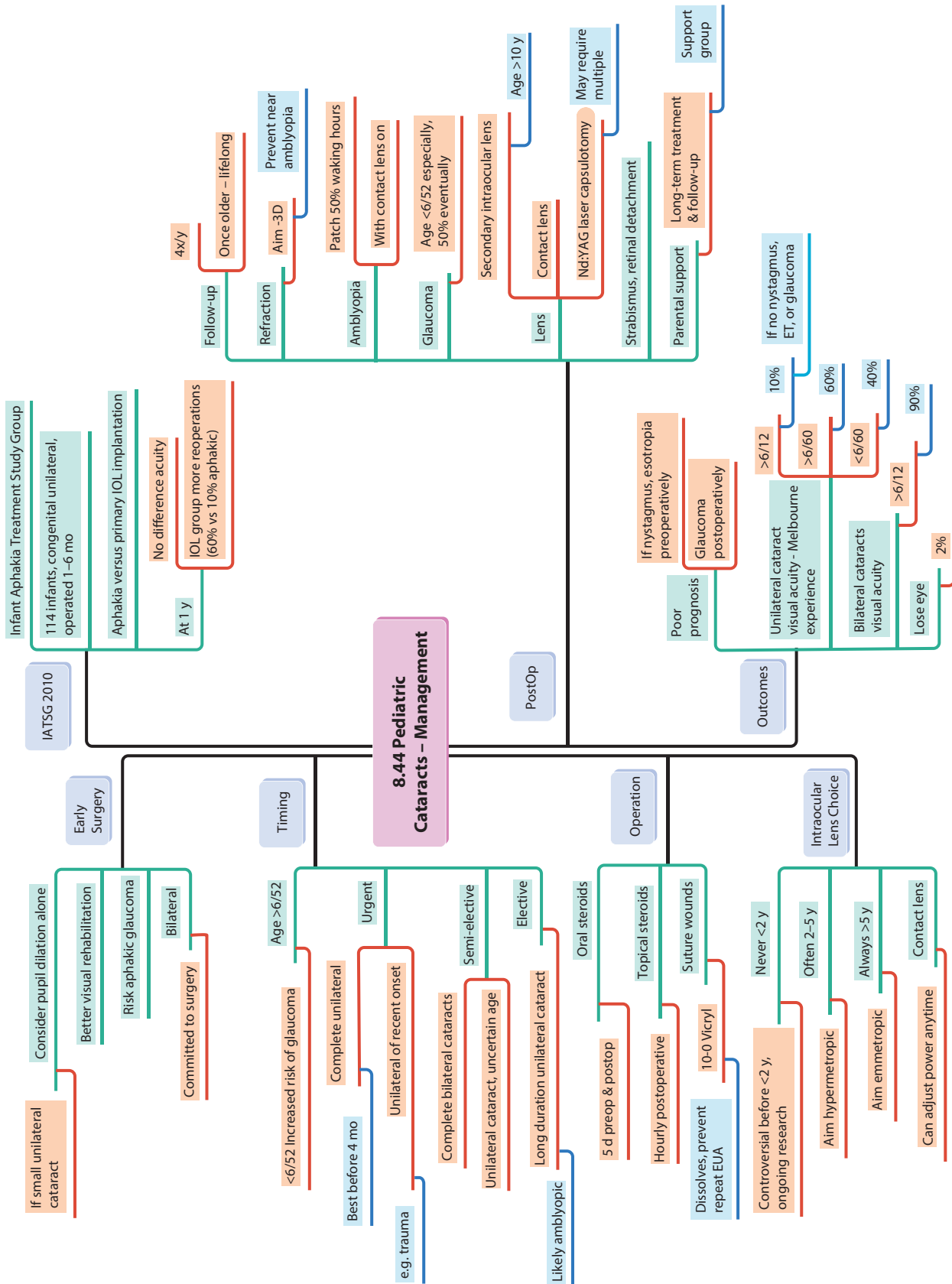


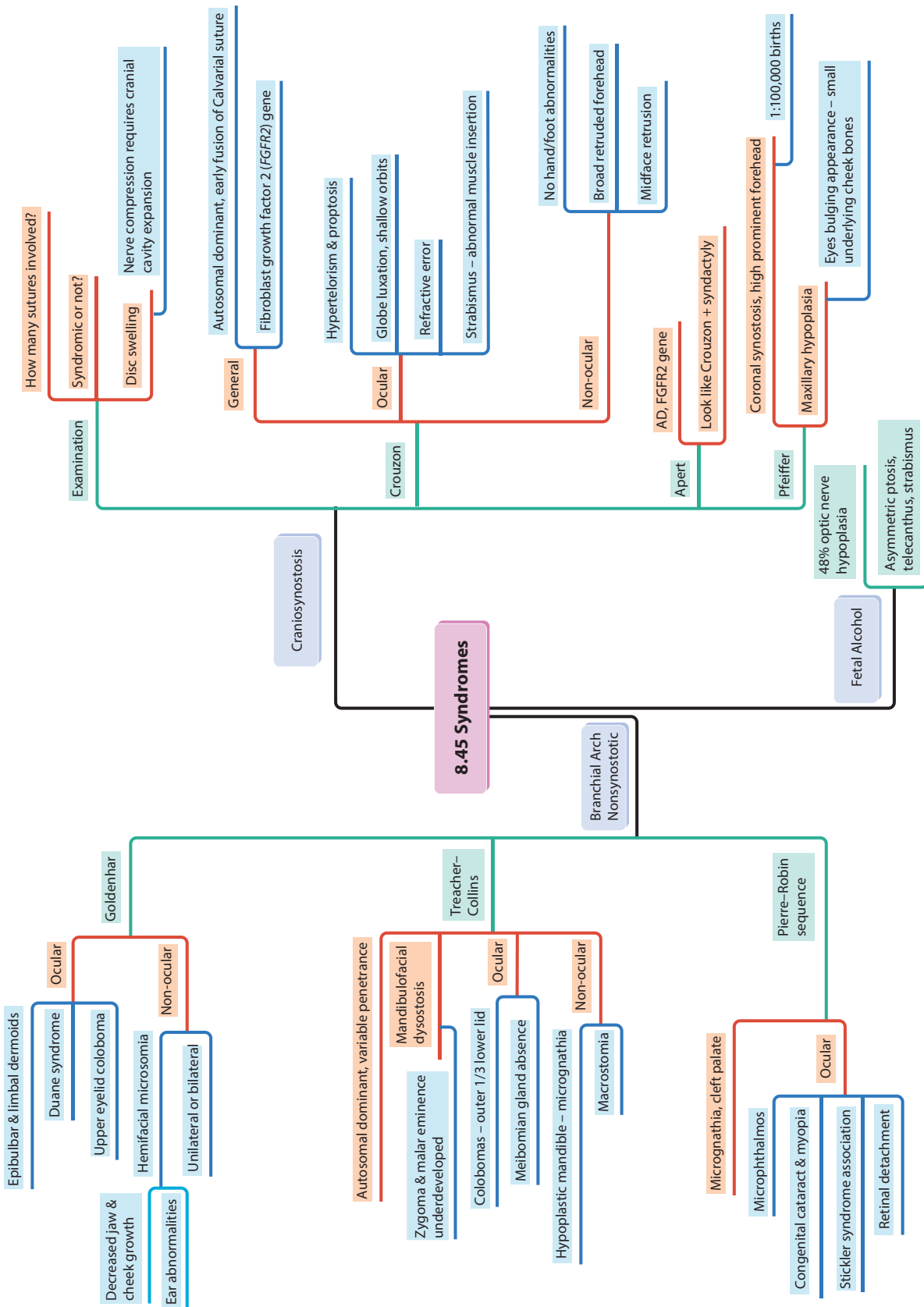


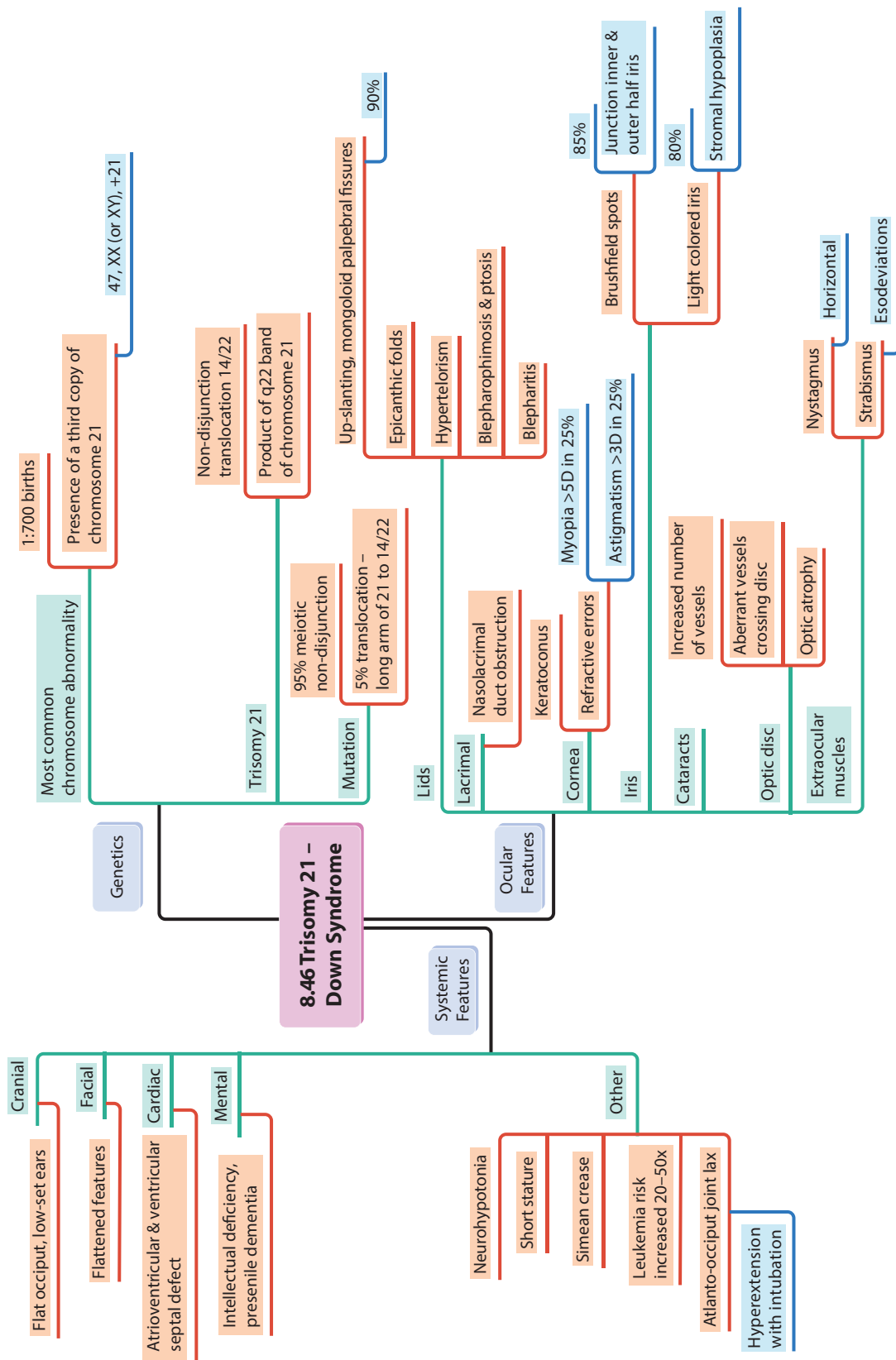


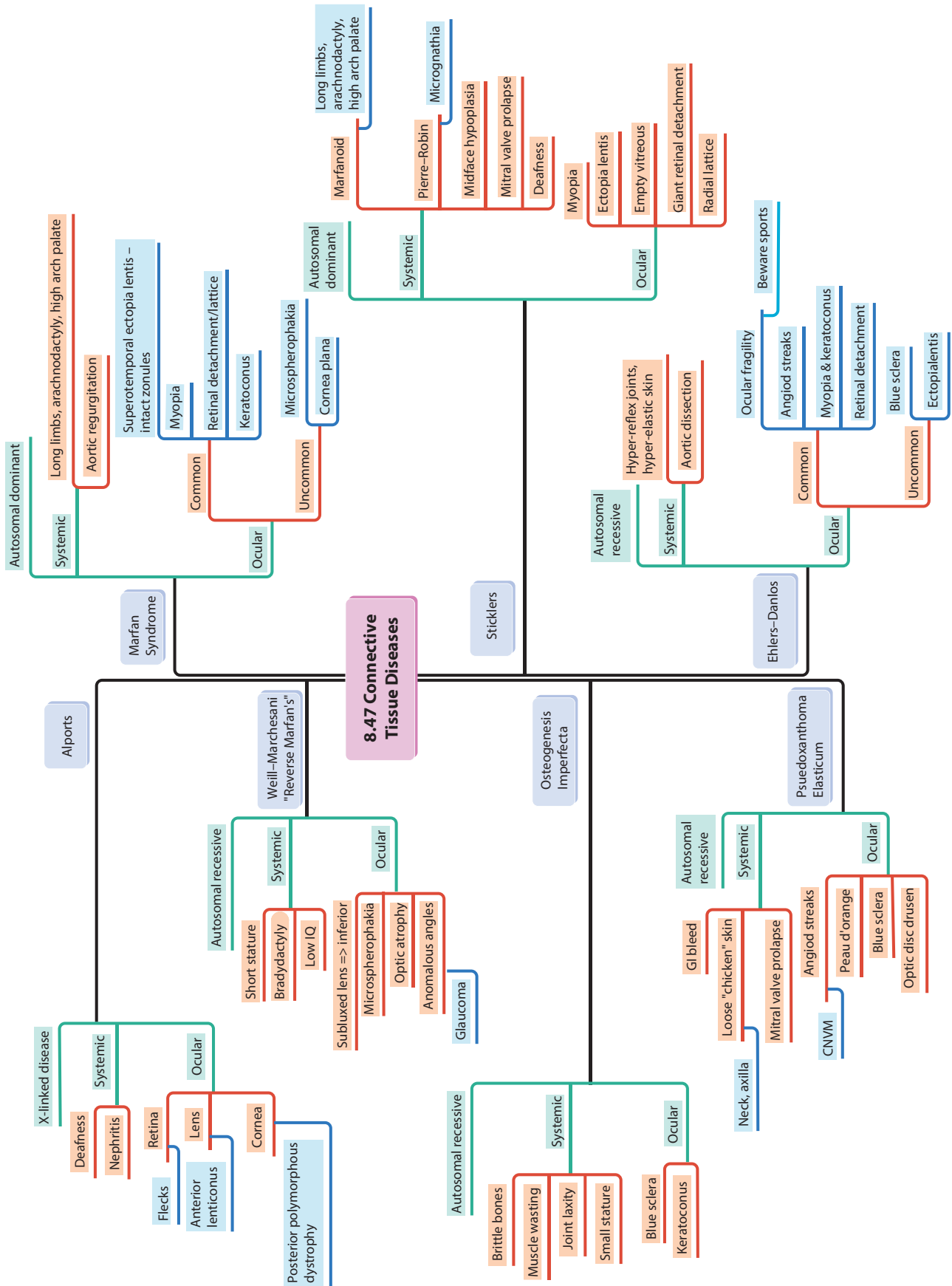


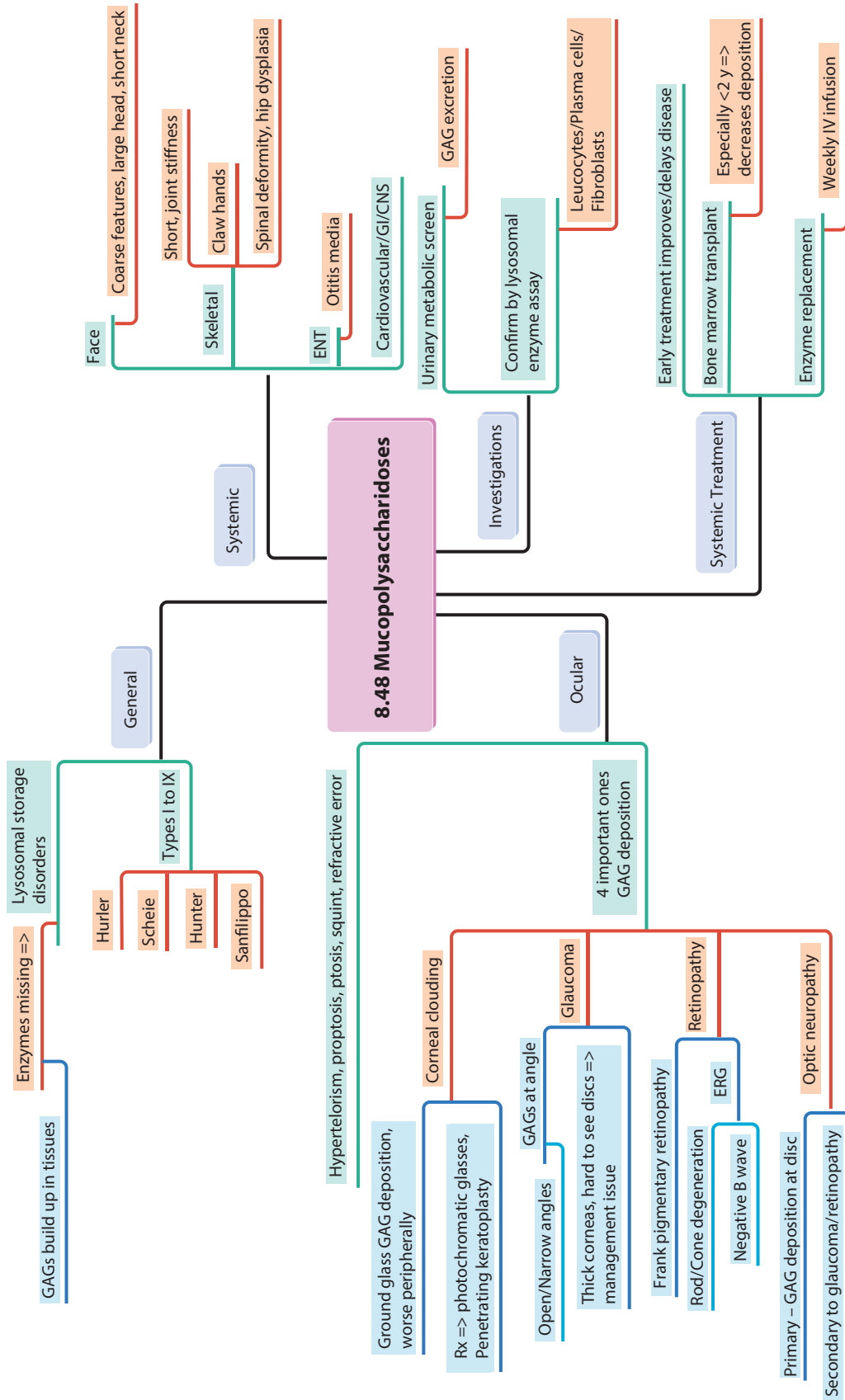


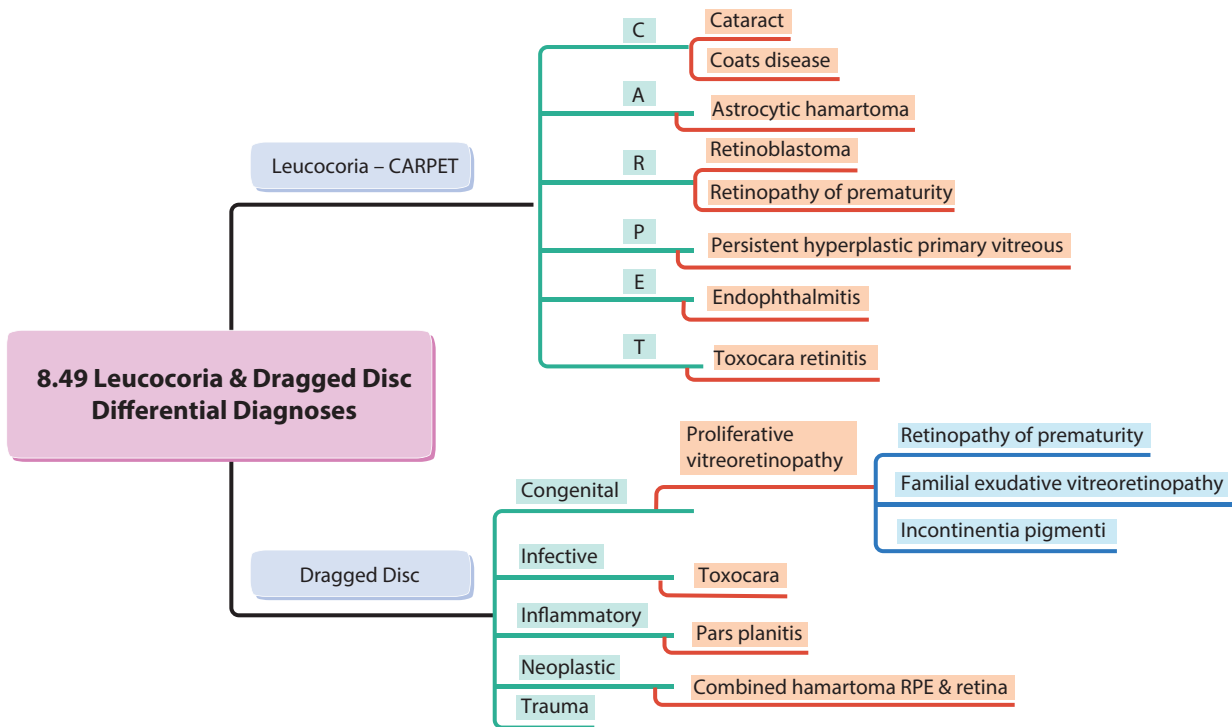


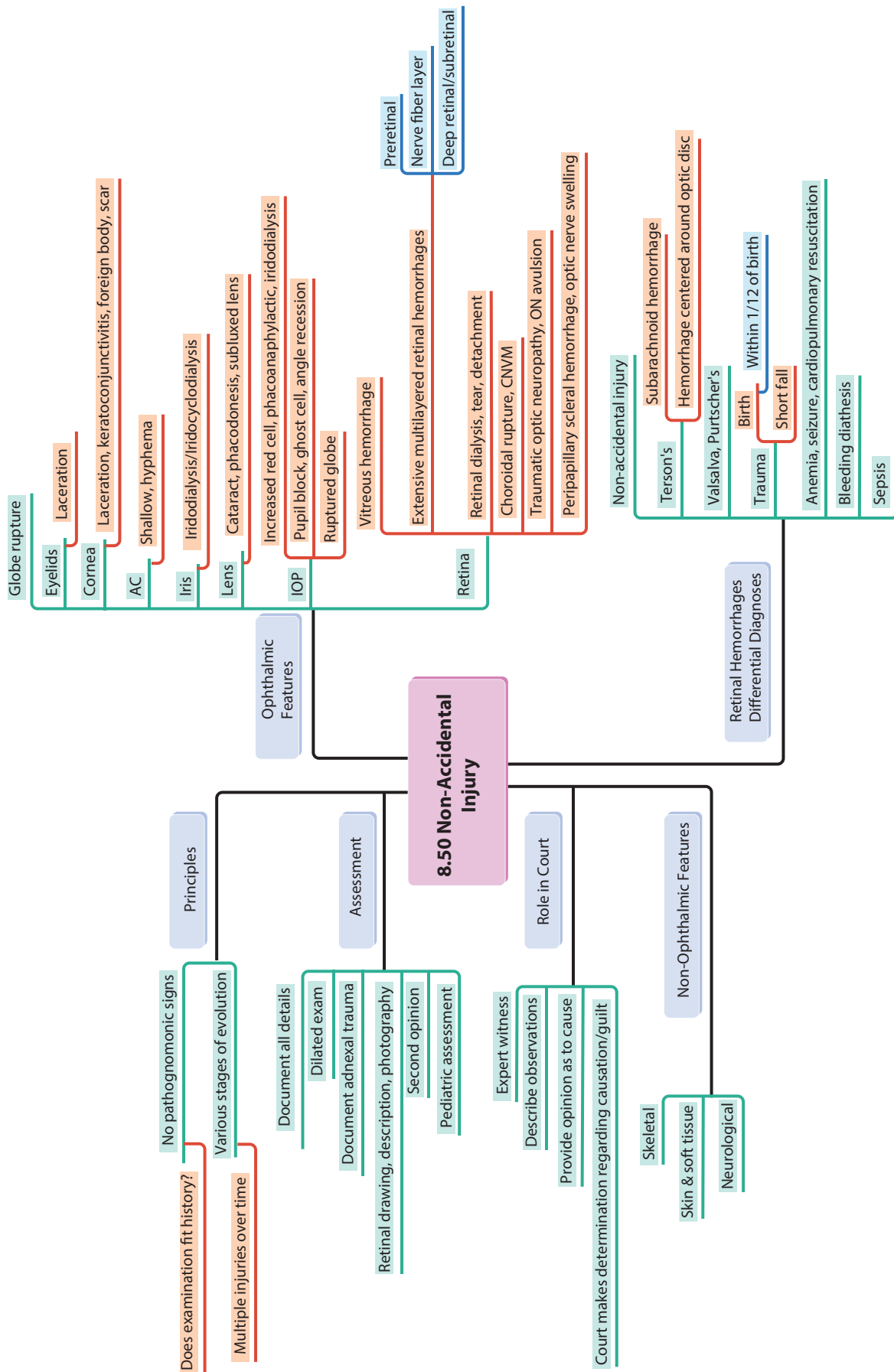




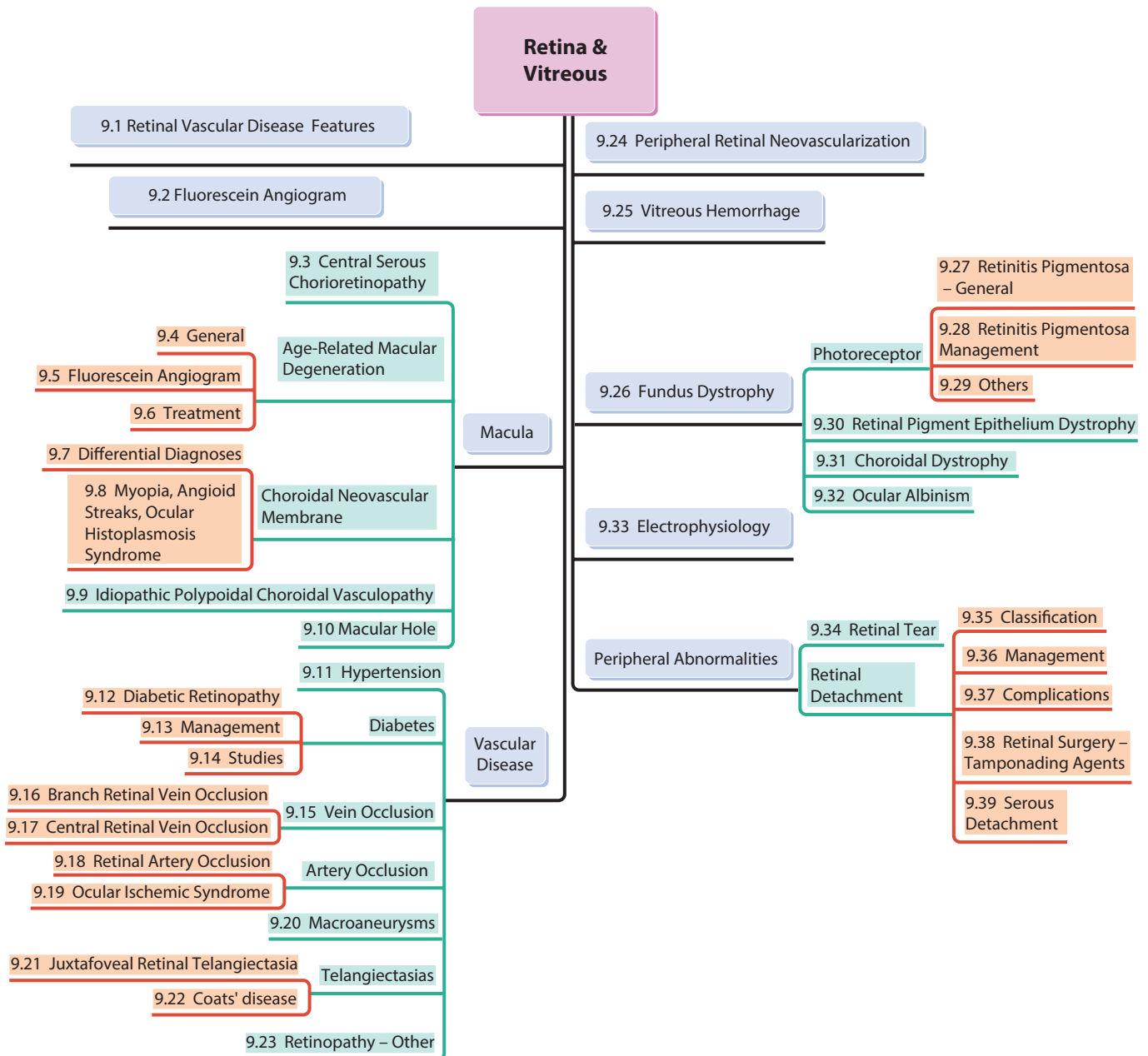


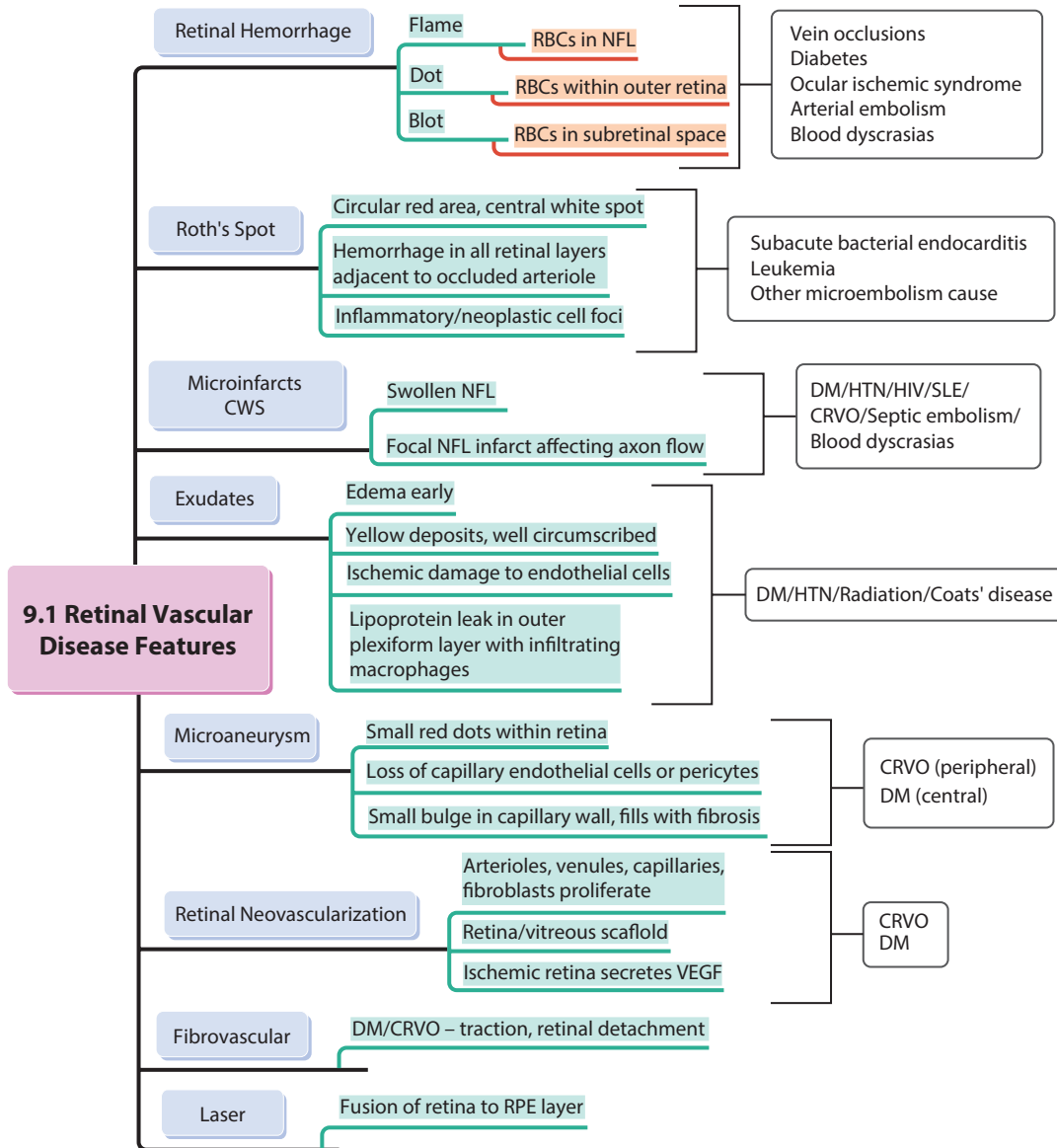


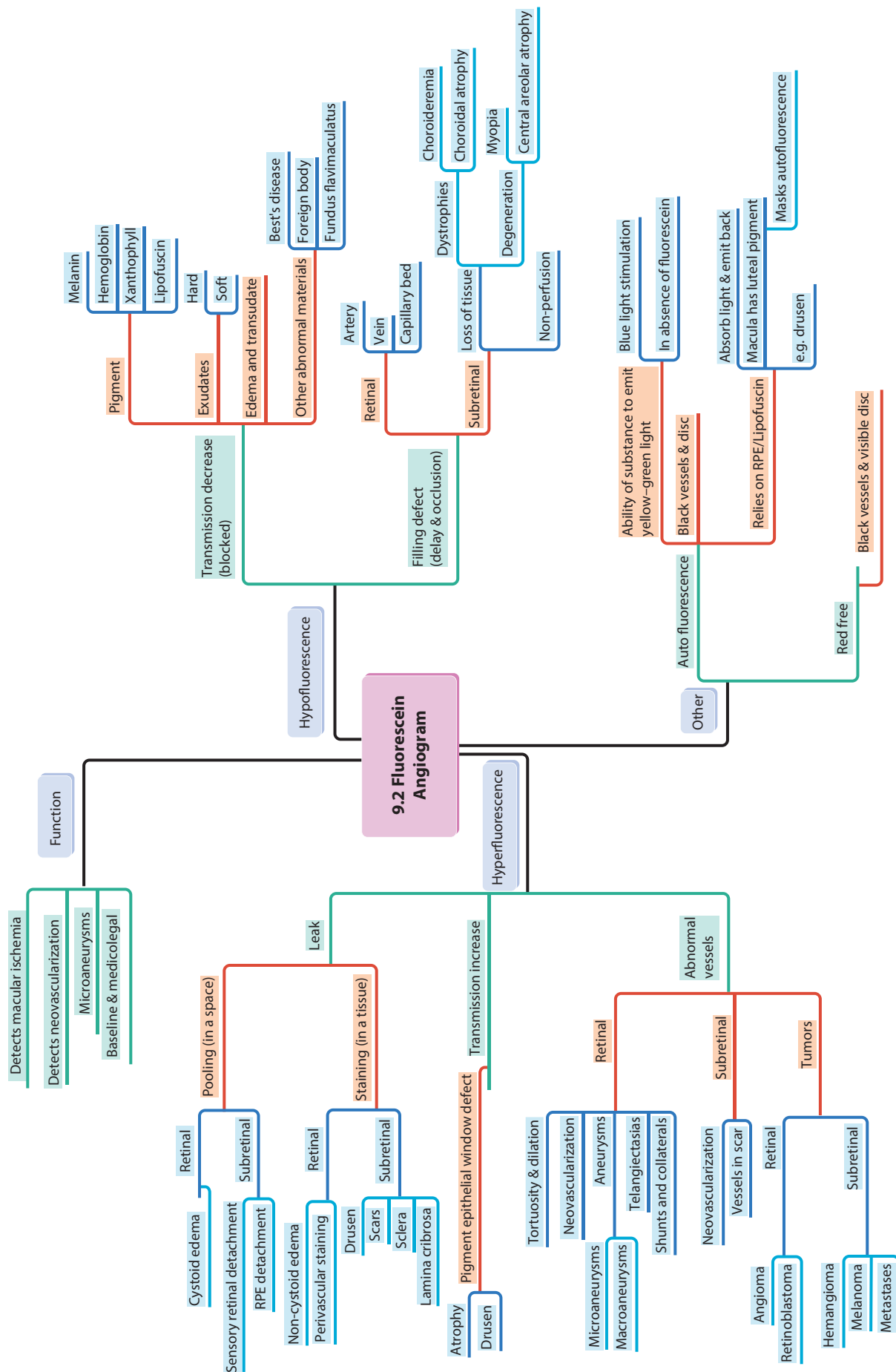


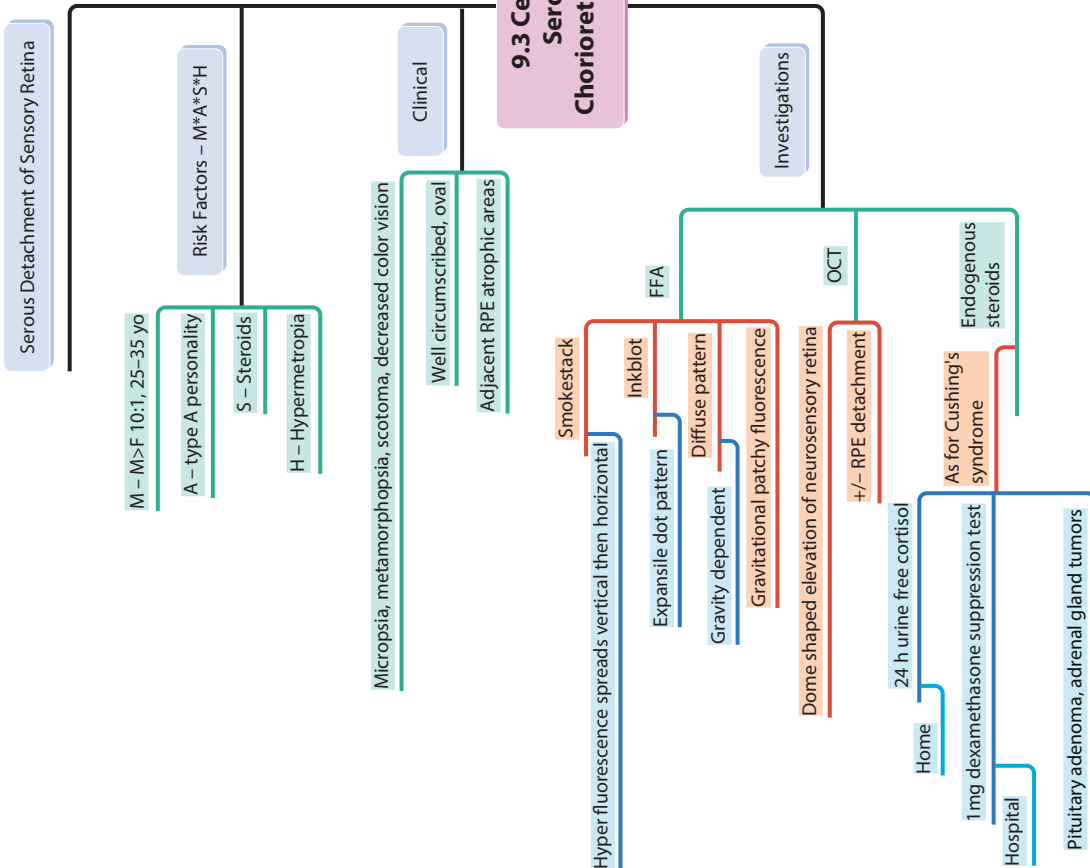
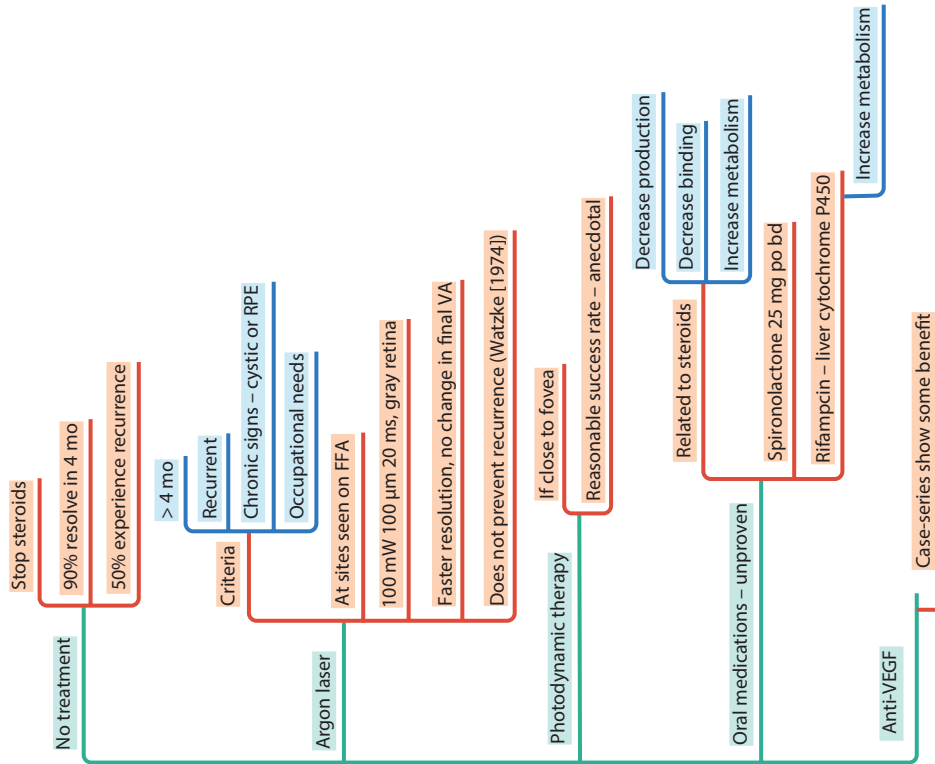


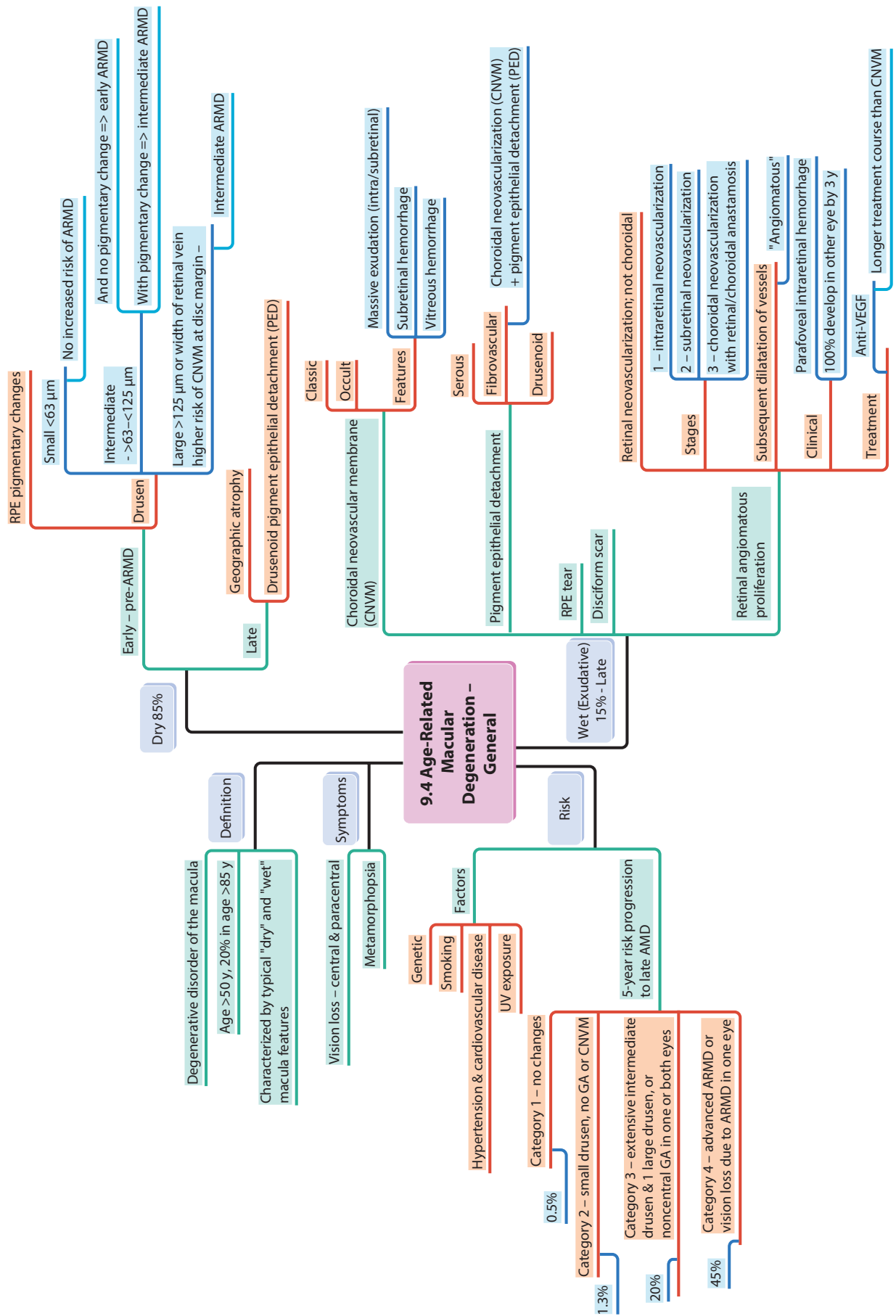
9 Retina and Vitreous

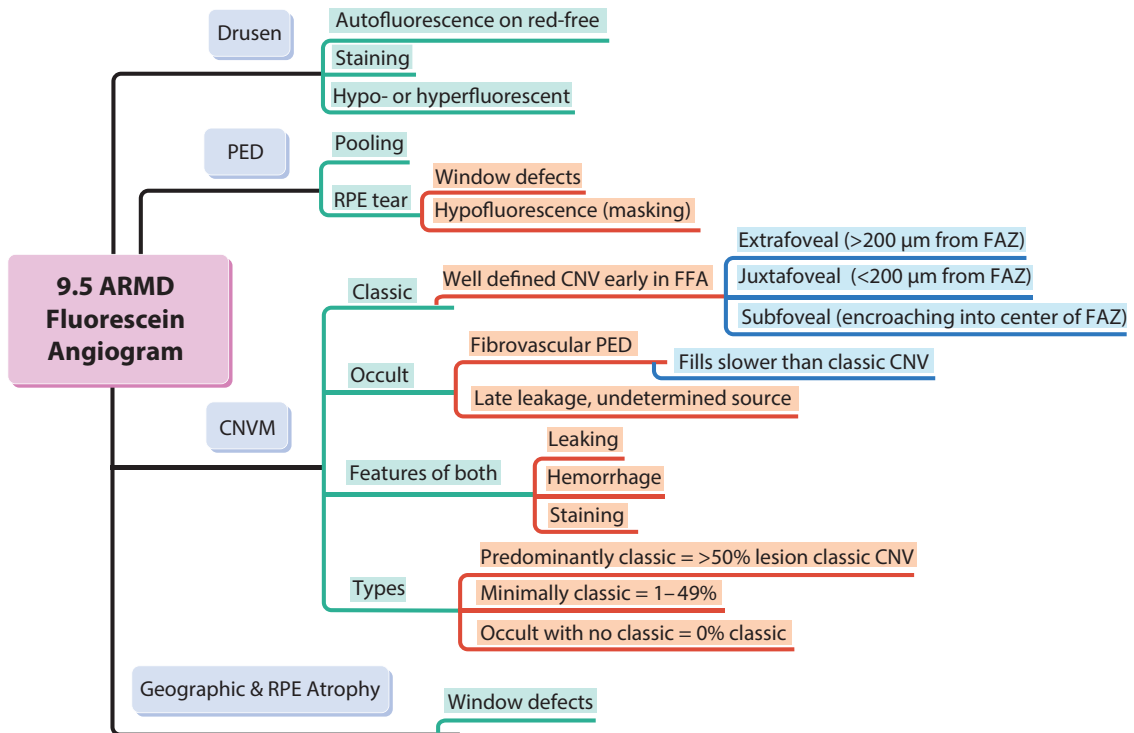


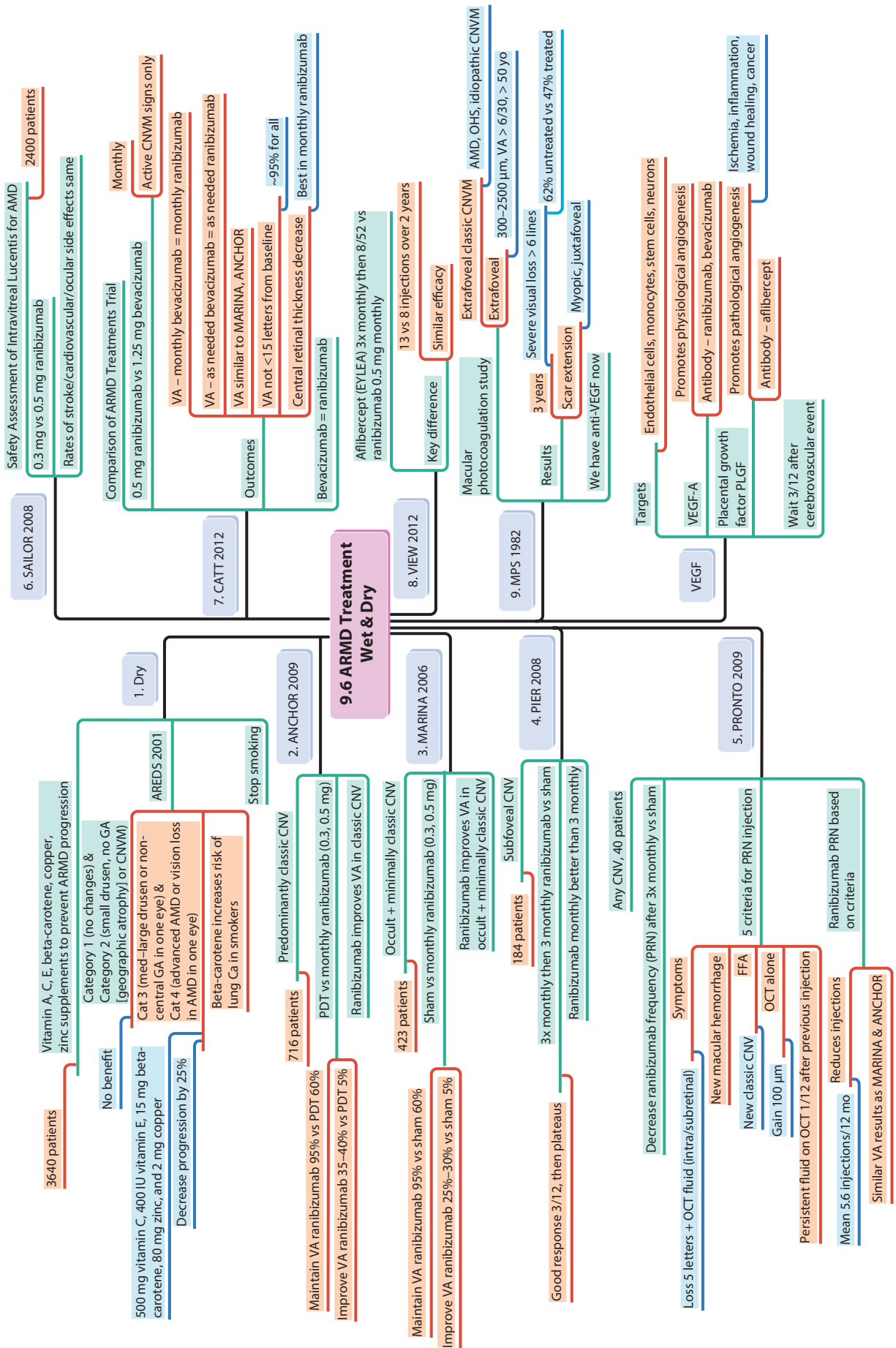


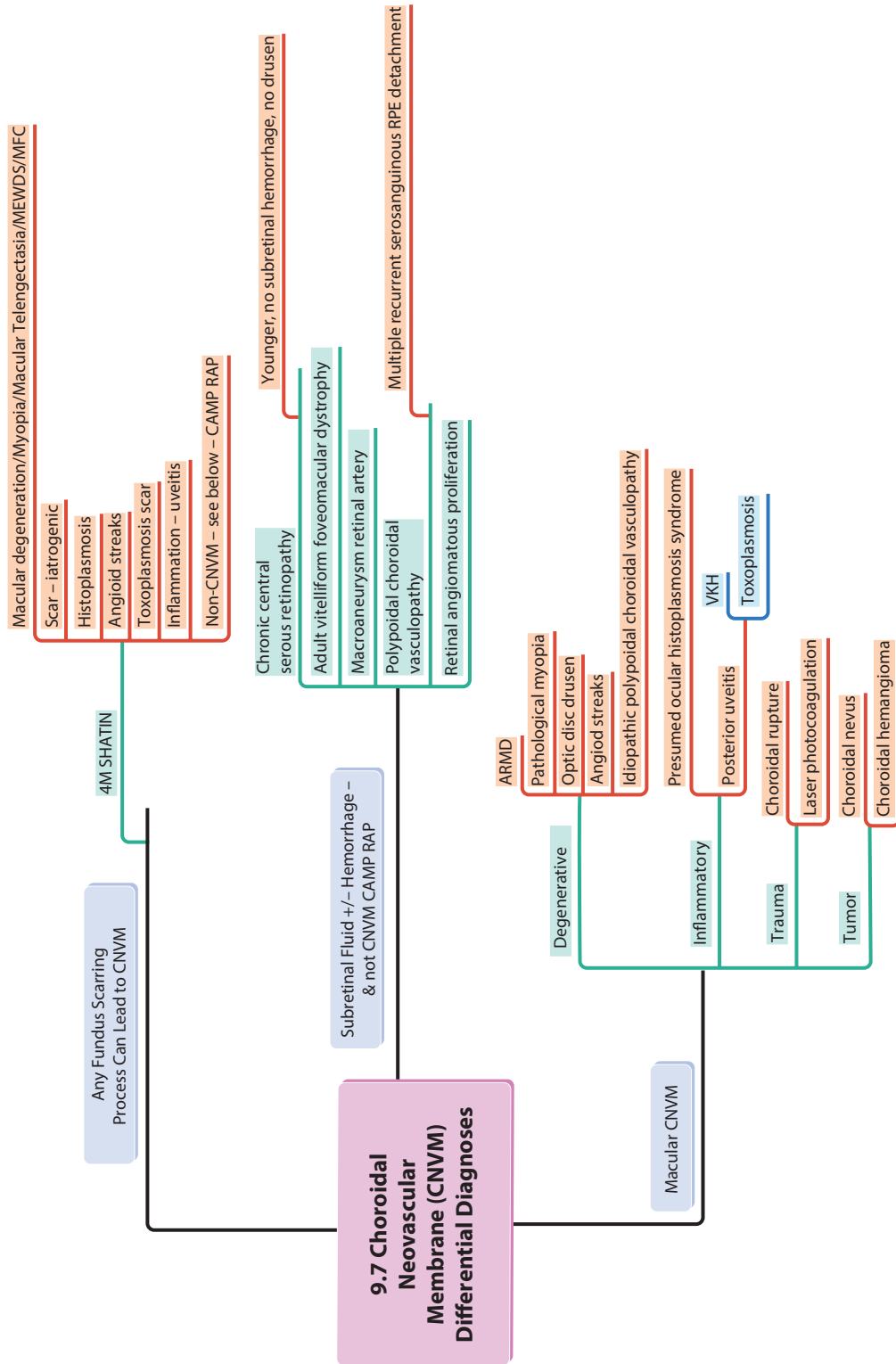


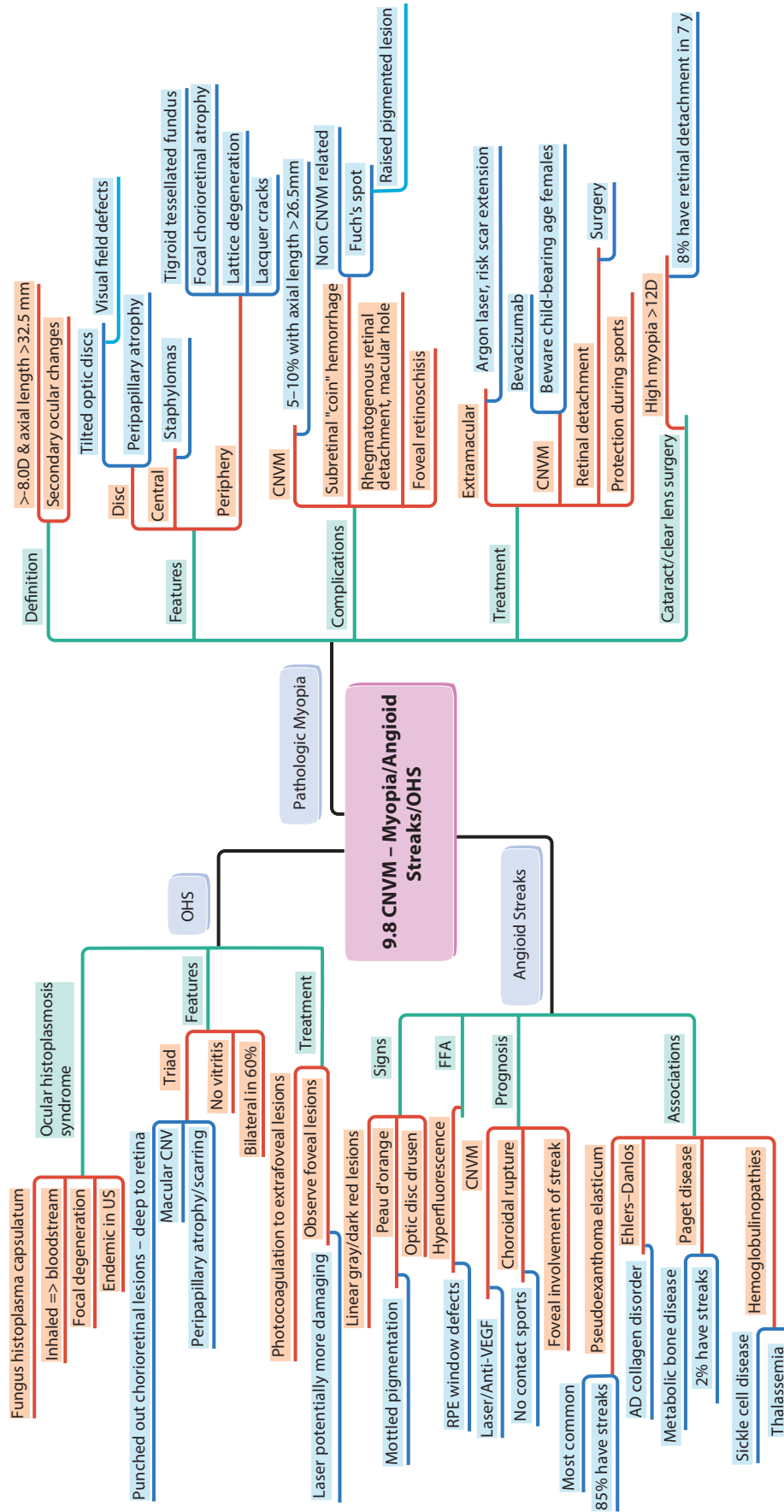


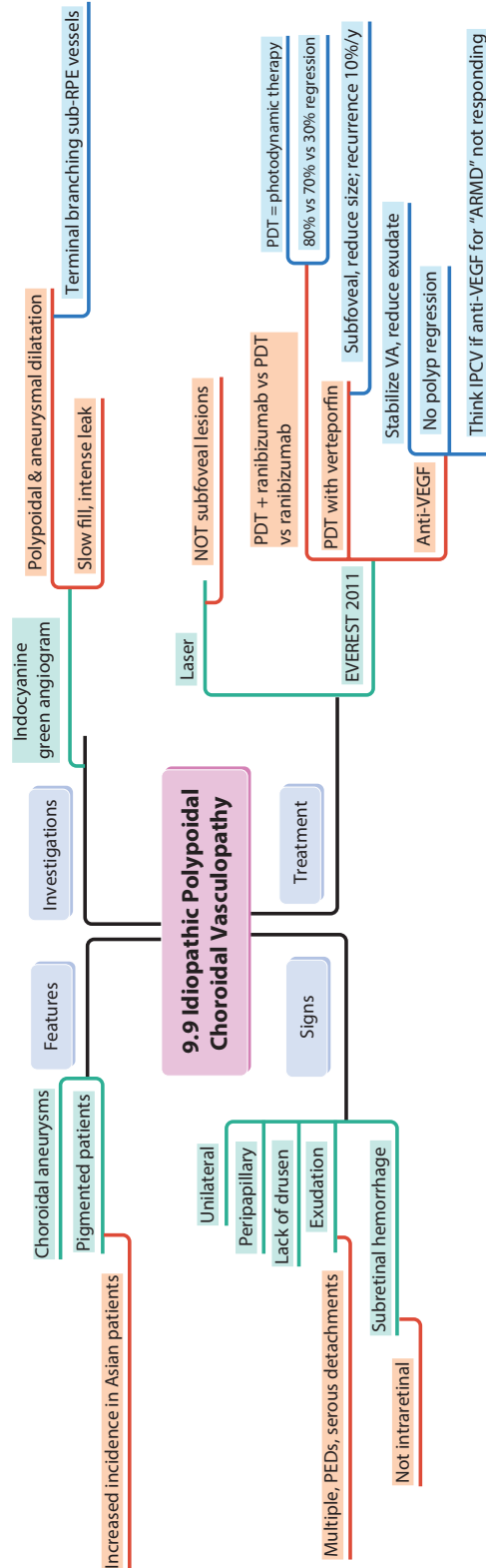


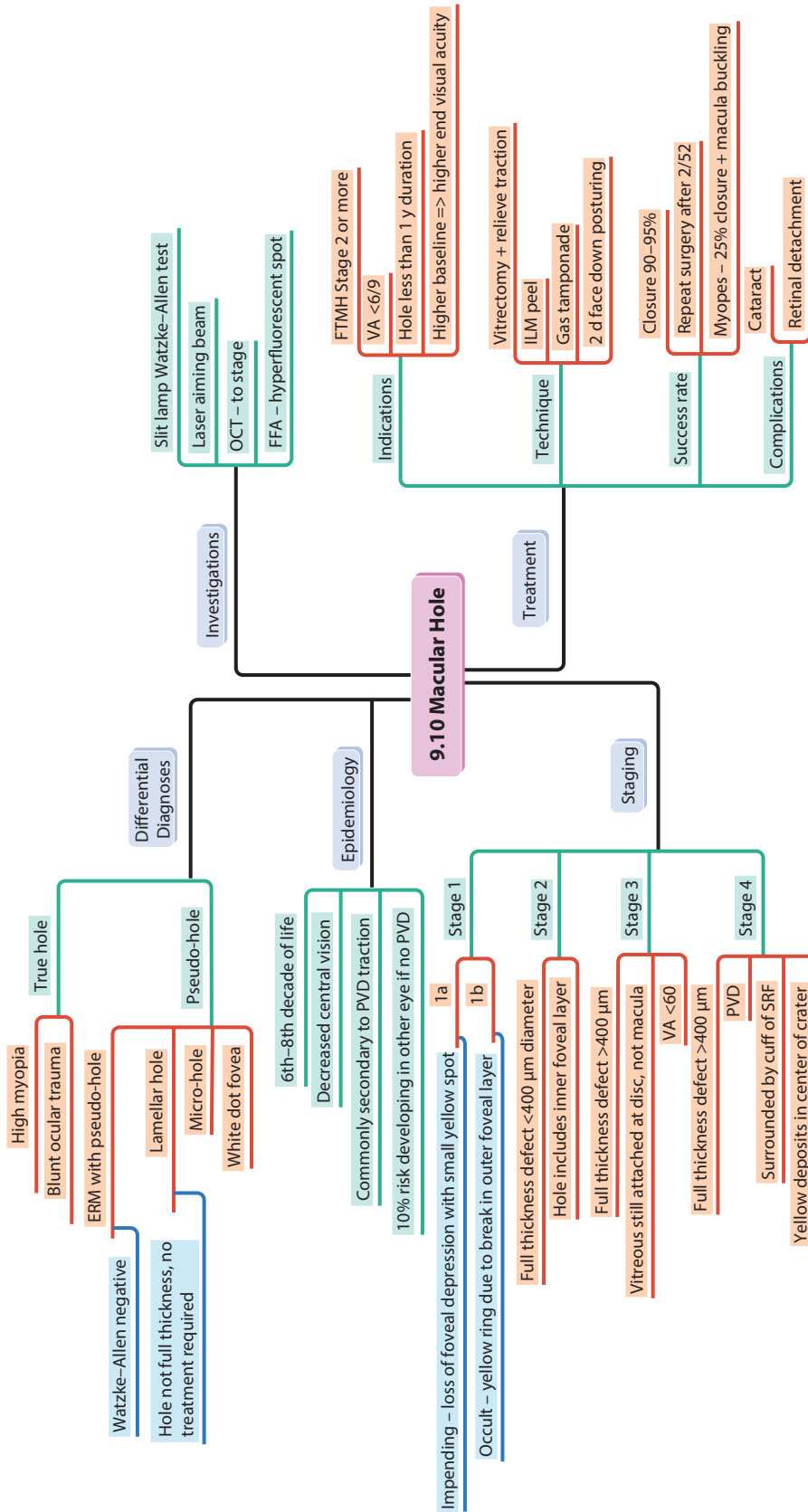


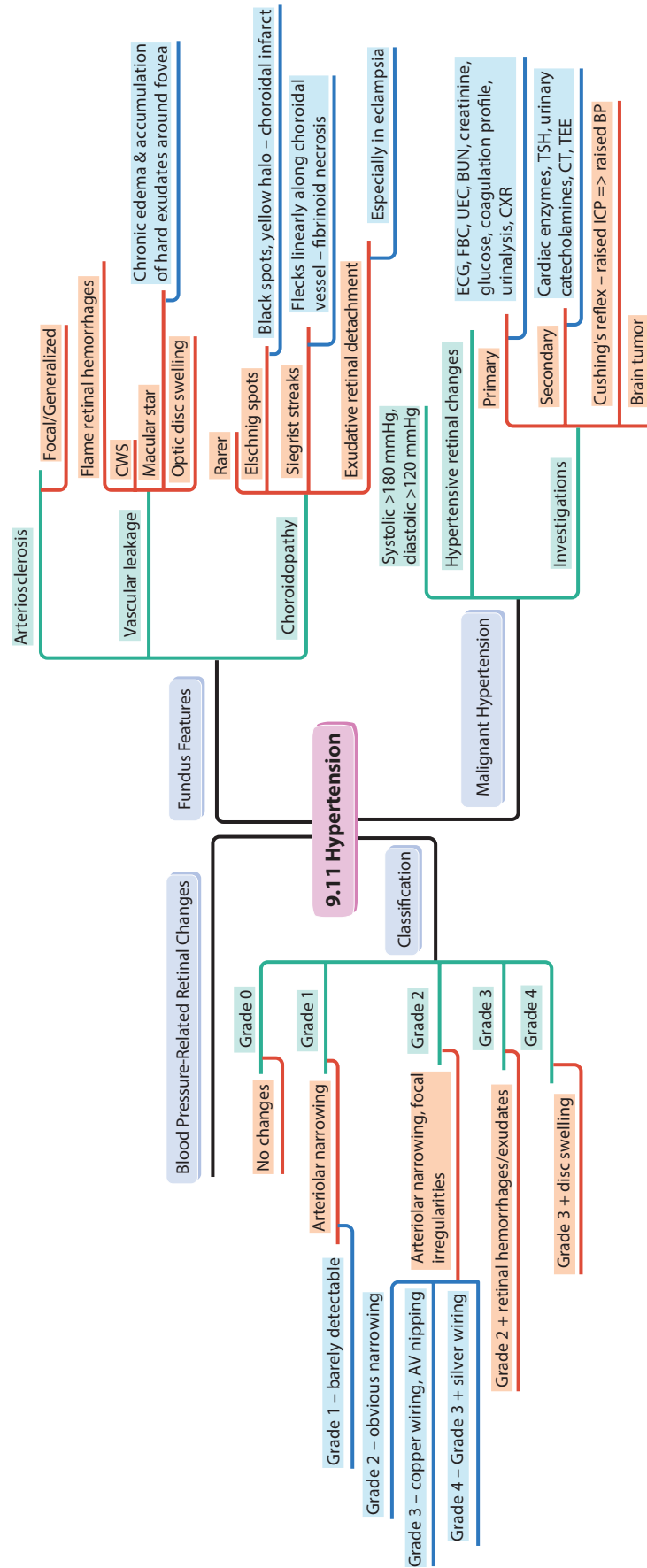


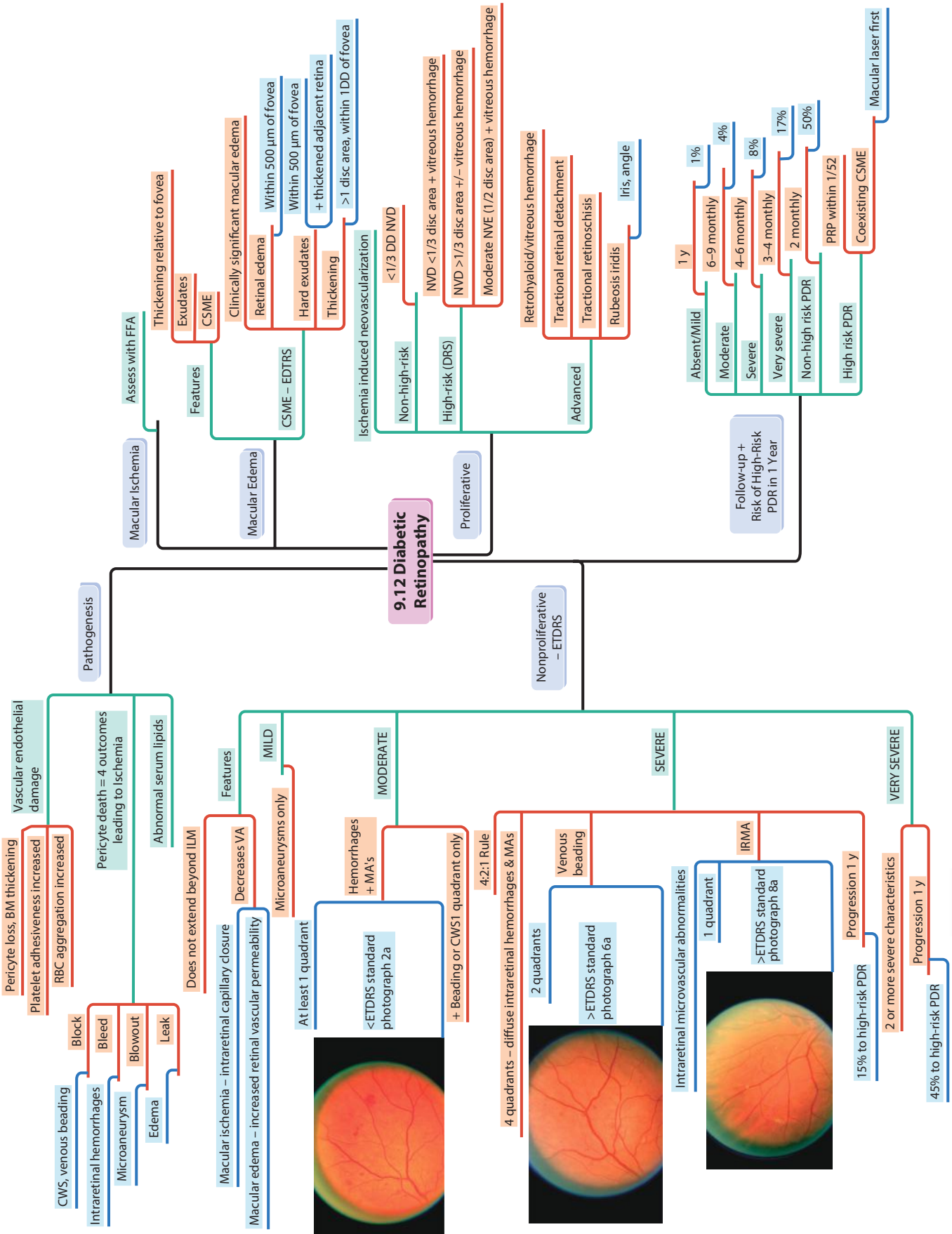




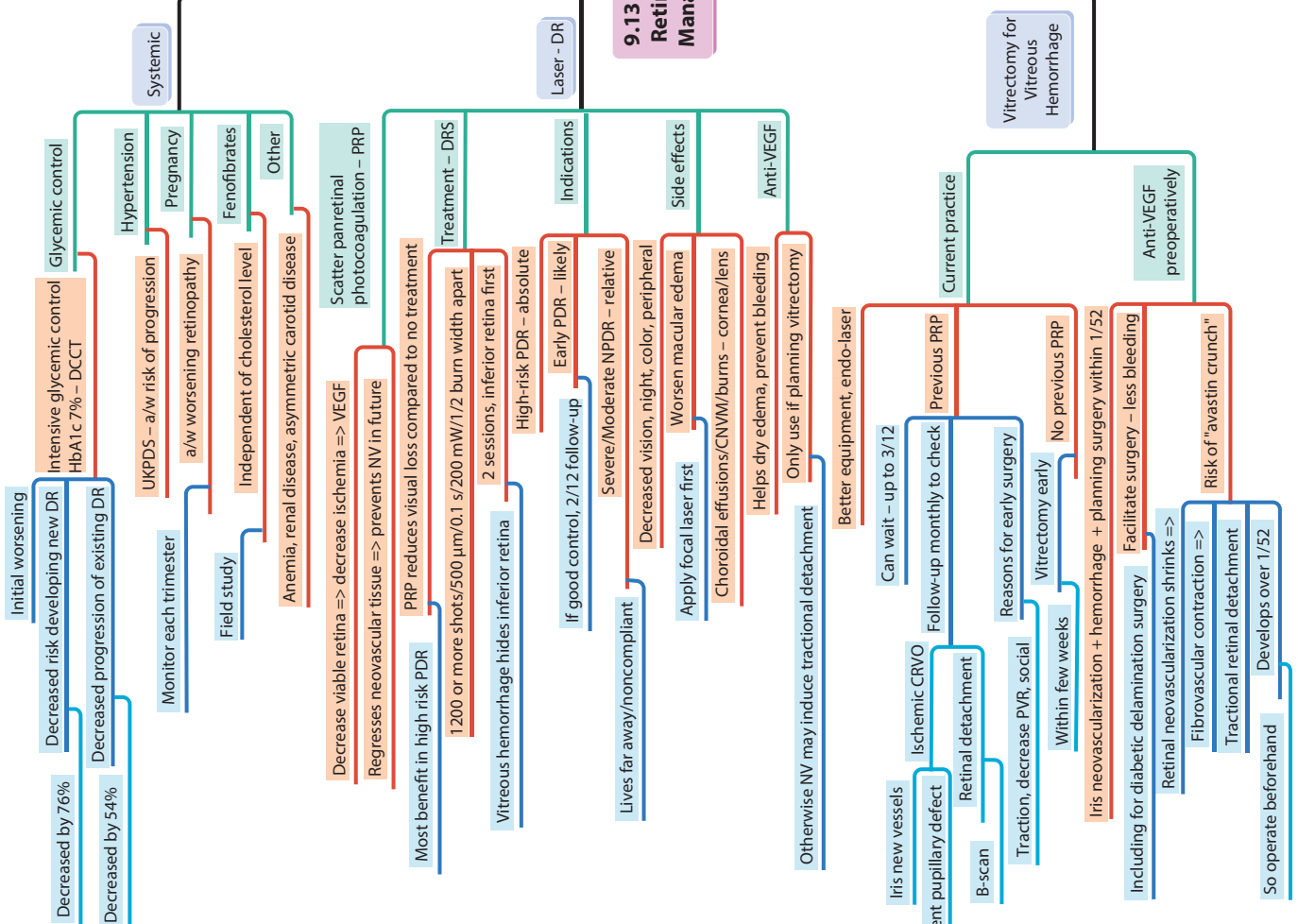
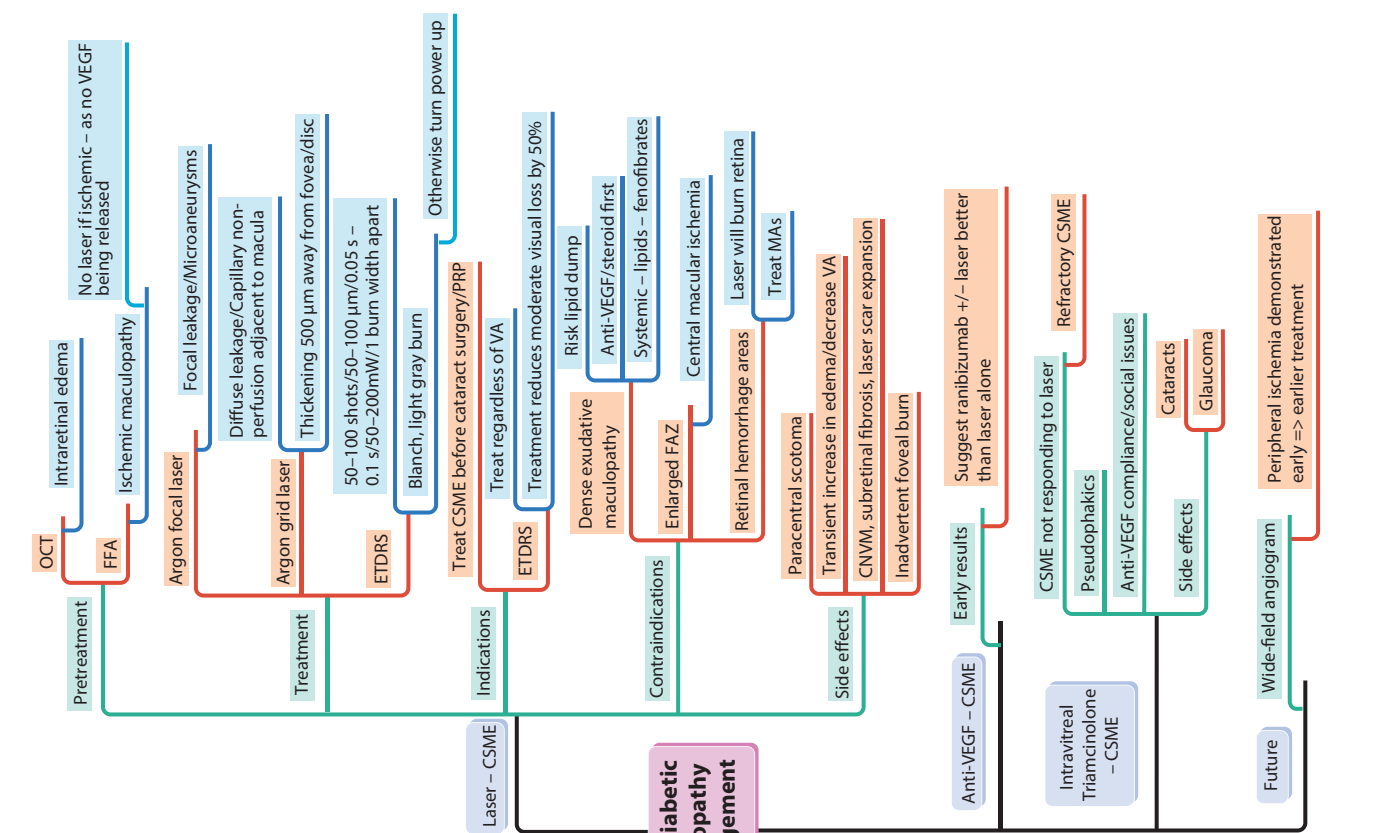


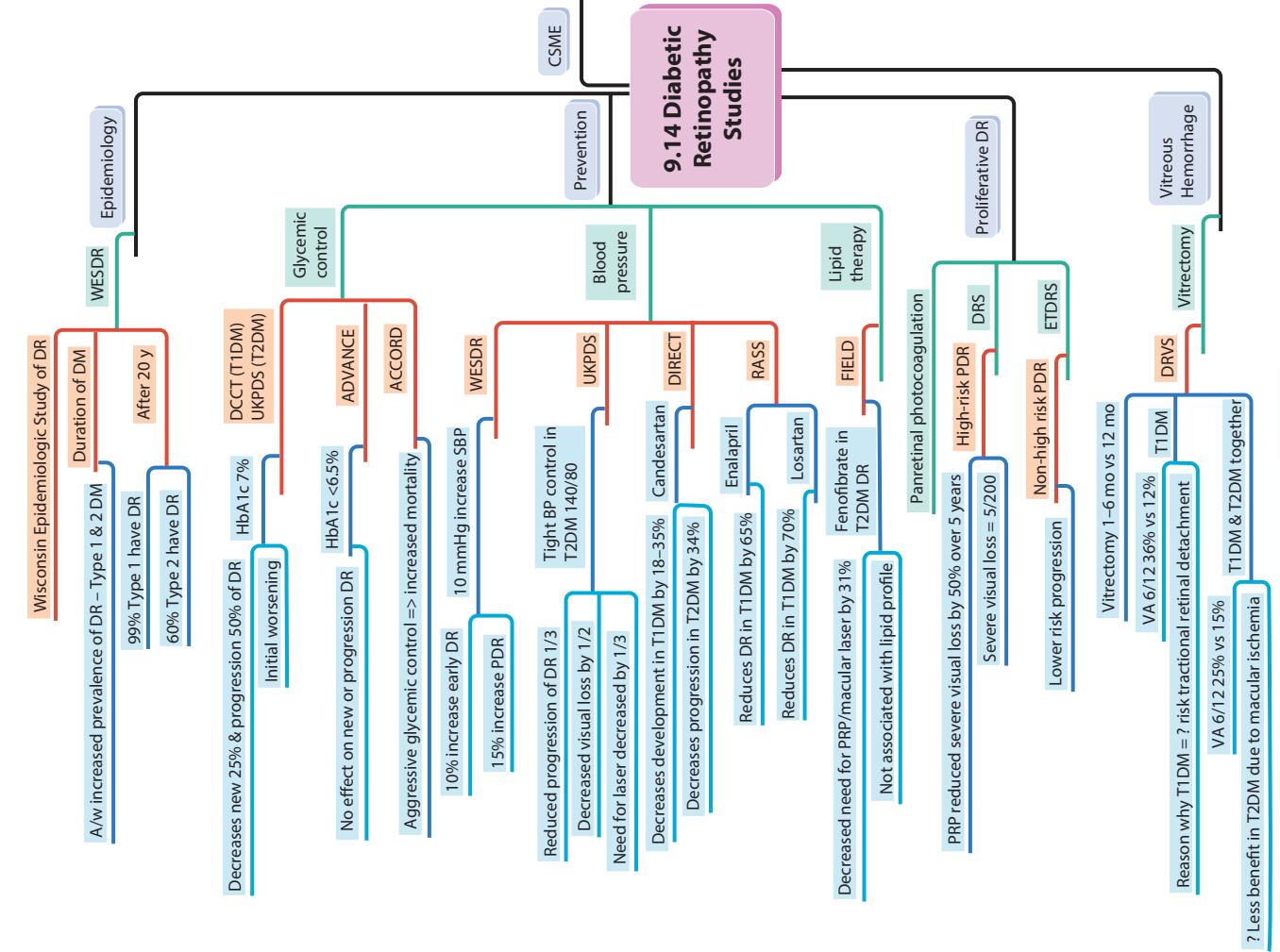
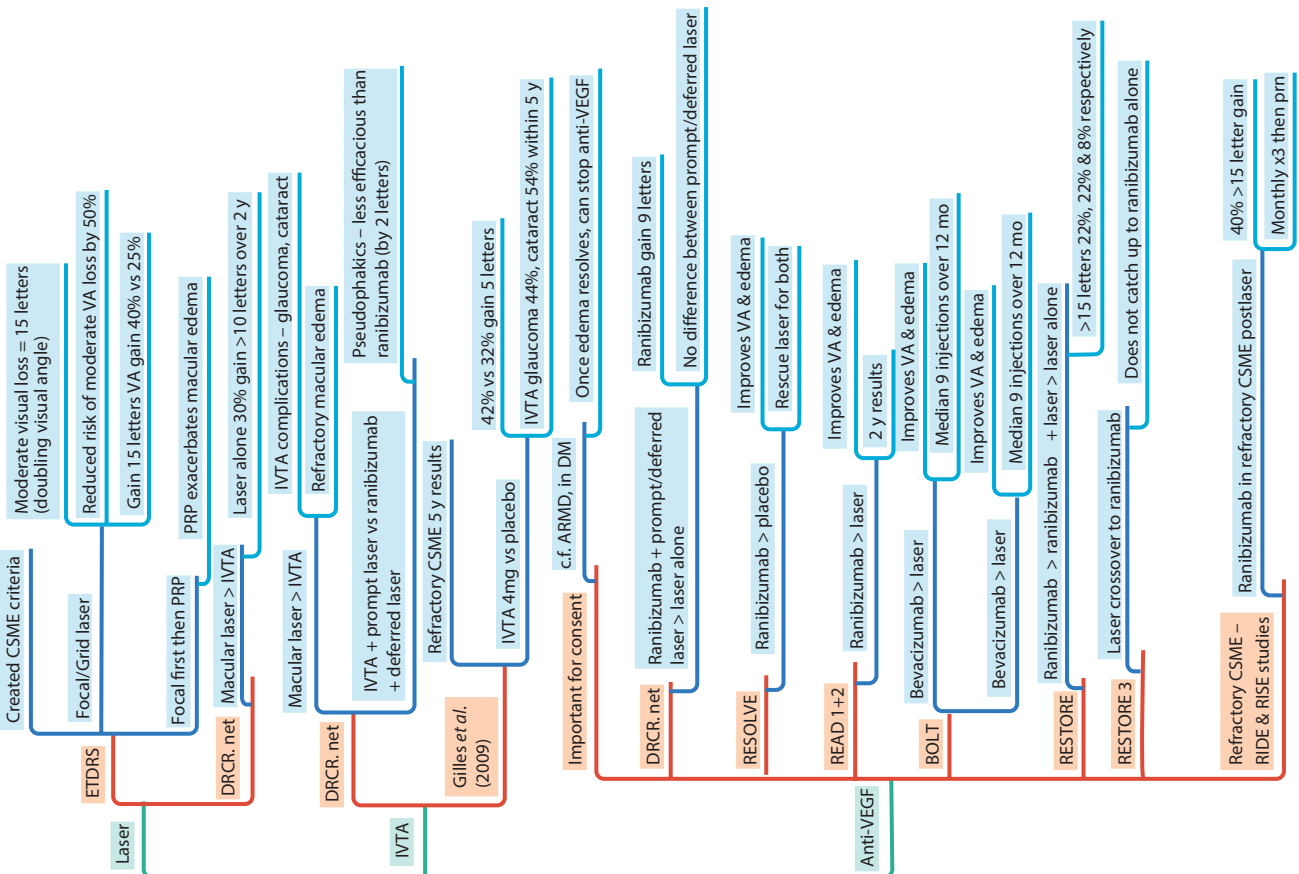


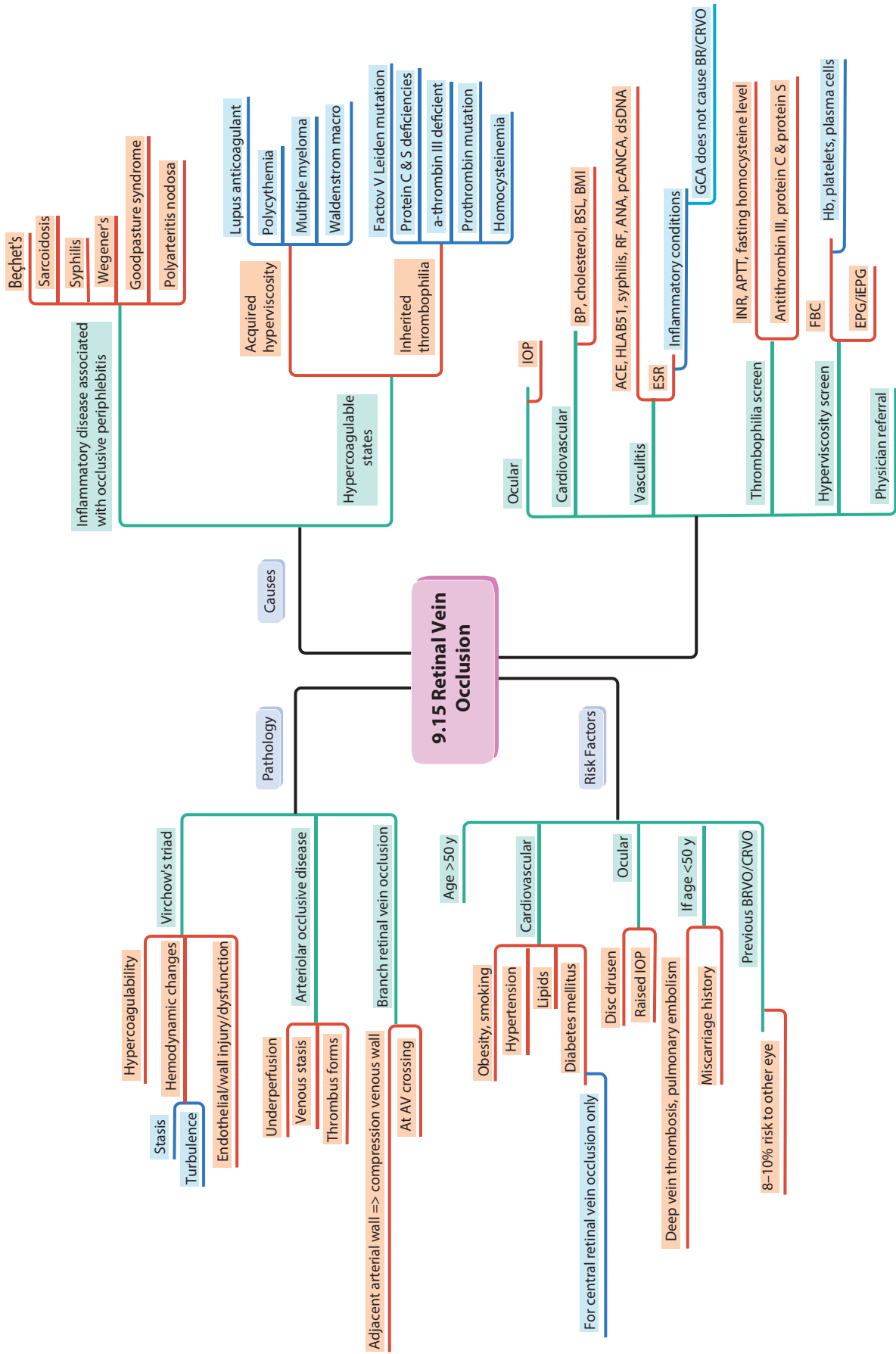


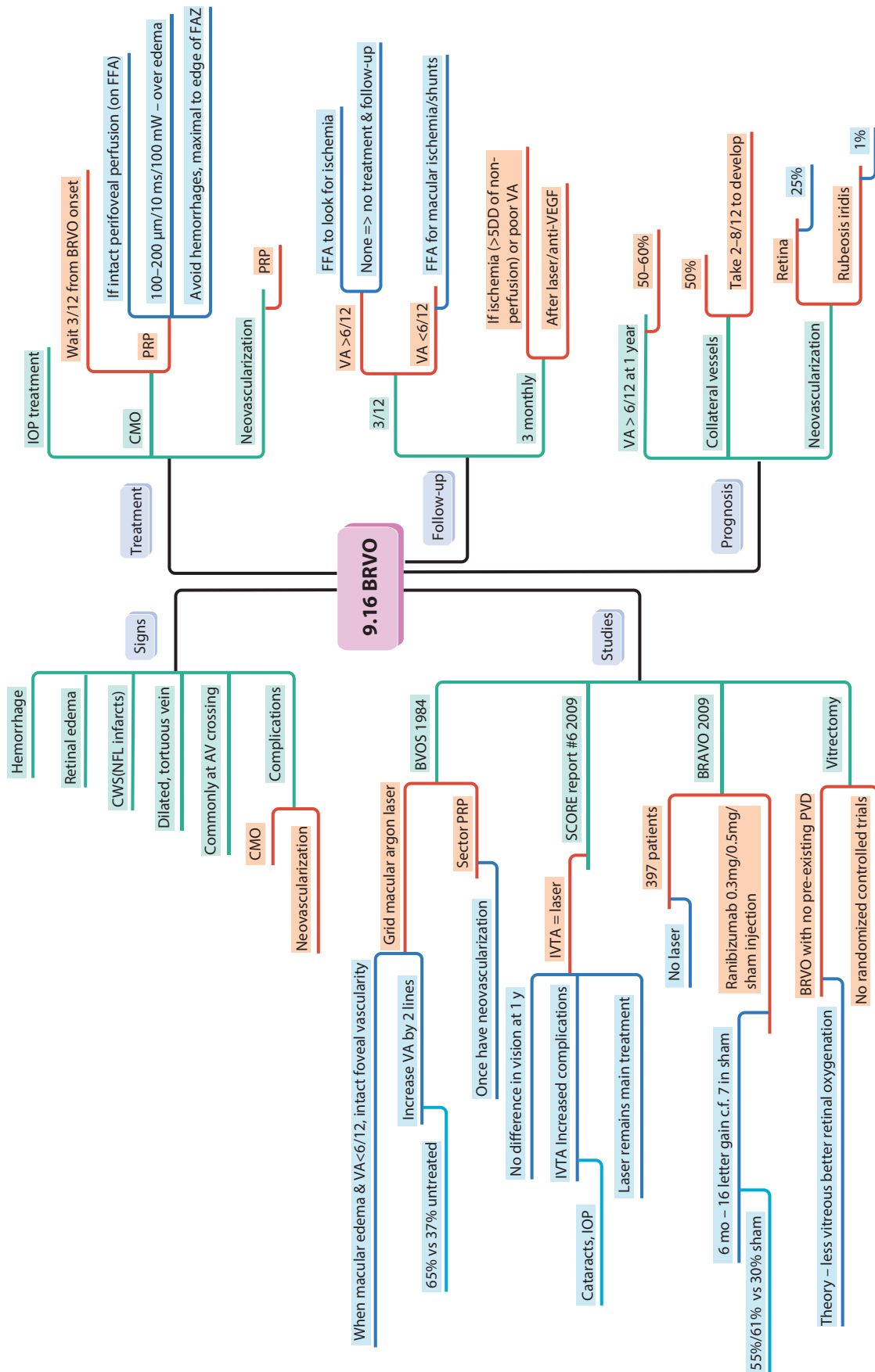


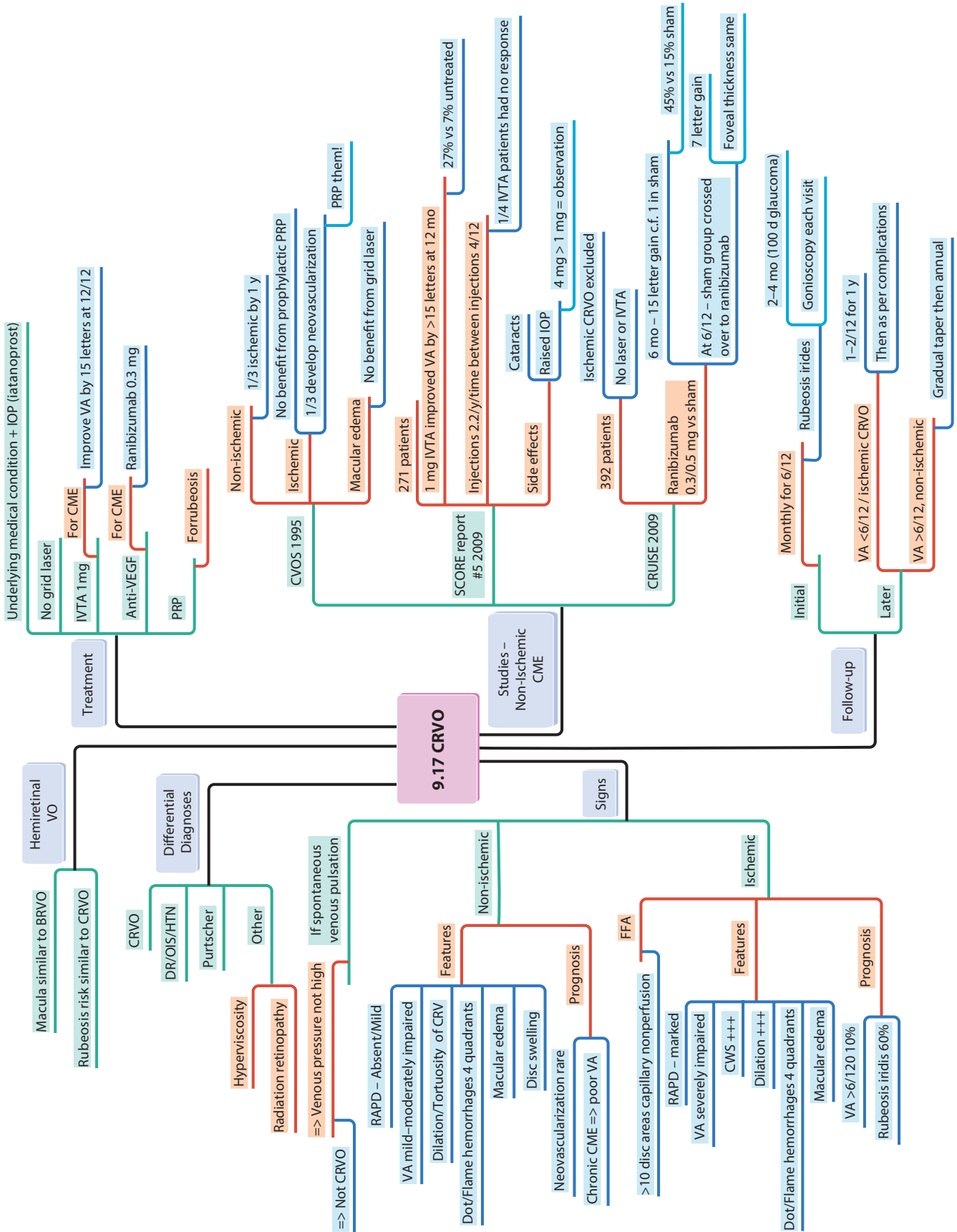
9.13 Diabetic Retinopathy Management

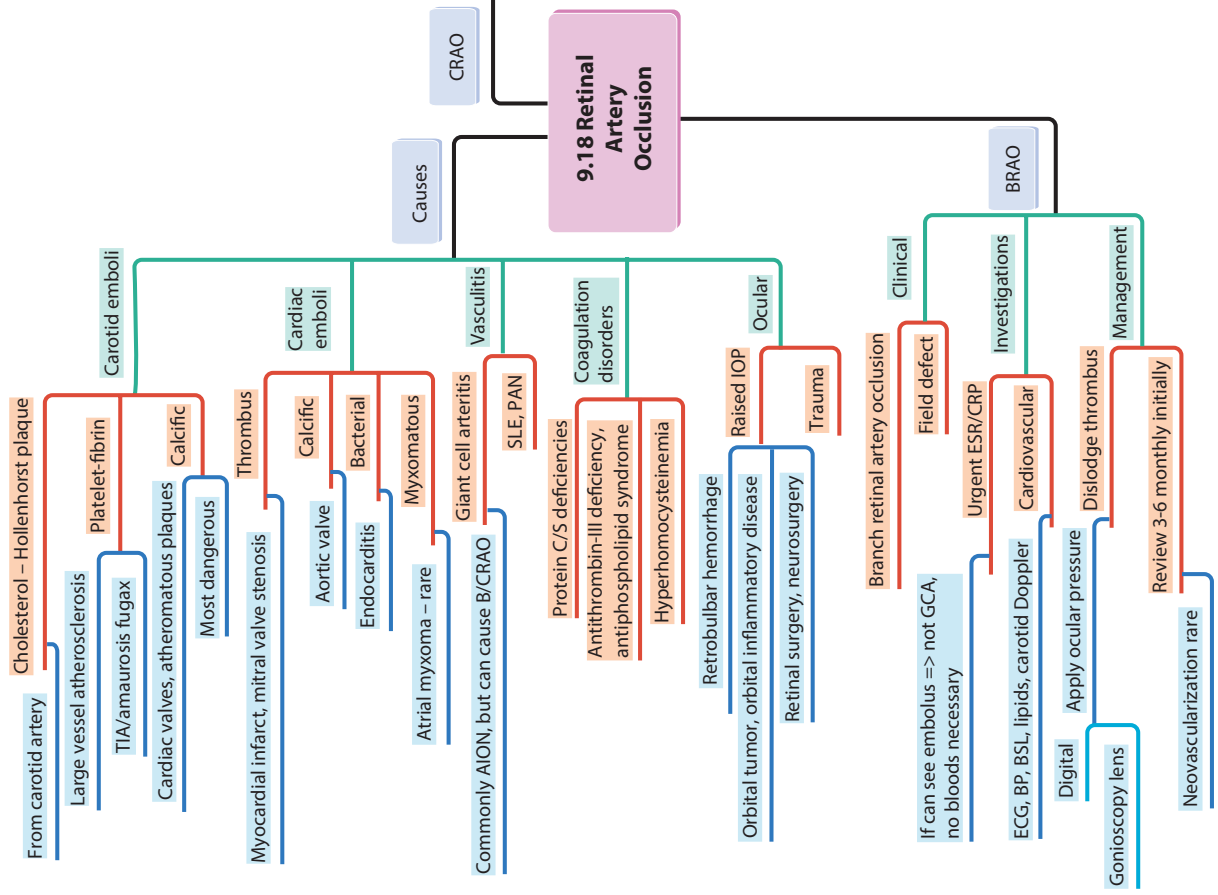
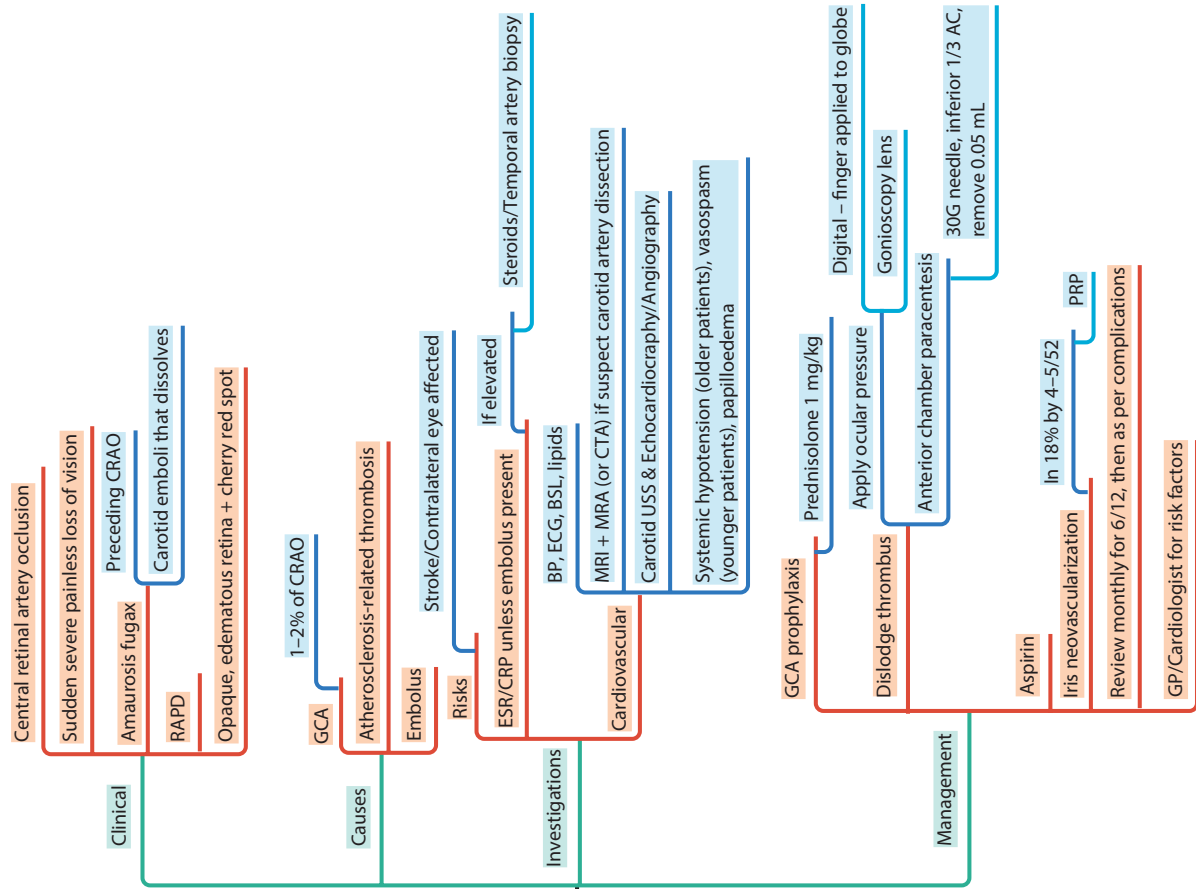


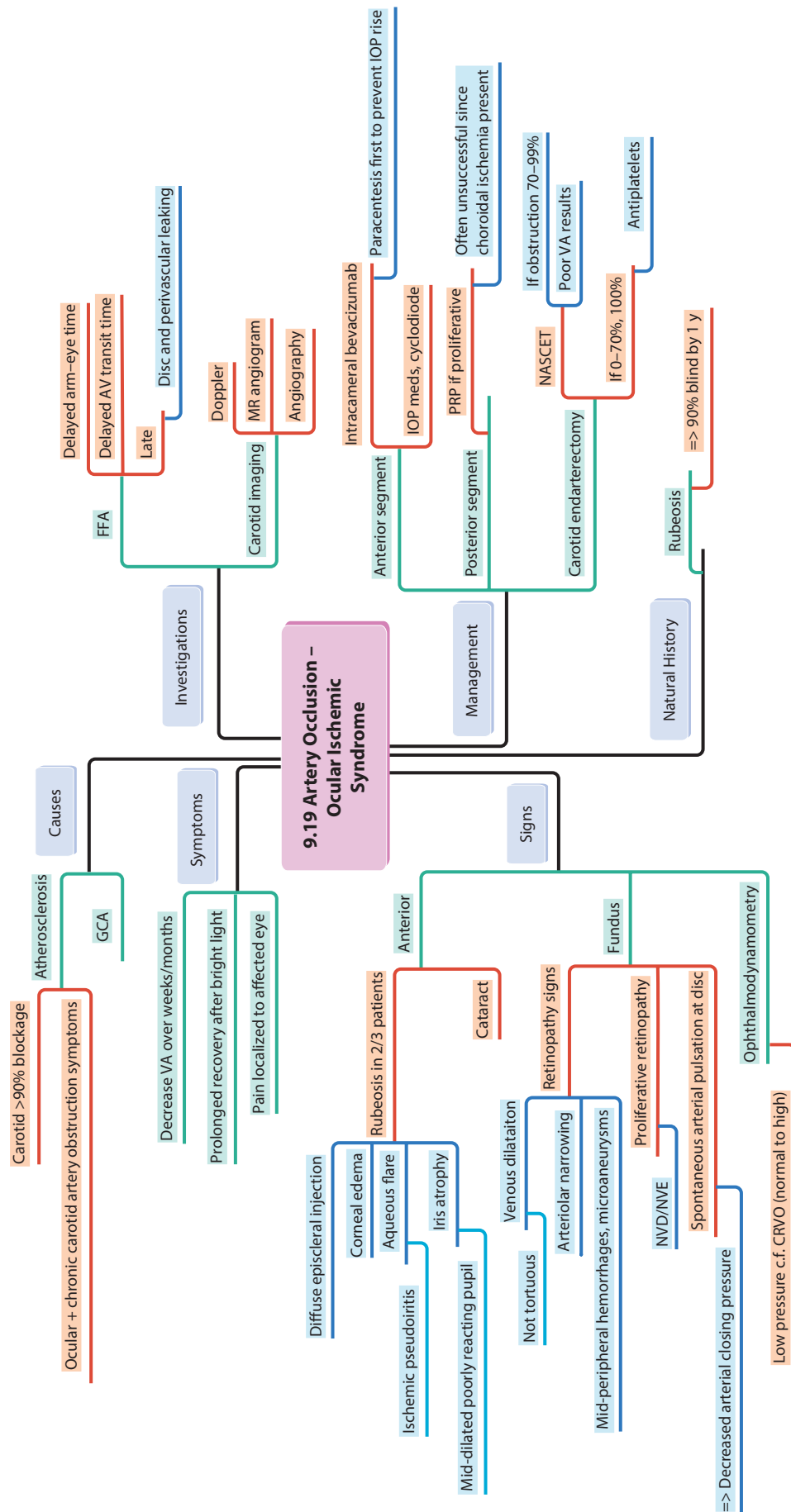


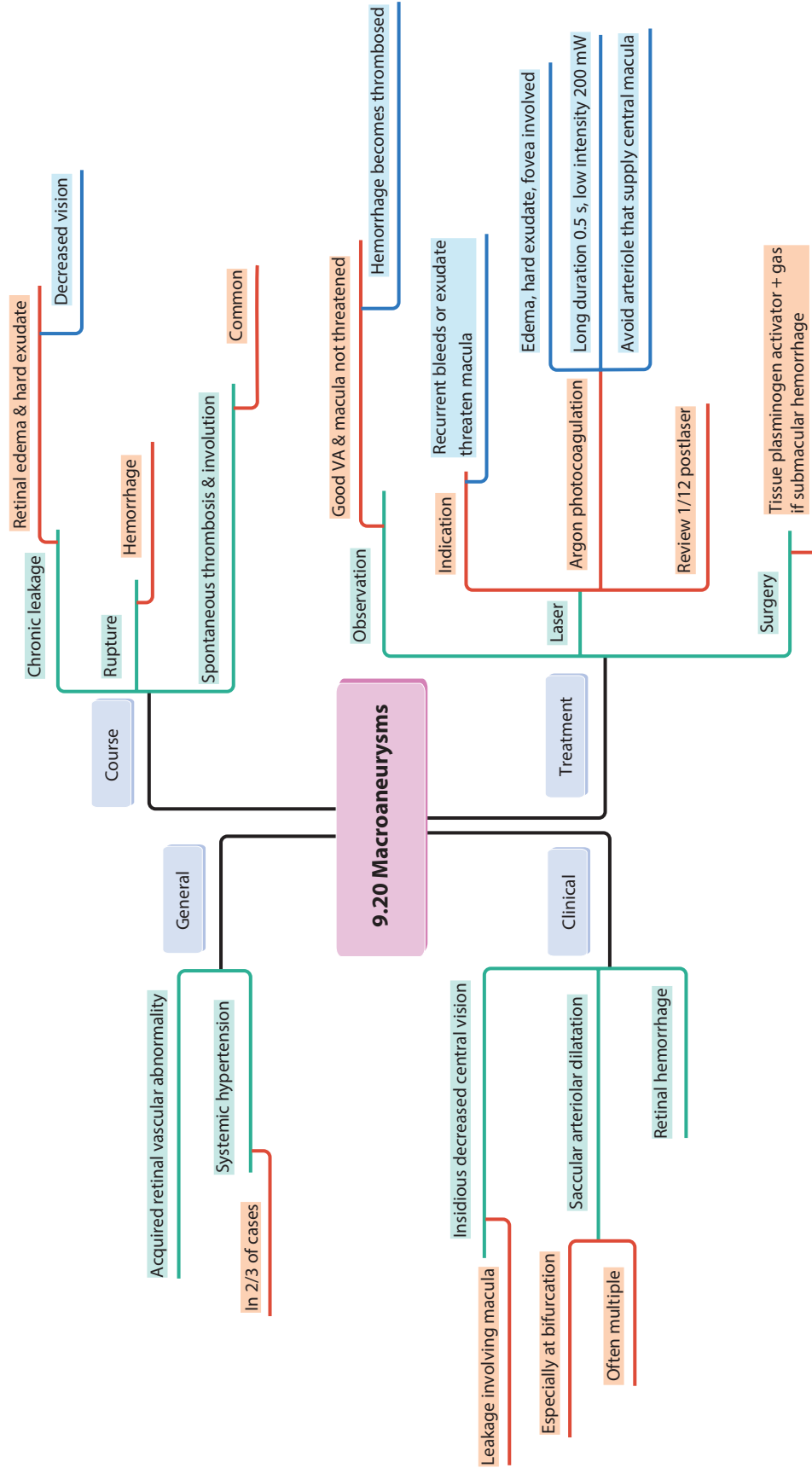


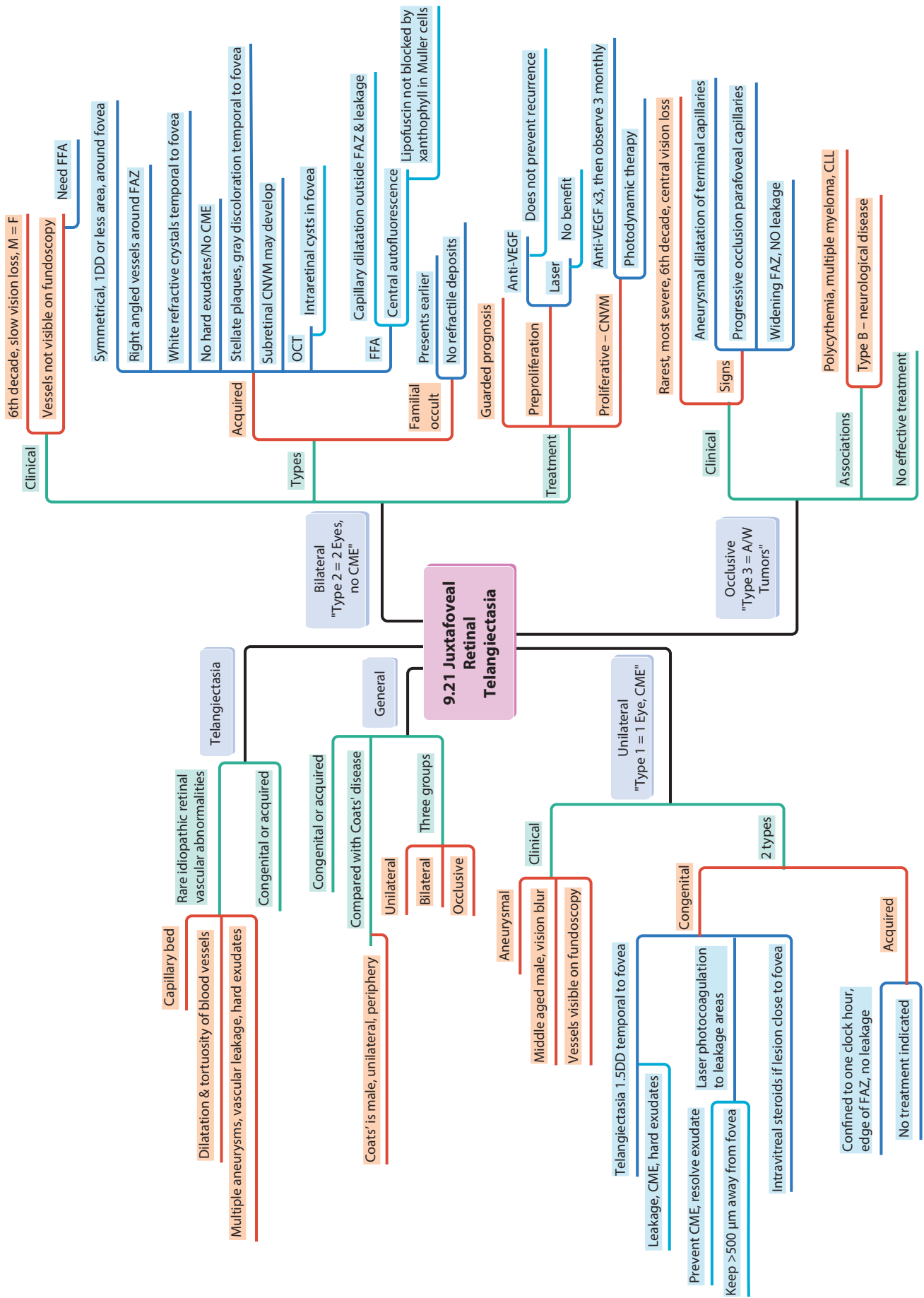


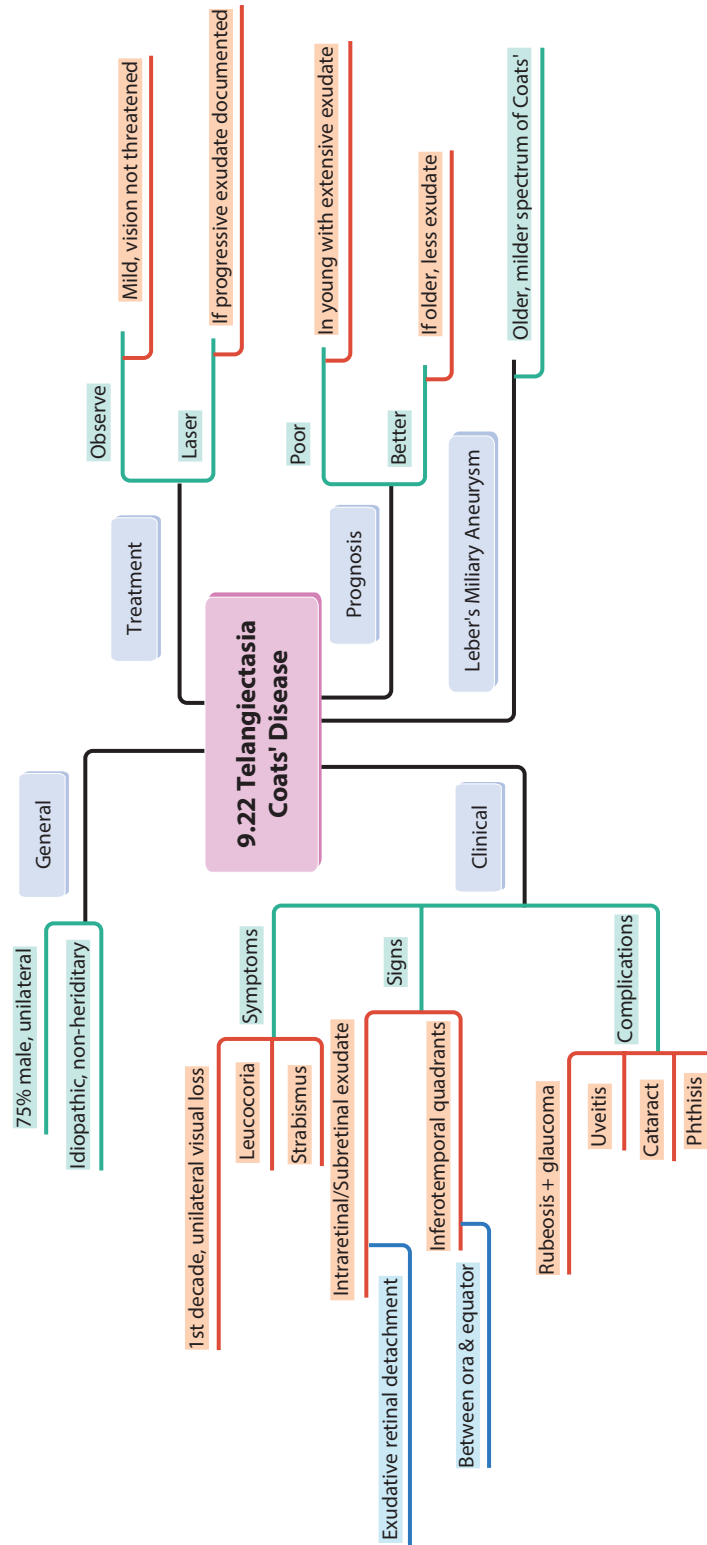


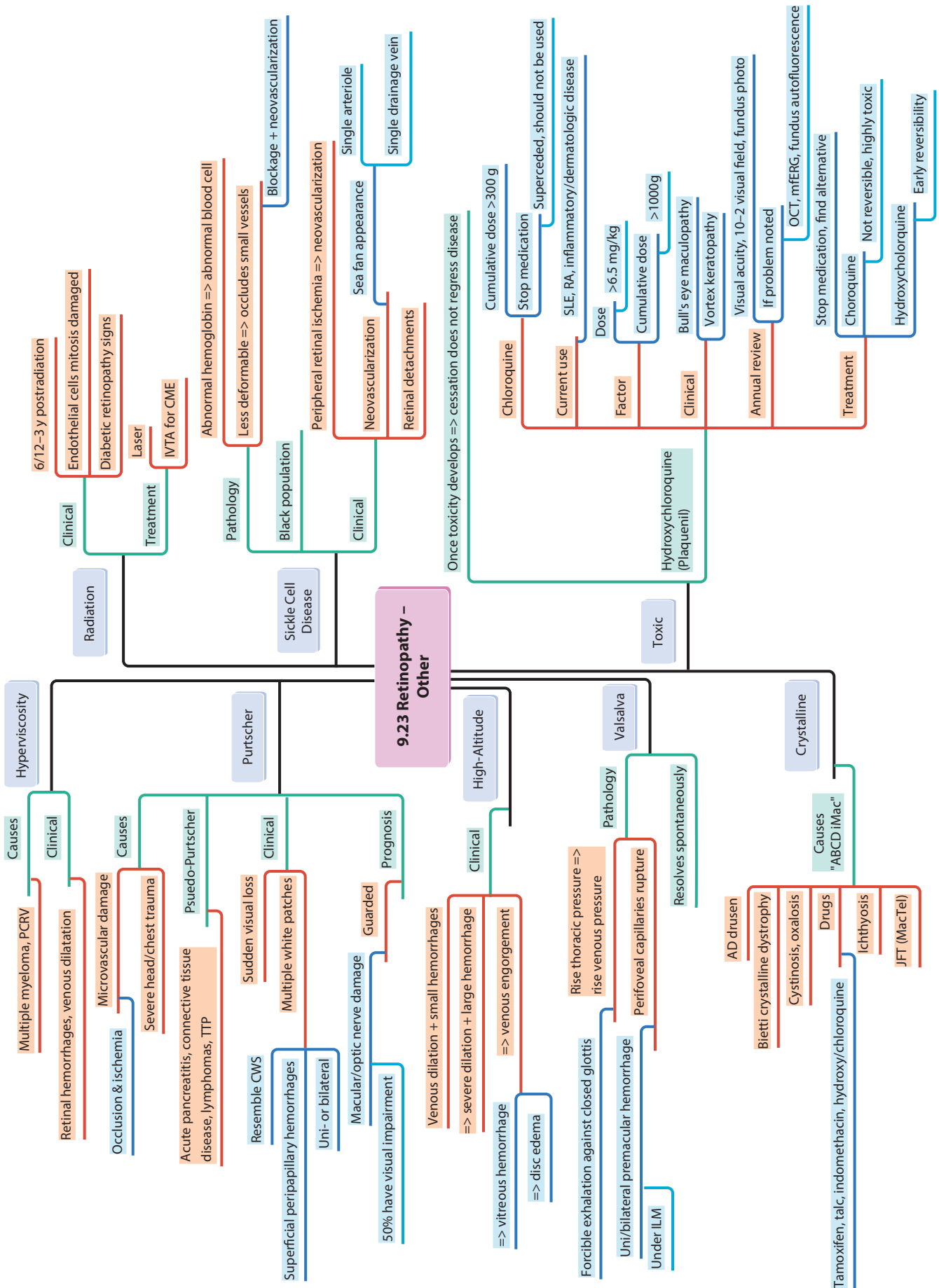


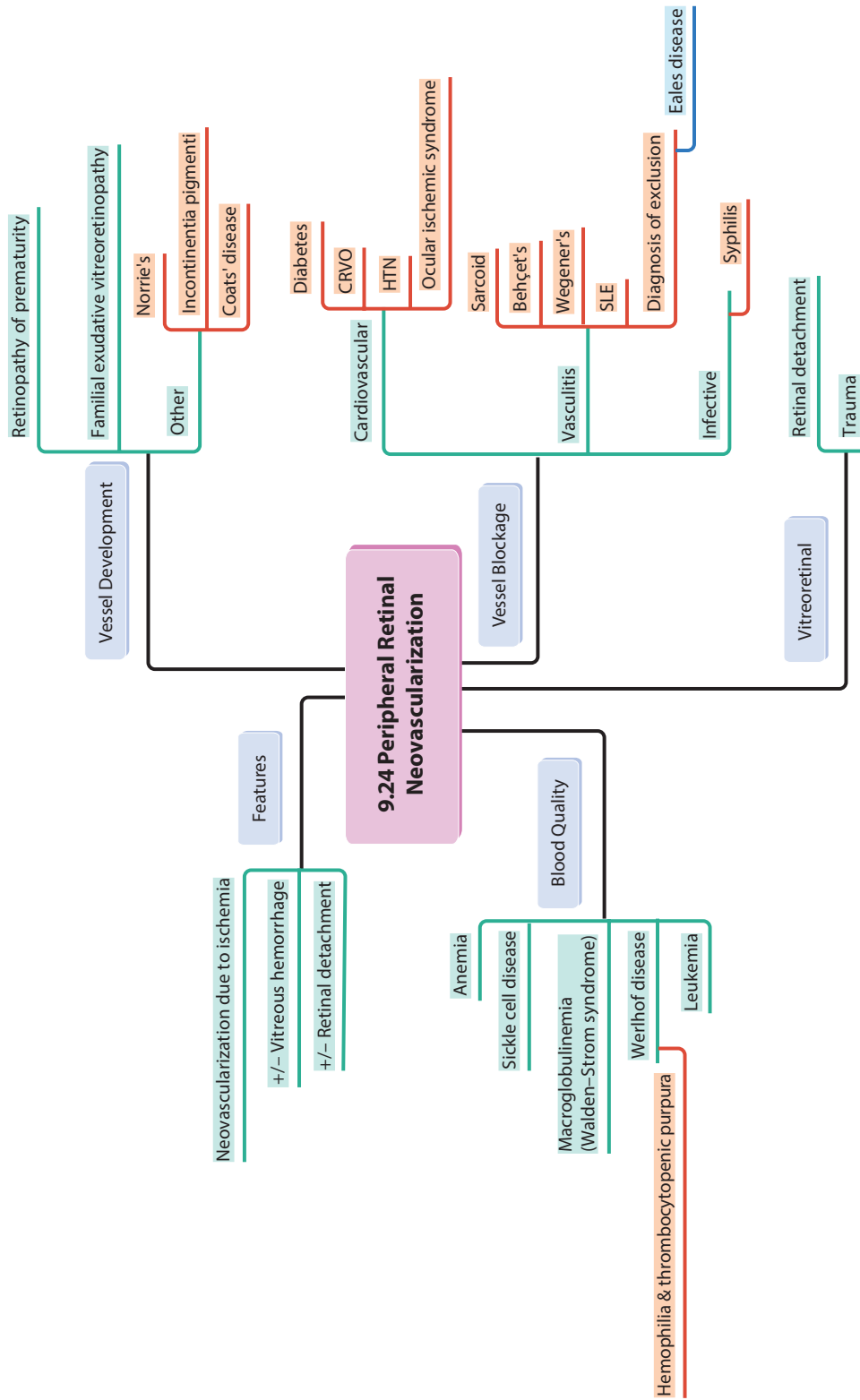


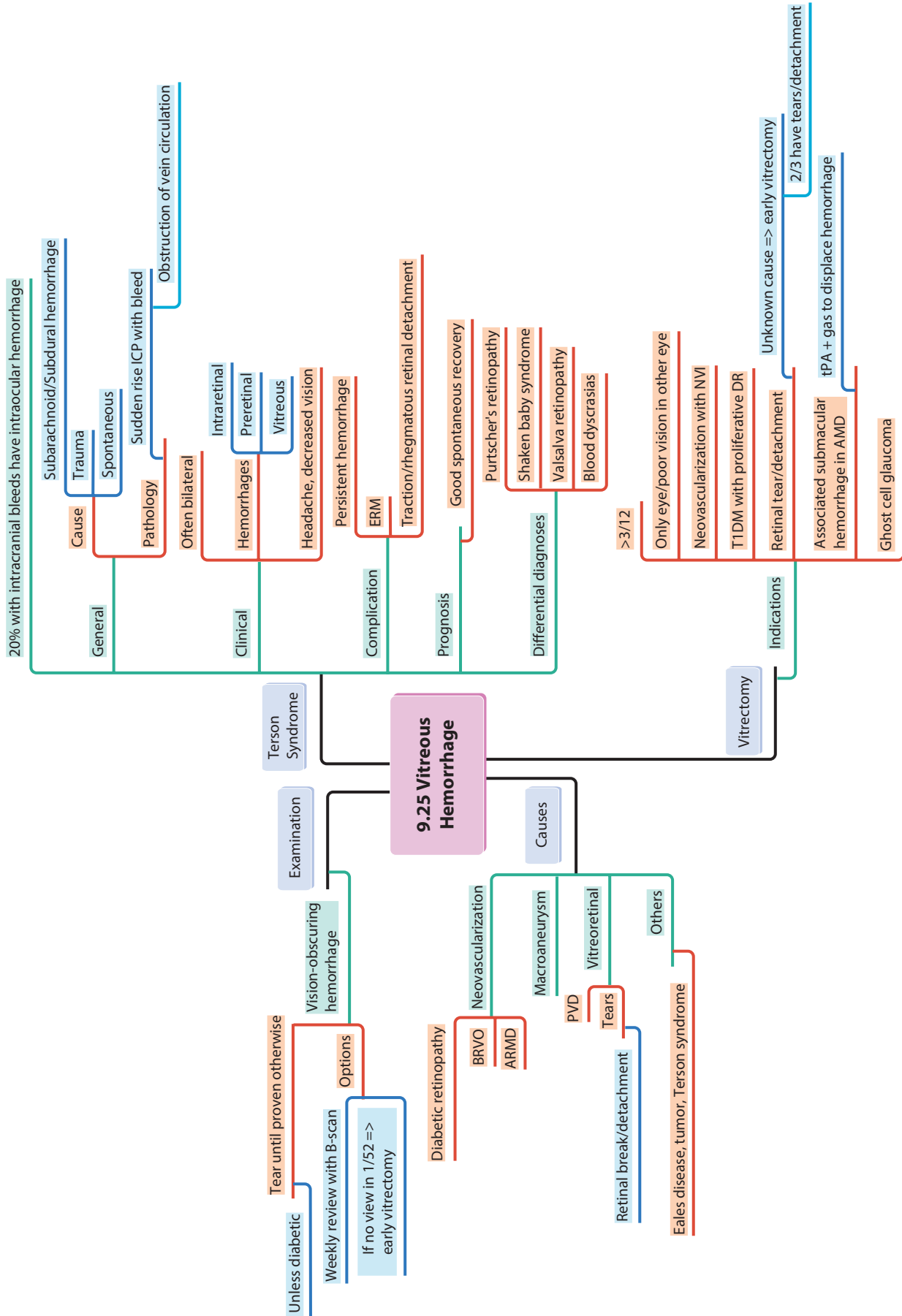


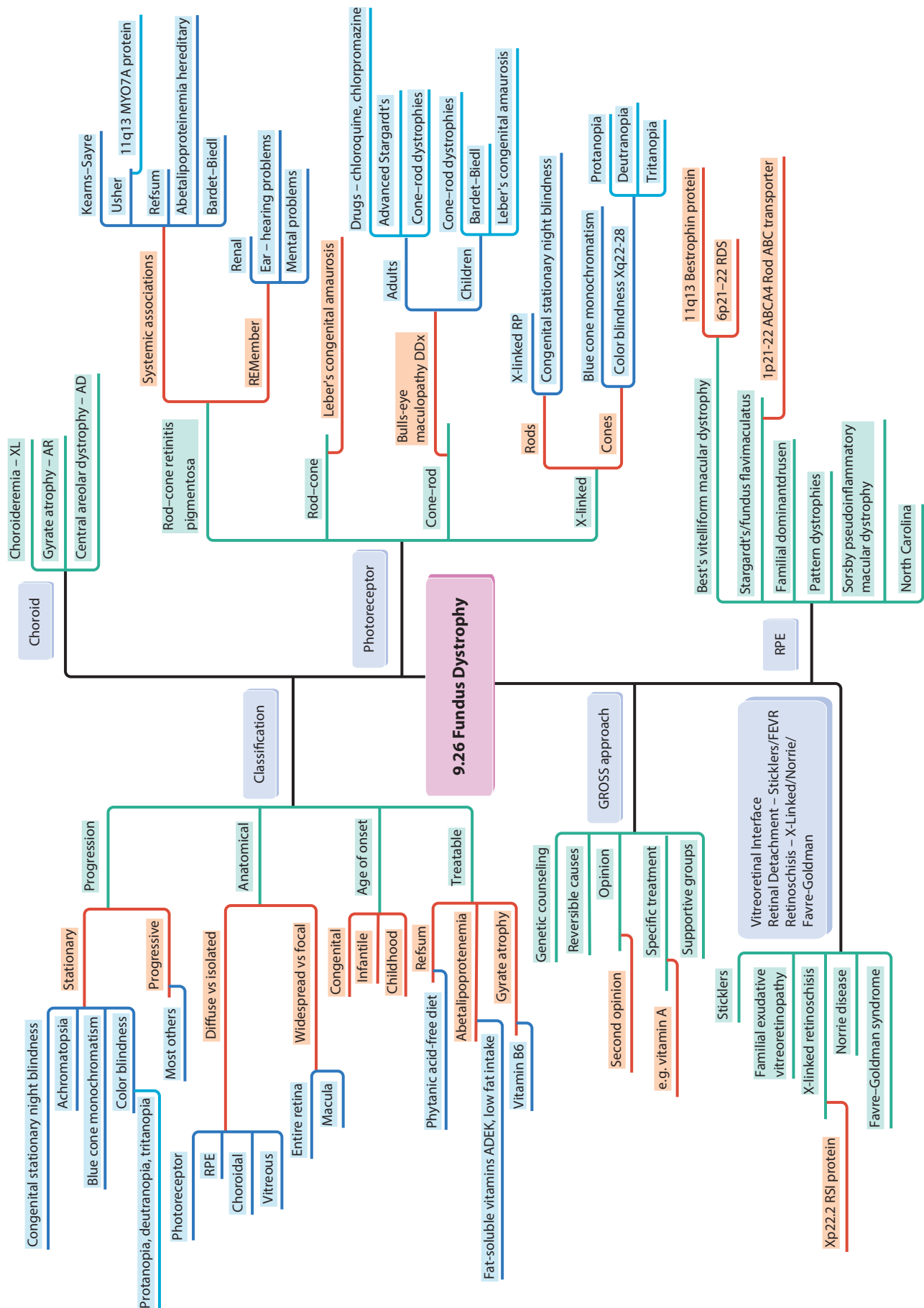












9.26 Fundus Dystrophy

Classification

- Choroid
 - Choroideremia - XL
 - Gyrate atrophy - AR
 - Central areolar dystrophy - AD
- Photoreceptor
 - Rod-cone
 - Cone-rod
 - X-linked

Progression

- Stationary
 - Achromatopsia
 - Blue cone monochromatism
 - Color blindness
- Progressive
 - Protanopia, deuteranopia, tritanopia

Anatomical

- Most others
 - Diffuse vs isolated
- Entire retina
 - RPE
 - Choroidal
 - Vitreous
- Macula
 - Widespread vs focal
 - Congenital
 - Infantile
 - Childhood

Age of onset

- Refsum
 - Phytanic acid-free diet
- Abetalipoproteinemia
 - Gyrate atrophy
 - Vitamin B6

Treatable

- Fat-soluble vitamins ADEK, low fat intake
- Vitamin B6

GROSS approach

- Genetic counseling
- Reversible causes
- Opinion
- Second opinion
- Specific treatment
 - e.g. vitamin A
- Supportive groups

Sticklers

- Vitreoretinal Interface
- Retinal Detachment - Sticklers/FEVR
- Retinoschisis - X-Linked/Norrie/
- Favre-Goldman
- Familial exudative vitreoretinopathy
- X-linked retinoschisis
- Norrie disease
- Favre-Goldman syndrome

Xp22.2 RSI protein

- Familial exudative vitreoretinopathy
- X-linked retinoschisis
- Norrie disease
- Favre-Goldman syndrome

Best's vitelliform macular dystrophy

- 11q13 Bestrophin protein
- 6p21-22 RDS

Stargardt's/fundus flavimaculatus

- 1p21-22 ABCA4 Rod ABC transporter

Familial dominant drusen

- Pattern dystrophies

Sorsby pseudoinflammatory macular dystrophy

- North Carolina

REMember

- Renal
- Ear - hearing problems
- Mental problems

Leber's congenital amaurosis

- Drugs - chloroquine, chlorpromazine
- Advanced Stargardt's
- Cone-rod dystrophies
- Cone-rod dystrophies
- Bardet-Biedl
- Leber's congenital amaurosis

Bulls-eye maculopathy DDX

- Adults
- Children

X-linked RP

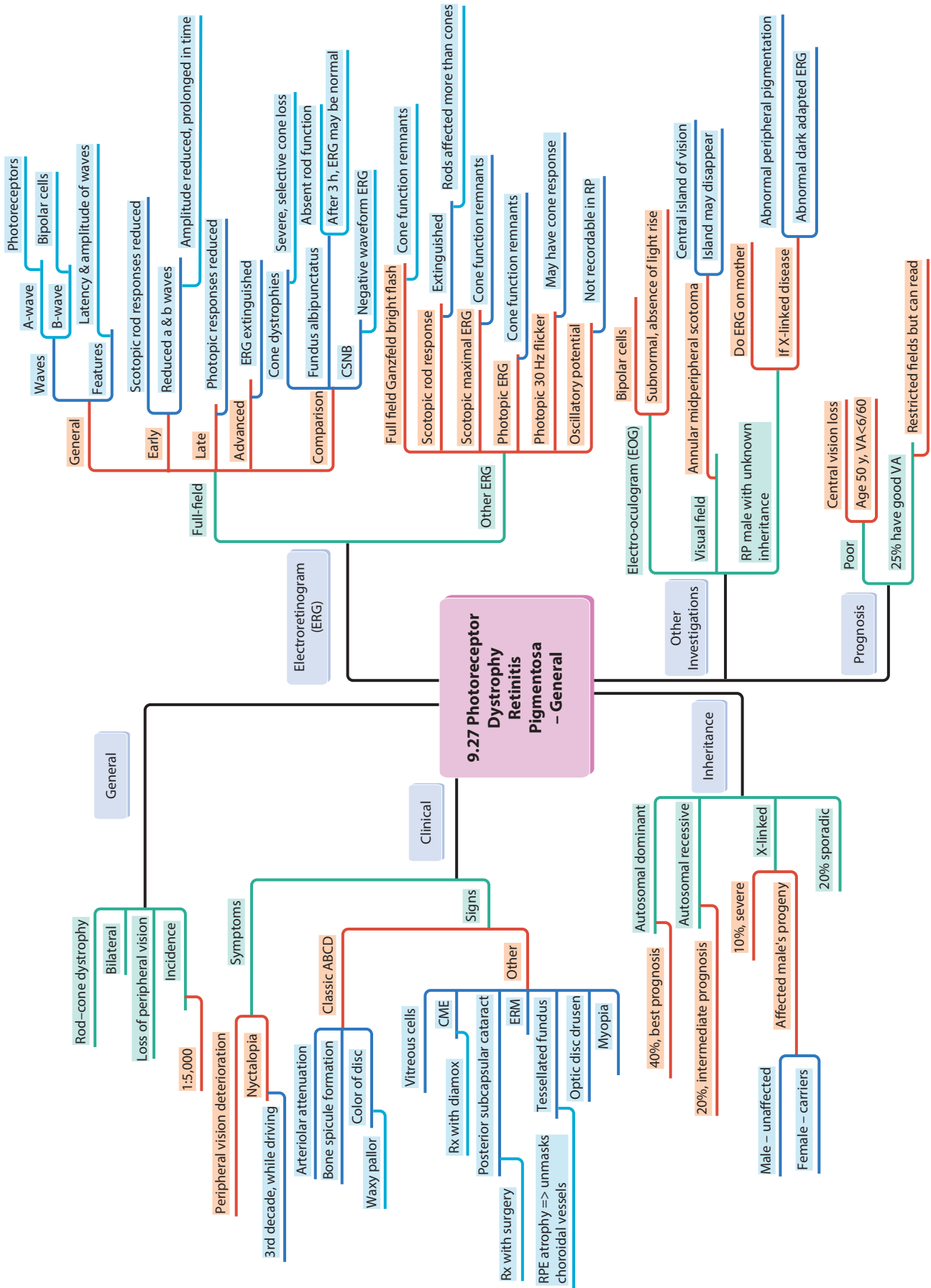
- Congenital stationary night blindness
- Blue cone monochromatism
- Color blindness Xq22-28

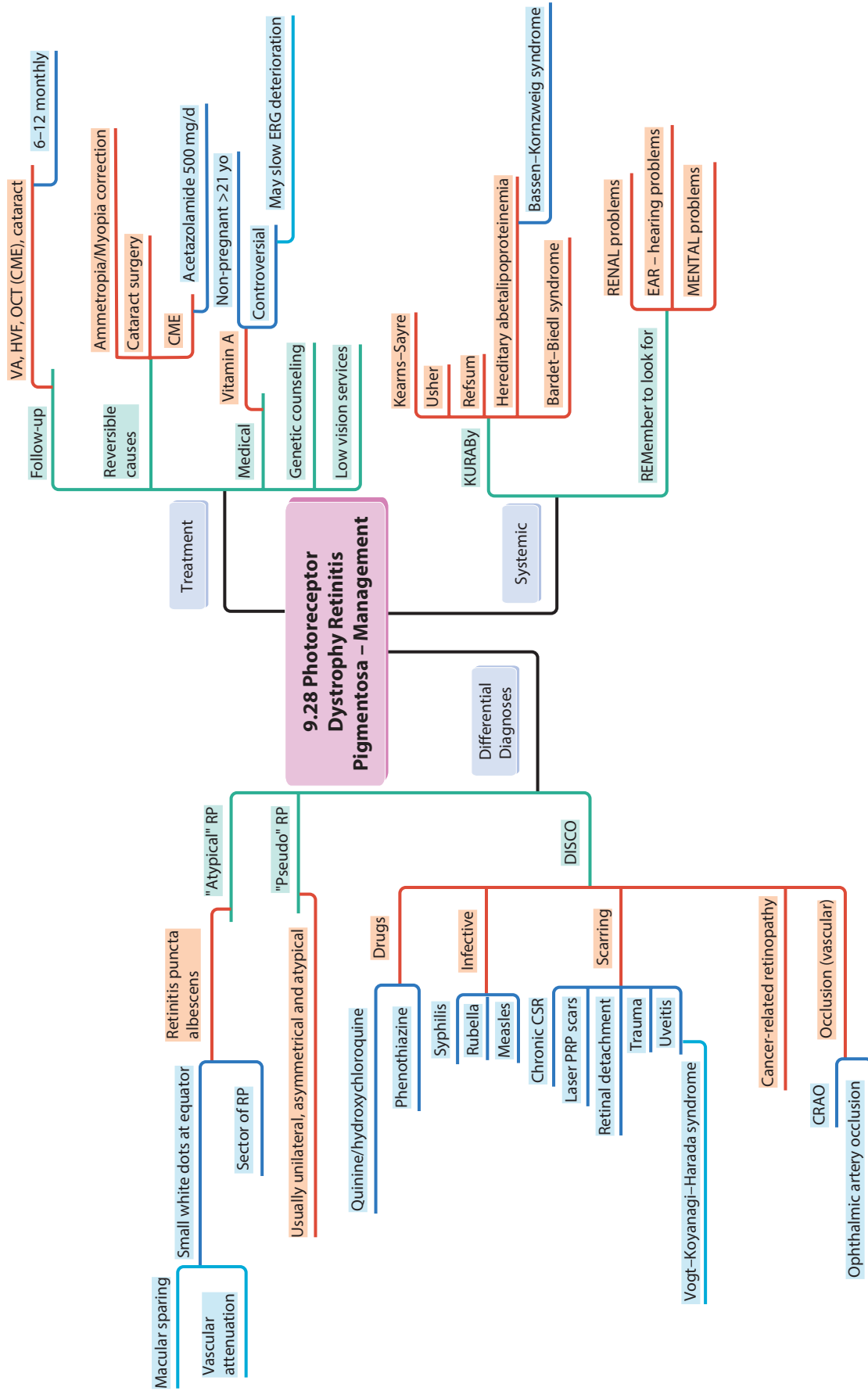
Rods

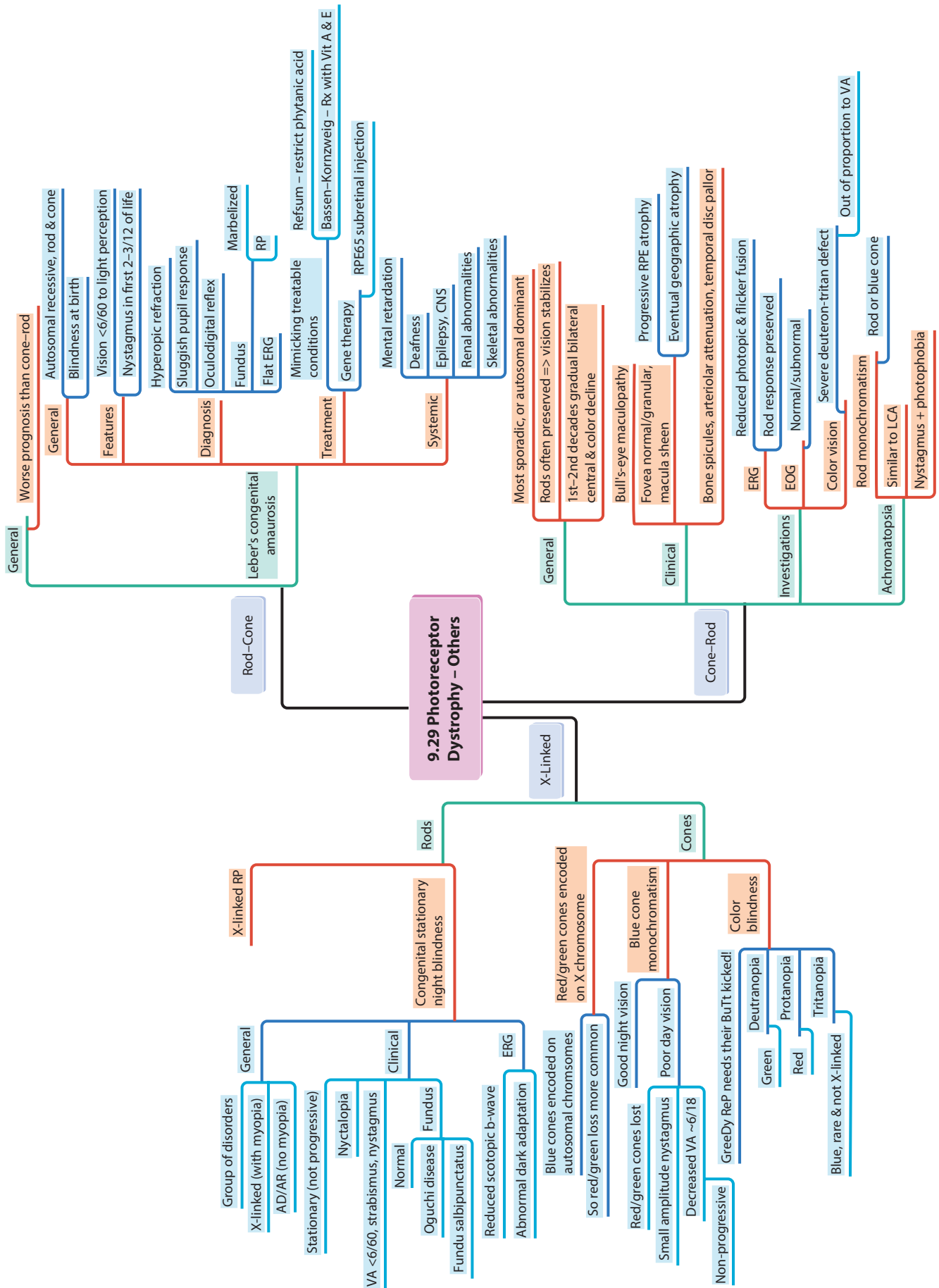
- Congenital stationary night blindness
- Blue cone monochromatism
- Color blindness Xq22-28

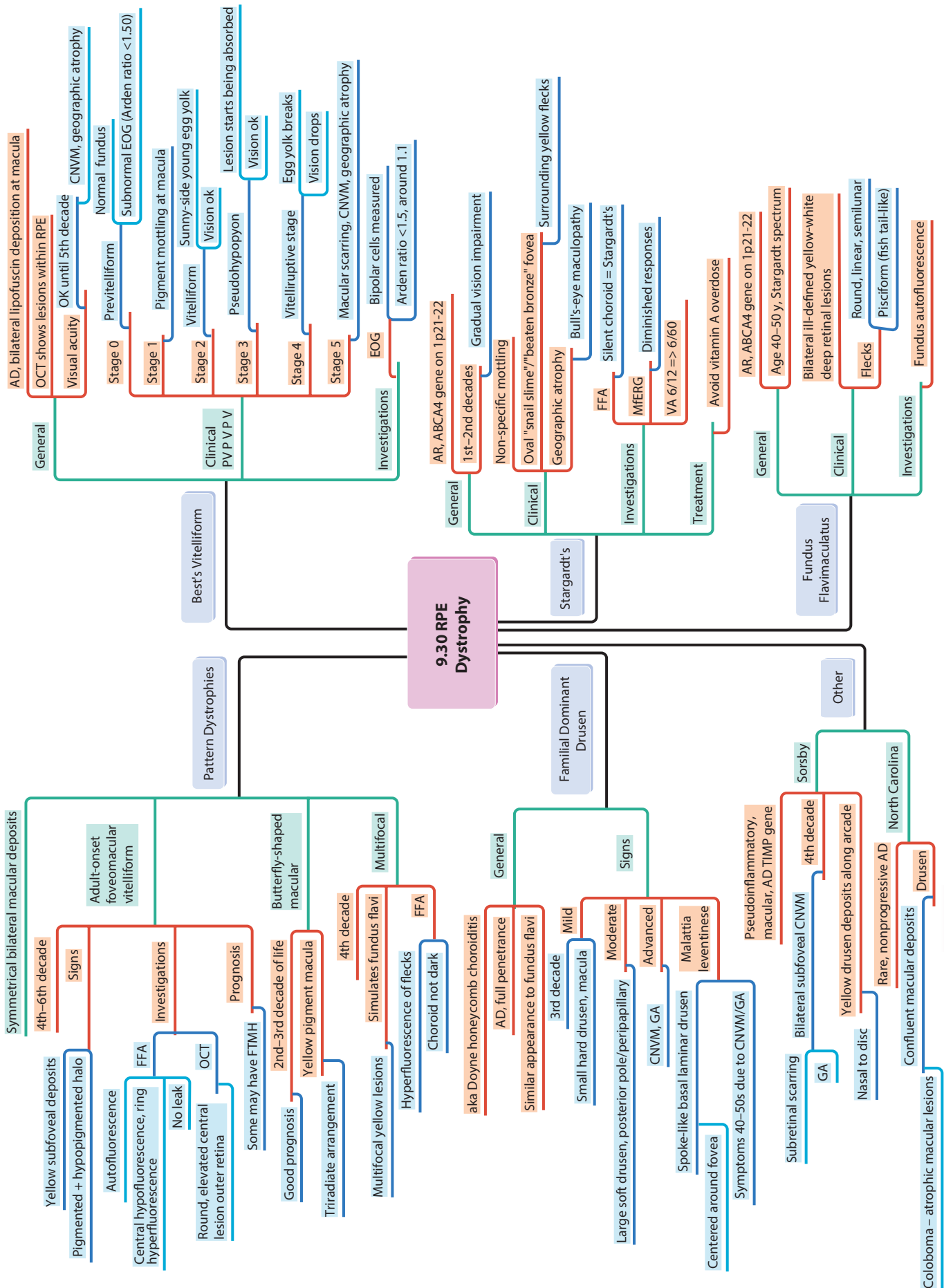
Cones

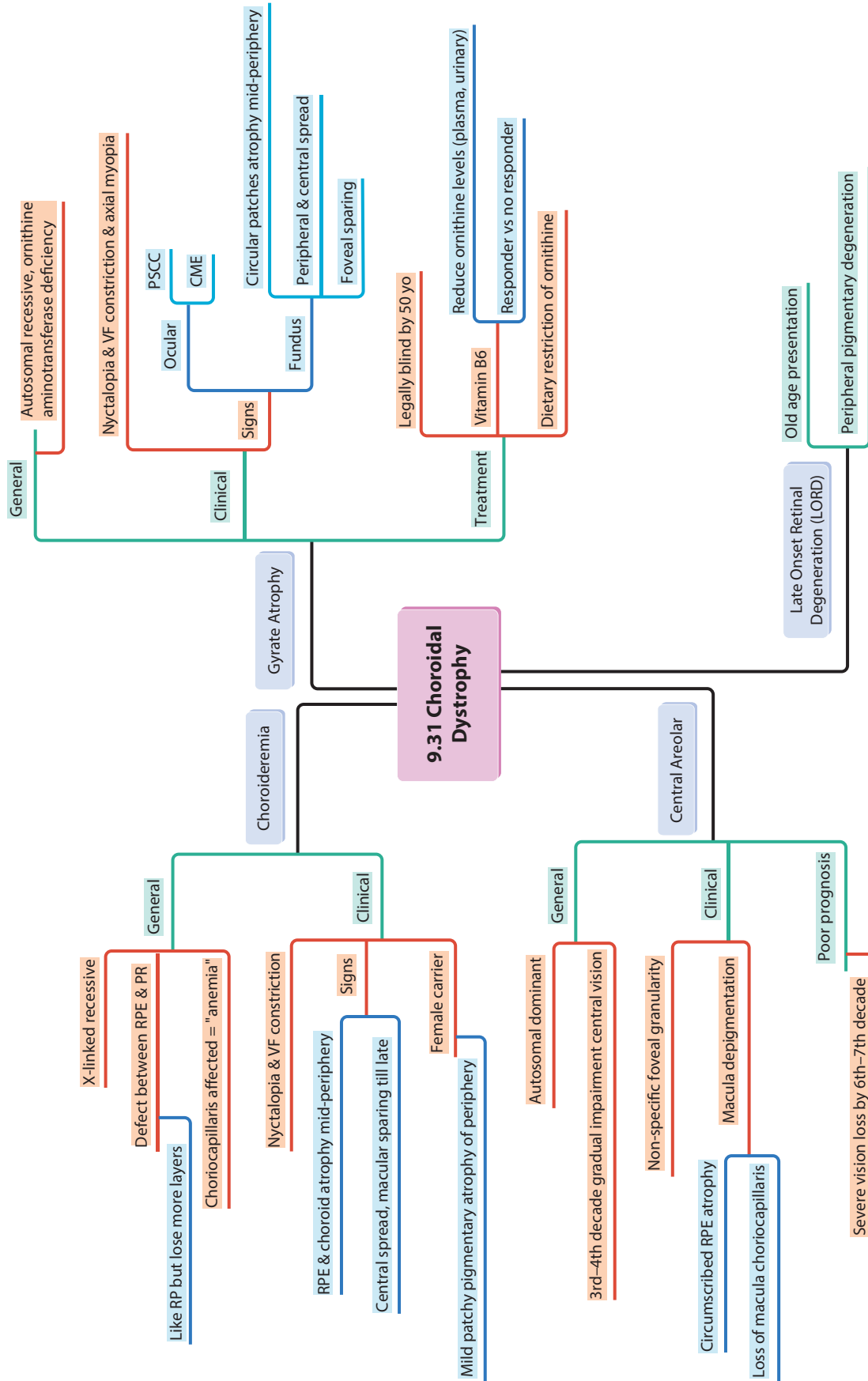
- Protanopia
- Deuteranopia
- Tritanopia

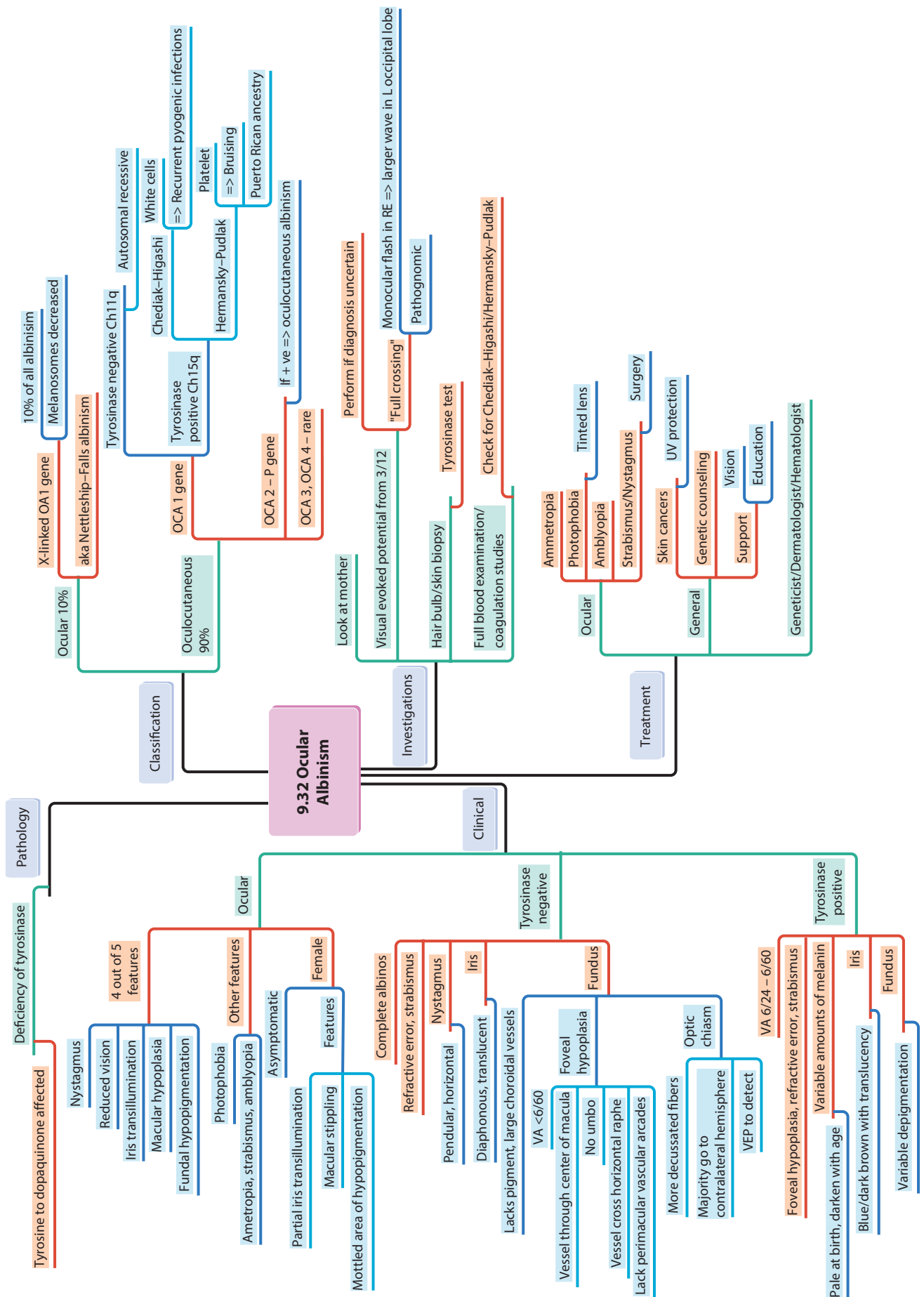












Pathology

Deficiency of tyrosinase

Tyrosine to dopaquinone affected

- Nystagmus
- Reduced vision
- Iris transillumination
- Macular hypoplasia
- Fundal hypopigmentation

4 out of 5 features

Other features

- Photophobia
- Ametropia, strabismus, amblyopia
- Asymptomatic
- Partial iris transillumination
- Macular stippling
- Mottled area of hypopigmentation

9.32 Ocular Albinism

Classification

Ocular 10%

Ocular 90%

- X-linked OA1 gene
- Melanosomes decreased
- aka Nettleship-Falls albinism
- Tyrosinase negative Ch11q
- Autosomal recessive
- Chediak-Higashi
- Hermansky-Pudlak
- White cells => Recurrent pyogenic infections
- Platelet => Bruising
- Puerto Rican ancestry
- OCA 1 gene
- Tyrosinase positive Ch15q
- OCA 2 - P gene
- If + ve => oculocutaneous albinism
- OCA 3, OCA 4 - rare

Investigations

Look at mother

- Visual evoked potential from 3/12
- Hair bulb/skin biopsy
- Full blood examination/coagulation studies

Perform if diagnosis uncertain

Clinical

Complete albinos

- Refractive error, strabismus
- Nystagmus
- Iris
- Pendular, horizontal
- Diaphanous, translucent
- Lacks pigment, large choroidal vessels
- VA <6/60
- Foveal hypoplasia
- No umbo
- Vessel cross horizontal raphe
- Lack perimacular vascular arcades

Tyrosinase negative

- More decussated fibers
- Majority go to contralateral hemisphere
- VEP to detect
- VA 6/24 - 6/60
- Foveal hypoplasia, refractive error, strabismus

Tyrosinase positive

- Pale at birth, darken with age
- Blue/dark brown with translucency
- Variable depigmentation
- Variable amounts of melanin

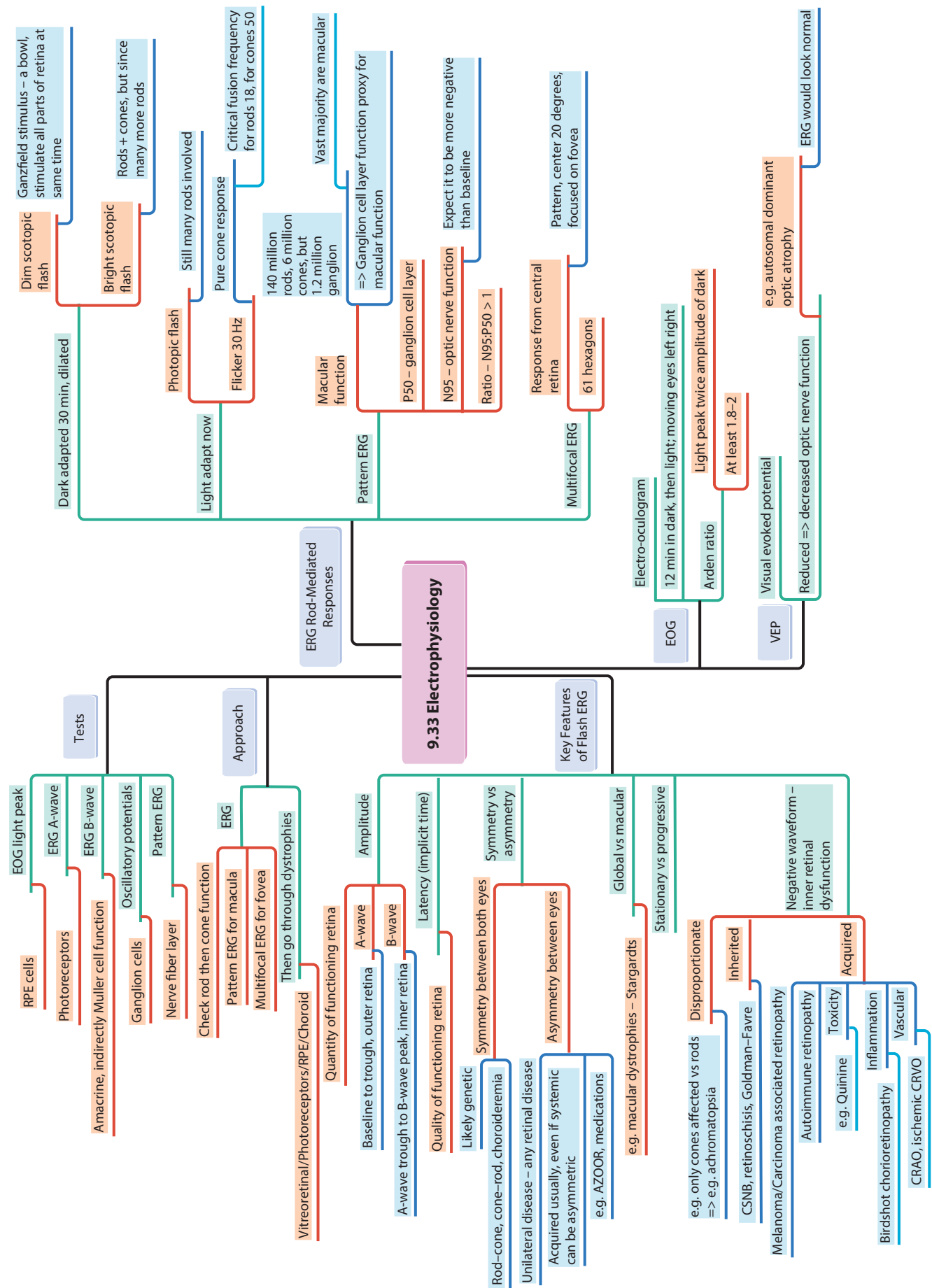
Treatment

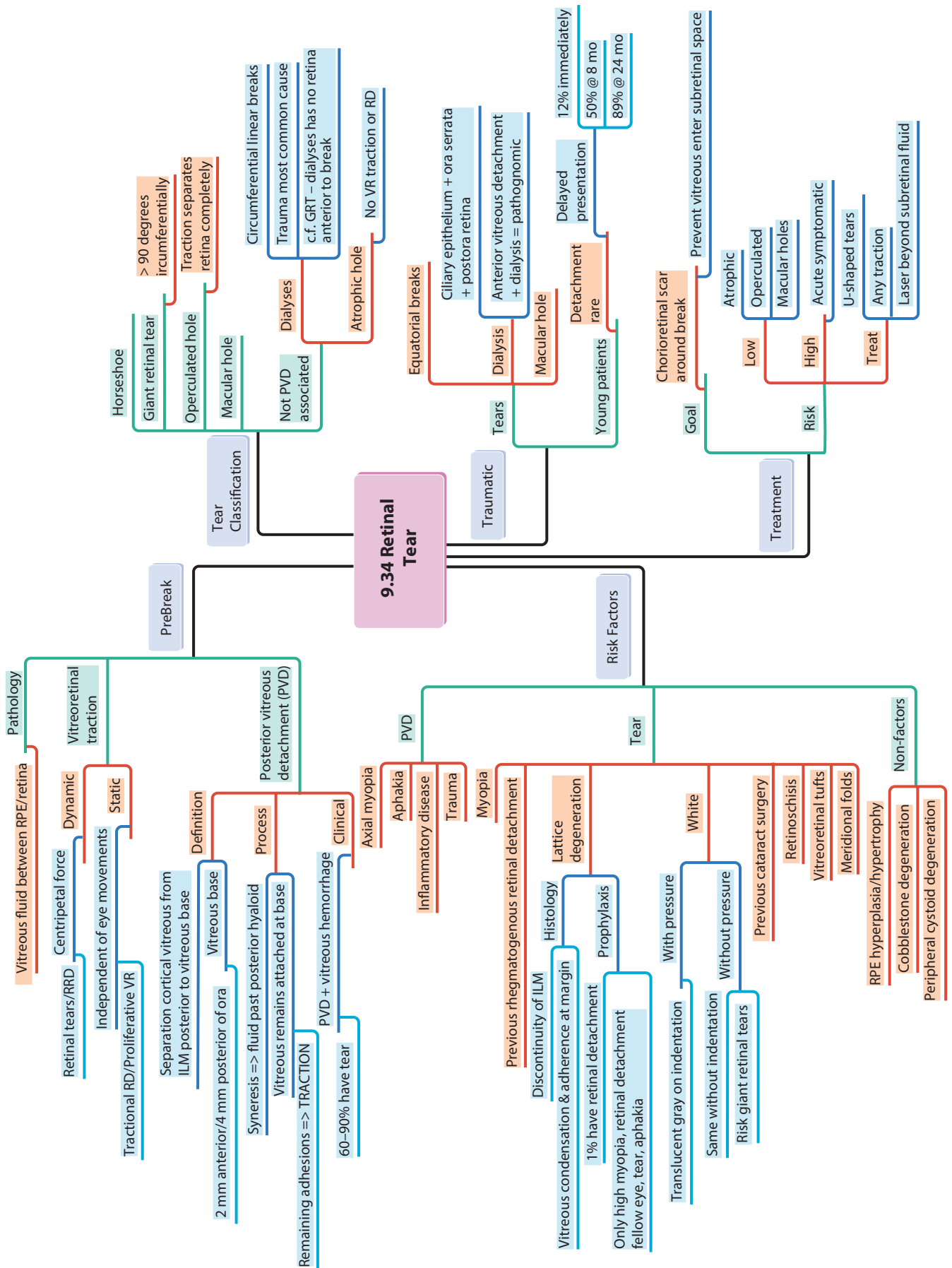
Ocular

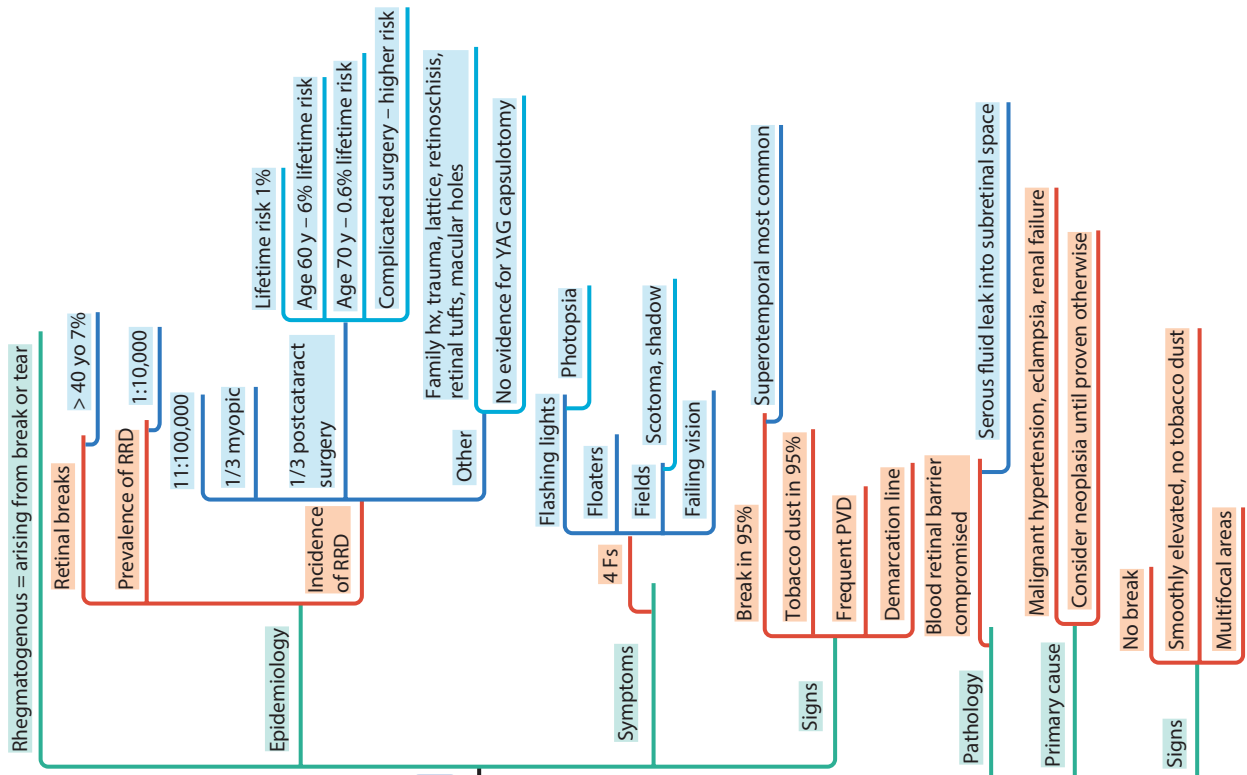
- Ammetropia
- Photophobia
- Amblyopia
- Strabismus/Nystagmus
- Surgery
- Skin cancers
- UV protection

General

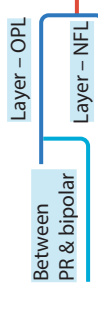
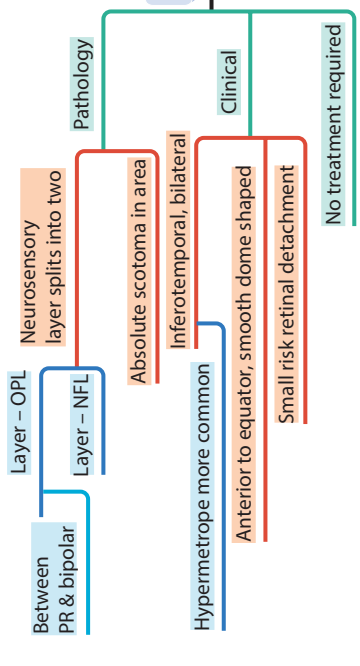
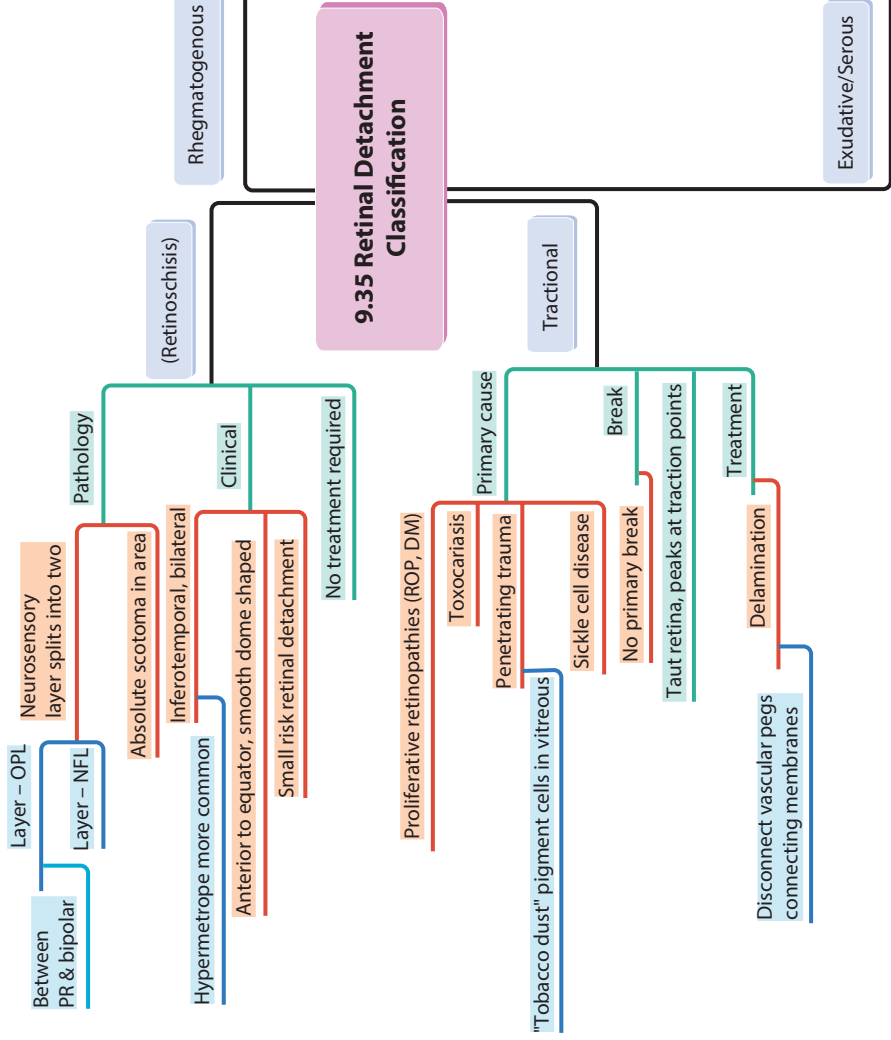
- Genetic counseling
- Support
- Vision
- Education
- Geneticist/Dermatologist/Hematologist

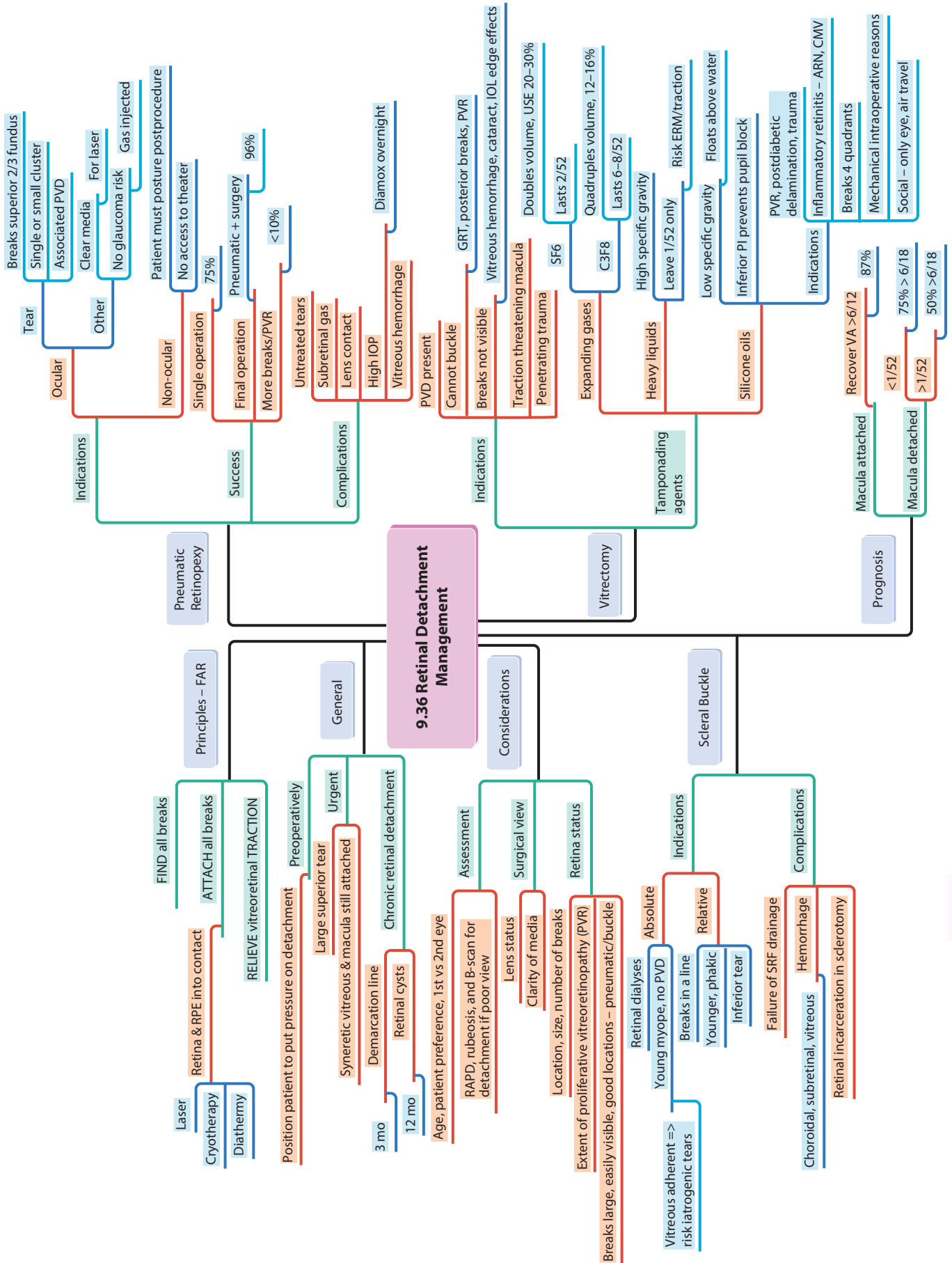


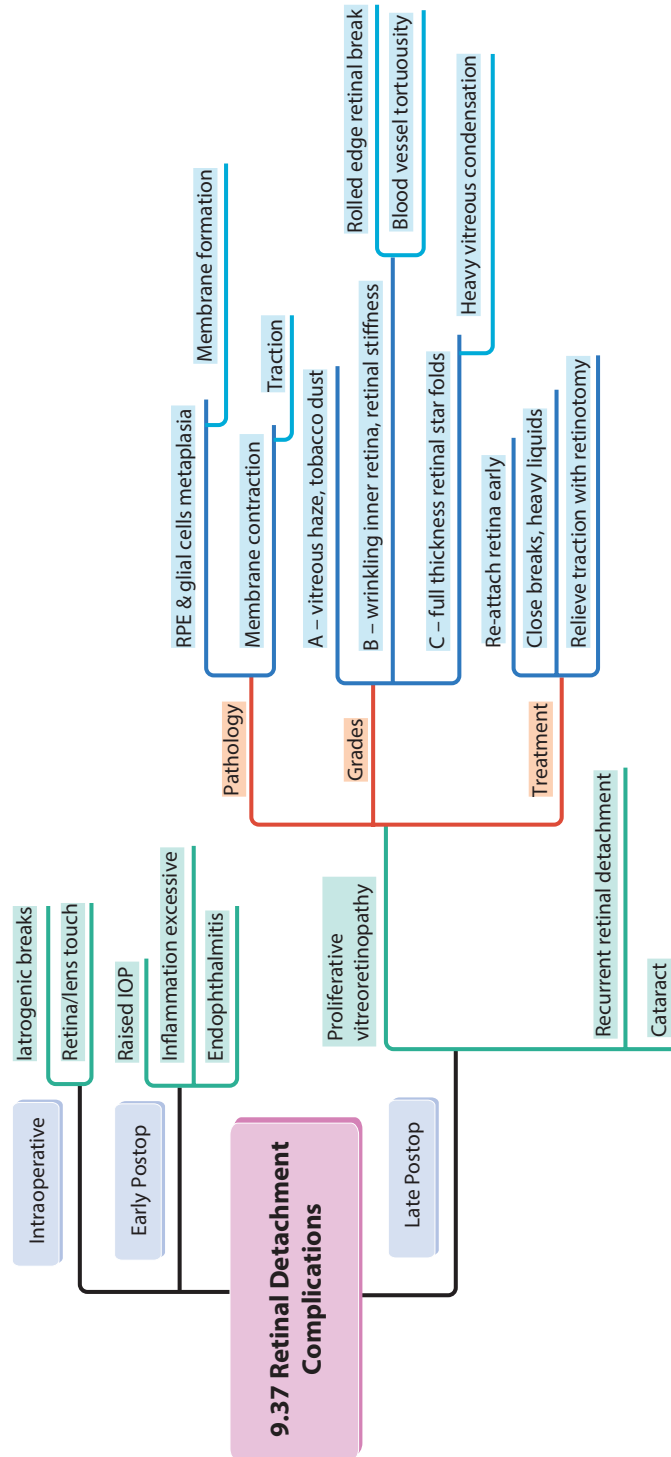


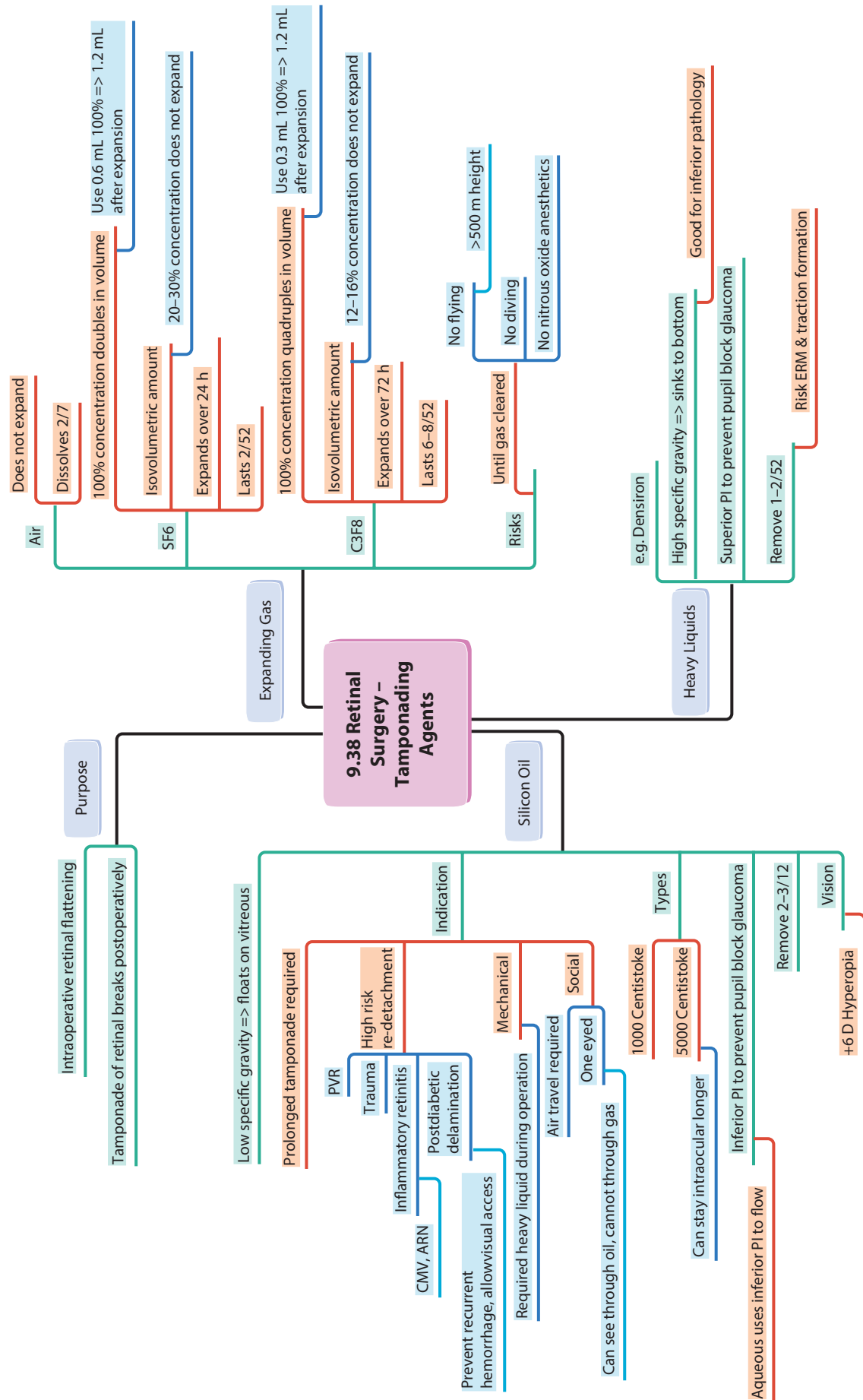


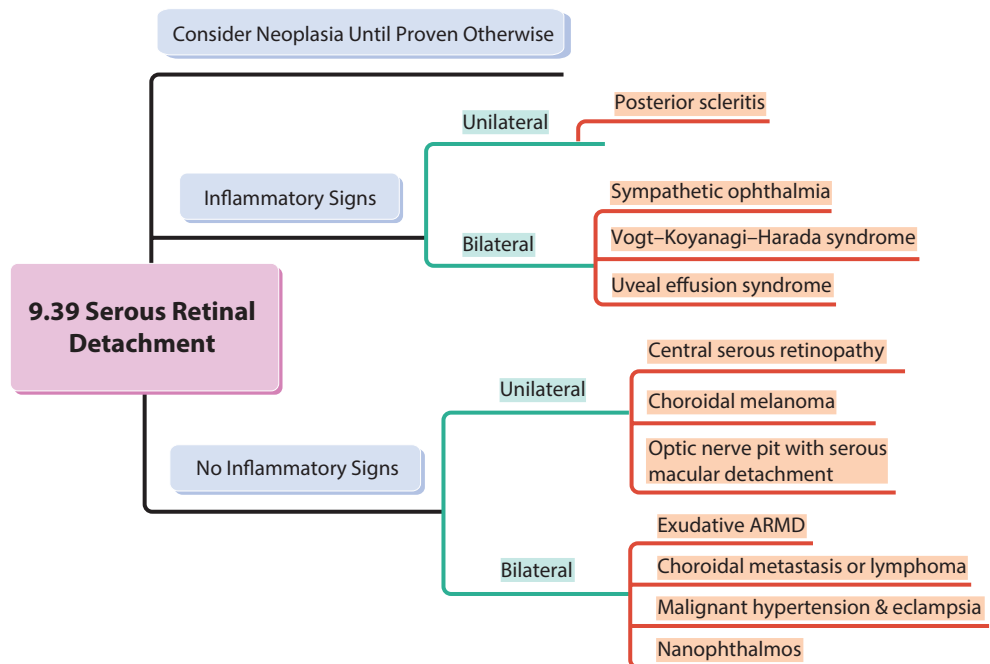
9.35 Retinal Detachment Classification



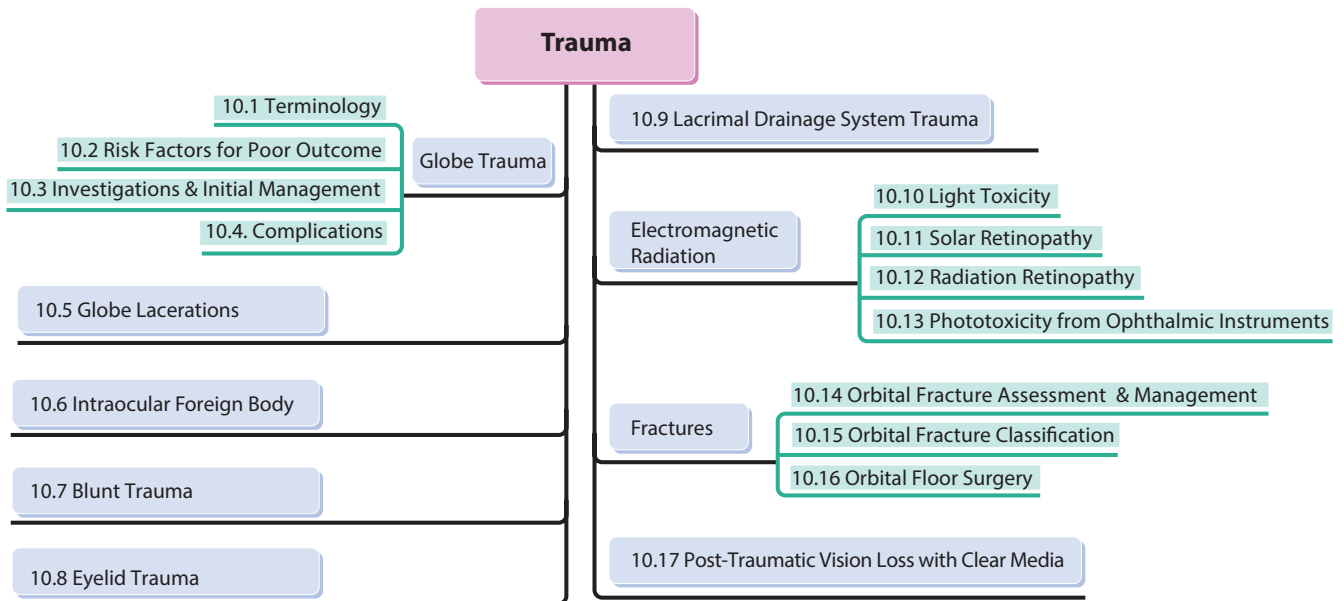


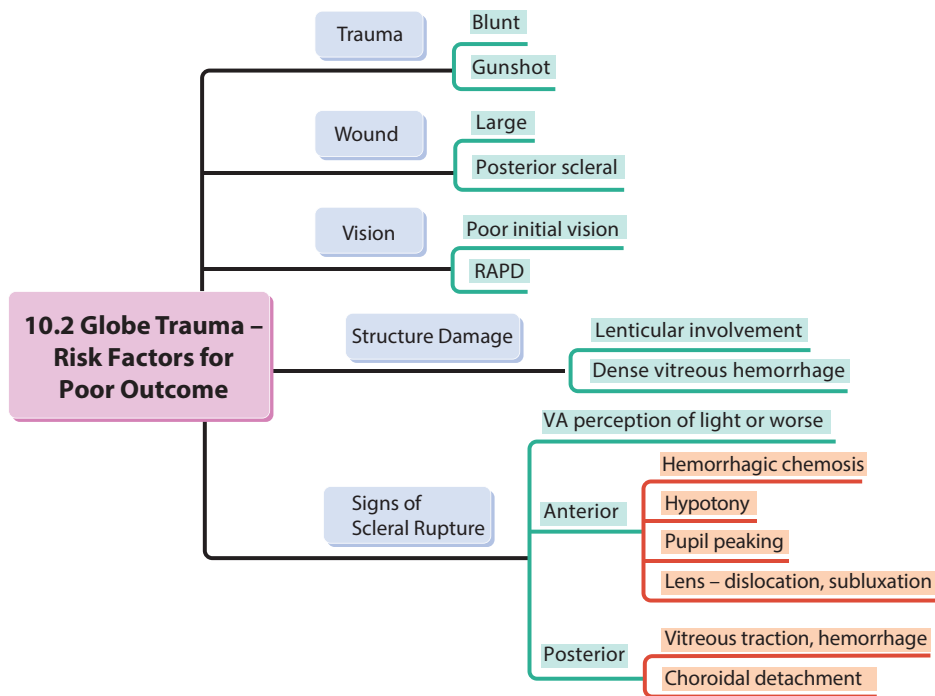
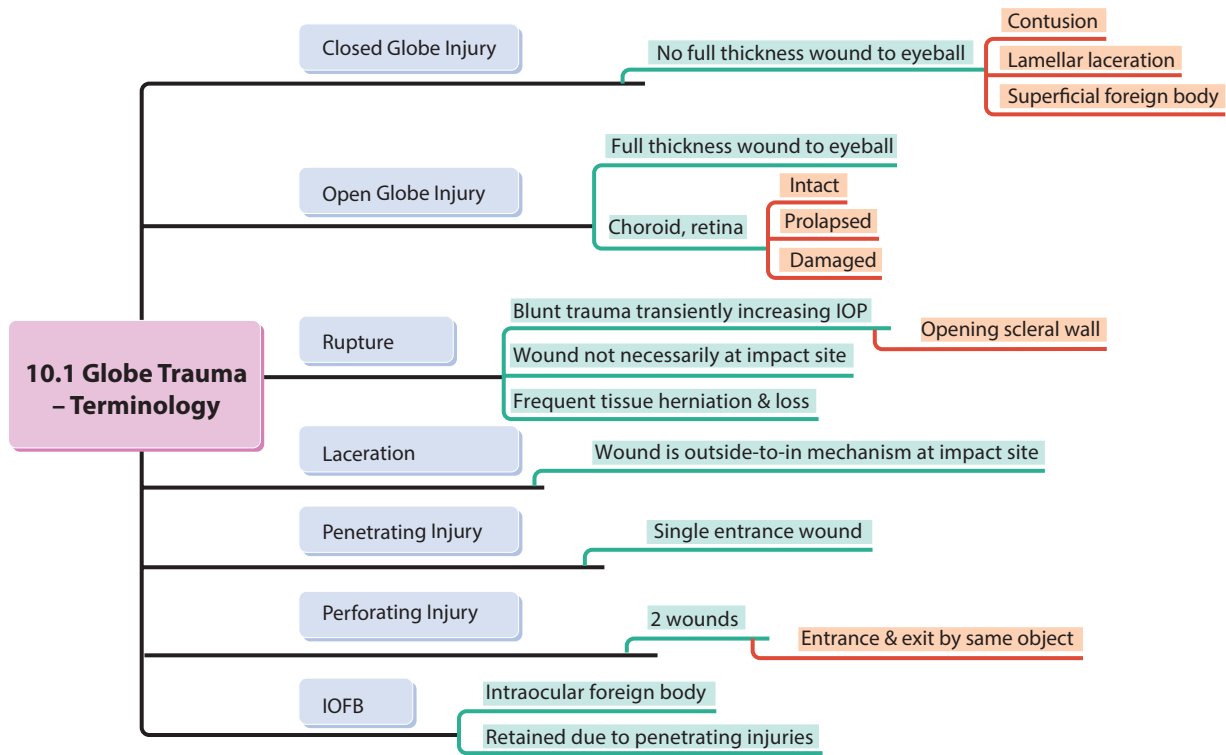


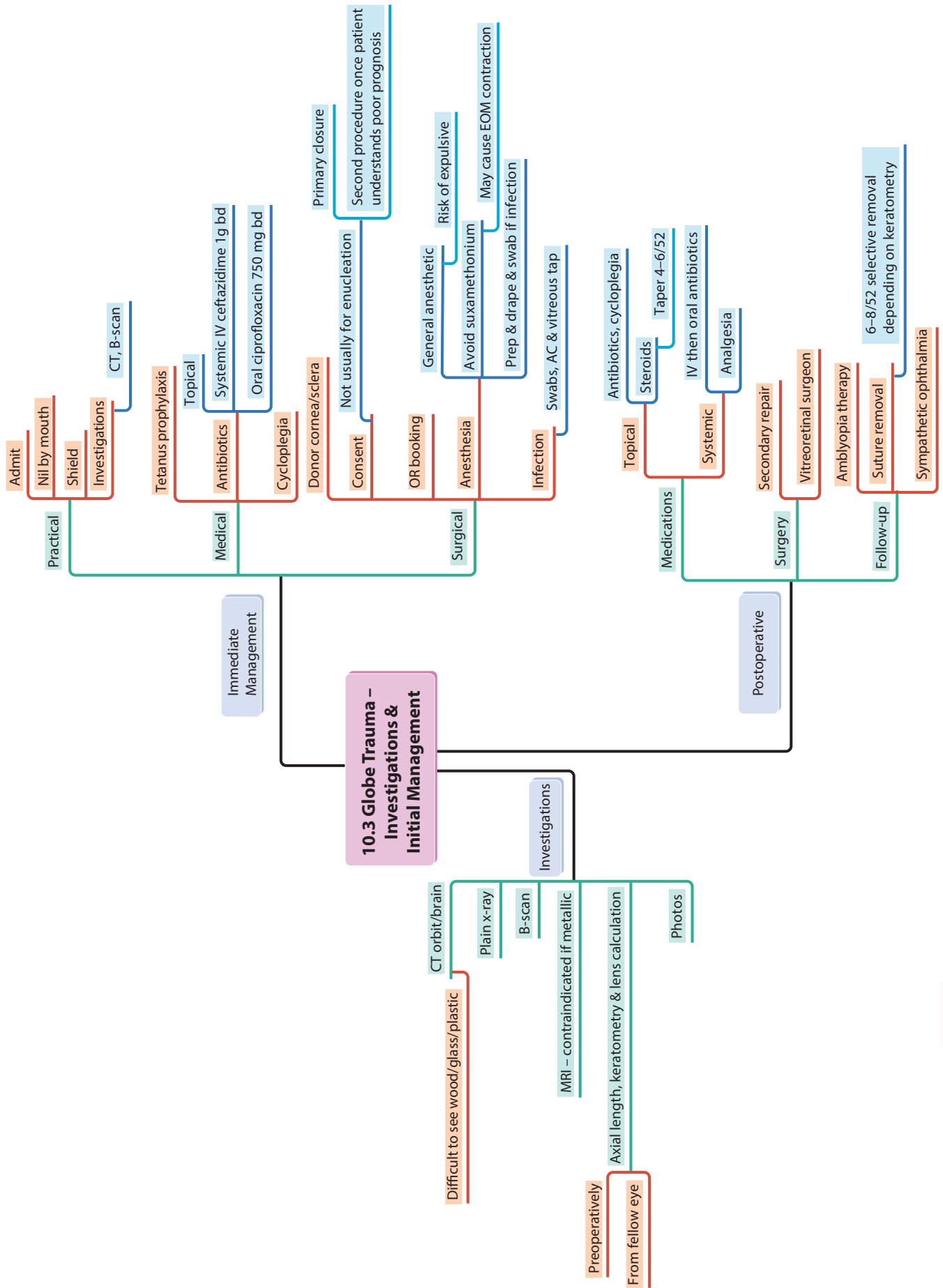


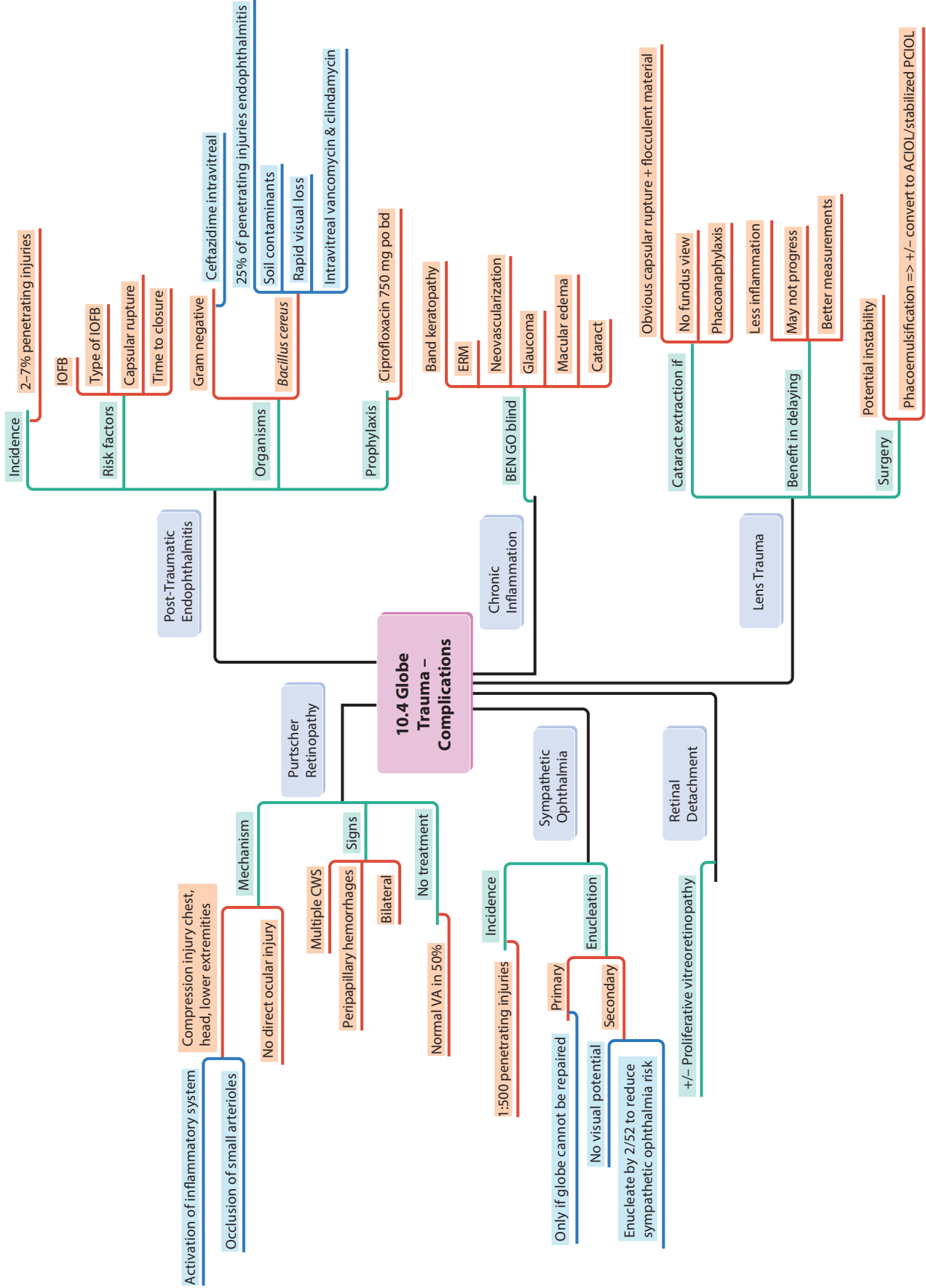


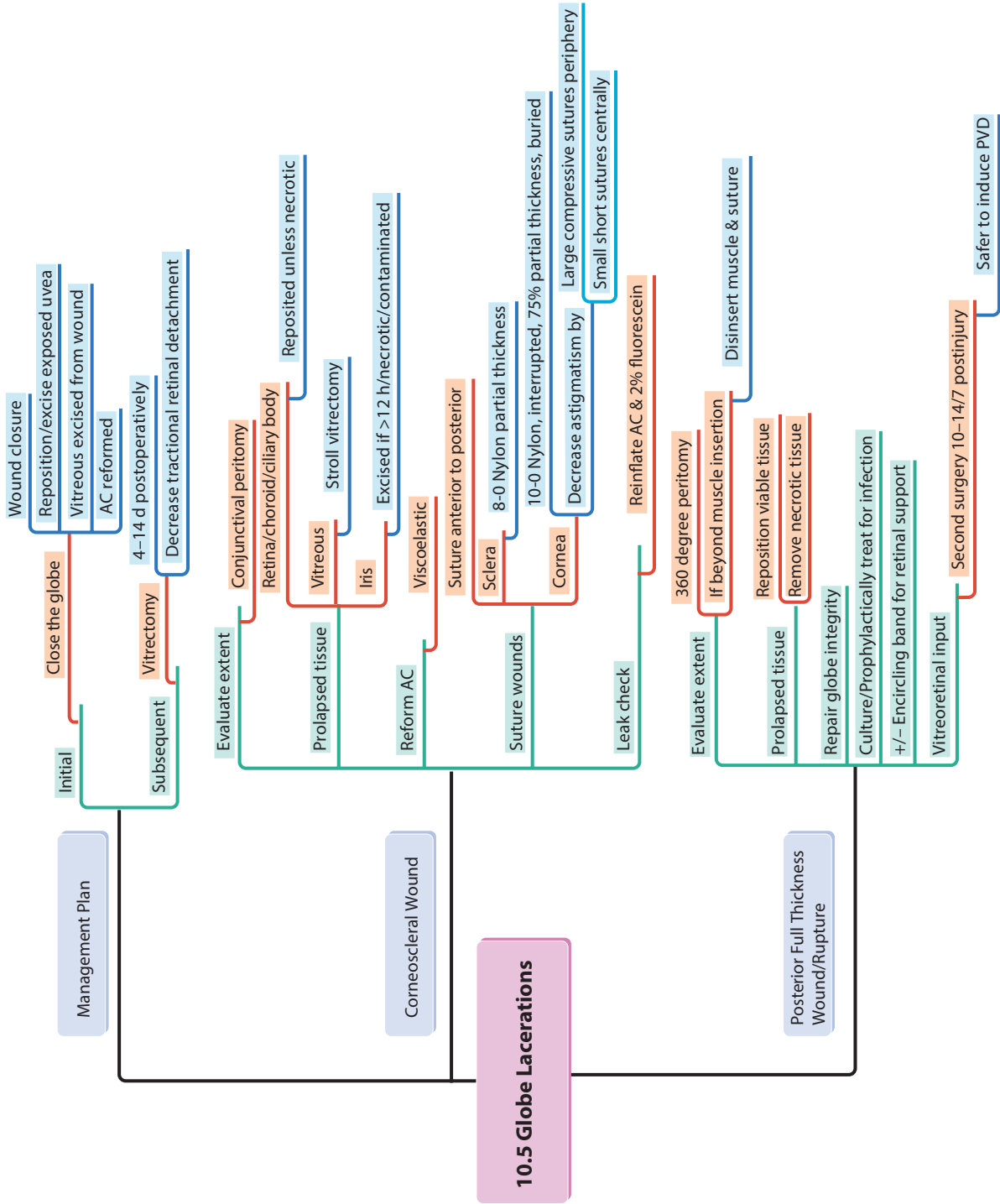
10 Trauma

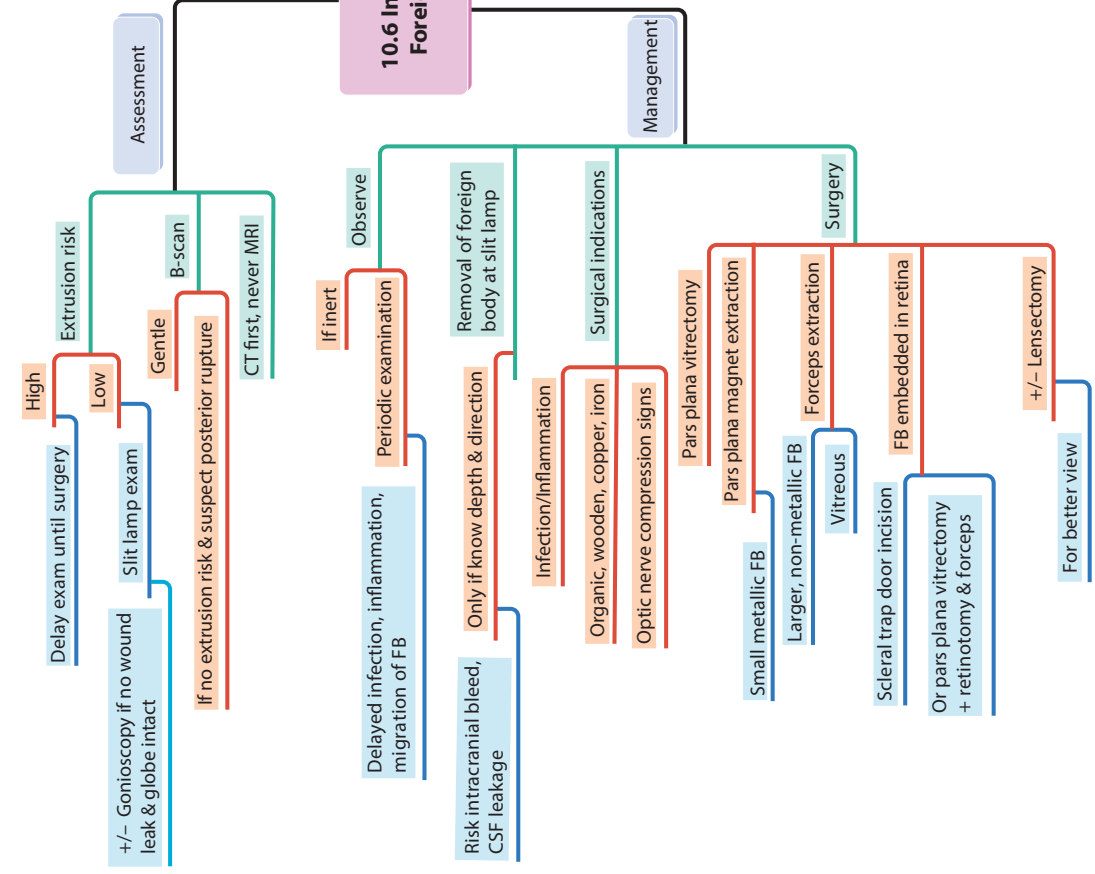
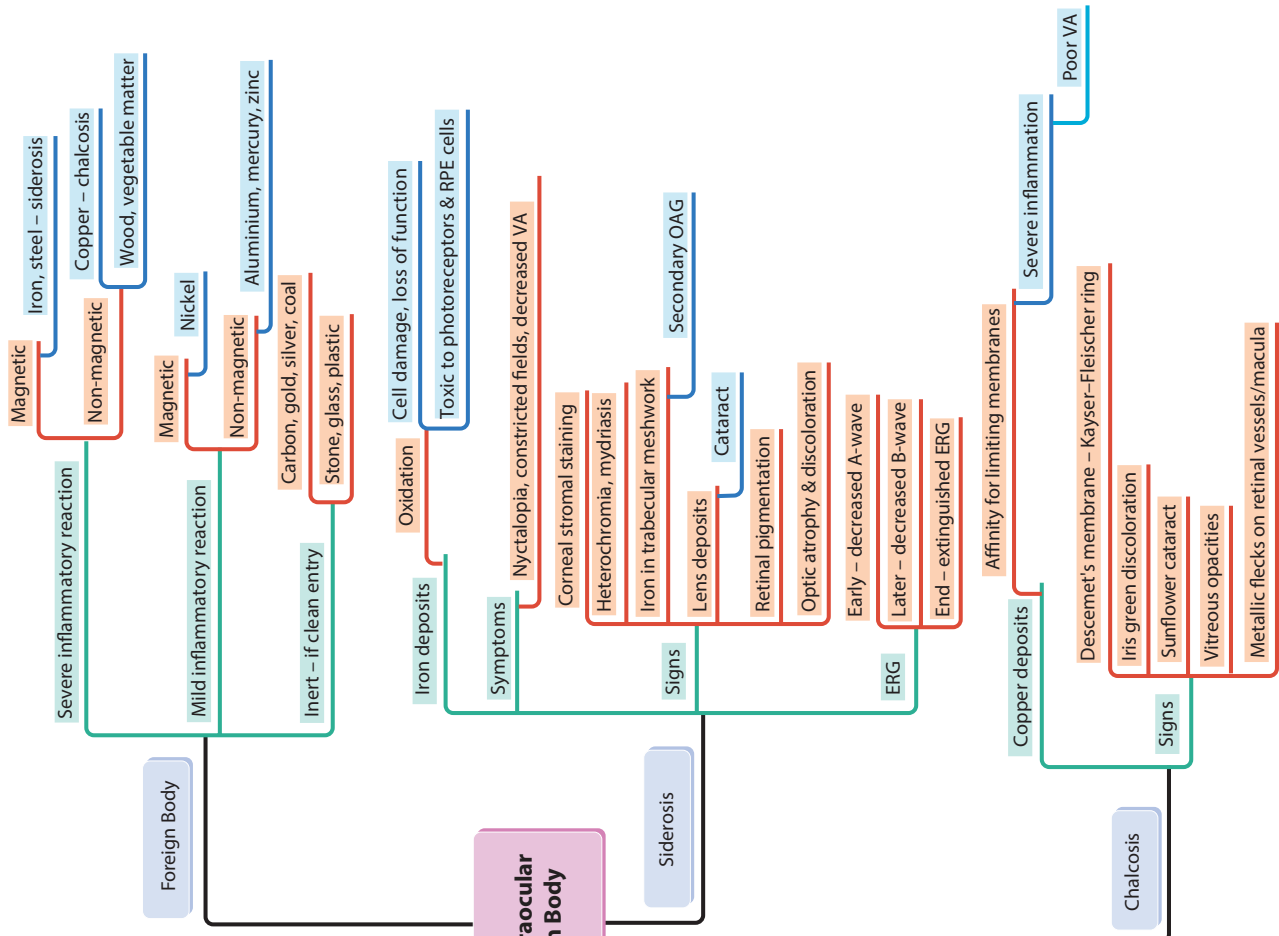


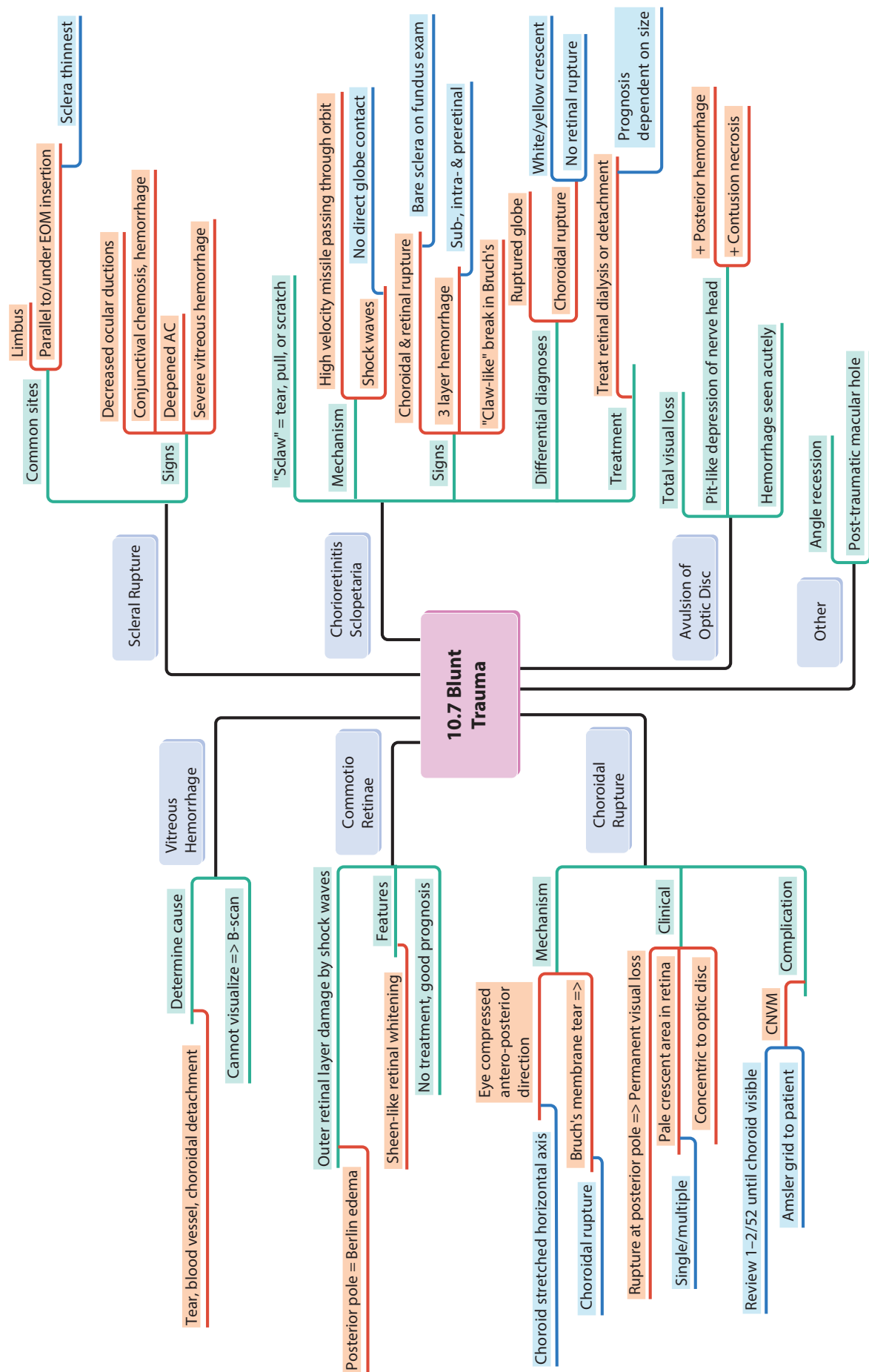


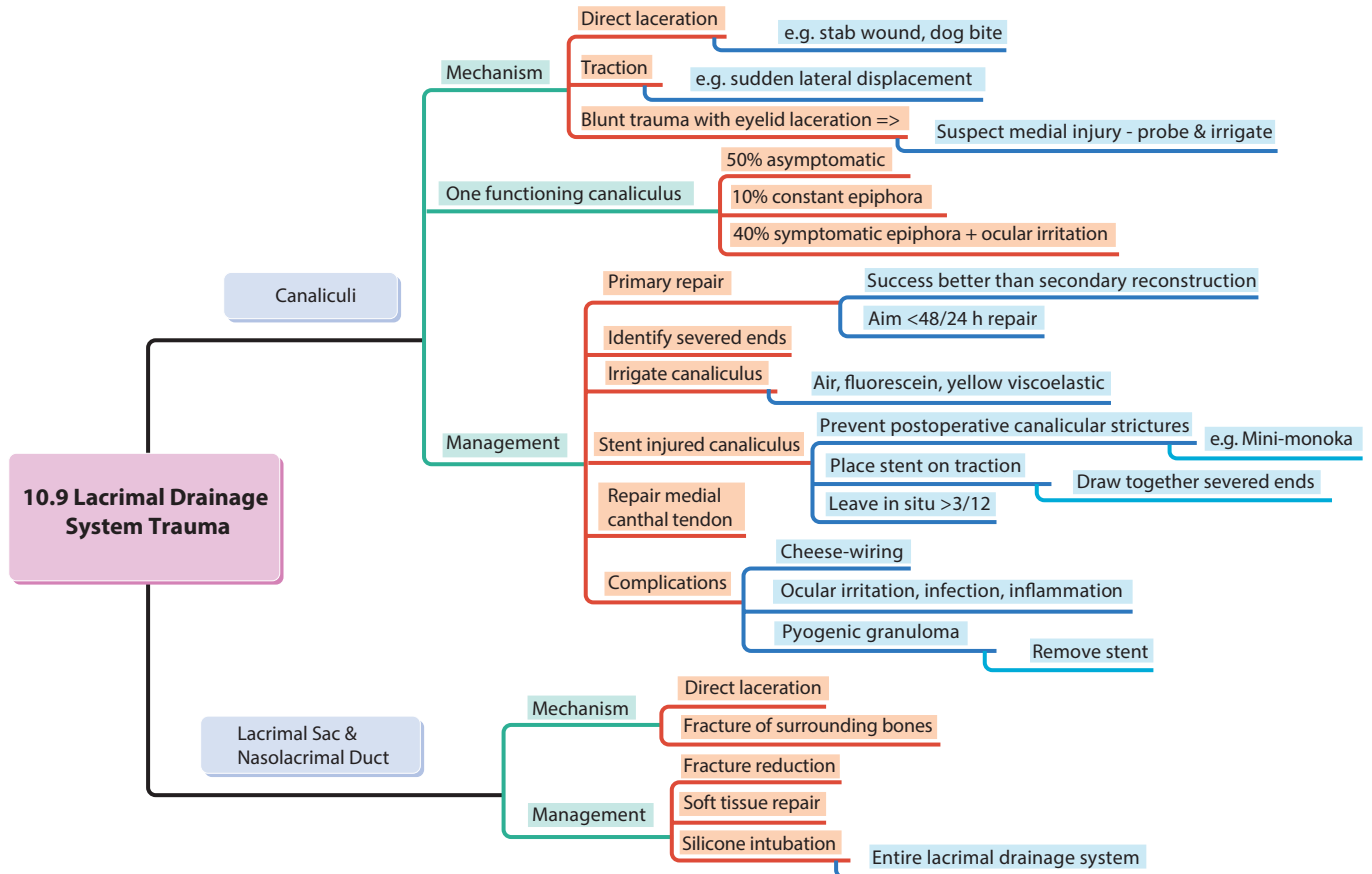
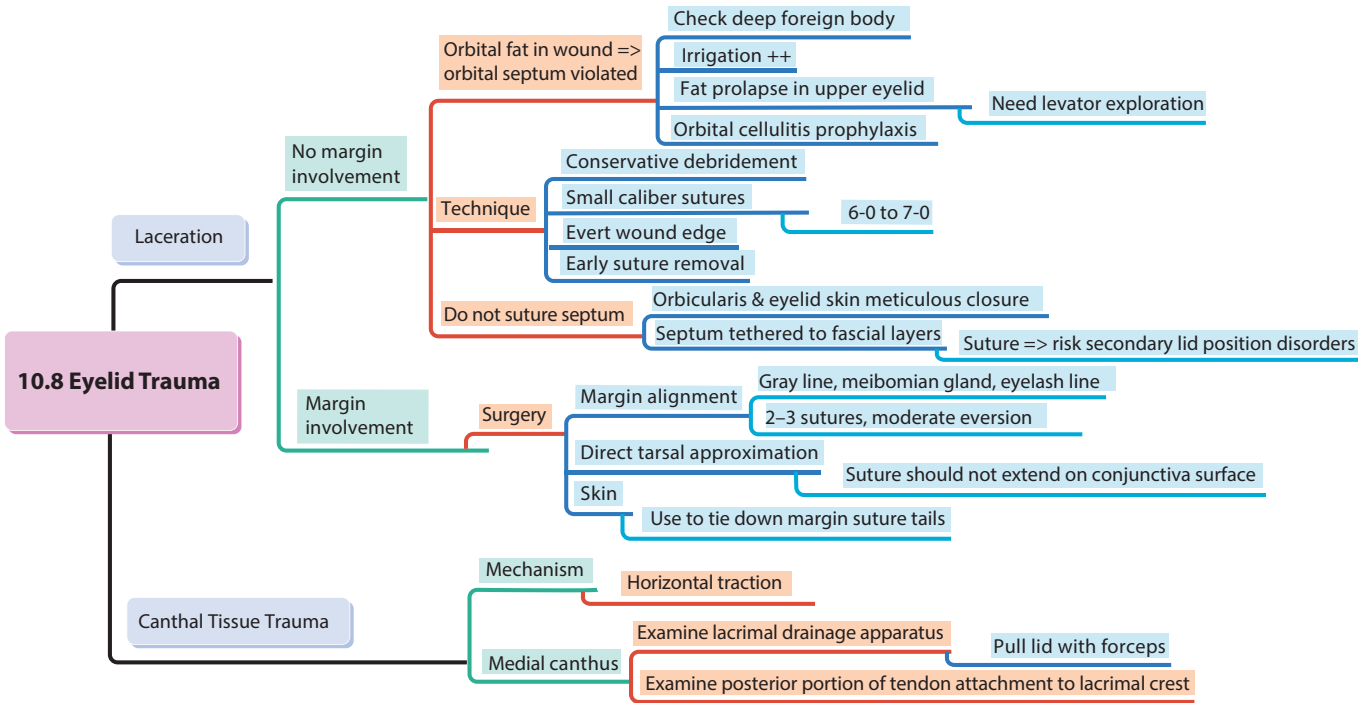


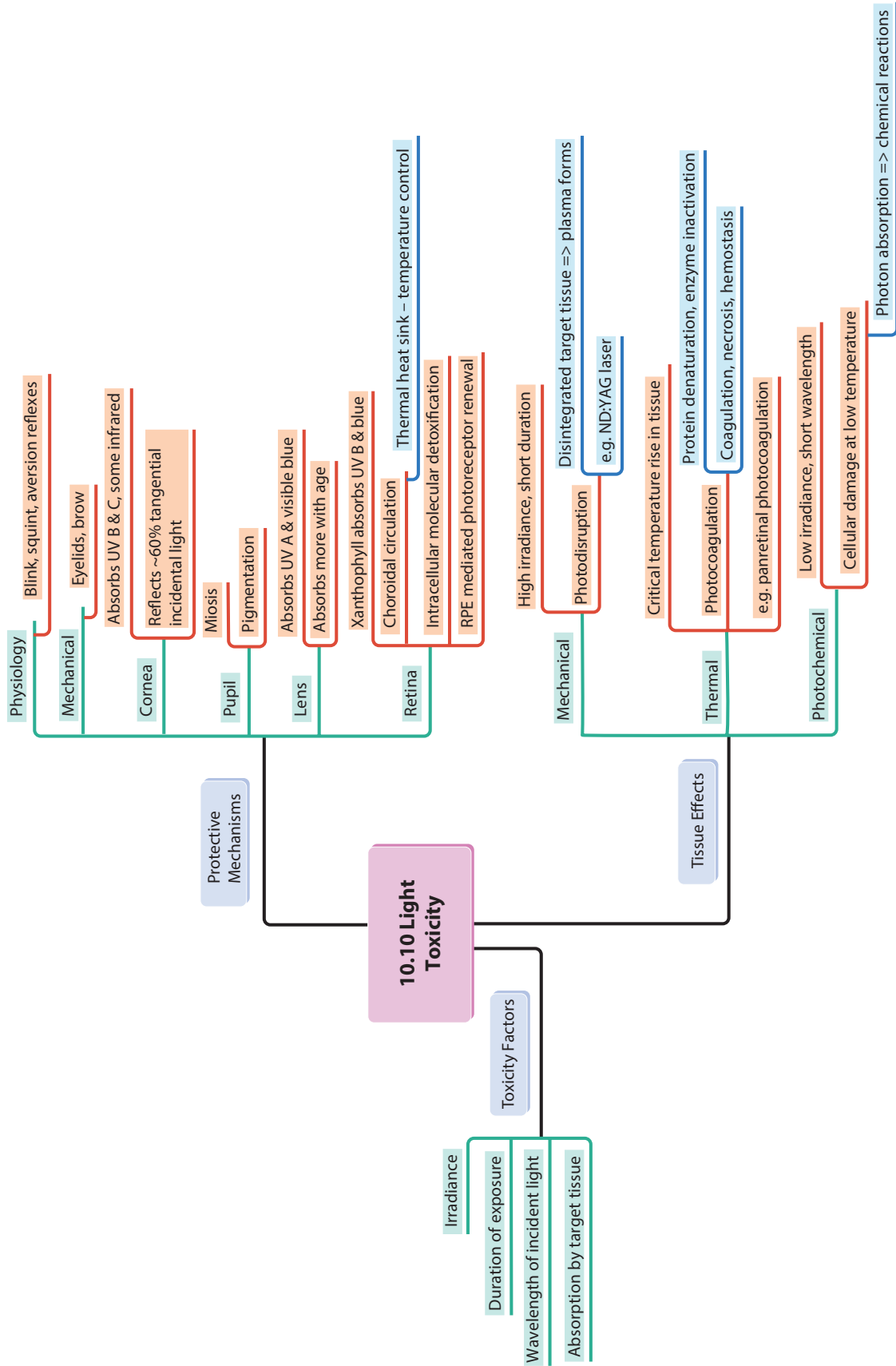


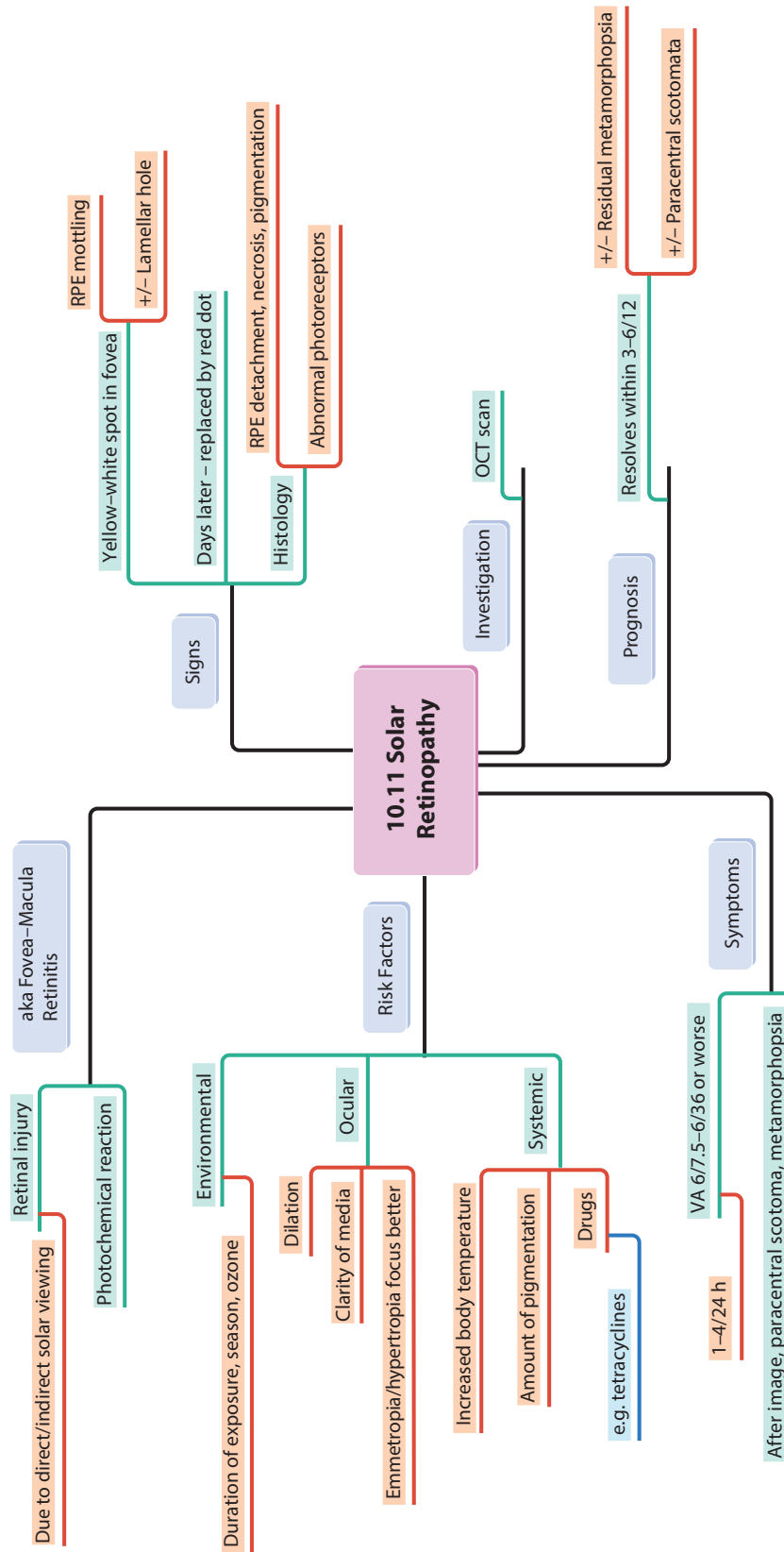


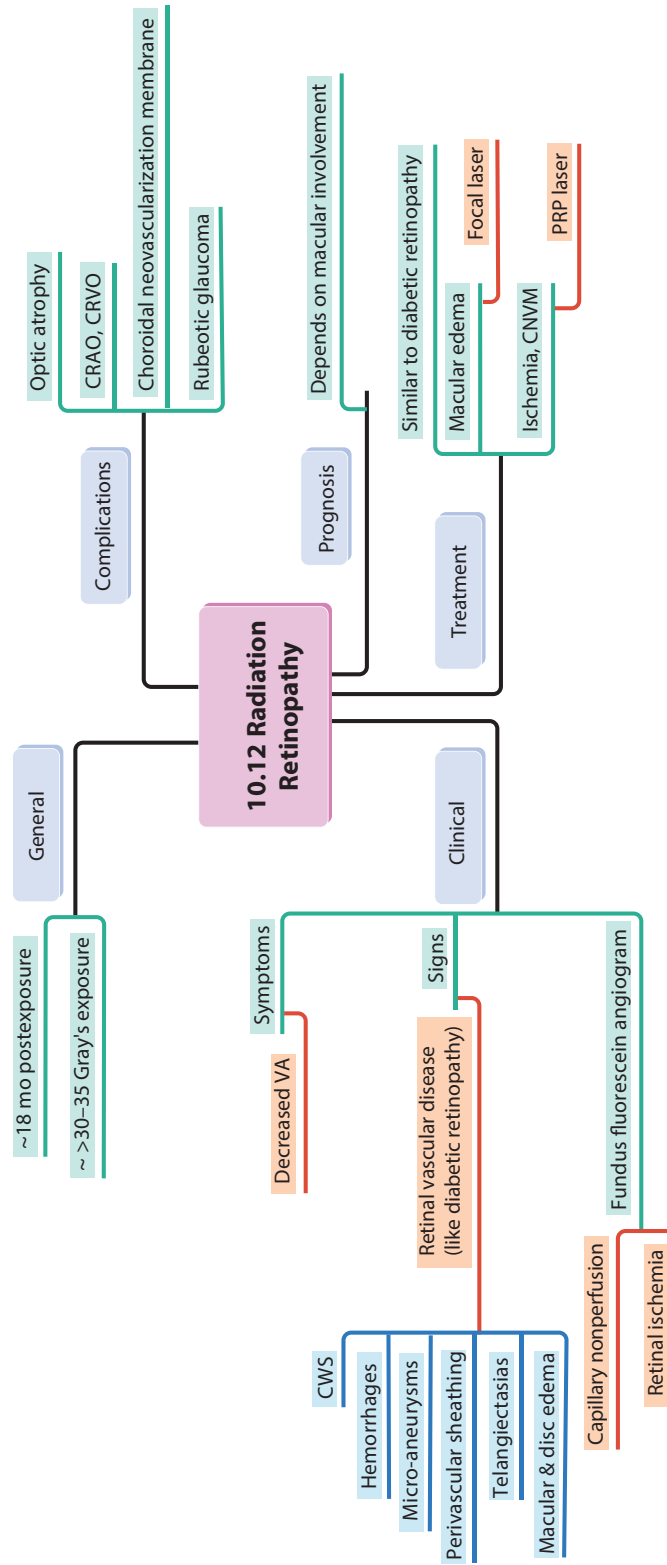


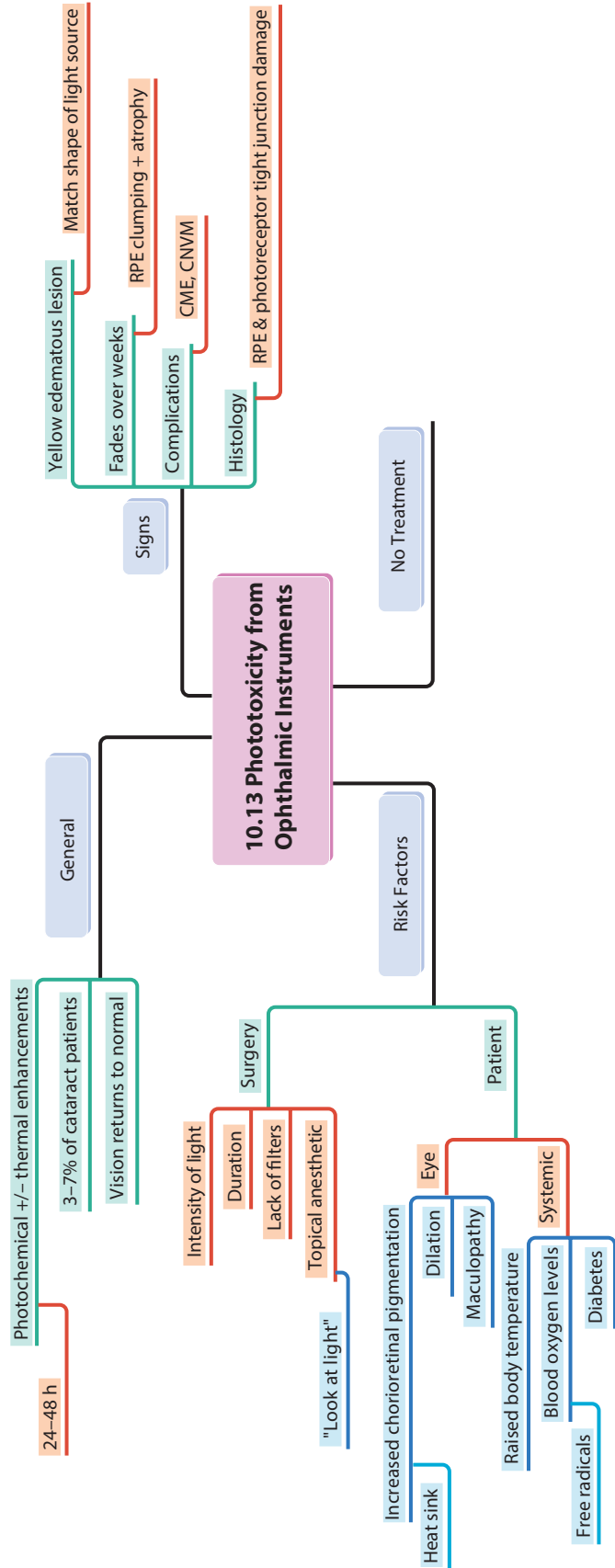


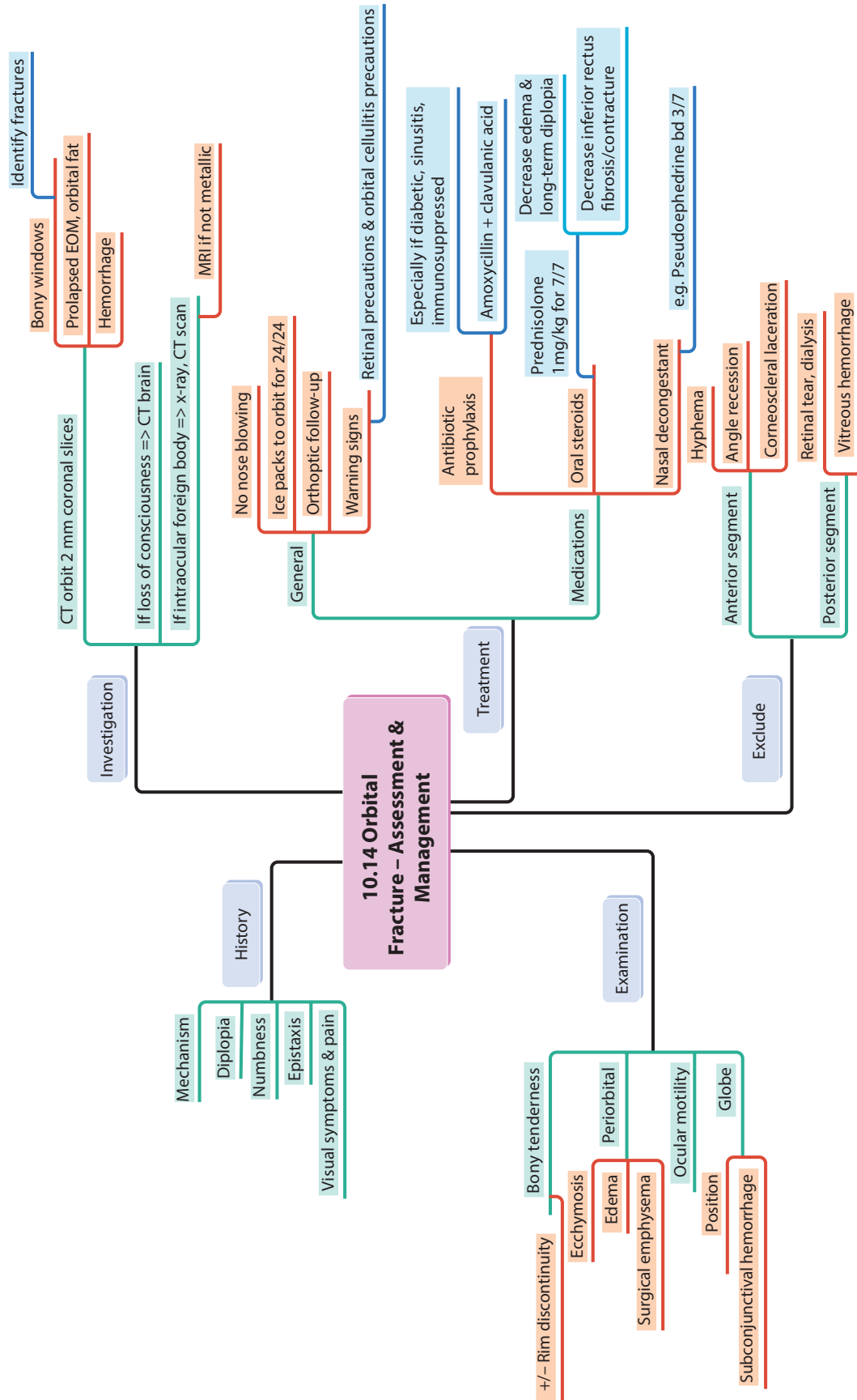


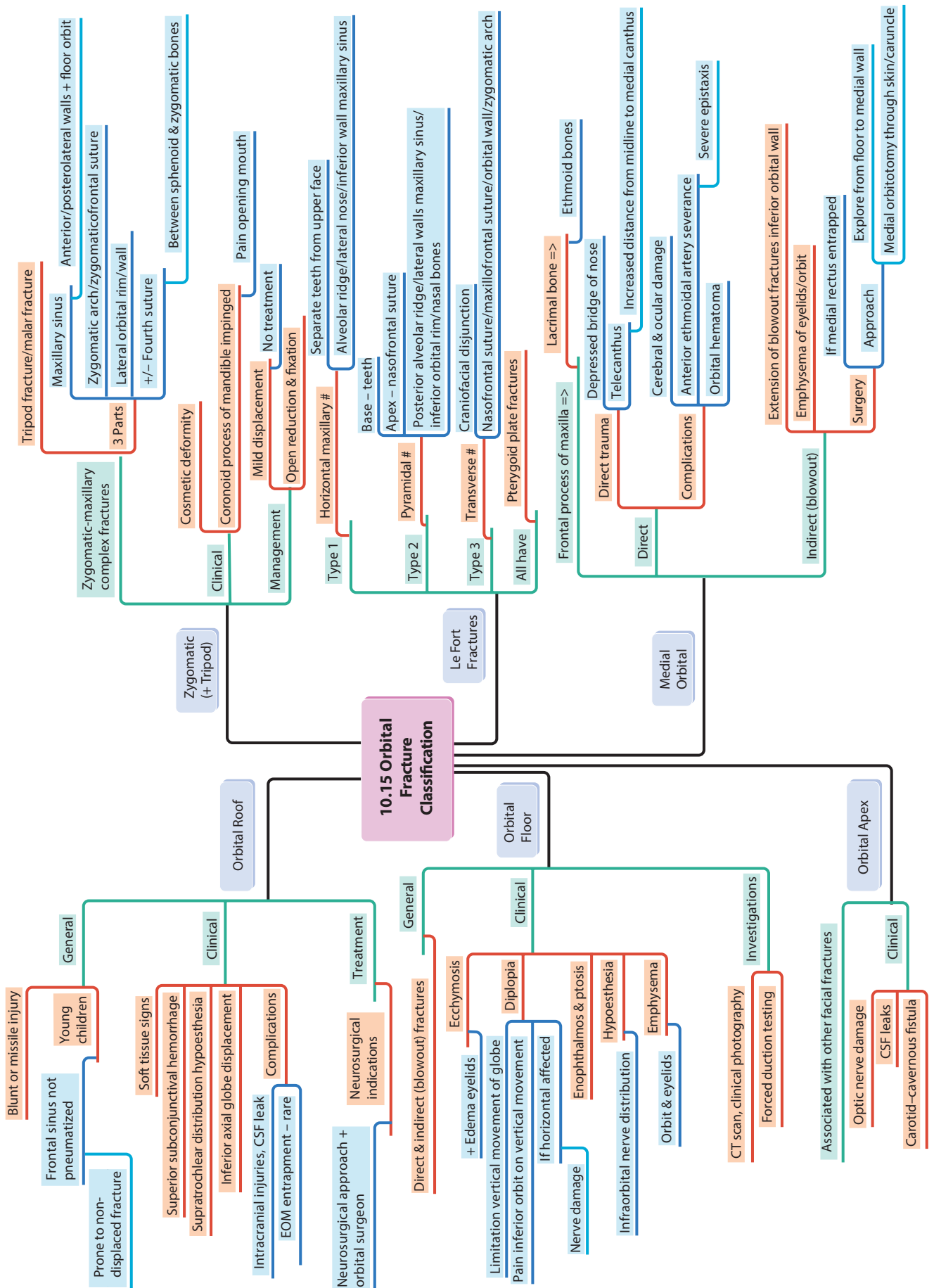


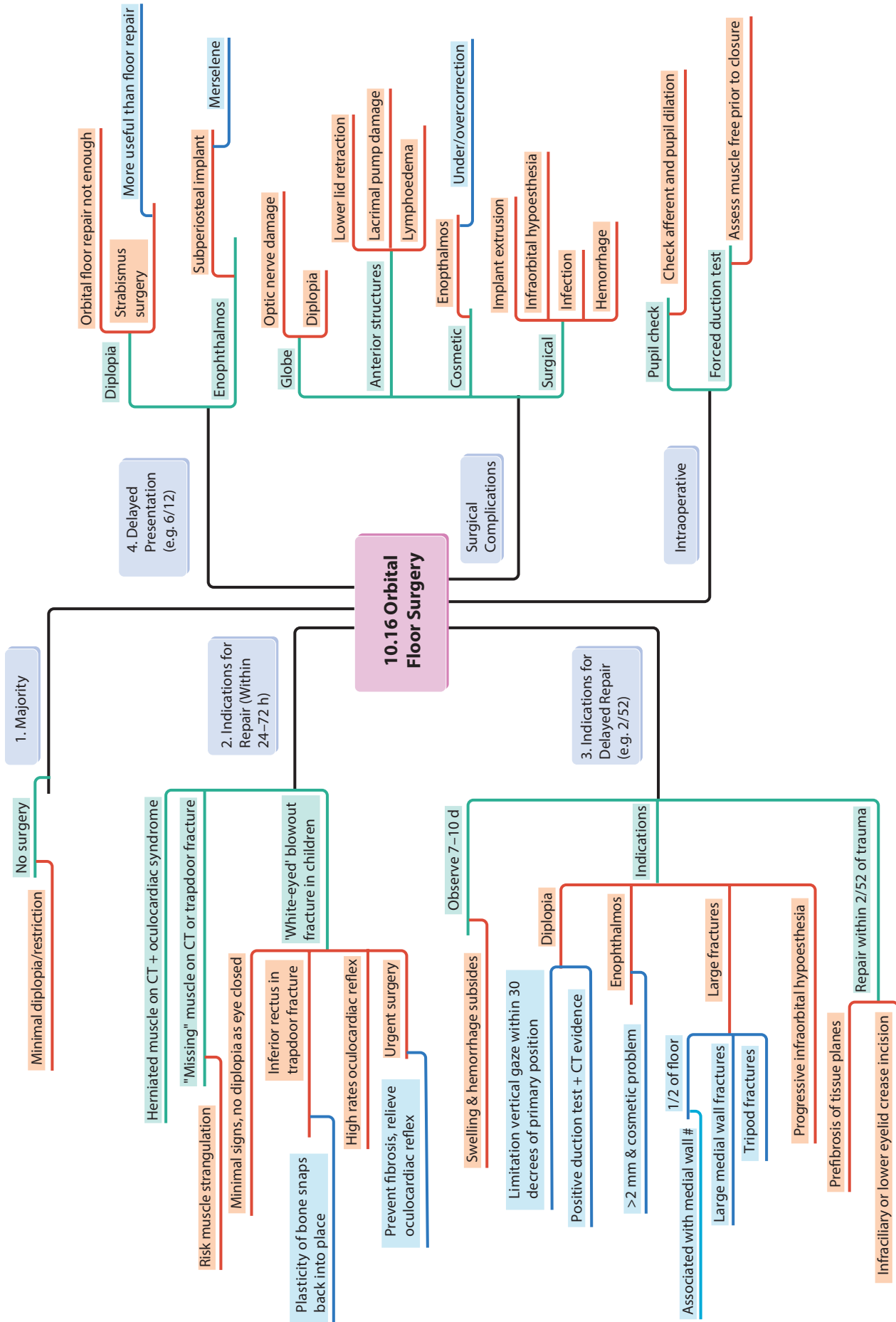


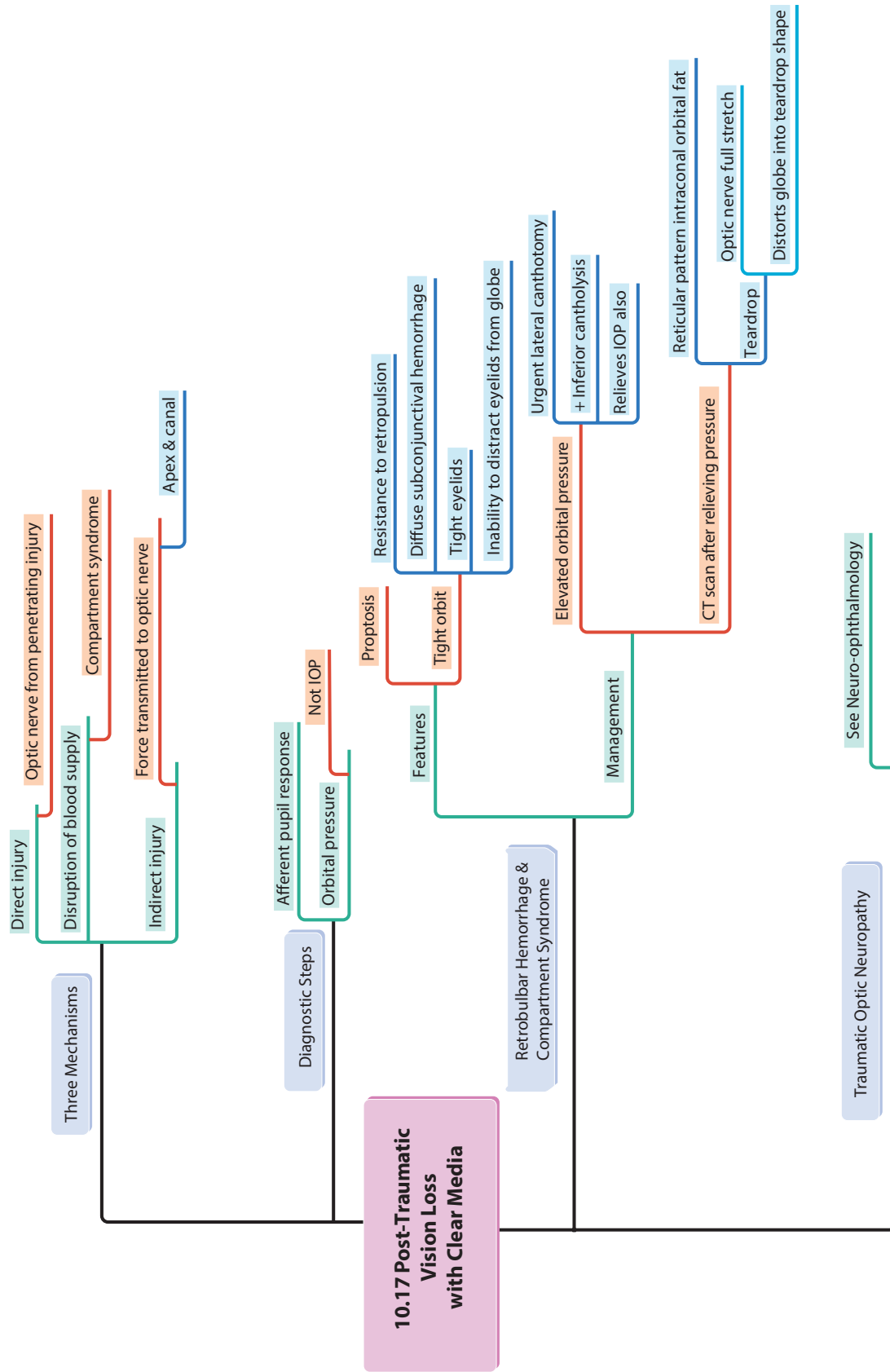




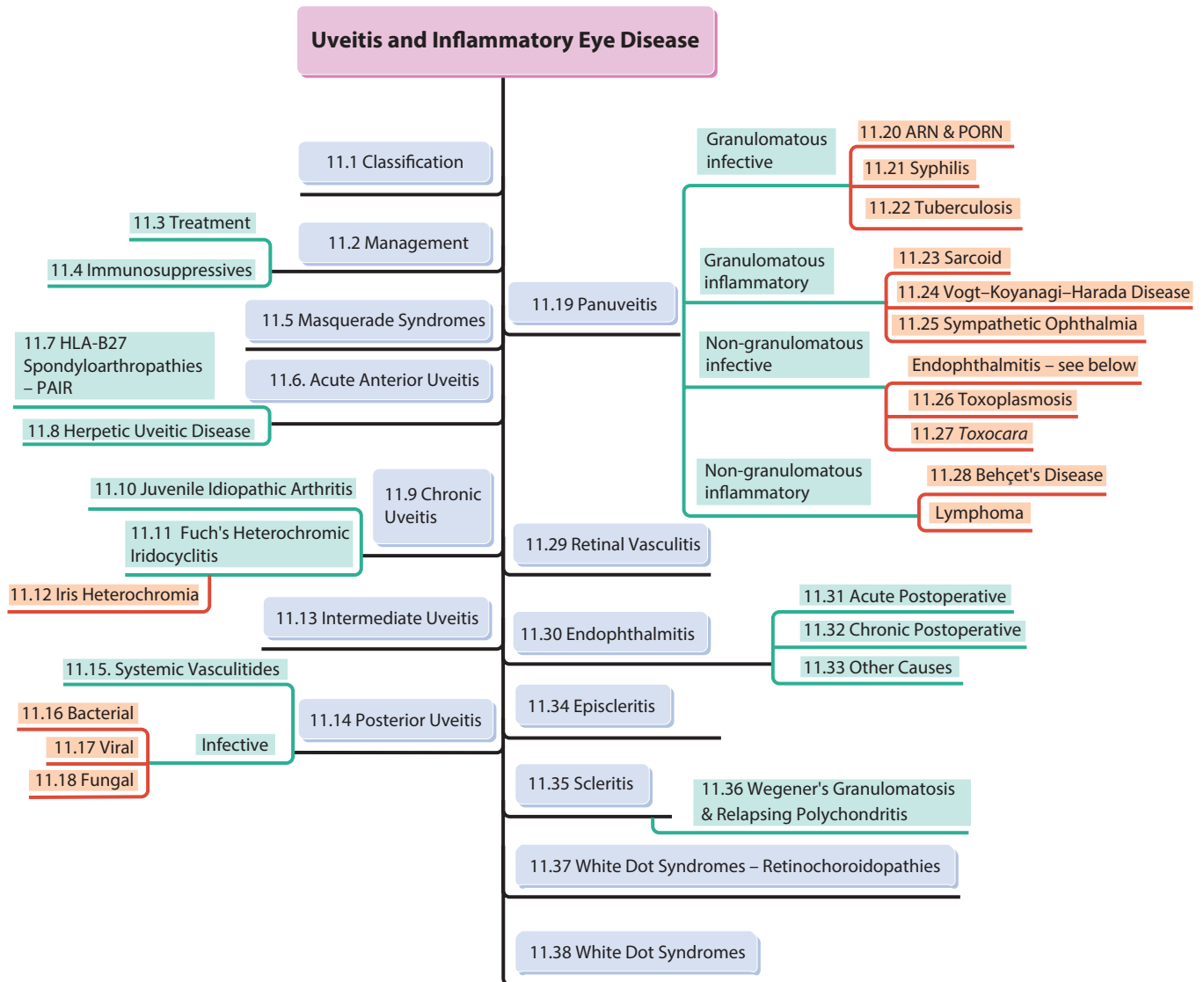


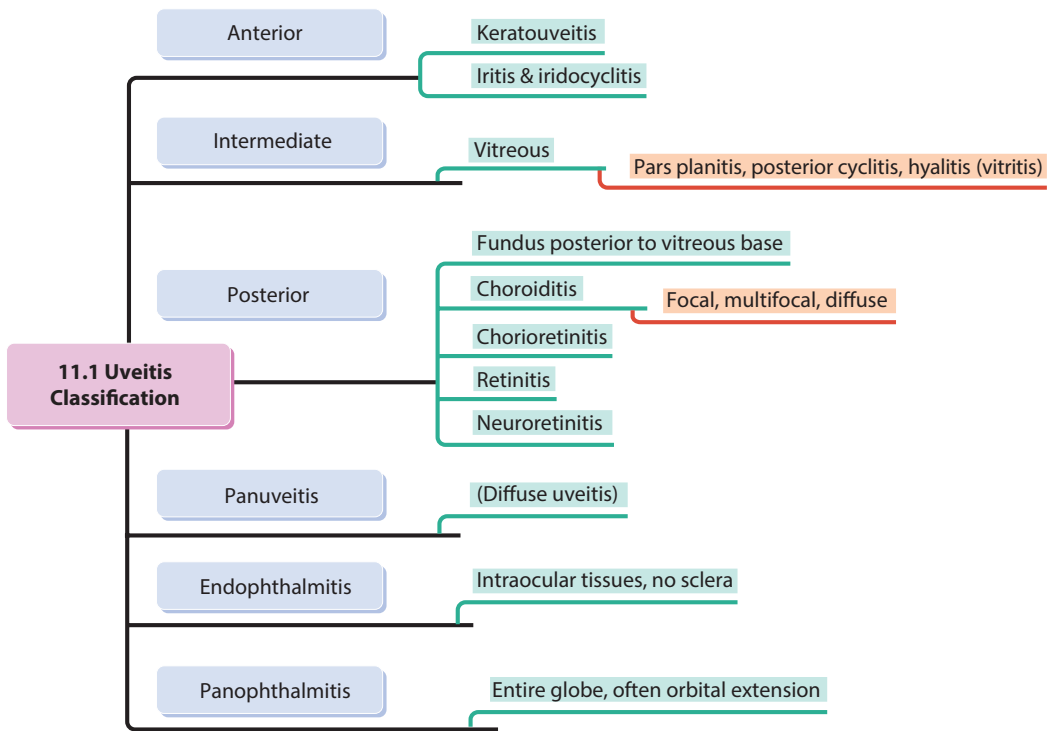


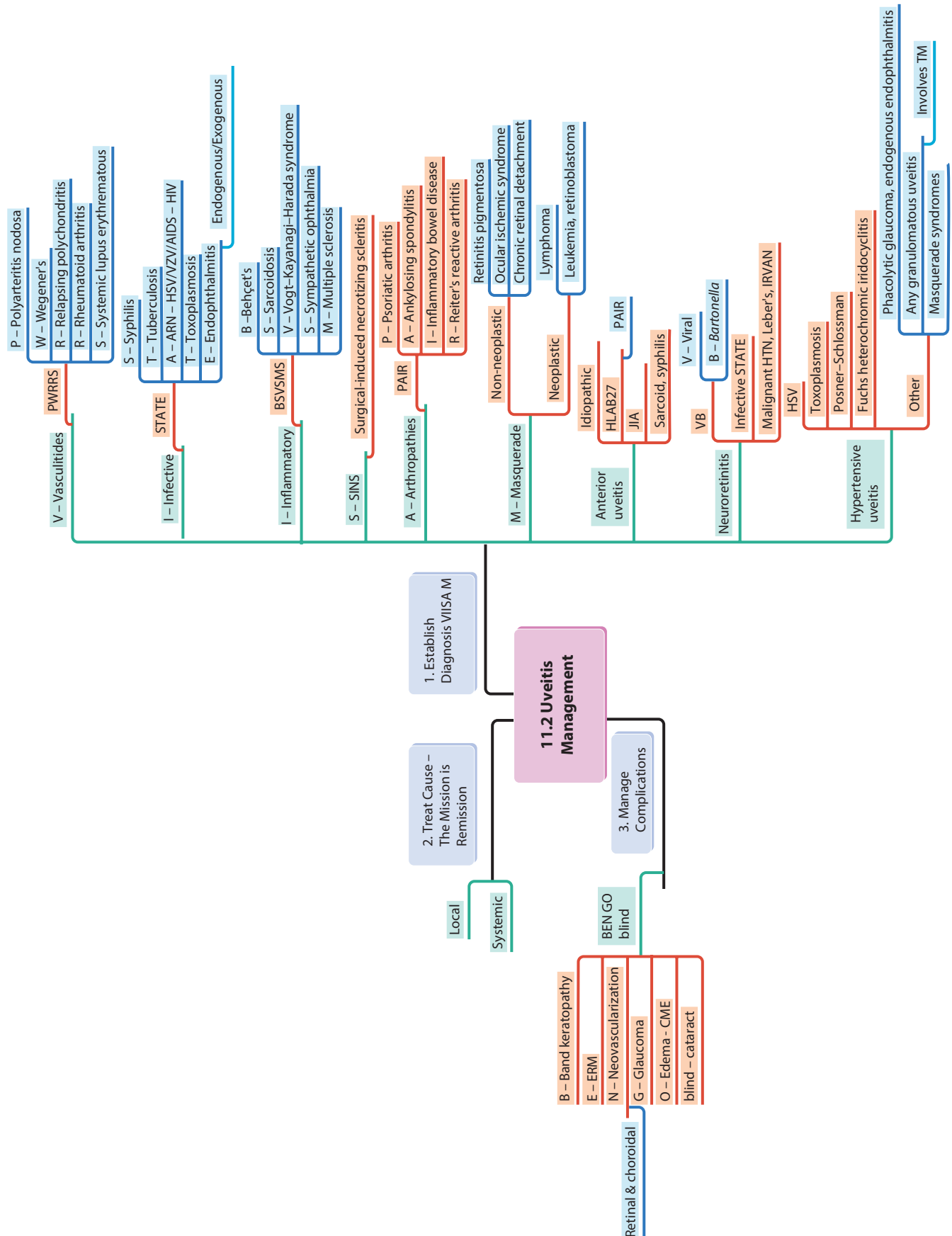


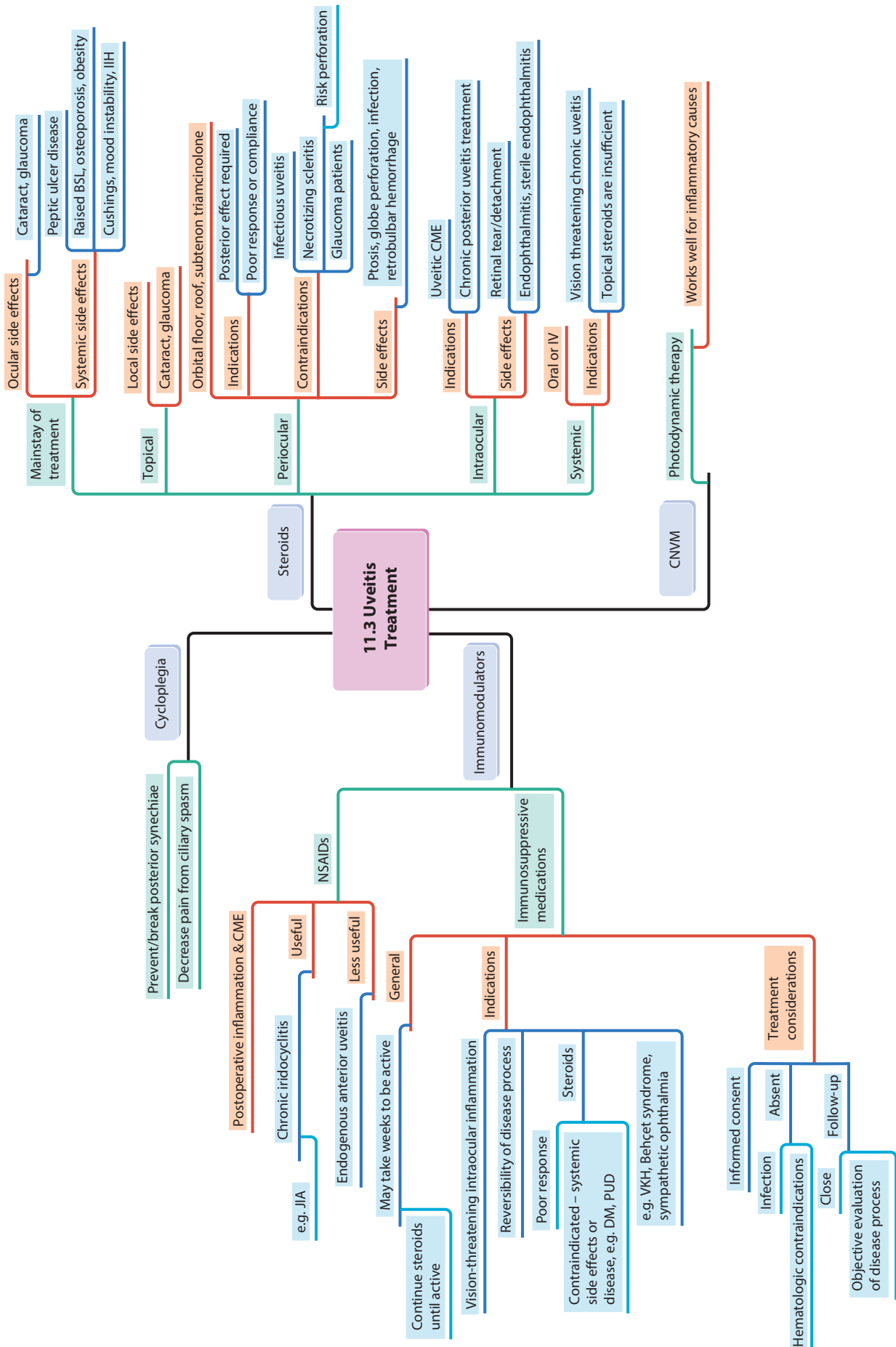


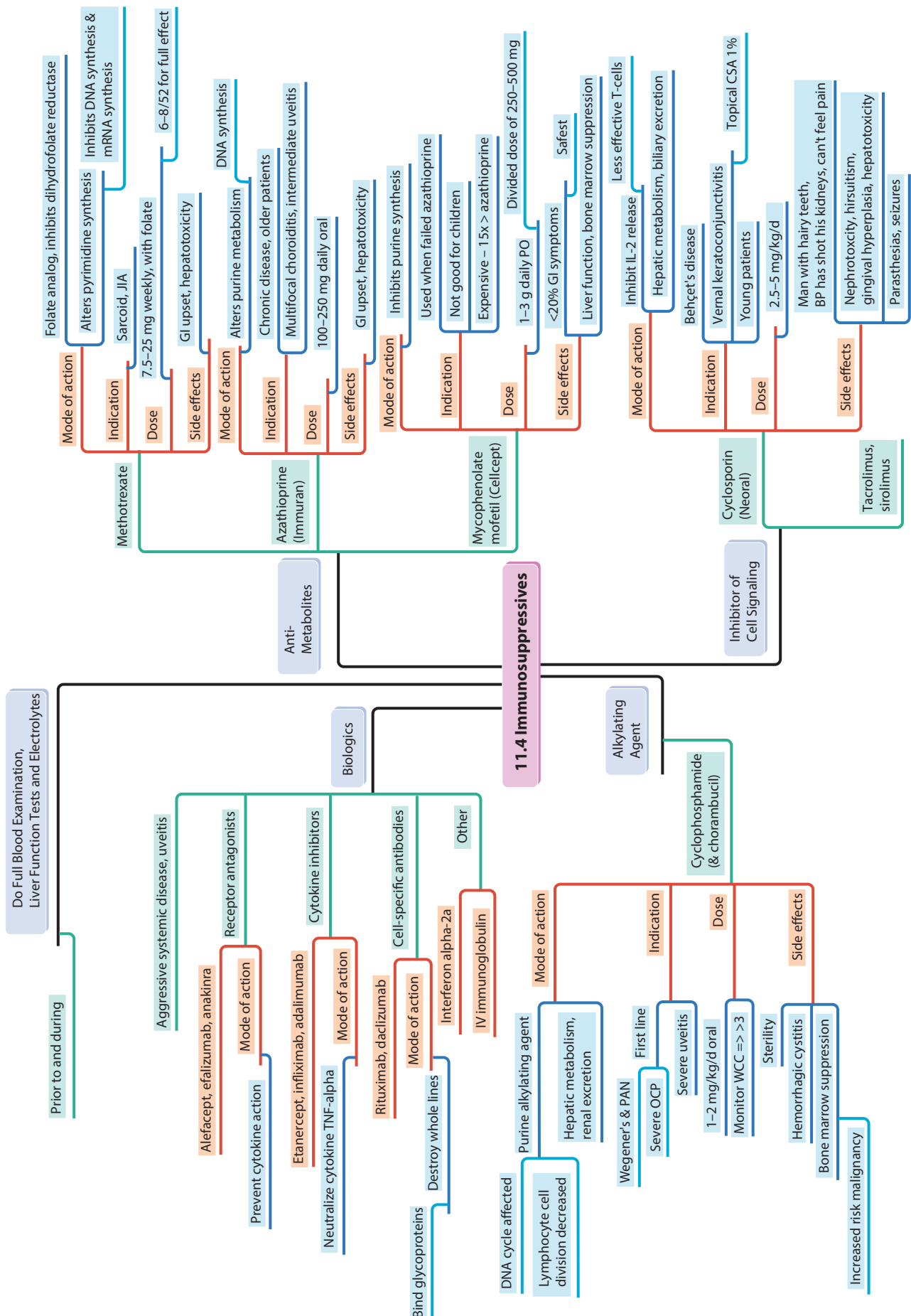
11 Uveitis and Inflammatory Eye Disease

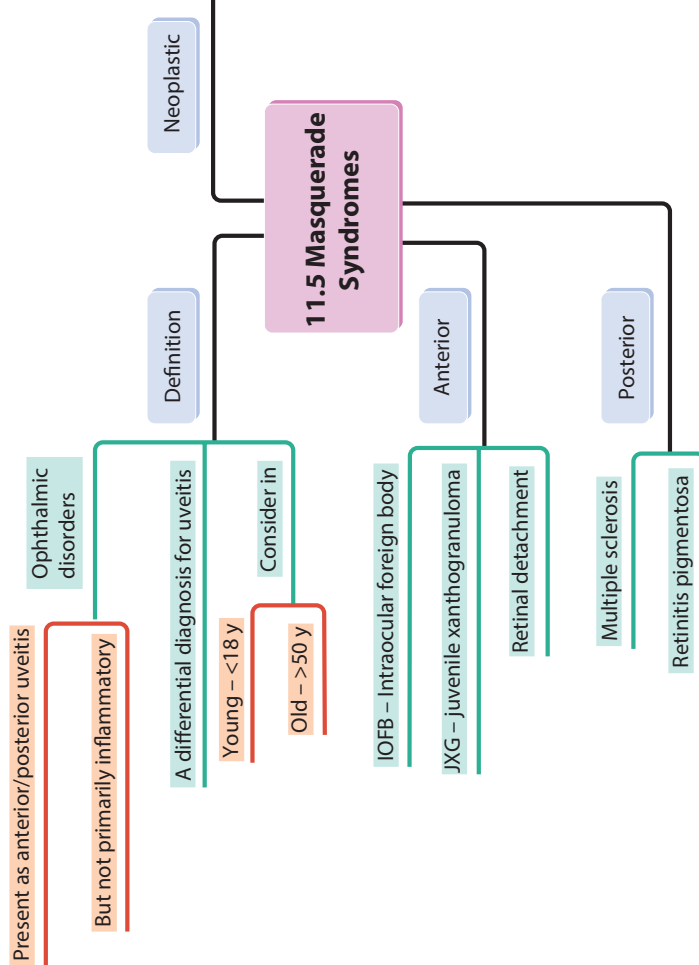
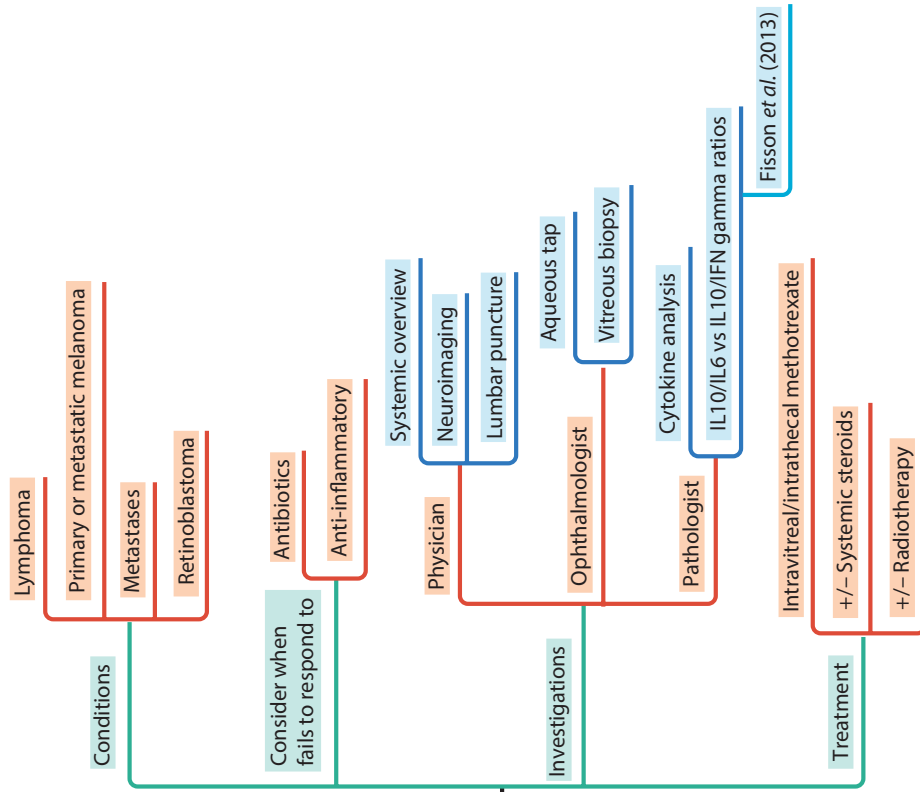


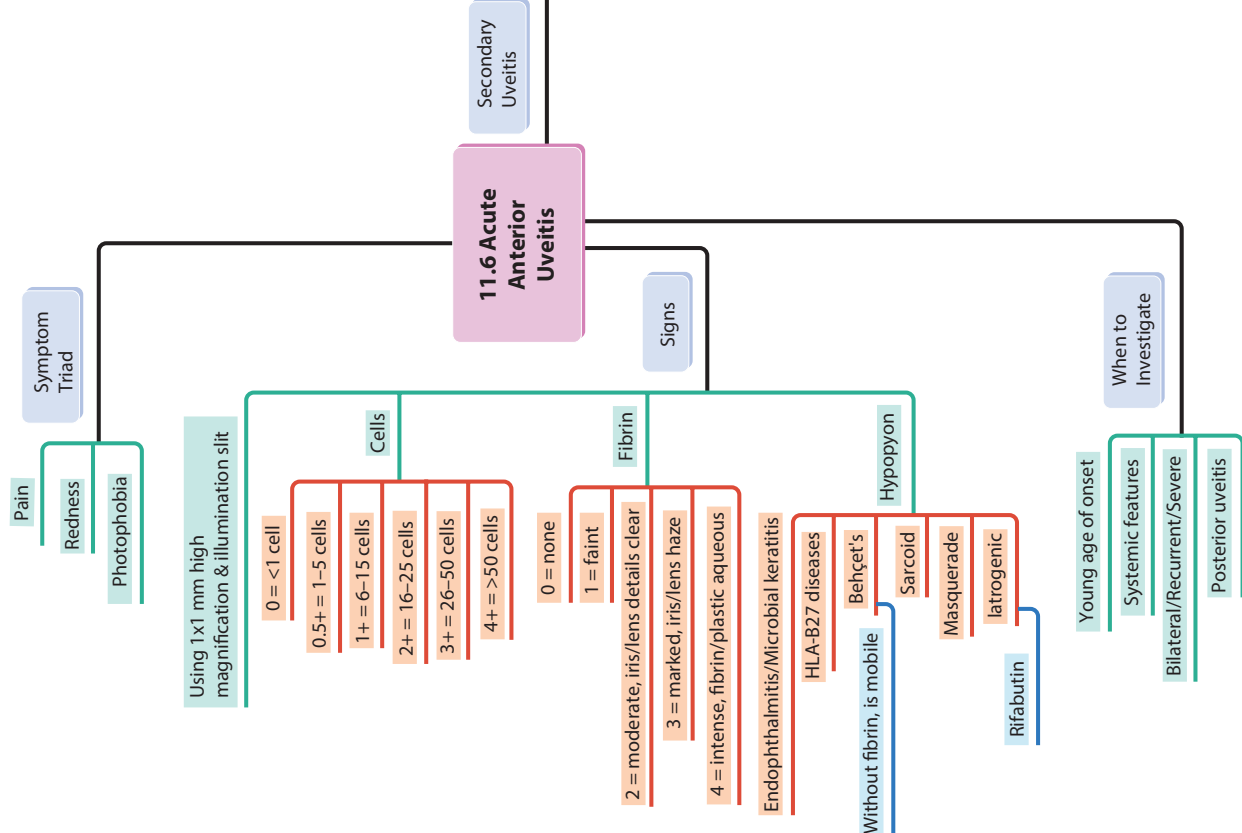
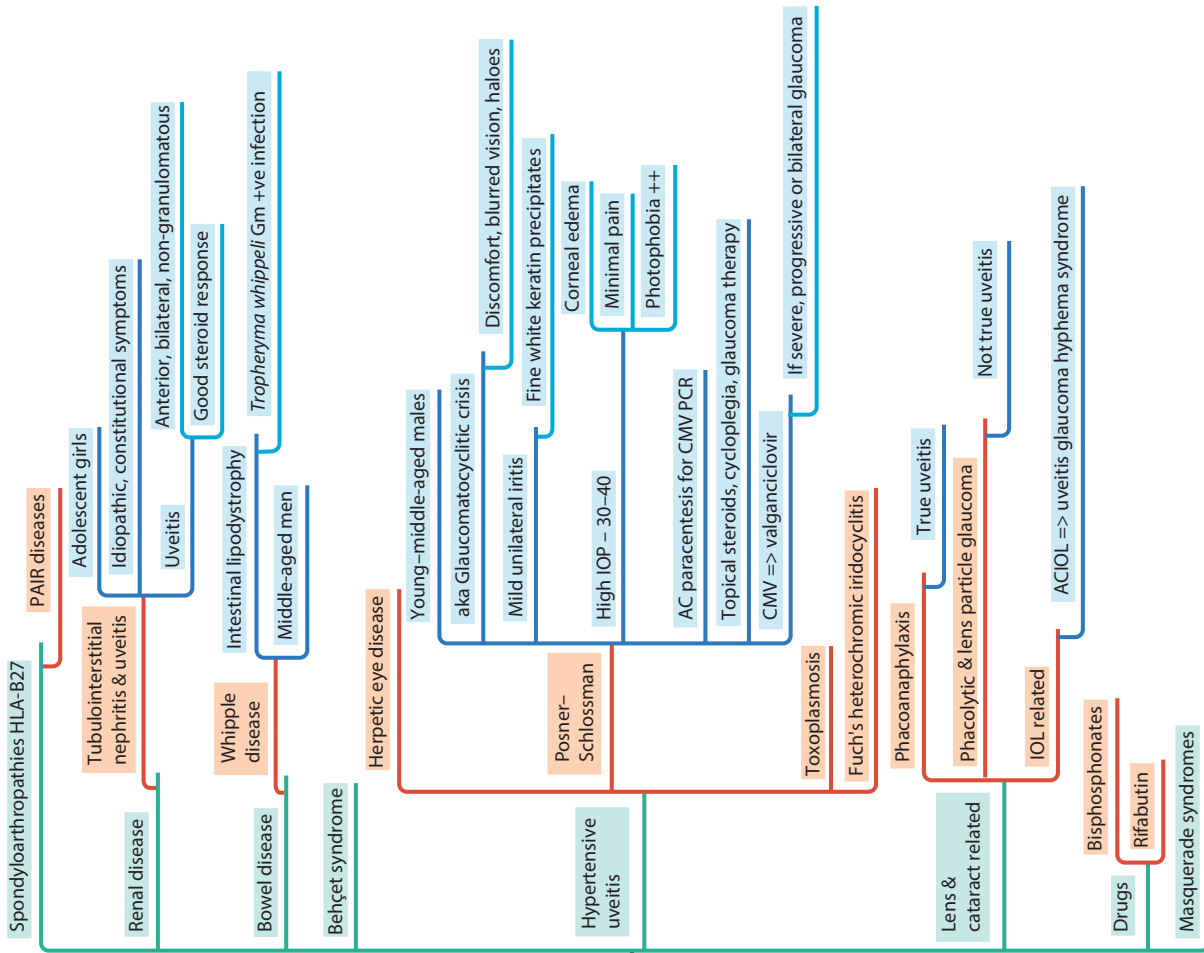


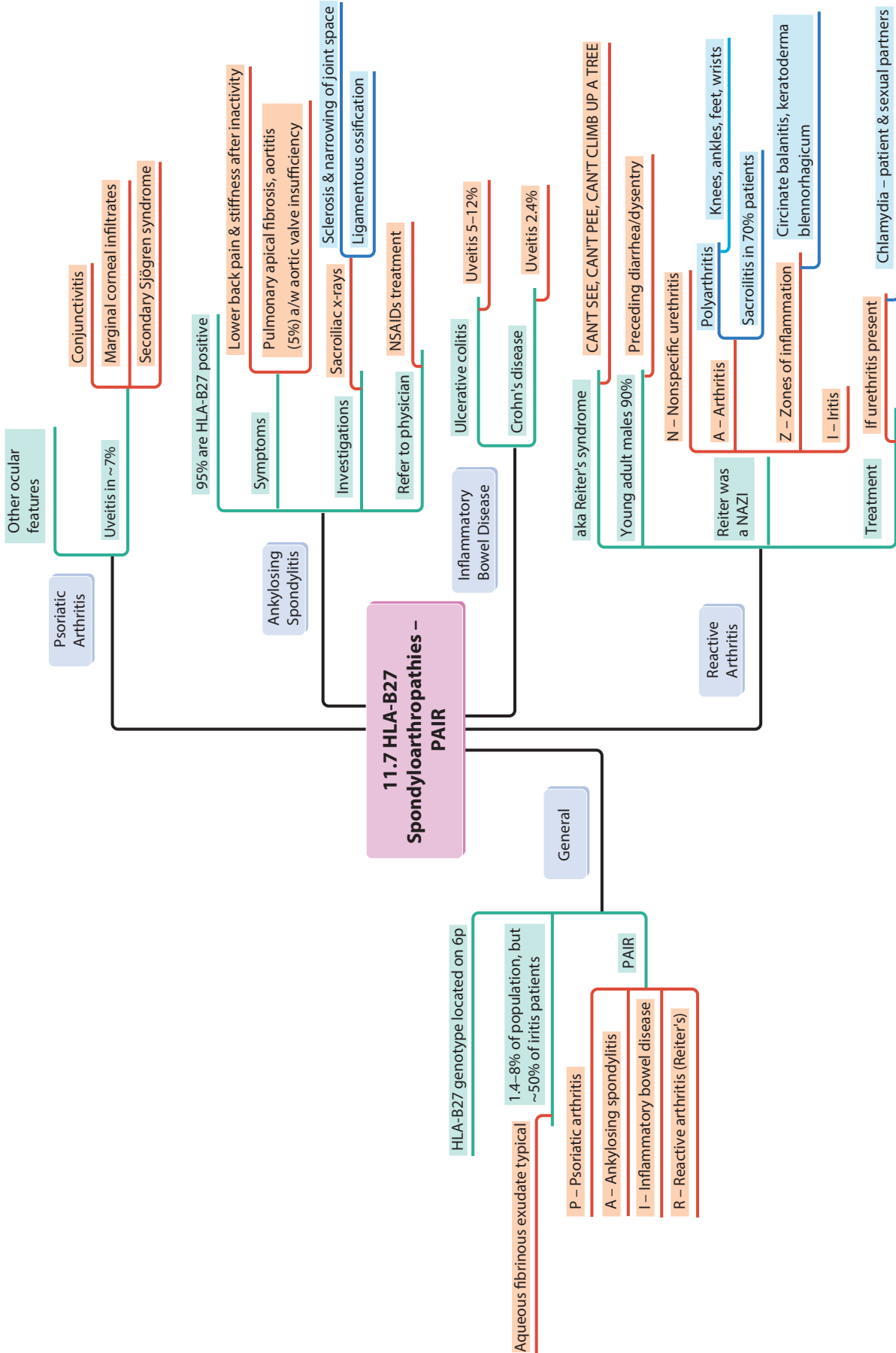


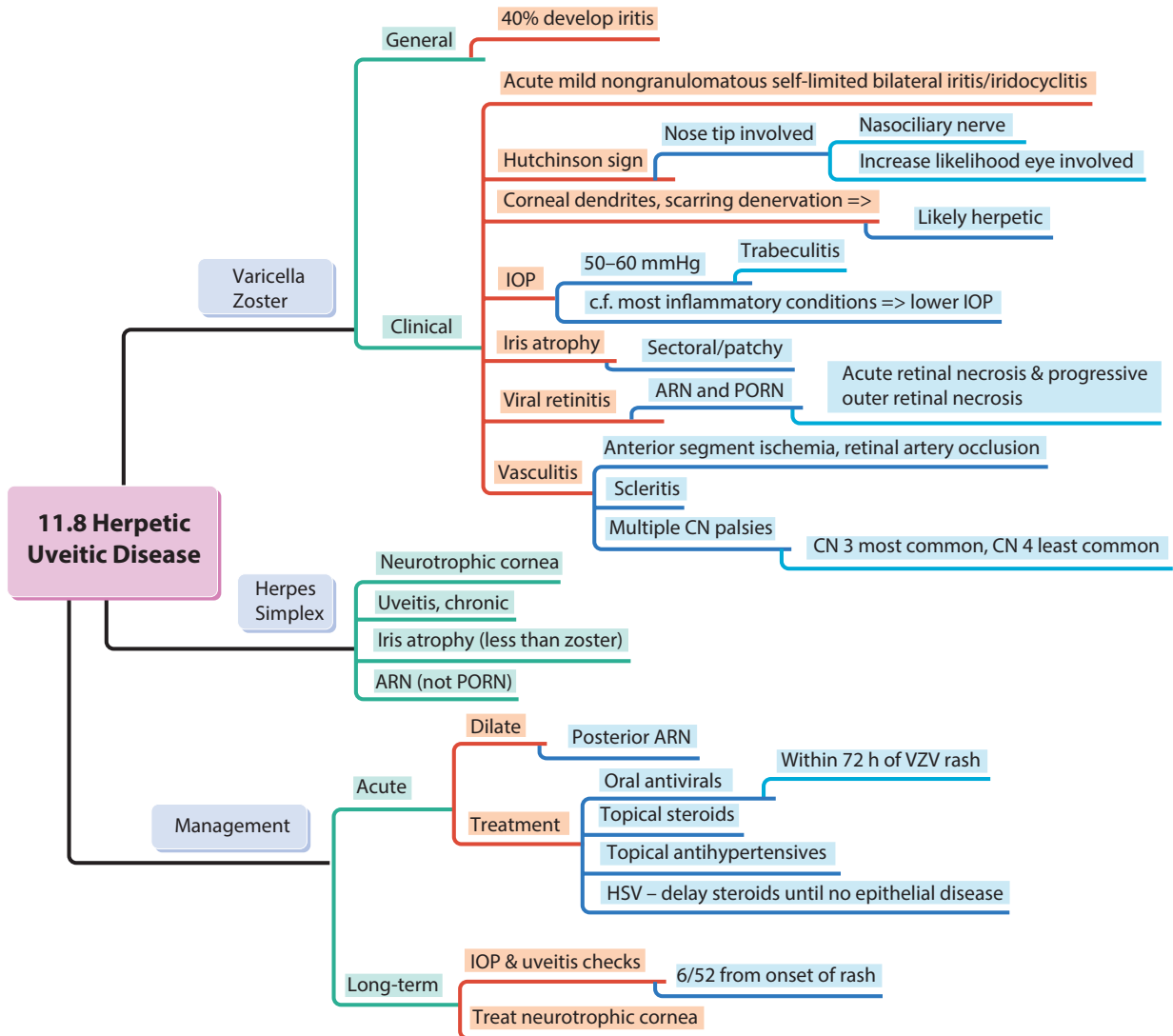


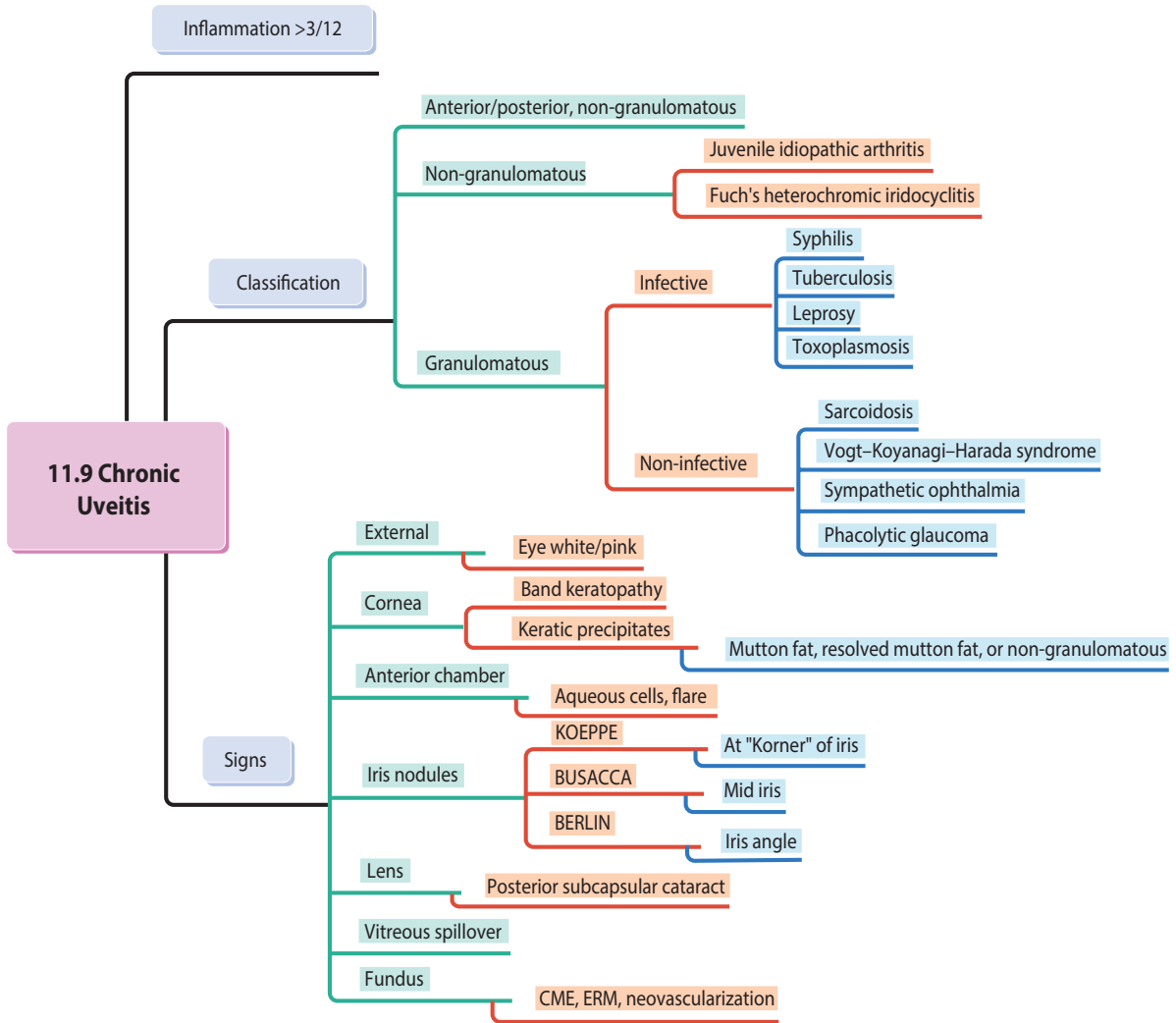


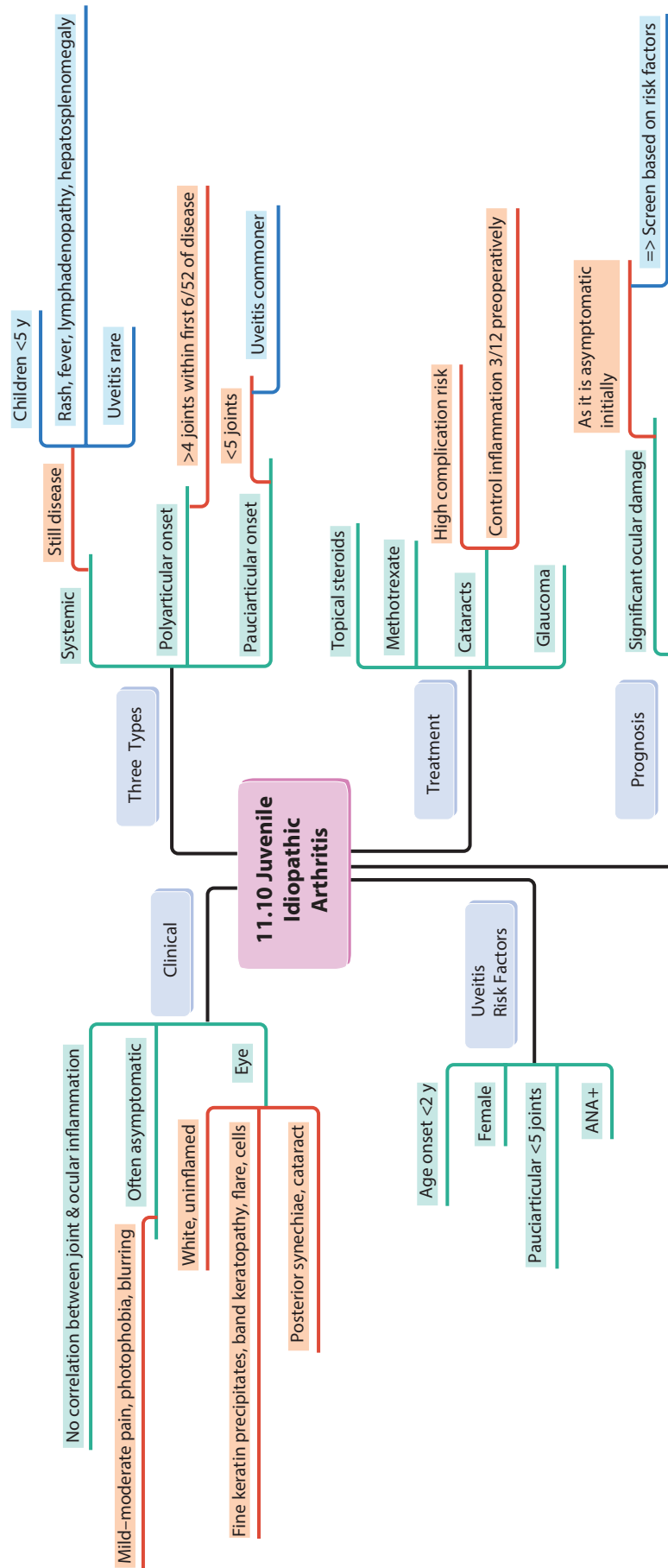


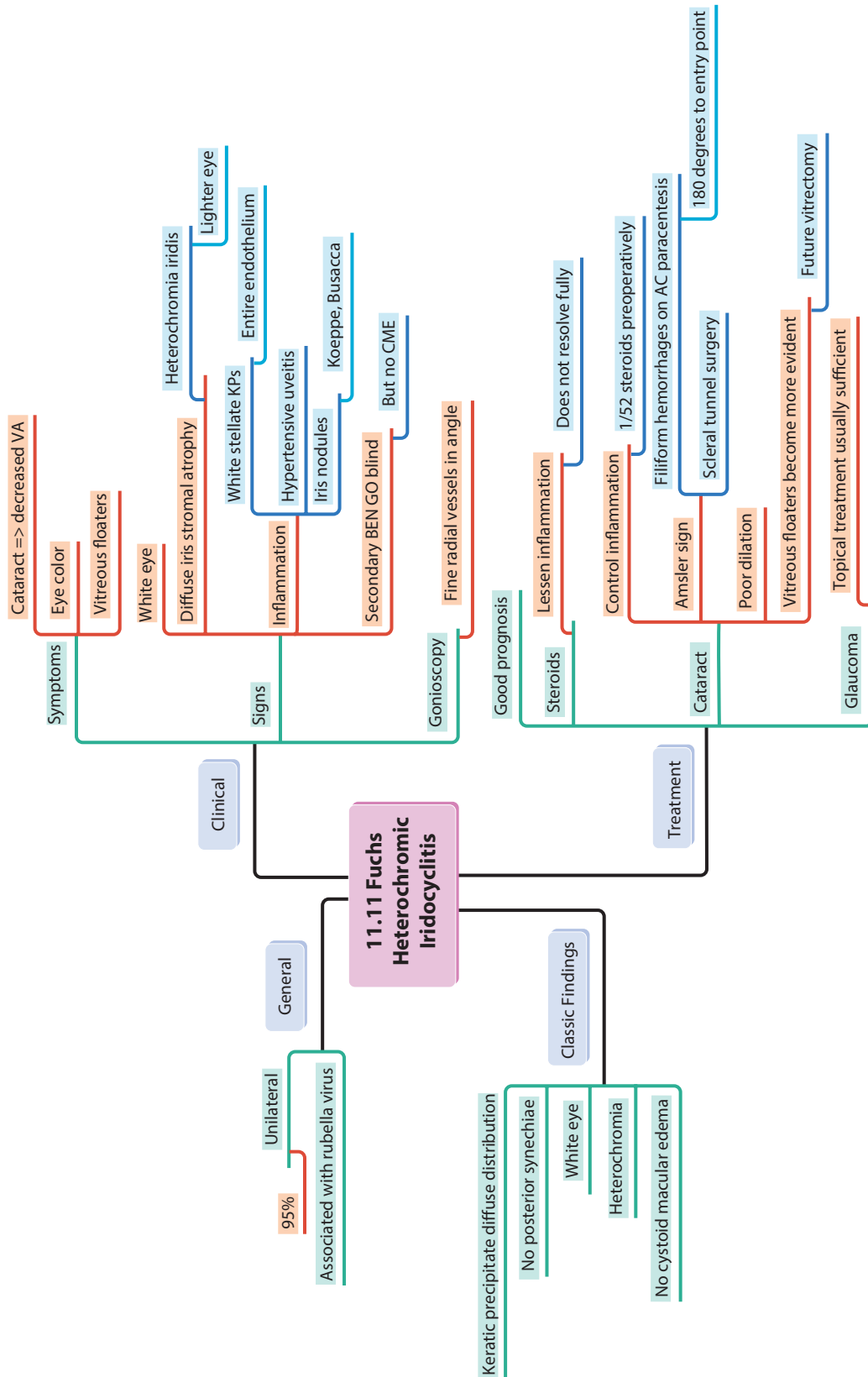


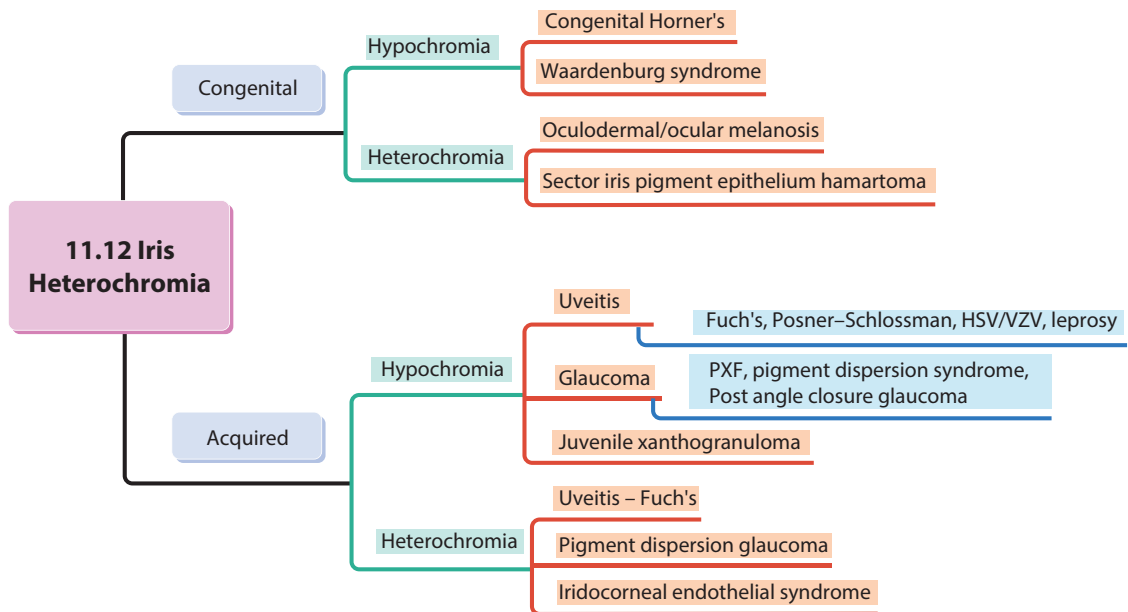


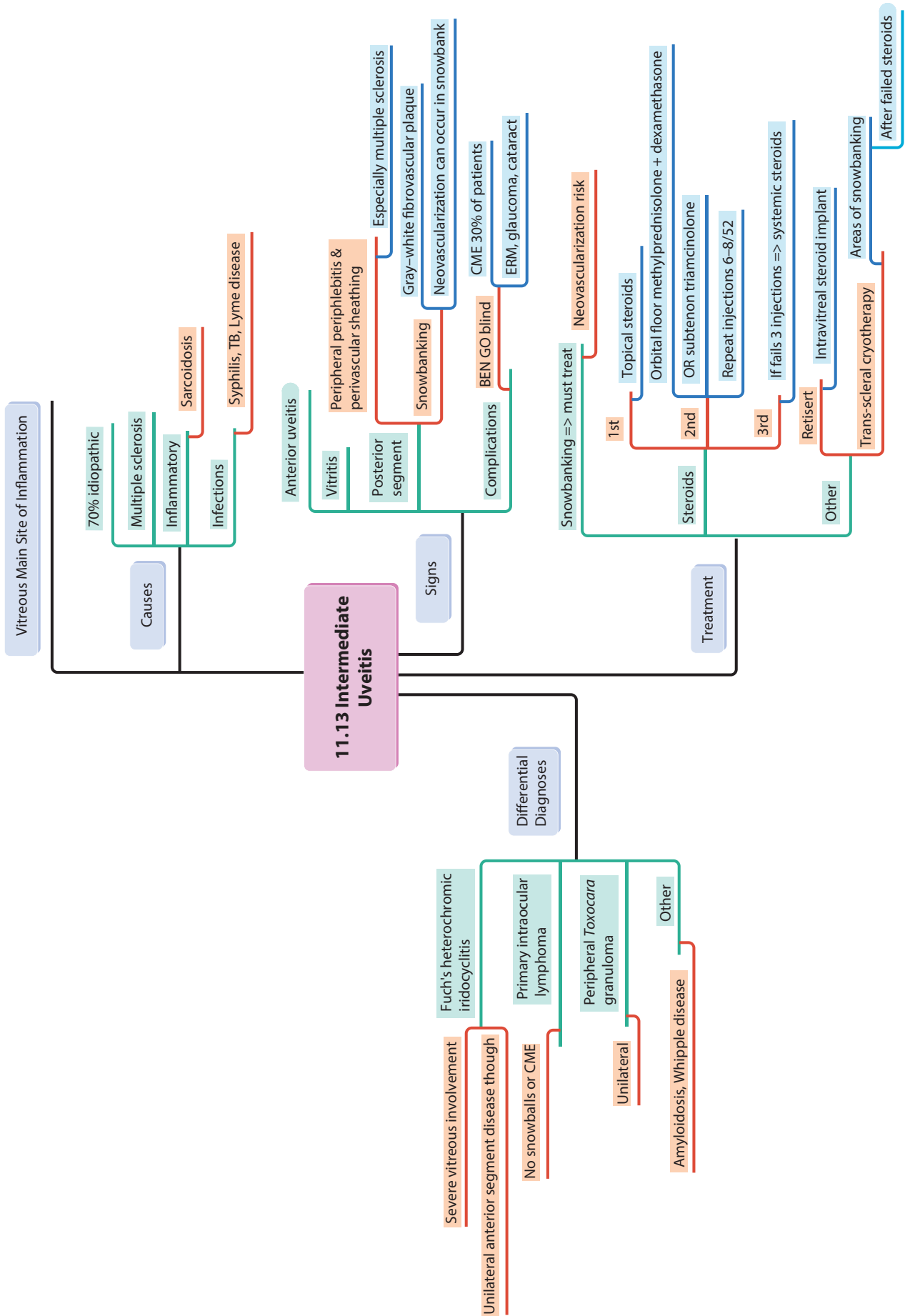


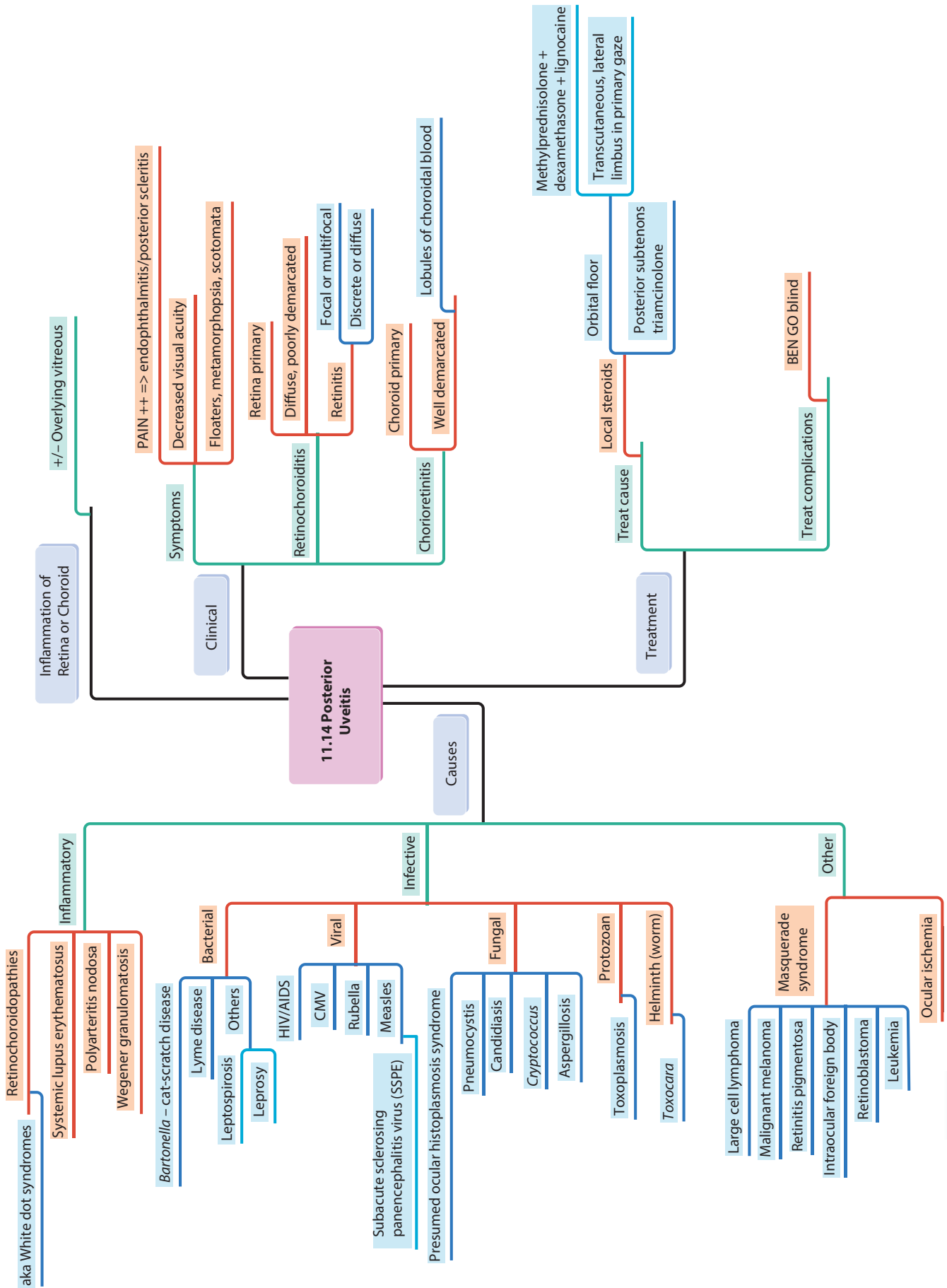


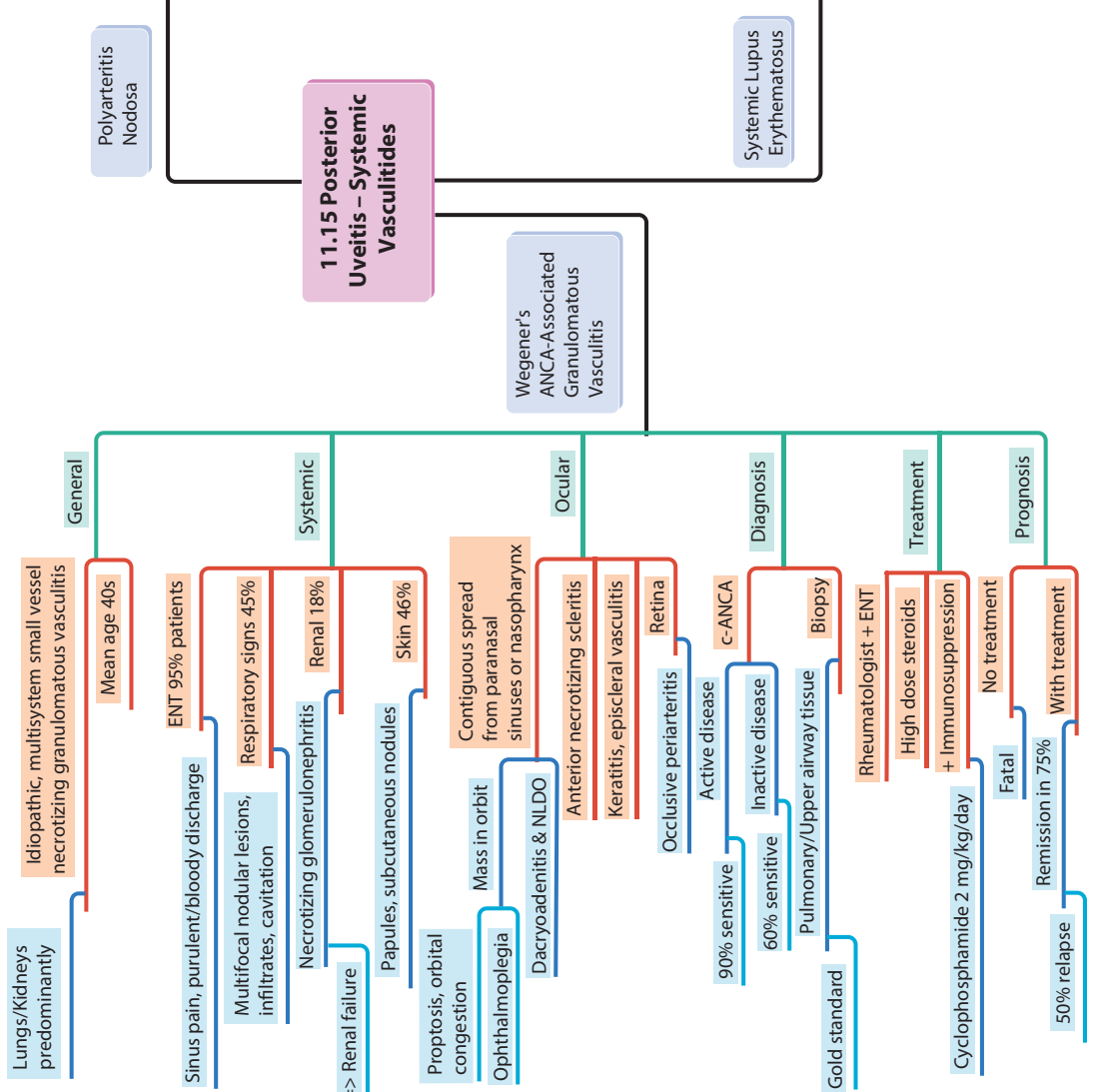
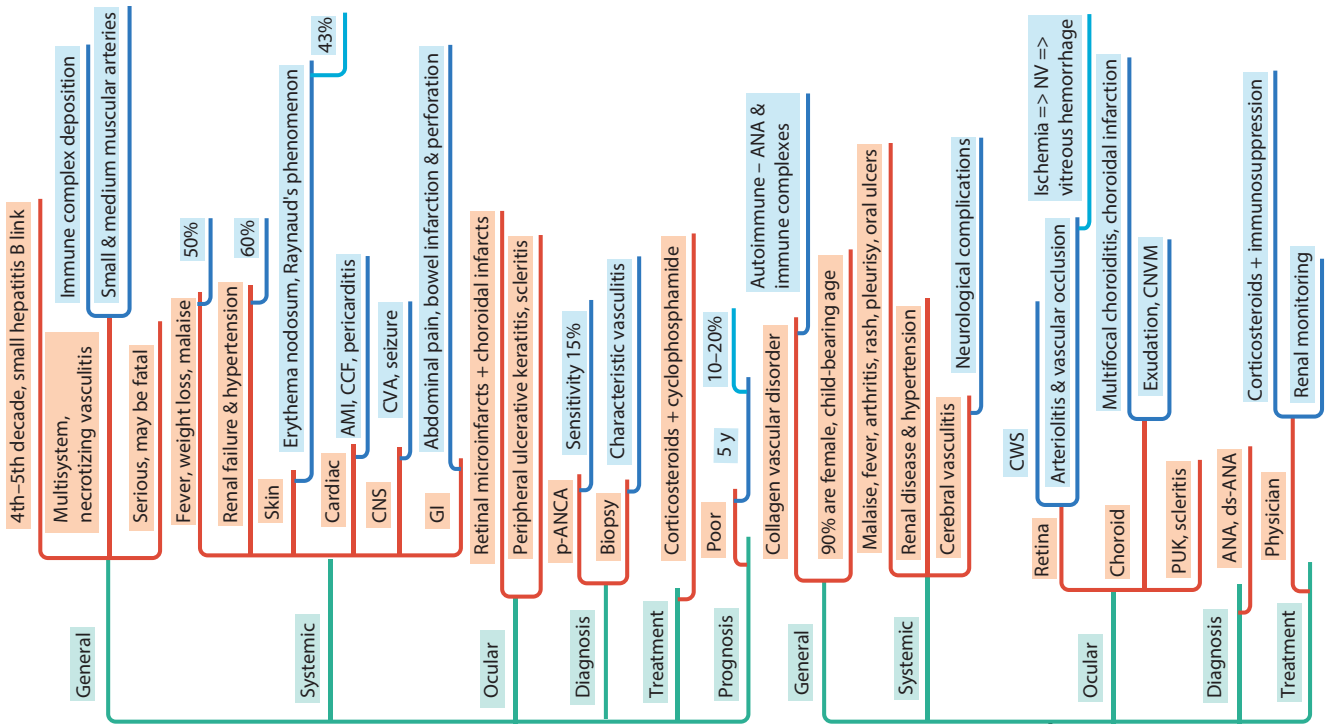


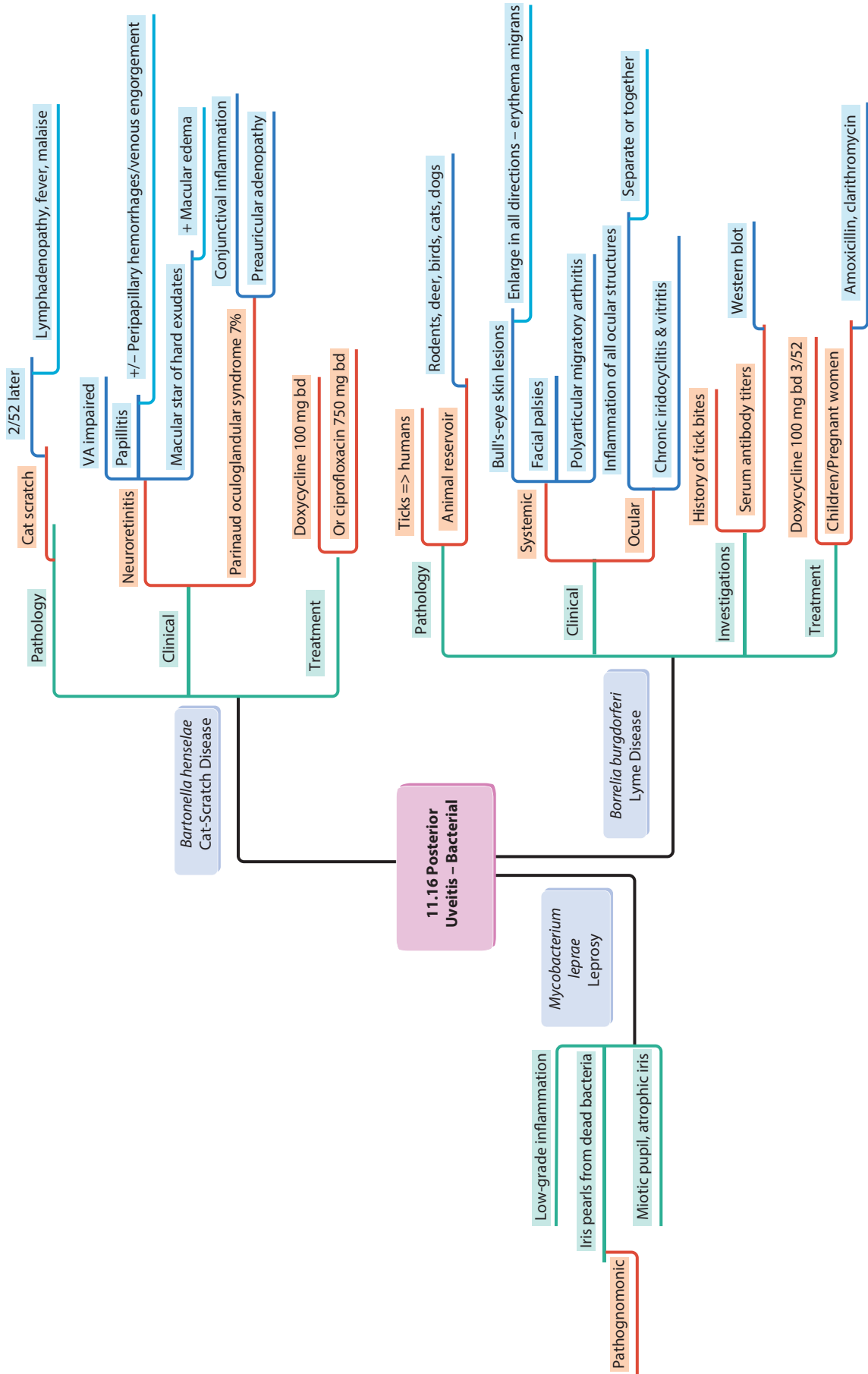


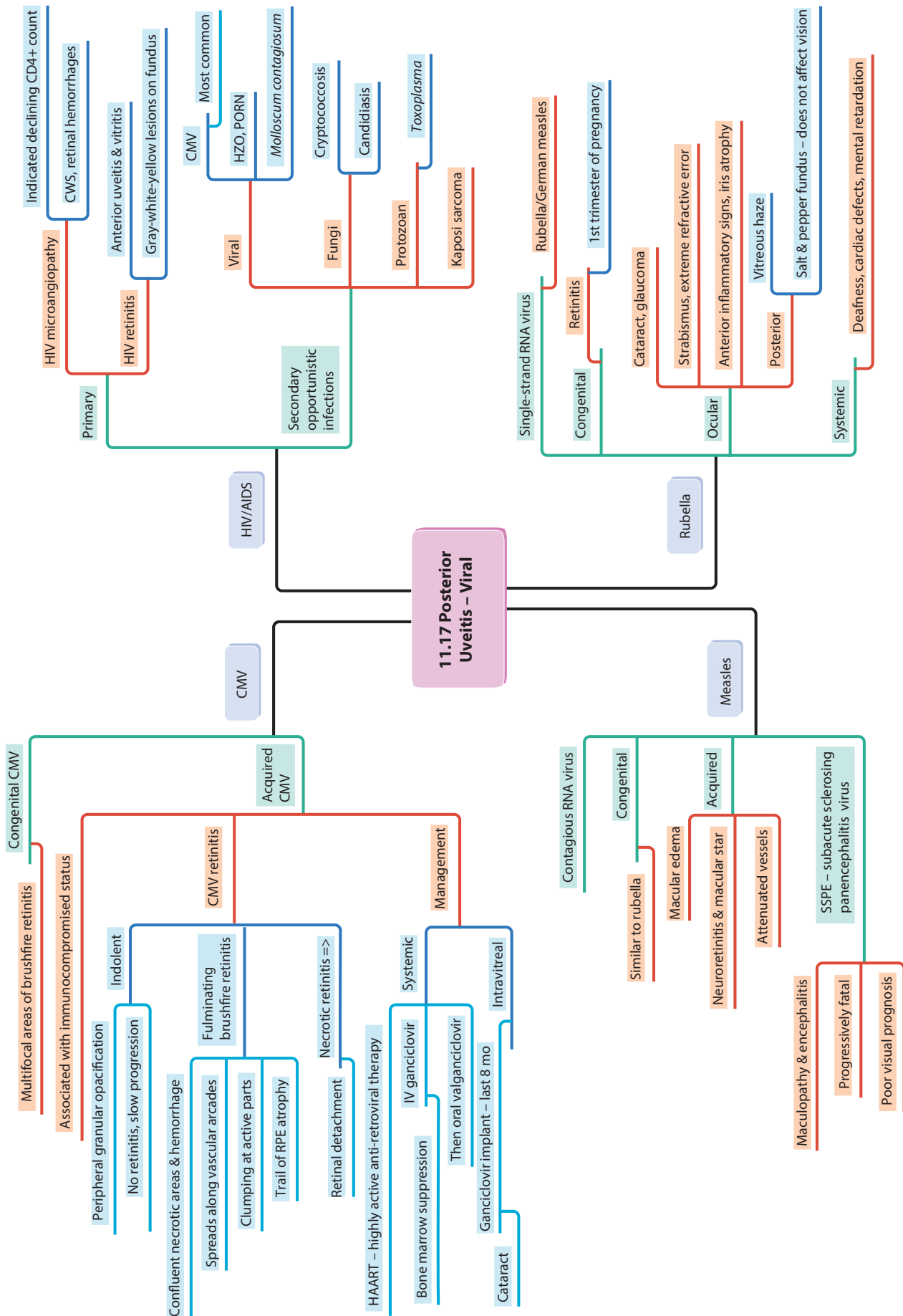


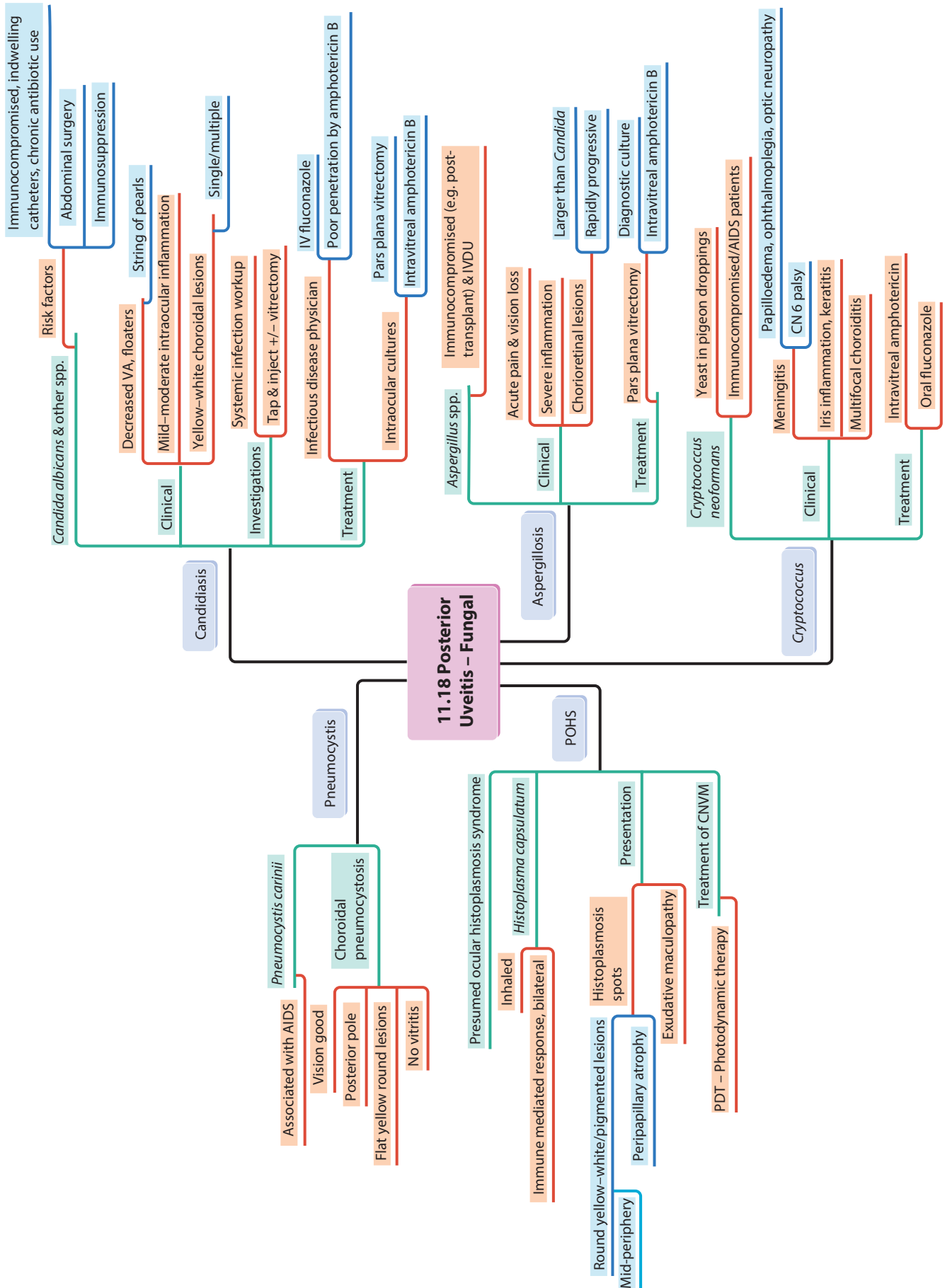


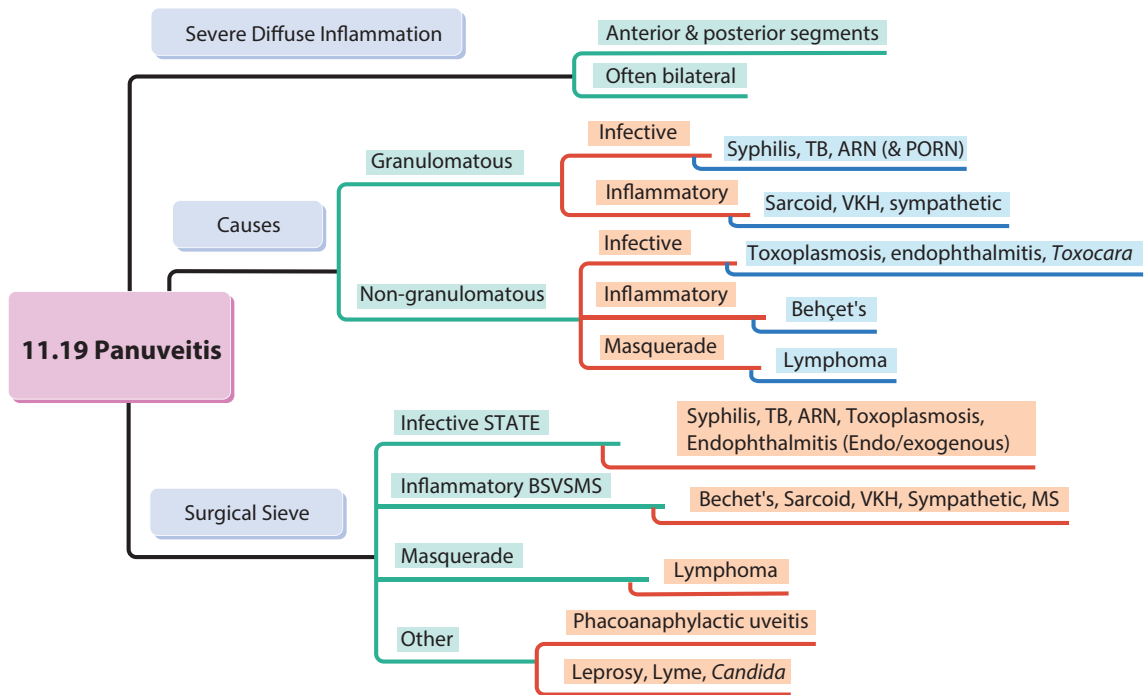


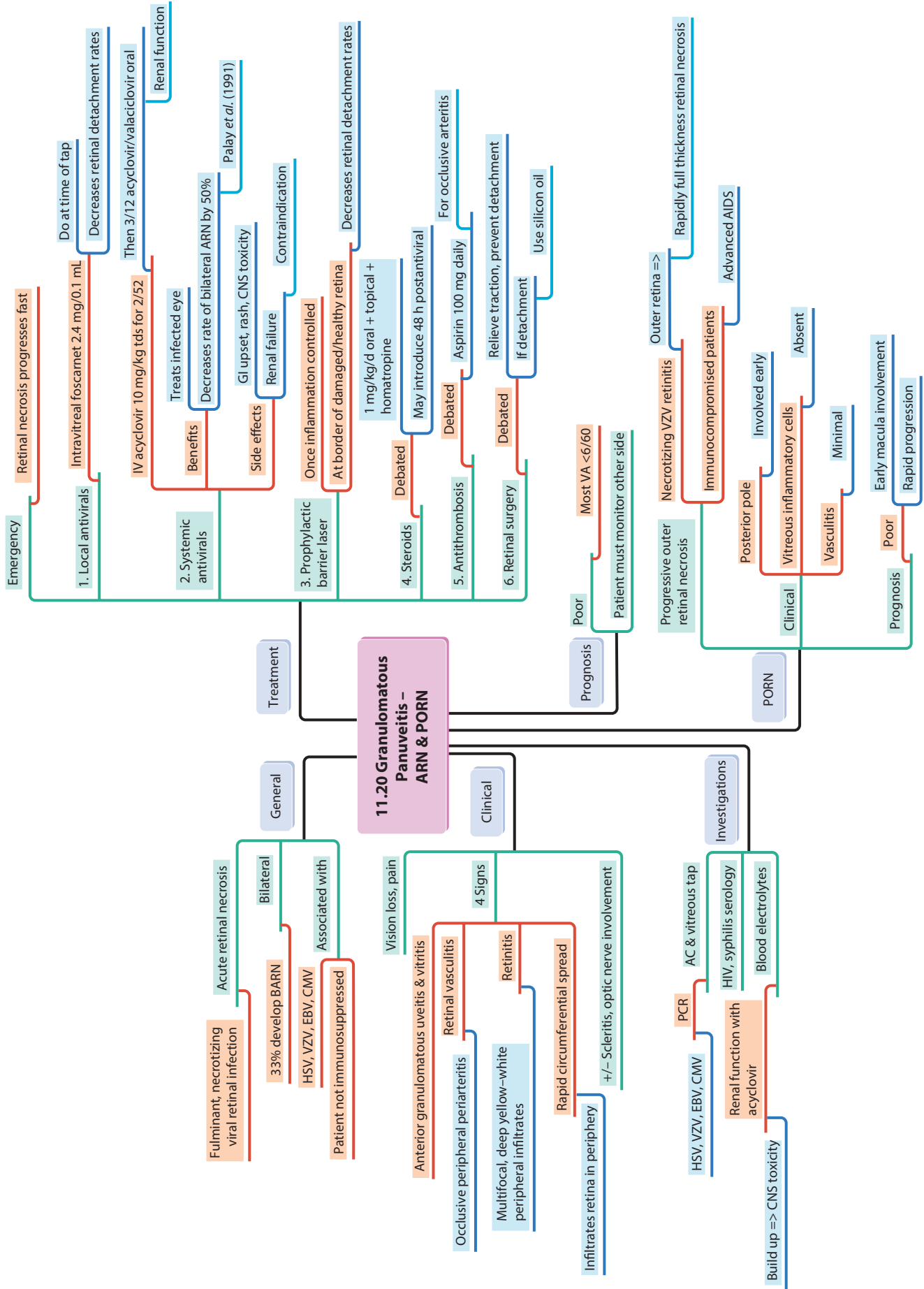


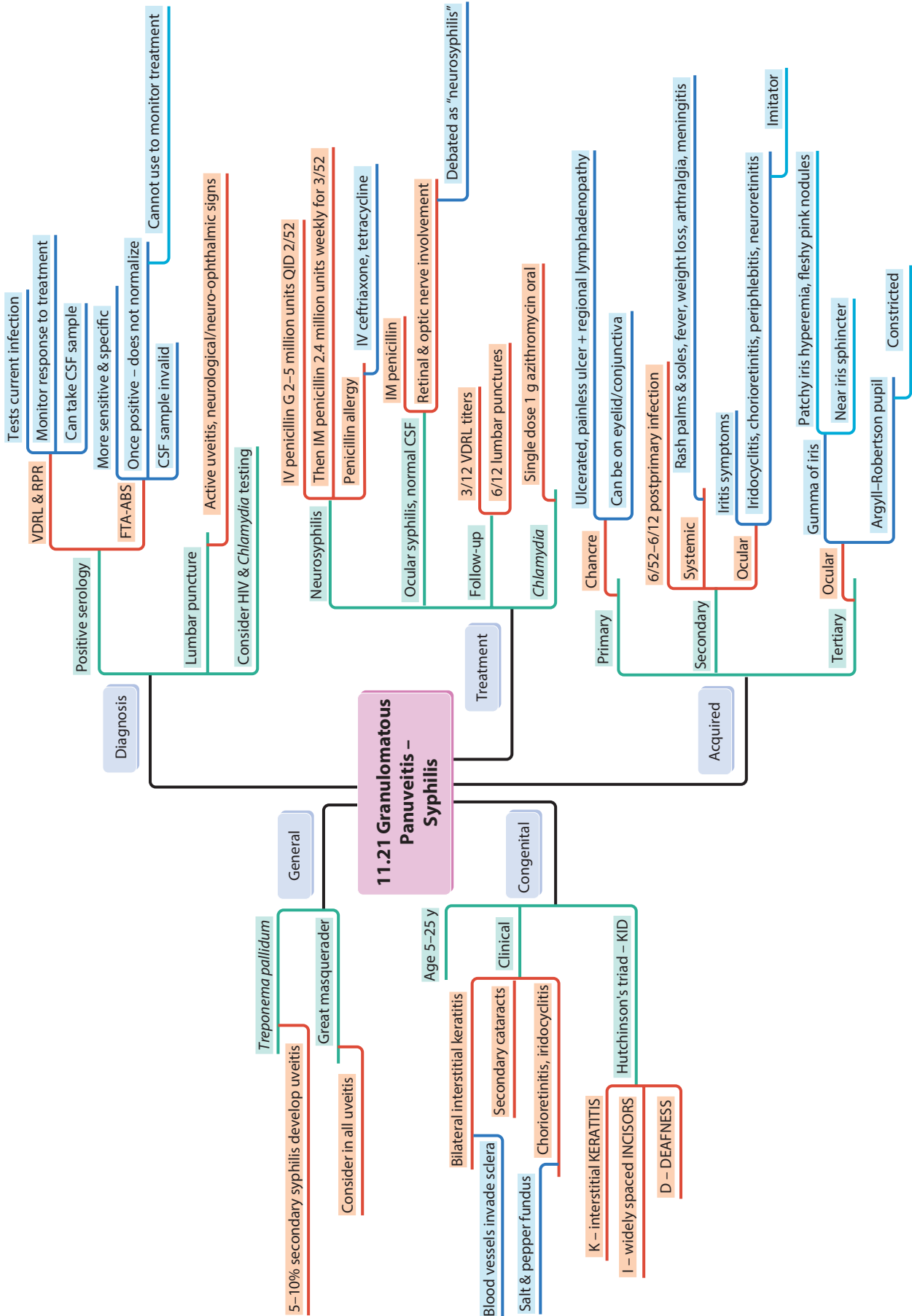


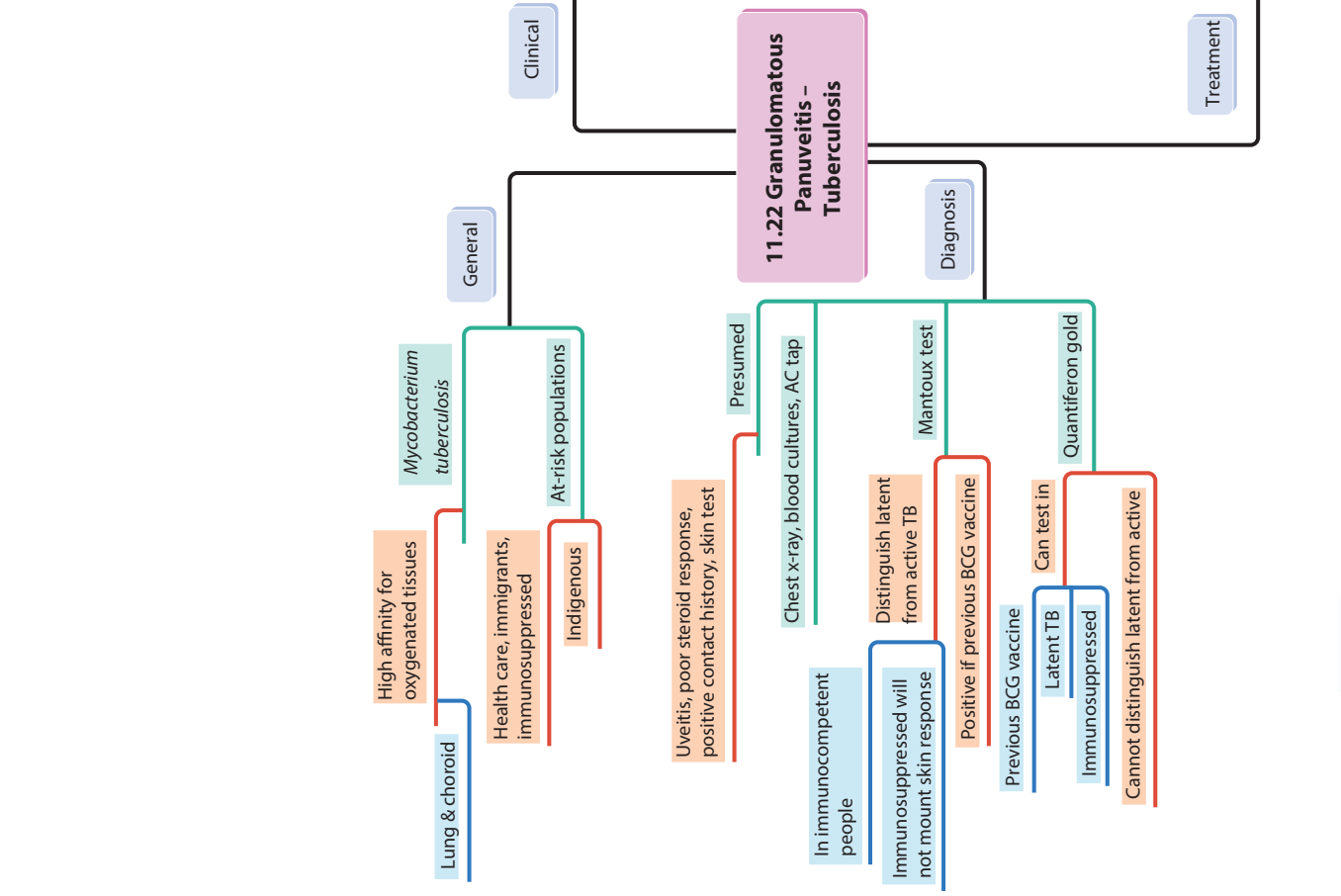
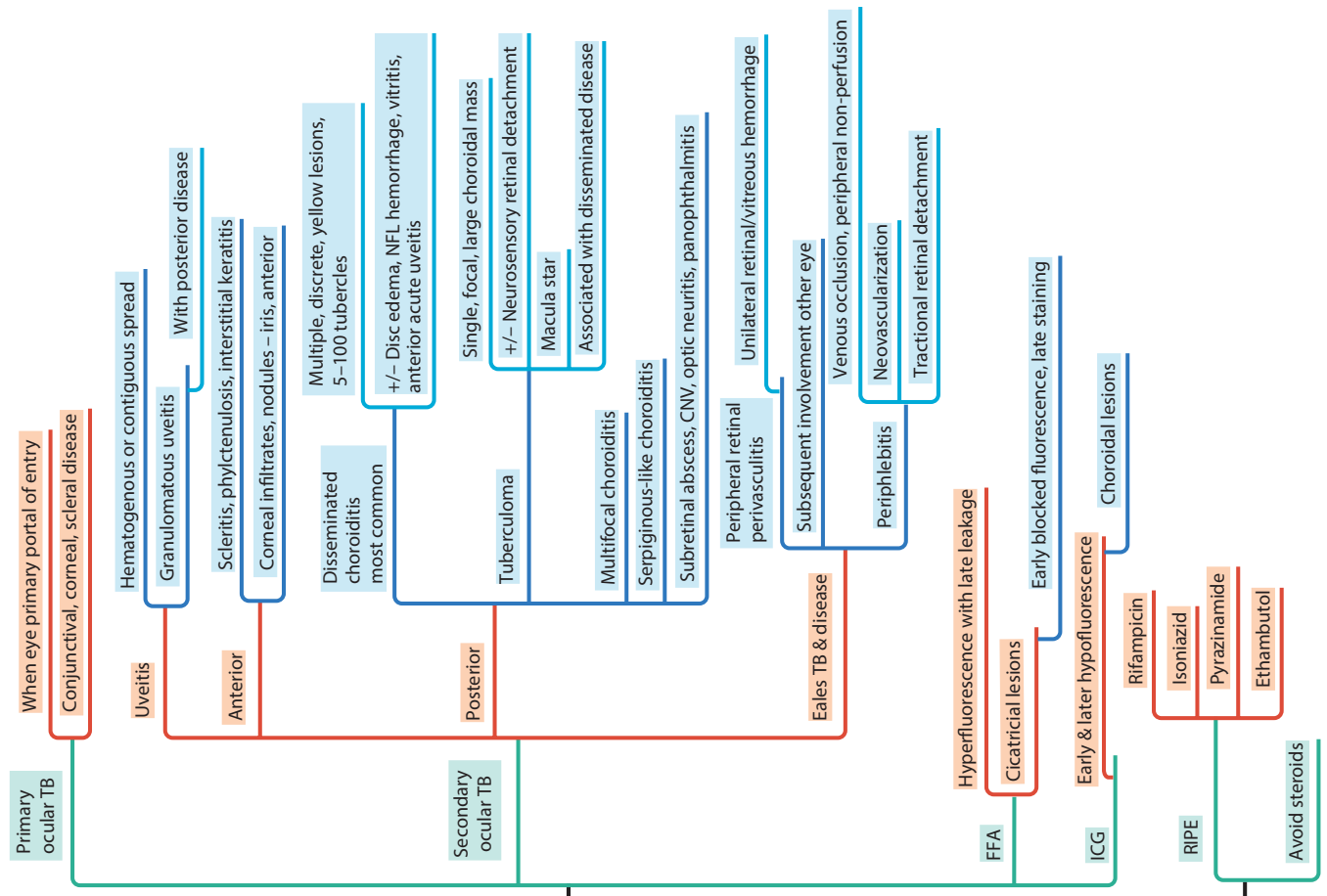


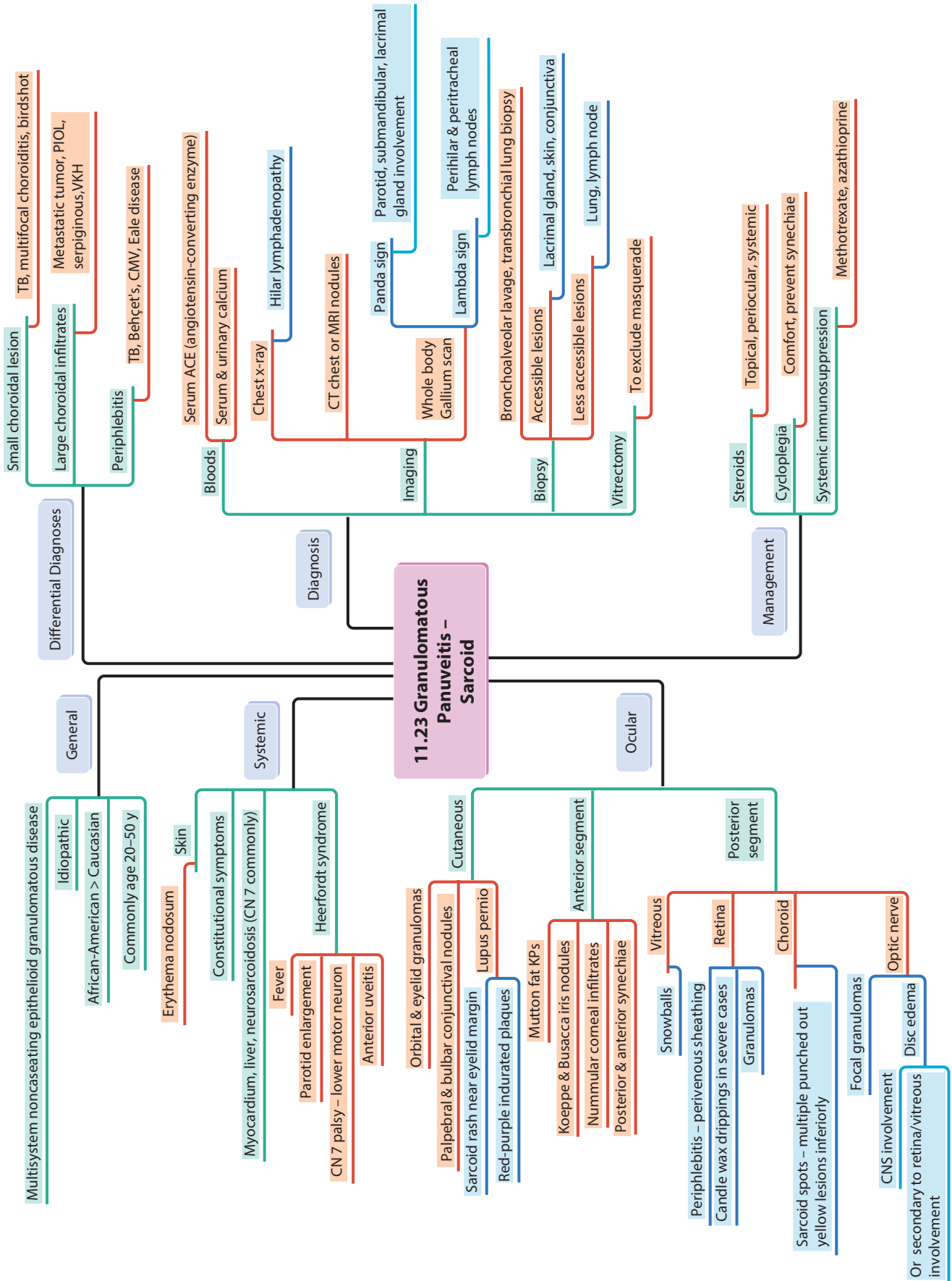


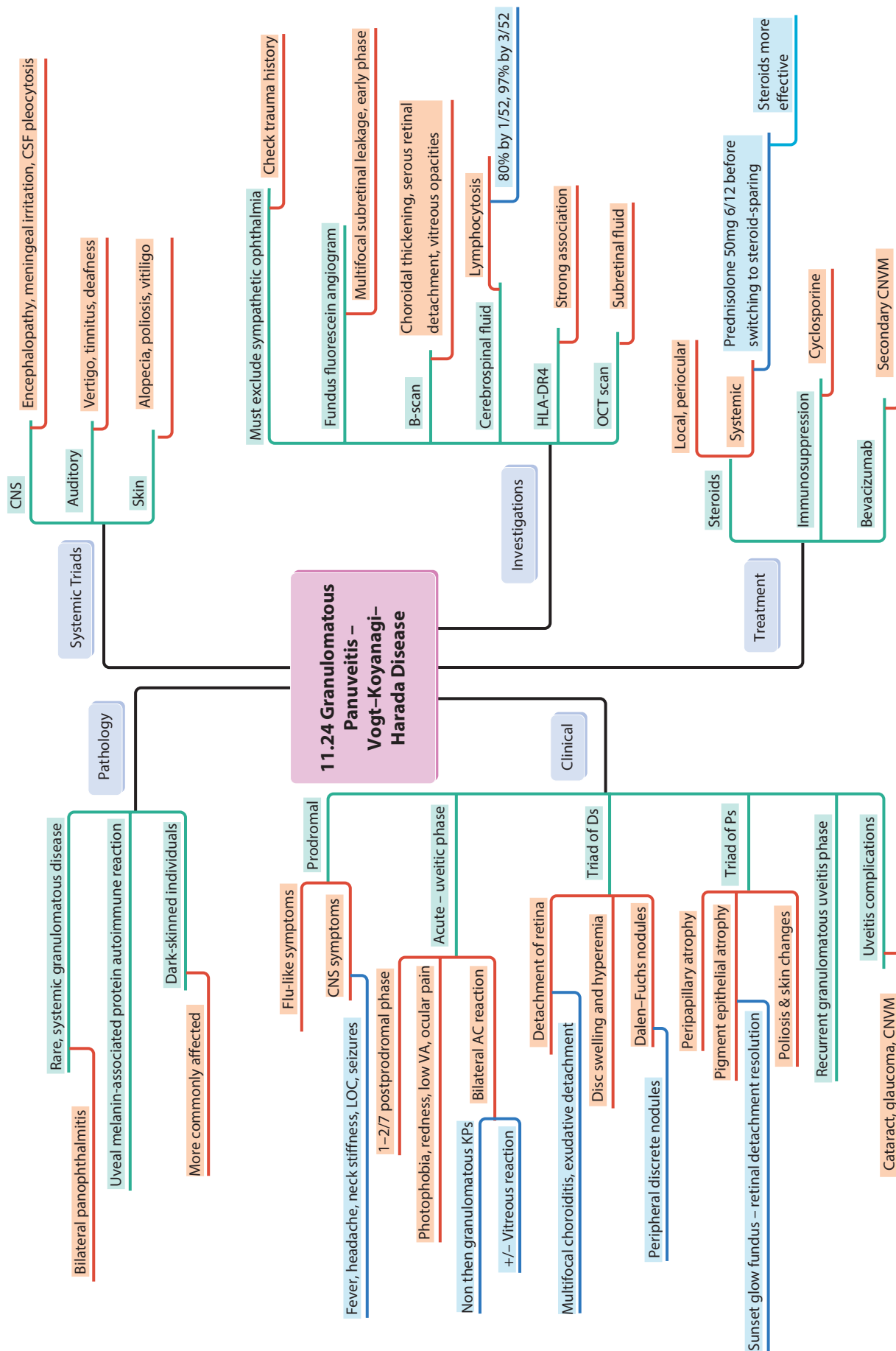


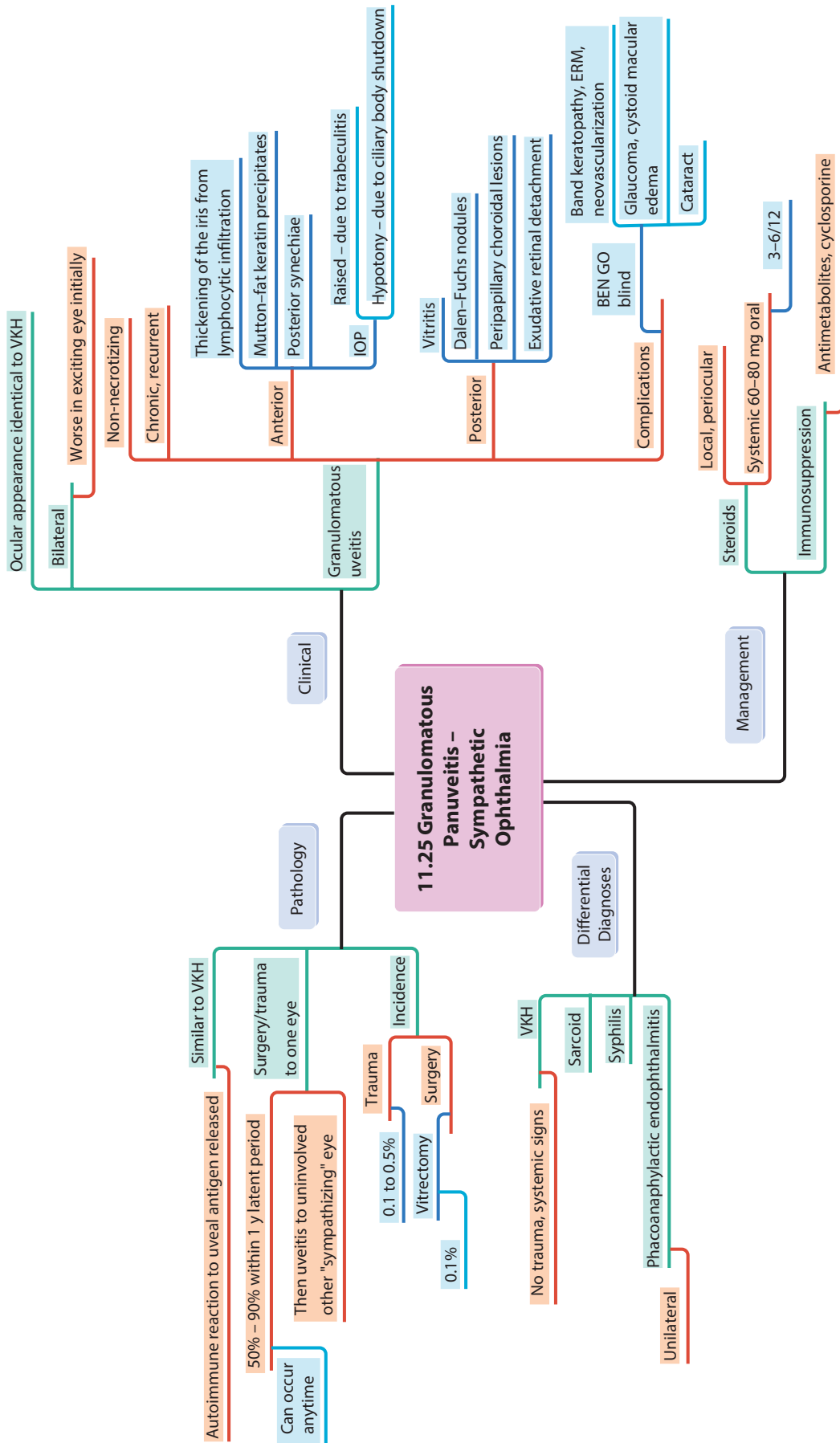


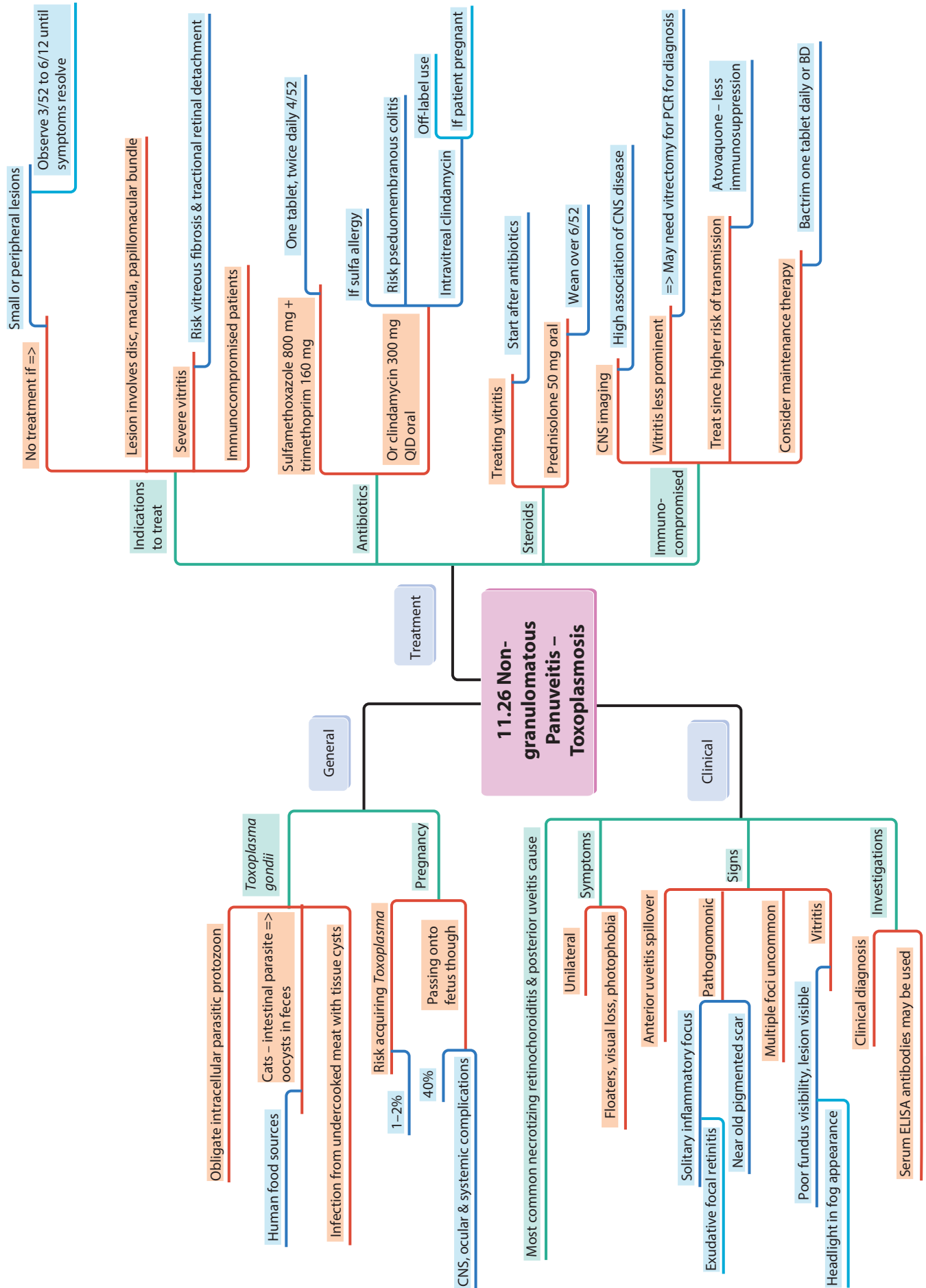


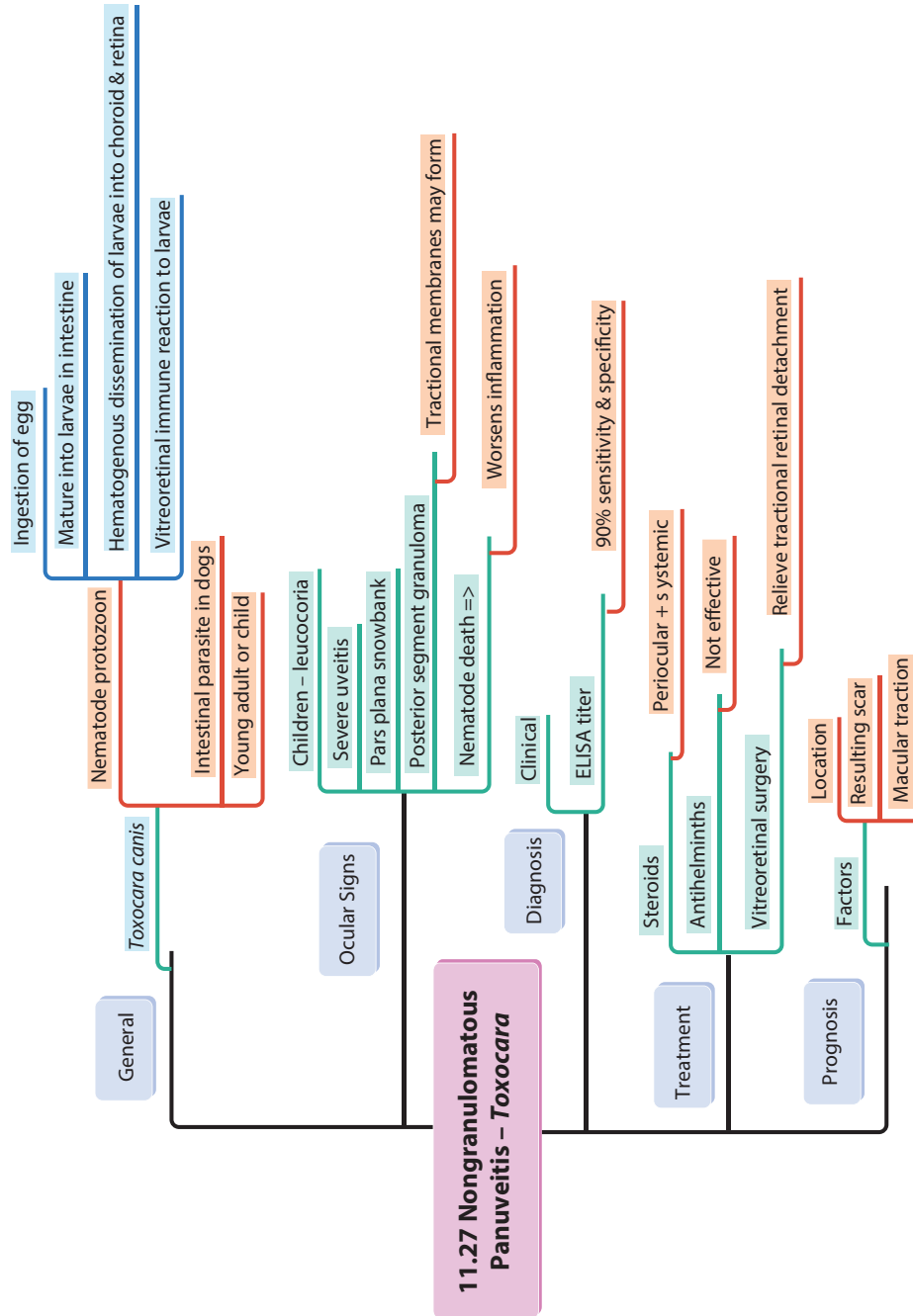


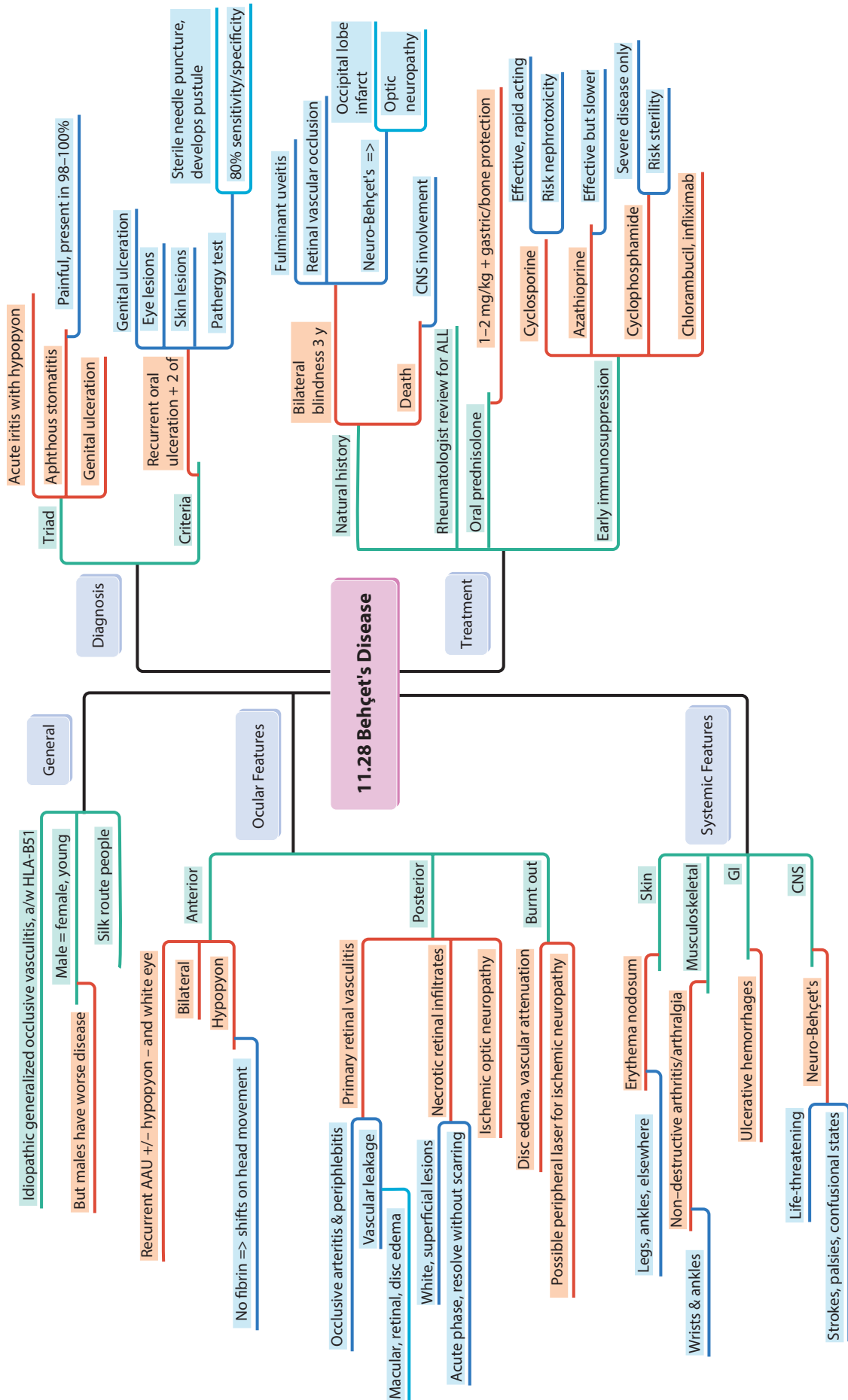


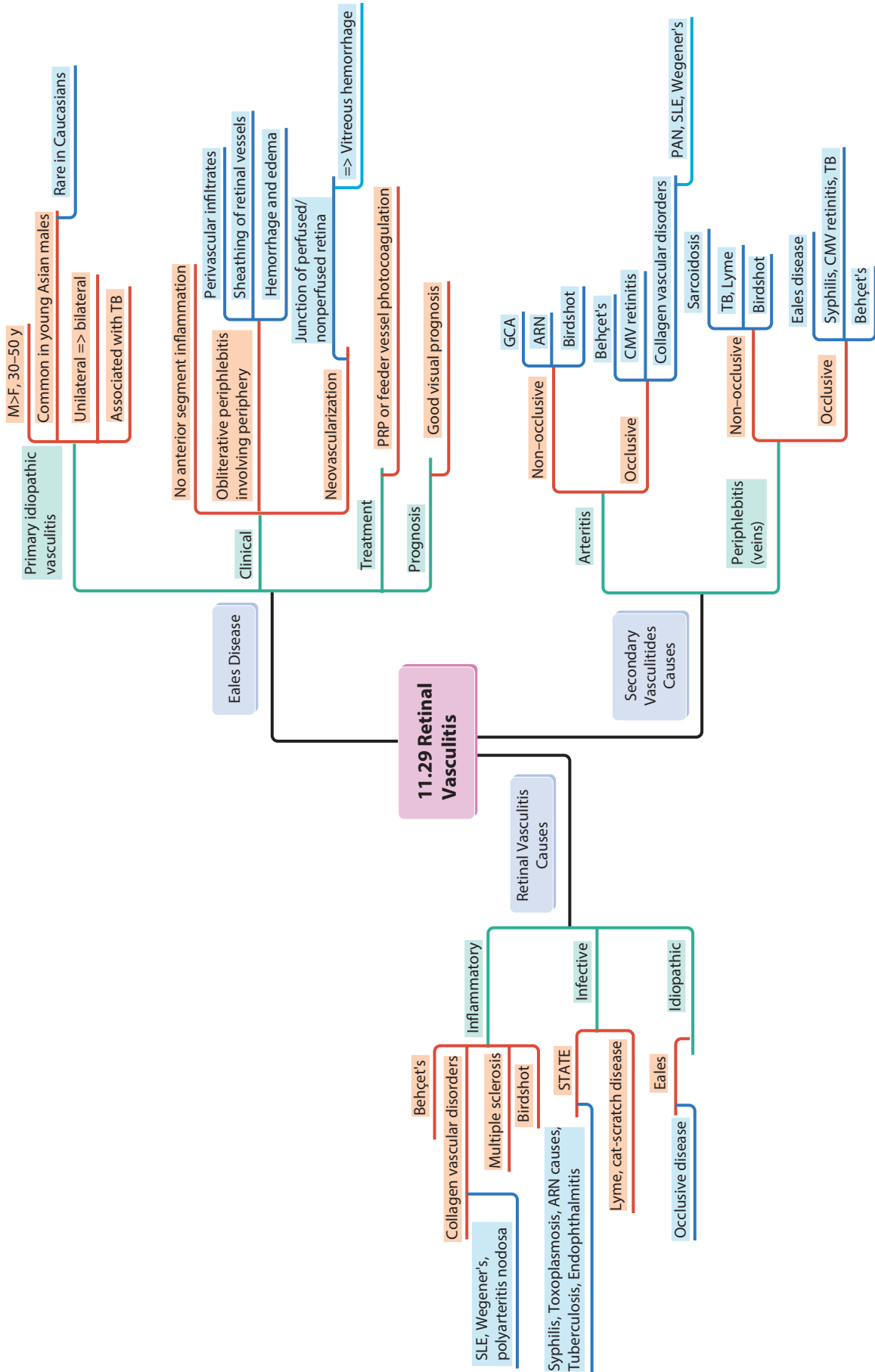


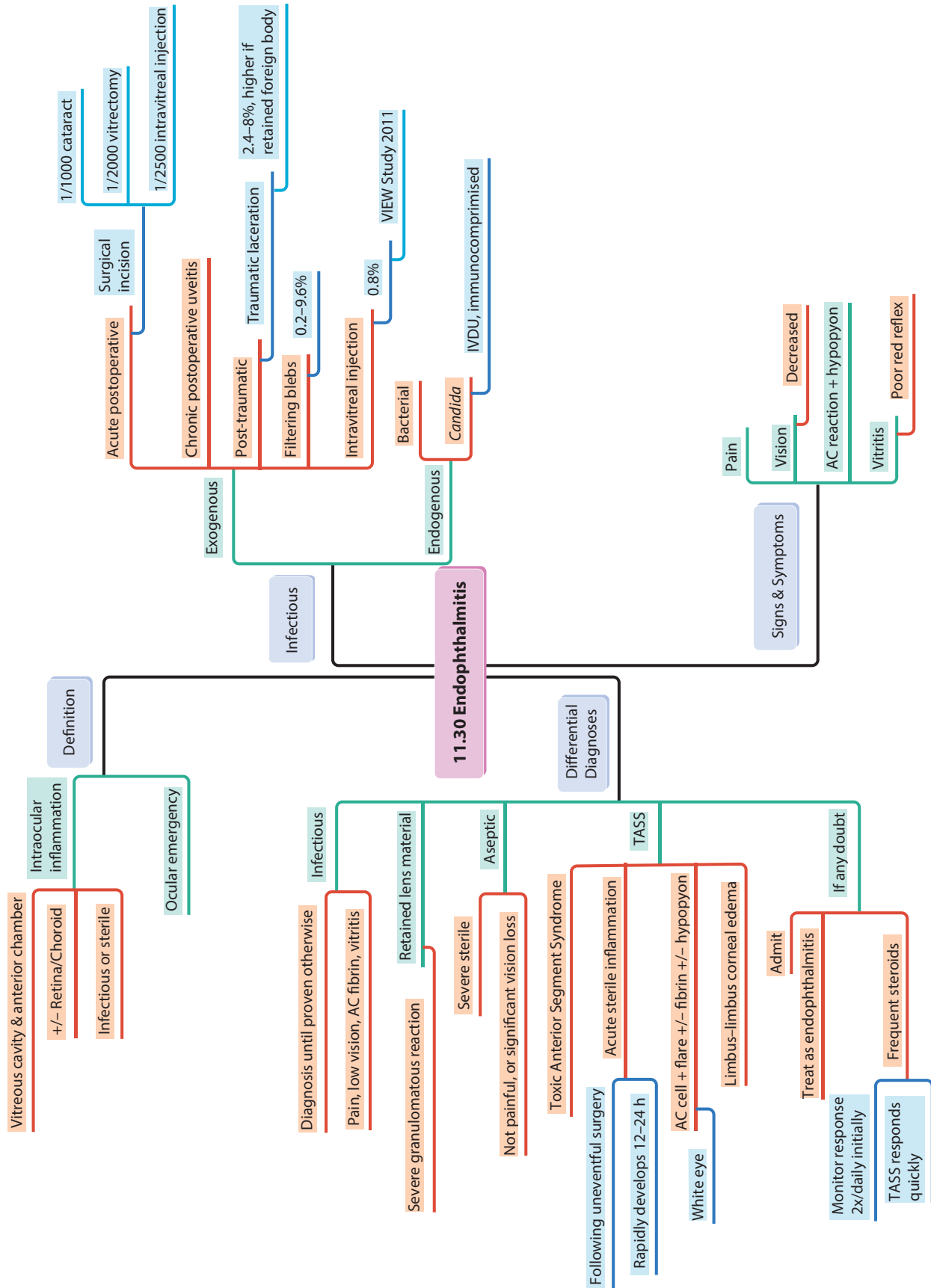


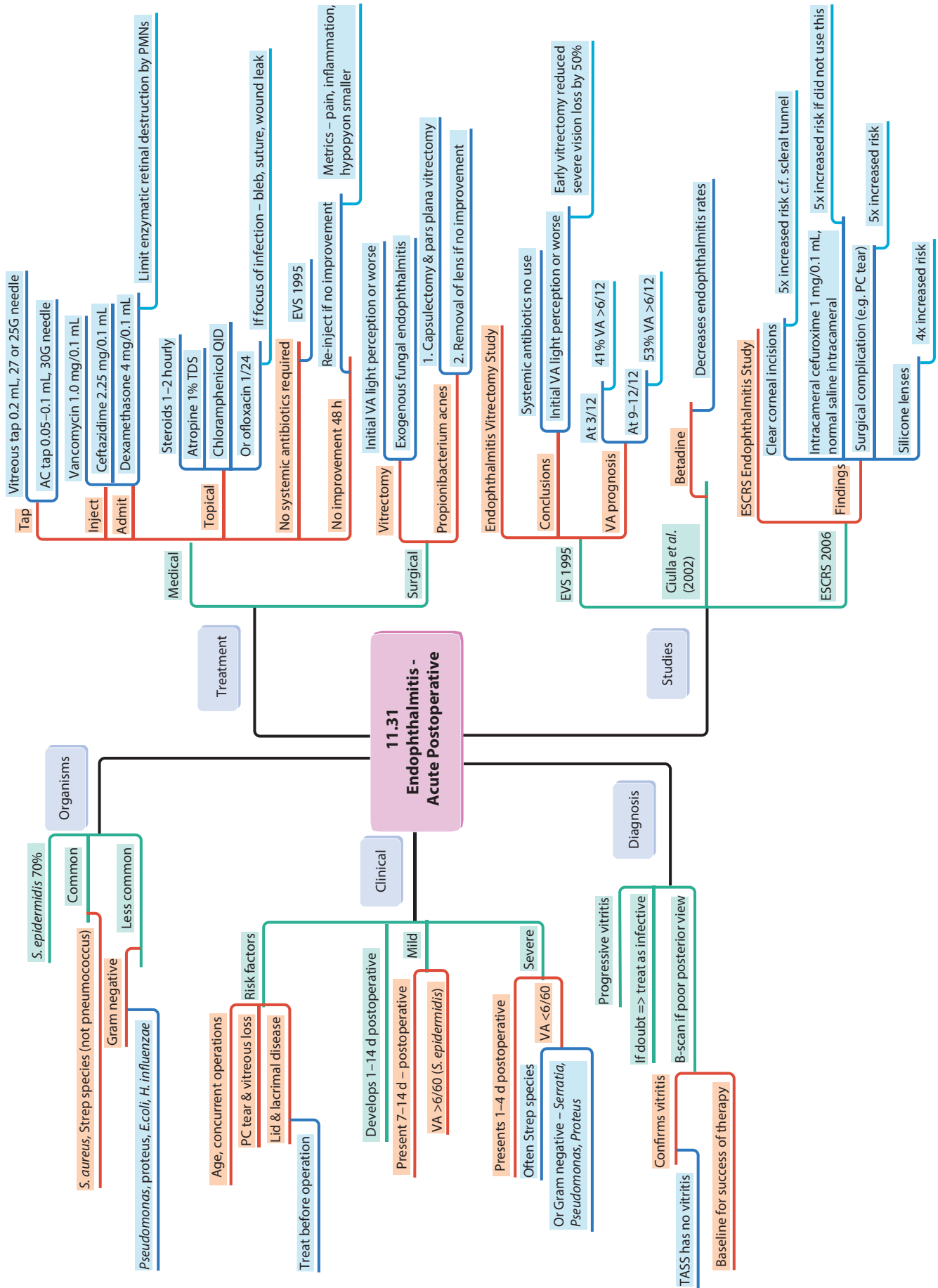


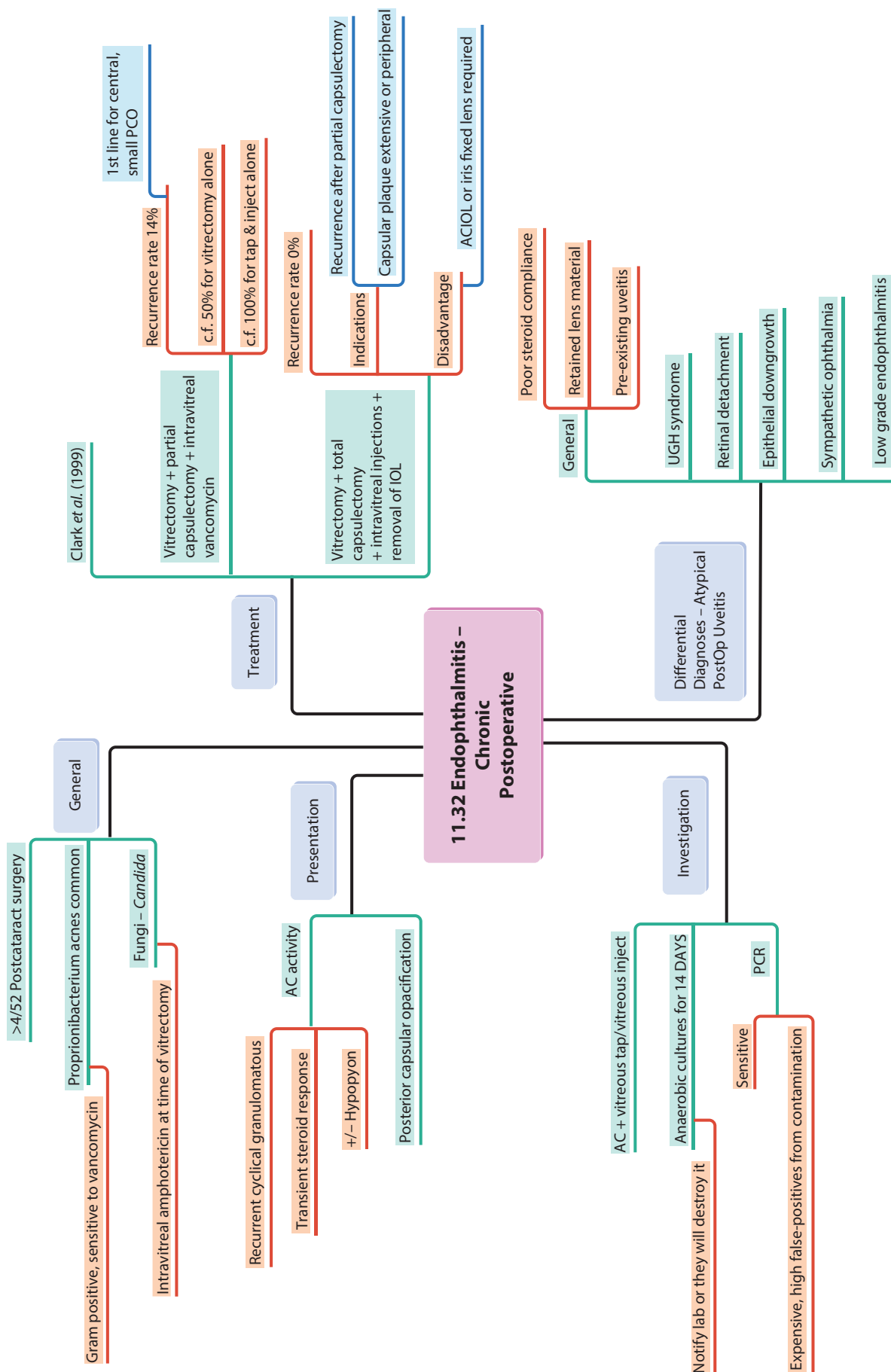


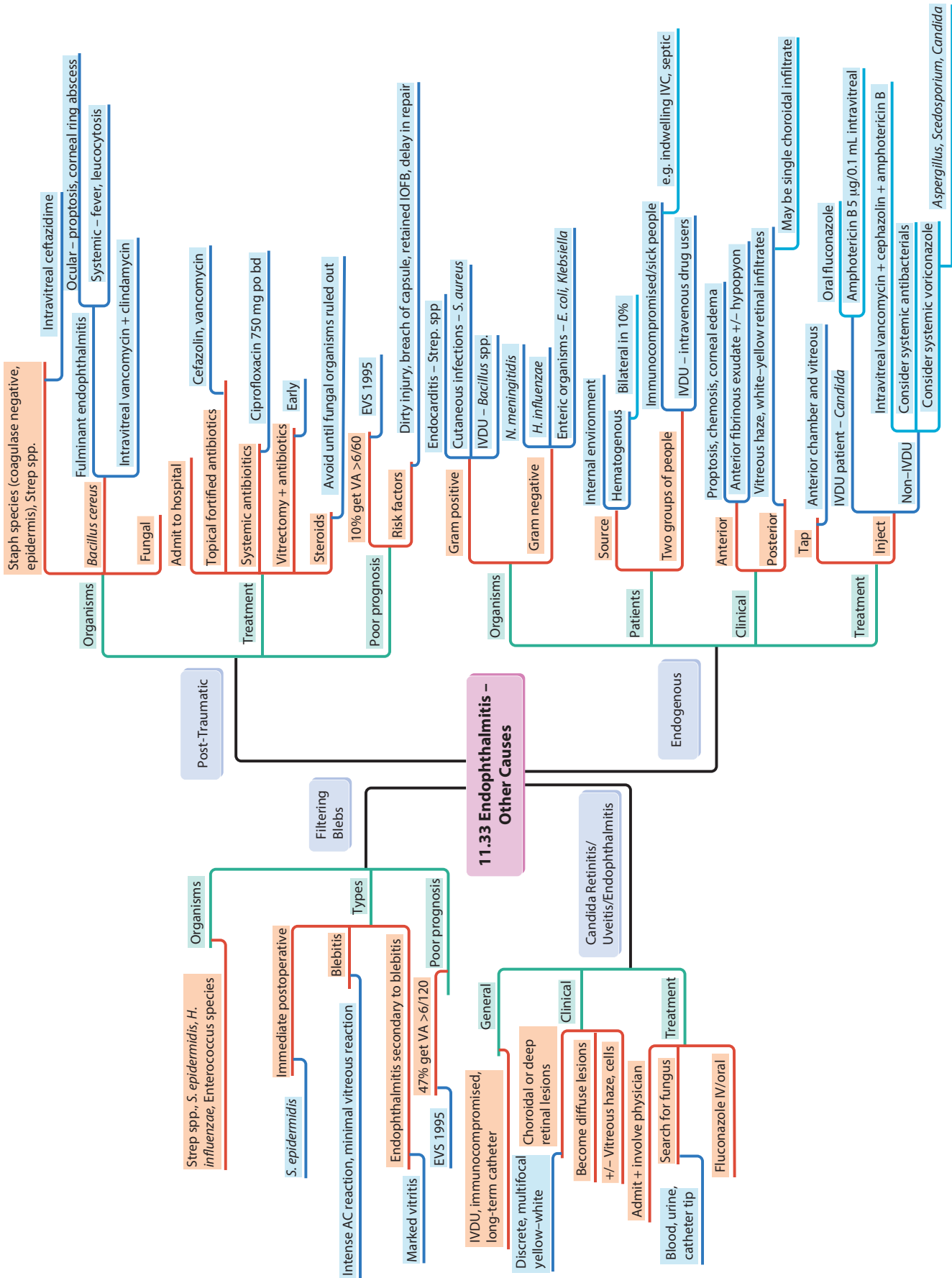


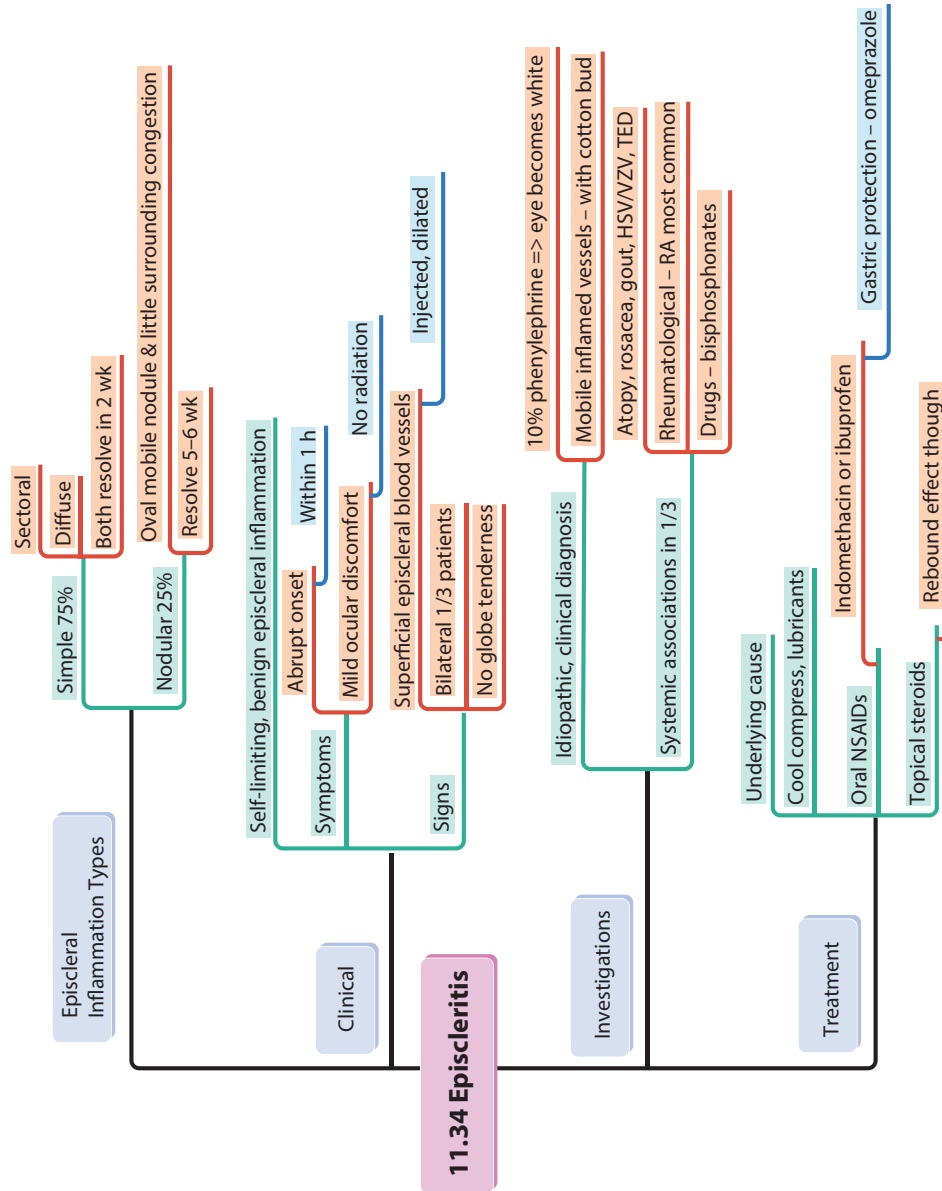


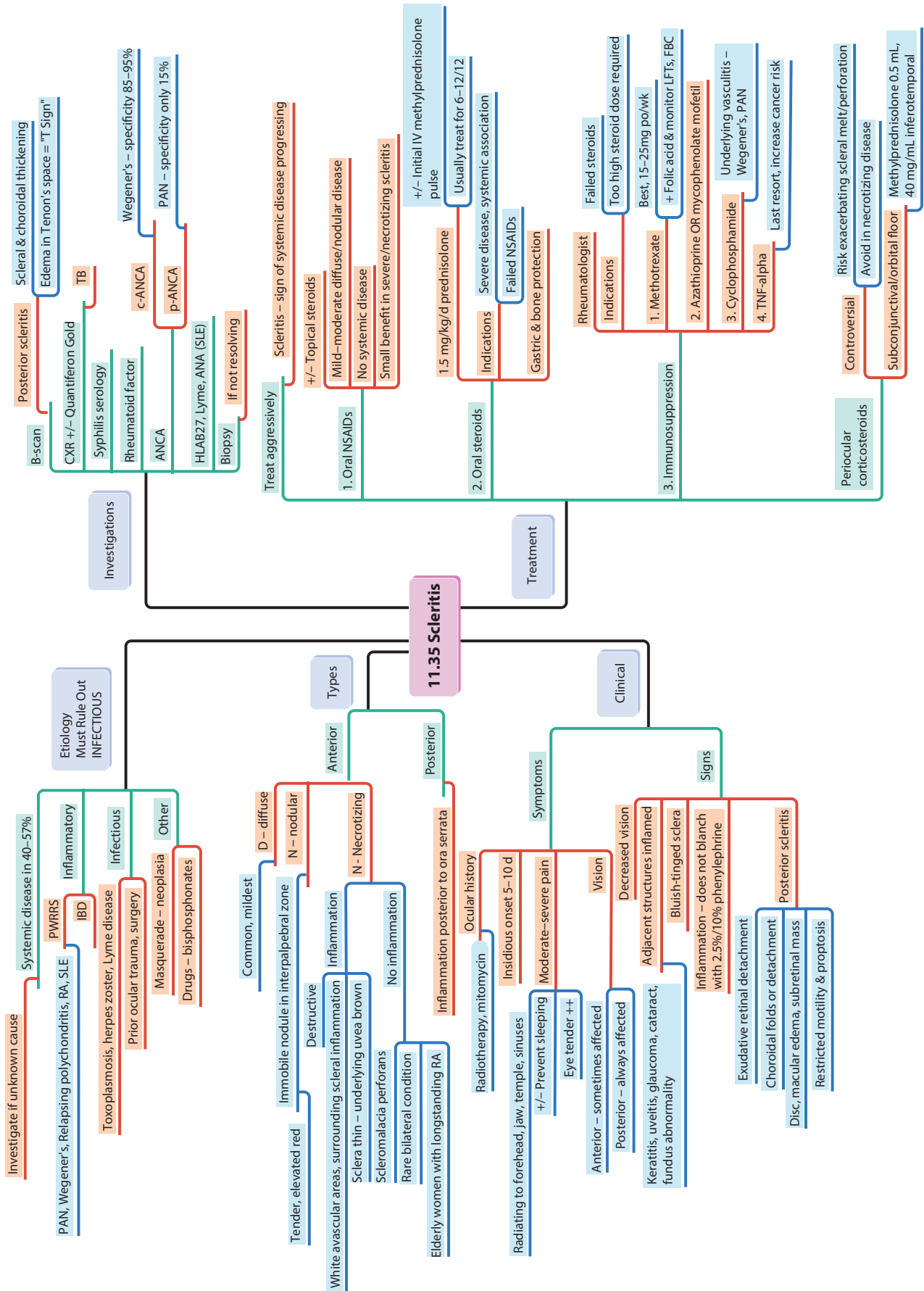


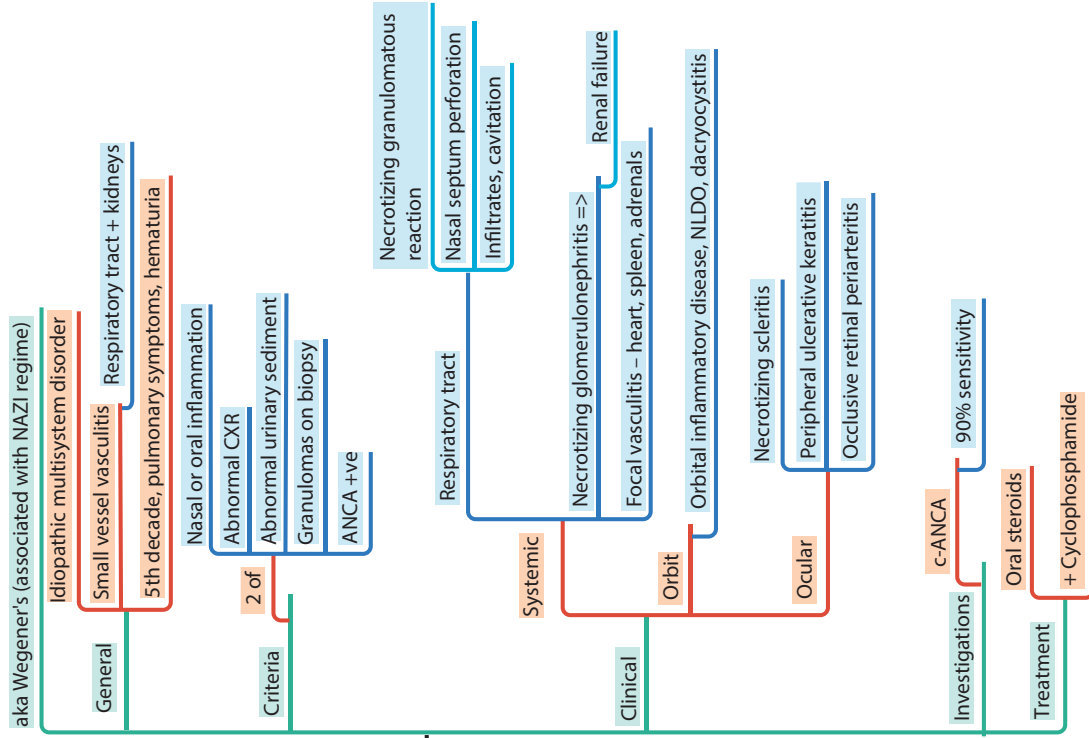








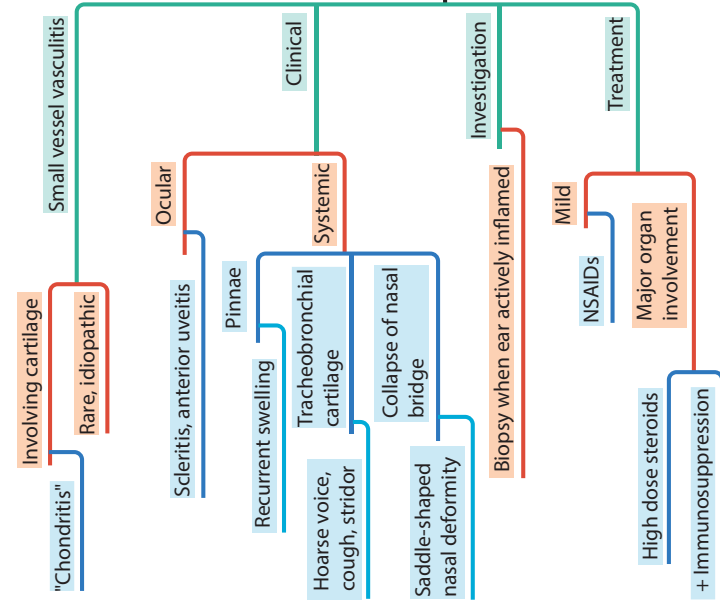


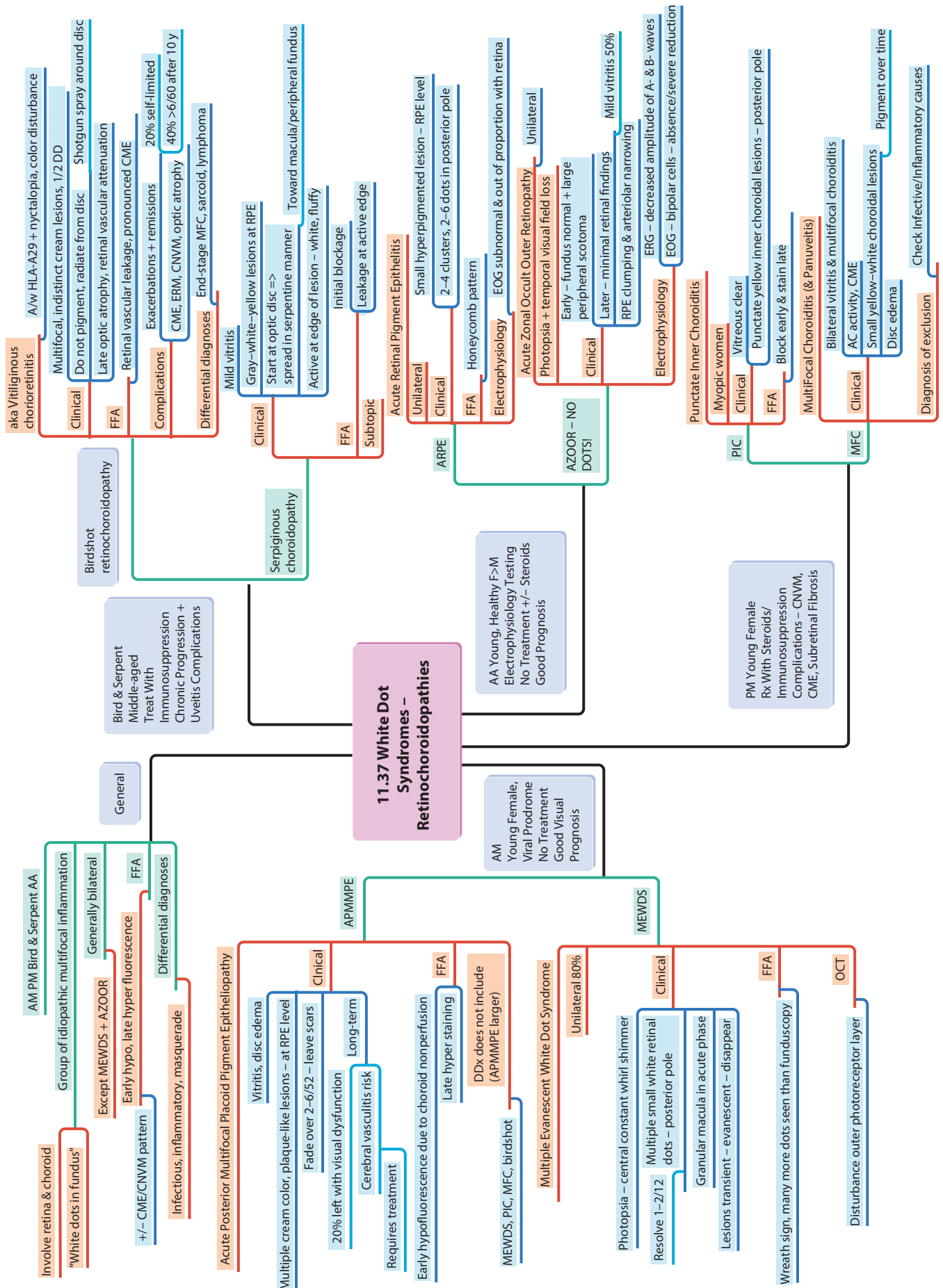


ANCA-Positive Granulomatosis, Granulomatosis with Polyangiitis

11.36 Scleritis - Wegener's Granulomatosis & Relapsing Polychondritis

Relapsing Polychondritis





11.37 White Dot Syndromes - Retinochoroidopathies

Bird & Serpent Middle-aged
 Immunosuppression
 Chronic Progression +
 Uveitis Complications

Birdshot retinochoroidopathy

aka Vitiliginous chorioretinitis
 A/w HLA-A29 + nyctalopia, color disturbance
 Multifocal, indistinct cream lesions, 1/2 DD
 Do not pigment, radiate from disc
 Shotgun spray around disc
 Late optic atrophy, retinal vascular attenuation
 Retinal vascular leakage, pronounced CME
 Exacerbations + remissions
 20% self-limited
 CME, ERM, CNVM, optic atrophy
 40% >6/60 after 10 y
 End-stage MFC, sarcoid, lymphoma

Serpiginous chorooidopathy

Mild vitritis
 Gray-white-yellow lesions at RPE
 Start at optic disc => spread in serpentine manner
 Toward macula/peripheral fundus
 Active at edge of lesion - white, fluffy
 Initial blockage
 Leakage at active edge

Acute Retinal Pigment Epitheliopathy

Unilateral
 Small hyperpigmented lesion - RPE level
 2-4 clusters, 2-6 dots in posterior pole
 Honeycomb pattern
 EOG subnormal & out of proportion with retina
 Acute Zonal Occult Outer Retinopathy
 Photopsia + temporal visual field loss

AZOOR - NO DOTS!

Clinical
 Early - fundus normal + large peripheral scotoma
 Later - minimal retinal findings
 RPE clumping & arteriolar narrowing
 Mild vitritis 50%

Electrophysiology
 ERG - decreased amplitude of A- & B- waves
 EOG - bipolar cells - absence/severe reduction

Punctate Inner Choroiditis

Myopic women
 Vitreous clear
 Punctate yellow inner choroidal lesions - posterior pole
 Block early & stain late

Multifocal Choroiditis (& Panuveitis)

Bilateral vitritis & multifocal choroiditis
 AC activity, CME
 Small yellow-white choroidal lesions
 Disc edema
 Diagnosis of exclusion - Check Infective/Inflammatory causes

General

Involve retina & choroid
 "White dots in fundus"
 AM PM Bird & Serpent AA
 Group of idiopathic multifocal inflammation
 Generally bilateral
 Except MEWDS + AZOOR
 Early hypo, late hyper fluorescence
 +/- CME/CNVM pattern
 Infectious, inflammatory, masquerade
 Differential diagnoses

Acute Posterior Multifocal Placoid Pigment Epitheliopathy

Vitritis, disc edema
 Multiple cream color, plaque-like lesions - at RPE level
 Fade over 2-6/52 - leave scars
 20% left with visual dysfunction
 Cerebral vasculitis risk
 Requires treatment
 Early hypofluorescence due to choroid nonperfusion
 Late hyper staining
 DDX does not include (APMMPE larger)

MEWDS, PIC, MFC, birdshot

Multiple Evanescent White Dot Syndrome
 Unilateral 80%
 Photopsia - central constant whirl shimmer
 Resolve 1-2/12
 Multiple small white retinal dots - posterior pole
 Granular macula in acute phase
 Lesions transient - evanescent - disappear
 Wreath sign, many more dots seen than funduscopy
 Disturbance outer photoreceptor layer

APMMPE

AM
 Young Female,
 Viral Prodrome
 No Treatment
 Good Visual Prognosis

MEWDS

AA Young, Healthy F>M
 Electrophysiology Testing
 No Treatment +/- Steroids
 Good Prognosis

PM Young Female
 Rx With Steroids/
 Immunosuppression
 Complications - CNVM,
 CME, Subretinal Fibrosis

