

DISEASES OF
THE NOSE, THROAT AND EAR

LOGAN TURNER'S DISEASES OF THE NOSE, THROAT AND EAR

Edited by

J. F. BIRRELL, MD, FRCS(ED)

*Consultant ENT Surgeon, Royal Hospital for Sick Children and City Hospital,
Edinburgh*

assisted by

G. D. MCDOWALL, FRCS(ED)

Consultant ENT Surgeon, Royal Infirmary and City Hospital, Edinburgh

K. MCLAY, FRCS(ED)

Consultant ENT Surgeon, Royal Infirmary and City Hospital, Edinburgh

J. R. MCCALLUM, FRCS(ED)

*Consultant ENT Surgeon, Western General Hospital, Royal Hospital for Sick Children
and City Hospital, Edinburgh*

A. G. D. MARAN, MD, FRCS(ED)

Consultant ENT Surgeon, Royal Infirmary and City Hospital, Edinburgh

EIGHTH EDITION

K. M. VARGHESE COMPANY

Post Box 7119

WADALA

BOMBAY-400031, INDIA

1977

© JOHN WRIGHT & SONS LTD 1977

All Rights Reserved. No part of this publication may be reproduced, stored in a retrieval system, or transmitted in any form or by any means, electronic, mechanical, photocopying, recording, or otherwise, without the prior permission of the copyright owner.

First Edition (based on the Third Edition of 'Porter's Throat, Nose, and Ear'), 1924

Second Impression, 1925

Second Edition, 1927

Reprinted, 1928

Reprinted, 1930

Third Edition, 1932

Reprinted, 1934

Fourth Edition, 1936

Reprinted, 1937

Reprinted, 1938

Reprinted, 1940

Fifth Edition, 1952

Sixth Edition, 1961

Reprinted, 1964

Seventh Edition, 1968

Eighth Edition, 1977

Reprinted, 1979

ISBN 0 7236 0434 7

THIS WORK IS DEDICATED
TO
THE MEMORY
OF
ARTHUR LOGAN TURNER
MD, LLD, FRCSE
AND TO THOSE CONTRIBUTORS TO THE PREVIOUS EDITIONS
WHO HAVE SINCE DIED

PREFACE TO THE EIGHTH EDITION

It is just over fifty years since Logan Turner, with the collaboration of the teaching staff of the Edinburgh Ear, Nose and Throat Department, published the first edition of this textbook. Its aim was to provide a comprehensive survey of the specialty for senior students and general practitioners. During successive editions this aim has been widened and the book enlarged to form a more detailed introduction to the specialty for postgraduates embarking on a career in otolaryngology.

In the preparation of this edition much thought has been given to the scope of the book. If it were to continue as a postgraduate preparation for the Fellowships it would require very considerable expansion, and might lose its individuality. On the other hand, the time allocated by the various universities for the teaching of otolaryngology is so curtailed, and the technical expansion of the specialty is now so great, that there is little time for the student to learn, with any degree of understanding, the basic principles far less the ramifications of the specialty. This is reflected in general practice, and many trainees eagerly embrace the opportunity of attending routine clinics to learn more about the conditions commonly met with in practice. Many have sought a book which, while covering the specialty, would deal with its basic principles.

It has been decided that this edition should revert to the original aim of the book, and it has been rewritten for house officers, registrars in their first year and general practitioners specifically while retaining brief notes on the more uncommon conditions. The detailed anatomical descriptions, which have always been a feature, have been simplified to a greater or lesser degree. Teaching in anatomy has changed over the years, and our intention has been to stress the more salient features and to discard the minutiae. The anatomical chapter on the ear remains more detailed, deliberately so because microsurgery has given it greater practical prominence, and reports on operations to general practitioners often assume their knowledge of the structure of the middle and inner ears. In the same way different sections place different emphasis on practical physiology, and again, that of the ear is most detailed.

Throughout the book an attempt has been made to achieve an essentially practical approach, to explain modern investigations, to discuss basic principles, to analyse the reasons for treatment and to give some positive answers to the questions which patients may ask of their general practitioners or of junior hospital staff. Some of the more simple procedures of treatment which are commonly carried out in hospital or in general practice are fully described, but the details of operations have given place to the aims of surgical treatment.

As in all previous editions the contributors are in active practice in the specialty in Edinburgh. I have been honoured by being invited by the authors of the previous edition to act as Editor, and I have undertaken the section on the nose and sinuses. George McDowall continues to be responsible for part of otology and is joined by Kenneth McLay in writing this section. John McCallum has taken over the pharynx and nasopharynx, and Arnold Maran has rewritten the sections on the larynx, bronchi and oesophagus.

About a hundred of the old illustrations have been discarded and there are some seventy new illustrations, many of them line drawings by Robert

Yorston of the Department of Otolaryngology in Dundee. Some new radiographs have been supplied by Professor Eric Samuel and his colleagues, and some of the contributors have included original illustrations. In order to save production costs the colour illustrations have been printed together, and both authors and publishers realize the frustration that this imposes on the readers and hope for their tolerance.

It is a very real pleasure to record once again our appreciation of the courtesy and co-operation which we have received from the publishers.

Edinburgh, 1976

J. F. BIRRELL

CONTENTS

SECTION I

J. F. Birrell

THE NOSE AND PARANASAL SINUSES

<i>Chapter</i>	<i>Page</i>
1 Anatomy and Physiology ✓	1
2 Clinical Examination ✓	12
3 Symptoms of Nasal Disease ✓	15
4 General Notes on Treatment ✓	20
5 The External Nose, Nasal Orifices and Nasal Septum	22
6 Epistaxis, Foreign Bodies and Parasites	29
7 Rhinitis	35
8 Specific Nasal Infections	39
9 Rhinorrhoea	43
10 The Catarrhal Child	50
11 Nasal Polyposis	56
12 Tumours of the Nose	61
13 Acute Sinusitis	65
14 Chronic Sinusitis	69
15 Complications of Sinusitis	79
16 Miscellaneous Affections of the Sinuses	84
17 Tumours of the Sinuses	89

SECTION II

J. R. McCallum

THE PHARYNX AND NASOPHARYNX

18 Anatomy and Physiology	93
19 Clinical Examination	96
20 Acute Inflammations of the Pharynx	99
21 Abscesses of the Pharynx	105
22 Chronic Pharyngitis	107

<i>Chapter</i>	<i>Page</i>
23 Specific Infections of the Pharynx	109
24 Miscellaneous Pharyngeal Disorders	112
25 Tumours of the Pharynx and Tongue	115
26 Affections of the Tonsils	119
27 Tonsillectomy	123
28 Diseases of the Nasopharynx	129
29 Diseases of the Salivary Glands	137

SECTION III

A. G. D. Maran

THE LARYNX, BRONCHI AND OESOPHAGUS

30 Anatomy and Physiology of the Larynx	142
31 Investigation of Laryngeal Disease	149
32 Voice Problems	154
33 Acute Laryngotracheal Infections	158
34 Chronic Laryngeal Diseases	161
35 Tracheostomy	167
36 Benign Laryngeal Tumours	174
37 Cancer of the Larynx	178
38 Vocal Cord Paralysis	186
39 Laryngotracheal Trauma	191
40 Paediatric Laryngology	198
41 Endoscopy	207
42 Inhaled and Swallowed Foreign Bodies	215
43 Dysphagia	223
44 Cancer of the Hypopharynx	234
45 Neck Masses	239

SECTION IV

G. D. McDowall and K. McLay


THE EAR

<i>Chapter</i>	<i>Page</i>
46 Anatomy of the Ear	247
47 Physiology and Functional Examination of the Ear	263
48 Physiology of the Vestibular Apparatus	270
49 Symptoms of Ear Disease	277
50 Otagia	280
51 Clinical Examination	282
52 Local Aural Treatment	287
53 The Auricle	292
54 The External Acoustic Meatus	296
55 Inflammation of the External Acoustic Meatus	302
56 The Eustachian Tube	309
57 Acute Otitis Media	312
58 Chronic Non-suppurative Otitis Media	319
59 Chronic Suppurative Otitis Media	324
60 Acute Mastoiditis	331
61 Chronic Mastoiditis	338
62 Tympanoplasty	342
63 Facial Paralysis	344
64 Local Spread of Mastoid Infections	348
65 Labyrinthitis	350
66 Intracranial Complications	354
67 Sinus Thrombosis	364
68 Tuberculosis and Syphilis of the Ear	369
69 Otosclerosis	373
70 Conditions producing Vertigo	377
71 Malignant Tumours of the Ear	381
72 The Labyrinth and the Eighth Nerve	383
73 Congenital Deafness	402
<i>Plates I-X (following p. xi)</i>	
Index	407


List of Plates

- Plate I*
1. Septal haematoma.
 2. Bleeding area of septum.
 3. Enlarged posterior ends of inferior conchae.
 4. Tuberculous ulceration of the lateral wall of the nasal cavity.
- Plate II*
1. Lupus of the nose.
 2. Nasal polypus seen on anterior rhinoscopy.
 3. Nasal polypi. The epithelium of the polypus in the left side has become vascularized as it approaches the nostril.
 4. Naso-antral polypus seen on posterior rhinoscopy.
- Plate III*
1. Rhinophyma.
 2. Pus in middle meatus seen on anterior rhinoscopy.
 3. Pus in olfactory cleft seen on anterior rhinoscopy.
 4. Pus seen on posterior rhinoscopy.
- Plate IV*
- Mucocele of left frontal sinus.
- Plate V*
1. Vincent's angina.
 2. Diphtheria.
 3. Pharyngeal ulceration in acute leukaemia.
- Plate VI*
1. Retropharyngeal abscess.
 2. Keratosis of the pharynx.
 3. Lupus of the pharynx.
 4. Acute tonsillitis.
 5. Peritonsillar abscess.
- Plate VII*
1. The so-called 'adenoid facies'.
 2. Acute laryngitis.
 3. Pachydermia.
 4. Fibroma of vocal cord.
 5. Papilloma nipped between the vocal cords on phonation.
- Plate VIII*
1. Cancer of the left vocal cord.
 2. Laryngomalacia.
 3. Laryngocele.
 4. Laryngeal web.
- Plate IX*
1. Otitis externa.
 2. Polypus projecting beyond the external meatus.
- Plate X*
- Various appearances seen on examination of the drumhead.


PLATE I



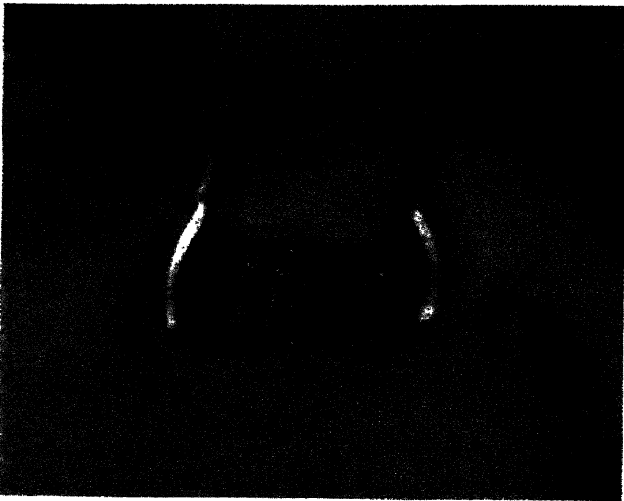
1. Septal haematoma.



2. Bleeding area of septum.




3. Enlarged posterior ends of inferior conchae.

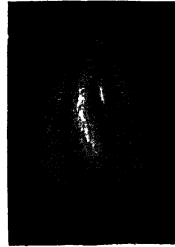


4. Tuberculous ulceration of the lateral wall of the nasal cavity.

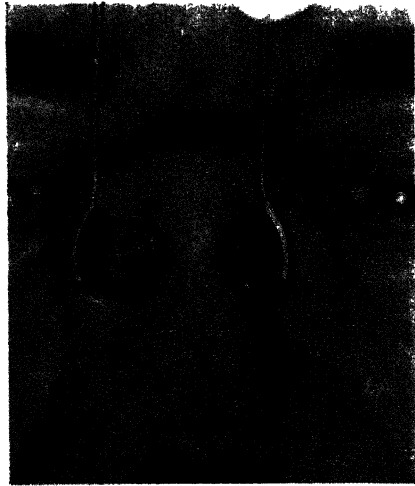
PLATE II




1. Lupus of the nose.



2. Nasal polypus seen on anterior rhinoscopy.




3. Nasal polypi. The epithelium of the polypus in the left side has become vascularized as it approaches the nostril.




4. Naso-antral polypus seen on posterior rhinoscopy.


PLATE III



1. Rhinophyma.



2. Pus in middle meatus seen on anterior rhinoscopy.




3. Pus in olfactory cleft seen on anterior rhinoscopy.



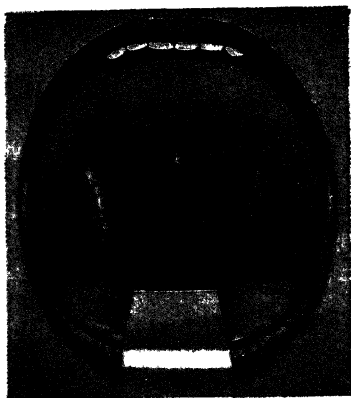
4. Pus seen on posterior rhinoscopy.

PLATE IV

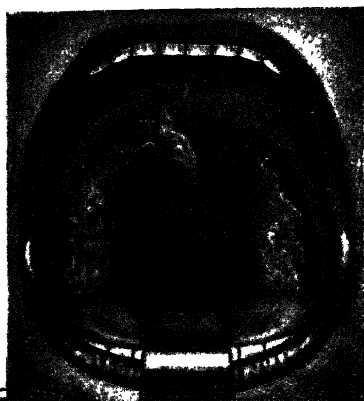

Mucocoele of left frontal sinus.

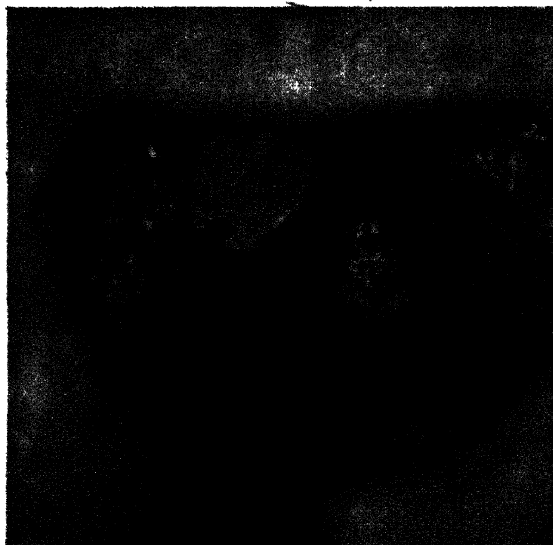
PLATE V



1. Vincent's angina.

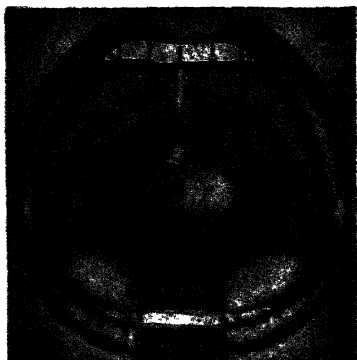

2. Diphtheria.

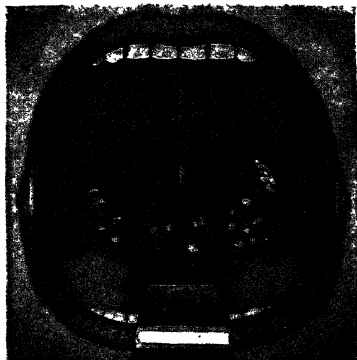


3. Pharyngeal ulceration in acute leukaemia.

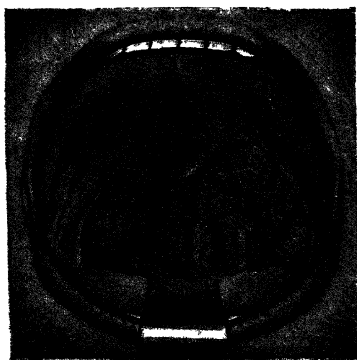
PLATE VI




1. Retropharyngeal abscess.




2. Keratoses of the pharynx.



3. Lupus of the pharynx.




4. Acute tonsillitis.




5. Peritonsillar abscess.


PLATE VII




1. The so-called 'adenoid facies'.




2. Acute laryngitis.



3. Pachydermia.

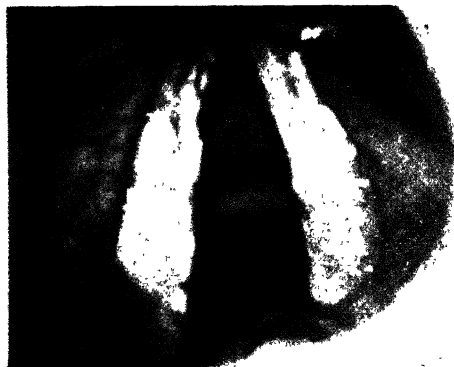

4. Fibroma of vocal cord.

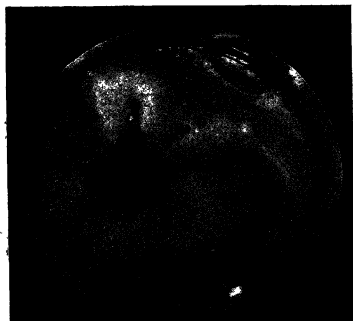

5. Papilloma nipped between the vocal cords on phonation.

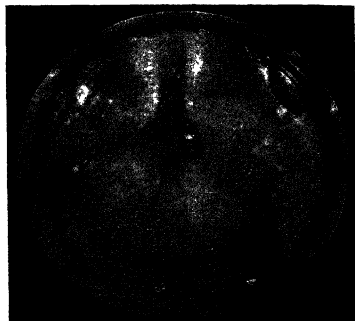
PLATE VIII



1. Cancer of the left vocal cord.



A

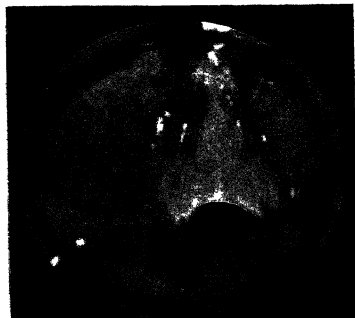


B

2. Laryngomalacia. A, Expiration; B, Inspiration. (By kind permission of the *'Journal of Laryngology and Otology'*.)

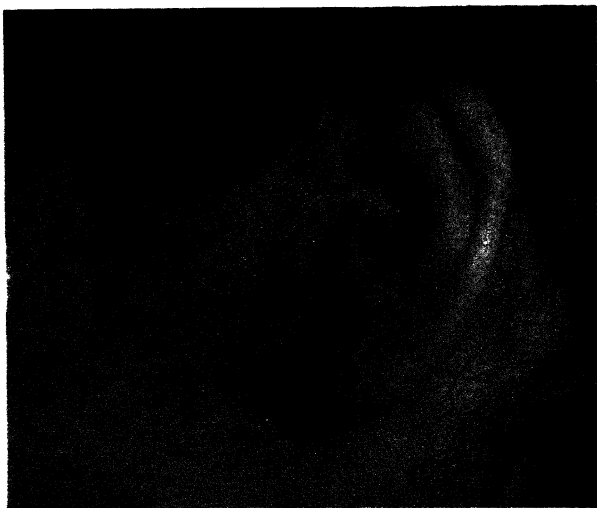


3. Laryngocele. (By kind permission of the *'Journal of Laryngology and Otology'*.)

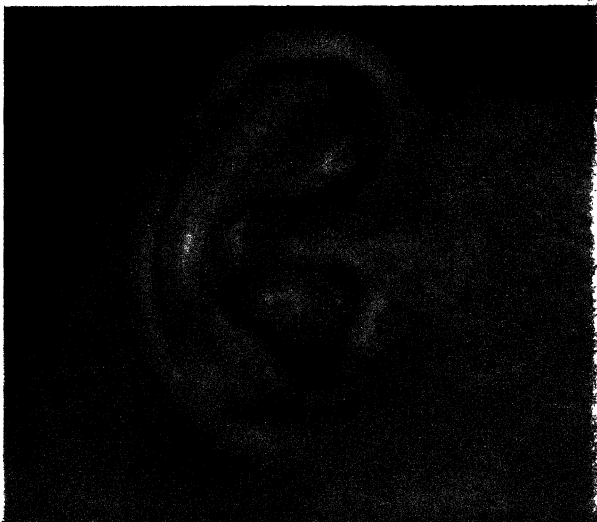

4. Laryngeal web. (By kind permission of the *'Journal of Laryngology and Otology'*.)

PLATE IX



1. Otitis externa. The inflammation has spread beyond the confines of the external meatus and extends on to the concha and adjacent parts of the face. Dandruff is apparent.



2. Polypus projecting beyond the external meatus.

- 1, Normal right tympanic membrane.
- 2, Markedly indrawn left drumhead, with prominence of the anterior and posterior malleolar folds. The handle of the malleus is greatly foreshortened.
- 3, Left drumhead. Secretory otitis media. Note the hair line at the upper margin of the exudate.
- 4, Right drumhead. Acute suppurative otitis media. The superficial vessels are seen radiating from the handle of the malleus.
- 5, Right drumhead. Acute suppurative otitis media during influenza, with haemorrhagic bullae on the drum membrane.
- 6, Right drumhead. Acute suppurative otitis media, with bulging of posterior superior quadrant.
- 7, From same patient as No. 6, showing appearances during healing process.
- 8, Right drumhead. Tuberculous otitis media with two perforations of the drumhead.
- 9, Chronic suppurative otitis media, left ear, with anterior central perforation. Posteriorly the drumhead shows a chalk patch.
- 10, Chronic suppurative otitis media, left ear, showing very large central perforation.
- 11, Chronic suppurative otitis media, right ear, with granulations covering the posterior superior quadrant.
- 12, Chronic suppurative otitis media, right ear, with granulations and cholesteatoma.
- 13, Chronic suppurative otitis media, left ear, showing large posterior marginal perforation and cholesteatoma.
- 14, Perforation of Shrapnell's membrane (attic perforation), left ear, with cholesteatoma.
- 15, Kidney-shaped scar in right drumhead, resulting from former middle ear suppuration.
- 16, Results of chronic middle ear suppuration in right ear: Anteriorly there is a chalk patch in the drumhead, and posteriorly a large perforation, showing the entrance to the round window niche.
- 17, Results of chronic suppuration in right ear. There is a large chalk patch in the drumhead, and a posterior marginal perforation, revealing the joint between the incus and stapes.
- 18, Large retracted scar in left drumhead, resulting from former chronic suppuration.
- 19, Shows the same ear as seen in 18, after inflation. The scar is now bulged outwards towards the meatus.
- 20, Otosclerosis. The normal transparent left drumhead shows a pinkish tinge of the promontory in the region of the oval window.

SECTION I

THE NOSE AND PARANASAL SINUSES

J. F. Birrell

CHAPTER 1

ANATOMY AND PHYSIOLOGY

THE EXTERNAL NOSE

The external nose is shaped as a triangular pyramid with its root above and its base directed downwards, and perforated by two nostrils or anterior nares, separated by a median septum. The free angle of the external nose is the apex, connected to the root by the dorsum, the upper part of which is termed the bridge. Each side of the external nose ends in a rounded eminence, the ala nasi, which forms the outer boundary of the nostril or anterior naris. The skin over the apex of the nose is thick and adherent, and contains many sebaceous glands. The external framework is osseous and cartilaginous. The nasal bones form the bridge, and each is united above with the frontal bone and laterally to the frontal process of the maxilla. Four paired cartilages—the lateral, the greater alar, the lesser alar and the vomeronasal—and one unpaired cartilage—the septal—complete the external framework, and their inter-relationship is shown in *Figs. 1 and 2*.

The chief muscles acting upon the external nose are the compressors and dilators of the ala nasi, and are supplied by the facial nerve. In confirmed mouth breathers the dilators tend to atrophy from disuse so that the anterior nares become narrow and slit-like.

Blood supply to the external nose derives from the external maxillary and ophthalmic arteries, while venous drainage is through the anterior facial and ophthalmic veins, the latter being a tributary of the cavernous sinus. Lymphatic drainage follows the anterior facial vein and opens into the submandibular glands, but other lymphatics drain into the pre-auricular glands.

THE NASAL VESTIBULE

This is the name given to the entrance to the nasal cavity, within the nostrils. It is lined by skin which contains hair follicles, and it ends at the mucocutaneous junction. The part between the two nasal vestibules, containing the anterior end of the nasal septum, is called the columella.

SECTION I

THE NOSE AND PARANASAL SINUSES

J. F. Birrell

CHAPTER 1

ANATOMY AND PHYSIOLOGY

THE EXTERNAL NOSE

The external nose is shaped as a triangular pyramid with its root above and its base directed downwards, and perforated by two nostrils or anterior nares, separated by a median septum. The free angle of the external nose is the apex, connected to the root by the dorsum, the upper part of which is termed the bridge. Each side of the external nose ends in a rounded eminence, the ala nasi, which forms the outer boundary of the nostril or anterior naris. The skin over the apex of the nose is thick and adherent, and contains many sebaceous glands. The external framework is osseous and cartilaginous. The nasal bones form the bridge, and each is united above with the frontal bone and laterally to the frontal process of the maxilla. Four paired cartilages—the lateral, the greater alar, the lesser alar and the vomeronasal—and one unpaired cartilage—the septal—complete the external framework, and their inter-relationship is shown in *Figs. 1 and 2*.

The chief muscles acting upon the external nose are the compressors and dilators of the ala nasi, and are supplied by the facial nerve. In confirmed mouth breathers the dilators tend to atrophy from disuse so that the anterior nares become narrow and slit-like.

Blood supply to the external nose derives from the external maxillary and ophthalmic arteries, while venous drainage is through the anterior facial and ophthalmic veins, the latter being a tributary of the cavernous sinus. Lymphatic drainage follows the anterior facial vein and opens into the submandibular glands, but other lymphatics drain into the pre-auricular glands.

THE NASAL VESTIBULE

This is the name given to the entrance to the nasal cavity, within the nostrils. It is lined by skin which contains hair follicles, and it ends at the mucocutaneous junction. The part between the two nasal vestibules, containing the anterior end of the nasal septum, is called the columella.

THE NASAL CAVITY

The lateral wall of each nasal cavity is convoluted in appearance due to the three conchae or turbinates (*Fig. 3*). The superior and middle conchae constitute the medial surface of the lateral mass of the ethmoid bone. The inferior concha is a separate bone attached to the maxilla. Each concha overhangs a channel or meatus corresponding in length to the concha beneath which it is situated. All three reach forwards from the posterior

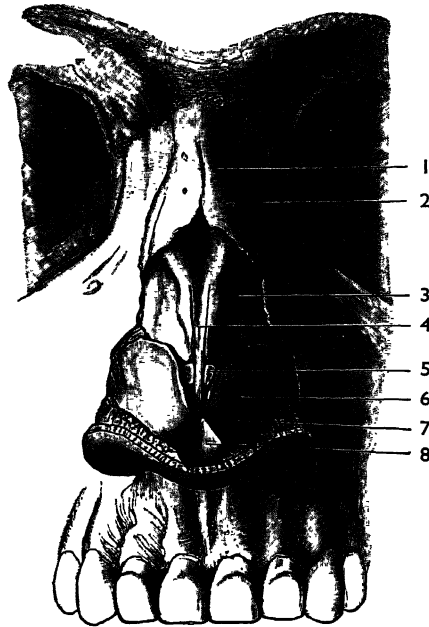

Fig. 1. The external nose. 1, Nasal bone; 2, Frontal process of maxilla; 3, Lateral cartilage; 4, Cartilage of septum; 5, Accessory cartilage; 6, Greater alar cartilage; 7, Lateral crus; 8, Medial crus.

aperture of the nose, called the posterior naris or choana. The superior meatus is confined to the posterior third of the lateral wall of the nasal cavity; the middle meatus runs forward about two-thirds of its length; and the inferior meatus extends the whole length of the lateral wall of the cavity. The space above the superior concha is called the spheno-ethmoidal recess. Between the three conchae and the nasal septum, which separates the two nasal cavities, is a space called the olfactory cleft.

The meatuses are of clinical importance in respect of their contents. The nasolacrimal canal opens into the anterior end of the inferior meatus. Communication between the paranasal sinuses and the nasal cavity takes place through openings, or ostia, in the middle and superior meatuses. The frontal, anterior ethmoidal and maxillary sinuses open into the middle

meatus; the posterior ethmoidal sinuses drain into the superior meatus; the sphenoidal sinus communicates with the sphenothmoidal recess. An appreciation of the detailed structure of the meatuses will be obtained by studying *Fig. 4* in which the middle concha has been removed, and *Fig. 5* in which the superior concha has also been removed.

The nasal septum (*Fig. 6*) separates the two nasal cavities and is partly osseous and partly cartilaginous. The perpendicular plate of the ethmoid and

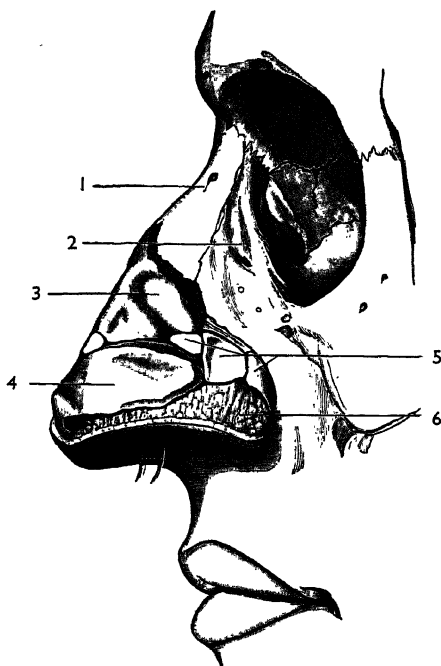


Fig. 2. The external nose. 1, Nasal bone; 2, Frontal process of maxilla; 3, Lateral cartilage; 4, Greater alar cartilage; 5, Lesser alar cartilages; 6, Fatty tissue of ala nasi.

the vomer bone constitutes the upper and posterior part, while the septal cartilage completes the septum anteriorly, stretching from the dorsum of the nose above to the nasal crests of the maxillary and palatine bones below. The main arterial supply of the nasal septum arises from the septal branch of the sphenopalatine artery, and this anastomoses with the greater palatine artery and septal branches of the superior labial and anterior ethmoidal arteries at the antero-inferior part of the septum, the so-called 'bleeding area' or Little's area, which is of importance in epistaxis (*Fig. 7*). The lateral nasal wall is supplied by lateral branches from these vessels. Venous drainage from the nasal cavity is through the sphenopalatine foramen to the pterygoid

plexus, but some veins join the superior ophthalmic vein in the orbit, while others enter the anterior facial vein. Lymphatic vessels from the anterior part of the cavity join cutaneous lymphatics to the submandibular glands, and so to the superior deep cervical glands. Posteriorly the lymphatic drainage is to the medial deep cervical glands.

The nasal membrane consists of a layer of fairly dense connective tissue containing large blood vessels and some unstriped muscle fibres. There

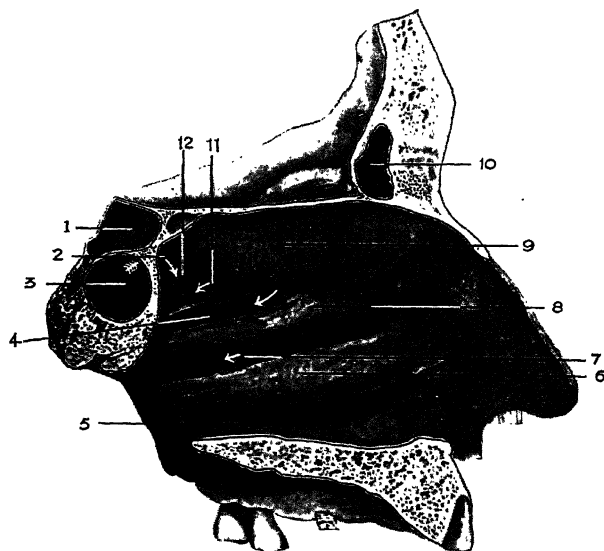


Fig. 3. Lateral wall of left nasal cavity, showing the conchae or turbinate bodies, the meatuses and spheno-ethmoidal recess. 1, Right sphenoidal sinus; 2, Sphenoidal ostium; 3, Left sphenoidal sinus; 4, Superior meatus; 5, Inferior meatus; 6, Inferior concha; 7, Accessory ostium of maxillary sinus; 8, Middle concha; 9, Superior concha; 10, Frontal sinus; 11, Ostium of posterior ethmoidal cells; 12, Spheno-ethmoidal recess.

is erectile tissue comprising irregular thin-walled blood spaces in the anterior and posterior ends of the inferior concha. A layer of elastic tissue fibres is present beneath the basement membrane, and this layer allows the mucosa to return to normal size when the vascular engorgement of the erectile tissue has worn off. The surface epithelium is columnar ciliated lying upon several layers of cuboidal cells resting upon the basement membrane. There are many mucous glands beneath the basement membrane, their ducts penetrating the membrane to open on the surface.

There are two nerve supplies to the nasal cavity, sensory and secretory. The main sensory nerve supply is derived from the maxillary division of the trigeminal nerve through branches arising in the pterygopalatine ganglion (*Fig. 8*). The lateral and medial internal nasal branches of the ophthalmic nerve supply the anterior part of the nasal cavity, while the floor and anterior

end of the inferior concha is served by the anterior dental branch of the infra-orbital nerve.

Secretory nerve fibres supplying the glands and unstriped muscle belong to the sympathetic and parasympathetic systems. Sympathetic fibres, which produce vasoconstriction and diminished secretion, arise from the superior cervical ganglion via the nerve of the pterygoid canal to the pterygopalatine ganglion. Parasympathetic fibres, which produce vasodilatation and increased

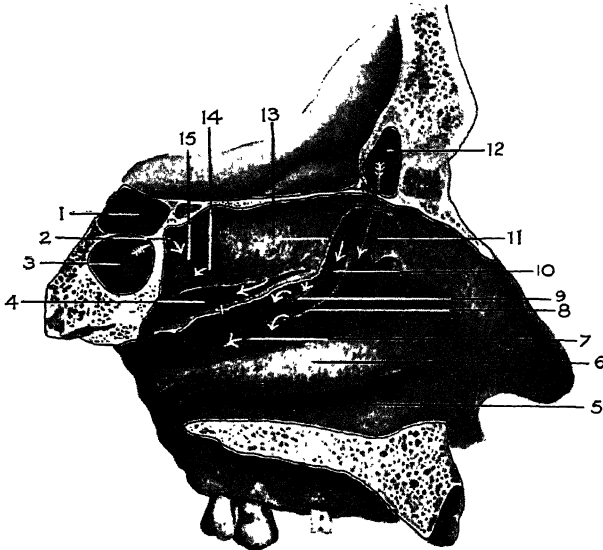


Fig. 4. Lateral wall of left nasal cavity with the middle concha removed; the lateral wall of the middle meatus is exposed, and the position of the ostia of the sinuses is indicated by arrows. 1, Right sphenoidal sinus; 2, Sphenoidal ostium; 3, Left sphenoidal sinus; 4, Superior meatus; 5, Inferior meatus; 6, Inferior concha; 7, Accessory ostium of maxillary sinus; 8, Uncinate process; 9, Ethmoidal bulla; 10, Infundibulum or semilunar groove; 11, Nasofrontal duct; 12, Left frontal sinus; 13, Superior concha; 14, Ostium of posterior ethmoidal cells; 15, Spheno-ethmoidal recess.

secretion, are carried in the greater superficial petrosal nerve and the nerve of the pterygoid canal to the pterygopalatine ganglion from which post-ganglionic fibres are distributed.

The olfactory nerves—some twenty filaments—derive from the olfactory bulb, enter the nasal cavity through the cribriform plate of the ethmoid, and are distributed in a network in the mucous membrane in the upper third of the nasal septum and the lateral wall of the nasal cavity. The perineural sheaths of these filaments communicate directly with the pia-arachnoid and thus may transmit infection to the meninges.

PHYSIOLOGY OF THE NOSE

The functions of the nose are respiratory and olfactory.

Respiratory. The nose is the normal method of respiration, and a baby born with an occlusion of both posterior nares makes strenuous efforts at nasal

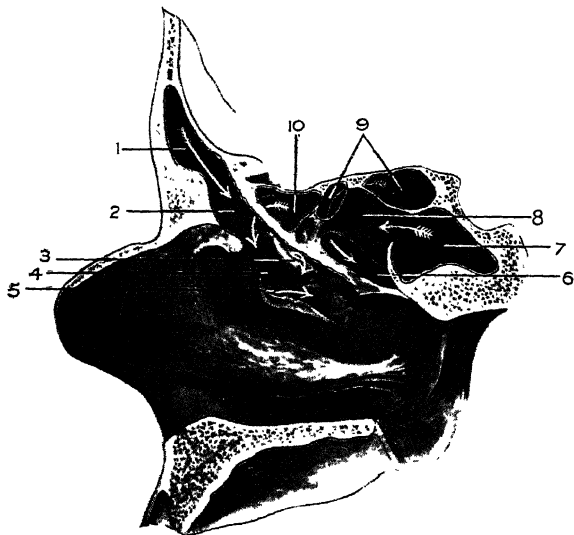


Fig. 5. Lateral wall of right nasal cavity with the superior and middle conchae removed; the infundibulum and nasofrontal duct are continuous; the unciniate process has been turned down in order to show the maxillary sinus ostium. 1, Right frontal sinus; 2, Nasofrontal duct; 3, Ethmoidal bulla; 4, Infundibulum or semilunar groove; 5, Maxillary ostium; 6, Superior meatus; 7, Right sphenoidal sinus; 8, Spheno-ethmoidal recess; 9, Posterior ethmoidal cells; 10, Anterior ethmoidal cell.

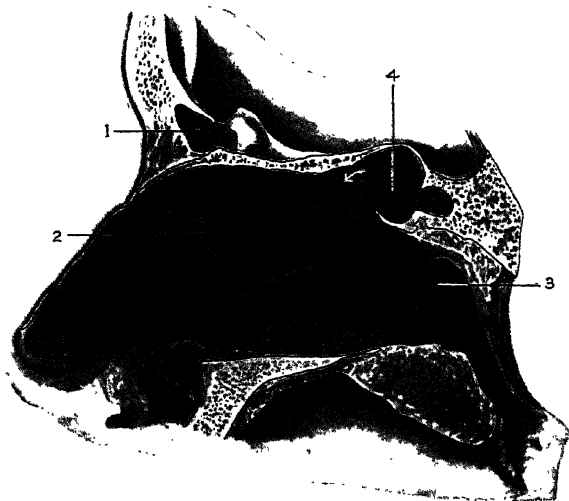


Fig. 6. Left side of the nasal septum, covered with mucous membrane, showing an oblique septal crest at the junction of the vomer with the cartilage of the septum. 1, Left frontal sinus; 2, Septum of the nose; 3, Nasopharyngeal cavity; 4, Left sphenoidal sinus.

respiration while keeping the mouth tightly shut. Inspiratory and expiratory air currents follow similar paths in the nasal cavity. Inspired air enters through the anterior naris, passes over the anterior end of the inferior concha

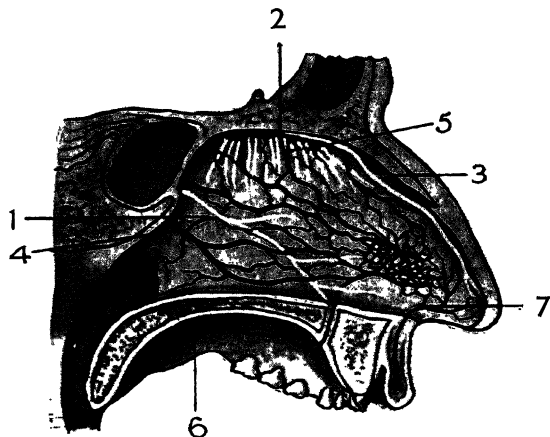


Fig. 7. Right side of the nasal septum showing the nervous and arterial supply, and the 'bleeding area' of the septum anteriorly and inferiorly. 1, Right long sphenopalatine nerve; 2, Olfactory nerve branches; 3, Medial nasal nerve; 4, Septal posterior nasal artery from sphenopalatine; 5, Anterior and posterior ethmoidal arteries; 6, Greater palatine artery; 7, Septal branch of superior labial artery.

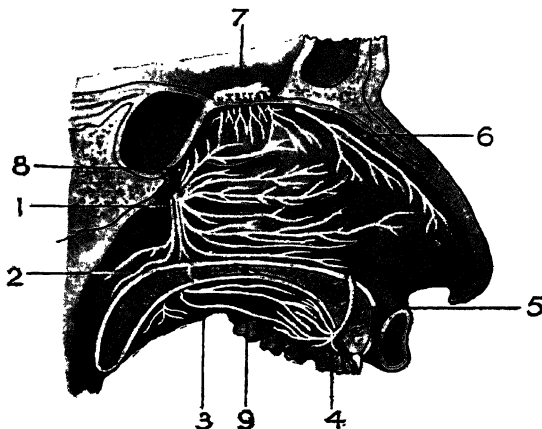


Fig. 8. Innervation of the lateral nasal wall. 1, Ganglion (pterygopalatine); 2, 3, Lesser palatine nerves; 4, 5, Long sphenopalatine nerve; 6, Lateral internal nasal nerve; 7, Olfactory bulb and nerves; 8, Short sphenopalatine nerves; 9, Greater palatine nerve.

to meet the anterior end of the middle concha. Here the stream splits, the main part passing along the middle meatus and the olfactory cleft beside the middle concha, and the lesser part passing above the middle concha to aerate the superior meatus and the sphenothmoidal recess. The air leaves the nose

over the posterior end of the inferior concha. Little or no air seems to travel through the inferior meatus. Expired air follows a similar pathway in reverse, but some of it forms eddies around the middle concha. There is a rhythmic alternation in the use of either nasal cavity, and both sides are seldom used equally at the same time.

During its inspiratory passage through the nasal cavity the air is filtered, warmed and moistened so that, whatever the state of the outside air, it is delivered through a normal nose to the lungs in a stable condition as regards warmth and humidity. If a tracheostomy has been performed, thus bypassing the nasal cavity, the air entering the bronchioles is too cold and too dry, unless the patient is nursed in an appropriate atmosphere, and the bronchi respond to this stimulus by producing an excessive secretion of mucus. Similar, if less dramatic, changes occur in children who adopt mouth breathing.

Filtration is accomplished by the vibrissae in the nasal vestibule which enmesh larger particles of fluff and dust, and by the nasal mucous blanket which covers the mucous membrane and is constantly propelled posteriorly by the cilia of the lining membrane. This mucous blanket is adhesive, and bacteria and particles of dust adhere to it. It is also, to some extent, bactericidal by virtue of its lysozyme content. Warming of the air is achieved by the vascular conchae with their submucous blood spaces, and the air is moistened by absorption of water content from the seromucinous gland secretions.

A nose depends for its health upon the mucous glands and the ciliated epithelium which keeps the mucus in constant movement. The cilia are robust enough to function even in infections, but their action is slowed by oily drops or sprays, and is destroyed by drying. For this reason centrally heated premises should have the air humidified, and for this reason also surgeons should respect the integrity of the surface epithelium during operative procedures.

Olfactory. The olfactory sense is less well developed in man than in some of the lower animals, but it is still sufficient to allow human beings to perceive odours in extreme dilution. The acuity varies greatly between individuals. The direction of the air current ensures that airborne odorous substances reach the olfactory area, and this is increased by forced inspiration or sniffing. Olfactory cells are stimulated by these substances, but they may also be stimulated by the blood stream. In order that an odour may be perceived a sufficient volume of the air containing the odour must reach the olfactory area, and the olfactory mechanism must be unimpaired. Thus, nasal congestion or obstruction, as, for example, during the common cold or in the presence of nasal polypi, diminishes olfactory acuity. Similarly, the effects of toxins, such as virus infections and certain poisons, may reduce the efficiency of the olfactory pathway, while a fracture through the cribriform plate of the ethmoid will destroy it. The acuity of smell may be estimated by the application of varying strengths of different substances, such as volatile oils, to the nostrils. The olfactory sense is allied to the sense of taste which is also affected if the former is impaired.

THE PARANASAL SINUSES

The paranasal sinuses, arranged in pairs and in relation to each nasal cavity, comprise two groups, anterior and posterior. The former includes the

maxillary sinus, the frontal sinus and the anterior ethmoidal cells, all of which communicate with the middle meatus. The posterior group consists of the posterior ethmoidal cells and the sphenoidal sinus communicating respectively with the superior meatus and the sphenoidal recess.

The *maxillary sinus* is also known as the maxillary antrum, or, simply, the antrum. It exists at birth as a small but definite cavity adjacent to the middle meatus, and it enlarges gradually to reach its maximum dimensions about the twenty-first year with the eruption of the upper wisdom tooth (*Figs. 9, 10*).

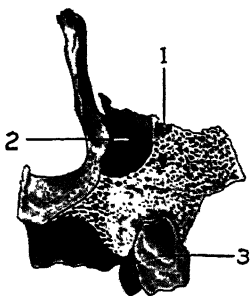


Fig. 9. Coronal section of the right maxilla during the period of the first dentition; the small maxillary sinus lies medially to the infra-orbital canal; the maxilla consists largely of cancellous bone. 1, Infra-orbital canal; 2, Right maxillary sinus; 3, Second molar tooth.

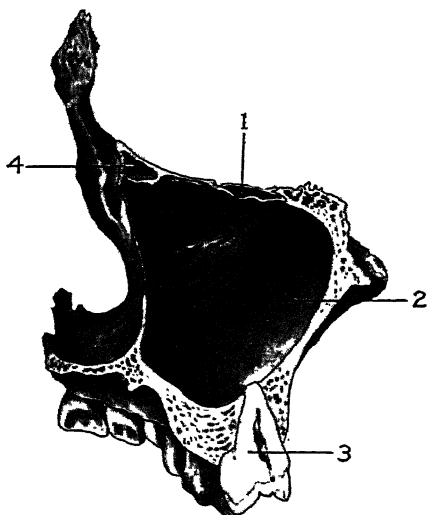


Fig. 10. Coronal section of the right maxilla of an adult showing the fully developed maxillary sinus. The floor of the sinus is on a lower plane than that of the nasal floor; the molar fang projects into the cavity of the sinus. 1, Infra-orbital canal; 2, Right maxillary sinus; 3, First molar tooth; 4, Maxillo-ethmoidal cell.

The sinus expands in the maxilla during the eruption of the primary dentition until it reaches the level of the floor of the nasal cavity about the seventh year. In adult life it is somewhat pyramidal in shape, its roof being formed by the floor of the orbit; its floor being in close proximity to the roots of the second dentition; its posterior wall lying in relation to the infratemporal and pterygopalatine fossae; its medial wall adjoining the lateral wall of the nasal cavity; and its anterolateral walls being superficial. The opening into the middle meatus, is near the upper part of the cavity of the sinus, and is thus unfavourably placed for drainage. There may be one or more accessory ostia posterior to the main one.

The *frontal sinus* is rudimentary at birth, being represented by a small upward prolongation from the anterior end of the middle meatus, the nasofrontal duct. During childhood this duct enlarges upwards to reach the level

of the orbital roof about the ninth year. Thereafter the sinus extends for a variable distance as a result of absorption of cancellous bone between the outer and inner tables of the frontal bone. The anterior wall is formed by the outer table; the posterior wall is related to the inner table which separates it from the frontal lobe of the brain; its floor forms part of the orbital roof; and the medial wall is a septum separating the two frontal sinuses. The opening of

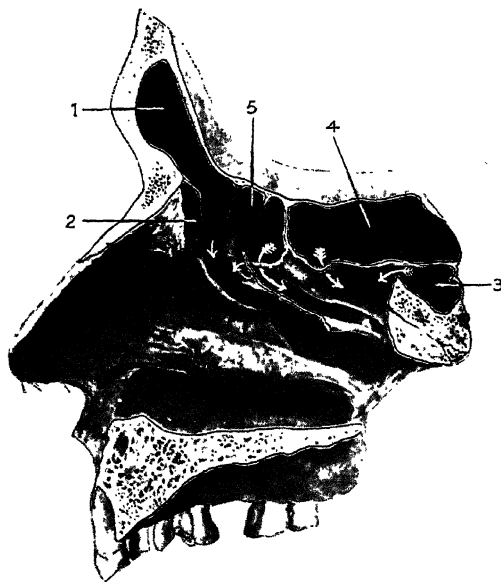


Fig. 11. Lateral wall of right nasal cavity. 1, Frontal sinus; 2, Cell of the agger nasi; 3, Sphenoidal sinus; 4, Large sphenoidal cell; 5, Anterior ethmoidal cell.

the frontal sinus is in its floor, and communicates with the middle meatus through the nasofrontal duct (*Fig. 11*).

The *ethmoid sinuses* constitute a cell labyrinth and are present at birth as prolongations of the nasal mucosa into the lateral mass of the ethmoid bone. In adult life they vary in number, size and shape, and for clinical purposes they are classified as anterior or posterior, depending upon whether they communicate with the middle or the superior meatus. The cell labyrinth lies between the upper half of the nasal cavity medially and the orbit from which the cells are separated laterally by the lamina papyracea. The cells abut anteriorly on the frontal process of the maxilla, and posteriorly they lie against the sphenoid bone. The anatomical details may be seen in *Figs. 11 and 12*.

The *sphenoid sinus* occupies the body of the sphenoid bone, and may be present at birth as a small indentation of nasal mucosa. The sinus varies greatly in size in the adult. The lateral wall is contiguous with the internal carotid artery and the cavernous blood sinus; the roof is related to the frontal

lobe, the olfactory tract, the optic chiasma and the pituitary gland lying in the hypophyseal fossa; the floor adjoins the pterygoid canal; while the medial wall is a septum separating it from its neighbour. The ostium is placed high up in the cavity of the sinus.

Physiology of the Sinuses. The sinuses are lined by mucous membrane continuous with that of the nasal cavity through the ostia, but the sinus

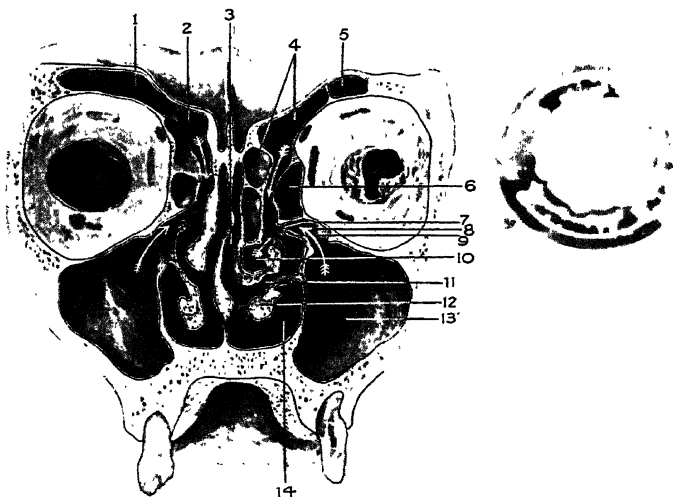


Fig. 12. Coronal section through the nasal cavities and maxillary sinuses on the plane of the ostia of the sinuses (viewed from behind). 1, Left frontal sinus; 2, Left anterior ethmoidal cell; 3, Olfactory sulcus; 4, Right anterior ethmoidal cells; 5, Right frontal sinus; 6, Ethmoidal bulla; 7, Hiatus semilunaris; 8, Infundibulum or semilunar groove; 9, Uncinate process; 10, Middle conchal cell; 11, Middle meatus; 12, Inferior concha; 13, Maxillary sinus; 14, Inferior meatus.

mucosa is thinner. The lining epithelium consists of a low stratified columnar type containing cilia which move the mucus secreted from the subepithelial glands towards the ostium.

The function of the sinuses is imperfectly understood although many theories have been proposed, none of which withstand critical scrutiny. It has been postulated that they assist in humidification of inspired air, that they aid vocal resonance, that they act as insulators to protect the base of the brain from cold air, and that they serve to lighten the bones of the skull.

CHAPTER 2

CLINICAL EXAMINATION

Good illumination is essential for the examination of the nasal cavities as well as for that of the pharynx, larynx and ear. The specialist has the benefit of a bull's eye lamp which concentrates the rays of a frosted light bulb. The light is reflected by a concave forehead mirror through the aperture in which the examiner conducts his investigation with one eye while the other gives binocular vision past the side of the mirror. During the examination the patient sits upright with the lamp close to the left side of his head. Direct sunlight should be excluded from the room. In other situations, the consulting room of the general practitioner or the patient's home, these desirable aids may be lacking. A forehead mirror may be used to reflect daylight or the light from a bedside lamp, but the fact that the rays reflected from the mirror are not concentrated means that the intensity of light is not sufficiently good to

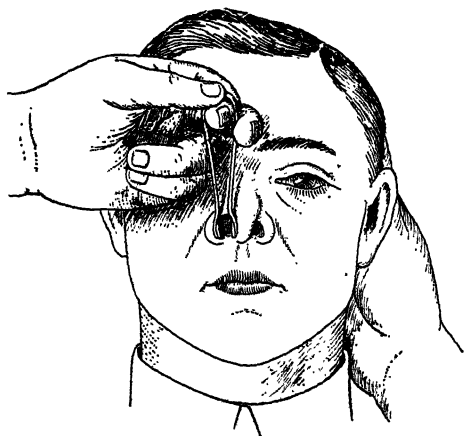


Fig. 13. Anterior rhinoscopy, with the aid of a nasal speculum.

give penetration or to give an accurate impression of mucosal colour. A small lamp attached to a band around the head and powered by dry batteries may be sufficient, or the electric auriscope may be used with the largest speculum.

Anterior rhinoscopy is achieved by focusing the light into the nasal cavity to be examined, and dilating the anterior naris by means of a nasal speculum. This is not easy to manipulate by the beginner, and the correct method of holding it is shown in Fig. 13. The blades are apposed and inserted into the nostril and are allowed to open slowly thus exposing the nasal cavity. The

anterior end of the inferior concha is immediately seen bulging from the lateral wall of the cavity. If the concha is large it may obscure the view of the rest of the nose. In this event the specialist may place a pledget of cotton-wool soaked in 10 per cent cocaine hydrochloride against the concha to reduce the oedema. This may succeed in an allergic swelling, but it may fail if the enlargement is due to hypertrophy. It must be remembered that some persons are sensitive to cocaine, and tend to become restless or excited, or with greater absorption of the drug to become pale and sweating with a rapid pulse and dilated pupils. In this event they should be advised to place their head between their knees, or to lie flat.

The nasal septum is easily seen, and should be examined for deviation from the midline, or dislocation, and the bleeding area should be inspected for dilated blood vessels in the anastomotic area. If the inferior concha is not enlarged the olfactory cleft and the middle concha will be seen, and occasionally details of the middle meatus may be inspected.

Examination of the nose, apart from noting septal deflections, should be directed to the colour of the mucous membrane, the width of airway in the olfactory cleft, the presence or absence of nasal polypi, and the occurrence and nature of any secretions.

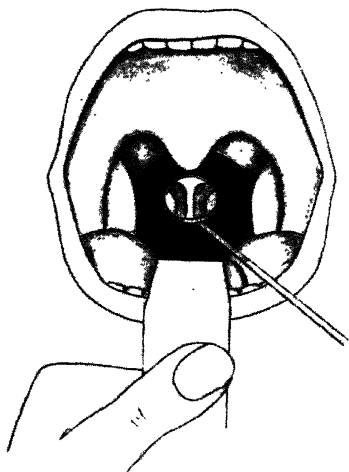


Fig. 14. Posterior rhinoscopy.

Posterior rhinoscopy is essentially a specialist examination because it demands a strong light source, and even in such hands it is not invariably successful because of hypersensitivity of the pharynx. It is performed by depressing the tongue with a spatula and passing a small mirror, angled on a handle, below the soft palate. The mirror should be heated in the flame of a spirit lamp so that it does not steam over from the moisture of the breath. The patient is encouraged to relax and to breathe through his nose. The light is directed into the mouth and on to the mirror from which it is reflected into

the nasopharynx, a mirror image of which is seen in the glass. When performed successfully (*Fig. 14*), a view is obtained of the posterior end of the nasal septum, which is seen as a pale vertical ridge. On either side the posterior nares, or choanae, are seen, and the posterior ends of the three conchae are visible. Laterally the tubal ridges surrounding the pharyngeal ends of the auditory tubes come into view. In the roof of the nasopharynx one may see adenoid tissue, or occasionally a dimpling within a small ridge denotes the pharyngeal recess (*fossa of Rosenmüller*).

Nasopharyngoscopy may be undertaken through an electrical nasopharyngoscope which is made on the principle of the cystoscope. It is usually necessary to anaesthetize the floor of the nose with cocaine before using this, and, as with all endoscopies, considerable practice and experience are necessary before the examiner becomes proficient.

In *children* examination of the nose is easily accomplished by tilting up the tip of the nose with the thumb and directing the light along the nasal cavities. Examination of the nasopharynx is not easy without frightening the child, and should be reserved for the older age group. If it is unsuccessful at the first attempt it should not be persisted with. The barbarous habit of digital palpation of the nasopharynx in the conscious child has fortunately been abandoned. Digital palpation may be performed with ease and accuracy under anaesthesia when the nature of any swellings may be determined and dealt with at the same time. Much information regarding the child's nasopharynx may be obtained from lateral radiography.

CHAPTER 3

SYMPTOMS OF NASAL DISEASE

NASAL OBSTRUCTION

This is a common symptom of nasal disease and may affect one or both sides. It may be complete or partial, continuous or intermittent, and it may vary from time to time and from side to side. Nasal airway may vary with atmospheric conditions. The air currents within the nasal cavities may be impeded by a deflected septum, enlargement of the anterior or posterior ends of the inferior concha or the anterior end of the middle concha, the presence of nasal polypi or intranasal tumours, atresia of the choanae, enlarged adenoids, or polypus or tumour of the nasopharynx. Intranasal surgery may cause mucosal oedema with nasal obstruction, and a similar condition may be produced by alterations of temperature or humidity of the inspired air. Nasal obstruction which is more marked on expiration is often due to a large posterior polypus on a stalk which swings as a ball-valve to block the airway.

The most serious effect of nasal obstruction is seen in a neonate with a bilateral choanal atresia, and the baby may die if this is not relieved. Partial nasal obstruction in infancy interferes with the act of sucking, the baby having to come off the breast or bottle repeatedly in order to breathe. Thus feeds are prolonged, the infant tires and takes insufficient food. In children nasal obstruction leads to mouth breathing being established, and, if unchecked, this leads to the constantly open mouth, high arched palate, crowded teeth and atrophy of the dilator muscles of the alae nasi, a picture which used to be described as 'adenoid facies'.

The presence or absence of a nasal airway is usually easily determined by holding a cold plated tongue depressor on the upper lip, and observing the presence and size of the steamed area due to condensation of expired air. If an airway appears to be confined to one side in a child the possibility of a unilateral choanal atresia must be suspected, and tested for by passing a probe through that side of the nose under general anaesthesia.

NASAL CATARRH

This is also a very common symptom of nasal disease. The seromucinous glands of the nasal mucosa constantly produce mucus which covers the mucosa like a blanket and is propelled by the cilia towards the posterior nares. From there it descends through the nasopharynx, pharynx and hypopharynx to reach the oesophagus which transmits it to the stomach where it is digested. In the normal course of events the subject is unaware of this unless the amount of the secretion varies or its viscosity alters. Typically, this occurs in the common cold when in the early stages the amount of mucus increases

and is blown out of the nose, while in the later stages it becomes more viscid and may be felt passing down the throat. Nasal catarrh may be complained of either because the patient has to blow his nose frequently or because he has a postnasal drip, or because he has both.

One must determine the duration of the symptoms, and, if of long-standing, one tries to discover the initial cause. The catarrh may be present all day, and every day, or it may be worse at certain times, or during certain seasons, or it may waken the patient at night if it collects in the throat. The nature of the catarrh may help the diagnosis. A thin, watery, mucoid discharge is present briefly at the onset of a coryza, while if it is of long duration it suggests a nasal allergy or a vasomotor rhinitis. A mucopurulent or purulent discharge, which is often produced on a paper handkerchief for inspection, denotes infection which may have its origin in the paranasal sinuses. Crusted material is blown out of the nose in atrophic rhinitis or rhinitis sicca, or may appear for some time following a virus infection, or following nasal surgery if the mucosal surface has been destroyed. Blood may be mixed with the catarrh in inflammatory conditions, or due to excessive nose blowing, but it may denote malignancy.

Examination of the nose should attempt to determine the origin of the catarrh, especially if it is mucopurulent or purulent, and posterior rhinoscopy is often important in locating infected catarrh in the choanae. A swab may be taken of the catarrh for bacteriological or cytological studies. Radiography of the paranasal sinuses should be performed in order to condemn or exclude the sinuses, and in children a lateral view is important to determine the presence and size of any adenoid pad which might be the cause of the catarrh.

HEADACHE

There is a popular belief that headache is commonly associated with chronic sinus infection, whereas sinus disease accounts for a very small proportion of headaches. In children headache is not a common complaint although many authorities claim that sinus infection is common in children. Investigation of the cause of headache may be long and painstaking, and often inconclusive. It may involve general medical, neurological, ophthalmic and psychiatric examinations, apart from a clinical study of the nose, sinuses, pharynx, teeth and ears. A careful history is important in ascertaining the position of the pain, and whether this is constant, whether it radiates from one point or whether the site of the headache varies. Descriptions of the type of pain may be difficult to classify as dull, boring, sharp, severe, agonizing etc. because patients vary in their threshold to pain. A history should be taken of the periodicity of the headache to discover whether it always appears about the same time or whether this varies. Radiography of the paranasal sinuses should always be done, even if only to exclude them as a cause.

Sinus headache will be discussed later, but in general an acute sinusitis gives rise to a pain in the region of the sinus involved while the headache of chronic sinusitis is usually frontal, although chronic sphenoiditis may give retro-orbital pain.

Fibrositis of the neck muscles may cause pain in the occipital region spreading forwards over the skull to the forehead or to the mastoid area. *Cervical arthritis* may produce a similar pain.

Migraine, which is frequently ushered in by an ocular prodromal symptom and is associated with nausea, causes a unilateral headache due to the vasomotor disturbance of the meningeal arteries. It is of variable duration and frequency, and is controlled by ergot.

'*Cluster headache*', or histamine headache, facial migraine, or sphenopalatine neuralgia, is of vascular origin, being due to episodic dilatation of facial vessels. It occurs in young males in whom it causes intense unilateral headache around one eye and sometimes extends towards the temporal region. These attacks come on during the night, and during the attack the ipsilateral side of the face is flushed. The pain often ceases with the outpouring of a watery rhinorrhoea from the same side of the nose. These attacks are controlled by ergotamine tartrate (Femergin), either by injection (0.5 mg) or orally given up to 5 mg daily; or by methysergide (Deseril) given 4-6 mg daily in divided doses. Clonidine (Dixarit) is said to diminish the response of the cranial vessels to constriction or dilatation, and may be given over a period in doses of 25 μ g twice daily.

Temporal arteritis, which is due to a granulomatous arteritis of the vertebral or cerebral arteries, leading ultimately to their occlusion, gives rise to pain in the scalp, face and jaws. The pain is constant and is aggravated by chewing. This is a self-limiting disease of the elderly which may end in blindness in half of the sufferers. It should be treated by prednisolone in doses of 40-60 mg daily.

Trigeminal neuralgia is the most severe of the neuralgic pains, and causes intense spasms of pain in any or all branches of the fifth nerve. Many of these patients have trigger points around the nostril or on the upper lip, palpation of which—as in the acts of shaving or washing—initiates the spasm. The aetiology is unknown. There may be remissions between the attacks. It is treated by carbamazepine (Tegretol) in doses of 100 mg once or twice daily, increasing the dose until relief is obtained. This drug is so specific in its action that the operations of alcohol injections into the ganglion or nerve, or root section of the nerve, are now less frequently indicated. Glossopharyngeal neuralgia is discussed on p. 114.

Anterior ethmoidal neuralgia is due to pressure on the anterior ethmoidal nerve in the region of the anterior end of the middle concha and the adjacent part of the nasal septum. It causes periodic pain from the eyebrow down the nasal bone. The pain is not intense, but may make the wearing of spectacles uncomfortable. Inspection of the nose will show a high deflection of the septum pressing on the middle concha, and the treatment is a submucous resection of the nasal septum and a fracturing of the middle concha medially.

Atypical facial neuralgia is a generic term to include many complaints of a deep dull ache in the maxillary region in one side or both, and which is not confined to any nerve distribution. It is more commonly found in somewhat haggard middle-aged women, and before labelling them neurotic one must exclude any cause in the sinuses or teeth. There is no specific treatment if these investigations are negative. Many of the patients have had their teeth removed, and even nerve sections performed, in an effort to get relief. Most will require a neurological investigation, and, if this is also negative, a psychiatric opinion.

Temporomandibular pain may arise from malfunction of the temporomandibular joint. The pain is often acute and may be facial or referred to the ear, and if aural examination is unrewarding the oral surgeon may detect an

abnormal opening of the jaw which does not show up on radiography of the temporomandibular joints. Manipulation of the mandible gives instant relief. A more chronic type of pain in the ear and face is *Costen's syndrome* which occurs in patients who have inadequate molar teeth to support the joint, or have ill-fitting dentures. In either case proper dental treatment will alleviate the pain.

Dental pain may arise from apicitis or apical abscess, or from the impaction of unerupted teeth, particularly the wisdom teeth.

DISTURBANCES OF OLFACTION

Anosmia, or loss of the sense of smell, may be a symptom of nasal disease. Any bilateral obstruction to the airborne odour which prevents it from reaching the olfactory area is the most common cause, but anosmia may arise from damage to the olfactory pathway. Acute rhinitis may temporarily annul the sense of smell. A more permanent anosmia will occur in the presence of atrophic rhinitis or of nasal polypi. Inhalation of pungent fumes, or the toxic effects of the virus of influenza may be the cause, while the excessive use of tobacco may diminish olfactory acuity. A fracture involving the cribriform plate or the skull base, cerebral haemorrhage or intracranial tumour may damage the olfactory pathway. A proportion of cases are of psychological origin. The olfactory sense is tested by volatile oils in various strengths, such as cloves, camphor and asafoetida. Pungent odours such as ammonia should not be used. Treatment is directed to the cause, and, if this is remediable, the result is favourable, but in many instances no improvement is obtained. Much of the distress is due to the associated disturbance with the sense of taste.

Parosmia is a perversion of the sense of smell, and consists usually in the perception of an unpleasant smell, when the term *cacosmia* is applied. Investigation for infection in the sinuses, tonsils or teeth may reveal the underlying cause, but in a number of cases no cause is found, and the condition is considered to be of neurotic origin.

Hyperosmia, or increased sensibility of the olfactory sense, is found in many normal individuals. It is never easy to determine normality of the sense of smell, and its investigation is not accurate in terms of measurement. The symptom is thus a subjective one, and may be complained of in neurotic patients.

DISTURBANCES OF THE VOICE

The effect of nasal obstruction upon the voice is familiarly met with in the common cold. Similar voice changes are found in chronic nasal obstruction due, for example, to nasal polypi or the mucosal oedema of nasal allergy. The changes affect certain consonants, *m* becoming *b*, *n* is changed to *d*, and *ng* to *g*. The speech is muffled and lacks tone due to the absence of nasal resonance.

SNEEZING

Sneezing is a protective mechanism in which a generalized reflex reaction is initiated by an abnormal stimulation of the nasal mucous membrane. The

reflex is an explosive one, and is accompanied by a twitching of the face and eyes, and by an increased secretion of nasal mucus and tears, while there is a transient engorgement of the nasal mucosa. Sneezing cannot be induced voluntarily, but it is brought about by the inhalation of an irritant, such as pepper, or an allergen in atopic individuals, or by looking at bright sunlight.

SNORING

Many individuals do not seek advice regarding snoring until pressed to do so by their wife or husband, while parents may complain of snoring in their children. The sound is made by vibrations of the soft palate while the patient is asleep, often on his back, and during inspiration through the mouth. It has been shown that a reservoir of air in the nasopharynx is essential for snoring, and thus it is not found in complete nasal obstruction, e.g. a bilateral choanal atresia. Snoring may occur in families, and this is usually due to a characteristic configuration of the face and jaw, or in those with a short thick neck. One of the facial characteristics is a receding chin, so that the tongue may slip backwards. In children snoring may be due to hypertrophied adenoids with or without hypertrophied tonsils, but it may also occur in the child with the high arched palate and an underslung lower jaw which leaves a gap between the upper and lower incisor teeth. Nasal allergic swelling of the mucous membrane of the nose or a deflected nasal septum may result in snoring in children or adults, while nasal polypi frequently cause it in adults. Collapse of one or both alae nasi may give rise to snoring in adults (*Fig. 15*).

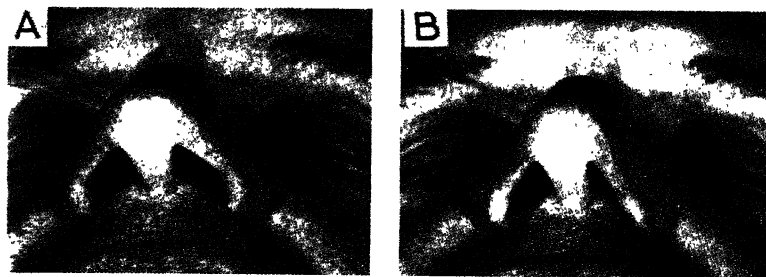


Fig. 15. Snoring due to collapsed alae nasi. (Reproduced by permission of Mr Ian Robin and the 'Proceedings of the Royal Society of Medicine'.)

Treatment is that of the cause. In children removal of hypertrophied tonsils and adenoids alone if the tonsils are of normal size, will usually result in a cure. Removal of any intranasal cause, such as nasal polypi, or correction of a deflected nasal septum, or treatment of nasal allergy should be recommended. Collapse of the alae nasi should be treated by the insertion of silver nasal dilators during the hours of sleep. Positive breathing exercises to correct the weak dilator muscles should be advised. The open mouth may be corrected by some form of chin strap, while correction of ill-fitting dentures may prevent the tongue from slipping posteriorly. A cotton reel or other such object fastened to the back of the pyjama jacket or nightdress will prevent the snorer from sleeping on his back.

A cure is only obtained in some 50 per cent of cases.

CHAPTER 4

GENERAL NOTES ON TREATMENT

In the following chapters reference will be made to standard forms of treatment, and general directions for these are given here.

NASAL LAVAGE OR DOUCHING

This is used to clear the nose of crusts or sticky secretions. It should never be employed during acute infections or if the patient has a cold. The temperature of the fluid should be about blood heat, and the solutions should be isotonic with blood plasma. The usual solutions are of common salt or sodium bicarbonate or a mixture of these using two teaspoonfuls in a pint (0.5 l) of water. The patient should sit with the head low over a basin to catch the return flow, and the solution should be gently injected into the nose by means of a Higginson's syringe or a rubber ball syringe. The practice of sniffing up fluid from cupped hands is not to be encouraged as this serves to drag the infected material posteriorly where it may infect the auditory tubes. One side is douched at a time, and if the patient breathes through the mouth the fluid can run through the nasal cavity and into the nasopharynx and down both nasal cavities without any entering the pharynx.

NASAL DROPS

Various medications are prescribed in the form of drops. The patient should lie on his back across a bed with his head hanging over the edge. As the drops are instilled he should sniff in as this disperses the fluid with the inspired air, and prevents it from running uselessly through the nasal cavity into the nasopharynx.

NASAL SPRAYS

Medications may be sprayed into the nose by means of a glass atomizer equipped with a rubber bulb and a nozzle which has a bulbous end to fit into the nostril. There are many proprietary preparations which are sold in plastic containers with a fine aperture. Pressure on the container releases a fine spray if the aperture is pointed vertically upwards, but ejects a jet if the aperture is pointing down. Spraying of the nose is performed with the patient upright so that the drug is dispersed through the nose.

STEAM INHALATIONS

These are generally used in inflammatory conditions, and great care must be taken if they are prescribed for children in case the hot water should spill and

GENERAL NOTES ON TREATMENT

scald the child. They should never be used by young children in whom the hot steam may precipitate a laryngeal oedema. The most common medicaments are menthol and tinct. benzoin. co. Menthol may be used as crystals, in which case not more than three crystals should be used in a pint (0.5 l) of water, or as 20 per cent solution of menthol in rectified spirit in which case only five drops are added to the pint (0.5 l) of water. Tinct. benzoin. co. (Friar's balsam) is used in the proportion of 5 ml to the pint (0.5 l) of water. The disadvantage of this is that it stains the jug in which the inhalation is made up. The water should have been boiled and allowed to stand for a few minutes before being used at a temperature of about 70 °C. The patient sits upright and covers the head with a towel which also covers the jug, and inhales for 5-10 minutes.

CHAPTER 5

THE EXTERNAL NOSE, NASAL ORIFICES AND NASAL SEPTUM

NASAL INJURIES

Direct injury to the nose is common. It frequently occurs in sport, such as boxing, football or rugby; in falls in toddlers, children or adults; and in accidents, either car accidents or in beating up by thugs.

In *children* fracture of the nasal bones is uncommon when one considers the frequency with which they injure their noses. Toddlers often fall while learning to walk with consequent injury, and children may suffer injury to the face in falls or by being struck by a swing. They may suffer extensive bruising with ecchymosis, and not infrequently there is a subperiosteal effusion of blood over the nasal bones, giving rise to a swelling on one side which takes some weeks to absorb fully. A direct blow to the nose may splay the nasal bones, and this may not be apparent radiographically. It may result in a permanent broadening of the nasal bridge, to the distress of the mother; and, if it is severe, it may require plastic correction when the child is older. The effects of this may be minimized by the application of narrow adhesive strips across the bridge at the time of the accident which serve to prevent further splaying when fibrosis occurs. In children, too, the cartilaginous nasal septum may become dislodged either out of its sulcus in the columella so that the dislocated anterior end projects into the anterior nares, or out of its attachment to the nasal crests of the maxillary and palatine bones so that it becomes deviated to one side or the other. If this dislocation is diagnosed early enough following the accident the cartilage may be repositioned under anaesthesia. Again, children more frequently develop a septal haematoma or abscess than a fracture of the nasal bones.

Fracture of the Nasal Bones. A direct blow to one side of the nose may produce a depressed fracture of that nasal bone under its fellow, while a direct blow on the front of the nose may fracture both nasal bones with depression of the tip (*Fig. 16*). The extent of the injury may not be immediately apparent because of the swelling, but radiography will demonstrate bony injury. The nose should be inspected with the head thrown back, when any asymmetry is apparent, and a comparison of the two anterior nares will reveal any septal dislocation. Gentle palpation of the nasal bones is carried out with the forefingers, the other fingers being steadied on the sides of the head. A sensation of elasticity or springing will be experienced on the side opposite the depressed fracture because the bone has been driven under its neighbour. Firm pressure on this side may reduce the fracture, the depressed bone snapping back into place if the fracture is recent. Usually a general anaesthetic is required because of the pain of such a manoeuvre. Pentothal

anaesthesia allows the surgeon to elevate the depressed bone, which may be impacted, and reposition it. Sometimes impaction is so great that the opposite bone should be elevated laterally to disimpact the fractured one which may then be manipulated into place. Splinting is not usually necessary, but some surgeons prefer to fix the bones in place with splints of gauze in collodion or of plaster of Paris. Fracture of the tips of the nasal bones may be elevated together under pentothal anaesthesia using forceps inside the nasal cavities



Fig. 16. Fracture of the nasal bones with depression of the tip.

until the shape of the nose has been restored. In severe fractures with splintering of the bones repositioning of the fragments is required and the nose should be splinted by a plaster-of-Paris headband.

Fractured nasal bones which have not been treated become fixed in about 2 weeks, after which it may be extremely difficult or impossible to refracture them and reposition the bones. Such cases may call for plastic surgical correction. Patients with such an uncorrected deformity may again injure the nose and report the recent accident but make no mention of any previous one. Radiography will show the previous fracture and it may only be at an attempted manipulation when repositioning is impossible that the true state of affairs emerges.

In motor car accidents, when the head strikes the dashboard, fracture of the nasal bones may be associated with fractures of the zygoma and maxilla, and in these cases extensive procedures are required to correct the deformities.

SEPTAL HAEMATOMA AND ABSCESS

Haematoma of the nasal septum may result from injury or may follow septal surgery. Extravasation of blood causes a smooth rounded swelling affecting both sides of the nasal septum and causing pain and bilateral nasal obstruction. The swelling is easily visible inside each nostril (*Plate I, 1*). Infection frequently supervenes to transform the condition into a septal abscess with increase of pain. Under general anaesthesia a wide-bore needle is inserted into the swelling and the contents are aspirated into a syringe. If no pus is found, aspiration may continue until no more blood is obtained, and the two nasal

THE NOSE AND PARANASAL SINUSES

cavities are packed for 24 hours to prevent reformation. Should pus be obtained on aspiration, and this is more usual, the swelling is incised, the contents evacuated and a drain is left in place until drainage ceases. Such patients should be given a course of antibiotics. This cures the condition but in a percentage of cases there is a permanent depression of the cartilaginous dorsum of the nose (*Fig. 17*) which, if severe, may require plastic correction to restore the shape of the nose.



Fig. 17. Depression of the dorsum of the nose following a septal abscess. (Reproduced by permission of Baillière Tindall from 'The Ear, Nose and Throat Diseases of Children'.)

DEPRESSED NASAL BRIDGE

This deformity may affect the osseous bridge of the nose or the cartilaginous part of the dorsum, and the deformity is sometimes called 'saddle nose'. It is usually due to injury, often repeated injuries as in boxers, to a septal abscess or to intranasal syphilis. The shape of the nose may be restored by a rhinoplasty in which an inlay is introduced after correction of the bony deformities.

CONGENITAL ATRESIA OF THE CHOANAE

This uncommon condition (*Fig. 18*) consists in the occlusion of the posterior naris by a bony or membranous diaphragm due to the failure of the nasobuccal or the buccopharyngeal membrane to absorb during fetal life. It is usually unilateral, but bilateral cases occur and these are observed at birth as the infant has the greatest difficulty in breathing, and the condition constitutes a neonatal emergency. Because nasal breathing is normal the neonate strives for breath while keeping the lips tightly closed. The accessory muscles of respiration are used, the alae nasi dilate, and eventually the lips are sucked inwards and part as cyanosis appears. A few gulping inspirations are taken

through the mouth, the lips close tightly again and the sequence continues. Emergency treatment consists in the insertion of a mouth airway which is fixed in place to ensure respiration until curative surgery can be undertaken. The symptoms of unilateral atresia are those of nasal obstruction including snoring but are slight in infancy or childhood, and are often not complained of until later in life. Examination of the nose will show thick gelatinous



Fig. 18. Congenital unilateral atresia of the choana; view on posterior rhinoscopy. On the left side the normal appearances are seen. (Note the fold, white in appearance, on the roof of the choana on that side.)

secretion in the affected side, and no airway can be demonstrated by holding a cold plated spatula below the nares—only the clear side steaming the plating. Posterior rhinoscopy may be undertaken in the older child and will show the occlusion. A probe or a soft rubber catheter cannot be passed through the affected side into the nasopharynx. If doubt still exists radio-opaque oil may be instilled into the suspected side of the nose, and lateral radiography will show that it is arrested at the choana (*Fig. 19*).




Fig. 19. Complete choanal atresia. Lipiodol has been injected into the nasal cavity, but none has passed beyond the posterior border of the hard palate.

Treatment of the infant with a bilateral atresia consists in perforation of the occlusion. If this be membranous in origin perforation is easy, and the membrane may be opened widely. If it be osseous, it must be opened by a proof puncture trocar and cannula, or by a special instrument devised for the purpose. The opening is widened by nibbling forceps, and when it is sufficiently wide a plastic tube is inserted through it. The other side is treated in the same way, and the plastic tube is brought back through this nasal cavity to the

anterior naris. The tube is withdrawn sufficiently to allow a cut to be made in one side, so that when it is drawn back again the cut lies in the nasopharynx, thus creating two nasal tubes joined over the posterior end of the nasal septum. The tubes are fixed across the columella, and are left in position for at least 2 months. Thereafter dilatation of the choanae by bougies is carried out at increasing intervals to ensure that the openings do not reclose.

Treatment of a unilateral atresia may be similarly dealt with if it is diagnosed in infancy. If it is not recognized until later in life the operative approach is through an incision at the junction of the hard and soft palates. The soft palate is retracted, and the occlusion is removed together with part of the posterior edge of the septum and the border of the hard palate. A plastic tube is again inserted and anchored to prevent it from slipping.

DERMATITIS AND FURUNCULOSIS OF THE NASAL VESTIBULE

This skin infection involving the hair-bearing area of the nasal vestibule calls for a careful investigation of the nasal cavity and sinuses. There is redness, excoriation and fissuring of the skin around the nostril, leading to crusting which may cause obstruction. A nasal swab should be taken to determine the infecting organisms, which are usually staphylococcal, and to discover their antibiotic sensitivity.

Treatment consists of the application of an ointment containing an antibiotic with or without hydrocortisone, e.g. a mixture of framycetin and gramicidin (Soframycin) or of oxytetracycline, nystatin and hydrocortisone (Terra-Cortril). The ointment should be applied twice daily, and should be continued for some days after the apparent cure, as the condition is prone to early recurrence. A course of the appropriate antibiotic by mouth may be given in addition.

If the infection is in a hair follicle a furuncle occurs. This gives rise to pain in addition to the irritation of the dermatitis. The furuncle is easily seen in the anterior naris and the temptation to squeeze it must be resisted because the infection may be spread by this means to involve the cavernous sinus by a spreading thrombosis. Hot fomentations, or the local application of 10 per cent ichthyol in glycerin on ribbon gauze will relieve the pain, while a full course of the appropriate antibiotic should cure the infection. The most useful antibiotics are ampicillin, erythromycin or flucloxacillin.

DEVIATIONS OF THE NASAL SEPTUM

A perfectly straight septum is rarely found, and, even when it is basically straight, it frequently shows a ridge or spur to one side or the other. Deviations and spurs of the septum may be very slight, causing no trouble, or very marked so as to block one cavity to a greater or lesser degree. In some deviations both sides may be obstructed. Individuals vary greatly in the degree in which they suffer from apparent blocking of the nose from septal deviation. In some in whom the obstruction appears slight there may be pronounced symptoms, while others make no complaint although one nostril is almost completely blocked. It is accordingly necessary to be guided largely by subjective symptoms in deciding the advisability of operative interference. Deviations may be developmental in origin or they may arise from trauma.

In traumatic cases there may be twisting of the dorsum or the tip of the external nose. In most deviations (*Fig. 20*) the septum presents a convex surface on the narrow side, while it is concave on the other. Not infrequently the inferior concha on the concave side is enlarged to compensate for the widening. The anterior edge of the septal cartilage is sometimes dislocated to project into one side of the nose, usually opposite that to which the rest of the septum is deflected. There are often ridges or crests on the septum, usually



Fig. 20. Simple angular deviation of nasal septum to the left.

low down, near the attachment of the septum to the maxillary spur, or at the junction of the cartilage with the vomer. On occasion the deviation is high up on the septum, so that it presses on the middle concha.

SYMPTOMS. Deviations of the septum may be symptomless, but may cause unilateral or bilateral nasal obstruction to a greater or lesser degree. A deflected septum may interfere with drainage from, or air entry into, the anterior group of sinuses. Sinus radiography should be performed in order to discover the extent of this. A deviated septum may occasionally cause pain, either neuralgia of the anterior ethmoidal nerve (p. 17) or the so-called 'vacuum headache' which results from obstructing the air entry into the frontal sinus.

TREATMENT. This is essentially operative if the obstruction is causing the patient discomfort, or if neuralgic pains are complained of. Surgery of the nasal septum may be called for as a preliminary to plastic reconstruction of the shape of the external nasal framework, or it may be performed as part of the rhinoplasty operation. The operation is called a submucous resection of the septum, and the principle is to remove the deviated or crested parts of the septum, while conserving, not only the perichondrium, periosteum and mucous membrane on either side, but also those parts of the cartilaginous or bony septum which are not deflected from the midline. The complete removal of all the cartilaginous and osseous septum is not frequently done now. The operation of septoplasty aims at conserving much of the septum, and by plastic means repositioning it into whichever sulcus it has been dislocated from during a previous injury. *Septal surgery in children* must be undertaken with caution, because of the growth of the nasal skeleton. A radical operation removing the greater part of the septum should not be performed in the child. The indications for surgery are stringent, and operation is only advised if the deviation is so severe as to cause headaches or gross interference with breathing while playing games. Minimal removal is performed in order to give the child a bilateral airway, and reposition of dislocated and deflected structures is attempted.

POSTOPERATIVE CARE. The patient need only lie up for 3 or 4 days. The packs which are inserted at the end of the operation are removed on the

following morning. Steam inhalations may be comforting, and the patient should be discouraged from nose blowing for a few days. Postoperative swelling of the nasal mucosa will occur, and will take some weeks to resolve fully, so that the patient must not expect immediate relief. He should be warned about further nasal injury until the tissues have soundly healed, and for this reason he should not indulge in boxing or football for some months after the operation.

COMPLICATIONS. These are not frequent. Septal haematoma has been mentioned, and is treated by reopening the incision to allow the blood to drain, and repacking the nasal cavities. Adhesions between the nasal septum and the inferior concha may occur if the mucosa has been lacerated, and if the inferior concha has been trimmed to ease the airway in that side. The adhesion takes place between the two raw surfaces. If seen early, it may be broken down, and a splint inserted, but if it is not found until some time after surgery, it may require a second slight operation to remove it completely. Perforation of the septum may occur if both mucosal surfaces have been opened, and the openings are opposite one another. It is usually permanent.

PERFORATION OF THE SEPTUM

The septum may become perforated as a result of septal surgery, from syphilis or tuberculosis, or following the application of chemical caustics such as chromic acid in the treatment of epistaxis. Perforation of the nasal septum may cause no symptoms, and many people are unaware of it. If it is associated with syphilis, it usually involves the bony septum and causes little discomfort. If the perforation is situated anteriorly, it may cause an annoying whistling noise during nasal respiration. If the perforation is large, crusting may appear around its edges, and such crusts are uncomfortable, and may be blown out by the patient.

Perforating ulcer of the septum is idiopathic in origin, and affects the cartilaginous part of the septum close to the anterior naris. Before the ulcer develops a small scab appears in this region, which is usually picked off by the patient, only to be followed by another. The process is repeated until a small sharply defined ulcer forms under the scab. This deepens gradually, and erodes and perforates the septum. The edges of the perforation heal leaving a small circular or oval perforation. The absence of inflammation distinguishes it from syphilis and lupus. If the patient is seen at the stage of shallow ulceration he must be enjoined not to pick the scab, and the ulcerated area is treated by the application of an ointment containing hydrocortisone and an antibiotic (Terra-Cortril or Soframycin) twice daily. The established perforation may be kept clean by similar treatment, but if there is much discomfort and crusting a grafting operation may be advised.

Septal haematoma

Adhesion

perforation of septum.

CHAPTER 6

EPISTAXIS, FOREIGN BODIES AND PARASITES

EPISTAXIS

Bleeding from the nose is common and may occur at any age and from many causes. It is frequently met with in children in whom the most common precipitating factors are picking the nose and acute rhinitis, usually of the epidemic influenzal type. Epistaxis in children nearly always arises from the 'bleeding area' of the nose which is situated on the nasal septum low down near the mucocutaneous junction (*Plate I, 2*). Following an epistaxis the blood clots and as the clot hardens it becomes irritable and is picked loose with further bleeding. During influenzal epidemics vascular engorgement may cause epistaxis and the chance of this is increased by nose blowing. After the infection settles there may be residual crusting in the nasal cavities and this may promote picking of the nose with further haemorrhage. Such an event may occur during light sleep, or may take place when the child is in bed and away from the reproving eye of the parents. Trauma is a common cause of epistaxis in children, and blood diseases such as haemophilia, leukaemia and purpura predispose to nose bleeding.

In the adult epistaxis may occur from the same causes as in children, and it is also met with in diseases of the heart, liver and kidney, or from intranasal crusting and tumours. It occurs most commonly in hypertension from whatever cause, and this is especially so in the elderly. It is very rarely vicarious, replacing menstruation.

Epistaxis may be slight in amount, there merely being a streaking of blood in the nasal catarrh, or it may occur in any quantity up to the point at which a great deal of blood is lost rapidly. In general, parents and patients tend to exaggerate any estimate of blood loss, but the haemorrhage may be so severe, so persistent or so frequently repeated as to require blood transfusion. Such severe cases should be treated in hospital.

Bleeding generally arises from the 'bleeding area' of the nasal septum, but in a proportion of cases the source is from the anterior ethmoidal vessels in the region of the middle concha. In the presence of actual bleeding the exact location may not be determined on inspection. If the haemorrhage has recently ceased the nasal cavity may be full of blood clot, and this may have to be douched out before one can discover the source. In patients who are first examined some time after bleeding has stopped the dilated vessel or raw area may be seen on anterior rhinoscopy. Apart from determining the site of the bleeding, a full blood investigation should be carried out in severe epistaxis. This not only gives the haemoglobin level but analysis of the blood may point to some haemorrhagic disease as the cause.

TREATMENT. Minor attacks of epistaxis may cease spontaneously and are helped to do so by seating the patient with his head over a basin and applying wool soaked in very cold water to the dorsum of the nose. Pressure over the affected bleeding area is applied by the thumb compressing the ala nasi on to the nasal septum for at least 5 minutes. Gripping the nose between finger and thumb means that the patient has to breathe through the mouth, and this is often frightening to the child or to the nervous patient. Unilateral pressure may be applied with the thumb on the ala nasi of the affected side and the middle finger behind the angle of the jaw on the opposite side. This allows the patient one side of the nose and the mouth for respiration. Such pressure is tiring after 5 minutes, both for the doctor and the patient.

In cases in which bleeding is not so easily controlled the nasal cavity must be packed with a length of ribbon gauze saturated with liquid paraffin. The gauze should be 25 mm wide for adults and 12 mm wide for children, and 1 m should be prepared for each side, if both require packing. The first 10 cm should be folded double and inserted along the floor of the nose, and the nasal cavity packed as tightly as possible and as far backwards and upwards as possible. This is a painful procedure and thus should be done in a good light and as rapidly as feasible. The use of liquid paraffin is recommended because it is easy to insert and, as it does not dry off by evaporation, it is easy to remove. It achieves its effect by pressure. Hydrogen peroxide (10 vol), which is haemostatic, produces much frothing on contact with blood on insertion, and it is uncomfortable to remove because the peroxide has evaporated leaving dry gauze which may adhere to the raw mucosal surface. Adrenaline hydrochloride is unsuitable because although it achieves a rapid vasoconstriction this is followed by a vasodilatation, and it has the same disadvantage as peroxide on removal. The packing should be left undisturbed for 24 hours provided that the haemorrhage has been controlled. During this time the patient should remain in bed and an appropriate dose of heroin for children or morphine for adults should be injected. The packing is often easier to insert if the sedation has been given previously.

Various thin rubber bags have been devised to overcome the discomfort of packing. The bag is inserted into the nasal cavity as far back as possible and then inflated to control the haemorrhage, in many instances quite effectively. It is easily removed after deflation.

Anterior packing is usually successful in controlling epistaxis from the 'bleeding area' although on occasions it may have to be repeated if further bleeding occurs after its removal. It may be less successful in some cases of haemorrhage from the anterior ethmoidal artery or if epistaxis is due to one of the blood diseases. In such an event a postnasal pack may have to be inserted. This is extremely painful to the conscious patient. A fine catheter is inserted through each nostril and brought out through the mouth. A rolled-up gauze swab round the middle of which a tape is securely tied is insinuated into the nasopharynx by attaching the free ends of the tapes to the catheters which are withdrawn. When the swab has been inserted into the nasopharynx by pulling on the tapes and using the forefinger to ease the swab under the soft palate the ends of the tapes are tied across the columella over a small piece of gauze. Both nasal cavities are then tightly packed as described. The anterior and posterior packs are removed in 24 hours.

In severe epistaxis blood should be taken for cross-matching and an intravenous drip of saline or packed cells started. Blood transfusion is given when matched blood is available and is continued until the haemoglobin reaches a satisfactory level. Several pints of blood may be required. Should the epistaxis not be sufficiently severe to require transfusion, a course of iron therapy should be ordered until the haemoglobin level is acceptable. Ferrous sulphate, ferrous gluconate or ferrous fumarate (Fersamal) are suitable preparations.

Recurring epistaxes should be treated by cauterization of the bleeding point. In children this is best done under a short general anaesthetic to prevent sudden movement of the head causing cauterization of the skin of the nostril. In adults cauterization may be performed after local anaesthesia of the bleeding point by the application of a pledget of cotton-wool soaked in 10 per cent cocaine hydrochloride or 2 per cent amethocaine solution for 20 minutes. In hospital the electric cautery is used with the cautery end at a red heat. If the end is heated to a bright red or a white heat the vessel may be cut through and not sealed. Chemical cauteries are useful in the patient's home, and they also require preliminary cocaineization. A fused bead of chromic acid may be made by picking up a crystal of chromic acid on the end of a metal probe and heating the metal in a spirit lamp close to the crystal which melts and fuses into a smooth bead. This is effective, covering the vessel with a black eschar which may burn deeply, and consequently a light touch is required. Another chemical cautery is trichloroacetic acid which may be applied, after cocaineization, on a small wool-tipped probe. Care must be taken not to touch the skin, which causes a smarting, but if this should happen with either chemical an immediate antidote is the application of sodium bicarbonate as a thick paste on the burnt area. The patient, especially if elderly, should rest for 24 hours after cauterization.

Cauterization is not recommended in young children unless there is a blood dyscrasia or unless epistaxis has been severe. Many children cause epistaxis by picking off crusts, and this explains why epistaxis is more often bilateral than unilateral in children. The application every night of a little petroleum jelly into each nostril will soften the crusts or scabs with cessation of the bleeding, and in most cases this should be given an extended trial before cautery is advocated.

Very rarely none of these methods will control the bleeding and this is especially so if the source is in the anterior ethmoidal artery. In such an event the artery may have to be exposed in the orbit and ligated.

FOREIGN BODIES

Children, especially young children aged 2 or 3 years, frequently push foreign bodies into the nose. Such objects may be classified as organic and inorganic. Inorganic foreign bodies include metal objects (*Fig. 21*), buttons, beads, plastic objects, etc. These may lie undetected for many weeks, giving rise to no symptoms and occasionally are found accidentally during routine examination. Organic foreign bodies, such as wood, paper, cotton-wool or foam rubber, produce a local inflammatory reaction which may proceed to the formation of granulation tissue. There is a nasal discharge from the affected side, and this quickly becomes purulent and foul-smelling, and may be

bloodstained. The object may swell with the absorption of moisture from the mucus, but pain is seldom complained of. A unilateral nasal discharge in childhood is nearly always due to a foreign body, and if the discharge has an unpleasant smell this is pathognomonic.

In the early stage the object is situated just within the nostril and is easily seen. In time it moves further into the nasal cavity—possibly due to the child's habit of sniffing or possibly because it is pushed further in—and it becomes

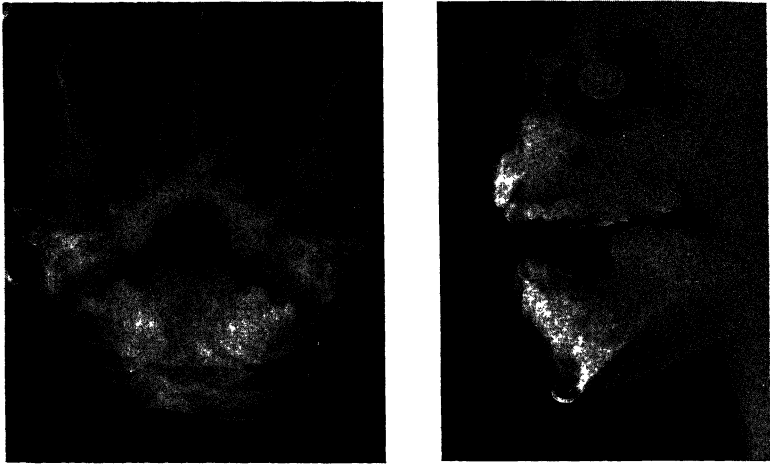


Fig. 21. Opaque foreign body (press stud) in left nasal cavity.

encased with mucus, or mucopus if the object is organic in origin. In this event it may not be seen because of the mucopus or the inflammatory swelling of the mucous membrane.

Removal of the foreign body may be easy if it lies in the nostril. It may be flicked out with a probe, or by getting the child to smell pepper and on closing the opposite nostril it may be sneezed out. When the object reaches the nasal cavity and becomes covered with secretions it becomes slippery and not easy to grasp. A child may sit through one attempt at removal but if this fails, and especially if the attempt produces bleeding, it is not likely to endure a second. Accordingly it is wiser to give the child an anaesthetic for the removal if one attempt has been made or if the object is situated far back at the initial inspection. The anaesthetic need only be a short one for removal is usually easily accomplished either with cupped forceps or with a metal probe, the distal 5 mm of which have been bent to a right angle. The probe is passed, point downwards, above the object which is pressed to the floor of the nose and then raked out. The probe may fail with such a narrow object as a shirt button because it slips, or with foam rubber which has become adherent to the mucosa. In these cases the cup-shaped forceps is preferable. Very occasionally the foreign body may be of such an irregular shape that it cannot be brought out through the anterior naris, and it may have to be pushed gently into the

nasopharynx and recovered from there. The surgeon must be alive to the possibility that there is a second foreign body present, either in the same side or in the opposite one, and after removal of the object the nose must be examined for this.

RHINOLITHS

Rhinoliths are calcareous masses which are occasionally found in the nose. They may be found in one side only or they may be bilateral. The deposit of salts, chiefly calcium and magnesium carbonates and phosphates, takes place around a nucleus which may be organic or inorganic, and the nucleus may be a foreign body or merely dried secretions of blood and mucus. Their presence must be considered in any long-standing cases of nasal discharge.

SYMPTOMS. These are nasal obstruction and discharge, but if the rhinoliths have been present for some time they may give rise to considerable destruction of the nasal mucosa with the formation of sequestra of cartilage or bone, and the development of an extremely unpleasant odour. Rhinoliths may attain a considerable size and are often irregular in shape. The diagnosis is usually easily made by inspection, but if there is any doubt palpation with a probe will disclose the rough hard object.

TREATMENT. The treatment is removal under general anaesthesia. The rhinolith may be too large to remove in a single piece and it may require to be broken with a strong pair of forceps before removal in fragments. There is a brisk haemorrhage during the removal, and this may require packing with ribbon gauze for 2-4 hours.

FUNGI AND PARASITES

Aspergillus infections of the nose are not common. The symptoms are sneezing, rhinorrhoea and headache, and the most important clinical sign is the discharge of pieces of tough greenish membrane which may coexist with polypi and granulation tissue. The fungus can be cultured from this tissue, and treatment consists in a thorough removal of the fungus.

Rhinosporidium seeberi causes a rare parasitic affection which has been observed among the natives of southern India, although its distribution is not limited to that area. The nasal polypi which are formed contain the spores in all stages of development. Clinically the masses present the appearance of slender filiform or narrow leaf-like processes of a dull pink or reddish tint, with the surface studded with many minute pale spots due to the presence of the sporangia in the tissue. The growths are friable and bleed readily when touched, so that they should be examined histologically to exclude malignancy. Treatment consists in surgical removal of the infected areas.

MAGGOTS (MYIASIS)

In hot climates flies may deposit their ova in the nose and maggots result. It is rare for this to occur in the healthy nose and is more common in patients suffering from ozaena or syphilis of the nose. Epistaxis, headache, lacrimation and sneezing develop, and the nasal discharge which is bloodstained at first soon becomes purulent. Myiasis may produce ulceration and destruction of

THE NOSE AND PARANASAL SINUSES

the nasal structures, and the condition may cause death from meningitis. The treatment consists of spraying or instilling oil or chloroform into the nasal cavities. This irritates the larvae which crawl out of the nose when they may be killed. They should not be killed inside the nasal cavity as the bodies will constitute a source of secondary septic infection.

CHAPTER 7

RHINITIS

In this chapter will be discussed a group of inflammatory conditions of the nasal mucous membrane comprising acute rhinitis, fibrinous rhinitis, chronic hypertrophic rhinitis, atrophic rhinitis and rhinitis sicca.

ACUTE RHINITIS

Acute rhinitis, or coryza, is a condition familiar to all as the common cold. It is especially prevalent in the spring and autumn, and is liable to occur after exposure to wet and cold, or to others suffering from the infection. Coryza is more apt to occur in those affected by fatigue or vitamin deficiency or in those with nasal obstruction or chronic sinus infection. It is met with in the course of the exanthemata, especially measles, and it occurs in epidemic form as influenza. Acute rhinitis is a virus disease, but it is thought that complications arise from invasion by secondary organisms, such as the streptococcus, *M. catarrhalis* and *H. influenzae*.

SYMPTOMS. The attack is ushered in by a fit of sneezing, and the nose becomes blocked, usually unilaterally at first. Loss of the sense of smell, headache and a feeling of chilliness accompany the obstruction, while there is a profuse nasal discharge at first watery and later becoming mucopurulent and finally purulent. The discharge subsides in a few days, but by this time the infection may have spread to the pharynx, larynx and bronchi. Hearing may be impaired from a temporary obstruction of the auditory tube. In infants the obstruction of a coryza may interfere with feeding and sleeping.

CLINICAL FEATURES. The nasal mucosa is red and swollen while the cavity contains mucoid or mucopurulent secretion. The nasopharynx and pharynx are similarly congested. The tympanic membranes may be flushed and retracted.

TREATMENT. There is no specific treatment, and the cold usually runs its normal course whatever therapy is adopted. In the early stages a hot bath at bedtime followed by 0.6 g of aspirin is helpful. Nasal obstruction may be relieved by a nasal spray of 1 per cent ephedrine hydrochloride in normal saline or by a steam inhalation. Should the ostia of the maxillary sinuses become blocked by oedema with consequent infra-orbital pain, relief may be obtained by an ephedrine spray followed in 5 minutes by a steam inhalation. Secondary effects are due to the invasion of other organisms, most of which are antibiotic-sensitive, a course of a wide-spectrum antibiotic may help to prevent the development of sinusitis or bronchitis. Vigorous nose blowing may lead to otitis media and should be discouraged.

The prevention of colds consists in avoiding infections and building up general resistance. During epidemics, public transport, schools, offices,

factories, etc. are fruitful sources of infection from droplets spread by coughing, sneezing and even speaking. Overheated and overcrowded rooms lead to the easy spread of infection, and fresh air should be allowed to circulate widely. Resistance may be increased by a regular intake of vitamins, especially vitamin C. Polyvalent vaccines against the common cold have proved successful in some patients if given in the late summer or early autumn, by reducing the frequency and severity of attacks, but this is by no means the general experience.

FIBRINOUS RHINITIS

This is characterized by the formation of a false membrane on the nasal mucosa, and is always associated with the presence of *C. diphtheriae*, but, in keeping with the reduced incidence of faucial diphtheria, the disease is now extremely rare in this country.

SYMPTOMS. The symptoms are those of nasal obstruction and discharge which may be clear or mucopurulent, and is often combined with epistaxis. There is little general upset. The condition is infectious, and may persist for weeks if untreated.

CLINICAL FEATURES. The mucous membrane of the inferior and middle conchae is covered with a greyish membrane which is rather difficult to remove, and leaves a bleeding surface on which the membrane re-forms. The membrane is indistinguishable from true diphtheria.

TREATMENT. The patient should be isolated until the nose is clinically and bacteriologically clear, and a full course of penicillin should be given.

CHRONIC HYPERTROPHIC RHINITIS

This may result from repeated acute attacks, but it is predisposed to by certain occupations involving dusty atmospheres or exposure to chemical irritants. It may occur with a deflected nasal septum or in patients with chronic sinus infection, and in those who are excessive in the use of alcohol or tobacco.

SYMPTOMS. The main symptom is nasal obstruction, especially at night. If the obstruction is marked there may be impaired sense of smell and taste. The nasal secretion may be either mucoid or viscid, and may be profuse in some patients.

CLINICAL FEATURES. The nasal mucosa is congested, and areas of hypertrophy are seen, particularly in the anterior or posterior ends of the inferior concha. There may be a hypertrophic fringe running along the entire length of the inferior concha. The middle concha is less affected. The application of cocaine hydrochloride (10 per cent) on a pledget of cotton-wool will serve to distinguish true hypertrophy from vascular or allergic swellings which will shrink markedly. Posterior rhinoscopy shows the hypertrophy of the posterior ends of the inferior conchae as mulberry-like swellings (*Plate I, 3*).

TREATMENT. This varies with the degree of discomfort and the amount of hypertrophy. An early case may respond to simple decongestant sprays containing ephedrine hydrochloride, 1 per cent in normal saline, but the established hypertrophy may require surgical trimming of the overgrown fringe or the mulberried posterior ends of the inferior concha. There is a danger in overzealous removal, which may produce a degree of atrophy.

This leaves the patient liable to crust formation, and he is often more miserable than before the operation. Diminution of the fringe by cryosurgery or by cautery is less destructive, while shrinkage of the concha by submucous diathermy will preserve the mucous lining. No after-treatment of surgery should be necessary.

ATROPHIC RHINITIS

Atrophic rhinitis is a chronic disease which may or may not be associated with foetor. If there is foetor, the condition is called *ozaena*. The aetiology of *ozaena* is uncertain. It has been ascribed to an unsuspected chronic infection, or to a severe nasal infection in patients suffering from vitamin or endocrine deficiency, or who have an inadequate diet. Many organisms may be cultured from the nose—*Coccobacillus foetidus*, *B. mucosus* and diphtheroids—but they are thought to be secondary invaders which may produce the foetor. The disease is familial in many instances, and appears to be more prevalent in equatorial races. It is much more common in women than in men, and usually starts about puberty, although it may be seen in children. Its occurrence at puberty has raised the possibility of some endocrine disturbance playing a part. Fortunately *ozaena* is becoming a relatively rare disease, because it is a most distressing one to the patient. The reason for this reduced frequency is not known. Atrophic rhinitis without foetor is very commonly due to over-exuberant surgery, with removal of large parts of the inferior conchae to leave large raw surfaces of the bone, and a consequent wide nasal cavity.

PATHOLOGY. The atrophic changes in the mucosa have been ascribed to a chronic inflammatory process producing endarteritis and periarteritis of the terminal arterioles, resulting in a diminished blood supply to the nasal mucosa. There is a progressive atrophy of the mucosa with conversion of the ciliated epithelium to cuboidal or stratified squamous epithelium. The bone of the inferior concha may share in the atrophic process. A thick viscid secretion is exuded, and this dries rapidly to form crusts which emit the characteristic foetor. Both sides of the nose are usually affected in *ozaena*, but the postoperative atrophy may be unilateral, depending on the surgery.

SYMPTOMS. The most characteristic symptom of *ozaena* is the foetor, which varies in intensity, and is sometimes worse during menstruation. It may be noticed at some distance from the patient, who, because of anosmia, is unaware of it. Nasal crusting causes obstruction, and dryness of the throat may be troublesome, and crusting may be seen in the pharynx. Headaches are frequent. Epistaxis may occur when the crusts separate, and crusts are blown out of the nose, although some are too large to be got rid of in this way. In atrophic rhinitis without foetor there are similar symptoms—anosmia, headache, epistaxis, nasal obstruction and crust formation.

CLINICAL FEATURES. The nasal cavities contain greenish crusts and, on posterior rhinoscopy, these may be seen in the nasopharynx. When the crusts are removed the nasal cavities are unduly wide, so that the posterior nares, auditory tubes and the posterior wall of the nasopharynx may be seen, while during speech the movement of the soft palate is visible from the anterior nares. The absence of ulceration distinguishes atrophic rhinitis from tertiary syphilis.

PROGNOSIS. There is no known cure for this condition, although spontaneous cure is on record.

TREATMENT. This consists in the main in cleanliness. In the first place the nostrils are plugged with tampons of cotton-wool inserted as tightly as possible, and allowed to remain for half an hour. Many crusts may come away when the wool is removed. The nose is then douched with a solution of normal saline, or sodium bicarbonate (1.3 per cent), or boric solution (1-60), using a pint (0.5 l) of fluid for each side. After the nose has thus been thoroughly cleared of crusts the nasal mucosa should be sprayed with a solution of 1 per cent stilboestrol in oil. This regime is used twice daily to begin with, and later reduced to once daily for the rest of the life of the patient.

Operations to reduce the width of the nasal cavities have been devised. Some sought to narrow the cavities by submucous implantations into the inferior concha or by the submucous injection of Teflon paste. A recent operation consists of raising folds of skin inside the nostrils and suturing them together to close the nasal cavities completely. It is said that such a complete closure over a period of years can lead to the regeneration of ciliated epithelium, and that when the nostrils are reopened after several years the ciliated epithelium does not revert to the squamous type.

RHINITIS SICCA

This is not generally recognized as a clinical entity, but the term is used to denote a condition which is met with in patients who work in hot, dry, dusty surroundings, such as rubber-workers, furnacemen, bakers, etc. It may also be found in those addicted to tobacco, and may be found postoperatively as a lesser stage of atrophic rhinitis.

SYMPTOMS. The patient complains of dryness in the nose, the expulsion of thin crusts, and occasional epistaxis.

CLINICAL FEATURES. The nasal mucosa is dark red and congested and there may be sticky secretion and small adherent crusts. The septum may be excoriated with picking, and may even be perforated.

TREATMENT. If crusting is marked, douching of the nose will remove the crusts and sticky secretion. If not, the daily application of petroleum jelly or an ointment containing an antibiotic and hydrocortisone (Terra-Cortril or Soframycin) should prevent the crust formation. Smoking should be reduced or discontinued.

CHAPTER 8

SPECIFIC NASAL INFECTIONS

SYPHILIS

Inherited Syphilis. This may appear in the form of coryza (snuffles) beginning in the first 3 months of life. It is characterized by an obstinate nasal discharge which tends to dry up and form crusts, while the irritation of the secretion causes fissures to appear at the anterior nares. At a later stage, usually at puberty but sometimes not until adult life, gummatous ulceration may destroy the tissues and lead to atrophy and scarring, so that the bridge of the nose is depressed and foetid crusts form within the nasal cavity. The permanent teeth and the cornea show the well-known defects (Fig. 22). In infants so

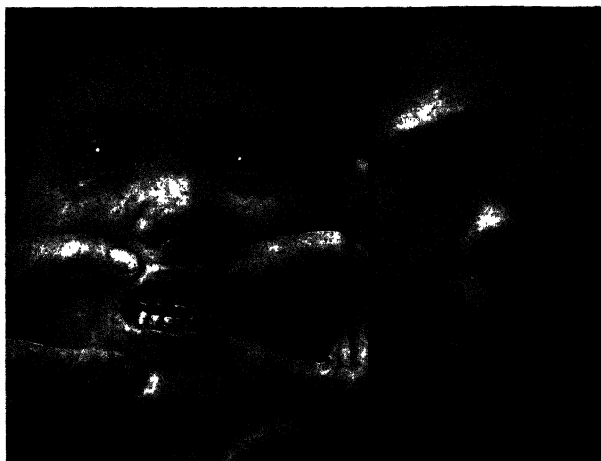


Fig. 22. Stigmata of congenital syphilis. Hutchinson's teeth. Sunken bridge. Corneal opacities.

affected other evidence of the disease should be looked for and the family history must also be investigated.

Acquired Syphilis. Primary infections of the nose are very rare. Secondary lesions in the form of mucous patches are met with less commonly than in the pharynx, and only slight symptoms are produced. In its tertiary form syphilis may occur in the nasal cavities. The septum is most commonly involved, but the lateral wall of the nose may also be affected. The stage of gummatous infiltration is rarely seen because, as a rule, ulceration and destruction of tissue have taken place before the patient is examined. The gumma takes the form of

an irregular mamillated infiltration, dark red in colour, involving one or both sides of the septum. Usually at this stage the only symptom is nasal obstruction, but there may be headache and severe pain in the nose, which may be swollen and tender. When ulceration occurs it is accompanied by a purulent discharge which tends to dry and form crusts which emit a horrible stench. After removal of the crusts by douching the nose may be more fully inspected. If the septum is affected it will be found to be perforated, and the perforation usually involves the bony structures as well as the cartilaginous portion. If the process is still active the edges of the perforation will be covered with granulations. The loss of tissue may be so extensive that there may be sinking of the bridge of the nose and even ulceration and destruction of the external nose. The structures of the lateral wall of the nasal cavity may also be extensively ulcerated and in part destroyed.

DIAGNOSIS. The diagnosis is not difficult as a rule, but syphilis must be distinguished from ozaena, tuberculosis and lupus. In ozaena the foetor is different and septal perforation does not occur. Tuberculous ulceration of the nose is almost always secondary to some other tuberculous lesion, and it is not accompanied by foetor. In lupus there is not the rapid loss of tissue found in syphilis, and there is usually nodular infiltration of a characteristic nature. In all doubtful cases the serological tests should be carried out.

TREATMENT. Penicillin is the treatment of choice. The nose should be kept clean by frequent douching with mild antiseptic solutions, and all loose sequestra should be removed.

TUBERCULOSIS

Tuberculosis very rarely affects the nose. It takes the form of a tumour which may produce ulceration and destruction of tissue (*Plate I, 4*). If it appears as a granular growth arising from the septum it may be mistaken for a sarcoma, but histological examination will show the granulation tissue and tuberculous giant cells. The septum is most commonly ulcerated, usually in its cartilaginous part, and perforation soon follows. Occasionally the lateral wall of the nasal cavity is affected.

SYMPTOMS. These are slight. Ulceration gives rise to nasal discharge, but pain is generally absent.

DIAGNOSIS. The diagnosis has to be made from syphilis and lupus. In tuberculosis the perforation affects the cartilaginous septum while syphilis involves the bony septum as well. There is evidence of tuberculosis or syphilis in other parts of the body. In cases of doubt serological tests and biopsy will provide the solution. Lupus is distinguished by nodular formation and skin lesions.

TREATMENT. As a rule, tuberculosis of the nose resolves on a full course of streptomycin, sodium aminosalicylate (PAS) and isoniazid.

LUPUS VULGARIS

In the nasal cavities lupus is more commonly met with than tuberculosis. Young persons, especially females, are attacked, and the disease is extremely chronic. It is often associated with some cutaneous lesion, and it is possible

that nasal lupus and lupus of the face have a common origin in the nasal vestibule at the mucocutaneous junction (*Plate II, 1*). The septum is the part generally affected where the characteristic nodular infiltration is found leading in some cases to ulceration and loss of tissue. External deformity may be met with, such as sinking in of the tip of the nose, while the alae nasi and the mobile part of the septal cartilage may be eroded and finally destroyed.

DIAGNOSIS. The diagnosis is not difficult as a rule. The slow progress of the disease distinguishes it from syphilis while the characteristic nodules, called apple-jelly nodules, and in many cases the coexisting skin lesion will differentiate it from tuberculosis.

TREATMENT. Isoniazid is the drug of choice in the treatment of lupus vulgaris, either alone or combined with streptomycin and PAS. In some cases a response may be obtained from vitamin D₂ (calciferol) given in the form of high potency ostelin in a dose of 100 000–150 000 units daily, depending on body weight. The danger of high doses are hypercalcaemia and renal damage, so that regular checks must be made, especially if there is evidence of dehydration.

SARCOIDOSIS

Sarcoidosis resembles lupus in the formation of nodules in the mucosa of the nasal vestibule, but the disease may affect the nasal bones which show characteristic cystic lesions on radiography. The aetiology of sarcoidosis is unknown. Diagnosis is made from histological examination of the nodules, and it is treated by steroid therapy supplemented by vitamin D.

MALIGNANT GRANULOMA

This is a progressive destructive ulceration of the nose and often the nasal cavities and sinuses. It is chronic inflammatory in nature but is potentially malignant and may become a lymphoma. There are two main types described. Stewart's type consists of an indurated swelling of the nose, nasal vestibule and septum leading to a progressive ulceration of cartilage and bone. Microscopy shows a dense accumulation of cells, mainly lymphocytes. The second type is Wegener's which takes the form of a necrotizing giant-cell granuloma beginning in the nose but showing confluent necrotic lesions in the lungs and a granulomatous involvement of the kidneys, resulting in renal failure which often proves fatal. Microscopically the presence of multinucleated giant cells in necrotizing granulation tissue, often grouped around blood vessels showing periarteritis and sometimes thrombosis, is diagnostic. The disease is more common in males, and has to be distinguished from syphilis, tuberculosis and malignant disease as well as from certain tropical diseases, such as yaws, gangosa, leprosy and oriental sore.

TREATMENT. Treatment of Stewart's type is by low-dosage irradiation, which often gives good results. Wegener's type, which causes much more constitutional upset, is now treated by azathioprine (Imuran) tablets, 50 mg twice daily and increasing to 200 mg in the day. This is combined with prednisolone in doses of 10 mg thrice daily. The outlook in Wegener's type, which formerly was very poor, is now improved.

SCLEROMA

FRISCH Bacillus
R. Leishman

Scleroma is found in certain parts of Eastern Europe, Indonesia and Central and Southern America, and is due to *Klebsiella rhinoscleromatis*. It consists of a hard rubbery nodular infiltration of the mucous membrane, reddish-brown in colour at first, but becoming pale pink later when fibrosis occurs. There is nasal obstruction, crusted discharge and a slowly progressive, but painless, stenosis of the nasal cavity. Prolonged antibiotic treatment by ampicillin, streptomycin or tetracycline may be helpful. Local excision of the lesions tends to destroy healthy tissue, and stenosis may be treated by dilatation of the nasal cavities and the insertion of polythene tubes which are retained for up to 2 months.

LEISHMANIASIS

This condition is rare in Britain, but is met with in Eastern Mediterranean countries and South America. It begins with an induration of the skin of the upper lip spreading to the cheek and the nasal vestibule. Later there is an ulcerated granulating area in the anterior part of the lateral wall and floor of the nasal cavity to give rise to considerable narrowing of the nose. Similar granulations may appear on the gums. Histological examination of a piece of excised tissue will show the Leishman-Donovan bodies. Treatment is by injections, either intramuscular or intravenous, of organic pentavalent antimony compounds, or, in resistant cases, of pentamidine.

LEPROSY

Leprosy is due to *M. leprae* which may invade the nasal mucosa and result in the destruction of the cartilaginous and bony frameworks of the nose with consequent collapse. Lepromatous granuloma and ulceration of the mucosa may be found. The condition is diagnosed from syphilis, tuberculosis and lupus by histological examination which shows macrophages containing the acid-fast bacilli. Treatment is by sulphone in increasing doses until a maintenance dose of 100 mg daily is attained, and this must be continued for many years.

CHAPTER 9

RHINORRHOEA

Rhinorrhoea means discharge from the nose, and in this chapter it is taken to imply a non-suppurative nasal discharge.

NASAL ALLERGY

Certain people produce an abnormal response to various foreign substances, especially proteins, which are called allergens. Whereas in non-sensitive subjects the reticulo-endothelial system reacts to foreign proteins by producing a specific antibody, susceptible individuals produce additional reaginic antibodies associated with the IgE immunoglobulins. In these allergic subjects there is often a high IgE level in the blood. The sensitization process is essentially due to the combination of the IgE reaginic antibody with cells such as tissue mast cells. On exposure to the foreign protein the allergen combines with the cell-bound reaginic antibody to release histamine and similar amines. This leads to vasodilatation and an increase in capillary permeability resulting in local oedema. There is a cellular infiltration of eosinophils, and the seromucinous glands of the nasal mucosa are stimulated to an increased activity with the outpouring of thin mucus.

AETIOLOGY. The condition of nasal allergy is hereditary in about half of the cases, and the chance of a child of two atopic parents developing nasal allergy is about 75 per cent. With one atopic parent the chance is about 50 per cent. It is frequent in children and young adults who are often of the highly strung emotional type. Nasal allergy is more common in certain geographical localities, occurring with greater frequency in low-lying areas rich in vegetation than in hilly districts. While some children with allergic manifestations appear to outgrow them at puberty, others may start their symptoms at that time. There tends to be an increase of symptoms in pregnant women or in women during their menstruation and at the menopause.

There are many allergens. Among the inhalants are pollens, house dust, animal emanations, moulds, feathers, wool, etc. while the aromatic oils from soaps and cosmetic preparations are frequent offenders. Foods such as fish, eggs, milk, wheat and citrus fruits; drugs such as aspirin, iodine, antibiotics and sulphonamides; and bacteria including streptococci, staphylococci and pneumococci may all produce allergic responses in certain individuals, and the list is by no means exhaustive.

SYMPTOMS. The complaints are of nasal stuffiness, profuse watery, mucoid, nasal discharge, and sneezing which in hay fever sufferers may prove exhausting. These symptoms may erupt suddenly on contact with the allergen, and such exacerbation is often preceded by an itching in the nose. This occurs in hay fever in which the patient is sensitive to the pollen of plants, trees or

grasses, usually the Timothy grass which pollinates in this country from May to July, being rather later in starting the further north one lives. In recent years daily pollen counts have been included in weather forecasts, the count being higher in hot still weather. The severity of hay fever thus varies from year to year, depending upon the weather. Those who are sensitive to proteins which are met with all the year round, like house dust, cosmetics, animal emanations, etc. have less violent perennial symptoms with acute exacerbations from time to time. Children have the habit of rubbing their itchy allergic nose with the palm of the hand, and may even cause a transverse fold or wrinkle to develop on it.

CLINICAL FEATURES. It is most important to take a detailed personal and family history, including particulars of the daily life and habits of the patient. One must not only diagnose the condition, but should attempt to pinpoint the allergen. Many patients have a knowledge of their condition and have tried to discover the cause for themselves, so that their history may be extremely helpful. In those patients whose symptoms are of relatively short duration it may be possible to establish certain altered circumstances of life about the time of the onset, getting married, becoming pregnant, moving house, acquiring a garden or changing gardens, changing occupation, altering habits with regard to cosmetic preparations, bed covers, etc.

Anterior rhinoscopy in the acute phase will show pallor and oedema of the mucous membrane of the inferior concha which may be so swollen as to lead the inexperienced to mistake it for a nasal polypus. There may be watery nasal secretion in excessive amount in the nose. The conjunctivae are congested. During remissions in hay fever subjects, who are often symptom-free from August to April, the nasal mucous membrane may appear healthy. The perennial sufferer will show oedematous mucous membrane in the nose, usually pale grey, but sometimes reddish with a blue tinge, and this mucosa shrinks rapidly on the application of a pledget of cotton-wool soaked in 10 per cent cocaine hydrochloride solution. These patients also have an increase of mucoid secretion in the nose. It is not uncommon to see a small oedematous raised mound on the floor of the nose at the level of the anterior end of the inferior concha in allergic subjects, whether they be children or adults, and this may be seen even during remission of symptoms. The nose may or may not contain one or more nasal polypi of varying size.

Radiography of the paranasal sinuses may be negative, but often shows some thickening of the mucosal lining, comparable to the nasal oedema, while occasionally, more often in children, there is a solitary polypoid opacity in the floor of the maxillary sinus.

An increase in the number of eosinophils may be found in the peripheral blood, and a swab of nasal secretions may reveal the presence of many eosinophils.

Skin testing is done to determine the group of allergens, or even the particular allergen, to which the patient is sensitive. There are two methods of testing: the intradermal injection, and the scratch or prick test. The former is the more sensitive test but it may give rise to severe reactions. In the prick test a positive reaction is an area of congestion and a weal appearing on the spot on the forearm about 10 minutes after the test. The forearm is used for testing a number of allergen groups at the same time. Those groups showing positive responses are noted and at a later test the constituent members of the group

are used individually in the same manner. A positive result proves that the skin is sensitive to the allergen employed, and the assumption that the nasal mucosa is similarly sensitive is not invariably correct. This may explain some of the disappointments from desensitization treatment.

TREATMENT. If the offending allergen can be eliminated from the patient's normal life, this is the obvious treatment of choice. It is most applicable to food allergies. Unfortunately most allergens cannot be avoided, and it is all too common that the patient is susceptible to more than one allergen or to more than one group of allergens.

The symptoms of perennial nasal stuffiness may be treated by simple vasoconstrictive drops or sprays, such as 1 per cent ephedrine hydrochloride in normal saline. There is a host of proprietary preparations made up as sprays and containing decongestants, antihistamines and often corticosteroids. These are often effective, but must be used with discretion as they tend to be habit-forming and lead to a condition of chronic mucosal congestion. Sodium cromoglycate (Rynacrom) may be insufflated in powder form from a special applicator giving a metered dose, and is a useful aid in the treatment of hay fever as it blocks the release of the amines that congest the mucosa. Beclomethasone dipropionate (Beconase) may be used in a metered dose in an aerosol spray in the treatment of nasal allergy, and it has the advantage of not being too vasoconstrictive, nor is it an antihistamine. It has the disadvantage of requiring regular use, and thus may become habit-forming.

Antihistamines, which, as the name implies, seek to minimize the effect of histamine liberation in the allergic subject, are generally more effective in preventing an allergic response than in curing one. They produce their effect within half an hour, and are widely prescribed in the treatment of the established case and meet with some success. There are very many such preparations on the market, differing in their chemical composition, and it may be a matter of trial and error with the chronic sufferer to discover the preparation most suitable to the individual. Most of them have the side-effect of producing drowsiness, so that the patient must be warned of the danger of driving a car or working with machinery while on a course of antihistamines, while the drowsiness produced may have an adverse effect on schoolchildren or students working for examinations. Some antihistamines are effective for 24 hours, e.g. promethazine (Phenergan) or triprolidine hydrochloride (Pro-actidil), and others are made up in the form of slow-release tablets or capsules, e.g. diphenylpyraline hydrochloride (Histryl), brompheniramine maleate (Dimotane) and chlorpheniramine maleate (Priton spandet). These should be taken at nights when the soporific effect will ensure a sound sleep while the therapeutic effect lasts during the day. Alcohol and certain depressants of the central nervous system tend to potentiate antihistamines, and patients must be warned of this. On the other hand, phenindamine tartrate (Thephorin) is a stimulant and should not be taken late at night.

Corticosteroid therapy is effective in the control of allergy but it should not be used on a long-term basis because of the side-effects. It is used in severe chronic asthma, and in such patients it controls any nasal allergy which is present. Steroid depot therapy is effective in the prevention of hay fever, and in some other cases of perennial allergy. An injection of 2 ml methylprednisolone acetate (Depo-Medrone) may last for 3 months or longer, and

this covers the hay fever season. Weekly injections of 0.5 mg of tetracosactrin zinc (Cortrosyn Depot or Synacthen Depot) are effective and do not depress pituitary-adrenal function.

Desensitization may be carried out if skin testing shows a limited spread of sensitivity. It is less successful in patients who react to several groups of allergens. Injections are given weekly in increasing doses for 6-8 weeks and thereafter a booster dose may be given annually. As with other vaccine therapy, anaphylactic shock may develop, so that adrenaline should be at hand to counteract this. There are standard vaccines on the market to control the more commonly found allergens, pollens and house dust. Hay fever subjects are given Alavac-P, Allpyral-G or Pollinex, while perennial allergy may be treated by Alavac-D, Allpyral mite-fortified house dust or Migen. Specific vaccines may be prepared from the results of skin testing and are prescribed as Alavac-S, Allpyral Specific or S.D.V., and are given for 18 weeks. Children are especially liable to anaphylactic reactions, and special precautions must be taken before a course of vaccine therapy is prescribed for them.

The size of the oedematous inferior concha may be reduced by shrinking the concha, under local or general anaesthesia, by drawing the electric cautery along its length to produce two or three linear scars. This has been criticized because of the destruction of the surface epithelium, and a satisfactory reduction in size may be obtained by submucous diathermy in which similar linear burns are made in the submucosa along the length of the concha.

Nasal surgery should be minimal in allergic subjects, but submucous resection of the nasal septum, removal of nasal polypi, or trimming of grossly hypertrophic fringes of the inferior conchae may be indicated on general grounds, as there is little point in controlling the allergy and leaving the nose obstructed from mechanical causes. Surgery of the sinuses should also be minimal. Some patients may produce an asthmatic attack following nasal or sinus surgery, and this may be averted by operating under a cover of corticosteroids.

Removal of tonsils and adenoids in children has no effect on nasal allergy. Parents tend to believe that this operation will cure any nasal obstruction and are greatly disappointed when it does not. If removal of tonsils and adenoids is indicated in a child who is found to have the pale oedematous nasal mucosa of allergy, the parents should be specifically warned not to expect relief from the underlying allergy, although removal of adenoids may play a considerable part in the mechanical relief of the airway. The treatment of nasal allergy in children is often made more difficult because there is frequently a coexisting low-grade infection of the nasal lining, and it is difficult to cure both the infective and allergic elements.

VASOMOTOR RHINORRHOEA

In order to understand vasomotor rhinorrhoea, or vasomotor rhinitis, or vasomotor imbalance, it is necessary to consider the various factors which affect the engorgement or otherwise of the submucosal vascular system in the conchae. The vasomotor nerve supply derives from the parasympathetic and sympathetic systems which join in the nerve of the pterygoid canal (Vidian's nerve) and run to the pterygopalatine ganglion. Here the parasympathetic

fibres relay while the sympathetic ones do not. The parasympathetic nerves cause vasodilatation and increased nasal secretion, and the sympathetic fibres have the opposite effect. Alterations in temperature and humidity of inspired air may rapidly produce vasodilatation when the temperature falls or vasoconstriction when it rises, and this is as true of the atmosphere as it is of central heating. There are certain drugs which have a similar effect. The sympathicomimetic drugs, such as adrenaline, ephedrine, neosynephrine, 2-aminoheptane sulphate, amphetamine and Propadrine produce a vasoconstriction rapidly or, at least, within 2 hours. They also produce a watery discharge in the nose and an irritative condition of the mucous membrane leading to a secondary vasodilatation, called the 'rebound' effect. Of the drugs named, adrenaline and ephedrine give rise to this most rapidly, which explains why adrenaline should not be used as a nasal pack for epistaxis. The parasympathicomimetic drugs, such as neostigmine and carbachol, produce nasal vasodilatation together with excessive secretion and sneezing.

Certain antihypertensive drugs may have the effect of upsetting the vasomotor balance. Methyldopa (Aldomet, Dopamet, Hydromet, Medomet) block the sympathetics, while guanethidine sulphate (Ismelin) blocks the postganglionic adrenergic neurons. Reserpine (Abicol, Adelphane, Serpasil) may cause vasomotor instability, as may the psychotropic drugs, e.g. phenothiazine.

The endocrine glands also have an effect on the nasal mucosa, hyperthyroidism raising the intranasal temperature to cause vasoconstriction while hypothyroidism may give rise to pale, boggy nasal mucous membrane. Hormonal factors, such as puberty, periods, sexual intercourse, pregnancy and the menopause, may upset the vasomotor balance, as may the contraceptive pill. Emotionally, fear results in vasoconstriction, while anger, resentment, frustration, humiliation and anxiety have the reverse effect.

The condition of vasomotor rhinorrhoea is thus commonly found in individuals of the type prone to anxiety, frustration or humiliation who may erupt in anger or nurse a resentment. It is common to both sexes, but particularly women, up to middle age. In men the underlying cause may lie in their work, while in women it may be due to stresses at home or at work.

SYMPTOMS. The complaints are of nasal stuffiness or of excessive nasal secretion or postnasal secretion, or both stuffiness and secretion. The affected side may vary from day to day, or from hour to hour, which adds to their frustration. The explanation lies in the physiological fact that there is an alternating vasodilatation and vasoconstriction in each side of the nose, and that these cycles become exaggerated. Nose blowing is frequent and ineffectual in improving the airway in spite of the constant use of paper handkerchiefs. Nasal symptoms worsen on changes of temperature or humidity, and bursts of sneezing first thing in the morning are commonplace. There may be other complaints, including facial neuralgias, headaches 'like a vice', and general malaise or fatigue.

CLINICAL FEATURES. Anterior rhinoscopy reveals large, turgid inferior conchae, the mucosa being rose-red or a more dusky shade. There may be hypertrophic fringes on the conchae and nasal polypi are occasionally found. Radiography of the sinuses is usually unrewarding. Allergy may be excluded by skin tests, and by the inability to demonstrate eosinophilia in the blood or nasal secretions.

TREATMENT. The condition should never be treated by vasoconstrictor drops or sprays which merely exaggerate the vasomotor imbalance. Ephedrine hydrochloride may be given orally in doses of 15–30 mg thrice daily for its sympatheticomimetic effect, but in the elderly it has the disadvantage of tending to suppress urine. Pseudoephedrine hydrochloride (Sudafed) may be used in doses of 60 mg thrice daily. Phenylpropanolamine hydrochloride combined with mepyramine and pheniramine (Triominic) or triprolidine hydrochloride with pseudoephedrine (Actifed) are useful decongestants when taken by mouth. Tricyclic antidepressives, e.g. imipramine (B.P.) in doses of 25 mg thrice daily, may be used.

Care must be taken to explain the condition to the patient, and to make him break the reliance on various intranasal medications to which he has become addicted. This in itself can do much to help, but in certain severe cases psychiatric assistance may be necessary to overcome deep personal worries.

The swollen conchae may be shrunk by cautery or submucous diathermy, while hypertrophic fringes may be reduced by a limited trimming of the conchae and nasal polypi should be removed. In severe cases when conservative therapy has failed destruction of the nerve of the pterygoid canal via a radical anastromy (Caldwell–Luc) or a transpalatal approach may give a dramatic cure, but the operation is a major one.

RHINITIS MEDICAMENTOSA

This term is used to describe the iatrogenic disorder resulting from the widespread overuse of nasal drops and sprays as mentioned above. The overuse of snuff may also promote this condition. The sympatheticomimetic drugs vary in the intensity and duration of their vasoconstriction, and consequently in the subsequent vasodilatation. This results in further nasal obstruction compelling the patient to resort to stronger vasoconstrictors so that the frequency of their use increases progressively. Vasomotor rhinitis is the condition which, pre-eminently, gives rise to this abuse, and is the condition in which, above all others, nasal drops and sprays containing sympatheticomimetic drugs should never be used. The only treatment for this is to explain the condition to the patient, and to persuade him to stop the use of these drugs. Treatment for vasomotor rhinorrhoea will help.

CEREBROSPINAL RHINORRHOEA

Cerebrospinal rhinorrhoea is not a common condition. As its name implies, it consists of a leakage of cerebrospinal fluid into the nose. The most common cause is a head injury resulting in a fracture of the anterior cranial fossa with a tear in the dura mater, but it may also arise from a congenital defect in this fossa, such as a leaking meningocele, or from erosion of the cribriform plate of the ethmoid bone by prolonged increased intracranial pressure from a tumour or hydrocephalus. There may be a cerebrospinal fluid leak following trans-sphenoid hypophysectomy.

The fluid is clear and watery, and is more commonly unilateral. The amount varies widely, and is increased by bending forwards or by straining, sneezing or coughing, and the flow may be intermittent or continuous. When the

patient is recumbent the fluid passes into the nasopharynx. Cerebrospinal fluid contains a reducing substance, but this is not diagnostic as lacrimal secretion also reduces Fehling's solution. Radiography and tomography of the skull may locate the underlying lesion. The source of the fluid may be tested for by placing two pledgets of cotton-wool into the anaesthetized nose, one in the sphenoidal region in the olfactory cleft and the other in the posterior part of the middle meatus. At lumbar puncture 1 ml of 5 per cent fluorescein is injected and the patient is laid flat with his head dependent. Examination under ultraviolet light will detect the dye. If the cerebrospinal fluid arises from the frontal sinus the dye is anterior to the meatal wool; if from the cribriform plate the wool in the olfactory cleft is stained; and if from the sphenoidal sinus the dye will be found in the nasopharynx on posterior rhinoscopy.

Spontaneous recession may occur, but the presence of a leak exposes the meninges to infection from the nose. Antibiotics may be used on a long-term basis to prevent this, and they are used should meningitis develop. Intranasal medication or surgery is contra-indicated in this condition. Surgical repair of the dural defect and the inlay of a strip of fascia lata to seal the cribriform plate, the inner table of the frontal sinus or the sphenoid sinus may be undertaken once the defect has been located.

CHAPTER 10

THE CATARRHAL CHILD

Nasal catarrh and a history of frequent colds in children are commonly encountered in general practice and in the outpatient clinics of both paediatricians and otolaryngologists. The history varies a great deal, depending upon the insight of the parents, and it may not be a simple matter to reduce a rambling story to clinical facts. It all too often happens that the parents form preconceived and perhaps inaccurate ideas and will stress some parts of the history and minimize or omit others. Yet an accurate history is essential, and is best obtained by the family doctor from his knowledge of the family, the house and the illnesses of the child and the siblings.

PREDISPOSING FACTORS. Certain factors may predispose to the problems met with in the catarrhal child.

Environment. This includes the occupation, financial status and intelligence of the parents; the size, hygiene, surroundings and structure of the house; the nourishment, overcrowding and cleanliness of the children; the previous illnesses of the parents and the children, etc. Chronic catarrh in the child is more often, but by no means exclusively, found in the poor, who live in overcrowded conditions, often in areas polluted by smoke, and whose diet is unsatisfactory from the point of view of balance and vitamin content. It may be argued that much is being done by slum clearance and the welfare state to improve the housing position, but the increase in population housed in modern high-rise flats may not in fact be an improvement, and overcrowding still exists. It may also be argued that with an improved standard of living poor nutrition should be less common than previously, but the increased cost of living may mean that a diet sufficiently rich in protein and vitamins is still impossible to achieve, and may be aggravated by the increasing problem of the working mother. The Smoke Abatement Act has reduced one type of pollution, but this has been replaced by a polluted atmosphere from exhaust fumes which affect the small child more than the parents. There are families who appear to regard nasal catarrh as normal, and who never train their children in nasal hygiene. It has been argued that to sniff back nasal secretion is as effective as to blow it out into a handkerchief, but an appreciable percentage of children appear to do neither effectively, and secretion is allowed to run down the upper lip or to lie in the nasal cavities.

Virus infections. These are brought into the home from buses, trains, factories, offices, schools, supermarkets, etc. by parents or older children, and such infections may be increased in virulence by passage through several hosts. The overcrowding and lack of fresh air in the home increase the chance of infection spreading, and this is especially true during epidemics of upper respiratory tract infections of virus origin. Indeed, at the other end of the social scale, the families living in an atmosphere of overhot central heating

are just as exposed to the spread of virus infection. Young children attend nursery schools in greater numbers and from an earlier age and are thus doubly exposed to infection. There are two main types of respiratory viruses. The first type enter the cells of the respiratory tract where they multiply to cause respiratory infections, and among these are the influenzal and para-influenzal viruses, the adenovirus, the respiratory syncytial virus and the rhinovirus. The second type enter the respiratory cells where they cause no local trouble but spread by the blood stream to give rise to the exanthemata such as measles, rubella, varicella, etc.

Allergy. Allergy is frequently hereditary in origin, and the child of two atopic parents stands a 75 per cent chance of producing symptoms of nasal allergy. In many cases this is a food allergy, where the allergen is often milk, or an infantile eczema which may lead to nasal catarrh, and often ultimately to hay fever or bronchospasm.

Antibiotics. The ready prescription of antibiotics for minor illnesses which normally would recover without such therapy prevents the development of the normal resistance of the child against such infections as the common cold or sore throat. In this respect they create the very conditions that they might be expected to prevent, the susceptibility of the child to upper respiratory tract infections.

CLINICAL FEATURES. The complaints include nasal catarrh, frequent upper respiratory tract infections which may proceed to lower respiratory tract infections, sore throats, sore ears, lack of appetite, pallor, insomnia often with spasms of non-productive coughing, and lack of normal growth and development. There are many problems to be resolved in this history. Is the undernourishment and poor appetite due to catarrh, or is the catarrh due to poor appetite? Does the catarrh lead to sinusitis and bronchitis and even bronchiectasis, or is the bronchitis the primary disease and the nasal catarrh secondary to it? Is the insomnia due to nasal catarrh or to poor home conditions with overcrowding in which the younger children get no peace to get to sleep? Is the pallor due to the catarrh or to the lack of fresh air in the house or the lack of playing facilities in high-rise flats? Is the allergy a true allergy or is it a vasomotor condition engendered by parental anxiety or tensions being communicated to the child?

From a more clinical aspect one must consider other factors which may uncommonly predispose to nasal catarrh. Hypothyroidism may occasionally play a part. Hypogammaglobulinaemia may rarely predispose to a susceptibility to upper respiratory tract infections, giving rise to a condition known as the antibody deficiency syndrome in which the child cannot produce a sufficient natural resistance to infection. Mucoviscidosis may underlie a frequency of upper and lower respiratory tract infections and should always be suspected in intractable cases.

The catarrhal child should be thoroughly investigated by the family doctor and the paediatrician to exclude these factors before treatment is undertaken, or before he is examined by the laryngologist. If referral is made in the first instance to an ear, nose and throat clinic the specialist should endeavour to establish in taking the history that there is no general medical problem requiring attention before recommending treatment, and especially before he recommends surgery. The best results are achieved by a collaboration between the two specialists.

The natural history of the catarrhal child who presents no factors such as recurrent tonsillitis, otitis media or bronchial trouble requiring a specific form of treatment is one of slow improvement. The symptoms are at their height when the child goes to school, either when the town child goes to nursery school or when the country child, reared perhaps in isolation on a farm, goes to primary school at which he first comes into close contact with numbers of other children. Absences are frequent in the first year at school and, again provided that infected tonsils or middle ears do not develop, the natural sequence of events is for the child to develop his own immunity, if he is allowed to do so, and he may well outgrow these infections by the time he reaches the age of 8 or 9 years.

There are many children who do not pursue this course which is relatively benign in spite of frequent absences from school. Such children develop recurring infections of lymphoid tissue of the pharynx and nasopharynx, when their illnesses become more serious. They have frequent attacks of follicular tonsillitis, or of acute or chronic otitis media. Some develop bronchitis at an early age and a proportion of these may degenerate into bronchiectasis. In this group treatment must be positive rather than expectant because such children may be sowing the seeds of ill-health later in life.

Lastly there is the allergic group who may progress from infantile eczema to allergic rhinitis perhaps with exacerbations of hay fever at the pollinating season and so to asthma. Many of these children appear to grow out of their allergy when the eczema finally heals, but an appreciable percentage persist with nasal catarrh and stuffiness, so that their allergens should be sought for and, where possible, avoided or treated.

TREATMENT. In the early stages this should be medical and hygienic in the widest sense. Training may have to begin with the parents by teaching them how to house, feed and look after their children. Early training in nasal hygiene and nose blowing prevents infected mucopus lying in the child's nose. No hard-and-fast rules can be laid down for the timing of this, but when a child goes to school he should be capable of blowing his own nose, and should be aware of when this is required. Yet it is not uncommon to give a child a swab and ask him to blow his nose in the outpatient department only to find that a 9-year-old has no idea of what this means. Mucopus lying in the child's nose obstructs air entry into and drainage from the nasal sinuses. Simple nose breathing exercises allow the nasal mucosa a chance to recover its normal function. Nasal mucus, containing the bactericidal lysozyme, and the ciliated epithelium are the best natural defences a child has against infection. If they are aided by good home conditions and a well-balanced diet with plenty of vitamins the child's natural resistance to disease will be greatly strengthened.

Antibiotics should be reserved for serious infections, and not prescribed for the common cold. Certain children, however, may require antibiotic therapy for any acute infection, and among these are sufferers from mucoviscidosis or children with congenital cardiac lesions. Some susceptible children may be given a long-term course of antibiotic therapy under the supervision of the paediatrician.

Children with nasal allergy may be treated with antihistamines and by nasal drops of 0.5 per cent ephedrine hydrochloride in normal saline, reserving corticosteroids either in nasal sprays or by mouth for the established cases of bronchospasm. Many children combine a basic atopy with a mild chronic

rhinitis, and they present the greatest problem in therapy. Silver protein combined with ephedrine hydrochloride as nasal drops or spray (Argotone) is most helpful in these cases.

Surgery is reserved for those children in whom clinical features warrant it. Many children improve following the removal of adenoids when the discharge from the nose is mucopurulent or when there have been attacks of otitis media. Tonsillectomy is justified in those children who have recurrent attacks of acute tonsillitis with clinical evidence of sepsis in the tonsils. Proof punctures of the maxillary sinuses may be required if radiography suggests infection, and in those cases in which pus is aspirated it should be cultured and the appropriate antibiotic given, either by mouth or by direct injection into the sinus through an indwelling polythene tube for 5-7 days.

SINUSITIS IN CHILDREN

The paranasal sinuses develop during childhood. At birth the maxillary, ethmoidal and sphenoidal sinuses are present and the frontal sinuses begin to grow shortly after birth as the nasofrontal ducts. The *maxillary* sinuses grow into the body of the maxilla, occupying the space left as the primary and secondary teeth move towards the alveolar margin. The floor of the antrum is level with the floor of the nasal cavity about the age of 7 years, and thereafter growth proceeds rapidly until the sinus attains its full size with the eruption of the wisdom teeth. The *ethmoidal* and *sphenoidal* sinuses enlarge to form recognizable sinuses between the ages of 4 and 6 years. The *frontal* sinus develops more slowly, and is not recognized as a sinus until its cupola appears above the level of the roof of the orbit radiographically, about the age of 8 years.

Acute sinusitis may occur in children as a direct extension of an acute rhinitis, but, as the openings of the sinuses into the nasal cavity are relatively larger in children, they rarely close to set up the conditions for acute sinusitis. Acute maxillary sinusitis is uncommon. Acute ethmoidal sinusitis may only show itself when the infection has spread through the lamina papyracea to cause an orbital cellulitis (*Fig. 23*). Acute frontal sinusitis may occur in the older child and produce symptoms identical to those in the adult, except that there is more often a visible swelling in the forehead over the affected sinus due to an osteomyelitis of the frontal bone (*see Fig. 37, p. 81*). Treatment is by antibiotics, giving a broad-spectrum antibiotic in full doses. Inhalations should not be prescribed for a young child, in whom it may produce laryngeal oedema, or for any child being treated at home because of the danger of the inhalation fluid being spilled down the child's front. Local decongestant drops or sprays of 0.5 per cent ephedrine hydrochloride in normal saline with silver protein (Argotone) may be used.

Chronic sinusitis in children is usually confined to the maxillary sinus. Chronic maxillary sinusitis may develop in children who suffer from repeated head colds and in whom drainage of the infected mucopus is hampered by enlarged adenoids, by a deflected septum, or by enlargement of the conchae from nasal allergy. The symptoms are persistent nasal catarrh of a mucopurulent character, frequent, protracted head colds and nasal stuffiness. The repeated upper respiratory tract infections may cause recurrent bronchitis, bronchiectasis or pneumonia, and children with mucoviscidosis are generally

considered to be prone to sinus infection. Examination of the nose shows mucopus either in the floor of the nasal cavity or in the middle meatus. The mucosa of the inferior concha may be congested and swollen. In children with an underlying allergy there is often a small swollen area in the floor of the nose opposite the anterior end of the inferior concha.

Radiography should be carried out in all children suspected of sinus infection, and a lateral view to show the nasopharynx should always be

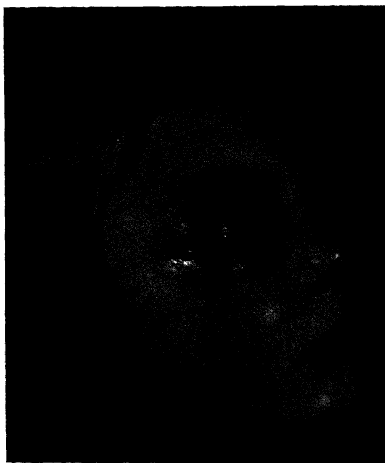


Fig. 23. Acute ethmoiditis with orbital cellulitis in a child aged 6.

requested. The films may be misleading. Many children are incapable of clearing their noses by blowing and the nasal secretions which remain in the nasal cavities combined with the swelling of the nasal mucous membrane result in a lack of air entry into the sinuses. This may give a false impression of sinus opacity on the radiograph, and it requires a paediatric radiologist to read the films accurately. The opacity from infection is much more dense, while a fluid level in a sinus is diagnostic of infection. Thickening of the mucous lining of the maxillary sinuses may be due to allergic oedema or to a chronic infection of the sinuses. A solitary polypoid swelling in the floor of the maxillary sinus may be due either to nasal allergy or to a cyst within the sinus.

Diagnostic proof puncture is performed on these children who show radiographic evidence of sinus disease. This should be an aspiration proof puncture, and not an antral wash-out because the latter will expel not only the antral contents but also those of the nasal cavities into the receiver, and this may give a false impression of sinus infection. If mucopus is obtained on aspiration of the maxillary sinus, it can only have come from the sinus, and should be sent for bacteriological culture and sensitivity tests. A Higginson's syringe may then be attached to the cannula and the sinus washed clear of infected contents. This is often curative, but if infection recurs a polythene tube may be threaded through the cannula and the sinus washed out through it, or the appropriate antibiotic instilled directly into the antrum.

THE CATARRHAL CHILD

Whether mucopus is obtained or not from the sinus the adenoids are removed if they are present, and some authorities believe that removal of adenoids alone without proof puncture will clear up any sinus infection by improving the nasal airway and thus aerating the sinus.

Nose drops of 0.5 per cent ephedrine hydrochloride with silver protein (Argotone) may be prescribed. They are best administered to a child by laying him flat on his back on a bed with his head hanging over the side. If he sniffs in as the two drops are instilled into each side the medication is thus dispersed throughout the nasal cavities.

It is uncommon for children to require further sinus surgery as described in Chapter 14. Some surgeons perform intranasal antrostomy on children for chronic sinusitis, and some even advocate such an operation routinely when the tonsils and adenoids are removed if there is radiographic opacity of the sinuses. There seems to be little to commend this, and there are few criteria for intranasal antrostomy in children. It should be borne in mind that childhood is a period of upper respiratory tract infections; that most children improve with simple conservative therapy including proper nose blowing and nose breathing; that radiography may show sinus opacity which is due simply to a lack of air entry into the sinuses; and that nasal allergic oedema is frequently combined with a mild chronic rhinitis to cause persistent catarrh.

By the same token it is even more uncommon for radical sinus surgery to be undertaken in childhood except in the case of complications of sinusitis which do not resolve with antibiotics, or in the case of malignant diseases when biopsy of the intrasinus tumour is necessary.

Conservatism should be the standard practice in the catarrhal child in whom the aims of treatment should be the establishment of free drainage, the training in proper nose blowing to evacuate the catarrh so drained into the nasal cavities, and nasal breathing to allow the nasal mucus and the cilia to fulfil their physiological functions.

CHAPTER 11

NASAL POLYPOSIS

NASAL POLYPUS

The polypus is a projection of oedematous mucous membrane composed of loose fibro-oedematous tissue, the surface of which is covered with ciliated epithelium. Small blood vessels traverse the surface and are sometimes visible to the naked eye. There is a variable degree of infiltration of round cells, and in allergic polypi large numbers of eosinophils are found.

Any condition of hyperaemia or inflammation within the nose or sinuses may give rise to polypus formation. Polypi may be found in cases of sinusitis, allergic conditions or malignancy. Nasal polypi are uncommon in childhood or adolescence but they are common in adult life. Those arising early in adult life are usually of allergic origin. Nasal polypi are more common in males than in females.

Nasal polypi occur most frequently in the ethmoidal region and they may be pedunculated or sessile arising almost always from the lateral wall of the nasal cavity. They may be attached to the middle concha, but usually arise from the ethmoidal labyrinth of cells and appear in the nasal cavity through the ostia as protrusions into the middle meatus. They enlarge partly by gravity and partly by nose blowing by virtue of an increase in their fluid content aided by a constriction of the blood vessels in the bony walls of the ostia which results in oedema. Nasal polypi may be single but are usually multiple, and they may be unilateral but are more often bilateral. They vary in size, and may grow as big as a large grape.

SYMPTOMS. The principal symptom is nasal obstruction. As polypi are slow growing there may be a considerable collection before the patient becomes aware of the obstruction. At times the patient suddenly becomes conscious of a blockage after a cold when congestion and nose blowing cause a rapid increase in size. Patients vary greatly in their tolerance of nasal obstruction, some complaining bitterly of the blockage of a single polypus while others endure large multiple polypi for months before seeking advice. Occasionally a pedunculated polypus in the posterior part of the nasal cavity may swing forwards on expiration to act as a ball-valve and cause blockage. The pressure of large oedematous masses of polypi may distend the nasal cavities to cause a visible broadening of the external nose (*Fig. 24*). On occasions, usually during a cold, a polypus may so enlarge as to appear at the anterior naris and be seen by the patient. There may be a complaint of frontal headache, and there is often a loss of the senses of smell and taste. Nasal catarrh is often present, either thin and watery in the case of allergic polypi or mucopurulent if there is an underlying chronic infection.

CLINICAL FEATURES. Anterior rhinoscopy will reveal the smooth, glossy, movable, bluish-grey swelling which is characteristic of the nasal polypus (*Plate II, 2*). When the polypus reaches the anterior naris the epithelium undergoes a change to the squamous type from exposure and trauma, and the surface is less glistening, and the polypus appears white or pinkish in colour (*Plate II, 3*). If a pedunculated polypus twists on its stalk it may become congested. The polypus may be mistaken for the enlarged end of the inferior



Fig. 24. Nasal enlargement; the result of neglected polypi.

concha to the inexperienced eye but it is more common for the enlarged concha to be taken for a polypus. It may be difficult to distinguish an enlarged or cystic middle concha from a polypus unless it is probed. The polypus is soft, mobile and insensitive, and may thus be moved inside the nose without causing discomfort.

Posterior rhinoscopy should always be attempted. It may be that the posterior ethmoidal cells are responsible for polypus formation and the growths will be seen in the choana or in the nasopharynx.

The nature of any nasal discharge should be noted. A thin mucoid discharge will suggest allergy while the presence of mucopus will denote an infective origin. Nasal polypi will shrink if a pledget of cotton-wool soaked in 10 per cent cocaine hydrochloride is placed against them, and this shrinkage is especially noticeable with allergic polypi.

Radiography of the nasal sinuses should be done because the films may show the underlying sinus pathology, and because any infection within the maxillary sinuses may conveniently be treated at the same time as the polypi are removed.

TREATMENT. Nasal polypi may decrease in size to some extent with the use of a decongestant nasal spray of 1 per cent ephedrine hydrochloride in normal saline. They may also decrease after a course of corticotrophin (ACTH) injections, giving 40-120 units daily by intramuscular injection in suitable

patients. Polypi, however, rarely disappear without surgical removal. Each case must be judged on its merits. There is no justification for removing small nasal polypi which are discovered incidentally or which give rise to no symptoms. In such cases conservative treatment is ordered and the patient examined at intervals because growth is generally slow. Nasal polypi which are causing nasal obstruction should be removed together with the small area of bone at their point of emergence.

The surgical removal of a single pedunculated polypus may be accomplished under local anaesthesia with a suitable snare which is closed as close as possible to the point at which the polypus emerges from the ethmoidal cells. The removal of multiple polypi is usually performed under general endotracheal anaesthesia, the endotracheal tube being packed off to prevent the entry of blood into the trachea and bronchi. The nose is usually packed or otherwise anaesthetized preoperatively with cocaine hydrochloride and adrenaline hydrochloride to reduce bleeding which is often brisk. In many instances this preoperative treatment shrinks the nasal polypi, especially the allergic polypi, so that small growths may disappear from sight, only to reappear when the vasoconstriction has worn off. Multiple polypi are removed with the snare and with forceps, and the affected ethmoidal cells are opened up in the hope of minimizing the chance of recurrence. If haemorrhage is brisk a pack of ribbon gauze is left in the nasal cavity and removed when the patient is conscious and can be propped up. After-treatment consists of steam inhalations. Vigorous nose blowing should be forbidden as this may restart the bleeding. The patient is kept in hospital for 48 hours and will be off work for a week.

Recurrences of nasal polypi are common, especially in allergic patients who may be subjected to repeated removals. This is partly due to the preoperative shrinkage and partly to the continuing allergic state. In order to diminish the frequency of recurrence it is possible in some patients to operate under hypotension without any preoperative cocainization, and in this way small polypi may be removed under vision.

Some surgeons advocate a short course of corticosteroids following removal of allergic polypi. A suitable routine is to prescribe betamethasone (Betnesol) tablets, giving 0.5 mg thrice daily for 3 days; 0.25 mg thrice daily for 3 days; 0.25 mg twice daily for 3 days and 0.25 mg daily for 3 days. This is followed immediately by a course of one of the antihistamines. Other surgeons prefer to give an injection of 80 mg of methylprednisolone (Depo-Medrone) continuing this at intervals of 3 months or longer, depending upon the response.

Radical external ethmoidal surgery may be required for frequent recurrences of nasal polypi when simple methods have failed, and the results are encouraging.

NASO-ANTRAL (CHOANAL) POLYPUS

The naso-antral polypus arises from the mucous membrane of the maxillary sinus. The morbid condition of the antrum is probably catarrhal, and as the swelling increases a small polypus develops in the region of the accessory ostium of the sinus. The polypus protrudes into the nasal cavity through the accessory ostium, which is situated posterior to the normal orifice. It increases

in size because of the oedema within it, and it passes posteriorly towards the choana and enters the nasopharynx. Here it enlarges to fill the nasopharynx, and as greater growth occurs the polypus then grows forward through the nasal cavity of the original side, and thus becomes bilobed (*Fig. 25*). It resembles the ordinary nasal polypus in structure.

SYMPTOMS. A naso-antral polypus is more commonly found in childhood or adolescence than in adult life. There is a complaint of unilateral nasal

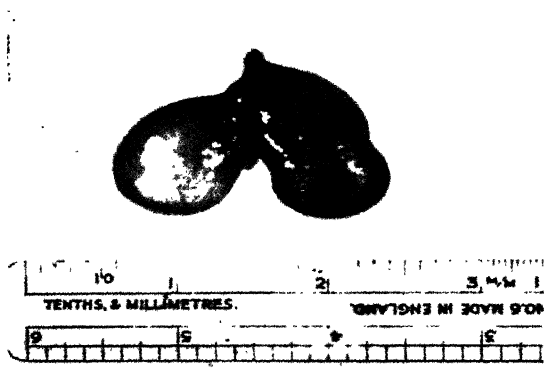


Fig. 25. Naso-antral polypus showing stalk of attachment and bilobed appearance. (Reproduced by permission of Baillière Tindall from 'The Ear Nose and Throat Diseases of Children'.)

obstruction which becomes bilateral as the polypus fills the nasopharynx. A mucoid discharge is noted, again unilaterally at first and later bilaterally. The voice becomes affected and hyponasality develops. Snoring may be complained of initially. There is no pain, nor is there earache, but deafness may be present because of the occlusion of the auditory tubes.

CLINICAL FEATURES. Anterior rhinoscopy in the early stages may reveal no abnormality, although there may be accumulated mucus on the floor of the nasal cavity of the obstructed side. It may occasionally be possible to see the polypus far back in the nasal cavity. When the polypus becomes bilobed it will be seen with increasing ease. Posterior rhinoscopy is not always easy to perform in the young, but when it is successful a smooth, greyish-white, spherical mass will be seen in the choana early on, and later filling the nasopharynx (*Plate II, 4*). Once the nasopharynx is filled the polypus may project below the soft palate, or may be seen when the palate rises on phonation. It presents as a greyish convex mass on examining the pharynx. Radiography will show a lack of air entry into the affected maxillary sinus, while a lateral projection will demonstrate the polypoid swelling in the nasopharynx.

TREATMENT. This is essentially surgical. A small polypus may be snared off in the same way as a nasal polypus if the snare wire can be passed round the polypus in the choana. When the choanal polypus is fully developed it is easier to avulse it under endotracheal anaesthesia. The main mass in the nasopharynx is grasped with forceps and steady traction will avulse the growth from the accessory ostium, and the polypus is removed completely.

THE NOSE AND PARANASAL SINUSES

Recurrence occasionally takes place and may be treated in the same way. Should removal be incomplete and a second recurrence take place the antrum should be opened by a Caldwell-Luc approach, the mucosal origin of the polypus should be removed, and the freed polypus lifted out from the nasopharynx.

CHAPTER 12

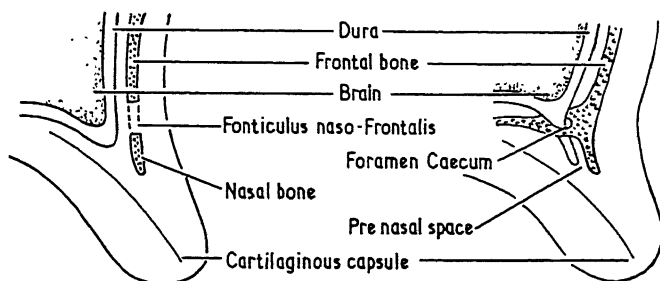
TUMOURS OF THE NOSE

CONGENITAL TUMOURS

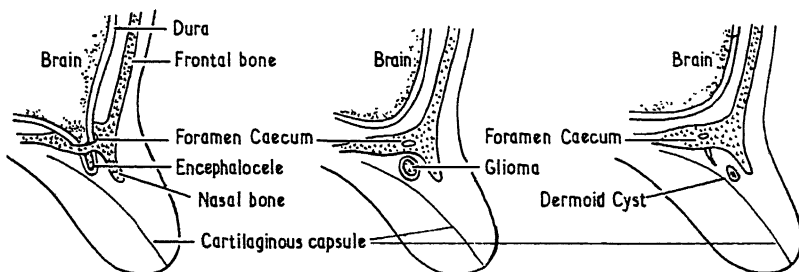
Congenital tumours are occasionally met with either externally or within the nasal cavity (*Fig. 26*).

Glioma. This is a solid tumour which may present externally at the root of the nose which becomes broadened, or it may appear intranasally from the roof or the lateral wall of the nasal cavity. It arises from a failure of the dural process to become sealed off in the foramen caecum during embryonic

DORSUM OF NOSE AT BIRTH



CONGENITAL NEOPLASMS OF NOSE AT BIRTH



ENCEPHALOCELE

GLIOMA

DERMOID CYST

Fig. 26. Congenital neoplasms of the nose. (Reproduced by permission of Baillière Tindall from 'The Ear Nose and Throat Diseases of Children' after Macomber and Wang, 'Plastic and Reconstructive Surgery' 1953.)

development. The external tumour is subcutaneous, firm and elastic to the touch, and it must be distinguished from a dermoid cyst. The intranasal type resembles a small nasal polypus on inspection and it may appear in the nasal vestibule. It is firm to the touch with a probe and does not enlarge when the baby cries, a fact which distinguishes it from an encephalocele. The glioma is composed of neuroglial tissue and astrocytes, and is not malignant. It should be removed completely.

Encephalocele. This is a herniation of dura mater which enters the nose through the foramen caecum or through a dehiscence in the cribriform plate of the ethmoid bone. The cyst contains cerebrospinal fluid and occasionally cerebral tissue. It is smooth, freely movable on its stalk, readily compressible and enlarges with crying. In view of its composition it is dangerous to puncture the cyst to determine the nature of its contents in case an intracranial infection results. The removal is a neurosurgical one and the deficiency in the floor of the skull is closed at the same time.

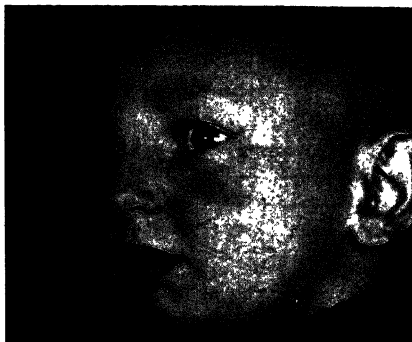

Fig. 27. Dermoid of the nose in a child aged 18 months. The sinus opening on the external nose has become infected.

Dermoid Cyst. This is an external midline cyst on the dorsum of the nose which contains hair and amorphous material. It may open on to the surface by a small sinus (*Fig. 27*) through which hair may protrude. This serves to distinguish it from an external glioma. The cyst tends to extend widely beneath or between the nasal bones towards the base of the skull, so that surgical removal may be an extensive procedure which may necessitate plastic reconstruction.

BENIGN TUMOURS

Rhinophyma. This condition occurs almost entirely in males past middle age in whom it may produce considerable deformity thus causing much distress on account of the disfigurement (*Plate III, 1*). It is a hypertrophy of the sebaceous glands of the tip of the nose and produces a marked swelling of the nasal apex which becomes bulbous in appearance. The skin is coarse and pitted and has an oily appearance because of the excessive secretion of sebaceous material. It is red or blue in colour from vascular engorgement. Treatment consists in shaving off the excess tissue to trim the nose to a suitable size after which a skin graft may be applied.

Papilloma. This may appear as a wart-like growth arising from the skin of the nasal vestibule where it may enlarge to become unsightly. It is removed by an incision around its base under local infiltration of novocaine. The incision is closed by a suture which is removed in a week.

Angioma. This uncommon tumour is sometimes called a bleeding polypus of the septum. It is a fibro-angioma which arises from the bleeding area of the septum as a dark red, rounded, often pedunculated tumour. It may cause some nasal obstruction and frequent epistaxis, and is removed under local anaesthesia by making an incision around its base which is then cauterized. If removal is complete recurrence does not take place.

Cysts. Cysts may arise from retention in the mucous glands in the floor of the nose or from the apices of the incisor teeth, and a differential diagnosis between the two types may require dental radiography. The retention cyst may be dissected out either intranasally or through an incision in the buccal mucosa. If the cyst is of dental origin it is approached through the mucoperiosteum of the premaxilla.

Cyst of the Middle Concha. This is not a true cyst but is a developmental anomaly causing enlargement of the anterior end of the middle concha with a cavity in the bone containing air or mucoid secretion. Nasal obstruction is caused and this may be sufficient to justify a limited removal of the anterior end of the middle concha including the cystic portion.

MALIGNANT TUMOURS

Sarcoma. Sarcoma is the most common intranasal malignant tumour arising in young people or even in children. It also occurs in adults and in the elderly. It may be a primary growth of the nasal septum or be an extension of sarcoma in one of the sinuses. It gives rise to nasal obstruction which may be considerable, to nasal discharge which is at times purulent and offensive, and to epistaxis which may be spontaneous or may be induced by probing the tumour. Pain is frequently met with. Sarcoma may resemble a polypus but it is more often a reddish sloughing mass of friable tissue. When such an appearance is found the nose should be examined under general anaesthesia, not only to remove the tissue for histological examination but in an endeavour to determine the origin. Radiography of the sinuses should be done. Radiotherapy is the treatment of choice, but in some instances resection of the nasal septum or other parts of the nasal framework may be undertaken, followed by the provision of a prosthesis once the tumour has been eradicated.

Carcinoma. Carcinoma is less common as an intranasal tumour. It is found in elderly patients either as a growth arising from the lateral wall of the nasal cavity or as an extension from the sinuses, especially the maxillary antrum. It produces symptoms similar to those of a sarcoma, and there may be considerable pain. Epiphora will develop if the nasolacrimal duct is blocked. Radiography of the sinuses should be carried out if a sloughing mass is found in the nose. A small early carcinoma may be excised intranasally, but usually the patient does not present until there is considerable growth which necessitates radiotherapy, or major excision, or both.

Melanoma. This is an extremely lethal tumour which is occasionally found as a smooth, dark, rounded growth arising from the lateral wall of the nose. It bleeds readily if probed. Treatment is local excision with diathermy followed

THE NOSE AND PARANASAL SINUSES

by radiotherapy. Recurrence is not uncommon and there may be glandular spread requiring a block dissection of the glands.

Fibroma. Fibroma is a rare borderline tumour and may present as a soft pedunculated growth arising from the nasal septum or the floor of the nasal cavity. It is removed locally, but may recur and degenerate into a fibrosarcoma. Removed tissue should always be sent for histological assessment.

CHAPTER 13

ACUTE SINUSITIS

Acute inflammation of the paranasal sinuses is due in most instances to extension of an infection in the nasal cavity, and is only very occasionally blood-borne. The sinuses may be involved singly, or two or more may become infected. The most common cause is an acute rhinitis, especially during a virus epidemic, but it may follow the acute infectious diseases, infections of the pharynx or tonsils, dental infections such as apicitis or apical abscess, or dental extraction should the floor of the maxillary sinus be ruptured. Injury to the facial bones, operations on the nose, bathing and particularly diving may result in sinusitis. Obstruction to the normal aeration of, or drainage from, a sinus because of a deviated nasal septum predisposes to sinus infection.

BACTERIOLOGY. The paranasal sinuses are probably bacteriologically sterile in normal conditions of health, although a healthy nasal cavity may contain micro-organisms. Acute infections are generally primarily virus in origin, the rhinovirus, para-influenzal viruses, ECHO viruses, Cocksackie viruses and respiratory syncytial viruses being the most common. Secondary infection occurs from pyogenic organisms such as pneumococci, streptococci, staphylococci, *H. influenzae*, *M. catarrhalis*, *B. Friedländer*, *Esch. coli*, *B. proteus* and diphtheroids. In dental infections *B. dentalis* and *B. necrodentalis* may also be present. Anaerobic organisms are not uncommonly found in the pus from infected sinuses.

PATHOLOGY. An acute sinusitis may be catarrhal or suppurative, the difference being one of degree. A catarrhal infection results in submucosal oedema with a moderate leucocytic infiltration and only slight alteration in the superficial epithelium. The discharge is mucoid. In the suppurative variety there may be little oedema, but there is considerable leucocytic infiltration and the surface epithelium may disappear or be subject to an extensive metaplasia. The discharge is mucopurulent or frankly purulent. Obstruction of the ostium usually occurs at the catarrhal stage and interferes with the drainage from the sinus, allowing the infection to increase in virulence and perhaps spread through the periosteum to involve the bony walls.

SYMPTOMS. The symptoms vary in severity. In milder cases with a patent ostium the symptoms are similar to those of the acute coryza which precedes the sinus infection so that it may be unrecognized until it passes to the chronic stage. There may be complaints of a feeling of fullness or tension in the affected sinus, or even of a slight ache which is accentuated by stooping, straining or coughing. There may be slight tenderness on pressure over the affected sinus.

In the more severe type there are malaise and pyrexia. Headache and pain are complained of, and there is a sensation of tightness in the sinus. The voice

loses its resonance. There is catarrh, at first mucoid, and becoming mucopurulent until the ostium closes when the discharge may cease, to reappear when the ostium reopens. Postnasal catarrh and a feeling of fullness in the nasopharynx may be experienced. The affected sinus is tender on pressure, often acutely so. Maxillary sinusitis causes infra-orbital pain. Ethmoidal sinusitis gives rise to pain over the bridge of the nose and between the eyes, while in sphenoidal sinusitis the pain may be occipital, vertical or retro-ocular. The pain of acute frontal sinusitis is supra-orbital with a characteristic periodicity. It starts in the forenoon, reaches its peak about midday and subsides in the afternoon, and thus does not disturb sleep at nights. During the exacerbation the sinus is exquisitely tender, the conjunctivae are injected and photophobia may be complained of.

Acute maxillary sinusitis is the most frequent form of acute sinusitis, then acute frontal sinusitis, while acute ethmoidal and acute sphenoidal sinusitis are seldom found as separate clinical entities. Acute ethmoidal sinusitis occasionally presents in young children in whom it may not be recognized until the infection passes through the lamina papyracea to give rise to an orbital cellulitis which shows itself as an inflammatory oedema of the eyelids, especially the upper eyelid, beginning at the inner canthus and spreading laterally to involve the whole lids (*see Fig. 23, p. 54*).

CLINICAL FEATURES. Anterior rhinoscopy shows congested oedematous mucosa and the inferior concha may be so swollen as to prevent a view of the middle concha and meatus. If it is not turgid, or if it has been shrunk by the application of cocaine hydrochloride solution on a pledget of cotton-wool, the middle concha may be inspected. Its mucosa is similarly congested and oedematous, and if the ostium is patent a streak of mucopus will be seen in the middle meatus (*Plate III, 2*). This starts high up and anteriorly in frontal sinus infection, but lower down and further posteriorly in maxillary sinusitis. The presence of mucopus confined to the olfactory cleft (*Plate III, 3*) medial to the middle concha suggests that the posterior ethmoid cells or the sphenoid sinus may be involved. Posterior rhinoscopy will show mucopus in the choana on the affected side (*Plate III, 4*).

There may be flushing and some swelling of the affected cheek in maxillary sinusitis, while oedema of the eyelids or of the forehead will suggest infection in the frontal or anterior ethmoidal sinuses. Tenderness over the inflamed sinus will be elicited on pressure, and palpation must be gentle and must avoid the supra-orbital and infra-orbital nerves which may be tender in trigeminal neuralgia.

Radiography of the sinuses must be performed. The standard occipitmental and lateral views are usually sufficient but oblique and verticomenal projections may be required to display the ethmoid and sphenoid sinuses (*see Fig. 30, p. 71*). The acutely inflamed sinus will appear homogeneously opaque (*Fig. 28*) or a fluid level may be present (*Fig. 29*).

DIFFERENTIAL DIAGNOSIS. This usually presents little difficulty when there is a history of a preceding coryza, pyrexia and sinus tenderness, but acute sinusitis may have to be distinguished from other causes of headache and from such dental lesions as apical abscess and an impacted tooth.

TREATMENT. Treatment is directed to controlling the infection and to establishing drainage from the sinus by reducing the mucosal swelling which occludes the ostium.

While the original virus infection does not respond to antibiotics the secondary invaders are usually antibiotic-sensitive. In the absence of a specimen of the mucopus, which may be obtained either with a throat swab in the nose, which may cause pain on touching the inflamed mucosa, or by blowing the nose into a sterile swab and taking a specimen from this, a broad-spectrum antibiotic such as ampicillin should be given in full doses for 7 days. If a sample of the pus is obtained and cultured the appropriate antibiotic should be prescribed if the strain is resistant to ampicillin.




Fig. 28. Acute left maxillary sinusitis showing radiological opacity.

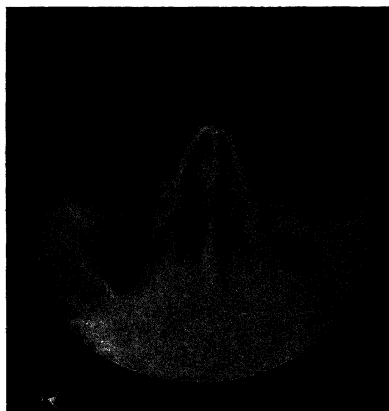


Fig. 29. Fluid level in the left maxillary sinus.

Decongestion of the inflamed oedematous mucosa is achieved by nasal drops or spray of 1 per cent ephedrine hydrochloride either alone or in combination with 1 per cent silver protein (Argotone). Steam inhalations of menthol crystals or of a 20 per cent alcoholic solution of menthol should be used some 10–15 minutes after the decongestant spray, as this allows a greater penetration. It is important in acute infections that these inhalations are not too strong, three crystals or 1 ml of the solution being sufficient in a pint (0.5 l) of water at 70 °C.

Analgesics may be required in the acute stage, and in very severe pain an injection of morphine may be necessary.

These measures are usually sufficient to result in a cure. Once the infection is controlled and drainage established the sinus generally clears itself of infected mucopus which is got rid of by nose blowing. The patient must be warned against too vigorous blowing of the nose in case the auditory tubes become involved and otitis media results.

Surgery is rarely necessary in the acute phase, nor is it desirable to operate through acutely inflamed bone. In some cases treatment of an acute sinusitis is not pursued with sufficient thoroughness, and occasionally it is unsuccessful. In such events a limited drainage operation may be considered necessary. The ostium of the maxillary sinus is unfavourably placed in the upper part of the medial wall so that drainage is difficult and infection may be retained

within the sinus. This may require to be got rid of by a proof puncture and lavage of the sinus (*see Fig. 32, p. 73*). The operation should be performed under general anaesthesia in acute cases. A trocar carrying a cannula is introduced into the antrum by piercing the bone of the lateral nasal wall near the roof of the inferior meatus where the wall is thinnest. The trocar is withdrawn and pus may be aspirated through the cannula and sent for bacteriological investigation and sensitivity tests. A Higginson's syringe is then attached to the cannula and sterile saline solution at blood heat is syringed into the antrum, the return flow passing through the ostium into the nasal cavity and collected in a receiver. In some cases a fine polythene tube is then passed into the sinus through the cannula which is withdrawn. The tube is attached to the cheek by strapping and the sinus may be washed out daily through it and a solution of the appropriate antibiotic instilled.

Should there be a dental cause for the acute maxillary sinusitis the dentist may deal with the septic tooth under the antibiotic cover for the sinusitis. When the sinusitis has been precipitated by a rupture of the antral floor during a dental extraction the treatment is on conservative lines until the acute stage has settled. In many cases the sinus between the antrum and the alveolar margin will heal, but if not and if infection persists in the antrum corrective surgery will be required (p. 85).

The ostium of the frontal sinus is favourably placed for drainage through the nasofrontal duct. Sometimes the duct remains occluded in spite of conservative therapy and in a few cases it may be necessary to open the frontal sinus externally through a small incision below the medial end of the eyebrow and to insert a drain into the sinus after making a small opening into its floor.

Acute ethmoidal and acute sphenoidal sinusitis rarely require any form of surgical interference, but an orbital abscess following ethmoiditis will require incision and drainage.

Short-wave diathermy should not be employed in the acute stage but is of value in the subacute phase to give relief from discomfort, and combined with decongestants to assist in drainage from the maxillary antrum.

CHAPTER 14

CHRONIC SINUSITIS

Chronic sinusitis usually follows an acute sinusitis in which the infection has failed to resolve because it was undiagnosed, untreated or insufficiently treated. Certain cases of chronic maxillary sinusitis may arise from a dental cause in which there has been no acute sinusitis. One or more of the paranasal sinuses may be involved, and the condition may be unilateral or bilateral. The maxillary sinuses are the most commonly involved, and next the ethmoidal sinuses with polypus formation.

The latent character of the infection may cause it to be unsuspected by the patient or the practitioner. Provided that the ostium remains even partially patent there will be an evacuation of a small amount of mucopus without any acute symptoms associated with blockage of the opening. Attention may only be drawn to chronic sinus disease in the course of a search for the origin of a complaint unrelated by the patient to his nasal sinuses. Inflammatory lesions in the pharynx, larynx, bronchi and middle ears are obvious examples, as is offensive breath, but gastric symptoms, rheumatic pains, neuralgias ophthalmic disorders or general malaise may on occasion be associated with chronic sinusitis, the treatment of which may afford relief. In such cases the absence of any gross nasal discharge or its non-purulent character may explain why attention is not directed to the sinuses.

SYMPTOMS. Nasal discharge is the most common symptom, the discharge being either blown out of the nose or felt trickling into the nasopharynx and pharynx. It is not always easy for the patient to determine the date of onset of the condition as months or years may have elapsed since the initial infection. Maxillary sinusitis arising from a carious tooth may have been insidious from the first. Nasal discharge varies in its amount and character. It may be so slight as to be hardly noticeable except with each fresh cold. The discharge may be transparent tenacious mucus or it may show any appearance and consistence up to creamy yellow pus, occasionally with crust formation. It may or may not be foetid, imparting an offensive odour to the breath, this being especially apparent with crust formation. The amount of the discharge may be increased on stooping. Postnasal catarrh is frequently present, and may be swallowed or spat out. This is not an invariable sign of sinusitis because nasal secretion is propelled towards the choanae and any condition within the nose which alters the consistence or amount of nasal secretion will lead to its becoming noticeable to the patient.

Nasal obstruction of varying degree is found in chronic sinus infection, and is due to the infected oedema of the nasal mucosa or to polypus formation. A slowly developing nasal obstruction is less obvious to the patient than a rapid occlusion from a growing polypus.

Pain is also a variable symptom in chronic sinus infections. Many people do not complain of any pain. It is more often met with in chronic frontal sinusitis on account of impeded drainage in the nasofrontal duct, but it may occur from swelling of the middle concha pressing on the lateral wall of the middle meatus.

Headache is a more common symptom, although chronic sinusitis accounts for only a small proportion of headaches. The headache is frequently referred to the frontal region, and this is always so in chronic frontal sinusitis. Chronic maxillary sinusitis may cause frontal headaches or an ache below the infra-orbital margin. Chronic inflammation of the sphenoidal and ethmoidal sinuses may cause frontal headaches or the pain may be seated behind the eyes or be felt in the occipital region. A type of headache, known as 'vacuum headache', results from the closure of the nasofrontal duct resulting in a diminished air pressure in the frontal sinus from absorption of the air and a passive congestion of its lining membrane. It may occur at any time and is often present during descent in an air flight. This headache is increased by movement of the eyes and there is tenderness in the floor of the frontal sinus.

Pharyngitis is a common accompaniment of chronic sinusitis while catarrhal deafness or otitis media, either a recurring acute infection or a chronic infection, may be precipitated or maintained by infection in the sinuses.

PATHOLOGY. In chronic catarrh of the sinuses the mucous membrane becomes greatly thickened or even polypoidal, and a similar state occurs in chronic allergic conditions especially in the maxillary and ethmoidal sinuses. Provided that chronic pyogenic infection does not supervene this mucosal change may be reversible after appropriate treatment. When chronic pyogenic infection takes place the pathological changes may become irreversible until surgery has been performed. The changes are those described in acute sinusitis, but the mucosa becomes thickened and often polypoidal, and the surface epithelium is destroyed.

CLINICAL FEATURES. Anterior rhinoscopy will show redness and swelling of the nasal mucous membrane. The inferior concha may be turgid thus obscuring a view of the middle meatus. If the middle meatus is seen, mucopus or pus will be found in it and running down to pool on the floor of the nasal cavity (see *Plate III, 2, 3*). If the ostium of the infected sinus is blocked there may be no abnormal secretions visible. Nasal polypi may be seen and their location should be identified.

Posterior rhinoscopy may reveal mucopus or pus in the posterior naris (see *Plate III, 4*) or in the nasopharynx, sometimes towards its roof. Polypi may also be found in the choana, and on occasion there may be a mulberry hypertrophy of the posterior end of the inferior concha.

Radiography of the nasal sinuses must be performed. The routine occipitomenthal and lateral views should be taken, but when infection is suspected in the ethmoidal and sphenoidal sinuses in particular oblique or verticomental views may also be obtained (*Fig. 30*). A well-exposed film will show details of mucosal thickening or early polypus formation. A homogeneous opacity may be found if the infected sinus is filled with secretion, while if it is partially filled a fluid level will be seen (see *Fig. 29, p. 67*). The translucency of the sinuses is compared with that of the orbits, and a haziness in a sinus may suggest a lack of air entry into the sinus. A polypus will appear as a rounded

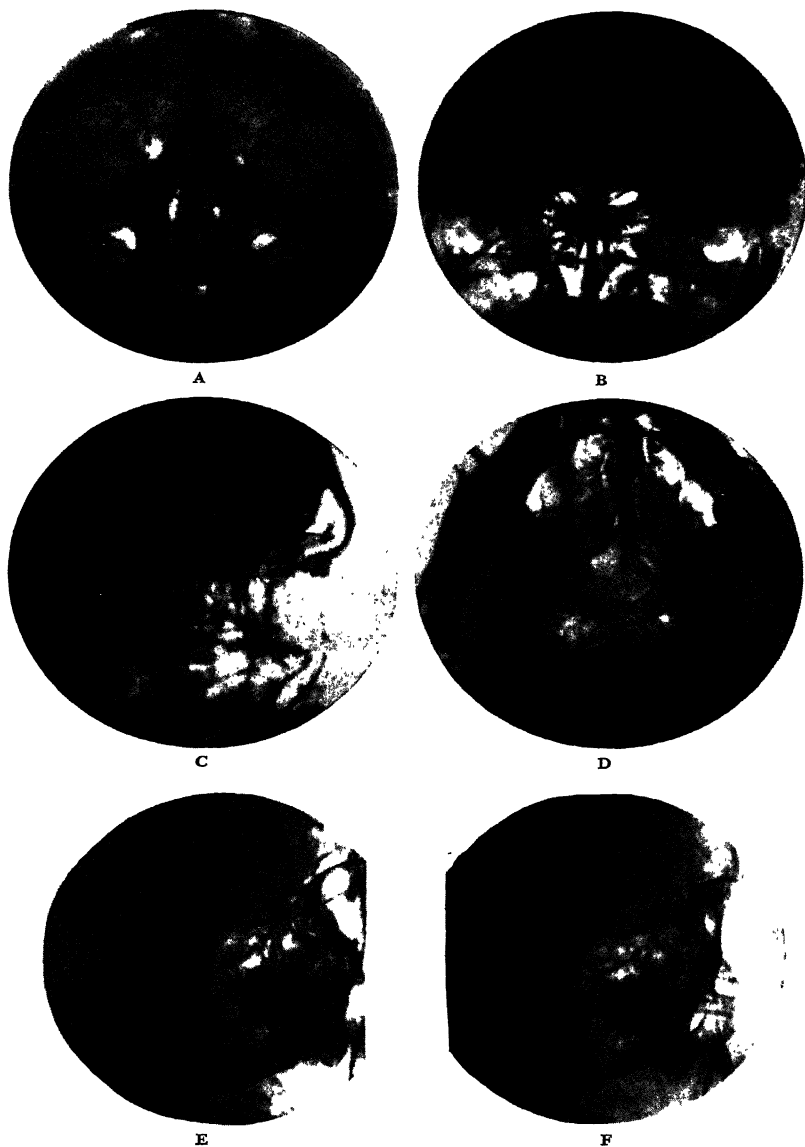


Fig. 30. Radiographs of normal paranasal sinuses. A, Occipitomenital view demonstrating the maxillary and frontal sinuses; B, Occipitofrontal view demonstrating the ethmoid cells; C, Lateral view to demonstrate the depth of the frontal and sphenoidal sinuses; D, Verticomenital view demonstrating the sphenoidal sinuses; E, F, Right and left oblique views demonstrating the right and left posterior

shadow, often on the floor of the maxillary sinus (*Fig. 31*), but multiple polypi may be found on the antral walls and roof. It may not be easy radiographically to distinguish a polypus from a cyst of the antrum. The cyst tends to be larger and a tooth may be seen within the opacity if the condition is one of dentigerous cyst. The bony walls of the affected sinus must be carefully inspected for erosion which might suggest the presence of a malignant tumour (*Fig. 44*, p. 91).

On the whole, radiography of adult sinuses gives a true picture of the contained pathology. In children the films may be less accurate because the

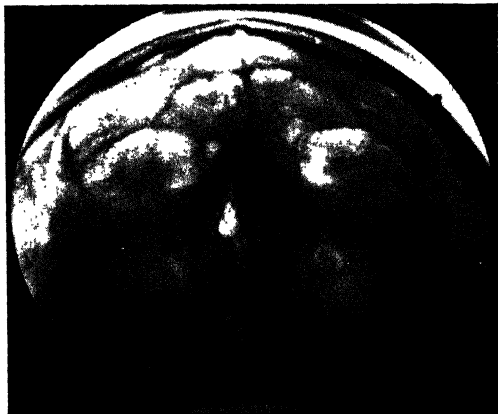


Fig. 31. Radiograph of paranasal sinuses demonstrating a polypus in the right antrum.

sinuses are in a state of growth and mucosal thickening may occur without significant pathology. Also, the child's nose may contain secretions which have not been blown clear so that air entry into the sinuses is impaired with a consequent loss of translucency on radiography.

In cases of doubt in adults a radio-opaque oil may be introduced into the maxillary sinus at proof puncture when subsequent radiography will make the pathology more evident. When erosion of a bony wall of one of the sinuses is suspected tomography will clarify the situation (*Fig. 45*, p. 91).

There may be an absence of the frontal sinus in one or both sides. This sinus is usually only seen radiologically after the age of 8 years by which age the cupola of the nasofrontal duct reaches the upper rim of the orbit. Arrest of growth of the sinus may occur in childhood but this does not denote any underlying pathology. Frontal sinuses are not always symmetrical as their development depends upon the absorption of cancellous bone between the outer and inner tables of the frontal bone. All varieties of asymmetry may occur without there being any pathology. A very shallow frontal sinus may simulate an opaque sinus on radiography in the occipitomeatal view but the lateral projection will generally disclose the fact that this opacity is apparent rather than real.

Apart from affording information on the state of the sinuses radiography will show deviations of the bony nasal septum, and the degree of nasal congestion may be estimated from the translucency of the nasal cavities.

Proof Puncture. As its name implies this is a puncture of the maxillary sinus to prove or disprove that a radiographically opaque sinus contains infected material. It is performed as a rule under local cocaine anaesthesia in adults but under general anaesthesia in children or nervous adults. The antrum is punctured through the inferior meatus by a trocar and cannula, the needle being inserted near the roof of the meatus where the antral wall is thin

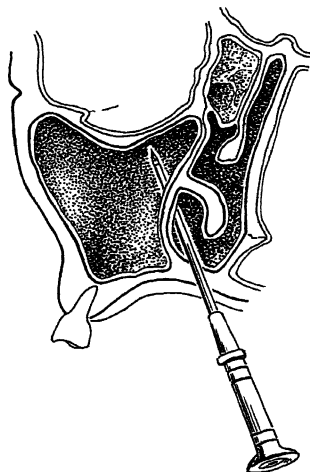


Fig. 32. Proof puncture of the right maxillary sinus.

(Fig. 32). On entering the antrum the trocar is withdrawn leaving the cannula in the sinus. A blunt pointed needle attached to a syringe containing 3 ml of sterile normal saline is passed through the cannula, the needle being of sufficient length to project beyond the tip of the cannula. The saline is injected into the sinus and slowly re-aspirated into the syringe and the contents inspected. If pus is found it can only have come from the sinus and it is sent for culture and sensitivity tests.

Some surgeons then remove the syringe and needle and pass a polythene tube through the cannula which is then withdrawn and the tubing is fixed to the cheek by adhesive tape. This tube may be used for lavage of the sinus or for instilling antibiotic solution into the sinus.

Antral Lavage. Antral lavage is an extension of the proof puncture. If mucopus is obtained at proof puncture the needle is withdrawn and a Higginson's syringe is attached to the cannula. The sinus is then washed through with a warm sterile solution of normal saline. This fluid will enter the nasal cavity if the ostium is patent and the flow is caught in a receiver held under the patient's nose. Some surgeons do not perform a preliminary aspiration but wash out the sinus immediately after puncture. It is important

to remember that the returning fluid contains not only the material contained in the antrum but also the catarrh which may be lying in the nasal cavity. It cannot be used for bacteriological tests with the same accuracy as that obtained at aspiration, and it is less diagnostic of the source of the infected material. An antral lavage is a therapeutic measure in that it mechanically clears the infection from the maxillary antrum, and thus may cure a chronic infection. It may have to be repeated on several occasions before the returning fluid is clear, and this is usually done at weekly intervals.

Accidents may occasionally complicate this simple procedure. If the maxillary sinus is small and narrow the trocar may be inserted with such force as to penetrate both medial and lateral walls of the sinus so that fluid is injected into the soft tissues of the cheek. This is recognized by pain and by the appearance of a swelling visible on the face. Such swelling soon resolves without incident if aseptic precautions have been observed. More uncommonly, but more seriously, the roof of the sinus may be punctured so that fluid is injected into the orbit with swelling and pain. Again this fluid is absorbed in time. These complications are more liable to occur if the puncture has been performed in children.

TREATMENT. The principles of treatment of chronic sinusitis are: (i) the establishment of drainage from the infected sinus, which may provide a cure if the pathological changes in the sinus mucosa are reversible, and (ii) the surgical removal of infected mucosa when conservative therapy has failed or when the pathological changes are irreversible.

Conservative therapy aims at the re-establishment of free drainage and the control of infection, and it is usually advocated in the first instance, especially in cases of relatively short duration. Antibiotics are given to combat the infection. If the organisms are known as, for example, when infected material has been cultured following a proof puncture, a course of the appropriate antibiotic is prescribed for 7 days. In some cases lavage may be continued through an indwelling polythene catheter during this time. If the infecting organisms have not been identified a broad-spectrum antibiotic may have to be used as the bacteriological flora varies considerably. Ampicillin is a suitable drug. Many of the cultures are staphylococcal, some of which are penicillinase producing in which event methicillin (Celbenin), cloxacillin (Orbenin) or flucloxacillin (Floxapen) must be used. Carbenicillin (Pyopen) is employed if the organisms are *B. proteus*, *Esch. coli* or pseudomonas which are penicillinase producing. In some resistant cases cephalosporin will have to be used as cephalixin (Ceporex or Keflex) but these should be reserved for particular cases and never employed as a first choice. In chronic cases in which there is no urgency about starting antibiotic therapy it is much more satisfactory to identify the strain and sensitivity of the infecting organisms at proof puncture before therapy is begun.

Decongestion should be combined with antibiotic therapy, and this is achieved by nasal sprays or drops of 1 per cent ephedrine hydrochloride either alone or combined with 1 per cent silver protein (Argotone). Steam inhalations may also be used to promote drainage, and are given some 10 minutes after the decongestant spray. Short-wave diathermy is indicated at this stage, and the combination of decongestants, antibiotics, short-wave diathermy and antral lavage, if the maxillary sinus is involved, is frequently effective in curing the condition.

Chronic infection of the frontal sinus may be treated by broad-spectrum antibiotics, decongestants and short-wave diathermy. Chronic infection of the ethmoidal sinuses is less amenable to conservative methods because of the production of nasal polypi in many instances.

Surgical Treatment. Surgery is generally reserved for those cases not responding to conservative means, but it may be recommended initially in cases of chronic infection of long standing, especially if radiography shows mucosal changes of such a nature as to be regarded as irreversible, and in cases in which the disease appears to be producing complications. The aim of surgery is to establish drainage and to remove the chronically infected mucosa. In most instances these aims are accomplished at the same operation, but in cases of short duration or in children preference may be given to simple drainage operations in the first instance. Surgery by itself will not produce a cure and it requires to be supplemented by conservative means in many cases.

Maxillary Sinus. This is by far the most commonly infected sinus, and its anatomical situation makes it readily approached surgically as it is separated from the nasal cavity by a thin bony wall and it lies superficially antero-laterally. The most conservative surgical procedure is antral lavage, which has been described (p. 73). Antral lavage may be curative in children and in many adults with short histories, but it may have to be repeated weekly until the return flow of fluid is clear.

Intranasal Antrostomy. This may be recommended in children in whom antral lavage has failed to cure the condition, and it may be performed in adults for similar reasons if radiography does not suggest irreversible mucosal changes. The principle is to create a drainage hole low down in the medial wall of the sinus through which secretions may easily escape from the antrum. It is essentially the same operation as the proof puncture except that a larger opening is fashioned lower down on the medial antral wall by drill and punch forceps. If there is hypertrophy of the anterior end of the inferior concha this may be trimmed to facilitate drainage and subsequent lavage. This is effective in many cases if these have been properly selected. It may be performed under local anaesthesia, but a general anaesthetic is usually employed. The stay in hospital is only for a few days. Decongestant sprays and inhalations are usually prescribed following surgery. Some surgeons wash out the antrum on the day after the operation to get rid of blood clot and secretions, and some continue this at intervals after the patient has gone home. This serves to maintain the patency of the opening created.

Radical Antrostomy. Radical antrostomy, or the Caldwell-Luc operation, is performed in cases where conservative therapy and minor surgery have failed to produce a cure, but it may be advocated as a first choice in long-standing cases in whom radiography shows dense mucosal thickening with polypoid formation in the antrum. It consists in opening the antrum through an incision in the gingivolabial fold (*Fig. 33*). The sinus is opened with a gouge, the opening enlarged and infected material aspirated to afford a view of the walls of the sinus (*Fig. 34*). Polypi are removed and thickened lining membrane is cleared out. A large counter-opening is made into the nasal cavity through the inferior meatus and the incision closed with catgut sutures. After-treatment is similar to that for the intranasal operation, the cavity being washed out through the nasal opening. The sutures slough out in about a week and the patient is then discharged from hospital to continue with

decongestants and steam inhalations. The patient is usually off work for a further 2 weeks at the most.

Frontal Sinus. Operations on the frontal sinus are not commonly necessary but will be required in the presence of continuing headache, or should there be evidence of spreading infection.

Intranasal operations are rarely performed because the passage of catheters or other instruments through the nasofrontal duct may result in stricture or



Fig. 33. Operation on the maxillary sinus through the canine fossa wall (Caldwell-Luc). The buccal incision.

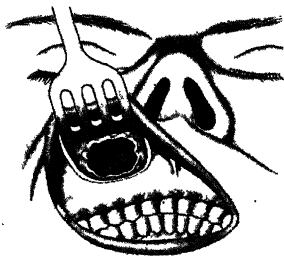

Fig. 34. Operation on the maxillary sinus (Caldwell-Luc). Opening in the canine fossa wall, exposing to view the lateral wall of the inferior meatus.

occlusion of the long duct, and this defeats the surgical aim of providing drainage.

External operation is more generally performed. The standard procedure consists in making an external incision from beneath the supra-orbital margin medial to the inner canthus and along the side of the nasal bridge (Fig. 35A). The frontal sinus is entered near its floor (Fig. 35B), the opening is enlarged and the diseased mucosa removed. The adjacent ethmoidal cells are cleared to afford a wide drainage into the nasal cavity (Fig. 35C) and this is kept patent by the insertion of a polythene tube of appropriate size. The incision is closed and the sutures are removed in a week. The polythene tube is removed at the same time or later. After-treatment is by nasal decongestants and steam inhalations. The patient is in hospital for about 2 weeks and will be off work for as long again. If much of the anterior wall has had to be removed there may be an indentation in the forehead.

The osteoplastic flap operation has been devised to avoid this deformity following surgery for chronic frontal sinusitis, and especially for the surgery for osteoma of the frontal sinus. It is also used for a mucocele of the sinus or if osteomyelitis develops. It consists in making a coronal incision behind the frontal hair line and turning down the forehead skin and with it the anterior wall of the affected sinus which is opened from its superior aspect. The resulting scar is invisible, provided that the patient is not bald, and by preserving the anterior sinus wall there is no disfigurement.

Ethmoidal Sinuses. Chronic infection of the ethmoidal sinuses is often accompanied by the production of nasal polypi, but infection may occur without this.

Intranasal surgery of the ethmoidal cells is frequently performed during the operation for removal of nasal polypi (Chapter 11). In the absence of nasal

polypi intranasal ethmoidectomy is rarely performed because access is limited and adequate drainage of the labyrinth of cells is not easily achieved.

External ethmoidectomy is recommended for chronic infection of the ethmoidal sinuses with evidence of complications, usually an extension into the orbit. It is also performed for frequent recurrences of nasal polypi which are not controlled by simple removals and when a more radical cure is desirable. The standard operation is through an incision around the inner



Fig. 35. Radical frontal operation. A, Incision. B, Opening of frontal sinus. C, Ethmoidal cells opened and drainage into nose created.

canthus through which the ethmoidal labyrinth is reached and the cells exenterated ensuring a wide drainage into the nasal cavity. The incision is closed and the stitches removed in a week. The after-treatment is that of external frontal sinus operation.

The Patterson operation is an external ethmoidectomy in which the incision starts near the inner canthus and extends downwards and laterally in the natural fold between the lower eyelid and the cheek, thus achieving an almost invisible scar. The exposure of the ethmoidal cells is claimed to be much wider than in the standard approach.

THE NOSE AND PARANASAL SINUSES

Sphenoidal Sinus. Chronic infection of the sphenoidal sinus may rarely exist alone, but usually accompanies chronic infection of the ethmoidal sinuses, especially the posterior ones.

Intranasal operation is seldom performed except for the purpose of hypophysectomy (p. 87).

External operation is through the same approach as for the ethmoidal cells which are removed posteriorly until the anterior wall of the sphenoidal sinus is seen. The anterior sinus wall is then removed and access to the sinus thus gained.

CHAPTER 15

COMPLICATIONS OF SINUSITIS

ORBITAL CELLULITIS AND ABSCESS

A spread of infection into the orbit may occur in acute sinusitis or more commonly in acute exacerbations of chronic infection of the ethmoidal and frontal sinuses. These sinuses are in close anatomical relationship with the roof and the medial wall of the orbit, and infection may spread directly to involve the orbital contents. There will be an orbital periostitis and a subperiosteal abscess formation leading to oedema of the eyelids, chemosis of the conjunctiva and displacement of the eyeball with impairment of its mobility (Fig. 36). If the spread occurs from the posterior ethmoidal cells there is

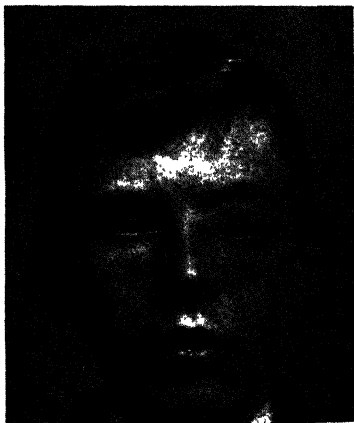


Fig. 36. Left orbital abscess secondary to suppuration in the frontal sinus. Oedema of the left upper eyelid, narrowing of the palpebral fissure, proptosis with downward and lateral displacement of left eyeball.

retrobulbar neuritis, optic atrophy and paralysis of the ocular muscles. The infecting organisms are staphylococcus, streptococcus, including the anaerobic type, pneumococcus and *H. influenzae*.

SYMPTOMS. The patient complains of pain around the orbit and of swelling of the lids and the conjunctiva. Limitation of movement of the eyeball results in diplopia, while pressure on the optic nerve may lead to optic atrophy and blindness.

CLINICAL FEATURES. Swelling of the eyelids especially near the inner canthus may be the first sign, followed by chemosis of the conjunctiva and limited eye movements. Testing of visual acuity will show a central scotoma and a peripheral contraction of the field of vision, especially for colours, and this may be bilateral. Anterior rhinoscopy will show congested oedematous

mucosa and mucopus may be seen in the middle meatus or the olfactory cleft. The affected sinus will be tender to the touch. Radiography of the sinuses will confirm the source of the orbital infection.

TREATMENT. This is initially antibiotic and unless a sample of the pus is available a broad-spectrum antibiotic, such as a mixture of ampicillin and flucloxacillin (Magnapen) or ampicillin and cloxacillin (Ampiclox), should be given. If no improvement is apparent, and imperatively if visual symptoms deteriorate, the orbit should be opened through an incision in the superomedial quadrant of the orbit and the abscess sought for and drained.

PROGNOSIS. Many of these cases recover completely with a return of full vision. Blindness may ensue if optic atrophy is not promptly relieved. Death may occur from a spreading thrombophlebitis of the ophthalmic veins to involve the cavernous blood sinus.

OSTEOMYELITIS

Osteomyelitis of the skull may occur wherever there is diploetic bone in the neighbourhood of an infected sinus, and thus it is most frequently found in frontal sinusitis and less commonly in maxillary sinusitis. Acute osteomyelitis may occur in untreated acute sinusitis or it may follow operations upon inflamed sinuses. The disease is more common in young people. Pus under pressure may produce a septic thrombophlebitis in the diploetic bone between the two tables of the frontal bone. Surgical opening of diploetic bone in the presence of an acute infection and, especially, curettage of cancellous bone, may precipitate osteomyelitis. Surgery of non-diploetic bone, such as the bony wall of the floor of the frontal sinus or the wall between the nasal cavity and the maxillary sinus, may be undertaken in the acute phase without the danger of osteomyelitis, but such surgery must be strictly limited to these areas. The common organisms are staphylococcus and streptococcus, especially its anaerobic variety, while *H. influenzae* and pneumococcus are less frequent causes.

SYMPTOMS. Symptoms may not be marked unless the condition is fulminating. The disease occurs a few days after the sinusitis or the surgical procedure, and is ushered in by pyrexia often accompanied by rigors. There is a dull boring pain in the affected bone, and a headache which may be generalized or occipital. A swelling appears over the affected bone which is tender. Further swellings may appear later in the frontal region if this sinus is the source. Radiography (*Fig. 37*) will show the sinus infection and may reveal a mottled appearance in the osteomyelitic areas.

TREATMENT. A broad-spectrum antibiotic such as ampicillin either alone or combined with cloxacillin (Ampiclox) or with flucloxacillin (Magnapen) should be given unless sensitivity tests of the responsible organism are available. The affected sinus should be drained through non-diploetic bone, the maxillary sinus being opened intranasally and the frontal sinus through a small burr hole in its floor. The pus is cultured and sensitivity tests done and the appropriate antibiotic is given in maximum dosage. Many cases settle completely with this regime, but a fulminating osteomyelitis of the frontal bone may produce sequestra which can be seen radiographically. If these appear the osteoplastic flap operation (p. 76) will afford the best opportunity of removing them.

PROGNOSIS. This is a serious disease and although the majority of patients recover death may occur from septicaemia or from intracranial complications.

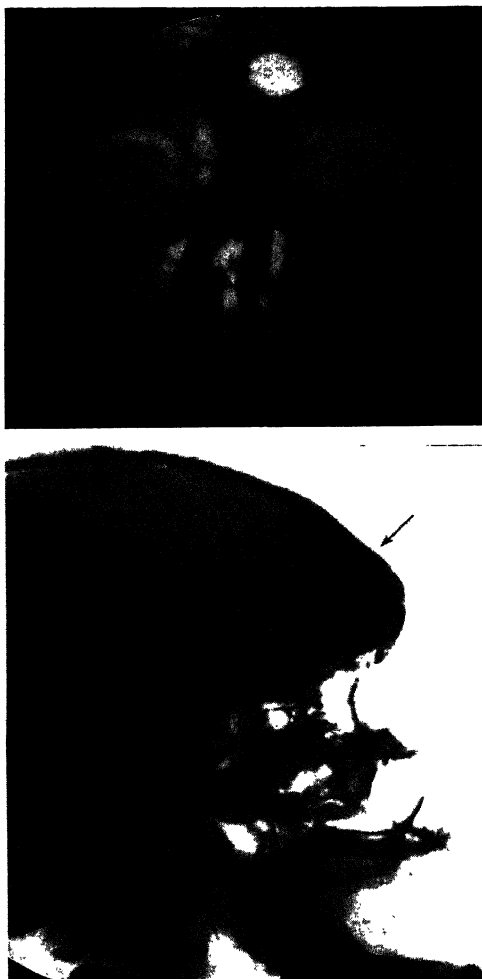


Fig. 37. Radiographs demonstrating osteomyelitis of the frontal bone; showing an area of necrosis in relation to the left frontal sinus.

Infantile Osteomyelitis of the Maxilla. This is a disease of young infants in the first few weeks of life. It is due to infection in the bud of the first upper molar tooth. The infection is frequently staphylococcal in origin, but the streptococcus, including the anaerobic variety, is sometimes found. Infection spreads

from the tooth bud: (i) to erupt on the alveolar margin; (ii) to involve the neighbouring infantile maxillary sinus so that pus escapes into the nasal cavity and appears at the anterior naris; and (iii) into the orbit to produce an orbital cellulitis (*Fig. 38*) which may be severe and give rise to sequestrum formation at the outer canthus.

Pus from the nose and alveolar margin is cultured and from the sensitivity tests a course of the appropriate antibiotic is given. Until these results are

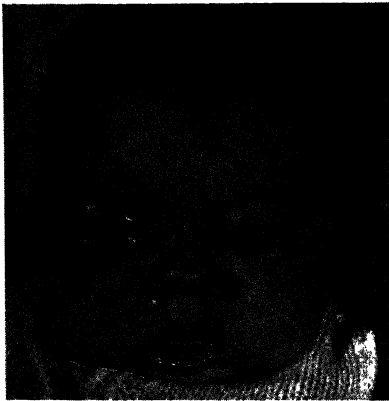


Fig. 38. Osteomyelitis of the maxilla in an infant, showing oedema of the eyelids and nasal discharge.

obtained a broad-spectrum antibiotic such as ampicillin with cloxacillin (Ampiclox) is used. If the correct antibiotic is given for at least 7 days, and preferably 10 days, a complete recovery is to be expected. There is no need to drain the maxillary sinus. When the first upper molar tooth erupts it is discoloured and lacks enamel.

INTRACRANIAL COMPLICATIONS

Infection may spread from the sinuses to involve the brain or the meninges, either by a spreading thrombophlebitis or by direct extension if there has been a fracture or surgical trauma. Infection may spread from the nasal cavity along the perineural sheaths of the olfactory nerves. Intracranial complications have become less common since the routine treatment of sinus infections by antibiotics.

Meningitis may arise from acute or chronic infection in the ethmoidal or frontal sinuses by a spreading thrombophlebitis, from a spread along the perineural sheaths of the olfactory nerves following infection in the nasal cavity, or rarely from surgical puncture of an encephalocele. The clinical features are those of meningitis from any other cause, and treatment is antibiotic, preferably the appropriate one if this can be discovered.

Brain abscess most commonly arises from frontal sinusitis in which the infection erodes the posterior wall of the sinus to produce an extradural abscess or an abscess of the frontal lobe. The frontal lobe does not give rise to

any localizing phenomena from abscess formation and diagnosis is consequently difficult to make. There may be evidence of progressive cerebral compression in that there is a complaint of headache sometimes accompanied by vomiting. The temperature is subnormal and the pulse is slow. There are slowly developing personality changes such as delayed cerebration and defective memory. The pupil may be contracted and react sluggishly but a large abscess may result in the pupil being in a state of stable mydriasis. The



Fig. 39. Cavernous sinus thrombosis.

frontal sinus should be explored and its posterior wall examined for evidence of erosion. Enlargement of the defect will drain an extradural abscess into the sinus. A frontal lobe abscess may be drained via a burr hole, but the help of the neurosurgeon is frequently sought to localize and deal with the abscess.

Cavernous sinus thrombosis is a serious and frequently fatal complication of ethmoidal sinusitis which is now rarely seen as a result of antibiotic therapy for the original infection. A thrombophlebitis of the ophthalmic vein causes oedema of the eyelids, chemosis of the conjunctiva and proptosis of the eyeball with blurring of the optic disc, while paralysis of the ocular muscles leads to fixation of the eyeball. The thrombosis spreads from one cavernous sinus to the other so that similar signs appear in the other eye either simultaneously or after a brief interval (*Fig. 39*). Treatment by broad-spectrum antibiotics and anticoagulants must be vigorous.

CHAPTER 16

MISCELLANEOUS AFFECTIONS OF THE SINUSES

AERO-SINUSITIS

Aero-sinusitis, or barotrauma, is still met with despite pressurization of aircraft as greater altitudes and greater speeds of ascent and descent are achieved. It is also found in deep diving and under-water swimming. The body cavities, including the middle ears and sinuses, are affected directly by changes in barometric pressure if their communicating passages to the outside are obstructed. If obstruction occurs during ascent the pressure inside the sinus becomes greater than that outside with consequent expansion of enclosed air to the limit of the lining walls and resultant pain. During descent the opposite effect occurs and the mucosal lining may even be torn from the walls with submucosal haemorrhage. Pus in the nose may be sucked into the sinuses with pain in the frontal region, the cheek or the ear. The treatment is largely preventive in that any anatomical obstruction to airway from a deflected nasal septum or polypi or allergic oedema should be corrected before flying or deep diving. Pilots with such defects should not be accepted until these have been corrected, and patients should be discouraged from flying if they suffer from coryza or known sinus infection.

INJURY TO THE SINUSES

Frontal Sinus. Direct violence may cause a fracture of the anterior wall of the sinus with depression of the fragments which may be elevated into place. A fracture involving the posterior wall of the sinus may cause a tear in the dura mater and is thus potentially serious. It may be diagnosed on lateral radiography which will show the presence of air in the anterior fossa, and from a discharge of cerebrospinal fluid from the nose. If the condition does not resolve on antibiotic treatment the dural defect must be closed at an external operation either by means of an osteoplastic flap approach or by access being gained directly through the frontal sinus if the anterior wall is also fractured.

Maxillary Sinus. A direct blow to the face may fracture the frontal process of the maxilla, the fracture line extending from the lower rim of the orbit at the infra-orbital foramen down the anterior wall of the sinus. A more lateral blow may fracture the malar bone and even the lateral wall of the antrum. The malar bone is elevated into place by a lever inserted through an incision over the temporal fossa. Diplopia suggests an involvement of the orbital wall of the antrum, and fragments may have to be repositioned through a Caldwell-Luc approach.

Compound Fractures. These are treated on general surgical principles of cleaning the wound and removal of foreign bodies and bony spicules. Reconstruction is not undertaken in the presence of infection. It involves the correction of the bite and elevation of the bony walls of the antrum and fixation until union has occurred.

Penetrating Wounds. Penetrating wounds involve the frontal and maxillary sinuses as a rule. Bullet wounds of the frontal sinus may involve the dura mater, while bullets entering the maxillary sinus may pass into the nose, the orbit or the pterygoid fossa depending on the trajectory. Surgical removal of the missile and bony fragments is undertaken with antibiotic cover.

ORO-ANTRAL FISTULA

An oro-antral fistula occurs most frequently through the alveolar border following dental extractions, particularly of upper molar teeth, but it may also follow a Caldwell-Luc operation in which the incision has broken down, or the spread of a malignant tumour of the maxillary sinus through the hard palate. Predisposing factors include a root abscess, a retained tooth root or a dental cyst. The early management of an oro-antral fistula following dental extraction is important. A small, clean fistula may be sutured immediately, and many fistulas heal provided that the blood clot in the lumen is undisturbed and that antibiotics are given. In the larger fistula a temporary acrylic plate may be fitted to prevent food entering the fistula or infecting the suture line during healing. Should a tooth root have been forced into the antrum during extraction a Caldwell-Luc operation is performed, the tooth root removed and the incision and fistula are closed by sutures. Should the maxillary sinus have become infected before the patient is seen a radical antrostomy is performed. A large fistula which cannot be closed by direct suturing is repaired by sliding a palatal flap laterally to cover the defect and suturing it to the freshened buccal edge of the fistula.

MUCOCELE

A mucocele may arise, for no known reason, in the ethmoidal or frontal sinuses, and is characterized by the appearance and slow painless growth of a rounded swelling in the superomedial quadrant of the orbit, usually above the inner canthus. The affected sinus is distended and its bony walls are thinned. The orbital contents may be displaced forwards, downwards and laterally (*Plate IV*), and this causes diplopia. It is not uncommon that the swelling has been present for many months before advice is sought because enlargement is slow and painless.

CLINICAL FEATURES. The characteristic swelling is obvious, and feels elastic. It is not tender and it cannot be reduced by pressure. The skin is freely movable over the swelling. The eyeball is limited in its movement medially and upwards; the pupil reacts to light and the fundus is normal. There is usually no abnormality on anterior rhinoscopy. Radiography will show the increased density and enlargement of the sinus.

TREATMENT. The mucocele should be removed completely at an external fronto-ethmoidal operation, and there should be no recurrence. The cyst contains sterile green or brownish fluid.

CYSTS OF THE MAXILLARY SINUS

Cysts of the maxillary sinus are usually of dental origin and are called dental cysts. If the cyst contains a tooth it is termed a dentigerous cyst. The cause of a dental cyst lies in the periodontium or periosteum of a diseased upper premolar or molar tooth. The cyst enters the antrum through its floor and gradually enlarges until it may distend the sinus cavity by pressure on its walls. Dental cysts may occur at any age.




Fig. 40. Cyst almost filling the maxillary antrum of a child.

SYMPTOMS. The cyst may be entirely painless, giving rise to no symptoms and being discovered accidentally. Infection within the cyst causes toothache and pain in the infra-orbital region. Similarly, distension of the sinus produces local pain.

CLINICAL FEATURES. Clinical examination may be negative if the cyst is small. When the antrum becomes enlarged there may be a fullness of the inferior meatus or even of the hard palate, and palpation of the gingivolabial fold gives a sensation of crackling elasticity. Radiography will show a spherical dense area in the floor of the maxillary sinus if the cyst is small (Fig. 40). When the cyst fills the antrum there is a homogeneous opacity, and if it contains a tooth this will be seen on radiography (Fig. 41).

TREATMENT. Proof puncture of the affected antrum will produce clear greenish or amber-coloured fluid which may issue through the cannula when the trocar is withdrawn. The rest of the contents may be aspirated into a syringe through a blunt-pointed needle inserted through the cannula. This in itself may cure the condition if dental attention is given to the unhealthy tooth. If the cyst is large or infected, or if it should contain a tooth, a Caldwell-Luc operation is performed and the entire cyst removed.

FACIAL FIBROUS DYSPLASIA

This denotes a unilateral fibro-osseous thickening of the frontal bone or the alveolar border of the maxilla, and it is most often found in young women between the ages of 10 and 20 years. It is a rare condition which in the maxilla results in a unilateral broadening of the alveolus which presents a smooth surface with a normal mucosal covering from which the teeth project



Fig. 41. Radiograph of the paranasal sinuses, demonstrating a cyst containing a tooth in the maxillary antrum.

only to a slight extent. The cavity of the maxillary sinus may become obliterated. The only complaint is of toothache. In the frontal region there is a unilateral swelling over the frontal sinus.

The condition as it affects the maxilla must be distinguished from a dental cyst by the absence of a crackling sensation on palpation of the swelling; and from a malignant tumour by its slow growth and the absence of pain. Fibrous dysplasia of the frontal region must be differentiated from osteomyelitis by its painless nature and by the fact that there is no general ill-health. The diagnosis is confirmed by histology of the tissue after removal.

Should treatment be called for in the maxillary type it consists in reflecting the mucosa and trimming the vascular cancellous new bone. In the frontal region cosmetic trimming may be required. Recurrence is unlikely because growth ceases about the age of 20 when skeletal growth stops.

HYPOPHYSECTOMY

Hypophysectomy is performed on the normal pituitary gland for the control of carcinoma of the breast or of the prostate, or in Cushing's syndrome. The

THE NOSE AND PARANASAL SINUSES

operation is also undertaken in tumours of the gland, such as eosinophil adenoma, basophil adenoma, chromophobe adenoma or malignant tumours of the gland. The pituitary gland may be approached through the nasal cavity, often following an extensive septal resection to reach the anterior sinus wall, or through an external incision when access is gained through the ethmoidal cells. Operation is contra-indicated in the presence of sepsis in the nose or sinuses and it may be technically difficult if the sphenoidal sinus is shown radiographically to be small. Some surgeons attempt to destroy the pituitary gland by the implantation of seeds of yttrium-90 through the nose using a special instrument. There may be a leak of cerebrospinal fluid into the nose following hypophysectomy and this requires reopening of the sphenoidal sinus and closure of the defect or plugging of the sinus.

CHAPTER 17

TUMOURS OF THE SINUSES

BENIGN TUMOURS

Osteoma. Osteoma of the frontal sinus is probably the most common benign tumour arising in the nasal sinuses, and it is often discovered accidentally on routine sinus radiography, possibly during the search for some other condition. The osteoma arises from the floor of the frontal sinus near the midline (*Fig. 42*). In many instances there are no symptoms unless the osteoma enlarges to block the entrance to the nasofrontal duct, or unless the sinus becomes infected when headache is experienced. The chance discovery of an osteoma calls for no treatment, and there should be no necessity to make the patient aware of its presence. Removal of the osteoma by an osteoplastic flap approach should be undertaken in the presence of symptoms due to a blocked nasofrontal duct. The results are satisfactory.

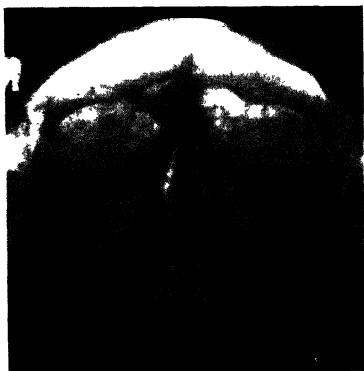


Fig. 42. Osteoma of the right frontal sinus.

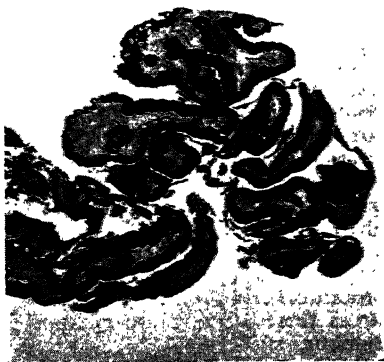

Fig. 43. Section of papillomatosis of the nose.

Papilloma. A diffuse form of papillomatosis may be found in the nasal cavity and in the maxillary and ethmoidal sinuses. The papillomatous mass spreads by expanding the walls of the sinus rather than by invasion, and it may be difficult to determine the exact site of origin. The tumour is histologically benign (*Fig. 43*), and it neither spreads to lymph nodes nor does it metastasize. On the other hand, it tends to recur rapidly after removal. Nasal obstruction

is complained of in the affected side of the nose. There is often epistaxis, and there may be pain either over the affected sinus or referred to the forehead. The pain is due to the expansion of the walls of the sinus. On anterior rhinoscopy the nasal cavity contains a pinkish-white, friable mass of wart-like growth which bleeds readily on being probed. Radiography will demonstrate the extent of involvement of the maxillary and ethmoidal sinuses. The tumour mass should be removed through a wide Caldwell-Luc approach. The mass is followed upwards and removed from the ethmoidal cells and from the nasal cavity, and a large counter-opening is made. The use of radium, either as an implant or as radiotherapy, has been advocated. The tumour mass must be examined histologically at every removal for evidence of malignant degeneration, although this is uncommon.

Fibroma. Fibroma is rarely found within the sinuses as a soft, pedunculated tumour which recurs after removal, and is liable to become sarcomatous. In view of this it should be treated as a malignant tumour when the histological report is available, and a course of radiotherapy given.

Angioma. Angioma uncommonly involves the ethmoidal cells and gives rise to profuse epistaxis. It may be amenable to cryosurgery or to the injection of sclerosing solutions, but very often diathermy removal after an external approach is required, followed by radiotherapy or radium implantation.

MALIGNANT TUMOURS

Malignant tumours which develop primarily in the sinuses usually originate in the maxillary or ethmoidal sinuses.

PATHOLOGY. The most common tumour is the squamous-celled carcinoma, which accounts for 80 per cent of the cases. Adenocarcinoma, transitional-celled carcinoma, sarcomata of various types—round-celled sarcoma, myxosarcoma, fibrosarcoma, chondrosarcoma and lymphosarcoma—and the melanomata such as melanosarcoma and melano-epithelioma may all be found. The melanoma, sarcomata and carcinoma of the immature-celled type are the most highly malignant.

SITE OF ORIGIN. Malignant tumours arise in the maxillary sinus, ethmoidal sinuses, sphenoidal sinus and frontal sinus in that order of frequency, the latter two being very rarely involved. It is often extremely difficult to determine the exact site of origin as patients are not usually seen until the disease is advanced and the tumour has spread beyond the original site. The one exception is the adenocarcinoma which is found in the ethmoidal cells of woodworkers in whom the disease may be discovered early because in certain areas these workers are examined at regular intervals specifically for the tumour.

CLASSIFICATION. Various classifications have been used over the years from the point of view of prognosis. In general, a better prognosis is likely if the tumour can be shown to arise from the antero-inferior part of the maxillary sinus, while the outlook is poorer if the growth has its origin in the postero-superior part of the antrum or in the ethmoidal sinuses.

SYMPTOMS. There are few early symptoms, which may explain why so many cases are seen after considerable spread has occurred. When the tumour has invaded the nasal cavity there is increasing unilateral nasal obstruction, a bloodstained nasal discharge which is often foetid, pain in the cheek or teeth,

sometimes loosening of the upper teeth on the affected side, and swelling of the cheek or hard palate. Later there is neuralgic pain referred to the ear, and involvement of the orbit with disturbance of vision. Extension to the base of the skull produces intense headache. The degree and constancy of the pain in the late case are the most distressing features. Three-quarters of all cases arise in the 40–60-year-old age groups.

CLINICAL FEATURES. These depend upon the degree of extension of the tumour, when swelling of the cheek or hard palate may be found. Anterior rhinoscopy may show invasion of the nasal cavity by a friable, granular tumour mass which bleeds readily. The orbit must also be examined for evidence of spread. The cervical lymph nodes may be involved late in the disease. Radiography of the sinuses will show opacity of those involved with destruction of the bony walls (*Fig. 44*). Tomography of the maxillary sinus (*Fig. 45*) may give further information regarding this site and extension of the

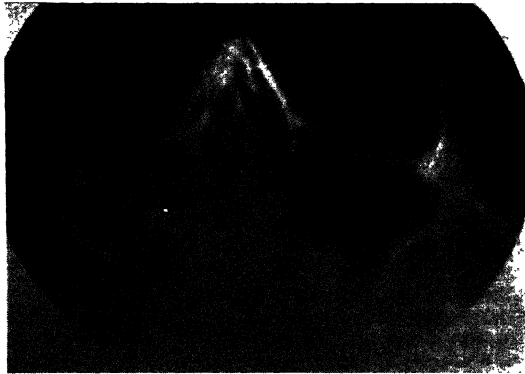


Fig. 44. Radiograph of carcinoma of the maxillary sinus with erosion of the medial wall.




Fig. 45. Tomogram showing carcinoma of the maxillary sinus.

tumour. Biopsy should be performed under general anaesthesia to allow a more thorough investigation of the site of the tumour and the extent of its spread.

While malignant disease of the sinuses usually occurs in those over the age of fifty, it must be remembered that children and young adults may also suffer, particularly from sarcoma.

TREATMENT. This is a distressing condition to treat because in general the tumour has advanced so considerably before advice is sought. Briefly, the patient should be given first a course of irradiation by the linear accelerator or the cobalt beam. The purpose of this is to reduce the bulk of the tumour, and if this is successful surgical excision of the growth may be attempted. There are two approaches: (i) a radical removal of the hard palate, the alveolus and the lateral nasal wall which affords an entry into the maxillo-ethmoidal area; and (ii) a lateral rhinotomy in which the incision starts below the inner end of the eyebrow and continues down the lateral side of the nose close to the cheek to the ala nasi. This offers a wide exposure for resection of the maxilla and the ethmoidal cells. In either case a prosthesis will ultimately be required. If the cervical glands are involved they are resected in the usual way. In the majority of cases enucleation of the eye will be necessary.

Considerable experience is required to select cases for radical surgery. Many are too far advanced when first seen, and their lot may be made worse by surgery if there is extension of the tumour into the nasopharynx or the base of the skull, or if there is gross involvement of the cervical lymph nodes, or in those cases with distant metastases. Such patients should be treated by palliative irradiation and local excision of the growth in the nasal and buccal cavities.

Chemotherapy by cytotoxic drugs may be employed in these advanced cases. There are a number of such drugs available, and their action depends upon the vulnerability of tumour cells at the time of mitotic activity. Unfortunately, the drugs have a similar effect on normal tissue by suppression of the bone marrow so that therapy must be controlled by frequent blood counts. In sinus tumours intra-arterial infusions of methotrexate are used giving 50 mg in 24 hours through a plastic cannula which is introduced into the external carotid artery through the superior thyroid artery. Folinic acid may have to be injected intramuscularly in doses of 6 mg every 6 hours to combat the drop in the numbers of white blood cells and platelets. Recently some antibiotic drugs have been used, notably bleomycin, which may be injected intravenously or intramuscularly. It is claimed that better results are obtained if radiotherapy follows the administration of cytotoxic drugs.

PROGNOSIS. The outlook is grave in children and young adults and in the more lethal types of tumour in adults. It is better in tumours of low malignancy especially if these arise in the antero-inferior half of the maxillary sinus. Any spread to the nasopharynx or the base of the skull, or a gross involvement of the cervical glands denotes a poor prognosis. In general, and in the best hands, there is a 33 per cent survival rate 5 years after diagnosis of the tumour.

SECTION II

THE PHARYNX AND NASOPHARYNX

J. R. McCallum

CHAPTER 18

ANATOMY AND PHYSIOLOGY

The *pharynx* is a fibromuscular tube lined with epithelium. It extends from the base of the skull superiorly to the level of the sixth cervical vertebra where it becomes continuous with the oesophagus (*Fig. 46*). Anteriorly it communicates with the nasal cavities, the mouth and the larynx, and is thus divided anatomically into the nasopharynx, oropharynx and laryngopharynx (hypopharynx). The lining epithelium is of the stratified squamous type, except in the nasopharynx where columnar ciliated epithelium is found. There are numerous mucous glands. The middle fibrous tissue layer consists of the pharyngobasilar fascia. The outer muscular layer comprises chiefly the three constrictor muscles, superior, middle and inferior, which overlap from below upwards.

The Nasopharynx. At the junction of the roof and the posterior wall lies a small mass of lymphoid tissue called the pharyngeal tonsil or adenoids. There is a central mass of this tissue, and there are smaller accumulations of lymphoid tissue laterally around the pharyngeal openings of the auditory (Eustachian) tubes. These tubes connect the nasopharynx with the middle ear cavities, and are lined by columnar ciliated epithelium in continuity with that of the nasopharynx. Anteriorly the nasopharynx communicates with the nasal cavities through the posterior nares.

The Oropharynx. This part is usually referred to as the 'pharynx', and is the easiest part to examine when the patient opens his mouth. The free edge of the soft palate forms the palatine arch which separates the oral cavity from the pharynx. From its centre the uvula hangs downwards, and from the arch, on either side, run two folds of mucous membrane, raised up by bands of muscle fibres of the palatoglossus and palatopharyngeus muscles, to form the palatoglossal and palatopharyngeal arches, or anterior and posterior pillars of the fauces. The palatine tonsil lies between these folds.

The laryngopharynx (hypopharynx) is that part of the pharynx which extends from the base of the tongue to the upper end of the oesophagus. It is lined by mucosa, and is enclosed within the three constrictor muscles of the pharynx—superior, middle and inferior. The middle constrictor is attached to the hyoid bone which gives stability to the hypopharynx. Lymphoid tissue is

present on the base of the tongue, and is called the lingual tonsil. It lies in the vallecula, which is a recess between the tongue and the anterior surface of the epiglottis. The ary-epiglottic folds run from the epiglottis to the arytenoid cartilages and form the walls of the entrance to the larynx. On either lateral side of the ary-epiglottic folds is a recess, the pyriform fossa, which forms a channel for food during deglutition. The two pyriform fossae lead to the

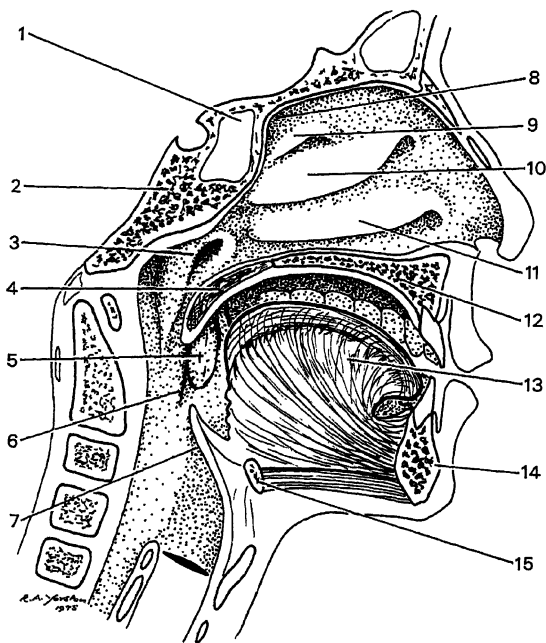


Fig. 46. Median section of head. 1, Sphenoid sinus; 2, Basisphenoid; 3, Orifice of Eustachian tube; 4, Soft palate; 5, Palatine tonsil; 6, Palatopharyngeal fold; 7, Epiglottis; 8, Spheno-ethmoidal recess; 9, Superior concha; 10, Middle concha; 11, Inferior concha; 12, Hard palate; 13, Tongue; 14, Mandible; 15, Hyoid bone.

opening of the upper end of the oesophagus which is situated behind the cricoid cartilage—the postcricoid region.

THE PALATINE TONSILS

The palatine tonsils, more commonly called the tonsils, are masses of lymphoid tissue lying between the faucial pillars. At birth they are of insignificant size, but they enlarge during early childhood, especially between the third and sixth years of age, probably in response to upper respiratory tract infections. Thereafter some regression in size is to be expected, and in old age they atrophy. Each tonsil is described as having an upper pole, a body and a lower pole. About a dozen pitted depressions may be seen on the surface of the body

ANATOMY AND PHYSIOLOGY

of the tonsil. These are the openings of the tonsillar crypts which extend into the substance of the tonsillar lymphoid tissue. The lateral surface of the tonsil is covered by a fibrous capsule, separating it from the pharyngeal aponeurosis, and providing a convenient plane of separation during the removal of the tonsil. The lower pole of the tonsil is extended on to the dorsum of the tongue, where it is called the lingual tonsil.

The arterial supply to the tonsil derives mainly from the tonsillar branch of the facial artery and the descending palatine artery. The veins drain into the pharyngeal plexus. Lymphatic drainage from the tonsil is into the upper deep cervical glands, which may enlarge during tonsillar infection. There is an intercommunicating ring of lymphoid tissue in the pharynx including the pharyngeal tonsils, the palatine tonsils, and the cervical and retropharyngeal glands, and this is called Waldeyer's ring.

PHYSIOLOGY OF THE TONSILS

There is considerable controversy regarding the importance of the role of the tonsils in the body's defence against disease. It is probable that upper respiratory organisms multiply in the tonsillar crypts and that the surrounding lymphoid tissue manufactures antibodies against these organisms. This might explain the 'physiological' enlargement of the tonsils that takes place in the 3-6 years age group when the child is exposed to frequent upper respiratory infections, against which he gradually builds up some immunity.

Apart from this function of the tonsils, the pharynx affords a channel for respiration and for swallowing.

CHAPTER 19

CLINICAL EXAMINATION

A good light is essential for a proper examination of the pharynx and nasopharynx. In hospital this is achieved by reflecting the light from a bull's eye lamp by a forehead mirror, or by the use of an electric headlamp worked off the mains. A similar headlamp powered by batteries may be used in the patient's home, but this has the same disadvantages as an electric torch—when the battery begins to fail the light is poor and an appreciation of colour changes diminishes. A constant source of light is important in examination when much depends on the recognition of changes in colour in the buccal and pharyngeal mucosa.

The patient should be encouraged to relax and breathe easily through his mouth. An angled metal tongue depressor is more useful than a wooden spatula because the view with this is obstructed by the examiner's fingers holding the spatula. The blade of the depressor is introduced centrally so that the tip reaches just beyond the highest part of the dorsum of the tongue. Gentle pressure downwards and forwards should depress the tongue to expose the pharynx (*Fig. 47*). If the instrument is placed too far forward the tongue arches posteriorly to obstruct the view, while if it is placed too far back the patient will gag. In some patients with irritable throats the depressor may be placed to one side of the midline and then the other, pressing the tongue towards the midline to expose each side of the pharynx in turn. Some patients will reject this, and many of these can display their throats adequately without any assistance. Should a thorough examination be essential in a patient who resents the depressor, the throat may first be sprayed with a 10 per cent solution of cocaine hydrochloride.

Examination should be systematic and thorough. The buccal mucosa, teeth and tongue should be inspected before examining the pharynx. Dentures should be removed because if they are loose the patient will not relax during the examination. The soft palate is next inspected for mobility and adequate closure of the nasopharynx during phonation. Any evidence of a midline cleft should be noted, whether it be a bifid uvula, a submucous cleft or a frank cleft palate.

The function of the soft palate is highly important, especially in children. The only speech sounds pronounced with an open nasopharynx are 'm', 'n' and 'ng'. For all other sounds the soft palate rises to close off the nasopharynx. Failure to do this results in hypernasality with escape of air through the nose during phonation. The classic example of this is the patient with a cleft palate, but it occurs to a lesser degree if the palate is insufficient, as in bifid uvula or submucous cleft, or if it is paralysed. The action of the soft palate may be demonstrated by a palatogram in which lateral radiographs are taken with the patient at rest, saying 'n', and saying 'ee' (*Fig. 48*).

The opposite effect, that of hyponasality, occurs due to nasal or nasopharyngeal obstruction, e.g. from nasal polypi, a naso-antral polypus, a nasopharyngeal tumour or very large adenoids.

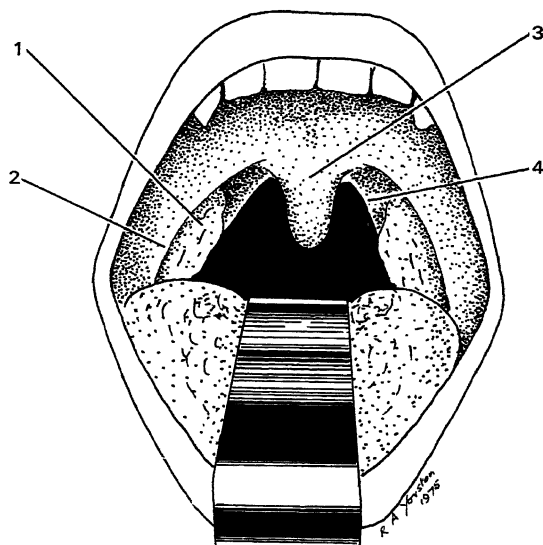


Fig. 47. Examination of the oropharynx. 1, Palatine tonsil; 2, Palatoglossal fold; 3, Uvula; 4, Palatopharyngeal fold.




Fig. 48. Palatograph taken with child saying 'ee' to show immobile palate incapable of closing nasopharynx. Adenoids had been removed twice for poor speech, converting hyporhinophonia to hyper-rhinophonia. Plastic surgery may now be required.

Attention is next turned to the tonsils. In the adult they may be concealed to a greater or lesser degree behind the palatoglossal arch (anterior pillar) in which event they are described as submerged or buried. Tonsils which project into the lumen of the pharynx are called pedunculated. The size of the tonsils is

noted, but size is not an indication of sepsis. The surface of the tonsils is examined to see whether the mouths of the crypts contain pus. In the adult the tonsil may be squeezed by the pressure of a spatula on the anterior pillar to see if pus or food particles are extruded from the crypts. Pus is fluid, but particles of food appear as solid yellowish pellets which have an unpleasant smell and taste, of which the patient often complains. The free edge of the anterior pillar is examined for a band of congestion in this area. The neck is then palpated for enlarged cervical lymph nodes. There are no absolute criteria of tonsillar sepsis on inspection, but the combination of palpable cervical glands, flushing along the free edge of the anterior pillar, and the presence of pus in the tonsillar crypts is generally agreed to denote sepsis in the tonsil.

Attention is then turned to the condition of the mucosa of the posterior pharyngeal wall. Dryness and glazing of the epithelium suggests an atrophic condition in the nose. Mucopus may be seen coming down from the nasopharynx to suggest sinus infection. Dilated blood vessels may be seen on the pharyngeal wall or on the surface of the tonsil. In some cases there is a roughness of the mucosa, or small submucosal swellings due to discrete lymphoid nodules. An appearance suggesting an abnormal gland may be suspected in thin, long-necked people if they are examined with the head slightly rotated to one side. This swelling is due to the prominence of a cervical vertebra.

EXAMINATION IN CHILDREN

Most children can be coaxed to open their mouths sufficiently to allow an adequate examination of the pharynx without the use of a depressor. Indeed, most children resent having a spatula inserted into their mouths, and it is wise not to use one except in the case of the child who clamps his mouth tightly. The young child will be sat on his mother's knee, and she should hold his hands. Mothers should not be encouraged to hold their child's head, because they usually over-restrain the child who becomes fractious. Children over the age of 4 years will usually sit by themselves provided that the mother is close by. The child will open his mouth, and the older one will say 'ah' which is sufficient to depress the tongue and expose the tonsils and pharynx. The younger child can generally be persuaded to put his tongue out, and this protrudes the anterior pillars so that the tonsils are swung into view. Difficulty is usually only experienced with frightened children. Those who howl will open their mouths sufficiently to allow an inspection. The child who clamps his jaws tightly must be examined with a tongue depressor which is of a suitably small size. It is inserted between the cheek and the teeth and the tip is turned medially behind the back teeth, and as this makes the child gag the pharynx is exposed, even if momentarily.

Examination of the nasopharynx (posterior rhinoscopy) has been described on p. 13.

CHAPTER 20

ACUTE INFLAMMATIONS OF THE PHARYNX

Acute pharyngitis is commonly met with, varying in severity from the transient sore throat which is often the precursor of a virus infection of the upper respiratory tract to a more severe septic pharyngitis.

SIMPLE PHARYNGITIS

This is the more frequent variety, occurring primarily during the winter months and less often in autumn or spring. It precedes the common cold, and may accompany influenza, measles, scarlet fever, typhoid fever or smallpox. While all are prone to this mild pharyngitis those with dental sepsis or nasal obstruction are thought to be more susceptible.

SYMPTOMS. The sore throat which ushers in the coryza begins with a feeling of chilliness, a slight pyrexia, headache, backache and joint pains. The throat feels dry, raw, uncomfortable or painful especially on swallowing. There may also be some hoarseness. These symptoms last for a day or two until the coryza, influenza or infectious fever becomes apparent.

CLINICAL FEATURES. On examining the throat there is an obvious redness, and sometimes swelling, of the mucosa of the soft palate, tonsils and posterior pharyngeal wall. The uvula shares in this and occasionally there is some haemorrhage into it. The cervical glands are palpable and tender. In children the mouth should be examined for Koplik's spots in case the pharyngitis is the precursor of measles.

TREATMENT. As a rule no treatment is required, but if advice is sought the patient should remain indoors and take a hot bath and aspirin 0.3–0.6 g before bed. There is no indication for prescribing antibiotics unless the pharyngitis proceeds to one of the fevers. Hot astringent gargles, such as hydrogen peroxide or ferric chloride, may be used three or four times daily. Lozenges, such as domiphen bromide (Bradosol), dequalinium chloride (Dequadin) or tyrothricin and benzocaine (Tyrozets), are often soothing if allowed to dissolve slowly under the tongue.

SEPTIC PHARYNGITIS

This is a more serious condition and is caused by the pyogenic organisms, haemolytic streptococcus, *Staphylococcus aureus*, pneumococcus and *H. influenzae*. It is more severe in those with lowered resistance from overwork, alcoholism, debilitating illnesses, etc.

SYMPTOMS. The onset is sudden and may be ushered in by a rigor. There is severe pain in the throat so that swallowing, even of fluids, is difficult.

Temperature is raised, the pulse rate is increased and there may be profuse sweating.

CLINICAL FEATURES. On examination there is a marked congestion and swelling of the pharyngeal mucosa and the uvula is oedematous. The cervical glands are enlarged and tender. The inflammatory oedema may spread to the larynx to give rise to hoarseness and later to airway obstruction if the condition is not treated. At other times infection may spread to the submandibular region where it causes a hard brawny cellulitis (Ludwig's angina). In some cases the infection may involve the lungs, the pleura or the pericardium.

TREATMENT. The patient should be confined to bed until convalescent. A throat swab is taken for sensitivity of the organisms, and until the results are available a wide-spectrum antibiotic, such as ampicillin, should be prescribed. This may be given intramuscularly until swallowing is easier, and a total daily dosage of 1-3 g should be administered to the adult in divided doses. When the patient is able to swallow the appropriate antibiotic is given in full dosage for at least 5 days. This must be insisted on because there is a tendency for the patient to discontinue treatment when the symptoms abate. Dehydration is frequently a problem and copious nutritious fluids should be ordered. If swallowing is impossible the patient should be hospitalized and given intravenous infusions.

If airway obstruction threatens, as evidenced by stridorous breathing, the patient should be treated in hospital where frequent pulse and respiratory rate readings and the results of blood gas analysis may suggest that tracheostomy is necessary. The onset of Ludwig's angina will also call for hospitalization in case incision and drainage should prove necessary. These two severe complications of septic pharyngitis are less common than formerly provided that antibiotic treatment is given vigorously and early in the disease, but they may occur in a patient living alone and unable to summon early medical advice.

ACUTE MEMBRANOUS PHARYNGITIS

Acute membranous pharyngitis or Vincent's angina is a highly infectious and ulcerative lesion of the tonsils. It was common during the first World War, being called trench mouth, and the frequency with which it occurred was probably due to lack of hygiene in the cleaning of eating and drinking utensils. It is now much less common. The infection is caused by two Gram-negative organisms, a fusiform bacillus and a spirochaete, which can be isolated together from the ulcers. Vincent's infection may contaminate malignant lesions of the mouth and pharynx.

SYMPTOMS. The patient has a low pyrexia and complains of a sore throat. The cervical glands may be enlarged. Constitutional symptoms are slight.

CLINICAL FEATURES. Usually only one tonsil is involved, but the membrane may often spread on to the gums and the soft and hard palate. The typical lesion presents as a greyish slough (*Plate V, 1*) which bleeds easily when it is removed to reveal a deep ulceration of the tonsil. The membrane re-forms after removal. There is a characteristic smell from the breath. The infection may persist for several weeks if untreated, but should clear up in a week with appropriate therapy.

DIAGNOSIS. A swab from the affected area will show the causative organisms. Differentiation is from other diseases which produce a membrane—diphtheria

and especially nowadays glandular fever. Tertiary syphilis may closely simulate the ulceration of Vincent's angina, and the fact that the two conditions may coexist means that serological tests may be inconclusive.

TREATMENT. The condition responds readily to systemic antibiotics such as penicillin and erythromycin, and to metronidazole (Flagyl) tablets, giving 200 mg thrice daily. Apart from this, warm gargles of sodium bicarbonate solution will help to remove the membrane. The patient and his relatives must be warned about the infectious nature of the disease. The patient should be confined to his room, and his dishes must be thoroughly cleaned.

DIPHTHERIA

Because of the success of inoculation there is now almost no part of the Western world where the diphtheria bacillus exists as a virulent strain. If it is isolated on a throat swab it will be so avirulent that it will respond to penicillin therapy. The attenuated strain will not cause membrane formation which characterizes the typical infection.

Unfortunately some of the developing countries do not have a successful programme of inoculation, and in these the disease is still found. It affects those in the first 10 years of life, particularly in the 2-3 years age group. Incubation takes 2-7 days and the onset is insidious with a temperature of some 39.5 °C. The disease is characterized by the appearance of a false membrane on the tonsils, soft palate and posterior pharyngeal wall (*Plate V, 2*). The colour of the membrane is usually grey, but it may be white, yellow or dark brown. It is firmly attached to the mucosa, and leaves a bleeding surface when it is removed, after which it quickly re-forms. The cervical glands are enlarged, often markedly so, and tender. The disease may affect the nasal cavities and nasopharynx to produce a foetid and bloodstained discharge. Diphtheria may spread to involve the larynx and trachea where membrane formation imperils the airway.

When the disease is suspected a throat swab is taken and treatment is started without delay. A dose of antitoxin, 10 000 units in a mild case and up to 80 000 units in a severe one, is given. The *Corynebacterium diphtheriae* is sensitive to antibiotics, particularly penicillin and erythromycin, and one of these should be ordered together with the antitoxin to prevent complications.

ULCERS OF THE MOUTH AND PHARYNX

The epithelium of the mouth and pharynx may be involved in a number of conditions which produce ulceration. Vincent's angina has already been described, and the chronic ulcerations will be discussed in Chapter 23. Leucoplakia is described on 115p. .

Streptococcus viridans produces characteristic small shallow ulcers with a yellow centre distributed on the soft palate and palatoglossal arches. Each ulcer resembles the effect of a scratch with a finger-nail. They respond to antiseptic gargles such as hexetidine (Oraldene). Shallow ulcerations may be found with pneumococcal and streptococcal infections, and are treated by systemic penicillin.

Aphthous ulcers are not associated with acute infection, and appear for no obvious reason. They take the form of small, shallow ulcers with a clean base and surrounding erythema, and may be found anywhere on the buccal mucosa, the pharyngeal mucosa and the tongue. They give rise to considerable pain. There is no specific treatment. Some help has been obtained by the treatment of any deficiency shown by a full blood examination—especially if there is reduced vitamin B₁₂ or folic acid. Dental treatment to obviate rough edges of teeth may be required. Triamcinolone (Adcortyl) may be prescribed for its antibacterial and anti-immunosuppressive actions, or hydrocortisone may be applied locally as small pellets (Corlan). The local use of a salicylate gel (Bonjela) may be soothing. There are reports of success from the use of tranquillizers as many patients are of the highly emotional type.

Behçet's Syndrome. This is most commonly found in eastern Mediterranean countries. The cause is unknown, but it may be due to virus infection or it may be an auto-immune response. The syndrome consists of ulcerations below the tongue or on the buccal mucosa accompanied by ulceration of the genitals. There are various ocular lesions, such as episcleritis, iridocyclitis and corneal ulceration. Steroid therapy combined with a wide-spectrum antibiotic is the most frequent treatment. Folic acid in doses of 5–20 mg daily may be useful.

Virus infections show lesions in the mouth and pharynx. *Measles* may be diagnosed before the rash appears by the presence of white Koplik's spots on the buccal mucosa. *Chicken pox* may produce herpetiform lesions in the mouth. *Herpes* may rarely be met with in the throat when groups of small vesicles appear on the soft palate accompanying herpes zoster oticus or ophthalmic herpes. The palatal ulcers cause considerable discomfort and are usually confined to a specific nerve distribution. The virus concerned is Coxsackie A.

Skin conditions may be accompanied by lesions of the buccal or pharyngeal mucosa. *Lichen planus* appears as white papules on the buccal mucosa, and these may coalesce to form larger symmetrical milky reticulate patches which do not give rise to pain, but do cause some discomfort. Treatment is symptomatic by frequent gargles and aureomycin mouth washes, or even Corlan pellets or triamcinolone paste. *Pemphigus vulgaris* is a much more serious disease which affects the middle age group, and it may be fulminating and fatal. Large bullae containing haemorrhagic fluid may appear in the mouth and on the pharyngeal mucosa, and these leave shallow ulcers when they rupture. The diagnosis is confirmed by biopsy. The condition is treated by the corticosteroids or prednisolone in the usual dosage. *Pemphigoid* lesions may be found in the mouth of older patients, especially women. They begin as bullae which break down to cause wide ulceration. Topical steroid therapy is helpful. *Erythema multiforme* may affect the mouth in its serious form (Stevens-Johnson syndrome). The condition may be drug-induced or it may be a reaction to sepsis in the nose or throat. Large bullae form in the mouth, but they usually respond to the corticosteroids in large doses. Any other drugs which are being taken should be withheld. *Polydysplastic epidermolysis bullosa* is a rare, sometimes fatal, hereditary disease of infancy in which haemorrhagic bullae may appear on the skin and on mucosal surfaces giving rise to some degree of scarring in the pharynx. There is no specific treatment.

ACUTE PHARYNGITIS IN BLOOD DISORDERS

Infectious mononucleosis (glandular fever) is a systemic virus infection of unknown aetiology. It is thought to be due to a virus, and is spread by direct contact with the mouth, such as kissing. It is a disease of young adults and is characterized by an increase in the large mononuclear cells of the blood.

SYMPTOMS. In the prodromal period which lasts from 4 to 14 days there is anorexia, malaise, a low-grade fever and a sore throat of varying severity.

CLINICAL FEATURES. The pharynx is very congested and there may be superficial ulcers, especially on the tonsils. Crops of red spots may appear on the palate and last for several days. A transient maculopapular rash is often found. There is enlargement of the cervical lymph nodes, and the post-auricular, suboccipital, axillary and inguinal glands may also be affected. This adenopathy may persist for several months. In about half of the cases there is a moderate enlargement of the spleen. The acute febrile symptoms may persist for several weeks, and relapses are common.

DIAGNOSIS. The diagnosis is confirmed by finding atypical large mononuclear cells in a blood film. A blood count will usually show a leucocytosis of $10\cdot0\text{--}20\cdot0 \times 10^9/\text{l}$. Serum agglutinin tests (Paul-Bunnell) should be done, but the results are not invariably positive. In over half of the cases liver function tests will show some rise in the serum glutamic pyruvate transaminase level.

TREATMENT. There is no specific treatment apart from the usual remedies such as soluble aspirin to lower the pyrexia. Antibiotics play no part in treatment, and ampicillin should never be used as it will cause a toxic skin reaction if given during any phase of infectious mononucleosis. Corticosteroids should be reserved for the severe case in which they give good results.

COMPLICATIONS. These are few but occasionally a peripheral neuropathy may occur. Many patients remain depressed and devitalized for several months, and during this time the adenopathy, the abnormal blood picture and a positive serological reaction may be found.

Agranulocytic angina is characterized by a reduction of the neutrophil polymorphs in the blood, and may be associated with pharyngeal ulceration. The cause is a depression of white cell formation in the bone marrow, and is often drug induced. The treatment is that of the blood dyscrasia.

Acute leukaemia may also be associated with necrotic ulceration in the pharynx (Plate V, 3). Purpuric haemorrhages and a typical leucocytosis of $20\cdot0\text{--}100\cdot0 \times 10^9/\text{l}$ will confirm the diagnosis.

Hodgkin's disease may occur in the lymphoid tissue of the pharynx and nasopharynx. There may be a unilateral enlargement and ulceration of a tonsil which is a dark purplish colour. The cervical lymph nodes show a characteristic enlargement.

FUNGOUS INFECTIONS IN THE THROAT

The most frequently found fungus in the throat is that which produces *moniliasis* or *thrush*. It is found in marasmic infants or poorly nourished children, but it may occur in older patients suffering from a debilitating illness. Creamy-white plaques are found on the tongue and on the buccal and pharyngeal mucosa. These are easily removed with slight bleeding. The treatment is by painting the lesions with 1 per cent aqueous solution of

THE PHARYNX AND NASOPHARYNX

gentian violet after each feed. The condition may be treated by systemic nystatin given orally in doses of 100 000 units four times daily for a week, or amphotericin (Fungilin) lozenges 10 mg four times daily.

Candida albicans may be caused by the long-term use of antibiotics, and produces white spots on the tonsils or the posterior pharyngeal wall. The treatment is that for thrush.

Blastomycosis produces shallow granulating ulcers, and it responds to a slow intravenous infusion of amphotericin (Fungizone). There is a danger of renal damage if the infusion is not slow. Local lozenges of the same drug (Fungilin) may be allowed to dissolve slowly in the mouth, and have a local effect on the lesion.

Actinomycosis gives rise to characteristic sulphur granules in the pus of deep ulcers, and may be treated by a prolonged course of penicillin.



CHAPTER 21

ABSCESSSES OF THE PHARYNX

ACUTE RETROPHARYNGEAL ABSCESS

The prevertebral fascia stretching across the midline separates the visceral compartment of the pharynx and neck from the prevertebral muscles and cervical vertebrae. Between the pharynx and the prevertebral muscles, on either side of the midline, is a potential space, the space of Gillette, which contains the retropharyngeal lymph glands. These glands are present in infancy but gradually disappear as the child gets older. Infection of the deep cervical glands may readily pass to the retropharyngeal group to give rise to abscess formation (*Plate VI, 1*). The most frequent cause is the haemolytic streptococcus. The acute abscess occurs only in infants under 1 year.

SYMPTOMS. The infant is irritable and may refuse feeds while the abscess is developing. At this stage localizing signs are few. When the abscess has developed there is pyrexia and the infant is obviously in considerable pain. Because of the proximity of the abscess to the cervical vertebrae any movement of the head causes agony, and the baby lies with the head stiff and often extended, sometimes in opisthotonos. Any extension downwards of the abscess impairs the airway so that there is stridor and a muffled cry and croupy cough.

CLINICAL FEATURES. The swelling of the posterior pharyngeal wall, to one side of the midline, is apparent on inspection. Should there be a downwards extension there will be inspiratory stridor and suprasternal indrawing. Palpation may demonstrate fluctuation, and lateral radiography will show the size and extent of the abscess in the prevertebral region.

TREATMENT. The abscess is not usually seen until it has fully developed, and at this stage the only treatment is incision and drainage. General anaesthetic is dangerous because of the impaired airway. The infant is wrapped in a binder and held upright by a nurse. The abscess is opened with sinus forceps which are plunged into the swelling closed and then opened to release a copious flow of pus which is under considerable tension. The baby is turned upside down to allow the pus to escape. This results in an immediate cure. Feeding becomes easy, the temperature drops and movement of the head is once again possible. Antibiotics are not usually necessary.

CHRONIC RETROPHARYNGEAL ABSCESS

The chronic abscess is secondary to tuberculous involvement of the cervical spine, the deep cervical glands or the middle ear cavity. It occurs in the older child or young adult. It is of slow onset and gives rise to pharyngeal discomfort, rather than pain, and to some degree of dysphagia. The lesion in the cervical spine will be seen on radiography, and the tuberculous cervical glands

THE PHARYNX AND NASOPHARYNX

may be diagnosed on palpation. The ipsilateral ear must be examined for evidence of tuberculosis. The abscess is opened through an incision over the posterior border of the sternomastoid muscle, and the abscess is sought for by dissection between the carotid sheath and the prevertebral muscles, and is drained from the neck. Full antituberculous therapy must be ordered.

PARAPHARYNGEAL ABSCESS

This is an uncommon condition, usually arising after removal of the tonsils when there has been a tear of the pharyngeal wall, but it may accompany a severe tonsillar infection. There is a rapid spread of infection into the mediastinum along the tissue planes, and air in the parapharyngeal tissues produces surgical emphysema of the neck. Trismus makes inspection difficult, and the abscess may be mistaken for a quinsy. Treatment is by free incision either through the pharynx or through the neck if a course of antibiotics does not improve the condition. Tracheostomy may be necessary on account of an extension involving the larynx.

CHAPTER 22

CHRONIC PHARYNGITIS

This is a most common condition and follows repeated attacks of acute pharyngitis, over-indulgence in smoking, the use of raw spirits or an addiction to highly seasoned foods. It may be caused by excessive or faulty use of the voice, dental sepsis or prolonged exposure to dusty atmospheres. Chronic infection of the nose or sinuses may predispose to it. Exacerbations tend to occur after a period of increased work or worry.

For clinical purposes it may be discussed under three headings: (i) simple catarrhal pharyngitis; (ii) hypertrophic pharyngitis (granular pharyngitis); (iii) atrophic pharyngitis.

SIMPLE CATARRHAL PHARYNGITIS

This is the most common variety and is due to over-smoking, exposure to dust or errors of diet. There is some oedema and congestion of the uvula, the soft palate and the posterior pharyngeal wall on the surface of which dilated veins may be seen. It produces a feeling of thickness in the throat and a frequent desire to clear the throat. Treatment consists in avoidance of the cause—correction of the diet, abstinence from alcohol and tobacco—or a drastic reduction of consumption—and avoidance of dusty atmospheres. Locally an astringent paint, such as Mandl's paint, or an astringent gargle, such as hydrogen peroxide or ferric chloride, may be used.

HYPERTROPHIC PHARYNGITIS

This form is met with in those who have to use their voices professionally, usually those who have not had training in voice production. The symptoms are exaggerated when the patient is tense, overworked or worried. There is a constant desire to clear the throat, and a feeling as if a foreign body were present, but the chief complaint is that the voice soon becomes tired and its carrying power is diminished. Most cases exhibit great irritability of the throat and the mere opening of the mouth may induce the patient to gag and retch. Small nodules of lymphoid tissue are seen scattered over the posterior pharyngeal wall—hence the term granular pharyngitis. A thick vertical band of lymphoid tissue may be seen on the lateral walls of the pharynx behind the posterior pillars of the fauces.

TREATMENT. Treatment is by no means easy owing to the difficulty in determining how far the symptoms are due to the objective changes seen in the pharynx. A search should be made for any underlying factor in the teeth, tonsils, sinuses or larynx. In a number of cases faulty voice production may be the chief cause. Pitching the voice too high or incorrect breathing are common

mistakes, and in these cases corrective measures, such as slower delivery allowing for adequate pauses for inspiration, and the pitching of the voice in a lower key should be advised. It may be necessary for the patient to consult a teacher of voice production. Granules may be destroyed by 25 per cent silver nitrate on a fine wool-tipped probe under local anaesthetic by spraying with cocaine hydrochloride. The use of an electric cautery or a diathermy for this purpose calls for general anaesthesia. Local gargles of hydrogen peroxide or ferric chloride and local painting with Mandl's paint are of secondary use.

ATROPHIC PHARYNGITIS

This accompanies atrophic rhinitis. The main complaint is of dryness in the throat, and the posterior pharyngeal wall is glazed and covered with a little dry secretion. The nose must always be examined for evidence of atrophy. Treatment is largely that of the nasal condition, but crusting in the pharynx may be removed by local spraying with a warm alkaline solution, or an oily spray such as parolein.

KERATOSIS OF THE PHARYNX

This is an uncommon condition found in either sex usually between the ages of 15 and 30. It is due to a horny outgrowth from the crypts of the tonsils and is composed of keratinized epithelial cells which are arranged in concentric layers within the tonsillar crypts. The cause is unknown, but is thought to be a metaplasia. On examination, white or yellow excrescences are seen projecting from the crypts. There is no evidence of infection, and the horny growths cannot be wiped off (*Plate VI, 2*). Occasionally they may be seen on the posterior pharyngeal wall, and they have been described in the larynx. As a rule there are no symptoms, but they may cause some irritation in the throat. Generally the growths are found accidentally by the patient on looking into his throat. The condition is harmless and no treatment is required beyond reassurance that the condition is not malignant. Spontaneous disappearance of the excrescences often occurs. Should the patient insist on treatment, removal of the tonsils is indicated.

CHAPTER 23

SPECIFIC INFECTIONS OF THE PHARYNX

SYPHILIS OF THE PHARYNX

Primary syphilis is uncommon, but the tonsil is second to the lip as the most frequent extragenital site. The chancre is unilateral, persists for several weeks and is accompanied by enlarged cervical glands. Palpation by a gloved finger will disclose that the lesion is of cartilaginous hardness. The discovery of *Sp. pallida* may confirm the diagnosis.

Secondary syphilis in the pharynx is much more common and much more important in that it is most contagious because the lesion teems with spirochaetes. Initially there is congestion of the palate and fauces, and some tonsillar enlargement, but soon the mucous patch develops. This may be found on any part of the mucosa of the mouth or pharynx, the principal sites being, in order of frequency, the tonsil, the palatine arches, the tongue and the inner aspect of the lips. The patch is round or oval, bluish-grey in colour with a surrounding zone of congestion. The patches may be multiple and symmetrical, and may become confluent. Ulceration takes place, leaving a snail-track ulcer of a dirty grey colour. The cervical glands are enlarged, and there may be a skin eruption.

Tertiary syphilis does not appear as a gumma for some years after the initial infection. A hard purplish swelling appears on the palate, posterior pharyngeal wall, or, less often, on the tonsil. It may appear in the vallecula between the epiglottis and the tongue, and so be overlooked unless a laryngeal mirror has been employed in routine examination. The gumma breaks down at its centre to form a punched out ulcer with a greenish-yellow base and red, indurated edges.

Postsyphilitic complications are much less often seen now. They were prone to follow hereditary syphilis when they appeared about the age of puberty. The palate may perforate with destruction of tissue or there may be considerable cicatricial stenosis of the pharynx.

SYMPTOMS. The chancre may not cause any symptoms. Secondary lesions cause only slight pain in the throat, although some dysphagia may be felt when ulceration takes place. Pain is rare in the tertiary lesions, and the patient may only complain of a nasal speech or of food entering the nose while eating.

DIAGNOSIS. This must be made from other lesions causing ulceration or membrane formation. The primary and secondary stages are usually recognized, but the gumma may be confused with Vincent's infection or with carcinoma. Serological tests and a biopsy will generally decide the question. Lupus also causes destruction of the pharyngeal mucosa, but is more slow and is associated with skin nodules.

TREATMENT. Treatment is that of syphilis, and should be undertaken by a venereologist. Local hygiene is necessary and the highly contagious nature of the mucous patches must be explained to the patient.

TUBERCULOSIS OF THE PHARYNX

Acute miliary tuberculosis is the most common variety found in the pharynx, but is a rare complication of the pulmonary lesion. It is characterized by minute grey or yellow tubercles on the fauces or palate. These rapidly break down into shallow ulcers which spread widely in the mouth and pharynx to cause pain on swallowing, excess salivation, a throaty voice and rapid emaciation. The diagnosis must be made from syphilis, in which pain is absent, and from diphtheria, which is excluded by a throat swab and by a biopsy from the edge of the ulcer. Treatment is by antituberculous therapy with streptomycin, PAS and isoniazid. The prognosis is improving, but the miliary nature of the condition calls for a guarded outlook.

LUPUS OF THE PHARYNX

Lupus rarely attacks the pharynx, but when it does it produces minute pinkish-yellow nodules which resemble the apple-jelly nodes on the skin, which is also affected. The nodules cause some discomfort, but even when they break down, ulcerate and then heal with radiating scars there is little pain (*Plate VI, 3*). Treatment is largely that for tuberculosis, but calciferol may be prescribed with due care to guard against renal damage.

SCLEROMA AND LEPROSY

Scleroma is rarely seen in this country in the pharynx. It is fairly common in Eastern Europe and in Asia. The nose is more often affected than the pharynx. It forms painless hard infiltrations which on section show hyaline bodies and Mikulicz cells. The diplobacillus may be obtained from the lesions. There is no specific treatment.

Leprosy is also uncommon in this country. Leprosy of the pharynx is secondary to cutaneous leprosy, and gives rise to painless nodules which contract to leave pale cicatrices involving the palate, uvula and faucial pillars. The condition is diagnosed by recovering the bacilli from the nasal discharge, and by biopsy of the nodules. Treatment is by sulphone which must be continued for years.

SUBMUCOSAL FIBROSIS

This is an uncommon and recently described disease affecting young Indians. It has been ascribed to the chewing of betel nuts or tobacco, to deficiency in vitamin A or B and to a deficient iron metabolism. Vesicular eruptions occur on the palate and the faucial pillars, and these lead to submucosal fibrosis with trismus. Treatment with the steroids may help in early cases, but not once fibrosis has occurred.

SPECIFIC INFECTIONS OF THE PHARYNX

AFFECTIONS OF THE TONGUE

Three conditions of the tongue may be briefly mentioned. *Macroglossia* is a congenital enlargement of the tongue resulting in it being bitten by the child's teeth with a rawness of its edges. No treatment is required unless there is considerable overgrowth when surgical trimming may be needed. *Geographical tongue* is a condition of unknown aetiology in which the dorsum displays convoluted patterns. No treatment is necessary, and the condition may resolve spontaneously. *Black hairy tongue* is also of unknown aetiology. Hypertrophy of the filiform papillae is unsightly and causes distress to the patient, but it requires no treatment except reassurance.

CHAPTER 24

MISCELLANEOUS PHARYNGEAL DISORDERS

CONGENITAL ABNORMALITIES

Congenital abnormalities of the uvula and palate are the most common anomalies found. Bifid uvula is perhaps the most frequent disorder. The uvula may be split at its tip or may be cleft in its whole length. A further extension of this is the submucous cleft of the palate, and the ultimate deformity is a complete cleft of the palate. A bifid uvula is of no significance, except that it should warn the surgeon of the possibility of a coexisting submucosal cleft of the palate. This results in insufficient closure of the nasopharynx during phonation with hyperrhinophonia. Should removal of adenoids be required in a child with a bifid uvula it would be wise to test the efficiency of the soft palate in closing the nasopharynx. If the palate is insufficient, a modified adenoid removal should be performed (p. 134).

Congenital abnormalities of the palatine arches are rarely seen and are usually associated with abnormalities or absence of one or both tonsils. When the tonsil is congenitally absent the space between the palatine pillars contains a few nodules of lymphoid tissue. A congenital perforation of the palatoglossal arch may be found, but is of no significance. A congenitally short soft palate is sometimes found without any cleft. Such children have an increased distance between the ear and the point of the chin, and show nasal escape on speech due to lack of closure of the nasopharynx. This must be discovered before any operation on the adenoids is contemplated, because this merely aggravates the difficulty in phonation. Some form of plastic closure of the nasopharynx may be required.

CYSTS OF THE PHARYNX

Thyroglossal cyst arises from the thyroglossal duct which extends from the foramen caecum on the dorsum of the tongue to the thyroid gland. A cyst may occur anywhere along this duct, but is most common in the neck, where it forms a midline swelling. It rarely presents as a *fistula* in the midline at the level of the cricoid cartilage, and from the fistula a leakage of mucus may occur. The treatment is surgical excision.

Branchial cyst arises from persistence of the first or second branchial arch. It is usually found in childhood as a swelling postero-inferior to the angle of the mandible, partially covered by the sternomastoid muscle. It is removed surgically. A *branchial fistula* is rare and opens by a slit-like aperture either below the angle of the mandible or on the anterior border of the sternomastoid muscle, often near its lower end. It has a long track reaching up

towards the external acoustic meatus, and in relation to the facial nerve, which makes surgery difficult.

Ranula is a retention cyst and is found in the floor of the mouth. It causes a feeling of fullness. If it arises in association with a mucous gland, simple incision may cure it, but if it is associated with a salivary gland the cyst must be excised.

FOREIGN BODIES

Foreign bodies frequently lodge in the pharynx, and are most often found in the tonsil, the lingual tonsil at the base of the tongue or the palatine arches. Fish bones are the usual objects to stick in the throat, but toothbrush bristles may be seen. The foreign body causes pain and pricking, especially on swallowing. These symptoms are not diagnostic of the object being still present, because the scratching of the foreign body and the efforts to get rid of it by the finger aggravate the symptoms even if they move the intruder. Foreign bodies are not always easy to see on examination. A good light is essential. If the bone projects from the tonsil or other part of the pharynx, it may easily be seen, but if it lies flat on the surface of the tonsil, recognition is less easy. Examination is made more difficult by the outpouring of saliva, and an injection of atropine sulphate may be necessary to dry up the mouth. Removal is fairly easy in a co-operative patient once the object is sighted, but if the patient will not sit still, or if the foreign body cannot readily be identified, a general anaesthetic may be required, and inspection and palpation may have to be employed. The most difficult cases are those in which the object sticks at the base of the tongue, because it can only be removed in the outpatient department in a co-operative patient who will hold out the tongue while the surgeon searches for the object with a laryngeal mirror and removes it with a suitable pair of forceps.

HAEMORRHAGE FROM THE PHARYNX

Although patients often seek advice because of spitting up blood which they insist comes from the throat, true haemorrhage from the pharynx is uncommon. A search must be made in the throat for bleeding points, or for any lesion, such as a malignant ulcer. The nose, nasopharynx and larynx must also be examined, and the chest radiographed in the search for the cause. The treatment is that of the cause, and if it is found to be a bleeding point in the pharynx, this should be cauterized under local anaesthesia.

HYPERTROPHY OF THE LINGUAL TONSIL

The lingual tonsil is a mass of lymphoid tissue normally found on the dorsum of the tongue between the vallate papillae in front and the epiglottis behind. Hypertrophy may occur after tonsillectomy, or it may be found in women at the menopause. If the swelling is large it causes the feeling of a lump in the throat. Acute inflammation, or even abscess formation, may occur in the lingual tonsil, and is seen with the help of a laryngeal mirror. Acute infections are treated in the usual manner with antibiotics. Chronic enlargement may be

helped by astringent gargles or paints. Removal of the hypertrophied tissue may be necessary.

SENSORY NEUROSES

Anaesthesia may be found in diseases of the central nervous system, such as syringomyelia, bulbar paralysis and intracranial tumours. There is usually an associated paralysis of the soft palate.

Hyperaesthesia is a common condition, especially in those who over-indulge in tobacco or alcohol, and it is usually associated with a pharyngitis. Examination of the pharynx produces violent gagging and choking fits.

Paraesthesia is often met with in women at the menopause. The complaint is of a feeling of a lump behind the tongue, and a constant desire to clear the throat. There is no true dysphagia. A careful examination must be made to exclude any malignancy or other organic disease. Enlargement of the lingual tonsil is not uncommonly found. Treatment is symptomatic, and the use of an astringent gargle or paint, reinforced by a dogmatic assurance that there is no malignancy, is usually sufficient. Spontaneous cure often results.

Secretory neurosis is the name which might be applied to those patients who have a constant desire to expectorate. The sputum is usually frothy, with little mucus content, and is produced by the action of clearing the throat. The patient should be assured that there is no disease, and advised to refrain from the clearing and spitting.

NEURALGIA OF THE PHARYNX

Glossopharyngeal neuralgia is uncommon. Severe shooting pain radiates from the tonsillar region to the ear. It may be stimulated by swallowing or may occur after tonsillectomy. If relief is not obtained by carbamazepine neurosurgical destruction of the nerve may be required.

MOTOR NEUROSES

Rhythmic movement of the soft palate is a rare condition. The movements may be accompanied by a clicking sound which can be heard by both patient and doctor. In some cases this condition is associated with trigeminal neuralgia. There is no specific treatment.

Paralysis of the soft palate used to be seen after diphtheria and poliomyelitis, and occasionally after influenza. Diseases of the central nervous system such as syringomyelia, embolism, tumours and meningitis may produce a palatal paralysis along with other manifestations of the diseases. The paralysis is usually unilateral but may be bilateral. When unilateral the palate is drawn to the healthy side on phonation, but when bilateral the palate hangs loosely and does not respond to stimulation. The voice has a nasal quality, and fluid or food may escape into the nose.

CHAPTER 25

TUMOURS OF THE PHARYNX AND TONGUE

NON-MALIGNANT TUMOURS

Simple tumours are not commonly seen in the pharynx. *Papillomata* may be found attached to the uvula, the tonsil, the margins of the soft palate or the palatine arches. They are pedunculated. *Fibromata* are less common. They also are pedunculated and may attain a larger size. *Angiomata*, which may be cavernous or capillary in type, are often associated with larger angiomata of the face and neck.

SYMPTOMS. Simple tumours do not usually give rise to symptoms, and may be noticed by the patient or by the doctor during routine inspection. Should the tumour be large it will cause a feeling of a lump in the throat and may cause some dysphagia.

TREATMENT. It is probably always wise to remove the tumour however simple it may appear clinically in order to avoid overlooking an early malignant growth. The tumours should always be examined histologically. Pedunculated tumours are easily removed with scissors, but small sessile growths may require destruction with diathermy. Angiomata are less easily dealt with.

PRE-MALIGNANT TUMOURS

Leucoplakia may appear as a white patch on the tongue or the buccal mucosa where it may be mistaken for lichen planus. It is thought to follow heavy pipe or cigar smoking or the irritation of carious teeth, and it is regarded as potentially malignant. Biopsy should always be performed especially if the patch loses its whiteness to become red and velvety. Dental hygiene should have attention and smoking should be forbidden. The patch may be removed by stripping or it may require excision or cauterization. The patient must be followed up regularly. A speckled leucoplakia or an erythroplakia is very liable to malignant change.

Parapharyngeal tumours, such as neurilemma, chemodectoma, reticulosarcoma and fibrosarcoma, may lie lateral to the walls of the pharynx which are bulged inwards by the tumour. The symptoms are of a feeling of fullness in the mouth, a swelling of the neck, muffling of the voice if the soft palate is involved and pain which radiates to the ear or along the lower jaw. The diagnosis is confirmed by biopsy, and treatment is by radiotherapy combined with surgical excision where this is possible.

MALIGNANT TUMOURS

Tumours of the Tongue and Mouth. The tongue must be examined routinely in every patient with a complaint of a swelling in the throat or the neck, and to

do so the tongue should be protruded to its full extent and moved to either side. Impaired mobility may be due simply to tongue tie, but it may be caused by a tumour within the muscle of the tongue. Right and left movements of the tongue may disclose ulceration of its lateral borders or an early tumour arising at the junction of the palatoglossal fold and the tongue. The dorsum of the tongue and the base of the tongue are examined with the aid of a laryngeal mirror (p. 150).

Carcinoma may affect any part of the tongue. It may appear first as a submucosal swelling, or it may erupt through a patch of leucoplakia. It is not usually seen thus early, and patients generally do not present until there has been a breakdown to form an ulcer with hard everted edges. Palpation of any suspicious swelling or ulcer, using the gloved finger, will demonstrate the hardness of the growth. There is early involvement of the cervical lymph nodes, and the neck must be palpated systematically and routinely. Biopsy should be performed from every hard swelling or ulcer, being careful to take the specimen from the growing edge of the ulcer. Chest radiography and full blood examinations must be carried out in every case as they will exclude tuberculosis, syphilis and blood dyscrasias.

In general, malignant disease of the tongue and mouth occurs in those past middle age, and is more frequent in males. Squamous carcinoma, in various stages of differentiation, is the most common tumour.

Anterior Two-thirds of Tongue

Cancer in this region may be preceded by leucoplakia or by a papillomatous growth. The swelling ulcerates early and this gives rise to foetor and limitation of movement of the tongue. Bleeding may occur from the edges of the ulcer. Pain is a late feature. The cervical lymph nodes are involved at an early stage on account of the rich lymphatic supply, and enlarged glands must be sought for. At first, the node may feel firm and not fixed, but this changes shortly to the characteristic hard, fixed node. Cancer involving the tip of the tongue may cause enlargement of the submental glands.

Buccal Mucosa and Floor of the Mouth

This area may be involved primarily, often near the openings of the submandibular glands, or it may be affected by the spread of a tumour from the tongue or the alveolus.

Base of Tongue

Tumours in this region may be exophytic or ulcerative. They give rise to foetor and some dysphagia due either to the size of the growth or to the invasion of the muscles. There may be bleeding from the edge of an ulcerated lesion. As a rule the patient presents late, after cervical gland metastasis has occurred.

TREATMENT. Treatment is surgical or radiotherapeutic or a combination of both. Surgical treatment involves a wide resection of the tumour area. It may be possible to operate within the oral cavity on a small growth, but tumours in the base of the tongue may require a hemiglossectomy, or a translingual approach in which the tongue is split in the midline. Pharyngotomy may be required, and access is gained medially through the thyrohyoid membrane or laterally through the thyroid. The discovery of enlarged lymph nodes will call

for a dissection of the glands in the neck. On account of the mutilating nature of the surgery, many tumours, especially the less differentiated ones, are treated in the first instance by irradiation, surgery being reserved for recurrences. The cytotoxic drugs are of use in advanced cases.

Cancer of the Pharynx. Malignant disease in the pharynx is usually primary. Secondary deposits from a melanoma of the skin are rare. The average age of onset is about 60 years, but sarcoma may occur in children. Males are more often affected than females.

The tumour is nearly always a *carcinoma*, the most common type being a *squamous epithelioma*. The majority of these show little or no differentiation. Undifferentiated squamous epitheliomata are sometimes referred to as lympho-epithelioma or transitional-celled epithelioma. The less a tumour is differentiated the greater is its propensity for spread to the lymph nodes. A common site of origin of the carcinoma is the angle between the palatoglossal fold and the tongue. From here it spreads along the edge of the tongue and on to the floor of the mouth and the alveolus. In some cases it spreads upwards to invade the fauces and soft palate, while occasionally spread occurs downwards along the lateral wall of the pharynx. Exophytic tumours are less common than the ulcerative invasive type.

Sarcoma may occur in children, but is found in adults of any age. The tumour arises within the tonsil, and as the tumour grows the tonsil enlarges. The sarcoma may remain within the tonsillar capsule for some time, but once it erupts beyond it, spread is rapid.

SYMPTOMS. Pain is generally the first symptom, and is constant in position so that the patient may indicate the site with the tip of a finger. The pain is most marked on swallowing. There is foetor of the breath. In most cases the patient does not seek advice until there is a neck swelling from spread to a regional gland. If the tongue is involved there may be alteration of speech, and if the tongue becomes fixed there may be excessive salivation. Later, pain radiates to the ear, and there may be difficulty in opening the mouth.

CLINICAL FEATURES. Both in diagnosis and in the determination of the extent of the tumour, palpation is of greater value than inspection. The early induration may be detected by the gloved finger before the growth is readily visible. Palpation should never be omitted. Biopsy should be performed in all cases. A routine palpation of the neck must be made for lymph nodes (p. 243). On inspection the tumour may be seen either directly or with the help of a laryngeal mirror. Chest radiography and a full blood count should be carried out in every case, because the differential diagnosis lies between tumour and tuberculosis, syphilis or blood disorders. A sarcoma causing a painful swelling of one tonsil has frequently been mistaken for a quinsy, and many have been incised as a result of this misdiagnosis.

PROGNOSIS. This varies with the tumour histology, the length of the symptoms and the presence of enlarged lymph nodes. The more extensive the tumour, the worse the outlook; 30 per cent of carcinomata treated before gland involvement may be expected to survive 5 years, but this percentage drops to about 12 per cent if there are unilateral glands when the patient is first treated, and to less than 5 per cent should bilateral gland involvement be present. With sarcomata, the 5-year survival rate in patients with no glandular invasion is something over 65 per cent, but is only about 15 per cent with gland metastasis.

THE PHARYNX AND NASOPHARYNX

TREATMENT. The treatment is usually primarily irradiation, while cytotoxic drugs are used for advanced cases. Surgical removal involves a massive resection, often a hemiglossectomy, removal of part of the mandible and a block dissection of the neck glands, and is generally reserved for recurrences.

CHAPTER 26

AFFECTIONS OF THE TONSILS

ACUTE TONSILLITIS

Acute tonsillitis may affect any age group but it is most frequently found in children. Streptococci, staphylococci and *H. influenzae* are the most common organisms, either in pure growth or in combination, but pneumococci may also be cultured.

SYMPTOMS. The symptoms are those of acute pharyngitis but there is usually more constitutional disturbance, especially in the case of children. The onset is often sudden with the temperature rising to 40 °C. The tongue is furred and the breath is offensive. There is some trismus and a constant yet dreaded desire to swallow; dysphagia is considerable and pain radiates up to the ears. Constipation is common, and the urine is scanty and highly coloured. There are often abdominal pains due to a mesenteric adenitis.

CLINICAL FEATURES. In the early stages the tonsil is enlarged, red and swollen, while later the infection involves the crypts which fill with fibrin. This turns purulent within the follicles and necrotic areas appear. In this stage the tonsils are congested, swollen and studded with yellow beads of pus which at first appear in the mouths of the crypts (*Plate VI, 4*) but later coalesce. The cervical glands are enlarged and tender.

DIAGNOSIS. This is usually easy. A throat swab may be taken to isolate the organisms. If there is confluence of the infected material the condition may be mistaken for glandular fever, and a blood film and serological tests may be necessary. Scarlet fever presents with a similar throat appearance but there is a strawberry tongue in most cases. At times scarlet fever may not be diagnosed until the typical rash appears, but even then the rash may be a streptococcal one which does not desquamate. Skin eruptions due to sensitivity to antibiotics may confuse the picture.

TREATMENT. The patient should be sent to bed, and aspirin in a dose appropriate to the age of the patient may be given every 4 hours until the temperature falls. Antibiotics are usually prescribed, and they must be given in full doses because if they are discontinued too early a relapse may occur. The disadvantage of giving ampicillin in glandular fever has been mentioned, but it is most useful in a tonsillitis due to *H. influenzae*. Penicillin, tetracycline or erythromycin may be used. In mild attacks one may be justified in withholding antibiotics to allow the patient to develop his own resistance to the infecting organisms. The administration of fluids is important to prevent dehydration, and they are more acceptable than solid or semisolid food.

ABSCESSSES OF THE TONSILS

Peritonsillar Abscess (Quinsy). This consists of suppuration outside the tonsillar capsule, and is situated in the region of the upper pole and involves the soft palate. Infection begins in the intratonsillar fossa which lies between the upper pole and body of the tonsil, and from here it extends around the tonsil. A quinsy is usually unilateral and most frequently affects adult males. It may occur at any age, and is much more common in children than is thought. Many extremely fibrous and adherent tonsils are removed from quite young children who have never been suspected of having had a quinsy.

SYMPTOMS. A peritonsillar abscess follows a tonsillitis which appears to settle and then recurs severely on one side. The patient looks ill and his temperature rises to about 40 °C with a shivering attack or a rigor. There is acute pain in the throat radiating to the ear, and this makes swallowing so impossible that saliva dribbles from the mouth. The swelling in the throat imparts a thick, muffled tone to the voice.

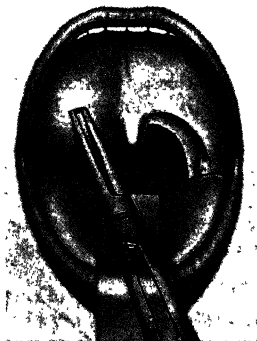


Fig. 49. Evacuation of peritonsillar abscess.

CLINICAL FEATURES. Examination may be difficult because the patient can only open his jaws to a slight extent, but with good illumination the affected side of the palate is seen to be congested and bulging (*Plate VI, 5*); the uvula is oedematous and pushed towards the opposite side; the affected tonsil is usually hidden by the swelling but may have some mucopus on its surface. The glands are enlarged and tender. If not relieved either by antibiotics or by surgery the abscess may burst or leak slowly in about a week.

TREATMENT. Systemic penicillin should be given in large doses whenever the diagnosis is made. Frank pus forms on about the fifth day, so that if the patient is not seen until then, or if penicillin fails to relieve the condition, the abscess must be opened. A long pair of sinus forceps is plunged into the most prominent part of the swelling and the abscess drained by opening the blades of the forceps (*Fig. 49*). The throat may first be sprayed with 10 per cent cocaine hydrochloride solution in the adult. This reduces the trismus which makes the operation easier, but it does not relieve the pain of incision, and the patient should be so warned. The immediate relief compensates for the agony. In children a short anaesthetic is given, a mouth gag inserted and opened and

the child turned on to the affected side. The abscess is opened as recovery from the anaesthetic takes place, and the child is turned face down and suction employed to evacuate the pus. The returning cough reflex will prevent aspiration of the pus. Rapid improvement follows but penicillin should be continued until resolution is complete. The tonsils should be removed 6-8 weeks following a quinsy.

Intratonsillar Abscess. This is uncommon and implies an abscess within the tonsil following retention of pus within a follicle to give pain and dysphagia. The tonsil is swollen and inflamed, but the soft palate does not bulge. It is treated on the same lines as a quinsy.

Lingual Tonsil Abscess. This is a rare condition causing extreme dysphagia and profound pain behind the tongue. It may give rise to laryngeal oedema. The abscess follows a lingual tonsillitis and is only seen with the aid of a laryngeal mirror. The abscess is treated as for a quinsy, but restricted access makes incision a matter of difficulty.

CHRONIC TONSILLITIS

Chronic Enlargement of the tonsils. The physiological enlargement of the tonsils in childhood between the ages of 3 and 6 years has already been described. It probably represents the development of active immunity when children begin to play with others and to attend nursery or primary schools. If this hypertrophy is unassociated with tonsillitis no action need be taken and swelling will settle down without constitutional upset.

Chronic inflammatory enlargement may follow acute tonsillitis or one of the infectious diseases such as measles or scarlet fever, and may be found between the ages of 4 and 15 years. There is a sequence of attacks of acute tonsillitis, and speech may be affected, the child talking as if his mouth were full. An irritating cough is frequently complained of, and there may be choking attacks during meals or at night. The tonsils are seen to protrude towards the midline and may actually meet. The pharyngeal mucosa is red, particularly on the anterior faucial pillars, and the cervical lymph nodes may be persistently enlarged.

The treatment may be expectant in the first instance, and if there is no constitutional upset an adequate diet of vitamins and sufficient fresh air and exercise may be all that is required. In the inflammatory state this regime may be followed initially but should exacerbations persist removal of the tonsils should be considered.

Chronic tonsillitis results from repeated acute attacks when infected material remains in the crypts. Cheesy food particles may collect in the follicles and present on the surface of the tonsils, or they may be squeezed out of the crypts as small white or yellow solid particles with an offensive smell and taste. This gives an unpleasant smell to the breath to the embarrassment of the patient, and often to the misery of a child whose schoolmates are not slow to comment. On occasion one of the crypts becomes distended owing to the blocking of its mouth, and a smooth yellow swelling, containing creamy fluid and debris, appears on the surface. This is called a retention cyst and may be easily opened and drained.

SYMPTOMS. The patient suffers from repeated sore throats, an unpleasant smell and taste in the mouth, and systemic upsets. Toxic effects in children are

anorexia and the development of changes in temperament, such as tantrums or bouts of crying for little reason. There is a lack of the usual vigour.

CLINICAL FEATURES. Examination of the throat may reveal these white particles at the mouths of the crypts from which they may be easily removed, in contradistinction to those of keratosis pharyngis (p. 108). There is flushing of the margins of the palatoglossal arches, and the cervical glands are palpable. Pressure on the anterior pillars may squeeze fluid pus from the crypts.

TREATMENT. The treatment is removal of the tonsils. Should there be contra-indications to surgery, such as haemophilia, severe diabetes, acute pulmonary tuberculosis, gross hypertension, advanced age, etc. conservative therapy with long-term antibiotics may be ordered, and the throat may be painted regularly with Mandl's paint or a paint containing resorcin 0.3 g in 28.5 ml glycerine, or astringent gargles of hydrogen peroxide or ferric chloride may be prescribed.

TUBERCULOSIS OF THE TONSIL

Tuberculosis of the tonsil is now extremely rare in countries where the milk supply is controlled, and it presents no characteristic features. Attention is drawn to the tonsils by the diagnosis of tuberculous cervical glands. The tubercle bacilli in infected milk are presumed to reach the glands via the tonsils, which may or may not remain infected. There is no means of diagnosing this by clinical inspection, and the condition is discovered by histological examination after tonsillectomy. This is the more unfortunate because half of the tonsils so sectioned do not show evidence of tuberculosis. It is, however, sound surgical practice to remove the tonsils from children who have a tuberculous cervical adenitis rather than to leave potentially infected tonsils in situ. Full antituberculous therapy should be started when the diagnosis is made in the glands.

CALCULUS OF THE TONSIL

A calculus, or tonsillolith, may originate in the upper pole of the tonsil from calcification of cheesy food debris, and it may attain considerable size. It may be seen on the surface or detected with a probe. Sometimes the calculus is extruded spontaneously, or it may be removed with a probe. In many instances the tonsil must be removed, and this would be recommended if it were deemed septic.

BONE AND CARTILAGE IN THE TONSIL

Small islands of cartilage have occasionally been demonstrated in tonsils at microscopic examination, and they are thought to represent the remains of the first and second branchial arches.

Enlarged styloid process is occasionally found in the tonsil and, although it usually causes no symptoms, it may give rise to pain radiating to the ear. The bony spine may be palpated with the finger or it may be demonstrated radiologically. It may be removed surgically with relief.

CHAPTER 27

TONSILLECTOMY

The operation of tonsillectomy, with or without the removal of adenoids (p. 133), is the surgical procedure most frequently performed in the hospitals of this country.

INDICATIONS. The indications for removal of tonsils in adult life are: (i) repeated attacks of acute tonsillitis affecting the general health and causing frequent absences from work and (ii) one attack of peritonsillar abscess (quinsy) because further acute inflammation of the tonsils is apt to produce a further quinsy.

The indications for removal of tonsils in children are the subject of some controversy, mainly between paediatricians, who favour conservatism, and otolaryngologists who are more surgically inclined given certain criteria in the history and certain clinical appearances. It has been stressed (p. 96) that the inspection of the pharynx of a child or, indeed, an adult, must be conducted with a uniform light source if the interpretation of the appearance of tonsils and the buccopharyngeal mucosa is to be meaningful. This uniformity is only achieved by the use of reflected light from a standard bull's eye lamp with a bulb of unchanging wattage, or by the use of a headlamp powered from the mains with the reading of the transformer constant and the bulb of uniform wattage. The laryngologist will be correct to reject descriptions of tonsils achieved by other means.

When this has been said, it must be admitted that the clinical criteria of what constitutes a septic tonsil are not measurable, and each surgeon, from his experience, decides his own base lines. The appearances which suggest tonsillar sepsis are: (i) the presence of enlarged palpable lymph nodes in the deep cervical chain when there is no acute inflammatory lesion to account for them; (ii) the presence of a band of congestion along the free edge of the palatoglossal fold (anterior faucial pillar) in the absence of acute inflammation of the pharynx; and (iii) the presence, either on inspection or after squeezing the tonsil with a spatula, of purulent material in the crypts of the tonsils. Given these three criteria the tonsil may be considered to be unhealthy; given two of the three criteria the tonsils may be suspected of being unhealthy; given only one it may be thought unnecessary to recommend surgical removal on clinical grounds alone.

It will be noted that the size of the tonsils is not one of the criteria of their sepsis. It often happens in children that tonsils which are judged to be unhealthy are also large, but in adults the small buried tonsil may prove to be more septic than the larger one. Nor would a tonsil whose surface shows open crypts be deemed more unhealthy than one with a smooth surface unless pus can be seen in the crypts.

History plays a vital part in the assessment for surgery, and history depends on the case records of the general practitioner and upon the parents. Thus the letter from the family doctor, especially if it is documented, may play a vital role in the surgical opinion. Only he can assess the effect on the general health of the child of repeated infections. Parents vary in the way that they describe the illnesses of the child. Those who are anxious for surgery will exaggerate the frequency and severity of the sore throats, while parents opposed to surgery may minimize them. By the same token results are difficult to assess because the parents who have successfully pressed for surgery may well paint a different picture from those who have had reservations about the operation and who may ascribe many subsequent illnesses as dating from the operation. Between these two extremes is the vast majority of cases in which the practitioner's letter and the parents' story are in agreement.

On the question of taking a history one must not confine this entirely to the throat. Many parents have been led to believe from casual conversation with friends and relatives that the removal of tonsils and adenoids will cure all manner of illnesses. So convinced of this do they become that they may not mention these conditions specifically unless asked about them. It is thus wise to take a history in depth regarding such things as poor appetite, speech defects, nasal catarrh or colds, hearing loss, chest troubles, etc. because, while the operation may in certain cases be helpful, in others it may have no effect. Poor appetite may be due to other causes than tonsillar size or sepsis. Speech disorders may even be aggravated by the operation if the soft palate is inadequate and depends on a large adenoid pad for closure of the nasopharynx. Nasal catarrh may be due to allergy and will be unaffected by the operation, and this holds good for bronchospasm. Deafness may be congenital, or may be due to high tone loss, or to a sensorineural loss over the range of hearing, and none of these will be any better for the removal of tonsils or adenoids.

The history should be taken methodically and with care, and any chance remarks should be followed up. The frequency of sore throats is noted, as is their severity, their effect on the general health of the child, the need for antibiotics, including any history of antibiotic sensitivity, the length of absences from school, etc. The question of the catarrhal child has been discussed (p. 50) and one would want to discover whether sore throats only began with school attendance, whether they were the transient precursors of head colds and whether they occurred throughout the year or only during the winter months.

Appetite is investigated, and in particular any change in appetite associated with the onset of a sequence of tonsillitis. Loss of appetite may be an indication of tonsillar sepsis, and many children eat much better following tonsillectomy. It has been shown that on average they make a sudden gain in weight after the operation, and that this levels out later. On the other hand, a poor appetite is no indication for tonsillectomy if the tonsils are healthy.

Speech may be affected by the size of tonsils, especially the large buried tonsils whose upper poles are embedded in the soft palate. If one asks a child with such tonsils to say 'ah' it is noticeable how little the soft palate can move to close the nasopharynx. Removal of such tonsils, in spite of the post-operative scar tissue formation, will release the soft palate and allow it to recover its normal function. But in such cases the soft palate is often relatively

short and inadequate, so that it may be necessary to modify the adenoid removal to achieve a functional improvement in speech (p. 134). The large pedunculated tonsil has a different effect on speech in that the soft palate can move freely but the tonsillar bulk makes the child talk as if he had something in his mouth, and removal of the tonsils will cure this.

It has been said in other chapters, and it must be repeated, that tonsillectomy has little or no effect on allergy. It will not prevent hay fever or cure nasal allergy, nor will it cure the majority of cases of bronchospasm. It may help the allergic patients by improving the general health of the child if septic tonsils are removed. In any analysis of postoperative results from the operation the least benefit occurs in allergic patients, generally because the parents expect too much. If surgery is recommended in such cases the parents must understand that the operation is being done on account of tonsillar sepsis, and that no other results are to be expected.

It is true that hearing loss may improve following the removal of tonsils and especially adenoids (p. 321). This will occur if the hearing loss is conductive and is due to catarrh or infection in the auditory (Eustachian) tube or middle ear. The operation has no effect on other forms of deafness, so that if a history of deafness is obtained the tympanic membranes must be examined and audiometry carried out. Should the deafness be sensorineural over the whole range of hearing or confined to the high tones, or should severe or total deafness be found in one ear or both, either congenitally or as a result of mumps or meningitis or head injury, no improvement can follow operation on the tonsils, and the parents must be so informed.

The classic history of tonsillar sepsis in children is of frequent sore throats which affect the general health of the child. There may be abdominal pains from mesenteric adenitis, a poor appetite which persists between attacks, a loss of energy and a disinclination for games and a change of temperament leading to tantrums or crying for little reason in a child who was formerly free from these. There may be frequent colds or sore ears.

There is a popular belief that tonsils should never be removed before a certain age on the basis that the child will grow out of the succession of sore throats. It is true that the frequency of tonsillitis diminishes the older the child becomes, but each case must be judged on its merits. There can be little justification for delaying surgery until a certain birthday if the child is having repeated severe tonsillitis which affects the general health. On the other hand, there is equally no ground for recommending surgery unless the criteria in the history or on clinical examination are fulfilled. In the latter case, when sore throats are few or slight, it is wiser that the child should be kept under observation at regular intervals until either the attacks stop or they become more severe and more frequent. Some paediatricians advise long-term antibiotics in such cases.

There is the case in which, without any previous history of tonsillitis, a child develops several attacks in rapid succession and usually in spite of one or more antibiotics having been given on each occasion. This history suggests a virus infection which persists unaffected by therapy. In some such cases the tonsils will show minute yellow spots in the crypts between attacks and in this event if there is constitutional upset tonsillectomy gives good results. If, on the other hand, the tonsils appear clear and the child's general health is good, it is better to temporize and to review the position at intervals, and there

may be no further recurrences, the virus infection having 'burned itself out'.

It is generally accepted that the role of focal sepsis in tonsils was exaggerated in the past and tonsillectomy for rheumatic or renal disorders is now less commonly recommended unless the tonsils require removal on their own account. Some children who are due for cardiac surgery may be recommended for tonsillectomy, if the criteria of sepsis are found, because of the danger of subacute bacterial endocarditis with subsequent acute streptococcal tonsillitis.

In a few cases tonsils are removed because of size alone. Such children have tonsils which, although not inflamed, meet in the midline and cause gross difficulty with speech, swallowing and breathing. There is loud snoring and often choking attacks at night, and there have been reports of cor pulmonale on this account. During the day the child is constantly blocked and mouth breathes loudly.

CONTRA-INDICATIONS. These include severe diabetes and gross hypertension although neither is an absolute contra-indication and the patient may be prepared medically for the operation if it is imperative. Blood dyscrasias, such as leukaemia and haemophilia, are contra-indications although tonsillectomy has been performed with success in haemophiliacs following transfusions of plasma enriched with antihæmolytic globulin.

Tonsillectomy is not performed during epidemics of poliomyelitis although these are now uncommon in the Western countries as a result of inoculation. There is evidence to suggest that the virus may gain access to the exposed nerve sheaths and so give rise to the more fatal bulbar form of the disease.

Tonsillectomy is an elective operation and should not be undertaken in the presence of respiratory tract infections, or during the period of incubation after contact with one of the infectious diseases, or if there is tonsillar inflammation. It is much safer to wait some 3 weeks after an acute inflammatory illness before operating because of the greatly increased risk of postoperative hæmorrhage.

The operation should not be performed without overriding reasons in the very young. Nor should it be recommended in those past middle age unless there are urgent indications. While there is no contra-indication to the operation in professional voice users, such as singers, care should be taken that they have a prolonged period of retraining of the voice following surgery.

CHOICE OF OPERATION. There are two methods of removing tonsils—by the guillotine or by the dissection method. The guillotine method is shorter. In it the tonsil is manœuvred through the ring of the guillotine and the blunt blade is closed to constrict the areolar tissue between the tonsillar capsule and the pharyngeal aponeurosis. Stripping with the forefinger enucleates the tonsil. In the dissection method the mucosa is incised behind the palatoglossal fold, over the upper pole of the tonsil and down the palatopharyngeal fold. The tonsil is grasped and the areolar tissue is dissected along the plane of cleavage. Bleeding vessels are then caught and either tied or sealed with diathermy, whereas in the guillotine method they are allowed to seal themselves by contraction. The guillotine method has the further disadvantage that if there has been peritonsillar fibrosis, such as after a quinsy, the tonsil may tear during removal and some lymphoid tissue may be left near the upper pole. During a dissection this should not occur. For these reasons the dissection method is supplanting the guillotine in many centres.

AFTER-TREATMENT. On the day of operation the patient is warned of a reactionary haemorrhage. Later in the day mouth washes are given and the patient is encouraged to drink fruit juice. Jelly or ice-cream may be given in the evening. Pain may require morphine for adults or heroin for children in doses appropriate to the age and body weight. On the following morning breakfast should consist of scrambled egg, bread and butter, and fluids, and from then on three meals a day should be eaten. It is not sufficient for the patient merely to drink, he must be encouraged to chew food. Hard foods are avoided, but mince, fish and eggs are acceptable. Raw fruit is painful until the throat has healed.

Children are allowed home 2 or 3 days after surgery, but adults may stay in hospital for 4 or 5 days. On going home the patient should go to bed, and be allowed up for increasing lengths of time each day. Sloughs form in the tonsil beds, and these harden and finally separate some 7-10 days after the operation. When this happens swallowing becomes easier and the patient may then be allowed out. Children will be off school for a further 10 days, and adults will be off work for a total of 3 weeks from the operation.

COMPLICATIONS. *Reactionary haemorrhage* occurs within a few hours of the operation and may be severe. It may occur after either form of operation, and is treated by a return to the theatre when the vessel is ligated under anaesthesia. If there has been much loss of blood a transfusion may be given, but this is less liable to be required if the nursing staff is alert and prompt action is taken.

Secondary haemorrhage occurs some 5-8 days after the operation, and is usually due to a refusal on the part of the patient to eat. Chewing of food keeps the muscles of the throat active and appears to keep the tonsil beds free from infection. If food is refused the slough becomes septic and bleeding occurs at the time of its separation. A similar haemorrhage may occur if a patient is incubating an upper respiratory tract infection at the time of surgery. The patient should be readmitted to hospital and an appropriate dose of morphia for adults or heroin for children is injected, and a course of systemic antibiotic ordered. This is usually enough to control the bleeding, and only rarely is a transfusion necessary. It is not common to have to anaesthetize the patient and search for the bleeding point. The haemoglobin level of the blood should be ascertained and if necessary a course of ferrous fumarate (Fersamal) or some other iron preparation is prescribed. The patient can usually be discharged in 48 hours provided that he is eating well.

Infection may occur after operation. A pyrexia is not uncommon on the morning after tonsillectomy, but this usually settles after the bowels are opened, helped by an aperient if necessary. Prolongation of the pyrexia should be treated by systemic antibiotics for 5 days.

Pain on swallowing is common for the first week after tonsillectomy until the slough has separated. As a rule breakfast causes most discomfort and swallowing becomes easier during the day. Adults may find that a gargle of soluble aspirin before meals makes swallowing easier. The patient should be encouraged to talk freely as this also activates the muscles of the pharynx. Pain is often referred to the ears during swallowing, and relief may be obtained by the expedient of holding the hands over the ears during deglutition provided that there is no evidence of otitis media to cause the pain.

Nervous complications are found in children following hospitalization. Visiting of a child on the day of operation is not encouraged because the child

THE PHARYNX AND NASOPHARYNX

needs much sleep and parents tend to prolong their stay. A brief visit may comfort the child if he is awake and lonely, but the child should not be wakened merely to see the parents. Children are resilient and with sympathetic nursing care they largely accept the position on the day of operation provided that visits are paid on every other day that the child is in hospital. Some children suffer from fear of the dark or of strange people, while others have nightmares. With proper premedication and sedation, and with a greater understanding on the part of ward and theatre staffs these sequelae are becoming less.

Speech is affected until the slough separates, but if care has been taken to modify removal of adenoids in children with insufficient soft palates there should be no long-term deterioration in speech.

RESULTS. The only result that should be claimed for the operation is freedom from attacks of acute tonsillitis. It will not stop the transient pharyngitis before upper respiratory tract infections, and during this pharyngitis there will be congestion of small islands of lymphoid tissue on the posterior and lateral walls of the pharynx and in the lingual tonsil. Head colds will not disappear following surgery, although they may decrease in frequency and severity. Appetite may improve initially. Attacks of otitis media should diminish, especially if the adenoids have also been removed, and a conductive deafness should improve, again especially when adenoids have been removed at the same time. Snoring and mouth breathing should disappear, but occasionally a confirmed mouth breather will be helped by breathing exercises.

In the adult relief from acute tonsillitis ensures the success of the operation.

CHAPTER 28

DISEASES OF THE NASOPHARYNX

ACUTE NASOPHARYNGITIS

Acute inflammation may extend from the nose or pharynx to involve the nasopharynx. In addition, one may recognize an acute inflammation, confined to the lymphoid tissue of the nasopharynx, which resembles an acute tonsillitis. In such cases the pharyngeal tonsil is covered with mucopus and this may be the cause of obscure feverish episodes in children. It is often accompanied by enlargement of the cervical lymph nodes, and there is a complaint of discomfort in the back of the nose, nasal obstruction and pain on swallowing. Examination of the pharynx may be negative but posterior rhinoscopy will show the adenoiditis. Treatment, in so far as this is applicable, is that for acute rhinitis. In severe cases a broad-spectrum antibiotic is prescribed, but in less severe cases an antibiotic nasal spray with a decongestant should suffice.

CHRONIC NASOPHARYNGITIS

AETIOLOGY. Chronic inflammation may extend from the nose or pharynx, and chronic rhinitis, chronic sinusitis or chronic pharyngitis may produce chronic postnasal catarrh. It is common in smokers, heavy drinkers and in those exposed to dust or irritating fumes.

SYMPTOMS. The chief symptom is the feeling of some accumulation at the back of the nose giving rise to a constant desire to clear the throat by hawking followed by the expectoration of viscid secretion. The subjective disturbances vary greatly in different individuals and are unrelated to the extent of the objective changes.

CLINICAL FEATURES. There may be merely congestion of the mucosa of the nose, pharynx and nasopharynx or there may be hypertrophy of the mucosa with small lymphoid aggregations. In the nasopharynx these changes are seen in the vault where there may be tenacious mucus or mucopus. A chronic abscess in the remains of the median recess in the pharyngeal tonsil is called Tornwaldt's bursitis.

TREATMENT. Infection in the paranasal sinuses or tonsils should be dealt with, and any nasal obstruction should be corrected. The general health of the patient must be regulated. The urine should be examined for sugar and albumen; excessive smoking and drinking corrected; and overheated poorly ventilated environments should be corrected. The use of nasal sprays such as framycetin and gramicidin (Soframycin) or 1 per cent silver protein (Argotone) are helpful.

ADENOIDS

The name adenoids is given to the pharyngeal tonsil, but it has come to be loosely applied to enlargement of that tissue. More correctly 'adenoid hypertrophy' should be used. Adenoid tissue arises from the junction of the roof and posterior wall of the nasopharynx, and is composed of vertical ridges of lymphoid tissue separated by deep clefts (*Fig. 50*). It differs from tonsillar tissue in that it contains no crypts, is bounded by no capsule and is covered by ciliated epithelium. Adenoids are present at birth, continue



Fig. 50. Mass of adenoids removed from a child aged 3.

throughout childhood and atrophy at puberty, although persistence into adult life is not uncommon. It is probable that they are subject to the same physiological and pathological enlargement and retrogression as tonsils, but, being more difficult to examine, these are not recognized clinically. Adenoids probably form part of the body defence mechanism against infection.

Adenoids are liable to inflammatory changes. *Acute adenoiditis* may occur alone or in association with rhinitis or tonsillitis. It produces pain behind the nose and postnasal catarrh, lack of resonance of the voice, nasal obstruction and feeding difficulties in babies and it is often accompanied by cervical adenitis. Treatment is that of acute rhinitis. *Chronic adenoiditis* may result from repeated acute attacks or from infection in small adenoid remnants. The main symptom is postnasal catarrh which is got rid of by hawking or by snorting in young children, and the secretion is seen to hang down behind the soft palate as tenacious mucopus. Treatment consists of removal of the infected adenoids or adenoid remnants.

Adenoid hypertrophy. The enlargement may be simple or inflammatory, and the symptoms may be referable to hypertrophy, to infection or to both.

SYMPTOMS. Symptoms due to hypertrophy are produced, not from the actual size of the lymphoid mass, but from the relative disproportion in size between the adenoids and the cavity of the nasopharynx. This leads to nasal obstruction, which manifests itself in the following ways:

1. In infants enlarged adenoids may interfere with feeding because the baby has to stop sucking intermittently in order to take a breath. This makes feeding a wearisome process for both mother and child. The infant tires easily, takes insufficient food and fails to thrive. It may also have noisy respirations and a wet bubbly nose. Removal of even a small mass of adenoid tissue in such a case is often sufficient to result in an immediate improvement.

2. In older children nasal obstruction leads to mouth breathing, a habit which is very difficult to break. Mouth breathing is abnormal, and no normal baby will breathe through the mouth. Once the habit of mouth breathing due to obstruction is established, however, the child has little desire to use the nose for respiration. Therefore the sooner the condition is corrected the better chance there is for the re-establishment of the nasal mechanism.

3. The voice loses tone, and becomes nasal and lifeless. It must be shown that the fault is entirely due to adenoids. Movement of the palate may be demonstrated by lateral palatography, and if it is impaired speech therapy should be given before and after a modified removal of adenoids to give good results.

4. There is nasal discharge, partly due to mechanical obstruction at the posterior nares, and partly to a secondary chronic rhinitis.

The term 'adenoid facies', which used to be applied to the child with an open mouth, a vacant expression and an underslung lower jaw (*Plate VII, 1*) is in many instances a misnomer. It has been shown that many of these children, whose mouths remain open, are breathing normally through the nose and the defect is one of dental malocclusion, with consequent inadequate musculature of the mouth. This should be treated by remedial exercises and orthodontic measures. Children who have enlarged adenoids do not develop these skeletal and muscular changes and, after removal of adenoids, no re-education is



Fig. 51. Lateral radiograph of child with protruding upper incisors suggesting mouth breathing. The dental gap may be seen, while the nasal airway is completely free and is being used.

necessary. The differential diagnosis may be made by lateral radiography of the nasopharynx (*Fig. 51*), which will demonstrate a normal nasal airway in the resting phase, and by the cold spatula test. This consists in holding a cold metal spatula against the upper lip below the nose and estimating the nasal airway during normal respiration by the amount of steaming produced on the spatula.

The other symptom arising from adenoid hypertrophy is deafness due to the adenoid mass obstructing the openings of the auditory tubes. This diminishes air entry to the middle ears.

Symptoms due to infection are also referred to the nose and middle ears. Infection of the adenoids will cause an infection of the mucous membrane of the nose, and vice versa. This, in turn, may lead to an obstruction to the drainage of secretion from the paranasal sinuses and thus to infection of the sinuses. Removal of adenoids is usually sufficient to clear up most cases of sinus involvement in children. More serious is the effect of spread of infection




Fig. 52. Adenoids as seen by posterior rhinoscopy.

from the adenoids along the auditory tubes to give recurring attacks of acute otitis media, or to perpetuate a chronic otitis media. Enlarged infected adenoids are also a contributory factor in secretory otitis media.

CLINICAL FEATURES. On posterior rhinoscopy a lobulated mass of the same colour as the mucous membrane is seen in the nasopharynx (*Fig. 52*). It may be so slight as to form only a moderate projection which does not encroach on the posterior nares, or it may hang down and obscure either part or the whole of the septum and choanae. The growths occasionally extend laterally to lie in close relation to the openings of the auditory tubes (the tubal tonsils). In rare instances the adenoids extend into the pharynx and project below the soft palate. Examination with a postnasal mirror can sometimes be carried out in young children. If not, it is never necessary to palpate the nasopharynx unless under general anaesthesia. Lateral radiographs of the nasopharynx will demonstrate the presence and size of adenoids (*Fig. 53*).

DIAGNOSIS. The diagnosis is usually easy, but in the case of young infants it may not be possible to come to a definite conclusion prior to operation. In such cases it is wiser to give an anaesthetic and to palpate the postnasal space, and if adenoids are present they may then be removed. In all cases anterior rhinoscopy should be carried out to eliminate any other cause of nasal obstruction. The possibility of a coexistent infection of the paranasal sinuses must not be forgotten.

TREATMENT. If adenoid hypertrophy is not well marked and the symptoms are slight, surgical treatment should not be advised. Simple breathing exercises may suffice in such cases. The patient should be reassessed after an interval of a few months. When, however, one or more of the cardinal symptoms are present no time should be lost in removing the adenoids. It is not a sufficient contra-indication to operation that the adenoids tend to atrophy at puberty.



Fig. 53. Lateral radiograph showing a large mass of adenoids.

COMPLICATIONS OF ADENOIDECTOMY. Among these incomplete removal must be mentioned. This occurs in part because the removal of adenoids is a blind operation. The adenoids may be partly detached and hang down below the soft palate as a tag. This can usually be removed later, although removal of adenoid remnants at a later date is made more difficult by fibrous scarring. Adenoid remnants produce symptoms by virtue of the sepsis they may contain, and persisting deafness or middle ear infection may be experienced.

Hypernasality may occur after removal of adenoids from children whose soft palate is insufficient to close the nasopharynx during speech. Their speech is often affected, even before operation, and surgery may have been sought because of this. The inadequate palate may depend upon a large pad of adenoids for any contact during phonation. If this large adenoid mass is completely removed to relieve aural or nasal symptoms the insufficient palate may then be unable to close off the nasopharynx. Nasal escape occurs and hyperrhinophonia has been converted into the more serious hyperrhinophonia. This may be sufficiently severe to require correction by pharyngoplasty, or more simply it may be helped by the injection of Teflon paste into the posterior aspect of the soft palate. If the condition is diagnosed preoperatively,

and nasal or aural complications demand relief, it is possible to remove the upper part of the adenoid mass, thus leaving a lower ridge of adenoid tissue against which the defective palate may continue to make contact (*Fig. 54*).

Reactionary haemorrhage shows itself shortly after the operation by persistent bleeding from the nose. This does not, as a rule, respond to sedation by diamorphine injection. Very frequently there is a copious vomit containing much fresh blood. The pulse rate increases and the blood pressure drops.



Fig. 54. Palatographs showing, on left, a short stubby insufficient palate dependent upon a large adenoid mass for closing the nasopharynx. On right, the result of a modified removal of adenoids showing the palate closing the nasopharynx against the adenoids left at the operation.

Experience shows that the best treatment is to return the child to the theatre where a postnasal pack is inserted under anaesthesia, and is removed on the following morning, again under anaesthesia. If blood loss is severe or prolonged before being controlled a blood transfusion will be required.

Secondary haemorrhage from the adenoid bed may occur, although uncommonly, 4–10 days after the operation. It is usually not sufficiently severe to justify a postnasal pack, and it generally responds to sedation with an injection of diamorphine in a dosage suitable to the age and weight of the child.

NASOPHARYNGEAL ANGIOFIBROMA

This interesting tumour is rare in Britain, but is relatively common in some Middle Eastern and Far Eastern countries. It occurs typically in young males, the usual age range being 10–25 years. If it appears before puberty it often undergoes spontaneous regression at that milestone. It is probably of congenital origin and arises from the periosteum of the sphenoid, or the basi-occiput. It is a simple tumour in that it never gives rise to metastases, but it may be highly locally invasive, often spreading to the ethmoidal cells and orbit, the maxillary antrum and the sphenoidal sinus, and it may erode through the base of the skull. The rate of growth is variable, and this may depend upon the predominance of either fibrous tissue or a more vascular stroma. Microscopically, it consists of a variable amount of dense fibrous

tissue with a rich supply of blood vessels, some of which may be greatly dilated.

SYMPTOMS. The most common early symptom is nasal obstruction with consequent nasal speech. Excessive nose bleeding may occur from time to time, especially if surface ulceration is present. This may also give rise to a foetid nasal discharge. The growth may extend into the nasal cavities and present as a fleshy polypus. Broadening of the nasal bones may take place in advanced cases. Proptosis may occur from invasion of the ethmoidal cells and orbit. The tumour can often be seen protruding below the soft palate. Deafness and middle ear effusions result from occlusion of the auditory tubes. In later stages severe pain may be complained of due to involvement of branches of the trigeminal nerve. Invasion of the base of the skull may give rise to meningitis. In untreated cases death may occur from haemorrhage or from intracranial complications.

CLINICAL FEATURES. On examination of the pharynx a bulging of the soft palate may be observed. In other cases the tumour may appear below the soft palate as a dark red fleshy mass. In less advanced cases the postnasal mirror may be needed to visualize the tumour. Examination of the nasal cavities may reveal an extension of the growth. A firm mass can be felt on palpation of the nasopharynx.

DIAGNOSIS. This is not difficult in typical cases although the condition has to be differentiated from a naso-antral polypus. This, however, is much paler and less firm in consistency. Biopsy of the tumour will confirm the diagnosis. Even this simple procedure may initiate an alarming haemorrhage necessitating control by packing and often by blood transfusion.

TREATMENT. Treatment is by a combination of radiotherapy and surgical removal via a transpalatal approach, and close co-operation between the surgeon and radiotherapist is essential. Intensive follow-up is necessary for some years.

PROGNOSIS. Prognosis is always guarded. Spontaneous remission may occur but the tendency is for the tumour to progress and spread, although this is less likely after the age of 25 years.

SIMPLE TUMOURS

Enchondroma, exostosis, adenoma, angioma and many other tumours may be found in the nasopharynx, but they require no special description.

MALIGNANT TUMOURS

Neoplasms of the nasopharynx, while not common, are by no means rare, and are prevalent in south China. They may occur at any age and are found at a relatively younger age than other tumours. Both sarcoma and carcinoma are found although an undifferentiated squamous epithelioma is probably the most frequent, with reticulum cell sarcoma only a little less common. The tumour arises from the roof and lateral wall of the nasopharynx, commonly just behind the opening of the auditory tube. Lateral spread to the jugular foramen leads to involvement of the IXth, Xth, XIth and XIIth cranial nerves, either singly or in combination. Upward extension through the base of the skull causes meningitis and involvement of intracranial nerves. Invasion of the

THE PHARYNX AND NASOPHARYNX

orbit will give rise to proptosis. Most tumours are proliferative in type and cause downward displacement of the soft palate. The tumour may metastasize early to the upper deep cervical lymph nodes.

SYMPTOMS. The symptoms vary greatly according to the direction of spread. Profuse epistaxis or bloodstained nasal discharge may occur early, or unilateral conductive deafness, often with middle ear effusion, may be the first symptom. An enlarged firm upper cervical lymph node may appear even before there is a visible tumour mass in the nasopharynx. The spread to involve cranial nerves has been described, as has metastases to glands.

CLINICAL FEATURES. Any of the symptoms described should lead to a careful examination of the nasopharynx, which is often best done, under a general anaesthesia, through a nasopharyngeal speculum. If the tumour is obvious a piece is removed for biopsy, but if there is no obvious tumour a biopsy should be taken from the nasopharyngeal roof or from the region behind the opening of the auditory tube on the side of the presenting symptoms.

TREATMENT. In all cases this is by radiotherapy. Results obviously depend upon the extent of the growth when first diagnosed, and are not good in advanced cases. As in other situations, sarcomata respond rapidly at first but recurrence is common, and cytotoxic drugs may be given systemically in such cases.

PROGNOSIS. This varies with the spread of the tumour when first treated. About one third of the patients survive for 4 years.

CHAPTER 29

DISEASES OF THE SALIVARY GLANDS

ANATOMY. The salivary system comprises three large paired glands and hundreds of small glands. The large paired glands are the parotid, submandibular and sublingual glands (*Fig. 55*). The small glands are of simple

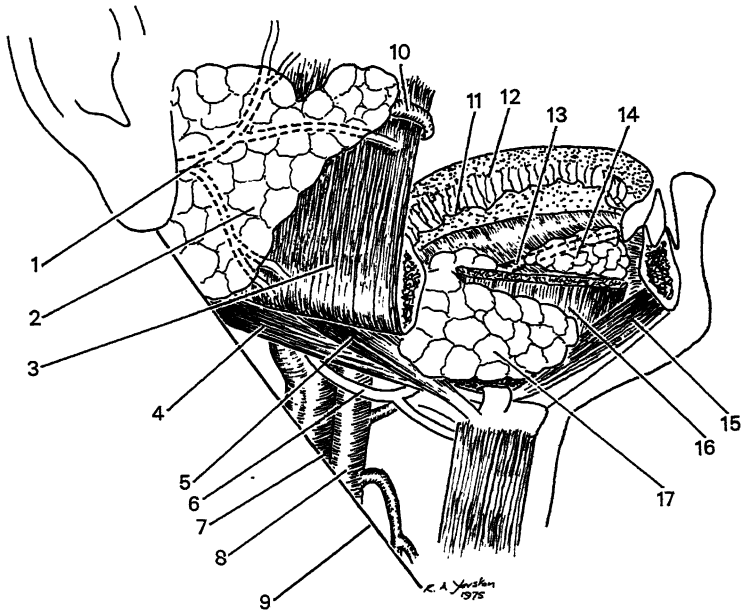


Fig. 55. The salivary glands. 1, Outline of course of facial nerve within the parotid gland; 2, Parotid gland; 3, Masseter muscle; 4, Digastric, posterior belly; 5, Stylohyoid muscle; 6, Hypoglossal nerve; 7, Internal carotid artery; 8, External carotid artery; 9, Anterior border of sternomastoid muscle; 10, Parotid duct; 11, Sublingual fold; 12, Tongue; 13, Submandibular duct; 14, Sublingual salivary gland; 15, Digastric, anterior belly; 16, Mylohyoid muscle; 17, Submandibular salivary gland.

structure with a small secretory acinus and a simple duct, and are most numerous in the mucous membrane covering the palate and the lower lip. The parotid and submandibular glands secrete into the oral cavity through a main duct for each gland, but the sublingual gland has numerous small ducts.

The *parotid gland* is the largest and assumes an irregular pear shape. It is wedged into the hollow behind the mandible and extends upwards to the external auditory meatus and downwards beyond the angle of the mandible, while a forward extension lies over the masseter muscle. It is enclosed in a

sheath of fascia extending upwards from the neck to form a capsule. The parotid duct is formed within the gland by the union of ductules that drain the lobules, and it runs over the masseter to open on the buccal mucosa through a small surface papilla opposite the second upper molar tooth. The facial nerve has an intimate relationship with the parotid gland, entering the posterior part of its deep surface to divide into its five radiating terminal branches. The secretory nerve supply of the parotid gland comprises sympathetic fibres from the carotid plexus, and a parasympathetic supply derived indirectly from the glossopharyngeal nerve. This gives a branch to the otic ganglion from where fibres pass to the auriculotemporal nerve and thence to the parotid gland. Sensory nerve fibres reach the parotid gland from the auriculotemporal and great auricular nerves.

The *submandibular gland* is about half the size of the parotid gland and lies between the mandible and the hyoid bone, partly under cover of the mandible. It is related to the mucous membrane of the floor of the mouth and extends backwards to the angle of the mandible and forwards as far as the mental foramen. It is partially enclosed in a sheath of cervical fascia. Its duct emerges from the medial surface of the gland and proceeds upwards and forwards to open into the floor of the mouth on the summit of the sublingual papilla. It derives its sympathetic nerve supply from the plexus around the facial artery, and its parasympathetic secretory fibres from the lingual nerve via the submandibular ganglion.

The *sublingual gland* is the smallest of the paired glands and lies in the anterior part of the floor of the mouth where it raises up the mucous membrane as the sublingual fold. The nerve supply is from the lingual nerve which contains sympathetic and parasympathetic fibres.

The *secretions* differ in the glands. Parotid secretion is wholly serous whereas submandibular secretion is partly mucous, and it is this fact that facilitates stone formation in the submandibular gland.

INFLAMMATORY DISEASES

The parotid gland is the most commonly affected by inflammation.

Acute inflammation in the parotid gland may be non-suppurative or suppurative. *Mumps* is an acute non-suppurative inflammation of the parotid gland, and although it may be unilateral it is more commonly bilateral. It is due to a virus and affects young children more commonly than adults. An attack confers a lifelong immunity. The symptoms are of an acute febrile illness with dryness of the mouth because of suppression of secretion. There is swelling and tenderness of the gland and some degree of trismus. The symptoms persist for a few days to be followed by a resolution of the swelling. There is no specific treatment beyond that of a febrile illness, and, because the disease is infectious, some degree of isolation is necessary. Mumps occasionally gives rise to encephalitis and meningitis, and a severe attack may be followed by a permanent bilateral or unilateral sensorineural deafness in children. In the adult orchitis or oophoritis may occur, causing sterility in the male.

Acute suppurative parotitis may arise from a septic focus in the mouth, such as chronic tonsillitis or dental sepsis, and may be found in patients taking tranquilizer drugs or antihistamines, both of which tend to suppress salivary excretion. The gland becomes swollen and tender, and there is a pyrexia. The

mouth of the parotid duct is red and pouting, and pus may be seen exuding, or may be produced by gentle pressure on the duct. Pus rarely points externally because of the dense fibrous capsule of the gland. Most cases respond to a broad-spectrum antibiotic, the common organisms being *Staphylococcus aureus*, haemolytic streptococcus and pneumococcus, and a swab should be taken from the duct mouth for sensitivity tests. Tranquillizers and anti-histamines should be discontinued.

Chronic inflammatory diseases may involve the submandibular or parotid glands. Recurring infections of the *submandibular gland* usually lead to the formation of a calculus in the duct. This is caused by the mixed mucous and serous constitution of the secretion of this gland. The gland becomes swollen and painful while eating. The sight and taste of food stimulates salivary secretion which is held up in the gland because the duct is partially blocked by the calculus. As a rule the swelling subsides gradually afterwards but in long-standing cases there is always some palpable enlargement of the gland.



Fig. 56. Sialogram to show sialectasis.



Fig. 57. Parotid tumour.

While the history is typical the presence of a calculus may be demonstrated by a straight radiograph. Treatment is surgical, and consists either in incising the duct in the floor of the mouth and removing the calculus or, if this is impossible and in the event of a recurrence, the whole gland may be removed.

Chronic recurring parotitis results in chronic inflammatory changes in the parenchyma of the gland with some suppression of salivary secretion. There may be acute exacerbations accompanied by pain and swelling. Between these the gland remains swollen. There is redness and oedema of the duct mouth with occasionally a purulent discharge appearing at the orifice either spontaneously or after gentle pressure. Sialography will demonstrate a typical sialectasis (Fig. 56). If doubt exists regarding the cause of the parotid swelling a needle biopsy may be taken from the gland without danger of producing a salivary fistula. Treatment consists in paying attention to oral hygiene and eradicating any septic foci such as infected tonsils or carious teeth. Should these measures fail surgery may be required for the gland itself. Resolution of symptoms may be achieved by dividing the secretory-motor fibres in the anterior part of the tympanic plexus in the middle ear. Ligation of the parotid duct may result in atrophy of the gland. If neither of these lesser methods succeeds a parotidectomy may be necessary.

Salivary gland sarcoidosis may involve both parotid glands to cause enlargement of the glands and depression of salivary secretion. Diagnosis is made by serological tests for sarcoidosis or by needle biopsy. There is no specific treatment, and as the gland involvement is part of a generalized sarcoidosis the management should be in the hands of a chest physician.

Sjögren syndrome (Mikulicz syndrome) is a chronic non-specific inflammatory reaction producing cellular infiltration of the parenchyma of all the salivary glands. It is usually associated with chronic rheumatic disease. There is initially a generalized enlargement of the salivary glands, but this decreases as a result of the progressive atrophy produced by the disease. The condition is characterized by a progressive and distressing dryness of the mouth, often complicated by a superficial infection of the buccal and pharyngeal mucosa. There is also dryness of the eyes from reduced secretion of tears. There is no specific therapy. Some stimulation of salivary secretion may be obtained by sucking sour sweets of the acid-drop variety. Frequent mouth washes and attention to oral hygiene are important.

SALIVARY TUMOURS

Salivary gland tumours are not common. Over 80 per cent of salivary tumours are found in the parotid gland (*Fig. 57*), and 70 per cent of these are of the non-malignant variety. The minor salivary glands are the most frequent site of malignant tumours.

Pleomorphic Adenoma (Mixed Salivary Tumour)

This is very firm on palpation, and may grow from the substance or the surface of the gland. It is a benign tumour, but may recur after incomplete removal. It usually occurs between the ages of 20 and 40.

PATHOLOGY. The tumour is firm, lobulated and encapsulated. Histologically the growth is found not to be confined within its capsule, and it is these extensions which tend to recur after removal. The tumour consists of epithelial cells in a hyaline stroma.

SYMPTOMS. The swelling is painless, and is usually situated above the angle of the mandible. It is smooth, firm and slow-growing, and the main complaint is of unsightliness, while in males it produces some difficulty with shaving.

Malignant Tumours. The most common site for these is the minor salivary glands. They may be found on the mucous membrane covering the hard palate, the base of the tongue or the posterior pharyngeal wall, and they are occasionally met with in the maxillary sinus. The tumours do not metastasize readily, but are locally invasive and may spread to the regional lymph nodes. Rarely they spread along nerve sheaths into the cranial cavity.

Muco-epidermoid tumours are uncommon. They consist of epidermoid and mucus-secreting cells. Although classified as malignant the prognosis is reasonably good.

Adenoid cystic carcinoma (cylindroma) is a rare tumour and is more usually found in the salivary tissue of the hard palate than in the salivary glands. It is malignant and locally invasive, and may metastasize, but the spread is very slow.

Acinic-cell tumours are uncommon malignant growths of the parotid gland which occur mainly in females.

DISEASES OF THE SALIVARY GLANDS

SYMPTOMS. The main symptom is swelling, but pain may be present. There may be dysphagia in tumours involving the palate, the tongue or the pharyngeal walls, while a tumour of the hard palate may cause discomfort in wearing a previously well-fitting dental plate. Involvement of the facial nerve suggests malignancy.

TREATMENT. Biopsy is generally not advised because it leads to leak of tumour cells, and therefore surgical excision is advised at the outset. The principal danger of excision is that of damaging the facial nerve, but modern techniques are such that most tumours may be removed completely without injury. The tumour must not be shelled out from its capsule because of the frequent extensions. Therefore wide removal is necessary, including normal parotid tissue. In palatal tumours palatectomy or maxillectomy may be required. The common tumours are not radiosensitive, but irradiation may occasionally be used after surgery, especially with malignant growths.

PROGNOSIS. With advances in surgical techniques, recurrences are less common, and only some 2 per cent of all tumours recur.

SECTION III

THE LARYNX, BRONCHI AND OESOPHAGUS

A. G. D. Maran

CHAPTER 30

ANATOMY AND PHYSIOLOGY OF THE LARYNX

The larynx is an integral part of the respiratory tract and is the organ of voice production. Only the essential parts of the anatomy will be dealt with in this chapter as specialized points will be mentioned in chapters relating to the appropriate diseases.

SKELETON

The main part of the laryngeal skeleton is formed by the thyroid cartilage which articulates with the cricoid inferiorly. The hyoid bone lies superiorly (*Fig. 58*). The epiglottis is attached to the thyroid prominence (Adam's apple) at the level of the vocal cords and forms the anterior wall of the laryngeal compartment. Anterior to the epiglottis (between the epiglottis and the thyroid cartilage, thyrohyoid membrane and hyoid) is the pre-epiglottic space (*Fig. 59, 2*), an area into which cancer spreads readily. From the sides of the epiglottis two folds of mucosa pass posteriorly to be attached to the arytenoids; these are the ary-epiglottic folds and they form the lateral wall of the upper laryngeal compartment (*Fig. 60*). They have a very rich lymphatic supply and so tumours of this area have a three out of four chance of producing a metastatic neck node. Laterally, the space between the ary-epiglottic fold and the thyroid cartilage is the pyriform fossa which is part of the pharynx. Food passes over the back of the tongue and down the lateral food channels formed by the pyriform fossae before entering the oesophagus. Inferiorly, the ary-epiglottic fold turns laterally to form the laryngeal ventricle immediately superior to the vocal cords (folds). The thick area where it turns laterally is the false vocal cord (ventricular folds) and shares the same rich lymphatic drainage.

The laryngeal ventricle (*Fig. 59, 4*) is the site of the primitive air sac and lies between the vocal and ventricular folds. It is the potential origin of a laryngocele.

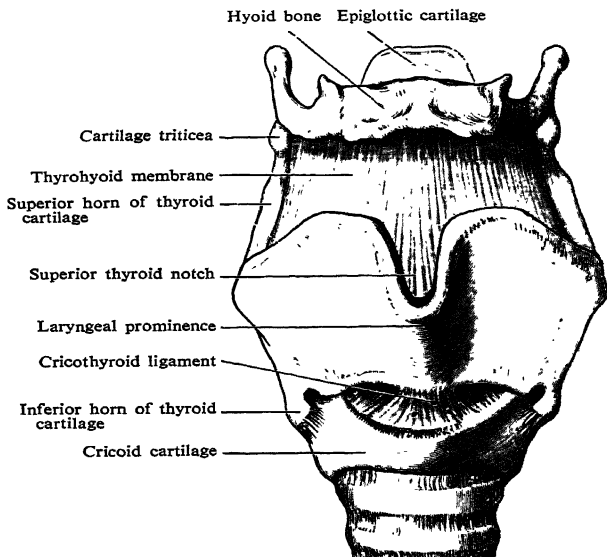


Fig. 58. Anterior aspect of cartilages and ligaments of larynx. (Reproduced from Cunningham's *Textbook of Anatomy*.)

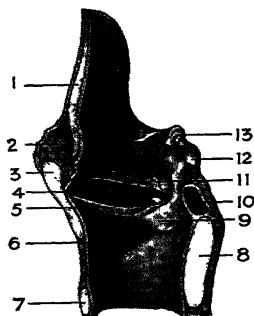


Fig. 59. Larynx, vertical median section, seen from left side. 1, Epiglottis; 2, Adipose tissue; 3, Thyroid cartilage; 4, Ventricle; 5, Vocal cord or fold; 6, Cricothyroid membrane; 7, 8, Cricoid cartilage; 9, Respiratory glottis, showing submucous position of arytenoid cartilage; 10, Arytenoid muscle; 11, Vestibular fold or false vocal cord; 12, Corniculate cartilage; 13, Cuneiform cartilage.

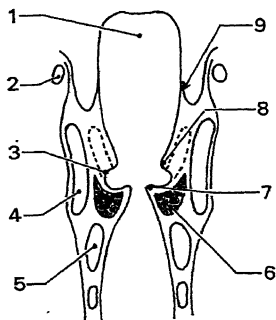


Fig. 60. The compartments of the larynx. 1, Epiglottis; 2, Hyoid bone; 3, Ventricle of larynx; 4, Thyroid cartilage; 5, Cricoid cartilage; 6, Thyro-arytenoid muscle; 7, Vocal fold; 8, Vestibular fold; 9, Ary-epiglottic fold.

Articulating with the upper border of the cricoid cartilage are the arytenoid cartilages to which are attached the vocal cords. The arytenoids are pyramidal in shape and have an anterior projection called the vocal process, to which the vocal cords are attached, and a lateral projection called the muscular process to which the main abducting and adducting muscles are attached (*Fig. 61*). The crico-arytenoid joint and the cricothyroid joint are synovial joints and may be affected by all synovial joint diseases. The arytenoids adduct and abduct on the cricoid, closing and opening the vocal cords. The thyroid cartilage moves in relation to the cricoid at the cricothyroid joint causing lengthening and shortening of the vocal cords. The anterior end of each cord is attached to the thyroid cartilage at the level of the epiglottis while the posterior end is attached to the cricoid via the arytenoid (*Fig. 59*).

The epiglottis is composed of yellow elastic cartilage and never ossifies. The thyroid and cricoid cartilages are hyaline and begin ossifying after the age of 25 in a patchy fashion—this is well seen in radiographs of the neck in older patients.

MUSCLES

One muscle abducts (opens) the vocal cords, two adduct (close) them, one adjusts the length and two adjust the tension.

Posterior crico-arytenoid muscle. This paired muscle arises from the posterior surface of the cricoid and is attached to the muscular process of the arytenoid. As it contracts the arytenoid is rotated around its axis, the vocal processes move laterally and the cords abduct (*Fig. 61*).

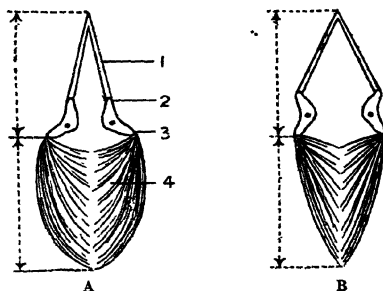


Fig. 61. To show action of posterior crico-arytenoid muscle (diagrammatic). In A the muscle 4 is at rest, the vocal process 2 is pointing medially, the muscular process 3 lies further to the side and the vocal folds 1 are only slightly separated. In B the muscles are contracted, the conditions are reversed and the glottis is widely open.

Lateral crico-arytenoid muscle. This paired muscle arises from the lateral part of the cricoid arch and runs obliquely posterosuperiorly to be attached to the muscular process of the arytenoid. On contraction, the muscular process is drawn anteriorly, the vocal process medially and the cords adduct and close (*Fig. 62*). This action is aided by the *interarytenoid muscle* which is unpaired and is attached to the posterior surface of both arytenoids.

Cricothyroid muscle arises from the oblique line on the lateral surface of the thyroid lamina and is attached to the anterior face of the cricoid arch. As it

supply is one of the reasons for different positions of the vocal cord after neural paralysis. The longer course of the left recurrent laryngeal nerve makes left-sided lesions commoner than right-sided ones (*Fig. 65*).

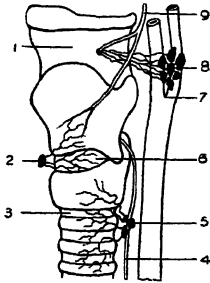


Fig. 64. Nerves and lymphatics of larynx. 1, Hyothyroid membrane; 2, Small lymphatic gland over front of cricothyroid membrane, and lymphatics draining into it; 3, Cricotracheal membrane; 4, Recurrent laryngeal nerve; 5, Lower group of lymphatic glands; 6, Cricothyroid membrane; 7, Bifurcation of common carotid artery; 8, Group of glands at bifurcation, with lymphatics draining upper region of larynx; 9, Superior laryngeal nerve, with internal (sensory mostly) and external (motor to cricothyroid) divisions.

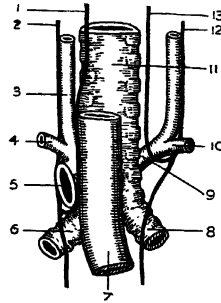


Fig. 65. To show the comparative course of the right and left recurrent laryngeal nerves (back view). 1, Left recurrent laryngeal; 2, Left vagus; 3, Left common carotid artery; 4, Left subclavian artery; 5, Aorta; 6, Left bronchus; 7, Oesophagus; 8, Right bronchus; 9, Innominate artery; 10, Right subclavian artery; 11, Trachea; 12, Right vagus; 13, Right recurrent laryngeal.

BLOOD SUPPLY

The larynx above the vocal cords is supplied and drained by the superior laryngeal artery and vein which enter the larynx through the thyrohyoid membrane. The region below the cords is supplied and drained by the inferior laryngeal artery and vein—branches of the inferior thyroid artery.

LYMPHATIC DRAINAGE

The vocal cords have, to all intents and purposes, no lymph drainage; occasionally a small node on the cricothyroid membrane (*Fig. 64*) is described, the delphian node, but its involvement in tumour spread is very rare. The cords thus act as a lymphatic watershed and very effectively divide the supraglottis from the subglottis, a most important fact in partial laryngectomy.

The supraglottis drains upwards via the superior laryngeal lymphatic pedicle which pierces the thyrohyoid membrane and ends in the upper deep cervical chain (*Fig. 64*).

The subglottis drains to both the prelaryngeal and the paratracheal nodes and from there lymph drains to the lower deep cervical chain and also to the mediastinum (*Fig. 64*).

HISTOLOGY

The larynx is lined by two different types of epithelium—squamous over the true cord and the upper quarter of the posterior surface of the epiglottis, and

columnar ciliated over the rest of the larynx. This latter type commonly undergoes squamous metaplasia in response particularly to atmospheric pollution and smoking.

The supraglottis is rich in mucous glands and lymphatics and so metastases are commoner in supraglottic tumours than others. There are no mucous glands in the glottis and very few in the subglottis. This latter compartment has a much poorer lymph drainage than the supraglottis accounting for the fact that only 1 in 5 patients with subglottic cancer have metastatic lymph nodes.

The mucosa of the glottis and supraglottis is firmly bound down to the underlying tissue, but not so in the subglottic region. Here, the laxity of the tissue allows a dangerous degree of oedema, especially in children, where the diameter of the area is relatively smaller than in the adult. In this situation, a degree of oedema, which would not cause too much trouble to an adult, could be fatal in childhood.

LARYNGEAL COMPARTMENTS

The larynx is divided into three different compartments, namely, the glottis, supraglottis and subglottis. This division is not only of academic anatomical interest but is of prime importance in the staging and treatment of cancer of the larynx.

The glottis is basically composed of the vocal cords from the extreme lateral edge of the cord to the inferior border of the medial surface of the cord. Anteriorly it extends from the anterior commissure (which is where the vocal cords meet) to the posterior commissure (where the arytenoids meet). Approximately half the length of the glottis is formed by the arytenoid body and vocal process (i.e. cartilage) and half by the membranous vocal cord.

The subglottis extends from the lower border of the glottis to the inferior border of the cricoid. Below this is the trachea. The subglottis is dome shaped and is relatively small and restricted.

The supraglottis extends from the upper border of the glottis inferiorly (the ventricle of the larynx) to the hyoid bone superiorly being bounded laterally by the ary-epiglottic folds; the pyriform fossa, which is part of the pharynx, begins at the edge of the ary-epiglottic folds. The suprahyoid epiglottis and vallecula are considered part of the oropharynx.

PHYSIOLOGY

The functions of the larynx are: (i) to protect the lung, (ii) to control air-flow and (iii) to initiate phonation. The protective function is well known to all who have choked on a crumb and have experienced the laryngeal spasm which follows. It is provided by three sphincter-like actions: (a) the approximation of the ary-epiglottic folds assisted by the epiglottis which tilts posteriorly, (b) the apposition of the false cords (ventricular folds) and (c) the closure of the vocal cords (folds) to prevent the entry of foreign material. During this phase respiration is arrested but once the foreign particle is ejected into the hypopharynx a long inspiration occurs.

THE LARYNX, BRONCHI AND OESOPHAGUS

During respiration the vocal cords abduct during inspiration (*Fig. 66*) abduction being greater during forced inspiration, and they adduct to some extent although never completely during expiration.

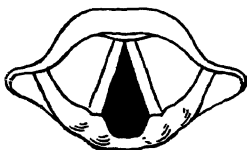


Fig. 66. Glottis on inspiration.

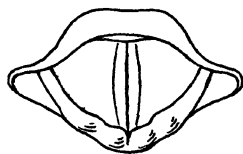


Fig. 67. Glottis on phonation.

Adduction of the vocal cords (*Fig. 67*) is essential for clear phonation, and anything, whether it be oedema, tumour or paralysis, which prevents this results in dysphonia. The cords also adduct fully during coughing.

CHAPTER 31

INVESTIGATION OF LARYNGEAL DISEASE

HISTORY. As the patient gives his history it is possible to form some opinion as to the cause of the voice problem. If he is aphonic the vocal cords are not meeting, and if he is dysphonic the vocal cords are meeting but the mucosal surfaces are damaged in some way. The volume and the quality of the voice can also give some help in cases of voice strain, neuromuscular problems and hysteria.

Inquiry must be made about the onset of the problem and its progress since the onset. The onset of a vocal cord paralysis is sudden and the voice gradually improves as the mobile cord compensates. On the other hand, the onset of a carcinoma or vocal cord polyp or nodule is gradual, and the hoarseness increases as time passes. Most inflammatory conditions start fairly quickly and then gradually improve. One must inquire about precipitating and alleviating factors.

Not many laryngeal conditions, apart from cancer, arthritis and perichondritis, give rise to pain but many laryngeal conditions may cause an irritating cough. Laryngeal pain is usually referred to the ear.

If the arytenoids are swollen they will partially obstruct and overhang the mouth of the oesophagus causing dysphagia. Another form of difficulty in swallowing may be caused if the vocal cords fail to meet. In this event swallowing is incoordinate because the patient cannot create a positive subglottic pressure when the glottis is open with the result that food tends to enter the trachea through the gap to give rise to bouts of coughing.

The patient's social habits must be investigated, especially with respect to smoking, exposure to occupational air pollution and vocal abuse. With regard to vocal abuse one must not forget that shouting at a deaf relative in the home is every bit as traumatic as vocal abuse at work.

Lastly, inquiry must be made regarding the general health and past medical history of the patient.

GENERAL EXAMINATION. While examination of the larynx is of paramount importance a general examination must be performed. The neck is examined for lymph node enlargement or added masses on the larynx. The size, shape and mobility of the laryngeal framework are studied. The ears and nasopharynx are examined because tumours in these areas may paralyse the laryngeal nerves. Myxoedema often affects the larynx and therefore the configuration of the thyroid gland and the skin, hair and nails of the patient must be examined.

INDIRECT LARYNGOSCOPY. It is impossible to teach indirect laryngoscopy by the written word. Nothing can take the place of practice in order to learn the skill. It is necessary to use a headlight, whether powered by a battery or by mains electrical supply through a transformer, or to use light reflected on to a

head mirror from a bull's-eye lamp. When the light is properly directed on to the patient's lips the laryngeal mirror, held in the right hand after the manner of a pen and with the reflecting surface downwards and forwards, is heated over the flame of a spirit lamp until the moisture which has condensed on its surface has evaporated. It is now suitably warmed for introduction but it should first be tested against the cheek in case it is too hot.

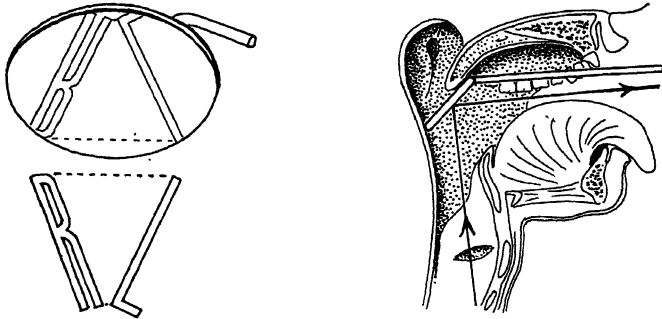


Fig. 68. Indirect laryngoscopy. The drawing on the right illustrates the placing of the mirror against the soft palate to obtain a reflected image. The drawing on the left shows how the right and left vocal cords are reversed in the mirror (cf. *Fig. 69*).



Fig. 69. Indirect laryngoscopy. The view obtained in the mirror.

The patient is asked to protrude his tongue as far as possible and the anterior part of the tongue is grasped by a swab held in the left hand. Edentulous patients should have removed their dentures because there is always the chance that they may slip thus causing apprehension to the patient who will not open his mouth sufficiently for examination. The patient is requested to breathe quietly through the mouth and the mirror is gently placed on the anterior surface of the uvula (*Fig. 68*). The light illuminates the mirror and the laryngeal image is seen as shown in *Figs. 68* and *69*. The anterior

part of the larynx, the epiglottis and the anterior commissure, is seen towards the top of the mirror and the posterior part, the arytenoids and the posterior commissure, is seen at the lower portion of the mirror. The patient's right vocal cord is on the left side of the mirror as the examiner looks at it. The patient is asked to continue to breathe gently through the mouth so that the form and colour of all parts of the larynx may be examined (*Fig. 70*). One first

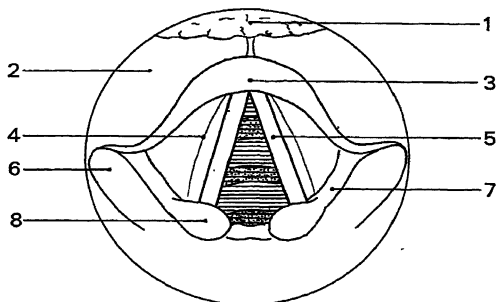


Fig. 70. The laryngeal image on indirect laryngoscopy. 1, Dorsum of tongue; 2, Vallecule; 3, Epiglottis; 4, Vestibular fold; 5, Vocal fold (cord); 6, Pyriform fossa; 7, Ary-epiglottic fold; 8, Arytenoid cartilage.

examines the vallecule and the tip of the epiglottis, and then the ary-epiglottic folds and the pyriform fossae on each side, and from there attention is directed medially to the mouth of the oesophagus and the arytenoids. The false cords (ventricular folds) and the normally white vocal cords (vocal folds) are next inspected. It is sometimes possible to see the upper few centimetres of the trachea through the glottis. Finally, the movements of the vocal cords are studied by asking the patient to phonate 'ee' several times, when the glottis should normally close.

It may not be possible to do an indirect laryngoscopy on some patients due to an overactive gag reflex. In these cases the soft palate and uvula may be painted with 5 per cent cocaine hydrochloride, and the larynx may be similarly sprayed. In spite of this it may still be necessary to give some patients a general anaesthetic in order to examine the larynx, especially if there is an overhanging epiglottis.

LABORATORY INVESTIGATIONS. These do not form a major part of the investigation of laryngeal disease but in appropriate cases blood may be taken for blood counts, thyroid function tests, serological tests, rheumatoid arthritis factor tests and monospot tests. In cases of suspected tuberculosis a Mantoux test may be done.

RADIOLOGY.

1. *Plain Radiographs.* Radiographs of the chest and neck may be of use in demonstrating the presence of air as, for example, in surgical emphysema or a laryngocele. The state of ossification of the cricoid and thyroid cartilage can be assessed and any displacement of the trachea will be seen. Mediastinal masses causing recurrent laryngeal nerve paralysis are usually obvious.

2. *Tomography.* Tomography of the larynx (*Fig. 71*) is a most useful investigation in assessing the extent of a laryngeal tumour especially an

exophytic supraglottic tumour which obscures the vocal cords on mirror examination. It is also of importance in identifying the site and extent of a tracheal stenosis. The use of the polytome has made this a procedure of high value.



Fig. 71. Tomograph to show glottic carcinoma of larynx.




Fig. 72. Laryngogram.

3. *Laryngography* (*Fig. 72*). Laryngography is a relatively new procedure which has added a new and valuable dimension to the investigation of laryngeal disease. It is done by drying the larynx by giving the patient an injection of atropine, anaesthetizing it by a superior laryngeal nerve block, and running a little radio-opaque dye into the larynx by means of a catheter passed through one nostril into the pharynx. Once the dye is in the larynx the

patient has a picture taken while breathing quietly, during phonation, while doing a Valsalva manoeuvre to outline the ventricles, and while doing forced inspiration.

A laryngogram has the advantage over the tomogram that it can be screened and the laryngeal movements better assessed.

SPECIAL INVESTIGATIONS. These tests are applied to voice problems rather than to cases with organic disease processes.

1. *Tape Recordings.* These are essential to record the progress of any case having speech therapy.

2. *Stroboscopy.* This produces an optical illusion whereby an object moving rapidly appears to move very slowly. The illusion is obtained by viewing the larynx by indirect laryngoscopy using a stroboscope as the light source and synchronizing the illumination with the frequency of the phonated 'ee'. This arrests or slows down the rapid movement of the vibrating vocal cords and allows of their inspection in any desired position by changing the phase of the light.

3. *Pitch and Frequency Measurements.* These measurements should be performed on all patients with voice problems. The ideal speaking pitch should be one third of the way up the patient's range. To measure this the patient should sing his lowest note and then sing a scale so that his highest frequency can be measured. The pitch frequency of his speaking voice should then be measured and the speech therapist will then be able to adjust this to his ideal conversational pitch one-third of the way up the range.

4. *Respiratory Function Tests.* These tests are occasionally useful because altered breathing patterns can cause vocal abnormalities.

5. *Fibreoptic Laryngoscopy.* This is a new addition to the investigative armoury resulting from the technological advances in fibreoptic instrumentation. It is possible to pass a small fibreoptic bundle through the nose and into the larynx to examine certain areas very closely and also to avoid the need for direct laryngoscopy in some cases with an overhanging epiglottis. It may also be combined with stroboscopy for laryngeal examination.

DIRECT LARYNGOSCOPY. A fuller description of the technique of this will be given in Chapter 41. Suffice it to say at this point that it is the most important laryngeal investigation. It permits a close examination of the laryngeal and pharyngeal structures, it allows the extent of tumours to be assessed and biopsied, and it is a route for minor laryngeal surgery such as vocal cord stripping or removal of polyps and other benign tumours.

In recent years use has been made of the Zeiss operating microscope with a 400-mm lens for microlaryngoscopy. With this innovation many new instruments have been developed to allow for fine microscopic work to be performed on the laryngeal structures with a high degree of accuracy and thoroughness. A stroboscopic light source may also be used with the microscope as an additional help in micro-examination of the larynx.

CHAPTER 32

VOICE PROBLEMS

PHYSIOLOGY OF VOICE PRODUCTION

To comprehend how a sound is produced in the larynx it is necessary to understand the Bernoulli effect. This principle states that during the steady flow of a fluid or a gas, the pressure is less where the velocity is greater. In other words, when air passes from one large space to another (i.e. from lung to pharynx), through a constriction (the glottis), the velocity will be greatest and the pressure least at the site of the constriction.

When we wish to phonate, the recurrent laryngeal nerves set the vocal cords into the adducted position, but because the vocal processes are slightly bulkier than the membranous cord a slight gap exists between the membranous cords. The lungs then expel air and the air stream passes through this chink between the vocal cords. According to the Bernoulli principle, therefore, there is a drop of pressure at this site and this causes the mucosa of the vocal cords to be drawn into the gap thus blocking it. At this time the subglottic pressure rises causing another stream of air to flow through the cords with another resultant pressure drop and closure of the gap. As this process is repeated a vibratory pattern develops at the vocal cords and the resulting sound is what we appreciate as voice. The change of this sound into speech is accomplished by the tongue, teeth, lips and palate.

At birth the vocal cords are about 7 mm long, at puberty about 14 mm long, in the adult female 15–16 mm long and in the adult male from 17 to 21 mm long. Because the anterior commissure is situated at the thyroid prominence this increased length in the male explains why men have larger 'Adam's apples' than women. It can also be understood from the above that, as a general principle, as the length of the cord is decreased so the pitch of the voice rises. The alteration in the length of the cord is produced by the cricothyroid and the thyro-arytenoid muscles. Length is not the only factor in voice pitch, however—both the tension or elasticity of the cord and the tracheal air pressure are important. As the cord is shortened the 'slack' must be taken up and the tension readjusted—this is done by the vocalis muscle. Increase in tension, maintaining the same length of cord, will also cause some rise in pitch. It is a well-known fact that as one speaks louder so the pitch of the voice rises. Further reference will be made to this fact in the sections on voice strain and vocal nodules.

In actual phonation, pitch and pressure are associated in such a way that a slight increase of air pressure causes a considerable rise in pitch. If this were the whole story, however, the pitch of the voice would rise linearly as the loudness increased. In actual fact, increase of loudness is attained by rise of air pressure associated with decrease of elasticity of the glottis. It is a truism to

state that most professional singers sing better than amateurs. The difference is defined as quality. To a large extent good singers are born rather than made. With practice, the vertical depth over which the cords meet, i.e. the medial apposing surfaces of the cords, can be increased in size; this involves hypertrophy of the vocalis and thyro-arytenoid muscles. The most important factor in quality is the relationship of the size of the resonating chambers—the lungs, pharynx and upper respiratory tract—to the fundamental frequency of the note produced. It is this relationship that cannot be created by practice, and one has to be born with it.

VOICE STRAIN

This is a very common problem and will, of course, be noticed much earlier by, and cause most inconvenience to, professional voice users.

As stated in the previous chapter, the optimum pitch of the voice is one-third of the way up the person's own range. At this pitch, optimum cordal length and tension can be maintained, as can a proper breathing pattern. If any of these factors of pitch, length, tension or breathing is altered, then some strain will be placed on the thyro-arytenoid and interarytenoid muscles. The degree of voice strain will depend upon the length of time the person has practised wrong voice usage, and for how many hours each day. The type of person who is liable to get voice strain is an actor who has to project his voice abnormally loudly in poor acoustics, a preacher or a teacher who speaks too loud and at too high a pitch, a pop singer or someone with an elderly deaf relative who needs constantly to be shouted at. Another very common cause of voice strain is to overuse the voice during an acute laryngitis. During an inflammatory process in the larynx some round-cell infiltration occurs in the thyro-arytenoid muscle, when a myositis may be said to exist. If the voice is over used in this circumstance it will become easily tired, and permanent damage can occur to the muscle. A singer or actor therefore must cancel all performances if they have acute laryngitis.

APPEARANCES. The larynx has a very typical appearance in this condition. Basically, it is difficult for the glottis to maintain closure, and some part of it remains open. If the thyro-arytenoid muscle is most affected there will be closure of the arytenoids and posterior glottis but not of the cords—this results in an appearance of bowing (*Fig. 73*). If the interarytenoid muscle is most affected there will be closure of the cords but not of the posterior glottis, leaving a triangular gap posteriorly (*Fig. 74*). If both muscles are affected the larynx will have a keyhole appearance.

MANAGEMENT. The voice will be good in the mornings or after prolonged rest but will become 'breathy' as the muscles become fatigued with use. The best treatment therefore is voice rest for 1–2 weeks—and this must be total. The patient is instructed to use a pad and pencil to write down communications—whispering is not voice rest. After this time advice should be sought from a speech therapist to correct the causative factor be it faulty breathing or faulty pitching of the voice.

VOCAL NODULES

These are also called singer's nodes or screamer's nodes and, from this, some idea may be obtained of the aetiology. It is fashionable now for pop groups to

use falsetto voices on occasion. This is a trick whereby the voice is produced by vibrating the anterior part of the vocal cords thus causing a tremendous 'shortening' effect combined with an increased cordal tension. The same is true of yodelling. This is the extreme situation, but it occurs in miniature when a natural baritone tries to sing tenor parts, and a natural contralto sings soprano. It happens, too, with anyone who pitches the voice far too high. Maximum vibration occurs in the anterior larynx and at the posterior part of

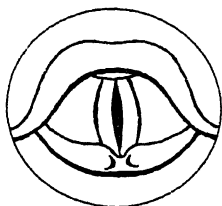


Fig. 73. Bowing of vocal cords due to thyro-arytenoid muscle weakness.

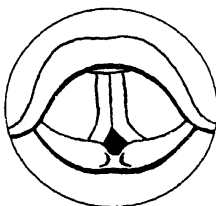


Fig. 74. Triangular gap from weakness of interarytenoid muscle.



Fig. 75. Singer's nodules.

this maximally vibrating portion, fibrosis and traumatic scarring occurs on both cords.

Thus, typical nodules are bilateral, small, and greyish-white and are situated at the junction of the anterior third and posterior two-thirds of the glottis (Fig. 75). This point is half way along the membranous vocal cord because the vocal process forms the posterior third of the cord. The patient becomes hoarse, and the nodules require to be removed at direct laryngoscopy using microsurgical techniques. If they are very small speech therapy can sometimes improve the situation. In all cases, after surgery, the advice of a speech therapist should be obtained to correct the causative factor in voice production.

DYSPHONIA PLICAE VENTRICULARIS

As the term implies, this is phonation with the false cords instead of the true cords. It can occur in extreme vocal cord strain, after operations on the vocal cords, or for no apparent reason. The voice has a peculiar sound, almost like a duet, and is therefore called diplophonia. In some instances the patient's breathing pattern may be improved by the speech therapists with a consequent improvement in the voice. Generally, however, the results of speech therapy in this condition are not good.

FUNCTIONAL VOICE PROBLEMS

Aphonia is dealt with in the chapter on vocal cord paralysis (p. 189).

Phonic spasm is a condition met with in adults who use their voice professionally. The cords act quite normally during respiration, but when the patient attempts to speak they become firmly pressed together after a few

VOICE PROBLEMS

words and no further sound can be emitted. The spasm ceases as soon as the endeavour to phonate is abandoned.

Mogiphonia is a similar condition seen in singers, teachers and clergymen. While the ordinary conversation voice is unaffected, professional speaking or singing is painful and impossible.

Phonasthenia is an allied condition where the voice becomes easily fatigued on speaking with no evidence of vocal strain.

The treatment of all these conditions is by speech therapy and relaxation exercises supervised by the therapist.

CHAPTER 33

ACUTE LARYNGOTRACHEAL INFECTIONS

ACUTE LARYNGITIS

This is a viral or bacterial inflammation of the larynx, which very commonly presents as part of a generalized upper respiratory infection. On many occasions it may also occur as part of a lower respiratory tract infection. It occurs more often in smokers and other people with altered laryngeal states, such as those working in polluted atmospheres. Overuse of the voice does not cause it but merely brings it to light sooner.

DIAGNOSIS. Nowadays the diagnosis is easy because anyone who becomes dysphonic or aphonic during a cold or with an acute bronchitis has almost certainly got acute laryngitis. Formerly, however, much greater care had to be taken with the diagnosis since the febrile illness and upper or lower respiratory infection could well be diphtheria, tuberculosis or syphilis. The average laryngologist, in this country, will now see one such case every 2 or 3 years, but in developing countries the practising laryngologist will have to keep all these conditions in mind.

The present-day diagnostic error is to miss an underlying cordal carcinoma during an upper respiratory infection especially where the 'laryngitis' persists for some weeks, or to miss a vocal cord paralysis in a lower respiratory infection secondary to a bronchial carcinoma, or left-sided heart failure.

Thus in all cases of hoarseness the larynx must be seen if the problem persists for more than a week or two. In acute laryngitis the whole larynx is reddened as are the normally white vocal cords (*Plate VII, 2*). If the condition is severe then the cords and false cords will be oedematous and pus will be seen in the interarytenoid region and perhaps even around the epiglottis.

TREATMENT. If a cold is sufficiently severe to cause laryngitis it is probably advisable for the patient to have a few days of bed rest and voice rest, since going to work and straining the voice will not only prolong the hoarseness but may permanently scar the thyro-arytenoid and vocalis muscles. This is particularly important in actors and singers. During a laryngitis the muscles and spaces are infiltrated by round cells and if the normal healing processes are not allowed to take place under rest conditions, then the muscle will scar causing permanent damage. This may not be obvious in the average person, but it will certainly be noticed by a singer or actor.

Since the vast majority of these cases are due to virus infections antibiotics play no useful role, unless there is secondary infection in which case ampicillin would be the drug of choice. Steam inhalations, sweetened by the smell of menthol or tincture of benzoin, are comforting and should be used. If there is pain simple salicylic acid analgesics are usually enough, but if

stronger ones are required then one should reconsider the diagnosis and think of epiglottitis or perichondritis.

ACUTE EPIGLOTTITIS

This is seen in children more commonly than adults and while it may present as part of a generalized upper respiratory tract infection, it may also occur on its own.

DIAGNOSIS. The usual presentation is with fever and severe pain deep in the throat especially on swallowing. If allowed to progress unchecked the inflammatory oedema will track through the vast lymphatic spaces of the supraglottis—especially the ary-epiglottic folds—and will cause muffling of the voice and respiratory obstruction. Since these spaces are larger in children than in adults, it is a more dangerous disease in childhood.

Examination with a mirror shows a bright red epiglottis, which will become very swollen as the disease progresses. The oedema will later be seen in the ary-epiglottic folds and arytenoids and examination will also become progressively more difficult since it becomes painful and difficult to protrude the tongue.

TREATMENT. The commonest infecting organism is *H. influenzae* but whether it is an opportunistic invader secondary to a viral cause has not yet been shown. The antibiotic of choice is therefore ampicillin in larger doses than would be used in acute laryngitis because it is necessary for the drug to penetrate cartilage.

All other efforts must be towards preventing supraglottic oedema and respiratory obstruction. In the early stages, inhalations and adrenaline hydrochloride (1 : 10 000) sprays may be sufficient, but if the oedema progresses the patient will have to receive at least 100 mg hydrocortisone intravenously every 4 hours. If respiratory obstruction continues the patient should have a tracheostomy because intubation may be difficult or impossible, and if the diagnosis is correct the bronchial tree should be relatively clear. The tracheostomy is only required for a few days provided that adequate therapy is maintained.

ACUTE LARYNGOTRACHEOBRONCHITIS

This is a dangerous and common viral infection of the larynx, trachea and bronchial tree. It is almost confined to children and is seen more commonly in Australia and the Western side of the United States than elsewhere.

DIAGNOSIS. The onset is relatively sudden and the child's temperature rises; he complains of a painful cough; the respiratory rate rises and signs of respiratory obstruction, such as indrawing of the suprasternal notch and venous engorgement, soon become obvious. There is increasing evidence of general toxicity.

TREATMENT. The reason that respiratory obstruction is liable to occur early is that the subglottic region in the child is very lax and oedema occurs early in the upper trachea and subglottic space. If this were the only problem, then tracheostomy, if done in time, would prevent any deaths. This is not the case, however, because the inflammatory process extends downwards to involve the

terminal bronchi and the child, even with a tracheostomy, may not be able to effect an efficient gas exchange in the lungs.

Thus while antibiotics, such as ampicillin, inhalations and adrenaline sprays, may cure many cases, a considerable proportion will require intravenous hydrocortisone. Of these some will require further help, and the procedure of choice in these cases is to intubate the child and carry out intermittent positive-pressure ventilation. If the endotracheal tube requires to be in place for more than 72 hours a tracheostomy should be performed and intermittent positive-pressure ventilation continued for as long as is necessary by this route. In the severe case, a close watch should be kept for the possibility of the development of a Gram-negative septicaemia, which may well cause renal shut-down.

ACUTE ALLERGIC LARYNGITIS

This may be a manifestation of a systemic allergic problem such as a drug reaction, a local allergic reaction such as angioneurotic oedema or a contact mucositis as a result of inhaling the offending allergen in the form of dust particles.

On examination, the first two aetiological factors cause the larynx to be swollen and pale, but the contact mucositis (due to a product such as bauxite) presents as a red, swollen painful larynx not unlike that seen in acute laryngitis, but without the accompanying respiratory infection and fever. Initial treatment should be with intramuscular chlorpheniramine maleate (Piriton) 4 mg and intravenous hydrocortisone 100 mg if necessary. Because there should be a quick response to this once the precipitating allergen is removed, further respiratory obstruction should be handled by intubation rather than tracheostomy.

The less severe contact mucositis is more difficult to get rid of and occasionally persists for months in rather a painful way. Sprays such as 5 per cent glucose in glycerine may be used together with analgesics.

CHAPTER 34

CHRONIC LARYNGEAL DISEASES

CHRONIC LARYNGITIS

The aetiology of this condition is quite unknown. In a minority of instances repeated attacks of acute laryngitis will cause the chronic state to occur. In others, excessive smoking, or occupational pollution, cause metaplastic changes which alter the lining of the larynx enough to warrant a diagnosis of chronic laryngitis. It is true, however, that only a small proportion of those who smoke or are exposed to pollution suffer from chronic laryngitis. Some cases have associated chronic sinusitis with or without chronic bronchitis but, again, not all cases of sinusitis and bronchitis have laryngitis.

In summary, therefore, while a lot of associated features are recognized, the underlying cause of chronic laryngitis is unknown. Different types are recognized and described according to the laryngeal appearances. Many cases look very like cancer of the larynx, but the important diagnostic point in chronic laryngitis is that the changes are bilateral and symmetrical. There are several varieties.

1. Chronic Hyperaemic Laryngitis. The characteristic appearance is that the whole larynx, including the vocal cords, is red and there are increased secretions. It looks rather like a subacute laryngitis.

2. Chronic Hypertrophic Laryngitis. In addition to redness, this type displays a hypertrophy in the supraglottis and glottis.

3. Chronic Oedematous Laryngitis. In this variety the outstanding feature is the polypoidal swelling of the glottis and also of the false cords. It can be mimicked by myxoedematous laryngitis.

4. Chronic Atrophic Laryngitis. This condition is usually seen in laundry workers and cooks and is characterized by an atrophy of all laryngeal structures including the mucous glands of the supraglottis. The result of this is an excessive crusting within the larynx and trachea.

SYMPTOMS. The common symptom to all the above conditions is continuous hoarseness. If there is any degree of myositis there will be air wastage resulting in a breathy voice. There will also be a feeling of dryness and irritation in the throat and a frequent desire to clear the throat.

TREATMENT.

a. Voice Rest. This forms an important part of the treatment especially in professional voice users who could do permanent damage to their voice if they did not rest it. If vocal abuse plays a part in the aetiology then voice rest must be enforced.

b. Speech Therapy. This service must be offered to patients who do not use their voices properly.

c. Avoidance of Pollutants. It is essential to stop smoking and to take steps to avoid or lessen exposure to environmental factors.

d. Local Applications. Laryngeal sprays are difficult to use and have no direct therapeutic value; they are, however, comforting and medications such as glucose in glycerine or oil of pine may be used. The tongue is held forwards as for an indirect laryngoscopy and the laryngeal spray is introduced into the pharynx nozzle downwards. As the spray is used the patient inspires deeply. Sprays are especially helpful in atrophic laryngitis.

e. Endoscopic Procedures. Vocal cord stripping is of use in oedematous and hypertrophic laryngitis. It should be confined to one vocal cord at a time since the infection will inevitably involve the anterior commissure which, if bared on both sides, may lead to the formation of a laryngeal web. In most cases a biopsy will be required to confirm the diagnosis.

LEUCOPLAKIA OF THE LARYNX

The word 'leucoplakia' is derived from the Greek meaning a white patch. In the larynx these 'white patches' nearly always occur on the dorsum of the vocal cords. No assessment of their malignant potential can be made by naked eye examination alone and so each area of leucoplakia of the larynx must be removed and submitted to histology. From this two reports are possible: (a) *Keratosis*. In this condition the white patch is due to a heaping up of keratin. This is quite benign and never becomes malignant. (b) *Dysplasia*. Although pathologists differ in their interpretation of the severity of this state, all will probably agree that this is the stage before carcinoma-in-situ. Dysplasia is pre-malignant and patients whose leucoplakia shows evidence of dysplasia should be put on a cancer follow-up schedule.

If the condition progresses to the stage of *carcinoma-in-situ* (see p. 184) the affected vocal cords should be carefully stripped using microlaryngoscopy and the specimen sectioned. If there are any areas of invasive cancer radiotherapy should be used but provided that it stays at the carcinoma-in-situ stage radiotherapy is contra-indicated. A policy of repeated vocal cord stripping should be adopted.

PACHYDERMIA

Pachydermia of the larynx is a condition of unknown aetiology and until the aetiology is discovered, it would seem reasonable, on the basis of its natural course, to include it under the heading of chronic diseases of the larynx.

The name describes a heaping up of red or grey granulation tissue in the interarytenoid area. Occasionally this tissue spills anteriorly on to the vocal processes and the posterior ends of the vocal cords (*Plate VII, 3*). As the granular area replaces the thin mucosa on the medial surface of the vocal processes this mucosa becomes worn away and damaged by repeated compression when the vocal processes meet in talking. This results in cartilage becoming exposed and in the surrounding granulation tissue becoming raised. This configuration is known as a 'contact ulcer' and forms part of the clinical picture of pachydermia.

The most recent thoughts on the aetiology suggest that, with an incompetent *cardia*, acid refluxes up the oesophagus as the patient lies down at night thus

causing an acid mucositis in the interarytenoid area. Speech therapists, on the other hand, suggest that forceful voicing ('glottic attack') exposes bare cartilage on the vocal processes with a resulting formation of granulation tissue.

The only symptom caused by pachydermia is hoarseness. The diagnosis by indirect laryngoscopy causes little problem since the characteristic red or grey tissue in the interarytenoid region is seen whether contact ulcers are present or not. In all cases this must be biopsied to exclude carcinoma, tuberculosis or granulation tissue at the mouth of a small cleft larynx. At endoscopy as much tissue as possible should be removed, and in this instance the microlaryngoscopic scissors are very useful. The tissue on the vocal processes is trimmed at the same time. Several such procedures may be required before the condition resolves.

PROLAPSE OF THE VENTRICLE

This condition is of uncertain pathology. The mucosal lining of the ventricle is prolapsed so that it comes to lie on the vocal fold, where it appears as a smooth, pink, fleshy mass with a broad base. The cause of this condition is most probably the strain of coughing and the negative pressure which is exerted by the spasm. The condition may be simulated by tuberculosis, cysts and simple tumours.

Hoarseness and cough are the main complaints. Diagnosis is made at direct laryngoscopy, when replacement of the prolapsed ventricle may be effected by the blade of the laryngoscope or by forceps. A biopsy of the tissue should be taken to establish the diagnosis. Endoscopic removal of the medial portion of the projection is the most satisfactory treatment. Diathermy puncture will cause fibrosis and prevent recurrence.

TUBERCULOSIS OF THE LARYNX

Over the past 20 years, not only has the incidence of this condition changed, but so has the clinical presentation. Formerly, laryngeal tuberculosis presented as part of a pulmonary tuberculosis affecting mainly the posterior part of the larynx. Oedema of the arytenoids and the epiglottis due to perichondritis was a feature, as was oedema and ulceration of the vocal cords. Of these cases that survived a proportion developed scarring and stenosis of the larynx.

The chronic attenuated form of laryngeal tuberculosis is called lupus of the larynx and is contagious. It is usually secondary to well-marked lupus of the face, nose or pharynx, and the epiglottis is most frequently involved.

Since tuberculosis is so rare nowadays it is unusual for the otolaryngologist to diagnose it from mirror examination alone. The appearances are indistinguishable from those of carcinoma. There is an ulcerative vocal cord, arytenoid oedema or a verrucous overgrowth in the supraglottis. It is not invariably the case that the patient has pulmonary tuberculosis also—in fact it is now more common for the laryngeal manifestation to be the only one.

Each case must be examined at direct laryngoscopy and a biopsy taken to rule out carcinoma. When the diagnosis has been made treatment by chemotherapy is supervised by the tuberculosis specialist.

SYPHILIS OF THE LARYNX

This is now even rarer than tuberculosis. It may be congenital or acquired and is more common in males than females.

Congenital syphilis of the larynx is a very severe condition which in appearance resembles chronic hypertrophic laryngitis.

Of the acquired types, the primary and secondary stages are rarely seen in the larynx, but if they do occur, the anterior half of the glottis and the epiglottis are most often affected. Gumma may occur in any part of the larynx and it presents as a smooth swelling which may later ulcerate. Diagnosis is by biopsy, but this must be confirmed by the battery of appropriate serological tests. Treatment should be supervised by the appropriate specialist.

ARTHRITIS OF THE CRICO-ARYTENOID JOINT

The crico-arytenoid joint and the cricothyroid joints are both synovial, and may be affected by the same types of arthritis affecting synovial joints elsewhere in the body. It is thus possible to get rheumatoid arthritis, infective arthritis or gout of the larynx. Other causes of fixation of the joints are perichondritis (due to irradiation, tuberculosis or syphilis) or trauma. In the acute phase the joint is swollen and limited in movement, causing a large, swollen, red, immobile arytenoid. The patient is dysphonic and has severe pain in the larynx which is made worse by talking.

After several such attacks the joint becomes less inflamed, but more fixed. If the joint is fixed in the adducted position the voice will be quite good, but if it is fixed in the abducted position the characteristic feature is air wastage with a breathy voice.

The diagnosis is made by the appropriate laboratory tests for rheumatoid arthritis and the degree of fixation is established by attempting to mobilize the joint during direct laryngoscopy. This latter step is necessary to differentiate arthritis from a recurrent laryngeal nerve paralysis.

In the acute phase treatment is symptomatic and it may be necessary to add steroids to the analgesic medication. A close watch should be kept on the patient in case respiratory obstruction occurs from oedema. In the chronic phase no treatment is necessary if the position in which the joint is fixed is in adduction so that there is a good voice. If it is not, then some form of cordopexy or arytenoid operation should be performed (*see* Chapter 38, p. 189).

PERICHONDRITIS OF THE LARYNX

Because of the number of cartilages involved in the make-up of the laryngeal framework it is not unusual to find perichondritis as a response to many disease processes. Formerly it used to be seen not uncommonly as part of the symptom complex of tuberculosis, lupus and syphilis, and it was also seen in typhoid, diphtheria and acute infectious fevers. Nowadays it most commonly presents as a complication of irradiation for carcinoma of the larynx. Should the larynx become swollen, painful and oedematous after radiotherapy the problem is to know whether or not there is a recurrence of the tumour

concealed by the oedema. This is a very difficult situation to manage because to take deep biopsies in a search for cancer, and to expose cartilage in so doing, is a certain way to make the perichondritis worse. It is possibly better to treat the perichondritis with ampicillin and diuretics, and to delay a biopsy for as long as possible. If the larynx is still swollen and useless 6 months after radiation therapy a total laryngectomy should be performed even if the biopsies are negative. Sections of the excised larynx in such a case will almost certainly show evidence of residual cancer.

MYCOSIS OF THE LARYNX

Three main fungi are found, causing the following conditions:

- 1. Blastomycosis.** This is the most common and may attack the larynx primarily. It is found in grain workers in South America who are exposed to the fungus. The disease is a chronic granuloma and presents in the early stages as an intense inflammation of the larynx colouring it very dark red. There is a grey nodular surface with isolated yellow nodules and string-like secretions. Diagnosis is made by bacteriological examinations and biopsy. The latter is the more important since coexisting blastomycosis of the lungs may give a positive bacteriological finding. The finding of blastomycosis in the biopsy tissue is the only absolute diagnostic feature. It is treated by a prolonged course of a saturated solution of potassium iodide given in increasing doses from 0.3 ml daily until a maintenance dose of 2 ml is reached. The ultimate prognosis depends upon the state of the lungs.
- 2. Actinomycosis.** This is due to the actinomyces organisms and the source is usually animal hides. It is very rare in the larynx and presents as a yellow granulomatous tumour with associated glandular involvement. Treatment is by penicillin, but the prognosis depends on the response of the pulmonary lesion.
- 3. Leptothricosis.** This is due to the *Leptothrix buccalis* fungus and is associated with bad dental hygiene. It usually occurs at the base of the tongue, but it may involve the larynx where it produces small, white areas in otherwise healthy mucosa. The condition has to be differentiated from keratosis of the larynx and is not dangerous. Potassium iodide may be given as for blastomycosis.

SCLEROMA OF THE LARYNX

This disease is prevalent in Poland and other East European countries and is not unknown in Egypt and India. It starts in the nose and oral cavity and spreads downwards to involve the pharynx and larynx. The typical lesion is in the subglottic region and takes the form of a smooth red swelling covered by crusts. The patient complains of nasal obstruction followed later by hoarseness, wheezing and stridor. Diagnosis is made by biopsy when plasma cells and hyaline bodies are seen in granulation tissue together with the diagnostic Mikulicz cells which are large cells looking like enormous fat deposits. If it is untreated the condition progresses to laryngotracheal stenosis. The first line of treatment is streptomycin with steroids added if there is a danger of stenosis.

THE LARYNX, BRONCHI AND OESOPHAGUS

LEPROSY

The larynx is involved in less than half the cases of leprosy. The epiglottis and ary-epiglottic folds become infiltrated and nodular, and later the lesions ulcerate. Finally, scarring and contraction occur. Biopsy of the swelling will differentiate the condition from tuberculosis and syphilis. Treatment is by a course of sulphone which must be maintained for years.

CHAPTER 35

TRACHEOSTOMY

There has been confusion between the terms tracheotomy and tracheostomy which have in the past been used indiscriminately. Etymologically, tracheotomy means making an opening into the trachea, while tracheostomy means converting this opening to a stoma on the skin surface. Thus in the operation of tracheostomy the actual opening of the trachea is tracheotomy. Tracheostomy is one of the earliest operations ever described, and there is evidence that it was performed by the Egyptians in Biblical times.

FUNCTION OF A TRACHEOSTOMY

A tracheostomy is performed to relieve an upper airway obstruction, to facilitate bronchial toilet, to decrease dead space, to assist ventilation and as an elective procedure in head and neck surgery.

Relief of Upper Airway Obstruction. An obstruction of the airway may occur with dramatic suddenness as in the case of an inhaled, impacted foreign body in the larynx. There may be a moderate urgency in acute inflammatory lesions, such as acute epiglottitis, acute laryngotracheobronchitis or the acute laryngeal oedema of the child burned by drinking from a boiling kettle. There may be the slowly progressive respiratory embarrassment, for example in laryngeal cancer which is being treated by irradiation.

Bronchial Toilet. A basic failure in respiration may require that the patient receive assistance by removing his bronchial secretions. This may occur in a central depression of the respiratory centre from coma, cerebrovascular accidents, head injury or drug overdosage; or there may be neurological problems such as poliomyelitis, cervical cord lesions, polyneuritis, myasthenia gravis or tetanus.

Dead Space. Dead space may be reduced by 30–50 per cent thereby improving respiratory efficiency, and thus assisting the patient who has to rely on his own respiratory efforts rather than on assisted ventilation.

Assisted Ventilation. Should assisted ventilation be required this may be started with an endotracheal tube for 72 hours. While there is still no absolute proof that intubation which has been prolonged for more than 72 hours causes laryngotracheal damage, it is probably safer to do a tracheostomy at this stage and to continue the intermittent positive-pressure ventilation by this means. Should the patient not have improved sufficiently in the first 3 days with an endotracheal tube, it becomes difficult to assess how much longer the tube must be worn, and each 24 hours increases the risk of serious laryngotracheal damage.

Elective Operation. In nearly all cases of major head and neck surgery it is safer to perform an elective tracheostomy, not only to maintain the airway but to protect it against haemorrhage.

TYPES OF TRACHEOSTOMY

1. **Elective Temporary Tracheostomy.** This is performed as a planned procedure, usually under general anaesthesia, as a temporary stage in the patient's management. Examples of this are in the management of recoverable coma or of inflammatory lesions such as acute epiglottitis, or as a safety measure in a head and neck malignancy operation.
2. **Permanent Tracheostomy.** In an operation involving removal of the larynx, such as a laryngectomy or laryngopharyngectomy, the tracheal remnant is brought out on to the surface as a permanent mouth to the respiratory tract.
3. **Emergency Tracheostomy.** Nowadays there ought to be very few indications for this—on occasion a patient will be seen first with a large laryngeal tumour and require an emergency tracheostomy; this, however, is a situation that would only occur once every 2 or 3 years. To have to do an emergency tracheostomy in conditions such as acute epiglottitis, respiratory failure, coma, etc. is a sign of poor forward planning in the management of the patient. It is usually done under local anaesthetic if it is a true emergency and this, to the inexperienced, is a difficult, dangerous operation.

TRACHEOSTOMY TUBES

1. **The Silver Jackson Tube.** This is used for a temporary tracheostomy and consists of an outer tube and an inner tube which can be cleaned without disturbing the outer tube. It is inserted over an introducer.
2. **Portex Tubes.** These are also widely used and can be used cuffed or uncuffed. No introducers are used with them. There is no inner tube, but they are almost non-irritant.
3. **Radcliffe Tube.** This is a right-angled tube, not used with an inner tube, which is useful in a patient with a thick, fat neck.
4. **Durham's Tube.** This is a tube with an adjustable flange and can be made to fit any size of neck.

TECHNIQUE OF TRACHEOSTOMY

This is usually done with the patient intubated and positioned with a sandbag underneath the shoulders in order to extend the neck and to pull as much trachea as possible into the operative site. A horizontal incision is marked with methylene blue two fingers breadth above the sternum (*Fig. 76*). The incision is carried through the skin and subcutaneous tissue down to the strap muscles. These are separated in the midline, held aside with two retractors and the prevertebral fascia identified. This is then incised in a vertical direction, avoiding the inferior thyroid veins, and the thyroid isthmus is identified (*Fig. 77*). This latter structure is freed from the trachea, clamped, divided and oversewn with 3/0 silk. The tracheal rings are then seen and at this point the cricoid should be deliberately identified since to make an incision through the cricoid or first tracheal ring will cause laryngeal collapse and stenosis. A vertical incision is made through the third and fourth rings and a semicircle of tracheal wall is removed from either side (*Fig. 78*). The appropriately-sized tracheostomy tube is inserted and the wound closed, but not tightly, with 4/0 silk sutures.

TECHNIQUE OF LARYNGOTOMY

Our views on emergency tracheostomy have been expressed previously. If an inexperienced doctor is called to this situation he should do a laryngotomy to obtain an airway which will save life until an anaesthetist can come and intubate the patient, or a more experienced surgeon can come and do a tracheostomy. The first step in a laryngotomy is to palpate the cricoid and then

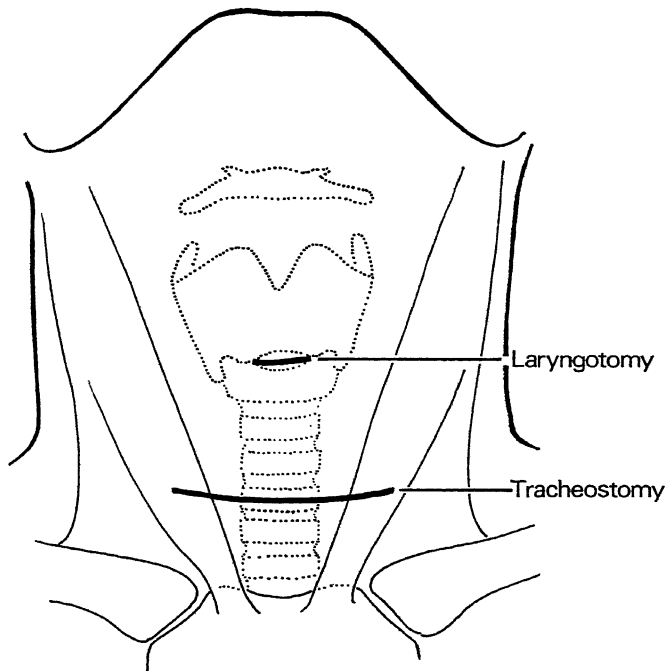


Fig. 76. Incision for elective tracheostomy and laryngotomy.

the lower border of the thyroid cartilage. In the notch between the two is the cricothyroid membrane and with the head extended this lies just underneath the skin. The space is stabbed horizontally with the blade of a knife of at least No. 10 size and the incision is lengthened. The blade is then withdrawn and the handle of the knife inserted and turned at right angles to open an airway. Special 'all in one' instruments exist to do this procedure, but it is normally such an emergency that a knife is usually the most readily available instrument.

POSTOPERATIVE CARE

1. Nursing. A nurse who understands the care of tracheostomy patients should be in attendance for the first 48 hours and should carry out the care with

sterile precautions. She should wear a mask. She should make sure that the patient has a 'magic slate' on which to write and he should have a bell with which to summon assistance. The 'magic slate' is the device on which

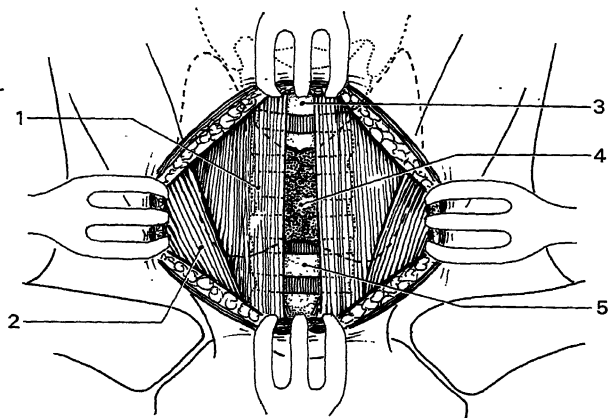


Fig. 77. Tracheostomy—to show structures exposed. 1, Sternohyoid muscle; 2, Sternomastoid muscle; 3, Cricoid cartilage; 4, Isthmus of thyroid gland; 5, Trachea.

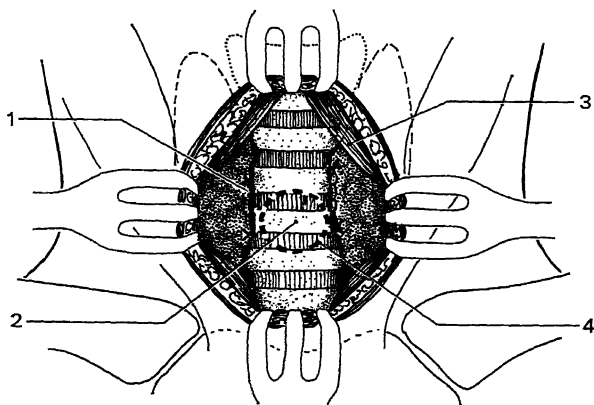


Fig. 78. Tracheostomy—site of incision in trachea. 1, Isthmus of thyroid gland divided and ligated; 2, Third ring of trachea; 3, Sternohyoid muscle retracted; 4, Site of incision in trachea.

messages may be written and erased by pulling out the plate under the cellophane surface.

2. Fixation of the Tracheostomy Tube. It is essential not to tie the tube too tight and not to tie the knot in a bow since this may come undone. If it is tied with tapes the head should first be flexed to relax the neck muscles. If tapes

are tied with the head extended the tube may become loose on flexion when the muscles relax. The safest way is to stitch it to the skin with 2/0 silk.

3. Removal of Secretions. Excess secretions occur after a tracheostomy since the trachea is exposed to cold dry air and the tube acts as a foreign body and stimulates the formation of secretions. During the first 48 hours secretions should be removed half-hourly and thereafter every 1 or 2 hours. The nurse should wear sterile gloves. A sterile rubber catheter is attached to one limb of the Y-shaped plastic connector from the suction apparatus and the sterile catheter is inserted into the tracheostomy tube by means of sterile artery forceps. She then places her thumb over the open limb of the Y-shaped connection to close the air entry into the suction apparatus and withdraws the catheter. This manoeuvre should not take more than 10 seconds or else the patient will be rendered hypoxic. This is repeated until no further secretions remain.

4. Humidification. This is necessary to prevent crusting of the secretions and is done most simply by instilling normal saline down the tracheostomy tube. Before suction 5 ml of normal saline are dripped down the tube, suction is then performed and afterwards 5 ml of normal saline are dripped down the tube and left in the tracheobronchial tree.

5. Changing the Tube. Tracheostomy tubes should not be disturbed for the first 48-72 hours, but thereafter the tube is changed daily and cleaned at regular intervals. On inserting the tube it is essential to check that it is in the trachea and not lying anterior to it in the mediastinum. If this happens respiration will not be heard through the tube and respiratory embarrassment may recur.

6. Care of the Inflatable Cuff. When a cuff is blown up to occlude any leaks in the airway the pressure must be higher than the systolic blood pressure. This means that the area of tracheal wall with which it is in contact is liable to ischaemic necrosis if the cuff is inflated for more than a few hours. It should therefore be let down every half hour when the nurse attends the patient for suction.

7. Dressings. Waterproof squares are made which protect the surrounding skin from maceration from secretions and the movement of the tube edges.

8. Removal of the Tube. This presents no problem in the adult—the tube is removed once the patient can sleep for a night with the tube corked. The wound should then be freshened and sutured to prevent ugly scar formation. In children it is very much more difficult to remove a tracheostomy tube that has been present for more than a few days. It was thought at one time that this difficulty was psychological, but it is now thought that the subglottic region above the trachea acts as a sump and that subglottic oedema occurs. This is avoidable by using the Rees-Pracy tracheostomy tube which is fenestrated and valved so that when the patient exhales, air goes up through the larynx thus blowing out any secretions which are stagnating in the subglottis.

COMPLICATIONS

✓ **Surgical Emphysema.** This is occasionally found in the immediate post-operative period and presents as a swollen area around the root of the neck and upper chest which displays crepitus on palpation. It is due to overtight

suturing of the wound and is not dangerous unless it leads to mediastinal emphysema and cardiac tamponade.

2. Blockage of Tracheostomy Tube. This can occur if there is lack of humidification or poor toilet. It is more likely to occur with Portex tubes than silver tubes, but presents little problem if it is recognized in time. The tube should be changed and if crusts have occurred down the trachea they must be removed by bronchoscopy.

3. Tracheal Erosion and Haemorrhage. The initial erosion can be caused by using a tube with the wrong curvature or by passing the tube anterior to the tracheal opening to lie on the anterior tracheal wall. A tube in this position may erode the innominate vein with almost invariably fatal results.

4. Dysphagia. This is fairly common in the first few days after tracheostomy. In normal swallowing a positive subglottic pressure is created by the closing of the vocal cords—which is why one cannot speak during swallowing. This is not possible with a tracheostomy tube in place, and thus swallowing is incoordinate. Another reason for dysphagia is that if an inflatable cuff is blown up it will press on and obstruct the oesophagus.

5. Difficult Decannulation. The problems of decannulating children have been mentioned earlier; on occasion this is due to psychological factors, but on other occasions it is due to subglottic oedema. If infection and necrosis of cartilage occur the cartilaginous tracheal rings soften, and when the tube is removed the lumen collapses causing respiratory obstruction and difficulty in decannulation. Another cause of this is tracheal stenosis due to infection because too much anterior tracheal wall has been removed at the operation, or to cricoid collapse following a high tracheostomy.

TRACHEOSTOMY VERSUS INTUBATION

If a patient requires assisted ventilation then either a tracheostomy tube or an endotracheal tube supplies an adequate route for this. Similarly, if a patient requires an airway to by-pass an obstruction then either method is equally good, given the proviso that an endotracheal tube can be inserted past or through the obstruction.

In spite of the relatively rare complication of tracheal stenosis due to an indwelling endotracheal tube it is probably safer not to leave one in situ for more than 72 hours. In considering this oft-repeated complication of intubation it is prudent to consider the list of complications of tracheostomy listed above.

In the emergency situation, which with careful patient care should not be allowed to occur, given an equally skilled anaesthetist and surgeon, intubation will be the quicker procedure. In the hands of unskilled doctors in the emergency situation, both of the procedures are dangerous and a laryngotomy is quicker and safer. Generally, however, the procedure adopted depends upon which one the attending doctor can do better, more safely and quicker, and this will usually be intubation.

The use of hydrocortisone in inflammatory states had decreased the need for tracheostomy in an illness such as acute laryngotracheobronchitis. This is an effective and safe method and occasionally has to be complemented by intubation for a short time. Very few patients have died from an overdose of intravenous hydrocortisone. Since this problem usually arises in children and

TRACHEOSTOMY

since tracheostomy in small children is difficult owing to the anatomy, intubation is the method of choice.

In summary, therefore, one can say that while the old adage stated that 'the time to do a tracheostomy is the time you first think of it', the newer adage might be 'when you think of doing a tracheostomy, intubate, and think again'.

CHAPTER 36

BENIGN LARYNGEAL TUMOURS

Benign laryngeal tumours are not common and are usually diagnosed by the pathologist because most of them appear as solitary masses on the vocal cords causing hoarseness.

FIBROMA

This connective tissue tumour can arise from any laryngeal structure but mainly occurs on the dorsum of the vocal cords. It presents as a sessile reddish-grey smooth mass (*Plate VII, 4*) which can move downwards between the cords on inspiration. The mass is removed at direct laryngoscopy as an excision biopsy. Recurrence is rare. *Neurofibroma* may also occur and is dealt with similarly.

PAPILLOMA

1. *Single*. This usually arises from the free edge of a vocal cord in adults (*Plate VII, 5*). Histologically it is often a squamous-cell papilloma. It is liable to recurrence and may undergo malignant change. The papilloma should be removed at direct laryngoscopy, and the patient should be followed up for 5 years because of the danger of recurrence and malignant degeneration.

2. *Multiple*. These are described more fully in Chapter 40. They occur at any age from birth to 5 or 6 years and although they are said to disappear at puberty this is the exception rather than the rule. They may present as scattered single papillomata all over the larynx or as a huge exuberant mass causing respiratory obstruction. They are not pre-malignant, but the larynx may be severely damaged from repeated removals. The papillomata can become implanted into the trachea and bronchi. Patients with this condition should be followed up at monthly intervals and the papillomata removed whenever they appear. In most instances this prevents the papillomata building up to cause respiratory obstruction which would require emergency laryngoscopy and tracheostomy.

GRANULOMA

1. **Intubation Granuloma**. This is occasionally seen after a traumatic blind intubation but it most commonly occurs after a long operation on a lightly anaesthetized patient where the arytenoids and posterior ends of the vocal cords vibrate against the tube. This causes abrasion and subsequent granulation tissue formation. The granuloma should be removed locally and it should not recur.

2. **Pyogenic Granuloma.** This can occur anywhere in the head and neck region and often resembles a carcinoma. It is basically an infected granuloma and it does not recur after adequate local removal. Bleeding and ulceration also occur.

3. **Granuloma Gravidarum.** This is a pyogenic granuloma occurring during pregnancy. It is better to leave it alone until the pregnancy is over.

GRANULAR-CELL MYOBLASTOMA

This has a characteristic histological appearance of pseudo-epitheliomatous hyperplasia. The tumour is always sessile and can usually be removed totally at direct laryngoscopy. It is now believed that it is not a malignant or a pre-malignant tumour.

CHONDROMA

This is a rare tumour affecting almost exclusively the cricoid cartilage. It is very slow growing and presents a smooth swelling which encroaches into the lumen of the larynx (*Fig. 79*). Occasionally the difference between benign

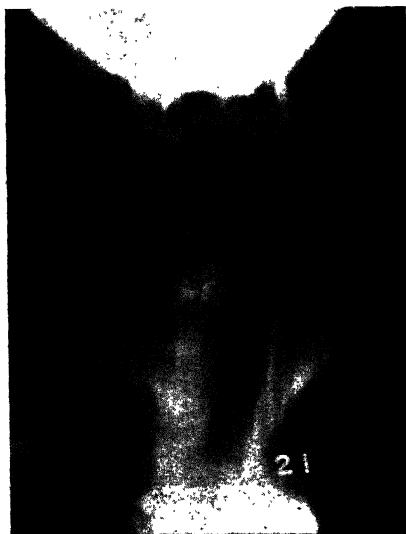


Fig. 79. Tomograph of larynx of a man, aged 70 years, with a chondrosarcoma of thyroid cartilage showing considerable narrowing of the airway.

chondroma and chondrosarcoma is difficult to make. If the diagnosis is made early and if local removal can be accomplished while preserving the ring of the cricoid cartilage the condition may be kept under control, but if it is not possible to preserve the ring of the cricoid the condition is probably sarcomatous and a laryngectomy should be performed.

SALIVARY GLAND TUMOURS

Pleomorphic adenoma and less commonly oxyphil-cell adenoma (oncocytoma) may occur in any salivary tissue in the supraglottis. The most usual site is the false cord and wide local removal is sufficient to cure the condition.

HAEMANGIOMA

This vascular tumour is most commonly diagnosed in the first 2 years of life, and may present on the cord or in the subglottis. Since spontaneous resolution often occurs no treatment need be undertaken in early childhood unless there is respiratory obstruction. If the growth is confined to the cord it may be removed at direct laryngoscopy.

AMYLOID

It is not only as a concomitant feature of a debilitating illness that amyloid disease of the larynx occurs. Although uncommon it has to be borne in mind in the differential diagnosis of the solitary laryngeal mass. It is removed locally, but it may require more radical surgery if it recurs.

LARYNGOCELE

Lower animals have air sacs and in some humans remnants of these remain and are situated in the laryngeal ventricle. If one expands to form a laryngocele it either grows outwards through the thyrohyoid membrane and appears in the neck (external laryngocele) or it extends upwards and presents as a swelling in the vallecula (internal laryngocele). The presentation is often an intermittent neck swelling with or without hoarseness. On other occasions if the neck of the sac is blocked the sac becomes infected and it presents as a pyocele. Laryngocele is often said to occur most commonly in trumpet players and glass blowers but a review of the literature shows this to be false. The relationship is that if a person has a residual air sac that is liable to form a laryngocele this will occur when pressure is put upon it by blowing. The blowing *per se* does not cause the laryngocele, it only brings it to the patient's attention. It may be diagnosed by the characteristic radiographic appearance (*Fig. 80*) when the large translucent sac is seen and is made larger by the Valsalva manoeuvre. Treatment is to approach the sac from the neck, dissect it free, remove the upper half of the thyroid lamina, locate the neck of the sac, ligate it and remove the laryngocele. The repair line is reinforced by the strap muscles of the neck.

CYSTS

An internal laryngocele may resemble a supraglottic cyst but it is diagnosed and differentiated by the typical radiographic appearances. A cyst occurs mainly in the supraglottis where there are a large number of mucous glands and the mouth of one of these may become blocked to cause a mucous retention cyst. Treatment is to uncap the cyst at direct laryngoscopy hoping that marsupialization will be permanent.

VOCAL CORD POLYPUS

Although this is probably the most common laryngeal mass its aetiology is not understood. The polyp may arise from an area of unresolved infection or it may be a response to traumatic abrasion or haematoma formation. It occurs almost exclusively on a vocal cord and arises from the subepithelial connective



Fig. 80. Laryngocele. Radiograph showing a typical air-filled cavity.

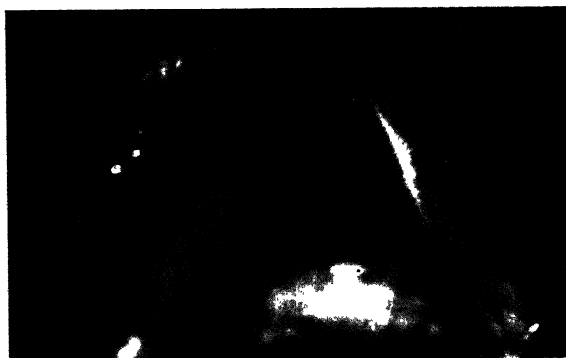

Fig. 81. Laryngeal polypus. Microphotograph of polypus showing below left vocal cord.

tissue of Reinke's layer (*Fig. 81*). A single vocal cord polyp must be differentiated from the polypoidal swelling of the vocal cords which is part of the chronic laryngitis spectrum (p. 161). A single polyp is removed at direct laryngoscopy and seldom recurs.

CHAPTER 37

CANCER OF THE LARYNX

The larynx is divided, for purposes of tumour classification, into three regions—supraglottis, glottis and subglottis (*Fig. 82*). The *supraglottis* includes the laryngeal surface of the epiglottis, ary-epiglottic folds, arytenoids, false cords and ventricle. The lingual surface of the epiglottis and vallecula are in the oropharynx. The *glottis* comprises the vocal cords and the anterior and posterior commissures.

The lymphatic drainage of the larynx (*Fig. 83*) is compartmentalized into the above regions. The glottis has virtually no lymphatic drainage and so acts as a watershed. The area above the vocal cords drains upwards via the superior lymphatic pedicle to end in the upper deep cervical chain. The subglottis drains both to the prelaryngeal and paratracheal glands.

Tumours of the larynx are classified according to the U.I.C.C. T.N.M. system, but it is beyond the scope of this book to detail the system. It is of little value in a tumour with such a relatively low incidence as laryngeal cancer. It is of much more value to be acquainted with the surgical pathology and behaviour of cancer in the various laryngeal regions.

Ninety-nine per cent of laryngeal cancer is squamous carcinoma and it is much more common in males and smokers.

SUPRAGLOTTIC CANCER

PATHOLOGY. These tumours usually present in one of three ways: (*a*) as a large exophytic tumour on the laryngeal surface of the epiglottis; (*b*) as a relatively small discrete growth on the ary-epiglottic fold; and (*c*) as an isolated ulcerative growth on the false cord.

The supraglottic space has a rich lymphatic drainage and a high proportion of these tumours spread to lymph nodes. Roughly 1 in 3 epiglottic tumours, 3 out of 4 ary-epiglottic tumours and about half the false cord tumours metastasize. Nearly all these tumours will invade the pre-epiglottic space but only a small proportion will involve the vocal cords until late in the course of the disease. This fact makes partial laryngectomy a distinct possibility in supraglottic cancer.

SYMPTOMS. These tumours do not affect the vocal cord and so rarely present with hoarseness. If the tumour is very large there will be some muffling of the voice. Occasionally the ary-epiglottic tumours will present with painful dysphagia or on account of a lump in the neck from a metastatic gland. In other words, these tumours are often diagnosed late since the supraglottis is not a region to give rise to early symptoms. Sometimes, in fact, tumours in the supraglottis are discovered accidentally by an anaesthetist during intubation for another procedure.

INVESTIGATIONS. The two key areas in assessing these tumours are the neck and the vocal cords. The neck should be carefully palpated because there is a high incidence of glandular metastasis and the presence of palpable cervical nodes would necessitate a radical neck dissection. If the tumour has spread to the vocal cords no possibility exists of doing a partial laryngectomy, so they must be closely examined for evidence of spread. This is best done at direct laryngoscopy and biopsy but if the tumour is exophytic and the laryngoscope

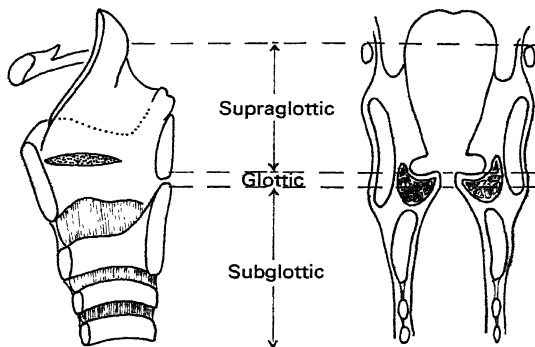


Fig. 82. Divisions of the larynx.

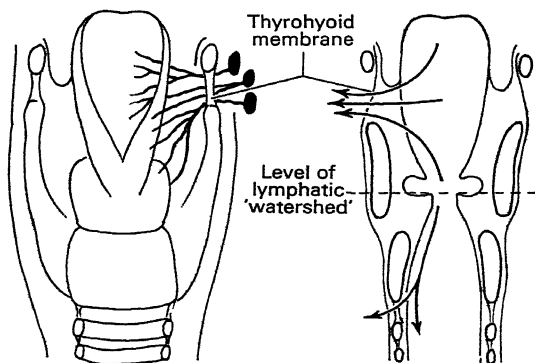


Fig. 83. Lymph drainage of larynx.

cannot visualize the whole of the cord, a laryngogram will be of great assistance in assessing the site and mobility of the vocal cords.

TREATMENT. Before the evolution of partial laryngectomy, patients with laryngeal cancer could only be offered two alternatives—total laryngectomy or radiotherapy. For smaller tumours most surgeons rejected the idea of the rather mutilating total laryngectomy and used primary radiotherapy, reserving total laryngectomy for recurrences. With this policy, surgery was only about

10 per cent better than radiotherapy but the 50 per cent who were cured by radiotherapy retained a good voice.

Supraglottic laryngectomy (*Fig. 84*) was fully developed in the 1960s and it involves removing the entire supraglottis, from the vallecula to the ventricle, and joining the lower half of the larynx to the base of the tongue using a perichondrial flap (*Fig. 85*). The resultant proximity of the vocal cords to the base of the tongue makes swallowing a little difficult so the mouth of the oesophagus has to be widened by a cricopharyngeal myotomy. This operation

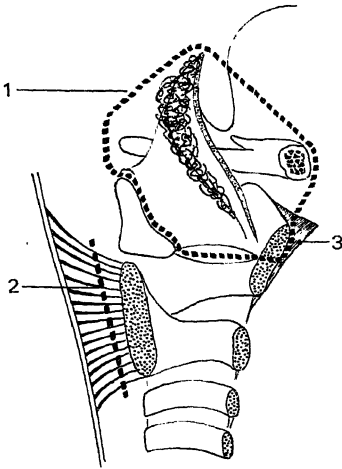


Fig. 84. 1, Showing the area of larynx to be removed; 2, Site of the cricopharyngeal myotomy; 3, Perichondrial flap.

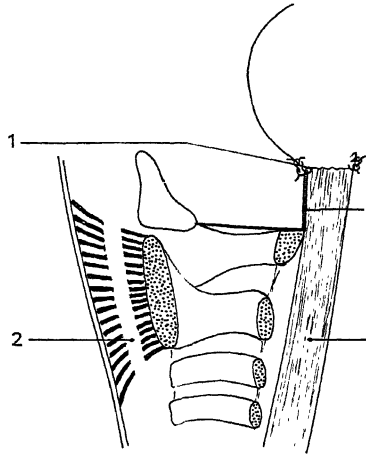


Fig. 85. After removal of the specimen the perichondrial flap (3) is sutured to the base of the tongue (1) and supported by the strap muscle layer (4). A cricopharyngeal myotomy is done over a distance of 5 cm (2).

allows the patient to retain a normal voice and gives about an 80 per cent 5-year cure (i.e. 30 per cent better than radiotherapy). If the tumour involves the tongue, the pyriform sinus or the vocal cords the operation should not be done, nor should it be done if the patient is over 65, or if he has a bad chest. In all of these conditions the postoperative dysphagia will be of such severity that repeated aspirations may be fatal.

At one time the accepted procedure was to do a radical neck dissection in every patient on the assumption that the high incidence of metastatic glands made it likely that most patients had at least non-palpable metastases. Time showed, however, that the result of this policy gave no advantage over doing a radical neck dissection only in those cases with palpable glands, or doing a radical neck dissection as a second stage if and when glands became palpable.

GLOTTIC CANCER

PATHOLOGY. The glottis extends from the anterior to the posterior commissure. It consists of both cartilage and membrane—cartilage forming the posterior

half and membrane the anterior half of the glottis. The length of the adult male vocal cord is about 2 cm. This should mean that if a cancer is confined to the vocal cord, it is less than 2 cm at its widest point and thus should be eminently curable.

Tumours of this region present as two distinct types: (a) A small tumour limited to the vocal cord (*Plate VIII, 1*). (b) A large tumour involving the glottis, supraglottis and subglottis—the so-called transglottic tumour. This carries a high incidence (75 per cent) of lymph node metastases because it involves both the rich lymphatic fields of the supraglottis and subglottis. These tumours also spread to the strap muscles (5 per cent) and the thyroid gland (10 per cent).

SYMPTOMS. Both tumours present with hoarseness. Why one should be seen at a very much later stage than the other is unknown, but, in theory, if every

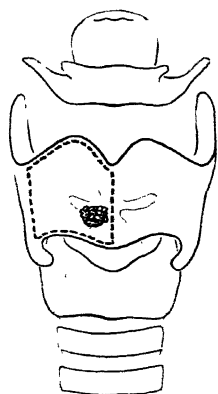


Fig. 86. Hemilaryngectomy. Showing the outline of the perichondrial flap pedicled posteriorly.

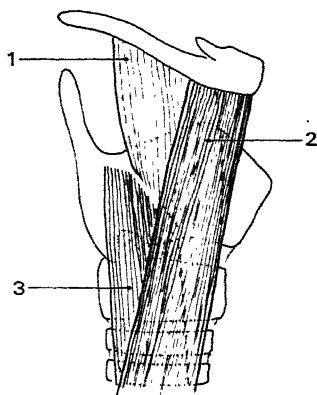


Fig. 87. Hemilaryngectomy. 1, Thyrohyoid muscle; 2, Sternohyoid muscle; 3, Sternothyroid muscle.

patient with hoarseness had the larynx examined within the first month then all tumours should be seen at an early stage. This is not the whole story, however, because the length of history of the transglottic variety is about the same as the glottic group. Occasionally the transglottic group will present with a gland in the neck in addition to hoarseness.

INVESTIGATION. As mentioned previously, if a glottic tumour is confined to the vocal cord it is less than 2 cm in length and thus should be readily curable with radiotherapy. While this gives good results it is by no means 100 per cent successful. One of the reasons for the failures is that radiotherapy does not sterilize cartilage well. Therefore in assessing the tumour it is essential to gauge whether cartilage is involved or not. The cartilages that could be affected are the arytenoid, by way of the vocal process, and the thyroid cartilage at the anterior commissure. At laryngoscopy it is also essential to assess the degree of mobility of the vocal cord, and to search for any extension into the subglottis or supraglottis. It is unlikely that there will be any neck glands palpable in the glottic tumours but a high chance exists of such

metastases in the transglottic group. Since subglottic extension is so important in the prognosis all cases in the transglottic group should have tomograms or laryngograms.

TREATMENT. If no cartilage is involved a cure should be achieved with radiotherapy in over 90 per cent of cases. If cartilage is involved radiotherapy may also be used and an expectant policy adopted. If no recurrence occurs, the patient will have a good voice, but if there is a recurrence surgery will be necessary. Either a hemilaryngectomy or a total laryngectomy may be offered. A hemilaryngectomy (*Figs. 86-89*) involves removing half of the thyroid cartilage with the false and true vocal cords, part of the supraglottis and the upper half of the cricoid cartilage. The resulting gap is closed by the strap muscles fashioned so as to form a new fixed vocal cord. The results of this

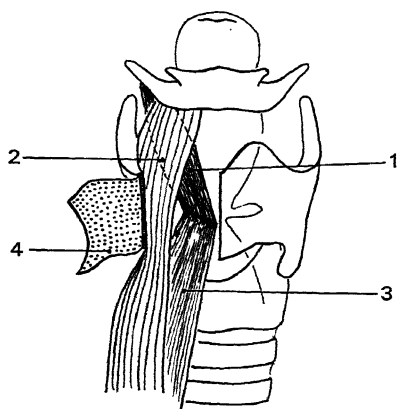


Fig. 88. Hemilaryngectomy. After the hemilarynx is removed the muscles are repositioned as shown. 4 is perichondrial flap.

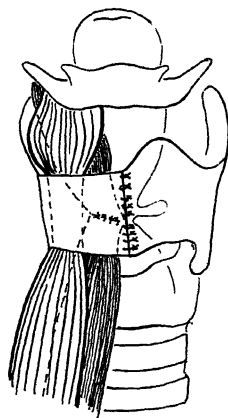


Fig. 89. Hemilaryngectomy. The perichondrial flap is replaced and sutured to the remaining lamina.

as a primary operation for glottic tumours affecting cartilage are better than those from radiotherapy. If a hemilaryngectomy is used as a salvage procedure after failed radiotherapy the results will be poorer than if it had been used as a primary treatment. It does, however, give the patient a chance of keeping some sort of voice instead of having to learn oesophageal speech after a total laryngectomy.

TRANSGLOTTIC TUMOURS

These seldom present until they are large and have palpable cervical gland metastases. The most satisfactory treatment is total laryngectomy with a radical neck dissection if glands are palpable. A total laryngectomy (*Fig. 90*) involves removing the hyoid, thyroid and cricoid cartilages and several tracheal rings. When this is removed the pharynx is left open from the base of the tongue to the mouth of the oesophagus, and this is repaired in layers to form a new

gullet. The upper airway is detached from the lower airway by the removal of the larynx and there is no way of joining them up again. The trachea is therefore brought out on to the surface as a permanent end tracheostome (Fig. 91). It will never be closed, but most patients quickly adjust to life with a

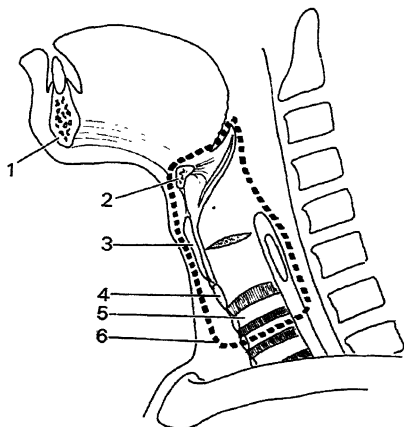


Fig. 90. Laryngectomy showing area to be removed. 1, Mandible; 2, Hyoid bone; 3, Thyroid cartilage; 4, Cricoid cartilage; 5, Trachea; 6, Line of excision.

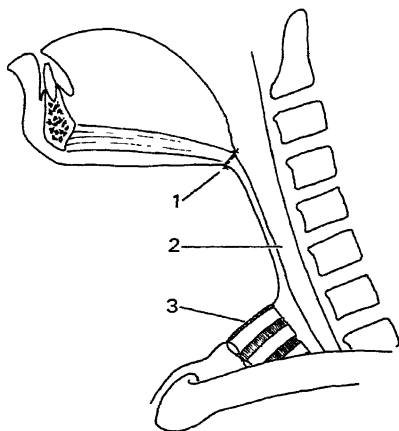


Fig. 91. Laryngectomy showing end result after removal. 1, Pharynx sutured to base of tongue; 2, Lumen of pharynx; 3, Permanent tracheostome.

permanent tracheostomy. After a few weeks they can dispense with the tracheostomy tube and conceal the hole with a collar and tie. With effective speech therapy instruction about 60 per cent will learn to speak again in a satisfactory manner using oesophageal speech. Once the technique has been mastered the patient produces a sound from the reconstructed gullet by

regurgitating air in the form of a 'belch'. Speech is produced by coordinated movements of lips, tongue, teeth and palate.

If the patient feels strongly about losing his larynx, radiotherapy can be offered as the primary treatment with total laryngectomy being reserved for the recurrences. This form of treatment gives poorer results and a higher complication rate especially with regard to fistula formation.

CARCINOMA-IN-SITU

This usually presents as a leucoplakia of the cord (p. 162). Unless there are signs of invasion, it is unwise to use radiotherapy for this tumour as it can be kept under control perfectly safely with vocal cord stripping repeated as often as required at microlaryngoscopy.

SUBGLOTTIC CANCER

PATHOLOGY. Again, this is predominantly a squamous-cell cancer and is more common in males who smoke. The subglottis is by far the rarest region to be affected by laryngeal cancer and this is fortunate because the results are so much poorer than in cancer of the glottis and supraglottis. The subglottis is a small area extending from the lower border of the cricoid to the under surface of the vocal cords. Cancer of the thyroid gland and the trachea can spread to involve the subglottis and cancers of the subglottis spread to the thyroid gland, in 20 per cent of cases, and to the trachea. Twenty per cent also involve the strap muscles of the neck and the same percentage gives rise to cervical node metastases. There are 6-8 paratracheal nodes in the mediastinum and these, too, may be involved by spread of subglottic cancer.

SYMPTOMS. If the vocal cord is involved early the presenting symptom is hoarseness but if the tumour is lower in the subglottis the patient will present with respiratory obstruction and a normal voice. These latter usually present as surgical emergencies.

INVESTIGATION. Examination must be made for cervical node metastases and to ascertain the extent of spread of the tumour. Since subglottic tumours may involve the thyroid gland this should be scanned. There is a higher proportion of second primary tumours in these cases and so particular attention should be paid to the chest X-ray to see if the patient has a second chest primary tumour.

TREATMENT. Neither radiotherapy nor surgery in the form of total laryngectomy gives good results in this tumour. As things stand at the moment it is advisable to give the patient primary radiotherapy and to reserve a total laryngectomy for any recurrence. At the same time the paratracheal nodes should be removed. In the future use will perhaps be made of planned combined radiotherapy and total laryngectomy, the patient receiving about 3500 r over a 2-week period, and then 2 weeks later having a total laryngectomy. In the case of a large subglottic tumour presenting with respiratory obstruction a case could be made for doing an emergency laryngectomy. If a tracheostomy is done as the emergency procedure, it will have to be placed so near tumour that there is a 60 per cent chance of the tumour implanting in the tracheal stoma unless the area is removed within 72 hours.

SOCIAL AND PSYCHOLOGICAL EFFECTS OF LARYNGECTOMY

If laryngectomy is advised there must be a very good reason for doing it. This means that the patient has to be told in some way that he has cancer. In this country the word 'cancer' is interpreted by the patient as a fatal disease that spreads all over the body and kills. Thus if the word 'cancer' is used it must be explained to the patient that it is unlikely to have spread anywhere else and that if local control can be obtained then the outlook is good. The distant metastasis rate is 2 per cent. This will mean that the larynx and possibly the neck glands must be removed. Most patients will be relieved when the diagnosis is discussed openly since the fear of the unknown is removed and if his doctor talks to him about it he is less apprehensive than if he feels that his doctor is avoiding the issue. During the discussion, however, the doctor must have an optimistic outlook. To lose the larynx and voice conjures various emotive words in the layman's mind such as 'dumb' and 'dummy'. If the loss of voice is compared to loss of sight or loss of hearing it may take on a different perspective.

Learning to speak again after a laryngectomy depends upon the teaching skill of the speech therapist. In the best hands about 25 per cent of patients never learn to speak again, but in areas where there are no skilled speech therapists then about 60 per cent of patients will never learn to vocalize. The basis of the new voice is oesophageal speech. Air is swallowed, belched up again and the sound made is converted into language by the lips, tongue, teeth and palate. If the patient cannot learn oesophageal speech he will have to use an electronic larynx. These are vibrators that make a 'buzz' like an electric razor, they are placed under the chin and by mouthing the words the patient can convert the 'buzz' to intelligible speech.

In recent years various operations have been designed to remake speaking tubes by joining the tracheal stump to the base of the tongue by means of skin flaps. These operations, however, have not realized the potential initially hoped for.

A laryngectomee will have a permanent tracheostomy but will soon be able to do without a tube. He will be able to wear a collar and tie or cravat with no embarrassment to respiration. He will not, however, be able to swim and must take care while bathing or showering.

Most laryngectomees can return to their work especially if they learn oesophageal speech. Since most of those who fail to learn oesophageal speech are over 60 years of age they may prefer to accept an early retirement in which they may enjoy reasonable health.

To someone with a larynx the thought of losing it may represent an intolerable mutilation. The author has performed over 100 such procedures and only 1 patient has committed suicide and another 2 have suffered severe reactive depression in response to what they consider an unacceptable change.

CHAPTER 38

VOCAL CORD PARALYSIS

Depending upon the cause, vocal cord paralysis may be unilateral or bilateral, complete or incomplete, giving four possible combinations, namely: (a) unilateral incomplete; (b) unilateral complete; (c) bilateral incomplete; and (d) bilateral complete. Each of these presents a different clinical picture and each requires a different management.

PATHOLOGY. The recurrent laryngeal nerve is the motor nerve to all the laryngeal muscles except the cricothyroid muscle which is supplied by the external branch of the superior laryngeal nerve. This latter muscle has an adductor effect on the vocal cords, and thus a lesion which spares the superior laryngeal nerve will leave the cord lying nearer the midline than one which paralyses both the recurrent and superior laryngeal nerves. This, in effect, means that a high lesion of the vagus nerve will leave the paralysed cord further from the midline than a paralysis of the recurrent laryngeal nerve.

Three positions of paralysed vocal cords are described: (a) paramedian; (b) intermediate; and (c) cadaveric. There is little point in differentiating between the first two as it is of little diagnostic significance and the difference is one of only a few millimetres. Reference will only be made therefore to the paramedian and the cadaveric positions.

Another factor which controls the position of the paralysed cord is the curious fact described by Semon—'in all progressive organic lesions of the centres and trunks of the motor laryngeal nerves, the fibres supplying the abductors of the vocal cords become involved much earlier than do the adductors'. What this means, in fact, is that a partial lesion will leave the cord in the paramedian rather than the cadaveric position. Neither Semon's Law nor the site of the lesion decide the position of the cord absolutely, but both are useful guides.

The most commonly affected nerve is the left recurrent laryngeal nerve due mainly to the high incidence of bronchial carcinoma.

AETIOLOGY. Vocal cord paralysis arises as a rule from remote causes. The lesions which affect *either vagus nerve* are: (1) tumours at the base of the skull, e.g. glomus jugulare tumours and nasopharyngeal carcinoma, (2) bulbar paralysis, (3) peripheral neuritis due to influenza, herpes or the Epstein-Barr virus, (4) high neck injuries, e.g. trauma or surgical complication of radical neck dissection, (5) metastatic glandular enlargement, (6) basal meningitis, and (7) vagal tumours, e.g. glomus vagale or neurilemmoma.

The lesions affecting the *left recurrent laryngeal nerve* include: (1) carcinoma of the bronchus, (2) carcinoma of the cervical or thoracic oesophagus, (3) carcinoma of the thyroid gland, (4) operative trauma from thyroidectomy, radical neck dissection, pharyngeal pouch removal, cricopharyngeal myotomy, ligation of a patent ductus and other cardiac and pulmonary surgery, (5)

mediastinal glands or tumour, e.g. Hodgkin's disease, (6) any enlargement of the left atrium, e.g. mitral stenosis, (7) peripheral neuritis, and (8) aortic aneurysm.

The lesions affecting the *right recurrent laryngeal nerve* are: (1) carcinoma of the thyroid gland, (2) operative trauma from thyroidectomy, pharyngeal pouch removal or myotomy procedures, (3) carcinoma of the oesophagus, (4) carcinoma of the apex of the right lung, (5) peripheral neuritis, and (6) subclavian aneurysm.

UNILATERAL COMPLETE PARALYSIS

As the cord will be in the cadaveric position (*Fig. 92*) the patient will be practically aphonic at the onset of the paralysis. In a matter of a week or two

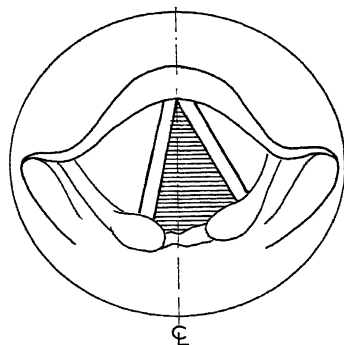


Fig. 92. Laryngeal paralysis. Mirror image to show left vocal cord in cadaveric position. (CL = centre line.)

the opposite cord will cross the midline on phonation and the voice will begin to return. Closure of the gap is aided by the mucosa of the normal cord becoming more lax. The paralysed cord later drops to a lower level than normal as the arytenoid falls forward. The quality of the voice at this time is harsh, warbling and breathy—a sound called diplophonia. It is almost impossible for a normal cord ever to meet a paralysed cord lying in the cadaveric position, especially posteriorly, and so a normal voice will never return unless some form of surgery is undertaken.

TREATMENT. Provided that the causative lesion is curable or is under control, this condition is worth treating because the voice is so poor and it can easily be improved. If the causative lesion is incurable it is kinder to leave the paralysis untreated unless the patient insists on surgery.

All treatment is directed to replacing the cord in the midline and this can be accomplished either endoscopically or by open operation.

1. *Teflon Injection.* Using a special syringe which delivers a measured amount of Teflon paste the paralysed cord is injected at direct laryngoscopy. It is important that this procedure is carried out under local anaesthesia so that the patient can phonate, and Teflon paste can be injected until a satisfactory voice is produced. Once Teflon is in place it cannot be removed, so that injection must be undertaken slowly.

2. *Crico-arytenoid Arthrodesis.* Using a laryngofissure approach (in which the thyroid cartilage is split vertically near the midline) the arytenoid is exposed, the crico-arytenoid joint opened and roughened, and the arytenoid (after being rotated medially) is arthrodesed to the cricoid by means of a Montgomery screw.

3. *Implant Procedures.* Via a laryngofissure approach the internal perichondrium of the thyroid cartilage lamina is stripped off and the space created is filled with either the sternohyoid muscle or with a free cartilage implant the cartilage being obtained from the upper half of the thyroid lamina.

BILATERAL COMPLETE PARALYSIS

This is the least common condition and both cords lie in the cadaveric position. There is aphonia which does not recover, and there is no possibility of developing a positive subglottic pressure. This means that the patient cannot control coordinated swallowing and food is inhaled, a situation further compounded by an inability to produce a good cough.

TREATMENT. Nearly all patients suffer from bronchopneumonia and will require a tracheostomy for removing pulmonary secretions and debris. The swallowing and inhalation problem is not helped by either Teflon injections or cricopharyngeal myotomy. If the situation is severe it may be necessary to do a total laryngectomy. In cases requiring this form of treatment the larynx and upper trachea (i.e. the trachea above the tracheostomy tube) will be oedematous and infected because they will have been acting as a sump.

UNILATERAL INCOMPLETE (ABDUCTOR) PARALYSIS

This paralysis, in which one vocal cord is fixed in the paramedian position (*Fig. 93*), is most commonly due to a bronchial carcinoma at the left hilum.

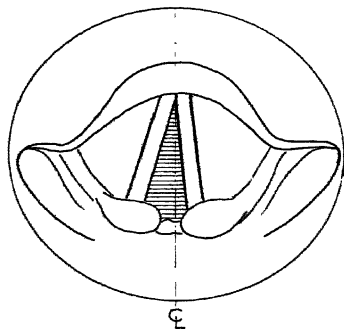


Fig. 93. Laryngeal paralysis. Mirror image to show left vocal cord in paramedian position. (CL = centre line.)

Every patient who is discovered to have such a paralysis in the absence of any other discoverable cause must be regarded as having a left-sided bronchial carcinoma until proved otherwise. Often it takes many months for such a carcinoma to come to light at radiography and so early bronchoscopy with

cytology and carinal biopsy must always be performed. If a carcinoma causing a nerve paralysis is discovered it is generally considered to be inoperable although, if it is small, other treatment methods may have a better than usual chance of success.

TREATMENT. No treatment of the paralysed cord is generally indicated because the voice problem is minimal and the other cord usually compensates.

BILATERAL INCOMPLETE (ABDUCTOR) PARALYSIS

This lesion is not common. Both vocal cords lie in the paramedian position, and sooner or later every patient with this condition will have stridor. The time of onset of the stridor depends generally upon the use to which the larynx is put. For example, a thin old lady who is in the house all day will not have stridor unless she gets laryngitis, but a well-built active man will have stridor on any moderate exercise, such as climbing stairs. In all cases the voice is acceptable, and in a few cases it is virtually normal.

TREATMENT. Given the two facts of stridor and a good voice, treatment must be tailored to the needs of the individual patient. Basically, a permanent tracheostomy in which a speaking tube (a valved tracheostomy tube) is worn relieves the patient both from stridor and from the danger of respiratory obstruction (and the anxiety which is engendered by this possibility). The disadvantage of this is the aesthetic fact of a hole in the neck with a tube that needs to be cleaned. One of the cordopexy operations will give the patient freedom from stridor, but will leave a slightly breathy voice which is weak. On the other hand, there is no hole in the neck, no external appliance and no social embarrassments.

If a patient has stridor he should have a tracheostomy performed and must be told that it will be there for at least 6 months. This is because recovery is possible during this time, and also because it allows him to see what life with a tracheostomy is like. If no recovery has taken place at the end of 6 months, the patient should be told of the possibility, advantages and disadvantages of cordopexy. The final decision must always be left to the patient.

A cordopexy is an operation the objective of which is to move and fix the arytenoid, vocal process and vocal cord into an abducted position. A number of variations have been described, but only two will be outlined.

1. *External arytenoidectomy* is performed by entering the larynx behind the posterior lamina of the thyroid cartilage, removing the body of the arytenoid and stitching the vocal process to the thyroid cartilage. As the suture is being put into position a direct laryngoscopy is carried out by the assistant to guide the surgeon into creating a gap of 4 mm at the posterior end.

2. *Arytenoidoplasty* is done by a laryngofissure approach. A wire is passed from outside the thyroid lamina to enter the larynx below the vocal process; it is then passed above the vocal process to the outside of the thyroid cartilage again. As the wire is tightened the cord is abducted.

BILATERAL ADDUCTOR PARALYSIS (FUNCTIONAL APHONIA)

As the name suggests, inability to adduct the vocal cords is always bilateral and always functional, and the symptom is always aphonia. In its most severe form the voice may be barely audible because, as well as being a whisper, the

severely disturbed patient will make very little effort to project the voice. One can almost imagine her deliberately making no attempt to use any throat or chest muscles in the act of voice production. The condition is most common in young females with love or work problems. On the rarer occasions when it occurs in males the cause is usually to be found in promotional difficulties at work or staff incompatibilities.

One of the most helpful diagnostic features is the effort involved in creating the symptom. Mention has already been made of the associated lack of volume of the whisper. Examination shows not only that the cords are in abduction but where adduction does occur it is incoordinated—as if the patient is trying to suppress the normal reflex adduction of gagging. The single most important diagnostic feature, however, is that no matter how aphonic the patient is for speech she will always produce a good cough when asked to, showing that normal adduction of the cords can occur.

TREATMENT. This lies outwith the field of otolaryngology. In suitable patients, quackery, such as the subcutaneous injection of sterile water accompanied by appropriate reassurances, is occasionally rewarding. In the vast majority of cases, however, the patient requires some form of psychotherapy, whether from her family doctor, a speech therapist or a psychiatrist. The otolaryngologist should limit himself to diagnosis and an explanation of the psychosomatic nature of the condition.

CHAPTER 39

LARYNGOTRACHEAL TRAUMA

After head injury respiratory obstruction is the second most common cause of death at the roadside following an automobile accident. A high proportion of these deaths is due to such injuries blocking the airway at the upper end, either at the larynx or trachea. In a multiple injury, laryngeal fractures may well be missed because all efforts will be directed towards establishing an airway either by tracheostomy or intubation and dealing with the more spectacular problems in the chest, abdomen, head or limbs. At this point the laryngeal trauma is classified as 'acute' and remains in this eminently remedial state for 3 or 4 weeks. After this, the state of 'acute trauma', which is rewarding to treat, passes into a state of 'chronic stenosis' which is very unrewarding to treat. All too often this is when the problem comes to light because after 3 or 4 weeks, if the patient survives the first period, the other injuries are well controlled and attempts are made to remove the tracheostomy tube. In these unfortunate cases it is only when the patient is seen to be unable either to breathe or speak without a tracheostomy tube that the larynx is examined. To rebuild a larynx from the scarred state in order to free respiratory obstruction is relatively easy, but to make such an organ an efficient sphincter or an efficient 'voice box' is extremely difficult.

ACUTE LARYNGOTRACHEAL TRAUMA

The commonest cause of laryngeal or tracheal injury is a road traffic accident. Other causes are bullet and knife wounds, damage by other sharp objects such as sticks or falling on to a sharp edge such as a kerb, and blows to the neck from such sports as karate and basketball where the neck is often extended and unprotected.

The result of a car accident depends on the seat-belt situation. (a) If a full harness is worn the occupant will be as safe as possible and will only die from severe crushing, seat-belt injury or whiplash (*Fig. 94B*). (b) If the occupant has no seat-belt on, he will be thrown about, or out of the car and the injuries received will be a matter of chance. (c) If, as is common in North America, lap-type seat-belts are worn, the injury sustained depends upon the length of the front compartment of the car, and the height of the driver or passenger (*Fig. 94A*). At impact, the occupant, being held at his waist, is jack-knifed forwards and if the distance is short the face will hit the steering wheel or dashboard and the result is likely to be a facial fracture: If the distance is longer, the head will extend leaving a large area of neck unprotected by the mandible and when this strikes the wheel or dashboard, the larynx is pushed back against the cervical vertebral bodies.

Under the age of 40, the thyroid cartilage is still largely cartilaginous and so, when it hits the vertebrae, the laminae are spread outwards and a fracture occurs down the prominence. When the compressing force is removed, the cartilage recoils forwards, reassuming its normal shape, but with a linear fracture down the prominence. The effect of this fracture is to detach the

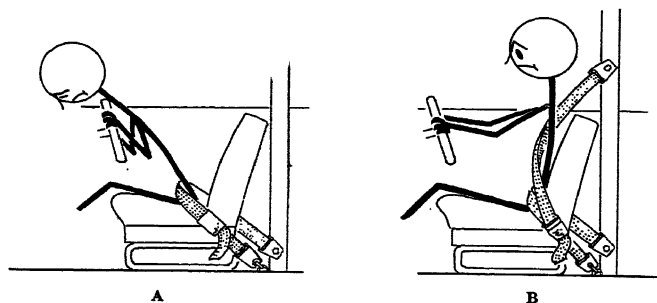


Fig. 94. Seat-belt injuries. A, If only a lap-belt is worn the driver is flung forwards with injury to the larynx. B, If full harness is worn this type of injury is prevented.

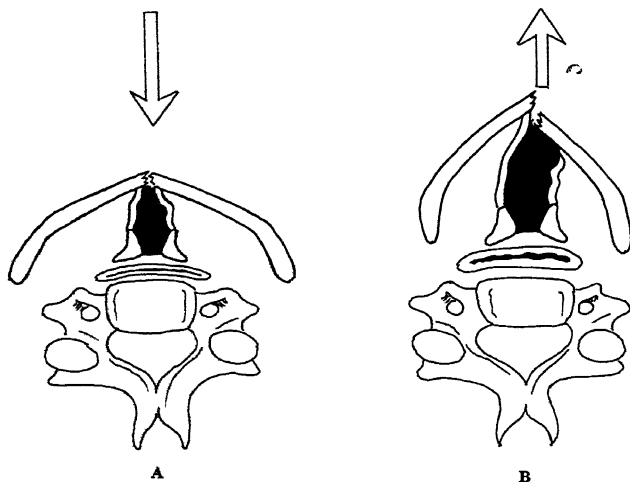


Fig. 95. Seat-belt injury. To illustrate the two phases in the younger patient. The larynx is forced backwards on to vertebral column and the thyroid cartilage fractures down the prominence. When the larynx springs forward to regain its normal shape, the vocal cords are detached at their anterior ends.

epiglottis which will now hang free in the laryngeal lumen causing obstruction. It will also detach the anterior ends of the vocal cords which may either hang into the trachea or roll up on themselves towards the arytenoid (Fig. 95). As the arytenoids are pushed against the cervical vertebrae they become bruised and swollen and perhaps even disarticulated from the cricoid.

Over the age of 40 the thyroid cartilage has lost much of its elasticity because of ossification of the cartilage. This means that as the larynx is forced back on to the cervical vertebrae the compressing force will shatter it, and when this force is removed the shattered, inelastic larynx will not recoil. The effect of this is to disorganize the cords and the base of the epiglottis, to

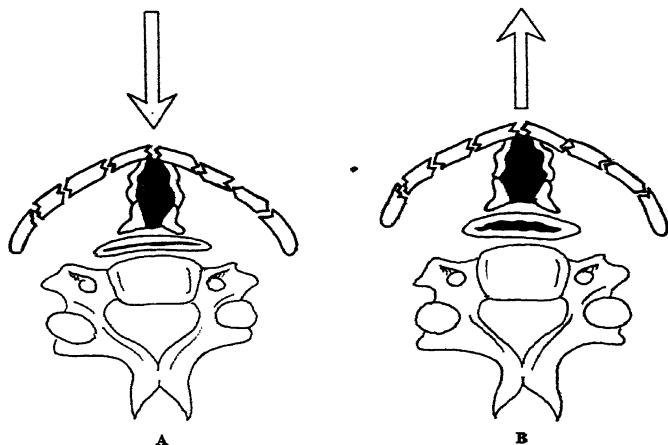


Fig. 96. Seat-belt injury. To illustrate the extent of injury in the older patient in whom the thyroid cartilage has ossified. The initial impact shatters the cartilage which cannot recoil. The neck is flattened and the airway reduced.

damage the arytenoids, to narrow or close the airway and to cause a flattening of the neck (*Fig. 96*).

Minor degrees of external trauma and other injuring factors such as burns and scalds will cause only internal soft tissue damage with no skeletal disruption. This can take the form of bruising, haemorrhage or laryngeal oedema.

The type of injury often sustained in karate or basketball is a fractured hyoid. This presents as exquisite pain over the fracture site on swallowing and also on 'springing' the hyoid by palpation.

DIAGNOSIS. As indicated in the introduction to this chapter a laryngeal fracture is easy to miss as the associated injuries mask it. It is vital to be aware of this condition and to suspect it in any multiple injury. Bruising and other soft-tissue injury is not always dramatically obvious and indeed a major laryngeal fracture can exist in the absence of bruising.

If the laryngeal lumen has been opened there will be surgical emphysema. This is diagnosed by palpating the neck and feeling the very typical crepitus. If, however, the forces applied to the larynx were sufficient to cause severe internal soft-tissue derangement without tearing the perichondrium surgical emphysema will be absent.

In the older patient with an ossified thyroid cartilage the neck will be flattened (*Fig. 97*) and in the young patient a linear fracture may be palpated down the line of the thyroid prominence.

If there is total airway obstruction the patient will die at the roadside, but if he gets as far as hospital then the dyspnoea may not be as marked as expected. Detached vocal cords could well increase the size of the airway initially only to decrease it again when reactive swelling occurs some hours after the injury. So it is that a patient with a fractured larynx, and say a ruptured spleen, could be admitted with shock and no respiratory obstruction. The anaesthetist could lift the detached epiglottis with his laryngoscope, intubate the patient, the spleen

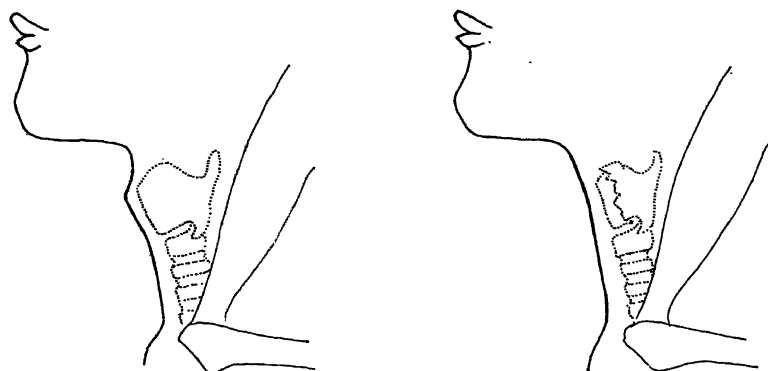

Fig. 97. Loss of normal neck outline after fracture of the larynx.

could be removed and on extubation the patient may well develop respiratory obstruction since by now the larynx is reactively oedematous.

Pain is a relatively minor feature; it may occur on swallowing and be transmitted to the ear.

Mirror examination may show oedematous, haemorrhagic arytenoids, mucosal tears and disorganized vocal cords. Direct laryngoscopy should be done in all suspected cases.

Plain films will show swelling within the larynx, and subcutaneous emphysema, but laryngographs do not have much importance in the acute stage because of the relative complexity of the examination and also because of the fact that the patient is seldom in a condition to cooperate with the investigation.

TREATMENT. When the injury is slight there is no need for any treatment apart from observation in case laryngeal oedema develops. If the patient's condition deteriorates he should be put to bed and treated with humidification, oxygen and steroids, and if oedema progresses a tracheostomy should be done.

In the more severe cases there are two principles of treatment: (a) the establishment of an airway with a tracheostomy, and (b) open exploration, repair and reduction, and fixation of the fracture.

After the tracheostomy has been done, further exploration is carried out through a horizontal collar incision. It is usually possible to enter the larynx through the fracture and all torn soft tissue, such as detached cords, are stitched back into position. There should be minimal débridement.

If there is a linear fracture down the thyroid then the aim of treatment is to reduce the fracture and to prevent the anterior ends of the vocal cords from joining together to form a web. This is done by using a piece of 0.18 mm thick tantalum sheeting, cut to the shape shown (*Fig. 98*), which is placed keel end first between the cords, and fixed by pressing the flanges over the thyroid




Fig. 98. McNaught keel.

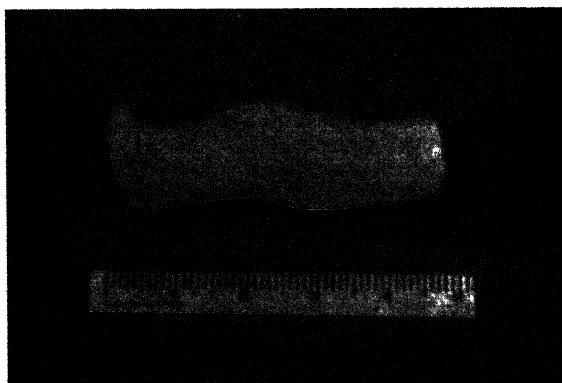


Fig. 99. Solid stent mould, made to the shape of the larynx, used to reform the shattered larynx.

cartilage which is wired. This is called a McNaught keel and is left in place for 5 weeks. The neck, but not the larynx, must be reopened to remove it.

When the thyroid cartilage is shattered the same principles are used but the larynx must be refashioned around a solid stent mould, which is made to the shape of the larynx (*Fig. 99*), wired in place and left for at least 8 weeks. This can be removed endoscopically.

Fractures of the hyoid are much easier to treat. The fracture is exposed and the piece of bone on either side of the fracture is removed leaving a gap in the hyoid which causes no functional problem.

Not all patients with tracheal avulsion or tears in the cricotracheal membrane die. If they survive long enough to get to hospital then it is possible to replace the trachea and to suture the first ring to the cricoid cartilage. There is no need to use a stent mould since this may result in infection and a breakdown of the anastomosis.

CHRONIC LARYNGOTRACHEAL STENOSIS

This is said to be established if the patient has not got a satisfactory airway 4 weeks after an injury. Apart from trauma other causes include: (a) *Tracheotomy*: If the tracheotomy is placed too high then the cricoid cartilage will collapse. Recently it has been shown, however, that some stenosis is common after all tracheostomies both at the site of the tracheotomy and at the site of the inflatable cuff on the tracheostomy tube. Post-tracheostomy stenosis, however, seldom gives rise to stridor but most commonly causes difficulty in clearing sputum. (b) *Partial laryngectomy*. If hemilaryngectomy includes more than one and one-fifth vocal cords then a McNaught keel must be used in reconstruction. Failure to do this will result in laryngotracheal stenosis. (c) *Granulomatous disease*. Stenosis may be the late result of tuberculosis or widespread aphthous ulceration. (d) *Tumours*. Subglottic and tracheal tumours are dealt with in Chapter 37 (p. 184).

DIAGNOSIS. There will be difficulty in breathing, speaking and clearing secretions from the lower respiratory tract, to a greater or lesser degree, depending upon the severity of the stenosis.

On mirror examination, narrowing, web formation, granulations or oedema may be seen. The arytenoids may also be seen to be fixed. This is better assessed at direct laryngoscopy, however, because the fixation may be due to cordal scarring or fixation of the crico-arytenoid joint. These two possibilities may be assessed by moving the arytenoid at direct laryngoscopy. The extent of the stenosis, especially if it is severe, is not always possible to assess at laryngoscopy. It is in these cases that laryngography is of greatest benefit because without it no adequate preoperative planning can be done, and to operate on a tracheal stenosis without knowing its exact extent is both foolish and dangerous.

TREATMENT.

Supraglottic Stenosis. This may be managed by doing a modified supra-glottic laryngectomy, excising only the scarred area and leaving the normal functioning vocal cords. The long-term results of the procedure are not as good as one would expect from this simple explanation of the procedure, but apart from wearing a permanent tracheostomy tube there is little else to offer the patient. If the stenosis is limited to the false cord region the scar may be pulled laterally by wiring it to the thyroid cartilage.

Glottic Stenosis. If stenosis is limited to the glottis it is due either to fixation of the arytenoids or to an anterior web of the cords. In the case of arytenoid fixation the arytenoid may be removed and the cord stitched in the desired fixed position, or the vocal process may be wired laterally.

A web is best dealt with by a laryngofissure approach, excising the web and closing the larynx over a McNaught keel.

If the whole glottis is stenosed and disorganized then it should be explored, the scar excised, the remainder refashioned as well as possible and fixed

over a solid stent inlay of silicone rubber which is wired in place for 8 weeks.

Subglottic and Tracheal Stenosis. A very mild case may be managed by repeated dilatations but such a case is the exception rather than the rule. Most cases will require excision of the stenosed portion and re-anastomosis of the trachea. Up to 4 cm of trachea may be excised and a primary repair carried out by freeing the tracheal stump in the mediastinum down to the carina, and 'dropping' the larynx by dividing the suprahyoid muscles. It is possible to manage most problems in this way, but if more trachea has to be resected then the left main bronchus should be removed from the carina, the trachea pulled up into the neck thus straightening the right main bronchus and the left main bronchus is reattached to the right main bronchus. If the end-to-end anastomosis in the neck has been done properly it is doubtful if a tracheostomy or a stent inlay would help the procedure at all.

CHAPTER 40

PAEDIATRIC LARYNGOLOGY

ANATOMY

In order to understand how laryngological problems in children differ from those in adults it is necessary to appreciate the anatomical differences. During fetal life the larynx descends from the level of the basi-occiput at the sixth week to lie opposite the 2nd, 3rd and 4th cervical vertebrae at birth. At the age of 6 years it is opposite the 5th cervical vertebra, and at puberty the larynx lies opposite C6, a position which it occupies throughout adult life. The lumen of the larynx and trachea in the child is small, especially in proportion to the rest of the body. The anteroposterior length of the glottis at birth is 7–9 mm and its lateral width in full abduction is 6 mm. Thus the area of the glottis in the newborn is some 24 mm². From this it is apparent that 1 mm of oedema in the neonate will reduce the area of the glottic space by 50 per cent to 12 mm². The diameter of the immediate subglottis at birth is 5–7 mm and that of the trachea is 6–8 mm. The area of this region is thus about 9π and this is reduced by 1 mm of oedema to 4π , or to 44 per cent of normal. By the same token 1 mm of oedema in a 3-mm bronchus reduces its area to 11 per cent of normal. The trachea is 4 cm long at birth, 5.5 cm about the age of 7 years and 9–15 cm in length in the adult.

The laryngeal cartilages in childhood are softer and more pliable than in the adult. The infantile epiglottis is infolded, and as the child grows the epiglottis opens out to become omega-shaped, and finally develops into the adult form after the age of 2 years. The mucosa of the child's larynx, especially in the subglottis, is very lax so that oedema forms more easily in this region than in the adult. The infant's larynx also has a rich sensory nerve supply and so the responses tend to be exaggerated.

Some of the more common laryngeal conditions seen mainly in children will be described.

LARYNGOMALACIA

This is the name now used for what used to be called 'congenital laryngeal stridor'. It is the most common condition causing an inspiratory stridor at or shortly after birth. It may persist throughout infancy. There is abnormal flaccidity of the laryngeal cartilages allowing the laryngeal structures to vibrate like a small elongated reed. On inspiration the air flow draws the laryngeal tissues into the lumen (*Plate VIII, 2*) thus causing an inspiratory stridor which is worse during exertion such as crying. The usual course of the condition is that the stridor is noticed shortly after birth, increases during the first few months of life and thereafter remains static. Most cases usually

develop enough firmness in the laryngeal structures for the condition to disappear by the age of 2. The condition is distinguishable from lesions affecting the vocal cords by the fact that the cry is normal.

The diagnosis can only be made at direct laryngoscopy which excludes other causes of inspiratory stridor.

The treatment is to reassure the parents that it will be self-resolving and to advise them to pay more attention than usual to upper respiratory tract infections in the infant because these are more prone to develop into bronchitis or bronchopneumonia.

INFLAMMATORY CONDITIONS

These are described more fully in Chapter 33.

Simple acute laryngitis is a condition to be taken seriously because of the danger of oedema. Supraglottic oedema begins in the arytenoids and spreads to the ary-epiglottic folds and the false cords. Subglottic oedema occurs only below the vocal cords in the lax subglottic submucosal spaces. In neither case do the vocal cords become oedematous.

Similar dangers exist in *acute epiglottitis* and *acute laryngotracheobronchitis* but to a much greater extent. In epiglottitis the supraglottic oedema may obstruct breathing and the large surface area affected in the inflammatory process will make the patient very ill. Pain is a characteristic feature of the condition as is the pyrexia which is usually higher than that found in acute laryngotracheobronchitis. This latter condition carries with it the danger of subglottic oedema but, as well as this, the whole tracheobronchial tree is oedematous and efficient gas exchange may not be possible.

Treatment consists of administering drugs such as ampicillin and hydrocortisone to diminish the infection and oedema and also to employ local applications such as adrenaline sprays and steam inhalations.

In any child presenting with stridor and a fever it is important not to forget the possibility of diphtheria.

LARYNGEAL TRAUMA

Foreign bodies in the larynx are uncommon because they are either coughed out or cause fatal obstruction within a few minutes if help is not to hand. In the desperate acute situation the child should be turned upside down and its back slapped. If the child arrives at hospital with a foreign body lodged in the larynx it usually means that there is sufficient airway to allow of careful induction of general anaesthesia and removal at laryngoscopy.

Scalds and burns of the larynx occur when a child inhales superheated steam, drinks a boiling liquid or is rescued from a fire. The supraglottic oedema may settle with conservative measures such as inhalations, sprays and steroids but intubation for 2-3 days may occasionally be required.

Injury to the larynx is less common in children than in adults since there is more 'give' in the pliable laryngeal cartilages. The shortness of the neck makes laryngeal injury from an automobile accident rare in children. The commonest cause is from beatings, attempted strangulations and running into a 'neck high' wire or clothes rope during play.

Tracheostomy, if done correctly, carries no morbidity. In the newborn or infant, however, it is a difficult operation and is fraught with danger. The diameter of an infant trachea is less than that of the adult's little finger. During the procedure a high subclavian vein or the bulging of pleura into the suprasternal area may force the surgeon to open the trachea at a higher level than usual. Damage to the first tracheal ring or the cricoid is not uncommon if an inexperienced operator performs a tracheostomy in an infant.

LARYNGEAL PARALYSIS

Laryngeal paralysis may be congenital and associated with other anomalies of the central nervous system, the heart and great vessels, the trachea or the oesophagus. Birth injury is not a common cause. The paralysis may be unilateral or bilateral, the latter being twice as common as the former. In unilateral paralysis the presenting feature is slight stridor and a weak cry. The most severe stridor is seen in bilateral incomplete paralysis. A complete account of the causes and management are given in Chapter 38. The only way to diagnose this condition and to assess the effect of the paralysis is to do a direct laryngoscopy under local anaesthesia, or with no anaesthesia, and to watch the cords during crying.

BENIGN TUMOURS

Congenital cysts of the larynx occur as developmental anomalies in the ventricle and sacculæ, as true retention cysts of the supraglottis and as laryngoceles. They project into the laryngeal lumen and produce dysphonia and stridor in proportion to their size. Small cysts can be uncapped and drained at direct laryngoscopy but larger cysts will require to be dealt with using suspension laryngoscopy and the techniques of microlaryngeal surgery.

Laryngoceles (Plate VIII, 3) are very rare and usually require no treatment in children.

Congenital haemangioma and lymphangioma are usually found in the subglottic area or on a vocal cord and are only distinguishable histologically. A purplish subglottic swelling may either be a haemangioma of the subglottis or an indentation and erosion of the subglottis by an abnormal vessel or aneurysm. Because of this no biopsy or removal should be attempted until the situation has been more fully assessed by angiography. It is unusual to have to remove subglottic lymphangiomas or haemangiomas surgically since they usually regress on their own. If they cause stridor it is better to irradiate them because surgery in the infant subglottis will almost certainly lead to laryngeal stenosis. If the tumours are on the vocal cord the cry will be hoarse and they can be removed with little difficulty at direct laryngoscopy.

Multiple papillomata are the most common laryngeal tumours in children but in the whole spectrum of laryngeal disease they are rare. They may be present at or soon after birth but more commonly they arise about the age of 2 years. Their cause is unknown but it is probable that they are due to a virus, not unlike that which causes warts elsewhere on the body. Strength is given to this theory by the fact that they are implantable, especially down the trachea after numerous intubations, and they are also transmissible since

mothers have grown warts on their fingers after managing a child who has had a tracheostomy for the condition.

At laryngoscopy the papillomata look like bunches of wart-like excrescences, pinkish-white in colour; they may be sessile or pedunculated and are always multiple (*Fig. 100*).

Symptoms depend upon the size and position of the growths. If the vocal cord is affected at all there will be dysphonia, and if the papillomata are big enough to compromise the airway there will be stridor (*Fig. 101*).

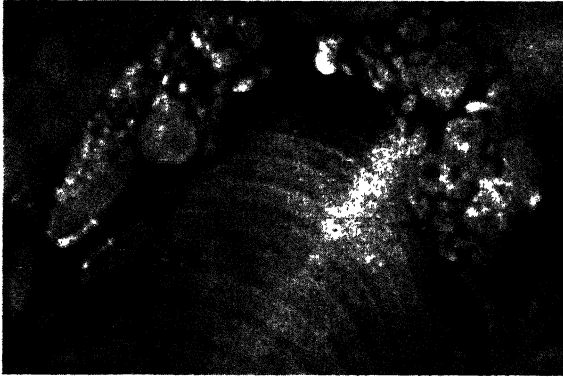


Fig. 100. Multiple papillomata of larynx.

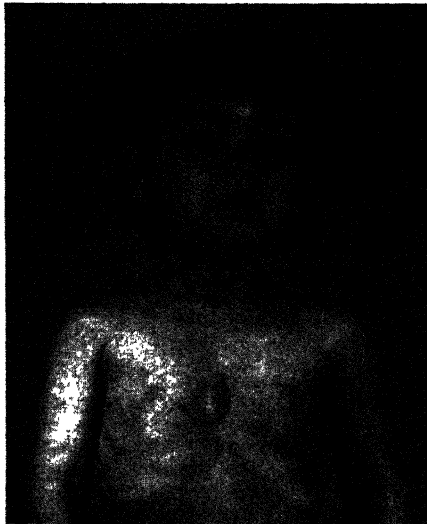

Fig. 101. The appearances in severe dyspnoea in a child with multiple papillomata of the larynx.

The principle of treatment is to remove the papillomata as they appear, without damaging the larynx in the process, and to wait for the normal resolution of the condition. It is also important to do everything possible to prevent spread down the tracheobronchial tree and to this end avoidance of a tracheostomy is of vital importance when one considers how the tumour is implantable. If the tumour affects the tracheobronchial tree the patient is in danger of death because of stenosis and scarring of that vital region.

Many treatments have been advocated over the years—administration of oestrogens, cautery with podophyllin, trichloroacetic acid or chromic acid, ultrasonic therapy, irradiation, vaccine therapy and local idoxuridine. None of these is as successful as careful and repeated local removal, aided by the microscope, and regular 2-monthly follow-up of the patient until the condition resolves some time in the late teens. This policy is safer than waiting until respiration becomes embarrassed because by then so many landmarks have disappeared that laryngeal damage and subsequent scarring are inevitable.

STENOSIS

Laryngeal atresia represents the ultimate in stenosis and is inconsistent with life unless it is recognized at birth and a tracheostomy performed. It is, in fact, a web filling the whole larynx and it is commonest in the subglottic region.

Congenital laryngeal web consists of a membrane lying between the vocal cords always at the anterior part of the glottis (*Plate VIII, 4*). The membrane is quite tough and the degree of stridor and aphonia is proportional to the size of the web. A small web will cause little respiratory difficulty and may safely be left until the larynx has stopped growing since it only causes slight dysphonia and not dyspnoea. A large web, however, should be dealt with immediately because the only alternative will be a permanent tracheostomy. The thyroid cartilage is divided in the midline and the web is excised. If the larynx were to be closed at this point, the raw anterior ends of the vocal cords would adhere causing further glottic stenosis, and so it is necessary to close the larynx over a McNaught keel (*Fig. 98, p. 195*). This is made of 0.18-mm thick tantalum sheeting and it is left in place for at least 5 weeks. During this time the patient breathes with a temporary tracheostomy. After 5 weeks the keel is removed.

Medium size webs may be removed at microlaryngoscopy, the anterior ends of the vocal cords being injected with steroid to try to prevent adhesions forming.

Subglottic stenosis may be caused by a congenital narrowing of the cricoid cartilage. It is said to be established if the internal diameter of the cricoid ring is less than 3.5 mm. It can also be caused by an improperly performed high tracheostomy.

STRUCTURAL ANOMALIES

Cleft larynx is really a high tracheo-oesophageal fistula. In its complete form, where the cleft goes through the whole lamina of the cricoid cartilage and the posterior wall of the trachea, death from aspiration of food and saliva is inevitable. If the cleft does not go completely through the cricoid lamina, however, it can be repaired in layers and the cleft closed.

In very minor cases the U-shaped indentation of the cricoid lamina fills with granulations and these interarytenoid granulations seen on laryngoscopy may be misdiagnosed as pachydermia.

Micrognathia (hypoplasia of the mandible, *Fig. 102*) can cause stridor or an inadequate airway because the tongue is displaced posteriorly. In the Pierre-Robin syndrome a cleft palate is associated with the micrognathia and the



Fig. 102. Hypoplasia of the mandible (micrognathia).

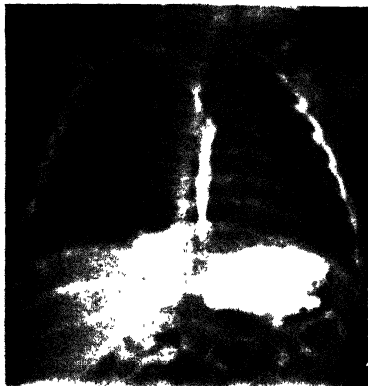

Fig. 103. Lipiodol swallow in dysphagia lusoria due to congenital vascular ring.

stridor is marked. The treatment of this is the Beverly-Douglas procedure in which the tongue is fixed anteriorly. Micrognathia may also be seen in the Treacher-Collins syndrome.

Vascular anomalies may cause a chronic stridor in infants often accompanied by a persistent brassy cough. If disorders of swallowing accompany the condition it is called 'dysphagia lusoria'. The common causes are: (a) a right

aortic arch, (b) a double aortic arch, (c) a vascular constricting ring formed by a patent ductus arteriosus or a ligamentum arteriosum and the pulmonary artery or aortic arch, (d) an abnormal right subclavian artery, and (e) an abnormal innominate artery. Diagnosis is made by a lipiodol swallow (Fig. 103) or by arteriography. At bronchoscopy a pulsatile swelling may be seen on the right anterolateral tracheal wall some 2 cm above the carina, and is best seen if the head of the baby is not overextended. If this swelling is occluded by the tip of the bronchoscope: (1) the right radial and right temporal pulses will stop if there is an abnormal innominate artery, (2) the right radial pulse stops but the right temporal pulse is unaffected if there is an abnormal subclavian artery, and (3) neither pulse is obliterated if there is a double aortic arch. The treatment is carried out by a thoracic surgeon.

SPASMS

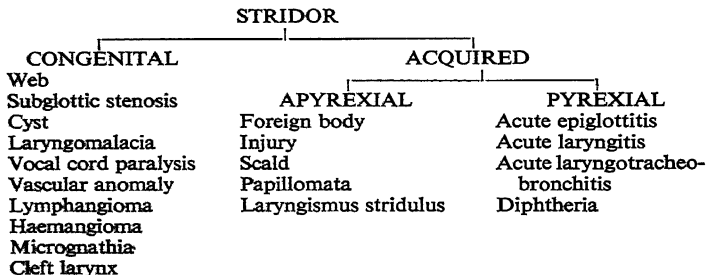
Laryngismus stridulus is a very uncommon condition causing stridor in undernourished children about the age of 2 years, and it is frequently associated with rickets and coeliac disease. The cause is thought to be a hyperventilation causing an alkalosis, a fall in serum calcium and an increased excitability of muscle tissue. It is treated by calcium gluconate.

Laryngeal spasm may be due to tetany, large tonsils causing dysphagia and to various anaesthetic agents.

STRIDOR

Stridor is the noise produced by an obstruction to the passage of air in and out of the lower respiratory tract. It may be inspiratory, expiratory and mixed inspiratory and expiratory. Laryngeal stridor is usually inspiratory, bronchial stridor is usually expiratory and the rare inspiratory and expiratory variety must bring to mind the possibility of an abnormal vessel arising from the aortic arch.

The following account will deal almost exclusively with the common laryngeal inspiratory stridor. Allergic or infective bronchospasm is the commonest cause of expiratory stridor but the otolaryngologist should always bear in mind the possibility of an inhaled foreign body, like a peanut or a bead, in these cases.



Management of Stridor.

Congenital Stridor

Two misconceptions exist in the management of this condition. First, because so many cases turn out to be laryngomalacia it is tempting not to do a laryngoscopy on children who have inspiratory stridor which is worse on crying and whose cry is normal. Secondly, there is occasionally the temptation to 'wait until the child is old enough to have an anaesthetic'. It is essential to remember that stridor means that there is an obstruction to the airflow in and out of the lower respiratory tract. Every case of stridor should have a direct laryngoscopy performed. In the hands of a skilled anaesthetist the procedure carries very little risk—certainly much less risk than that taken by choosing to remain in ignorance as to the cause. Prior to giving the infant an anaesthetic it is important to look for various things in the conscious state. First, the child is examined when it is asleep because, in the resting phase, the true state of the airway can be assessed. Infants with a unilateral vocal cord paralysis and laryngomalacia rarely make any noise when asleep. In case of micrognathia, tilting the chin forwards will stop the stridor. On waking, the child will tend to cry, and on the inspiratory phase of the first cry a further assessment can be made of the effect of effort on the stridor. The quality of the cry is all important. Any dysphonia means that cord movement or form is not normal and this would make one think of web, paralysis, tumour or cyst. A normal cry would suggest laryngomalacia, subglottic stenosis, a vascular anomaly or a cleft. The cords should be examined in the conscious state so that movement may be assessed. The infant's breathing during feeding should also be studied. When all this has been done, a direct laryngoscopy under general anaesthetic is done. Thereafter, the treatment is that of the specific cause.

Acquired Stridor

The same principles apply here. Every effort must be made to find a cause for the stridor. In the afebrile group the problem is simpler because the history will give a good guide as to the cause. The most difficult case is the laryngismus stridulus patient who can often pose a diagnostic problem.

The management of the febrile child with stridor is one of the most testing problems in medical practice. In the primary care situation the difficulty is increased. The croupy infant may just be an overweight child with a pliable larynx and an upper respiratory tract infection. On the other hand, the infant might have developed a subglottic laryngitis, an acute epiglottitis or an acute laryngotracheobronchitis. If the symptoms do not resolve very quickly (in a matter of hours) with warmth, humidity and antibiotics, the child should be sent to hospital. Primary treatment there should consist of oxygen, humidification, antibiotics and steroids. If the stridor persists in spite of this the question of assisting the airway arises. This is discussed at length in Chapter 35 but in summary here it can be repeated that a tracheostomy is a difficult operation, not without complications, when carried out on a small child by anyone other than an experienced operator. Every effort should be made to avoid this procedure as an emergency because the complication rate will be high. When it becomes apparent that airway assistance is required the first step should be to intubate the child. If the condition does not resolve in the next 48–72 hours—and failure to resolve is the exception rather than the rule—a tracheostomy

THE LARYNX, BRONCHI AND OESOPHAGUS

will need to be performed. When a tracheostomy is required care should be taken in choosing the type of tube to be worn. Due to the incoordination in swallowing following a tracheostomy, the larynx and the subglottic region above the tracheostome tend to act as a sump. To avoid this, the Rees-Pracy tube was designed. This is a valved tube which on expiration sends the airflow through the subglottis and glottic space. This prevents secretions collecting there and so cuts down the subglottic oedema which so often makes extubation in a child a tedious and difficult problem.

CHAPTER 41

ENDOSCOPY

Peroral endoscopy comprises direct laryngoscopy, bronchoscopy and oesophagoscopy. It is the general term used for all these methods by which a direct examination of the hypopharynx, larynx, trachea, bronchi and oesophagus may be undertaken.

ENDOSCOPIC INSTRUMENTS

Formerly, endoscopy was performed with rigid tubes provided with a source of illumination which was either of the proximal or distal lighting variety. The rigid tubes (*Fig. 104*) still form the main part of an endoscopy set, but the lighting is now done almost exclusively from a fibreoptic source. This gives a much superior light than was ever possible from an electric light source. The introduction of fibreoptics has also led to a new series of instruments being devised. These are narrow flexible endoscopes which can be used more easily under local anaesthesia and can also enable the surgeon to look more closely at the larynx and oesophagus and more distantly into the bronchial tree.

DIRECT LARYNGOSCOPY

ANATOMY. See Chapter 30.

ANAESTHESIA. This may be either local or general. The steps in applying local anaesthesia are: (a) The patient is premedicated with atropine sulphate, morphine sulphate and chlorpromazine with doses adjusted to weight and sex; (b) The patient should suck a benzocaine lozenge and then 2 per cent cocaine hydrochloride is applied to the base of the tongue and the palate; (c) A superior laryngeal block is achieved by holding with special forceps a cotton-wool ball soaked in 5 per cent cocaine hydrochloride in each pyriform fossa for 3 minutes; (d) Finally, to anaesthetize the subglottis the patient holds his own tongue forwards and the surgeon, holding a laryngeal mirror in one hand and a syringe with 1 ml of 10 per cent cocaine hydrochloride in the other, instils the cocaine under vision between the vocal cords into the trachea.

When general anaesthesia is used both the surgeon and the anaesthetist are competing for the same airway. The surgeon wants to examine all the laryngeal structures and the anaesthetist wants to keep the patient well ventilated and asleep. The anaesthetist should use the smallest diameter tube compatible with adequate anaesthesia and should place the inflatable cuff well down the trachea to permit adequate examination of the subglottic region. The larynx and trachea should also be sprayed with 5 per cent cocaine hydrochloride prior to starting the examination.

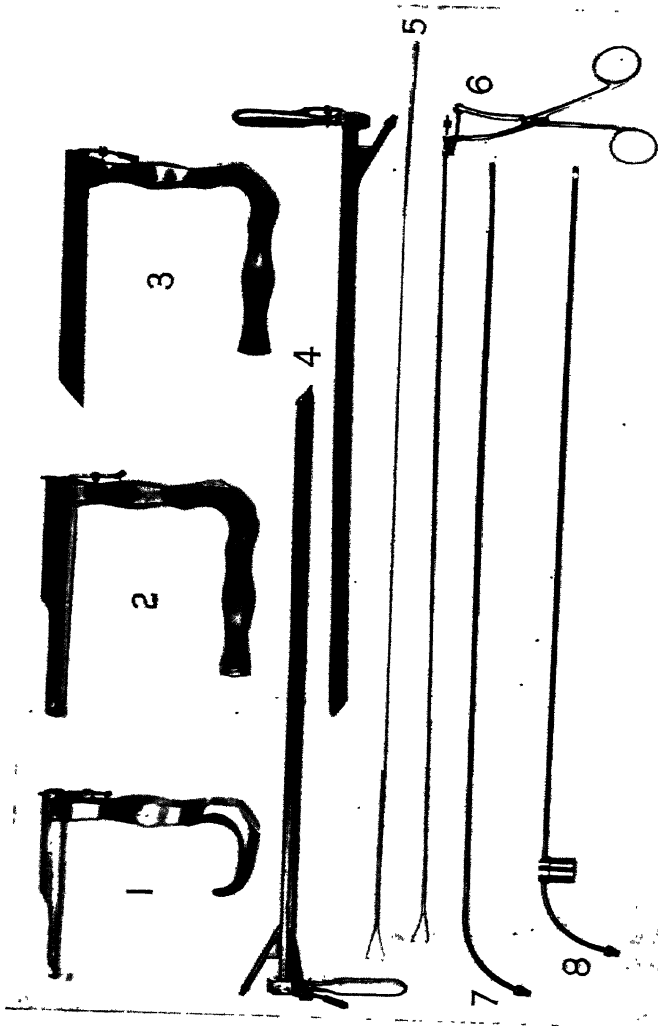


Fig. 104. Instruments for laryngoscopy and bronchoscopy. 1, Laryngoscope (child's); 2, Laryngoscope (adult's); 3, Laryngoscope (for anterior commissure); 4, Bronchoscope for suction and lavage; 5, Bronchoscope swab holder; 6, Bronchoscope forceps; 7, Suction tube; 8, Suction tube with specimen collecting glass.

OPERATION. The patient lies supine on the table and the cervical spine is flexed and the head then extended on the neck. This manoeuvre can be accomplished by special devices on the table, by assistants or by the surgeon himself. Whichever way is adopted, it has the effect of placing the oral cavity and larynx in as straight a line as possible. The head and chest are then draped and a tooth guard placed over the patient's teeth.

The Jackson laryngoscope is passed first and guided into the larynx by following the endotracheal tube. Care should be taken to examine the following areas in every case—the valleculae, the lingual epiglottis, the ary-epiglottic folds, the pyriform fossae and the postcricoid and interarytenoid area. The laryngoscope is then passed in front of the endotracheal tube and the laryngeal surface of the epiglottis is examined as are the false cords, the ventricles, by pushing the false cords laterally, and the vocal cords. At this point the Jackson laryngoscope (*Fig. 104, 2*) is removed and the anterior commissure laryngoscope (*Fig. 104, 3*) is passed to examine the anterior half of the glottis. It is then passed through the vocal cords and the subglottis is examined.

Micro-laryngoscopy. In recent years it has become common practice to carry out all minor laryngeal surgery such as vocal cord stripping, removal of masses, etc. using the technique of micro-laryngoscopy. The Zeiss operating microscope is used with a 400 mm objective so that the microscope will focus on the vocal cords and leave enough room for hands and instruments. Special laryngoscopes are used and they are suspended thus leaving the surgeon with both hands free for using instruments. This is one of the main advantages of the method, allowing, for example, the surgeon to use a sickle knife or scissors in one hand, and a sucker in the other. Apart from the magnification, use of the microscope allows photographs to be taken. The method is not to be recommended, however, for assessing the extent of large laryngeal tumours because the size of the field is too limited to be of use and the lesions are usually large enough not to require magnification.

Fibreoptic Laryngoscopy. This is usually done under local anaesthesia and the flexible laryngoscope is passed through one side of the patient's nose and all the previously mentioned areas are examined. It is particularly useful for examining the laryngeal surface of the epiglottis and the anterior commissure, both of which areas are difficult to see completely using other methods. Instrumentation is impossible down the fibreoptic bundle and so its prime use is for diagnostic examination.

BRONCHOSCOPY

ANATOMY. The *trachea* commences at the inferior border of the cricoid cartilage opposite the inferior border of C6. From this point it descends postero-inferiorly into the superior mediastinum to end at T5 by dividing into the right and left main bronchi. There are 15–20 cartilaginous rings which are incomplete posteriorly, the gap being filled by the trachealis muscle. The lining is stratified columnar ciliated epithelium whose cilia produce an upward movement of the mucus covering the surface. From within, the mucosa looks moist and glistening with whitish ridges corresponding to the cartilaginous rings. The male adult trachea is 12 cm long, and the female,

11 cm long. The lumen varies from 15 to 22 mm. The surface landmark of the bifurcation is at the angle of Louis.

The *right main bronchus* makes an angle of some 25° with the vertical and is therefore almost a direct continuation of the trachea. Since it is in this alignment and since the lumen is larger than that of the left main bronchus, foreign bodies are most liable to enter it. The right main bronchus gives branches to the upper lobe (apical, posterior and anterior); the middle lobe

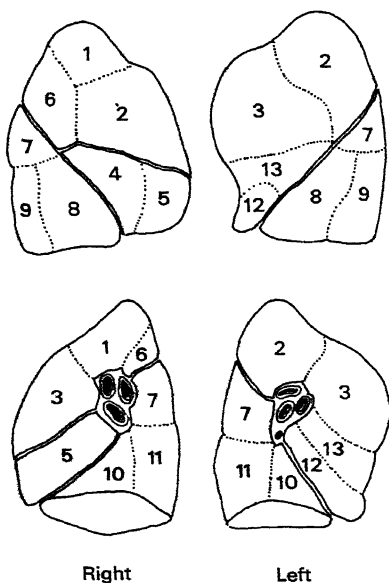


Fig. 105. Bronchopulmonary segments. 1, Apical; 2, Apicoposterior; 3, Anterior; 4, Lateral; 5, Medial; 6, Posterior; 7, Superior; 8, Anterior basal; 9, Lateral basal; 10, Medial basal; 11, Posterior basal; 12, Inferior lingular; 13, Superior lingular.

(lateral and medial); and the lower lobe (superior, medial basal, anterior basal, lateral basal and posterior basal).

The left main bronchus is longer than the right main bronchus and makes an angle of 75° with the vertical. It gives branches to the upper lobe (apicoposterior and anterior); the lingular lobe (superior and inferior); and the lower lobe (superior, lateral basal, posterior basal, medial basal and anterior basal). These are shown on Figs. 105 and 106.

The bronchoscopist must be familiar with the detailed anatomy of the bronchial tree so that when he looks at a segmental bronchus he knows precisely to which portion of the lung it leads. The branches detailed form the basic anatomy required for use with the rigid bronchoscope. If the fiberoptic bronchoscope is used, the fourth generation of the bronchi can be entered, but a detailed anatomy of these is beyond the scope of this book.

ANAESTHESIA. Bronchoscopy may be performed under local or general anaesthesia. The technique for local anaesthesia is that described for laryngoscopy, and that for general anaesthesia varies with the anaesthetist. It is

possible to perform a bronchoscopy without an endotracheal tube, with a small-bore tube or with a ventilating bronchoscope.

OPERATION. The position of the patient and the general preparations are the same as those for direct laryngoscopy. The commonly used size for adults is the 7 mm \times 40 cm bronchoscope, but frequently a smaller tube, e.g. 5 mm \times 30 cm bronchoscope is required.

In the case of children, bronchoscopes vary from the infant 4 mm \times 30 cm to the 5 mm and 6 mm bronchoscopes for older children and adolescents.

The bronchoscope (*Fig. 104, 4*) may be passed through a laryngoscope, or directly through the vocal cords into the trachea. As it passes through the glottis it is rotated so that the bevelled tip lies in the long axis of the glottis. The first point to be identified is the carina, a sharp, vertical spur at the distal end of the trachea and situated between the openings into the main bronchi on

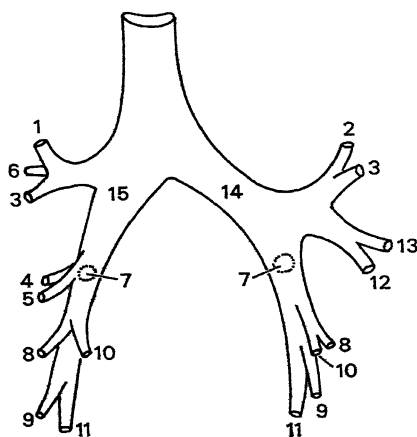


Fig. 106. Segmental bronchi. 1, Apical; 2, Apicoposterior; 3, Anterior; 4, Lateral; 5, Medial; 6, Posterior; 7, Superior; 8, Anterior basal; 9, Lateral basal; 10, Medial basal; 11, Posterior basal; 12, Inferior lingular; 13, Superior lingular; 14, Left principal bronchus; 15, Right principal bronchus.

either side. The right bronchus, virtually a direct extension of the trachea, is entered first and the lower tube segmental bronchi identified and examined. All the carinae should be sharp and white. As the bronchoscope is withdrawn, the middle and upper lobe bronchi are seen and the segmental bronchi examined with a right-angled telescope. The bronchoscope is withdrawn to the main carina, the patient's head flexed and turned to the right and the bronchoscope inserted into the left main bronchus. A similar examination is done using the right-angled telescope for the lingular and upper lobe bronchi.

Any obvious mass is biopsied, but in the absence of a visible mass 5 ml of saline should be instilled into each main bronchus and the washings sucked back into a sterile container and sent for cytology. If the carina is not sharp and narrow it, too, should be biopsied.

Fibreoptic Bronchoscopy. This is always done under local anaesthesia and a minute examination is made of the whole bronchial tree right out to the periphery. The fourth generation of bronchi can be entered. First reports

suggest that the early diagnosis of bronchial cancer will be vastly improved using this method. To use it successfully, however, a detailed knowledge of the anatomy of the *whole* bronchial tree is required.

OESOPHAGOSCOPY

ANATOMY. The oesophagus extends from the termination of the pharynx at the lower border of the cricoid cartilage at the level of C6 to the oesophagogastric junction, or the cardia, at the level of T11. The wall consists of muscle, submucosa and the mucosa which presents numerous folds which sharp pointed foreign bodies may readily penetrate. It is also covered by an adventitious coat by which it is loosely attached to surrounding structures. The nerve supply is from the vagus and the cervical plexus. In the adult, the length of the oesophagus is about 25 cm. The lumen shows great variation in size and presents four constrictions: (1) The cricopharyngeal constrictions at its mouth opposite C6; (2) At the crossing of the aorta opposite T4; (3) At the bifurcation of the trachea opposite T5; (4) As it passes through the diaphragm opposite T10. As the oesophagus is not very muscular, these constrictions, with the exception of the cricopharyngeal one, are easily distensible.

	From incisor teeth to opening of the oesophagus	From incisor teeth to bifurcation of the trachea	From incisor teeth to the cardia
Adult male	15 cm	26 cm	40 cm
Child of 7 yrs	10 cm	18 cm	27 cm
Infant	7 cm	13 cm	18 cm

ANAESTHESIA. Although oesophagoscopy can be done under local anaesthesia it is preferable to use general anaesthesia if any biopsy or dilatation is required.

OPERATION. The commonly used size of oesophagoscope (*Fig. 107, 7*) for adults is 9 mm × 30 or 50 cm but some surgeons use the much wider 16 mm × 45 cm. A fiberoptic oesophagoscope or gastroscope may also be used, but although biopsies can be done, no dilatation can be performed. For examination of the pharynx and upper oesophagus the Lynch oesophageal speculum (*Fig. 107, 3*) is used. The oesophagus is entered behind the endotracheal tube. When the posterior border of the cricoid is reached the beak of the oesophagoscope is used to lift it forwards thus opening the mouth of the oesophagus. The various constrictions should be identified and care must be taken in passing the oesophagoscope through them. It is often helpful to drop the head of the table progressively as the oesophagoscope is passed down the oesophagus.

A full description of oesophagoscopy is beyond the scope of this book, but mention will be made of perforation of the oesophagus which can occur during any biopsy or dilatation, or if force is used at any point of an oesophagoscopy.

PERFORATION OF THE OESOPHAGUS

This is the single most dangerous complication of oesophagoscopy and carries with it a significant mortality. A number of other causes of perforation




Fig. 107. Instruments for oesophagoscopy. 1, Steel rule (centimetres); 2, Upper-end oesophagoscope (child's); 3, Upper-end oesophagoscope (adult's); 4, Foreign body forceps for use with above; 5, Punch forceps for obtaining a specimen; 6, Paterson's forceps; 7, Long oesophagoscope; 8, Suction tube; 9, Swab holder; 10, Oesophageal bougie.

exist, namely, perforation by foreign body, excessive vomiting, surgical trauma, and erosion by caustics or drugs, but the commonest cause is oesophagoscopy.

The perforation may be in the cervical oesophagus or the thoracic oesophagus and it is important to distinguish these in the management of the condition. Perforation of the cervical oesophagus may be caused by trying to force a way through cricopharyngeus thus creating a false passage posteriorly (through the weak area), or by entering a pharyngeal pouch instead of the oesophagus and attempting to force a way through it. In the thoracic oesophagus perforations are most likely to occur by attempting to dilate a benign or malignant stricture, or by taking too deep a biopsy of a carcinoma or an oesophagitis. Rough attempts at removal of sharp foreign bodies can also perforate the oesophagus.

DIAGNOSIS. The symptoms manifest themselves within a few hours of the procedure. There is pain in the back between the shoulder blades and also painful dysphagia. After a short time the temperature rises rapidly to around 39 °C and surgical emphysema is palpable. Radiography shows a broadened mediastinum and if Dionosil is swallowed, the site of the perforation may be seen.

TREATMENT. At whatever stage the diagnosis is made a nasogastric tube should be passed, all oral feeding stopped, broad-spectrum antibiotics started and half-hourly vital sign charts commenced. If the diagnosis is made in the first 24 hours the neck or the chest should be opened, the perforation closed surgically and the wound drained. If the diagnosis is delayed, the edges of the perforation become necrotic, surgical closure is less certain and a conservative line of treatment is more likely to be successful. It is in this group that the mortality is high.

CHAPTER 42

INHALED AND SWALLOWED FOREIGN BODIES

An infinite variety of foreign bodies may be inhaled or swallowed. While many foreign-body accidents are preventable it is surprising that they are not more common when one considers how often pins, tacks or hair-grips are held in the mouth while the mind and hands are otherwise occupied. There is a natural tendency among children to carry small objects in the mouth, and they constantly experiment with the feel of different objects with their teeth. It may be that the protective reflex action is less well developed in children, so that such objects are more easily inhaled or swallowed.

A report that a foreign body has been 'swallowed' must not be taken literally, because laymen use this term to mean that it has left the mouth. It may have entered the oesophagus either to be arrested there or to pass into the stomach, or it may have been inhaled to lie in the trachea or bronchi. It is of the utmost importance that an accurate history of the incident be taken to determine whether or not there has been any spasm of coughing and dyspnoea, which would suggest inhalation. The absence of such a history usually implies that the object has entered the oesophagus although it is conceivable that before it did so it stimulated a reflex spasm in the larynx.

THE LARYNX

A foreign body in the larynx is readily diagnosed because the patient coughs and chokes, and is unable to speak. He points to the front of the larynx as the seat of the pain. A history of the accident is usually obtainable. There is generally no time to obtain a radiograph (*Fig. 108*), as a foreign body in the larynx calls for urgent removal. This is rarely possible at indirect laryngoscopy, and direct laryngoscopy gives an easier mode of access. When there is obstruction to breathing with cyanosis, and when the direct method is impossible at the moment, the circumstances call for an immediate tracheostomy, followed later by removal of the foreign body from the larynx when the danger to life has passed. In less urgent cases if there are an experienced anaesthetist and an experienced bronchoscopist available immediate removal may be undertaken, and under the relaxed conditions of anaesthesia the intruder is easily removed.

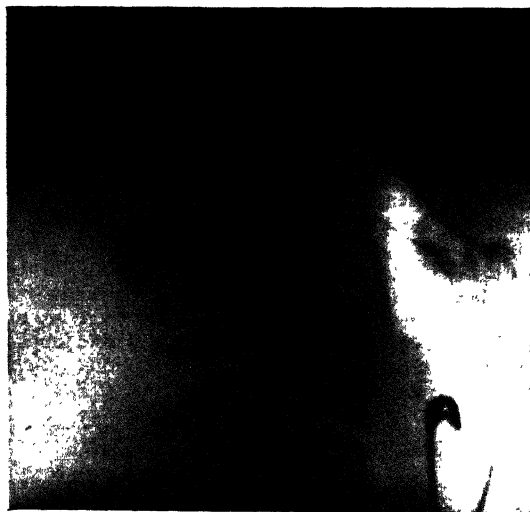THE TRACHEA AND BRONCHI

Foreign bodies only enter the trachea and bronchi after passing through the larynx. In the conscious patient their entry is resisted by the spasmodic closure of the vestibular and vocal folds with the production of a spluttering spasmodic coughing, and of dyspnoea with stridor. If this protective reflex has

been successful, the object will be coughed out or swallowed, and the spasm will settle. If the reflex has not been successful in preventing inhalation of the foreign body the symptoms also gradually settle, although an expiratory wheeze may persist. Failure of the reflex is more liable to occur if a sudden inspiration, due to fright or laughter, precedes the cough reflex, because this deep inspiration may open the glottis widely and allow the entry of the object.



A



B

Fig. 108. Foreign body (safety-pin) in subglottic region of the larynx, showing position of flattened body held up in the larynx and trachea. A, Anteroposterior view; B, Lateral view.

It cannot be stressed too strongly that the patient or parents must be closely and directly questioned regarding any such spasm, because once the foreign body enters a bronchus there may be a silent interval lasting from a few hours to some weeks with few if any symptoms. Many foreign bodies have been allowed to lie in a bronchus because the original incident has been concealed by the child, or gone unnoticed, or been ignored by parents or practitioners, or because direct questions have not been asked.

In the unconscious patient, whether during sleep or under an anaesthetic or intoxicated or under the influence of drugs, this spasm may be reduced or absent, and the occurrence may have passed unnoticed or may not be remembered clearly.

SYMPTOMS. In the usual case there is a history of a choking incident with a spluttering spasm of coughing, dyspnoea and perhaps cyanosis, followed by a relief of acute symptoms. There may be some subsequent stridor or an expiratory wheeze in children. If advice is not immediately sought the foreign body may give rise to few symptoms for a matter of weeks, depending upon its size and nature. In the case of a small object there may be little more than an occasional tickling spasm of coughing as the object changes its position in the bronchus or moves peripherally. If the foreign body is larger the cough is more persistent and is accompanied by an expiratory grunt. Should the object be organic, such as a peanut, decomposition may begin in a week or two, resulting in an inflammatory reaction in the surrounding mucosa. This causes pyrexia and a cough, and gives rise to an acute illness resembling a lobar pneumonia. By the same token, a patient with an unexplained cough, or with an apparent lobar collapse which does not respond to the usual therapeutic measures, should always be suspected of having inhaled foreign material.

CLINICAL FEATURES. These depend upon the size and nature of the foreign body, upon its position in the tracheobronchial tree and upon the length of time elapsing between inhalation and examination. The immediate signs are stridor, dyspnoea of varying degree and possibly cyanosis, with a spasmodic, irritative cough. There may be suprasternal or intercostal indrawing, but clinical examination of the chest at this stage may be negative.

A foreign body will remain in the trachea if it is too large to enter the bronchi. If it is very large it may never pass the larynx. A foreign body such as a plug of wool inhaled during sleep may acquire mucus and enlarge to lie across the carina and obstruct both main bronchi. Such an incident would give rise to gross dyspnoea, expiratory stridor, very little air entry into either lung, and thus cyanosis leading to pallor, unconsciousness and death. A smaller object, such as an orange pip, in a child's trachea may prove too large to enter the bronchi, and is moved up and down the trachea with respiration. This is especially noted if the child is lying flat, when the object may be heard and felt on palpation to slap gently against the subglottis on each expiration.

If a foreign body enters the bronchial tree, the right bronchi are more usually involved. The right main bronchus makes an angle of 25° with the vertical, and is thus nearly continuous with the trachea, while the left main bronchus is set at an angle of 75° with the vertical. The foreign body penetrates to a depth varying with its size and shape and consistency. Inhaled vomit or mucus may reach the smaller bronchi; a small pin may similarly reach the smaller bronchi if its long axis is in the line of the lumen. A small piece of

chewed nut, or a tack, for example, may only reach a major subdivision of a main bronchus, while a larger object, such as a peanut or a tooth, will be held up in the main bronchus itself.

When a foreign body enters a bronchus, either the object so occludes the lumen that air entry to the distal segment is inadequate and segmental collapse takes place, or the foreign body becomes so lodged in the lumen that it allows the more powerful inspiratory stream of air to pass but it obstructs the expiratory stream, which is less strong and is impeded by bronchial contraction, with a resultant emphysema of the distal segment (*Fig. 109*).



Fig. 109. Emphysema of left lobe due to a piece of nut in the lower lobe bronchus.

On clinical examination the features of collapse are dullness on percussion and lack of air entry, while if decomposition has taken place with the production of an inflammatory reaction moist sounds will be heard. If there is distal emphysema there will be a prolongation of expiration in the affected lobe, and later hyper-resonance over that lobe.

Radiography may be diagnostic. A radio-opaque foreign body will be seen (*Fig. 110*), and if anteroposterior, lateral and oblique views are taken its position may be accurately determined. A non-opaque foreign body, such as plastic or vegetable matter, is much more difficult to diagnose radiographically, and in the early stages the films may show no abnormality. It is important to realize this, and not to dismiss the possibility of an inhaled foreign body on the strength of a negative radiograph. Later there may be emphysema of a lobe (*Fig. 109*) or of a lung, while an occlusive non-opaque foreign body will eventually show the typical radiographic appearance of a collapse of one or more lobes of a lung, with a shift of the cardiac shadow to that side.

TREATMENT. This is the removal of the object at bronchoscopy, and a history suggestive of the inhalation of a foreign body is sufficient justification for a diagnostic bronchoscopy even in the absence of positive clinical or radiological signs. Bronchoscopy is performed under general anaesthesia administered by a skilled anaesthetist, whose duty it is to maintain a constant watch on the pulse, slowing of which is the earliest sign of hypoxia, which may rapidly lead to cardiac failure. The younger the child, the greater is the danger and the more difficult is the successful removal. Each bronchoscopist has his own method but it is found that satisfactory results are obtained by a two-stage procedure. The first bronchoscopy is used to aspirate secretions and to locate the foreign body and note its position. The child is immediately




Fig. 110. Tack in right main bronchus.

deepened anaesthetically, the bronchoscope re-inserted and the object grasped and removed. Inorganic foreign bodies of average size are usually easily removed. A small object, such as a pin, may have moved peripherally so that it cannot be seen through the bronchoscope, and if it cannot be extracted by a magnetized probe, its removal may have to be undertaken by the thoracic surgeons at a thoracotomy. An organic foreign body of recent inhalation presents fewer problems than one which has been allowed to remain in the lung for some time. In the latter instance there is local oedema and even granulation tissue around the object which itself may have become soft and friable. In such a case it is important that after removing the main part of the object a further examination is made immediately to ensure a complete extraction. A foreign body of plastic material produces no local reaction and is thus reasonably easy to remove.

PROGNOSIS. A successful removal of a foreign body will result in the recovery of the lung. If an organic object has lain for some weeks in the bronchus before removal the expansion of the collapsed lobe will be slow in virtue of the local infection present, and antibiotic therapy will be necessary. An incomplete removal of such an organic object, or the lack of diagnosis of an organic foreign body, will lead to a lung abscess, which may require thoracic surgery,

often of a major nature. Inhaled foreign bodies are potentially fatal, and the returns of the Registrar-General show many deaths each year attributable to inhaled objects.

THE OESOPHAGUS

Unlike inhaled foreign bodies, which are most commonly met with in children, swallowed foreign bodies are frequently found in adults as well. The upper end of the oesophagus is closed by the cricopharyngeus muscle which opens during the act of swallowing to allow the food bolus to enter. In children this sphincter-like muscle will contract rapidly if a foreign body enters the oesophagus, and the object is held immediately below the muscle at the upper end of the oesophagus where it may lie for a matter of hours. In adults it is usual for a sharp object to be similarly arrested, but other foreign bodies may pass the cricopharyngeus to become held up at a lower level because the weak oesophageal peristalsis cannot propel them onwards. Once a foreign body passes the upper end of the oesophagus it may be arrested at the hiatus, or, less commonly, at the level of the crossing of the left bronchus.

In children the most frequently swallowed objects are coins or small disc-shaped or irregular playthings. More rarely a child will swallow a sharp object such as an open safety-pin or a bone. The oesophagus only responds to the painful stimuli of scratching or stretching, so that the child may be symptomless when first seen. Indeed, a child may have no dysphagia or stridor, and may be able to swallow fluids with a coin 2.5 cm in diameter held just below the level of the cricopharyngeus. A larger disc-shaped object may induce dysphagia or even stridor, while a pointed foreign body will produce pain on swallowing, so that saliva may dribble from the mouth. It is important when radiographs are taken to locate the foreign body, that the films include the mandible or the object may be missed (*Fig. 111*). The upper end of the oesophagus lies behind the cricoid cartilage, and a radiograph in which the clavicles appear at the top of the plate may well have excluded a foreign body. Deaths have occurred from mediastinitis following perforation of the oesophagus by sharp foreign bodies which, for this reason, had never been demonstrated at radiography.

In adults the most commonly swallowed objects are bones of fish, game or meat. These are often retained in the pyriform fossa or they may be held up immediately distal to the cricopharyngeus, where they give rise to pain and dysphagia. Because of the insensitive nature of the oesophagus, localization is poor. A jagged bone may scratch the mucosa during its passage through the oesophagus, and such a scratch causes pain on swallowing. In older people unchewed meat may cause obstruction. This is especially the case if the patient is edentulous, when meat may not be sufficiently masticated to pass through the oesophagus and is retained at the hiatus. Patients with an oesophageal narrowing, whether due to a stenosis or to a carcinoma, will obstruct more easily, and it is important in certain cases to ensure, once the foreign body has been removed, that there is no underlying pathology. Such an obstruction is often complete, resulting in vomiting and even inability to swallow fluids, so that dehydration ensues, and in children this may be rapid and severe.

CLINICAL FEATURES. There is usually a history of the object having been swallowed, and this is true even in children. Very often a finger has been

inserted by the patient or parent and the epiglottis may have been felt in mistake for the object. The probing finger may scratch the mucosa of the pharynx or hypopharynx. On indirect laryngoscopy in the adult excessive secretion lying in the pyriform fossa is highly suggestive of a foreign body lodged in the oesophagus. In some cases the object may be seen.




Fig. 111. Coin arrested at upper end of the oesophagus. (Note the position of the coin in relation to the mandible and the clavicles.)

Radiography is advisable for all opaque foreign bodies (*Fig. 112*) and anteroposterior and lateral views should be obtained to determine the level and position of the object. If the foreign body is non-opaque it is debatable whether a thin barium swallow should be given before radiography. This may outline the object, which is thus demonstrated, but at subsequent oesophagoscopy the barium must be aspirated so that the foreign body may be inspected and removed, and later in order that the oesophageal walls may be thoroughly examined for any tear.

TREATMENT. When the presence of a foreign body in the oesophagus has been demonstrated radiographically it must be removed. If the symptoms of pain or obvious blockage lead to a diagnosis of foreign body, oesophagoscopy must be performed. If there is a history of something having been swallowed, and having stuck, but when there are no remaining symptoms, and the object is not opaque to radiographs, the decision to examine by oesophagoscopy must be considered. A negative oesophagoscopy removes all doubt. A positive oesophagoscopy also removes all doubt. If oesophagoscopy is not performed, doubt remains, and there is always the possibility that an object left in the oesophagus may ulcerate or perforate the walls. Oesophagoscopy under general anaesthesia causes little discomfort afterwards and it is wiser to recommend it on all occasions.

Oesophagoscopy is best performed under general intubation anaesthesia. It may be a prolonged procedure; the presence of an oesophagoscope may

embarrass the airway, especially in children, and this is prevented by intubation; oesophagoscopy under local anaesthesia is uncomfortable for the patient, who, should he struggle, may precipitate damage to the wall of the oesophagus by the forceps, the oesophagoscope or the foreign body itself. Disc-shaped objects or those with smooth edges are easily withdrawn after a little experience. Sharp-edged objects require considerable dexterity to disimpact them from the walls of the oesophagus and to remove them without

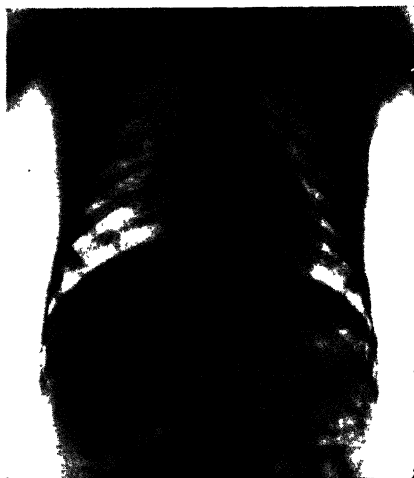


Fig. 112. Coin arrested in the lower part of the oesophagus.

further scratching. Large masses of unchewed meat tend to be friable and to come away in pieces, so that the procedure is prolonged. It may be tempting to push some of this through into the stomach, but the bolus may be held up by an undiagnosed carcinoma or hiatus hernia with oesophagitis, and such a manoeuvre may traumatize or perforate the oesophageal wall, and it is therefore to be condemned.

Any scratch or tear of the oesophageal wall calls for a course of antibiotics and for feeding by sterile fluids for 24 hours. The danger of infection spreading through the oesophagus into the mediastinum must always be borne in mind if the wall has been damaged by a foreign body or by attempts at its removal. Rarely a sharp object may have perforated the wall of the oesophagus to lie partly within and partly outside the lumen. In this case removal is best made by an external incision and dissection to the oesophagus, when the tear may be sutured after the object has been removed.

CHAPTER 43

DYSPHAGIA

About half of the patients with dysphagia present first to an otolaryngologist. He should therefore know how to manage the condition and how to decide which cases should be referred to a thoracic surgeon or to a gastro-enterologist, and which cases are best dealt with by his own discipline. This chapter will therefore aim to give some guidelines on how to approach the problem, and to make the above decisions. Although an outline description of the commonest oesophageal conditions will be given, it is to be appreciated that it is impossible to present an exhaustive treatise on oesophageal disease in a chapter of a book of this type.

HISTORY

Dysphagia is an all-embracing term meaning difficulty in swallowing, but there are all shades of difficulty ranging from a mere local discomfort to a total hold-up to the passage of food.

The first thing to establish is the nature of the symptoms which are presented by the patient with phrases such as 'food won't go down', 'food sticks', 'food comes back up', 'I've got a feeling of a lump in my throat', etc. It will be appreciated that there is a very distinct difference between food not passing and a mere feeling of discomfort in the throat.

The site of the problem is important. The oesophagus is shorter than one thinks—it begins just above the suprasternal notch—and symptoms at the oesophagogastric junction are often located at the xiphi-sternal notch. Patients are remarkably accurate in siting oesophageal problems. An example of this accuracy at the upper end is illustrated by the fact that if a foreign body is arrested just above the cricoid level the patient will point above the cricoid, and the foreign body should be seen on mirror examination, but if he points below the cricoid then he will need an oesophagoscopy for visualization of the foreign body.

The severity of the symptoms may be gauged by the amount of food and fluid the patient can swallow. Generally, when the patient is only able to take fluids or very soft foods there will be weight loss to confirm the desperate state of affairs. An exception to this pattern of events is in achalasia where there is often more difficulty in swallowing fluids than solids.

Pain is not often a feature of dysphagia unless there is some degree of oesophagitis, most commonly due to acid reflux, but is occasionally seen in monilial oesophagitis. A very characteristic pattern of presentation of oesophageal disease is pain and discomfort at the lower end with a feeling of tightness at the cricoid level. This is due to the fact that lower-end oesophagitis causes reflex spasm of the cricopharyngeus muscle.

If there is a total block in the oesophagus the patient will immediately vomit everything he eats or drinks. This type of picture must be differentiated from a later regurgitation of undigested food seen with a pharyngeal pouch. If food builds up and collects in the oesophagus, such as occurs above a stricture, a tumour or an achalasia, then it will eventually overflow, enter the larynx, and cause at first coughing fits, and later inhalation pneumonia.

The age of presentation of the patient gives some idea of the pathology. Children may have congenital problems such as tracheo-oesophageal fistula, web, congenital vascular anomalies or hiatus hernia and they are prone to foreign bodies and corrosive burns. In middle age, while cancer must always be considered, the most likely causes are achalasia, oesophagitis from reflux and hiatus hernia, globus hystericus, Paterson-Brown Kelly syndrome and pharyngeal pouch. In the elderly the cause of dysphagia is cancer of the oesophagus until proved otherwise, although it may be due to osteophytes impinging on the oesophagus, diverticula, or strictures from long-standing oesophagitis.

Enquiry must be made into precipitating factors such as the effect of position, various types of food, worry, etc. and alleviating factors such as antacids or tranquillizers.

Associated symptoms such as voice change may signify recurrent laryngeal nerve involvement or pachydermia due to reflux of acid burning the interarytenoid area. A large thyroid or a retrosternal thyroid, an aortic aneurysm or a bronchial carcinoma can cause extrinsic pressure, as can osteophytes.

In the past history one must find out about any accidental ingestion of corrosives in childhood, treatment for indigestion or peptic ulcer, and irradiation for thyroid or chest conditions.

EXAMINATION

1. General. There are few external signs of oesophageal disease. The patient must be weighed and assessed for weight loss. The neck should be carefully palpated for supraclavicular nodes on the left side and also for thyroid nodules or enlargement. The patient should be asked to swallow some water, and the swallowing efforts should be observed, and the neck palpated at the same time. The larynx should be examined for evidence of vocal cord paralysis or pooling of saliva in the pyriform fossa signifying hold-up. Note is taken of the state of the tongue, the corners of the mouth and nails as these are changed in the Paterson-Brown Kelly syndrome. The abdomen should be palpated for any epigastric tenderness.

2. Laboratory Investigations. All patients should have a full haematological examination and where the haemoglobin is low or the film confirms a microcytic anaemia, a serum iron and iron-binding capacity test should be done. If it is indicated the thyroid function tests should be performed and if there has been vomiting or loss of weight the urea and electrolytes ought to be investigated.

3. Radiography. This forms the keystone to the examination of oesophageal disease. A barium swallow with or without a barium meal must be done in every case of dysphagia. If any abnormality is seen then it is usually followed up by oesophagoscopy. This is best performed by the person who is going to carry out the future definitive treatment. If no radiographic abnormality is

seen then no immediate action need be taken, except in one circumstance. If the patient has ever complained of food sticking during swallowing he should have an oesophagoscopy because this is one of the earliest signs of cancer.

A chest radiograph should also be done in every case to rule out abnormalities that could cause extrinsic pressure, such as aneurysms. When the patient has inhalational problems signs are seen on the chest radiograph that may resemble cannonball secondaries. While these may well represent metastases, they may also denote patches of consolidation due to food debris and infection.

4. Oesophagoscopy. This is done with either a rigid tube or a flexible oesophagoscope. The technique is described in Chapter 41 (p. 212).

PATHOLOGY OF CONDITIONS CAUSING DYSPHAGIA

Hiatus Hernia.

CLASSIFICATION.

1. Congenitally short oesophagus with thoracic stomach. This accounts for 5 per cent of cases. The stomach is not truly herniated, since it has never been below the diaphragm.

2. Oesophageal hiatus hernia with shortened oesophagus. This is acquired rather than congenital and the oesophagus becomes shortened as a result of tonic contractions or cicatricial shrinkage.

3. Oesophageal hiatus hernia without shortening of the oesophagus ('Sliding hernia'). This type together with the hernia with a short oesophagus forms 87 per cent of hiatus hernias. The cardia is incompetent, as is the diaphragmatic valve.

4. Para-oesophageal hernia through the hiatus. This forms 6 per cent of cases. A portion of the stomach herniates through the oesophageal hiatus and comes to lie alongside, and parallel to, the lower end of the oesophagus. An important feature is that the oesophagogastric junction lies below the diaphragm.

AETIOLOGY. Most patients are obese and the male : female ratio is 1 : 2. It is most commonly seen over the age of 40 and its greatest frequency is between 60 and 80 years.

SYMPTOMS. No definite symptoms are pathognomonic and in some cases the patient is asymptomatic. In the symptomatic cases the main complaints are of epigastric discomfort, postural heartburn, flatulence, dysphagia and a feeling of a lump in the throat.

TREATMENT. The most important point in treatment is to get the patient to lose weight, sleep upright, avoid constrictive clothing and to eat small meals often. Antispasmodics and mild sedatives are useful, as is Mucaïne which acts as a protective to the inflamed oesophagus. 5-10 ml are taken four times daily before meals and at bedtime. If heartburn forms a major part of the picture then it should be treated with 10 ml of aluminium hydroxide gel (Aludrox) every 2 hours. If conservative treatment fails attempts should be made to reduce the hernia surgically and to repair the diaphragmatic sphincter.

OESOPHAGEAL STRICTURE

AETIOLOGY. The commonest causes of this are: (1) Long-standing oesophagitis; (2) Surgical correction of hiatus hernia or of a previous stricture; (3) Corrosive oesophagitis; (4) Cancer of the oesophagus.

Any site may be affected, but due to the nature of the above conditions it is usually found in the middle or lower thirds of the oesophagus.

SYMPTOMS. The symptoms are a gradually increasing dysphagia with some discomfort at the site of the stricture. On occasion the patient may present as an acute emergency with total dysphagia due to a bolus of meat becoming stuck in the stricture. If the condition is of long duration there will be weight loss.

TREATMENT. In the non-malignant conditions, attempts should be made to alleviate the condition by dilatation. The initial dilatations are done via oesophagoscopy using Jackson bougies. Dilatations should be done until the stricture becomes tight. On no account should the stricture be dilated until it bleeds because this leads to more fibrous tissue formation. The dilatations are done at weekly or fortnightly intervals until the maximum lumen is achieved. At this point the patient should be taught to swallow a Hurst mercury bougie before meals to maintain the dilatation. If this regime is unsuccessful the stricture should be excised surgically and an end-to-end anastomosis performed. This is easier if the stricture is in the lower third than in the middle third where the results are unrewarding.

PATERSON-BROWN KELLY SYNDROME

AETIOLOGY. In the United States this is known as the Plummer-Vinson syndrome and it consists of dysphagia, hypochromic microcytic anaemia, angular stomatitis, glossitis and koilonychia. It is more common in females than in males, and also more common on the West coast of Britain than the East coast. The cause of the syndrome is unknown, but since there is an atrophy of all the mucous membranes of the alimentary tract an auto-immune basis must be presumed.

SYMPTOMS. The dysphagia may be very marked, but it is not usually severe. The angular stomatitis, glossitis and koilonychia (*Fig. 113*) may be slight. The characteristic blood picture is a low haemoglobin and a hypochromic microcytic anaemia. All cases will have a low serum iron and a consequently high iron-binding capacity. A small, but significant, proportion of patients with this condition progress to the stage of postcricoid carcinoma. The relationship is not close enough to label the Paterson-Brown Kelly syndrome as a pre-malignant condition. A curious radiographic finding of unknown cause is a web at the postcricoid region (*Fig. 114*). This can often be seen at oesophagoscopy and may indeed be a firm diaphragm requiring dilatation, but sometimes a well-marked radiological web may not be visualized at oesophagoscopy.

TREATMENT. Iron should be given orally at first until the haemoglobin is within normal limits. From then on, a check should be kept on the serum iron and the iron-binding capacity. When the haemoglobin has been restored to normal the serum iron will still be low and, due to absorption problems, may stay low in spite of oral iron administration. While the serum iron is low, dysphagia will continue, and so if oral iron fails to raise it to the normal level then the patient will require to be given parenteral iron. A check on the course of the disease during follow-up should always be by means of the serum iron rather than the haemoglobin.

PHARYNGEAL POUCH

AETIOLOGY. The upper end of the oesophagus is guarded by a muscle sphincter called the cricopharyngeus which is normally closed. The lower part of the pharynx has a weak area at the lower part of the inferior constrictor muscle—the so-called dehiscence of Killian (*Fig. 115*). At this point there is only a mucosal layer, a submucosa and one layer of muscle fibres. If the patient has the habit of a 'double swallow' and develops an abnormally high intrapharyngeal pressure during swallowing then this weak area will be subjected



Fig. 113. Shows spoon-shaped, brittle nails in the Paterson-Brown Kelly syndrome.



Fig. 114. Radiograph to show the Paterson-Brown Kelly syndrome with web.

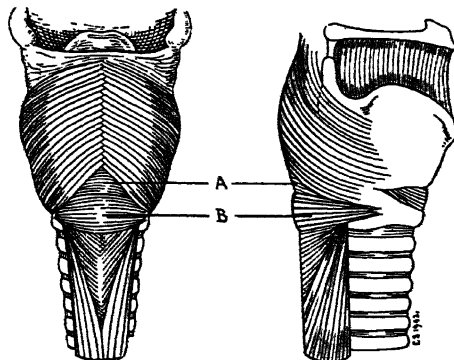


Fig. 115. A, Site of origin of pouch between oblique and transverse cricopharyngeus; B, Cricopharyngeal sphincter.

to pressure. This is reinforced if the cricopharyngeus stays closed longer than usual, or if it has a high state of tonus. Gradually the area expands and soon forms a pouch. Food collects in this small pouch thus stretching it more and enlarging it. When the pouch gets to a certain size it lies in line with the oesophagus and becomes the natural opening for food (and oesophagoscopes!) to enter. This further increases its size and causes it to expand and to press on the oesophagus when full of food, causing dysphagia.

SYMPTOMS. Even when the pouch is small there will be a feeling of a lump in the throat. As the pouch enlarges true dysphagia will follow. When the pouch fills with food during a meal there will come a point when it overflows into the pharynx causing regurgitation of undigested food. Some may overflow into the larynx resulting in coughing fits. A barium swallow will confirm the diagnosis (*Fig. 116*).

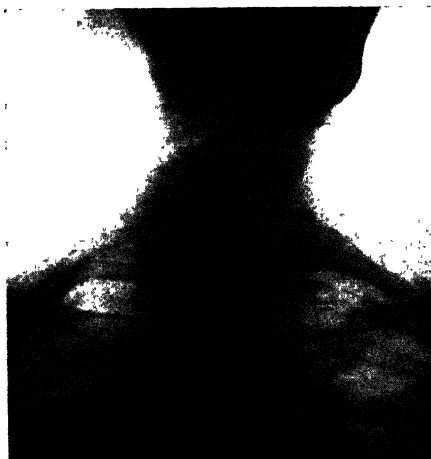


Fig. 116. Radiograph to show a pharyngeal pouch.

TREATMENT. The most satisfactory treatment of a pouch is to remove it. This is done by making a collar incision on the left side of the neck, retracting the carotid sheath laterally and the laryngopharynx medially, identifying the pouch (which can be made easier by packing it with acriflavine prior to surgery), dividing the neck of the pouch and suturing the opening in layers. If too much is removed there is a danger of stenosis, but if not enough is removed the pouch will recur.

An alternative method exists of using diathermy coagulation of the common wall between the pouch and the oesophagus (Dohlman's operation). This is a simpler and quicker method than excision, but in inexperienced hands it can lead to mediastinitis from perforation and damage to the recurrent laryngeal nerves by diathermy. The procedure is done endoscopically using a specially designed oesophagoscope with two beaks—one for the oesophagus and one for the pouch. The stretched wall between the two is clamped and diathermied, again using specially designed instruments.

GLOBUS HYSTERICUS

This is a descriptive term applied to cases usually complaining of a feeling of a lump in the throat which is brought on or made worse by anxiety and in which no other organic cause can be found.

Some cases are easy and safe to diagnose as globus—if there is an obvious emotional precipitating cause. The difficult cases are those in which there is no obvious psychological cause. Great care must be taken not to miss an early carcinoma. In this latter group oesophagoscopy must be done in spite of a negative barium examination.

Globus is diagnosed much less now than formerly, because it has been realized that oesophagitis and reflex spasm of cricopharyngeus can mimic the symptoms. In these cases antacids will help the 'globus' symptoms. In the true globus cases, reassurance that no organic disease or cancer is present helps the patient to accommodate to the symptoms which will usually be self-limiting.

Another cause of globus-type symptoms is the presence of cervical osteophytes indenting the posterior wall of the pharynx. These can be removed by exposing them using the same approach as for a pharyngeal pouch.

ACHALASIA

AETIOLOGY. This is also called 'cardiospasm', and is due to a defect in the intramural vagal supply (Auerbach's myenteric plexus). During swallowing, there is a loss of tone due to a lack of integrated parasympathetic stimulation and non-propulsive motility in the body of the oesophagus. There is also a failure of relaxation at the cardia.

The lower area acts as a stricture and the oesophagus above this becomes very dilated and usually full of food debris.

SYMPTOMS. There are few symptoms until the condition is advanced. The main symptoms are then intermittent difficulty in swallowing associated with discomfort and attacks of regurgitation. As the condition progresses and dilatation occurs, food entering the stomach does not initiate peristalsis, and so large quantities of food collect in the oesophagus. This causes an upset in the swallowing mechanism and the condition becomes progressively worse.

On barium swallow the oesophagus is very dilated, lengthened and occasionally sigmoid in shape (*Fig. 117*). When the patient is screened the barium will be seen to be held up for a considerable time and to pass into the stomach only when the pressure reaches a certain level. At the point of delay there is no irregularity and the barium emerges centrally as distinct from neoplasm.

TREATMENT. In mild cases treatment with anticholinergic drugs is successful, but most cases will come to surgery, when a Heller's operation is done.

CORROSIVE BURNS OF THE OESOPHAGUS

This injury is not as common in this country as in America, Africa and Scandinavia. It usually occurs in children or potential suicides and the substances swallowed are strong acids or alkalis. High concentration or large volumes of the substance are the most damaging.

The area first affected is the mouth (*Fig. 118*) and pharynx, and if the substance is swallowed the middle third of the oesophagus is the most frequently involved, although the strictures may be multiple. Spillage of the caustic substance on to the larynx may cause oedema.

PATHOLOGY. As with burns elsewhere, the caustic burn of the oesophagus varies in degree. It may involve only the mucous and submucous layers which heal without stricture formation. In more severe burns, necrosis may

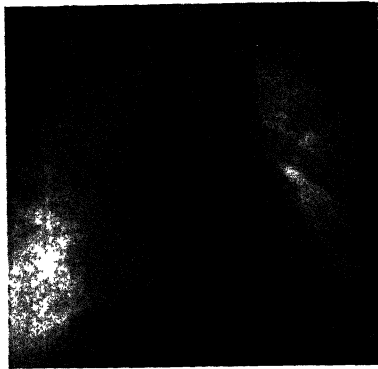


Fig. 117. Achalasia of the oesophagus, showing greatly dilated oesophagus.




Fig. 118. Lysol burn. The caustic stain is seen on the mouth and neck. A nasogastric tube has been inserted for feeding.

occur in the oesophageal wall involving all coats. This may heal with fibrosis and stricture formation, or perforation of the oesophageal wall may occur.

TREATMENT. If the substance can be identified attempts should be made to neutralize it. Most patients will have visible burns on the lips, mouth and pharynx. The problem is to decide whether the substance has been swallowed or if it has all been spat out. If doubt exists then it is probably safer to perform oesophagoscopy to see the extent of the burn if it is present. A flexible oesophagoscope should be used in preference to the rigid one. If no burn is

visible it may be assumed that no caustic was swallowed, and the oral burns will heal in time.

In cases where there is no doubt that the substance was swallowed there is little to gain by passing an oesophagoscope merely to assess the extent of the burn since the treatment will be unaltered and because there is a real risk of perforating the oesophagus with the instrument. These cases should have a nasogastric feeding tube passed. They should immediately be started on 60 mg prednisolone per day for a week, the dose tapering off thereafter over a further 3-4 weeks. This is given to prevent fibrosis and subsequent stricture formation. Antibiotics should also be given systemically during this period, a combination of penicillin G and streptomycin (Crystamycin) being the drug of choice.

After 3 or 4 weeks an oesophagoscopy should be done to assess the presence or absence of stricture formation. At this stage there is less danger of causing a perforation. If a stricture has formed a programme of dilatation should be started.

CANCER OF THE OESOPHAGUS

Cancer of the oesophagus has a particularly gloomy prognosis and can occur in the cervical oesophagus, the middle third and the lower third. While all three may present to the otolaryngologist in the first instance, he will usually only be involved in dealing with cancers of the cervical oesophagus. This is not to be confused with postcricoid cancer, which is higher and forms part of hypopharyngeal cancer, which is dealt with elsewhere (p. 234).

PATHOLOGY. Most of the tumours are squamous-cell cancers, but at the lower end of the oesophagus there is a proportion of adenocarcinomata which take origin from the gastric mucosa or glands. The tumours may be exophytic, projecting into and filling the lumen of the oesophagus, or they may be ulcerative.

There is a large network of submucosal lymphatics and thus spread up and down the oesophagus is common. It is typical to find islands of cancer with apparently ulcerating areas in between—so-called 'skip lesions'. Extension may also occur through the wall of the oesophagus to involve the recurrent laryngeal nerves, and even the trachea and bronchi with the formation of a broncho-oesophageal fistula.

SYMPTOMS. Early symptoms are frequently indefinite, a vague discomfort behind the sternum, a feeling of a 'lump' in the throat and food sticking on occasion. Late symptoms are marked difficulty in swallowing firstly with solids and later with fluids. There is loss of weight, dehydration and glandular enlargement in the left supraclavicular region.

INVESTIGATIONS.

1. *Mirror Examination.* In early cases all that may be noticed is some pooling of saliva in the pyriform fossae. Later on there may be some oedema of the postcricoid region or the arytenoids, or a vocal cord paralysis.

2. *General Examination.* There will often be a node palpable in the left supraclavicular region. In cancer of the lower end of the oesophagus it may be possible to palpate an epigastric mass in some cases.

3. *Radiological Examination.* A barium swallow may reveal a stricture which is constant and has a slight dilatation above it (*Fig. 119*). The usual filling

defect, however, is an irregular one from which the stream of barium issues eccentrically. This contrasts with the smooth tapering concentric appearance of cardiospasm. Cancer may also show as an irregular oesophagitis at the lower end with some ulceration.

4. *Oesophagoscopy*. This is indicated in the following circumstances:

(a) Where the radiograph suggests the presence of cancer, (b) Where there are no radiographic findings to explain the patient's condition, and (c) Where a

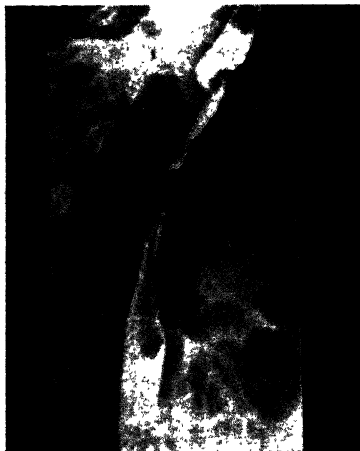

Fig. 119. Carcinoma of upper oesophagus.

benign condition has been diagnosed, but has failed to respond to the requisite treatment. At oesophagoscopy the site and extent of the lesion are noted, and a biopsy is taken.

TREATMENT.

Lower Third. If the tumour is a squamous-cell carcinoma, the initial treatment is by irradiation, and if a recurrence is found early enough an oesophagogastrectomy can be done. If the tumour is an adenocarcinoma the treatment should be primarily surgical.

Middle Third. These tumours are all squamous-cell carcinomas and thus the treatment is primary radiotherapy. In the event of a recurrence an oesophageal resection and gastric replacement can be attempted, but the chances of this being possible are remote.

Cervical Oesophagus. The treatment of these tumours is similar to that of postcricoid tumours. Radiotherapy is the primary method of treatment and will cure about 15 per cent. In recurrences the larynx, pharynx and at least part of the oesophagus must be removed. With regard to this it is wise to follow the example of the thoracic surgeons and to remove a hand's breadth of normal oesophagus distal to the lesion. This makes sound sense when one considers the extent of the submucosal lymphatic system and the presence of 'skip' lesions. If a hand's breadth is removed from below a cervical oesophageal tumour no type of skin repair is possible, and one is left with a choice of the various visceral transplants, among which are colon, jejunum and stomach.

DYSPHAGIA

For the past 8 years the author has preferred to use stomach to replace oesophagus removed in the treatment of this cancer. The larynx and pharynx are freed from the base of the tongue, the trachea is transected around the fourth ring and the oesophagus is freed by finger dissection down to the level of the left main bronchus. The abdomen is opened, the stomach freed and pedicled on the gastro-epiploic artery and the right gastric artery, the vagus nerve divided, a pyloroplasty done and the lower half of the oesophagus freed by blunt finger dissection. When the oesophagus has been freed, the top end of the specimen is gently pulled and the stomach is drawn through the posterior mediastinum into the neck. The oesophagus is divided from the stomach at the cardia and the fundus of the stomach is joined on to the base of the tongue and posterior pharyngeal wall. The pylorus lies then at the cardia. Only if neck glands are palpable is a radical neck dissection done; otherwise an expectant policy is adopted. The use of this operation as a salvage procedure rescues about 1 in 4 recurrences.

CHAPTER 44

CANCER OF THE HYPOPHARYNX

ANATOMY. For the purposes of tumour classification the hypopharynx is divided into three areas (*Fig. 120*).

1. The *pyriform fossa* is paired and lies on either side of the larynx being bounded medially by the ary-epiglottic folds, laterally by the inner surface of the thyroid ala, superiorly by the pharyngo-epiglottic fold and inferiorly it extends to the mouth of the oesophagus. Like the ary-epiglottic fold which bounds it, the pyriform fossa has a rich lymphatic drainage and a relatively

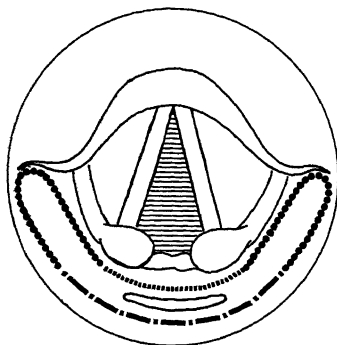


Fig. 120. The areas of the hypopharynx. pyriform fossa; postcricoid region; ——— posterior pharyngeal wall.

poor sensory supply resulting in tumours presenting late with lymph node metastases.

2. The *posterior pharyngeal wall* (*Fig. 121*) extends from the level of the hyoid bone above to the level of the inferior margin of the cricoid cartilage below and laterally to the posterior margins of the pyriform fossa.

3. The *postcricoid region* (*Fig. 121*) is in fact very small and is confined to the posterior surface of the larynx and extends from the posterior surface of the arytenoid cartilage and its connecting folds to the inferior surface of the cricoid cartilage; its lateral margin is the posterior part of the pyriform fossa. Inferior to the cricoid cartilage is the cervical oesophagus but, although inaccurate, the name postcricoid has been applied to the whole area around and including the mouth of the oesophagus. Postcricoid tumours *per se* are very rare and in this book tumours of the cervical oesophagus (which may be known as postcricoid) are dealt with in the chapter on dysphagia.

PATHOLOGY. Most of the tumours of the hypopharynx are squamous-cell carcinomas and their site incidence is as follows: pyriform fossa, 60 per cent; postcricoid/cervical oesophagus, 30 per cent; posterior wall, 10 per cent.

The pyriform fossa has the richest lymphatic drainage and so patients with tumours in this site have a 75 per cent incidence of lymph node metastases (*Fig. 122*); of these, about half will have bilateral nodes. Tumours on the

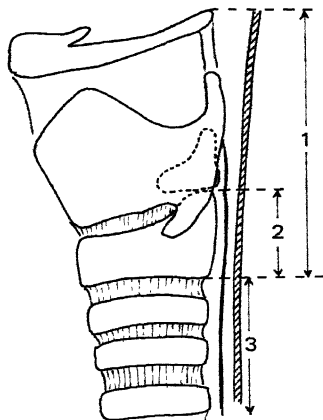


Fig. 121. Lateral view of larynx showing: 1, Posterior pharyngeal wall; 2, Postcricoid region; 3, Cervical oesophagus.

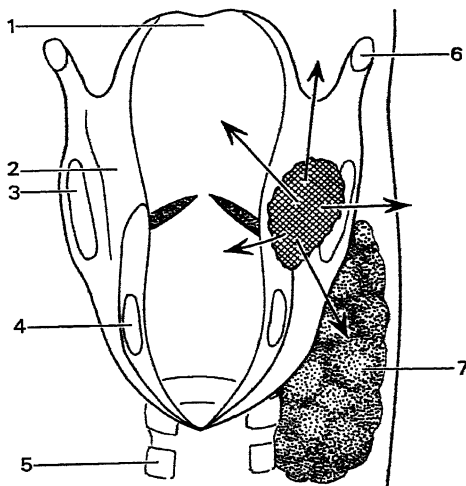


Fig. 122. Routes of spread of tumours of the pyriform fossa. 1, Epiglottis; 2, Pyriform fossa; 3, Thyroid cartilage; 4, Cricoid cartilage; 5, Trachea; 6, Hyoid bone; 7, Thyroid gland. (By courtesy of *Heinemann Medical Books.*)

lateral wall of the pyriform fossa often present as a mass in the neck—either a metastatic gland or an extension of the tumour outside the laryngopharynx. If the tumour is primarily on the medial wall it will involve the larynx and cause hoarseness. Any tumour of the pyriform fossa may extend up to the tongue or downwards into the cervical oesophagus.

Most tumours diagnosed as postcricoid are either cervical oesophageal tumours 'coming up' or pyriform fossa tumours 'going down'. Because the oesophagus is involved the incidence of 'skip lesions' due to wide dissemination in the submucosal lymphatics is high. About 20 per cent of these patients have a metastatic gland when first seen. In this tumour spread also occurs to the paratracheal nodes and mediastinal nodes.

Tumours of the posterior pharyngeal wall are usually midline and exophytic. They are confined to the posterior wall until late in the disease and about 50 per cent of patients have a metastatic node when first seen.

Although squamous carcinoma is the commonest tumour, various sarcomas may occur. The carcinosarcoma or spindle-cell carcinoma is a polypoidal tumour usually arising from the posterior pharyngeal wall. It is slow growing and relatively benign. Similarly the leiomyosarcoma is a polypoidal non-aggressive tumour which does well with merely wide local removal.

Benign tumours such as leiomyoma, lipoma and fibrolipoma are also found.

HISTORY. The clinical picture of the large hypopharyngeal tumour is unmistakable. The patient has dysphagia at first for solids and then for fluids with resultant aspiration and lung infections. There is weight loss of several stones and biochemical evidence of dehydration, protein and electrolyte deprivation and starvation. As the surrounding structures are involved, the patient will have dysphonia either due to direct invasion of the larynx or to vocal cord paralysis consequent to recurrent laryngeal nerve involvement.

The diagnosis of the early case presents some difficulty, however. These patients will complain of a feeling of 'something' in the throat around the level of the cricoid. Unfortunately, so too will many thousands of other patients with oesophagitis or anxiety neurosis in the globus hystericus type of picture. Every patient with this symptom must have a barium swallow and meal but to pass an oesophagoscope in every one of these people would be an impossible task. Two symptoms help in sorting out patients with this symptom and a normal barium swallow; first, if they have ever had food sticking and secondly if they have a constant feeling of a crumb in the throat. Such cases must have an oesophagoscopy.

Although it is not pre-malignant, a surprisingly high proportion of these cases give a past history of the Paterson-Brown Kelly syndrome (*see* Chapter 43). What is more significant, however, are those patients who give a history of irradiation for thyrotoxicosis 25–30 years before.

EXAMINATION. Indirect laryngoscopy may show the presence of a frank tumour in the pyriform fossa or the posterior pharyngeal wall. It will not, however, show up a cervical oesophageal or a postcricoid tumour—these will manifest themselves by oedema of the arytenoids, or by pooling of saliva in the pyriform fossae. If the recurrent laryngeal nerves have been involved one or both vocal cords will not move. In palpating the neck it is vital to differentiate the mass which is a direct extension of a pyriform fossa tumour from a

metastatic gland. One helpful guide is that metastatic glands do not move on swallowing.

Radiology. This is a mandatory investigation in all patients complaining of any throat symptoms. The plain radiograph is of limited value but an enlargement of the soft-tissue shadow posterior to the trachea is suggestive of a postcricoid tumour. As a general rule if the soft-tissue shadow is wider than the body of a vertebra then it is abnormal. Tumours of the pyriform fossa may also destroy areas of the thyroid cartilage.

The key investigation is the barium swallow which should demonstrate 95 per cent of all hypopharyngeal tumours. The greatest use of this investigation is in delineating the lower end of a cervical oesophageal lesion through which an oesophagoscope cannot be passed. A chest radiograph will occasionally show multiple opacities which may be secondary deposits or patches of consolidation due to aspiration of food.

Endoscopy. This will be done in every patient with an abnormal barium radiograph and also in those who have experienced food sticking or a feeling of a 'crumb' in the throat. The short oesophagoscope, the laryngoscope and the female small-diameter oesophagoscope are the most commonly used instruments. Not only must a biopsy be done but an accurate assessment of the extent of the tumour must be made because this will influence treatment.

TREATMENT POLICY. At the outset it should be said that the 5-year survival for any of these tumours is poor. Many of the patients present late with advanced tumours, and because of age, tumour dissemination and general condition about 1 in 3 are not treated by any modality. There is no such thing as 'palliative' radiotherapy in these tumours; they seldom have pain and radiotherapy will cause painful mucositis. Of those untreated, death will be by aspiration pneumonia in most instances. If the growth has been considered too advanced for successful treatment the general practitioner should be so informed, and he should not seek to prolong life by antibiotic therapy for intercurrent infections.

In nearly all cases it will be necessary to remove the larynx as well as the pharynx if surgery is chosen as the primary modality. On the other hand, radiotherapy does not show encouraging results, the best being about a 20 per cent 5-year survival. Another fact that must be borne in mind is the high incidence of lymphatic metastases.

Pyriform Fossa. If the tumour is small and does not involve the postcricoid region a total laryngectomy and partial pharyngectomy can be done, closing the remaining pharynx primarily. If a gland is palpable, and even if none is palpable, a radical neck dissection should be done.

If the tumour involves the postcricoid region or cervical oesophagus a total laryngopharyngectomy with radical neck dissection will be required. The pharynx is rebuilt by using deltopectoral skin flaps.

Postcricoid. In this site the cervical oesophagus will be involved and because clearance will require to be at least a hand's breadth, due to 'skip' lesions, repair with skin flaps is impractical. Because fresh tissue will be brought in for the repair and as lymph node metastases are less common, radiotherapy is the best initial treatment. If it is successful, the patient will keep his larynx. If it fails, a total laryngopharyngo-oesophagectomy will need to be done using either stomach or colon to replace the pharyngo-oesophagus. It is the author's

THE LARYNX, BRONCHI AND OESOPHAGUS

custom to use stomach replacement and this operation is described in Chapter 43.

Posterior Wall. In this site it is important to make sure of the histology of the tumour. If it is a leiomyosarcoma or a carcinosarcoma a wide local removal should be done and the patient followed closely for 5 years.

If it is a carcinoma radiotherapy should be the primary treatment unless a gland is palpable when surgery should be used. Small tumours can be removed via a lateral pharyngotomy with primary repair. If the tumour is larger the defect is replaced by a deltopectoral skin flap. In most instances these patients will be able to keep their larynx.

Combined Therapy. In recent years it has become common to make use of combined therapy in cases where neither surgery nor radiotherapy on their own give good results. The principle of this treatment is that a small dose of radiotherapy is 90 per cent cancerocidal. Going beyond this dose leads to mucositis and scarring which cause healing problems if secondary surgery is attempted. Furthermore, in large tumours, radiotherapy will not sterilize the centre of a tumour mass where there is no oxygen tension. Surgery will clear a tumour macroscopically, but it will not remove small extensions outside the immediate area of the tumour.

In planned combined therapy the patient has about 3000 r and 3 weeks later has the same surgery that he would have had, if surgery had been the prime treatment. In this way it is hoped that the best of both worlds will be obtained. Since the results of treatment of hypopharyngeal tumours are so poor many centres are using combined therapy. To date, however, no controlled trial has been published to show that this method of treatment is a significant advance.

CHAPTER 45

NECK MASSES

In the changing pattern of the specialty it is essential that every otolaryngologist should be familiar with the diagnosis and management of masses in the neck. It is also desirable that general practitioners should have some insight of what is a fairly common complaint.

In this chapter a description will be given of the main causes of neck masses and of the management of the patient who presents with such a complaint.

CAUSES OF NECK MASSES

1. Skin and Associated Structures. The most frequent skin lump is a *sebaceous cyst* and the diagnostic feature here is the presence of a punctum. *Neurofibromas* are usually multiple flat raised areas which may be associated with *café au lait* spots and occasionally with acoustic neuromas. *Lipomas* can occur anywhere in the neck, but usually present as a supraclavicular fat pad. In the presence of enlarged glands the skin should be searched for *melanomas* or *infected scratches* (as in cat scratch fever) or *boils*. Some fungous infections affect the skin and subcutaneous tissue of the cervicofacial region, the commonest being *actinomycosis*, *tularaemia*, *orf* and *blastomycosis*.

2. Thyroid Masses. This is the commonest group of neck swellings seen in a general hospital, and the simple *goitre* with or without hyperthyroidism is most frequently found. A painful hard swollen thyroid, often accompanied by a fever, is suggestive of *thyroiditis* and in this group is included *Hashimoto's disease*. A solitary *thyroid nodule* should always be regarded with suspicion because it might be a *simple adenoma*, a *papillary carcinoma*, a *follicular carcinoma* or a *medullary carcinoma*. A *squamous carcinoma* or a *reticulosis* of the thyroid gland presents as a painless swelling and causes tracheal compression or recurrent laryngeal nerve paralysis.

3. Infected Lymph Nodes. These are the most frequent swellings encountered in general practice. Of these, the enlarged *jugulodigastric node* seen in children with *tonsillitis* is the commonest, and this in turn drains into the deep jugular chain to cause further lymphadenopathy. Infected skin lesions such as *cat scratch fever* and other more simple infections may also cause enlargement of cervical glands. Enlarged lymph nodes in the posterior triangle usually occur in the adult population, and the commonest causes are *infectious mononucleosis*, *toxoplasmosis*, *brucellosis* and *cytomegalovirus*. This group may also produce some lymphadenopathy in the deep jugular chain. *Parapharyngeal abscesses* may arise from either dental or tonsillar sources.

4. Salivary Gland Diseases. These may be included in neck swellings, as the submandibular gland lies entirely within the neck, and the tail of the parotid,

in which most tumours start, is also within the neck area. These masses are commonest in middle-aged patients and are more fully discussed on p. 140.

Any diffuse swelling of these glands is probably not neoplastic but is much more likely to be due to *parotitis* (mumps), or *sialectasis* with or without calculus formation. This latter condition is to the salivary glands what bronchiectasis is to the lungs, and the contrast radiographic findings are very similar with duct stenosis and stricture, saccular and cystic spaces, and a loss of efficient functioning.

In the latter part of the nineteenth century *Mickulicz* described a syndrome consisting of swelling of all four salivary glands and of the lacrimal glands. This syndrome was later associated with keratoconjunctivitis and arthritis (*Sjögren's syndrome*), sarcoidosis and uveitis (*Heerfordt's syndrome*) and a dry mouth, dry eye complex (*Sicca syndrome*). This pot-pourri has been shown not to have many of the characteristics of auto-immune disease and is now called *benign lympho-epithelial lesion*.

Other causes of diffuse enlargement of the salivary glands include *diabetes, iodides, gout, thiouracil, obesity, fibrous replacement, myxoedema* and *Cushing's disease*. Parotid swelling can be mimicked by *masseteric hypertrophy, parasitic cysts* and *branchial cysts*.

The commonest benign tumour of salivary glands is a *pleomorphic adenoma* which in the parotid usually presents near the lobe of the ear. *Monomorphic adenomas* (Warthin's tumour) are usually bilateral and are cystic. The commonest malignant tumours are *adenoid cystic carcinoma* and *muco-epidermoid carcinoma*. The former invades nerves and often presents with associated nerve palsies.

5. Congenital Swellings. *Cystic hygroma* is probably the rarest of all neck swellings. It is obvious at birth and is due to a maldevelopment of the lymph spaces into lymph trunks on one side of the cervicofacial region. It often weighs nearly as much as the baby, is brilliantly transilluminable and can rarely be mistaken for anything else.

Dermoids can occur anywhere along lines of fusion, and in the neck they are almost invariably found above the hyoid bone in close relation to the mylo-hyoid muscle. They are midline swellings which move on swallowing and on protruding the tongue because they are intimately related to the muscle fibres forming the base of the tongue.

The commonest congenital mass occurring in the midline below the hyoid bone is the *thyroglossal duct cyst* (Fig. 123). The thyroid forms high in the neck at the base of the tongue and hyoid bone, and, as growth proceeds and the neck grows, it descends to the lower part of the neck. If it retains its attachment to the tongue it is called a thyroglossal duct and any cystic space in this duct is a thyroglossal duct cyst. The duct always joins the base of the tongue by passing behind the hyoid bone, and thus thyroglossal duct cysts are always found below the hyoid bone in the midline or occasionally just to the left of the midline. The cyst moves on swallowing because it is attached to the thyroid gland and also on protruding the tongue because of its attachment to this structure.

The commonest congenital lateral neck mass is the *branchial cyst* (Fig. 124). This occurs anywhere along the line of the sternomastoid muscle and represents the failure of disappearance of part of the branchial cleft apparatus. The most usual site is at the junction of the upper third and lower two-thirds

the anterior border of the sternomastoid muscle. It is cystic and quite mobile in all directions. If the fluid is aspirated it will be found to contain cholesterol crystals. Cysts in this position have their internal opening just behind the posterior pillar of the fauces. On occasion they may occur in the upper third of the sternomastoid muscle and mimic a parotid swelling by pushing the tail of the parotid outwards. These cysts represent remnants from the first branchial cleft and open internally at the junction of the bony and

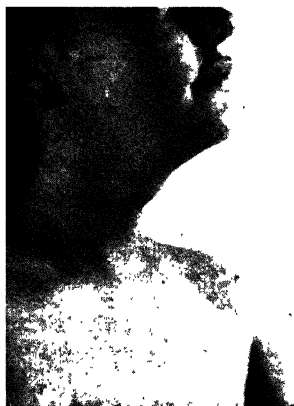

Fig. 123. Thyroglossal cyst.



Fig. 124. Branchial cyst.

artilaginous external auditory meatus. As well as presenting as a mass they may also cause a discharging ear.

Cervical ribs, if large, may simulate a stony hard lymph node in the lower part of the posterior triangle. The fact that they are the only structures that are stony hard in that area is helpful in the diagnosis.

Laryngocele is dealt with in Chapter 36 (p. 176). It is a remnant of the primitive air sac and presents at the side of the neck over the thyrohyoid membrane. It may be easily inflated and emptied of air, and it shows a characteristic radiographic appearance. Sometimes the mouth of the sac becomes blocked, infection supervenes and the presentation is that of a *yocele*.

Tuberculosis. This classically affects the lymph nodes in the neck and formerly it was not uncommon for the glands to involve the skin and to form a discharging sinus. Nowadays this is rare because such enlarged neck glands are usually dealt with at a much earlier stage. Tuberculosis commonly affects glands in the deep jugular chain around the carotid bulb and occasionally all the glands in the posterior fossa are affected. As the glands enlarge they tend to become intimately associated with the walls of the major blood vessels and this makes excision difficult. While many cases have associated pulmonary tuberculosis, the neck glands may be the only manifestation of the disease. The treatment is to excise one or two glands for biopsy, and to treat thereafter with the appropriate chemotherapy.

Sarcoidosis has a similar presentation, but there is never any sign of caseation. Diagnosis is confirmed by histology or the Kveim test.

7. **Reticulosis.** This group of diseases very commonly present primarily in the head and neck region. While the nasopharynx, tonsils or salivary tissue may be affected the commonest sites involved are the lymph nodes in the posterior triangle or around the carotid bulb. The glands are firm, rubbery and matted together. On section they have a smooth white appearance. The various stages of *Hodgkin's disease*, *lymphosarcoma* and *reticulum-cell sarcoma* are seen, as are all the *leukaemias*, especially the chronic lymphatic variety.

Long-term dosage with *epanutin* may cause lymph node enlargement in the posterior fossa.

8. **Primary Tumours of Neck Structures.** Tumours of the receptor cells in the carotid bulb have been given many names. On account of their histology they are called non-chromaffin paragangliomas; on account of their origin from chemoreceptors they are called chemodectomas; and on account of their site they are called *carotid body tumours*. They are very rare. They nearly always pulsate, but differentiation between their direct pulsation and the transmitted pulsation from a gland overlying the carotid bulb is very difficult. Although carotid body tumours may be moved from side to side, but not up and down, because of their attachment to the artery the only certain way to make the diagnosis is by angiography at which the typical tumour circulation is seen. It is doubtful if they ever become malignant and metastasize, and it is very rare for them to prove fatal by local extension. Any surgery to remove them, however, carries with it a significant mortality and morbidity risk. In a young patient surgery may be carried out to remove the tumour with adequate preoperative preparations made for carotid artery by-pass. In patients over the age of 45, however, it is probably safer to leave the tumour alone.

Neurogenous tumours of the vagus nerve may be either *neurofibroma* or *neurilemmoma*, and they are all benign. The presentation is that of a mass in the lateral pharynx which pushes the tonsil medially and forwards, but at the same time there is often diffuse thickening in the neck in the upper sternomastoid region and around the tail of the parotid. These tumours are not often distinctly palpable because they lie beneath the sternomastoid muscle, the parotid gland and occasionally the great vessels. A very rare tumour of the vagus nerve which presents in the same way is the *glomus vagale* or chemodectoma of the vagus. Because of the difficulty of distinguishing neurogenic tumours from carotid body tumours all such patients should have angiography done. Neurogenic tumours should be excised, especially in the case of a malignant neurilemmoma or a *glomus vagale*. If the vagus nerve has to be sacrificed at operation the corresponding vocal cord will be paralysed and lie in the fully abducted position. This will require a Teflon injection to replace it in the midline and thus rehabilitate the voice.

Chondroma occurs on the cricoid or more rarely on the thyroid cartilage. It presents as a hard midline swelling and there is little clinical doubt about the attachment to laryngeal cartilage. It moves on swallowing, grows slowly and very occasionally enlarges into the laryngeal lumen. Should this happen a diagnosis of *chondrosarcoma* must be considered. A simple chondroma may be excised locally provided that the integrity of the cricoid ring can be preserved,

but a chondrosarcoma requires a total laryngectomy because it is radio-insensitive.

The question of *branchogenic carcinoma* is one which has caused considerable confusion and discussion over the years. The basic question is whether carcinoma can arise in a branchial cyst or remnant, or whether the swelling is a metastatic gland from a silent primary site such as the nasopharynx. The author has removed a simple branchial cyst in which there was a small area of squamous carcinoma; this recurred in the tract remnant and required a radical neck dissection. A five-year follow-up failed to reveal any primary carcinoma elsewhere in the head and neck. There seems little doubt that such a branchogenic carcinoma is possible—but it is very rare.

9. Metastatic Glands. Primary tumours in the head and neck regions will metastasize to neck glands long before they get out of control and spread distantly. In most instances the primary tumour gives rise to symptoms and thus it may be easy to diagnose the site of the primary lesion which has caused the glandular enlargement. Some sites are notoriously silent, however, and the patient may present with enlarged neck glands long before local symptoms are complained of. The classic 'silent' sites are the nasopharynx, the posterior surface of the epiglottis and the pyriform fossae. Most often the glands in the deep jugular chain are affected but help cannot invariably be obtained from the situation of the glands in the search for the primary lesion. The only exception to this is with enlarged glands in the supraclavicular areas. These on the left side generally arise from carcinoma of the oesophagus, the stomach or below, and those on the right from lung and bronchial carcinoma.

Primaries from anywhere in the body can present as neck glands, but in 85 per cent of cases the primary tumour will be found above the clavicles and not uncommonly in the nasopharynx. On rare occasions no primary lesion ever comes to light.

MANAGEMENT OF A MASS IN THE NECK

HISTORY. The patient's age will give some guide as to the cause. Below the age of 20 the cause is likely to be inflammatory or congenital; between 20 and 40 it may be reticulotic, salivary or inflammatory; and above the age of 40 it is metastatic cancer until proved otherwise. If the cause is inflammatory the patient will usually have a pyrexia but if it is due to infectious mononucleosis, toxoplasmosis, etc. there may only be a complaint of a vague ill-health. Tuberculosis will be associated with night sweats, and Hodgkin's disease gives the irregular Pel-Ebstein fever pattern.

Abscesses and salivary gland enlargements are painful, but most of the other conditions are painless. A history should be sought of any precipitating factors such as eating (salivary gland disease) or blowing (laryngocele). It is of importance to ascertain the length of the history of neck masses.

CLINICAL FEATURES. It is important to have a system of examination of the neck so that no areas are missed. The cursory running of fingers over the neck, which is commonplace, will only palpate large masses. The examiner should stand behind the patient and observe the whole neck uncovered from the hairline to the clavicles. Palpation starts at the mastoid bone and follows the line of the trapezius muscle downwards to its junction with the clavicle. It is important to palpate beneath the trapezius muscle as this is where glands may

be felt between the flat of the fingers and the muscles from the floor of the posterior triangle to the tip of the mastoid. The line of the sternomastoid muscle is next palpated deeply under the muscle because the glands in this region may lie about 2.5 cm from the surface of the skin. This palpation is continued down to the clavicle. At this point the examiner's fingers will be in the midline and in a position to palpate the thyroid and trachea. Further palpation upwards in the midline allows an assessment to be made of laryngopharyngeal size and contour. In the submental region palpation laterally will include the submandibular glands and finally the parotids.

The first thing to determine about a neck mass is whether it is in the skin or deep in the neck. For example, a sebaceous cyst below the ear lobe may closely resemble a small parotid pleomorphic adenoma.

A midline mass is usually single. One may differentiate between a thyroglossal cyst and a thyroid adenoma by asking the patient to swallow and to protrude the tongue; a thyroid adenoma does not move on putting out the tongue but the thyroglossal cyst does. Chondroma of the cricoid is bony hard. Dermoids lie above the hyoid bone while thyroglossal cysts are found below it.

Posterior triangle masses are usually glandular in origin (apart from the bony hard cervical rib) and multiple. The commonest causes of small- or medium-sized unmatted soft nodes are infectious mononucleosis, toxoplasmosis, brucellosis and cytomegalovirus. Nodes from tuberculosis or a reticulosis are usually larger, matted and firm.

Supraclavicular masses are nearly always due to metastatic glands from lung or stomach cancer depending upon the side.

Submandibular gland swellings present below the mandible but never extend below the level of the hyoid or behind the angle of the mandible. Parotid swellings are easily diagnosed as to site if they are diffuse but small masses in the tail may be confused with jugulodigastric nodes. Generally speaking, parotid masses here are found behind the ear lobe whereas jugulodigastric gland enlargement is related to the angle of the mandible.

The difficult area is around the carotid bulb, especially if the mass appears to pulsate. The differential diagnosis is between a carotid body tumour, an enlarged gland due to tuberculosis, reticulosis, metastatic cancer, or a tense infected branchial cyst. Vagal tumours and nasopharyngeal metastatic glands are generally higher. A simple branchial cyst is found in this area and usually presents no difficulty in diagnosis, but if the swelling is tense it may be an infected cyst, a pyocele or a parotid abscess—all of which are painful to the touch.

Moving a painless pulsating mass does not help in diagnosis because not only carotid body tumours but also other masses lying on or adherent to the carotid artery are movable from side to side but not up and down.

Painless pulsating lumps commit the patient to having angiography done. If this investigation is not performed a surgeon may find himself in the position of operating on a neck mass which proves to be a carotid body tumour when no preparations have been made for a carotid artery by-pass.

Finally, the mobility of every mass must be assessed. If a gland is fixed it does not mean that it is inoperable. It all depends upon what it is fixed to and whether the structure to which it is fixed, e.g. the mandible, can be removed along with the gland.

RADIOLOGICAL EXAMINATION.

1. *Plain Films.* A plain film of the neck should always be requested because it will demonstrate such things as cervical ribs, laryngoceles, calcification in old tuberculous glands, and tracheal compression or altered direction from thyroid masses. A chest film may show pulmonary tuberculosis, mediastinal gland enlargement, bronchial carcinoma or evidence of secondary spread.

Base of skull and lateral skull films should be done if nasopharyngeal cancer is suspected.

2. *Contrast Studies.* Barium studies will demonstrate oesophageal and gastric carcinomas or any oesophageal displacement. Defects in filling in the pyriform fossa will also be seen.

Laryngography is useful in primary laryngeal pathology and sialography must be done in salivary gland disease. Perhaps the most important contrast study in neck masses is carotid angiography.

3. *Scanning Techniques.* Any thyroid mass demands a thyroid scan. A follicular adenocarcinoma and its metastases take up radioactive iodine whereas no other tumour does so. A cold area may thus be the site of a carcinoma, but all nodules which are cold on scan are far from being malignant as this appearance may be due to haemorrhage or to degeneration in a cystic goitre. Hot nodules are never malignant.

Salivary gland scanning can be done with technitium. It is said that all tumours are cold apart from Warthin's tumour which is hot. This test, however, is technically difficult and the results are too variable to be useful.

LABORATORY TESTS. In thyroid masses all the thyroid function tests should be done.

All patients in whom surgery is contemplated should have a full blood count, as should all those with the reticuloses. In cases where there are multiple glands in the posterior triangle blood should be sent for a Paul-Bunnell test, a toxoplasma titre, a brucella titre and a cytomegalovirus titre. If tuberculosis or sarcoid is suspected a Mantoux test is done.

TREATMENT POLICY. If a definitive diagnosis is made the treatment is usually straightforward, the inflammatory condition being drained if necessary and treated with antibiotics, and the congenital masses and benign tumours being removed.

The problem is greatest in the patient over the age of 40 with a hard mass in the neck. This might be tuberculosis, a reticulosis or a metastatic cancer. If a metastatic cancer is biopsied, the skin closed and the result awaited, before a search is made for the primary site, the potential survival of the patient is reduced by 66 per cent. For example, if a tonsillar cancer is silent and presents with a lymph node the patient's chance of living for 5 years after treatment of the primary is about 40 per cent. If the gland is biopsied with no concomitant treatment of the primary tumour the patient's chance of survival drops to about 14 per cent.

The way such a situation should be handled is to presume that the mass in the neck is a cancer and to make every effort to find the primary. A full head and neck examination should discover 85 per cent of the tumours and the other 15 per cent should be searched for with chest and barium radiographs. If this primary search is negative the next stage should be panendoscopy and biopsies. In this procedure the patient is anaesthetized and a close examination and biopsy are done of the nasopharynx, the base of the tongue and tonsil, the

THE LARYNX, BRONCHI AND OESOPHAGUS

oesophagus, trachea and bronchi and finally the larynx including the pyriform fossae and epiglottis. If these biopsies are negative the patient should be prepared for a radical neck dissection. A small incision is made over the mass, a biopsy taken and a frozen section done. If it is tuberculosis or a reticulosis then the gland is removed, the wound closed and the appropriate treatment begun by chemotherapy or radiotherapy. If it is a carcinoma the open gland should be plugged with muscle, the wound opened widely and a full radical neck dissection done. In these cases about 1 in 10 will never have a primary tumour discovered.

SECTION IV

THE EAR

G. D. McDowall and K. McLay

CHAPTER 46

ANATOMY OF THE EAR

Anatomically and clinically the ear is divided into three parts—the external ear, the middle ear and the internal ear.

THE EXTERNAL EAR

The external ear consists of the auricle and the external acoustic meatus. The *auricle* has two surfaces, lateral and medial; the parts of the lateral surface are shown in *Fig. 125*. The form of the auricle is derived from a plate of yellow fibrocartilage, absent in the lobule which is composed of fat and fibro-areolar tissue. The skin on the lateral surface is closely adherent to the perichondrium which predisposes to haematoma formation following injury to this surface. Attachment of the auricle to the side of the head is by ligaments and muscles, the latter being rudimentary and largely functionless in man. They are supplied by the facial nerve. The lymphatics of the auricle and external meatus drain anteriorly into the pre-auricular glands, inferiorly into superficial cervical glands along the external jugular vein and posteriorly into the group of glands overlying the mastoid process. The posterior glands also drain adjacent areas of the scalp, infection of which may produce swelling and tenderness over the mastoid area.

The *external acoustic meatus* in the adult measures about 24 mm from the introitus to the tympanic membrane but varies with growth and in individuals. Since the tympanic membrane at the inner end of the meatus is obliquely placed the anterior and inferior walls are longer than the posterior and superior walls, and at the junction of the inferior wall with the tympanic membrane a depression is formed, the inferior meatal recess, which may contain infected debris.

The meatus is composed of two parts, an outer or lateral third having a cartilaginous skeleton continuous with that of the auricle, and an inner or medial two-thirds having a bony skeleton (*Fig. 126*). The general direction of the cartilaginous meatus is medially, upwards and backwards whilst that of the bony meatus is medially, slightly downwards and forwards. There are

two constrictions in the canal, one near the junction of the two parts and the other in the osseous part. The meatus may be partially straightened by traction of the auricle upwards, outwards and backwards. Deficiencies of the cartilaginous meatus, the fissures of Santorini, may provide a pathway for infection between the parotid gland, the external meatus and superficial mastoid tissues.

The skin lining the external acoustic meatus is continuous with that of the auricle. The main glandular elements, sebaceous glands, ceruminous glands

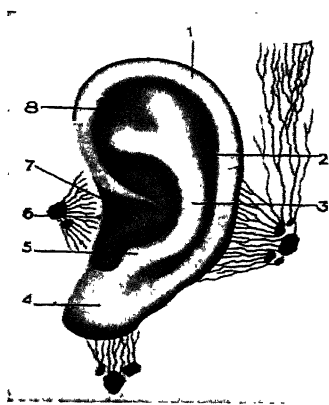


Fig. 125. Left auricle viewed from without. 1, Helix; 2, Scapha (fossa of helix); 3, Antihelix; 4, Lobule; 5, Antitragus; 6, Tragus; 7, Cavum conchae; 8, Fossa triangularis (fossa of antihelix). The lymph glands connected with the auricle are shown.

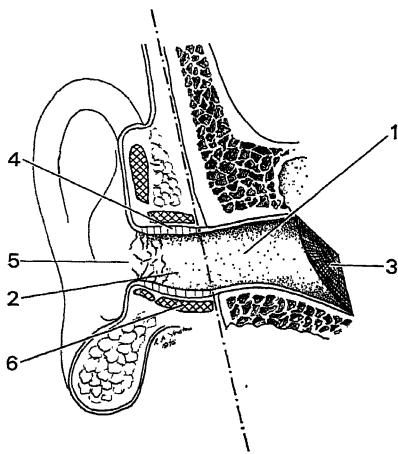


Fig. 126. Right external auditory meatus. 1, Bony part; 2, Cartilaginous part; 3, Tympanic membrane; 4, Hair follicles and ceruminous glands; 5, Introitus; 6, Meatal cartilage.

and the hair follicles are contained in the cartilaginous portion, none of these structures being present in the bony portion. The skin is closely adherent to the underlying tissue and for this reason furuncles in the cartilaginous portion are extremely painful owing to the increased tension in the tissue. The blood supply of the auricle is obtained from the superficial temporal and posterior auricular arteries. Whilst the meatus is also supplied by these vessels, it receives a supply in its inner part from the deep auricular branch of the maxillary artery. The veins accompany the arteries.

The nerves of the external ear are derived from four cranial nerves, the auriculotemporal nerve from the mandibular division of the trigeminal nerve, the posterior auricular branch of the facial nerve, a branch (Jacobson's) from the glossopharyngeal nerve, the auricular branch of the vagus nerve, and from the cervical plexus, C2 and C3, through the great auricular nerve.

The tympanic membrane, or drumhead (Fig. 127), separates the external meatus from the middle ear and functionally is part of the middle ear. The periphery of the drumhead is attached to an incomplete bony ring, the annulus, which lies at the medial end of the external meatus. The ring is

deficient above—the notch of Rivinus. The membrane is thin, and when examined with illumination has a pearly-grey colour with a triangular bright area, the cone of light, extending from the centre (the umbo) downwards and forwards. The membrane has an outer layer of squamous epithelium continuous with that of the meatus, a middle layer of fibrous tissue which has radiating and circular fibres, and an inner layer of mucous membrane continuous with the lining of the tympanic cavity. The fibrous tissue layer is deficient in the area of membrane bounded by the notch of Rivinus which,

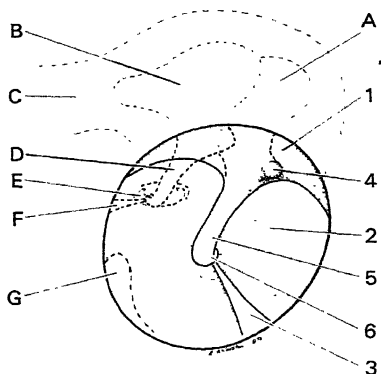


Fig. 127. Right tympanic membrane. Broken lines indicate medial relations. 1, Pars flaccida; 2, Pars tensa; 3, Cone of light; 4, Lateral process of malleus; 5, Handle of malleus; 6, Umbo; A, Head of malleus; B, Body of incus; C, Aditus; D, Long process of incus; E, Stapes; F, Stapedius tendon; G, Round window niche.

being less tense, is known as the pars flaccida or Shrapnell's membrane. The lower margins of this part are thickened and extend from the ends of the notch of Rivinus to the lateral process of the malleus forming the anterior and posterior folds of the membrane. The part of the drumhead containing fibrous tissue is known as the pars tensa.

The outer surface of the tympanic membrane has a blood supply from the deep auricular branch of the maxillary artery. The inner surface receives branches from the posterior auricular artery and from the maxillary artery through its tympanic branch.

The nerve supply of the outer surface of the drumhead is similar to that of the external meatus but the inner surface is supplied from the tympanic branch of the glossopharyngeal nerve.

THE MIDDLE EAR

The middle ear, a vertical cleft-like space in the temporal bone, includes the Eustachian tube, the middle ear or tympanic cavity and the aditus leading posteriorly to the mastoid antrum and air cells. Anteriorly the Eustachian tube opens into the nasopharynx from which the cleft develops in early fetal life.

The middle ear or tympanic cavity lies between the tympanic membrane laterally and the cochlea medially. Its upper part extending above the tympanic membrane is known as the epitympanic recess or attic, and the lower part extending below the level of the floor of the external auditory meatus is referred to as the hypotympanum (*Fig. 128*).

The cavity may be described as a six-sided box, frequently likened in shape to a match-box standing on end with its vertical length greater than its

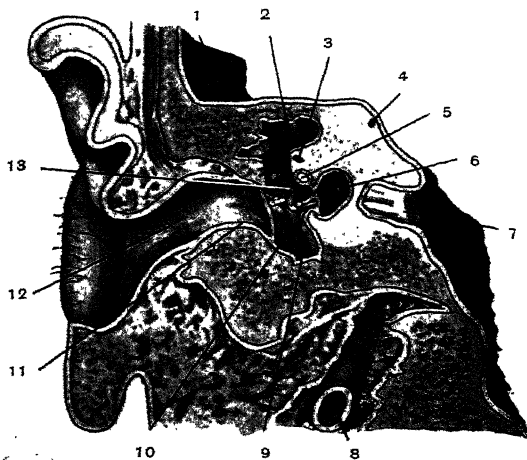


Fig. 128. Vertical coronal section through left ear, viewed from behind. 1, Middle cranial fossa; 2, Attic; 3, Lateral semicircular canal; 4, Posterior vertical semicircular canal; 5, Facial nerve; 6, Vestibule; 7, Internal acoustic meatus with nerves; 8, Internal carotid artery; 9, Hypotympanum; 10, Medial surface of drumhead; 11, Floor of bony meatus; 12, Junction of bony with cartilaginous meatus; 13, Incus.

breadth but narrow in depth, particularly in the central portion where the basal turn of the cochlea forms a bulge on the medial wall. The *roof* of the cavity is formed by a thin plate of bone (the tegmen tympani) from the petrous part of the temporal bone which joins the squamous part. This plate of bone also forms the roof of the mastoid antrum and separates the tympanic cavity and antrum from the middle fossa of the skull. The *floor* which is also thin separates the cavity from the bulb of the internal jugular vein which may be exposed by bony deficiency. The tympanic branch of the glossopharyngeal nerve enters the cavity through the floor.

The *anterior wall* in its lower portion is formed by a thin plate of bone separating the cavity from the internal carotid artery. The upper portion has two openings, the lower one being the auditory (Eustachian) tube and above it the canal for the tensor tympani muscle.

The *posterior wall* is wider than the anterior wall and in its upper part the aditus connects the epitympanic recess (attic) with the mastoid antrum. Below the aditus a bony projection, the pyramid, gives exit to the tendon of the stapedius muscle. Just above the pyramid the fossa incudis gives attachment for the short process of the incus. The facial nerve bends downwards at

the level of the floor of the aditus and lies in close relation to the posterior wall.

The *lateral wall* (Fig. 129) is formed mainly by the tympanic membrane and the outer bony wall of the epitympanic recess (attic). The *medial wall* is also the lateral wall of the internal ear. In it there are two openings (Figs. 129, 130, 131), the upper of which is the oval window (fenestra vestibuli) and below it is the niche leading to the round window (fenestra cochleae), which is closed

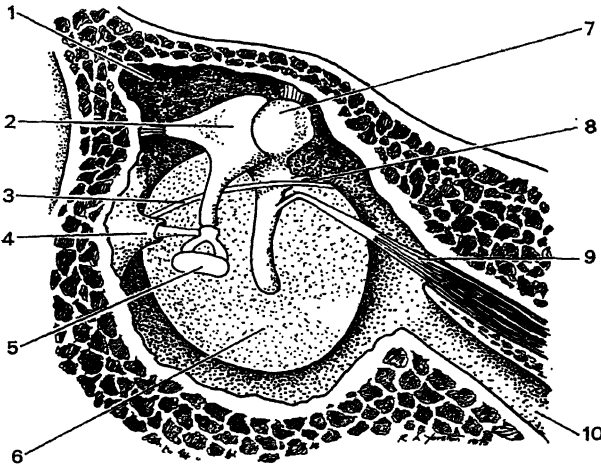


Fig. 129. Left tympanic cavity as seen from the medial aspect. 1, Epitympanic recess; 2, Body of incus; 3, Chorda tympani; 4, Pyramid; 5, Footplate of stapes; 6, Medial surface of tympanic membrane; 7, Head of malleus and superior ligament of malleus; 8, Anterior ligament of malleus; 9, Tensor tympani in its canal; 10, Eustachian tube.

by the secondary tympanic membrane. In front of and between these two windows lies the promontory. The surface of this bony covering of the basal coil of the cochlea is grooved for the nerve fibres of the tympanic plexus. The horizontal portion of the facial nerve is enclosed in a bony canal (the canal of Fallopius), which is sometimes deficient, and which crosses the medial wall above the oval window before turning vertically downwards at the posterior end of the window. The processus cochleariformis, containing the tendon of the tensor tympani, is situated on the anterior and superior part of the medial wall in front of the point of entry of the facial nerve from the inner ear.

The *mucosal or epithelial lining* of the tympanic cavity is of columnar ciliated epithelium in that part derived from the tubotympanic recess but in a posterosuperior direction there is a transition to cuboidal epithelium and finally to a flattened single layer epithelium lining the mastoid antrum and air cells.

The *ossicles*. The three ossicles, clothed in mucosa and supported by ligaments, form an articulated connection between the tympanic membrane and the oval window. The malleus consists of a head, neck, anterior and

lateral processes and handle. The handle is attached to the drumhead (*Fig. 129*) and the head is situated in the attic articulating with the body of the incus, the short process of which has a ligamentous attachment to the floor of the aditus. The long process of the incus extends downwards to articulate

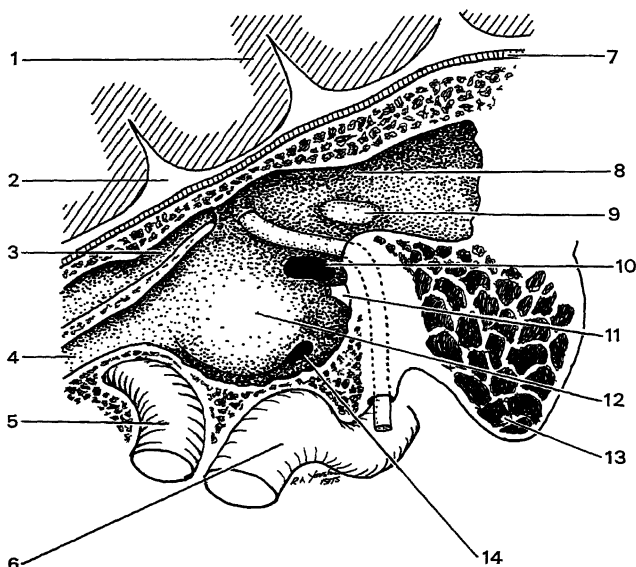


Fig. 130. Relations of the left tympanic cavity. 1, Cerebral cortex; 2, Subarachnoid space; 3, Canal for tensor tympani; 4, Eustachian tube; 5, Internal carotid artery; 6, Jugular bulb; 7, Dura mater; 8, Aditus; 9, Lateral semicircular canal; 10, Oval window; 11, Pyramid; 12, Promontory; 13, Mastoid process; 14, Round window.

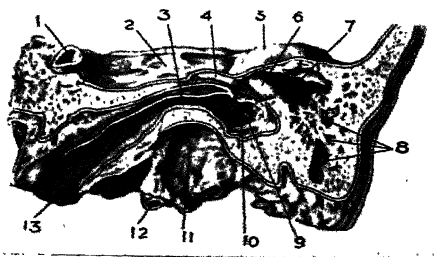


Fig. 131. Medial aspect of left middle ear and auditory tube. 1, Internal carotid artery; 2, Middle fossa; 3, Pharyngotympanic (Eustachian) tube—just above this lies the tensor tympani muscle; 4, Canal for facial nerve; 5, Arcuate eminence; 6, Prominence of lateral semicircular canal; 7, Tympanic antrum (mastoid antrum); 8, Mastoid air cells; 9, Fenestra cochleae (foramen rotundum); 10, Annulus tympanicus; 11, Jugular bulb; 12, Internal carotid artery; 13, Pharyngeal opening of pharyngotympanic (Eustachian) tube.

with the head of the stapes. The stapes, suitably named from its stirrup-shaped appearance, has a head, a neck, two crura or limbs, and a footplate which is fixed to the margins of the oval window by an annular ligament.

The *tympanic muscles* are stimulated by sound. The *tensor tympani* arises from the cartilaginous part of the auditory tube, from the adjacent part of the great wing of the sphenoid and from the bony canal in which it lies. Its tendon bends laterally around the processus cochleariformis and is inserted into the medial edge and anterior surface of the handle of the malleus. The nerve supply is from the motor division of the trigeminal nerve through the otic ganglion, and its action is to tense the tympanic membrane by drawing it medially. The tendon of the *stapedius muscle*, after emerging from the pyramid, is inserted into the neck of the stapes. It has an action of damping the movement of the stapes by tilting outwards the anterior end of the footplate, and it is supplied by the facial nerve.

Tympanic ligaments and spaces. The anterior and posterior ligaments of the malleus surround the neck and jointly form the axis ligament attached to the anterior and posterior ends of the tympanic notch. From the head of the malleus and the body of the incus a superior ligament suspends each from the roof of the attic. The posterior ligament of the incus attaches the short process of the incus to the fossa incudis in the aditus, and the annular ligament attaches the footplate of the stapes to the margins of the oval window. The folds of mucous membrane around the ossicles and ligaments form spaces or pouches in which local suppuration may occur. These spaces are related to the drumhead and are situated below the level of the lateral ligaments of the malleus. They are the anterior and posterior spaces of the drumhead and Prussak's space (Fig. 132). These well-defined intercommunicating spaces are present in the attic, the upper portion of the lateral space opening into the aditus. On the medial wall of the latter lies the rounded prominence of the bony wall of the lateral semicircular canal.

Tympanic vessels and nerves. The cavity is well supplied by branches arising from the maxillary, stylomastoid, middle meningeal, ascending pharyngeal and internal carotid arteries. The veins drain into the pterygoid plexus and

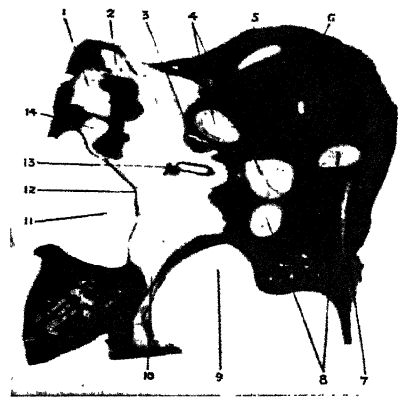


Fig. 132. Vertical coronal section through right ear, showing canals. 1, Epitympanic recess; 2, Head of malleus; 3, Facial nerve; 4, Two ends of lateral canal; 5, Superior canal; 6, Remains of fossa subarcuata in labyrinth nucleus; 7, Ductus endolymphaticus; 8, Two ends of posterior canal; 9, Jugular bulb; 10, Hypotympanum; 11, External meatus; 12, Tympanic membrane; 13, Stapes; 14, Prussak's space.

the superior petrosal sinus. The lymphatics mainly drain into the retro-pharyngeal and parotid lymph glands.

The *sensory nerve supply* is through the tympanic plexus which lies on the promontory and is formed by the tympanic branch of the glossopharyngeal nerve and the superior and inferior tympanic branches of the sympathetic plexus of the internal carotid artery. The plexus supplies the lining mucosa of the tympanic cavity, the mastoid air cells and the Eustachian tube. Branches pass to the greater superficial petrosal nerve and the otic ganglion via the lesser superficial petrosal nerve from which secretomotor fibres are relayed by the auriculotemporal nerve to the parotid gland.

The *facial nerve* after crossing the cerebellopontine angle where it is closely related to the acoustic nerve enters the temporal bone at the internal auditory meatus. It passes laterally curving slightly upwards over the labyrinth until it reaches the anterior part of the medial wall of the tympanic cavity, close to the roof, just behind or medial to the processus cochleariformis. Here it bends backwards at right angles, where the geniculate ganglion is situated, and passes almost horizontally enclosed in the Fallopian canal above the oval window and below the lateral semicircular canal. When it reaches the aditus it turns downwards behind the pyramid and continues almost vertically until it emerges at the stylomastoid foramen. The *nerve to the stapedius muscle* is given off close to the pyramid. The *chorda tympani nerve* leaves the descending part of the facial nerve and enters the tympanic cavity which it crosses enclosed in a fold of mucosa to pass between the handle of the malleus and the long process of the incus. It leaves the cavity through the medial end of the petrotympanic fissure to join the lingual nerve in the infra-temporal fossa.

The *auditory (Eustachian, pharyngotympanic) tube* (Fig. 131) connects the tympanic cavity with the nasopharynx and in the adult is about 36 mm in length. From its pharyngeal end it runs upwards, laterally and backwards. In infants the tube is shorter and wider and its course is more horizontal than in adults. The tube has two parts: a pharyngeal cartilaginous part which forms two-thirds of its length and a tympanic bony portion. The upper and medial walls of the pharyngeal portion of the tube are formed by a plate of cartilage, hook-shaped in vertical coronal sections (Fig. 133). The lateral wall is membranous. In the resting state the lateral and medial walls lie in apposition.

The fibres of origin of the tensor palati muscle are attached to the lateral wall of the tube so that contraction of this muscle on swallowing or yawning opens the tube and thus equality of air pressure is maintained on both sides of the tympanic membrane. The levator palati muscle runs below the floor of the cartilaginous part of the tube and it is generally considered that contraction of this muscle opens the tube.

The bony portion of the tube lies between the internal carotid artery medially and the temporomandibular joint laterally. Above the tube is the bony canal for the tensor tympani muscle and below it lies the jugular fossa.

The Eustachian tube is lined by columnar ciliated epithelium. The sub-mucous tissue of the cartilaginous part contains numerous mucous glands. The blood supply of the tube is from the ascending pharyngeal and middle meningeal arteries and from the artery of the pterygoid canal. Veins drain into the pterygoid plexus. The nerves are derived from the glossopharyngeal

nerve through the tympanic plexus and the maxillary division of the trigeminal nerve through the pharyngeal branch of the pterygopalatine ganglion.

The *mastoid bone* forms a part of the petromastoid portion of the temporal bone, the other portions being squamous, tympanic and the styloid process. It lies below and behind the squamous and behind and lateral to the petrous portions. The lower part of the mastoid bone, known as the mastoid process (Fig. 134), is absent at birth and in the infant the stylomastoid foramen lies

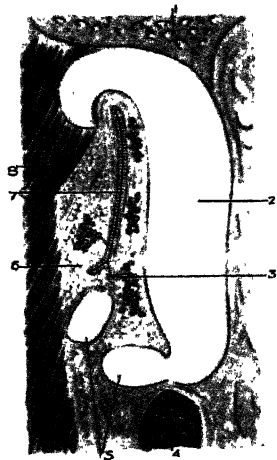


Fig. 133. Vertical coronal section through right Eustachian tube as seen from the front. 1, Petrous bone; 2, Cartilage of the tube; 3, Mucous glands; 4, Levator palati muscle; 5, Detached and semidetached portions of cartilage; 6, Fatty and fibrous tissue; 7, Lumen of the tube; 8, Tensor palati (dilator tubae) muscle.

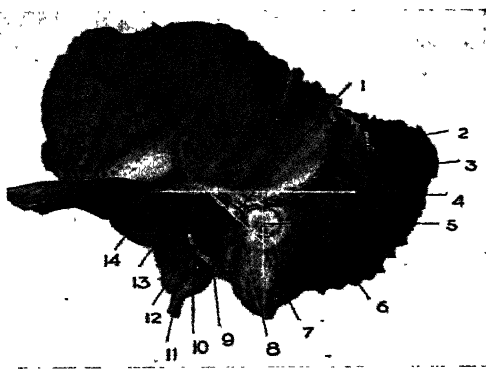


Fig. 134. Lateral aspect of left temporal bone. 1, Suprameatal spine; 2, Mastosquamosal suture; 3, Supramastoid crest; 4, Mastoid foramen (for emissary vein); 5, Fossa mastoidea (surface marking for tympanic antrum); 6, Mastoid notch for digastric muscle; 7, Site of suture between squama and mastoid; 8, Tip of mastoid (Note: Dotted lines joining 1, 8 and 3 mark the triangle for operation on the mastoid); 9, External acoustic meatus; 10, Anterior wall of bony meatus; 11, Styloid process; 12, Vaginal process of styloid; 13, Petrotympic fissure (Glaserian fissure); 14, Mandibular fossa. (Macewen's triangle—a guide to the position of the antrum—is outlined in white.)

close to the surface. For this reason a mastoid incision in young children should not be extended in a downward direction otherwise the facial nerve may be cut just after emerging from its foramen. The mastoid or tympanic antrum which is present from birth communicates anteriorly via the aditus with the epitympanic recess, and behind and below with the mastoid air cells. In the infant it lies at a higher level than in the adult and is superficial, being covered only by a thin plate of bone. The roof of the tympanic antrum is the backward extension of the tegmen tympani. The floor and medial wall are formed by the petromastoid bone, the medial wall being related to the bony labyrinth.

The mastoid cell system shows a considerable normal variation both in size and number of cells. Where the cell system is extensive the mastoid is referred to as pneumatic or cellular while one composed mainly of sclerotic or diploëic bone is termed an acellular or dense mastoid. The cells are lined by

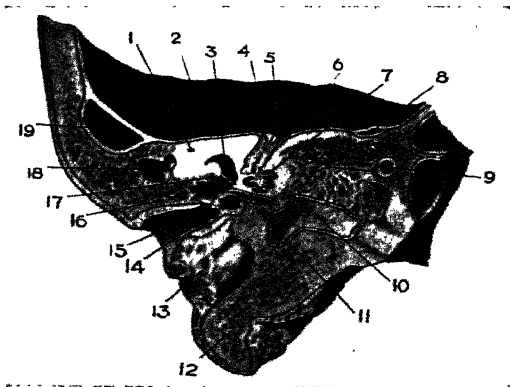


Fig. 135. Horizontal section through right temporal bone, viewed from above. 1, Posterior vertical canal; 2, Posterior fossa of skull; 3, Vestibule; 4, Vestibular nerve; 5, Cranial opening of perilymphatic aqueduct; 6, Cochlear nerve; 7, Cochlea; 8, Inferior petrosal sinus; 9, Internal carotid artery; 10, Dura mater of middle cranial fossa; 11, Tensor tympani; 12, Zygoma; 13, Meniscus of lower jaw-joint; 14, Inner surface of tympanic membrane; 15, External acoustic meatus; 16, Air cells between antrum and meatus (border cells); 17, Facial nerve; 18, Floor of tympanic antrum; 19, Sigmoid sinus.

very thin flattened epithelium. They form two groups—squamosmastoid and petromastoid. In an extensively pneumatized mastoid the groups form a definite arrangement and are designated anatomically: (1) Zygomatic cells extending into the root of the zygomatic process; (2) tegmen cells bordering the floor of the middle fossa; (3) petrosal angle cells lying in the angle between the roof and posterolateral wall of the mastoid cavity; (4) marginal cells lying posterior to the sigmoid sinus plate and sometimes extending into the occipital bone; (5) perisinus cells overlying the lateral sinus plate; (6) periantral cells related to the antrum; (7) retrofacial cells extending round and underneath the facial nerve; (8) perilyabyrinthine cells extending in the bony wall of the internal auditory meatus as far as the petrous apex; (9) tip cells (lateral and medial divided by the groove for the posterior belly of the digastric muscle) occasionally extending into the styloid process; and (10)

peritubal cells and cells in the floor of the tympanum which may extend towards the apex of the petrous bone.

The posterior and inferior aspects of the temporal bone are shown in *Figs. 136 and 137*.

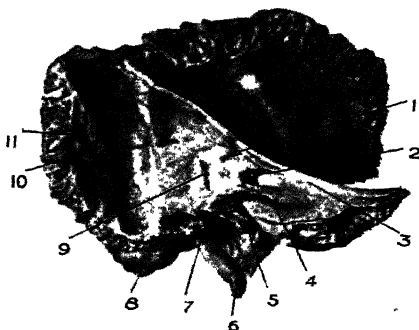


Fig. 136. Posterior aspect of left temporal bone. 1, Fossa subarcuata; 2, Internal acoustic meatus; 3, Groove for superior petrosal sinus; 4, Groove for inferior petrosal sinus; 5, Canaliculus cochleae (cranial opening of perilymphatic aqueduct); 6, Processus styloideus; 7, Fossa jugularis (jugular bulb); 8, Tip of mastoid process; 9, Cranial opening of aqueduct of vestibule; 10, Groove for transverse sinus; 11, Mastoid foramen (for mastoid emissary vein).

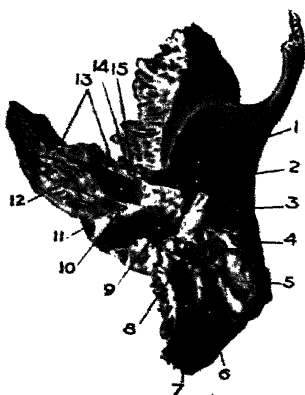


Fig. 137. Inferior aspect of left temporal bone. 1, Fossa mandibularis; 2, Fissura petrotympánica (Glaserian fissure); 3, Processus styloideus; 4, Meatus acusticus externus; 5, Processus mastoideus; 6, Incisura mastoidea (digastric groove); 7, Sulcus arteriae occipitalis (groove for occipital artery); 8, Foramen stylomastoideum; 9, Fossa jugularis; 10, Canaliculus tympanicus (opening for Jacobson's nerve); 11, Apertura externa canaliculi cochleae (cranial opening of perilymph aqueduct); 12, Area for attachment of pharyngeal basilar fascia; 13, Foramen carotidum; 14, Canal for tensor tympani; 15, Pharyngotympanic (Eustachian) tube.

THE INTERNAL EAR

The internal ear within the petrous part of the temporal bone consists of a membranous labyrinth (*Fig. 138*) enclosed in a bony (osseous) labyrinth (*Figs. 139, 140*). The membranous labyrinth contains fluid known as endolymph and the space within the bony labyrinth between its walls and the membranous labyrinth contains fluid known as perilymph.

The essential part of the inner ear is the membranous labyrinth, developed from an ingrowth of cephalic ectoderm called the otic vesicle, which later differentiates into two parts (*Fig. 141*): (1) the pars superior or static labyrinth consists of the utricle and three semicircular canals. This part contains the balance mechanism and is connected with the vestibular nerve, and (2) the

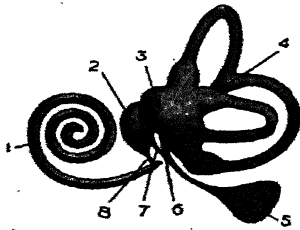


Fig. 138. Semi-diagrammatic representation of left membranous labyrinth, viewed from without. 1, Membranous cochlea; 2, Saccule; 3, Utricle; 4, Crus commune; 5, Sacculus endolymphaticus; 6 and 7, Fine ducts from utricle and saccule which join to form the endolymphatic duct; 8, Canalis reuniens, connecting intravestibular part of the cochlear duct with the saccule.

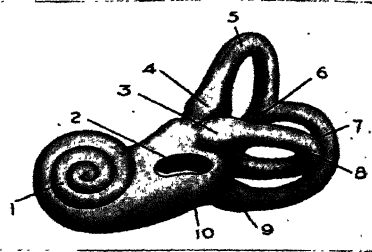


Fig. 139. Bony labyrinth of left side, viewed from without. 1, Bony cochlea; 2, Fenestra vestibuli (oval window); 3, Ampulla of lateral (horizontal) semicircular canal; 4, Ampulla of superior vertical canal; 5, Convexity of superior canal; 6, Crus commune; 7, Convexity of posterior vertical canal; 8, Convexity of lateral canal; 9, Ampulla of posterior vertical canal; 10, Fenestra cochleae (round window).

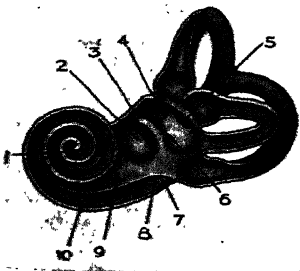


Fig. 140. Left bony labyrinth opened up and viewed from without. 1, Helicotrema; 2, Recessus sphericus for saccule; 3, Crista vestibuli; 4, Recessus ellipticus for utricle; 5, Opening of crus commune into vestibule; 6, Opening for endolymphatic aqueduct; 7, Fenestra cochleae (round window); 8, Cochlear opening of perilymphatic aqueduct; 9, Area of communication between perilymph space of vestibule and scala vestibuli of cochlea; 10, Scala tympani of cochlea. (Note: The ridge of bone between 9 and 10 is the bony spiral lamina.)

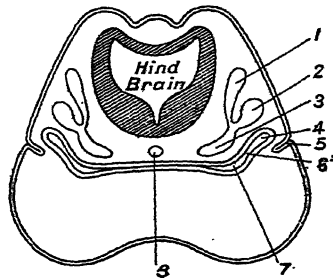


Fig. 141. Diagram showing transverse vertical section through head of fetus at an early stage of development, and indicating the development of the external acoustic meatus, the middle ear cleft, and the labyrinth. 1, Primitive duct endolymphaticus; 2, Primitive static labyrinth (utricle and canals); 3, Primitive auditory labyrinth (saccule and cochlea); 4, Primitive tympanic cavity; 5, External acoustic meatus; 6, Pharyngotympanic (Eustachian) tube; 7, Pharynx; 8, Notochord.

pars inferior or auditory labyrinth consisting of the saccule and membranous cochlea or cochlear duct containing the hearing mechanism is connected with the cochlear nerve.

The *bony labyrinth*. In the early embryo the membranous labyrinth sinks into the surrounding mesoderm which is converted into layers of cartilage

called the periotic capsule and this in turn changes to dense bone in which some cartilage cells persist throughout life. This dense enchondral bone forms the bony labyrinth embedded, fossil-like, in the petrous temporal bone. The interior of the bony labyrinth is lined by endosteum. The central part of the bony labyrinth is the vestibule in the lateral wall of which lies the fenestra vestibuli (oval window) closed by the footplate of the stapes and the annular ligament. The medial or inner wall of the vestibule is directed towards the internal acoustic meatus and is perforated by nerve endings. It contains two depressions—the spherical recess for the saccule and the elliptical recess for the utricle. Below the elliptical recess there is the small opening of the aqueduct of the vestibule which transmits the endolymphatic duct. The posterior, superior and inferior walls of the vestibule contain the five openings of the semicircular canals. The lateral or horizontal canal has an opening at each end but the superior and posterior vertical canals have a common opening at their non-ampullated ends, the crus commune (Figs. 139, 140).

The *bony cochlea*, anterior to the vestibule, is a spiral tube wound two and a half times round its central axis or modiolus. Its base is directed towards the

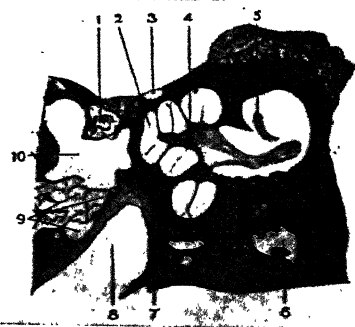


Fig. 142. Vertical coronal section through right ear, axial section through cochlea. 1, Tensor tympani; 2, Helicotrema; 3, Canal for greater superficial petrosal nerve; 4, Modiolus; 5, Facial nerve; 6, Cochlear aqueduct; 7, Edge of cartilage-bone capsule of cochlea; 8, Carotid canal; 9, Tubal cells; 10, Tubal part of tympanic cavity.

internal acoustic meatus and its apex towards the internal carotid artery (Fig. 142). From the modiolus, which contains the cochlear nerve, a hollow bony ledge (spiral lamina) projects into the lumen of the tube transmitting the branches of the nerve. This ledge commences in the vestibule just above the fenestra cochleae (round window) and ends near the apex of the cochlea at the hamulus or hook. The basilar membrane of the membranous cochlea is attached to the edge of the bony spiral lamina and the outer surface of the membranous cochlea is attached to the inner wall of the bony cochlea thus dividing each coil of the bony cochlea into three parts: (1) the upper part, the scala vestibuli, commences from an opening in the vestibule below the spherical recess, (2) the lower part, the scala tympani, begins at the fenestra cochleae (round window), (3) the membranous cochlea lying between the upper and lower parts is in effect part of the scala vestibuli separated from it by a membrane (Reissner's membrane) and is known also as the scala media. At the apex of the cochlea the membranous cochlea ends blindly and in this region, known as the helicotrema (Figs. 140, 142 and 143), the scala vestibuli and scala tympani are continuous with one another.

The *membranous labyrinth*. The three membranous semicircular ducts occupying, but not filling, the lumen of the bony canals communicate with the utricle by five openings, the superior and posterior vertical ducts having a common opening (*crus commune*) at their non-ampullated ends (see Fig. 138). The three ducts lie in the three planes of space and each duct is dilated at one end to form an ampulla which contains a ridge of neuro-epithelium termed the *crista ampullaris* (Fig. 144). The hair cells of the crista have long

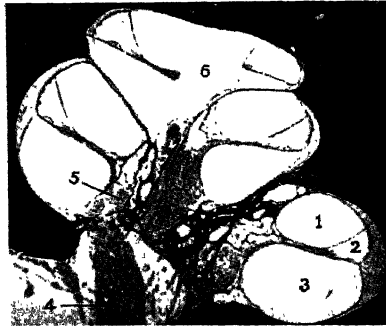


Fig 143. Horizontal section through the cochlea showing: 1, Scala vestibuli; 2, Cochlear duct (membranous labyrinth); 3, Scala tympani; 4, Cochlear nerve in internal acoustic meatus; 5, Spiral ganglion in modiolus; 6, Helicotrema.

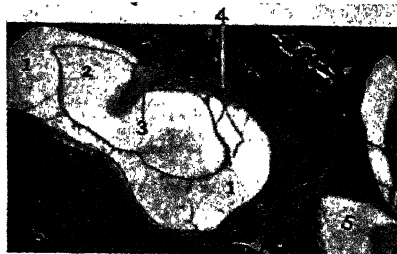


Fig. 144. Horizontal section through lateral semicircular canal (duct). 1, Perilymphatic space; 2, Endolymphatic space; 3, Crista covered by cupula; 4, Vestibular nerve to crista; 5, Internal acoustic meatus.

filaments which project into a mass of gelatinous material called the cupula. Movement of endolymph in the ducts bends the cupula and hair cells which are supplied by the terminal fibres of the vestibular nerve.

The utricle, occupying the recessus ellipticus of the vestibule, also contains a similar area of neuro-epithelium on the superior side of its lower wall. The neuro-epithelium of the saccule, lying in the recessus sphericus, is placed on the anteromedial wall at right angles to the plane of the sensory epithelium of the utricle. In the utricle and saccule the neuro-epithelium is termed the macula and from it hair cells are in contact with a membrane containing otoliths or ear stones. From the utricle a small duct joins the endolymphatic

duct from the sacculle ending in the endolymphatic sac (*see Fig. 138*) which lies between the layers of dura mater on the posterior surface of the petrous temporal bone midway between the internal acoustic meatus and the lateral sinus (*see Fig. 136*).

The *membranous cochlea*. This is sometimes called the ductus cochlearis or scala media, and is a blind tube, triangular in section, coiled round a central bony pillar called the modiolus. The floor of the tube, which is longer at the apex of the modiolus than at the base, rests on the basilar membrane on the inner part of which lies a mound of neuroepithelium called the organ of Corti. In the lateral wall or short side of the tube there is a layer of vascular epithelium known as the stria vascularis which is concerned with formation of the endolymph. The sloping roof and the third wall of the tube are formed by the vestibular (Reissner's) membrane completing the separation of the scala media from the scala vestibuli. The narrowest part of the membranous cochlea which lies within the vestibule is connected to the sacculle by a fine duct (ductus reuniens) (*see Fig. 138*).

The fluid system of the labyrinth is divided into two streams, endolymph and perilymph. The belief that endolymph, contained in the membranous labyrinth, was simply derived from the cells of the striae vascularis and absorbed from the saccus endolymphaticus has been questioned. Recent investigation suggests that separate endolymph circulations are present in the pars superior and the pars inferior of the membranous labyrinth but the exact mechanisms of production and disposal remain undecided.

Perilymph, which occupies the perilymphatic space of the bony labyrinth, though similar to cerebrospinal fluid, contains more protein and much less chloride. Whilst not yet proved it is believed that perilymph is derived from endolymph by diffusion through Reissner's membrane or the perilymphatic blood vessels, and is not, as previously thought, part of a continuous system with, and derived from, cerebrospinal fluid in the posterior cranial fossa.

Organ of Corti. The organ of Corti, situated on the basilar membrane and consisting of a complex arrangement of supporting and hair cells, is the area of commencement of the sensory transmission of sound to the auditory centres. In fulfilling this function the basilar membrane and the tectorial membrane, which is in contact with the hair cells of the organ of Corti, are necessary components. In its ascent from the basal coil of the scala media to the apical coil structural changes are found in the organ consisting of an increase in the width of the basilar membrane and in its fibrous tissue content. The tectorial membrane becomes larger, the tunnel of Corti enclosed by inner and outer rods increases in height and width and the nerve supply to the hair cells decreases.

Vessels of internal ear. The arteries are the labyrinthine arising from the basilar or anterior inferior cerebellar artery and the stylomastoid, a branch of the posterior auricular or occipital artery. The veins unite to form the labyrinthine vein which opens into the inferior petrosal sinus or the sigmoid sinus. Small veins pass via the aqueducts of the vestibule and cochlea to the superior and inferior petrosal sinuses respectively.

Vestibulocochlear nerve. The vestibulocochlear (acoustic) nerve is formed by cochlear and vestibular parts in the internal acoustic meatus from which it emerges on the lateral side of the sensory root of the facial nerve and enters the brain stem between the pons and the medulla. The cochlear part is

THE EAR

composed of fibres which are the central processes of bipolar cells in the spiral ganglion in the modiolus of the cochlea. The peripheral processes of the ganglion cells pierce the bony spiral lamina to reach the inner and outer hair cells of the spiral (Corti's) organ. Other fibres follow a spiral course on the internal part of the basilar membrane. The vestibular part consists of the processes of the bipolar cells of the vestibular ganglion in the internal acoustic meatus. From the superior part of the ganglion fibres pass to the macula of the utricle, the ampullae of the superior and lateral semicircular ducts and the anterior part of the macula of the saccule. The inferior part of the ganglion sends fibres to the macula of the saccule and the ampulla of the posterior semicircular duct.

CHAPTER 47

PHYSIOLOGY AND FUNCTIONAL EXAMINATION OF THE EAR

For clarity the consideration of the physiology of the auditory and vestibular apparatus in this chapter is followed immediately by an account of the methods employed in their functional examination. In clinical practice, however, the history of the patient's case is taken first and this is followed by otoscopic examination before the functional tests are carried out.

PHYSIOLOGY OF THE AUDITORY APPARATUS

Airborne sound consists of vibrations of the atmosphere, that is, of alternate phases of condensation and rarefaction. These vibrations of air are converted into vibrations of the fluids of the inner ear, which in turn converts them into nerve impulses to be transmitted along the auditory nerve.

The auricle to some extent collects the sound waves and they are transmitted along the external acoustic meatus to the tympanic membrane which is set in motion. The vibrations of the tympanic membrane are transmitted to the malleus, incus and stapes. The movement of the footplate of the stapes in the oval window (fenestra vestibuli) transmits the vibrations to the perilymph and endolymph. The conversion of airborne to fluid borne sound is assisted slightly by the lever system formed by the ossicles but to a much greater extent by the marked difference in area between the tympanic membrane and footplate of the stapes. During the compression phase of airborne sound the stapes is pushed inwards; the fluids of the ear cannot be compressed with the result that the round window membrane is forced outwards. This reciprocal action of the oval and round windows is essential for transmission of sound to the inner ear fluids. In the normal ear the presence of the tympanic membrane and an air-containing middle ear prevents the compression wave of airborne sound from reaching the round window and opposing the outward movement of the round window membrane. This protection of the round window is lost where there is a large perforation of the tympanic membrane and this is one of the factors which may produce deafness.

Optimum movement of the tympanic membrane depends upon equal pressure on its inner and outer aspects. This is achieved by the Eustachian tube (auditory tube) which normally opens during each act of swallowing. In this way middle ear pressure can be maintained at the same level as that in the external acoustic meatus during changes in atmospheric pressure. Reflex contraction of the tensor tympani and stapedius muscles, in response to loud sound stimuli, dampens the movements of the ossicles and thus provides some protection against excessive movement.

Vibrations of perilymph and endolymph produce movements of the basilar membrane and shearing movements between the hair cells and tectorial membrane of the organ of Corti and this initiates nerve impulses in the fibres of the auditory nerve. In the case of low frequency sound there results a synchronous nerve impulse with each sound wave and this simple analysis of frequency is possible up to about 1000 impulses per second but is limited by the rate at which nerve fibres can carry impulses. At higher sound frequencies some alternative method of coding frequency is required. Different parts of the basilar membrane respond maximally to sound of different frequency, the basal end of the basilar membrane responding maximally to high frequencies and the apical end to low frequencies. As each part of the organ of Corti in relation to the basilar membrane has its own individual pattern of nerve supply, nerve fibres in the auditory nerve will respond maximally to a limited range of frequency and within this range is a peak response. A similar spatial relationship of response to specific frequencies can be demonstrated in the central auditory pathways.

Vibrations of the basilar membrane produce electrical potentials which follow accurately the wave form and changes in intensity of the stimulating sound. These are known as cochlear microphonics and can be readily picked up by an electrode in the region of the round window. More elaborate recording techniques will demonstrate action potentials in the auditory nerve and other electrical changes which accompany stimulation of the cochlea.

FUNCTIONAL EXAMINATION OF THE AUDITORY APPARATUS

In the great majority of cases of ear disease it is necessary to investigate the condition of hearing and to ascertain whether deafness, if present, is due to involvement of the sound-conducting apparatus or of the inner ear and its central connections. Conductive deafness may be caused by lesions of the external auditory meatus, the tympanic membrane, the middle ear cleft or the tympanic ossicles, the inner limit of the sound-conducting apparatus being the footplate of the stapes within the oval window. Deafness due to lesions in the inner ear, auditory nerve or their central connections is known as sensorineural deafness.

In a number of cases examination of the vestibular apparatus will also be required.

Tests of Hearing

Whispered Voice Test

The distance at which the patient can hear a whispered voice with the opposite ear occluded is measured and the result is recorded for each ear. If the patient cannot hear a whispered voice a conversation voice is used and the distance at which he can hear this is measured. If he cannot hear a conversation voice, a raised conversation voice is used close to the ear and it may be necessary to shout into the ear. If it is necessary to raise the voice to allow the patient to hear, it is essential to prevent him from hearing with the opposite ear. This 'masking' is most conveniently applied by a Bárány noise box, a clockwork-driven source of loud noise (*Fig. 145*). A loud shout in the ear to be tested with the Bárány noise box in the opposite ear is still the most reliable test for total deafness. The whispered voice or conversation voice test

is a simple practical method of testing a patient's ability to understand speech which is the function of hearing most important to most people.

Tuning Fork Tests

Tuning fork tests provide the most reliable method of determining whether deafness is of conductive or sensorineural type. The tuning fork used should be large so that its rate of decay is not rapid and its frequency should be



Fig. 145. Békésy's noise apparatus.



Fig. 146. Testing with tuning fork by air conduction.

either 256 or 512 cycles per second. It should have an expanded base for application to the skull. The tuning fork is struck against a resilient surface and then held so that the acoustic axis is in line with the external acoustic meatus (Fig. 146). In this way the sound of the fork is heard by *air conduction*. If the vibrating tuning fork is held with its base held firmly against the skull the sound is transmitted through the bones of the skull to the cochlea and the sound of the fork is heard by *bone conduction*.

Rinne's Test

Air conduction in which the sound of the tuning fork is transmitted through the normal sound-conducting pathway is much more efficient than bone conduction in which the sound is transmitted through the bones of the skull to the cochlea. In Rinne's test air conduction is tested. The tuning fork still vibrating is then applied with its base to the mastoid process and the patient is asked which he hears louder. If the sound-conducting pathway is intact the tuning fork is heard much louder by air conduction than by bone conduction and Rinne's test is said to be positive. If the sound-conducting pathway is

disrupted bone conduction will be better heard than air conduction and Rinne's test is said to be negative. In conductive deafness Rinne's test will be negative if the conductive hearing loss is greater than 15 decibels.

Absolute Bone Conduction (A.B.C.)

In tuning fork bone-conduction tests the normal sound-conducting pathway is by-passed, so that bone-conduction tests are a measure of inner ear function. In the test of absolute bone conduction, the bone conduction of the patient is compared with that of the examiner and, assuming that the examiner has normal hearing, it is a test of the patient's inner ear functions. The tuning fork is struck and its base is applied to the patient's mastoid process with the meatus occluded. The patient signals as soon as the sound of the fork is no longer heard. The tuning fork is immediately applied to the examiner's mastoid process with the meatus occluded. If the examiner can still hear the tuning fork the patient's inner ear function is reduced and bone conduction is said to be shortened. In conductive deafness, and particularly in otosclerosis, bone conduction may be lengthened, i.e. the patient continues to hear the tuning fork when the examiner can no longer hear it.

Weber's Test

This tests bone conduction and is of greatest value in cases of asymmetrical conductive deafness. The tuning fork is set in vibration and applied to the vertex of the skull in the midline and the patient is asked in which ear he hears the sound. The vibrations are transmitted equally to the cochlea on each side. In sensorineural deafness one would expect the sound to be better heard in the better ear. While this sometimes occurs it is not a regular finding, the sound being more often heard in the midline. In conductive deafness, on the other hand, the sound is heard in the more affected ear.

Provided that the patient's reply is accurate Weber's test is very sensitive in conductive deafness. In unilateral conductive deafness, Weber's test will be heard in the affected ear where the hearing loss is only 5 dB. The student can verify this by applying Weber's test to himself and producing a mild conductive deafness by occluding the external acoustic meatus on one side. The sound of the tuning fork will be clearly heard in the occluded ear.

False Negative Rinne

This is an important observation. In unilateral total or severe sensorineural deafness Rinne's test will appear to give a negative result. Air conduction is absent, but bone conduction may be good because the sound is transmitted to the opposite cochlea. This result may lure the examiner into making a wrong diagnosis of conductive deafness. In this situation Weber's test is important. If the deafness is of conductive type, the tuning fork should be heard in the deaf ear. If Rinne's test is negative in one ear and Weber's test is not lateralized to that ear the examiner must consider that the condition may be total deafness. The final test is a loud shout in this ear with Bárány's noise box in the opposite ear.

Audiometry

A pure-tone audiometer is an instrument which delivers sound of set frequency to the ear by earphones. The frequencies usually tested are at

octave steps, i.e. 125, 250, 500, 1000, 2000, 4000 and 8000 cycles per second. In some instruments half-octave steps are available to test intermediate frequencies. At each frequency the intensity of the sound can be raised in 5-decibel steps above the normal threshold until the sound can just be heard. In a deaf ear, the amount that the intensity of the sound has to be raised above the normal level is a measure of the degree of deafness at that frequency. By measuring the threshold of hearing at each frequency, an accurate measure of the degree of hearing loss in each ear is obtained. Instead of using earphones to measure air-conducted sound, a receiver can be applied directly to the mastoid process and sound is transmitted to the cochlea by bone conduction. The sound-conduction apparatus is by-passed so that the threshold of bone conduction is a measure of inner ear function. As with the air conduction, measurement of bone conduction is expressed in decibels of hearing loss below the normal. The results are charted as audiograms (Fig. 147).

In audiometry it is important to eliminate the possibility that the test sound is being heard in the opposite ear. The audiometer provides a masking tone which may be played into the opposite ear. Masking must be applied to the better ear when testing the deaffer ear if the difference in threshold is found to be more than 30 decibels. When testing the bone-conduction

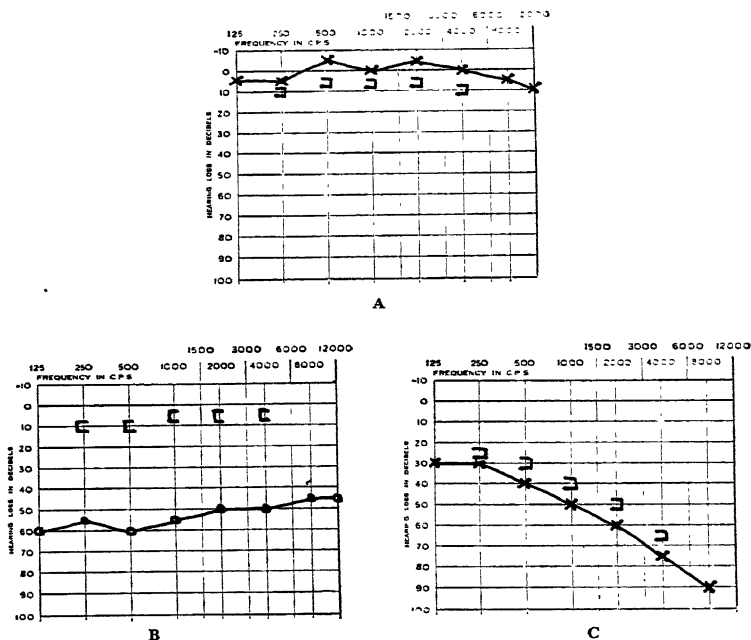


Fig. 147. Pure-tone audiograms. A, Normal; B, Conduction (middle-ear) deafness; C, Perceptive (nerve) deafness. Air conduction: Right = O; left = X. Bone conduction: Right = [; left =].

threshold masking of the opposite ear must always be used because of the ease with which bone conduction sound is transmitted through the bones of the skull.

In *speech audiometry* the ability to understand speech is measured. A recording of phonetically balanced word tests is used. These are played to the patient at increasing intensities and the proportion of words correctly repeated by the patient is expressed as a percentage; the results are charted (Fig. 148). When hearing is normal all the words will be understood if they are

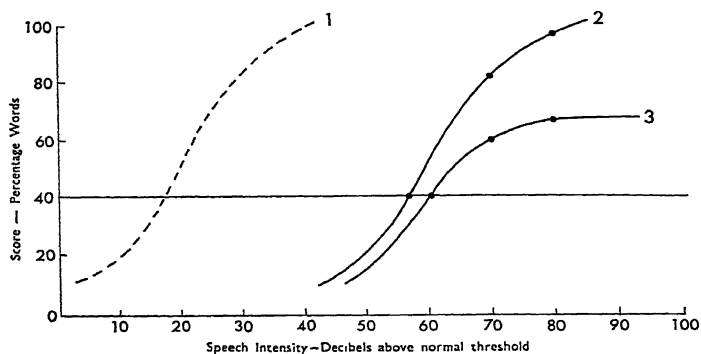


Fig. 148. Speech audiogram. 1, Normal hearing; 2, Conduction deafness; 3, Perceptive deafness.

played loudly enough. In conductive deafness all the words will be understood but they will require to be played louder than for the normal subject. In sensorineural deafness 100 per cent understanding of words will not be achieved and increasing loudness above the optimum may produce a reduction in understanding. If increasing the loudness can produce an understanding of more than 40 per cent of the words, it may be predicted that 90 per cent of sentence intelligibility can be obtained. This gives a useful method of assessing the degree of disability produced by the deafness and is also helpful in predicting the usefulness of a hearing aid or the benefit which might be obtained by an operation.

Tests for Recruitment

Recruitment is the inability to hear quiet sounds, yet loud sounds can be heard as loud or even louder than normal. Recruitment produces diminished understanding of speech and intolerance of loud sounds, particularly when a hearing aid is worn. Recruitment is present when the cause of the deafness is in the organ of Corti. Demonstration of recruitment may be used to localize the site of the lesion in sensorineural deafness and, in particular, to differentiate deafness due to a cochlear lesion from that due to an auditory nerve lesion. Recruitment in unilateral deafness is best demonstrated by the Fowler's Alternating Loudness balance test in which a tone is played alternately into the normal ear and into the deaf ear, the intensity in the deaf ear being adjusted until the sounds in both ears are heard equally loudly (Fig. 149).

In bilateral deafness it is customary to use a battery of tests, e.g. (a) Békésy self-recording audiometry, (b) SISI (short increment sensitivity index) loudness discomfort level, (c) tone decay level, and (d) acoustic impedance measurements.

a. *Békésy Audiometry*. In this type of audiometry the frequency of the tests signal is continuously altered from low to high frequency. The patient controls the intensity of the signal so that it fluctuates about the threshold and the level is plotted by a pen. This not only gives a record of the threshold

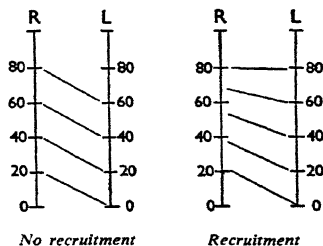


Fig. 149. Diagram showing loudness balance test. (After Dix, Hallpike and Hood.)

but it has been shown that in cochlear lesions the excursions of the pen around threshold become much smaller than when the hearing is normal. In lesions of the auditory nerve the plotted threshold may be lower than that demonstrated by normal pure tone audiometry due to abnormal adaptation.

b. *SISI*. In this test the patient's ability to distinguish small fluctuations in intensity of a tone is measured. In cochlear deafness smaller increments than normal may be distinguished.

c. *Tone Decay Level*. In cochlear deafness loud sounds may cause discomfort at a lower level above threshold than in normally hearing subjects and a quiet continuous tone may cease to be heard after an abnormally short duration of exposure.

d. *Acoustic Impedance Measurements*. A tone played in to the ear will be partly absorbed by the sound-conducting apparatus and partly reflected outwards from the surface of the drum. The maximum absorption will occur when the contour of the drum is normal with equal pressure on either side. This absorption or impedance of the drum can be measured. By altering the pressure in the external meatus until maximum absorption by the drum is demonstrated, the pressure in the middle ear can be measured, e.g. Eustachian obstruction where the middle ear pressure is reduced. Characteristic patterns can be shown in secretory otitis media, adhesions in the middle ear, ossicular disruption and otosclerosis. Alterations of the contour of the drum can also be demonstrated when the stapedius and tensor tympani muscles contract. The stapedius muscle can be made to contract by a loud sound and the intensity of sound required to induce contraction can be used as a measure of recruitment and it also provides a rough objective measurement of the threshold of hearing. Demonstration of the stapedius reflex can be used to show the level of a facial paralysis. Contraction of the tensor tympani muscle is produced by stimulation of the sensory part of the trigeminal nerve and the usual stimulus is cold air applied to the cornea.

CHAPTER 48

PHYSIOLOGY OF THE VESTIBULAR APPARATUS

The balance of the body is maintained by co-ordination of information from three systems: (1) proprioception: i.e. sensation from muscles, joints, tendons and ligaments; (2) the eyes; (3) the vestibular system.

The vestibular system consists of the semicircular canals, the utricle and the saccule. The utricle and saccule respond to linear acceleration. The greatest linear acceleration to which the body is normally subjected is gravity (32 ft per sec²) and it is alterations in the position of the head in relation to the direction of gravity which stimulate selective parts of the utricle and saccule. Impulses from the utricle and saccule not only give information about the position of the head in space but initiate reflexes which tend to keep the head in the upright position, and are contributory to the maintenance of muscle tonus. In modern life large horizontal linear accelerations may be added to the ever-present gravity so that the body reacts to the resultant force which is no longer vertical—a dangerous situation in aircraft take-offs and landings. The semicircular canals respond to angular (rotatory) acceleration, and stimulation of the semicircular canals gives rise to the sensation of rotation and to reflex movements of the eyes and body to counter the movement. Angular acceleration around any axis will stimulate at least one pair of semicircular canals, e.g. the horizontal canal on each side or the superior canal on one side and the posterior canal on the other side. The mechanism can most easily be explained by considering rotation in a rotating chair (*Fig. 150*) about a vertical axis (*Fig. 151*). Acceleration to the right will cause movement to the left of endolymph within the membranous horizontal canal and deflection of the cupola on the crista in the expanded ampulla of the canal. There is a constant impulse rate of 10–20 impulses per second in the fibres of the nerves leaving the crista. Movement of the endolymph and cupola towards the ampulla causes an increase in this impulse rate. Movement away from the ampulla causes a reduction in the impulse rate. In *Fig. 151* it will be seen that acceleration to the right will cause an increase in the impulse rate from the crista of the right horizontal canal and a reduction of the rate on the left side. This difference in impulse rate is interpreted by the central nervous system and gives rise to the sensation of rotation to the right. The eyes will move to the left at a rate proportional to the degree of stimulation, but as the eyes can only move a limited amount laterally, a central reflex will return them to midposition and the vestibular stimulation will again move them to the left. This constitutes *nystagmus* with a relatively slow vestibular component and a very much faster central component. Similar limb reflexes, e.g. past pointing, can also be demonstrated. When the acceleration stops, rotation will continue

at constant velocity, the cupola on the crista will return to rest and there will be no sensation of rotation and no nystagmus. If the rotation is suddenly



Fig. 150. Rotation chair.

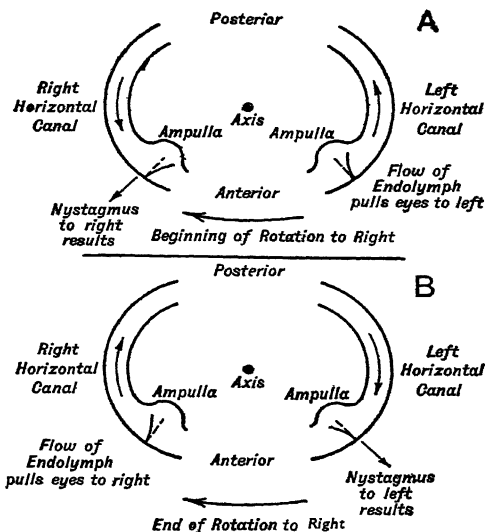


Fig. 151. Diagram of flow of endolymph in horizontal semicircular canals in rotation test. The observer, standing above and in front of the patient, is asked to visualize what is taking place in the canals at the beginning and also at the end of the test. The patient is looking towards the bottom of the page.

stopped, i.e. the equivalent of an acceleration to the left, the endolymph and cupola will continue to move to the right, the impulse rate from the left horizontal canal will reduce and the rate from the right canal will increase. There will be a sensation of rotation to the left, although the head and body are at rest; there will be nystagmus with the slow phase to the right and the quick phase to the left. It will be seen that destruction of one labyrinth with abolition of the resting impulse rate will produce imbalance of impulses arriving in the central nervous system from the two sides, resulting in the same effect as vestibular stimulation, i.e. sensation of rotation, nystagmus, righting reflexes and, if the stimulation is large enough, nausea, vomiting, pallor of the skin and sweating. Rotation carried out in this way using controlled accelerations may be used for testing semicircular canal function but it has the disadvantage of stimulation of the canals of both sides at the same time.

FUNCTIONAL EXAMINATION OF THE VESTIBULAR APPARATUS

A careful history of the case must first be taken as regards dizziness, its duration, severity, mode of onset, and effect of sudden changes in the position of the head. Was the dizziness associated with nausea and vomiting? Are the attacks periodic, and are they associated with any known cause? In which direction did external objects appear to move? Was the dizziness sufficiently severe to cause falling? To which side did the patient tend to fall?

SPONTANEOUS NYSTAGMUS

The patient's head is kept steady in the upright position, and he is told to look straight forward and then to follow the finger of the examiner held 2 feet away and moved to the right and left and also up and down. Spontaneous nystagmus in any of these positions is noted. In some normal people slight spontaneous (fixation or fatigue) nystagmus may be observed on looking to the extreme right and to the extreme left; this nystagmus is equal in both directions.

NYSTAGMUS

Nystagmus is of three main types—central, ocular and vestibular. *Central nystagmus* is generally associated with other signs of intracranial disease. *Ocular nystagmus* is usually accompanied by other signs of ocular disease and is commonly an oscillatory movement. *Vestibular nystagmus* is accompanied by vertigo and usually some loss of hearing. It is a rhythmic associated movement of the eyes and consists of a slow movement of the eyes in one direction followed by a quick return in the opposite direction. The slow movement or component of the nystagmus is the one produced by ear stimulation. The recovery, or quick movement, is usually held to be of cerebral origin, but the reflex arc for vestibular nystagmus in man and other animals consists of: labyrinth, vestibular nerve, vestibular nucleus, abducens nucleus, abducens nerve and external rectus muscle. It is perhaps unfortunate that the direction of the nystagmus has been named according to the direction of the quick component, i.e. nystagmus to the right means that the quick jerk

is to the right while the real vestibular component is the slow return to the left. Nystagmus is always most marked when the patient looks in the direction of the quick component, and is lessened or abolished when he looks in that of the slow component. Nystagmus which is present only when the patient looks in the direction of the quick component is known as nystagmus of the *first degree*; if nystagmus is also present when the patient looks straight in front it is said to be of the *second degree*; if still present when he looks in the direction of the slow component, the nystagmus is of the *third degree*. A patient with nystagmus to the right is requested to look at an object on his right side. The vestibular pull causes the eyes to deviate to the left. Under the influence of an anaesthetic the quick component of nystagmus is eliminated, and the slow or vestibular movement alone takes place, and results in conjugate deviation.

Spontaneous Pointing. Orientation means the determination of the relation of the body to space, while equilibration means the maintenance of position whether walking, standing or sitting. Pointing is a voluntary act by which the patient indicates his sense of orientation. The normal person is always aware of the location of his hand or finger in space and, with his eyes closed, is aware of the exact position of objects previously located with the finger. In carrying out Bárány's pointing test, the patient is seated and the examiner stands opposite to him. The patient shuts his eyes and extends one upper extremity with three fingers and thumb closed but the forefinger pointing forwards. The examiner also extends his hand and brings one forefinger below and in contact with that of the patient. At the word 'Up' the patient raises his arm to the vertical position, and then immediately brings it back again to touch the examiner's finger. In the same way downward and lateral pointing may be tested. Further, the accuracy of pointing at the elbow- and wrist-joints and also in the joints of the lower extremities may be investigated; even the pointing reaction of the head and trunk may be tried; but, as a rule, only the reactions of the upper extremities are examined.

Spontaneous Falling (Romberg's Test). The patient stands with heels and toes together and eyes closed, and the direction of any swaying or falling is noted. The patient is now asked to turn his head sharply to the right or left, and any change in the direction of falling is noted. The examiner now grasps the shoulders of the patient and attempts to over-throw him either to one side or the other, forward or backward. The patient is told to balance himself so that he will not fall. When the shoulders of the patient are pressed towards the right, the pelvis should sway towards the left in the attempt to maintain equilibrium.

Positional Nystagmus. Nystagmus, usually rotatory and accompanied by rotatory vertigo, may occur only in certain positions of the head; commonly in the recumbent position with the head extended and turned to one side. The patient can frequently assume the position in which vertigo is experienced. Changes in position of the head must be effected by slow movements in order to elicit a 'position' reflex due to movement. The presence of positional nystagmus is probably an indication of disturbance of the vestibular system—inner ear, vestibular nerve or brain centres.

Positional nystagmus has been divided into Nylen type 1, in which nystagmus changes direction on the assumption of different head positions; and Nylen type 2, in which nystagmus is always in the same direction but only occurs in certain head positions. Finally, it is classified as *fatiguable*, indicative

of a peripheral lesion (otolith organ); or *non-fatiguable*, associated with a lesion involving central vestibular connections.

Rotation Tests. The principle of rotation tests has been described, but these tests now have a very limited place, e.g. where there is a contra-indication to douching the ears, and in children. A more delicate turning test employing minimal stimuli (cupulometry) has been introduced. A subthreshold acceleration is given to the turning-chair until a certain angular velocity is attained and this is maintained for a certain time until every reaction has ceased. The chair is then suddenly stopped. This is repeated at different velocities and the duration of after-sensation and after-nystagmus are recorded on a logarithmic scale or 'cupulogram'. Rotation tests at present play a relatively subsidiary role in vestibular investigation.

Caloric Test. The main advantage of the caloric test is that each ear can be tested separately. Syringing the ear with cold or hot water induces convection currents within the semicircular canals and therefore stimulates them with resulting vertigo and nystagmus. In the caloric test this is done under controlled conditions. The patient lies with the head 30° above the horizontal (*Fig. 152*). This brings the horizontal semicircular canals into a vertical plane. Cold syringing cools the most superficial part of the semicircular canal and gives rise to a current in the endolymph away from the ampulla, e.g. cold syringing of the left ear will produce a current away from the ampulla of the left semicircular canal and induce nystagmus with a slow phase towards the left and a quick phase to the right. There will be a sensation of rotation to the left and if the stimulus is great enough nausea and vomiting. Douching with warm water produces exactly the opposite effect. The tests are carried out on each ear with water at 30 and 44 °C. The ear is freely irrigated for 40 seconds. During testing the eyes are fixed in the straight ahead position upon an object on the ceiling (*Fig. 152*). The nystagmus elicited is thus of second degree. The measure of response is the number of seconds between the commencement of the stimulus and the cessation of nystagmus. The results are recorded as shown in *Fig. 153*. The two continuous lines represent a 3-minute period subdivided into intervals of minutes and 20 and 10 seconds. The interrupted lines denote response durations. Normal variations occur in response duration, the average being 1½–2½ minutes, the hot reactions being slightly shorter than the cold. Where there is depression of function on one side, the response to hot and cold douching on that side will be depressed—canal paresis (*Fig. 153, C*). In some cases nystagmus in one direction, e.g. nystagmus to the left, may be more readily induced and this is known as directional preponderance of nystagmus (*Fig. 153, B*). Directional preponderance of nystagmus may be evidence of labyrinthine imbalance. In many cases there is a combination of canal paresis and directional preponderance.

Electronystagmography. Eye movements may be recorded by utilizing the standing electrical potential between the cornea and retina. This can be picked up by electrodes placed close to the eyes and the difference in signal between the two eyes, when amplified, gives an accurate record of eye deviation. This method may be used for detecting more accurately the presence of spontaneous or positional nystagmus and may also replace direct observation of nystagmus during caloric and rotation tests. Eye movements can be recorded with the eyes closed, making the detection of nystagmus more sensitive (*Fig. 154*).

Fistula Test. This test is of use in cases in which the bony wall of the lateral semicircular canal has been eroded by disease, with exposure of the endosteum. The condition is known as 'fistula' of the lateral canal. The reaction to the fistula test presupposes a live or functioning labyrinth. The test is carried out as follows: an olive-shaped ear-piece attached by means of rubber tubing to a valveless Politzer bag, or the ear-piece of a Siegle speculum, is fitted tightly into the meatus. The patient is directed to look straight forward. By squeezing

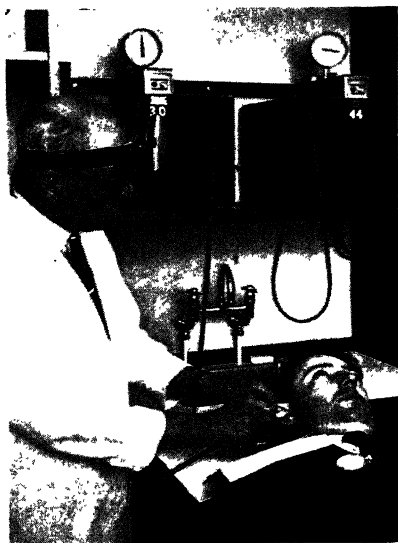


Fig. 152. Caloric test, showing thermostatically controlled tanks.

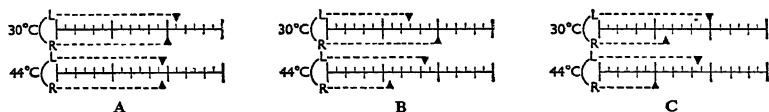


Fig. 153. Calorigrams. A, Normal; B, Directional preponderance to left; C, Predominance of left labyrinth (canal paresis of opposite side).

the rubber bag the air pressure in the meatus is raised, and the pressure is transmitted to the fluid in the labyrinth through the gap caused by the erosion. By releasing the bag without removing the ear-piece the pressure in the meatus is diminished. The direction of the nystagmus produced in this way cannot always be accurately predicted, but the effect of rarefaction is always the opposite of that due to condensation. In the 'typical' fistula symptom, on compression, nystagmus is produced to the diseased side—the slow movement being to the opposite side. In the 'reversed' fistula symptom,

THE EAR

on compression, the nystagmus is to the healthy side, and the slow component to the diseased side. (The reversed fistula symptom may be produced in cases of undue mobility of the stapes.) A positive fistula test is also present after the operation of labyrinth fenestration for the relief of deafness in otosclerosis.

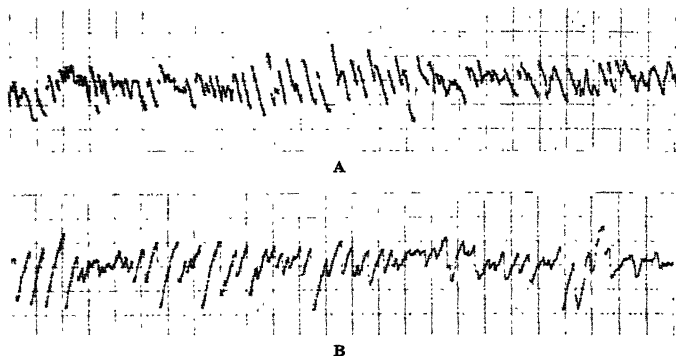


Fig. 154. Electronystagmograph recordings. A, Nystagmus to the right; B, Nystagmus to the left.

Examination of the auditory and vestibular system is not only of importance in diagnosing conditions of the external, middle and inner ear. It also plays an essential part in the investigation of lesions of the auditory and vestibular nerves and of their central connections.

CHAPTER 49

SYMPTOMS OF EAR DISEASE

The most common symptoms referable to the ear are deafness, discharge from the ear, pain, itching, tinnitus and giddiness. In addition to these there may be symptoms indicating invasion of the labyrinth or of the intracranial contents by disease. Spontaneous nystagmus, loss of coordination and balance, vomiting, headache, rigors and disturbances of the pulse and temperature are clinical features of graver import. In taking a history the presence or absence of the common symptoms should be ascertained and their duration noted. In all investigations of aural conditions the examination must include that of the pharynx, nasopharynx and nose.

Deafness. Deafness is the most common symptom of ear disease, and it may vary from a degree so slight as to escape the notice of the patient to complete loss of hearing. Certain anomalies of hearing sometimes accompany the deafness. In cases of middle ear deafness the patient may hear better in a noise, as for example when travelling in a train or a bus, and in some instances he appears to hear better than normal individuals in these conditions. This is called *paracusis*, and is found most typically in otosclerosis. The sudden onset of deafness may be due to a blast injury, a plug of wax in the meatus or to an acute otitis with effusion into the middle ear cavity. Deafness of gradual onset is met with in otosclerosis and in the arteriosclerotic deafness of old people. In other instances *hyperacusis* is met with, that is, the sensation of pain on exposure to loud, and especially shrill, noises. Much more rarely the patient complains of *diplacusis*, the same tone being heard as notes of a different pitch by the right and the left ears. Needless to say this condition is usually complained of by musical people.

Discharge. Discharge from the ear may arise from the external meatus or the middle ear cavity. The discharge varies in type. Some patients aver that their ear is running when the discharge is of wax. Aural discharge may be thick and composed mainly of epithelial debris and contains no mucus. This arises from the meatal walls. If pus is mixed with the epithelial debris, and if mucus is absent, the cause is probably an otitis externa. A profuse thin serous discharge which irritates the skin of the meatus and the auricle is found in a certain type of external otitis. There are no mucus-secreting glands in the external meatus and therefore if there is no mucus in the discharge, the cause is likely to be in the outer ear. Mucus is recognized by its tenacious adherence to a wool mop. Discharge from the middle ear may be mucopurulent, purulent or epithelial in nature. An acute otitis media which erupts through a perforation gives rise to a purulent or mucopurulent discharge which may exhibit pulsation. A chronic otitis media through a central perforation results in a mucopurulent discharge, while a chronic otitis media with an attic or marginal perforation causes a scanty discharge of pus and epithelial debris. The

discharge is often offensive, and this is found particularly in the chronic infection which produces cholesteatoma, but also occurs in a purulent otitis externa. A discharge of blood from the ear may arise acutely in an influenzal infection or chronically from granulation tissue, but the possibility of malignant disease must be kept in mind.

Pain. Pain in the ear may arise from the auricle, the external meatus or the middle ear and mastoid, or it may be referred from other sources (Chapter 50). Descriptions of pain vary. It may be lancinating and paroxysmal, severe and constant, deep and boring, or intermittent. It may be aggravated by pressure on the ear, by chewing, by sneezing or by blowing the nose. The patient should be asked to point to the exact spot of the pain, because it may be felt in front of the ear, or below the auricle, over the mastoid process or deep within the meatus. Pain in front of the ear, in the region of the tragus, is probably due to a furuncle, and this pain is aggravated by chewing, by lying on the affected ear, by pressure over the tragus or by pulling the auricle. Pain felt deep in the ear or behind it may arise from the middle ear or mastoid, when it is increased by blowing the nose. Pain behind the ear may be due to an infected gland at the mastoid tip, and this may have been caused by an otitis externa, infections of the scalp or rubella. Pain located below the ear, in the cleft between the ramus of the mandible and the mastoid process, is frequently due to a Eustachian tubal infection, but it may arise in the parotid gland.

Itching. Itching or irritation in the ear is generally associated with an otitis externa, and it may be so severe that the patient is constantly rubbing or scratching the ear, and may even abrade the skin at the meatal entrance. It may arise from the discomfort of wax resulting in the patient attacking the wax with a hair grip, matchstick or other such utensil, thus setting up an otitis externa.

Tinnitus. Tinnitus, or a subjective sensation of sound in the ear, is a very common, and sometimes the only, symptom of ear disease. Tinnitus may be regarded as a sign of irritation of the cochlear mechanism, just as pain is a sign of irritation of the sensory nerves. The sounds may be continuous or intermittent, and they may be synchronous with the pulse. In otitis media pulsating noises may be met with, but they commonly occur in the absence of any aural disease. The patient is sometimes conscious of tinnitus during the whole of his waking hours, or he may hear the noises only when in a quiet room or when he is in bed at night. Tinnitus may produce extreme depression, and may render the sufferer unfit for work. The nature of the sound varies. It may be described as hissing, buzzing, rushing, hammering, as being like the escape of steam, the sound of the sea, or of bells and so on. Tinnitus may be met with in any form of ear disease, and is also a symptom of some general diseases which indirectly affect the ear through the circulation. It is a common symptom of renal affections, cardiac disease and anaemia, and it may be caused by certain drugs, such as quinine, the salicylates and ototoxic antibiotics. The possibility of an intracranial tumour occurs to many patients, and their fears cannot be allayed without a neurological examination unless some other cause is found.

Vertigo. Vertigo may occur in certain ear diseases, and it must be regarded as a symptom of irritation of the vestibular apparatus. Rarely it may be produced by the pressure of cerumen against the tympanic membrane. It may accompany

SYMPTOMS OF EAR DISEASE

virus infections of the middle and internal ear. In cases in which the bony wall of the horizontal (lateral) semicircular canal is eroded by disease, giddiness is experienced on stooping or on suddenly turning the head. Neuritis of the vestibular nerve may be due to toxæmia. Tumours of the eighth nerve, cerebellar lesions such as abscess or tumour and Menière's disease give rise to vertigo. Arteriosclerotic changes in the blood vessels of the brain are a common cause of giddiness in old people. Vertigo may be severe and of short duration, or it may be more or less constantly present in which event it is usually less severe.

CHAPTER 50

OTALGIA

If a patient complains of earache the cause is usually determined by inspection of the external meatus and the tympanic membrane, but in a number of cases the pain is a referred one and the meatus is healthy and the drumhead normal. It is important that otoscopy is honestly conducted and that the examiner does not persuade himself that he is seeing pathology where none exists, otherwise both diagnosis and treatment will be incorrect. The ear receives sensory nerve supply from the trigeminal, glossopharyngeal and vagus nerves and from branches of the upper cervical roots, especially C2 and C3, and when otoscopy is normal the cause of the pain must be sought in the scalp, neck, nose, nasopharynx, pharynx, teeth, temporomandibular joint and larynx.

Dental otalgia. Dental pain may be referred through the trigeminal nerve to the ear. It originates in diseases of the molar teeth, e.g. pulp space infection, periodontal infection, impacted unerupted teeth—especially wisdom teeth, carious roots, etc. Even if the patient is edentulous dental radiography may reveal a retained root or an unerupted tooth. Pain in the ear may follow dental extraction, or arise from resorption of the lower jaw after clearance of the teeth. The latter is most often found in women who, for the sake of vanity, retain their dentures day and night.

The *temporomandibular joint* is a fairly common source of otalgia, and the cause is a capsular stress produced by dental malocclusion. It may be found in young people as a result of faulty mastication or incomplete eruption of the molar teeth so that there is overclosure of the bite. Badly fitting dentures throw a strain on the joint capsule, as does injury to the mandible. In 20 per cent of cases the pain is referred to the ear or the side of the face. Examination of the joint includes listening for a clicking sound on opening the mouth. The mandibular condyle should be palpated during jaw movements, and digital pressure during movement may produce the pain. There may be limitation or asymmetry of movement, and there is limitation of side-to-side movement of the opened mandible. Radiography of the temporomandibular joints may show no abnormality, but this does not exclude the joint as the source of the pain. The treatment lies in the hands of the experienced dental surgeon who may manipulate the joint in acute cases with immediate relief, or correct the bite or change the dentures in long-standing cases.

Pharyngeal causes of otalgia include acute tonsillitis, peritonsillar abscess, post-tonsillectomy pain, ulcers in the mouth and pharynx, malignant disease of the nasopharynx, pharynx and hypopharynx. The pathway of most of these is the glossopharyngeal nerve. *Glossopharyngeal neuralgia* is a primary neuralgia causing intermittent, agonizing paroxysms of pain affecting the base of the tongue, the fauces and the ear. The spasms are provoked by swallowing, talking or coughing, and the pain is unilateral. Treatment by

OTALGIA

carbamezapine (Tegretol) is less successful than in trigeminal neuralgia, and the roots of the glossopharyngeal nerve may have to be divided by a neurosurgeon. A *tympanic plexus neuralgia* is a similar paroxysmal pain, confined to the ear, and may be initiated by touching the ear.

Nasal and sinus causes of otalgia are not common, but malignant disease of the nose and sinuses may cause earache in addition to the local pain.

The *larynx* must be examined because pain may be referred to the ear in tuberculous laryngitis and postcricoid cancer.

Cervical causes are mainly neuralgic and may follow a whip-lash injury, intervertebral joint disease and cervical spondylosis. The pain usually starts in the occiput and radiates forwards, and it may involve the ear.

SYNDROMES ASSOCIATED WITH THE EAR

Chorda tympani syndrome causes sweating in the submental region after eating, and is treated by section of the nerve via a tympanotomy approach.

Auriculotemporal syndrome, or Frey's syndrome, is also associated with eating and is manifested by sweating and vasodilatation in the cutaneous distribution of the nerve. It may be found after infection or injury of the parotid gland, and is due to a disturbance between the sympathetic and parasympathetic nerves, the tympanic branch of the glossopharyngeal nerve of the latter system taking part. There is no specific treatment.

Costen's syndrome is the name sometimes given to disorders of the temporomandibular joint which have been discussed.

Behçet's syndrome is a triad of symptoms, ulceration of the pharynx and mouth, and of the genitalia, and iritis. It may cause a referred otalgia from the oral lesions.

CHAPTER 51

CLINICAL EXAMINATION

In examining the ear with a forehead mirror good illumination is necessary. Any fairly powerful lamp, such as an electric bull's-eye lamp, will answer the purpose. Daylight may suffice for the examination of the external meatus, but is less satisfactory for the drumhead. The source of light is arranged on one side of the patient's head and slightly above the level of his ear (*Fig. 155*). The electric headlamp may be employed. The patient is seated sideways to the surgeon who sits opposite the ear to be examined and reflects light on to it. Before introducing a speculum the mastoid process should be examined, and any abnormality, such as a scar, redness or oedema, is noted. The auricle is

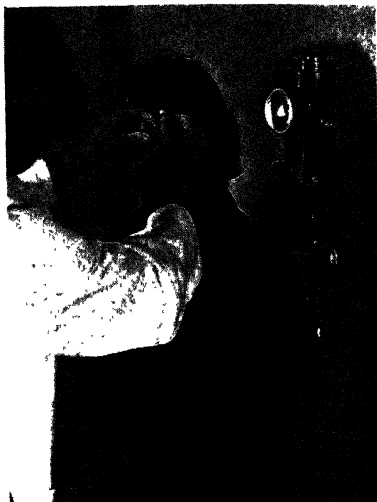

Fig. 155. Otosopic examination.

next examined for inflammation, swelling or skin lesions. The external meatus is investigated for swelling of the walls, dermatitis or visible discharge, and this inspection will allow a suitably sized speculum to be selected for insertion.

In order to see the drumhead the external meatus must be straightened by pulling the auricle upwards, outwards and backwards. In infants, owing to the non-development of the bony external meatus, the auricle has to be drawn

downwards and backwards. In a considerable proportion of cases these manipulations permit of an inspection of the drumhead without the use of a speculum, unless vibrissae interfere with the view or the outer end of the meatus is slit-like. The speculum should have a wide mouth and an oval or circular end, and there should be three or four different sizes to suit all ages. The auricle is held up by the middle and ring fingers as the speculum, held by the thumb and index finger, is gently inserted into the meatus (*Fig. 155*). Obstructing vibrissae may be passed by a rotary movement of the speculum, but the instrument must not be inserted far enough to come in contact with the bony meatus as this part of the canal is exceedingly sensitive.

The electric auriscope, or otoscope, is more frequently employed in general practice. There are many patterns on the market. It is wise to select one which gives a good light directed through the tip of the speculum and not falling on one of the walls. There should be four or five specula of different sizes, and especially one small enough for use in infants. Some auriscopes have closed heads while others have open heads to allow the passage of wool mops or wax cures, but the latter are generally used by specialists. Many have a fixed focus, and this may mean that the definition of the tympanic membrane is not always satisfactory. Others have an adjustable focus. Magnification is usually $\times 2$, but it is possible to acquire one with a magnification of $\times 3$, or even $\times 6$ although this is too great for general use. Some patterns have an attachment for a rubber bulb, thus adapting the instrument for use as a pneumatic speculum (*Fig. 156*), but frequently the rubber tube or the cement in the eye-piece becomes loose in time, and the advantage is lost.

On looking into the meatus, the skin of the posterior inferior meatal canal will probably meet the eye first. The tip of the speculum must be pointed upwards and inwards to display the membrane. In health, the drumhead presents a highly polished grey surface (*Plate X, 1*) of which the posterior and upper part is distinctly nearer the eye than the anterior and inferior. The colour alone is not sufficient for recognition of the membrane; the handle of the malleus must also be seen. At the upper end of the handle the short process is noted as a small projection, and running backwards and downwards from this the handle of the malleus appears as a whitish-yellow streak ending at a point (the umbo) below the centre of the membrane.

For purposes of description the membrane is divided into four quadrants by imaginary lines, one drawn horizontally through the umbo while the other bisects this line at right angles (*Fig. 157*). Extending downwards and forwards from the umbo the cone-shaped light reflex is seen. This is fairly constant in position as the anterior inferior quadrant of the membrane is the only part that is approximately at right angles to the meatus, and therefore in a position to reflect the light from the mirror. The reflex may be absent owing to loss of gloss, or it may be altered in position by changes in the curvature of the drumhead. In front of and behind the short process two folds are seen on the membrane. These are called the anterior and the posterior malleolar folds. They are only very slightly marked in the normal drumhead, but become exaggerated in cases of indrawing (*Plate X, 2*). Above the short process the membrana flaccida, or Shrapnell's membrane, fills the gap in the tympanic ring known as the notch of Rivinus. As its name implies, this part of the drumhead is less taut than the part inferior to the malleolar folds, called the membrana tensa.

The translucency of the drumhead varies considerably in health and, while the above description refers to one of average translucency, additional structures may be seen when the membrane is more transparent. The long process of the incus is frequently observed as a white line behind and parallel to the handle of the malleus (*Fig. 157*), but extending only about half its

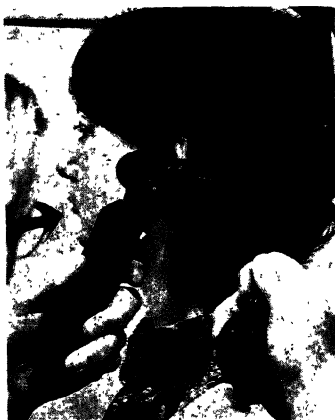

Fig. 156. Using the electric auriscope as a pneumatic speculum.

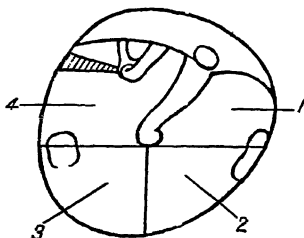


Fig. 157. Diagram of right tympanic membrane. 1, Anterior superior quadrant; 2, Anterior inferior quadrant; 3, Posterior inferior quadrant; 4, Posterior superior quadrant.

length. It is sometimes seen to end in a round spot which is the head of the stapes. At right angles to this, and extending to the posterior margin of the membrane, the tendon of the stapedius muscle presents a similar appearance. In the lower and posterior quadrant a round shadow may be seen at the circumference of the membrane which corresponds to the niche leading to the round window. The centre of the membrane may be of a pale yellow colour due to the promontory shining through, because the membrane is concave while the promontory is convex, and thus the medial wall of the middle ear cavity is much closer to the drumhead at this part. It is occasionally possible to see the tympanic opening of the Eustachian tube through the most anterior part of the membrane.

While the normal appearance is readily recognized after a little practice, the beginner experiences considerable difficulty in distinguishing many abnormal conditions. Where difficulty exists, the short process and handle of the malleus should be looked for in the first instance, because if they are seen there is no doubt that the structure they lie in is the drumhead, however much



Fig. 158. Siegle's speculum.

its appearance may be altered. When they are not detected the observer must attempt to estimate the depth of the structure at which he is looking. If it is obviously nearer the eye than the membrane, the appearance may be due to a polypus, granulation tissue, wax, a foreign body or some projection from the meatal wall. If the appearances are not comparable with any condition with which the observer is familiar, the ear should be syringed or mopped out, as the presence of even a little pus or a flake of wax or desquamated epithelium may be quite misleading and give rise to an incorrect diagnosis.

A minute perforation of the membrane appears as a black spot because, as it is small, the middle ear is not lit up through it. A healed influenzal bulla gives a somewhat similar appearance. A larger perforation allows light to illuminate the middle ear cavity. Perforations have clear-cut edges unless they are due to trauma in which case the edges may be ragged. A cicatrix is usually transparent and may appear like a dry perforation (*Plate X, 18*), but unless it is adherent to the medial wall of the middle ear it may be distinguished from a perforation by means of a Siegle's pneumatic speculum (*Fig. 158*). This is a speculum which expands into a small chamber and is closed at its outer end by a lens. A small hollow tube, to which a valveless rubber ball is attached by rubber tubing, is let into the side. The speculum is introduced into the meatus, which it should fit closely, and an enlarged view of the drumhead is obtained. By alternately compressing and releasing the bulb, the air in the meatus is alternately condensed and rarefied. In the case of a cicatrix each movement of the rubber ball makes it flap in and out (*Plate X, 19*) while a perforation shows no movement, although, if the middle ear contains secretion, some discharge may be sucked out through the perforation.

THE EAR

An indrawn membrane presents characteristic appearances (*Plate X, 2*); the short process is prominent and causes the anterior and posterior malleolar folds to be much exaggerated, especially the latter which frequently present a sickle shape. The handle of the malleus is foreshortened and rotated, so that it lies in a more backward direction than usual. This change in direction brings the umbo into the upper half of the membrane and thus the light reflex is displaced, being extended or fragmented to appear as a mere spot of light at the periphery.

CHAPTER 52

LOCAL AURAL TREATMENT

In this chapter some instruction will be given in the commonly practised treatments of diseases of the ear.

Syringeing. The most useful type of syringe for this purpose is made of brass or plated or rustless steel. It is impossible for a patient to syringe his own ear efficiently. Any competent person may, after a little training, learn to carry out this simple procedure. Sterile saline solution, or boracic lotion (1 : 40), or a solution of sodium bicarbonate, warmed to blood heat, should be employed for syringeing. After filling the syringe, bubbles of air must be expelled by pressing on the piston with the point of the syringe raised. The patient should be seated, a towel laid over his shoulder and a kidney dish held either by the patient or an assistant immediately below his ear and in close contact with the skin to catch the return flow of lotion. The patient's head is inclined slightly downwards and towards the same side to prevent the fluid from running down the neck. It is a natural reaction for the patient to tilt his head away from the stream of fluid. The auricle is pulled upwards and backwards to straighten out the meatus, and the fluid is injected along the upper wall of the meatus (*Fig. 159*). It is essential to illuminate the ear by direct or reflected light. Excessive force should not be exerted to remove wax. If the wax is hard and does not come away easily, it is better to ask the patient to instil drops of lukewarm sodium bicarbonate ear drops, B.P.C., for several days to soften the wax, and then return for syringeing. When the wax has been removed, the ear should be inspected to ensure that none remains. The meatus should be dried with cotton-wool mops after syringeing. This is important because any abrasion of the skin during the procedure may become infected if it is left in a moist condition. Some surgeons advise that a few drops of spirit be instilled after syringeing to complete this drying.

Suction clearance. Suction clearance of pus and debris is sometimes used in hospital. Under observation with the operating microscope a fine aural cannula is inserted and suction applied until the meatus, the mastoid cavity (if one is present) and the middle ear are clean.

Removal of Wax. This may be carried out under vision with the aid of wax curettes and fine forceps. This is essentially a specialist procedure, and great gentleness is necessary.

Mopping the Ear. Discharge may be mopped from the ear using cotton-wool on a fine wool carrier. Again, gentle handling must be observed, because of the sensitive nature of the skin in the bony meatus. It may be done by nursing staff who have been trained. Mopping of the ear by the patient or his relatives must be confined to the outer part of the meatus, and is thus rather social cleansing than curative or therapeutic.

Inflation of the Eustachian Tube. To complete the examination of the ear it is often necessary to try the effect of inflation of the middle ear cavity by driving air through the Eustachian tube into the tympanum. This procedure is important in diagnosis and prognosis, and as a method of treatment. It is of importance in diagnosis in that it gives information as to the patency of the tube, it demonstrates the presence of abnormal secretions within the tube or the middle ear cavity and it gives information as to the site of the



Fig. 159. Syringing the ear.

lesion by its effect on the acuity of hearing. It is of value in prognosis as this depends largely upon the immediate improvement of hearing after inflation, and upon the length of time such improvement lasts. Inflation may be performed by Valsalva's method, by Politzer's method or by the Eustachian catheter.

In *Valsalva's method* the patient pinches both nostrils and makes a forced expiration with his mouth shut. If the Eustachian tubes are patent air passes into the tympanum and the patient feels a crack or a sense of fullness in the ears. If the drumhead is inspected during inflation it is seen to move if there is nothing to interfere with its mobility. Valsalva's method is not always successful, even when the tubes are patent.

Politzer's method is carried out by means of a Politzer bag. This is a rubber bag about the size of a large orange, and is connected to an olivary nozzle which is inserted into the nostril. Both nostrils are then tightly closed by the finger and thumb of the surgeon's left hand, the bag being held in his right. The patient is given a sip of water and is told to swallow, and the moment he does so the bag is forcibly squeezed. The most effective moment at which to compress the bag is that at which the larynx rises at the beginning of deglutition. Part of the air thus driven into the nose will pass into the middle ear on each side through the Eustachian tubes, unless they are very blocked. In the case of children the bag may be compressed during the act of crying.

Eustachian catheterization is employed if Politzer's method fails, or if one ear only is to be inflated. The Eustachian catheter is a metal tube, the inner end of which is curved and blunt, while the outer end is expanded to permit the insertion of the end of a Politzer's bag. There is a ring on the tube which points in the same direction as the beak of the tube. Catheters vary in calibre and in the amount of curve. The nose should be first examined to see whether there will be obstruction to the passage of the tube. The nasal cavity to be used is then sprayed with a 5 per cent solution of cocaine hydrochloride to reduce the discomfort of passing the catheter. After ensuring that the lumen of the catheter contains no water by blowing through it with the Politzer's bag the catheter is passed into the nose. The tip of the patient's nose is tilted up, and the catheter is inserted point down. As soon as it is within the nasal cavity the catheter is swung into the horizontal position and gently pushed backwards along the floor of the nose until it impinges on the posterior wall of the nasopharynx. The catheter is then steadied at the anterior nares, and rotated through a right angle so that the point passes medially. It is withdrawn slowly until it catches on the posterior end of the nasal septum; then it is rotated through 180° when the beak will lie within the nasopharyngeal end of the Eustachian tube. Retaining the grip on the catheter at the nose, the Politzer's bag is fitted to the outer end of the catheter and squeezed. When the tube is patent air will be heard to enter the middle ear. This is heard through an auscultation tube, one end of which the patient holds in his ear while the other end is in the surgeon's ear. If the Eustachian tube is patent, a blowing sound is heard; if partly obstructed, the sound is less distinct; if there is fluid in the Eustachian tube, crackling noises are heard.

There are many difficulties in the passage of the catheter. Should the side of the nose be blocked, the catheter may be passed through the opposite side, turned towards the ear to be examined and withdrawn until it meets the posterior end of the septum, and inflation performed. Most beginners fail to bring the catheter to the horizontal position quickly enough, and this means that the catheter is passed above the inferior concha. Too much handling of the catheter in the nasopharynx may cause a spasm of the soft palate, and this locks the catheter. In such an event, one must wait until the spasm has subsided. Sometimes there is difficulty in driving air into a correctly passed tube, and in this event the patient should be asked to swallow, and the bag is compressed at the moment of swallowing. After inflation has been carried out by one or other of these methods the hearing must again be tested and the results noted.

The respective merits of inflation by politzerization and inflation must be considered. Politzerization is easier to carry out, is less disagreeable to the patient and is the only method possible in children. It has the disadvantage that its effect cannot be limited to one ear, and it may have the unfortunate complication, if repeated often, of stretching and slackening the healthy tympanic membrane with resulting impairment of hearing. Catheterization can be confined to one ear, the force of inflation can be more readily regulated and the auscultatory phenomena can be more easily observed.

Packing the Ear. The insertion of medicated gauze wicks into the external auditory meatus is a frequent and necessary method of applying local treatment to the skin of the meatus, and is commonly used in the treatment of

otitis externa. The wick consists of a suitable length of narrow (12 mm) ribbon gauze which is either soaked in a prescribed lotion such as aluminium acetate, 8 per cent in water, or ichthyol, 10 per cent in glycerine, or is impregnated with one of the anti-inflammatory ointments or creams. Packing should be done under direct vision with good illumination. Angled forceps are used to place the leading end of the wick well into the external meatus which is straightened by traction of the auricle upwards and backwards (*Fig. 160*). An adequate length of gauze is gently packed into the meatus



Fig. 160. Packing the external meatus with medicated gauze.

to ensure that contact is achieved with the meatal walls, which also derive some support from the pack. Medicated ear wicks are usually changed daily or on alternate days.

Minor per-meatal procedures, such as removal of granulations or an aural polypus, may be made easier in a patient with a narrow meatus by the preliminary insertion of a gauze wick which has been soaked in a solution of 1 : 1000 topical adrenaline hydrochloride, excess solution being expressed from the gauze.

Ear Drops. Solutions should be slightly warmed before use. The method of instillation is simple. The patient bends his head to one side, the affected ear being uppermost, the auricle is pulled upwards and backwards and up to ten drops are instilled into the meatus from a dropper. The tragus is pressed immediately afterwards to drive the fluid inwards and to expel air bubbles. After a lapse of 2 minutes the fluid is allowed to escape and the ear is dried. If a more than temporary action is required, the fluid is retained by a pledget of wool in the meatus.

Insufflation of Powder. Some cases of otorrhoea are benefited by the use of powder, which is insufflated into a dry ear. Any discharge must be mopped out, or if it is syringed out the ear must be thoroughly dried before the powder is blown in through an insufflator with a fine straight nozzle. Only sufficient powder to form a thin film should be used.

Caustics. These may be employed to destroy small granulations or the stumps of polypi. Copper sulphate, a bead of chromic acid fused on a probe,

trichloroacetic acid or silver nitrate may be used for this purpose. The caustic must be applied under direct vision, and confined to the required area.

Anaesthesia. Should local anaesthesia of the ear be required a watery solution of cocaine hydrochloride has but little effect. Anaesthesia of the tympanic membrane may be achieved by a 10 per cent solution of cocaine hydrochloride in aniline oil, but this carries a risk of aniline poisoning. Most surgeons inject a 0.5 per cent solution of procaine, containing a few drops of a solution of adrenaline hydrochloride 1 : 1000, under the skin at

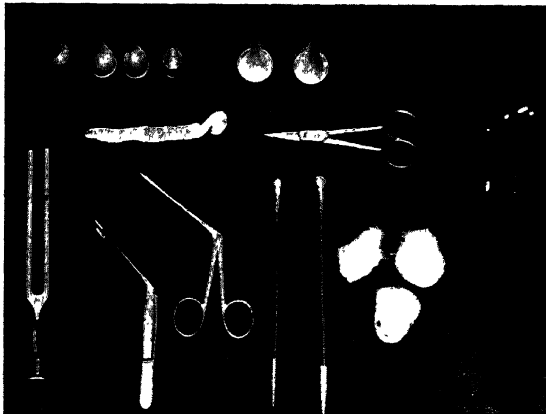


Fig. 161. Instruments for aural examination and treatment.

the upper and posterior part of the meatus. This is done under direct vision, and some practice is required before success is achieved.

Instruments. Most instruments (*Fig. 161*) for use in the external ear are bent at an angle of rather more than 90° , with the object of bringing the hand below the line of vision when the instrument is in use. During routine examination of the ear a pair of angled forceps should be at hand to remove shreds of epithelium or flakes of wax. There should be probes, both for carrying wool for mopping, and to be used as an aid to diagnosis. A blunt wax curette should be available. Gentleness of touch is of paramount importance in using instruments in the external meatus, especially in its inner half. Children will usually permit the removal of small pieces of wax by a moist wool-tipped probe to allow inspection of the drumhead, or the gentle mopping of discharge from the ear.

CHAPTER 53

THE AURICLE

Congenital malformation of the auricle and congenital meatal atresia (*Fig. 162*) are due to maldevelopments of the first pharyngeal cleft and the first and second visceral arches. The tympanum, malleus, incus and stapes are also involved. Several varieties of auricular deformity are described, varying from slight cases, such as pointed or Darwinian ears, to total absence of the external ear (anotia). In marked cases of meatal atresia the tympanic membrane is defective or even absent. As the otic vesicle, from which the membranous labyrinth is formed, develops earlier than, and quite independently of, the external and middle ears, the labyrinth is usually normal in these cases. The condition is as a rule unilateral. Facial paresis, maldevelopment of the mandible, hemiatrophy of the face, and other congenital deformities are sometimes associated with microtia and meatal atresia (Treacher Collins syndrome). It has been found in association with a congenital abnormality of the urinary tract. Hearing tests usually show the results obtained in lesions of the sound-conducting apparatus (p. 265), but even in bilateral cases the human voice is, as a rule, heard well enough to allow the patient's speech to develop.

TREATMENT. Operative treatment may be indicated in cases of bilateral congenital atresia but should not be undertaken until a thorough assessment has been made of the extent of the deformity and the degree of impairment of cochlear function. The first step in the management of these children is the early fitting of a bone-conduction hearing aid so that the natural stage of 'readiness for listening' is employed. A close liaison between parents, teacher and surgeon must be maintained. Surgery may be undertaken between the ages of 18 months and 2 years although some authorities recommend a delay for a further year depending upon the child's progress. Whilst the anatomical deformity can be defined with some accuracy by radiographic examination including tomography, the assessment of cochlear function may be more difficult.

The operative technique varies with the circumstances in each case. Where superficial landmarks are recognizable, an approach may be made to the mastoid antrum and the middle ear explored as in a radical mastoid operation, the two-tunnel approach. When no landmarks are present, a one-tunnel approach is made to the middle ear in the angle formed by the level of the dura mater above and by the posterior wall of the mandibular joint in front. When the necessary tympanoplastic procedure is completed, the resulting cavity is lined by a sac formed from a split-thickness skin graft. In the case of gross middle ear deformity a second-stage fenestration may be undertaken when the ear is healed or an air-conduction hearing aid may be worn in the reconstructed meatus.

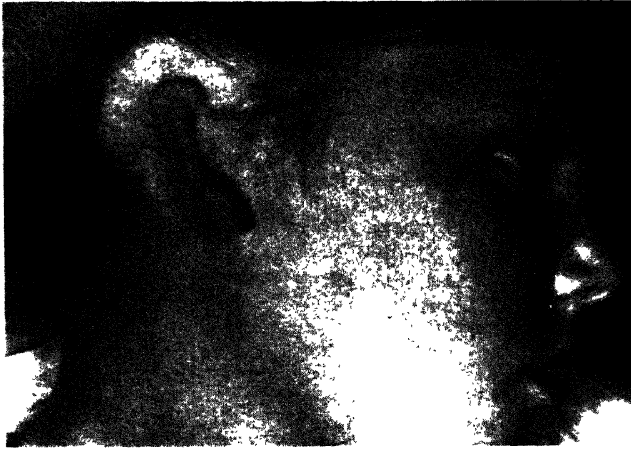
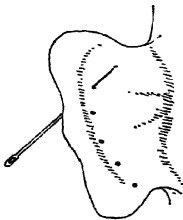
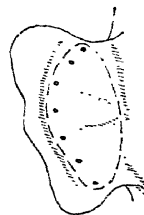


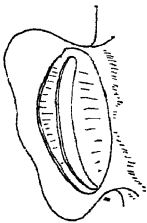
Fig. 162. Congenital malformation of auricle and atresia of meatus.



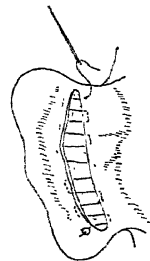
Line being marked on cranial surface of Pinna.



Elliptical skin incision marked.



Crescent of cartilage excised.



Subcuticular stitch inserted.

Fig. 163. Operation for outstanding auricle. (After Mawson.)

Outstanding Auricle or 'Bat-ear'

Many infants and young children appear to have unduly prominent ears but this feature becomes less striking with development of the mastoid process. In marked cases a plastic operation may be performed. It is insufficient to excise only an elliptical area of skin from the posterior aspect of the auricle and mastoid process, because the elasticity of auricular cartilage will cause the deformity to recur. The area of cartilage to be excised is determined by pressing the auricle back into a normal position so that a rounded convexity is produced where the fold of the antihelix should normally be present. This convexity is marked by a line on the lateral surface of the

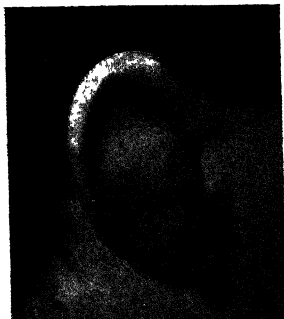

Fig. 164. Haematoma of auricle.



Fig. 165. Perichondritis of auricle.

auricle, and the situation of this line transferred to the cranial surface by transfixion at several points (Fig. 163). An elliptical area of skin is removed, the cartilage is incised along the marked line and a crescentic area of cartilage is dissected out, preserving perichondrium where possible. The wound is sutured and the head bandaged in an effort to prevent haematoma formation.

Congenital Aural Fistula

This is an opening which, when present, is usually found in front of the helix or tragus, and leads to a fine blind canal. The orifice may become blocked with the result that a fluctuating swelling forms, and abscess formation may occur. The fistula is the remains of the outer or lateral part of the first branchial cleft. Abscess formation is treated by antibiotics, and recurrences may demand the excision of the fistulous track after an injection of aniline dye to outline its course.

THE AURICLE

Haematoma of the Auricle

This generally results from injury. An effusion of blood occurs under the perichondrium and forms a swelling on the lateral or anterior surface of the auricle which may have a bluish tinge (*Fig. 164*), and considerable pain is experienced. Suppuration may take place, resulting in destruction of cartilage, and finally in shrivelling of the auricle. If uncomplicated by inflammation, the serum becomes absorbed, but a certain amount of permanent thickening remains.

TREATMENT. In the early stages, before coagulation of the blood has occurred, aspiration, with full aseptic precautions, may be employed, but may have to be repeated owing to further oozing taking place. A firm bandage is applied with pressure over the auricle. At a later stage free incision and evacuation of the haematoma may be required, but this should not be undertaken lightly because of the risk of introducing infection.

Perichondritis of the Auricle

This may follow a haematoma or result from the extension of infection from a furuncle on the posterior meatal wall. *Ps. pyocyanea* is the common causal organism, and the pus has a bluish tinge. There is severe pain in the ear and a rise of temperature. The auricle swells rapidly, and becomes dusky in colour, and its normal contour is lost, the swelling being apparent on both surfaces (*Fig. 165*). As the infection progresses, necrosis of the cartilage takes place, with the result that the auricle finally shrivels.

TREATMENT. This consists in a course of the appropriate antibiotic. Penicillin may be given until the results of sensitivity tests have been obtained. Ichthyol, 20 per cent in water, aluminium acetate, 8 per cent in water, or magnesium sulphate paste may be used frequently as local applications to relieve the discomfort. When fluctuation is apparent, incision and drainage are required.

CHAPTER 54

THE EXTERNAL ACOUSTIC MEATUS

ACQUIRED ATRESIA

Cases of meatal atresia which may take the form of webs, contractures or thickening of the epithelial lining are the result of infection, injury or surgical procedures involving the walls of the meatus. Web formation which occurs at the isthmus or within the bony segment of the meatus is usually associated with recurring attacks of otitis externa. Complete obliteration of the canal lumen due to fibrous tissue proliferation produces a varying degree of conductive deafness. Excision of the web may be necessary after the active infection has been removed by topical applications, exposure being obtained through an endaural incision. Skin-grafting of the raw area is not necessary. A gauze mesh pack impregnated with petroleum jelly (Sofratulle) promotes re-epithelization.

Injuries to the meatus are sometimes followed by thin membrane formation which is easily destroyed by application of a silver nitrate bead.

Contracture of the introitus of the meatus may result from burns and lacerations, and a stenosed meatus may follow mastoid surgery. In these cases a meatoplasty provides the most satisfactory restoration of an adequate meatal opening. Narrowing of the external orifice of the meatus is also seen in old age and deafness may result from quite small accumulations of wax.

Hypertrophied skin lining of the meatus is encountered in association with chronic otitis externa which is often secondary to chronic otitis media. The meatal swelling may be sufficiently reduced by packing the meatus with ribbon gauze wicks soaked in 8 per cent aluminium acetate solution to permit examination of the tympanic membrane in order to exclude middle ear disease. If this cannot be excluded the patient will require radiological examination and possibly mastoid surgery with a suitable meatoplasty.

IMPACTED WAX

The accumulated secretion from the ceruminous glands situated in the outer part of the meatus may form a solid, often hard, mass giving rise to deafness and discomfort in the ear. Tinnitus and disturbance of balance may occur from pressure of the wax on the drumhead, and a cough reflex due to stimulation of the auricular branch of the vagus has been described. The onset of deafness is often sudden following washing or bathing when the entrance of water to the meatus closes a previously narrow passage for the transmission of sound by causing the wax to swell and a more profound blockage results.

DIAGNOSIS. Diagnosis is in most cases easily made by otoscopic examination, the mass or plug having a brown or yellowish colour but sometimes it is black or greyish when mixed with desquamated epithelium. The drum-head may be partially or totally obscured from view.

PROGNOSIS. Provided that no other cause of deafness exists in the middle or inner ear, removal of wax should restore hearing to its previous level. Prior to treatment patients should be asked about any previous ear disease, and the possible presence of a perforated drumhead, or one which has healed with a thin scar, should be kept in mind so that a warning may be given of a possible reactivation of otitis media. In such situations it may be decided that the wax should be removed by suitable instruments rather than by syringeing of the ear.

TREATMENT. Wax is removed either by instrumental manipulation or by syringeing. The former method should be reserved for special situations and performed only by an otologist. Syringeing is advised for most cases and may be carried out by trained personnel after the presence of wax has been confirmed. Soft wax is easily removed by a stream of lotion directed along the posterosuperior meatal wall. Where the wax completely occludes the meatus, a passage for the fluid may be made by elevating the wax from the meatal wall with the flat end of a Jobson Horne probe. During syringeing the ear should be inspected at intervals so that syringeing is not continued after all the wax has been removed.

Hard impacted wax requires preliminary softening by the instillation of wax solvent drops, such as sodium bicarbonate ear drops B.P.C., which are instilled, slightly warmed, twice daily for a few days before syringeing. Further use of drops and repeated syringeing may be necessary before complete removal of wax is achieved. Very occasionally wax may resist softening and repeated syringeing, and will require removal by instrumentation under general anaesthesia.

Syringeing, though causing discomfort, should never produce actual pain and if such occurs syringeing should cease and the ear must be inspected. Severe lancing pain occurs if the drumhead is ruptured and this may be accompanied by intense vertigo while the returning fluid is tinged with blood. The syringeing lotion should be at body temperature. If too hot or too cold a caloric response may be induced from the labyrinth and vertigo experienced by the patient. After completion of the procedure the meatus should be carefully dried and the hearing tested. Any small excoriation of the meatal skin can be treated by the insertion of a ribbon gauze wick, impregnated with a bland antiseptic ointment, into the meatus for 48 hours.

KERATOSIS OBTURANS

In this condition the meatus on one or both sides becomes blocked in its deep portion by a mass consisting of wax, desquamated epithelium and cholesterol. The exact cause of the formation of these hard accumulations has not been determined but hyperaemia of the meatal skin and instability of the epidermis are possible factors. In young adults the disease has been found in association with bronchiectasis and with a chronic sinusitis. The mass is closely attached to the meatal walls and pressure effects cause absorption of bone and widening of the meatus. In severe cases the facial

nerve may be exposed causing paralysis, but in most cases the initial symptoms are pain and deafness. There may also be tinnitus and discharge from the ear. Removal of the mass is often difficult and general anaesthesia is frequently required. Initially softening of the mass with sodium bicarbonate ear drops instilled daily for several days followed by syringeing should be tried. In order to prevent recurrence an ointment containing salicylic acid, precipitated sulphur (each 600 mg) and petroleum jelly (30 g) should be applied frequently to the meatal walls. Regular observation of the patient is also necessary to prevent further solid accumulations from forming.

FOREIGN BODIES IN THE EAR

Foreign bodies, both animate and inanimate, may be found in the ear. The latter are much more frequently found, and especially so in children, and are often introduced by the patients themselves. Inanimate objects may be divided into those which swell with moisture, such as peas and beans, and those which do not swell, such as beads, buttons or shells. Foreign bodies rarely cause any trouble unless the tympanic membrane has been injured, and they may remain undetected for years. Most complications result from ill-directed attempts at removal. Gentle inspection will reveal the object in most cases. If it is not seen the ear may be gently syringed, because a very small foreign body may lie out of sight in the meatal floor, beyond the isthmus and close to the drum. When the foreign body is seen and determined not to be of vegetable composition, removal may be effected by syringeing. The stream should be directed along that part of the meatal wall where there is the widest space between it and the foreign body.

While the removal of a foreign body may be easily accomplished when it has not been driven in by ill-directed interference, great difficulties may be presented in cases of impaction, or when the object has become swollen from absorption of fluid, or if the meatal walls have become inflamed. Such cases are best treated in hospital. In cases of impaction it is sometimes possible to withdraw the object by means of a fine hook. The use of forceps is inadvisable except in the case of small or thin objects, because the jaws of the forceps often cause the foreign body to slide further into the meatus. Some objects may be removed by suction, a suitable catheter being used.

Attempts at removal of foreign bodies in children should not be prolonged, because of the pain produced and the fright engendered. In such cases, and in all cases when the object lies beyond the isthmus, it is wiser to remove it under a general anaesthetic, often with the use of the operating microscope.

If the walls of the meatus are swollen and bleeding, it is advisable, before operating, to insert a strip of 12 mm ribbon gauze soaked in a 10 per cent solution of cocaine hydrochloride to which a few drops of adrenaline hydrochloride have been added. Should a diffuse inflammation of the meatus have been set up by attempts at removal, it may be best to treat the inflammation before attempting removal. In rare instances repeated attempts at removal may have driven the object into the middle ear, and an external operation will be required for its extraction.

Animate foreign bodies in the external meatus are rarely met with in Great Britain, but are found in Eastern countries. Maggots cause intense pain, and their presence is most likely in an ear where discharge is already

present, and which has become very offensive and bloodstained. It is useless to attempt to syringe them out as they are firmly attached to the meatal walls. Chloroform water or vapour must be applied to the external meatus in order to anaesthetize or kill the maggots and so release their grip on the skin. Thereafter they may be removed by syringeing.

TUMOURS OF THE EXTERNAL MEATUS

Osteoma is the most common type of benign tumour encountered in the meatus occurring either as multiple exostoses composed of ivory bone or as a single osteoma of cancellous structure. The exostoses vary in size, and arise from the walls of the osseous meatus as rounded swellings, or as a flat area of thickening of part of the meatal wall to which the term hyperostosis is applied.

AETIOLOGY. The repeated entry of cold water into the external meatus in swimming and diving is regarded as the primary cause of the condition, but other factors such as trauma, long-standing irritation as in otitis externa or prolonged middle ear suppuration may be contributory.

Osteomata are slow growing, often occurring in both ears, and are more common in men than in women.

CLINICAL FEATURES. A single cancellous osteoma or exostosis is less common than the multiple variety. It is usually attached to the posterior wall of the osseous meatus by a narrow base and appears as a smooth rounded body which may completely fill the canal. Multiple exostoses are frequently bilateral and symmetrical, arising from the anterior and posterior osseous meatal walls. The drumhead may be almost hidden by the growths but complete blockage of the canal is unusual in this variety.

SYMPTOMS. Multiple exostoses seldom cause symptoms unless the lumen of the meatus is obstructed by accumulation of wax or epithelial debris, when the patient complains of deafness. In cases of otitis media pain may occur if there is obstruction to discharge from the middle ear or if there is a secondary otitis externa.

DIAGNOSIS. The diagnosis is generally clear on inspection although wax and debris may first require to be removed in order to view the growth. Its bony consistence is confirmed by touching it with a probe.

TREATMENT. Multiple osteomata which are not giving rise to symptoms require no treatment, and when they are observed only as part of a routine examination their presence is best left unremarked to the patient. These growths are very hard and the visible part may resemble the tip of the iceberg. The larger submerged portion of a growth arising from the posterior meatal wall may be closely related to the facial nerve canal so that removal may cause damage to the facial nerve. When removal is necessary on account of persistent symptoms it is best effected by the use of a high-speed drill and suitable burrs applied directly to the growths via the external meatus, which is widened if necessary by an endaural incision.

Surgery is more often necessary in the case of single cancellous osteoma which is likely, by its continued and more rapid growth, to cause complete obstruction of the meatus. Because of its pedunculated attachment this type of osteoma may frequently be removed by applying a gouge to the pedicle of the growth and cracking it at its base. Care must be taken to

protect the drumhead and middle ear by supporting the growth on its medial aspect with a curved dissector. Large osteomata may require a wider exposure by means of an endaural incision or an external retro-auricular approach.

Other benign tumours of epithelial and mesenchymal origin may affect the external meatus but, apart from papillomata, these are only occasionally found.

MALIGNANT TUMOURS (*see* Chapter 71)

TRAUMATIC RUPTURE OF THE TYMPANIC MEMBRANE

Rupture of the drumhead may result from a variety of causes, the commonest of which arises from ill-advised attempts at clearing the ear of wax or relieving irritation by the insertion of a matchstick, hair grip or similar readily available instrument. The introduction of foreign bodies in the ear and unskilled attempts at their removal can also produce rupture. During syringeing of the ear a stream of lotion directed at the drumhead instead of along the posterior wall of the meatus has not infrequently been the cause of perforation, although in many of these cases there has been a pre-existing thin scar which has ruptured under pressure. The accidental application of a caustic agent has been reported to produce a perforation, and a spark entering the meatus during metal welding has been known to burn through the membrane. The detonation of high explosives results in the formation of blast waves of expansion and contraction, which may not only rupture the drumhead but may seriously injure the inner ear. Blast injuries of the drumhead generally affect the antero-inferior quadrant although almost complete destruction of the membrane may occur. Either phase of the explosion may be responsible for the damage but the view is expressed that the drumhead which has been displaced inwards by the expansion or positive wave can less readily respond to the contraction or negative wave and the membrane ruptures outwards. Comparatively less severe pressure changes resulting from a blow over the external ear by the palm of a hand or a robust kiss on the ear are potential causes of injury. Bleeding from the ear and a tear in the drumhead are common complications of skull fracture involving the tympanic part of the temporal bone.

SYMPTOMS. Pain of varying intensity occurs at the moment of rupture and is accompanied by deafness and sometimes by bleeding. Tinnitus may be severe and there may also be nausea and vertigo. With inner ear involvement deafness may be profound and permanent.

PROGNOSIS. The prognosis regarding hearing depends largely on the extent of the damage to the cochlea. Many of these cases result in legal proceedings and therefore audiometric examination should be done and a full description of the injury noted. Secondary infection of the middle ear may adversely affect recovery of hearing and the full effect of blast injury on the cochlea may not be apparent for several years.

TREATMENT. Many small tears will heal without treatment apart from measures taken to avoid the introduction of infection. Syringeing of the ear or instillation of ear drops must be strictly avoided. A plug of sterile cotton-wool should be placed in the meatus and the patient warned against allowing water to enter the ear. These measures must be scrupulously maintained

THE EXTERNAL ACOUSTIC MEATUS

until the perforation has healed. In cases of suspected or known contamination of the ear a prophylactic course of antibiotic such as intramuscular penicillin should be given. Small perforations which have not healed in 3 or 4 weeks may be stimulated by very light applications of trichloroacetic acid to the margins. The perforation may be covered by a small patch of oiled silk or a piece of gelfoam soaked in a drop of the patient's blood. In the case of unhealed or large perforations myringoplasty is necessary.

CHAPTER 55

INFLAMMATION OF THE EXTERNAL ACOUSTIC MEATUS

OTITIS EXTERNA

The origin of disorders of the skin involving the external ear may not be immediately recognized, particularly those involving the meatus, and even manifest disease of the auricle and adjacent skin areas may arise in the meatus or middle ear. Otitis externa has been classified as localized or generalized. When it is confined within the external meatus two clinical forms are recognized: (i) circumscribed otitis externa or furuncle, (ii) diffuse otitis externa.

The generalized form affecting meatus, auricle and adjoining areas of skin may be primarily otological or primarily dermatological. In addition, the condition may be classified as infective, due to bacterial, fungal or viral agents; and reactive, from contact with numerous external sensitizing agents or resulting from constitutional allergies. In many cases the disease is of mixed origin, a primary infective lesion developing an eczematous reaction and vice versa.

INCIDENCE. The incidence of otitis externa is highest in tropical countries with a high humidity where the symptoms are often severe and recurrences are frequent.

AETIOLOGY. Many factors can be implicated in the onset of otitis externa. Scratching the ears with dirty fingers or with contaminated objects such as a matchstick or a hair grip, or the use of dirty instruments may introduce pathogenic organisms to the meatus. If the skin is traumatized infection may penetrate the barrier of the stratum corneum. Syringeing the ear for the removal of hard wax or badly fitting and infrequently cleaned hearing-aid ear-pieces may also cause minor injury and subsequent infection. In other cases allergy is the primary factor. The development of skin allergy may be due to a large variety of antigens many of which are contained in topical applications such as cosmetics and antibiotic preparations. Intense itching is an early symptom of sensitization and scratching often leads to secondary infection. A sensitivity reaction may result from psychological factors such as prolonged mental stress.

BACTERIOLOGY. The normal external meatus is sterile, or contains *Staphylococcus albus* alone or in combination with other non-pathogenic organisms. Less often *Staph. aureus* or non-haemolytic streptococci are found. In cases of otitis externa the bacteriological flora is often mixed, and *Staph. aureus* and Gram-negative organisms such as *Pseudomonas pyocyanea* and *Proteus vulgaris* are present. *Escherichia coli* occurs also in mixed infections. The

proportions of these organisms vary with the geographical area, *Ps. pyocyanea* being commonest in tropical and subtropical regions.

SYMPTOMS. At an early stage pain in the ear and discharge from the meatus are commonly present. Pain is usually severe in furunculosis, aural herpes and the acute primary stage of diffuse otitis externa being preceded in the latter by a hot burning sensation and followed by a thin serous discharge which may become thicker and more profuse as the condition develops. When discharge is present a swab should be taken to determine the organisms and their sensitivity to antibiotics. If the discharge has a sticky mucoid content an underlying otitis media must be suspected. Itching is a prominent symptom in seborrhoeic dermatitis, drug sensitivity, neurodermatitis and otomycosis. Conductive deafness results from obstruction of the meatus by oedema of the walls and accumulated debris or discharge. In cases of chronic diffuse otitis externa thickening of the meatal skin causes a permanent meatal stenosis so that small amounts of wax and epithelial debris may give rise to deafness. Fissuring of the skin around the meatal introitus is associated with seborrhoeic dermatitis and eczema. Furunculosis of the posterior meatal wall may be accompanied by retro-auricular oedema with retraction or protrusion of the auricle.

MANAGEMENT. Cleansing of the skin of the external meatus is necessary. All discharge and epithelial debris must be carefully and gently removed, first so that the drumhead may be inspected and secondly to allow local therapeutic applications to gain contact with the skin of the meatus. Cleansing in the tender ear may be done by gentle irrigation with a bland solution, such as isotonic saline at 38 °C, and when inspection has shown that the meatus is clean it is carefully dried with lightly dressed cotton-wool mops on a wire carrier. Further otoscopic examination should be done to visualize the drumhead and to ensure that no debris remains in the antero-inferior meatal recess. Failure to clear this pocket may result in prolonged treatment and recurrences. In dry, scaly and crusted ears cleansing may be helped by the use of mops dipped in sterile liquid paraffin. Trauma to the meatal skin must be avoided and treatment by trained staff is necessary.

Furunculosis. Boils (furuncles) are due to a staphylococcal infection of hair follicles or sebaceous glands which are present in the skin of the outer cartilaginous part of the external meatus. They may develop in the superficial layers of the skin or may be more deeply seated. A boil may occur as a single lesion or as multiple lesions confined to the ear or associated with boils elsewhere in the body. They commonly recur particularly in debilitated individuals and in diabetics.

Furuncles produce severe pain in the ear and tenderness in the region of the meatus at an early stage. Swelling of the meatal walls may occlude the meatus thus causing deafness. The superficial infection may be seen as a small, red, circumscribed and very tender swelling on the skin of the meatus. Deep infection is more diffuse and the skin initially shows no significant change although the area may be tender on gentle pressure. When a boil is situated on the anterior or inferior meatal wall chewing movements of the jaw cause increased pain and swelling of the lower eyelid may be present. If the boil is on the posterior wall the swelling may cause protrusion of the auricle and obliteration of the postauricular sulcus by oedema. Infection may spread to lymph glands either anterior to the auricle or below the tip

of the mastoid process. Swelling of the meatus associated with discharge from the ear may cause difficulty in deciding whether infection is limited to the outer ear or originates within the middle ear.

In distinguishing between furunculosis of the external meatus with oedema and acute otitis media with mastoiditis several observations should be noted: (1) A history of recent head cold or influenza is suggestive of middle ear infection whereas staphylococcal infection in some other area of the body may point to furunculosis. (2) Careful and gentle otoscopic examination may reveal a boil and when a normal drumhead can be seen the diagnosis is not in doubt. (3) Hearing in the affected area is better in furunculosis than in mastoiditis. Insertion of an infant-size aural speculum into the meatus when possible without causing undue pain will improve the hearing if no middle ear infection is present. (4) Pain in furunculosis is of a continuous dull throbbing character and may last for several days until the boil bursts, or is incised, when there is a scanty yellow discharge. In acute otitis media a sharp piercing pain varying in duration and intensity occurs and is relieved by the appearance of discharge which may be copious. The presence of mucus in the discharge suggests an otitis media. (5) Movement of the auricle and pressure on the tragus increase pain in furunculosis but not in otitis media. (6) In furunculosis maximum tenderness is present over the tragus, below and medial to the lobe of the ear and along the anterior border of the mastoid process. Tenderness in mastoiditis is more often elicited along the posterior border of the mastoid and over the mastoid antrum. (7) Obliteration of the postauricular sulcus with forward displacement of the auricle suggests a furuncle and this is confirmed if aspiration of a fluctuant swelling yields pus on piercing skin. If it is caused by a subperiosteal abscess from mastoid infection pus is not met with until bone is reached. (8) Mastoid radiographs showing well-developed clear cells on the affected side will exclude mastoiditis but a retro-auricular oedema produces some haziness of the cells compared with those of the normal side. Furunculosis and mastoiditis may occur together and if the latter cannot be excluded an exploratory operation may be justified.

TREATMENT. Local and general measures are necessary. Heat applied to the ear by a covered hot-water bottle, radiant heat or short-wave diathermy relieves pain especially if combined with the administration of sedatives. Meatal packs consisting of narrow (12 mm) ribbon-gauze wicks soaked in 10 per cent ichthammol glycerine B.P.C. solution, gently inserted, have a soothing effect. The wicks are changed daily. Most furuncles burst spontaneously and the discharge should be removed by dry mopping, the ichthammol glycerine wicks being continued until the ear is dry. After-treatment consists in keeping the external meatus clean and applying a disinfectant such as 1 per cent solution of gentian violet in spirit. The majority of boils are due to *Staph. aureus* infections and unless there is a previous history of sensitivity a 5-day course of treatment with penicillin gives a rapid relief of pain, particularly if given intramuscularly. Incision of a boil should be delayed until it is clearly pointing on the skin. Recurring boils are not uncommon. In persistent cases the urine should be tested to exclude diabetes mellitus. The patient is frequently a scratcher and transfers infection from the nasal vestibules which are also a source of *Staph. aureus* infection. In such cases the application of a chlorhexidine cream (Naseptin) for several

days will clear this carrier area. In more resistant cases the whole body requires to be washed in a bactericidal liquid soap and dried with a fresh clean towel. Artificial sunlight baths and a reduced carbohydrate diet may be included in general measures.

Diffuse Otitis Externa. This condition occurs in acute or chronic stages in which the skin of the external meatus varies from an acute exfoliative and exudative reaction to a chronic granular or proliferative state.

Acute Stage

This presents usually as a feeling of heat in the ear, soon changing to pain which is often severe and is increased by jaw movements. The appearance of a thin serous discharge is accompanied by easing of the pain. Later the discharge becomes thicker and purulent and in some infections foul-smelling. On examination the meatal skin is inflamed, swollen and very tender. Deafness of conductive type is usually present due to accumulation of discharge and epithelial debris. Enlarged tender periauricular glands are palpable and surrounding oedema may displace the auricle. Wax is noticeably absent.

Chronic Stage

The features of this stage are discharge and constant irritation or itching. The desire to scratch is great and severe at night-time resulting often in re-infection and exacerbations of the acute stage. Thickening of the meatal skin with narrowing of the lumen may be present, or oedema and desquamation with superficial ulceration of the skin may occur. The drumhead is often congested, with a granular surface, and intermittent deafness results from accumulated debris.

TREATMENT. The treatment of both stages requires thorough and gentle cleansing of the external meatus, keeping the ears dry, avoiding trauma by scratching, attention to personal hygiene and the treatment of associated skin conditions.

In the acute stage local treatment may begin with gentle irrigation of the meatus with warm isotonic saline followed by dry mopping. An attempt should be made to see the drumhead and to clean the antero-inferior meatal recess. Provided that regular toilet of the meatus can be carried out treatment with ear drops may give satisfactory results. Preparations containing an anti-inflammatory corticosteroid and a broad-spectrum antiseptic are effective in many patients, e.g. drops containing triamcinolone acetonide and halquinol (Remotic) may be instilled twice daily. Alternatively, after cleansing, the meatus may be packed with a 12 mm ribbon-gauze wick impregnated with a cream containing triamcinolone acetonide 0.025 per cent and halquinol 0.75 per cent (Remiderm) this treatment being repeated on alternate days. Antibiotic drops and ointments should be employed circumspectly because of the risk of sensitization or secondary fungus infection, and should be related to results of bacteriological examination. In the wet stage packing of the meatus with 12 mm ribbon gauze soaked in an astringent solution such as 8 per cent aluminium acetate may produce a dry meatus. Packing should be done daily and the patient provided with a quantity of the solution so that the wick can be kept moist by applying a few drops to it three or four times a day.

Local treatment of the chronic stage requires the same meticulous toilet of the meatus. Swelling of the meatal walls may be relieved by ribbon-gauze wicks soaked in 10 per cent ichthammol glycerine. Irritation, causing reinfection by scratching, is controlled by packing the meatus with a wick impregnated with an antiseptic/cortisone cream. As the condition improves the cream may be lightly applied to the meatal walls by a wool-tipped applicator. Nocturnal itching may be relieved by sedatives, and scratching prevented by a light gauze bandage over the affected ear or by wearing a pair of clean cotton gloves.

Failure to respond to treatment may be caused by an underlying middle-ear infection, sensitivity of the skin to the local application, usually an antibiotic, or by secondary fungus infection.

OTOMYCOSIS

Mycotic infection of the external auditory meatus is prevalent in tropical and subtropical climates. The incidence in temperate climates has increased in association with the use of topical antibiotics which leave a medium sterilized of other organisms in which the fungus may flourish. The condition should be suspected when routine treatment fails to relieve a diffuse otitis externa, where there is continued irritation in the ear and when the mass of debris in the meatus rapidly re-forms after cleansing. The fungi which are commonly found are *Aspergillus niger* and *Candida albicans*. In aspergillus infections numerous black specks may be seen in the epithelial debris. Microscopic examination of a smear from the debris will confirm the diagnosis.

TREATMENT. Treatment consists in thorough cleansing of the meatus by dry mopping and the application of nystatin either in powder or ointment form. Amphotericin B (Fungilin) is also effective in candida infections. Alternatively, drops of 2 per cent salicylic acid in alcohol, or a ribbon-gauze wick soaked in this solution, may be applied to the external meatus. Regular attendance for treatment lasting 3 or 4 weeks is necessary for elimination of the infection.

SEBORRHOEIC DERMATITIS

Seborrhoeic dermatitis, commonly referred to as scurf or dandruff, is characterized by a scaly state of the scalp with patches of erythema, visible at the hair margins and the postauricular sulcus, spreading below the lobe to adjacent areas of the face. A diffuse otitis externa frequently results, with secondary infection induced by scratching (*Plate IX, 1*).

TREATMENT. The scalp condition should be controlled by regular shampoos, initially twice weekly, containing selenium sulphide (Selsun) or cetrinide B.P. The meatus should be kept clean. An ointment containing salicylic acid, precipitated sulphur (each 600 mg) and petroleum jelly (30 g) may be applied to the meatal skin with a wool-tipped applicator to prevent further scalliness and formation of fissures at the introitus.

SEBORRHOEIC ECZEMA

Seborrhoeic eczema, occurring as the result of skin sensitivity, may be infective in origin or due to contact of the skin with an external substance,

such as cosmetics, jewellery or hair lotions and hair lacquer, but more commonly to the topical use of antibiotics. The typical appearance is of vesiculation followed by a serous exudate and accompanied by severe irritation. Scratching is likely to introduce secondary infection in those cases of contact origin (*Fig. 166*).

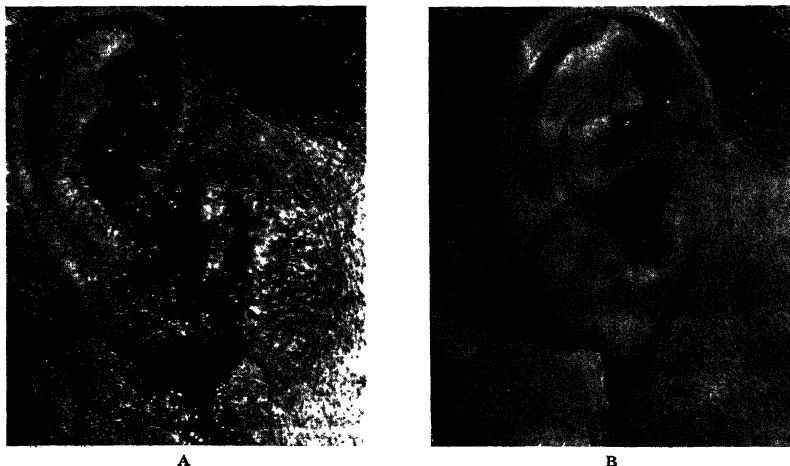


Fig. 166. Seborrhoeic dermatitis and otitis externa. A, Non-infective (contact) dermatitis showing vesiculation and weeping; B, After treatment with aluminium acetate dressings followed by beta-methasone cream.

TREATMENT. In infected allergic skin conditions the use of anti-inflammatory, anti-allergic steroids combined with antibacterial agents is advised. A cream containing triamcinolone (Adcortyl) or fluocinolone acetonide (Synalar) should be applied.

NEURODERMATITIS

In eczematous types of otitis externa resistant to treatment an underlying psychological disturbance may be present. Intense itching is the main symptom causing considerable distress to the patient with loss of sleep. Secondary infection usually produces a diffuse reaction. A disturbed mental state may be apparent or careful enquiry may reveal a state of stress.

TREATMENT. Local measures are directed at the relief of secondary infection and the control of irritation with the topical use of antibacterial, anti-allergic steroids. Prevention of further scratching is necessary and psychiatric assistance in solving the basic problem may be required.

OTITIS EXTERNA HAEMORRHAGICA

During certain epidemics of influenza the infection shows a predilection to attack the ear, and the patient complains of severe earache and tinnitus. On

THE EAR

inspection blood blisters of a reddish-brown or purple colour may be seen on the meatal walls (otitis externa haemorrhagica), close to the annulus and on the tympanic membrane (*Plate X, 5*) (myringitis bullosa). The bullae are prone to spontaneous rupture, with bloodstained discharge from the ear which may be profuse. The infecting organism is a haemolytic streptococcus combined with a virus. These blisters may occur independently of any middle ear lesion, and in such cases the hearing is practically normal. In the majority of cases, however, the bullae are associated with an otitis media, for the subperiosteal space of the posterior meatal wall is in anatomical continuation with the submucous space of the tympanum.

TREATMENT. Incision of the bullae is not indicated unless otitis media with exudate in the middle ear is present, when there will be conductive deafness and severe pain. A course of antibiotics, either penicillin or ampicillin, should be given and sedatives may be required for the pain. The meatus may be lightly plugged with cotton-wool.

Malignant Otitis Externa

The majority of reported cases of this uncommon disease have occurred in elderly diabetics. It is characterized by increasingly severe pain in the ear and purulent discharge. The organism responsible is *Ps. pyocyaneus*. Granulation tissue is present in the floor of the meatus at the junction of the cartilaginous and osseous portions. Infection spreads to the deeper tissues through the normal clefts in the cartilage of the floor to involve the parotid gland and structures at the base of the skull. Despite energetic management of the local infection the disease is often progressive causing widespread osteomyelitis, intracranial complications and death.

TREATMENT. Granulation tissue should be removed and necrotic tissue excised from the meatus to which daily packs of ribbon-gauze wicks impregnated with gentamicin ointment (Cidomycin, Genticin) are applied. The administration of gentamicin intramuscularly and carbenicillin intravenously in full dosage is also recommended. Progress of the infection may necessitate a wide excision of tissues.

CHAPTER 56

THE EUSTACHIAN TUBE

The primary function of the Eustachian tube is the maintenance of equal air pressure on each side of the tympanic membrane, normally the atmospheric pressure. Air reaches the middle ear by way of the Eustachian tube which is closed in its cartilaginous part but is opened by the movements of swallowing or yawning. The passage of air or fluid along the tube occurs more freely from middle ear to nasopharynx than in the reverse direction except in infants whose tube is wider and has a more horizontal course. Obstruction of the Eustachian tube can result from causes within its lumen or from causes arising at either end in the nasopharynx or the middle ear. When blockage of the tube occurs air within the middle ear is absorbed, the relative decrease in pressure being accompanied by inward retraction of the drumhead and congestion of the tympanic mucosa. Increase in the middle ear vacuum results in the formation of a transudate from the vessels and in some cases small haemorrhages may occur in the middle ear.

ACUTE SALPINGITIS

Inflammatory reaction in the Eustachian tube is a frequent accompaniment of the common cold or of a severe bout of hay fever. In the majority of these cases the middle ear is not involved, in others with a more severe infection otitis media may develop. The condition is associated with slight deafness and a feeling of 'stiffness' in the ear which may be temporarily relieved by swallowing. 'Popping' or 'crackling' noises may be complained of or there may be a more continuous tinnitus. Pain may radiate to the ear on nose-blowing but a more severe or persistent pain suggests the onset of otitis media. Examination of the nose and nasopharynx will frequently reveal evidence of an acute upper respiratory infection or of an allergic state. In a few cases the pharyngeal opening of the tube may be seen to be inflamed and prominent. On otoscopy the drumhead shows retraction with alteration or absence of the cone of light (*see Plate X, 2*). Vascular injection may be seen in the superficial vessels of the drumhead but quite often the drumhead is normal.

TREATMENT. Decongestant nasal drops such as 1 per cent ephedrine hydrochloride in normal saline should be instilled with the patient recumbent and the head extended and rotated to the affected side. No attempt should be made to inflate the Eustachian tube, and blowing of the nose should be reduced to the minimum, sniffing being preferable. Treatment should also be directed to the nasal and nasopharyngeal conditions.

CHRONIC SALPINGITIS

Chronic tubal obstruction has many causes, originating either at the tympanic or the pharyngeal end of the tube, which produce hyperplastic thickening, adhesions or strictures but in a number of cases no abnormality is present in these areas or it has previously been eliminated. In such cases repeated infections, often accompanied by otitis media, have caused thickening of the tubal lining and consequent obstruction. Rarely congenital stenosis or other anatomical abnormality gives rise to obstruction.

Chronic salpingitis produces conductive deafness described as a blocked or stuffy feeling in the ear with a variable amount of discomfort. The patient cannot clear the ear by auto-inflation (Valsalva's manœuvre) although catheterization may inflate the ear with improvement in hearing which is not maintained for more than a few hours.

On examination the characteristic feature is retraction of the drumhead in whole or in part. Retraction of the membrana tensa is seen when the handle of the malleus appears shortened and lies in a more horizontal position, the lateral process of the malleus is prominent and the cone of light is absent (*see Plate X, 2*). Partial or localized retraction may involve any segment of the drumhead but often produces an appearance in which the membrane is draped over the incudo-stapedial joint or appears to adhere to and outline the promontory of the middle ear. On catheterization of the tube the sounds heard on auscultation differ from the soft blowing murmur heard with a normally patent tube.

TREATMENT. In the majority of patients treatment of this condition provides only temporary relief. Periodical catheterization and inflation is usually practised despite its short-term benefit. At the pharyngeal end of the tube any factors predisposing to infection should be treated. The insertion of a grommet may be required in cases with recurrent middle ear exudate, and the prescription of a hearing aid is necessary in those patients whose deafness persists.

ABNORMAL PATENCY OF THE TUBE

An unduly open Eustachian tube is sometimes associated with atrophic changes in the mucous membrane of the nose and pharynx. The mucosa of the whole tube may be affected or changes may be limited to the pharyngeal opening. It may occur in elderly patients particularly those with debilitating diseases and marked weight loss. Congenital abnormality may account for a small number of cases.

Patients suffering from this condition complain of the loudness or resonance of their own voice (autophony) whilst their hearing is reduced for other voices and sounds. They may be aware of their own breath sounds and the patient's breathing can be heard through an auscultation tube. On examination the characteristic sign is the inward and outward movements of the drumhead accompanying respiration.

TREATMENT. In patients suffering from atrophic conditions of the nose and pharynx measures appropriate to the treatment of those diseases should be employed. Elderly and debilitated patients may benefit from attention to their general health and correction of dietary deficiencies. The insertion

of a grommet in the drumhead will give some symptomatic relief. Insufflation of an irritant powder, consisting of four parts of boric acid and one part of salicylic acid, into the Eustachian tube was formerly recommended as a means of obtaining temporary relief.

EUSTACHIAN TUBAL FOREIGN BODIES

The use of bougies for dilatation of the Eustachian tube accounted on some occasions for a foreign body consisting of a part of the bougie which had accidentally broken off and become lodged in the cartilaginous part of the tube. Small foreign bodies perforating the tympanic membrane may pass into the Eustachian tube and become lodged in the bony portion or at the isthmus. Foreign bodies should be removed from the tube as soon as possible. A surgical approach by a combined postauricular and transmeatal route to the bony Eustachian tube has been described.

OTITIC BAROTRAUMA (AERO-OTITIS MEDIA)

Otitic barotrauma is related to the condition and patency of the Eustachian tube in its function of ventilating the middle ear so that atmospheric pressure pertains on both sides of the drumhead. Barotrauma follows rapid descent in an aeroplane or, in high-speed aircraft, a very fast ascent. It may occur in the presence of tubal dysfunction involving its patency and preventing adequate ventilation of the middle ear in a situation which often arises suddenly. Swallowing and yawning cause contraction of the tensor and levator palati muscles which open the Eustachian tube thus allowing equalization of pressure in the middle ear. Chewing of sweets or gum may therefore be advised as a preventive measure during descent. For those who have previously suffered from the condition a decongestant nasal spray or a benzedrine inhaler is a useful prophylactic measure. The symptoms of barotrauma vary from slight discomfort and feeling of fullness in the ear to acute pain with effusion and deafness. Deafness and tinnitus may persist after landing and inspection of the drumhead may show gross retraction and congestion. Equalization of pressure is necessary at the earliest moment. During descent the intermittent performance of Valsalva's manoeuvre may be useful and later catheterization and inflation are often necessary. Many cases settle spontaneously or with the help of conservative measures but in a few cases myringotomy and aspiration of the effusion are necessary. In the presence of an acute upper respiratory infection the risk of a suppurative otitis media is increased and a prophylactic course of an antibiotic such as penicillin is justifiable. In the majority of patients return of normal function may be expected.

CHAPTER 57

ACUTE OTITIS MEDIA

An inflammatory reaction of the lining mucous membrane of the middle ear cleft in the whole or part of its extent from the Eustachian tube to the mastoid antrum and air cells is known as otitis media. The classification of the disease is generally related to the extent and degree of the inflammatory reaction in which there is either no formation of pus in the middle ear, non-suppurative otitis media, or one in which there is exudation of pus, suppurative otitis media. It should, however, be noted that an initially non-suppurative condition may proceed to a suppurative one. Acute and chronic forms of the disease are found.

ACUTE NON-SUPPURATIVE OTITIS MEDIA

(Acute Secretory Otitis Media)

Acute non-suppurative otitis media, characterized by a non-purulent effusion in the middle ear, commonly follows Eustachian tube obstruction. The majority of cases are associated with upper respiratory infections of nasal origin or with allergic rhinitis. The latter may be a more common causal agent than expected, the symptoms appearing suddenly after exposure to, or ingestion of, some allergen to which the patient is sensitive. In other cases the predisposing factor may be an obstructive one such as adenoids or nasopharyngeal tumour. It may occur in patients who have a palatal paresis. In a few cases there may be no apparent cause. The effusion is either thin or viscid and is sterile on culture.

SYMPTOMS. Earache is a more frequent symptom in children but when pain occurs it is usually associated with Eustachian obstruction and diminishes as the effusion increases in the middle ear and the negative middle ear pressure decreases. The leading symptom is deafness which is described in various ways, often as 'a blocked or woolly feeling' in the ear. The degree of deafness is variable and improvement may occur when the ear is felt to 'crack' or 'pop'. An undue resonance of the patient's voice in his own ear, autophony, is a quite common complaint. Tinnitus is sometimes present and may be a troublesome aftermath in cases involving barotrauma.

CLINICAL FEATURES. In the earliest stage with Eustachian obstruction the drumhead is indrawn or retracted (*see Plate X, 2*), and the short process of the malleus appears more prominent. With involvement of the tympanum, effusion is present and the appearances vary with the amount and character of the fluid. When the fluid does not fill the tympanum its upper margin may be seen as a hairline crossing the drumhead (*see Plate X, 3*); which has a yellow colour below the line, and a more normal

grey tinge above the line. Bubbles may also be visible through the drum-head, produced by the pressure of air in the fluid and may be seen immediately after inflation of the middle ear. Catheterization produces differing sounds on auscultation, being unduly loud in some cases and in others producing an interrupted gurgling sound. If catheterization results in complete diffusion of fluid the membrane assumes a more normal colour, but in the presence of a thickened drumhead these changes may not be seen. Detection of the condition may also be difficult when the tympanum is full of fluid. Then the membrane may have a darker colour than normal or a distinctly yellow tinge with a glistening appearance. In some cases the colour is bluish owing to the presence of blood in the effusion. The handle of the malleus is often sharply defined.

In cases where the drumhead has a full or slightly bulging appearance with dilatation of the vessels radiating from the malleus and showing as red wavy lines on its surface (see *Plate X, 4*), an intermediate stage between acute non-purulent and acute purulent otitis media has developed.

DIAGNOSIS. The diagnosis can generally be made on the otoscopic appearances particularly when a hairline or bubbles of air can be seen in the tympanum. Deafness of conductive type, shown by tuning fork tests and confirmed by audiometry, is present. The pneumatic speculum used to determine mobility of the drumhead may also demonstrate movement of the hairline and air bubbles when they are present. In uncomplicated cases successful inflation disperses fluid, equalizes pressure within the tympanum to atmospheric pressure and restores hearing.

PROGNOSIS. In recent cases and in those due to obstructive causes such as adenoids the prognosis is good provided that the causal condition is adequately treated. Recurrences lead to structural changes in the middle ear with a less favourable prognosis in regard to hearing.

TREATMENT. Drainage of fluid from the middle ear firstly by the natural route, the Eustachian tube, may be assisted by the use of decongestant nasal drops such as ephedrine hydrochloride 1 per cent in normal saline, by steam inhalations containing menthol and by the administration of an anti-histamine preparation especially where an allergic factor is present. During inhalations Valsalva's auto-inflation may be performed but successful inflation may require politzerization or Eustachian catheterization carried out daily. Failure of these measures with persisting deafness requires surgical treatment, which should result in the immediate return of normal hearing.

Myringotomy is preferred to needle aspiration because of the latter's frequent failure. The procedure is usually performed under general anaesthesia employing the operating microscope. A small stab incision in the antero-inferior quadrant of the membrane permits the entry of air into the middle ear and allows aspiration of the effusion. The myringotomy incision tends to heal rapidly so that an effort should be made to obtain total aspiration of fluid. In cases of persistent or recurring effusion myringotomy requires to be repeated and a small plastic tube, a grommet, is inserted. This provides further drainage and aeration of the middle ear. In most cases the grommet is self-extruded in a few weeks or months. If not, it may be removed either as an outpatient in adults or under anaesthesia in children.

Where the causal condition is in the nose, nasal sinuses or nasopharynx appropriate treatment should be applied early, adenoidectomy being done when myringotomy is performed.

ACUTE SUPPURATIVE OTITIS MEDIA

(*Acute Purulent Otitis Media*)

Acute inflammation of the middle ear cleft with pus formation is the result of invasion of the mucoperiosteal lining by pyogenic organisms.

AETIOLOGY. It is a common disease of childhood and it occurs frequently as a result of acute upper respiratory infections of viral origin in which there is secondary infection with pyogenic organisms. Certain other diseases with respiratory involvement such as measles, scarlet fever, mumps, whooping cough and diphtheria may be complicated by acute otitis media. The inhalation of infected water from swimming and diving during which infection reaches the Eustachian tube is sometimes the cause of otitis media. Inhalation or aspiration of food and other fluids may occur during vomiting and introduce infection. A nasopharyngeal pack inserted to control bleeding in a case of epistaxis, if left there too long, may initiate infection spreading along the tube to the middle ear.

The middle ear may also be infected via the external meatus when the drumhead is perforated. Invasion of the middle ear through the oval or round window may rarely follow suppuration in the inner ear and meninges, but blood-borne infection is uncommon.

BACTERIOLOGY. *Staph. aureus*, *Strep. haemolyticus* and *Strep. pneumoniae* are the most common organisms responsible for acute otitis media. Less commonly, *H. influenzae*, *Esch. coli*, *B. proteus* and *Ps. pyocyanea* are found and in many cases cultures are sterile as a result of antibiotic therapy.

SYMPTOMS. In the early stage of the infection pain is a variable symptom, the patient complaining more often of fullness in the ear, dullness of hearing with excessive loudness of their own voice in the affected ear and sometimes a high-pitched tinnitus. As the inflammatory reaction spreads from the Eustachian tube to involve the tympanic cavity resulting in increasing vascular dilatation and tension, pain becomes the most prominent symptom and deafness more pronounced. Earache is variously described as sharp, throbbing or lancinating. It is initially confined to the depths of the ear but later radiates over the affected side of the head and is intensified by any activity which increases intratympanic pressure. Sleep may be lost on account of the severity of the pain. 'Early' mastoid tenderness in the first few days of the illness is not of serious import, since it usually disappears after tension is relieved in the middle ear. Symptoms of a general nature may occur, especially in children, such as restlessness, fever, thirst and vomiting, before there is clear evidence of suppuration.

In the early stage of frank suppuration with production of pus tension within the middle ear reaches a peak at which the symptoms are most severe. Children may show a sharp rise in temperature to around 39 °C. There may also be symptoms suggestive of meningitis, e.g. vomiting and convulsions with positive Kernig and Babinski signs. In infants significant signs are persistent restlessness, rubbing the affected ear, boring into the pillow on the affected side and suddenly waking, screaming with pain. In adults the

presence of headache, especially frontal headache, may indicate intracranial invasion. Facial paralysis may occur in the suppurative stage if there is a dehiscence in the bony wall of the facial nerve canal.

CLINICAL FEATURES. In the early stage there is retraction of the drumhead and possibly an effusion which may not be visible because of slight thickening of the drumhead. The next stage of progressive hyperaemia shows injection of vessels along the long process of the malleus and the appearance of fine vessels between the umbo and the periphery, resembling the spokes of a wheel (*see Plate X, 4*). If the infection is arrested at this stage the tympanic membrane will return to normal. If the condition progresses, the hyperaemia becomes general and the membrane bulges (*see Plate X, 6*), at first in its posterior half; later the whole membrane becomes very red and convex and the handle of the malleus can no longer be seen. Perforation is now almost inevitable and is preceded by the appearance of a small yellow pulsating spot frequently in the posterior half of the membrane. Sometimes a nipple-shaped projection surmounted by a yellow spot develops on the membrane.

After rupture of the membrane there is a discharge of pus with relief of tension and a marked improvement in the patient's condition. Pain is relieved and sleep follows. Temperature becomes normal and resolution of the infection begins.

Accumulation of pus and desquamated epithelium may obscure the drumhead so that cleansing of the meatus by gentle syringing or mopping is necessary. At this stage the perforation may appear as a pulsating bead of pus which reappears after mopping.

PROGNOSIS. In the large majority of cases the prognosis is good as regards healing of the drumhead and the return of hearing provided that adequate treatment and supervision are maintained until resolution is complete. Discharge should cease within a few days and the drumhead should gradually assume a normal appearance. In some cases a small scar may be seen at the site of the previous perforation, in others there is no sign of the infection remaining. A persisting dry perforation is associated with some loss of hearing and further treatment will be required to obtain complete healing.

TREATMENT. This is directed locally to: (a) relief of pain, (b) the maintenance of the patency of the Eustachian tube, (c) neutralization of the infection and (d) restoration of normal hearing. In mild cases the patient should be confined to the house and, if a child, should be kept in bed. The diet should be light and the patient encouraged to drink freely.

Relief of pain is best achieved by the use of analgesics and the early administration of penicillin. For children paracetamol elixir paediatric in doses of 5-10 ml is preferable to the routine use of soluble aspirin. Intense pain may require the use of morphine in adults. The application of dry heat, e.g. a half-filled covered hot-water bottle or an electrically heated pad, may be useful.

The instillation of nasal decongestants, such as ephedrine hydrochloride nasal drops 0.5-1 per cent in normal saline, is indicated for the relief of tubal obstruction. Drops should be instilled into the nostril on the side of the affected ear with the patient recumbent, the head extended and rotated slightly to the affected side. The patient is encouraged to sniff gently, but forceful inflation of the tube should be discouraged. Medicated (menthol

and benzoin) steam inhalations are helpful in relieving viscid nasal secretion.

The finding of an inflamed drumhead is an indication for antibiotic therapy and the antibiotic of first choice, except in cases of known sensitivity, is penicillin which should initially be administered parenterally. The first dose should be of 1 million units of benzyl penicillin. Therapy may then be continued, if the initial response is favourable, by an oral penicillin, e.g. phenoxymethylpenicillin, giving 250 mg 4- or 6-hourly to the adult and 125 mg at the same intervals to the child.

The duration of treatment is important and should be judged by the clinical and, where there is aural discharge, bacteriological response. If the response is satisfactory treatment should be continued for not less than 5, and preferably 7, days. If there has been no clinical improvement after 48 hours on full penicillin dosage a change to a broad-spectrum antibiotic,




Fig. 167. Incision of the drumhead (myringotomy). The small figure shows the extent and direction of the incision.

e.g. ampicillin or the cephalosporins, in suitable dosage must be considered. These should be given for 7 days. Inadequate dosage or the too early withdrawal of an antibiotic increases the risk of persisting infection with the possible production of a masked mastoid infection.

In severe cases, where it is believed that perforation is imminent, *myringotomy* may be required (Fig. 167). The decision to operate is made on the appearance of the drumhead and the persistence of pain which robs the patient of a night's sleep. Another indication for myringotomy is a delayed resolution of the drumhead which remains congested and full in spite of adequate antibiotic therapy. The operation is performed under general anaesthesia, the incision being made in the most bulging part of the membrane. The membrane is thickened and the incision must be sufficiently deep to enter the middle ear cavity. Pus usually wells out, and a swab should be taken for bacteriological culture and sensitivity tests.

When the ear is discharging, either after a myringotomy or because the drumhead has perforated, dry mopping is required at frequent intervals in addition to the administration of the appropriate antibiotic as determined by sensitivity tests. Mopping is performed with sterile cotton-wool as frequently as appears necessary from the amount of the discharge. The discharge must be cleaned as thoroughly as possible, and this is best achieved by a trained nurse. Some surgeons advise gentle syringing with warm sterile saline solution to remove the discharge, and this may have to be repeated several times daily. Syringing or mopping is continued until the ear is dry. The use of drops is not likely to be helpful in the presence of copious discharge, and they should not be used until all the mucopus has been cleared. Hydrocortisone and neomycin drops are less likely than chloramphenicol drops to cause sensitization reactions. Should the discharge be sterile on culture, e.g. when myringotomy is performed because of a delayed response to antibiotics, boric acid ear drops may be sufficient.

In cases where copious discharge persists for a period of 4 weeks, where deafness becomes more progressively marked, and if the perforation is small, it may be advisable to drain the mastoid at a cortical operation. This is more urgently necessary if there is a diminution of discharge and a return of pain.

Systematic inflation of the Eustachian tube may be carried out, after the acute phase has passed, if the hearing does not rapidly improve.

It is important to ensure that the upper respiratory tract does not require treatment, especially if the discharge persists. Adenoids may have to be removed or sinuses washed out in such an event.

It is necessary to be certain that there is a complete resolution of an acute otitis media or the condition may become chronic. If the drumhead is intact and remains congested myringotomy is called for. If discharge persists in spite of energetic treatment radiography of the mastoid processes should be done to ensure that there is not a reservoir of infection in the cells, and if this is discovered the mastoid should be opened.

OTITIS MEDIA IN INFANTS

During the first 2 years of life aural suppuration is more frequent than at any subsequent age. Whilst infants may not often be affected by the common cold, which is a frequent cause of the disease in older children, there are other factors such as lack of immunity, the short, wide Eustachian tube, bottle feeding while lying in a cot or pram, vomiting or regurgitation and teething which predispose to middle ear infection. An otoscopic examination should be made in all cases in which an infant is feverish at night without any other obvious cause. The drumhead is thicker in infancy than later in life, so that there is less obvious bulging and less tendency to spontaneous rupture. The prognosis in acute otitis media is favourable, most infants showing no discharge and no deafness later in life. Failure of an infant to respond to antibiotic therapy given for an upper respiratory tract infection or gastro-enteritis should focus attention on the ears where changes in the tympanic membranes may call for myringotomy. A swab of the discharge must be taken at operation or from any mucopus in the ear so that appropriate antibiotic therapy can be started. Not infrequently the original

THE EAR

infection is of virus origin, and the pus may be sterile on culture. This occurs so often that it is wise not merely to make an incision for drainage purposes alone but to evacuate the mucopus and thick secretion from the middle ear by aspiration. This may well result in a complete cure. In other instances adenoids may have to be removed at an early age, especially if there have been repeated attacks of otitis media.

CHAPTER 58

CHRONIC NON-SUPPURATIVE OTITIS MEDIA

This condition is characterized by the chronic accumulation of non-purulent fluid in the middle ear cavity. It has been called exudative otitis media, secretory otitis media, seromucinous otitis media and, more simply, glue ear. These titles suggest that there is, as yet, no agreement as to the nature of the fluid, or of its cause, while glue ear avoids any theory regarding the aetiology and is merely descriptive of the high viscosity of the middle ear contents.

AETIOLOGY. There is no universally agreed cause. Popular belief holds that obstruction of the Eustachian tube results in absorption of air from the middle ear and mastoid cells. This results in a passive congestion of the lining mucosa. Doubt arises as to whether the fluid which is produced is a transudate or an exudate, and it is possible that each theory is correct, each resulting in a different type of fluid. The fact that the condition is commonly bilateral points to a central cause, and the fact that glue ear is most commonly found in children suggests that the central cause is adenoids. This, however, cannot be the whole explanation because a considerable proportion of cases occurs in children in whom either the adenoids have been previously removed or the adenoid pad found at operation is quite small. In an acute otitis media in a child with a pad of adenoids the mucopus in the middle ear eventually drains into the nasopharynx through the Eustachian tube. In glue ear the middle ear fluid, whether it be thin or thick, does not drain, and this implies a dysfunction of the tube. Further confirmation of this theory arises from the fact that inflation of the tube in glue ear appears to show that it is patent, and if it is patent and fluid does not drain through it, it cannot be functioning properly.

Allergy has been regarded as a cause, but the majority of patients show no other evidence of allergy, and eosinophils are rarely, if ever, found in the middle ear fluid. Inadequate or incorrect antibiotic therapy may be the cause. If, for example, a child develops a virus infection of the upper respiratory tract with involvement of the Eustachian tube and middle ear cavity, and if this is treated with antibiotics, no cure of the virus infection will occur. Secondary pyogenic organisms will not supervene, and thus no acute suppuration will take place in the middle ear. The fact that in the 1-3 years age group red bulging drumheads may persist in spite of antibiotic therapy, and that on myringotomy glue-like secretion may follow mucopus on aspiration gives some weight to this theory.

The condition is extremely common in children with a cleft palate. This might suggest that a chronic nasopharyngitis causes the middle ear condition, but it may be that during the surgical repair of the palate fracturing of the hamulus alters the function of the Eustachian tube.

Recently much work has been done on the theory that this condition may be included among the auto-immune diseases.

PATHOLOGY. The fluid is always sterile on culture, and has a relatively high protein content especially in serous fluid, while protein-bound carbohydrates are frequently present in higher concentration in fluid of a high viscosity. Cellular elements, macrophages, lymphocytes, polymorphs and plasma cells are found in varying proportions, but eosinophils are seldom identified. Culture for viruses has generally proved unrewarding. Biopsy of the middle ear mucosa demonstrates an increase of mucus-secreting cells, a decrease of serum-secreting cells and a degeneration of the ciliated epithelium.

SYMPTOMS. The prime, and often the only, symptom is deafness. This may not be noted by the parents, but may be recognized by the teacher in the nursery or primary school. It may only be discovered by the screening of children by the school audiometric service. If deafness is suspected by the parents it may be said to have dated from a specific upper respiratory tract infection, with or without earache. All too often parents attribute lack of hearing to inattention or preoccupation on the part of the child. Many parents will comment on the fact that the child turns up the volume of the television set. The ambient level of noise in many households is such that voices are raised, and the deafness of the affected child goes unnoticed.

CLINICAL FEATURES. The onset is generally gradual, and in very young children it may be unrecognized. In such children slow development of speech or defects in speech may be the cause of referral to hospital, and all such children should have an otological examination. Aspiration of middle ear glue may be all that is required.

The condition occurs most frequently in the 4-7 years age group, and is less common in older children. Examination of the ear may show the drumheads occluded by wax which is often crusted. When the membranes are seen there is no single diagnostic feature. The drumhead may be indrawn, sometimes slightly, sometimes acutely. On other occasions it may appear full posteriorly or postero-inferiorly. A long-standing case or a recurrent case may show retraction pockets either in the attic above the lateral process of the malleus, or posterosuperiorly below the posterior horizontal fold. In the latter instance there is a well-defined lower edge to the retraction, and this edge is concave upwards.

Various colours of the membrane may be noted. In a few cases the drumhead may appear nearly normal in colour but there are dilated surface vessels along the handle of the malleus and as a palisade in the lowest part of the membrane. A thin serous fluid may show as a yellow or amber-coloured drumhead, and the handle of the malleus appears chalky-white against the darker background. Most membranes are flushed rather than congested, and dilated vessels are seen to radiate on the surface. Should the middle ear fluid contain blood pigments the membrane will appear blue, varying from a slate colour to inky blue.

A characteristic finding, which is not easy to elicit in children, is that there is a loss of the normal drum movement when positive and negative pressures are applied by the pneumatic (Siegle's) speculum.

The condition is occasionally met with in adults or in the elderly, usually after a severe cold. It is more often unilateral. Otoscopy may show a fluid level with a concave meniscus (*see Plate X, 3*), or air bubbles

may be seen through the membrane. These findings are uncommon in children.

Audiometry shows a conductive deafness of some 40 dB over the range tested. The degree of deafness has some bearing in practice on the treatment advised in that a loss of less than 25 dB may respond to removal of adenoids alone, while a loss of 40 dB or more calls for evacuation of the fluid. Impedance audiometry gives a flattened curve with displacement to the side of negative pressure. Any coexisting high tone deafness found on audiometry must be noted, because recovery after treatment will be confined to the conductive element, and the child or elderly patient may still have hearing impairment from the perceptive loss.

Mastoid radiography will show haziness of the mastoid cells from lack of air entry, but there will be no breakdown of the intercellular walls unless the condition is of long standing.

TREATMENT. The aim of treatment is to restore the hearing and to prevent recurrence. A child whose symptoms have lasted for less than 6 weeks may respond to medical treatment. Nasal decongestion is achieved by nose drops of 1 per cent ephedrine hydrochloride in normal saline, or by giving a syrup containing triprolidine hydrochloride and pseudoephedrine (Actifed). It has been found that in such cases a month's course of sulphamethoxazole syrup (Gantanol) giving 5 ml once a day is effective in about 50 per cent of patients.

Children with clinical evidence of middle ear fluid who have a conductive deafness of less than 25 dB, and who suffer from symptoms suggestive of adenoid enlargement, may be cured by removal of the adenoids.

The majority of patients have had a hearing loss for months when they are first seen at hospital, and myringotomy and aspiration of the fluid are the treatment of choice. Under general anaesthesia and with the operating microscope wax and crusted material are removed. An incision is made in the postero-inferior quadrant of the membrane and powerful suction is applied. There may be considerable difficulty in aspirating all the tenacious glue which is contained, not only in the middle ear, but also in the mastoid antrum and cells. To facilitate this some surgeons make a second incision of the drumhead anteriorly so that air may enter and so reduce the vacuum. Others inject a mucolytic agent, such as chymotrypsin or urea, which liquefies the viscid fluid. Aspiration must be continued until no more fluid is obtained, or the chances of a recurrence are increased.

Some surgeons insert a small plastic tube, or grommet, through the incision as a routine, while others reserve this for recurrences. The grommet acts as a ventilating tube for the middle ear, and continues to function until its lumen is blocked or until it is extruded. The grommet may be retained for a few weeks or for over a year. It is momentarily painful to remove if still in place, and in children a short anaesthetic is advisable if it becomes necessary to remove it. Once the grommet has been extruded spontaneously it is easily removed from the meatus in the outpatient department.

After-treatment consists in allowing no water to enter the ear. If no grommet has been inserted the incision heals rapidly, but the parents are advised not to allow the ear to become wet for at least a fortnight, and swimming is forbidden for a month. If a grommet has been inserted these restrictions obtain until it has been extruded or removed and the drumhead has healed. Auto-inflation of the Eustachian tube is important, and the

most acceptable method of achieving this in children is to encourage them to chew gum.

Removal of the adenoids, and of tonsils if there are sufficient reasons for this, may be performed under the same anaesthetic as for the myringotomy. Some surgeons recommend this routinely while others only remove the adenoids if they are large, or if there is a history of earache.

PROGNOSIS. The immediate result of myringotomy and aspiration of the fluid is an improvement in hearing, often to normal on audiometry (Fig. 168). In some 70 per cent of cases this is permanent. Recurrences of fluid

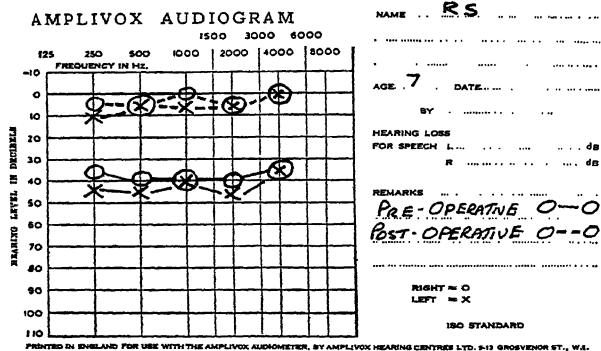


Fig. 168. Audiogram showing a return to normal hearing following myringotomy and aspiration of a 'glue' ear.

and deafness are found in about 20 per cent, and these are treated in the same manner. It is usual to insert a grommet on this occasion. A small percentage have further recurrences, and in them mastoid radiography may show cellular breakdown. On opening the mastoid considerable destruction of the cells is found with glue throughout, especially in the tip cells.

Long-term follow-up shows that tympanosclerosis is the most common complication, and there is evidence to suggest that the insertion of grommets may have a bearing on this. Much more serious is the development of atrophic areas in the tympanic membrane, particularly in the attic or the postero-superior regions. This leads to the formation of retraction pockets, and these form a potential source of cholesteatoma formation with its sequelae.

TYMPANOSCLEROSIS

In the past this has been known under various titles—chronic adhesive otitis media, chronic adhesive catarrh, chronic catarrhal otitis media, etc. In more than half of the cases in which this diagnosis has been made there has been a previous history, and often clinical evidence, of middle ear suppuration. In other cases the adhesive process has resulted from non-suppurative otitis media, possibly undiagnosed or inadequately treated. The latter aetiological factor has undoubtedly assumed greater importance as a result of premature cessation and inadequate dosage of antibiotics. The

suggestion that the condition is the end-result of deficient Eustachian tube ventilation in childhood implies that many cases result from chronic non-suppurative otitis media.

Fibrosis in the middle ear is the significant pathological feature, and fibrous adhesions have been found between drumhead and promontory and between ossicles and promontory. Fibrous tissue may fill the niches of the oval and round windows, and fibrous thickening of the tympanic membrane will be seen on otoscopy as an opaque and lustreless drum, often with white plaques (*Plate X, 16, 17*) on the surface—previously called chalk patches. The membrane is frequently indrawn so that the lateral process of the malleus is prominent, and the membrane may be so retracted that it is partly or wholly adherent to the medial wall of the middle ear cavity, and its mobility is thus impaired.

As a rule the only symptom is deafness, but tinnitus of a variable character and intensity is present in some cases. The deafness is of the conductive type, and may be stationary or progressive.

DIAGNOSIS. This can be made from abnormality of the tympanic membrane and the absence of the characteristics of otosclerosis with which the condition is sometimes confused. In a few cases the coexistence of both conditions cannot be excluded. Eustachian catheterization and inflation may reveal partial or complete obstruction, or a normal air entry which, however, because of the presence of adhesions and other middle ear changes, does not produce replacement of the drumhead.

PROGNOSIS. Restoration of normal hearing is unlikely except in a few early cases. The precept of prevention being better than cure is evident in this condition, and the results of sweep testing of schoolchildren with the detection of early deafness and its effective treatment are bearing fruit.

TREATMENT. In its early stage active steps must be taken to prevent progress of the condition. The removal of tonsils and adenoids, the treatment of sinus infection and the aspiration of middle ear secretions all contribute towards the prevention of the formation of fibrous tissue in the middle ear. The observation of all cases of acute otitis media until a cure results is a further preventive measure. Advanced cases of tympanosclerosis present a difficult problem and in many cases the only satisfactory treatment of the deafness is the provision of a hearing aid. Exploration of the middle ear cavity by tympanotomy will display the underlying pathology, and will determine the possibility of relieving the condition by removing the fibrous tissue and restoring mobility to the sound-conducting mechanism. Stapedectomy may succeed in some cases, but its successful outcome cannot be predicted. In older patients an associated or secondary perceptive deafness is a limiting factor.

CHAPTER 59

CHRONIC SUPPURATIVE OTITIS MEDIA

AETIOLOGY. Chronic suppuration of the middle ear results from infection of the mucosal lining of the middle ear cleft and in the vast majority of cases is preceded by an acute suppuration which has been untreated or inadequately treated. The expected decrease in incidence following the introduction of antibiotic therapy for acute infections has not been fully realized and it remains a common disorder in otological clinics. Sociologically it is more common in poorer sections of the population amongst whom hygienic, housing and dietetic factors may be contributory. In some cases of tubotympanic disease upper respiratory tract infection is an important cause of continued otorrhoea.

BACTERIOLOGY. Compared with the pyogenic organisms found in acute infections there is in chronic disease a substantial increase in Gram-negative organisms such as *B. proteus*, *Ps. pyocyanea* and *Esch. coli*. Invasion of the middle ear by these bacilli occurs by way of the external meatus and the perforation in the drumhead.

CLINICAL FEATURES. Chronic suppurative otitis media may be seen in varying stages, an active one where there is purulent discharge, an inactive one when there has been no discharge or evidence of infection for 6 months or longer and a quiescent stage of shorter duration occurring between periods of activity. A final stage of healed otitis media is present when all signs of activity have ceased and the perforation in the drumhead, which is the portal for reinfection, has healed.

The presence of discharge may obscure the tympanic membrane in which case the meatus should be cleared by gentle syringeing or by dry mopping to obtain a satisfactory view. The characteristics of the perforation must be noted. The site of the perforation is of particular importance in determining with other factors whether the ear infection is of a dangerous type or of a safe type. In the latter type the perforation will be situated in the central or anterior portions of the drumhead and is associated with disease in the tubotympanic area of the middle ear. Perforations in the attic region or extending to the posterior margin of the membrane are associated with disease in the attic and mastoid antrum signifying a dangerous or unsafe ear (see Plate X, 9-14).

In a number of cases the drumhead is hidden by an aural polypus in the external meatus. The polypus may originate from the margin of the membrane or from the promontory of the medial wall of the middle ear, its stalk passing through the perforation. Not infrequently the membrane is partially obscured by granulations protruding through an attic or posterior marginal perforation, these being more commonly associated with unsafe ears, whereas an aural polypus may be present in either type of disease.

The appearance of an accumulation of white epithelial debris also in association with attic or marginal perforations must suggest the presence of cholesteatoma which is very commonly present in the dangerous or unsafe ear.

SYMPTOMS. Chronic purulent discharge from the ear, perforation of the tympanic membrane and deafness are the principal symptoms and signs of chronic middle ear suppuration. Discharge may be profuse and mucopurulent, especially in cases in which the Eustachian tube and anterior part of the tympanum are affected (tubotympanic infection). The discharge is also usually odourless and the hearing impairment may be slight. On the other hand, in attico-antral disease (the unsafe ear) the discharge may be very scanty, perhaps represented by a small crust of dried pus on the posterior margin of the membrane or overlying the membrana flaccida. After removal of the crust a perforation is usually evident and the purulent discharge has a characteristic foetid smell. Impairment of hearing is more severe since destructive disease in the middle ear has caused an interruption of ossicular continuity, the loss exceeding 50 dB. Tinnitus is an occasional symptom, particularly in the older patient with a healed ear.

Pain is uncommon and should be regarded as a warning symptom denoting an acute exacerbation of infection and inadequate drainage from the middle ear. Other symptoms and signs such as headache, vertigo, sickness or rigors indicate a spread of infection beyond the confines of the middle ear.

DIAGNOSIS. Whilst the diagnosis of chronic suppurative otitis is readily made in the large majority of cases from the history of chronic otorrhoea, from the accompanying symptoms and signs, and from the appearances of the drumhead, it is important that the stage of the disease should be noted and every effort made to determine whether the ear belongs to the safe or unsafe category. Routine clinical examination requires to be supplemented by bacteriological studies, by audiometry, by mastoid radiography and in many cases by examination with the operating microscope with or without general anaesthesia.

TREATMENT. The aims of treatment are to render the ear safe by overcoming infection so that the ear is dry and inactive, to remove disease and prevent extension beyond the middle ear and to promote recovery of function. Whether treatment is medical or surgical depends upon the result of the clinical examination of the ear, the degree of activity of the infection, the situation of the disease, the nature of the discharge and the location and size of perforation. The presence of granulations, polypi and cholesteatoma prevent the effective application of local medical treatment.

Routine aural toilet is necessary for the success of medical measures in chronic middle ear suppuration. Cleanliness of the ear can be obtained by suction, by dry mopping or by gentle syringeing so that the prescribed topical application may come into contact with the diseased tissues. Further discharge may be aspirated using Siegle's pneumatic speculum and by Eustachian inflation. A high degree of cleanliness can be obtained using the technique of suction clearance with the operating microscope. When the ear is clean and no further discharge appears, drops are instilled or powder insufflated.

Whilst the parenteral administration of antibiotics has proved of little value in the treatment of chronic otitis media owing to the difficulty of obtaining a sufficient concentration and maintaining it in the diseased middle

ear, local applications are more useful. Sensitivity reactions may follow the topical use of antibiotics particularly penicillin and chloramphenicol, and the prolonged use of antibiotic ear drops may cause the development of resistant strains of organisms or the onset of a fungus infection. The use of antibiotics whether as drops or powder must be governed by bacteriological studies identifying the sensitivities of the infecting organisms. Hydrocortisone and neomycin ear drops may be prescribed initially and other antibiotics such as framycetin, gentamicin and polymyxin B are valuable against the mixed growths of Gram-negative organisms. Alternatively, other topical substances such as boric acid ear drops or spirit ear drops may be instilled. Drops should be instilled by filling the meatus with solution then applying intermittent pressure over the tragus so that the drops are encouraged to pass through the perforation into the middle ear. In cases in which there is a large perforation and scanty discharge treatment by insufflation of powder may be effective. Boric acid with or without the addition of 1 per cent iodine is often effective and the antibiotics previously mentioned may also be employed in powdered form. These medical or conservative measures are applicable in cases of tubotympanic disease where an active state may be made quiescent or inactive in many cases, but in others the ear may never become completely dry despite the removal of any focus of infection in the upper respiratory tract. When suppuration ceases, leaving a dry perforation, instructions should be given that water should not be allowed to enter the ear at any time. Swimming may only be permitted if the meatus is completely occluded by a suitable ear-plug and a bathing cap is worn. Diving and under-water swimming should be forbidden.

The hazard of reinfection persists as long as a perforation remains and closure is a further desirable step in treatment particularly as some improvement in hearing may follow. *Myringoplasty* is the operation employed for repairing a perforation from which there should have been no discharge for 6 months. The conditions necessary for the success of this operation are good cochlear function, a patent Eustachian tube and a healthy external meatus. Various operative techniques have been developed, the majority of operations employing a graft of temporalis fascia which is applied to the prepared surface of the drumhead and the adjacent bony meatal wall (*Fig. 176, A, p. 343*). Even if hearing is not materially improved, the presence of an intact membrane reduces the risk of reinfection and swimming, etc. may be more freely permitted.

When disease is located in the attic and mastoid antrum there is a greater risk of complications calling for active surgical treatment to place the ear in a safe condition. Granulation tissue protruding through a perforation may prevent drainage from the middle ear and should be destroyed by cauterization with a fused bead of silver nitrate or chromic acid. Large granulations may be removed by ring curette and cup forceps under general anaesthesia and magnification. An aural polypus may also obstruct drainage and is best removed with a wire snare under a general anaesthetic. If adequate drainage is established from the middle ear by these procedures medical treatment may overcome the infection and a dry ear result. Such ears, however, require prolonged observation and in the event of recurring bouts of otorrhoea more radical surgery is indicated. The presence of cholesteatoma is a clear indication for surgery to remove all diseased tissue from

the middle ear and this may take the form of tympanoplasty or radical mastoidectomy.

PROGNOSIS. Chronic tubotympanic infection may cause continuous or intermittent otorrhoea but is seldom a serious health hazard. It requires treatment of the upper respiratory tract rather than mastoid surgery. By intensive local conservative treatment and co-operation of the patient a majority may obtain a dry ear and in some a successful myringoplasty can be undertaken. A hard core of patients will continue to have intermittent aural discharge which with regular toilet of the ear can be an acceptable condition but they should be advised to report additional symptoms such as pain, headache or changes in the character of the discharge.

Chronic suppuration in the attic and antrum associated with attic and posterior marginal perforations of the drumhead constitutes a potentially serious condition for patients because of the risk of progressive bone destruction and the spread of the disease to intracranial structures.

Apart from danger to life attico-antral disease causes necrosis of the ossicles with a progressive and more severe hearing loss, and the purulent foetid discharge often makes patients seek advice. Persistent purulent discharge in this type of infection indicates an active destructive process requiring surgical treatment. Following radical mastoidectomy or its modified form a safe dry ear can be expected in 80 per cent of cases. Auditory function will depend upon the extent to which middle ear mechanisms can be retained or later reconstructed by tympanoplastic procedures. In many cases a staged programme is more satisfactory than attempting to eradicate disease and restore hearing at one operation.

In a small number of cases surgery produces a safe ear although discharge may persist from the mastoid segment of the cavity and this requires local medical treatment.

GRANULATIONS AND POLYPI

Granulations and polypi are frequently found in chronic suppuration and much more rarely in acute inflammation. Polypi arise from granulation tissue which is a poorly differentiated connective tissue. Polypi may grow from the promontory, the region adjacent to and around the orifice of the Eustachian tube or the tympanic ring. They may also originate in the attic spaces and the mastoid antrum. It may be possible, if an inspection of the drumhead is carried out, to determine from the position of the perforation the site of origin of the polypus. This information as to the origin of the polypus has a very important bearing on the chances of recurrence. It should be quite possible to remove a polypus originating from the promontory or the region of the Eustachian tube so that it will not recur, but those polypi which arise in the attic spaces and the mastoid antrum are almost bound to recur because of the great difficulty of access to their roots. One must expect a recurrence after removal of those polypi which grow from the tympanic ring because they are arising from caries of the bone in that site. The distinction between granulations and polypi is somewhat arbitrary.

Granulations are sessile red growths which bleed readily when touched (see *Plate X, 11 and 12*). Polypi vary greatly in size and appearance. They may be little larger than a pin's head or they may entirely fill the

meatus, and even project beyond it (*Plate IX, 2*). One or more may be seen and, unless they are very small, they are pear-shaped, being constricted where they pass through the tympanic membrane. They may be bright red, but if they are large and if they project from the outer opening of the meatus they are skin-coloured. The large polypi which are pale and oedematous usually arise from the tympanic ring, and their removal is free from the danger of setting up a labyrinthitis, while the red vascular polypi often arise from the promontory and labyrinthitis may follow their removal.

SYMPTOMS. Granulations and polypi frequently do not produce any symptoms apart from those due to the chronic otorrhoea to which they owe their origin, but in some cases there is a history of bleeding from the ear. Pain is not a common symptom and occurs only when secretions are dammed up due to blockage by the polypus. The amount of deafness varies greatly, and depends upon the size and position of the polypus and upon the destruction of the tympanic structures caused by the original infection.

DIAGNOSIS. This is usually made without difficulty after any discharge has been cleared away either by mopping or syringing. A granulation appears as a red sessile growth, situated on the medial wall of the middle ear, or appearing to fill a perforation of the drumhead, or to grow from the membrane or the posterior meatal wall adjacent to the drum. In the last situation it may be possible to detect carious bone through the granulations by means of a probe. A polypus is soft and mobile, and does not arise from the meatal wall but appears to protrude through the drumhead. The polypus is characteristically pear-shaped and has a long pedicle, and is pink or red in colour. Because granulations and polypi may arise from the labyrinthine wall cochlear and vestibular reactions should be tested before removal is undertaken. Differential diagnosis must be made from a glomus tumour (p. 382) if a polypus bleeds easily on manipulation. In this event a biopsy may be taken after preparations have been made to control profuse bleeding.

TREATMENT. The treatment of granulations and polypi must be combined with that of the chronic suppuration in the middle ear. When cochlear and vestibular tests indicate that the labyrinth is involved, no attempt at simple removal should be made. When there is very little granulation tissue present treatment may be confined to spirit drops after each syringing of the ear to remove discharge. Should this not destroy the granulations, they may be cauterized by the application of a silver nitrate stick or copper sulphate, or they may be removed by curettage. The simplest method of removing a polypus is by means of the aural snare via the meatus (*Fig. 169*). The snare is threaded over the polypus and carried medially as far as possible when the wire is tightened and the polypus removed. After-treatment consists of syringing the discharge and the use of spirit drops.

Polypi and granulations tend to recur after removal in the majority of cases, and such recurrence usually requires mastoid surgery to eradicate the underlying disease.

CHOLESTEATOMA

Other descriptive titles such as 'cholesteatosis', 'epidermosis', 'keratosis' and 'destructive ear disease' have been applied to this condition, which

occurs as two histological types, epidermoid cholesteatoma and cholesterol granuloma.

Epidermoid cholesteatoma consists of a matrix of keratinizing stratified squamous epithelial cells from which masses of squamous epithelial cells are cast off to form a smooth glistening cystic swelling initially occupying the attico-antral region. The contents of the swelling accumulate, and as cholesteatoma expands osteitis and bone absorption occur. It is unlikely

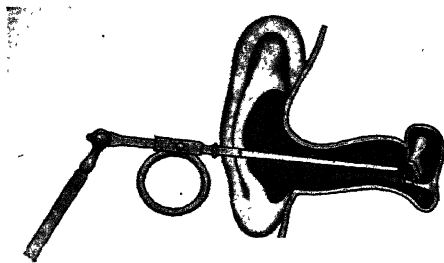


Fig. 169. Removal of aural polypus with the cold wire snare.

that pressure of cholesteatoma alone is sufficient to cause erosion of bone, but the exact process is not known. It is, however, a fact that the erosion exposes other vital structures, infection of which leads to intracranial complications.

Cholesterol granuloma is identified microscopically by the presence of cholesterin crystals surrounded by foreign body giant cells in fibrous granulation tissue. Blood pigments may be present and the dark coloured viscid secretion has been encountered in mastoid air cells, generally in children. There is often a discoloration of the tympanic membrane referred to as 'blue drum'.

PATHOLOGY. (i) *Congenital cholesteatoma* may arise from an embryonic rest in any of the bones of the skull. It may occur in the petrous bone as a primary epidermoid tumour and by its growth it will eventually break through to the middle ear cleft from which it becomes infected. It is not considered that the congenital origin is likely to be more than a very rare cause of attic cholesteatoma. (ii) *Acquired cholesteatoma*. A distinction is made between primary acquired cholesteatoma which arises in the attic or in the posterosuperior part of the middle ear without previous history of otitis media, and secondary acquired cholesteatoma occurring in ears which are or have been the seat of chronic infection of which there is clinical evidence.

Most otologists believe that ingrowth of epithelium from the external auditory meatus or the outer surface of the drumhead is the cause of acquired cholesteatoma. In the primary type the preliminary stage is characterized by indrawing or retraction of the membrane flaccida into the attic. The predisposing cause of the retraction is thought to be the negative pressure in the attic resulting from Eustachian tube dysfunction, non-suppurative otitis

THE EAR

media and impaired mastoid pneumatization. In this stage of 'pre-epidermosis' the retracted membrane forms a pouch or sac which becomes filled with desquamated epithelial cells. As the sac enlarges it becomes further invaginated into the attic to occupy the spaces of the tympanic cavity in which secondary infection leads to the stage of manifest disease.

Others are of the opinion that the cholesteatoma is produced by a metaplasia of the epithelium of the middle ear cleft as a result of chronic supuration. The theory of metaplasia is more acceptable in cases of prolonged irritation, i.e. in cases of the secondary acquired type. Acute necrotizing otitis media may be accompanied by severe loss of tissue of the drumhead. Healing may occur with migration of squamous epithelium into the middle ear from the external meatus, particularly when the perforation is marginal, or the flattened epithelium of the attico-antral area may undergo a metaplasia to squamous epithelium as a result of the infection.

Whereas primary acquired cholesteatoma may remain latent for a period of years, secondary acquired cholesteatoma is easily recognized by its characteristic foul-smelling discharge and the presence of white epithelial debris.

Cholesteatoma is treated by mastoid surgery, as this is the only means of eradicating the spread of the condition.

CHAPTER 60

ACUTE MASTOIDITIS

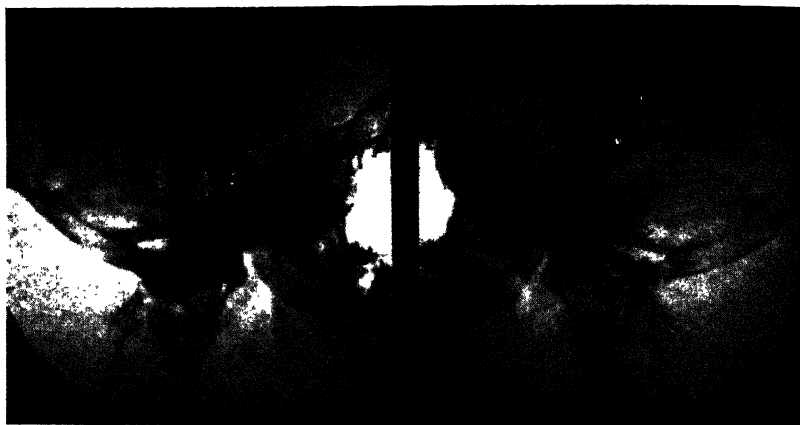In infancy, with the exception of the tympanic antrum and a layer of small cells in its lateral wall, the mastoid process contains no cells, the bone being diploeic. This acellular or infantile type of mastoid process persists throughout life in about 20 per cent of people. It may be converted to a compact acellular mastoid by the laying down of cancellous bone in the marrow spaces (*Fig. 170, B*). In normal circumstances the infantile mastoid process becomes pneumatized (*Fig. 170, A*), but between the acellular and pneumatic types there are intermediate stages. Controversy still exists as to which comes first, failure of pneumatization or infection, some otologists believing that failed pneumatization is the result of infection and not the precursor. Studies of the histopathology of acute mastoiditis have shown in some cases that during the process of healing the lumen of the air cell is filled with granulation tissue in which new bone is formed. There is then the possibility that an originally pneumatic process may become sclerotic, though such an occurrence is held by some to be rare.

Mastoiditis is a complication of otitis media in which infection spreads from the tympanic antrum to involve the bony walls of the cells of the mastoid process. The infection may be acute or chronic.

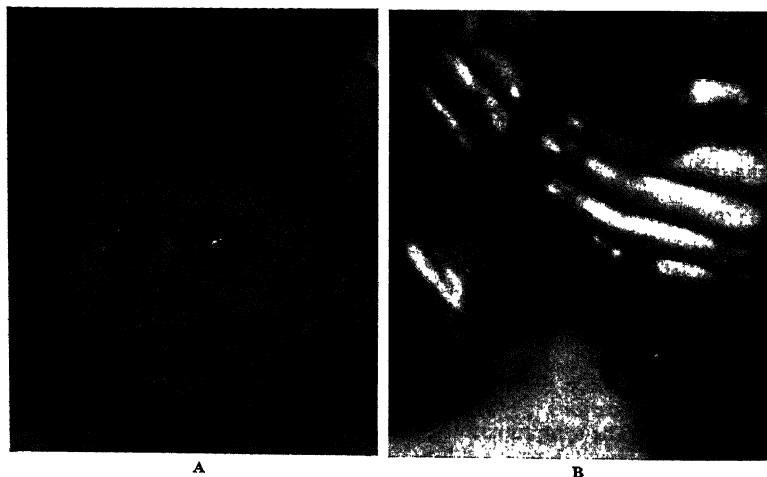
AETIOLOGY. Acute mastoiditis arises from an acute otitis media by extension of infection from the mastoid antrum to the air cells and occurs therefore in a cellular temporal bone. In many cases of acute otitis media infection, although present in the cellular system, produces no bone destruction but in severe acute infections there is a greater inflammatory reaction resulting in pus formation, increased tension, resorption of bone with loss of trabeculation and the formation of an empyema. Eventually the inflammatory process may erupt through the lateral surface to produce a subperiosteal abscess. An untreated abscess may spread in several directions: (1) Through the periosteum and skin covering the mastoid process. (2) Into the external meatus to simulate a discharging furuncle. (3) Through the medial aspect of the mastoid tip into the digastric fossa (Bezold's mastoiditis). (4) Through the posterior root of the zygoma beneath the temporal fascia (zygomatic mastoiditis) causing slight oedema of the upper eyelid as an early sign. (5) Through the canal for the mastoid emissary vein or through the temporo-occipital suture to form an abscess posterior to the mastoid process. (6) Beyond the confines of the middle ear cleft giving rise to intracranial complications.

SYMPTOMS. The symptomatology of the majority of cases of acute mastoiditis seen in hospital practice has been modified or obscured by previous unsuitable or inadequate antibiotic therapy. In acute otitis media pain behind the ear and tenderness over the area of the mastoid antrum are

commonly present but are relieved by successful antibiotic treatment. Increasing pain or the return of pain and increasing mastoid tenderness are therefore significant. Tenderness occurs not only over the mastoid antrum (Macewen's triangle) but may be elicited on pressure over the mastoid tip and posterior border. In an untreated case of mastoiditis discharge from the ear will usually have increased with extension of the disease but in a 'masked' case discharge may be absent and the perforation may have healed.



A B
Fig. 170. Mastoid radiographs. A, Cellular; B, Sclerotic.



A B
Fig. 171. Acute mastoiditis. A, Anterior and B, posterior views showing the swelling produced by a subperiosteal abscess.

Fever is not marked in adults but may be high in children, in whom a rising pulse rate is a potential danger signal. Deafness is present in most cases but varies in severity. Local signs vary with the stage and extent of the infection.

In the case of periostitis palpation over the mastoid area may reveal thickening of the periosteum on the affected side. Later there is oedema of the soft tissues with displacement of the auricle downwards and outwards and the erection of the auricle is seen more easily from behind the patient. If a subperiosteal abscess forms there is a fluctuant swelling behind the ear (*Fig. 171*). Narrowing of the external meatus due to sagging of the postero-superior meatal wall is a significant finding on otoscopy which may reveal a perforated drumhead with pulsating discharge or an intact one which has a thickened or full appearance. Patients generally look ill and feel off colour and disinterested. Those with pain and systemic disturbance are more anxious and aware of their illness.

DIAGNOSIS. In some cases difficulty may arise in distinguishing between mastoiditis and furunculosis of the posterior meatal wall with cellulitis (*see p. 304*). Considerable help in arriving at a diagnosis of mastoiditis may be obtained from radiography of the mastoids by comparing films of the affected and unaffected sides in different views of the temporal bone. Anatomical asymmetry of the mastoid process is found in 12 per cent of cases. The radiograph shows the type of mastoid process and the extent of cellular development (*Fig. 173, A*). In early cases of mastoid infection, slight blurring of the cellular outlines is present on the affected side and the outline of the bony plate of the lateral sinus becomes more prominent. Increasing opacity with pus formation is followed by loss of cellular outlines or trabeculation, by destruction of bone proceeding eventually to formation of an abscess cavity. The radiological appearances should at all stages be correlated with the clinical manifestations and follow-up radiography is often necessary.

Blood examination generally shows a polymorphonuclear leucocytosis and the erythrocyte sedimentation rate is increased except possibly in those patients who have had antibiotic treatment.

TREATMENT. The incidence of acute mastoiditis has been greatly reduced since the advent of antibiotic treatment particularly with penicillin. The majority of cases of acute suppurative otitis media now resolve by early and adequate treatment with parenteral penicillin combined if necessary with paracentesis. The presence of pus in the middle ear may be associated with increased tension requiring relief by surgical drainage otherwise some permanent loss in hearing may result.

When the clinical features of mastoiditis develop the patient should be confined to bed and antibiotic administration commenced. Until pus from the ear is available for bacteriological examination, penicillin should be given by intramuscular injection starting with 1 million units (benzyl penicillin) followed by 500 000 units 6-hourly. Lack of improvement in the patient's condition in 48 hours is an indication for a change of antibiotic or a cortical mastoidectomy.

The indications for the cortical mastoid operation, also known as Schwartz's operation, are: (1) Continued pain and mastoid tenderness for more than 2 or 3 days despite antibiotic therapy in full dosage and adequate drainage

by paracentesis. (2) Increasing constitutional signs, e.g. fever and rising pulse rate. (3) Copious pulsating discharge, rapidly refilling the meatus after mopping out. (4) Sagging of the meatal wall, increasing oedema over the mastoid process or zygoma. (5) Symptoms or signs of labyrinthine or intracranial complication. (6) Onset of facial paralysis. (7) Persistent suppurative otitis media for more than 2 weeks despite efficient treatment. (8) Progressive deafness.

MASKED MASTOIDITIS

This serious and treacherous condition associated with an unresolved or latent otitis media is the result of inadequate treatment with antibiotics. Failure to recognize the state of the infection and to apply vigorous treatment may result in the development of an intracranial complication such as meningitis or lateral sinus thrombosis. At the present time it occurs mostly after the administration of oral penicillin given for too short a period of time and, in some cases, in inadequate dosage, particularly at night-time.

DIAGNOSIS. Many cases are referred to hospital because of the persistence of pain, deafness, fever and discharge or because of the appearance of an intact unresolved reddish drumhead. Others are seen on account of recurrence of these symptoms after an apparent recovery. The persistence of deafness is an important symptom. There may be mastoid tenderness and headache with a slight rise in temperature. The drumhead is usually congested and full or thickened in appearance. Mastoid radiographs show opacity or haziness with, in some cases, loss of cellular outlines on the affected side.

TREATMENT. Admission to hospital for observation and adequate treatment is necessary. Resumption of full antibiotic therapy is justifiable in the absence of acute signs of mastoiditis, a watch being kept on the patient's general condition, temperature chart, tympanic membrane, mastoid process and hearing. In the absence of early signs of improvement and whenever some doubt exists a cortical mastoidectomy is indicated, effective drainage of the middle ear reducing the possibility of some permanent conductive deafness.

THE CORTICAL MASTOID OPERATION

The steps of this operation are shown in *Fig. 172*. Its aim is to remove all infected mastoid cells, and to this end each group of cells is systematically explored and cleared so as to leave an appearance as in *Fig. 173, B*. Particular attention is paid to removing the reservoir of infection that tends to accumulate in the tip cells, and to eradicate any spread of infection into the petrosal cells between the middle fossa dura mater and the lateral (sigmoid) sinus. The zygomatic cells are less frequently involved, but if there is clinical evidence of such an extension they are opened. If the plates of bone overlying the dura mater and lateral sinus appear healthy they are not opened to expose these structures, but unhealthy bone in these situations must be removed and the dura mater and sinus wall examined for extension of disease. A swab of pus will be taken routinely for culture and sensitivity

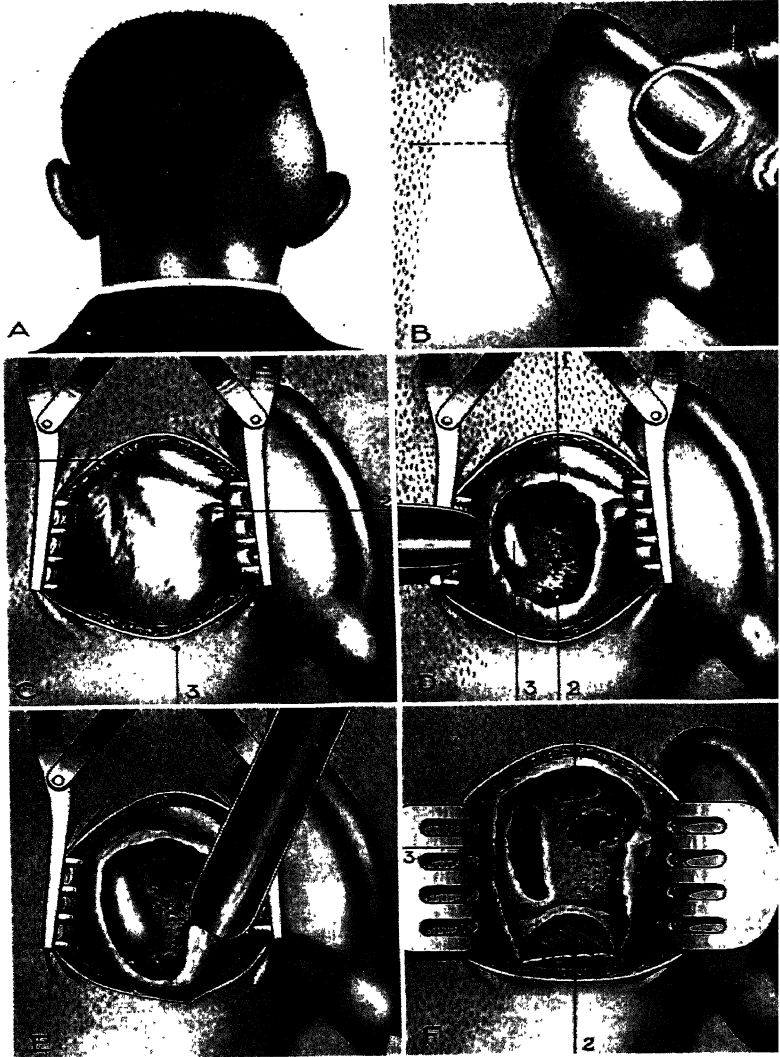


Fig. 172. Schwartz's operation for acute mastoiditis. A, Subperiosteal abscess over right mastoid. Line of incision. The dotted line indicates a second incision which may have to be made in cases in which the sinus is to be exposed; C, Area of operation exposed: 1, Posterior root of zygoma; 2, Supramastoid spine; 3, Tip of mastoid process. The area of operation lies within the triangle made by joining these three points. D, Mastoid antrum opened: 1, Mastoid antrum; 2, Air cells at the tip; 3, Sinus; E, The gouge is shown in the position for removal of bone to expose the sinus. E, Removal of the mastoid lip. F, The operation completed: 1, Dura of middle fossa exposed; 2, Posterior belly of digastric muscle exposed by removal of mastoid lip; 3, Exposure of sigmoid sinus.

tests, and any granulation tissue should be sent for histological examination. The wound is sutured, and a drain of ribbon gauze is left in the lower end of the incision.

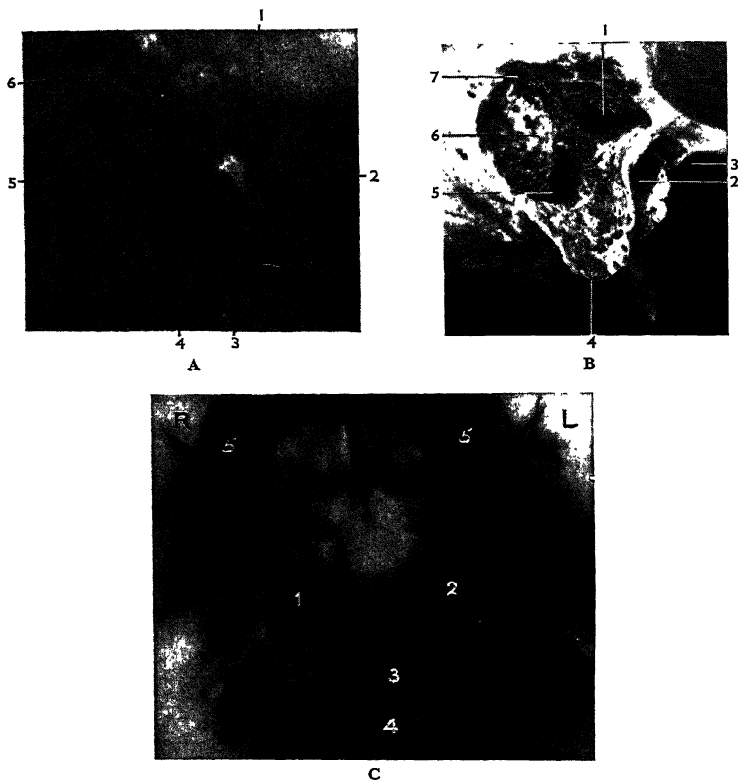


Fig. 173. Bone involvement in otitis media. **A.** Radiograph of right mastoid process showing extensive development of air cells: 1, Zygomatic cells; 2, Condyle of mandible; 3, External acoustic meatus; 4, Cells at tip of process; 5, Marginal cells (the clear area in front of this line indicates the position of the sigmoid sinus); 6, Posterior-superior or petrosal angle cells. **B.** Cortical mastoidectomy on dry temporal bone: 1, Antrum; 2, Glenoid fossa; 3, External acoustic meatus; 4, Cells at tip of process; 5, Sub-labyrinthine cells; 6, Bulging of sinus plate into operation cavity; 7, Posterior-superior or petrosal angle cells. **C.** Vertical radiograph of head of patient with acute inflammation of cells at apex of left petrous pyramid: 1, Normal cells of pyramid on right side; 2, Cloudy cells on left side; 3, Anterior arch of atlas; 4, Odontoid process of axis; 5, Mandible.

The stitches and the drain are removed under anaesthesia after a week, by which time it is expected that the wound will be healed, apart from the lower end, and the meatus will be dry. Further wound dressings are continued daily until complete union has taken place, and the patient is usually discharged from hospital 2 weeks after operation.

ACUTE MASTOIDITIS

Lack of healing or continued meatal discharge suggests that some infected cells may have been missed, or that spicules of infected bone have been left in the cavity, and in either case the wound may have to be re-opened. It may be that some contributing factor, such as infected adenoids, is still present, and in many instances the adenoids may be removed under the same anaesthetic as is used for the first dressing.

The Schwartze operation results in the cure of the discharge in 90 per cent of cases, and in the return of normal hearing in 70 per cent.

CHAPTER 61

CHRONIC MASTOIDITIS

Acute infections of the middle ear in the acellular type of mastoid process may resolve if the virulence is slight and drainage is free. In more severe infections the bony walls are involved with the formation of granulation tissue resulting in chronic suppuration. Spread of infection may also occur to the labyrinth or intracranially either at the time of the original infection or later. Most cases of chronic mastoiditis, however, arise as a complication of chronic suppurative otitis media of attico-antral type and may therefore be further complicated by the presence of cholesteatoma.

SYMPTOMS. Except in cases of acute exacerbation of infection pain is not a usual symptom but when present it is generally due to retention of discharge and this is regarded as a danger signal. Discharge is usually foul-smelling, abundant and creamy and persistent despite conservative treatment. The presence of granulation tissue which rapidly recurs after removal is very suggestive of bone infection and gentle probing may reveal the roughness of carious bone. Deafness of a conductive type is present, its severity depending upon the integrity or otherwise of the ossicular chain. A hearing loss exceeding 50 dB is regarded as indicative of interruption of the ossicular chain, found most often at the incudo-stapedial joint. Sometimes hearing loss is diminished by the continuity being maintained by part of a mass of cholesteatoma. Bulging of the meatal wall may occur from erosion of the bony wall by cholesteatoma and a discharging sinus may develop at this site. Facial paralysis may develop during the course of the disease.

TREATMENT. In cases of tubotympanic disease with an odourless mucopurulent discharge from an anterior or central perforation of the drumhead bone destruction is not a causative factor of persistent discharge. In these cases medical treatment should be continued in preference to mastoid surgery. Where the symptomatology points to attico-antral disease with bone involvement surgical treatment is necessary. The chief signs indicating a need for operation are: (1) A discharge which remains foul-smelling in spite of antibiotic and antiseptic treatment. (2) Granulations which recur rapidly after removal. (3) Mastoid abscess or a sinus into the external meatus or opening on to the surface. (4) Facial paralysis (Bell's palsy may develop concurrently with middle ear suppuration). (5) Cholesteatoma. (6) Meatal stenosis.

The objectives of surgery are the removal of all diseased tissue, mucosal and bony, from the middle ear cleft after which tympanoplastic procedures are employed in reconstruction of the sound conductive mechanism.

The operations performed to obtain these objectives are divided into two types: (a) Open techniques—the radical or modified radical mastoidectomy which provide good access for removal of all diseased parts but leave a

cavity liable to infection and requiring supervision. Additionally good functional results are difficult to achieve later by tympanoplasty. (b) Closed techniques—combined approach mastoidectomy avoids the formation of a cavity and provides better conditions for functional restoration but exposure of all disease is technically difficult and may on occasion be impossible. The recurrence rate of cholesteatoma is higher and less easily detected.

RADICAL MASTOIDECTOMY

The object of this operation is to remove chronic infection, especially cholesteatoma, from the mastoid cavity and middle ear, and, by creating a window in the posterior meatal wall, to allow of toilet of the cavity until healing takes place. The steps of the operation are shown in *Fig. 174*, and the incisions in the posterior meatal wall to create a flap of soft tissue to turn outwards and effect a window are illustrated in *Fig. 175*.

Once the mastoid cavity has been entered all cholesteatoma is meticulously removed because any that is overlooked will result in regrowth and a recurrence of symptoms. This entails dissection forwards through the mastoid antrum into the attic. Removal of the outer attic wall and the lateral wall (bridge) of the aditus exposes the attic and ossicles. Cholesteatoma and granulations are removed from this area, and necrosis of the ossicles may necessitate the removal of the incus and the amputation of the head of the malleus.

When the ossicles and tympanic membrane can safely be retained the operation is one of *modified radical mastoid*, but when the malleus, incus and drumhead are sacrificed the operation is called a *radical mastoidectomy*.

The plastic flap to create a window in the posterior meatal wall is fashioned in both these operations. The cavity is packed via the external meatus, and the incision is completely closed. The sutures and pack are removed 1 week later, and thereafter the cavity is dressed regularly until squamous epithelium grows into it from the meatal skin, and healing is complete. This takes an average of 2 months although the patient may be discharged from hospital in 2 or 3 weeks, and will attend as an outpatient. Healing occurs more quickly in an adult with an acellular cavity than in a child with a cellular mastoid cavity.

The aim of the operation is to make the ear safe in that cholesteatoma is not shut off from inspection via the meatus. Should it recur it may be removed at a *suction clearance* using an operating microscope, usually under anaesthesia although it may be done in the outpatient department in a suitable patient. The resulting hearing level depends upon whether the ossicles have been removed or not. Removal of the incus will cause a loss of at least 50 dB. Many patients are left with a moist ear, which disappoints them as it requires regular cleaning. Some of this catarrh is of Eustachian origin, but some is due to a low-grade infection in the cavity, and it may continue throughout

Transmeatal Operation. Many surgeons favour an incision through the external meatus rather than a postaural one. The operation is then conducted in the same manner. This approach is particularly useful in those patients who have a limited cholesteatoma in an acellular mastoid, but is less satisfactory in an extensive infection.

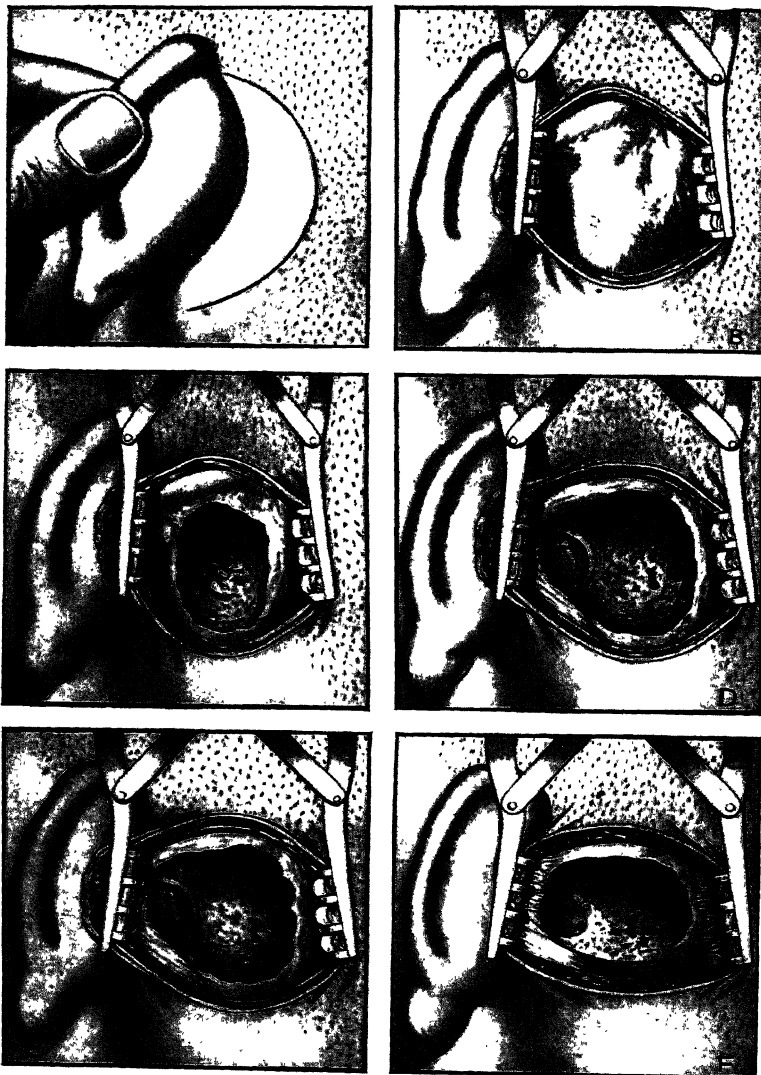


Fig. 174. Radical mastoid operation. A. Skin incision. B. Area of operation exposed. C. Mastoid antrum opened. D. Outer or lateral part of posterior bony meatal wall removed, but inner end, or bridge, remains. Drumhead is visible. E. Most of the bridge has now been removed, body of the incus and head of the malleus are revealed. F. Radical operation completed. Malleus and incus, with the stapes, promontory and facial spur lowered. Prominence of lateral canal, facial nerve, operation cavity.

Modifications of the Standard Operation. Dissatisfaction with the prolonged care of an open mastoid cavity which is exposed to the ravages from external sources such as washing, hair shampoo, swimming, meatal infection, etc. has led surgeons to explore means of avoiding this. One of the early methods was to fill the mastoid cavity with a muscle graft swung on a pedicle from the temporalis muscle. No meatal flap was cut. This was satisfactory only if every minute particle of disease had been removed, and it has largely been abandoned.

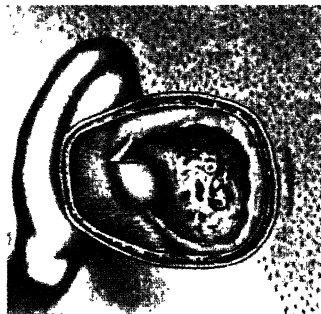


Fig. 175. Radical mastoid operation. Körner's meatal plastic. The sharp-pointed tenotomy knife has been passed through the external meatus and is making the upper cut of the tongue-shaped flap. The lower cut is indicated by dotted lines.

More recently the *combined approach technique* has been evolved. At this operation, performed under the operating microscope, the middle ear is entered, after mastoid disease has been eradicated, through the bony posterior meatus instead of removing the outer attic wall and the bridge over the aditus. The posterior meatal wall is left intact and no flap is cut. The operation is a lengthy one and the facial nerve is at greater risk. Visualization of all parts of the middle ear cavity may not readily be made, especially by those who have not performed many operations by this technique. Cholesteatoma may not be completely removed around the ossicles, and it will recur. Such recurrence is more difficult to detect in its early stage than if the mastoid cavity is fully exposed to view through the window, and thus is not easily removed without converting the operation to a standard radical type.

CHAPTER 62

TYMPANOPLASTY

The techniques of tympanoplasty are concerned with the restoration of hearing by reconstruction of the sound-conducting mechanism damaged in whole or part by middle ear disease or as the result of surgery essential for the elimination of chronic infection. The introduction of antibiotics and the operating microscope have contributed greatly to the development of these operations.

The basic requirements for successful results are: (1) Control of infection. (2) The presence of good cochlear function. (3) Patency of the Eustachian tube. (4) Mobility of the oval and round window membranes.

The normal transmission of sound waves to the fluid of the inner ear is dependent not only upon mobility of the membranes of the oval and round windows, but also upon a greater proportion of sound energy being transmitted via the tympanic membrane, the chain of ossicles and the oval window (the sound-pressure transformer mechanism), than that which reaches the round window across the air in the tympanum. The baffle mechanism (sound protection) is provided by the intact tympanic membrane which ensures that sound waves reach the two windows in different phases. In addition, the sound pressure effect is increased by the hydraulic and lever actions of the tympanic membrane and ossicular chain on the oval window. The changes in the drumhead, ossicular chain and window regions which result from disease may cause not only a reduction in the total amount of sound energy transmitted to the oval window, but also a reduction in the difference of the amount of sound reaching the two windows. Theoretically, if sound reaches the two windows with equal energy and at the same time, perilymph being non-compressible, neither window membrane will move and no disturbance of perilymph or basilar membrane will occur. In practice, however, a slight difference in impedance and a certain amount of bone conduction provide retention of some hearing. The objective of tympanoplasty is therefore the preservation or recreation of the disproportionate conductivity of the two fenestrae.

Techniques in tympanoplasty have developed rapidly in the past 25 years. There has been a wide diversity of tissues used for reconstruction in myringoplasty and ossiculoplasty. Autograft temporalis fascia is widely used in the repair of perforations while for simpler types of ossicular discontinuity the patient's own incus can be remodelled and repositioned. The use of homograft materials has increased steadily and is preferable to the use of inert substances.

Considering the principles already described, the procedures used in reconstruction vary according to the deficiency of the sound transmission mechanism of which five types have been described:

1. Myringoplasty (*Fig. 176, A*).

2. Attico-antrostomy is indicated where the ossicular chain is intact but where a marginal or attic perforation, granulations or cholesteatoma indicate underlying bony disease which must first be completely removed. Reconstruction may require use of fascia only or fascia plus homologous incus or cartilage if the ossicular chain has been interrupted by excision of diseased tissues (*Fig. 176, B*).

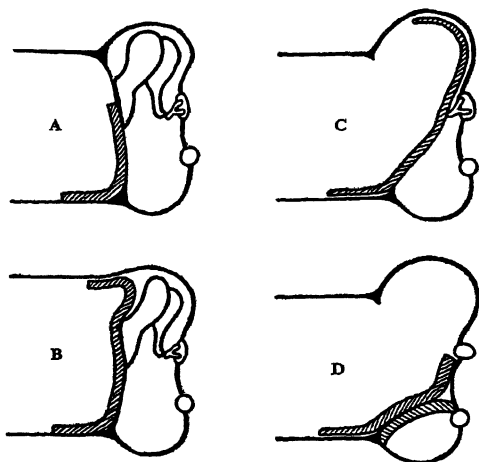


Fig. 176. Tympanoplasty. A, Myringoplasty; B, Attico-antrostomy with application of graft; C, Columella type of tympanoplasty; D, Total tympanoplasty (baffle effect).

3. A type three repair is possible where there is an intact mobile stapes. After removing all bony disease the graft is applied from the remnants of the drumhead or adjacent meatal wall to the facial ridge and inner attic wall, thus reconstituting a middle ear cavity. The graft is in direct contact with the head of the stapes so that a columella type of conduction is obtained (*Fig. 176, C*).

4. Type four tympanoplasty is indicated when the ossicular chain is disrupted and the only remaining part of the stapes is a freely mobile footplate. A columella type reconstruction may be obtained by a homologous T-shaped cartilaginous graft from fascia to footplate or else the oval window is left exposed in the cavity while a baffle is constructed which provides sound protection for the round window. This is achieved by forming a pouch between the Eustachian tube and the round window, the pouch being covered with a fascial graft (*Fig. 176, D*).

5. When free mobility of the stapes is unobtainable on account of tympanosclerosis, excision of chronic disease may be followed at a second operation by fenestration of the lateral semicircular canal, a type five tympanoplasty. Such a procedure presupposes good cochlear function.

CHAPTER 63

FACIAL PARALYSIS

Facial paralysis may be due to a lesion of the nerve: (i) within the cranial cavity, (ii) in its passage through the temporal bone and (iii) after its exit from the stylomastoid foramen.

Various tests have been devised in order to ascertain the state of the muscles supplied by the facial nerve. Some give very accurate and valuable information about the stages of degeneration which the nerve and muscles may have undergone, and indicate the reparative processes in regeneration. The faradic and galvanic tests are of limited value owing to the difficulties in accurate measurement of the strength of the electrical stimulus in faradism and the duration of the stimulus in galvanism. When the latter test is employed the reaction of degeneration (RD) takes 10–14 days to appear following the actual nerve lesion. If there is complete absence of response to galvanism nerve surgery is useless owing to the advanced atrophic changes in the muscular tissue.

The conductivity test is a quantitative test of nerve excitability and is applicable to lesions proximal to the point of stimulation which is at the stylomastoid foramen. It consists of a comparison of the threshold intensities, on the normal and abnormal sides, required to stimulate the nerve when the electrode is applied below the ear and an electrical pulse of 1 msec is passed. The findings may indicate no degeneration, partial degeneration or complete degeneration. The test is of value 3–4 days after the onset of paralysis, and gives a high rate of accuracy in the prognosis of the palsy.

Another test, interpreted by strength–duration (SD) or intensity curve (IT), is recorded by means of a special instrument which gives an output of known strength and duration and is of importance. The technique is specialized, and the intensity threshold is charted and the state of each individual muscle must be ascertained (*Fig. 177*).

Electromyography. This depends upon the presence or absence of contraction in the muscle fibres when stimulated. With a needle electrode inserted directly into the muscle, contraction of a functioning muscle will produce action currents on stimulation, and these may be recorded by amplification and the sound interpreted by a skilled technician. Fibrillation of the muscle fibres may develop in 2 or 3 weeks' time following severe trauma of the nerve, and this suggests a poor prognosis. The outlook is more favourable if there is the occasional appearance of normal motor potentials. Electromyography records any improvement or recommencement of muscle function before any clinical sign is apparent. Polyphasic potentials are found a week or two before clinical evidence of returning movement is detectable, and should be looked for after 10–12 weeks of complete paralysis as their presence

indicates that nerve continuity exists, and that some regeneration of fibres will take place.

BELL'S PALSY

There are various theories as to the causation of this condition. Some authorities believe that it is due to a primary ischaemic paresis of vascular origin which is most marked at the stylomastoid foramen. The nerve suffers

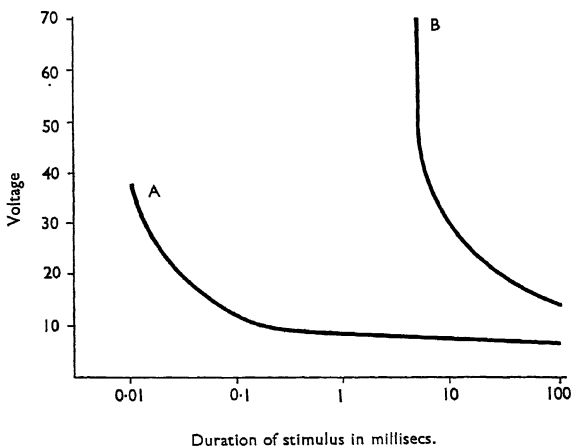


Fig. 177. Strength-duration curves. A, Normally innervated muscle; B, Denervated muscle.

from malnutrition due to its greatly diminished blood supply, and ischaemic paralysis results. Further, this arterial block produces a capillary dilatation and an increase in permeability so that a secondary oedema of the nerve results with its consequent compression in the bony canal. The condition is always unilateral, and there may be a history of exposure to cold or draught on the affected side.

PROGNOSIS. This depends upon the presence or absence of degeneration.

Ⓜ The large majority of cases recover spontaneously or with conservative treatment, but the degree and duration of the palsy are of importance in determining the outcome. If the paralysis is complete and has been present for 2 months some residual loss of movement may occur. Loss of electrical conductivity in a case of complete paralysis persisting for 4 weeks after the onset is unlikely to be followed by complete recovery of function.

TREATMENT. In a relatively large proportion of patients complete recovery occurs spontaneously, and treatment is not required in the majority of patients. This group includes those with an incomplete paralysis of whom 85 per cent regain full function and 15 per cent have a partial recovery of function. Patients should be observed daily for 7-10 days for signs of deterioration as indicated by reduction or loss of nerve conductivity. Physiotherapy in the form of massage of the muscles on the affected side may help to maintain tone. In cases where recovery may be prolonged the oral muscles

may be supported and prevented from stretching by a small plastic hook cemented to the upper teeth. Active facial exercises are only of value during the stage of recovery. In all patients suffering from facial paralysis an explanation of the nature of the illness must be given at the outset, and regular attendance at the clinic is necessary to evaluate progress and to maintain morale.

Medical treatment may be limited to patients with a complete paralysis, of whom a number, less than 50 per cent, would recover spontaneously. Where complete paralysis is associated with severe pain, or if there is an electrogustometric threshold (p. 347) difference of $100\ \mu\text{A}$ or more between the two sides of the tongue treatment is clearly indicated. Stapedius paralysis also indicates a more complete loss of function, and calls for treatment. Unless special contra-indications are present the administration of oral prednisolone should be given as soon as possible after the onset of the palsy. It is given in a dose of 20 mg four times daily for 5 days and then reduced by 20 mg each day thereafter. This treatment has replaced the administration of ACTH and other methods of inducing vasodilatation. Surgical decompression of the facial nerve is not now recommended in the treatment of Bell's palsy.

FACIAL PARALYSIS COMPLICATING OTITIS MEDIA

Facial paralysis is especially liable to occur in tuberculous infection and malignant disease of the middle ear. It is not a common complication of suppurative otitis media, but it may follow acute or chronic infections. It may be due to a congenital dehiscence of the bony wall of the facial canal, or may result from erosion of the wall by cholesteatoma. Facial paralysis may appear after mastoid surgery, and be due to section of the nerve or to compression of the nerve by haemorrhage or oedema, or by an inward fracture of the bony wall of the canal. If a paralysis of the nerve is observed immediately after the patient regains consciousness following surgery the condition is serious, and the wound should be explored so that repair may be effected. The nerve supplies the dilator muscle of the ala nasi, and this may reveal its involvement. If the paralysis does not appear until 2 or 3 days after operation a gradual return of function may be expected.

SURGICAL TREATMENT. When facial paralysis occurs in the course of chronic suppuration radical mastoid surgery is indicated and is frequently followed by a return of function once the granulations and cholesteatoma surrounding the nerve have been removed. Facial paralysis due to operative trauma is usually an indication for the early re-exploration of the cavity. If electrical tests do not show muscle degeneration nerve surgery may be delayed for a month or more. There are four policies in surgery:

1. The mastoid is opened, the nerve decompressed or the cut ends placed in apposition.

2. A nerve graft may be employed. Autoplastic nerve graft, using the lateral cutaneous nerve of the thigh, is inserted after the nerve sheath has been opened and the damaged nerve ends have been excised. The inlay graft is longer than the gap to be bridged, and it is held in place by fibrinogen or human thrombin. Some recovery of function may be expected in 6-8 weeks, although full recovery may take 6-9 months or even longer.

3. If severe muscle atrophy has occurred muscle grafts or strips of fascia lata may be employed as a sling to elevate the sagging corner of the mouth. This is usually carried out by the plastic surgeon.
4. The facial nerve may be re-routed with an end-to-end anastomosis.

FACIAL PARALYSIS IN SKULL FRACTURES

The facial nerve is more commonly injured in fractures of the skull than any other cranial nerve except the olfactory nerve. It may be damaged in fractures of the base of the skull either at the internal auditory meatus or in its canal. Diagnosis of the exact site is always difficult. The paresis may be immediate or delayed, and may be complete or partial in either event. Immediate paralysis is due to laceration or bruising of the nerve with intraneural haemorrhage. Delayed paralysis follows pressure on the nerve from bleeding inside its canal, and, whether partial or complete, it usually clears up completely and rapidly. Immediate paralysis is less certain of recovery on account of degeneration. There may be slow, but often incomplete, return of function, and the prognosis is worse if infection of the middle ear occurs during healing. Treatment is primarily concerned with care of the facial muscles, and operative interference is not justified within 6 months after the onset. The progress is assessed by the electrical tests, and the site of the injury is located by hearing and vestibular tests and topognostic facial nerve investigations.

Schirmer's blotting paper test, a quantitative method for measuring lacrimation, is sometimes of value in determining damage situated proximal to the geniculate ganglion and the greater superficial petrosal nerve. Loss of taste in the anterior two-thirds of the tongue in a lower motor neuron paralysis is suggestive of damage proximal to the chorda tympani nerve. Impairment of taste may be mentioned by the patient or may be detected by testing and comparing sensation on both sides of the anterior two-thirds of the tongue, using salt and sugar. *Electrogustometry* can be used to assess progress as studies have shown that recovery of taste within the first 10 days is a good indication of eventual complete recovery. The anterior part of the tongue is stimulated electrically on each side to determine the smallest direct current in microamps which will evoke a distinct acidic or metallic taste. When a definite increase of threshold is found in the affected side a lesion involving the chorda tympani or more central fibres within the facial nerve may be deduced. A difference in threshold between the two sides suggests that denervation is likely to occur.

Involvement of the nerve to the stapedius tendon may be determined by measurement of acoustic impedance. If the evidence points to damage within the facial nerve canal it should be explored. If the lesion is in the internal acoustic meatus, facio-hypoglossal anastomosis may be indicated, and possibly some subsequent plastic procedure. In many lesions direct repair of the defect may be possible.

CHAPTER 64

LOCAL SPREAD OF MASTOID INFECTIONS

PETROSITIS

This may occur in an acute or chronic form in a pneumatized or diploeic petrous bone, and is due to direct extension of infection from the middle ear or mastoid. It may occur before operation or as a postoperative complication, usually 2 or 3 weeks, but occasionally several months, later.

PATHOLOGY. The pathology is essentially that of the mastoid infection which precedes it. Infection may be confined to the petrous bone, or it may extend intracranially and result in a localized meningitis or an extradural abscess in the middle or posterior fossa. Spread may also occur downwards and cause abscess formation in the pharynx. Occasionally a spontaneous drainage through the middle ear may result in recovery.

CLINICAL FEATURES. There is severe unilateral headache, spasmodic in type and usually retro-orbital, supra-orbital or temporal in distribution, due to irritation of the related nerves. In the presence of otitis media, such headache with diplopia due to paralysis of the abducens nerve (Gradenigo's syndrome) is almost diagnostic of the condition. A slight rise of temperature may accompany the onset of the headache. Following mastoidectomy a sudden recurrence or increase of discharge, often with pulsation, suggests a petrositis. Other transient features may occur, such as facial palsy and vertigo with vestibular nystagmus due to labyrinthine irritation. Lumbar puncture should be performed. The cerebrospinal fluid may be under slightly increased pressure, but is otherwise normal. Any departure from normality, such as a slight increase in cells, is an indication for early surgical exploration. Disappearance of symptoms may indicate resolution, but if this is of sudden onset it may signify intracranial rupture and the development of meningitis or extradural abscess.

DIAGNOSIS. Diagnosis is made from: (i) persistent otorrhoea following cortical mastoidectomy; (ii) positive findings on radiography of the petrous bones (*Fig. 173, C, p. 336*); and (iii) the discovery of a fistulous track leading to the petrous apex on revision of the operation.

TREATMENT. In the early acute stages treatment is that of the associated otitis media and mastoiditis, and includes vigorous antibiotic therapy with the appropriate drug after sensitivity tests have been carried out. The pain may be sufficiently severe to require morphine. As a rule mastoidectomy is indicated and a search must be made for the presence of a fistula leading to the petrosal apex, and, when found, it must be curetted to facilitate drainage. When the condition is chronic, or when it becomes manifest after the failure to obtain a cure with a simple cortical mastoid operation, the radical type of operation may be required.

LOCAL SPREAD OF MASTOID INFECTIONS

PHARYNGEAL ABSCESS

Pharyngeal abscess may develop secondary to otitis media in two ways: (i) directly from the tympanic and tubal air cells in which case the infection passes along the inferior surface of the petrous bone in close relation to the Eustachian tube, or (ii) indirectly from air cells situated more deeply in the mastoid process, or from an extradural abscess in the posterior cranial fossa when the pus forms in the suboccipital region deep to the digastric muscle.

In pharyngeal abscess of otitic origin the patient complains of pain or difficulty in mastication and swallowing, or of toothache, or of pain in the parotid region. Speech may become 'thick'. Redness and swelling will be seen in the lateral wall of the pharynx or the peritonsillar region. The abscess usually resolves following antibiotic therapy with the appropriate drug, but if the condition should be tuberculous external drainage of the abscess may be required.

CHAPTER 65

LABYRINTHITIS

Labyrinthine and intracranial complications have become rare, not only because of the widespread use of antibiotics but also because both acute and chronic otitis media are in most cases adequately treated. Nevertheless these are dangerous complications which, if not recognized or if neglected, can lead to a fatal outcome. The importance of the early recognition and treatment of labyrinthine and intracranial complications of middle ear suppuration can hardly be stressed enough.

ROUTES OF INFECTION. From the middle ear and tympanic antrum infection may spread in the following directions:

1. Medially to the labyrinth either through the oval or round windows or by erosion of the lateral semicircular canal. In rare cases the promontory may be eroded, especially in tuberculous disease.

2. Upwards towards the middle cranial fossa resulting in extradural abscess or in abscess of the temporal lobe; purulent meningitis is a very rare complication from spread of infection by this route.

3. Backwards towards the posterior cranial fossa producing (a) an extradural abscess between the sigmoid sinus and its bony wall or an abscess medial to the sinus, i.e. between the posterior surface of the petrous bone and the cerebellar dura mater; (b) septic thrombosis of the sigmoid sinus; (c) purulent meningitis beginning in the posterior cranial fossa; (d) cerebellar abscess.

4. Downwards through the floor of the tympanum producing septic thrombosis of the bulb of the internal jugular vein. In rare cases downward spread of infection may lead to abscess formation below the petrous bone resulting in retropharyngeal abscess.

PATHOLOGY. From the point of view of pathology labyrinthitis may be circumscribed or diffuse. The *circumscribed* form may affect the bony capsule alone or it may invade the perilymph space, and it is almost invariably due to cholesteatoma which has eroded the bony prominence of the horizontal (lateral) semicircular canal in the aditus. *Diffuse* labyrinthitis may be an extension of the circumscribed type, but it more frequently follows invasion through the oval and round windows, especially the former. It may involve the peri- and endolymphatic spaces, and there may also be infection of the bony capsule.

Labyrinthitis may follow an acute otitis media, tuberculous otitis media or chronic otitis media with cholesteatoma; it may be caused by a fracture of the base of the skull; or it may be due to direct injury with a pointed object such as a knitting needle or to unfortunate attempts at removal of a foreign body from the external meatus. While most cases of labyrinthitis follow otitis media some may be associated with meningitis.

Serous labyrinthitis may result from oedema during an acute otitis media or following radical mastoid surgery. Infection reaches the labyrinth from the middle ear via the oval or round windows or through a fistula of a semi-circular canal or of the promontory. The usual cause of such fistula is erosion of the bony wall by cholesteatoma to expose the endosteal lining to infection (*Fig. 178*). If air pressure in the external meatus is artificially

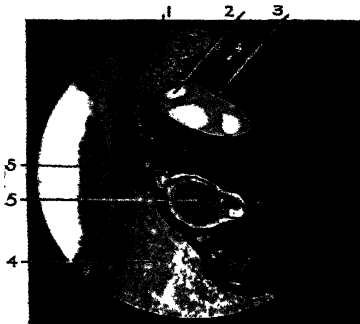


Fig. 178. Chronic middle ear suppuration and cholesteatoma. Note erosion of bony prominence of lateral canal. 1, Erosion of bone over prominence of lateral canal (so-called 'fistula'); 2, Endolymph space of canal; 3, Perilymph space, largely filled up by new connective tissue; 4, Granulation tissue on inner wall of tympanum below; 5, Facial nerve; 6, Cholesteatoma lining aditus and antrum.



Fig. 179. From a case of acute purulent otitis media followed by purulent labyrinthitis and meningitis without rupture of the tympanic membrane. 1, Swollen, engorged and infiltrated mucosa of tympanum; 2, Pus in tympanic cavity; 3, Footplate of stapes; 4, Anterior crus of stapes—note that pus is entering the vestibule between the stapes and the margins of the oval window; 5, Pus in internal meatus; 6, Sacculle; 7, Pus in vestibule; 8, Haemorrhage and pus; 9, Utricle.

increased, this is communicated through the tympanic perforation and the fistula to the labyrinthine fluid and so to the crista of the lateral (horizontal) canal. Giddiness and nystagmus are thus produced (fistula sign). Hearing loss is not greatly aggravated in serous labyrinthitis and recovery is usual.

Purulent labyrinthitis implies a continuation of the inflammatory process so that the serofibrinous exudate in the labyrinth becomes purulent (*Fig. 179*). There is severe giddiness, vomiting and loss of balance with the sensation of external objects rotating. Deafness is complete, but there is not much tinnitus. If untreated, or if treatment is delayed, the membranous labyrinth may be destroyed within a few days. The condition passes into a latent phase during which granulations, connective tissue and finally new bone form within the labyrinth (*Fig. 180*). This produces a spontaneous cure as far as vertigo is concerned but hearing never returns. Labyrinthitis may lead to meningitis as a result of spread either along the cochlear aqueduct

or along the sheath of the cochlear nerve. Spread to the posterior fossa may result in a cerebellar abscess.

CLINICAL FEATURES. During the stage of fistula formation there are attacks of dizziness and occasional vomiting, especially on stooping or turning quickly. Spontaneous nystagmus may or may not be present and, if elicited, may be to either side. The patient tends to fall to the healthy side. On examination of the ear cholesteatoma is usually seen and a fistula sign is



Fig. 180. Vertical coronal section through vestibule in case of chronic middle ear suppuration, with obliteration of tympanic cavity. The labyrinth was infected through the lateral canal. The pathological condition is one of latent labyrinthitis. 1, Vestibule filled with granulation and fibrous tissue; 2, Facial nerve partially surrounded by connective tissue—the bony wall of the facial canal has been eroded; 3, Cystic space in attic; 4, Caries of promontory; 5, Perforation of drumhead; 6, Tympanic cavity almost obliterated by new connective-tissue formation; 7, Round window membrane incorporated in new connective tissue; 8, Jugular bulb; 9, Footplate of stapes.

present. Hearing is reduced, although not severely, and the caloric reaction is diminished.

In serous labyrinthitis there may be pain, tinnitus and increased hearing loss occasionally, and there will be vertigo, vomiting and loss of balance with a sensation of objects moving from the diseased to the healthy side. At times the patient feels as if he were turning. If he is in bed he lies on his healthy side and looks towards the diseased side as this reduces the vertigo. There is spontaneous nystagmus, in the earliest stages to the affected side and later to the sound side. The fistula sign is usually absent and the caloric reaction is diminished. As a rule there is no pyrexia.

The purulent phase is short lived and unassociated with fever, unless there is an intracranial complication. Giddiness is intense and nausea and vomiting are frequent. There is marked spontaneous nystagmus to the healthy side, while spontaneous pointing and falling are to the diseased side. The membranous labyrinth is destroyed so that there is no fistula sign, no response to caloric testing and complete deafness.

TREATMENT. The discovery of a fistula sign on examination is evidence that cholesteatoma has eroded the labyrinth. This may be confirmed on radiography or tomography, and it is an indication for radical mastoid surgery. When an acute infection supervenes with the production of a serous labyrinthitis treatment is a full course of antibiotics with surgical interference by myringotomy or mastoidectomy if this is indicated. The further development of purulent labyrinthitis calls for antibiotic therapy in large doses in the hope of preventing destruction of the membranous labyrinth. Should

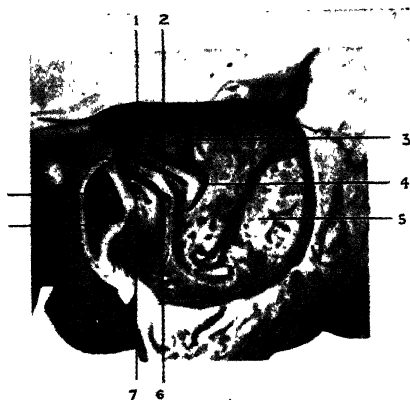

Fig. 181. Anatomical relations concerned in dealing with labyrinth. 1, Horizontal part of canal for facial nerve; 2, Lateral semicircular canal; 3, Superior vertical canal; 4, Posterior vertical canal; 5, Bony wall of sigmoid sinus; 6, Vertical portion of canal for facial nerve; 7, Oval window; 8, Anterior wall of bony meatus; 9, Promontory.

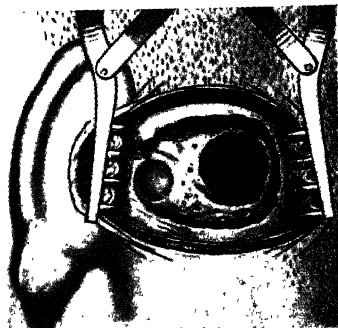


Fig. 182. Neumann's labyrinth operation. After the radical mastoid operation has been completed, a further removal of bone in a medial direction opens up the posterior vertical canal.

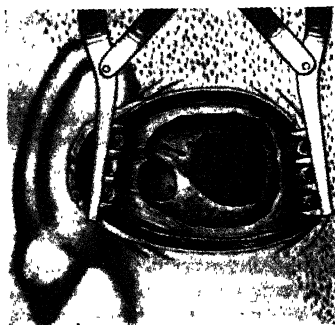


Fig. 183. Neumann's labyrinth operation. Still further removal of bone opens up the lateral or horizontal canal.

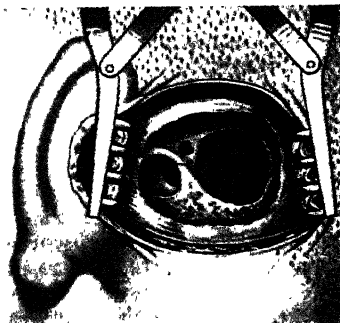


Fig. 184. Neumann's operation. The smooth or medial end of the lateral canal is followed up into the vestibule, and, later, the promontory is removed by a gouge cut which joins the oval and round windows. The facial canal is seen intact between these two openings into the vestibule.

the acute onset of symptoms follow a known chronic otitis media, or have been caused by injury during mastoid surgery, exploration of the labyrinth should be undertaken. There are two standard operations. Hinsberg's consists in performing a radical mastoidectomy, opening into the horizontal (lateral) semicircular canal, removing the stapes and opening the promontory. Neumann's is more radical in that it opens the two vertical semicircular canals as well (Figs. 181-184).

CHAPTER 66

INTRACRANIAL COMPLICATIONS

The incidence of intracranial complications secondary to either an acute or chronic suppurative otitis media has become much less in the past 30 years. Two factors have probably been responsible for this, the first and most important being the use of antibiotics and the second, the more skilful and enlightened treatment of the suppurative conditions of the middle ear which must reflect to a large extent the modern teaching of the undergraduate.

EXTRADURAL ABSCESS

An extradural abscess consists in a collection of pus between the bone and the dura mater. Unless it is opened and drained it is frequently followed by other intracranial complications. It is more common in the posterior than in the middle cranial fossa. Extradural abscess occurs more commonly in acute than in chronic middle ear suppuration. In chronic purulent otitis media it is met with chiefly in cases of cholesteatoma and in acute exacerbations of chronic suppuration. The extent of the abscess varies greatly; it may be quite small, or in chronic cases it may attain a considerable size.

SYMPTOMS. The symptoms are rarely characteristic; the majority of extradural abscesses are only discovered at the time of operation. The condition is associated with deep-seated boring pain, tenderness on tapping over the temporal lobe or posterior fossa and rise of temperature. If the abscess is large, there may be evidence of compression of the brain. There are rarely any localizing symptoms although occasionally paresis of the sixth nerve may be met with.

DIAGNOSIS. This is not easy as a rule. The relief of pain by the spontaneous evacuation of a large quantity of pus, or the aspiration of much pus by mopping or aspiration through the external meatus, may suggest the diagnosis. The continuance of pain, pyrexia and a raised pulse rate after operation for a mastoid complication should suggest the probability of the presence of a deeper-seated collection of pus.

TREATMENT. This consists in opening the abscess and evacuating its contents by free removal of the bony wall. When the abscess is opened the pus flows out in a pulsating manner. The affected dura mater may be covered with red 'healthy' granulations, or it may be greyish-green and slough-like. Removal of the underlying bony wall should be continued until the whole abscess cavity has been freely exposed. The cortical or the radical operation—according to circumstances—is performed at the same time. The patient should be carefully watched in order to detect the first signs of

further intracranial complications, e.g. sinus thrombosis, brain abscess or meningitis.

MENINGITIS

In order to understand the changes which occur in meningitis it is necessary to discuss briefly the secretion, circulation and absorption of the cerebrospinal fluid. The fluid is secreted mainly by the choroid plexuses of the cerebral ventricles. Starting in the lateral ventricles, the fluid flows through the foramen of Monro to reach the third ventricle. Here its volume is augmented by the choroid plexus of that cavity. It then passes through the aqueduct of Sylvius into the fourth ventricle. The fluid now passes out into the cisterna magna of the subarachnoid space through the minute foramina of Magendie and of Luschka, which perforate the lower part of the ventricular roof, and permeates upwards and forwards round the sides of the medulla and over the cerebellar hemispheres. It also passes through the opening in the tentorium and over the cerebral hemispheres. The fluid also passes caudally into the spinal theca—the most convenient anatomical site at which to obtain fluid for investigation, i.e. by lumbar puncture. The cisterna pontis and cisterna lateralis—which contain the seventh and eighth nerves—communicate freely with the cisterna magna. Absorption of cerebrospinal fluid takes place almost entirely from the subarachnoid space overlying the cerebral hemispheres. It will thus be seen that a meningitis commencing on the posterior surface of the petrous bone tends to be confined, for a time at any rate, below the tentorium and only spreads slowly upwards along the Sylvian fissure.

The cells of the choroid plexus form a selective barrier between the blood and the cerebrospinal fluid, allowing certain substances, e.g. chlorides, to pass freely and keeping back others, e.g. protein. When, however, there is widespread meningeal inflammation, the barrier between the blood and fluid becomes less complete and the chemical composition of the cerebrospinal fluid approximates to that of the blood. Glucose in the cerebrospinal fluid tends to disappear, due to the action of bacteria. So long as the meningitis is limited to a small area, the percentages of the inorganic salts in the fluid remain unaltered, even though the fluid be turbid with pus cells and contains an excess of protein, whereas when the meningitis becomes more widespread, the chlorides are diminished.

Meningitis may be serous or purulent, localized or diffuse, and may run an acute or a chronic course. It may be the result of either acute or chronic suppuration in the ear. The infection may pass through an erosion of the bone situated in the groove of the transverse sinus, or the posterior surface of the petrous bone—more rarely in the roof of the middle ear. It may also arise, in the absence of defects in the bone, through the inner ear and internal auditory meatus and perilymphatic aqueduct or along the sheaths of the vessels which run between the middle ear and in the meninges, e.g. those which pass from the inner wall of the tympanic antrum to the fossa subarcuata and posterior cranial fossa. Lastly, infection may come through the blood stream in septicaemic cases.

There are two degrees of meningitis: (1) in which the organisms have not reached the internal surface of the arachnoid, e.g. extradural abscess; and

(2) in which they have invaded the subarachnoid space. The dura mater, arachnoid and pia mater are all resistant to infection. In very severe cases the superficial layers of the brain itself are infected and the condition is one of meningo-encephalitis.

Circumscribed Serous Meningitis. This may occur in the middle cranial fossa associated with petrositis or Gradenigo's syndrome (p. 348). When found in the posterior cranial fossa—*Bárdány's syndrome*—it may follow an otitis media or occasionally a radical mastoid operation. The patient complains of giddiness, occipital headache, deafness and tinnitus, and on examination there is nystagmus on looking towards the healthy side, and falling and past-pointing to the diseased side. There may or may not be optic neuritis. On lumbar puncture the cerebrospinal fluid is normal. There may be spontaneous disappearance of the symptoms after a feeling that something has burst in the back of the head. Treatment is by antibiotics.

Diffuse Purulent Meningitis. The first sign of meningitis in a case of labyrinthitis is slight torpidity and confusion without irritability, but with evidence of premonition regarding an eventual recovery. This stage may have been recognized by the patient's friends. Males are affected in 75 per cent of cases. The early features associated with this disease are headache, neck stiffness and loss of the superficial abdominal reflexes. Should these be present in combination with a diminution of the chlorides and sugar in the cerebrospinal fluid the diagnosis of diffuse purulent meningitis is no longer in doubt. The temperature in the early stage is usually between 38 and 38.5 °C and the patient suffers from frontal or occipital headache, with tenderness and rigidity of the muscles at the back of the neck. This is most easily tested by lifting the patient's head off the pillow or by pressure over the atlanto-occipital membrane.

In the earlier stages of meningitis arising from extradural abscess in the posterior cranial fossa the symptoms are not definite. There may be an initial rigor. Pain is localized at first to the side or back of the head, but later becomes general. Accompanying the headache are fever, restlessness, and marked irritability of temper; vomiting is often present and the tongue is heavily coated, and the teeth covered by sordes. The patient frequently lies with his knees drawn up and head turned away from the light (photophobia). Periods of excitement come on at times, during which he may cry out or talk incoherently. In meningitis the strength of the cry gradually increases, whereas in brain abscess the cry is strongest at first and tails off as the patient relapses into a semi-comatose condition. Delirium is common in children and convulsions are not infrequent. Herpes labialis may be present. Occasionally severe pain in the back is complained of. The reflexes are increased and, especially in children, the abdomen is retracted. An inability to extend the knee when the thigh is flexed (Kernig's sign) is generally present. The temperature rises sharply and remains elevated (39.5 to 40 °C) and towards the end may rise to 41 or 42 °C. The pulse, at first strong and slow considering the presence of fever, soon becomes weak and fast, and the blood pressure becomes very low. Blood examination usually shows a leucocytosis of about $20 \times 10^9/l$.

In meningitis arising in the middle cranial fossa, headache and fever may be the only symptoms, or the case may closely resemble one of temporal lobe abscess.

In the final stages paralysis may develop, and may affect various parts of the body and also some of the cranial nerves, especially the third and sixth with the production of squinting. Optic neuritis is frequently met with, while the pupils are contracted and equal and react sluggishly. Coma supervenes before death.

DIAGNOSIS. Meningitis has been aptly described as the 'great imitator' and must be diagnosed and treated at an early stage for the best chance of survival. Diagnostic lumbar puncture in cases of high temperature alone has been recommended. The progress of the case depends as much on the resistance of the individual to the organism and its toxins as on the nature of the organism. The character of the cerebrospinal fluid at the point of maximum infection is not necessarily represented by the sample obtained on lumbar puncture.

Meningitis is often combined with other intracranial complications. When meningitis is suspected, lumbar or cisternal puncture should be carried out, as it often gives a great deal of information. The normal pressure of the cerebrospinal fluid is 80–120 mm of water and in meningitis it is raised. It is important that there should be no blood in the fluid sent for examination, and therefore the first few drops should be allowed to escape. Four cells per mm³ may be regarded as normal in cerebrospinal fluid. If the fluid is under tension, but clear and sterile, and the cell elements on examination are not found to be greatly increased, the meningitis is still at the 'serous' stage. On the other hand, if the fluid is under pressure and is turbid from the presence of leucocytes, purulent meningitis may usually be diagnosed. If organisms are present in addition to pus cells, there can, of course, be no doubt. The changes found in the cerebrospinal fluid obtained by lumbar puncture are of the greatest importance. The fluid may be clear and sterile even in purulent meningitis, especially if this is localized to the middle cranial fossa. The fluid may be turbid but sterile when a brain abscess is present. In meningitis globulin is increased, glucose is diminished or absent and the chlorides decrease in proportion to the severity of the symptoms. The temperature curve is consistently high in an uncomplicated meningitis in contrast to the hectic rises and falls of a sinus thrombosis and the subnormal temperature in brain abscess (*Fig. 185*). Not infrequently two or more intracranial complications may coexist.

TREATMENT. Without waiting to identify the organisms responsible, 2–4 megaunits of penicillin are given intramuscularly every 4 hours. Swabs from the ear, and fluid obtained at lumbar puncture, are cultured to discover the organisms and to determine their sensitivity, and antibiotic treatment is continued with the appropriate drug until the cerebrospinal fluid and clinical examination are normal. Surgery must be considered, and if there is acute mastoid infection associated with the meningitis a cortical mastoid operation should be performed. At operation the dura mater of the middle cranial fossa is widely exposed (*see Fig. 188*, p. 363), and the lateral (sigmoid) sinus is carefully inspected for any evidence of thrombosis. Should the meningitis be associated with chronic otitis media, and especially if antibiotic therapy has failed, the labyrinth operation (Neumann) may have to be performed (*see Figs. 182–184*, p. 353).

PROGNOSIS. Uncomplicated meningitis has a more favourable outlook than one associated with sinus thrombosis or brain abscess or labyrinthitis.

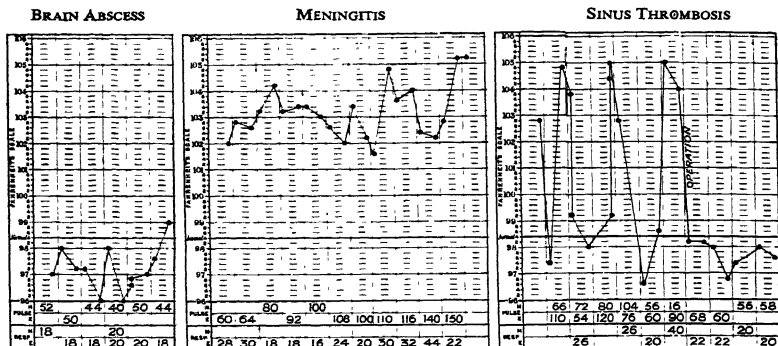


Fig. 185. Charts showing characteristic temperature and pulse rate in various intracranial complications of middle ear suppuration.

The level of chlorides in the cerebrospinal fluid is of prognostic significance, and if it remains normal the case is likely to recover.

BRAIN ABSCESS

An otitic brain abscess is usually found close to the disease which causes it, and is therefore situated, in the vast majority of cases, in the temporal lobe (*Fig. 186*) or in the cerebellum (*Fig. 187*) of the diseased side. Most authorities believe that the temporal lobe abscess is the more common. An otitic brain abscess is usually single. It may be acute, i.e. without a definite capsule, especially in cases in which the abscess results from acute middle ear suppuration. Chronic abscesses have a more defined capsule.

Meningeal abscess formation may occur—either subdural or between the pia and arachnoid. Such collections of pus may be regarded as a protective process which tends to prevent general infection of the meninges. Brain abscess occurs as a rule between the ages of 10 and 30; it is commoner in males than females, and is more frequently the result of chronic than of acute suppuration. In chronic cases cholesteatoma is usually present.

Cerebellar abscess is due to: (1) Extension of infection from the mastoid process posteriorly and medially, through the triangular area (Trautmann's) bounded above by the superior petrosal sinus, below and in front by the facial nerve, and behind by the sigmoid sinus: this is the most frequent route of infection, and as a rule an extradural abscess precedes the formation of the cerebellar abscess which is situated in or near the anterior surface of the cerebellum. (2) Septic thrombosis of the sigmoid sinus which is usually associated with an extradural perisinus abscess. (3) Labyrinthitis in cases of chronic middle ear suppuration. As the cerebellar abscess grows it may produce internal hydrocephalus and 'coning' of the brain-stem.

Temporal lobe abscess is caused by the spread of the infection through the roof of the tympanic cavity or mastoid antrum. Abscess of the brain is frequently preceded by extradural abscess. The dura mater, pia arachnoid membrane and brain become adherent, and, an area of encephalitis or red softening having formed first of all, the abscess develops in close relation

to the extradural abscess. More rarely the abscess is due to septic infection of one of the pial veins of the temporal lobe or cerebellum. Infection by this route, which is common in cases of acute middle ear suppuration, may result in multiple abscesses and meningitis.

Once it has formed, a brain abscess tends to expand at the expense of the white matter, which has less vascularity than the grey. In the temporal lobe an abscess spreads along the vessels towards the lateral ventricle.

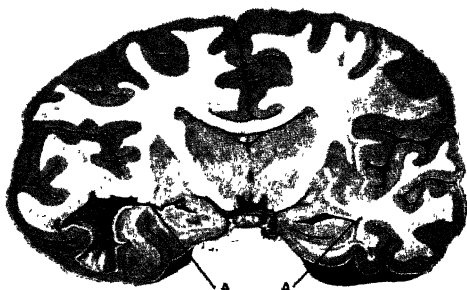

Fig. 186. Abscess of left temporal lobe. Note that the abscess has ruptured into the left lateral ventricle. A, Lateral ventricles.

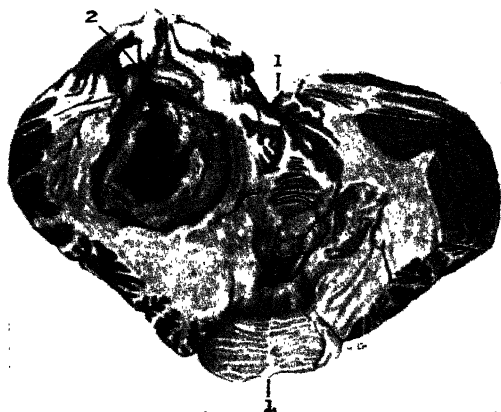


Fig. 187. Cerebellar abscess. 1-1, indicates what would be the normal middle line of cerebellum and pons—note the swelling of the cerebellar hemisphere containing abscess; 2, Opening made for drainage.

SYMPTOMS. A brain abscess may be divided clinically into four stages:

1. *Initial.* There may be an initial rigor, with headache, vomiting and rise of temperature during the period of red softening. This stage lasts for a few days and is usually preceded by stoppage of the aural discharge.

2. *Latent.* During the latent stage, of variable duration, there are no marked symptoms, although the patient's mentality may change. He may

be irritable and moody, and there may be more or less headache. Constipation and loss of weight are present in cases of chronic brain abscess but at times the patient feels fairly well and may continue his work.

3. *Manifest.* In this stage the symptoms are in part due to compression of the brain, and in part to toxæmia resulting from the suppuration.

a. Symptoms due to compression are headache, nausea, vomiting of the projectile type, slow pulse and subnormal temperature (see Fig. 185). Papilloedema is frequently present and is usually more marked on the diseased side. Headache is one of the earliest symptoms and lasts as long as consciousness persists. Nausea and vomiting are unconnected with the ingestion of food and may recur several times a day. In many cases of brain abscess the patient has a ravenous appetite—a symptom not infrequently associated with a favourable prognosis. The pulse, at first rather quick, gradually becomes slower, and may drop to 50 or 40. The temperature also becomes subnormal unless the condition is masked by coexisting meningitis or sinus thrombosis but even in these cases the pulse remains relatively slow. The patient is drowsy and his cerebration slow. He may have to be shaken gently before he answers a question, and relapses almost at once into his former semi-comatose condition.

b. The symptoms due to the infection are rapid exhaustion and very marked emaciation; there is also a peculiar and very disagreeable odour of the breath. The appetite is poor, the tongue thickly furred, the patient pale and constipated and sordes form on the teeth. A blood count usually shows a well-marked leucocytosis. On lumbar puncture the fluid may be quite normal but more frequently there is an increase in the cells—chiefly small lymphocytes. Even when the fluid is turbid it is usually sterile.

4. *Terminal.* The terminal or paralytic stage is associated with coma and sometimes with convulsions.

DIAGNOSIS. While in many cases it is possible from the signs and symptoms described above to say with some degree of certainty that a brain abscess exists, it is much more difficult and sometimes impossible to locate it for there may be no focal symptoms. There are, however, certain signs which, if present, point to a definite situation of the abscess. The pressure of the cerebrospinal fluid is important. If it is below 200 mm of water the suspected acute otogenic abscess is more likely to be cerebellar, while if the pressure should be above 300 mm of water the abscess is invariably above the tentorium.

ABSCESS IN THE TEMPORAL LOBE

Localized headache over the temporal lobe may be present, and the patient may claw uneasily at the affected region. Tenderness on tapping over the temporal region is found in cases in which an extradural abscess is also present. Paresis of the third nerve is often present on the side of the lesion and is indicated by dilatation of the homolateral pupil. Ptosis may develop later, followed by paralysis of the external muscles supplied by the third nerve. Not uncommonly there are contractions of the facial muscles on the side of the lesion, especially of those concerned in wrinkling up the skin of the forehead and in frowning. When asked a question the patient may repeat the same word over and over again—a condition known as 'perseveration'.

Not infrequently his friends notice a change for the worse in his character. When the abscess is sufficiently large to cause pressure on the internal capsule paresis may develop in certain of the groups of muscles of the opposite side of the body, and even hemiplegia may arise. In such cases there is dorsiflexion on eliciting the plantar reflex. Crossed deafness and crossed facial paralysis sometimes occur. Cases of encephalitis of the temporal lobe associated with convulsions have been recorded. If the abscess is situated on the left side optic aphasia is frequently found, but is a late symptom and by no means constantly present. The purulent collection interferes with the nerve tract connecting the centres for visual and auditory memory. Thus the patient is unable to name such simple objects as a pen, knife or keys, though he may demonstrate by pantomime that he knows how to use them. It will thus be seen that an abscess of the left temporoparietal lobe is more easy to diagnose than one on the right side. Indeed in cases of bilateral purulent otitis media with well-marked general symptoms of brain abscess it may only be possible to diagnose the presence of the abscess in the right temporal lobe by finding that the localizing symptoms of abscess in the left temporal lobe and those of abscess in both lateral cerebellar lobes are absent. It has been stated that the most important signs of abscess of the temporal lobe are slight weakness of the opposite side of the face in its lower half, most obvious when the patient talks or smiles, and absent or diminished abdominal reflexes, with increased knee jerk and extensor or doubtful plantar response on the contralateral side due to pressure of the abscess on the pyramidal tract. Paralysis of the contralateral arm and even of the lower extremity have been described. Anosmia may sometimes be detected, but it is a symptom which may readily escape notice unless specially looked for. Homonymous hemianopia may be present if the abscess is large and extends towards the optic radiation. The usual type of defect is in the superior quadrant. When the patient is alert this sign is easily demonstrated, but when his mental state is impaired it is necessary to take the patient by surprise. The observer stands opposite the patient and makes certain that he (the patient) is looking directly at him. The observer then raises a finger on either side of the patient's face, on a level with the eyes, and says sharply, 'Take hold of my finger'. If the patient makes no response he is probably incapable of understanding. If he raises both hands and grasps each of the observer's fingers, it is evident that there is no gross temporal hemianopia. If, however, the patient only raises one hand to grasp one finger, it is then obvious that he does not see the other finger. This method is also of use in the case of young children. Radiological examination may aid the diagnosis, as brain abscesses sometimes contain gas which can be shown by radiographs. Air-encephalography, arteriography or an electro-encephalogram may yield very useful information as a help in diagnosis, but the first is contra-indicated where a cerebellar abscess is suspected and ventriculography should be substituted in its stead. Nystagmus is very rare in temporal abscess and only occurs if the suppuration extends backwards to the occipital lobe. Sudden onset of coma with high fever indicates that the abscess has ruptured into the lateral ventricle (see Fig. 186, p. 359). In cases of localized collection of pus on the surface of the brain, beneath the pia arachnoid membrane, there may be a sudden onset of Jacksonian epileptic attacks on the contralateral side.

CEREBELLAR ABSCESS

The patient generally lies curled up, his head turned towards the side of the lesion. When sitting up or standing he tends to hold his head inclined to this side. Often there is considerable rigidity of the neck, and persistent nuchal rigidity is considered the most constant and earliest sign of an acute cerebellar or cerebral abscess of otogenic origin when it is combined with a cell content in the cerebrospinal fluid of chiefly under 100 lymphocytes. The patient complains of dizziness when sitting up, and when erect he stands with a wide base. Although the headache is usually occipital it is well to remember that in cerebellar abscess there may be complaint of headache in the frontal region. Yawning and hiccough may be symptoms suggestive of pus in the posterior cranial fossa. The speech may resemble that in disseminated sclerosis, i.e. scanning speech. Vomiting and papilloedema are more common in cerebellar than in cerebral abscess. Cerebellar ataxia may also be present, the patient staggering or falling towards the diseased side as a rule. Further, the direction of the fall on Romberg's test (backwards and to the diseased side) is not influenced by cold syringing of the ear or by altering the position of the patient's head. As cerebellar control is homolateral, the signs of cerebellar abscess are on the same side as the lesion. Movements of the homolateral limbs are asynergic, and the patient is disinclined to use the limbs on this side when he is irritated, e.g. by holding his nose. The deep reflexes may be increased on the side of the lesion. A valuable localizing sign is 'dysidiadochokinesia'. In testing for this the forearms are alternately and quickly pronated and supinated; if the sign is present, fatigue is rapidly induced in the arm on the diseased side. When the patient raises both hands in the position of surrender the arm on the suspected side starts to fall gradually. Nystagmus is usually present and is coarser and of greater amplitude than that due to labyrinthitis; it is generally directed towards the affected side and becomes more noticeable as the disease progresses. The variability of the nystagmus of cerebellar abscess is characteristic. At one time it is directed to the affected side and at another to the sound side, or it may be absent for short periods. This is in marked contrast to the conditions found in labyrinthitis in which the nystagmus is always directed to the healthy side and gradually diminishes in intensity, passing from the third to the second, and later to the first, degree before disappearing. It will thus be seen that in labyrinthitis the symptoms and signs gradually diminish and pass off, whereas in cerebellar abscess they show a progressive increase. The pointing test may be found useful. In cerebellar abscess there is usually deviation in the pointing test and as a rule it is outwards on the site of the lesion, but, like the nystagmus, may show considerable variation from day to day. There may be distinct tremor on the affected side in the 'finger-nose' test. Complete hemiparesis of the limbs is occasionally met with, and is due to compression of the pyramidal tract below the decussation of the pyramids. Respiratory paralysis occurs not infrequently in cerebellar abscess, and is caused by coning of the foramen magnum by the brain stem.

COURSE AND TERMINATION. If untreated, a brain abscess invariably ends fatally. The patient at first becomes stuporous but can still be roused although his response to external stimuli is very slow; he may even fall asleep while

attempting to eat. The stupor deepens to coma, which continues till death.

PROGNOSIS. The prognosis of abscess of the brain is still grave. The statistics of various authorities differ, but it may be said that the early recognition and neurosurgical treatment of otogenic intracranial infection combined with antibiotic therapy have reduced the mortality to the region of 10 per cent or less. In adults recovery may be followed several months later by epileptiform attacks. Even after the apparently successful evacuation of an abscess, death may occur from spread of the infection. Those cases are least hopeful

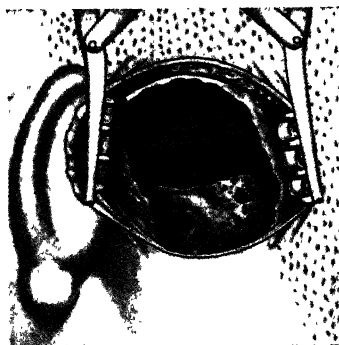


Fig. 188. Exposure of dura of middle cranial fossa on left side preliminary to drainage of temporal lobe abscess.

in which more than one abscess is present, or which are complicated by sinus thrombosis or meningitis.

TREATMENT. When the site of the abscess has been localized it is drained through a burr hole in the squamous temporal in cases of temporal lobe abscess, and midway between the mastoid and the external occipital protuberance in cerebellar abscess. When the abscess is located and pus aspirated 30 000–50 000 units of pure crystalline penicillin mixed with 2 ml of thin barium emulsion should be injected and the wound closed. Progress can be checked by radiographs every few days. Should the abscess increase in size or remain stationary it may be excised by the neurosurgeon, but should it shrivel excision is not required. A cure is claimed when the cerebrospinal fluid and air encephalogram are normal. The otologist should co-operate closely with the neurosurgeon in the treatment of brain abscess, and mastoid surgery (*Fig. 188*) may be necessary to remove the source of the infection, and to deal with any extradural abscess or an accompanying sinus thrombosis. Such mastoid surgery should be performed early in the disease and the wound left unsutured, to be closed after the brain abscess shows improvement.

CHAPTER 67

SINUS THROMBOSIS

The transverse (sigmoid) sinus is the venous channel most frequently affected by purulent infection, and from it the disease may spread: (1) backwards to the confluens sinuum (torcular); (2) rarely forwards to the superior petrosal and cavernous sinuses; or (3) downwards to the bulb and internal jugular vein in the neck. Thrombophlebitis of a venous sinus is one of the most common of otitic intracranial complications. It occurs in both acute and chronic suppurations, although more frequently in the latter. The infection usually passes through the bone to the walls of the sinus where an extradural perisinus abscess may be formed. Such an extradural abscess may be present for a considerable period before the wall of the sinus succumbs and a clot is formed on the adjacent wall of the vessel. If the process continues (*Fig. 189*) the thrombus spreads upwards and backwards as far as the entrance of the superior petrosal sinus and forwards and downwards to the jugular bulb. At these points the thrombosis tends to stop, but if it extends backwards beyond the opening of the superior petrosal there is nothing to prevent its reaching the confluens sinuum (torcular). In the same way the thrombus, after passing the jugular bulb, may continue until the junction of the common facial and the internal jugular veins is reached where again there is a natural tendency to arrest of the process. Long before this stage has been reached the transverse (sigmoid) sinus in the region of the upper 'knee' has become occluded. An abscess forms from the breaking down of the clot, portions of which may pass into the blood stream and set up abscesses in distant parts of the body (pyaemia).

Especially in cases where there is an almost complete absence of mastoid air cells, and where in consequence the sigmoid sinus lies far forward, the infection may pass by way of the small veins which open into the sinus without the formation of an extradural perisinus abscess. In such conditions the thrombosis is of endophlebitic origin, and when exposed at operation the sinus wall may show little or no change. In rare cases the veins passing through the floor of the tympanum to the jugular bulb may carry infection and produce primary thrombosis of the bulb (*Fig. 190*). Pyaemic symptoms come on more rapidly in these cases.

SYMPTOMS. Sinus thrombosis may run its course without symptoms, particularly where antibiotics have been used, but typically it is characterized by the occurrence of chilly sensations or rigors in which the temperature rises suddenly to 39.5 or 40 °C, and falls again as rapidly, the fall being accompanied by profuse sweating (*see Fig. 185, p. 358*). There may be only a single daily rigor, as a rule in the afternoon or evening, or several may occur in a day. A high evening temperature for several days after a mastoid operation calls for prompt exposure of the transverse sinus. The pulse rate rises with

the temperature. In the intervals between the rigors, the patient may be free from symptoms; but in some cases, especially later in the disease, the temperature remains elevated. Headache and vomiting are sometimes met with; the tongue presents a very significant appearance and is usually dry and brown; there may be herpes or sordes on the lips; the spleen may be enlarged; a choked optic disk occurs in a considerable proportion of cases. Lumbar puncture demonstrates raised fluid pressure, particularly when

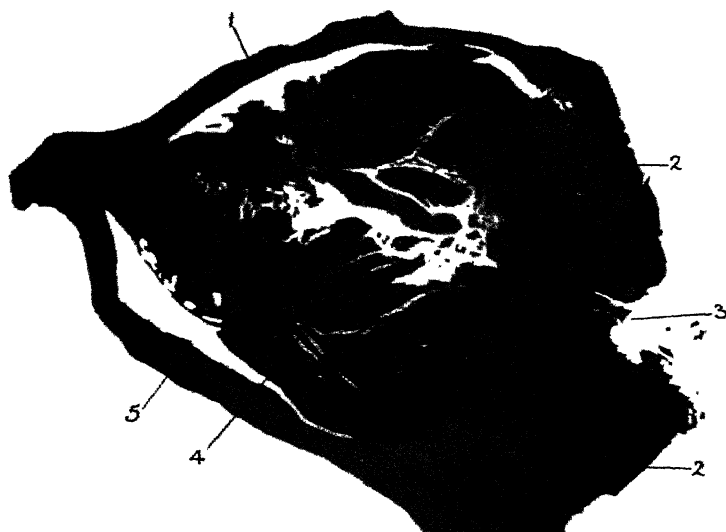


Fig. 189. Horizontal section through thrombosed sigmoid sinus showing extradural perisinus abscess. 1, Normal dura of sinus wall; 2, Sinus wall replaced by granulation tissue; 3, Position of perisinus abscess; 4, Laminated clot in sigmoid sinus, breaking down in centre; 5, Normal dura of cerebellar surface of the sigmoid sinus.

complete occlusion is present and the Tobey-Ayer test is positive. Pressure on the jugular vein of the normal side produces a rise of pressure of cerebrospinal fluid in the manometer which is connected to the lumbar puncture needle. Compression of the vein on the affected side produces little or no rise of pressure. Occasionally oedema is manifest in the neighbourhood of the mastoid emissary vein (Griesinger's sign). When the thrombosis extends into the neck, torticollis may supervene, and tenderness may be complained of along the line of the jugular vein, while a swelling, due to inflammatory enlargement of the cervical lymphatic glands, is sometimes found. The thrombosis may extend along the superior or inferior sinuses to the cavernous sinus.

As a result of the escape of portions of the clot into the general circulation, septic pneumonia and empyema (infarction) may arise, or metastatic abscesses may appear in other parts of the body, especially in the subcutaneous tissues or in the bones and joints. If the septic particles are large they are

held up in the pulmonary capillaries, but if they are small they can pass through and reach the bones, joints or subcutaneous tissues.

DIAGNOSIS. The conditions with which sinus thrombosis is most likely to be confused are malaria, typhoid fever, bronchopneumonia and erysipelas. The diagnosis of sinus thrombosis is suggested by the occurrence of rigors in the course of a middle ear suppuration; it is more difficult if the condition is complicated by the presence of meningitis or brain abscess. Sinus thrombosis may occur in cases where middle ear suppuration is not suspected;

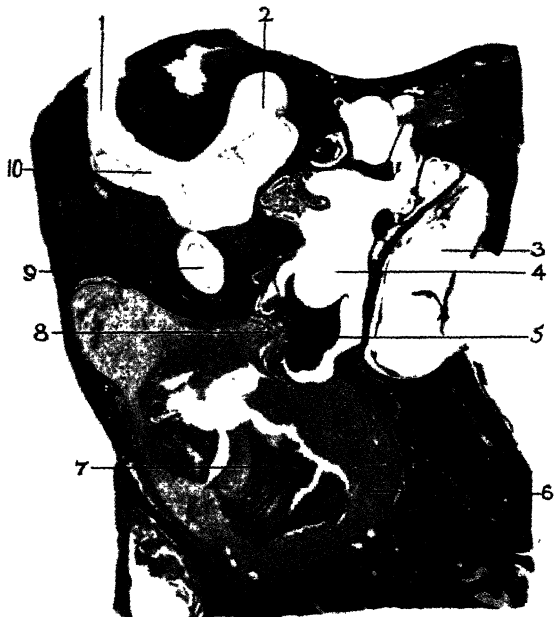

Fig. 190. Vertical coronal section through middle and inner ear showing route of infection in a case of primary septic thrombosis of the jugular bulb. 1, Smooth part of superior vertical canal; 2, Ampulla of superior canal; 3, External meatus; 4, Tympanic cavity; 5, Pus in lower part of tympanum; 6, Thickened lining membrane of jugular bulb; 7, Laminated clot in the bulb; 8, Point at which infection passed from tympanum to bulb; 9, Ampullary end of posterior vertical canal; 10, Crus commune.

this error is not likely to arise if the condition of the ears is ascertained. A high leucocyte count with a high percentage of polymorphonuclear leucocytes (80-95 per cent) shows a severe infection. Repeated examinations of the blood are of more value than single tests in regard to prognosis, but it cannot be said that the leucocyte count serves to distinguish cases of venous infection from those of extradural abscess or septic meningitis. As a rule, however, the count is lower in brain abscess than in the other intracranial complications. Blood cultures taken during the phase of rising temperature

have been employed as an aid to diagnosis, but have not been found of great value, because: (1) living organisms are not always present in the peripheral veins even in cases of undoubted sinus thrombosis, and (2) the organisms may not show a growth until 48 hours have elapsed by which time in the majority of cases immediate operative interference has been undertaken.

The general aspect of the patient differs markedly in the three main intracranial complications—purulent meningitis, brain abscess and septic sinus thrombosis. In meningitis the patient is anxious, frightened and has a very severe headache. In brain abscess he is usually dull and apathetic, although here also the headache is severe. In septic sinus thrombosis the patient is bright and, when questioned, usually says he feels well except, of course, during or just after a rigor.

PROGNOSIS. The prognosis of transverse sinus thrombosis is much more favourable since the introduction of antibiotics and its incidence reduced thereby. It is more favourable than brain abscess if an operation is performed before systemic infection has occurred and if there is no other intracranial complication. With antibiotics and timely surgery a cure is to be expected.

TREATMENT. As in the other intracranial complications, energetic treatment by antibiotics is carried out and in many cases operative treatment is quite unnecessary, but when active surgical intervention is required this consists of removing the primary focus of disease, by performing a cortical mastoidectomy in cases due to acute middle ear suppuration, and a radical operation

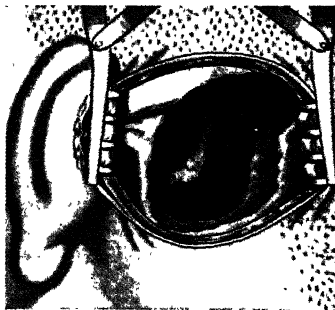


Fig. 191. Exposure of sigmoid sinus.

in cases of chronic suppuration. If sinus thrombosis be present, there is usually excessive bleeding from the bone at the mastoid operation. In every case which shows symptoms suggestive of extradural perisinus abscess or sinus thrombosis, the sigmoid sinus should be exposed (*Fig. 191*) until the healthy wall is seen.

If an extradural perisinus abscess is found, with healthy red granulations on the sinus wall, and if only one rigor has occurred it is advisable to leave the wound open and await developments. Nor should the sinus be opened if the sinus wall returns evenly and instantly to its previous shape after being compressed with a blunt probe which is suddenly released. The sinus should be opened if the temperature rises over 38°C for two successive

nights following operation, or if the sinus wall should appear greyish-yellow or brownish-green and slough-like at the first or subsequent operations. Before opening, the sinus plate is removed to expose the healthy sinus wall above and below the diseased area. Gauze packing is inserted between the sinus and bone in an attempt to shut off the flow of blood, and the sinus is slit open and the clot evacuated. In most cases there is free bleeding in spite of the pack, and a BIPP pack should be introduced into the lumen of the sinus to check the haemorrhage. Some surgeons like to tie off the internal jugular vein in the neck at the same operation, but if this is not done routinely it is called for if the case does not settle down after the initial surgery, or if there is evidence of blood-borne infection.

Septic thrombosis occasionally follows accidental injury to the sinus during mastoid operations. Injury to the wall should be treated by the application of a postage-stamp graft of fascia from the mastoid cortex, or a piece of temporalis muscle should be cut off and applied. This usually arrests the bleeding, and very often there is no further trouble. Should rigors occur postoperatively the case is treated as a sinus thrombosis.

OTITIC HYDROCEPHALUS

This condition may be caused by thrombosis occurring in a dural blood sinus, and the symptoms produced are considered to be due to poor absorption of the cerebrospinal fluid by the arachnoid villi secondary to a choke in one of the dural sinuses, especially the sigmoid sinus. Severe headache, which may be intermittent but very intense, is a prominent symptom and it may be accompanied by vomiting. There is a variable nystagmus, inconstant in direction, and papilloedema is frequently present while occasionally there is involvement of the abducent nerve on the homolateral side of the ear infection. The pressure of the cerebrospinal fluid is raised to 300 mm or more, but examination shows a normal cytology. On ventriculography the ventricles show no variation in size but intraventricular pressure may be raised. Treatment is by anticoagulant therapy given in the hope of preventing further thrombosis, and by frequent ventricular or lumbar punctures to relieve the pressure of the cerebrospinal fluid. The therapy may require to be continued for some time as the condition tends to persist for a month or longer.

CHAPTER 68

TUBERCULOSIS AND SYPHILIS OF THE EAR

TUBERCULOSIS OF THE EAR

External Ear. The external ear may be involved by lupus vulgaris, but this is now rare. For details of treatment, reference should be made to the standard textbooks on dermatology.

Middle Ear. Tuberculous otitis media is now a rare condition in Great Britain. Cases of tuberculous otitis media may be divided into two groups: (1) In infants and very young children who are fed, in whole or in part, on unsterilized cow's milk which contains the bovine type of tubercle bacillus. Suppurative otitis media in an infant, which is not responding to treatment, should make one think of tuberculous middle ear disease. (2) In the advanced stages of pulmonary tuberculous disease of the middle ear cleft sometimes occurs.

PATHOLOGY.

Infection by Way of the Eustachian Tube. (1) Tuberculous infiltration of the mucous membrane spreads up the tube to the tympanic cavity, or (2) Infectious particles may be insufflated up the Eustachian tube during the acts of coughing and sneezing. Invasion of the labyrinth occurs first of all through the oval and round windows. In advanced cases there is caries and necrosis of the bony labyrinth capsule. In rare cases there is a tendency to spontaneous cure of the tuberculous labyrinthitis.

Infection by the Blood Stream. If the Eustachian tube and tympanum appear to be healthy, while the mastoid process alone is diseased, the probability is that infection has occurred by way of the blood stream.

SYMPTOMS. The onset appears to be painless, in marked contrast to the early stages of pyogenic otitis media. The lymph glands surrounding the ear are often enlarged. In the early stage the discharge is watery, and later it may be flocculent: in the advanced stages, where mixed infection is present, it is offensive and purulent. Pale granulations may be seen and these recur rapidly after removal. Paralysis of the facial nerve may occur and multiple perforations in the tympanic membrane (*Plate X, 8*), may sometimes be seen in adults. Involvement of the labyrinth is of frequent occurrence, and takes place at a comparatively early stage of the disease. Tuberculous labyrinthitis, like tuberculous otitis media, appears to have a quiet onset, in marked contrast to the violent symptoms produced by an attack of acute purulent labyrinthitis.

COMPLICATIONS. Tuberculous otitis media and interna do not, as a rule, give rise to intracranial complications, although tuberculous granulation tissue on the dura mater is frequently met with at operation. A number of cases, however, have been reported where a tuberculoma of the brain has occurred, the cerebellum being the most likely site.

DIAGNOSIS. This is made by attention to the following points: (1) The clinical characteristics of the case already described. (2) Examination of the ear discharge for tubercle bacilli. (3) Microscopic examination of granulations removed from the middle ear. (4) Guinea-pig inoculation. (5) The findings at operation—enlarged caseous glands, presence of necrosed bone, pale flabby granulations, putty-like pus in the tympanic antrum, extensive caries of the bone and necrosis of the labyrinthine wall. (6) Microscopic examination of the swollen and infiltrated mucosa removed at operation.

TREATMENT. This consists of intensive chemotherapy with antituberculous drugs but surgical treatment may also be required.

SYPHILIS OF THE EAR

Congenital Syphilis. After epidemic cerebrospinal meningitis and middle ear suppuration, this condition once ranked as the most frequent cause of acquired deaf-mutism. It is probable that some cases of so-called 'congenital' deaf-mutism are still due to intra-uterine syphilis or to syphilitic changes in the ear occurring before the child has learned to talk. Statistics as to the frequency of deafness in children suffering from congenital syphilis vary from 30 to 60 per cent.

1. *In the fetus and infant.* The most severe forms of ear syphilis probably occur in intra-uterine life. The infants show all the signs of congenital deafness, and the static labyrinth is not excitable. Otitis media is of common occurrence in syphilitic infants. In some the infective process involves the labyrinth by rupture of the annular ligament.

2. *In young children* suffering from congenital syphilis what appears to be a case of simple Eustachian catarrh runs a protracted course. The usual treatment has little effect, and the drumheads remain thickened and indrawn, while the deafness is severe and persists. There is a combination of middle ear catarrh and labyrinthine deafness.

3. *The late type of congenital syphilis*, where deafness occurs usually between the seventh and thirteenth years, may be due to: (a) Otitis media followed by invasion of the labyrinth capsule and degeneration of the membranous labyrinth (*Figs.* 192, 193). In cases of congenital syphilitic deafness the tympanic membranes are seldom normal, pointing to a past attack (or attacks) of otitis media. (b) Syphilitic osteomyelitis of the bony labyrinth capsule due to spirochaetal blood infection. (c) Syphilitic neuritis of cochlear nerve.

CLINICAL ASPECT. The patient is very often the eldest living child of the family and, on questioning the mother, a history is often obtained of miscarriages and stillbirths preceding the birth of the patient. Females are affected much more frequently than males. As a rule eye trouble (interstitial keratitis) comes on 2 or 3 years before the deafness. 'Hutchinson' teeth (peg-shaped, notched incisors) are present in 50 per cent of cases (*see Fig. 22*, p. 39). Deafness may come on in one night; in such cases the vestibular tests give normal results, thus pointing to an isolated affection of the cochlear nerve. In other cases the onset of deafness is gradual, but eventually the patient becomes completely or almost completely deaf. In the early stages the deafness is probably of the middle ear type. As a rule, however, the case is not seen till later, when perceptive deafness is present.

In the majority of cases there is a reduction of caloric response. In cases of congenital origin the cerebrospinal fluid is practically always normal, and the seat of the lesion is therefore most likely in the labyrinth. Both ears are usually affected and the patients are often deaf-mutes.

DIAGNOSIS. Very profound or complete deafness in a child should suggest the possibility of congenital syphilis. Suspected cases should be examined for the presence of interstitial keratitis, 'Hutchinson' teeth, ozaena, saddle-back nose, perforation of the nasal septum, and scars on the palate, pharynx



Fig. 192. Congenital syphilitic disease of the ear showing degeneration of Corti's organ in the basal coil. (Compare with Fig. 143, p. 260.)

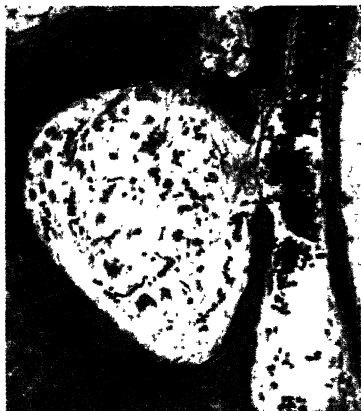

Fig. 193. Congenital syphilitic disease of the ear. Spiral ganglion of the basal coil, showing atrophy of nerve cells.

and at the angles of the mouth. The patient's mother should be questioned as to miscarriages and stillbirths. Serological tests for syphilis should be done.

Acquired Syphilis.

External Ear

(1) Primary syphilis of the outer ear is rare. (2) Secondary syphilitic affections (condylomata and papules) of the external ear and meatus may be associated with middle ear suppuration.

Middle Ear

Secondary syphilis is probably more common than is usually supposed. Syphilitic nasopharyngitis may spread to the tympanum and give rise to catarrhal otitis media. The labyrinth is often affected in these cases. As a rule one ear is involved. The onset of deafness is usually rapid, but the pain is slight. Tinnitus is marked and giddiness may be present. Inflation produces no improvement in hearing. Syphilitic otitis media in the tertiary stage is usually due to an affection of the nasopharynx—gumma or

THE EAR

ulceration. Caries and necrosis of the tympanic walls may be present, associated with facial paralysis and labyrinthitis.

Labyrinth and Eighth Nerve—'Neurolabyrinthitis'

In the early stages of syphilis there is often a pleocytosis in the cerebrospinal fluid along with an increase of albumin, i.e. a luetic meningitis. In secondary syphilis complaints of tinnitus, giddiness and disturbance of balance are by no means rare. In some there are changes in the posterior cranial fossa, as evidenced by nystagmus of central origin and cerebellar disturbance of balance. These cases nearly all show definite changes in the cerebrospinal fluid, i.e. positive serological tests and increased cell count. Deafness is sometimes of sudden onset, but may be gradual. As a rule only one ear is involved. Functional examination shows an inner ear deafness and microscopic examination of the labyrinth reveals atrophy of Corti's organ and its ganglion cells.

Tertiary Affections of the Eighth Nerve

The eighth nerve may be affected along with other cranial nerves by gummatous infiltration of the meninges and nerve sheaths. These conditions are often preceded by severe headache, sometimes of long duration. Headache of syphilitic origin is worst at midnight while that of nasal origin is most severe in the forenoon. In cases of nerve deafness serological tests may be positive.

TREATMENT. Treatment of acquired and congenital syphilis is by large doses of penicillin to control the infection, but only limited improvement in the symptoms can be expected.

CHAPTER 69

OTOSCLEROSIS

In normal conditions the membranous labyrinth is surrounded by two distinct layers of bone: (1) The inner of these two, the labyrinth capsule proper, is composed of dense bone directly derived from the cartilaginous capsule of the otic vesicle in the embryo. For good hearing it is necessary that the nerve structures of the inner ear should be immediately surrounded by this layer of dense non-vascular bone. (2) Enclosing this cartilaginous bone, but distinct from it, there is the ordinary lamellar bone derived from the muco-periosteum of the middle ear and from the osteogenic layer of the dura mater. These two layers are partially separated from one another in the embryo, and also in infants, by a well-marked lymph space. In young subjects, remains of fetal cartilage are sometimes to be found in the promontory near the anterior margin of the oval window (*Fig. 194*).

Otosclerosis is a very common disease. Probably 1 person in every 200 suffers from the affection. In many cases otosclerosis is present, unsuspected, in the labyrinth capsule and only becomes manifest when it involves the hearing mechanism.

AETIOLOGY. The disease is much more common in the female than the male sex. There is marked hereditary tendency to otosclerosis in certain families, and in nearly 50 per cent of cases a history of deafness in the family can be obtained. The disease usually becomes manifest between the ages of 18 and 30, but it may begin earlier. There appears to be a close relationship between the onset of deafness and the onset of puberty or the occurrence of pregnancy.

PATHOLOGY. The bony changes vary according to the duration of the disease. At first the normal bone is absorbed and replaced by vascular spongy osteoid tissue. The process advances along the blood vessels. Later the new bone becomes thicker and less vascular. The most common site of disease is the promontory in the region of the anterior margin of the oval window (*Figs. 195, 196*), and in advanced cases the stapes becomes ankylosed in position by a mass of spongy new bone. Various reasons have been given to explain this 'site of election' for bone disease in otosclerosis. It may be worthy of note that there is in this region an anastomosis between the vessels of the middle ear and those of the labyrinth capsule. Of greater possible significance is the fact that in this area is located the *fistula ante fenestram*, a vestigial structure which frequently contains cartilaginous remnants and which is particularly prone to otosclerotic change.

SYMPTOMS. The chief symptoms are gradually increasing deafness and tinnitus. The noises are often referred to the head rather than the ear and occasionally cause the patient more discomfort than the deafness. If tinnitus is marked, the case is likely to progress rapidly. Paracusis Willisii is frequently

present, i.e. the patient states that he can hear better in a noisy place such as a railway carriage or motor-car. Various explanations have been put forward to account for paracusis, the most probable being that patients suffering from otosclerosis, and consequently unable to hear lower tones, obtain more advantages than normal people from the raising of their friends' voices in a noisy place, as they (otosclerotics) are not distracted by the low-pitched hum of machinery to the same extent as people with perfect hearing.

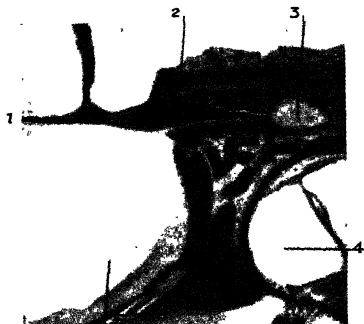


Fig. 194. Horizontal section through anterior margin of oval window of fetus. 1, Footplate of stapes; 2, Fibrous tissue joining endosteum of vestibule to—3, Remains of fetal cartilage in bony capsule of cochlea; 4, Basal coil of cochlea; 5, Saccule.



Fig. 195. Normal joint between footplate of stapes and margin of oval window.



Fig. 196. Otosclerosis, with ankylosis of footplate of stapes to anterior margin of oval window. 1, Spongy bone.

Otosclerotics speak in a low, well-modulated voice, very different from the loud, harsh speech of an advanced case of nerve deafness. Giddiness is a rare symptom, but may be present in varying degree even to the extent of true paroxysmal vertigo.

EXAMINATION. In otosclerosis the tympanic membrane is usually normal. In about 10 per cent of cases a flamingo-pink blush (*Plate X, 20*), may be seen

through the membrane, usually behind the handle of the malleus. This is due to hyperaemia of the promontory and affords good evidence that the otosclerotic process is in an active phase. The Eustachian tube is usually patent. On the other hand, the presence of scars in, or opacity or retraction of, the drumhead in association with Eustachian obstruction by no means negatives the diagnosis of otosclerosis. Otosclerosis may be complicated by middle ear suppuration.

Tuning fork tests show a negative Rinne's test and Weber's test is lateralized to the more affected ear. Audiometry confirms the presence of a conductive deafness with, usually, normal inner ear function. Sometimes there may be a diminution of inner ear function, earlier than can be accounted for by presbycusis.

There are rare cases of otosclerosis in which the focus of spongification does not affect the region of the oval window but involves the capsule of the cochlea at a separate spot. In such cases there is no paracusis, and tuning-fork tests give the results normally obtained in a case of sensorineural deafness. It has been suggested that if a young or middle-aged patient suffers from nerve deafness for which no other cause can be found, and if in her or his family there are individuals suffering from typical otosclerosis, the case should be regarded as one of spongification of the labyrinth capsule (atypical otosclerosis).

PROGNOSIS. Patients should be assured that the progress of the disease is usually very slow, that no brain disease is present, that the condition is not dangerous to life and does not result in absolute deafness. Pregnancy, illness and accident may cause a rapid increase of the deafness and tinnitus. If the affection comes on early in life, the prognosis is extremely poor from the hearing point of view.

TREATMENT. Patients with otosclerosis hear well with a hearing aid, but as treatment is usually sought in early adult life or in middle age, surgical treatment is usually preferred.

Since the widespread practice in the past 25 years of the operation of *mobilization of the stapes*, many different techniques have been described. In these operations, carried out through an aural speculum under the operating microscope, the skin of the posterior bony meatal wall is incised to form a U-shaped flap, which is elevated together with the annulus tympanicus, and the posterior half of the tympanic membrane is folded forwards, thereby exposing the tympanic cavity. A direct approach can then be made to the site of the disease (*Fig. 197*). Mobilization of the stapes was effected by applying pressure to its neck in the direction of the stapedius tendon. Successful mobilization was achieved in about one-third of cases, but re-fixation of the stapes was almost invariable.

Satisfactory improvement in hearing in more than 80 per cent of cases, with closure of the air-bone gap in the great majority, has resulted from various techniques based on complete removal of the stapes, i.e. *stapedectomy*. The stapes is replaced by a prosthesis, e.g. of vein graft and polythene tube, fat and wire, or a Teflon piston inserted into a small opening in the footplate (*Fig. 198*). The stay in hospital is short.

RESULTS. In about 80 per cent of cases hearing approaching normal can be achieved, but this will be limited by any inner ear loss. This high success rate has to be balanced against a possible operative deterioration of hearing,

sometimes total loss of hearing, in under 5 per cent of cases. Because of this risk to the hearing the operation should only be carried out on the ear with the poorer hearing.

COMPLICATION. The most important complication is loss of hearing and this may occur at the time of the operation but it may not occur until many

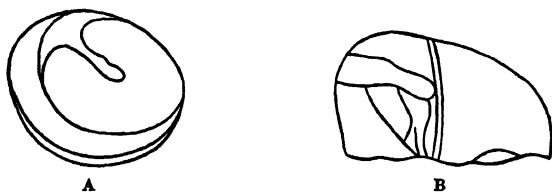


Fig. 197. A, Line of meatal skin incision. B, Exposure of the tympanic cavity.

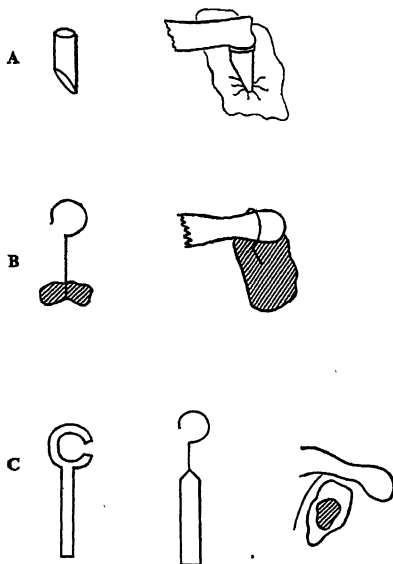


Fig. 198. A, Vein graft and polythene tube operation; B, Fat and wire stapes prosthesis; C, All-Teflon or Teflon-wire piston.

months later. For this reason operation on the second ear should only be considered after at least 6 months, and many surgeons believe that operation on the second ear should never be performed. Sudden hearing loss is particularly liable to occur after sudden changes in pressure, and patients should avoid diving and only fly in pressurized aircraft.

CHAPTER 70

CONDITIONS PRODUCING VERTIGO

MENIÈRE'S DISEASE

Menière's disease is characterized by deafness and tinnitus, as well as vertigo, loss of balance, nausea, vomiting and nystagmus, and thus involves both the cochlear and vestibular apparatus.

As the lymphatic spaces of the inner ear are continuous, it seems almost impossible to conceive of an isolated affection of the cochlear or vestibular apparatus. On the other hand, the cochlear and vestibular nerves may be affected separately by toxins with a specific affinity for one or the other division. Vertigo has been defined as a false sense of orientation of ourselves in relation to our environment. The patient feels 'as if' he were moving, or 'as if' his surroundings moved, while realizing that such interferences are really erroneous. If the attack is severe the patient staggers, and unless he can grasp some fixed object he may fall, but he does not become unconscious.

AETIOLOGY. It has been shown that there is a distension of the endolymphatic system in Menière's disease. This has come to be regarded as being due to recurring failure of the regulating mechanism concerned with the production and/or disposal of endolymph. However, the precise cause of the hydrops has not yet been determined. The numerous theories may conveniently be grouped as: focal infection; allergy; vasomotor; physical, i.e. increased endolymphatic tension *per se* from distortion of the endolymphatic system or rupture of some part of the system; biochemical, which may also be concerned with the mixing of the endolymph and perilymph due to rupture of the endolymphatic membrane. Vasomotor theories are probably the most generally acceptable, but the cause of the condition is speculative.

SYMPTOMS. The outstanding features are vertigo, vomiting, tinnitus and deafness. The onset of the giddiness is sudden, usually without warning, and may render the patient completely helpless within seconds of the onset. The patient may fall if support is not at hand, and may injure himself. Vomiting may accompany the dizziness or may follow it. There is frequently a feeling of tension in the head or tinnitus during the attack, and this passes off afterwards. Similarly deafness may occur during an attack, but with recurrence of the attacks deafness becomes established, and is progressive in most cases. It is characteristic that the attacks frequently waken the patient from sleep in the early morning. Between attacks clinical and cochlear examination may be completely negative, and the diagnosis may have to be assumed after a careful consideration of the history.

The typical attack may be modified in that instead of vertiginous episodes there may be a constant sense of imbalance with occasional exacerbations

and periodic increases in the deafness with slight nausea only. Fullness in the ear and suboccipital headaches are not uncommon features. Diarrhoea has been noted during the first attack and it may recur on each occasion.

CLINICAL FEATURES. During the attack the patient is completely disorientated, unable to stand or to do anything for himself. Nystagmus is present, and spontaneous past-pointing and falling may be elicited. There is a diminished hearing response in the affected ear, and this is always a sensorineural deafness, while distortion of sound (diplacusis) is not infrequent.

DIAGNOSIS. Diagnosis must be made from many other conditions affecting the labyrinth and cerebellum, and, in particular, an acoustic neuroma must be considered. Some conditions causing vertiginous symptoms are mentioned later in this chapter. Full clinical examination must be carried out, and any source of sepsis noted and corrected. All cochlear tests, Rinne, Weber, audiometry, etc. and vestibular testing by caloric studies and electro-nystagmography are performed. In the early case, between attacks, no abnormality may be found, but, when present, the most common abnormality is canal paresis on the affected side on caloric testing. The audiogram may be normal, but usually a slight deterioration may be found in one ear, and when the disease has progressed there is an increasing sensorineural loss of the flat or low tone type, as compared with the steep upper tone fall of traumatic or senile nerve deafness. Recruitment is present, and must always be tested for, and speech discrimination is notably reduced. When nystagmus is seen it is markedly rotatory and is to the unaffected side.

In advanced Menière's disease the acute symptoms frequently disappear, leaving an imbalance which may be constant or may recur at intervals without nausea. In some instances there is a progressive loss of balance over days or weeks with increasing deafness and headache which terminates with a paroxysm of vertigo, to be followed by immediate improvement in the hearing and other symptoms (*Lermoyez syndrome*). The occurrence of associated migraine is not unknown, while an anxiety state is understandably and quite frequently a feature of considerable significance.

PROGNOSIS. This depends upon the response to the various forms of treatment. If treatment does not control the attacks the outlook for the affected ear is bad. At the same time, remission occurs so frequently that it is difficult to be precise in prognosis after one attack. The disease may be bilateral in as many as 20 per cent of cases, and under such circumstances the outlook is unpleasant if treatment does not succeed, for prolonged invalidism may lead to profound deafness.

TREATMENT. Many cases can be controlled by antihistamine labyrinthine sedatives such as prochlorperazine maleate (Stemetil), cinnarizine (Stugeron) or promethazine theoclate (Avomine), while betahistine hydrochloride (Serc) or Lipoflavonoid, a compound containing choline bitartrate and other drugs, have their advocates. Because many of these patients are anxious they may be helped by sedatives or tranquillizers. Alternatively, an attempt may be made to improve the blood supply to the inner ear. Nicotinic acid has been widely used, but thymoxamine (Opilon) appears to be as effective, particularly in those cases where hearing is fluctuating. A combination of these treatments will control the symptoms in the majority of cases. Attempts to reduce the labyrinthine hydrops by fluid and salt restriction have been

widely advocated, but it is an unpleasant regime which should be reserved for cases uncontrolled by the methods described. One way and another, medical therapy adequately controls the condition in 80 per cent of cases.

During the acute attack sedation is essential, and vomiting may necessitate intramuscular administration. Among the drugs commonly used are promethazine theoclate (Avomine), prochlorperazine maleate (Stemetil), chlorpromazine hydrochloride (Largactil) and promethazine hydrochloride (Phenergan), while phenobarbitone and hyoscine are effective alternatives. If circumstances are favourable stellate ganglion block may be effective in severe cases.

In unilateral cases, when medical treatment has failed, surgical destruction of the affected labyrinth is the most certain method of controlling the symptoms, but it results, of course, in loss of hearing in that side. It is indicated where the hearing is already poor, and if the patient is having difficulty in maintaining a useful working and social life. If the hearing is still useful selective destruction of the vestibular labyrinth may be achieved by using ultrasound to the affected horizontal (lateral) semicircular canal. This method may also be used in bilateral cases. Alternative operations are decompression of the endolymphatic sac, division of the vestibular nerve in the internal auditory meatus and stellate ganglionectomy.

ALLIED DISORDERS

Menière-like symptoms may be produced by a variety of conditions which should be considered in any differential diagnosis. They include: a plug of wax; Eustachian tubal obstruction; otitis media, catarrhal or suppurative; circumscribed labyrinthitis; purulent labyrinthitis; labyrinthine haemorrhage in leukaemia, haemophilia, etc.; spasm of the internal auditory artery; toxic neuritis from excess of alcohol or tobacco, or following a septic infection in the teeth, tonsils, sinuses or the genito-urinary tract; drug toxicity, e.g. from salicylates, quinine, ototoxic antibiotics, etc.; syphilitic disease of the ear; allergy with urticaria, angioneurotic oedema, etc.; tumour of the eighth nerve or of the cerebellopontine angle; anaemia of the brain from haemorrhage; endocrine disorders; vascular spasm in cerebral arteriosclerosis; localized meningitis in the posterior fossa; thrombosis of the arteries supplying the pons medulla or cerebellum; syphilis of the midbrain or gumma of the cranial base; functional disturbance of the medullary nuclei or cortical centres allied to migraine, epilepsy or asthma; and cerebellar tumours. From this list it is evident that the help of a neurologist may be frequently necessary in arriving at a diagnosis.

Vestibular Neuronitis. This is characterized by severe vertigo of sudden onset without deafness or tinnitus, and with no signs of neurological involvement, but with abnormal caloric responses. It is frequently preceded by a mild febrile illness and is usually thought to be of an infective, possibly virus, origin. It is sometimes called *epidemic vertigo*. It may be slow to resolve but symptomatic recovery is the rule, and treatment is merely symptomatic.

Positional Nystagmus. There are two types described. The *benign paroxysmal* type which is associated with degenerative changes in the utricle and is characterized by the occurrence of vertigo and nystagmus with the head in a particular position. The condition has certain features—the nystagmus

THE EAR

occurs after a latent period; the nystagmus is directional according to the head position; and the nystagmus is fatiguable. Reassurance is required, and the patients learn to avoid the position which stimulates the vertigo. The *central type*, which is sometimes called *malign* or *malignant*, may occur in association with tumours, either primary or secondary, in the posterior cranial fossa, with disseminated sclerosis or with vascular lesions. There is no latent period before nystagmus appears, the direction varies and the nystagmus persists and is not fatiguable.

Vertebrobasilar Artery Ischaemia. This may produce vertigo as the main symptom, and is associated with black-outs. The vertebrobasilar artery is compressed by a lesion in the cervical spine, notably spondylosis, and vertigo results from movement of the head, either rotation or extension. Treatment is that of the cause, and the wearing of a cervical collar often brings relief.

Posterior Inferior Cerebellar Artery Thrombosis. The onset of this condition is associated with severe vertigo having features suggestive of labyrinthine origin. The development of ipsilateral cerebellar signs and a Horner's syndrome, together with a contralateral hemi-analgesia, indicates the true nature of the condition. Deafness may or may not be found.

CHAPTER 71

MALIGNANT TUMOURS OF THE EAR

EXTERNAL AUDITORY MEATUS

Tumours in this region constitute a relatively small proportion of the total number of tumours associated with the ear, only some 20 per cent being found confined to the meatus. *Squamous epithelioma* begins as a small ulcer, covered by a horny layer, usually in the cartilaginous part of the meatus near its junction with the bony portion. The patient complains of considerable discomfort and irritation; later of severe pain, worse at night; and of scanty serosanguineous discharge. If a pledget of cotton-wool, soaked in a solution of sodium bicarbonate, is applied to the lesion the horny covering is easily removed and the underlying ulcer exposed. Even in the case of a small growth, operation should involve complete removal of the cartilaginous and bony meatus and the resulting cavity is lined by a skin graft. In advanced cases with occlusion of the external meatus by a fungating growth accompanied by haemorrhage, foetor, excruciating pain, and facial paralysis operation must of necessity be extremely radical and followed by an intensive course of radiotherapy. Cancer limited to the external meatus offers a fairly reasonable prognosis.

MIDDLE EAR

Malignant disease rarely affects the middle ear although both carcinomata and sarcomata are occasionally met, the former in the middle-aged and elderly, while sarcoma is most frequent in children. In either case there is, as a rule, a history of chronic otorrhoea. Cancer of the middle ear is difficult to diagnose from epitheliomata beginning in the deeper part of the external meatus because of the subperiosteal space of the posterior meatal wall being in anatomical continuity with the submucous space of the tympanum. Malignant disease is generally associated with severe pain in the ear, copious and generally very foetid bloodstained discharge, and exuberant granulations which bleed readily and recur rapidly after removal. Facial paralysis is frequently an early sign, but the cervical lymph glands are only involved at a late stage. Labyrinthine symptoms such as giddiness and nausea may be present. Death takes place from general exhaustion or from a chest complication. Direct extension to the brain is common. Carcinoma is occasionally found to occur in long-standing radical mastoid cavities.

DIAGNOSIS. When malignant disease is suspected, e.g. when the granulations recur rapidly after removal in a patient past middle life, the diagnosis must be confirmed by biopsy.

THE EAR

PROGNOSIS. This is bad in the majority of patients, although freedom from recurrence may occur for long periods following efficient treatment.

TREATMENT. Treatment is by a combination of surgery and radiotherapy. The surgery consists of a radical mastoid operation with removal of all malignant tissue, sacrificing the facial nerve and labyrinth if necessary. The patient's best chance lies in a bold concerted attack by both surgeon and radiotherapist acting in close accord.

TUMOURS OF THE GLOMUS JUGULARE

The glomus jugulare is one of the components of the chemoreceptor system. When it becomes involved by tumour it is locally invasive but very rarely forms metastases. The growth of the tumour is insidious at first and slow. It invades the middle ear, but backward extension is common with destruction of the petromastoid bone. It is a disease of the middle-aged and elderly. Females are more commonly affected than males (6 : 1). The true nature of these tumours is very apt to be overlooked.

SYMPTOMS. The earliest symptom is pulsating tinnitus. A bloodstained discharge from the ear occurs when the tumour breaks out through the drum. It may be accompanied by otalgia varying in intensity but possibly severe. Complete deafness on the affected side is the rule, while tinnitus and vertigo may prove very distressing. In the more advanced cases facial paralysis is present.

APPEARANCES. Before the growth has eroded the drumhead a cherry-coloured swelling may be seen through the tympanic membrane. Should this appearance be present a Siegle's speculum is inserted firmly into the external meatus and when pressure is raised the mass behind the drumhead is seen to pulsate and as pressure is further increased the pulsation ceases and the mass looks avascular. On gradual release of the pressure the reverse appearances take place. More often these tumours present as a fleshy looking polypus growing from the middle ear and it is only on instrumentation during examination or on removal that massive bleeding takes place and draws attention to the true nature of the growth.

DIAGNOSIS. Diagnosis is confirmed by biopsy, where the appearances are of a duplication of chemoreceptor tissue, complicated by variable combinations of haemorrhage, inflammation, degeneration, fibrosis and epithelial accompaniments. Involvement of any of the last eight cranial nerves may be demonstrated.

TREATMENT. In very early cases excision may be possible, but most cases will be treated by radiotherapy, which reduces the vascularity of the tumour, delays its spread and occasionally cures the condition.

CHAPTER 72

THE LABYRINTH AND THE EIGHTH NERVE

TRAUMATIC AFFECTIONS OF THE AUDITORY NERVE AND LABYRINTH

Direct Injury. The labyrinth may be affected as the result of direct injuries by missiles or by the passage of a sharp implement, such as a knitting-needle, through the external auditory meatus and the oval window, into the inner ear. Deafness, giddiness and nausea supervene at once, facial paralysis is also met with, and acute labyrinth suppuration may result. The local treatment is the same as in the case of injuries to the middle ear. Rest in bed is indicated as long as the giddiness lasts and antibiotics should be given in full doses.

Indirect Injury. *Labyrinthine concussion* followed by sensorineural deafness can be caused either by transmission of the effect of a blow on the head or by the sudden alteration in atmospheric pressure from an explosion. Disturbance of vestibular function may also result from such injuries (see 'Explosion' Deafness, p. 386). Examination of temporal bones from soldiers who died after exposure to severe concussion shows rupture of the tympanic membranes and haemorrhage into the middle ear, with slight haemorrhages into the scala tympani in the region of the round window and basal coil of the cochlea; also haemorrhage at the fundus of the internal auditory meatus. The nervous elements of the cochlea show degenerative changes and Corti's organ has a ghost-like appearance (*Fig. 199*).

Fractures of the base of the skull involving the temporal bone are followed by deafness which may be permanent.

Dislocation of the incus or malleus, resulting in the interruption of the ossicular chain, may be the essential cause of such deafness. The middle fossa is most frequently involved in fractures of the base of the skull and this is due to the line of weakness which exists by the union of the basioccipital and basisphenoid from the petrotympanic fissure to the foramen lacerum. The Eustachian tube, canal for tensor tympani, tympanum, and tympanic antrum are intimately connected with this line.

Fractures of the temporal bone are divided into two main groups, longitudinal and transverse, while in severe injuries a combination of these may occur. The *longitudinal fracture* is the more common. The fracture line runs either from the squamous portion medially, involving the roof of the external auditory meatus, the tympanic ring and tegmen tympani; or from the parietal bone across the upper part of the mastoid process to the tegmen. From the tegmen the line follows the anterior aspect of the petrous pyramid and ends in one of the foramina of the middle cranial fossa. The tympanic membrane is generally torn and there is bleeding from the ear. The internal

ear, however, remains intact, the deafness being of middle ear type. In *transverse fractures* the line crosses the petrous bone at right angles to its long axis, i.e. it traverses the floor of the skull anteroposteriorly. It may cross the internal acoustic meatus or, if situated more laterally, will involve the internal ear, in which case the medial wall of the middle ear may be fractured. The tympanic membrane remains intact, so that there is no




Fig. 199. Injury to left ear due to explosion of rifle grenade. Horizontal section. 1, Rupture of drum-head, with blood clot on anterior margin; 2, Scala tympani just internal to round-window membrane, with thin layer of haemorrhage on the walls; 3, Fundus of internal meatus with haemorrhage.




Fig. 200. Radiograph demonstrating a longitudinal fracture of the right temporal bone.

haemorrhage from the external meatus, but there is loss of internal ear function. Thus in the typical longitudinal fracture the middle ear is opened, while in a transverse fracture the inner ear is involved.

A peripheral paralysis of the facial nerve has been recorded in about 46 per cent of fractures of the skull and almost all the cases which survive are associated with middle ear deafness. Therefore the prognosis of cases in which the labyrinth capsule is involved may be extremely grave.

In all cases of suspected fracture a thorough examination of the ear, nose and throat should be carried out. Radiographic examination of the temporal bones should be undertaken in the hope of demonstrating the position and extent of the fracture (*Fig. 200*). Failure to do so, however, does not exclude its presence. Repeated examinations employing different positions will increase the frequency of positive findings. Tomography is often required to

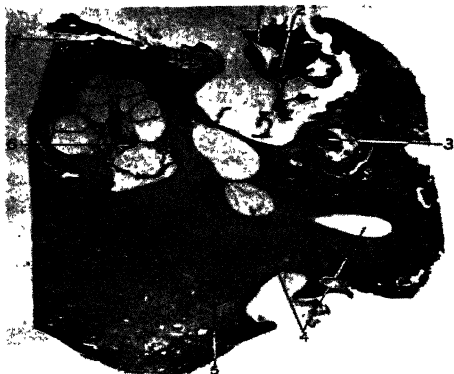


Fig. 201. Fracture of cranial base injury to labyrinth capsule. Horizontal section through right ear. 1, Malleus; 2, Incus surrounded by blood clot; 3, Facial nerve; 4, The two ends of the posterior vertical canal; 5, Haemorrhage in branch of vestibular nerve to ampulla of posterior canal; 6, Haemorrhage in fundus of internal meatus; 7, Haemorrhage in Eustachian tube. ($\times 3$.)

demonstrate the fracture. Giddiness and tinnitus may accompany the deafness, but the giddiness usually disappears after a time. While bleeding from the external meatus is frequently met with, in rare cases the drumhead remains intact and presents a blue-black appearance (haematotympanum). If blood alone is present in the meatus, the prognosis from the otological point of view is better, because it is probable that only the walls of the middle ear have been involved (*Fig. 201*). If, however, both blood and cerebrospinal fluid flow from the ear, the labyrinth capsule or dura mater or both have been injured (*Fig. 202*), and, if due to the former, permanent deafness will result if the patient recovers. In many cases infection is superadded to the injury—either from the nasopharynx through the auditory (Eustachian) tube or from the external meatus—with the result that purulent leptomeningitis may supervene (*Fig. 203*). Patients who have recovered from fracture of the temporal bone are predisposed, if they get an acute otitis media, to suffer from meningitis, the infection in these cases passing to the meninges along the line of the old fracture.

TREATMENT. The general treatment of fracture of the base of the skull need not be discussed here. If there is no bleeding from the ear the meatus, if healthy, should be left severely alone. At a later stage surgical exploration of the middle ear may be indicated and if dislocation of an ossicle is confirmed re-establishment of the ossicular chain may be effected. If haemorrhage is profuse the meatus should be carefully cleansed and a strip of

sterile ribbon gauze inserted. Antibiotics should be given in full doses. *The meatus should not be syringed.* If middle ear suppuration had been present previously, and if cerebrospinal fluid is noted along with blood in the meatal discharge following a fracture of the base, it may be considered advisable



Fig. 202. Fracture of cranial base with injury to labyrinth capsule. Horizontal section through right ear just above round window. 1, Fracture of promontory; 2, Both peri- and endolymph spaces of posterior canal contain blood; 3, Vestibule with slight haemorrhage; 4, Line of fracture reaches the canal from nerve to ampulla of posterior semicircular canal; 5, Basal coil of cochlea with haemorrhage in all three scalae. ($\times 5$.)




Fig. 203. Male, aged 44, fell striking the right side of his head. Concussion and bleeding from right ear and also from mouth. Severe headache and feeling of rotation about a vertical axis. Right ear quite deaf. Nausea but no vomiting. Spontaneous nystagmus to left (sound) side. Patient fell to right and showed a pointing error to right. Temperature 105° . Pulse only 72. Kernig's sign present. Facial paralysis (right). *Post mortem*—Purulent leptomeningitis at base of brain. 1, Fracture; 2, Exudate in vestibule; 3, Fracture of bony spiral lamina; 4, Scala tympani; 5, Fracture of tympanic floor; 6, Exudate in tympanum; 7, Perforation in drumhead; 8, Fracture of meatal wall.

to facilitate free drainage, even to the extent of performing the radical mastoid operation with exposure of the dura mater along the line of fracture. **'Explosion' Deafness.** Both cochlear and vestibular organs may be damaged by explosion or gun fire but the vulnerability of the cochlea is much greater.

During the wars many cases of labyrinthine deafness due to high explosives came under observation. Sometimes the patients suffered from shock and presented all the signs of sensorineural deafness. As a rule the deafness and tinnitus diminish in the weeks following the injury and, when present, vertigo and disturbances of equilibrium disappear in a few weeks. A degree of deafness usually remains sometimes with severe loss of the higher frequencies. Such injuries are frequently accompanied by rupture of the tympanic membrane (*Figs. 199, 204*). *Treatment* consists of complete rest and

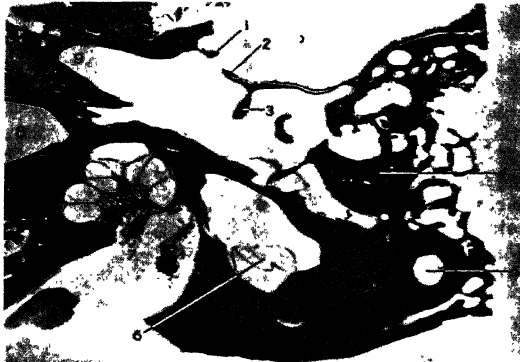

Fig. 204. High-explosive shell injury of ear. Horizontal section. Shows rupture of anterior part of drumhead, with everted edges. 1, Anterior portion of ruptured drumhead (everted); 2, Posterior margin of rupture, also everted; 3, Malleus; 4, Facial nerve, with stapedius to the left; 5, Smooth end of posterior vertical canal; 6, Lower part of utricle with crista quarta; 7, Internal meatus; 8, Carotid canal; 9, Tubal part of tympanum.

administration of sedatives. In a certain number of cases a functional element is present, especially in those in which examination of the vestibular apparatus shows normal reactions. It must not, however, be taken for granted that deafness—especially when only moderate in amount—in the presence of normal vestibular responses is necessarily functional. The cochlear apparatus lies between the oval and round windows, and it is thus more sensitive to violent commotion of the atmosphere than the vestibular structures.

'Noise' Deafness. The ever-increasing din to which most of us are exposed in everyday life constitutes a potential hearing hazard, though individuals vary greatly in their subjective response to noise. Too little attention is still paid to the problems of noise control. Constant exposure to loud noises is a well-known cause of labyrinthine deafness. It is met with in boiler-makers, coopers, factory workers and service personnel. Miners and others who use pneumatic or electric drills are also affected. The deafness is due to degeneration affecting Corti's organ. Most observers hold that the pathological condition is an exhaustion atrophy from over-excitation affecting primarily that part of the cochlear duct which corresponds to the prevailing sound. The deafness increases gradually and is not as a rule accompanied by tinnitus. Men who use a sporting gun occasionally suffer from deafness in one ear—as a rule the left, as they usually shoot from the right shoulder.

In many cases such as those exposed to aircraft engine noise, a characteristic hearing loss is observed at a frequency of 4000 c.p.a. which apparently bears no relation to the frequencies of greatest intensity produced by aircraft. Such loss may be reversible if continued prolonged exposure is avoided. It would appear that the ears of some persons are more easily fatigued and more susceptible to acoustic trauma than those of others, and it has been suggested that the relation between liability to auditory fatigue and traumatic deafness might be employed as a test for predisposition to the latter. There is no indication that ultrasound constitutes a hazard to hearing.

TREATMENT. Treatment in all these cases is unavailing. Further trauma should be avoided whenever possible, but as a prophylactic measure ear protectors should be worn during exposure to the noises. The great difficulty is to get individuals to use protectors regularly. Artillerymen may wear obturators which reduce concussion during gunfire but permit of hearing instructions. It must be admitted, however, that such measures do not afford really adequate protection.

Caisson Disease. Caisson workers are liable to nerve deafness if compression or decompression is carried out too rapidly. The symptoms manifest themselves after the individual has left the caisson; the onset is acute, the deafness being accompanied by giddiness, tinnitus and vomiting. The pathological changes are due either to haemorrhage into the labyrinth or to air emboli forming in the blood and reaching the labyrinth. Airmen, mountaineers and divers are liable to similar lesions.

NEUROLABYRINTHITIS

Labyrinthitis secondary to middle ear inflammation has already been dealt with.

Meningitic Neurolabyrinthitis. Although the majority of cases of labyrinthitis result from middle ear suppuration, a considerable minority are due to leptomeningitis. Meningitic neurolabyrinthitis is a frequent cause of deafness, e.g. deafness after epidemic cerebrospinal or tuberculous meningitis is due to this cause. Measles and pneumonia may also be followed by meningitis and secondary neurolabyrinthitis. In acquired syphilis, and mumps, leptomeningitis is sometimes met with, and is associated with inner ear deafness, which is probably to be explained by neuritis or neurolabyrinthitis. Certain cases of deafness after influenza may also be of meningitic origin. A systemic infection probably forms the connecting link between the primary disease and the onset of meningitis. Meningitic neurolabyrinthitis is generally, but by no means always, bilateral. The onset is usually sudden. Irritative symptoms, such as tinnitus, nystagmus and giddiness, are present but may not be observed owing to the comatose condition of the patient. In epidemic cerebrospinal meningitis and parotitis, deafness, if it occurs, usually comes on early in the course of the disease. Deafness due to meningitic neurolabyrinthitis may be associated with other metastatic lesions. The infection usually passes along the subarachnoid space from the base of the brain into the internal acoustic meatus, and then along the nerves and vessels to the labyrinth. In some cases the perilymphatic aqueduct is the route of invasion, while in others both paths may be involved. As a

rule both the cochlear and vestibular apparatus are affected. Sometimes the cochlear apparatus alone is involved; rarely do we have a more or less isolated affection of the vestibular apparatus. The pathological changes producing the deafness may be: (1) Hydrocephalus. (2) Changes in the walls

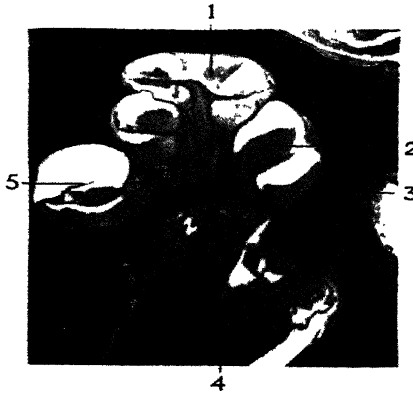


Fig. 205. Meningitic neurolabyrinthitis. Pus is invading the cochlea along the branches of the cochlear nerve from the internal meatus. 1, Purulent exudate in helicotrema; 2, Exudate in scala vestibuli; 3, Same in scala tympani; 4, Cochlear nerve with haemorrhagic purulent exudate around; 5, Endosteum detached from wall of scala tympani of basal coil (artefact).

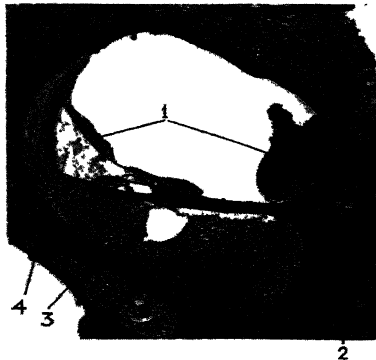


Fig. 206. Meningitic neurolabyrinthitis following pneumonia. 1, Purulent exudate in scala vestibuli—to the left it is lying on the upper surface of Reissner's membrane; 2, Spiral ganglion infiltrated with pus; 3, Scala tympani full of pus; 4, Cochlear canal with fibrinous and slightly purulent exudate.

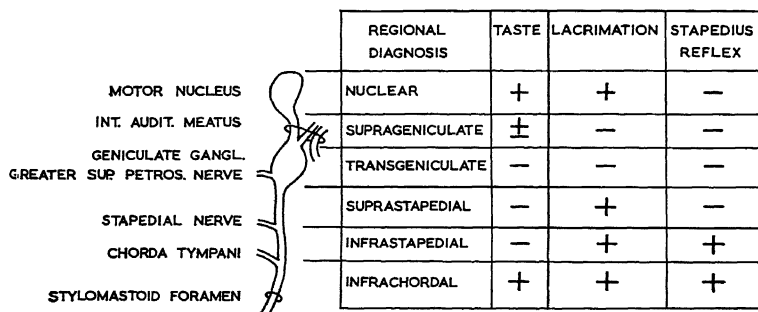
of the fourth ventricle. (3) Purulent infiltration of the eighth nerve, with subsequent descending neuritis accompanied by atrophy of the spiral ganglion. (4) Purulent labyrinthitis (*Figs. 205, 206*) which, if the patient lives long enough, is followed by the formation of granulation tissue and, later,

of new connective tissue and bone in the hollow spaces of the labyrinth. The resulting deafness is complete and permanent in the ear (or ears) affected.

After recovery the vestibular symptoms pass off rapidly in adults, but in young children they may last as long as 1 year. In cases of sudden nerve deafness, with or without vestibular symptoms, lumbar puncture should be performed and the cerebrospinal fluid examined chemically and microscopically. Serological tests for syphilis should be carried out. Repeated lumbar punctures are of use in treatment, especially in cases of deafness due to hydrocephalus.

HERPES ZOSTER OTICUS

Herpes zoster affecting the ear, or *Ramsay Hunt's syndrome*, is a rare disease which is due to inflammation of the geniculate ganglion of the facial nerve, the causative agent of which is probably a filterable virus. Hunt's concept of the geniculate ganglion as the site of inflammation has, however, been challenged. The facial nerve is a mixed nerve, having a sensory root (*pars intermedia*) and ganglion (geniculate) similar to the sensory ganglion of the



The diagram shows the peripheral course of the facial nerve from the motor nucleus to the stylomastoid foramen. Key anatomical points labeled are: MOTOR NUCLEUS, INT. AUDIT. MEATUS, GENICULATE GANGL., GREATER SUR. PETROS. NERVE, STAPEDIAL NERVE, CHORDA TYMPANI, and STYLOMASTOID FORAMEN. A table to the right classifies lesions based on these points and their effects on taste, lacrimation, and the stapedius reflex.

	REGIONAL DIAGNOSIS	TASTE	LACRIMATION	STAPEDIUS REFLEX
MOTOR NUCLEUS	NUCLEAR	+	+	-
INT. AUDIT. MEATUS	SUPRAGENICULATE	±	-	-
GENICULATE GANGL. GREATER SUR. PETROS. NERVE	TRANSGENICULATE	-	-	-
STAPEDIAL NERVE	SUPRASTAPEDIAL	-	+	-
CHORDA TYMPANI	INFRASTAPEDIAL	-	+	+
STYLOMASTOID FORAMEN	INFRACHORDAL	+	+	+

Fig. 207. Classification of peripheral facial nerve lesions based on the anatomy and functions of the facial nerve. (After Jepsen.)

spinal nerves. Fibres of general sensation emerge at the stylomastoid foramen and are distributed to a portion of the auricle, external auditory meatus and tympanic membrane.

The peripheral course of the facial nerve can usefully be divided into four parts (Fig. 207): (1) Suprageniculate, where lesions will be associated with absence or diminution of tears due to involvement of the secretory fibres of the greater superficial petrosal nerve, but no loss of taste; (2) Transgeniculate, where lesions will result in loss of taste of the anterior two-thirds of the tongue and absence of tears; (3) Between the geniculate ganglion and the point of exit of the chorda tympani nerve, where a lesion will result in loss of taste, but tears will be present; (4) Below the exit of the chorda tympani nerve, where lesions will not involve taste fibres, but associated paralysis and normal tear secretion may result in epiphora. The recent

introduction of the acoustic impedance meter provides a means of determining the presence or absence of an acoustic stapedius reflex. If this reflex is absent the lesion is above the point of exit of the nerve to the stapedius muscle, while if it remains present the lesion is below that level.

SYMPTOMS. Severe neuralgic pain in the ear precedes the herpetic eruption on the auricle (*Fig. 208*), external auditory meatus and tympanic membrane, which is commonly accompanied by facial paralysis of lower neurone type and sometimes homolateral loss of taste of the anterior two-thirds of the

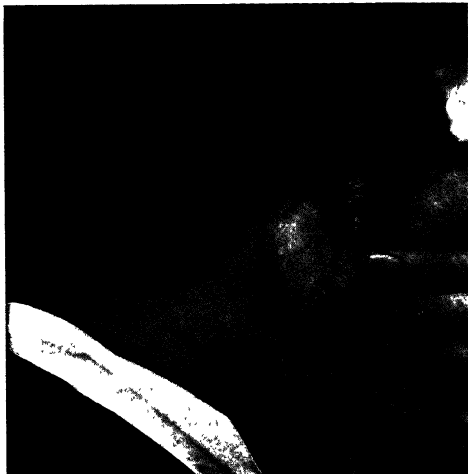

Fig. 208. Herpes zoster oticus.

tongue. Acoustic and vestibular complications are not infrequent, due to extension of the inflammatory process to the adjacent eighth nerve and its acoustic and vestibular ganglia. These vary from a slight diminution of hearing to a severe form with tinnitus, deafness and vertigo with nausea, vomiting and nystagmus. An increase of lymphocytes in the cerebrospinal fluid has been observed. The acute features of the disease usually run a rapid course, but resolution of the associated facial palsy may be slow, while some hearing impairment may be permanent.

TREATMENT. Analgesics are called for and even morphine may be indicated. The skin eruption should be kept dry. Suggestions regarding treatment have included vitamin B₁ and cortisone, while chloramphenicol has a specific effect on some viruses. After the acute stage has subsided, massage, exercises and electrotherapy may be given for the facial paralysis.

DEAFNESS DUE TO DRUGS

It is well known that *quinine* and the *salicylates* may cause deafness, which is generally accompanied by tinnitus and sometimes by vertigo. In people

who suffer from disturbance of hearing after very small doses of quinine the trouble is probably due to an idiosyncrasy of an anaphylactic nature. Changes in the cells of the spiral ganglion have been found in quinine poisoning. *Mercury* and *aspirin* may cause neuritis of the eighth nerve. In rare cases, *tobacco* and *alcohol*, if used to excess, may cause impairment of the hearing. It is accordingly advisable to prohibit their use in cases of nerve deafness in which no other cause can be ascertained and in which excessive consumption of alcohol or tobacco is suspected or admitted. Abstinence is frequently followed by improvement in hearing.

The *organic arsenical drugs* may have a secondary action on the eighth nerve, due to a Herxheimer reaction. The cochlear branch is affected four times as often as the vestibular branch, but both portions may be involved. In some cases the changes are not limited to the eighth nerve, but also involve other cranial nerves.

Lead poisoning may give rise to nerve deafness and vertigo. Certain *hair dyes* contain a labyrinthine poison—paraphenylenediamene—which causes headache, vertigo, deafness and tinnitus. The symptoms clear up when the dye is stopped.

The number of *ototoxic antibiotics* is now quite considerable. *Streptomycin*, particularly if given in large doses and over a prolonged period, not infrequently causes vertigo and changes in the caloric reactions. The hearing may occasionally be affected. On the other hand, deafness occurs much more frequently when *dihydrostreptomycin* is administered and its use should be avoided as far as possible. The list also includes *neomycin*, *kanamycin*, *vancomycin*, *viomycin* and *ristocetin*.

Deafness has recently been found in subjects with renal failure treated by haemodialysis combined with the use of the antiheparinizing agent *polybrene*. It may also result from the use of some diuretics.

SENILE DEAFNESS (PRESBYACUSIS)

In old age the hearing frequently becomes impaired to some extent. This impairment is characterized by a rise in threshold for the higher frequencies, a lowering of the upper tone limit, and the presence of loudness recruitment (patients may remark that they can no longer hear the birds whistling—while raising the voice, because of their inability to understand, will sometimes elicit the response 'don't shout'). Bone conduction is shortened and Rinne's test is positive. The pathology of senile nerve deafness is said to consist of degeneration of the cochlear ganglion cells and hair cells of Corti's organ. The onset of the deafness is generally very insidious and the progress slow. A good deal of what is usually regarded as 'deafness' in old people is really due to the fact that they do not 'comprehend' what is said as well as they did in childhood, youth and middle age, i.e. there is a *loss of discrimination*. Lack of concentration along with a slowing down of the mental processes must also be taken into account. Old people suffering from nerve deafness often talk in a loud, unpleasant tone—in marked contrast to the low, well-modulated voice of cases suffering from otosclerosis. Hearing aids are often of benefit in senile deafness, but they are frequently not tolerated. Some assistance may be obtained by placing the hand behind the auricle and holding it forward so as to collect the sound waves.

DEAFNESS DUE TO MUMPS, ETC.

Mumps may produce labyrinthine deafness. The pathology of the condition is not known with certainty. It may be due to meningitic neurolabyrinthitis or to metastatic infection of the cochlea by way of the blood stream. Petechial haemorrhages in the medulla in the region of the cochlear nerve have been recorded. The vestibular reactions may be normal although there is complete deafness in the affected ear. In half of the cases one ear only is affected. Deafness usually comes on about the fourth or fifth day of the disease, sometimes later, and does not pass off.

Influenza is sometimes followed by tinnitus and nerve deafness, which is probably due to toxic neuritis. Isolated affection of the vestibular nerve may be associated with the sudden onset of vertigo, vomiting and rotatory nystagmus. Both parts of the eighth nerve may be involved. The symptoms may persist for weeks or even months.

Nerve deafness may occur in *typhus fever*, and it is sometimes an early feature of *disseminated (multiple) sclerosis*, in which defects of the auditory field comparable to defects in the ocular field have been observed.

DEAFNESS DUE TO VITAMIN DEFICIENCIES

The nervous lesions, including degeneration of the cochlear and vestibular divisions of the eighth nerve, occurring in young, growing, experimental animals *deprived of vitamin A*, but provided with vitamin D, have been explained on the basis of disproportionate growth of the nervous and skeletal systems.

Vitamin B Complex. Deafness and vestibular disturbance were a frequent occurrence in association with the severe nutritional disorders of the nervous system which occurred in prisoners of the 1939-45 war. While there is ample evidence that lack of the vitamin B complex leads to disturbances of the nervous system, the question of which particular member or group of members, known or unknown, is concerned with these disorders remains uncertain.

SENSORINEURAL DEAFNESS OF DOUBTFUL ORIGIN

It must be admitted that in many cases of nerve deafness, whether of sudden or gradual onset, the cause cannot be ascertained. In cases of sudden onset, vasospasm or thrombosis involving the internal auditory artery may be responsible, while a possible virus infection should not be overlooked. Such cases should be treated as an emergency and appropriate measures may include repeated stellate ganglion block, administration of a vasodilator drug such as nicotinic acid or anticoagulant treatment. In the young or middle-aged serological examination of the blood for syphilis and cerebrospinal fluid is advised.

Certain cases of otosclerosis, in which the focus of spongification affects the capsule of the cochlea in a region away from the oval window, present the signs and symptoms of sensorineural deafness (*atypical otosclerosis*) and not those of a middle ear or obstructive deafness. Such cases are rare as compared with those in which the deafness is of the middle ear type; but, as

otosclerosis is a very common disease, the atypical cases must amount in all to a considerable number. If sensorineural deafness begins early in life in a member of a family in which other well-marked cases of otosclerosis are present, and if there be no other probable cause for the nerve deafness, the case should be regarded as one of otosclerosis.

In certain families there is a tendency for the hearing to deteriorate before the age at which presbycusis is usually found.

TUMOURS OF THE EIGHTH NERVE

Neurofibroma of the eighth nerve arises from the neurilemma (Schwann sheath) in the most lateral part of the internal auditory meatus. It is a benign tumour which usually grows very slowly, interfering with the function of the auditory and vestibular nerves, but later occupying the cerebellopontine angle of the posterior fossa (*Fig. 209*).

Other lesions occurring in the cerebellopontine region include meningioma, angioma, epidermoid and aneurysm, but the acoustic neurofibroma is the commonest tumour found in the posterior cranial fossa.

Changes in the Labyrinth. The first stage appears to be a fibrinous exudation (choked labyrinth), with atrophy of the cochlear ganglion and Corti's organ (*Fig. 210*). Later the exudate becomes organized into myxomatous tissue, in which new bone formation may be seen.

SYMPTOMS. The age of onset is usually 30–50 years. The clinical history may be divided into three stages: (1) Initial or 'otological', in which the patient suffers from tinnitus, deafness, giddiness, loss of balance and nystagmus. This stage ends with the occurrence of headache which is worst at night. (2) Intermediate or 'neurological' stage, with headache, and involvement of neighbouring nerves, producing loss of the corneal reflex, numbness over the cheek and slight weakness of the masseter muscle on the affected side (fifth), diplopia (sixth) and facial paralysis (seventh). Later there is dimness of vision (choked disk), dysphagia and thickness of speech, with muscular hypotonia and dysdiadokokinesia on, and tendency to fall to, the side of the lesion. The so-called 'cerebellar seizures' or vagal attacks are a distressing feature. They may be preceded by giddiness, headache and dimness of vision. At first the patient is conscious during attacks, but later he is unconscious. The pupils are dilated, with stertorous breathing and rapid, irregular pulse. Jerkings of the head and extremities are followed by general rigidity. The attacks may be accompanied by vomiting. They have been attributed to excessive tension in the lateral cistern in which the tumour lies, or to compression of the middle cerebellar peduncle. (3) Terminal stage, with weakness of sphincter control, delirium, dementia, Cheyne-Stokes respiration and coma.

FUNCTIONAL EXAMINATION OF THE EARS

The Cochlear Apparatus. Sensorineural deafness varying from slight to total deafness may be found. Normal hearing is found in less than 1 per cent of proved acoustic neurofibroma. There is absence of loudness recruitment in 90 per cent of cases in which deafness is still of moderate degree. Speech discrimination is poor. Abnormalities may be demonstrated by electro-cochlegraphy and the stapedia reflex may be reduced.

The Vestibular Apparatus. Spontaneous nystagmus is usually present to both sides. It generally appears first towards the unaffected side and is followed, as the tumour progresses, by nystagmus to the side of the lesion. Positional nystagmus (non-fatiguable) has been observed in more than 50 per cent of cases. In advanced cases there is, as a rule, vertical nystagmus.

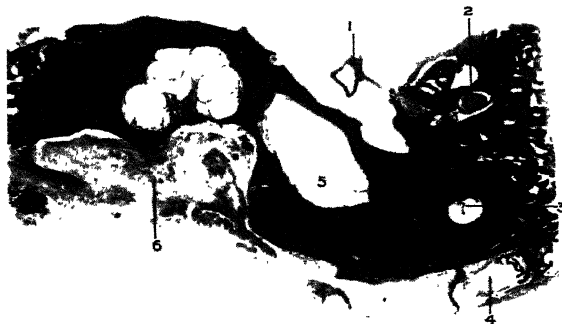

Fig. 209. Horizontal section of right ear in a case of neurofibroma of the eighth nerve. 1, Head of stapes with stapedius; 2, Facial nerve; 3, Posterior canal with haemorrhage in perilymph space; 4, Tumour; 5, Lower part of utricle; 6, Dilated internal meatus with tumour. ($\times 3$)

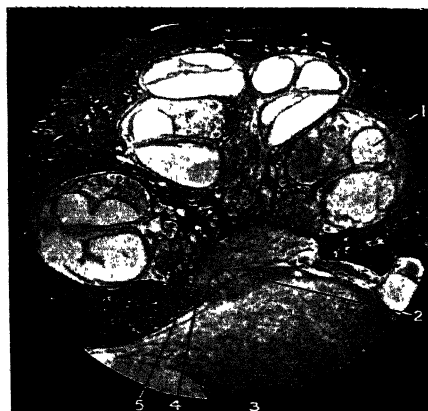

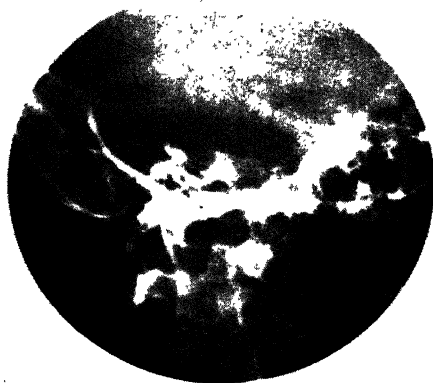
Fig. 210. Tumour of the eighth nerve. Axial section through right cochlea. 1, Dilated cochlear canal, basal coil; 2, Capsule of tumour; 3, Tumour tissue; 4, Cochlear nerve, which is compressed by tumour tissue; 5, Central canal of modiolus. Note the infiltration of the scala vestibuli and scala tympani by delicate connective tissue.

The pointing reaction is usually normal. On Romberg's test the patient usually tends to fall to the side of the lesion. The caloric tests are abnormal—and indeed are absent on the affected side—in the large majority of cases. When the cold and hot method of caloric testing is employed, abnormal results are reported to occur in all cases, by far the commonest finding being complete canal paralysis on the affected side.

DIFFERENTIAL DIAGNOSIS. If tumours of the eighth nerve are to be diagnosed at the early 'otological' stage, otologists must *thoroughly examine all cases of unilateral nerve deafness*. Radiographic examination of both temporal bones (Figs. 211, 212), including tomography, may show dilatation of the internal acoustic meatus and, less frequently, erosion of the apex of the petrous bone on the affected side. An air encephalogram is probably more informative



A



B

Fig. 211. A, Postero-anterior view showing enlargement of the right internal acoustic meatus due to neurofibroma of the eighth nerve. B, Stenver's position, right side. (By courtesy of Dr E. Samuel.)

than a ventriculogram. The intrathecal introduction of a positive contrast medium (pantopaque)—*myeloencephalography*—by outlining a filling defect in the internal acoustic meatus (Fig. 212), is of considerable value in the presence of doubtful small tumours. The protein content of the cerebrospinal fluid is nearly always raised (100–300 mg per cent).

The clinical features of an acoustic neurofibroma are in large degree also characteristic of other lesions in the cerebellopontine angle. In the latter,

however, the eighth nerve signs are usually less evident than the other neurological signs.

1. Syphilitic neurolabyrinthitis should be diagnosed by the history of syphilitic infection and the serological reactions of the blood and cerebrospinal fluid.

2. Neuritis due to toxæmia may be eliminated by a careful history of the cases and thorough physical examination. Such cases do not show complete deafness and loss of vestibular reaction.

3. Haemorrhage into the labyrinth in the bleeding diseases should be excluded by an examination of the blood.

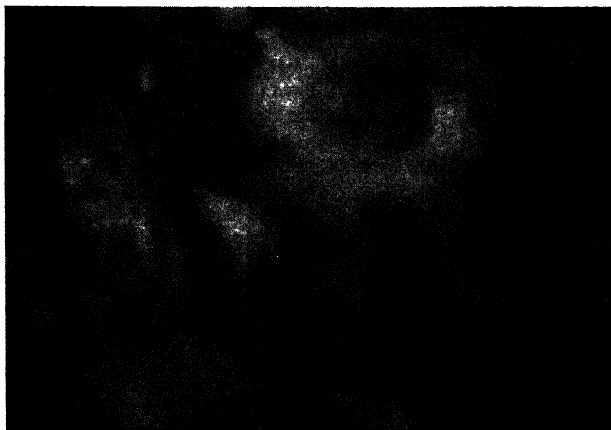


Fig. 212. Myelencephalograph demonstrating filling defect in the internal acoustic meatus due to neurofibroma. (By courtesy of Dr E. Samuel.)

4. Senile or arteriosclerotic nerve deafness is bilateral. The low tones are retained, along with the vestibular reactions.

5. Unilateral congenital deafness is rare. The vestibular reaction is present in such cases.

6. Circumscribed labyrinthitis is associated with otitis media and cholesteatoma.

7. Otosclerosis is occasionally associated with giddiness, but audiometric examination should demonstrate the conductive deafness.

8. Serous meningitis in the lateral cistern is as a rule associated with a history of otitis media and a well-marked pointing error, which is not usually found in acoustic tumour.

TREATMENT. Acoustic tumours should be dealt with by surgical removal as early as they can be diagnosed; and this signifies in the 'otological stage' of diagnosis. Four types of surgical approach are employed: (1) By way of the middle cranial fossa, for removal of tumours confined to the internal acoustic meatus and to save the hearing and the facial nerve; (2) Translabyrinthine; (3) Suboccipital; and (4) Combined suboccipital-petrosal. Small tumours may be removed by a middle cranial fossa or translabyrinthine approach with

little morbidity or mortality. A suboccipital or combined approach is required for the larger tumours.

The classic neurosurgical approach to the tumour is by way of an occipital osteoplastic flap, with bilateral suboccipital craniectomy. In the *early* case with a small tumour, complete removal can be achieved with no prospect of regrowth, although sometimes the facial nerve must be sacrificed. In *advanced* cases it is rarely possible to effect complete removal without undue risk to neighbouring structures and consequently incomplete subtotal removal is resorted to, with associated greater surgical risks and more severe postoperative residual disabilities. Being relatively slow-growing the incidence of further tumour growth after 9 years is only 20 per cent. A more common sequel (40 per cent within 2 years) is chronic progressive hydrocephalus due to adhesive arachnoiditis, provoked by proteinous transudate from residual tumour tissue into the surrounding cerebrospinal fluid.

PSYCHOGENIC DEAFNESS

Deafness may be met with in *hysteria*; it is not as a rule attended by tinnitus or giddiness. The deafness may come on without obvious cause and is subject to marked variations; it is sometimes transferred from one side to the other. The results of hearing tests repeated on several occasions vary greatly and this is a valuable diagnostic point. Further evidence of hysteria can generally be found, such as the presence of areas of anaesthesia, or the loss or impairment of smell or taste on the same side as the deafness. Sudden and complete recovery of hearing clinches the diagnosis of hysterical deafness.

Cases of *bilateral functional deafness* have been met with as the result of explosions. There is frequently an associated initial degree of organic deafness. The functional element, however, persists after the organic defect has more or less recovered. Such cases are extremely difficult to assess. Deafness may be accompanied by *mutism*. To differentiate between bilateral organic and functional deafness, the study of the voice resonance is helpful; in total deafness of organic origin, the patient's voice quickly acquires the intonation characteristic of the deaf, while in functional lesions the voice remains normal. It is important to examine the *cochleo-auricular*, *-pupillary and -palpebral reflexes*: a shrill whistle, a motor horn or a bell with a spring hammer is suddenly sounded behind the patient, who should look into the distance to avoid fixation of the pupil. If the patient hears the sound, a movement of the pinna may be noted, accompanied by contraction of the pupil and winking. Where the deafness is absolute the reflex is absent; but in partial deafness, whether organic or functional, it is usually present. If it is present, but the patient says he can hear nothing, he is probably a malingerer; but so long as he admits that he can hear something, the test does not help in distinguishing between organic deafness, functional deafness and malingering. When total deafness is not of organic origin, the vestibular reactions are, of course, normal. An unexplained discrepancy between pure-tone and speech audiograms arouses suspicion, especially when speech is better than pure-tone reception.

Attention is an active process. It may be spontaneous, as in a child, or it may be voluntary, i.e. due to training. In functional deafness both spontaneous and voluntary attention are withdrawn. In the subconscious malingerer, the

voluntary attention is in abeyance, as in a person who has to sit through a long, dull sermon. The individual does not listen, but he does not try not to listen; he hears, but does not attend. In the true malingeringer, on the other hand, not only is voluntary attention withdrawn, but the patient is in opposition and damps down even the spontaneous attention. The true malingeringer listens intently, but tries hard not to respond. He is attempting to act the part of a deaf man, and is consequently under great mental strain, from which he desires to be relieved. Time is therefore on the side of the examiner, who should never hurry. When the patient imagines the examination is finished, he lets himself go, and may often be readily caught out.

Experience has shown that when hysterical (functional) deafness is associated with mutism it requires no special treatment, as hearing almost invariably returns spontaneously when speech is restored. It is advisable to let the patient know that directly he speaks he will hear his own voice and that then he will hear everything clearly. There is rarely any difficulty in curing the mutism by simple explanation and persuasion. Uncomplicated deafness is much more difficult to treat. Hypnosis is seldom of any use, as the patient remains deaf while hypnotized. 'Fake' operations on the ear are not invariably successful, and cannot be regarded as desirable. Most cases can be cured by explanation with persuasion and re-education. The patient is made to understand by a written statement why he is deaf, and that the original cause of his deafness long ago disappeared. Since at first the deafness was organic, he could not hear, however much he listened, and consequently after a time he ceased to listen at all. He is next persuaded to listen intently, and is taught that listening is just as active a process as moving, and requires a conscious effort on his part until it becomes automatic once more. Sounds are generally heard before words can be recognized. Even when a man has apparently recovered his hearing, if caught unawares he often fails to hear.

TESTS FOR SIMULATED DEAFNESS

There are two classes of malingeringers—those who complain of: (1) *unilateral*, and (2) *bilateral* deafness. Simulation of *bilateral deafness* requires very considerable intelligence and hardihood, and consequently its detection becomes increasingly difficult. It is only by constant observation that people who simulate bilateral deafness can be detected and it is wise to admit the suspected case to hospital where he will more easily be caught off his guard, e.g. he may be awakened from sleep by a loud noise, or he may be observed listening to the radio. A possible motive should be sought for. Before commencing the tests for malingering in *unilateral* cases, it is as well to blindfold the patient.

1. If the hearing has been entirely lost on the right side, a tuning-fork placed upon the vertex of the skull should be heard on the left side. If the suspected malingeringer is now told to place the finger in his left or hearing ear, he should hear the tuning-fork in that ear even louder than before; but he will more probably say that he does not hear it at all, in which case of course, the fraud is detected.

2. Place two speaking-tubes, one in each ear of the patient. Two people now speak, one into each tube, on different subjects and at different rates. If the patient hears with both ears, he will confuse the voices and be unable to

understand either of the people talking. If he is able to hear and follow, it will indicate that he really does not hear on one side.

3. The patient closes his good ear with a finger. The surgeon now repeats words and numbers to him, at first in a low voice and then in progressively louder tones. If, when one has reached a pitch at which he *should be able to hear the words with the sound ear even though tightly occluded* he still states that he cannot hear, one knows at least that he is an intentional malingerer.

4. *Lombard's test* depends upon the fact that to the normal man the sound of his own voice is necessary to the proper regulation of its tone and intensity. The Bárány noise apparatus is adjusted in the patient's sound ear, and its machinery started in order to accustom him to its grating noise. He is given a book, and told to read aloud in his natural voice, and not to stop reading when the instrument is set in action. As soon as the noise begins, a man whose opposite ear is profoundly deaf will at once raise his voice and, if his unilateral deafness is absolute, may literally shout. The malingerer, on the other hand, claiming a one-sided deafness which is not real, will continue to read in an even tone or in a tone only slightly elevated. Many malingerers, when asked to co-operate in this test, pretend that they are unable to read. When admitted to hospital, however, they may be seen surreptitiously reading the daily papers.

5. *Teal's method*. The patient is again blindfolded, and in a friendly manner told that if he is really deaf there is no disposition to overlook it. But he is also warned that if he tries to show dishonesty he is sure to be 'tripped up'. Air-conduction is tested and, of course, is negative. The Weber test is then used, and usually (though reluctantly) he hears the fork in the deaf ear. Bone-conduction over the mastoid process is next tested, and again he admits hearing the fork. The real test is now used. After saying one wants to try the last test once more, a non-vibrating fork (or lead pencil, flat end) is placed over the process to make him think he is being tested in the same manner, but at the same time a vibrating fork is brought up close to the auricle with the other hand to test the air-conduction. If he is simulating deafness he will, of course, answer that he hears the fork, and the fact of a normal path of air-conduction is established. If he is really deaf, he will, of course, not hear the vibrating fork.

The *pure tone audiometer* facilitates detection of malingering. The sounds of the audiometer being loud enough to carry to the opposite ear, if a listener with unilateral deafness does not admit such 'shadow' hearing, he is a malingerer; while marked variations in repeated threshold readings must arouse suspicion. Some of the tests for which tuning-forks are employed can be performed equally well or better with the audiometer. Impedance audiometry, using the stapedial reflex, can objectively demonstrate the presence of hearing. Evoked response audiometry also has a place.

AIDS TO HEARING

1. *Electrical Hearing Aids*. These are the most widely used aids to hearing and consist of a microphone, an amplifier and a receiver or ear-piece. The amplifier and microphone are usually contained in the same unit which may be worn on the body or in a much smaller unit behind the ear. In the case of a body-worn aid the sound is delivered to the ear by a wire which is connected to a receiver which fits into the ear. In a behind-the-ear aid the receiver is in

THE LABYRINTH AND THE EIGHTH NERVE

the same unit as the microphone and the amplifier and the sound is piped into the ear by a narrow plastic tube.

In patients with conductive deafness, simple amplification will give excellent results. In sensorineural deafness there are problems of distortion and recruitment and in many cases the results are disappointing. To a large extent the aid can be selected so that it is powerful enough to compensate for the rise in the threshold of hearing. The frequency response can be adjusted to compensate for the different losses at different frequencies but the matching is never accurate and often a trial of several similar instruments is required to get the best results. When a hearing aid is first fitted there is often difficulty in picking out the sound that the patient wishes to hear from the background noise which is also amplified. With practice and perseverance this problem tends to diminish as does the intolerance of loud sounds particularly where there is recruitment.

2. *Non-electrical Hearing Aids.* The simplest form of non-electrical hearing aid is cupping the hand behind the ear and this method is often brought into use subconsciously by the deaf. Various forms of ear trumpet can still give useful service, particularly in the elderly or the disabled who have difficulty in manipulating the small electrical aids.

3. *Lip Reading.* All patients with incurable progressive deafness should be advised to learn to lip read as early as possible. Its acquisition becomes more difficult with increasing deafness and age. Some people learn to lip read spontaneously but instruction by a trained teacher is recommended. Lip reading is not only useful to the severely deaf but in the partially deaf it gives additional information particularly helping in the understanding of consonants which tend to be cut off by deafness affecting the higher frequencies.

4. *Speech Therapy.* In severe sensorineural deafness the patient has difficulty in hearing his own voice so that he is unable to monitor its quality and loudness. Eventually, speech becomes slurred, flat in tone and raucous. This loss of quality of speech can be delayed by speech therapy.

CHAPTER 73

CONGENITAL DEAFNESS

A normal child learns to speak because it hears its mother and those around it speaking. The desire to imitate is inborn, and the child gradually learns to reproduce the sounds that it hears. If a child cannot hear the speech of others it will not learn to speak itself. Even a child with normal hearing, if brought up in total isolation by deaf-mute parents, both of whom suffer from acquired deaf-mutism, would not learn to speak—indeed such a case has occurred. It should be noted that in about 99 per cent of cases of mutism or dumbness the trouble is due to deafness. There are rare instances in which the patient suffers from congenital aphasia, and such a child, even when blindfolded, will carry out whispered orders, e.g. 'raise your arms' and 'shut the door'. The causes of congenital deafness may be classified as prenatal, perinatal and postnatal.

1. PRENATAL CAUSES

A. Familial defects of the labyrinth are responsible for the condition known as *sporadic congenital deafness*. Complete absence of the labyrinth has been described. Both the bony and membranous cochlea may be malformed. As a rule, however, only the membranous cochlea and saccule are involved, the utricle and semicircular canals being normal (*Figs. 213–216*). In the great majority of cases both ears are affected. The anatomical findings may be divided into two types—primary changes in the cochlear duct and saccule, and primary degenerate atrophy of the spiral ganglion.

The incidence of hereditary deafness is determined by Mendelian law and the occurrence of deafness in certain families is well known. If hearing people carrying deafness marry pure hearing people, no deafness results. But if by chance—and the chance is bound to come—two hybrids (hearing people carrying deafness) marry, then deaf children must follow.

Among the recognized syndromes in which deafness may be noted are:

i. *Waardenburg's syndrome* which consists of some or all of the following—perceptive deafness of any severity either unilaterally or bilaterally; shortening of the eye fissures; hypertrichosis of the eyebrows which may meet in the midline; differently coloured eyes (heterochromia iridium); and a white forelock.

ii. *Klippel-Feil's syndrome* in which the neck is short or absent with a low hairline at the back and limited head movements. There is paralysis of the external rectus of one or both eyes and a perceptive deafness which is often severe.

iii. *Treacher Collins' syndrome* in which there are deformed malar bones and infra-orbital ridges so that the palpebral fissures slope downwards; the lower eyelids are notched and deficient in lashes medially; there may be

microtia and meatal stenosis or atresia with malformation of the middle and/or inner ears.

iv. *Van der Hoeve's syndrome* in which there is osteogenesis imperfecta, blue sclerotics and conductive deafness.

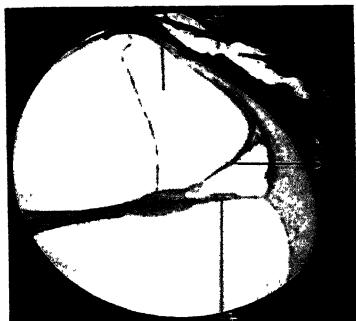


Fig. 213. Congenital deaf-mutism due to faulty development of membranous cochlea. Horizontal section through upper part of left basal coil. 1, Dilated cochlear duct; 2, Split in bony capsule (artefact); 3, Adhesion between membrana tectoria and stria vascularis; 4, Rudimentary Corti's organ.

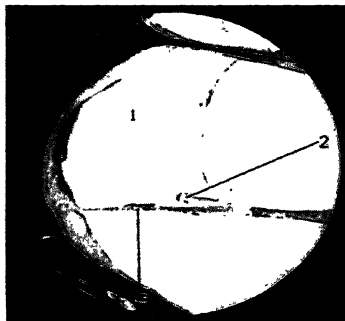


Fig. 214. Same case as Figs. 213, 215, 216. Horizontal section through lower part of left middle coil. 1, Dilated cochlear duct; 2, Membrana tectoria lying on the apex of the limbus; 3, Rudimentary Corti's organ. The spiral ligament shows oedematous degeneration. The stria vascularia appears to be well formed.

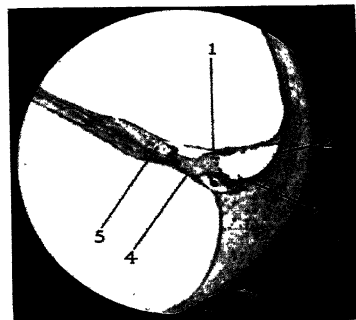


Fig. 215. Same case as Figs. 213, 214, 216. Vertical section through upper part of right basal coil. 1, Reissner's membrane depressed and attached to malformed Corti's organ; 2, Position of stria vascularis, which is absent; 3, Position of spiral prominence, which is absent; 4, Basilar membrane; 5, Membrana tectoria tucked into spiral sulcus. It will be seen that there is a complete malformation of the epithelium lining the cochlear canal.

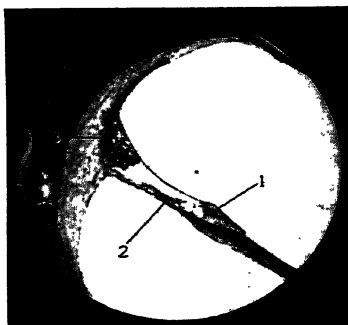


Fig. 216. Same case as Figs. 213, 214, 215. Vertical section through lower part of right middle coil. 1, Membrana tectoria, which lies between the origin of Reissner's membrane and the limbus; 2, Rudimentary Corti's organ; 3, Great proliferation of stria vascularis, which occupies the outer third of the narrow cochlear canal.

v. *Dyostosis cleidocranialis* which consists of absence of the clavicles and abnormalities of the skull, spine and pelvis. There may be stenosis of the bony meatus with hearing loss.

vi. *Hunter's syndrome* is a recessive type of gargoylism associated with progressive deafness.

vii. *Alport's syndrome* is found mainly in boys in whom a progressive glomerulonephritis is associated with deafness.

viii. *Refsum's syndrome* which consists of ichthyosis, ataxia, retinitis pigmentosa, night blindness, mental retardation and a perceptible hearing loss.

B. *Endemic congenital deaf-mutism* is associated with goitre and cretinism. The pathological changes mainly affect the middle ear and the window niches become narrowed or occluded and the stapes more or less immobile. In many cases, however, deaf-mutism probably depends mainly on the poor mental development of the child.

C. *Maternal rubella*. Children born of mothers who have suffered from rubella during the first 3 months of pregnancy have a 35 per cent chance of being born deaf and may also have heart defects, cataract and dental abnormalities. Other virus illnesses in the first trimester, e.g. glandular fever and influenza, may have a similar effect.

D. Other maternal diseases have been blamed for deafness in the baby, e.g. measles, nephritis, diabetes and syphilis.

E. *Drugs taken during pregnancy*. The results of thalidomide are now well known but deafness has also been attributed to the mother being treated with streptomycin and quinine.

2. PERINATAL CAUSES

Prematurity, dysmaturity, birth injuries, anoxia during delivery, prolonged labour and especially hyperbilirubinaemia can cause deafness.

3. POSTNATAL CAUSES

Deafness in early infancy is mainly due to infection, e.g. meningitis—due to meningococcus, pneumococcus or tuberculosis—measles, mumps, influenza, etc. It may be also due to treatment of infections by drugs such as streptomycin, neomycin or kanamycin.

DIAGNOSIS OF CONGENITAL DEAFNESS. If a deaf child is to make the best use of its residual hearing, if it is to learn to speak well and if it is going to benefit from education the diagnosis must be made at as early a stage as possible so that suitable treatment and education may be commenced early enough. Where any of the causative factors exist during pregnancy, at the time of delivery or if illnesses which might cause deafness occur in infancy the possibility of deafness must be excluded. This will require screening tests by doctors or health visitors, which may have to be repeated on several occasions until deafness can be eliminated with certainty in those 'At Risk' children.

Deafness may be suspected by the parents who notice that their baby does not respond to sound. This suspicion must be treated seriously and hearing tests applied until there is no doubt that the hearing is normal. Unfortunately, in many cases still, deafness is not suspected until there is delay in the development of speech. In these cases also the hearing must be thoroughly and accurately tested.

Whenever deafness is suspected a careful history must be taken and this will include the antenatal history as well as the nature of the confinement and postnatal health.

DIAGNOSTIC TESTS OF HEARING IN YOUNG CHILDREN

In adults, most tests of hearing depend on the active co-operation of the patient who can tell whether the various test sounds have been heard. In infants, this is obviously impossible and whether a child has heard a sound has to be assessed by its reaction to the sound. This examination is time consuming and requires experience and patience on the part of the examiners. It is also of the greatest importance that the child should be completely relaxed in a natural and friendly atmosphere. The room in which the test is done should be sound-proofed and it should be comfortably furnished with small tables and chairs and there should be a good selection of toys and suitable testing apparatus. Time must be allowed for the child to settle in and to become accustomed to these new surroundings and to those who are going to carry out the tests. Several visits may be required before rapport is achieved and the child enjoys his visits to his new friends.

DISTRACTION TECHNIQUES

Active co-operation of any kind is not to be expected in most children under $2\frac{1}{2}$ years. A newborn baby will respond to loud sounds by a startle reflex. This has been described as a sort of jerky extension of the spine and limbs, followed by a quick bowing movement of the arms over the chest, usually accompanied by a cry. The reflex may be less marked, a blink of the eyelids or he may simply interrupt what he is doing for a moment. After 6 months he may turn his head towards the sound. To carry out the test the child is preferably seated on his mother's knee and his attention held by one examiner who also observes any responses. A second person makes a variety of noises out of sight of the child and the first examiner notes any response by the child. By using sounds of different pitches and loudness an assessment of the degree of any deafness and the pattern of the loss can be made. Additional accuracy can be introduced by using a free field audiometer as the sound source.

CONDITIONING TECHNIQUES

After about $2\frac{1}{2}$ years the child can be taught to make some simple movement, e.g. building up bricks or some other progressive toy, in response to sounds to which it is known that he responds. At first he is allowed to see the sound source which could be a xylophone being struck. Once he appears to understand the 'game' the sound is made out of sight and his response to a variety of sounds can be noted. Once the child has been conditioned in this way accurate assessment of any hearing loss becomes possible, the most accurate results being achieved when the child agrees to wear earphones and to respond to the pure tones of the audiometer.

AUDIOMETRY IN CHILDREN

By 5-7 years of age audiometry is usually possible without preliminary conditioning.

THE EAR

MANAGEMENT OF THE DEAF CHILD

Once a diagnosis of deafness has been made the problem is largely an educational one and it must be commenced at as early a stage as possible. The development of speech is dependent on exposure to speech sounds and the mother must be encouraged to take her part in training the child as well as the teachers of the deaf. In most cases there is some residual hearing which can be utilized by fitting a hearing aid. Exposure to the speech of mother, the family and teachers has to be augmented by intensive auditory training, the oral method (lip reading) being generally the accepted basis for such training. It must be admitted that many of the severely deaf eventually come to rely on communication by sign using the manual alphabet.

The detection of deafness in children, its assessment and management requires the close co-operation of otologists, obstetricians, paediatricians, health visitors, psychologists and teachers of the deaf as well as those who may be dealing with other handicaps, e.g. cerebral palsy.

INDEX

- Abducens nerve, paralysis of, 348
Abscess, apical, 65
— brain (*see* Brain and Extradural abscess)
— cerebellar (*see* Cerebellar abscess)
— intratonsillar, 121
— lingual tonsil, 121
— peritonsillar, 120
— pharyngeal, 349
— retropharyngeal, acute, 105, 110
— subperiosteal, in mastoiditis, 331
— temporal lobe, 350, 356, 358–61
— of tonsils, 120
— — hypertrophic, 113
Absolute bone conduction test, 266
Achalasia of oesophagus, (*Fig.* 117), 22
Acinic cell tumour, 140
Acoustic impedance measurement in hearing test, 269, 347, 391
— meatus, external (*see* External)
ACTH (corticotrophin) injection for polypi, 57
Actinomycosis of larynx, 165
— pharynx, 104
Acute purulent otitis media (*see also* Otitis media, acute suppurative), 314–18
Adenoid(s) (*see also* Adenoidectomy), (*Figs.* 50, 52, 53, 54) 14, 93, 130–4
— associated with otitis media, acute, 317
— — — — chronic suppurative, 319
— cystic carcinoma of, 140, 240
— enlarged, 15
— — in infants, 130
— — and tonsils, 131
— facies, 15
— hypertrophy, 130, 131
— infection, symptoms of, 132
— and mastoiditis, 337
— and otitis media, 312
— in palatal arch abnormality, 112
— and snoring, 19
Adenoidectomy, 46, 53, 55, 124, 128
— in bifid uvula, 112
— complication of, 133
— in otitis media, 314, 321, 322
— and speech, 125
Adenoiditis, acute, 130
— chronic, 130
Adenoma, monomorphic, 240
— nasopharyngeal, 135
— pleomorphic, 240
— simple, 239
Adenosarcoma of sinus, 90
Adrenaline causing vasoconstriction, 47
— hydrochloride, uses of, 58
Aero-otitis media, 311
Aero-sinusitis, 84
Agger nasi, cell of, (*Fig.* 11) 10
Agranulocytic angina, 103
Aids to hearing, 400–1
Air conduction in hearing tests, 265
— flight and sinusitis, 70
Aircraft engine noise, hearing loss from, 388
— — — — pressurization after otosclerosis, 376
— — — — and sinuses, 84
Air-encephalography, 396
— in temporal lobe abscess, 361
Airway obstruction, tracheostomy, 167
Ala nasi, 1, 15
— collapse of, and snoring, 19
Alar cartilage, (*Figs.* 1, 2) 1, 2
Alcohol excess, hearing impaired by, 392
— — — — and hyperaesthesia of pharynx, 114
— — — — Menière-like symptoms in, 379
— — — — and rhinitis, 36
Allergic diseases in children (*see also* Allergy), 52
— laryngitis, acute, 160
— rhinitis, 52
Allergy and catarrh, 51
— — — — Menière-like symptoms in, 379
— nasal, treatment of, 52–3
— and otitis externa, 302
— in otitis media, chronic non-suppurative, 319
— and tonsillitis, 125
Alport's syndrome, 404
Amyloid disease of larynx, 176
Anaemia and tinnitus, 278
Anaesthesia in aural treatment, 291, 297, 298–9
— bronchoscopy, 210–11
— in foreign body removal, 200
— laryngeal diagnosis, 200
— of pharynx, 114
Analgesia in sinusitis, 67
Anastomosis of facial nerve, 347
Aneurysm, 394
— subclavian, 187
Angiofibroma, nasopharyngeal, 134
Angioma(ta), 63, 90
— of cerebello-pontine angle, 394
— face and neck, 115
— nasopharynx, 135
Angioneurotic oedema, 379
— — — — and allergic laryngitis, 160
Angular acceleration, response to, 270
Anosmia, causes of, 18
— in rhinitis, 37
Anotia, 292
Anoxia during delivery, and child deafness, 404
Anterior facial vein, 1
Antibiotics, after skull fracture, 386
— and candida albicans, 104
— for catarrh, 51, 52
— in cavernous sinus thrombosis, 83
— cerebellar abscess, 363
— diphtheria, 101
— ear infections, 311
— labyrinthine injuries, 383
— for lingual tonsillitis, 113
— meningitis, 82, 356
— nasal infection, 26, 53
— oesophagus, perforation of, 216

- Antibiotics for orbicular cellulitis, 80
 — in osteomyelitis, 53, 82
 — otitis media, chronic suppurative, 325-6
 — and otomycosis, 306
 — ototoxic, 392
 — for perichondritis of auricle, 295
 — in pharyngeal abscess, 349
 — pharyngitis, septic, 100
 — and seborrhoeic eczema, 307
 — sinus infection, 323
 — — thrombosis, 367
 — sinusitis, chronic, 74, 75
 — and skin allergy, 302, 303
 — in stridor, 205
 — therapy in mastoiditis, 331, 332, 333
 — for Vincent's angina, 101
 — and virus infection, 67
- Antibodies, ototoxic, and tinnitus, 278
- Anticoagulant therapy in otitic hydrocephalus, 368
- Antihistamine, labyrinthine sedatives in
 Menière's disease, 378
 — in nasal allergy, 43, 52, 58
- Antihypertensive drugs in vasomotor rhinorrhoea, 47
- Antorice type B neurolemmoma, 242
- Antral lavage, 73
 — — in sinusitis, chronic, 75
 — — walls, polypi in, (Fig. 31) 71
- Antrochoanal polypi, 97
- Antrostomy, intranasal, 75
 — for oro-antral fistula, 85
 — vasomotor rhinorrhoea, 48
- Antrum, maxillary, 9
 — — cysts in, 86
 — — fracture in, 84
 — — polypi in, (Figs. 33, 34) 58, 60, 75
 — — proof puncture for, 68, 72, 73
 — — in sinus infection, 54
- Anxiety state in Menière's disease, 378
- Aorta, (Fig. 65) 146
- Aortic aneurysm and dysphagia, 224
 — — vocal cord paralysis, 187
- Aphasia, optic, 361
- Aphonia, 156, 189-90
- Aphthous ulcers, 102
- Apical abscess, 65
- Apicitis, 65
- Arachnoiditis adhesive, 398
- Arsenical drugs, action on eighth nerve, 392
- Arteries, thrombosis of, Menière-like
 symptoms in, 379
- Arteriography in temporal lobe abscess, 361
- Arteriosclerotic changes in blood vessels of
 brain, 279
 — nerve deafness, diagnosis of, 397
- Arthritis, of crico-arytenoid joint, 164
 — infective, 164
 — laryngeal, 149
 — rheumatoid, 164
 — — rest for, 151
- Ary-epiglottic folds, (Figs. 60, 70) 94, 147, 178,
 234
 — — laryngoscopy, 209
 — — in leprosy of larynx, 166
 — — oedema of, 159
 — — tumour of, 178
- Arytenoid cartilage, (Figs. 59, 70) 145, 178,
 181, 234
 — — in laryngeal examination, 151
 — — oedema of, 163
- Arytenoid cartilage, seat-belt injury, 192
 — — swollen, 149
- Arytenoidectomy, 189
- Arytenoid muscle, (Fig. 59) 143
- Arytenoidoplasty in vocal cord paralysis, 189
- Aspergillus* infection, 33
- Aspirin causing neuritis of eighth nerve, 392
- Asthma, in children, 52
- Ataxia in deafness syndrome, 404
- Atresia of acoustic meatus, 296
 — congenital bilateral choanal, 24
 — laryngeal, 202
 — unilateral choanal, 25
- Atrium, enlargement of, and vocal cord
 paralysis, 187
- Atrophic laryngitis, 161, 162
 — pharyngitis, 108
 — rhinitis, 16, 108
- Attention, voluntary, 398-9
- Attic, cholesteatoma, arising in, 329-40
 — perforation of, 324, 325, 326, 327
 — suppurative of, 327
- Attico-antral disease, 327, 330
 — — discharge in, 325
 — — epidermoid cholesteatoma, 329
 — — in otitis media in mastoiditis, 338
- Attico-antrostomy, (Fig. 176) 343
- Audiogram, (Fig. 147) 267
 — in Menière's disease, 378
 — otitis media, 321, 325
 — otosclerosis, 375, 397
- Audiometry, for children, 405
- Auditory apparatus, physiology of, 263-4
 — — examination of, 264-9, 276
 — — artery, internal, spasm, 379
 — — thrombosis of, 393
 — fatigue, 388
 — meatus, external (*see under External*)
 — — internal injury (*see also under Internal*),
 383
 — nerve (*see also Eighth nerve*), traumatic
 affection of, 387-8
 — tube, 93, 94
- Auerbach's plexus, 229
- Aural fistula, congenital, 294
 — polypus, obstruction by, 326
 — snare in removal of polypus, (Fig. 169)
 328
 — toilet in middle ear suppuration, 325
 — treatment, 287-91
- Auricle, 292-5
 — congenital malformation of, (Fig. 162) 292
 — — meatal atresia, (Fig. 162) 292
 — haematoma of, 294-5
 — outstanding, operation for, (Fig. 163) 294
 — perichondritis of, (Fig. 165) 295
- Auricular deformities, 292
- Auriculotemporal syndrome, 281
- Auriscopes, electric, use of, 283
- Autograft temporalis fascia, 342
- Autophony, 310
- Autoplastic nerve graft, 346
- Axillary glands in infective mononucleosis, 103
- Babinski's sign in meningitis, 314
- Balance of body, disturbance of, 296
 — — in secondary syphilis, 372
 — — loss of, in labyrinthitis, 352
 — — in Menière's disease, 377, 378
 — — tumour of eighth nerve, 394

- Bárány's noise apparatus in hearing tests, (Fig. 145) 264, 266, 400
 — pointing test, 273
 — syndrome, 356
 Barium studies, 245
 — swallow, (Fig. 117) 230
 — — for cancer of oesophagus, 231
 — — hypopharynx tumour, 236
 — — in pharyngeal pouches, 228
 Barotrauma, effect on sinuses, 84
 — tinnitus in, 312
 Basal meningitis and vocal cord paralysis, 186
 Bat ear, 294
 Bathing as cause of sinusitis, 65
 Behçet's syndrome, 102, 281
 Bell's palsy, 345
 — — in middle ear suppuration, 338
 Benign tumours of nose, 62-3
 Bernoulli effect and voice sounds, 154
 Beverly-Douglas procedure in micrognathia, 203
 Bezold's mastoiditis, 331
 Bilateral adductor paralysis, 189-90
 — complete vocal cord paralysis, 188
 — congenital atresia of external auditory meatus, 292
 — deafness, from explosion, 398
 — simulated, 399
 — — in vocal cord paralysis, 188, 189
 Biopsy, for maxillary tumour, 91
 — neck examination, 245
 Birth injuries and child deafness, 404
 Black hairy tongue, 111
 Blast injuries to ear, 300
 Blastomycosis of larynx, 165
 — pharynx, 104
 Blindness following orbital cellulitis, 80
 Blood diseases and epistaxis, 30
 — disorders, acute pharyngitis in, 103
 — dyscrasia, 103
 — examination, 151
 — stream, tuberculous infection by, 369
 — transfusion in epistaxis, 29, 31
 Blue sclerotics, 403
 Boils (furuncles), 303-5
 Bone conduction tests, 265, 267, 400
 — — absolute, 266
 — infection in mastoiditis, 338
 — in tonsil, 122
 Bony cochlea of ear, 259
 Brain abscess, (Figs. 185, 186, 187) 82-3,
 358-60, 366, 367
 — — cerebellar, (Fig. 187) 358, 362-3
 — — from extradural abscess, 355
 — — — frontal sinusitis, 82-3
 — — meningeal, 358
 — — otitic, 358
 — — suppurative, 358
 — — temporal lobe, (Fig. 186) 358-61
 — stem, coning of, 358
 — tuberculoma, 369
 Branchial cysts, 112, 243
 — — resembling parotid swelling, (Fig. 124) 240
 — fistula, 112-13
 Branchogenic carcinoma, 243
 Breath, offensive, in sinusitis, 69
 — — tonsillitis, 121
 Bridge, nasal, depression of, 24
 Bronchi, foreign body in, (Fig. 108) 215-16
 — inflammatory lesion in, 69
 — papillomata in, 174
 Bronchial carcinoma, 158
 — — and dysphagia, 224
 — — radiography of, 245
 — secretion, removal of, 167
 — toilet, tracheotomy for, 167
 — virus infection, 159-60
 Bronchiectasis and keratosis obturans, 297
 — sinusitis and, 53
 Bronchioles, effect of tracheostomy on, 8
 Bronchitis in children, 52
 — sinusitis and, 53
 Broncho-oesophageal fistula, 231
 Bronchopneumonia, bilateral complete
 paralysis of vocal cords in, 188
 Bronchoscope, (Fig. 104) 211, 219
 — for children, 211
 Bronchoscopy, (Figs. 104, 105, 106) 209-10,
 211, 219
 — anaesthesia of pharynx in, 210-11
 — in children, 211
 — instruments for, (Figs. 104, 110) 207
 Bronchus, (Fig. 65) 146, (Figs. 105, 106) 210-11
 — carcinoma of and vocal cord paralysis in, 186
 — foreign body in, (Fig. 109) 217
 Brucellosis, 239
 — nodes in, 244
 Buccal mucosa, examination of, 96
 — — infection, 140
 — — ulcer, 102
 Bulbar paralysis, 186
 — — anaesthesia in, 114
 Bullae in mouth conditions, 102
 Burns of oesophagus, (Fig. 118) 229-31
 Burr-hole approach to brain abscess, 363
 Cacosmia, 18
 Caisson disease, 388
 Calculus of submandibular duct, 139
 — tonsil, 122
 Caldwell-Luc approach to antrum, 60
 — antrostomy, 48
 — operation, (Fig. 33) 75
 — — for papilloma, 90
 — — sinus cysts, 86
 — surgery, 84, 85
 Caloric responses in vestibular neuronitis, 379
 — tests, 395
 — — in nystagmus, (Figs. 152, 153) 274
 Calorigrams, (Fig. 153) 275
 Canal paresis in caloric testing in Menière's
 disease, 378
 Cancer and dysphagia, 224
 — of external auditory meatus, 381
 — glottis, 180-1
 — larynx, 178-85
 — oesophagus, (Fig. 119) 224, 231-3
 — surgery for, 233
 — squamous cell of oesophagus, 231
 — stomach, 244
 — subglottic, 147, 184
 — supraglottic, 178-9
 — tonsillar, 245
Candida albicans, antibiotics and, 104
 Canthus, outer, sequestrum formation at, 82
 Carcinoma(ta), adenoid cystic, 240
 — of apex of lung, 187
 — bronchial, 243, 245
 — — vocal cord paralysis in, 158
 — confused with pharyngeal syphilis, 109
 — cystic goitre resembling, 245

- Carcinoma(ta), follicular, 239
 — of glands, 246
 — granuloma resembling, 175
 — of larynx, 147, 149, 162, 184
 — — tomograph of, (*Fig.* 71) 152
 — medullary, 239
 — middle ear, 381
 — muco-epidermoid, 240
 — nasal, 63
 — of nasopharynx, 135
 — oesophagus, 187, 213, 220, 222, 243, 245
 — papillary, 239
 — perichondritis and, 164, 165
 — of pharynx, 117–18
 — postcricoid, (*Fig.* 114) 226
 — in radical mastoid cavity, 381
 — radiotherapy in pharyngeal tumour, 238
 — of sinus, 90–2
 — squamous, 90, 116, 239, 243
 — — cell of hypopharynx, 235, 236
 — of thyroid gland, 187
 — tongue, 116
 — and vocal cord paralysis, 186, 188–9
 Carcinoma-in-situ, of larynx, 162, 184
 Carcinosarcoma, 236, 238
 Cardia, incompetent, associated with pachydermia, 162
 Cardiac disease and tinnitus, 278
 Caries in promontory, (*Fig.* 180) 352
 — syphilis of ear, 372
 Carotid artery, (*Fig.* 55) 137
 — bifurcation of, (*Fig.* 64) 146
 — body tumours, 242
 — bulb, 241, 242
 Cartilage of larynx in children, 198
 — cricoid (*see* Cricoid)
 — nasal, (*Figs.* 1, 2) 1, 2
 — in radiotherapy, 181, 182
 — tonsil, 122
 Cat scratch fever, 239
 Catarrh, 55
 — chronic in children, 50–3
 — nasal, 15–16
 — postnasal, 69
 — — in children, 66
 Catarrhal deafness in chronic sinusitis, 70
 — pharyngitis, simple, 107
 — sinusitis, 53
 Catheterization of Eustachian tube, 289
 Caustics in ear treatment, 290–1, 300
 Cauterization in epistaxis, 31
 — in leucoplakia, 115
 Caution of tumour, 63
 Cavernous sinus, 1
 — — thrombosis, 365
 — — — in ethmoidal sinusitis, 83
 Cellulitis in pharyngitis (*see also* Orbicular cellulitis), 100
 Central nervous system, anaesthesia in, 114
 — heating, effect of, 8
 — nystagmus, 272
 Cerebellar abscess, 352, 358, 361, 362–3
 — — burr-hole drainage in, 363
 — — signs and symptoms, 362
 — — surgery for, 363
 — — treatment of, 363
 — — artery thrombosis in, 380
 — ataxia, due to brain abscess, 36
 — seizure, 394
 — tumour and Menière's disease, 379
 Cerebellopontine angle, lesions in, 394, 396
 Cerebellum, conditions diagnosed from
 — Menière's disease, 378
 Cerebral arteriosclerosis, Menière-like symptoms in, 379
 — haemorrhage and anosmia, 18
 — palsy, 406
 Cerebrospinal fluid in brain abscess, 362
 — — herpes zoster oticus, 391
 — — leak, 48
 — — in meningitis, 355, 356, 357, 388
 — — normal pressure, 357
 — — in otitic hydrocephalus, 368
 — — rhinorrhoea, 48–9
 — — sinus thrombus, 365
 Cervical arthritis and headache, 16
 — causes of otalgia, 281
 — collar for vertebral artery ischaemia, 380
 — ganglion, superior, 5
 — gland metastases in transglottic tumour, 182
 — — in syphilis, 109
 — — tuberculosis of, 122
 — lymphatic glands in sinus thrombosis, 365
 — lymph nodes, enlargement of, 103, 121
 — — node metastases, examination for, 184
 — — — in tumour of tongue, 116
 — oesophagus, perforation of, 213
 — — tumour of, 234
 — ribs in neck swelling, 241
 — spine, tuberculosis and, 105
 — — tuberculous glands and, 105
 Chancres of syphilis, 109
 Chemical caustics and septum perforation, 28
 — cauteries, 31
 Chemodectomas, 242
 — parapharyngeal, 115
 Chemosis of the conjunctivae, 79
 Chest complications in middle ear tumour, 381
 — tumour, X-ray for, 184
 Chicken pox, mouth lesion in, 102
 Children, anatomy of larynx in, 198
 — asthma in, 52
 — bronchitis in, 52
 — bronchoscopy for, 211
 — catarrh in, 50–3, 66, 69
 — cauterization for epistaxis, 31
 — cleft larynx, 202–3
 — congenital deafness in, 402–6
 — — laryngeal cysts, 200
 — — syphilis of ear in, 370
 — deafness in, 371, 406
 — diagnostic hearing tests for, 405
 — dysphagia in, 224
 — ear, foreign body in, 298
 — epiglottitis in, 159, 199
 — epistaxis, 29
 — Eustachian tube inflation for, 322
 — foreign bodies in bronchus, 218–20
 — — ear, 298
 — — nose, 31–3
 — — oesophagus, 222
 — fracture of nasal bones, 15
 — haemangioma in subglottis, 200
 — hearing aids for, 292
 — hospitalization, nervousness of, 127
 — inhalations, effect of, 53
 — intranasal antrostomy for, 55
 — Koplik's spots in, 99
 — laryngeal trauma in, 199
 — laryngomalacia in, 198–9
 — laryngotracheobronchitis in, 159–60, 199

- Children, larynx, oedema of, 147
 — lymphangioma of, 200
 — mastoiditis in, 331, 333, 334
 — meningitis neurolabyrinthitis in, 389
 — meningitis in, 356
 — micrognathia in, 203-4
 — mucoviscidosis in, 53
 — mumps in, 138
 — nasal allergy, 44, 46
 — — antral polypi in, 59
 — — bones, fracture of, 22
 — — obstruction, 15
 — — nose blowing in, 52, 54
 — — drops for, 55
 — — foreign bodies in, 31-3
 — oedema of larynx in, 199
 — oesophagus, foreign bodies in, (*Fig.* 111) 220
 — otitis media in, 52, 312, 313, 314, 319
 — outstanding auricle in, 294
 — papillomata of larynx in, 200-2
 — paralysis of larynx in, 200
 — peritonsillar abscess in, 120-1
 — proof puncture, 54, 55
 — rotation test in, 274
 — sarcoma of middle ear, 381
 — — pharynx in, 117
 — septal surgery for, 27
 — sinus radiography in, 71
 — sinusitis in, 53-5
 — — sphenoidal, 66
 — soft palate, function of, 96-7
 — spasm in, 204
 — speech development for, 406
 — stenosis in, 202
 — stridor with pyrexia in, 205-6
 — testing for deafness, 405
 — tonsillar sepsis in, 125
 — tonsillectomy for, 122
 — tonsillitis in, 52, 121
 — — successive, 125
 — tracheostomy in, 200
 — — decannulation, 172
 — vascular anomalies in, 203-4
 — visiting in hospital, 128
- Choanae, 14
 — atresia, complete, (*Fig.* 19) 24, 25
 — bilateral, treatment in infant, 25
 — congenital atresia of, (*Fig.* 181) 15, 24, 25
 — polypi in, 54, 59
 — — removal of, 59
- Cholesteatoma, 278, 346, 354
 — acquired, 329, 330
 — in circumscribed labyrinthitis, 396
 — congenital, 329
 — in labyrinthitis, 350
 — lining aditus and antrum, (*Fig.* 178) 351
 — mastoid, surgery for, 330
 — mastoiditis, 328, 339, 341
 — suction, clearance of, 339
- Cholesteatosis, 328
- Cholesterol granuloma, 329
- Chondroma of cricoid, 175, 242, 244
 — thyroid cartilage, 242
- Chondrosarcoma, (*Fig.* 79) 175
 — and laryngectomy, 243
 — of sinus, 90
- Chorda tympani, 254
 — — nerve, damage to, in skull fracture, 347
 — — syndrome, 281
- Chronic asthma, treatment of, 45
- Cicatricial stenosis of pharynx in syphilis, 109
- Ciliated epithelium, function of, 8
- Circumscribed labyrinthitis associated with otitis media, 397
 — serous meningitis, 356
- Clavicles, absence of, in dysostosis cleidocranialis, 403
- Cleft larynx, 202, 203, 204, 205
 — palate and otitis media, chronic non-suppurative, 319
- Cluster headaches, 17
- Cocaine hydrochloride, 31, 44
 — — in ear treatment, 289
 — — laryngoscopy, 151, 207
 — — nasopharyngoscopy, 14
 — — polyposis, 57, 58
 — — rhinitis, 36
 — — sensitivity, 13
 — — in sinusitis, 66
- Cochlea affected by drugs, 392
 — aqueduct in labyrinthitis, 351
 — basal coil, haemorrhage in, 386
 — capsule of, spongification effect of, 393
 — damage to, 300
 — examination of, 300
 — injury to, 383
 — — in explosion deafness, (*Fig.* 204) 386, 387
 — metastatic infection in, 393
 — petechial haemorrhage in, 393
- Cochlear apparatus, examination of, 394
 — deafness, 269
 — function, impairment of, 292
 — — in tympanoplasty, 342
 — ganglion, atrophy of, 394
 — — cells, degeneration of, 392
 — nerve, 352
 — — compression by tumour, (*Fig.* 210) 395
 — — syphilitic neuritis and, 370
 — tests, 328
 — — in Menière's disease, 300
- Cochleo-auricular reflex, 398
- Cochleo-palpebral reflex, 398
- Cochleo-papillary reflex, 398
- Cold, common, 15
 — prevention of, 35-6
 — and salpingitis, 309
 — vaccine for, 36
- Columella, 1
 — type of tympanoplasty, (*Fig.* 176) 343
- Coma in meningitis, 357
- Combined approach mastoidectomy, 341
- Commisure, anterior, 151
- Conchae, (*Fig.* 4) 7, 8, 14
 — cell, middle, (*Fig.* 12) 11
 — cystic middle, 63
 — — mistaken for polypus, 57
 — inferior, enlarged, (*Fig.* 12) 27
 — — nasal, 13
 — — oedema of, 13
 — nasal, (*Fig.* 3) 2, 3, 4
 — — allergy, enlargement from, 53
 — oedema in, 46
 — polypi and, 56, 57
 — in sinusitis, (*Plate* III, 2, 3) 66, 70
 — swollen in vasomotor rhinorrhoea, 48
- Conditioning techniques in hearing tests for children, 405
- Conductive deafness (*see* Deafness, conductive)
- Confusion in meningitis, 356
- Congenital abnormality of palate, 112
 — — uvula, 112
 — — aphasia, 402

- Congenital aural fistula, 294
 — cysts of larynx, 200
 — deaf-mutism, (*Figs.* 213-16) 403
 — deafness, (*Figs.* 213-16) 402-6
 — — diagnosis of, 404
 — laryngeal web, 202
 — malformation of auricle, (*Fig.* 162) 292
 — — of external ear, (*Fig.* 16) 292
 — neoplasms of nose, (*Fig.* 26) 61
 — swellings of neck, 240
 — syphilis, 370-1
 — — in fetus and infant, 370
 — — young children, (*Figs.* 22, 192, 193) 370
 — tumours of nose, 61-2
 Conjunctiva, chemosis of, 79, 80
 Contact ulcer of larynx, 162, 163
 Co-ordination and balance in ear disease, 273
 Cordopexy, 189
 Cords, false, examination of, 158, 209
 — — and vocal paralysis (*see also* Vocal cords), 158
 Cornea, syphilis and, (*Fig.* 22) 39
 Corniculate cartilage, (*Fig.* 59) 143
 Corrosive(s) burns of oesophagus, (*Fig.* 118) 229-31
 — ingestion of, and dysphagia, 224
 Corti, organ of, 261, 262, 264
 — — atrophy of, (*Fig.* 210) 372, 394
 — — deafness in, 268
 — — degeneration of, 387
 — — — hair cell, 392
 — — injuries of, 283
 — — rudimentary, (*Figs.* 213, 214) 403
 Cortical mastoid operation, (*Figs.* 172, 173) 334-5
 Corticosteroids, 52, 103
 — in nasal allergy, 45
 — polypi, 58
 Coryza, 16, 89, 99
 — in influenza, 35
 — measles, 35
 — sinusitis, acute, 65
 Cosmetics and nasal allergy, 43
 Costen's syndrome, 18, 281
 Cough due to foreign body in bronchus, 215, 216, 217
 — in laryngeal conditions, 149
 — reflex, 296
 Coxsackie A virus, 102
 Cranial nerve paralysis in meningitis, 357
 Cretinism in deaf-mutism, 404
 Cribriform plate, fracture of, and anosmia, 18
 Crico-arytenoid joint, arthritis of, 164
 — muscles, 145
 Cricoid cartilage, (*Figs.* 60, 63, 77, 90, 94, 122) 142, 145, 234
 — — collapse of, 172, 196
 — — chondroma of, 175, 224
 — — in hemilaryngotomy, 182
 — — removal, 182
 — — seat-belts and, 192
 — — tracheostomy damage in infants, 200
 Cricopharyngeal myotomy and vocal cord paralysis, (*Figs.* 84, 85) 186, 188
 — sphincter, (*Fig.* 115) 227
 Cricopharyngeus and perforated oesophagus, 213
 — foreign bodies in regions of, 220
 Cricothyroid joint, 164
 — membrane, (*Figs.* 59, 64) 143
 — muscle, (*Figs.* 61, 62, 63) 144
 Cricotracheal membrane, tears in, (*Fig.* 64) 196
 Crusts, in attico-antral disease, 325
 — rhinitis, 37, 38
 — scleroma of larynx, 165
 — sinusitis, 69
 — syphilis, 39
 — trachea, 172
 Crypts, tonsil, distension of, 121
 — — pus in, 123
 Cuneiform cartilage, (*Fig.* 59) 143
 Cupola, 270, 271
 Cupulogram, 274
 Cupulometry in nystagmus test, 274
 Cushing's disease and salivary gland enlargement, 240
 — syndrome, 87
 Cyanosis due to foreign body, 217
 Cylindroma, 140
 Cystic goitre, 245
 — hygroma, 240
 Cysts, 205, 240
 — of antrum, 71
 — branchial, 240
 — in children, congenital, 200
 — — supraglottis, 200
 — dentigerous, 71
 — dermoid, 62
 — infected, 244
 — laryngocele resembling supraglottic, 176
 — of maxillary sinus, (*Fig.* 40) 86
 — — and toothache, 86, 87
 — middle concha, 63
 — neck, 240, 241
 — pharynx, 112-13
 — and prolapse of ventricle, 163
 — puncturing, danger of, 62
 — retention of, 121
 — sebaceous, 239
 Cytomegalovirus, 239
 — cervical nodes in, 244
 Dandruff, 306
 Darwinian ears, 292
 Dead space, tracheostomy for, 167
 Deaf child, management of, 406
 Deaf-mute parents, 402
 Deaf-mutism, acquired, cause of, 370 ✓
 — congenital, 370
 — endemic congenital, 404
 Deafness (*see also* Labyrinthitis; Nerve deafness; Tympanic membrane), 384
 — after meningitis, 388
 — associated with tonsils, 124
 — in children, detection of, 371, 406
 — conductive, 263, 264, 320, 397, 403
 — — aids for, 401
 — — in mastoiditis, 338
 — — salpingitis, 310
 — congenital, 402-6
 — due to barotrauma, 311
 — — drugs, 391-2
 — — explosion, 386-7
 — — hydrocephalus, 389
 — — noise, 387-8
 — — otosclerosis, 373
 — — polypi, 328
 — — syphilis, 370, 371
 — — tumour of eighth nerve, 394
 — — wax in ear, 296
 — hereditary, 402
 — in herpes zoster oticus, 391

- Deafness in labyrinthitis, 351
 — leptomeningitis, 388
 — mastoiditis, 333
 — Menière's disease, 377, 378
 — meningitis, 356
 — otitis media, non-suppurative, 312
 — — — chronic suppurative, 313, 325
 — permanent in labyrinth capsule injury, 385
 — in polyposis, 59
 — psychogenic, 398-9
 — in salpingitis, 309, 310
 — senile, 392
 — — nerve, 378
 — sensorineural, 375, 378, 387
 — simulation of, examination for, 397, 399-400
 — and skull fracture, 383
 — as symptom of ear disease, 277
 — in temporal lobe abscess, 361
 — traumatic, 378, 383, 385
 — in tympanosclerosis, 323
 — unilateral congenital, diagnosis, 397
 — in vestibular neuronitis, 379
- Decongestant(s) drops, 53
 — postoperative use of, 76
 — in sinusitis, 74, 75
- Decongestion in acute sinusitis, 67
- Defective memory from brain abscess, 83
- Delayed cerebation from brain abscess, 83
- Delphian node, 146
- Dental abscess and pharyngitis, 107
 — cysts, 86, 87
 — extraction and ear pain, 280
 — hygiene and leptothricosis, 165
 — infections as cause of sinusitis, 65, 68
 — otalgia, 280
 — pain, 18
 — sepsis and parotitis, 139
 — — pharyngitis, 99
 — treatment for mouth ulcer, 102
- Dentigerous cysts, 86
- Dentures, illfitting, 18
- Dermatitis of nasal vestibule, 26
- Dermoid(s), 244
 — cyst of nose, (*Fig. 27*) 62
 — of neck, 240
- Desensitization in nasal allergy, 46
- Destructive ear disease, 328
- Diabetes associated with tonsillectomy, 126
 — and child deafness, 404
 — malignant otitis externa, 308
 — salivary gland enlargement, 240
- Diffuse otitis externa, 305-6
- Digastric muscle, (*Fig. 55*) 137
- Dihydrostreptomycin, deafness and, 392
- Diphtheria, 101, 204
 — diagnosis from tuberculosis of pharynx, 110
 — laryngitis in, 158
 — membrane in, (*Plate V, 2*) 101
- Diplacusis, 277
 — in Menière's disease, 378
- Diploic bone, septic thrombophlebitis in, surgery for, 80
- Diplophonia, 156, 187
- Diplopia, 79, 84
- Discharge, bloodstained, in middle ear tumour, 381
 — from ear, 277-8, 298
 — — — foul-smelling, in chronic mastoiditis, 338
 — — — removal of, 287
 — in glomus jugulare tumour, 382
- Discharge, increase after mastoidectomy, 348
 — in mastoiditis, 331, 332
 — otitis externa, acute, 277, 305, 308
 — — — media, acute, 315
 — persistent purulent, danger of, 327
 — purulent in otitis media, 325
- Discrimination, loss of, in senile deafness, 392
- Dissection method of tonsillectomy, 126
- Disseminated (multiple) sclerosis, nerve deafness in, 393
 — — — positional nystagmus in, 380
- Distraction techniques in hearing tests, 405
- Diving, avoidance of, after stapedectomy, 376
 — as cause of otitis media, 299, 314, 326
 — — sinusitis, 65
 — deep, effect on sinuses, 84
- Dizziness, history of, in vestibular examination, 272
 — in Menière's disease, 377
- Dohlman's operation for pharyngeal pouch, 228
- Douching nose, 20
- Drainage, lymphatic, of larynx, 146
- Drinking, excess of, and nasopharyngitis (*see also* Alcohol excess), 129
- Drug(s), associated with vasomotor rhinorrhoea, 47
 — deafness due to, 391-2
 — in pregnancy and child deafness, 404
 — reaction and laryngitis, 160
 — and tinnitus, 278
 — vasomotor balance upset by, 47
- Drumhead (*see* Tympanic membrane)
- Dry eye complex, 240
 — mouth and dry eye complex (*Sicca syndrome*), 240
- Dural blood sinus and otitic hydrocephalus, 368
- Dust, exposure to and pharyngitis, 107
- Dysdiadokokinesia, in cerebellar abscess, 362
 — tumours of eighth nerve, 394
- Dysmaturity and child deafness, 404
- Dysostosis cleidocranialis, 403
- Dysphagia, 223-33
 — associated with cancer, 224
 — examination for, 224-5
 — foreign body and, 223
 — lusoria, 203
 — oesophageal, 223
 — in Paterson-Brown Kelly syndrome, 226
 — pathology of conditions causing, 225
 — in perforation of oesophagus, 214
 — postoperative, after laryngectomy, 180
 — treatment of, 226
- Dysphonia, 138, 205
 — in crico-arytenoid joint, 164
 — hypopharynx cancer, 236
 — plicae ventricularis, 156
- Dysplasia in leucoplakia of larynx, 162
 — facial fibrous, 87
- Dyspnoea due to foreign body, 216, 217
- Ear(s), abscess of congenital aural fistula, 294
 — absence of (anotia), 292
 — anatomy of, (*Figs. 125-44*) 247-63
 — balance and, 270ff.
 — bleeding after trauma, 300
 — — — granuloma and polypus, 328
 — cauterization of granulations, 290-1
 — clinical examination of, (*Figs. 154-8*) 282-6
 — congenital malformation of, (*Fig. 162*) 292

- Ear(s), discharge from, 277
 — disease, symptoms of, 277-9
 — drops, administration of, 290, 326, 328
 — drugs affecting, 391-2
 — external, (Fig. 126) 247
 — — acoustic meatus, 247
 — — total absence of, 292
 — — tympanic membrane (*see* Tympanic membrane)
 — foreign bodies in, 289-90
 — fractures, examination for, 385
 — function, examination for, (Figs. 145-8, 152-3) 264-9, 272-6
 — hearing tests, (Figs. 145-9) 264-9
 — herpes zoster oticus in, 390-1
 — inflation of Eustachian tube, 288
 — injury from noise and explosion (*see* Explosion; Noise), (Fig. 199) 384
 — instruments for treatment, (Fig. 161) 291
 — insufflation of powder into, 311, 335
 — internal, (Figs. 138-44) 257-62
 — — bony cochlea, 259
 — — labyrinth, 257, 258, 259
 — — membranous, 260, 261
 — — vessels of, 261
 — middle, (Figs. 128-37) 249-57
 — — anterior wall, 250
 — — Eustachian (auditory) tube (*see* Eustachian tube)
 — — — catheterization, 289
 — — — inflation of, 288
 — — — lateral wall, (Fig. 129) 251
 — — — ossicles, 251
 — — — posterior wall, 250
 — — sensory nerve supply, 254
 — — tympanic ligament and spaces, (Fig. 132) 253
 — — — vessels and nerves, 253
 — mopping, 287
 — nerve supply of, 280
 — packing of, 289-90
 — physiology of, (Fig. 151) 263-4, 270-2
 — protectors, 388
 — suction clearance of, 287
 — syphilis, acquired, of, 371
 — syringing, (Fig. 159) 287
 — traumatic affections of, 383-8
 — tumour of eighth nerve, examination of, 394-5
 — wax in, 277
 — — removal of, 287
 Earache (*see also* Otitis media; Polypos), 280
 Eczema and otitis externa, 303
 — infantile, 52
 Eighth nerve, 261
 — — drugs causing neuritis in, 392
 — — inflammation of, in herpes, 391
 — — labyrinth changes and, 394
 — — neurofibroma of, (Figs. 209-12) 395
 — — purulent infiltration of, 389
 — — in syphilis of ear, 372
 — — tumours of, (Figs. 209, 210) 394-8
 — — — differential diagnosis of, 396
 — — — examination of, 394-5
 — — — and giddiness, 279
 — — — in Menière's disease, 379
 — — — vitamin deficiency and, 393
 Electrical hearing aids, 400-1
 Electrocochleography, 394
 Electro-encephalogram in temporal lobe abscess, 361
 Electrogustometry, 347
 Electromyography in facial paralysis, 344
 Electronic larynx, 185
 Electronystagmography recording eye movements, (Figs. 142, 154) 274
 — in Menière's disease, 378
 Empyema due to inhaled foreign body, (Fig. 109) 218
 — surgical, in parapharyngeal abscess, 106
 — — perforation of oesophagus, 214
 — — radiology for, 151
 — — after tracheostomy, 171-2
 Empyema in mastoiditis, 331
 — sinus thrombosis, 365
 Encephalitis associated with mumps, 138
 — in brain abscess, 358
 — of temporal lobe, 361
 Encephalocele, 62
 — puncture of, 82
 Enchondroma of nasopharynx, 135
 Endemic congenital deaf-mutism, 404
 Endocarditis, subacute bacterial, danger of, 126
 Endocrine disorders and Menière-like signs, 379
 — glands, effect on nasal mucosa, 47
 Endolymph, in caloric test, 274
 — movement of, in body rotation and head movement, 270, 271
 Endolymphatic sac, decompression of, in Menière's disease, 379
 — tension in Menière's disease, 377
 Endoscopic procedure in chronic laryngitis, 162
 Endoscopy, functions of, 207
 — instruments for, (Fig. 104) 207
 — in pachydermia, 163
 — reverse in vocal cord paralysis, 188
 — ventricle prolapse, 163
 Environment as factor in catarrh, 50
 Eosinophils in middle ear fluid, 319
 — nasal allergy, 43, 44
 — — polypi, 56
 Epanutin and lymph node enlargement, 242
 Epidemic cerebrospinal meningitis, 388
 — vertigo, 379
 Epidermoid cholesteatoma, 329
 Epidermosis, 328
 Epiglottis, (Fig. 46) 59, 60, 70, 94, 151, 178
 — infantile, 198
 — in leprosy of larynx, 166
 — and metastatic glands, 243
 — oedema of, 163
 — overhanging, 151, 153
 — in seat-belt injury, 192
 — tumour of, 178
 Epiglottitis, acute, 159, 204, 205
 Epilepsy, Menière-like symptoms in, 379
 Epileptiform attacks in brain abscess, 361
 Epistaxis, (Fig. 7) 3, 29-31, 33
 — in angioma, 90
 — blood transfusion in, 29, 31
 — in elderly, 29
 — haemophilia and, 29
 — in influenza, 29
 — intranasal crusts in, 29
 — leukaemia and, 29
 — papilloma and, 90
 — purpura and, 29
 — in rhinitis, 38
 — treatment for, 30-1
 — tumours and, 29, 43

- Epithelioma, squamous, of external meatus, 381
 — — pharynx, 117
 Epstein-Barr virus, 186
 Erysipelas confused with sinus thrombosis, 366
 Erythema multiforme, 102
 Erythroplakia, 115
 Ethmoid bone, 2, 3, 10
 Ethmoidal arteries, superior and inferior,
 (Figs. 5, 7) 3, 6, 7
 — bulla, (Figs. 4, 5, 12) 5, 6
 — cells, (Figs. 12, 30) 9, 135
 — — and adenocarcinoma, 90
 — — angiofibroma of, 134
 — — draining of, 76
 — — posterior, (Fig. 5) 6
 — nerve, anterior, pressure on, 17
 — — neuralgia of, 27
 — sinuses, (Figs. 4, 5) 3, 10, 75
 — — anterior, infection of, 66
 — — development of, 53
 — sinusitis, acute, 66
 — surgery, (Fig. 35) 77
 — — radical external, surgery for, in nasal
 polypi, 58
 Ethmoidectomy, external, 77, 78
 — — in infection, 76, 78
 — — for mucocele, 85
 — — polypi in, 56
 — — sinusitis in, 53, 68, 69, 70, 83
 — — surgery, 76-7
 Ethmoiditis, acute, (Fig. 23) 54
 Eustachian tube, 125, 250, 309-11
 — — abnormal patency of, 310-11
 — — auto-inflation in, 321
 — — catarrh in, 339, 370
 — — catheterization of, 289
 — — in drainage of middle ear, 313
 — — dysfunction, 329
 — — foreign bodies in, 311
 — — haemorrhage in temporal bone fracture,
 (Fig. 201) 385
 — — infection, 278, 369
 — — inflation of, 288-9, 321, 325
 — — obstruction, Menière-like symptoms of,
 379
 — — — in otitis media, 312, 375
 — — — acute, 314
 — — — chronic non-suppurative, 319
 — — otosclerosis, 375
 — — polypi in, 327
 — — primary function of, 309
 — — in tuberculosis of ear, 369
 — — tympanoplasty, 342, 343
 Exophytic supraglottic tumours, 152
 — tumours, 117
 — — of epiglottis, 178
 Exostosis(es) of external meatus, 299
 — nasopharynx, 135
 Expectoration and secretory neurosis, 114
 Explosion deafness, 386-7
 — — bilateral functional, 398
 — — labyrinth concussion in, 383, 387
 — — and tympanic membrane rupture,
 (Figs. 199, 204) 300, 387
 External auditory meatus, 296, 302
 — — — contracture of introitus, 296
 — — — discharge of, 277
 — — — disease, 296-301
 — — — exostosis 299
 — — — foreign bodies in, 298
 — — — furunculosis, 303-5
 External auditory meatus, haemorrhage in
 temporal bone fracture, 385
 — — — hypertrophied skin in, 296
 — — — impacted wax, 296-7
 — — — inflammation of, 302-8
 — — — injury, 296, 383
 — — — keratosis obturans, 297-8
 — — — maggots in, 298
 — — — malignant tumours in, 381-2
 — — — in mastoiditis, 331, 333
 — — — and middle ear infection, 314
 — — — otalgia, 280
 — — — otitis externa, 296
 — — — in polypi, 324
 — — — tumours of, 299-300
 Extradural abscess, 348, 349, 350, 354-5, 359,
 363
 — — in labyrinthitis, 350
 — — meningitis arising from, 355, 356
 — — paresis in sixth nerve from, 354
 — — perisinus, (Fig. 191) 358, 364, 367
 Eye, abnormalities of, in various syndromes,
 402
 — fissures, shortening of, 402
 — hypertrichosis of, 402
 — paralysis of external rectus (*see also*
 Eyeball; Eyelids), 402
 Eyeball, displacement of, in orbital cellulitis,
 79
 — proptosis of, 80
 Eyelids, abnormalities of, 402
 — oedema of, (Fig. 23) 66, 80
 — — in mastoiditis, 331
 — — orbital cellulitis, 79
 Face, hemiatrophy of, 292
 Facial angiomas, 115
 — bone injury and sinusitis, 65
 — fibrous dysplasia, 87
 — nerve in Bell's palsy, 345
 — — compression of, 346
 — — course of, (Fig. 55) 137
 — — end-to-end anastomosis, 347
 — — in facial palsy, 344
 — — graft of, 346-7
 — — inflammation of, in herpes zoster, 390
 — — in keratosis obturans, 297-8
 — — lesion of, 344
 — — classification of peripheral,
 (Fig. 207) 390
 — — palsy in petrositis, 348
 — — paralysis complicating otitis media,
 346-7
 — — — in injury to labyrinth, 383
 — — — mastoiditis, 338
 — — — middle ear syphilis, 372
 — — — tumour, 381
 — — — in otitis media, acute, 315
 — — skull fracture, 347, 384
 — — temporal lobe abscess, 361
 — — tests for, (Fig. 177) 344-7
 — — in tuberculosis of ear, 369
 — — — tumour of eighth nerve, 394
 — — — — glomus jugulare, 382
 Facio-hypoglossal anastomosis in facial
 paralysis, 347
 False cords, phonation with (*see also* Cords,
 false), 156
 Fauces, pillars of, 94
 — in syphilis, 107

- Fetus, congenital syphilis in, 370
 Fibreoptics, 207, 209, 211-12
 Fibrolipoma of hypopharynx, 236
 Fibroma, 64, 90, 115
 — of larynx, (*Plate VII*, 4) 174
 Fibrosarcoma, parapharyngeal, 115
 — of sinus, 90
 Fibrosis, submucosal, 110
 Fibrositis of neck muscles, and headache, 16
 Filiform papillae, hypertrophy of, 111
 Finger-nose test, 362
 Fistula ante fenestram, 351, 373
 — broncho-oesophageal, 231
 — congenital aural, 294
 — formation with radiotherapy, 184
 — in labyrinthitis, 352
 — oro-antral, 87
 — test in nystagmus, 275-6
 — thyroglossal, 112
 — tracheo-oesophageal, 202
 Fluid intake restriction in Menière's disease, 378
 Foeter in atrophic rhinitis, 37
 Foods, highly seasoned, and pharyngitis, 107
 — particles of, in tonsils, 121
 — producing allergies, 43
 Foramen magnum, coning of, 362
 Forehead indentation after chronic frontal sinusitis operation, 76
 Foreign bodies, 31, 113, 215 et seq., 298
 — — danger in removal of oesophageal, 214
 — — decomposition of, 217
 — — in ear, 283, 298
 — — Eustachian tube, 311
 — — inhaled or swallowed, 215-22
 — — in larynx, (*Figs.* 108, 109, 110) 199, 215
 — — nose, 31-3
 — — oesophagus, 220-2
 — — pharynx, 113
 — — thoracotomy for, 219
 — — trachea and bronchi, 215-16
 Forelock, white, in Waardenburg's syndrome, 402
 Fowler's Alternating Loudness balance hearing test, (*Fig.* 149) 268
 Fractures affecting sinuses, 84-5
 — of nasal bones, (*Fig.* 16) 22-3
 — skull, 383-6
 Frey's syndrome, 281
 Frontal bone, 72
 — sinus, (*Figs.* 3, 5, 10, 12, 30, 37) 6, 9-10, 71, 72-6
 — — brain abscess in, 82-3
 — — development of, 53
 — — drainage of, 68
 — — dysplasia in, 87
 — — and headaches, 56
 — — infection in, 66
 — — injury to, 84-5
 — — mucocele in, 85
 — — osteoma of, 89
 — — osteomyelitis, 53, 76, 80
 — — and process of maxilla, (*Fig.* 2) 1
 — — surgery for, (*Fig.* 35) 76, 83, 84
 — sinusitis, acute, 53, 66
 — — chronic, 70, 75
 — — — treatment, 75
 — — and brain abscess, 82-3
 — — infection in, 66
 Functional aphonia, 189-90
 Fungus growth in larynx, 165
 Fungus growth in nose, 33
 — — throat, 103-4
 Furunculosis, 303-5
 — diagnosis from otitis media, acute, 304
 — of external meatus, 333
 — nasal vestibule, 26
 — treatment for, 304-5
 Gag reflex in laryngoscopy, 151
 Gargoylism in deafness syndrome, 403
 Gastric carcinoma, 245
 — symptoms associated with chronic sinusitis, 69
 Genitals, ulceration of, in Behçet's syndrome, 102
 Genito-urinary tract, Menière-like symptoms, 379
 Geographical tongue, 111
 Giddiness, 277
 — in caisson disease, 388
 — labyrinth injury, 283, 285
 — meningitic neurolabyrinthitis, 388
 — meningitis, 356
 — middle ear tumour, 381
 — otosclerosis, 374
 — secondary syphilis, 372
 Gillette, space of, 105
 Glands, metastatic, 243
 — pre-auricular, 247
 — salivary, 137-141
 Glandular fever, 103
 — metastasis in cancer of the larynx, 179
 Glioma of nose, 61-2
 Globus hystericus, 224, 229, 236
 Glomerulonephritis in deafness syndrome, 404
 Glomus, jugulare, tumours of, 186, 382
 — tumour, 328
 — vagale of vagus nerve, 242
 — and vocal cord paralysis, 186
 Glossitis, 226
 Glossopharyngeal nerve, 254-5
 — neuralgia, 17, 114
 — — and otalgia, 280
 Glottic cancer, 180-1
 — — surgery for, 182
 — stenosis, 196
 Glottis, (*Fig.* 62) 145, 147, 178
 — cancer of, 184
 — examination of, 209
 — foreign body in, 216
 — on inspiration, (*Fig.* 66) 148
 — in laryngeal examination, 151
 — on phonation, (*Fig.* 67) 148
 — polypoidal swelling in laryngitis, 161
 — in voice production, 154
 Glue ear, 319
 Goitre, cystic, 245
 — in deaf-mutes, 404
 Gout, of the larynx, 164
 — and salivary gland enlargement, 240
 Gradenigo's syndrome, 348, 356
 Granular pharyngitis, 107
 Granular-cell myoblastoma, 175
 Granulation(s), (*Plate X*) 327
 — in chronic mastoiditis, 338
 — drumhead perforation, 328
 — facial paralysis, 346
 — mastoid antrum, 326
 — middle ear tumour, 381
 — otitis media, chronic suppurative, 325

- Granulation(s) and polypi, (*Plate IX*) 327-8
 — — in otitis media in attic and antrum, 327
 — tissue, 285
 — — in mastoiditis, 331
 — in tuberculous of ear, 369
 Granuloma of larynx, types, 174-5
 — gravidarum during pregnancy, 175
 Griesinger's sign, 365
 Guillotine method in tonsillectomy, 126
 Gullet reconstruction after laryngectomy, 183-4
 Gumma of cranial base, 379
 — larynx, 164
 — in syphilis of middle ear, 371
 Gummatous ulceration in syphilis, 39
- Haemangioma, 176
 — congenital, 200
 — removal of, 176
 — subglottic, 200
 Haemorrhage, after removal of adenoids, 134
 — following tonsillectomy, 127
 — from pharynx, 113
 — in skull fracture, 385
 Haematoma of auricle, (*Fig. 164*) 294-5
 — nasal septum, (*Plate I*, 1) 23-4
 Haematotympanum, 385
 Haemophilia, 126
 — and epistaxis, 29
 — Menière-like symptoms of, 379
 Hamulus, fracture of, 319
 Hard palate, (*Fig. 46*) 94
 Hashimoto's disease, 239
 Hay fever, 43-4
 — — and salpingitis, 309
 Headache in anterior ethmoidal neuralgia, 17
 — brain abscess, 83
 — causes, 16-17
 — in cerebellar abscess, 362
 — cervical arthritis, 16
 — cluster, 17
 — due to drugs, 392
 — in ear disease, 227
 — examination for, 16
 — in facial neuralgia, atypical, 17
 — fibrosis of neck muscles, 16
 — glossopharyngeal neuralgia and, 17
 — in Menière's disease, 378
 — occipital meningitis, 356
 — otitic hydrocephalus, 368
 — otitis media, acute suppurative, 315
 — — — chronic suppurative, 325
 — in petrositis, 348
 — polyposis, 56
 — rhinitis, 37
 — sinusitis and, 16, 65, 70
 — in sinus thrombosis, 365
 — temporal lobe abscess, 359, 360
 — temporomandibular pain and, 17-18
 — trigeminal neuralgia and, 17
 — in tumour of eighth nerve, 394
 — vacuum, 27, 70
 Hearing aids, 400-1
 — — and otitis externa, 302
 — — senile deafness, 392
 — impairment in otitis media, chronic suppurative, 325
 — restoration by tympanoplasty, 392
 — tests, 264-9
 — — for children, 405
- Hearing tests for malingers, 399-400
 Heart disease and epistaxis, 29
 Heller's operation for achalasia, 229
 Hemianalgesia, contralateral, 380
 Hemianopia homonymous in temporal lobe abscess, test for, 361
 Hemiatrophy of the face, 292
 Hemilaryngectomy, (*Figs. 86-9*) 196
 Hemiparesis in cerebellar abscess, 362
 Hereditary deafness, 402
 Herpes labialis, 356
 — in throat, 102
 — zoster oticus, (*Fig. 208*) 102, 390
 — — — complications, 391
 Heterochromia iridium, 402
 Hiatus hernia, 222, 224
 — — and dysphagia, 225
 — — semilunaris, (*Fig. 12*) 11
 Hiccough in cerebellar abscess, 362
 Hinsberg's labyrinth operation, 353
 Histamine headache, 17
 Hoarseness in laryngitis, 149, 161
 — laryngocele, 176
 — of larynx, 158
 — in pachydermia, 163
 — scleroma of larynx, 165
 — subglottic cancer, 184
 — tumour of larynx, 181
 Hodgkin's disease, 103, 187, 242, 243
 Hormonal factor in nasal mucous, 47
 Horner's syndrome, 380
 Humidification after tracheostomy, 171
 Hunter's syndrome, 403
 Hurst mercury bougie, 226
 Hutchinson's teeth, (*Fig. 22*) 39
 — — in syphilis of ear, 370, 371
 Hydrocephalus in cerebellar abscess, 358
 — chronic progressive, 398
 Hygiene in nasal disease, 50
 Hyoid bone, (*Figs. 46, 60, 122*) 93, 142
 — — cyst, 240
 — — fracture, 193, 195
 — — removal of, (*Fig. 90*) 183
 Hyperacusis, 277
 Hyperaemia and polypus formation, 56
 — of the promontory, 375
 Hyperaemic laryngitis, chronic, 161
 Hyperaesthesia of pharynx, 114
 Hyperbilirubinaemia and child deafness, 404
 Hypernasality after adenoidectomy, 133
 Hyperosmia, cause of, 18
 Hyperplasia, pseudo-epitheliomatous, 175
 Hyperrhinophonia after adenoidectomy, 133
 — in palatal abnormality, 112
 Hypertension and tonsillectomy, 126
 Hypertrichosis of eyebrows, 402
 Hypertrophic laryngitis, chronic, 161
 — — syphilis resembling, 164
 — pharyngitis, 107
 Hypertrophied adenoids and snoring, 19
 Hypochromic microcytic anaemia and dysphagia, 226
 Hypogammaglobulinaemia and catarrh, 51
 Hypoglossal nerve, (*Fig. 55*) 137
 Hyponasality, 97
 Hypopharyngeal cancer, 231
 — tumour, 235, 236
 Hypopharynx, 93
 — cancer of, (*Figs. 120-2*) 234-8
 — disease in otalgia, 280
 — tumours, 235

- Hypophyseal fossa, 11
 Hypophysectomy, 87-8
 Hyporhinophonia in adenoidectomy, 133
 Hypothyroidism and catarrh, 51
 — nasal mucosa, 47
 Hysteria, deafness in, 398, 399
- Ichthyosis in deafness syndrome, 404
 Imbalance in Menière's disease, 377
 Implant procedures in vocal cord paralysis, 188
 Impulse rate, increase in, 270
 Incus, dislocation of and deafness, 383
 — removal in radical mastoidectomy, 339
 Indigestion treatment and dysphagia, 224
 Infancy, causes of deafness in (*see* Congenital deafness)
 Infant, acute retropharyngeal abscess in, 105
 — congenital syphilis of ear in, 370
 — enlarged adenoids in, 130
 — otitis media in, 317-18
 — — — tuberculous, 369
 Infantile osteomyelitis of the maxilla, (*Fig.* 38) 81-2
 Infectious diseases and acute sinusitis, 65
 Infective arthritis of crico-arytenoid joint, 164
 Inferior turbinate bones, (*Fig.* 46) 94
 Influenza, anosmia in, 18
 — coryza in, 35
 — deafness after, 388, 393
 — otitis externa haemorrhagica, 307
 — peripheral neuritis in, 186
 — pharyngitis in, 99
 — tinnitus, 393
 Infra-orbital canal, (*Figs.* 9, 10) 9
 — ridges deformed in congenital deafness, 402
 Infra-temporal fossae, 9
 Infundibulum, (*Figs.* 4, 5, 12) 5, 6, 11
 Inguinal glands in mononucleosis, 103
 Inhalation, steam, 20-1
 — — after polypectomy, 58
 — — and children, 53
 — — in chronic sinusitis, 74, 76
 — — laryngitis, 158, 159
 — — in otitis media, 316
 Innominate artery, (*Fig.* 65) 146
 Instruments for ear treatment, (*Fig.* 161) 291
 Insufflation of powder into ear, 290, 311, 325
 Intensity curve, 344
 Interarytenoid area, granulosomatous tissue on, (*Plate* VII, 3) 162, 163
 — — in laryngoscopy, 209
 — muscle, strain on, 155
 — — triangular gap in, (*Fig.* 74) 156
 — region, pus in, 158
 Internal acoustic meatus, enlargement of, (*Figs.* 211, 212) 396
 — auditory meatus, injury to, 383
 — — — haemorrhage in fundus of, (*Figs.* 199, 201) 384
 — — — with tumour, (*Fig.* 209) 395
 Interstitial keratitis in syphilis of ear, 370, 371
 Intracranial complications of otitis media, 350
 — — sinusitis, 82-3
 — disease and nystagmus, 272
 — tumours and anosmia, 18
 Intranasal antrostomy, 55
 — — for chronic sinusitis, 75
 — crusting and epistaxis, 29
 — tumours, 62-4
- Intraneural haemorrhage and facial paralysis, 347
 Intra-uterine syphilis, 370
 Intubation in allergic laryngitis, 160
 — granuloma and, 174
 — for ventilation assistance, 167
 — versus tracheostomy, 172-3
 Iodides and salivary gland enlargement, 240
 Irradiation and perichondritis, 164
 Isoniazid, use of, in tuberculosis, 40
 Itching in otitis externa, 303
 — of ear, 278
- Jackson bougies, 226
 — laryngoscopy, (*Fig.* 104) 209
 Jacksonian epilepsy in temporal lobe abscess, 361
 Jacobson's branch of facial nerve, 248
 Jobson Horne probe, 297
 Joints, crico-arytenoid, fixation of, 164
 Jugular bulb, septic thrombosis of, (*Fig.* 190) 364
 — vein, tenderness in sinus thrombosis, 365
 — — thrombosis in, 350
 Jugulodigastric nodes, 244
 — — in children, 239
- Kanamycin causing deafness, 392
 — — in children, 404
 Keratoconjunctivitis associated with Mickulicz's syndrome, 240
 Keratosis of larynx, 162
 — middle ear, 328
 — obturans, 297-8
 — of pharynx, (*Plate* VI, 2) 108
 Kernig's sign, 356
 — — in meningitis, 314
 Kidney diseases and epistaxis, 29
 — — in malignant granuloma, 41
 Killian, dehiscence of, (*Fig.* 115) 227
 Klippel-Fell's syndrome, 402
 Kollonychia, 226
 Korner's meatal plastic operation, (*Fig.* 175) 341
 Kveim test for sarcoidosis, 241
- Labial artery, septal branch of, (*Fig.* 7) 7
 Labour, prolonged, and child deafness, 404
 Labyrinth, (*Fig.* 153) 275
 — anatomical relations, (*Fig.* 181) 353
 — in caisson disease haemorrhage, 388
 — capsule, in fracture of cranial base, (*Figs.* 201, 202) 385
 — — injury to, 384
 — — spongification of, in otosclerosis, 373, 375
 — cholesteatoma and, 352
 — circumscribed, 397
 — conditions, diagnosed from Menière's disease, 378
 — defects of, in congenital deafness, 402
 — destruction of, in Menière's disease, 379
 — drainage of, 77
 — and eighth nerve, 383-401
 — — — neurolabyrinthitis, 372
 — exploration of, 353
 — exudate in, 351
 — fistula of, 351, 352
 — fenestration from otosclerosis, 276
 — in granuloma and polypi, 328

- Labyrinth, haemorrhage into, 397
 — infection of middle ear, (*Fig.* 180) 351
 — injuries to, 383–6
 — — surgical exploration in, 385
 — membranous, 352, 373
 — otitis media and, 350
 — surgery for, 352, 353
 — and syphilis of ear, 370
 — tuberculosis in, 369
 — and tumours of eighth nerve, (*Fig.* 210) 394–8
 — vestibular, destruction in Menière's disease, 379
 — in vestibular nystagmus, 272
- Labyrinthine complications, 350
 — concussion, 383
 — deafness, explosion, 387
 — — in mumps, 393
 — — noise, 387
 — haemorrhage in leukaemia, 379
 — hydrops in Menière's disease, 378
 — imbalance associated with nystagmus, 274
 — symptoms in middle ear tumours, 381
- Labyrinthitis, (*Figs.* 178–84) 350–3, 362
 — acute, purulent, (*Fig.* 179) 351
 — balance, loss of, 352
 — cerebellar abscess and, 358
 — — artery thrombosis, (*Fig.* 206) 380, 389
 — circumscribed, 350
 — — Menière-like symptoms of, 379
 — deafness in, 351
 — fracture of base of skull and, 350
 — and leptomeningitis, 388
 — meningeal infection in, 350, 351, 352, 356, 357
 — in middle ear infection, 350
 — nystagmus in, 351
 — otitis media, acute and, 350
 — purulent, 351, 352
 — — Menière-like symptoms of, 379
 — routes of infection, 350
 — serous, (*Fig.* 178) 351, 352
 — tinnitus in, 352
 — treatment for, 352–3
 — tuberculous, 350
 — vertigo and, 352
- Lacrimal glands, Mickulicz's syndrome in, 240
- Lacrimation, test for, 347
- Lamina papyracea, 10
 — — infection of, 53
- Laryngeal atresia in children, 202
 — cartilages in children, 198
 — diseases, chronic, 161–6
 — — investigation of, 149–53
 — examination, (*Figs.* 68, 69, 70) 149–50
 — inflammation, conditions in children, 199
 — nerve lesions, 187
 — — recurrent, (*Fig.* 64) 145, 146, 187
 — — paralysis, 186
 — — vocal cord, 186
 — paralysis, 146, 186
 — — mirror image of vocal cord in, (*Fig.* 93) 188
 — spasm, 204
 — sprays, 161, 162
 — stridor, 204–6
 — surgery, 153
 — trauma in children, 200
 — tumours, 174–7
 — vocal cord paralysis, 186
 — web, congenital, (*Plate* VIII, 4) 202
 — — tracheostomy in, 202
- Laryngectomy, areas removed, (*Figs.* 90, 91) 183
 — in cancer, 178
 — cricoid chondromas, 175
 — hypopharyngeal tumours, 237
 — partial, 146
 — in perichondritis, 165
 — social and psychological effects, 185
 — speech after, 185
 — in subglottic cancer, 184
 — supraglottic, (*Fig.* 84) 180
 — in transglottic tumours, (*Fig.* 90) 182
- Laryngismus stridulus in children, 204
- Laryngitis, acute, 158–9, 199, 204
 — chronic, 161–2
 — diphtheria and, 158
 — hoarseness in, 161
 — overuse of voice in, 155
 — polypoidal swelling of glottis, 161
 — rest for, 158
 — smoking, danger of, 162
 — syphilis and, 158
 — tuberculosis and, 158
- Laryngocele, (*Fig.* 80) 176, 241, 243
 — in children, (*Plate* VIII, 3) 200
- Laryngofissure, 189
 — approach, 196
 — in vocal paralysis, 188
- Laryngography, (*Fig.* 72) 152
 — technique, 152–3, 245
- Laryngomalacia, 204
 — associated with stridor, 205
 — in children, (*Plate* VIII, 2) 198
- Laryngopharyngectomy in hypopharyngeal tumour, 237
- Laryngopharyngo-oesophagectomy in hypopharyngeal tumour, 237
- Laryngopharynx (hypopharynx), 93–94
- Laryngoscopy, 201
 — anaesthesia for, 207
 — for cysts, 176
 — direct, (*Fig.* 104) 153, 207, 209
 — fiberoptic, 153
 — in glottic cancer, 181
 — haemangioma, 176
 — indirect, (*Figs.* 68, 69) 149–50
 — — in pachydermia, 163
 — in injury, 194
 — instruments for, (*Fig.* 104) 208
 — operation for, 209
 — for stridor, 205
 — in tuberculosis of larynx, 163
 — tumours of hypopharynx, 236
 — vocal cord paralysis, 189
- Laryngotomy, technique, 169–70
- Laryngotracheal infections, acute, 158–60
 — stenosis, chronic, 196–7
 — — from scleroma of larynx, 165
 — trauma, 191–7
- Laryngotracheobronchitis, acute, 159–60
 204, 205
- Larynx, 142
 — amyloid diseases of, 176
 — anatomy of, 142–7
 — blood supply, 146
 — carcinoma of, 147, 149, 164
 — in children, 198
 — — foreign bodies in, 199
 — — injury to, 199
 — — papillomata, (*Figs.* 100, 101) 200–1
 — — scalds and burns, 199
 — — stridor in, 204–6

- Larynx in children, tumours, 200-2
 — compartments of, 147
 — corrosive burns of, 230
 — crusting in, 161
 — divisions of, (*Fig. 82*) 179
 — electronic, 185
 — examination of, 151-3, 160
 — foreign body in, (*Fig. 108*) 215
 — fracture of, (*Fig. 97*) 193, 194
 — gout of, 164
 — histology, 146-7
 — hoarseness of (*see* Hoarseness)
 — inflammation of (*see* Laryngitis)
 — injury to, (*Fig. 99*) 195
 — — mirror examination for, 194
 — laboratory investigation of, 151
 — leprosy of, 166
 — lupus in, 163
 — lymphatics, drainage of, (*Figs. 64, 83*) 146, 178
 — mycosis of, 165
 — nerve supply of, 145-6
 — oedema of, 147
 — otalgia from diseases of, 281
 — perichondritis of, 164-5
 — physiology of, (*Figs. 66, 67*) 147-8, 154
 — removal of, 183
 — scleroma of, 165
 — seat-belt injury to, 192
 — structural anomalies of, 202-4
 — syphilis of, 164
 — tuberculosis of, 163
 — tumours of, 151-2, 153, 178
 — viral infection of, 159
 Lavage of nose, 20
 — of sinus, 68
 Lead poisoning, deafness and vertigo from, 392
 Leiomyoma of hypopharynx, 236
 Leiomyosarcoma of hypopharynx, 236, 238
 Leishmaniasis of nose, 42
 Leprosy of larynx, 166
 — nose, 42
 — pharynx, 110
 Leptomeningitis, 388
 — complicating labyrinthitis, 388
 — following temporal bone fracture, (*Fig. 203*) 385
 — and syphilis, 388
 Lermoyez syndrome, 378
 Leucoplakia, 101
 — of larynx, 162
 — tongue and mouth, 115, 116
 Leukaemia, acute, (*Plate V, 3*) 103
 — contra-indication to tonsillectomy, 126
 — epistaxis in, 29
 — labyrinthine haemorrhage in, 379
 — in reticulosis, 242
 Lichen planus, 102
 — — in mouth lesion, 115
 Lip reading, 401
 — site of syphilis, 109
 Lipomas in cervical region, 239
 — of hypopharynx, 236
 Liquid paraffin in nose packing, 30
 Little's area, 3
 Lombard's hearing test, 400
 Ludwig's angina, 100
 Luetic meningitis, 372
 Lumbar puncture in meningitic neuro-labyrinthitis, 389
 — — petrositis, 348
 Lung, apex, carcinoma of, 187
 — protected by larynx, 147
 — in voice production, 154
 Lupus of face, 163
 — larynx, 163
 — nose, 163
 — pharynx, (*Plate VI, 3*) 110, 163
 — diagnosis from syphilis, 109
 — vulgaris in external ear, 369
 Lymphangioma, 200
 Lymphatic drainage of hypopharynx, 234
 — — of larynx, (*Fig. 81*) 178
 — — tonsil, 95
 — glands of larynx, (*Fig. 64*) 146
 Lymph glands and furunculosis of ear, 303
 — — tuberculosis of ear, 369
 — node, 239
 — — dissection, 116-17
 — — enlarged, 123, 149, 239
 — — infected, 239
 — — metastases, 181, 234, 235
 — — in neck reticulosis, 242
 Lympho-epithelial lesion, benign, 240
 Lympho-epitheliomata of pharynx, 117
 Lymphoid tissue, 93, 94, 95
 — — hypertrophy of, 107, 113-14
 — — in nasopharynx, inflammation of, 129
 Lymphoma in malignant granuloma, 41
 Lymphosarcoma of pharynx, 242
 — of sinus, 90
 Macewen's triangle, 332
 McNaught keel, (*Fig. 98*) 202
 — — in hemilaryngectomy, 196
 Macroglia of tongue, 111
 Maggots (myiasis) in ear, treatment for, 298-9
 — — nose, 33
 Magic slate in tracheostomy, 170
 Malar bones deformed in congenital deafness, 402
 Malaria diagnosed from sinus thrombosis, 366
 Malignant disease of middle ear and facial paralysis, 346
 — — sinuses, 90
 — granuloma of nose, 41
 — otitis externa, 308
 — tumours of ear, 381-2
 — — nasopharynx, 135-6
 — — nose, 63-4
 — — pharynx, 115-18
 — — salivary gland, 141
 Malingerers, hearing tests for, 399-400
 Malleus, amputation of, in radical mastoidectomy, 339
 — dislocation of, and deafness, 383
 Mandible, maldevelopment of, 292
 Mandl's paint, 107, 108
 Mantoux test, 151, 245
 Manual alphabet in training deaf children, 406
 Masked mastoiditis, 334
 Masseter hypertrophy resembling parotid swelling, 240
 — muscle, (*Fig. 55*) 137
 Mastoid, 255-7
 — abscess of, 331, 338
 — air cells in, (*Fig. 173*) 331
 — — and pharyngeal abscess, 349
 — — antrum, (*Figs. 131, 172*) 250, 331

- Mastoid antrum, absence of, tenderness in meatal furunculosis, 304
- fluid in, 321
 - infection of, 331, 333
 - — cellular effect in otitis media, 331
 - — tenderness in, 332
 - opening of, 321
 - suppuration, 327
 - and temporal lobe abscess, 358
 - bone, (Fig. 134) 255
 - cavity, carcinoma in, 381
 - cells, in otitis media, chronic suppurative, 319
 - cellular, (Fig. 170) 332
 - cortical operation associated with meningitis, (Figs. 172, 173, 188) 333-4, 335, 357
 - drainage of, 317, 333-4
 - emissary vein, oedema of, 365
 - infection, local spread of, 348-9
 - pain in, 278, 331
 - pneumatization, impaired, 330
 - process in infants, (Fig. 170) 331
 - — infection of cerebellar abscess, 358
 - radiography in otitis media, chronic suppurative, 324, 325
 - sclerotic, (Fig. 170) 332
 - subperiosteal abscess in, (Figs. 171, 172) 331, 333
 - surgery for, (Figs. 172, 174) 335, 340
 - — in cholesteatoma, 339
 - — facial paralysis, 346
 - — for granuloma and polypi, 328
 - — in labyrinthitis, 352, 353
 - — meningitis, 357
 - — septic thrombosis from, 368
 - tenderness of, after treatment, 333
- Mastoidectomy for cholesteatoma, 339
- modification of standard operation, 341
 - radical, (Figs. 174, 175) 327, 338, 339
 - for sinus thrombosis, 367
 - stages of, (Fig. 172) 334-5
- Mastoiditis, acute, (Fig. 171) 331-7
- — antibiotic therapy and, 331
 - — Bezold's, 331
 - — blood examination in, 334
 - — diagnosis, 331, 333
 - — discharge in, 333, 334
 - — fever in, 333
 - — masked, 334
 - — pain of, 332, 333
 - — radiography in, (Fig. 173) 333
 - — Schwartz operation for, (Fig. 172) 335
 - — surgery for, (Figs. 173, 174) 333-4
 - — symptoms, 331-2
 - — treatment, 333-4
 - — zygomatic, 331
 - chronic, (Figs. 174, 175) 338-41
 - — attico-antral disease and, 338
 - — bone infection in, 338
 - — cholesteatoma in, 338, 339, 341
 - — deafness in, 338
 - — discharge in, 338
 - — facial paralysis, 338
 - — granulation tissue in, 338
 - — operation for, 338-41
 - — otitis media, chronic suppurative and, 338
 - — tympanoplasty in, 339
- Maternal rubella and child deafness, 404
- Maxilla, (Figs. 9, 10) 9
- fracture of, 23
- Maxilla, frontal process of, (Fig. 2) 2
- infantile osteomyelitis of, (Fig. 38) 81-2
- Maxillary antrum, 9
- — accessory ostium of, (Fig. 4) 5, 6
 - — angiofibroma of, 134
 - — carcinoma in, 90
 - — cyst in, (Figs. 40, 41) 86-7
 - — artery, external, 1
 - — sinus, allergic oedema of, 54
 - — catarrh in, 53
 - — cysts of, (Figs. 40, 41) 86-7
 - — development of, 9
 - — facial fibrous dysplasia in, 87
 - — injury to, 84-5
 - — malignant tumour in, 90
 - — oro-antral fistula in, 85
 - — polypi in, 58-60, 69
 - — proof puncture for, 73
 - — in rhinitis, 35
 - — sinusitis, acute, (Figs. 28, 29) 53, 66
 - — — dental care in, 68
 - — — osteomyelitis in, 82
 - — chronic, 69
 - — — dental cause of, 69
 - — — head colds in, 53
 - — — headaches in, 70
 - — — surgery in, 75
- Maxillo-ethmoidal cell, (Fig. 10) 9
- Measles associated with meningitis, 388
- — — otitis media, acute, 314
 - — and child deafness, 404
 - — coryza in, 35
 - — Koplik's spots in, 102
 - — pharyngitis in, 99
 - — tonsil enlargement in, 121
- Meatal atresia, (Fig. 162) 292, 296
- — acquired, 296
 - — introitus and skin conditions, 303
 - — stenosis, 303, 403
 - — in chronic mastoiditis, 338
 - — wall fracture, (Fig. 203) 386
- Meatus of nose, (Figs. 3, 4, 8, 12) 2, 3, 5, 6, 8, 9
- Medial nasal nerve, (Fig. 7) 7
- Mediastinal gland enlargement, 245
- Mediastinitis due to foreign bodies, 220
- Mediastinum, infection of, in parapharyngeal abscess, 106
- Melanoma of neck, 239
- nose, 63-4
 - sinuses, 90
- Melano-epithelioma of sinus, 90
- Melanosarcoma of sinus, 90
- Membrana tensa, retraction of, (Plate X) 310
- Membranous pharyngitis, acute (see also Vincent's angina), 100-1
- — causes, 100
 - — infectious nature of, 101
- Menière's disease, 377-9
- — aetiology, 377
 - — allied disorders, 379-80
 - — clinical features of, 378
 - — diagnosis, 378
 - — surgery for, 379
 - — symptoms of, 279, 377
 - — treatment of, 378
- Meningeal abscess, 358
- inflammation, 355
- Meninges, gummatous involvement of, 372
- Meningioma of eighth nerve, 394
- Meningitic neurorabyrinthitis, (Figs. 205, 206) 388-90, 393

- Meningitic neurolabyrinthitis following pneumonia, 388, 389
- Meningitis, (*Fig.* 185) 355-8
- associated with masked mastoiditis, 334
 - — — mumps, 138
 - — — otitis media, 356, 357
 - — — petrositis, 348
 - blood examination for, 356
 - as cause of child deafness, 404
 - cerebrospinal fluid in, 355, 356
 - — — testing, 357
 - circumscribed serous, 356
 - complicating labyrinthitis, 388
 - — sinus thrombosis, 82, 357, 366
 - cranial nerve, paralysis, 357
 - degrees of, 355-6
 - diffuse purulent, 356-7
 - extradural abscess arising from, 354, 356
 - luetic, 372
 - Menière-like signs in, 379
 - myiasis of nose and, 34
 - paralysis in, 357
 - pulse rate in, (*Fig.* 185) 358
 - purulent, 357, 367
 - — — and labyrinthitis, 350
 - serous, diagnosis of, 397
 - surgery for, (*Figs.* 182-4, 188) 357
 - symptoms in otitis media, acute, 314
 - temperature in, (*Fig.* 185) 357
 - treatment for, 357-8
- Meningocele, leakage of, 48
- Meningo-encephalitis, 356
- Menopause, pharyngeal paraesthesia in, 114
- Mental retardation in deafness syndrome, 404
- Mercury causing neuritis of eighth nerve, 392
- Mesenteric adenitis, abdominal pain in, 125
- Metaplasia in aetiology of cholesteatoma, 330
- Metastases of hypopharyngeal tumours, 236
- lymph node, 181, 234, 235, 236
 - in transglottic tumours, 182
- Metastatic abscess in sinus thrombosis, 365
- glands, 237, 243, 244
 - — enlargement, and vocal cord paralysis, 186
- Micrognathia, (*Fig.* 102) 203-4
- chin-tilting in, 205
- Microlaryngeal surgery for cysts in children, 200
- Microlaryngoscopic scissors, 163
- Microlaryngoscopy, 153, 184
- for minor laryngeal surgery, 209
 - web removal at, 202
- Microtia, 292, 403
- Middle ear, acute inflammation of, 314
- — aspiration of, 323
 - — cavity, 249
 - — — tuberculosis of, 369
 - — cholesteatoma in, 326
 - — and cochlear injury, 300
 - — — secondary infection in, 300
 - — in deaf-mutism, 404
 - — deafness, 277
 - — drainage, 313
 - — fibrosis of, 323
 - — haemorrhage after explosion, 383
 - — infection, acute, 312 et seq.
 - — — chronic, 324 et seq.
 - — — facial paralysis, 346, 347
 - — malignant tumours of, 381-2
 - — non-purulent fluid in, 319
 - — otitis media, chronic non-suppurative, 312, 319, 321
- Middle ear perforation, 324
- — — pus in, 314, 324
 - — — surgical drainage of, 333
 - — — tension in, 314
 - — squamous epithelium in, 330
 - — suppuration, (*Fig.* 180) 352
 - — — drainage of, 322, 371
 - — — in extradural abscess, 354
 - — — and sinus thrombosis, 366
 - — — in syphilis, 371
 - — fossa, fracture of, 383
 - — meatus, (*Fig.* 4) 5, 9
 - — mucopus in, 54
 - — in sinusitis, (*Plate* III) 66
 - — turbinate, 46
- Migraine and headache, 17
- and Menière's disease, 378, 379
- Mikulicz cells, 165
- syndrome, 140, 240
- Mirror, examination with, in epiglottitis, 159
- — — laryngotracheal stenosis, 196
 - — — for tuberculosis of larynx, 163
 - — — vocal cord paralysis, (*Figs.* 92, 93) 187
- Mixed salivary tumour, 140
- Mobilization operation of the stapes, (*Fig.* 197) 375
- Mogiphonias, 157
- Monilial oesophagitis, 223
- Moniliasis, 103
- Monomorphic adenoma, 240
- Mononucleosis, infectious, 103, 239, 243, 244
- Mopping the ear, 287
- Motor neuroses of pharynx, 114
- Mouth, carcinoma of, 115-16
- open, and adenoids, (*Plate* VII) 131
 - ulcers of, 101-2
- Mucocele of sinus, surgery for, 76
- — treatment, 85
- Muco-epidermoid carcinoma, 240
- tumour, 140
- Mucopus, nasal, 55
- — examination for, 54
 - — infected, 53
 - — taking specimens of, 67
- Mucosa, laryngeal, in children, 198
- infected, removal from maxillary sinus, 74
 - of mouth in syphilis, 109
 - polypoidal radiography in sinuses, 70
- Mucous glands, nasal, 4, 8
- — of pharynx, 93
 - membrane, nasal, inflammatory conditions of, 35-8
- Mucoviscidosis in catarrh, 51
- and sinus infection, 52, 53-4
- Mucus in nasal catarrh, 15-16
- Mumps associated with otitis media, 314
- as cause of child deafness, 404
 - labyrinthine deafness from, 393
- Muscle grafts in treatment of facial paralysis, 347
- Muscular hypotonia in tumour of eighth nerve, 394
- Mutism, 398, 399
- Mycosis of the larynx, 165
- Myeloencephalography, 396
- Myiasis of nose, 33-4
- Mylohyoid muscle, (*Fig.* 55) 137
- Myositis in laryngitis, 155
- Myotomy procedure, 187
- Myringoplasty, (*Fig.* 176) 326, 342, 343

- Myringotomy for drainage of middle ear, 313, 314
 — of drumhead, 316, 317
 — in labyrinthitis, 352
 — otitis media, chronic non-suppurative, 321, 322
 Myxoedema of larynx, 149
 — and salivary gland enlargement, 240
 Myxosarcoma of sinus, 90
- Nares, 1, 2, 7
 Nasal, allergy, 43–6, 52, 53, 54, 56, 58, 70
 — anosmia in, 18
 — atresia of choanae, 15
 — bones, (Figs. 1, 2) 1, 2
 — — fracture of, 22–3
 — bridge, depressed, 24
 — cartilage, (Figs. 1, 2) 1
 — catarrh, blood in, 16
 — — in children, 50–5
 — examination for, 16
 — cavity, (Figs. 3–7) 2–8, 9
 — — air filtration of, 8
 — — blood supply to, 3
 — — carcinoma of, 63
 — — in catarrh, 50, 72
 — — drainage, 3–4, 54, 55
 — — examination of, 12–14
 — — lateral walls of, (Fig. 11) 2, 10
 — — in leprosy, 36, 42
 — — malignant granuloma, 41, 89, 90
 — — nerve supplies to, 4
 — — packing of, 30
 — — polypi in, 58, 65
 — — in rhinitis, 37
 — — congestion, 8
 — — discharge, 90
 — — in polyposis, 57, 59
 — — rhinitis, 35
 — — scleroma, 42
 — — sinusitis, 65, 69
 — — syphilis, 39
 — — disease, symptoms of, 15–19
 — — drainage, 54, 55, 67, 68, 74, 76
 — — drops, 20, 53, 55, 67, 74, 309
 — — overuse of, 48
 — — haemorrhage (see Epistaxis)
 — — infections, specific, 40–2
 — — — leishmaniasis, 42
 — — — lupus vulgaris, 40–1
 — — — malignant granuloma, 41
 — — — otitis media following, 312
 — — — sarcoidosis, 41
 — — — of sinus (see Sinusitis)
 — — — syphilis, 39–40
 — — — tuberculosis, (Plate I, 4) 40
 — — inhalations, 67, 74
 — — lavage, 20
 — — leprosy and, 42
 — — mucosa, 15, 38
 — — mucous membrane, 35, 36
 — — — — allergy in, 43, 44
 — — — — non-suppurative, 43–9
 — — muscles, 1
 — — obstruction (see Obstruction, nasal)
 — — polyposis, 56–60
 — — rhinitis, 35
 — — rhinorrhoea, 43, 47, 48
 — — secretions, 13
 — — septum (see Septum)
- Nasal sinus disease and otalgia, 281
 — — sprays, 20, 52, 53, 67, 74
 — — overuse of, 48
 — — ulceration, 41
 — — unilateral discharge, 31, 54, 70
 — — vasomotor rhinorrhoea, 47
 — — vestibule, 1, 8
 — — — dermatitis of, 26
 — — — furunculosis of, 26
 — — — in leishmaniasis, 42
 — — — lupus vulgaris, (Plate II, 1) 41
 — — — malignant granuloma, 41
 — — — and sarcoidosis, 41
 — — — tumours in, 62
 Nasofrontal duct, (Fig. 5) 5, 9, 53
 — — closure of, 70
 Nasolacrimal canal, 2
 — — duct, blockage of, 63
 Nasopharyngeal angiofibroma, 134–5
 — — carcinoma and vocal cord paralysis, 63, 186, 188–9
 — — cavity, (Fig. 46) 93
 — — pack as cause of otitis media, 314
 — — tumour, obstruction in, 97
 — — — and otitis media, 312
 Nasopharyngitis and otitis, 319
 Nasopharyngoscopy, 14
 Nasopharynx, 14, 15, 93, 243
 — — cancer of, 135
 — — digital palpation of, 14
 — — diseases of, 129–36
 — — examination of, (Fig. 14) 13, 14, 149, 196–7, 277, 309
 — — haemorrhage of, 113
 — — infection of, 52
 — — and metastatic glands, 243
 — — obstruction of, 97
 — — palatography of, (Fig. 48) 97
 — — plastic closure in palatal arch disorders, 112
 — — polypi in, (Plate II, 4) 57, 59
 — — removal of, 60
 — — speech sounds and, (Fig. 48) 96
 — — tumours, 134–6
 Nausea in herpes zoster oticus, 391
 — — injury to labyrinth, 383
 — — middle ear tumour, 381
 Neck, angiomas in, 115
 — — dissection in hypopharyngeal tumour, 237
 — — — radical, and vocal cord paralysis, 186
 — — injuries, and vocal cord paralysis, 186
 — — masses, examination of, 243–6
 — — — radiological examination of, 245
 — — strap muscles, (Fig. 87) 181, 184
 — — structures, tumours in, 242
 — — surgical emphysema of, 106
 — — tumours of, 179, 242
 Necrosis in syphilis of ear, 372
 Neomycin, deafness caused by, 392, 404
 Nephritis and child deafness syndrome, 404
 Nerve deafness (see Deafness, nerve)
 Nervous complications after tonsillectomy, 127
 Neumann's labyrinth operation, (Figs. 182, 183, 184) 353
 Neuralgia, anterior ethmoidal, 17
 — — atypical facial, 17
 — — and chronic sinusitis, 69
 — — deviated septum and, 27
 — — glossopharyngeal, 17, 280
 — — in herpes zoster oticus, 391
 — — of pharynx, 114
 — — sphenopalatine, 17

- Neuralgia, trigeminal, 17
 Neurilemma, parapharyngeal, 115
 Neurilemmoma, malignant, excision of, 242
 — of vagus nerve, 242
 — in vocal cord paralysis, 186
 Neuritis, due to toxæmia, 397
 — toxic, 393
 — of vestibular nerve, 279
 Neurodermatitis, 303
 — itching in, 303
 Neurofibroma(s), 239
 — acoustic, 394, 396
 — of eighth nerve, (*Figs.* 209, 211, 212) 394
 — larynx, 174
 — vagus nerve, 242
 Neurogenous tumours of vagus nerve, 242
 Neurolabyrinthitis, 372, 388–90
 — meningitis, (*Figs.* 205, 206) 388–9
 — syphilitic, 397
 Neuroma, acoustic, in Menière's disease, 378
 Neuronitis, vestibular, 379
 Neuroses, motor, of pharynx, 114
 — secretory, of pharynx, 114
 Neurosurgical approach to acoustic tumour, 398
 Night blindness in deafness syndrome, 404
 Nodes, palpable cervical, 179, 343–4
 Noise deafness, 387–8
 Nose, anatomy (*see also* Nasal), 1–92
 — bleeding (*see* Epistaxis)
 — — area, 29
 — blood supply to, 1
 — blowing, 67
 — — ear pain in, 278
 — — training in, 52
 — — vigorous, danger of, 35, 67
 — — — in polyposis, 58
 — drops (*see* Nasal)
 — in Eustachian tube disorders, 310
 — examination of, 12–14
 — — children, 14
 — external, (*Fig.* 1) 1, 22–8
 — filtration of air in, 8
 — foreign bodies in, 31–3
 — fracture of, 22
 — functions of, 5–8
 — fungi and parasites in, 33
 — infection of, and pharyngitis, 107
 — injuries, 22–3
 — lymphatic drainage of, 1, 4
 — maggots in, 33
 — mucous membrane of, 4
 — nerve supply to, (*Fig.* 7) 4–5, 8
 — nostrils (*see* Nares)
 — paranasal sinuses of, 8–11
 — physiology of, 5–8
 — picking, in children, 29
 — scleroma of, 42
 — tumours of, 61–4, 89, 92
 — ulceration, 41
 Nostrils (*see* Nares)
 Nystagmus, 270, 271, 272–5
 — in cerebellar abscess, 362
 — degrees of, (*Figs.* 152, 153) 273
 — following head injury, 203
 — in herpes zoster oticus, 391
 — labyrinthitis, 351
 — in Menière's disease, 378
 — meningitic neurolabyrinthitis, 388
 — meningitis, 356
 — otitic hydrocephalus, 368
 — positional, 379–80, 395
 Nystagmus, rotatory, 393
 — spontaneous, 227, 273–4, 277, 395
 — in syphilis of ear, 372
 — temporal lobe abscess, 361
 — tumour of eighth nerve, 394
 — types of, 272
 Obstruction in aero-sinusitis, 84
 — due to foreign body in oesophagus, 220
 — of Eustachian tube, 310, 312, 319, 375
 — in laryngotracheal trauma, 194
 — nasal, 15
 — — in adenoids, enlarged, 15, 97, 130, 131
 — — children, 15
 — — concha, 15
 — — deviated septum and, 26–7
 — — effect on voice, 18
 — — examination for, 15
 — — pharyngitis in, 97, 99
 — — polyp and, 15, 18, 56, 59, 97, 326, 328
 — — in sinusitis, 69, 89
 — — in tumour, 89, 97, 134
 — — respiratory, 159, 172, 205
 Obturators, ear, 388
 Ocular muscles, paralysis of, in orbital cellulitis, 79
 — nystagmus and ocular disease, 272
 Oedema, allergic of sinuses, 54
 — angioneuritic, 160
 — in epiglottitis, 159
 — of eyelids, 80
 — — in orbital cellulitis, 79
 — laryngitis, in children, 199
 — of larynx, 147, 167
 — in nasal allergy, 44
 — — polypus, 59
 — rhinitis, 55
 — submucosal of nose, 65
 — in tuberculosis of larynx, 163
 Oesophageal carcinoma, barium study of, 245
 — speech, 185
 — stricture and dysphagia, 225–6
 — wall, scratch or tear of, 222
 Oesophagitis, 214
 — corrosive, 225
 — long-standing, 225
 — monilial and dysphagic, 223
 Oesophagoscope, (*Fig.* 107) 213
 Oesophagoscopy, 212–14
 — for corrosive burns, 230
 — dysphagia, 225
 — for tumour of hypopharynx, 236
 — — oesophagus, 232
 Oesophagus, (*Fig.* 65) 147, 149, 223, 224
 — cancer of, (*Fig.* 119) 224, 231–3
 — carcinoma of, 187, 212, 243
 — — and vocal cord paralysis, 186
 — cervical, (*Fig.* 121) 234
 — corrosive burns of, (*Fig.* 118) 229–31
 — in dysphagia, 223, 224
 — foreign bodies in, (*Figs.* 111, 112) 214, 221
 — — — radiography for, 221
 — perforation of, 212–13
 Olfactory bulb, (*Fig.* 8) 5
 — cleft in sinusitis, (*Plate* III, 3) 66
 — disturbances, 18
 — nerve, (*Figs.* 7, 8) 5, 7
 — — and sinusitis, 82
 — sense, 8
 — — factors affecting, 8

- Olfactory sense, tests for, 18
 — sulcus, (*Fig.* 12) 11
 — tract, 11
- Oncocytoma, 176
- Ophthalmic artery, 1
 — disorders and sinusitis, 69
 — nerve supply to nasal cavity, 4
 — vein, thrombophlebitis of, 80
- Optic aphasia in temporal lobe abscess, 361
 — atrophy in orbital cellulitis, 79
 — chiasma, 11
 — neuritis in meningitis, 356, 357
- Orbit, mucocele in, (*Plate IV*) 85
- Orbital cellulitis, (*Fig.* 23) 53, 66
 — and abscess, (*Fig.* 36) 79–80
 — from cellulitis, 66
 — periostitis, 79
- Orf, 239
- Oro-antral fistula, 85
 — — following dental extraction, 85
 — — — surgery, 85
 — — from malignant tumour, 85
- Oropharynx, (*Fig.* 47) 93, 147, 178
- Ossicles, 251
 — necrosis of, 327, 342
- Ossicular chain, disease of, 342, 343
 — — in skull fracture, 385
- Ossiculoplasty, 342
- Osteogenesis imperfecta, 403
- Osteoma of external meatus, 299
 — frontal sinus, 89
- Osteomyelitis of frontal bone, (*Fig.* 37) 53
 — maxilla, 80–3
 — surgery for, 76
 — syphilitic, of bony labyrinth, 370
- Osteoplastic flap operation, 76, 80
 — — surgery in injured sinus, 84
- Ostium(ia), 9, 11
 — nasal, (*Fig.* 3) 4
 — obstruction in sinusitis, 65
 — and polypi, 56
 — in rhinitis, 35
 — sinus, (*Fig.* 4) 5
- Otalgia, 280–1
 — and pharyngeal causes, 280
- Otitic barotrauma, 311
 — brain abscess, 358
 — hydrocephalus, 368
- Otitis externa, (*Fig.* 166) 302–5
 — — acute, 277
 — — antibiotics and, 303
 — — associated with atresia, 296
 — — bacteriology, 302–3
 — — chronic, 303, 305
 — — diffuse, 305–6
 — — discharge from, 277
 — — furunculosis in, 304
 — — haemorrhage in, 307–8
 — — malignant, 308
 — — and neurodermatitis, 307
 — — otomycosis, 306
 — — packing for, (*Fig.* 160) 290
 — — purulent, 303
 — — media, acute, 304, 308, 312–18
 — — — adenoids as factor in, 312, 314
 — — — in children, 312, 313, 314
 — — — infants, 317–18
 — — — adenoidectomy for, 317
 — — — aural suppuration and, 317
- Otitis media, acute, infants, myringotomy for, 317
 — — — — otoscopic examination in, 317
 — — — — nasopharyngeal tumour and, 312
 — — — — non-suppurative, 312–14, 329–30
 — — — — nasal, infectious and, 312
 — — — — rhinitis, allergic and, 312
 — — — — suppurative, 314–16
 — — — — associated with tuberculosis of middle ear, 369
 — — — — bacteriology, 314
 — — — — demanding mastoid surgery, 334
 — — — — discharge in, 316
 — — — — facial paralysis in, 315
 — — — — infants and, 314
 — — — — myringotomy for, 316, 317
 — — — — syringing in, 315, 317
 — — — — temperature in, 315–16
 — — — — tinnitus in, 312
 — — — — treatment for, 313–14
 — — — — upper respiratory disease in, 312
 — — — — associated with Eustachian tube conditions, 309
 — — — — bone involvement in, (*Fig.* 173) 336
 — — — — catarrhal and syphilitic nasopharyngitis, 371
 — — — — chronic, non-suppurative, 319–23
 — — — — adenoid infection in, 132
 — — — — adenoidectomy for, 322–3
 — — — — aetiology of, 320
 — — — — aspiration of fluid in, (*Fig.* 168) 321, 322
 — — — — in children, 52
 — — — — myringotomy for, (*Fig.* 168) 321, 322
 — — — — pathology of, 320
 — — — — symptoms of, 320
 — — — — tinnitus in, 323, 324
 — — — — treatment and after treatment, 321–2
 — — — — suppurative, 324–30
 — — — — aspiration of fluid from, 325
 — — — — bacteriology, 324
 — — — — clinical features, (*Plate X*) 324–5
 — — — — drainage in, 326
 — — — — myringotomy in, 326
 — — — — purulent discharge in, 325
 — — — — — and extradural abscess, 354
 — — — — surgery for, 326
 — — — — tinnitus in, 325
 — — — — treatment for, 325–6
 — — — — tubotympanic infections in, 325
 — — — — in circumscribed labyrinthitis, 397
 — — — — examination for, 297
 — — — — exudative, 319
 — — — — facial paralysis, 346–7
 — — — — in infants, 369
 — — — — intracranial complications, 354
 — — — — and labyrinthitis, 350
 — — — — mastoiditis, 331, 338
 — — — — — masked, 334
 — — — — Menière-like symptoms in, 379
 — — — — and meningitis, 356
 — — — — nose blowing and, 35, 67
 — — — — otitic barotrauma and, 311
 — — — — petrositis and, 348
 — — — — and pharyngeal abscess, 349
 — — — — pulmonary tuberculous disease, 369
 — — — — secretory, 319
 — — — — in sinusitis, chronic, 70

- Otitis media, syphilis in, 371
 — — — in infants, 370
 Otogenic intracranial infection, 363
 Otomycosis, 306
 — antibiotics and, 306
 — itching in, 303
 — otitis externa and, 306
 Otorrhoea, chronic, in middle ear disease, 381
 — — — otitis media, 325
 — — — following mastoidectomy, 348
 — in granulations and polypi, 328
 — recurrence after otitis media, chronic suppurative, 326
 Otosclerosis, (*Figs.* 194–7) 373–7
 Otoscope, (*Fig.* 155) 283
 Otoscopic examination of ear, 297
 Otoscopy in salpingitis, (*Plate X*) 309
 Ototoxic antibiotics, 392
 — antibodies and tinnitus, 278
 Outstanding auricle, (*Fig.* 163) 294
 — — — plastic surgery for, 294
 Oval window, (*Figs.* 194, 195, 196) 374
 — — — injury to, 383
 — — — in sensorineural deafness, 393
 Oxyphil-cell adenoma, 176
 Ozaena, 37
- Pachydermia of larynx, 162
 — removal of tissue in, 163
 Packing the ear, (*Fig.* 160) 289–90
 Pain in acinic-cell tumour, 141
 — aero-sinusitis, 84
 — after tonsillectomy, 127
 — in ear, causes of, 277, 278
 — extradural abscess, 354
 — from cysts, 86
 — in furunculosis, 304
 — granulations and polypi 328
 — labyrinthitis, 352
 — laryngeal, 149
 — in laryngitis, 158
 — malignant tumour of pharynx, 117
 — middle ear tumour, 381
 — nasal sarcoma, 63
 — orbital cellulitis, 79
 — salpingitis, 309
 — sinus infection, 70
 — — tumours, 90
 — ulcers of mouth, 102
 Palatal paresis associated with otitis media, 312
 Palate, cleft, 96
 — — submucous, 96
 — — hard, (*Fig.* 46) 94
 — in mononucleosis, 103
 — peritonsillar abscess, (*Plate VI*, 5) 120
 — soft, (*Fig.* 46) 94
 — — in adenoidectomy, 133
 — — bifid uvula, 112
 — — catarrhal pharyngitis, 107
 — — causing hyperrhinophonia, 112
 — — in Eustachian catheterization, 289
 — — papillomata, 115
 — — and tonsillectomy, 124
 — in syphilis, 109, 371
 Palatine arches, congenital abnormalities of, 112
 — — — papillomata of, 115
 — — — and syphilis, 109
 — — — artery, (*Fig.* 7) 3, 7
 — — — nerve, (*Fig.* 8) 7
 — — — tonsil, (*Fig.* 47) 97
- Palatoglossal fold, (*Fig.* 47) 97
 Palatograph of nasopharynx, (*Fig.* 48) 97
 Palatography, 96
 Palatopharyngeal fold, (*Figs.* 46, 47) 94
 Panendoscopy, 245
 Pantopaque contrast medium, 396
 Papilloedema in cerebellar abscess, 362
 — — — otitic hydrocephalus, 368
 Papilloma(ta), 63, 89–90, 204
 — — — of larynx, (*Plate VII*, 5) 174
 — — — multiple, in children, (*Figs.* 100, 101) 200–2
 — — — — — removal of, 90, 201
 — — — — — removal of, 174
 — — — of pharynx, 115
 Papillomatosis of nose, (*Fig.* 43) 89–90
 Paracentesis in otitis media, acute suppurative, (*Fig.* 167) 316
 Paracusis Willisii, 277
 — in otosclerosis, 373, 374
 Paraesthesia of pharynx, 114
 Parangiomas, 242
 — non-chromaffin, 242
 Paralysis of facial nerve (*see also* Facial paralysis), 381
 — — — in keratosis obturans, 298
 — — — in temporal bone fracture, 384
 — — — tuberculous otitis, 346
 — laryngeal, in children, 200
 — — — vocal cord in adults, 149, 186–90
 Paranasal sinuses, 8–11
 — — — cysts in, 86–7
 — — — development of, 53
 — — — infection in, 65–83
 — — — — — associated with nasal polypi, 56–60
 — — — — — dental causes, 68, 72
 — — — — — injury, 84–5
 — — — — — miscellaneous affections, 84–9
 — — — — — mucocele in, 85
 — — — — — nasopharyngitis, 129
 — — — — — orbital cellulitis in, (*Fig.* 23) 53, 79–80
 — — — — — oro-antral fistula in, 85
 — — — — — osteomyelitis in, 80
 — — — — — ostia, 67, 68, 69
 — — — — — polyposis in, 56–60
 — — — — — radiography of, (*Figs.* 28–31) 71, 72
 — — — — — sinusitis, acute, 65–8
 — — — — — in children, 53–5
 — — — — — chronic, 69–83
 — — — — — tumours of, 89–92
 Parapharyngeal abscess associated with tonsillectomy, 106
 — — — tumours, 115
 Parasitic cysts resembling parotid swelling, 240
 Parasympathetic fibres of nose, 5
 Parasympathomimetic drugs, effect of, 47
 Paratracheal nodes, removal of, 184
 — — — in subglottic cancer, 184
 Paresis, facial, 344–8
 — — — primary ischaemic, 345
 — — — of sixth nerve in extradural abscess, 354
 — — — third nerve, 360
 Parosmia, 18
 Parotid duct, (*Fig.* 55) 137
 — — — gland, (*Fig.* 55) 137–8
 — — — inflammation of, 138–9
 — — — swelling, diagnosis of, 138–141
 — — — tumours, (*Fig.* 57) 140
 Parotitis, 138
 — — — acute suppurative, 138–9
 — — — chronic, recurring, 139
 Paroxysmal vertigo, 374

- Pars intermedia of facial nerve, 390
 PAS (para-aminosalicylic acid), 110
 — in lupus vulgaris and tuberculosis, 40, 110
 Past-pointing test, 273
 Patent ductus, ligation of, and vocal cord paralysis, 186
 Paterson-Brown Kelly syndrome, (Figs. 113, 114) 224, 226, 236
 Patterson operation, 77
 Paul-Bunnell blood test, 103, 245
 Pel-Épstein fever pattern, 243
 Pemphigoid lesion of mouth, 102
 — vulgaris ulcers, 102
 Peptic ulcer treatment and dysphagia, 224
 Perceptive deafness, 402
 Perforation of septum, 28
 — tympanic membrane, (Plate X) 285
 — — — repair of, 342
 — — — traumatic, 300-1
 — ulcer of septum, 28
 Perichondritis of auricle, (Fig. 165) 295
 — larynx, 164
 — — and irradiation for cancer, 164
 — — tuberculosis of larynx, 163
 Perinatal cause of congenital deafness, 404
 Periostitis, 333
 Peripheral nerve lesion of facial nerve classification, (Fig. 207) 390
 — — and vocal cord paralysis, 186, 187
 Perisinus abscess, (Fig. 189) 365
 Peritonsillar abscess (quinsy), 120
 — — — evacuation of, (Fig. 49) 120
 — — — in otalgia, 280
 Perseveration in temporal lobe abscess, 360
 Petrosal nerve, 5
 Petrositis, associated with meningitis, 356
 — mastoid, 348
 Petrous bone infection, complications of, 348
 — — — in meningitis, 355
 Pharyngeal (*see also* Pharyngitis; Pharynx)
 — abscess, secondary to otitis media, 349
 — disorders, 112-15
 — infection, 140
 — mucosa, 103
 — pouch, (Figs. 115, 116) 187, 224, 227-9
 — — — removal of, 228
 — — and vocal cord paralysis, 186
 — recess, 14
 — tonsil (adenoid), 130-4
 — ulcers, 102
 — wall, posterior, mucosa in, 98
 — — — and pharyngitis, 107, 108
 — — — in syphilis, 109
 — — tumours in, (Figs. 120, 121) 234, 236, 238
 Pharyngectomy in hypopharyngeal tumour, 237
 Pharyngitis, acute, 99-103, 107
 — — — membranous, 100-1
 — — — in blood disorders, 103
 — — — chronic, 107-8
 — — — diseases associated with, 99
 — — — septic, 99-100
 — — — complication of, 100
 — — — treatment for, 100
 — — — simple, 99
 Pharyngo-epiglottic fold, 234
 Pharyngotomy and tongue tumours, 116
 Pharyngotympanic tube, (Fig. 131) 254
 Pharynx (*see also* Pharyngeal; Pharyngitis), 93
 — abscesses of, 105-6, 348
 — acute inflammation of, 99-104
 Pharynx, anatomy and physiology of, (Fig. 46) 93-5
 — atrophic condition of, 108
 — in blood disorders, 103
 — congenital anomalies, 112
 — crusting in, 37, 108
 — cysts of, 112-13
 — examination of, (Fig. 47) 96-8
 — fibroma of, 110
 — foreign bodies in, 113
 — haemorrhage of, 113
 — infections of, 99
 — in laryngectomy, 182
 — leprosy of, 110
 — lupus of, 110, 163
 — otalgia in, 280
 — sarcoma of, 115
 — scleroma of, 110
 — specific infections of, 109-11
 — syphilis of, 109
 — tuberculosis of, 110
 — tumours of, 115-18
 Phonic spasm, 156
 Phonasthenia, 157
 Phonation, (Fig. 67) 148
 — larynx and, 147
 — physiology, 154
 — with false cords, 156
 Photophobia in meningitis, 356
 Pierre-Robin syndrome, 203
 Pitch and frequency measurement in voice tests, 153
 Pituitary gland, 11
 — — — operations on, 87-8
 Pleomorphic adenoma, 140, 176
 — — — of the parotid gland, 240
 Plummer-Vinson syndrome, 226
 Pneumatized mastoid process, (Fig. 170) 331
 Pneumonia due to decomposed foreign body, 217
 — septic, arising from sinus thrombosis, 365
 — sinusitis and, 53
 Pointing test in cerebellar abscess, 362
 Politzer bag in fistula test, 274
 — ear inflation method, 288, 289
 Politzerization in ear treatment, 289
 Pollen allergy, 43-4
 Polybrene, deafness from 392
 Polydysplastic epidermolysis bullosa of pharynx, 102
 Polypus(i), (Plate II) 44, 55, 76-7, 91, 285
 — after-treatment, 58
 — aircraft pilots and, 84
 — allergic origin of, 56, 57, 58
 — anosmia in, 18, 56
 — aural, 324, 326, 327-8
 — — — removal by snare, (Plate X; Fig. 169) 328
 — bilobed, (Fig. 25) 59
 — bleeding in, 63
 — catarrh in, 56
 — decongestant sprays for, 57
 — nasal, 8, 113
 — naso-antral, (Fig. 25) 58-60
 — in otitis media, chronic suppurative, 325
 — pedunculated, (Fig. 24) 56, 57
 — — — removal of, 58
 — — — removal of, 58
 — resembling tumour, 62
 — in sinusitis, chronic, 69, 70, 71
 — and vocal cord, (Fig. 81) 149, 177
 — voice disturbance, 18
 Polytome in examination of larynx, 152

- Positional nystagmus, 379-80, 395
 — types, 273-4, 379-80
- Postauricular gland in mononucleosis, 103
- Poststricoid cancer and otalgia, 281
 — region, (*Figs.* 120, 122) 234
 — tumours, 234
- Posterior ethmoidal cells, ostium of, (*Fig.* 4) 5
 — inferior cerebellar artery thrombosis, 380
 — meatal wall, polypus and, 328
 — nares, 14
 — — occlusion, (*Fig.* 18) 24
- Postnatal causes of congenital deafness, 404
- Postsyphilitic complications, 109
- Post-tonsillectomy pain and otalgia, 280
- Post-tracheostomy stenosis, 196
- Pre-auricular glands, 247
- Pregnancy, effect of otosclerosis in, 375
 — granuloma gravidarum during, 175
- Premalignant tumours of pharynx, 115
- Prematurity and child deafness, 404
- Prenatal causes of congenital deafness, 402-3
- Presbycusis, 375, 392
- Primary tumours of neck structures, 242-3
- Promontory, caries of, (*Fig.* 180) 352
 — fracture of, 375
 — in otosclerosis, 375
- Proof puncture, accidents in, 86
 — — for cysts, 86
 — — in sinusitis, chronic, (*Fig.* 32) 68, 71, 72, 73
- Proptosis of eyeballs, 80
 — in nasopharyngeal tumours, 135
- Prosthesis in stapedectomy, (*Fig.* 198) 375
- Prussak's space, (*Fig.* 132) 253
- Pseudo-epitheliomatous hyperplasia, 175
- Psychogenic deafness, 398-9
- Pterygoid canal, 5, 11
 — — nerve of, 46, 48
 — — destruction of, 48
 — plexus, 3, 4
- Pterygopalatine fossae, 9
 — ganglion, (*Fig.* 8) 4, 5, 7 11
- Ptosis in temporal lobe abscess, 360
- Pulse disturbance in ear disease, 277
 — rate in meningitis, (*Fig.* 185) 358
 — — sinus thrombosis, (*Fig.* 185) 364-5
- Pure tone audiometry in hearing tests, 400
- Purpura and epistaxis, 29
- Purpuric haemorrhage in leukaemia, 103
- Pyæmia due to sinus thrombosis, 364
- Pyocoele, 176, 241, 244
- Pyogenic granuloma resembling carcinoma, 175
- Pyriform fossae, (*Fig.* 70) 94, 236
 — — foreign bodies and, 220
 — — in laryngoscopy, 209
 — — of larynx, 147
 — — lymphatic drainage, (*Fig.* 120) 234, 235, 236
 — — and metastatic glands, 243
 — — tumour and surgery, 180
 — — treatment, (*Fig.* 122) 234, 235, 236, 237
- Quinine causing deafness, 391, 392
 — and child deafness, 404
 — tinnitus, 278
- Quinsy, 120, 126
- Radical antrostomy for sinusitis, 75-6
 — neck dissection, 246
- Radiography for bronchial carcinoma, 245
 — cysts, (*Figs.* 40, 41) 86
 — for dysphagia, 224
 — foreign bodies, 218, 221
 — mediastinal gland enlargement, 245
 — mucocoele, 85
 — osteomyelitis, 80
 — sinus injury, 84
 — of sinuses for sarcoma, 63
 — in sinusitis, chronic, (*Figs.* 28, 29, 30) 66, 70, 71-3
- Radiological examination in temporal lobe abscess, 361
- Radiology for laryngeal disorders, 151
- Radiotherapy as alternative to laryngectomy, 184
 — in cancer of larynx, 179, 180
 — failure of, 181
 — for glomus jugulare, 382
 — hypopharyngeal tumour, 237
 — sarcoma, 63
 — subglottic cancer, 184
 — symptoms after, 164
- Ramsey Hunt's syndrome, 390
- Ranula, 113
- Recruitment tests for hearing, 268-9, 378
- Refsun's syndrome, 404
- Reinke's layer, 177
- Reissner's membrane, (*Fig.* 206) 259, 260
- Respiratory function of nose, 5-6
 — — tests in examination of larynx, 157
 — — paralysis in cerebellar abscess, 362
 — tract, infections associated with laryngitis, 159
 — — stridor in, 205
- Retention cyst of pharynx, 112, 113
- Reticulosarcoma, parapharyngeal, 115
- Reticulosis, gland removal in, 246
 — in neck swelling, 242
 — nodes in, 244
 — of thyroid gland, 239
- Reticulum-cell sarcoma, 242
- Retinitis pigmentosa syndrome, 404
- Retro-auricular oedema, 305
- Retrobulbar neuritis in orbital cellulitis, 79
- Retropharyngeal abscess of aural origin, 350
 — — chronic, 105-6
 — — of pharynx, acute, (*Plate VI*) 105
 — lymph glands, 105
- Rhinitis, acute, 35-6, 65
 — — and epistaxis, 38
 — — allergic and otitis media, 312
 — — and anosmia, 18
 — — atrophic, 16, 18, 37-8
 — — and pharyngitis, 108
 — — chronic, 52-3, 55
 — — hypertrophic, 36-7
 — — fibrinous, 36
 — — medicamentosa, 48
 — — ozaena in, 37
 — — sicca, 16, 38
 — — vasomotor, 16, 46
- Rhinoliths in nose, 33
- Rhinorrhoea, 33, 43-9
 — cerebrospinal, 48-9
 — medicamentosa, 48
 — nasal allergy and, 43-4
 — vasomotor, 46-8
- Rhinophyma, (*Plate III*, 1) 62
- Rhinoscopy, anterior, (*Fig.* 13) 12
 — posterior, (*Fig.* 14) 13

- Rinne's hearing test, 265-6
 — — — false negative, 266
 — — — in Menière's disease, 378
 — — — otosclerosis, 375
 — — — senile deafness, 392
 Ristocetin, deafness from, 392
 Rivinus, notch of, 249
 Romberg's test, 362, 395
 — — — in nystagmus, 395
 Rosenmüller, fossa of, 14
 Rotation tests, chair turning, 274
 — — — for children, 274
 — — — in nystagmus, 274
 Rotatory acceleration, 270, 271, 272
 Rubella, maternal abnormalities of children
 and deafness, 404
 — ear pain in, 278
- Saddle nose, 24
 Salicylates, deafness due to, 391
 — and tinnitus, 278
 Salivary glands, (*Fig. 55*) 137
 — — — diseases of, 138-41, 239-40, 243
 — — — enlargement of, 240
 — — — Mikulicz's syndrome, 240
 — — — sarcoidosis, 140
 — — — secretion, stimulation of, 140
 — — — suppression of, 138, 140
 — — — tumours, 176
 — — — tissue reticulosis, 242
 Salpingitis, acute, 309
 — chronic, 310
 Santorini, fissures of, 248
 Sarcoidosis, 41, 140, 242
 — and uveitis, Heerfordt's syndrome, 240
 Sarcoma(ta) of middle ear, 381
 — nasal tumour, 63
 — of nasopharynx, 135
 — pharynx, 115
 — tonsillar, 117
 Scala tympani and explosion injury, 383
 — — haemorrhage after explosion,
 (*Fig. 199*) 384
 — — infiltration of, (*Figs. 205, 206*) 395
 — — vestibuli, infiltration of, (*Fig. 206*) 395
 Scalds of larynx, 204
 Scalp, infection of, and ear pain, 278
 Scanning technique, 245
 Scarlet fever associated with otitis media,
 acute, 314
 — — pharyngitis in, 99
 — — tonsil enlargement in, 121
 Schirmer's blotting-paper test for measuring
 lacrimation, 347
 Schwartz's operation for cortical mastoid,
 (*Fig. 172*) 333-4
 Scleroma of larynx, 165
 — nose, 42
 — pharynx, 110
 Screamer's nodes, 155
 Seat-belts and injuries, (*Figs. 94, 95*) 191
 Seborrhoeic dermatitis, (*Plate X*) 306
 — — itching in, 303
 — — eczema, 306-7
 Secondary syphilis of pharynx, 109
 Secretions, removal of after tracheostomy, 171
 Secretory otitis media, 319
 Semicircular canal, diseased, giddiness in, 279
 — — response to angular rotation, (*Figs. 150,*
 151) 270, 271, 274
- Semon's Law, 186
 Senile deafness, 392-3
 — nerve deafness, 397
 Sensorineural deafness, aids for, 264, 266, 268,
 375, 394, 401
 — — of doubtful origin, 393-4
 — — and explosions, 387
 — — following injury to labyrinth, 383
 — — in Menière's disease, 378
 — — and speech therapy, 401
 Sensory nerve supply of ear, 257
 — neuroses of pharynx, 114
 Septal abscess, (*Fig. 16*) 23-4
 — cartilage, (*Fig. 1*) 1, 3
 — haematoma, aspiration of, 23-4
 — surgery and perforation of septum, 28
 — thrombosis of sigmoid sinus, 358
 Septum, nasal, (*Figs. 6, 14*) 3, 14
 — bleeding area of, 3, 7, 29
 — — polypus of, 63
 — blood supply of, 3
 — deflected, 15, 19, 84
 — — associated with sinusitis, 53
 — deviated, as cause of sinusitis, (*Fig. 20*) 26-7,
 65
 — — surgery for, 27-8
 — — — complications from, 28
 — examination of, 13
 — fibroma of, 64
 — perforation of, 28
 — — due to ulcer of, 28
 — — and syphilis, 39, 40
 — in rhinitis, 38
 — sarcoma of, 63
 — in tuberculosis, 40
 Serous meningitis, diagnosis, 397
 Short-wave diathermy in sinusitis, 68, 74, 75
 Sialiectasis, (*Fig. 56*) 239
 Sicca syndrome, 240
 Siegle speculum, (*Fig. 158*) 286
 Sigmoid sinus, exposure of, (*Fig. 191*) 367
 — — laminated clot in, (*Fig. 189*) 365
 — — septic thrombosis of, 358
 Simulated deafness, tests for, 399-400
 Singers, rest for, in laryngitis, 158
 — tonsillectomy and, 126
 — vocal disability in, 155-6
 Sinus(es), (*Fig. 3*) 4
 — function of, 11
 — infection, 53-4
 — — in children, 16
 — — treatment of, 66, 74
 — physiology of, 11
 — thrombosis, 364-8
 — — antibiotics and, 364
 — — associated with meningitis, (*Fig. 185*) 357
 — — blood examination in, 366
 — — diagnosis, 366-7
 — — in extradural abscess, 355
 — — following mastoid operation, 366
 — — surgery, (*Fig. 191*) 367
 — — treatment, 367-8
 — — tumours of nasal, (*Figs. 42-5*) 89-92
 — — wash-outs after otitis media, acute, 317
 Sinusitis, 16, 53-5
 — acute, 53, 65-8
 — — catarrhal, 65, 66
 — — causes of, 65
 — — complications of, 55
 — — coryza in, 65, 66
 — — dental infections in, 65

- Sinusitis, acute, discharge in, 65, 66
 — — ethmoidal, 66
 — — frontal, 66
 — — headaches in, 65
 — — malaise in, 65
 — — maxillary, 66
 — — miscellaneous, affections, 84–93
 — — pain in, 65
 — — polypus formation in, 56
 — — pyrexia, 65, 66
 — — secondary infection in, 65
 — — short-wave diathermy in, 68
 — — surgery for, 67–8
 — — virus infections of, 65, 67
 — — — — and antibiotics, 67
 — — chronic, 69–92
 — — — — air flight and, 70
 — — — — allergic conditions, 70
 — — — — antrostomy for, 75–6
 — — — — in children, 53–5
 — — — — disorders associated with, 69
 — — — — headache in, 70
 — — — — inflammatory lesion in, 69
 — — — — and keratosis obturans, 237
 — — — — polypi in, 70, 71, 74
 — — — — poppyoidal mucosa in, 70
 — — — — proof puncture, 73
 — — — — radiography in, 71–3
 — — — — short-wave diathermy for, 74
 — — — — surgery for, (Figs. 34, 35) 75, 76
 — — — — treatment of, 74
 — — complications of, 79–83
 SISI (short increment sensitivity test), 269
 Sixth nerve paralysis in meningitis, 357
 Sjögren's syndrome, 140, 240
 Skin allergy in otitis externa, 302
 — tests in nasal allergy, 44–5
 Skull abnormalities in deafness syndrome, 403
 — base of, fracture of, and anosmia, 18
 — — — — deafness following, 383
 — — — — tumours of, and vocal cord paralysis, 186
 — fractures causing facial paralysis, 347
 — — and rupture of tympanic membrane, 300
 Smell, sense of, 8
 — — loss of, 18, 56
 Smoking, avoidance of, in laryngitis, 149, 161
 — effect on larynx, 147
 — excessive, and hyperaesthesia of pharynx, 114
 — — leucoplakia and, 115
 — — and pharyngitis, 107
 — and nasopharyngitis, 129
 — rhinitis, 38
 — squamous cancer, 178, 184
 Sneezing, 18–19
 — nasal allergy, 43
 Snoring, (Fig. 15) 19
 — polypus and, 59
 Snuff, dangers of, 48
 Soft palate, (Fig. 46) 94
 Sound conduction in hearing tests, 267
 — distortion of, in Menière's disease, 378
 Spasm, foreign bodies and laryngeal, 216–17
 Speech after tonsillectomy, 124, 128
 — audiometer, (Fig. 148) 268
 — development in deaf child, 406
 — — hearing tests and, 292
 — enlarged tonsils and, 126
 — lessons after laryngectomy, 185
 — oesophageal, 185
 — in otosclerosis, 374
 Speech, sounds, nasopharynx and, 96
 — — therapists and pachydermia, 163
 — — therapy, 157, 401
 — — after laryngectomy, 183–4
 — — — — surgery, 183, 184, 185
 — — in laryngitis, 161
 — in tumours of eighth nerve, 394
 Spheno-ethmoidal cell, (Fig. 11) 9
 — recess, (Figs. 4, 5, 31, 46) 2, 3, 4, 5, 6, 7,
 Sphenoidal ostium, (Figs. 3, 4) 4, 5
 — sinus, (Figs. 4, 5, 6, 10, 30, 46) 3, 4, 5, 6,
 10, 11
 — — chronic inflammation of, 70
 — — development of, 53
 — — infection of, 78
 — — sinusitis, acute, 68
 Sphenopalatine artery, 3
 — foramen, 3
 — nerve, (Figs. 7, 8) 7
 — neuralgia, 17
 Spindle-cell carcinoma of hypopharynx, 236
 Spine abnormalities in deafness syndrome, 403
 Spiral lamina, fracture of, (Fig. 203) 386
 Spondylitis and vertebral artery ischaemia, 380
 Spontaneous nystagmus, 273–4, 395
 — — falling in, 273–4
 — — pointing in, 273
 Sporadic congenital deafness, (Figs. 213–16) 402
 Sprays, in laryngitis, 162
 — nasal, 20
 Stapedectomy, (Fig. 198) 375
 Stapedius paralysis, 346
 — tendon involvement in skull fracture, 347
 Stapes, mobilization of, (Fig. 195) 375
 — removal of, (Fig. 198) 375
 Stellate ganglionectomy in Menière's disease, 379
 Stenosis, chronic laryngotracheal, 196
 — in children, 202
 — and foreign bodies, 220
 — glottic, 196
 — laryngotracheal, chronic, 196
 — supraglottic, 196, 204, 205
 — tracheal, 172
 — in tuberculosis of larynx, 196
 — tumours and, 196
 Sternohyoid muscle, (Figs. 77, 78, 87) 170
 Sternomastoid muscle, (Figs. 55, 77) 137, 170
 Steroid depot therapy, 45
 Stewart's malignant granuloma, 41
 Stomatitis, angular, 226
 Strength-duration curves, (Fig. 177) 344
 Streptomycin and child deafness, 404
 — effect on ears, 392
 Stridor, 204
 — associated with diphtheria, 199
 — in children, 204–6
 — congenital laryngeal, (Plate VIII, 2) 198
 — in micrognathia, 203
 — scleroma of larynx, 165
 Stroboscopy in examination of larynx, 153
 Stylohyoid muscle, (Fig. 55) 137
 Styloid process, enlarged, 122
 Subclavian artery, (Fig. 65) 146, 204
 Subglottic cancer, 147, 184
 — haemangiomas, 200
 — laryngitis, 205
 — lymphangiomas, 200
 — oedema, in children, 199

- Sublingual fold, (*Fig. 55*) 137
 — salivary gland, (*Fig. 55*) 138
 — — — inflammation of, 139
 Submandibular duct, (*Fig. 55*) 137
 — gland, (*Fig. 55*) 1, 137
 — — in cancer of the tongue, 116
 Submucosal fibrosis of pharynx, 110
 Suboccipital craniectomy in tumour surgery, 398
 — glands in mononucleosis, 103
 Subperiosteal abscess, 79
 Superior turbinate, (*Fig. 46*) 94
 Supraclavicular masses due to metastatic glands, 244
 — — in stomach cancer, 244
 Supraglottic oedema in children, 199
 — stenosis, 196, 204, 205
 — — in children, 202
 Supraglottitis, 146, 147, 176, 178, 184
 — cyst in children, 200
 — in hemilaryngectomy, 182
 — redness in laryngitis, 161
 — tumour of, 181
 — — laryngectomy for, 180
 Swallowing and achalasia, 229
 — difficulty in, 149
 — disorders in micrognathia, 203
 — in epiglottitis, 159
 Sweating in sinus thrombosis, 364
 Swimming as cause of otitis media, 299, 314, 326
 Sympatheticomimetic drugs in acute sinusitis, 47
 Syndrome(s) associated with the ears, 281
 — deafness, 402-3
 Syphilis, (*Fig. 22*) 35-40
 — and child deafness, 404
 — of ear, 330-2, 370-1
 — larynx, 164
 — nose, 39
 — and osteomyelitis of bony labyrinth, 370
 — otitis media, 371
 — perforation of septum, 28
 — of pharynx, 109-10
 — — simulating Vincent's angina, 101
 Syphilitic disease of the ear, Menière-like symptoms in, 379
 — nasopharyngitis, 371
 — neuritis of cochlear nerve, 370
 — neuroabyrinthitis, 397
 Syringing ear, (*Fig. 159*) 274, 287, 297, 298, 324
 — in granuloma and polypi, 328
 — otitis externa, 302
 — — media, acute suppurative, 315
 — — — chronic suppurative, 325
 — precautions for, 297, 300

 Tape recording in examination of larynx, 153
 Taste, loss of, 56
 — — in skull fracture, 347
 Teal's test for simulated deafness, 400
 Teeth, carious and leucoplakia, 115
 — diseased, and cysts, (*Fig. 41*) 86
 — examination of, 96
 — loosening in sinus tumours, 90-1
 — molar, (*Figs. 9, 10*) 9
 — in otalgia, 280
 — syphilis and, (*Fig. 22*) 39
 — wisdom, (*Figs. 9, 10*) 9
 Teflon injections, 188
 — — for paralysed cord, 187

 Teflon paste, 187
 — piston in stapedectomy, (*Fig. 198*) 375
 Temperature in brain abscess, (*Fig. 185*) 358
 — ear disease, 277
 — rise in extradural abscess, 354
 — in sinus thrombosis, 364, 365
 Temporal arteritis, 17
 — bone fracture, (*Fig. 200*) 383
 — — radiography for, (*Fig. 200*) 385
 — lobe abscess, 358-61
 — — — anosmia in, 361
 — — — associated with meningitis, 356
 — — — character changes in, 361
 — — — compression in, 360
 — — — drainage of, 361
 — — — in labyrinthitis, 350
 — — — paresis in, 360, 361
 Temporomandibular joint and otalgia, 280
 — pain and headache, 17-18
 Temporoparietal lobe abscess, 361
 Tensor tympani, 253
 Thalidomide, 404
 Thiouracil and salivary gland enlargement, 240
 Third nerve paralysis in meningitis, 357
 — — in temporal lobe abscess, 360
 Throat, fungus infections of, 103
 Thrombophlebitis of ophthalmic veins, 80, 83
 — septic, in diploic bone, 80
 — sinusitis and, 82
 — of venous sinus, 364
 Thrombosis, cavernous sinus, (*Fig. 39*) 83
 — lateral sinus, 334
 — in malignant granuloma, 41
 — septic of sigmoid sinus, 350
 Thrush of throat, 103
 Thyro-arytenoid muscle, (*Figs. 60, 73*) 145
 — hoarseness and, 158
 — strain on, 155
 Thyroglossal duct cyst, (*Fig. 123*) 112, 240, 244
 Thyroid membrane, 146
 — laryngocele and, 176
 — muscle, (*Fig. 87*) 181
 Thyroid, adenoma, 244
 — cartilage, (*Figs. 58, 59, 60, 63, 122*) 142, 145
 — chondrosarcoma of, (*Fig. 79*) 175
 — fracture, 195
 — in hemilaryngectomy, 182
 — injury of, (*Fig. 96*) 192, 193
 — removal, (*Fig. 90*) 182
 — in vocal cord paralysis, 188
 — function test, 151
 — gland, cancer of, (*Fig. 122*) 187
 — — spread of, 184
 — — carcinoma and vocal cord paralysis, 186
 — examination of, 149
 — isthmus of, (*Figs. 77, 78*) 170
 — tumours of, 181
 — masses, 239
 — — nodule, suspicion of, 239
 — — and scanning, 245
 — and thyroglossal duct cyst, 240
 Thyroidectomy trauma and vocal cord paralysis, 186, 187
 Thyroiditis, 239
 Thyrotoxicosis, 236
 Tinnitus, 277, 307
 — in barotrauma, 312
 — caisson disease, 388
 — causes of, 278
 — drugs causing, 391, 392, 393
 — in glomus jugulare tumour, 382

- Tinnitus, herpes zoster oticus, 391
 — keratosis obturans, 298
 — labyrinthitis, 352
 — Menière's disease, 377
 — meningitic neurolabyrinthitis, 388
 — meningitis, 356
 — noise deafness, 387
 — otitis media, 312
 — otosclerosis, 373, 375
 — rupture of tympanic membrane, 300
 — syphilis, secondary, 372
 — — of middle ear, 371
 — in temporal bone fracture, 385
 — tumours of eighth nerve, 394
 — vestibular neuronitis, 379
 — wax and, 296
- Tobacco, excessive use of, and anosmia, 18
 — — — impairment of hearing by, 392
 — — — and rhinitis, 36
- Tobey-Ayer test, 365
- Tomography of larynx, (*Fig. 71*) 151-2
 — paranasal sinuses, (*Fig. 45*) 91
 — in temporal bone fracture, 385
- Tone decay level in hearing test, 269
- Tongue, (*Figs. 46, 55, 70*) 94, 137, 151
 — affected by lepto- and rhinitis, 165
 — affections of, 111
 — electrical stimulation of, 347
 — examination of, 96
 — in facial paralysis, 346, 347
 — foreign bodies in, 113
 — in laryngectomy, 180
 — laryngoscopy, indirect, 162
 — in neuralgia of pharynx, 114
 — pharyngeal paraesthesia, 114
 — site of syphilis, 109
 — in thyroid adenoma, 244
 — tumour of, 115-18
 — ulcer on, 102
- Tonsillar cancer, 245
- Tonsillectomy, 53, 55, 123-8
 — after treatment, 127
 — in chronic tonsillitis, 122
 — complications of, 127
 — examination for, 123
 — history, 124
 — hypertrophy of lingual tonsil after, 113
 — justification for, 53, 126
 — and speech disorders, 124
 — in tuberculosis, 122
- Tonsillitis, acute, 53, 121
 — associated with parotitis, 138
 — chronic, 120
 — follicular in children, 52
 — loss of appetite in, 124
 — in otalgia, acute, 280
 — virus infection in, 125
- Tonsillolith, 122
- Tonsils, 94
 — abscesses of, 120, 121
 — affections of, 119
 — bone in, 122
 — calculus of, 122
 — cartilage in, 122
 — enlargement of, 121
 — foreign bodies in, 113
 — infected, 52, 379
 — — and sinusitis, 65
 — and keratosis of the pharynx, (*Plate VI, 2*) 108
 — lingual, hypertrophy of, 113-14
 — — paraesthesia in, 114
- Tonsils, palatine, (*Figs. 46, 47*) 46, 94, 96
 — papillomata on, 115
 — pedunculated, 97
 — pharyngeal, in nasopharyngitis, 129,
 — in pharyngitis, 99
 — removal of, 46, 123-8
 — site of syphilis, 109
 — tuberculosis, 122
 — ulcers of, 103
 — Vincent's angina of, 100-1
- Tooth bud, infection from (*see also* Teeth), 82
 — septic, as cause of sinusitis, 68
- Toothaches, in facial fibrous dysplasia, 87
- Topognostic facial nerve test, 347
- Torticollis in sinus thrombosis, 365
- Toxaemia and giddiness, 279
- Toxic neuritis, Menière-like symptoms in, 379
- Toxoplasmosis, 239, 243, 244
- Trachea, (*Figs. 65, 77, 78, 122*) 147
 — in bronchoscopy, 209
 — cancer of, 184
 — in children, 198
 — crusting of, 172
 — — in atrophic laryngitis, 161
 — foreign body in, (*Fig. 108*) 215
 — viral infection in, 159-60
- Tracheal rings, removal of, 182
 — stenosis, 152, 172
- Tracheo-oesophageal fistula, in children, 202
 — — in dysphagia, 224
- Tracheostome, (*Fig. 91*) 183
- Tracheostomy, 167-73
 — in children, 200
 — complications in, 171-2
 — — blockage of tube, 172
 — — difficult decannulation in, 172
 — — dysphagia in, 172
 — — surgical emphysema in, 171-2
 — — trachea erosion and haemorrhage, 172
 — epiglottitis and, 159
 — functions of, 167
 — in laryngeal stenosis, 202
 — — web, 202
 — laryngotracheobronchitis, 160
 — larynx injury, 194
 — for papillomata, 174
 — postoperative care, 169-70
 — — — of dressings, 171
 — — — humidifier, 171
 — — — inflatable cuff, 171
 — — — magic slate in, 170
 — — — removal of tube, 171
 — — — secretions, 171
 — stenosis from, 196, 202
 — in subglottic cancer, 184
 — technique, (*Figs. 76, 77, 78*) 168
 — tubes for, 168
 — types of, 168
- Transglottic tumours, 182-3
- Transmeatal operation in chronic mastoiditis, 339
- Trans-sphenoid hypophysectomy and cerebro-spinal leak, 48
- Transverse fracture of temporal bone, 383
- Traumatic deafness, 388
- Trautmann's triangle, 358
- Tracher Collins' syndrome, 292, 402
 — — micrognathia in, 203
- Trigeminal nerve, 4
- Tubal air cells, 349
- Tuberculoma of the brain, 369

- Tuberculosis, acute miliary of pharynx, 110
 — associated with child deafness, 404
 — — — perichondritis of larynx, 164
 — of cervical glands, 122
 — ear, 369-70
 — — complications, 369
 — — diagnosis, 370
 — — labyrinthitis, 369
 — — treatment, 370
 — laryngitis and, 158
 — of larynx, 163-4
 — in neck swelling, 241
 — of nose, 40
 — pharynx, 110
 — and septum perforation, 28
 — stenosis in, 196
 — of tonsils, 122
 Tuberculous labyrinthitis, 369
 — laryngitis and otalgia, 281
 — mass in neck, 246
 — meningitis, 388
 — middle ear infection and facial paralysis, 346
 — — nodes in neck, 244
 Tubotympanic disease in chronic mastoiditis, 324, 338
 — infection, 325
 — — chronic, 327
 Tularaemia, 239
 Tumours, acoustic, 394-8
 — — differential diagnosis, 396
 — — examination, 394-5
 — — Menière-like symp.oms, 379
 — — treatment, 397
 — benign, of external meatus, 299-300
 — — larynx, 174-7, 200
 — — nasopharynx, 135
 — — nose, 62-3
 — — pharynx, 115
 — — salivary glands, 240
 — — sinuses, 89-90
 — — tongue, 115
 — carotid body, 242
 — congenital, of larynx, 200
 — — nose, (Fig. 26) 61-2
 — — glomus jugulare, 382
 — malignant, chemotherapy, 91, 118, 136
 — — of ear, 381-2
 — — hypopharynx, 234-8
 — — larynx, 178-85
 — — nasopharynx, 135-6
 — — nose, 63-4
 — — pharynx, 116
 — — oesophagus, 231-3
 — — salivary glands, 141
 — — sinuses, 90-3
 — — tongue, 115
 — and neck masses, 242-3
 — neurogenous, 242
 — premalignant, larynx, 162
 — — pharynx, 115
 — — Warthin's, 240, 245
 Tuning-fork tests for hearing, (Fig. 146) 265, 375
 Turbinate bone (see Conchae)
 Tympanic air cells, 349
 — antrum, (Fig. 131) 252
 — — infection of, in labyrinthitis, 350
 — — in mastoiditis, 331
 — cavity and temporal lobe abscess, 358
 — — and tuberculous ear, 369
 — floor, fracture of, (Fig. 203) 386
 Tympanic membrane, (Fig. 127) 248, 263, 285, 309, 310, 342
 — — appearance after temporal bone fracture, 385
 — — and cholesterol granuloma, 329
 — — damage to, by explosion, 383
 — — examination of, 125, 282, 283, 284
 — — and explosion rupture, (Figs. 199, 204) 387
 — — incision of, (Fig. 167) 316
 — — in masked mastoiditis, 334
 — — and meningitis, 356
 — — occluded by wax in non-suppurative otitis media, 320
 — — otitis externa haemorrhagica, 307
 — — in otitis media, (Plate X) 312, 313
 — — otoscopic examination of, 297
 — — perforation of, causes of, (Figs. 180, 203) 300, 326, 327
 — — — in mastoiditis, 333
 — — — myringoplasty for, (Fig. 176) 326
 — — — in otitis media, chronic suppurative, 324, 325
 — — — tuberculous ear, 369
 — — and polypus, 324
 — — pressure of wax on, 296
 — — removal of, in radical mastoidectomy, 339
 — — in acute rhinitis, 35
 — — syphilis of ear, 370
 — — tearing of, in fracture, bleeding from, 383
 — — traumatic rupture of, 300
 — — in tumour of glomus jugulare, 382
 — — tympanoplasty, 342
 — — and vertigo, 278-9
 — — muscles of ear, 253
 — — plexus neuralgia, 281
 Tympanoplastic procedures, 327
 — — total (baffle effect), (Fig. 176) 342, 343
 — — types of, 343
 Tympanoplasty, 342-3
 — — antibiotics and, 342
 — — for cholesteatoma, 327
 — — in chronic mastoiditis, 339
 Tympanosclerosis, in otitis media, 322-3
 Tympanotomy, 323
 Tympanum, exudate in, (Fig. 203) 386
 — in labyrinthitis, 350
 — otitis media, (Plate X) 312
 — rupture in explosion, (Figs. 199, 204) 387
 — in syphilitic nasopharyngitis, 371
 Typhoid fever confused with sinus thrombosis, 366
 — — nerve deafness from, 393
 — — pharyngitis in, 99
 U.I.C.C. T.N.M. tumour classification, 178
 Ulcer(s) in acute miliary tuberculosis of pharynx, 110
 — of mouth and larynx, 101-2, 280
 Ulceration, aphthous, 196
 — in leprosy of larynx, 166
 — malignant granuloma, 41
 — mouth and larynx in otalgia, 280
 — pyogenic granuloma, 41
 — syphilis of middle ear, 372
 Upper respiratory tract infection and otitis media, chronic non-suppurative, 312, 314, 319, 326, 327

- Uvula, (*Figs. 47, 69*) 93
 — bifid, 94, 312
 — in catarrhal pharyngitis, 107
 — laryngeal examination, (*Fig. 69*) 150
 — papillomata of, 115
 — in pharyngitis, 99, 100
- Vacuum headache, 27, 70
- Vagal tumours, 244
 — — and vocal cord paralysis, 186
- Vagus nerve, (*Fig. 65*) 146
 — — lesions affecting, 186
 — — tumour of, 242
- Vallate papillae in tonsil hypertrophy, 113
- Vallecula, (*Fig. 70*) 147, 178, 180
 — examination of, by laryngoscopy, 209
 — syphilis in, 109
- Valsalva's manoeuvre, 310, 311, 313
 — method of ear inflation, 403
- Vancomycin, deafness from, 392
- Van der Hoeve's syndrome, 403
- Vascular anomalies in children, 203-4
- Vasoconstriction, drugs causing, 47
- Vasodilatation, drugs causing, 47
- Vasomotor balance, factors affecting, 47, 48
 — — imbalance, 46
 — — rhinitis, 16, 46
 — — rhinorrhoea, 46-8
 — — theories in Menière's disease, 377
- Vein graft in stapedectomy, (*Fig. 198*) 395
- Ventilation assistance by tracheostomy, 167-8
- Ventricle of larynx, (*Figs. 59, 60*) 147, 176, 178
 — — prolapse of, 163
- Ventricular fold, 151
- Ventriculogram, 396
- Vertebrobasilar artery ischaemia, 380
- Vertigo caused by drugs, 391, 392
 — — conditions producing, 377-80
 — — in ear disease, 278
 — — epidemic, 379
 — — in explosion deafness, 387
 — — herpes zoster oticus, 391
 — — labyrinthitis, 352
 — — otitis media, chronic suppurative, 325
 — — in otosclerosis, 374
 — — petrositis, 348
 — — positional nystagmus, 380
 — — posterior inferior cerebellar artery thrombosis, 380
 — — tumour of eighth nerve, 394
 — — — glomus jugulare, 382
 — — vertebrobasilar artery ischaemia, 380
 — — in vestibular nystagmus, 272
- Vestibular apparatus, drugs affecting, 392
 — — examination of, 395
 — — functional examination of, 272-6
 — — physiology of, 370
 — — fold or false vocal cord, (*Figs. 59, 60, 70*) 142
 — — function, disturbance by explosion, 383
 — — injury in explosion deafness, 386, 387
 — — — meningolabyrinthitis, 386, 387
 — — nerve, affections in, 393
 — — — divisions of, in Menière's disease, 379
 — — — neuritis, 379
 — — nystagmus due to labyrinthine irritation, 248, 272
 — — test in facial nerve paralysis, 347
 — — testing by caloric studies in Menière's disease, 378
- Vestibulocochlear nerve, 261
- Vibrissae, nasal, and air filtration, 8
- Vidian's nerve, 46
- Vincent's angina, 100-1
 — — infection confused with syphilis, 109
- Viomycin, deafness from, 392
- Virus infection of pharynx, 102
 — — and sinusitis, 65
 — — in tonsillitis, 126
- Vision, dimness of, in tumour of eighth nerve, 394
- Vitamin B complex, deafness and vestibular disturbance from, 393
- Vocal cords or fold, (*Figs. 59, 60*) 145, 146, 202
 — — cancer in, (*Plate VIII, 1*) 181
 — — detached, 194
 — — development of, 154
 — — examination of, 149-51
 — — — by laryngoscopy, 207-9
 — — false, (*Fig. 59*) 147, 151, 178
 — — — examination of, 209
 — — — tumour in, 178
 — — — ulcerative growth in, 178
 — — — fibroma and, 174
 — — — function of, (*Fig. 60*) 148
 — — — in injury, 192
 — — — laryngitis, 161
 — — — oedema of, 163
 — — — papilloma and, (*Plate VII*) 174
 — — — paralysis, 149, 186-90, 204
 — — — lateral adductor, 189
 — — — — complete, 188
 — — — — incomplete, 189
 — — — in bronchial carcinoma, 158
 — — — children, 200
 — — — in hypopharynx cancer, 236
 — — — polypoid, and, 149
 — — — unilateral complete, 187-8
 — — — — incomplete, 188-9
 — — — polypus in, (*Fig. 81*) 149, 177
 — — — positions of paralysed, 186
 — — — removal of, in cancer surgery, 182
 — — — straining of, 149
 — — — stripping, 162, 184, 209
 — — — in subglottic cancer, 184
 — — — supraglottic laryngectomy, 180
 — — — thyroid fracture, 195
 — — — tumour of, (*Plate VIII, 1*) 181
 — — — ulceration of, in tuberculosis of larynx, 163
 — — — white patches in leucoplakia, 162
 — — — fold (*see* Vocal cords)
 — — — nodules, 155-6
 — — — processes and pachydermia, 162
- Vocalis muscles, 145
 — — hoarseness and, 158
- Voice, effect of adenoid hypertrophy on, 130, 131
 — — in cerebellar abscess, 362
 — — development, 155
 — — disturbance of, 18
 — — epiglottitis and, 159
 — — faulty use of, and pharyngitis, 107
 — — loss of, in laryngectomy, 185
 — — problems of, 154-7
 — — production, 190
 — — — and pharyngitis, 107
 — — — physiology of, 154-5
 — — rest in laryngitis, 155-6, 158, 161
 — — retaining, after supraglottic laryngectomy, 180
 — — — in glottic surgery, 182

INDEX

- Voice, strain, 155
— in unilateral complete paralysis, 187
Vomer bone, (*Fig. 6*) 3, 6
Vomer nasal cartilage, 1
Vomiting in caisson disease, 388
— cerebellar abscess, 362
— labyrinthitis, 352
— Menière's disease, 377, 379
— sinus thrombosis, 365
— temporal bone abscess, 359
- Waardenburg's syndrome in congenital deafness, 402
Waldeyer's ring, 95
Warthin's tumour, 240, 245
- Wax and deafness, 303
— in ear, 277, 285, 296-7, 298
— removal, (*Fig. 159*) 287, 297
— — softening, 297, 298
— — and rupture of drumhead, 300
Web(s) of larynx, 204, 205, 224
— formation of, in acoustic meatus, 296
Weber's hearing test, 266, 275, 278, 400
Wegener's malignant granuloma, 41
Whispered voice test, 264-5
- Zeiss operating microscope, 209
Zygoma, fracture of, 23
Zygomatic air cells, 334
— — — in mastoiditis, 331

