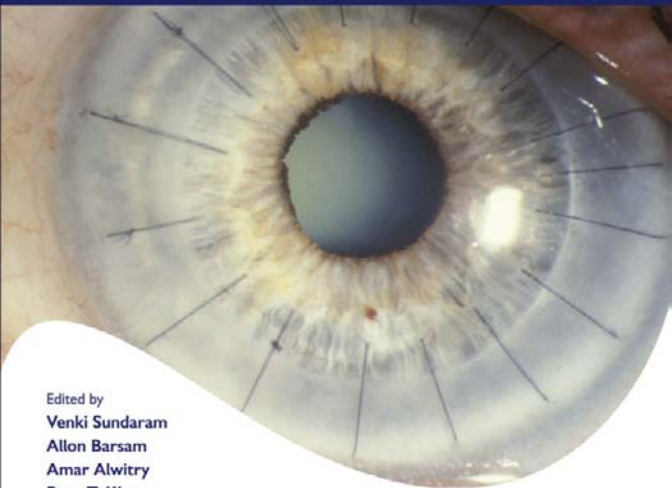



Edited by  
**Venki Sundaram**  
**Allon Barsam**  
**Amar Alwitary**  
**Peng T. Khaw**

# TRAINING IN **OPHTHALMOLOGY** the essential clinical curriculum

Foreword by Mr Larry Benjamin

---

## **Oxford Specialty Training: Training in Ophthalmology**

Oxford University Press makes no representation, express or implied, that the drug dosages in this book are correct. Readers must therefore always check the product information and clinical procedures with the most up-to-date published product information and data sheets provided by the manufacturers and the most recent codes of conduct and safety regulations. The authors and the publishers do not accept responsibility or legal liability for any errors in the text or for the misuse or misapplication of material in this work.

► Except where otherwise stated, drug doses and recommendations are for the non-pregnant adult who is not breast-feeding.

---

# Oxford Specialty Training: Training in Ophthalmology

**Edited by**

**Venki Sundaram**

Specialty Registrar in Ophthalmology,  
London Deanery,  
London

**Allon Barsam**

Specialist Registrar in Ophthalmology,  
Moorfields Eye Hospital,  
London

**Amar Alwitry**

Consultant Ophthalmologist,  
Derby Hospitals NHS Foundation Trust,  
Derby

**Peng T. Khaw**

Professor of Glaucoma and Ocular Healing and Consultant Ophthalmic Surgeon,  
Institute of Ophthalmology,  
University College London,  
London

**OXFORD**  
UNIVERSITY PRESS



# OXFORD

UNIVERSITY PRESS

Great Clarendon Street, Oxford OX2 6DP

Oxford University Press is a department of the University of Oxford.  
It furthers the University's objective of excellence in research, scholarship,  
and education by publishing worldwide in  
Oxford New York

Auckland Cape Town Dar es Salaam Hong Kong Karachi  
Kuala Lumpur Madrid Melbourne Mexico City Nairobi  
New Delhi Shanghai Taipei Toronto

With offices in

Argentina Austria Brazil Chile Czech Republic France Greece  
Guatemala Hungary Italy Japan Poland Portugal Singapore  
South Korea Switzerland Thailand Turkey Ukraine Vietnam

Oxford is a registered trade mark of Oxford University Press  
in the UK and in certain other countries

Published in the United States  
by Oxford University Press Inc., New York

© Oxford University Press 2009

The moral rights of the author have been asserted

Database right Oxford University Press (maker)

Crown copyright material is reproduced under Class Licence  
Number C01P0000148 with the permission of OPSI  
and the Queen's Printer for Scotland

First published 2009

All rights reserved. No part of this publication may be reproduced,  
stored in a retrieval system, or transmitted, in any form or by any means,  
without the prior permission in writing of Oxford University Press,  
or as expressly permitted by law, or under terms agreed with the appropriate  
reprographics rights organization. Enquiries concerning reproduction  
outside the scope of the above should be sent to the Rights Department,  
Oxford University Press, at the address above

You must not circulate this book in any other binding or cover  
and you must impose the same condition on any acquirer

British Library Cataloguing in Publication Data

Data available

Library of Congress Cataloging in Publication Data

Data available

Typeset by Cepha Imaging Private Ltd, Bangalore, India  
Printed in Italy  
on acid-free paper by  
LEGO SpA – Lavis, TN

ISBN 978-0-19-923759-3

1 3 5 7 9 10 8 6 4 2

To my wife Champa, and my parents and family,  
for their constant support and encouragement.  
(Venki Sundaram)

To Sarah, Aron, Ezekiel, our parents, and siblings for constant inspiration and support.  
Without you this work would not have been possible. (Allon Barsam)

To my wonderful wife Claudia, and my amazing boys Max and Toby. (Amar Alwitary)

*This page intentionally left blank*

# Foreword

Modern educational theory alludes to the different ways in which people learn. Some rely on text-based information and others are more at home with pictorial or graphic based material. This book provides both, with a rich source of factual text and beautiful complimentary photographs and diagrams.

Added to this is a structured and relevant approach to the subject for trainees and trainers alike, covering important basic science concepts as well as a wide range of clinical topics.

The link to the Royal College of Ophthalmologists' new curriculum with case-based discussions at the end of relevant chapters will make this book indispensable for all trainees as it provides a method of applying the learned facts to real clinical situations that in itself provides motivation to the reader.

Its portability and accessible style make it easy to use and it deserves to become the standard reference not only for Ophthalmic trainees but for those from other related specialties and the more enthusiastic medical student.

The authors bring many years of accumulated experience in teaching and learning Ophthalmology and this text is the carefully thought out, well presented and easily readable result.

Larry Benjamin FRCS(Ed) FRCOphth DO  
Consultant Ophthalmic Surgeon  
Honorary Secretary  
Royal College of Ophthalmologists

*This page intentionally left blank*

# Foreword—a trainee's perspective

It gives me great pleasure to write the trainee foreword for this book, which delivers a number of excellent features finally brought together in one place. It is written with the Royal College of Ophthalmologists' new curriculum in mind so will be ideally suited to the needs of the new Specialty Registrar from ST1 all the way up to junior consultant level. Chapters 1–10 conclude with a number of case studies which follow a similar format to the case-based studies of the undergraduate and Foundation Year curricula and reinforce the content presented in the chapters.

Emphasis on detailed therapeutic information makes this book useful in a very practical sense. In addition, recent advances have been incorporated throughout each chapter to reflect the rapid pace of change in our specialty over the past 10 years. For example, new sections on optical coherence tomography, refractive surgery, chemical injuries and the management of trauma, and anti-vascular endothelial growth factor therapies all convey a very contemporary feel to the content.

Furthermore, the book is presented in a compact format so that it can be used for quick reference on a daily basis. As a medical Junior House Officer in the late 1990s in southern Scotland I owned a copy of the *Oxford Handbook of Clinical Medicine*. This now infamous text never left my side. This book follows in its illustrious footsteps.

Professionalism is introduced as a new chapter which explores professional standards, audit, the organizational structure and funding of the NHS, and judgement and decision-making to name but a few topics. These non-clinical disciplines are fundamentally important to the conscience of the modern doctor as is clearly reflected in the new curriculum.

This book is written for trainees. It is concise, logical, beautifully illustrated, and referenced where appropriate. It starts with basic science and first principles and works through to complex surgical techniques and sophisticated decision-making. Surely it deserves a place in the briefcase of every ophthalmologist. After all, we may be promoted but we never really stop being trainees.

Jonathan Ross  
Chairman, Royal College of Ophthalmologists' Ophthalmic Trainees' Group  
May 2008

*This page intentionally left blank*

# Preface

Ophthalmology training has recently been radically changed with the introduction of Modernising Medical Careers (MMC), the Postgraduate Medical Education and Training Board (PMETB), and the new Ophthalmic Specialist Training (OST) curriculum from the Royal College of Ophthalmologists.

Trainees are now expected to clearly demonstrate evidence of having acquired the expected knowledge and clinical, technical and surgical skills at each stage of their training in order to progress.

With the relative lack of ophthalmology teaching at medical school and often inconsistent formal teaching of fundamental examination and clinical techniques during initial posts, ophthalmology trainees often feel they are being thrown in at the deep end.

This book aims to help address these issues by mapping the initial stages (ST1–3) of the new OST curriculum, and providing trainees with the core knowledge and clinical skills they will require to successfully progress.

The book predominantly follows a double-page format for each topic, with the chapters divided into subspecialties. Basic sciences are covered initially, followed by history and examination techniques, and then clinical conditions pertinent to each subspecialty. Case-based discussions complete Chapters 1–10 to test knowledge and help develop management and clinical decision-making processes. Core examination, practical, and technical skills have been highlighted and these are clearly listed at the start of each chapter.

Although this book is aimed primarily at trainees in the early years of OST, we feel that it would also be appealing for medical students to more senior ophthalmologists and other healthcare professionals with an interest in ophthalmology.

We hope that you enjoy and benefit from reading this book, and we welcome any feedback on how it may be improved for the future. If you have any comments or suggestions, please email us at [ost@oup.com](mailto:ost@oup.com).

Venki Sundaram  
Allon Barsam  
Amar Alwitary  
Peng T. Khaw  
April 2008



*This page intentionally left blank*

# Acknowledgements

We would like to thank Chris Reid at Oxford University Press for his considerable support and guidance throughout producing this book. We are grateful to Matthew Gardiner for helping to conceive this book and his advice since then. Thank you to Fiona Goodgame at Oxford University Press for her backing of this book.

Thank you to all the chapter authors for their hard work and cooperation.

We would also like to acknowledge Jonathan Ross for his reviews of all chapters and John Hungerford for his review of anterior segment tumours and Mandeep Sagoo for his review of the medical retina chapter.

*This page intentionally left blank*

# Contents

Detailed contents [xvii](#)

Contributors [xxiii](#)

Abbreviations [xxv](#)

## **1 External eye disease 1**

*Saurabh Goyal, Allon Barsam, and Stephen Tuft*

## **2 Oculoplastics 71**

*Allon Barsam and Jimmy Uddin*

## **3 Vitreoretinal surgery 103**

*Fred K. Chen and Simon D.M. Chen*

## **4 Medical retina 145**

*Bheema Patil and Pankaj Puri*

## **5 Medical ophthalmology 193**

*Edward Hughes and Miles Stanford*

## **6 Cataract 237**

*Georgia Cleary and David Spalton*

## **7 Glaucoma 275**

*Julie Huntbach and Amar Alwitry*

## **8 Strabismus and oculomotility 321**

*Rebecca Ford and Moneesh Patel*

## **9 Neuro-ophthalmology 355**

*Venki Sundaram and John Elston*

## **10 Orbit 399**

*Claire Daniel, Venki Sundaram, and Jimmy Uddin*

## **11 Professional skills and behaviour 423**

*Matthew Gardiner and Venki Sundaram*

Index [435](#)

*This page intentionally left blank*

# Detailed contents

Contributors *xxiii*

Abbreviations *xxv*

## 1 External eye disease 1

### Basic sciences

- 1.1 Corneal and conjunctival basic science 2

### Clinical skills

- 1.2 History taking for anterior segment disease 4
- 1.3 Examination of the anterior segment 6

### Clinical knowledge

- 1.4 Blepharitis 8
- 1.5 Staphylococcal hypersensitivity disorders 10
- 1.6 Dry eye disease 12
- 1.7 Conjunctivitis I: classification and adenovirus 14
- 1.8 Conjunctivitis II: other infectious causes 16
- 1.9 Conjunctivitis III: allergic 18
- 1.10 Conjunctivitis IV: miscellaneous 20
- 1.11 Cicatrizing conjunctival disease 22
- 1.12 Conjunctival degeneration 24
- 1.13 Conjunctival neoplasia I 26
- 1.14 Conjunctival neoplasia II 28
- 1.15 Corneal degeneration 30
- 1.16 Infectious keratitis I: bacterial 32
- 1.17 Infectious keratitis II: protozoal/fungal 34
- 1.18 Infectious keratitis III: viral; herpes simplex 36
- 1.19 Infectious keratitis IV: viral; herpes zoster 38
- 1.20 Interstitial keratitis 39
- 1.21 Peripheral ulcerative keratitis 40
- 1.22 Metabolic and drug-induced keratopathies 42
- 1.23 Miscellaneous keratopathies 44
- 1.24 Corneal dystrophies I 46
- 1.25 Corneal dystrophies II 48

- 1.26 Contact lenses 50

- 1.27 Corneal ectasia 52

- 1.28 Keratoplasty 54

- 1.29 Complications of keratoplasty and graft rejection 56

- 1.30 Anterior uveal tumours 58

- 1.31 Anterior segment trauma 60

- 1.32 Chemical injury 64

- 1.33 Refractive surgery 66

### Practical skills

Corneal glue 33

Removal of corneal sutures 55

Removal of corneal foreign bodies 61

Corneal topography 67

Corneal pachymetry 67

### Case-based discussions

- 1.34 Case 1 Chemical injury 69

Case 2 Herpes zoster keratitis 69

Case 3 Bacterial keratitis 69

## 2 Oculoplastics 71

### Basic sciences

- 2.1 Eyelid and nasolacrimal system anatomy 72

### Clinical knowledge

- 2.2 Lash abnormality 74

- 2.3 Entropion 76

- 2.4 Ectropion 78

- 2.5 Ptosis I 80

- 2.6 Ptosis II 82

- 2.7 Benign lid lesions 84

- 2.8 Premalignant and malignant lid lesions I 88

- 2.9 Malignant lid lesions II 90

- 2.10 Epiphora 92

- 2.11 Acquired nasolacrimal system abnormalities 94

- 2.12 Congenital abnormalities 96

- 2.13 Miscellaneous 98

### **Clinical skills**

- Ptosis examination 82
- Evaluation of the patient with acquired epiphora 92

### **Practical skills**

- Incision and curettage of chalazion 84
- Syringing and probing 92
- Botulinum-toxin injections 98

### **Case-based discussions**

- 2.14 Case 1 Epiphora 102
- Case 2 Ptosis 102
- Case 3 Lid lump 102

## **3 Vitreoretinal surgery 103**

### **Basic sciences**

- 3.1 Retinal anatomy and physiology 104

### **Clinical skills**

- 3.2 Posterior segment history taking and examination 106
- 3.3 Diagnostic lenses 108

### **Practical skills**

- 3.4 Optical coherence tomography 110
- 3.5 Ultrasonography 112
- 3.6 Retinal photocoagulation 114

### **Clinical knowledge**

- 3.7 Vitreous disorders 116
- 3.8 Retinal detachment I 118
- 3.9 Retinal detachment II 120
- 3.10 Peripheral retinal abnormalities 122
- 3.11 Macular surgery 124
- 3.12 Submacular surgery 126
- 3.13 Retinal tumours I 128
- 3.14 Retinal tumours II 130
- 3.15 Choroidal tumours I 132
- 3.16 Choroidal tumours II 134
- 3.17 Vitreoretinopathies 136
- 3.18 Retinopathy of prematurity 138
- 3.19 Posterior segment trauma 140

### **Case-based discussions**

- 3.20 Case 1 Retinal detachment 142
- Case 2 Elevated fundal mass 142

## **4 Medical retina 145**

### **Clinical skills**

- 4.1 Fundus fluorescein angiography 146

- 4.2 Abnormal fluorescein angiography 148
- 4.3 Indocyanine green angiography 150
- 4.4 Electrophysiology 152

### **Clinical knowledge**

- 4.5 Diabetic retinopathy I 156
- 4.6 Diabetic retinopathy II 160
- 4.7 Hypertensive retinopathy 162
- 4.8 Retinal vein occlusion I 164
- 4.9 Retinal vein occlusion II 166
- 4.10 Retinal artery occlusions 168
- 4.11 Age-related macular degeneration I 170
- 4.12 Age-related macular degeneration II 172
- 4.13 Intravitreal anti-VEGF injections 176
- 4.14 Central serous chorioretinopathy 178
- 4.15 Retinal vascular anomalies 180
- 4.16 Retinal dystrophies I 182
- 4.17 Retinal dystrophies II 184
- 4.18 Choroidal dystrophies 188

### **Case based discussions**

- 4.19 Case 1 Gradual visual loss 190
- Case 2 Central visual loss 190
- Case 3 Visual loss in a hypertensive patient 190
- Case 4 Sudden, painless visual loss 190
- Case 5 Diabetic retinopathy 191
- Case 6 Difficult night vision 191
- Case 7 Visual loss in child 191
- Case 8 Macular lesion 191

## **5 Medical ophthalmology 193**

### **Basic sciences**

- 5.1 Uveal anatomy 194

### **Clinical knowledge**

- 5.2 Anterior uveitis 196
- 5.3 Intermediate uveitis 198
- 5.4 Posterior uveitis 200
- 5.5 Specific non-infectious posterior uveitides I 202
- 5.6 Specific non-infectious posterior uveitides II 204
- 5.7 Viral infectious uveitis 206
- 5.8 Parasitic infectious uveitis 208
- 5.9 Fungal infectious uveitis 210

- 5.10 Bacterial infectious uveitis 212
- 5.11 HIV-related disease 214
- 5.12 Uveitis: systemic associations I 216
- 5.13 Uveitis: systemic associations II 220
- 5.14 Scleritis and episcleritis 222
- 5.15 Systemic treatment of ocular inflammatory disorders 224
- 5.16 Biological agents and periocular treatments of ocular inflammatory disorders 226
- 5.17 Intraocular treatments of ocular inflammatory disorders 227
- 5.18 Rheumatological disease 228
- 5.19 Vasculitis 230
- 5.20 Cardiovascular disease and the eye 232
- 5.21 Endocrine diseases in ophthalmology 234
- 5.22 Respiratory and skin diseases in ophthalmology 235

#### **Practical skills**

- Orbital-floor injection 226
- Posterior sub-Tenon injection 226
- Intravitreal injection 227

#### **Case-based discussion**

- 5.23 Case 1 Scleritis 236

## **6 Cataract 237**

#### **Basic sciences**

- 6.1 Lens anatomy and embryology 238

#### **Clinical knowledge**

- 6.2 Acquired cataract 240
- 6.3 Clinical evaluation of acquired cataract 244
- 6.4 Treatment for acquired cataract 246
- 6.5 Intraoperative complications of cataract surgery 250
- 6.6 Infectious postoperative complications of cataract surgery 252
- 6.7 Non-infectious postoperative complications of cataract surgery 254
- 6.8 Congenital cataract 256
- 6.9 Management of congenital cataract 258
- 6.10 Lens dislocation 260

#### **Practical skills**

- 6.11 Biometry 262
- 6.12 Local anaesthesia 266
- 6.13 Operating microscope and phacodynamics 268
- 6.14 Intraocular lenses 270
- 6.15 Nd:YAG laser capsulotomy 272

#### **Case-based discussions**

- 6.16 Case 1 Age-related cataract 274
- Case 2 Postoperative endophthalmitis 274
- Case 3 Posterior capsular opacification 274

## **7 Glaucoma 275**

#### **Basic sciences**

- 7.1 Optic nerve head anatomy 276
- 7.2 Aqueous fluid dynamics 277

#### **Clinical skills**

- 7.3 Optic nerve head assessment in glaucoma 278
- 7.4 Tonometry and pachymetry 282
- 7.5 Gonioscopy 284
- 7.6 Perimetry I 286
- 7.7 Perimetry II 288

#### **Clinical knowledge**

- 7.8 Ocular hypertension 290
- 7.9 Primary open-angle glaucoma 291
- 7.10 Acute angle closure 292
- 7.11 Normal-tension glaucoma 294
- 7.12 Steroid-induced glaucoma 295
- 7.13 Traumatic glaucoma 296
- 7.14 Inflammatory glaucomas 298
- 7.15 Pseudoexfoliative and pigmentary glaucoma 300
- 7.16 Neovascular glaucoma 302
- 7.17 Malignant glaucoma 304
- 7.18 Iridocorneal endothelial syndrome and iridocorneal dysgenesis 306
- 7.19 Ocular hypotensive agents I 308
- 7.20 Ocular hypotensive agents II 310
- 7.21 Laser therapy for glaucoma 312
- 7.22 Glaucoma surgery 316

#### **Case-based discussions**

- 7.23 Case 1 Open-angle glaucoma 318
- Case 2 Angle closure glaucoma 318
- Case 3 Steroid glaucoma 318



## 8 Strabismus and oculomotility 321

### *Basic sciences*

- 8.1 Anatomy and actions of the extraocular muscles 322
- 8.2 Central control of ocular motility 324
- 8.3 Patient assessment I: history, general examination, and cover testing 325
- 8.4 Patient assessment II: other methods of measuring ocular deviation 326
- 8.5 Assessment of ocular movements 327
- 8.6 Visual acuity testing 328
- 8.7 Tests of stereopsis and binocular single vision 330
- 8.8 Tests of retinal correspondence and suppression 331
- 8.9 Hess charts 332

### *Clinical knowledge*

- 8.10 Amblyopia 334
- 8.11 Binocular vision and stereopsis 335
- 8.12 Concomitant strabismus I: heterophorias 336
- 8.13 Concomitant strabismus II: esotropia 338
- 8.14 Concomitant strabismus III: exotropia 340
- 8.15 Incomitant strabismus 341
- 8.16 Restrictive ocular motility disorders 342
- 8.17 Complex ocular motility syndromes 343
- 8.18 Vertical deviations 344
- 8.19 Alphabet patterns 346

### *Practical skills*

- 8.20 Principles of strabismus surgery I: indications and types 348
- 8.21 Principles of strabismus surgery II: complications 350
- 8.22 Other procedures in strabismus 351

### *Case-based discussions*

- 8.23 Case 1 Myopic anisometropia 352
- Case 2 Esotropia 352
- Case 3 Infantile esotropia 352

- Case 4 Orbital floor fracture 353
- Case 5 Consecutive exotropia 353

## 9 Neuro-ophthalmology 355

### *Basic sciences*

- 9.1 Visual pathway and pupil reflex anatomy 356
- 9.2 Cranial nerve anatomy 358
- 9.3 Neuro-ophthalmology history taking 360
- 9.4 Neuro-ophthalmology examination I 362
- 9.5 Neuro-ophthalmology examination II 364
- 9.6 Neuroimaging 366

### *Clinical knowledge*

- 9.7 Chiasmal visual pathway disorders 368
- 9.8 Retrochiasmal visual pathway disorders 370
- 9.9 Optic nerve disorders I 372
- 9.10 Optic nerve disorders II 374
- 9.11 Papilloedema and idiopathic intracranial hypertension 376
- 9.12 Congenital optic nerve disorders 378
- 9.13 Cranial nerve palsies I 380
- 9.14 Cranial nerve palsies II 382
- 9.15 Nystagmus 386
- 9.16 Supranuclear eye movement disorders 388
- 9.17 Pupil abnormalities 390
- 9.18 Headache 392
- 9.19 Non-organic visual loss 393
- 9.20 Neuromuscular junction disorders 394
- 9.21 Ocular myopathies 395

### *Case-based discussions*

- 9.22 Case 1 Acute visual loss 396
- Case 2 Sudden-onset diplopia 396
- Case 3 Headache 396
- Case 4 Anisocoria 397
- Case 5 Nystagmus 397

## 10 Orbit 399

### *Basic sciences*

- 10.1 Orbital anatomy 400

**Clinical skills**

- 10.2 Orbital history and examination 402

**Clinical knowledge**

- 10.3 Orbital infections 404  
 10.4 Orbital inflammatory disease 406  
 10.5 Orbital vascular malformations 408  
 10.6 Orbital tumours I 410  
 10.7 Orbital tumours II 412  
 10.8 Thyroid eye disease 414  
 10.9 Orbital fractures and trauma 416  
 10.10 Orbital surgery 418

**Case-based discussions**

- 10.11 Case 1 Childhood proptosis 420  
 Case 2 Non-axial proptosis 420  
 Case 3 Traumatic proptosis 420  
 Case 4 Orbital pain 420  
 Case 5 Diplopia following trauma 420

## 11 Professional skills and behaviour 423

**Professional skills**

- 11.1 Good medical practice 424  
 11.2 Communication 425  
 11.3 Judgement and decision-making 426  
 11.4 Clinical governance and patient safety 427  
 11.5 Audit, appraisal, and revalidation 428  
 11.6 Consent and confidentiality in the UK 429  
 11.7 Education, training, and research 430  
 11.8 Child protection in the UK 431  
 11.9 NHS structure and economics 432  
 11.10 The Ophthalmic Trainees' Group (by Jonathan Ross) 433

**Clinical skills**

- Breaking bad news 425  
 Dealing with complaints 425

Index 435

*This page intentionally left blank*

# Contributors

**Amar Alwitary**, Consultant Ophthalmologist, Derby Hospitals NHS Foundation Trust, Derby

**Allon Barsam**, Specialist Registrar, Ophthalmology, Moorfields Eye Hospital, London

**Fred K. Chen**, Vitreoretinal Surgery Research Fellow, Moorfields Eye Hospital, London

**Simon D.M. Chen**, Retina Specialist, Vision Eye Institute, Sydney, New South Wales, Australia

**Georgia Cleary**, Clinical Research Fellow, St. Thomas' Hospital, London

**Claire Daniel**, Adnexal Fellow, Moorfields Eye Hospital, London

**John Elston**, Consultant Ophthalmologist (paediatrics and neuro-ophthalmology), Oxford Eye Hospital, John Radcliffe Hospital, Oxford

**Rebecca Ford**, Specialist Registrar in Ophthalmology, Moorfields Eye Hospital, London

**Matthew Gardiner**, Clinical Research Fellow in Plastic and Reconstructive Surgery, Kennedy Institute of Rheumatology, Imperial College London, London

**Saurabh Goyal**, Glaucoma Clinical Fellow, Moorfields Eye Hospital, London

**Edward Hughes**, Retinal Fellow, Moorfields Eye Hospital, London

**Julie Huntbach**, Specialist Registrar in Ophthalmology, Queens Medical Centre, Nottingham

**Moneesh Patel**, Specialist Registrar in Ophthalmology, Derby Hospitals NHS Trust, Derby

**Bheema Patil**, Advanced Specialist Trainee in Ophthalmology, Nottingham University Hospital, Nottingham

**Pankaj Puri**, Consultant Ophthalmologist, Derbyshire Royal Infirmary, Derby

**David Spalton**, Consultant Ophthalmic Surgeon, St Thomas' Hospital, London

**Miles Stanford**, Professor of Clinical Ophthalmology, King's College London, St Thomas' Hospital, London

**Venki Sundaram**, Specialty Registrar in Ophthalmology, London Deanery, London

**Stephen Tuft**, Consultant Ophthalmologist, Moorfields Eye Hospital, London

**Jimmy Uddin**, Consultant Ophthalmologist, Moorfields Eye Hospital, London

*This page intentionally left blank*

# Abbreviations

AC/A ratio	accommodative convergence/accommodation ratio
ACE	angiotensin-converting enzyme
AIDS	acquired immunodeficiency syndrome
AION	anterior ischaemic optic neuropathy
AKC	atopic keratoconjunctivitis
AMD	age-related macular degeneration
ANA	antinuclear antibody
ANCA	anti-neutrophil cytoplasmic antibody
BCC	basal cell carcinoma
BD	twice daily
BIO	binocular indirect ophthalmoscopy
BRAO	branch retinal artery occlusion
BRVO	branch retinal vein occlusion
BSV	binocular single vision
CCC	continuous curvilinear capsulorhexis
CCT	central corneal thickness
CDB	corneal dystrophy of Bowman's layer
CDR	cup/disc ratio
CHED	congenital hereditary endothelial dystrophy
CHRPE	congenital hypertrophy of retinal pigment epithelium
CMV	cytomegalovirus
CNS	central nervous system
CNV	choroidal neovascularization
CRAO	central retinal artery occlusion
CRP	C-reactive protein
CRVO	central retinal vein occlusion
CSCR	central serous chorioretinopathy
CT	computed tomography
CXR	chest X-ray
DCR	dacryocystorhinostomy
DEXA	dual-energy X-ray absorptiometry
DVD	dissociated vertical deviation
EBV	Epstein-Barr virus
ELISA	enzyme-linked immunosorbent assay
EOG	electrooculogram
Epi-LASIK	epithelial laser-assisted <i>in-situ</i> keratomileusis
ERG	electroretinogram
ESR	erythrocyte sedimentation rate
ETDRS	Early Treatment Diabetic Retinopathy Study
FBC	full blood count
FFA	fundus fluorescein angiography
FTA-ABS	<i>Treponema</i> -specific antibody test
G	gauge
G6PD	glucose-6-phosphate dehydrogenase
GAT	Goldmann applanation tonometry

GCA	giant cell arteritis
GMC	General Medical Council
GVHD	graft-versus-host disease
HAART	highly active antiretroviral therapy
HIV	human immunodeficiency virus
HLA	human leucocyte antigen
HSK	herpes simplex keratitis
HSV	herpes simplex virus
HZO	herpes zoster ophthalmicus
HZV	herpes zoster virus
ICE	iridocorneal endothelial
ICG	indocyanine green
IL	interleukin
IOL	intraocular lens
IOP	intraocular pressure
LASEK	laser-assisted subepithelial keratomileusis
LASIK	laser-assisted stromal <i>in-situ</i> keratomileusis
MRA	magnetic resonance angiography
MRI	magnetic resonance imaging
NHS	National Health Service
NPDR	non-proliferative diabetic retinopathy
NSAID	non-steroidal anti-inflammatory drug
NSR	neurosensory retina
NVD	new vessels of the optic disc
NVE	new vessels elsewhere
OCT	optical coherence tomography
OD	once daily
ONH	optic nerve head
OTG	Ophthalmic Trainees' Group
PAC	perennial allergic conjunctivitis
PAS	peripheral anterior synechiae
PCO	posterior capsule opacification
PCR	polymerase chain reaction
PDR	proliferative diabetic retinopathy
PDT	photodynamic therapy
PHPV	persistent hyperplastic primary vitreous
POAG	primary open-angle glaucoma
PORN	progressive outer retinal necrosis
PRK	photorefractive keratectomy
PRP	pan-retinal photocoagulation
PUK	peripheral ulcerative keratitis
PVD	posterior vitreous detachment
QDS	four times daily
SAC	seasonal allergic conjunctivitis
RAPD	relative afferent pupillary defect
RNFL	retinal nerve fibre layer
ROP	retinopathy of prematurity

RPE	retinal pigment epithelium
RRD	rhegmatogenous retinal detachment
TDS	three times daily
TNF $\alpha$	tumour necrosis factor $\alpha$
tPA	tissue plasminogen activator

VDRL	Venereal Disease Research Laboratory
VEGF	vascular endothelial growth factor
VKC	vernal keratoconjunctivitis
VZV	varicella zoster virus

## Chapter 1

# External eye disease

Saurabh Goyal, Allon Barsam, and Stephen Tuft

---

### Basic sciences

- 1.1 Corneal and conjunctival basic science 2

---

### Clinical skills

- 1.2 History taking for anterior segment disease 4  
1.3 Examination of the anterior segment 6

---

### Clinical knowledge

- 1.4 Blepharitis 8  
1.5 Staphylococcal hypersensitivity disorders 10  
1.6 Dry eye disease 12  
1.7 Conjunctivitis I: classification and adenovirus 14  
1.8 Conjunctivitis II: other infectious causes 16  
1.9 Conjunctivitis III: allergic 18  
1.10 Conjunctivitis IV: miscellaneous 20  
1.11 Cicatrizing conjunctival disease 22  
1.12 Conjunctival degeneration 24  
1.13 Conjunctival neoplasia I 26  
1.14 Conjunctival neoplasia II 28  
1.15 Corneal degeneration 30  
1.16 Infectious keratitis I: bacterial 32  
1.17 Infectious keratitis II: protozoal/fungal 34  
1.18 Infectious keratitis III: viral; herpes simplex 36  
1.19 Infectious keratitis IV: viral; herpes zoster 38  
1.20 Interstitial keratitis 39  
1.21 Peripheral ulcerative keratitis 40  
1.22 Metabolic and drug-induced keratopathies 42  
1.23 Miscellaneous keratopathies 44  
1.24 Corneal dystrophies I 46  
1.25 Corneal dystrophies II 48  
1.26 Contact lenses 50  
1.27 Corneal ectasia 52  
1.28 Keratoplasty 54

- 1.29 Complications of keratoplasty and graft rejection 56  
1.30 Anterior uveal tumours 58  
1.31 Anterior segment trauma 60  
1.32 Chemical injury 64  
1.33 Refractive surgery 66

---

### Practical skills

Corneal glue 33  
Removal of corneal sutures 55  
Removal of corneal foreign bodies 61  
Corneal topography 67  
Corneal pachymetry 67

---

### Case-based discussions

- 1.34 Case 1 Chemical injury 69  
Case 2 Herpes zoster keratitis 69  
Case 3 Bacterial keratitis 69



# 1.1 Corneal and conjunctival basic science

## Corneal anatomy and physiology

### Gross anatomy

The cornea is the transparent anterior portion of the eyeball. It has two main functions:

1. to protect the intraocular contents by providing a mechanical and chemical barrier
  2. to provide three-quarters of the overall refractive power of the eye.
- To fulfil these functions the cornea must maintain its shape, its strength, and its optical transparency. The cornea makes up approximately one-sixth of the area of the outer covering of the eye with the sclera making up the other five-sixths. The junction of the cornea and sclera is known as the limbus. The anatomical limbus lies slightly posterior to the surgical limbus.

The cornea is transversely oval with an average horizontal diameter of 12.6 mm and average vertical diameter of 11.7 mm in an adult. It is aspherical with greatest convex curvature in the central 3.0 mm zone. The cornea is thinnest in the centre (about 540  $\mu\text{m}$ ) and progressively thicker at the periphery (about 700  $\mu\text{m}$ ). The cornea provides 40–44 Dioptres (D) of the refractive power of the eye (anterior surface about +49D and posterior surface –6D).

### Corneal nutrition

The cornea is avascular. To maintain transparency it derives its nutrition mainly from the tear film and aqueous humour. The limbus is supplied by both internal (anterior ciliary branch of ophthalmic artery) and external (facial branch) carotid arteries.

### Corneal innervation

The cornea has a rich sensory innervation (300–400 times that of skin). Sensory innervation is derived from the long ciliary nerves, a branch of the ophthalmic division of the trigeminal (fifth cranial nerve). These nerves reach the cornea via the limbus. They pass radially forwards within the stroma before branching anteriorly to finish as free nerve endings within the corneal epithelium. Loss of corneal innervation reduces the stimulus for blinking, tear production, and epithelial proliferation.

### Precorneal tear film

The surface of the corneal epithelium is irregular with multiple finger-like projections (microvilli). To function as an optical surface the covering precorneal tear film is required. The air–tear interface is the major refractive interface of the eye. The tear film is 7  $\mu\text{m}$  thick. Tear film has three layers: (1) the outermost lipid layer (secreted by the meibomian glands) functions to reduce evaporation of the aqueous layer and act as a surfactant for tear spreading, (2) the middle aqueous layer (secreted by the main and accessory lacrimal glands) functions to supply oxygen and metabolites to the avascular corneal epithelium, carry antibacterial tear proteins (lactoferrin), and to wash away debris and bacteria, and (3) the innermost mucin layer (secreted by the conjunctival goblet cells and lacrimal gland) functions to bind aqueous layer to the normally hydrophobic epithelial cell surface and add viscosity to the aqueous layer.

### Corneal histology

The cornea is a multi-layer structure consisting, from anterior to posterior, of:

1. epithelium,
2. Bowman's layer,
3. stroma,
4. Descemet's membrane,
5. endothelium.

**Epithelium** (50  $\mu\text{m}$  thick) is five to six cell layers of non-keratinized stratified squamous epithelium, which can be further subdivided into:

1. two or three layers of superficial cells; tight junctions between these cells prevent the flow of water into the stroma and consequent stromal oedema;

2. two or three layers of wing cells; and

3. a monolayer of columnar basal cells which are capable of division to replace continuous desquamation from the surface. Basal cells adhere to the underlying basement membrane, which they also secrete. Replication and central migration of basal cells acts to repair epithelial defects. Limbal stem cells (see below) also have a function in epithelial wound healing.

**Bowman's layer** (10  $\mu\text{m}$  thick) is an acellular layer of collagen fibres lying between the epithelial basement membrane and the stroma. Bowman's layer does not regenerate after injury and breaks that occur in it heal with cellular scar tissue.

**Stroma** (450  $\mu\text{m}$  thick) consists of extracellular matrix (mainly Type I collagen and proteoglycans: 65% keratin sulphate and 30% chondroitin/dermatin sulphate), keratocytes (modified fibroblasts), and nerve fibres. Corneal transparency is maintained due to the size of and distance between (both less than half the wavelength of visible light) the stromal collagen fibres. If the stroma becomes over-hydrated, or after injury/scarring, this architecture and transparency is lost and the stroma becomes opaque.

Stromal wound healing involves the laying down of Type III collagen by the keratocytes. Collagen remodelling occurs and the tensile strength of the corneal stroma increases after injury for up to 6 months. In response to injury/inflammation/infection activated keratocytes and other inflammatory cells (from the limbal vessels and tear film) can cause collagenolysis and stromal melting.

**Descemet's membrane** is the basement membrane secreted by the endothelium. It consists of an anterior banded zone secreted in foetal life (2–4  $\mu\text{m}$ ) and a posterior non-banded zone that increases in thickness throughout life (12  $\mu\text{m}$  in the elderly). Composed of mainly Type IV collagen and laminin it is a barrier to the penetration of cells, but not water and small molecules, from the aqueous to the stroma.

**Endothelium** is a single layer of polygonal (mainly hexagonal) cells arranged in a mosaic. Cell density decreases with age (around 6000 cells/mm<sup>2</sup> at birth and 2600 cells/mm<sup>2</sup> in adults). Endothelial cells do not proliferate but cell loss is compensated for by an increase in size when the cells become more irregular in shape (polymegethism). A minimum density of about 600 cells/mm<sup>2</sup> is required to maintain hydration. Endothelial cells have sodium/potassium and bicarbonate pumps that cause water to be pumped out of the stroma and maintain the optimum level of stromal hydration (78% water) for transparency. Persistently high intraocular pressure (IOP) damages the endothelium and water will then enter the stroma and the cornea will swell and become hazy.

### Limbal stem cells

At the limbus, epithelial cells are thrown into folds by stromal ridges known as the palisades of Vogt. The corneal epithelial stem cells are thought to lie between these ridges. The function of the limbal stem cells is to provide a source of cells for epithelial regeneration. They also function as a junctional barrier that prevents the conjunctiva growing on to the cornea (conjunctivalization).

## Conjunctival anatomy and physiology

### Gross anatomy

The conjunctiva is a thin mucus membrane that lines the eyelids (see section 2.1) and is reflected at superior and inferior fornices on to the surface of the globe. Medially the conjunctiva is folded to form the plica semilunaris. Medial to the plica semilunaris lies the caruncle, a fleshy tissue mass containing fine hairs and sebaceous glands. The conjunctiva can be further subdivided as follows

### Palpebral conjunctiva

This starts at the lid margin and is firmly attached to the tarsal plate.

**Forniceal conjunctiva**

This is loosely attached to the underlying fascial expansions of the levator and rectus muscle sheaths.

**Bulbar conjunctiva**

This translucent layer lies over the anterior globe. It is loosely attached to Tenon's capsule below, except at the limbus where the Tenon's and conjunctiva fuse and are firmly attached to the sclera and cornea.

**Conjunctival histology**

The conjunctiva has an epithelial surface of non-keratinizing stratified columnar cells (bulbar conjunctiva) or stratified squamous cells (palpebral and limbal conjunctiva) that rest on a lamina propria of loose connective tissue. The conjunctiva contains goblet cells that contribute to the mucin layer of the tear film. The accessory lacrimal glands of Krause and Wolfring are located within the substantia propria.

**Follicles**

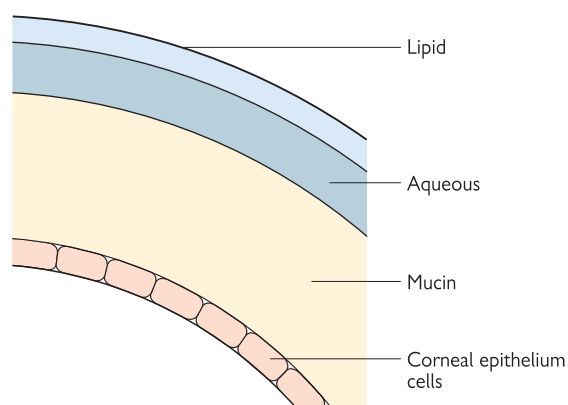
These are subepithelial aggregations of hyperplastic conjunctival-associated lymphoid tissue. They are encircled by blood vessels and are most clearly seen in the superior and infero-temporal fornix.

**Papillae**

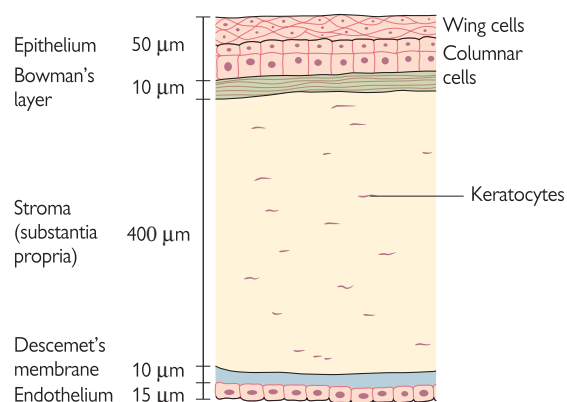
These result from epithelial hyperplasia and oedema and contain a vascular core.

**Blood supply and lymphatic drainage**

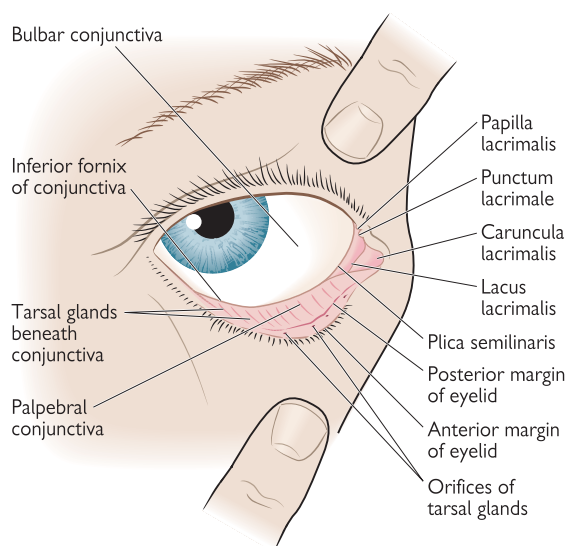
This is as for the eyelids (see section 2.1)



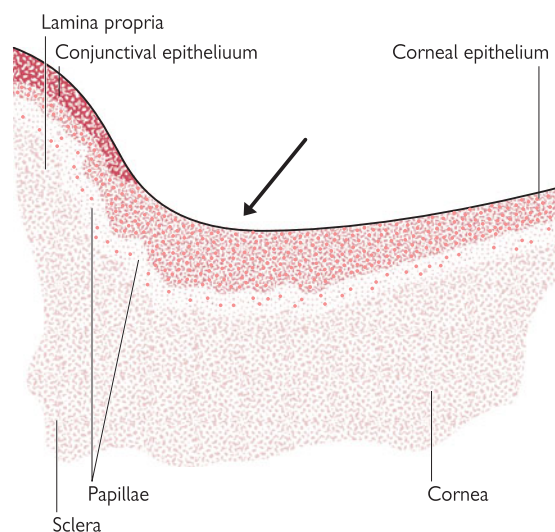
**Fig. 1.1** The three layers of the precorneal tear film.



**Fig. 1.2** Corneal histology.



**Fig. 1.3** Conjunctival anatomy. Right eye with lids everted to show the conjunctival sac, lacus lacrimalis, and caruncula lacrimalis. Note the position of the tarsal glands beneath the conjunctiva and the puncta lacrimalia.



**Fig. 1.4** Conjunctiva at the limbus (arrow): note the presence of papillae in the lamina propria. Note also the continuation of the conjunctival epithelium with the corneal epithelium (H&E;  $\times 200$ ).

## 1.2 History taking for anterior segment disease

Anterior segment disease history taking aims to identify risk factors for disease and severity and aetiology of the disease to facilitate making a correct diagnosis and initiating appropriate management.

When constructing a differential diagnosis it is important to bear in mind the following 'surgical sieve' of causes: infectious, iatrogenic (drugs/surgery), autoimmune, traumatic, vascular, metabolic, neoplastic, and congenital.

### Presenting complaint

#### Red eye

**Infectious disease:** bacterial or viral conjunctivitis, microbial keratitis especially from contact lens wear; secondary to lid/orbital infections (blepharoconjunctivitis, canaliculitis, preseptal/orbital cellulitis), blebitis, and endophthalmitis.

**Iatrogenic:** drop allergy, drop/preservative toxicity, following any form of eye surgery.

**Autoimmune/hypersensitivity:** allergic conjunctivitis, staphylococcal hypersensitivity (marginal keratitis, rosacea keratitis), episcleritis, scleritis, anterior uveitis, ocular cicatricial pemphigoid (OCP), Stevens–Johnson syndrome.

**Traumatic:** conjunctival/corneal abrasion, corneal/subtarsal foreign body, contact lens-associated giant papillary conjunctivitis, corneal laceration, chemical injury, phototoxic keratopathy.

**Vascular:** subconjunctival haemorrhage, carotid-cavernous fistula, cluster headache.

**Other:** dry eye, hypoxic contact lens keratopathy, eyelash ocular surface contact (trichiasis, entropion), inflamed pterygium/pingueculum, acute glaucoma, epithelial defect from corneal decompensation.

#### Burning/sore eye

Blepharitis, conjunctivitis, drop allergy, dry eye, non-infective contact lens-related keratopathy, marginal keratitis, episcleritis, inflamed pterygium/pingueculum.

#### Foreign body sensation

As for burning/sore eye. Any disturbance of the corneal or conjunctival epithelial integrity will give a foreign body sensation.

#### Itchy eyes

Allergic conjunctivitis, blepharitis, eyelid dermatitis, contact lens-associated giant papillary conjunctivitis.

#### Ocular pain/photophobia

Any corneal epithelial defect can give these symptoms. Causes include microbial keratitis, keratoconjunctivitis, corneal abrasion, corneal foreign body. Other causes are anterior uveitis, scleritis, endophthalmitis, and acute glaucoma.

#### Blurred vision

A tear-film abnormality can cause this clinical feature which normally improves or resolves after blinking. Corneal pathology affecting the central part of the cornea will also produce blurred vision. Other causes include uncorrected refractive error, cataract, posterior capsular opacification after cataract surgery, severe iritis, acute glaucoma, posterior segment/neurological disorders.

#### Watery eyes

See sections 2.10–2.12 for nasolacrimal outflow obstruction. Other causes include blepharitis, conjunctivitis, corneal abrasion, chemical injury, corneal/subtarsal foreign body, ectropion, acute glaucoma.

#### Discharge

Blepharitis, conjunctivitis, blepharoconjunctivitis, nasolacrimal outflow obstruction.

### History of presenting complaint

#### Onset/duration

Sudden (subconjunctival haemorrhage), acute (trauma, infection, angle closure glaucoma), subacute (allergic conjunctivitis), chronic (cataract), acute on chronic (rosacea keratitis), recurrent (epithelial erosion, anterior uveitis).

#### Associated features

Severity, precipitating/relieving factors, response to previous treatment if recurrent, mechanism of injury for trauma.

### Past ocular history

#### Refraction

Glasses; history of contact lens wear (type, overnight wear, cleaning regime, use of tap water/swimming with lenses).

#### Trauma

Physical (recurrent corneal erosion syndrome), chemical (limbal stem cell failure, corneal scarring), radiation (ocular surface disease, neoplasms).

#### Surgery

Intraocular surgery (endothelial dysfunction), refractive surgery (post-laser-assisted stromal *in-situ* keratomileusis (LASIK) dry eye/flap dehiscence).

#### Infection

Previous herpes simplex keratitis (HSK), herpes zoster ophthalmicus (HZO) (interstitial keratitis).

### Past medical history

General medical conditions that are associated with anterior segment pathology are discussed in more detail in sections 5.18, 5.19, and 5.22. Other diseases to enquire about primarily include the following:

- atopy: asthma/eczema/hay fever associated with allergic conjunctivitis;
- rheumatological diseases: dry eye, corneal melt, scleritis;
- neurological disease: facial nerve palsy and exposure keratopathy;
- sexually transmitted disease: chlamydial conjunctivitis;
- skin disease: acne vulgaris or rosacea;
- metabolic disease: hypercalcaemia and band keratopathy.

## Drug history

### Topical medications

- Topical steroid use causing cataract and glaucoma. Topical steroids can cause herpetic geographic ulcer.
- Toxicity to preservatives/drop allergy.

### Systemic medications

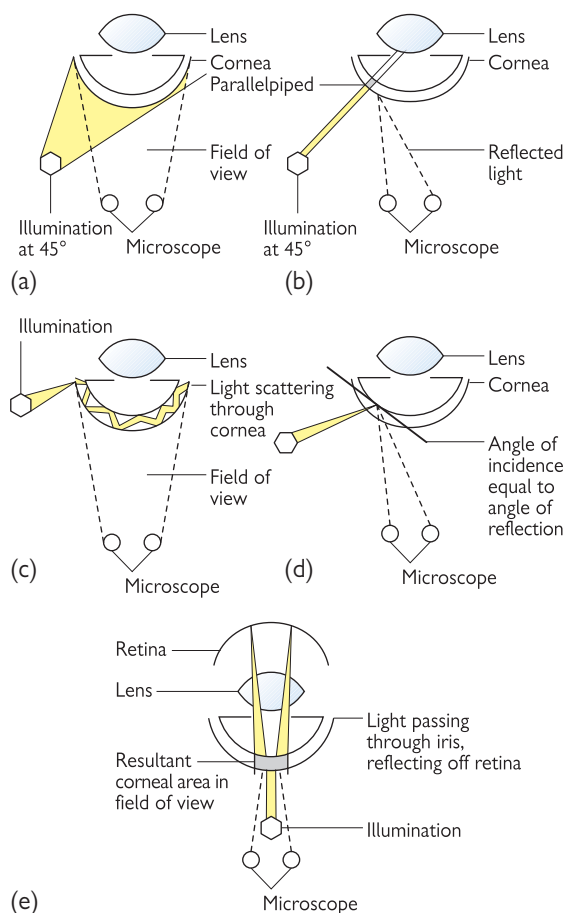
- Systemic steroid (as for topical).
  - Amiodarone (vortex keratopathy).
- Previous allergies to systemic and topical medications (including preservatives) must be documented.

## Family history

Contact with infectious conjunctivitis, inherited corneal dystrophies, glaucoma.

## Social history

- Country of previous residence (sun exposure and pterygium/pingueculum/neoplasms, poor sanitation and trachoma).
- Social and individual circumstances for compliance with treatment and follow-up.
- Occupation and hobbies: appreciation of these is needed to understand the patient's visual requirements; for example, with respect to sports, driving, and reading.
- Patient expectation is an important consideration for any surgery.



**Fig. 1.5** Diagrammatic representation of various slit lamp illumination techniques for corneal examination (see section 1.3): (a) diffuse illumination, (b) direct focal illumination, (c) sclerotic scatter, (d) specular reflection, (e) retroillumination.

## 1.3 Examination of the anterior segment

The slit lamp has two main components: the biomicroscope (the viewing system) and the slit illuminator. It is an essential instrument for anterior segment examination. Systematic examination of the anterior segment includes examination of: the ocular adnexa, conjunctiva, episclera, sclera, tear film, cornea, anterior chamber, iris, lens, and anterior vitreous.

### 1. Introduction

Introduce yourself to the patient.

### 2. Observation

General observation of the patient as a whole aimed at identifying features that may aid the diagnosis, as follows:

- **Skin:** atopic dermatitis (allergic conjunctivitis, keratoconus, cataract), acne vulgaris, seborrheic dermatitis, rosacea (blepharitis, rosacea keratitis).
- **Hands:** deformities in rheumatoid arthritis (dry eyes, corneal melt, scleritis) and nails (Stevens–Johnson syndrome).
- **Musculoskeletal:** kyphosis in ankylosing spondylitis (anterior uveitis).

### 3. Set up the slit lamp

- Ensure examiner and patient comfort/position by adjusting the chairs, slit lamp height, and chin-rest position.
- Ensure eyepieces are set for examiner's interpupillary distance and refraction so that binocularity is achieved.

### 4. Adnexa

- Set the slit lamp on low magnification with a neutral-density filter (low illumination) and diffuse illumination.
- Eyelids: closure, position, blepharitis, tumour.
- Eyelashes: trichiasis, madarosis, poliosis.  
(See Chapter 2 for more details and definitions.)

### 5. Conjunctiva

- **Palpebral conjunctiva:** evert upper lids (subtarsal foreign bodies, papillae, follicles, scarring).
- **Fornices:** chemosis/discharge/pseudomembrane (conjunctivitis), loss/symphepharon (OCP).
- **Bulbar conjunctiva:** hyperaemia, haemorrhage, pingueculum or pterygium, conjunctival stain with fluorescein (abrasion, drying, ulceration).

Note: remember to lift the upper lid to look for a trabeculectomy bleb.

- **Limbal conjunctiva:** ciliary flush (anterior uveitis), Horner–Trantas dots (vernal conjunctivitis), Herbert's pits (old trachoma).

Note: perform conjunctival swabs before instilling fluorescein (*Chlamydia* cannot be detected if fluorescein is present).

### 6. Episclera/sclera

Examine for evidence of inflammation (see section 5.14).

### 7. Tear film

- Examine tear meniscus for height and debris.
- Examine tear break up time using cobalt blue filter.
- Schirmer test.
- See section 1.6 for more details.

### 8. Cornea

See Fig 1.5 for description of slit lamp techniques for corneal examination. NB: if patients are in significant discomfort from ocular surface disease they may require topical anaesthesia to facilitate examination. It is important to test and document corneal sensation (herpetic/neurotrophic keratitis) prior to instillation of anaesthetic.

### Epithelium

- Defects are best seen with special staining (see below).
- Look for punctate epithelial erosions (non-specific sign of epithelial damage), microcysts (corneal oedema, epithelial erosion syndrome), and mucus filaments (dry eye). Dendritic ulceration of herpes infection.
- Iron lines: Hudson–Stähli line (old age), Fleischer ring (keratoconus). Best seen with blue light.

### Bowman's layer

- Subepithelial corneal vascularization and fibrosis, termed pannus if at the superior cornea border.
- Look for band-shaped keratopathy (chronic anterior uveitis, hypercalcaemia).
- Look for anterior scars and raised areas of Salzmann nodular degeneration.

### Stroma

- Infiltrates (sterile, infectious) and opacities (dystrophies and degenerations).
  - Stromal oedema (corneal decompensation after endothelial damage, herpes simplex disciform keratitis).
  - Stromal vascularization (interstitial keratitis, contact lens overwear, infection, or inflammation).
  - Stromal scarring.
  - Ectasia.
- With the exception of oedema all of the above processes can be associated with stromal thinning.

### Descemet's membrane

- Folds (hypotony, stromal oedema).
- Breaks: trauma, advanced keratoconus, congenital glaucoma (Haab's striae).
- Thickening causing guttata (Fuchs endothelial dystrophy).

### Endothelium

- Pigment deposits: Krukenberg spindle (pigment dispersion syndrome).
- Keratic precipitates (anterior uveitis).

### 9. Anterior chamber

Set slit lamp on high magnification, high-intensity filter, 1 mm width and 3 mm-long slit.

- Look for flare, cells, hypopyon, and hyphaema.
- Check anterior chamber depth.

### 10. Iris

- Distorted pupil (anterior segment dysgenesis, iridocorneal endothelial (ICE) syndrome).
- Deposits at pupil margin (pseudoexfoliation syndrome).
- Vessels (rubeosis iridis, vascular tufts).
- Peripheral iridotomy (superior for trabeculectomy or acute glaucoma, inferior after the use of silicone oil to treat retinal detachment in aphakic eye).
- Nodules (Koeppe and Busacca in anterior uveitis).
- Transillumination (pigment dispersion, trauma, albinism).
- Adhesions: anterior or posterior synechiae.

### 11. Lens and anterior vitreous

- Look for lens-capsule abnormalities, pseudoexfoliation, lens opacities, an intraocular lens (IOL), and cells in the anterior vitreous.

## Slit lamp techniques for anterior segment examination

### Diffuse illumination

#### Indication

- With white light this is the initial examination for obtaining an overview of ocular surface tissues.
- With cobalt blue and red-free filters respectively for examination with fluorescein and rose-bengal staining.

#### Technique

Place a full-height, broad, low-brightness beam on to the ocular surface with illumination angled at 45° from the nasal or temporal side.

### Direct focal illumination

#### Indication

- Examining the depth of lesions.
- Qualitative assessment of corneal thickness/thinning.
- Also used for episcleral/scleral examination, anterior segment, crystalline lens, and anterior vitreous examination.

#### Technique

Place a full-height, medium-width, bright beam obliquely into the cornea so that a quadrilateral block of light (parallelepiped) illuminates the cornea. The beam can be thinned further and placed on high magnification to provide a thin optical section giving a high clarity view of a cross section of the cornea.

### Specular reflection

#### Indication

- For examination of corneal endothelium for guttata.
- Can also be used for examining the anterior surface of the cornea or lens.

#### Technique

Direct a narrow beam (thicker than optical section) from the temporal side. The angle of illumination must be 50–60° from the viewing system, which should be offset nasally. High magnification with a ×16 eyepiece is preferable. Look at the image of the reflected light. It is a monocular technique.

Normally the illumination is directed at the point of focus of the viewing arm (parfocal). For the following techniques dissociating the two can be achieved by adjusting the centring screw of the slit lamp.

### Indirect illumination

#### Indication

- Translucent lesions such as subtle stromal opacities.

#### Technique

The light is directed adjacent to the lesion to be examined.

### Sclerotic scatter

#### Indication

- Detecting subtle corneal opacities and translucent cysts.

#### Technique

The illumination is directed at the limbus while the central corneal area is observed. When sclerotic scatter is achieved (by total internal reflection of light) the opposite limbus glows.

### Retroillumination

#### Indication

- Detection of microcystic epithelial oedema.
- Detection of abnormalities of posterior surface of the cornea such as guttata.
- Detection of posterior capsular opacification.

#### Technique

A medium-width beam of light is projected on to structures posterior to the area to be examined. Reflected light is then used to backlight the area to be examined. To examine the cornea in this way the iris, lens, or fundus can be used as the reflective surface. When using the fundus it is preferable to have the pupil dilated.

### Transillumination

#### Indication

- Detecting iris defects, position of peripheral iridotomy, and iris atrophy.

#### Technique

As for retroillumination, using the fundus as the reflective surface.

## Special dyes

### Fluorescein

This is available as a 0.25% solution ready mixed with proxymetacaine. It is also available as impregnated strips and as a 2% eyedrop. Fluorescein does not stain healthy corneal or conjunctival epithelium but readily enters and stains the stroma in areas where cells are lost or where there is an epithelial defect.

#### Indication

- To assess tear-film break-up time.
- To detect a corneal/conjunctival epithelial defect (punctate epithelial erosions, corneal abrasion, corneal ulcer).
- Seidel's test: 2% fluorescein is applied directly to the area in question and a leak of aqueous is seen diluting the stain (bleb leak, surgical wound, corneal perforation).
- To assess contact lens fit.
- For Goldman applanation tonometry.

### Rose bengal

This is available as a 1% eyedrop or as an impregnated paper strip. It stains devitalized epithelium and de-epithelialized areas (also stained by fluorescein). It also stains mucus. It can be used to assess dry eye disease but it may cause discomfort and it should be preceded by topical anaesthetic administration.



## 1.4 Blepharitis

Blepharitis (inflammation of the lid margins) is common. The term blepharitis is generally used to describe chronic lid inflammation but can also be used for acute lid infections. In this chapter we will focus on chronic blepharitis and associated conditions.

Blepharitis can be divided anatomically into anterior or posterior blepharitis. Anterior blepharitis refers to inflammation around the base of the eyelashes. Posterior blepharitis involves the meibomian gland orifices. Anterior blepharitis can be subdivided further into staphylococcal and seborrhoeic types. Posterior blepharitis can be subdivided into meibomian seborrhoea and meibomianitis. There is considerable overlap between the divisions and subdivisions with many patients manifesting multiple 'types' of blepharitis.

Blepharitis can be associated with systemic diseases (rosacea, seborrhoeic dermatitis, acne vulgaris) and can cause secondary ocular disease (dry eye syndromes, chalazion, trichiasis, conjunctivitis, keratitis).

### Anterior blepharitis

#### Pathophysiology

This involves bacterial colonization of the lash follicles. *Staphylococcus aureus* is the most common pathogen although the bacteria *Staphylococcus epidermidis*, *Propionibacterium*, *Corynebacterium*, and the parasite *Demodex follicularum* are also potential pathogens. Immune-mediated inflammation occurs due to bacterial toxins. Bacterially modified lipids can result in an unstable tear film.

Seborrhoeic blepharitis is seen in association with seborrhoeic dermatitis (generally older people) as compared to staphylococcal disease (which is seen in younger adults and occasionally children).

#### Clinical evaluation

##### History

Clinical features are normally fairly symmetrical and are characterized by chronic low-grade clinical features with exacerbations. Clinical features are normally worse first thing in the morning. They include:

- burning, itching, foreign-body sensation;
- mild photophobia, crusting, redness of the lid margins.

##### Examination

- Erythema, telangiectasia, and thickening of the anterior lid margin.
- Hard and brittle scales (collarettes) surrounding the base of the lashes in staphylococcal disease. When these are removed in severe cases there may be small ulcers beneath, on the lid margin.
- Soft and greasy scales (scurf) that cause matting together of lashes in seborrhoeic disease.
- A 'sleeve' of homogenous smooth material surrounding the eyelash base may indicate *Demodex* infestation.
- An external hordeolum (stye) may develop if the lash follicles or glands of Zeis/Moll become infected (see section 2.7).
- Decreased tear break-up time and evaporative dry eye.
- In chronic and severe cases: scarring of lid margin, irregularity of lid margin, madarosis (loss of eyelashes), poliosis (whitening of lashes), and trichiasis (misdirected eyelashes).
- Corneal changes can occur secondary to dryness and trichiasis, but are often immune-mediated (see below under Staphylococcal hypersensitivity, section 1.5).
- Skin changes: seborrhoeic dermatitis is characterized by oily skin and flaking from the scalp, nasolabial folds, brows, and behind the ears.

#### Differential diagnosis

- Dry eyes,
- Basal cell carcinoma, squamous cell carcinoma, sebaceous cell carcinoma.

NB: sebaceous gland carcinoma can occasionally mimic chronic blepharitis in the absence of a significant mass. 'Blepharitis' in such cases is resistant to treatment and may be associated with localized madarosis (see section 2.9).

#### Management

For all types of blepharitis the severity of clinical features correlates poorly with the clinical signs, which can make management frustrating. Treatment of blepharitis is aimed at control rather than cure. Acute exacerbations require more aggressive management while chronic disease requires maintenance therapy.

*Lid hygiene* and hot compresses are the mainstay of treatment. Cleaning with a cotton bud dipped in diluted baby shampoo or sodium bicarbonate can remove the scales and reduce the bacterial load.

*Topical antibiotics*, for example chloramphenicol or fucidic acid (applied on the lid margin after lid hygiene), especially useful for acute exacerbations.

*Tear-film supplements* symptomatically treat symptoms of dry eye.

*Topical corticosteroids* are useful acutely especially if there are signs of staphylococcal hypersensitivity.

### Posterior blepharitis

#### Pathophysiology

This is characterized by meibomian gland dysfunction. Obstruction of the meibomian glands occurs due to hyperkeratinization of the duct orifice. This alters the tear-film physiology resulting in tear-film instability. The stagnant material can also become a growth medium for bacteria. Posterior blepharitis can be associated with acne rosacea.

#### Clinical evaluation

##### History

- As for anterior blepharitis.
- Recurrent eyelid lumps (chalazia, meibomian gland cyst).

##### Examination

- Capping of meibomian gland orifices by oil globules, oily tear film, foam on the lid margin.
- Rounding, thickening, and telangiectasia of lid margin. On lid pressure turbid, thick, or paste-like fluid oozes out.
- Decreased tear break-up time and corneal punctate epithelial erosions. Corneal vascularization and infiltrates.
- Conjunctival papillae, concretions, chalazia.
- Skin changes: rosacea is characterized by facial erythema, rhinophyma, telangiectasias, and pustules.

#### Differential diagnosis

- As for anterior blepharitis.

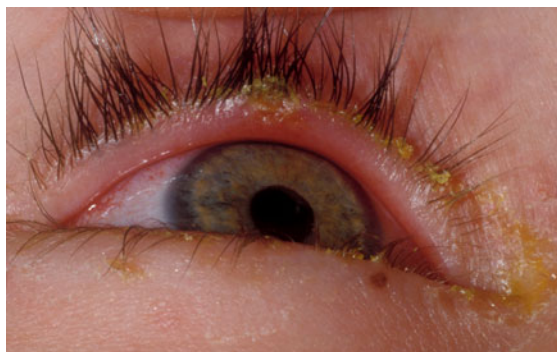#### Management

*Lid massage after heat*: this is the mainstay of treatment for posterior blepharitis. A warm compress is applied to the lids for several minutes to melt the thick lipid secretions. Following this meibomian secretions are expressed by pressing fingertip/cotton bud along the marginal tarsal plate.

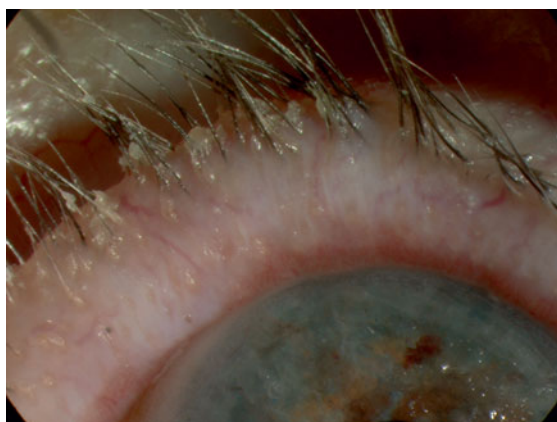
*Topical antibiotics/steroids*: short courses of these are particularly useful in cases of staphylococcal hypersensitivity (see below).

*Tear-film supplements*: indicated in the presence of an unstable tear film.

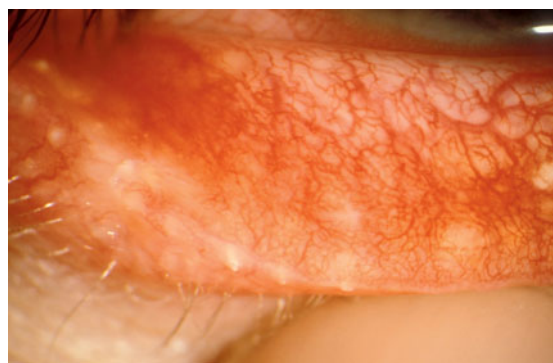**Systemic tetracyclines:** these are useful in persistent or severe cases. A 2–3 month course of oral doxycycline 100 mg once a day can bring symptoms under control. Side effects include photosensitivity and stomach upset. Tetracyclines are contraindicated in children under 12 years, pregnancy, and breast feeding due to the risk of tooth enamel abnormalities.



**Fig. 1.6** Staphylococcal anterior blepharitis. Note the collarettes surrounding the base of the lashes and the surrounding erythema.



**Fig. 1.7** Seborrhoeic anterior blepharitis. Note the greasy scales and matting of the lashes.



**Fig. 1.8** Posterior blepharitis. Note the telangiectasia of the posterior lid margin and the thickened meibomian gland secretions being expressed.



## 1.5 Staphylococcal hypersensitivity disorders

There are a variety of disorders characterized by ocular surface inflammation that occur in patients with coexisting blepharitis. The exact pathophysiology of these conditions has not been fully elucidated. A type IV hypersensitivity reaction to staphylococcal antigens is believed to be responsible. The antigenic stimulus for rosacea keratitis is not known but it is included in this section as it represents an ocular surface inflammation that can occur with blepharitis. Many of these conditions can coexist.

### Staphylococcal hypersensitivity syndrome

This is characterized by conjunctival injection and a punctate epithelial keratopathy that predominantly affects the inferior cornea and conjunctiva where it is in close physical contact with the eyelids. Occasionally a diffuse keratopathy can occur. The condition can be bilateral, asymmetrical, or unilateral. The extent of corneal involvement can be significant despite only mild eyelid disease. Symptoms range from mild irritation to foreign body sensation, watering, and photophobia.

#### Treatment

This involves treating the blepharitis together with a short course of topical steroids depending on the degree of inflammation.

### Marginal keratitis

This classically presents as a grey-white anterior stromal sterile corneal infiltrate. It commonly occurs on the peripheral cornea, leaving a 1 mm clear area between the infiltrates and the limbus. Symptoms are mild irritation, watering, redness, and photophobia. Initially the epithelium is intact but it eventually breaks down (i.e. fluorescein staining occurs) after prolonged inflammation and the ulcer spreads circumferentially with small blood vessels growing towards the infiltrate.

#### Treatment

Resolution often occurs spontaneously after several days. However, a short course of topical steroid with antibiotic cover can speed recovery. Treat associated staphylococcal blepharitis.

### Phlyctenulosis

This occurs commonly in children and young adults as a result of type IV hypersensitivity to microbial antigens (most commonly *Staph. aureus* but also *Mycobacterium tuberculosis* in endemic areas). Phlyctenules are single/multiple grey-yellow elevated inflammatory lesions at the limbus or conjunctiva surrounded by intense injection of blood vessels. They present with watering, redness, and photophobia. The lesion ulcerates and then heals with vascularization in the involved area over 2–3 weeks. Recurrences can occur at the edge of an area of vascularization associated with a previous scar and can progress centripetally on to the cornea.

#### Treatment

This is as for marginal keratitis (consider investigations for tuberculosis in endemic areas).

### Rosacea keratitis

Rosacea is a chronic idiopathic condition that affects the facial skin and eyes in adults (normally aged 30–60 years). Cutaneous features include mid-facial erythema, telangiectasia, papules, nodules, and rhinophyma

(thickened skin and connective tissue of the nose). It is thought to be due to dysfunction of the meibomian glands of the skin and eyelids with secondary inflammation. The ophthalmic manifestations can occur in the presence of minimum skin changes and include posterior blepharitis, recurrent chalazions, tear-film dysfunction, marginal keratitis, superficial, wedge-shaped peripheral vascularization with its base at the limbus, thinning, scarring, and even perforation.

#### Treatment

- Treatment is with topical corticosteroids, the intensity and frequency of which may need to be high initially if there is advancing corneal inflammation. They should be quickly tapered as symptoms permit.
- A course of systemic tetracycline.
- Sparing use of tear supplements and lubricants.

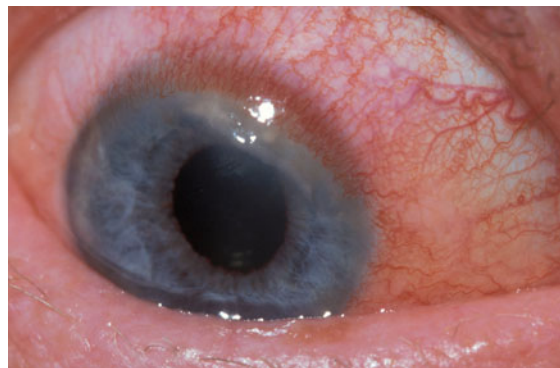

Fig. 1.9 Marginal keratitis.

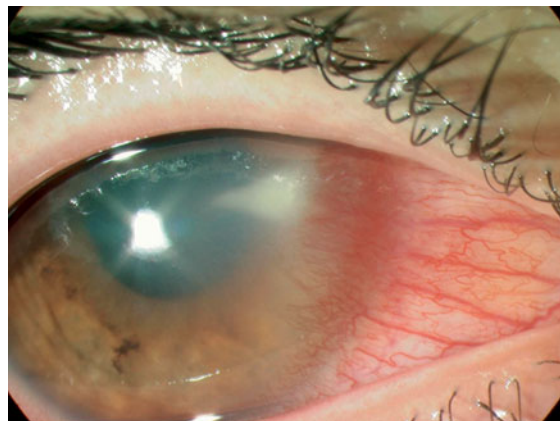
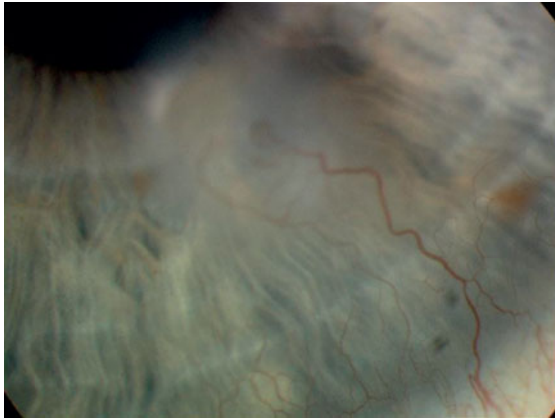


Fig. 1.10 Phlyctenulosis: corneal phlyctenule.



**Fig. 1.11** Rosacea keratitis.

## 1.6 Dry eye disease

Dry eye disease (also called dysfunctional tear syndrome or keratoconjunctivitis sicca) is a common, multifactorial disease. It is a disorder of the tear film that occurs due to either deficient production of aqueous tears or excessive evaporation of tears or a combination of the two. Inflammation and damage of the ocular surface may be either a cause or a consequence of the dry eye state.

### Pathophysiology

#### Aqueous tear deficiency

The main lacrimal glands produce the majority of the aqueous component of tears. There is also significant production of aqueous tears by the accessory conjunctival lacrimal glands. There is both a basic and reflex component to aqueous tear production. The reflex component occurs in response to any irritation of the ocular surface.

#### Sjögren syndrome

This is a disease characterized by dry eyes, dry mouth, and autoimmune-mediated inflammation of the lacrimal and salivary glands. It can be classified further into primary and secondary forms.

- Primary Sjögren syndrome: includes patients who have non-specific or lack of systemic immune dysfunction.
- Secondary Sjögren syndrome: includes patients with a well-defined systemic autoimmune disease. Secondary Sjögren syndrome occurs most commonly in rheumatoid arthritis but can also occur in other connective tissue diseases.

#### Non-Sjögren syndrome

- Lacrimal gland disease: congenital, infiltrative (lymphoma, sarcoidosis), infective (human immunodeficiency virus (HIV)), Epstein-Barr virus (EBV), inflammatory (thyroid eye disease) diseases.
- Lacrimal duct obstruction: cicatricial diseases (trachoma, OCP, Stevens-Johnson syndrome, post-irradiation fibrosis) and goblet cell destruction (vitamin A deficiency also known as xerophthalmia).
- Drug-related: anticholinergics, antihistamines, diuretics, and oral contraceptives.
- Loss of reflex tearing due to decreased surface innervation: contact lens wear, herpetic disease, diabetic neuropathy, topical/systemic anaesthesia, fifth cranial nerve disease, post-excision laser refractive surgery.

#### Evaporative tear dysfunction

- Meibomian gland dysfunction.
- Disorders of eyelid aperture and eyelid/globe congruity: exposure, ectropion, lagophthalmos, and proptosis.
- Contact lens wear.
- Blink abnormality (Parkinson's disease).

### Clinical evaluation

The spectrum of clinical manifestation of dry eye disease ranges from minimal ocular surface disease to sight threatening corneal complications.

#### History

- Burning, foreign body sensation, photophobia, red eye, blurred vision (normally intermittent), occasionally pain (filamentary keratitis).
- Excessive watering (paradoxical reflex watering).
- Symptoms worse with prolonged reading, using a VDU (decreased blink rate), in cold, windy weather, central heating, air conditioning, aeroplane cabin (increased tear evaporation, decreased humidity).
- Symptoms from aqueous tear deficiency tend to be worse at the end of the day. Those from meibomian gland dysfunction (evaporative dry eye) tend to be worse at the beginning of the day.

- Dry mouth, difficulty in swallowing dry food (Sjögren syndrome).
- Contact lens intolerance.

#### Examination

- Hyperaemia of the bulbar conjunctiva, redundant folds of bulbar conjunctiva (conjunctival chalasis).
- Decreased tear meniscus.
- Decreased tear break-up time: this is assessed by instilling fluorescein into the conjunctival fornix. After several blinks it is the time taken from the last blink to the first dry patch appearing on the cornea. It can be abnormal in all causes of dry eye syndrome.
- Schirmer test: this is performed by inserting a thin strip of filter paper (no. 41 Whatman) into the inferior fornix with the eyes closed for 5 minutes. The amount of wetting is then assessed. It is abnormal if <5 mm (suggestive of aqueous tear deficiency); 5–10 mm is borderline. If anaesthetic is instilled first then basal secretion alone is tested. Without anaesthetic basal and reflex secretion together are tested (Schirmer I test). Stimulation of the nasal mucosa tests reflex secretion (Schirmer II test).

#### Keratopathies

- Punctate epithelial erosions.
- *Filamentary keratopathy*. Corneal filaments are grey threads attached to the epithelium that move with blinking. They are composed of mucus debris and devitalized epithelium and are thus most readily seen with rose bengal staining.
- Mucus plaques. These are semi-transparent elevated lesions that occur on the surface of the cornea often associated with filamentary keratopathy.
- Severe cases can result in an epithelial defect or a sterile corneal infiltrate or ulcer. Secondary infectious keratitis can also develop. Both sterile and infectious corneal perforations can occur.
- Signs of associated keratopathies (see below).

#### Investigations

Dry eye syndrome is predominantly a clinical diagnosis. If there are symptoms of Sjögren syndrome (dry eye and dry mouth) then consider investigations to establish primary or secondary causes.

### Management

Needs to be directed depending on severity and aetiology. Underlying disease such as blepharitis must be adequately treated.

#### Mild disease

- Standard artificial tears such as a carbomer gel or hypromellose 0.3% 4 times daily (QDS).
- Lubricating ointment such as paraffin-based simple eye ointment at night.

#### Moderate disease

- Preservative-free artificial tears (e.g. carmellose 1%) as required up to every hour. Lubricating ointment at night.
- If filaments or mucus strands are present they should be gently removed with a cotton bud. Mucolytics such as acetylcysteine 5% (Ilube) QDS are also useful.
- Lower punctal occlusion. Temporary (dissolvable) plugs should be used in the first instance to ensure there is no epiphora. If effective then permanent plugs or surgical cautery can be used.
- Topical cyclosporin (0.05%) twice daily (BD) or short courses of topical steroids can be useful to modulate the inflammatory component.

#### Severe disease

- All of the above treatments.
- Upper and lower punctal occlusion.

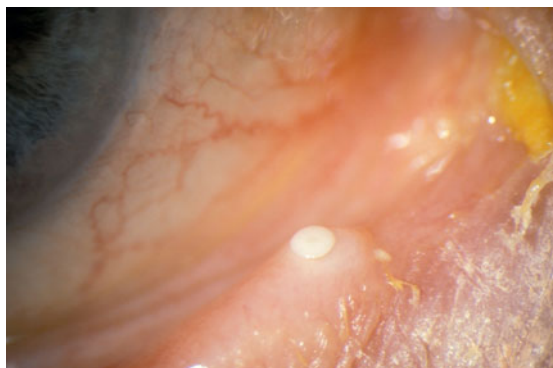
- Moist chamber goggles, humidifier.
- Autologous serum eyedrops.
- Lateral tarsorrhaphy (see section 2.4).

## Dellen

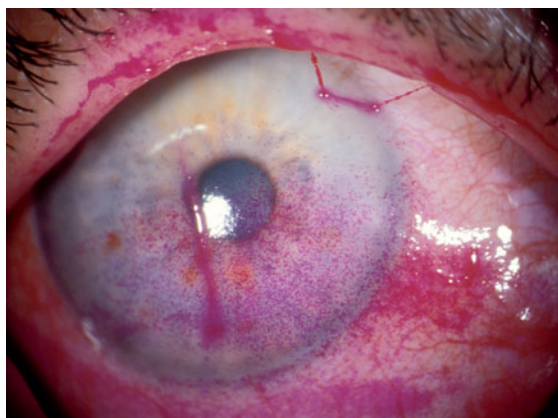These are caused by localized tear-film instability which results in a focal area of stromal dehydration and consequent thinning. They usually occur adjacent to a raised lesion present on the conjunctiva, limbus, or cornea (e.g. filtering bleb, pterygium, pingecula, nodular scleritis/episcleritis, oedema following squint surgery). Symptoms are normally of mild irritation. On examination there is no epithelial defect but a focal corneal depression with poor surface wetting.

### Treatment

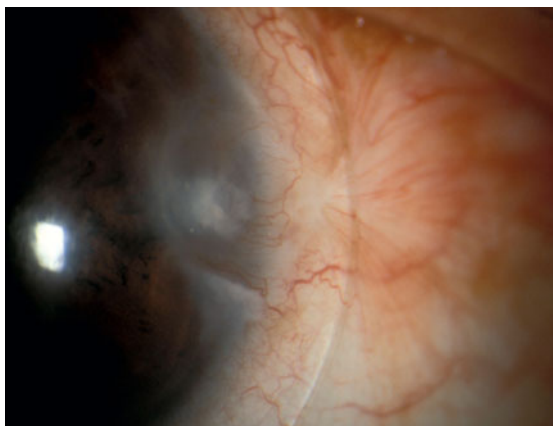
The aim is to restore the continuity of overlying tear film with tear supplements and lubricants. The causative elevated lesion may need to be treated surgically if symptoms persist.



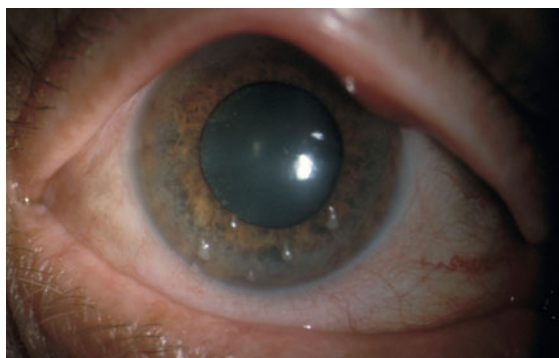
**Fig. 1.14** Silicone punctal plug occluding the lower punctum.



**Fig. 1.12** Rose bengal staining of a dry eye. Note the punctate epithelial erosions on the inferior corneal surface and the inferior bulbar conjunctiva.



**Fig. 1.15** Dellen.



**Fig. 1.13** Filamentary keratopathy.

## 1.7 Conjunctivitis I: classification and adenovirus

### Conjunctivitis classification

Conjunctivitis is a non-specific term for inflammation of the conjunctiva. It is characterized to a variable extent by:

1. exudation (discharge),
2. chemosis (oedema),
3. vascular dilatation (conjunctival hyperaemia).

There are a variety of ways of classifying conjunctivitis, which are outlined below.

#### Age

Neonatal (ophthalmia neonatorum), childhood, and adult.

#### Duration

Acute (<4 weeks in duration) or chronic (>4 weeks).

#### Aetiology

- Infective (viral, bacterial, chlamydial, parasitic).
- Allergic (seasonal, perennial, vernal, giant papillary).
- Autoimmune (OCP, Stevens–Johnson syndrome).
- Toxic (drop toxicity, chemical injury, post-irradiation).
- Mechanical (eye rubbing, mucus fishing syndrome, foreign body).
- Neoplastic (sebaceous gland carcinoma, conjunctival malignancies).

#### Morphology

- *Papillary*: this is a non-specific feature of many causes of conjunctivitis. Giant papillae (papillae >1 mm), which occur in chronic cases when individual papillae become confluent, are a characteristic feature of giant papillary conjunctivitis and vernal conjunctivitis.
- *Follicular* (viral, chlamydial, drop allergy).
- *Pseudomembranous*. These are not true membranes but rather coagulated exudates adherent to the conjunctival epithelium. They can be peeled off the epithelium. Causes include adenoviral conjunctivitis, gonococcal conjunctivitis, and the acute stage of Stevens–Johnson syndrome.
- *Membranous*. True membranes are continuous with the conjunctival epithelium and cannot be removed without traumatizing the conjunctiva. Causes include *Streptococcus pyogenes* and diphtheria.
- *Cicatricial* (trachoma, OCP, Stevens–Johnson syndrome).
- *Haemorrhagic* (enterovirus, adenovirus, haemophilus, gonococcus).
- *Granulomatous* (sarcoid, tuberculosis).

#### Discharge

Classifying conjunctivitis according to the type of discharge is not specific but can be helpful where a more complete examination is not possible, for example in very young children:

- purulent (acute bacterial infections),
- mucopurulent (bacterial, chlamydial),
- mucoid (allergic, viral),
- watery (viral).

### Adenoviral conjunctivitis

#### Pathophysiology

This is the most common cause of viral conjunctivitis. It is a double-stranded DNA virus with over 50 serotypes. The incubation period is about 8–9 days. The virus is shed for up to 2 weeks following the onset of conjunctivitis. Adenovirus is transmitted by close contact

with ocular/respiratory secretions or fomites. The virus is extremely contagious and care must be taken in the eye clinic to minimize spread of the virus to staff and other patients.

#### Clinical evaluation

Adenoviral conjunctivitis presents clinically as one of three possible syndromes.

- *Simple follicular conjunctivitis*: no systemic involvement. Corneal involvement is mild if present.
- *Pharyngoconjunctival fever*: fever, pharyngitis, and follicular conjunctivitis. Corneal involvement is mild if present.
- *Epidemic keratoconjunctivitis*: may be preceded by an upper-respiratory-tract infection. The hallmark with this syndrome is significant corneal involvement.

In reality these syndromes are difficult to distinguish clinically, especially in the early stages of disease. General features of adenoviral conjunctivitis and keratitis are considered below.

#### History

- Watery discharge and mild to moderate burning. Initially in one eye. Often becomes bilateral due to auto-inoculation of the other eye.
- Red eye, lid oedema, photophobia.
- If corneal involvement there may be pain and blurred vision.

#### Examination

- Palpable tender pre-auricular and submandibular lymph nodes.
- Conjunctival: follicles, chemosis, injection. Subconjunctival petechial haemorrhages. Conjunctivitis normally resolves within 2 weeks.
- In severe cases there may be pseudomembranes.
- Keratitis: there are two main forms of adenoviral keratitis:
  1. Punctate epithelial erosions occur 7–10 days after the onset of symptoms and normally resolve after 2 weeks.
  2. Round subepithelial infiltrates. These are thought to represent an immunological response to the virus and persist for several weeks (occasionally years) before complete resolution. Rarely large persistent lesions can leave a residual scar and blurred vision.

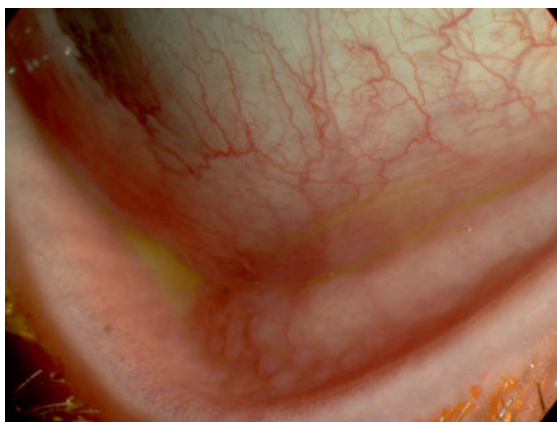
#### Investigations

Diagnosis is usually clinical. Confirmation by swab (polymerase chain reaction, PCR).

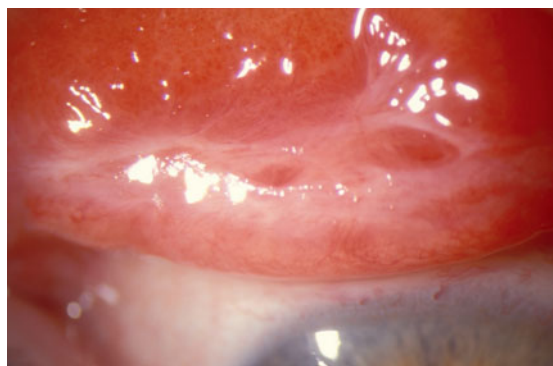
#### Management

- Cool compresses and artificial tears for symptomatic relief.
- Topical antibiotics are often given as there is some overlap with the clinical manifestations of bacterial conjunctivitis.
- Topical steroids can be used to treat: pseudomembranes and severe/persistent keratitis associated with decreased vision. The use of steroids accelerates resolution but does not otherwise affect the natural course of the disease.
- Patients should be educated about hygiene measures to prevent transmission of the virus.

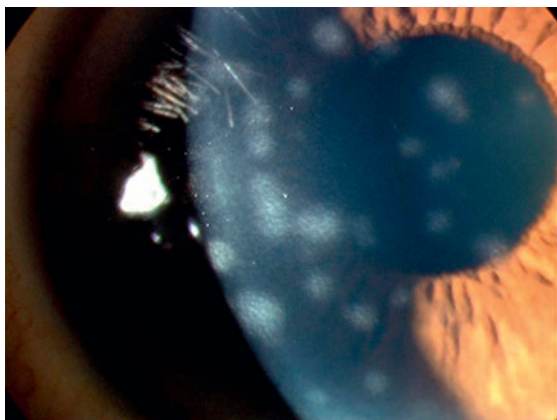




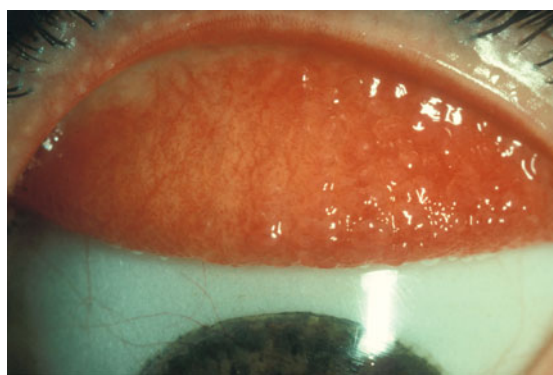
**Fig. 1.16** Follicles on the inferior palpebral conjunctiva in a case of adenoviral conjunctivitis.



**Fig. 1.18** Inflammatory conjunctival membrane in a case of severe adenoviral conjunctivitis.



**Fig. 1.17** Subepithelial infiltrates in adenoviral keratitis.



**Fig. 1.19** Papillae on the superior palpebral conjunctiva.

## 1.8 Conjunctivitis II: other infectious causes

### Herpes simplex conjunctivitis

Herpes simplex blepharoconjunctivitis occurs as either a primary infection or, more commonly, as a result of viral reactivation. Clinical features include unilateral follicular conjunctivitis, pre-auricular lymphadenopathy, lid/eyelid margin vesicles, and dendritic epithelial keratitis (see section 1.18). The condition is normally self-limiting with the conjunctivitis resolving within 1 week. Treatment to shorten the duration of symptoms is with topical acyclovir 5 times/day or oral acyclovir 400 mg 5 times/day for 10 days.

### Molluscum contagiosum conjunctivitis

This is a poxvirus, transmitted by direct contact or autoinoculation. Clinical features include pearly umblicated nodules at/near the lid margin and ipsilateral follicular conjunctivitis; in long-standing cases punctate epithelial erosions and corneal pannus may occur. Spontaneous resolution takes months to years. Removal of lid lesions by shave excision, incision, or curettage is curative. Multiple mollusca in the chin-strap region can be a feature of acquired immunodeficiency syndrome (AIDS).

### Chlamydial conjunctivitis

Chlamydia trachomatis is an obligate intracellular bacterium. It causes three conjunctivitis syndromes:

1. trachoma: serotypes A–C;
2. adult inclusion conjunctivitis: serotypes D–K;
3. chlamydial ophthalmia neonatorum: serotypes D–K.

#### Trachoma

This is the most common cause of preventable blindness in the world, with 150 million people estimated to be affected. In endemic areas it occurs in communities with poor access to facilities for hygiene and sanitation. It is transmitted by direct contact, by flies, or in fomites.

#### Clinical evaluation

Primary infection usually occurs during childhood.

- Recurrent severe follicular conjunctivitis with follicles predominantly on the superior tarsal conjunctiva and limbus. Follicles can be obscured by diffuse papillary hypertrophy.
- With time linear or stellate scarring over the tarsal plate occurs. Broad confluent scars are known as Arlt's lines.
- Involution and necrosis of limbal follicles results in depressions known as Herbert's pits.
- Progressive scarring of the conjunctiva results in trichiasis, entropion, and dry eye, which in turn leads to corneal disease.
- Corneal findings include punctate epithelial erosions, scarring, and vascularization.

#### Management

- Public health preventative measures such as increased hygiene (face washing) and access to clean water.
- Treatment for acute infection is azithromycin 1g orally as a single dose.
- Treatment for dry eye is often necessary and entropion or trichiasis may require surgical intervention.

#### Adult inclusion conjunctivitis

This is a sexually transmitted disease, which typically affects young adults. It often occurs in conjunction with urethritis or cervicitis.

#### Clinical evaluation

The onset is subacute. If untreated symptoms can persist for up to 18 months. Clinical features include:

- follicular conjunctivitis and pre-auricular lymphadenopathy,
- potential corneal involvement, which includes fine or coarse epithelial and/or subepithelial infiltrates.

#### Investigations

The investigation of choice is PCR, but a variety of laboratory tests are available: culture, enzyme-linked immunosorbent assay (ELISA), and direct monoclonal antibody fluorescence microscopy (note: topical fluorescein can interfere with immunofluorescence tests).

#### Management

- Patients with laboratory-confirmed infection and their sexual contacts should be investigated for coinfection with other sexually transmitted diseases before antibiotic treatment is initiated. Sexual partners need to be traced and treated to prevent reinfection.
- Treatment is azithromycin 1g orally as a single dose.

### Chlamydial ophthalmia neonatorum

This is the most common cause of neonatal conjunctivitis and like the other causes of infectious ophthalmia neonatorum is acquired with passage of the baby through the birth canal.

#### Clinical evaluation

- The time from birth until the onset of signs is variable but is typically subacute, starting at 5 days post-natal.
- There is no follicular response in neonates.
- There is a significant mucopurulent discharge.
- If associated with systemic chlamydial infection there is a risk of chlamydial pneumonitis.

#### Management

- Treatment is with systemic erythromycin (50 mg/kg per day orally or intravenously 4 times/day for 14 days).
- Both mother and her partner(s) need to be examined and treated by a physician for genital infections.

## Bacterial conjunctivitis

### Simple bacterial conjunctivitis

This is a common condition (particularly in children). It can be caused by a wide range of both Gram-positive and Gram-negative organisms. Common causative organisms include *Staph. aureus*, *Streptococcus pneumoniae*, and *Haemophilus influenzae*. Spread occurs by direct contact.

#### Clinical evaluation

- Onset is acute/subacute coming on over hours to days.
- There is usually bilateral (or sequential) involvement.
- The discharge may initially be watery but soon becomes classically mucopurulent with matting of the eyelashes.
- There is papillary conjunctival reaction and chemosis with variable lid oedema.
- There is usually no pre-auricular lymphadenopathy.
- There may be mild punctate epithelial erosions on the cornea.
- *Staph. aureus* conjunctivitis is commonly associated with blepharitis (blepharoconjunctivitis) and these cases may develop recurrent infections if left untreated.

#### Management

It is usually a self-limiting condition, resolving within 2 weeks. Treatment can reduce the duration of symptoms:

- cleaning of lids and removal of discharge;
- broad-spectrum topical antibiotic ointment or drops (chloramphenicol or fusidic acid 4–6 times/day).

NB: ointments blur vision and drops during the day may be preferable in adults. However, if there is considerable watering then ointment is more useful. *H. influenzae* conjunctivitis should be treated with oral amoxycillin because of the potential for extraocular infection. Hygiene measures are important to prevent spread to contacts.

### Adult gonococcal conjunctivitis

This is a sexually transmitted disease resulting from genital-to-eye contact. It is caused by the Gram-negative diplococcus, *Neisseria gonorrhoeae*, which can invade the healthy cornea. It is an ophthalmic emergency as infection can lead rapidly to perforation of the cornea.

#### Clinical evaluation

Onset is hyperacute (<24 hours), with severe mucopurulent conjunctivitis. Features include marked lid swelling, pre-auricular lymphadenopathy, copious purulent discharge, and pseudomembranes. Corneal involvement starts as a peripheral ulcer that progresses to become a ring ulcer. Corneal perforation and endophthalmitis can occur.

There may be associated genital infection.

#### Management

- Investigations include: conjunctival swabs for urgent Gram stain, culture, and sensitivities.
- If there is no corneal involvement treatment is with a single dose of ceftriaxone 1g intramuscularly.
- If there is corneal involvement, admission is necessary and treatment is with ceftriaxone 1g intravenously twice/day for 3 days. Frequent irrigation of the conjunctiva sac with saline may be necessary to remove discharge.
- Topical treatment is with erythromycin, bacitracin, gentamicin, or fluoroquinolones.
- Patients and sexual partners must be investigated and treated for other sexually acquired infections.

### Gonococcal ophthalmia neonatorum

#### Clinical evaluation

- Typically presents within 1–3 days of birth with a bilateral initially serosanguinous conjunctival discharge, which becomes purulent.
- As with adult disease there is also a significant risk of corneal involvement.
- Disseminated gonococcus occurs rarely, with potentially life-threatening meningitis, pneumonia, and sepsis.

#### Management

- Investigations include conjunctival swabs for urgent Gram stain, culture, and sensitivities.
- For non-disseminated disease treatment is with a single intramuscular or intravenous dose of ceftriaxone 50mg/kg.
- Regular irrigation of the conjunctival sac is necessary
- Topical treatment is as for adult gonococcal conjunctivitis.

Note: all ophthalmia neonatorum is a notifiable disease and should be managed in conjunction with a paediatric infectious diseases specialist.

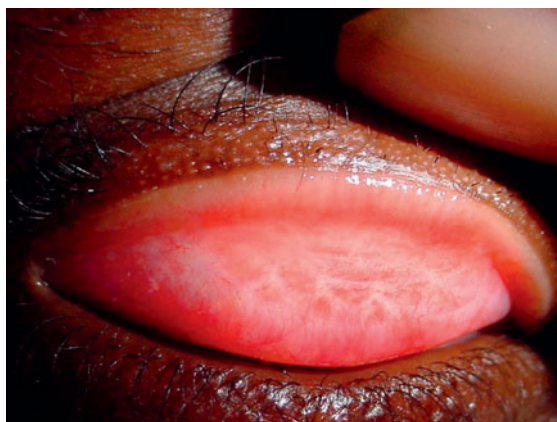

Fig. 1.20 Trachomatous scarring (courtesy of Matthew Burton).

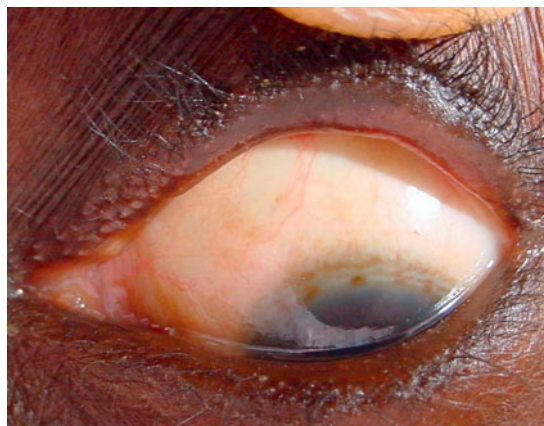

Fig. 1.21 Herbert's pits (courtesy of Matthew Burton).

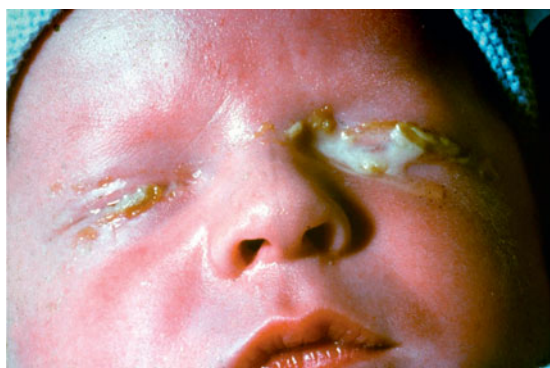

Fig. 1.22 Gonococcal ophthalmia neonatorum (courtesy of Volker Klaus).

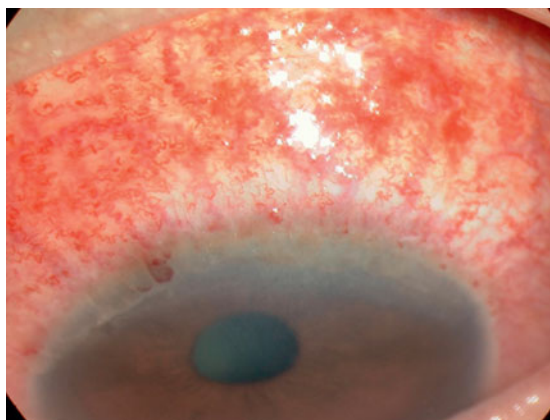


Fig. 1.23 Gonococcal conjunctivitis: note the intense vascular dilatation and conjunctival haemorrhages.



## 1.9 Conjunctivitis III: allergic

Allergic conjunctivitis represents a spectrum of disease that can be classified into:

1. seasonal (hay fever) allergic conjunctivitis (SAC),
2. perennial allergic conjunctivitis (PAC),
3. vernal keratoconjunctivitis (VKC),
4. atopic keratoconjunctivitis (AKC).

Categories 1 and 2 have overlapping clinical features and will be considered together.

### SAC and PAC

These conditions are common forms of acute allergic conjunctivitis.

#### Pathophysiology

Both conditions are type 1 IgE-mediated immediate hypersensitivity reactions that occur in response to airborne antigens. SAC causes symptoms during pollination in late spring and summer. PAC causes symptoms throughout the year with exacerbation in the autumn in response to greater levels of dust and fungal antigens. Both conditions can be associated with other atopic conditions such as eczema and asthma.

#### Clinical evaluation

##### History

- The hallmark symptom is itch. This is often associated with increased lacrimation, slight red eye, and occasionally mucus discharge.
- It can be associated with sneezing, nasal itch, and watery nasal discharge.

##### Examination

- Mild conjunctival injection and oedema with papillary reaction of the tarsal conjunctiva.
- Corneal disease is uncommon.

#### Management

Patients should be advised against rubbing their eyes.

##### Allergen avoidance

- Patients with SAC can be counselled to limit their outdoor activity on days of high pollen count.
- Patients with PAC should be advised on measures to reduce dust mites (avoid carpets, feather bedwear, etc.).
- A cold compress can provide symptomatic relief.

##### Medical treatment

- Artificial tears are beneficial in diluting and flushing away allergens and other inflammatory mediators from the ocular surface.
- Topical vasoconstrictors can provide temporary symptomatic relief but prolonged use can result in a compensatory rebound hyperaemia.
- The mainstay of treatment is a topical antihistamine, a topical mast cell stabilizer, or a drug that has both effects, such as olopatadine. It is important to start mast cell stabilizers prophylactically 2 weeks before the time when allergy normally occurs.
- Topical steroids are reserved for severe exacerbations.
- Oral antihistamines are useful, especially for associated symptoms of rhinitis.

### VKC

#### Pathophysiology

This condition is a bilateral chronic inflammation of the conjunctiva, often with secondary corneal involvement. Symptoms can occur

year round, with a marked seasonal component with exacerbations during the spring (vernal). It occurs more frequently in males (2:1) who commonly have a personal or family history of atopy. It is the result of both type 1 and type IV (cell-mediated) hypersensitivity reactions.

#### Clinical evaluation

##### History

- Severe itch and copious mucoid discharge.
- With corneal involvement there may be photophobia and blurring of vision.

##### Examination

There are two forms of VKC according to the anatomical location where clinical signs are most prominent.

##### Limbal VKC

- This occurs more commonly in Black and Asian patients and is more prevalent in hotter climates.
- There is thickened, fleshy appearance to the limbus with scattered papillae.
- In active disease there is a white apex to the papillae (Horner-Trantans dots) which represent aggregates of eosinophils and necrotic epithelial cells.

##### Palpebral VKC.

- Conjunctival hyperaemia and chemosis associated with diffuse papillary hypertrophy more prominent on the upper tarsus.
- In more severe cases the papillae can coalesce to giving rise to giant 'cobblestone' papillae.
- There may be a mechanical ptosis.
- Both limbal and palpebral VKC can occur in isolation or together.

##### Keratopathy

Keratopathy is more common with palpebral disease and includes the following.

- Punctate epithelial erosions most common superiorly.
- Pannus and corneal vascularization.
- Sterile epithelial breakdown with calcification of the exposed stroma (shield ulcer). Stromal opacification, infection, and vascularization are potentially sight-threatening complications.
- Pseudogerontoxon is arc-like opacification of the peripheral cornea adjacent to an area of limbus previously affected by inflammation.
- Severe allergic conjunctivitis is associated with both keratoconus and cataract.

#### Management

- For mild to moderate disease the treatment is as for SAC/PAC.

For more severe disease and in cases of significant corneal involvement there are the following treatment options:

- Topical steroids should be administered initially at high frequency and rapidly tapered.
- Topical cyclosporine 0.05–2% may act as a steroid-sparing agent.
- Topical acetylcysteine 5% is useful for mucus plaque.
- Surgical debridement or superficial keratectomy may be necessary to remove a calcified plaque. A supratarsal steroid injection given at this time can help prevent recurrence.

### AKC

#### Pathophysiology

This chronic condition, which typically has an onset in young adults, is strongly associated with severe atopic dermatitis. Atopic individuals

have depressed systemic cell-mediated immunity making them susceptible to herpes simplex viral keratitis and colonization of the eyelids with *Staph. aureus*. The pathophysiology is otherwise similar to VKC. Differences between this and VKC are shown in the table below.

### Clinical evaluation

#### History

- This is as for VKC with an exception being that disease tends to occur all year round with minimal or no seasonal exacerbation.

#### Examination

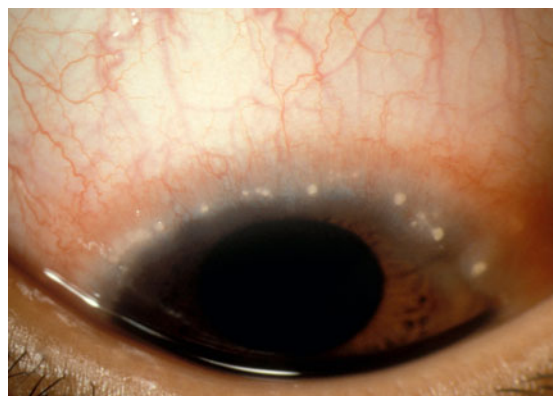
- Skin of the eyelids is thickened, macerated and fissured.
- Eyelid margin often has staphylococcal blepharitis.
- Conjunctiva is often pale, and featureless. During exacerbations there is hyperaemia, chemosis, and a small- to medium-sized papillary reaction on the upper and lower palpebral conjunctivae. In severe cases conjunctival scarring can prevent the papillary response over the upper tarsus. Forniceal shortening and symblepharon formation can occur.
- Cornea may display punctate epithelial erosions in mild disease. More extensive disease may result in persistent epithelial defects, stromal scarring, and pannus formation. Corneal disease may be further complicated by microbial or herpes simplex keratitis.

### Management

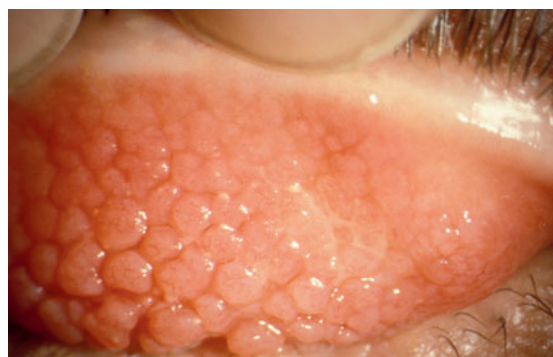- This is as for VKC but there may be a poor response to treatment.
- These patients also require treatment for associated infections such as staphylococcal blepharitis.
- In a minority of patients with severe disease systemic immune suppression may be necessary, especially prior to corneal surgery.

**Table 1.1 Features of VKC and AKC**

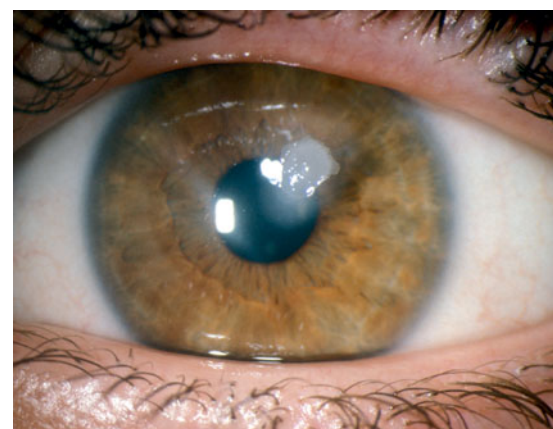
Feature	VKC	AKC
Age of onset	Before 10 years	25–50 years
Duration	Lasts 2–10 years (resolves by puberty)	Chronic
Sex	M>F	Equal
Exacerbations	Spring exacerbations	Minimal or no exacerbations
Conjunctival involvement	Upper tarsus, scarring rare	Upper and lower tarsus, scarring common



**Fig. 1.24** Horner–Trantas dots in limbal VKC.



**Fig. 1.25** Giant cobblestone papillae in palpebral VKC.



**Fig. 1.26** Shield ulcer in VKC.

## 1.10 Conjunctivitis IV: miscellaneous

### Superior limbic keratoconjunctivitis

#### Pathophysiology

Superior limbic keratoconjunctivitis is a chronic condition of superior conjunctival irritation occurring mostly in middle-aged women. There is an association with hyperthyroidism and dry eye. It is thought to be due to friction between the superior palpebral and bulbar conjunctiva causing mechanical irritation which occurs with tight lids, loose superior bulbar conjunctivae, exophthalmos, and dry eye. It is often bilateral but asymmetrical and tends to resolve spontaneously after recurrences for 1–10 years.

#### Clinical evaluation

##### History

- Redness, foreign body sensation, photophobia, and/or pain.
- Blepharospasm may be present especially if there is associated filamentary keratitis.

##### Examination

Signs are best seen with the patient looking down and with the upper lid elevated. Signs include:

- papillary reaction and congestion on the superior tarsal conjunctiva;
- hyperaemia/thickening/loosening of the superior bulbar conjunctiva; hyperaemia is maximal at the limbus;
- punctate staining (fluorescein or rose bengal) of the superior limbal conjunctiva and cornea;
- filamentary keratopathy of the superior cornea;
- there may also be signs of associated tear-film dysfunction and/or thyroid eye disease.

#### Treatment

A variety of potential treatments exist. These include the following.

- Tear-film supplements/lubricants, mucolytics, topical steroid, and punctal occlusion.
- Topical vitamin A, cyclosporin, pressure patching, large-diameter bandage contact lens, and/or thermal cauterization of the superior bulbar conjunctiva.
- Superior conjunctival resection (3–4 mm strip) may be effective in patients who do not respond to the above treatments.
- Silver nitrate 0.5% solution (do not use silver nitrate solid applicators as they can result in a corneal burn) on a cotton bud applied to the superior bulbar and palpebral conjunctiva.

### Toxic keratoconjunctivitis

#### Pathophysiology

This develops in response to a variety of topical or systemic medications. Toxic conjunctivitis is more commonly papillary but can also be follicular or cicatrizing in morphology.

Commonly implicated medications include aminoglycoside antibiotics (gentamycin, tobramycin), fortified antibiotics, and antifungals, antivirals, topical anaesthetics (see below), anti-glaucoma agents (pilocarpine, apraclonidine, brimonidine, dorzolamide), and preservatives (especially benzalkonium chloride and thiomersol).

#### Clinical evaluation

- Toxic papillary keratoconjunctivitis normally takes two or more weeks to develop and causes punctate staining of inferonasal conjunctiva and cornea (where medications gravitate with tear flow). There is redness, papillary reaction, and mucoid discharge.
- Toxic follicular conjunctivitis usually takes several weeks to develop in response to topical medications, eye make-up, or environmental pollutants. Follicles are most prominent in the

inferior fornix and on the inferior palpebral conjunctiva. There is normally mild conjunctival hyperaemia and punctate staining.

#### Treatment

This includes withdrawal of the medications, substitution with preservative free formulations and use of preservative free artificial tears.

Patients can also become allergic to topical medications and mount a hypersensitivity response (chloramphenicol, neomycin).

### Topical anaesthetic abuse

Chronic use of topical anaesthetic following an eye injury/erosion can lead to punctate keratitis, neurotrophic ulcers, corneal melt, and increase the risk of infection. Prophylactic topical antibiotics and occasionally oral analgesia is useful to break the pain cycle. Topical anaesthetic agents should not be prescribed as a form of analgesia for chronic ocular surface disease as their use can retard epithelial healing, and mask deterioration of disease.

### Mucus fishing syndrome

This results from a cycle of mechanical irritation from repeated attempts to remove mucus from the fornix in patients with chronic conjunctivitis (e.g. keratoconjunctivitis sicca, blepharitis, allergic conjunctivitis). Rubbing causes mechanical damage to the conjunctival epithelium which makes the condition worse.

The patients should be made aware of the problem and advised not to rub the eye. Treatment is with topical acetylcysteine and lubricants as well as any further treatment necessary for the underlying condition.

### Factitious keratoconjunctivitis

This includes self-inflicted physical or chemical harm in order for the patient to gain attention, avoid work, or seek financial gain (malingering). Self-induced harm can be in the form of medication, chemical abuse, or physical harm (lacerations, injection of air/chemicals into the cornea, anterior chamber, or lids).

Factitious keratoconjunctivitis can be difficult to diagnose and treat. It should be suspected if there is unexplained poor ocular surface healing or recurrent epithelial breakdown. It is usually present in the inferior or nasal quadrants. Twenty-four hour observations may be necessary to allow healing to occur. Psychiatric referral should be considered.

### Parinaud's oculoglandular syndrome

#### Pathophysiology

This is a rare unilateral nodular/ulcerative conjunctivitis with adjacent submandibular or pre-auricular lymphadenopathy. It occurs most frequently due to cat scratch disease (Bartonella) and tularemia. There are a variety of other infectious causes, such as sporotrichosis, tuberculosis, and syphilis.

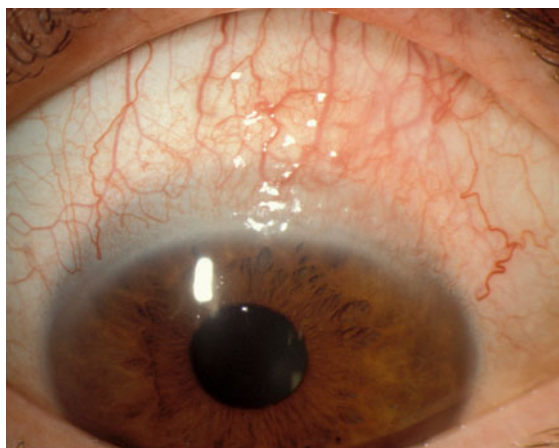
#### Clinical evaluation

- The disease has a self-limiting course over weeks to months.
- Presentation is with unilateral conjunctivitis and mild fever and/or rash.
- Conjunctival granulomas (red/whitish yellow nodules, 3–4 mm in diameter) appear together with adjacent lymphadenopathy.

#### Treatment

This should be directed at the underlying cause.

Bartonella is sensitive to oral doxycycline, ciprofloxacin, and co-trimoxazole.



**Fig. 1.27** Superior limbic keratoconjunctivitis.

## 1.11 Cicatrizing conjunctival disease

Cicatrization literally means scarring. There are a variety of conditions that can cause conjunctival scarring.

- **Infection:** severe infection with trachoma, adenovirus, or streptococcal conjunctivitis.
- **Trauma:** chemical or thermal injury.
- **Iatrogenic:** radiotherapy or ocular surface surgery, rarely following chronic topical medications (pilocarpine, adrenaline), or graft-versus-host disease (GVHD).
- **Blepharokeratoconjunctivitis:** severe chronic rosacea or AKC.
- **Autoimmune:** OCP or Stevens–Johnson syndrome.
- **Neoplasm:** conjunctival neoplasia/carcinoma or sebaceous gland carcinoma.

This section will focus on OCP, Stevens–Johnson syndrome, and GVHD. The other causes of cicatrizing conjunctivitis are covered in other sections.

### Ocular cicatrical pemphigoid

Mucus membrane pemphigoid is a systemic autoimmune disease characterized by chronic blistering and scarring of the skin and mucus membranes. If it affects the eye (40% of cases) it is termed ocular cicatrical pemphigoid (OCP). It is a slowly progressive, bilateral (can be asymmetric), and potentially blinding condition.

#### Pathophysiology

The exact pathophysiology of OCP is not understood. It is likely to occur due to cytotoxic (type II) hypersensitivity reaction with autoantibodies directed against antigens of the basement membrane complex. The conjunctival inflammation results in subepithelial scarring, destruction of conjunctival goblet cells, and obstruction of lacrimal ductules. This in turn causes mucus and aqueous tear deficiency and keratinization of the conjunctiva and corneal epithelium. OCP affects women twice as commonly as men and most patients are over 60 years. The mouth, oropharynx, genitalia, and anus can also be involved.

#### Clinical evaluation

##### History

The course of disease can be chronic and unremitting.

- Onset is with redness, foreign body sensation, watering, and photophobia. Misdiagnosis as blepharitis or allergic eye disease often delays appropriate treatment. Progressive disease results in decreased vision.
- There may be symptoms of systemic disease (e.g. dysphagia).

##### Examination

- The progression of disease can be categorized into four stages, as follows:
- **Stage I:** chronic conjunctivitis with subconjunctival fibrosis. Loss of the plica and flattening of the caruncle is an early sign.
- **Stage II:** cicatrization with shortening of the inferior fornix (depth <8mm).
- **Stage III:** symblepharon formation (adhesions between tarsal and bulbar conjunctiva).
- **Stage IV:** ankyloblepharon: dense adhesions to the lid margin, limiting eye movement (frozen globe). Severe keratopathy develops due to eyelid/lash malposition, aberrant eyelash growth and cicatricial entropion, dry eye, exposure and limbal stem cell deficiency. Persistent epithelial defects, ulceration, and neovascularization can occur.

##### Investigations

To support the clinical diagnosis, a conjunctival biopsy from an area of active inflammation should be examined for immunofluorescent

antibody labelling of immunoreactants (IgG, IgA) deposited in a linear pattern at the basement membrane zone.

#### Treatment

- Long-term systemic treatment is the mainstay.
- Dapsone is the front-line agent for mild to moderate inflammation (contraindicated in glucose-6-phosphate dehydrogenase (G6PD) deficiency). Alternatives to dapsone include mycophenolate, or azathioprine.
- For severe inflammation (conjunctival necrosis, limbitis) cyclophosphamide is used.
- High-dose systemic corticosteroid is very effective but only used for short periods of time for control of severe disease.
- Intravenous immunoglobulin therapy for refractory cases.

**Adjuvant therapy** to the above includes:

- treatment for dry eye (tear-film supplements, lubricants, punctal occlusion (if not already stenosed from scarring));
- topical steroids can be used for maintenance of mild disease or for acute exacerbations.

**Surgery** may be required in the following cases:

- for the treatment of eyelid/lash abnormality (see sections 2.2 and 2.3);
- penetrating keratoplasty has an extremely guarded prognosis if there is severe surface disease. A keratoprosthesis (artificial cornea) may be the only option to restore vision.

### Stevens–Johnson syndrome

This is a potentially fatal acute mucocutaneous disorder. The most severe manifestation of this disease is toxic epidermal necrolysis.

#### Pathophysiology

It is an immune-complex-mediated (type III) hypersensitivity reaction with immune-complex deposition in the skin and mucus membranes. The most common known aetiological factors include drug hypersensitivities (sulfonamides, penicillin, phenytoin), viral infections (herpes simplex, AIDS, influenza), or malignancies. The precipitating cause is not identified in up to half of cases.

#### Clinical evaluation

- Initial presentation is with a 1–14 day prodrome of upper-respiratory-tract symptoms.
- Mucocutaneous lesions develop abruptly. Skin lesions are classically erythematous maculopapules described as ‘target lesions’.
- The ocular acute phase lasts 2–3 weeks and consists most commonly of a transient self-limiting bilateral conjunctivitis.
- Occasionally there may be more severe conjunctival involvement with bullae, necrosis, and membrane formation. There may be secondary ocular surface infection.
- Long-term ocular surface scarring may occur depending on the severity of the disease. The features of OCP stages II–IV may all occur but these are usually non-progressive after the acute event.
- Ocular surface disease can lead to progressive corneal scarring and vascularization.

#### Management

- Diagnosis is clinical.
- The mainstay of treatment is supportive. The role of systemic immunosuppression for acute disease is disputed. This is best administered by an intensive care physician/dermatologist.



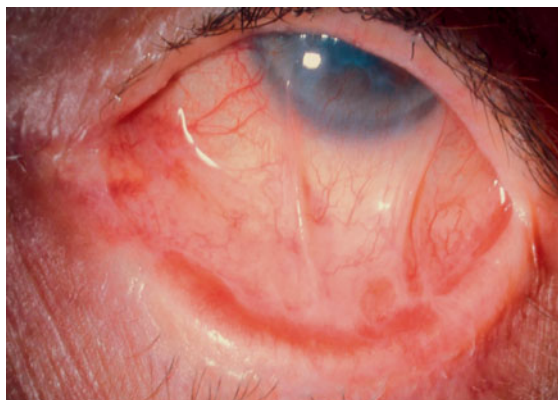- Ocular treatment involves intensive use of artificial tears and lubricants, prophylactic topical antibiotics, and possibly topical steroids. Any associated long-term dry eye, lash/lid abnormality are managed as for OCP.
- Systemic immunosuppression is only indicated if there are signs of recurrent conjunctival inflammation.

### Graft-versus-host disease

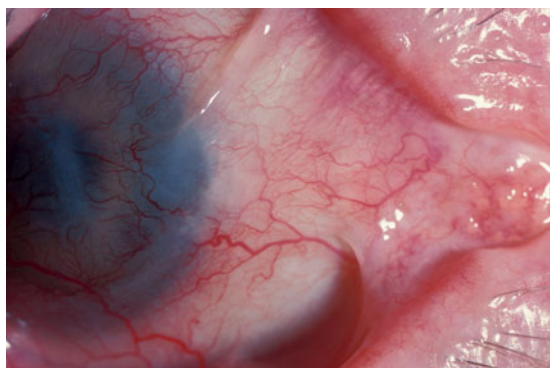This is a complication of allogeneic bone marrow transplantation. In this condition the grafted cells attack the patient's (host) tissues, including skin, gastrointestinal system, lungs, and eyes. Ocular complications tend to occur if the graft-versus-host disease (GVHD) becomes chronic. There are two main components:

- conjunctival inflammation possibly with cicatrization,
- severe dry eye from lacrimal gland failure.

Ocular treatment is as for dry eye disease.



**Fig. 1.28** Symblepharon formation in a case of OCP.



**Fig. 1.29** OCP: note the loss of normal conjunctival anatomy with effacement of the caruncle and loss of the plica. Note the corneal vascularization and opacification.

## 1.12 Conjunctival degeneration

All of these conditions are common and often asymptomatic findings.

### Pingueculum

#### Pathophysiology

This is a conjunctival degeneration in the exposed interpalpebral zone. The conjunctival stromal collagen undergoes elastoid degeneration and even calcification in response to prolonged exposure to ultraviolet light. The overlying conjunctival epithelium can be normal.

#### Clinical evaluation

- Pingueculae are located adjacent to the limbus more often on the nasal side. There is no corneal involvement.
- The appearance is of a subepithelial yellow-white nodule.
- Occasionally pingueculae become inflamed (pingueculitis) and irritated due to surface drying.

#### Management

- Artificial tears/lubricants for ocular surface irritation.
- Short course of weak topical steroids for pingueculitis.
- Excision is very rarely necessary for cosmesis or chronic inflammation/irritation.

### Pterygium

#### Pathophysiology

This is a triangular fibrovascular proliferation that grows from the conjunctiva on to the cornea. It arises most often from the nasal conjunctiva. There is subepithelial elastoid degeneration. The cornea shows destruction of Bowman's layer by fibrovascular ingrowth. The major aetiological factor is chronic exposure to ultraviolet light.

#### Clinical evaluation

##### History

- Cosmetic concern.
- Ocular irritation and redness if the pterygium has become inflamed.
- Reduced vision is rare and due to encroachment of the visual axis and induced astigmatism.

##### Examination

- They occur nasally or occasionally temporally.
- Localized decreased tear wetting.
- If actively inflamed there will be increased hyperaemia and breakdown of the overlying conjunctival epithelium (punctate stain with fluorescein).
- There may be iron deposition (Stocker's line) in the corneal epithelium in front of the advancing head of the pterygium.

##### Differential diagnosis

- Pseudopterygia occur following trauma, chronic conjunctival inflammation, or alkali injury. They can occur in any location around the limbus. Pseudopterygia are fixed only at the apex to the cornea whereas true pterygia are fixed to underlying structures throughout.
- Neoplastic causes: conjunctival intraepithelial neoplasia (CIN), carcinoma growing on to the cornea.

#### Management

- Patients should be reassured that visual loss from pterygium in temperate countries is uncommon.
- **Advise** on wearing sunglasses with good side protection to prevent further sun damage.
- **Topical** treatment is as for pingueculum.

- **Pterygium excision surgery** is usually requested for cosmesis. It is also indicated in the following circumstances: (1) chronic/recurrent redness and irritation, (2) blurred vision from induced astigmatism, and (3) progressive growth towards the visual axis. The technique for surgery is as follows:

1. The pterygium is dissected or avulsed from the cornea and the base removed down to bare sclera at the limbus.
2. Simple excision has an unacceptably high rate of recurrence. There are a variety of options to reduce this risk. The most commonly performed technique is conjunctival autografting. A free conjunctival graft normally from the superior bulbar conjunctiva (note: preferably not from this location in a patient with suspected glaucoma) is excised and sutured or glued in place to close the defect. The antiproliferative agent mitomycin C (0.02%) can be applied to the scleral defect.

Recurrence with this technique is approximately 5%. Recurrence can be complicated by more aggressively growing pterygia.

### Concretions

These are epithelial inclusion cysts filled with keratin debris. They occur in the elderly or following chronic conjunctivitis/blepharitis. They manifest clinically as multiple discrete white/yellow deposits in the palpebral conjunctiva. They are normally asymptomatic. If they erode through the overlying conjunctival epithelium they may cause a foreign body sensation. In symptomatic cases they can be removed under topical anaesthesia at the slit lamp with a 25gauge (G) needle.

### Inclusion cyst

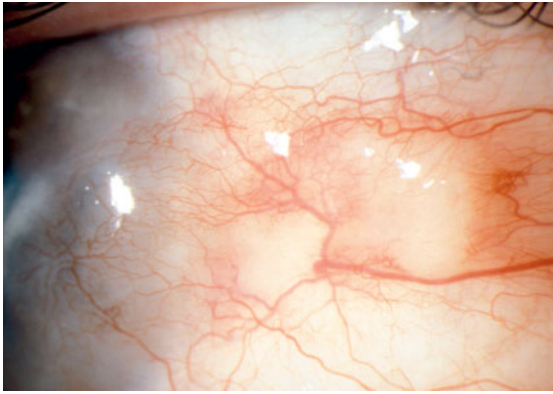
These are discrete, clear, fluid-filled cysts which if symptomatic (ocular surface irritation) should be surgically excised.

### Lymphangiectasia

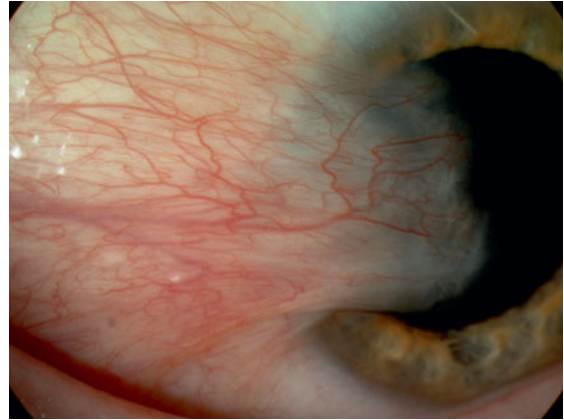These are local dilatations of thin-walled conjunctival lymphatic vessels. They appear as singly or multilobulated clear fluid-filled cysts.

### Conjunctivochalasis

This is a fold of redundant conjunctiva lying on the margin of the lower lid. It occurs with ageing or with chronic ocular surface inflammation. It can result in a foreign body sensation and there may be staining of the inferior cornea and conjunctiva with fluorescein. Treatment of associated blepharitis and the use of artificial tears and lubricants may result in remission. If these do not alleviate the problem then the redundant conjunctiva may be excised surgically.



**Fig. 1.30** Pingueculum with associated inflammation.



**Fig. 1.31** Large pterygium encroaching on to the centre of the cornea.



## 1.13 Conjunctival neoplasia I

These disorders can be classified according to the cell type that the lesion arises from and can then be subclassified into benign, premalignant, or malignant.

### Epithelial neoplasia

#### Conjunctival papilloma

This is a **benign** lesion. There are two forms, both caused by different strains of the human papilloma virus.

1. Sessile. These lesions normally found at the limbus are flat and shiny. Beneath the epithelium there are numerous dilated fronds of abnormal capillaries. Dysplastic change (more common with sessile than pedunculated lesions) can occur and is shown by symblepharon formation, inflammation, and invasion.
2. Pedunculated. These lesions, normally found in the inferior fornix, are fleshy multilobulated exophytic growths emanating from a stalk with a fibrovascular core.

#### Treatment

These lesions can regress spontaneously and can be observed closely if asymptomatic. If necessary complete surgical excision with adjunctive cryotherapy is the treatment of choice. If recurrent the options are repeat excision, interferon  $\alpha$ , topical mitomycin C, or oral cimetidine.

#### Conjunctival intraepithelial neoplasia (CIN)

This **pre-malignant** process occurs when there are dysplastic cells present that do not invade the underlying epithelial basement membrane. The process is graded histologically as mild, moderate, or severe depending on the extent of cellular atypia. When the full thickness of the epithelium is involved it is known as carcinoma *in situ*. Risk factors implicated include: light skin, chronic ultraviolet exposure, smoking, immunosuppression/HIV infection, human papilloma virus infection, and xeroderma pigmentosum.

#### Clinical evaluation

There are three clinical variants, all of which are slow-growing.

1. En plaque. This is the most common type. The appearance is of a raised, gelatinous, or leukoplakic (white) lesion with a 'stuck-on' appearance and tufts of superficial blood vessels.
2. Papilliform. Here the CIN arises from an existing dysplastic sessile papilloma.
3. Diffuse. This is the least common. The appearance is of indistinct, diffusely thickened conjunctiva.

All of these lesions are commonly associated with a granular, translucent epithelial sheet with fimbriated edges that extends on to the cornea. There is no corneal neovascularization associated with these lesions.

#### Treatment

- Surgical excision with a 1–2 mm margin of clinically uninvolved tissue. Rose bengal staining can be used to help delineate tumour margins.
- Adjunctive cryotherapy should be applied to the conjunctival margins in a double freeze–thaw technique at the time of surgery.
- If there is corneal involvement then the affected corneal epithelium should be removed with 100% alcohol.
- Recurrence is common especially with more advanced lesions.
- Topical: interferon  $\alpha$ , mitomycin C, or 5-fluorouracil can be used as adjuncts or alternatives to surgical treatment in select cases.

#### Squamous cell carcinoma

This **malignant** neoplasm results from a form of CIN that has either broken through the basement membrane to involve the subepithelial tissue or has metastasized. Morbidity is related primarily to local involvement of the conjunctiva and cornea. Regional spread and distant metastasis are a rare possibility. The risk factors are as for CIN.

#### Clinical evaluation

- Many patients are asymptomatic and are diagnosed incidentally on routine optician/ophthalmic examination.
- Possible symptoms include ocular surface irritation, a mass, or blurred vision if the central cornea is involved.
- The appearance may represent any of the forms of CIN described above.
- One feature particularly suggestive of malignancy is prominent conjunctival/episcleral feeder vessels.

#### Treatment

This is as for CIN. If malignancy is suspected wider surgical margins are advisable (3 mm) to prevent recurrence. An episclerectomy must be performed in these cases along with a superficial sclerectomy if there is tethering to underlying structures. Alcohol (100%) can be applied to the scleral base. In rare cases of globe or orbital invasion more radical surgery may be necessary.

### Lymphoma

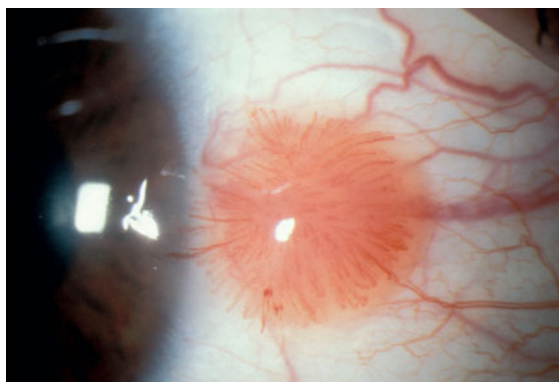The conjunctiva-associated lymphoid tissue can act as a reservoir or source of lymphoproliferative neoplasia that ranges histologically from lymphoid hyperplasia (formerly known as reactive hyperplasia) through to lymphoma. Conjunctival lymphomas represent a monoclonal proliferation predominantly of B-cells. Most conjunctival lymphomas are non-Hodgkin. Lymphomas may be limited to the conjunctiva or may be associated with systemic involvement.

#### Clinical evaluation

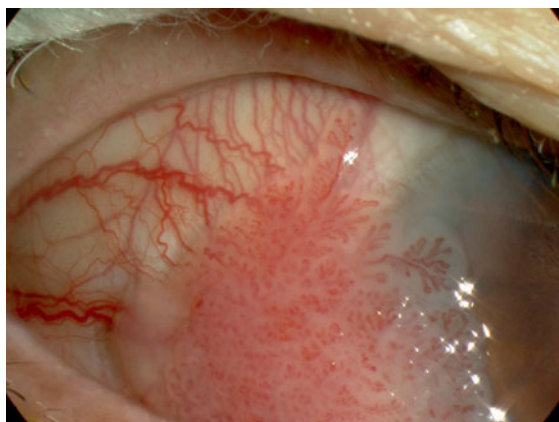
- Benign (lymphoid hyperplasia) and malignant lesions cannot be distinguished clinically.
- Affected patients are normally over 50 years of age or immunosuppressed.
- The classical presentation is a slow-growing salmon-coloured, diffuse, mobile, subepithelial mass with moderate vascularization.
- The lesions may be localized to the conjunctiva or may be associated with orbital involvement.

#### Treatment

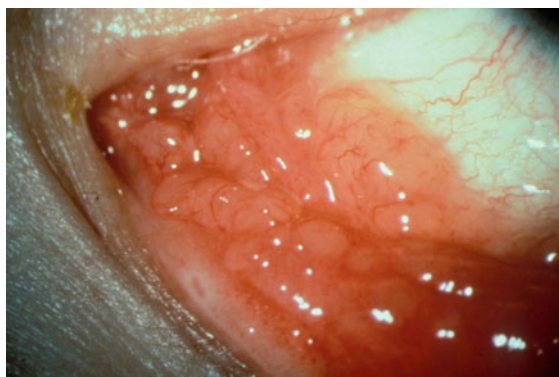
- Patients need to be referred to a haematologist for systemic investigation and staging.
- Incisional biopsy is necessary for histopathological diagnosis.
- Local radiotherapy is usually successful in treating lesions confined to the conjunctiva. Systemic chemotherapy may be required if there is systemic involvement.



(a)



(b)



(c)

**Fig. 1.32** (a) Sessile conjunctival papilloma. (b) En plaque CIN. Note the prominent episcleral feeder vessels. (c) Conjunctival lymphoma.

## 1.14 Conjunctival neoplasia II

### Melanocyte-associated neoplasia

#### Naevi

These are **benign** neoplasms that consist of an accumulation of melanocytes, naevus cells, and epithelial cells. They can be histologically classified into junctional, compound, or subepithelial. They arise during childhood and adolescence.

#### Clinical evaluation

They appear as solitary, variably pigmented, well-demarcated lesions. The most common location is at the limbus where they tend to be flat. In other conjunctival locations they are elevated. Increased pigmentation may occur at puberty together with rapid enlargement due to the development of epithelial down-growth cysts that are common in conjunctival melanocytic naevi.

#### Treatment

Malignant transformation is rare. Lesions can often be photographed and observed. Indications for surgical excision include lesions occurring on the palpebral conjunctiva (as naevi rarely occur here), other suspicion of malignancy (increase in size, change in pigmentation, vascularization), or for cosmesis.

#### Congenital epithelial melanosis

Also known as a conjunctival freckle. It is a **benign** lesion that appears within the first few years of life as a flat brown patch normally near the limbus.

#### Benign melanosis

This condition describes a bilateral diffuse increasing pigmentation of the conjunctiva that tends to occur in darkly pigmented, middle-aged individuals. It is characterized by light brown pigmentation of the perilimbal and interpalpebral bulbar conjunctiva. Streaks of pigmentation can extend into the peripheral corneal epithelium (striate melanokeratosis).

#### Ocular melanocytosis

This is a **benign** congenital pigmentation of the episclera that occurs most commonly in pigmented individuals. It occurs due to subepithelial proliferation of normal melanocytes.

#### Clinical evaluation

Patches of episcleral pigmentation have a slate gray appearance through the conjunctiva. Other ocular structures that may be affected by increased pigmentation include the iris and choroid. Approximately 50% of affected patients also have ipsilateral dermal melanocytosis (oculodermal melanocytosis also known as naevus of Ota; see section 2.7). Malignant transformation is rare but when it occurs usually takes place in the uveal tract. Very occasionally, primary orbital malignant melanoma arises in association with melanocytosis.

#### Primary acquired melanosis

This is a **premalignant**, predominantly unilateral condition that normally occurs in middle-aged, fair-skinned individuals. It arises due to a proliferation of abnormal melanocytes in the basal conjunctival epithelium. It is classified histologically depending on whether the cells exhibit atypia. If atypia are present there is a significantly greater chance of malignant transformation (to melanoma, see below).

#### Clinical evaluation

- Multiple flat brown non-cystic patches of pigmentation can occur on any area of the conjunctiva.
- Malignant transformation should be suspected when there is enlargement, fixation of the conjunctiva to deeper structures, nodularity, increased vascularization, and/or haemorrhage.

#### Treatment

- Discrete areas can be surgically excised with a similar technique to that used for CIN.
- More diffuse lesions that are too extensive to permit surgical excision can be treated with cryotherapy or topical mitomycin C application.

#### Melanoma

This rare, potentially fatal **malignant** neoplasm can arise *de novo* (approximately 10% of cases), from a pre-existing naevus (approximately 20% of cases), or from primary acquired melanosis with atypia (60–70% of cases). It typically occurs in fair-skinned individuals in their 50s.

#### Clinical evaluation

- Presentation is variable depending on the presence of pre-existing lesions and the extent, nature, and location of the tumour. They can occur in any part of the conjunctiva. The most common location is the bulbar conjunctiva, at the interpalpebral limbus.
- Typical presentation is a solitary, dark nodule, fixed to episclera and with dilated feeder vessels.
- Lesions can be amelanotic with a pink, fleshy appearance.

#### Treatment

- The primary treatment is surgical resection as for squamous cell carcinoma of the conjunctiva.
- Extensive lesions that are invading the orbit or globe may require exenteration, although this does not improve survival.
- Topical mitomycin C may have a role as an adjunct to surgery.

#### Prognosis

- Mortality is approximately 15% at 10 years.
- Poor prognostic factors include tumours not involving the limbus, multifocal lesions that arise *de novo*, residual involvement at the surgical margins, and lymphatic or orbital spread.

### Epibulbar choristomas

These are **benign** congenital lesions that occur when normal tissue grows in an abnormal location during embryogenesis.

#### Epibulbar dermoid

This results from displaced embryonic tissue that was otherwise destined to have become skin tissue. It is composed of fibrous tissue and can also contain hair follicles or sebaceous glands. It is embedded in the superficial sclera and/or cornea.

#### Clinical evaluation

- Typical presentation is in infancy/early childhood with a smooth, well-demarcated, white- to yellow-coloured lesion that is fixed to deeper structures.
- They normally occur beneath the conjunctiva at the inferotemporal limbus. They can also be found on the cornea or in the orbit.

- They can interfere with normal lid function, obscure the visual axis, or cause astigmatism and subsequent amblyopia.

They can be associated with Goldenhar syndrome (oculoauriculovertebral dysplasia). This is a congenital disorder of the first branchial arch. Other features include coloboma of the upper lid, pre-auricular skin tags, and vertebral anomalies.

#### Treatment

- This is indicated for obstruction of the visual axis, ocular surface irritation, astigmatism, or cosmesis.
- The elevated portion of a dermoid can be excised but there is often deep extension into underlying tissues preventing

complete removal. Lamellar keratoplasty may be necessary if there is significant corneal involvement.

### Dermolipoma (lipodermoid)

These lesions contain significant adipose (fat) tissue as well as other skin elements. They are normally found at the outer canthus where they have a gelatinous appearance. There is classically an indistinct posterior border with the lesion extending into the orbit. There is a well-demarcated anterior border several millimetres behind the limbus. These lesions tend to be more extensive than simple epibulbar dermoids. It is important to distinguish these lesions from prolapsed orbital fat which has a very similar clinical appearance. Prolapsed orbital fat, unlike dermolipoma, can be moved freely over the sclera beneath. Treatment is as for epibulbar dermoid.

## Vascular lesions

### Kaposi sarcoma

This condition is also described in section 2.9. It is a **malignant** neoplasm of vascular endothelium which can affect the skin and mucous membranes. It occurs following infection with the human herpes virus 8. In young patients it often occurs with AIDS.

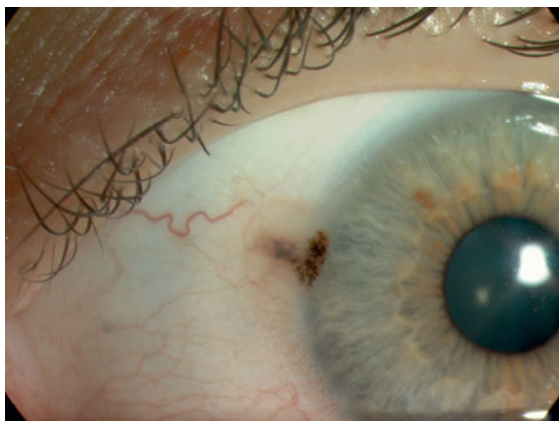


Fig. 1.33 Conjunctival naevus.

When present on the conjunctiva the appearance is of a bright red, highly vascular subconjunctival lesion that may simulate a chronic subconjunctival haemorrhage. It most commonly presents in the inferior fornix. Options for treatment include surgical debulking, cryotherapy, and radiotherapy.

### Pyogenic granuloma

This is an inflammatory vascular proliferation. It is a misnomer because it is not suppurative nor does it contain giant cells. The lesion may occur over a chalazion or when minor trauma or surgery simulates an excessive healing reaction. It is a rapidly growing lesion that is red, smooth, and pedunculated. Treatment is with topical steroids alone or surgical excision combined with topical steroids.

## Metastatic tumours

Secondary metastatic deposits in the conjunctiva from primary tumours elsewhere such as the breast, lung, and kidney do occur very rarely. Treatment is palliative.

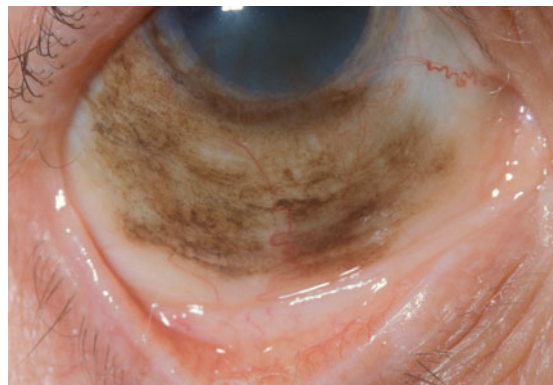

Fig. 1.35 Primary acquired melanosis.

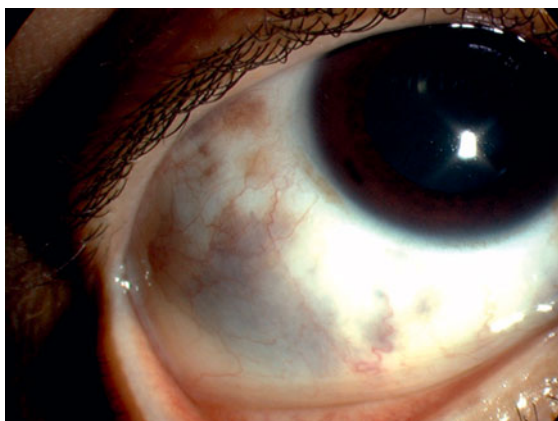


Fig. 1.34 Ocular melanocytosis.

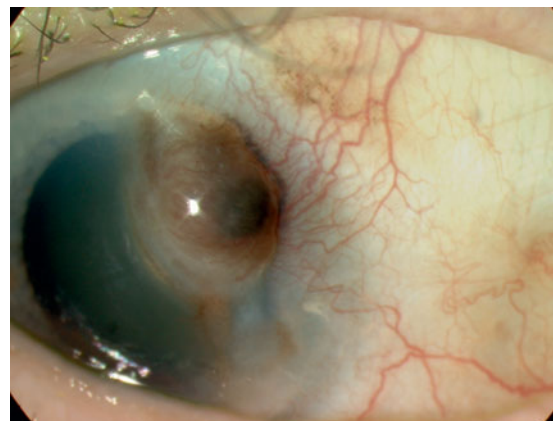

Fig. 1.36 Invasive melanoma occurring in an area of primary acquired melanosis.



## 1.15 Corneal degeneration

These are usually bilateral (often asymmetrical), corneal changes. They occur more commonly with increasing age. They can be categorized as follows:

- primary age-related: arcus senilis, shagreen, white limbal girdle and corneal farinata;
- inflammation-related: band keratopathy, lipid keratopathy, and Salzmann nodular degeneration;
- ultraviolet radiation-related: climatic keratopathy.

### Arcus senilis

#### Pathophysiology

This is an extremely common age-related condition that occurs due to the deposition of lipid in the peripheral corneal stroma. It affects nearly everyone over the age of 80 years. It is not usually associated with any underlying systemic disorder. However, arcus in young patients is occasionally secondary to hyperlipoproteinaemia. Unilateral arcus is rare and is associated with ocular hypotony or carotid artery disease.

#### Clinical evaluation

- This is first seen at the superior and inferior corneal periphery and progresses to encircle the entire corneal circumference.
- The arcus has a hazy white appearance with a sharp peripheral border and an indistinct central border.
- There is a clear corneal zone between the arcus and the limbus which may show mild thinning (furrow).

#### Management

This condition has no effect on the vision and no treatment is required. Young patients (<40 years) with a family history of cardiovascular disease should have a serum lipid profile performed.

### Corneal shagreen

This is characterized by bilateral, polygonal, greyish-white, stromal opacities separated by clear zones. They are usually centrally located and asymptomatic. These lesions can be located in the anterior (anterior form) or the posterior (posterior form) stroma. No treatment is required.

### White limbal girdle (of Vogt)

This is a crescent-shaped white chalky band that occurs along the nasal or temporal limbus in the interpalpebral fissure. No treatment is required.

### Corneal farinata

This is characterized by tiny, bilateral, asymptomatic deposits like grains of flour in the posterior stroma. The lesions are more prominent centrally and are best seen using oblique diffuse illumination.

### Band keratopathy

#### Pathophysiology

This is a common condition that occurs due to precipitation of calcium salts from the tear film into the Bowman's layer. It is often idiopathic, occurring more commonly with increasing age. It has a number of known causes:

- ocular: chronic anterior uveitis (especially in children), phthisis bulbi, intraocular silicone oil, and alkali injury;
- systemic: hypercalcaemia, hyperphosphataemia and hyperuricaemia (urate salts deposited);
- hereditary.

#### Clinical evaluation

- The first appearance is of peripheral white granular superficial deposition nasally and/or temporally with a clear zone separating the peripheral edge of the lesion from the limbus. There are often clear holes within the deposition.
- Eventually the deposits can coalesce to form a horizontal band-shaped plaque across the entire cornea. If the optical zone of the cornea is affected patients may complain of glare or reduced vision.
- When the band is long-standing there may be flakes of calcium that break through the overlying epithelium and result in discomfort and foreign body sensation.

#### Investigations

Investigate for systemic disease (serum calcium, phosphate, and renal function) if there is no identifiable ocular cause.

#### Treatment

- Ocular treatment is only indicated if the patient is symptomatic.
- For mild symptoms of discomfort, use ocular lubricants.
- If the above measures are not effective then the band can be removed using the following techniques:
- dilute a solution of 15% EDTA to create a 3% mixture;
- anaesthetise the eye with topical anaesthesia;
- debride the corneal epithelium with a scalpel;
- wipe a cellulose sponge saturated with EDTA over the band until the cornea clears (may require 20–30 minutes).
- Phototherapeutic keratectomy (PTK) is quick and effective if the surface is regular. Ablating an irregular surface will tend to leave irregular astigmatism.
- Systemic treatment (by the general physician) is indicated if systemic disease not previously identified. This may delay recurrence after treatment.

### Lipid keratopathy

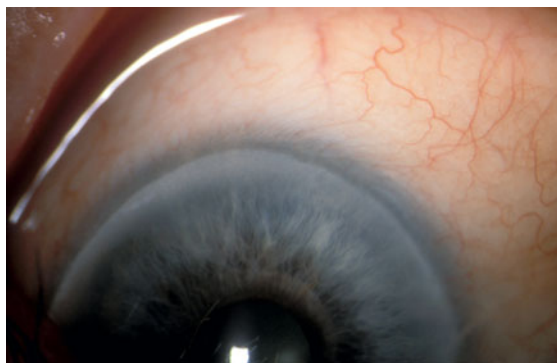
This occurs due to lipid deposition in the stroma. It normally occurs in a pre-existing vascularized scar such as those seen following herpetic keratitis or other causes of interstitial keratitis (e.g. syphilis). The blood vessels are incompetent and leak lipid. The clinical appearance is of a yellow/cream-coloured deposit within the corneal stroma. Treatment should be aimed at any underlying inflammatory process to prevent progression of disease. Occlusion of feeder vessels by argon laser photocoagulation or cautery can sometimes limit progression or help regression. Penetrating or lamellar keratoplasty can be considered for visually significant opacity.

### Climatic keratopathy

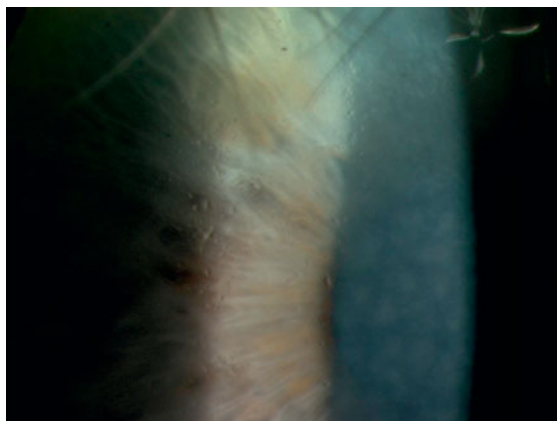
This is a bilateral condition caused by prolonged exposure to environmental ultraviolet light. Patients also often have pterygium. It is characterized by the presence of numerous yellow-golden spheres in the anterior interpalpebral stroma. It is usually asymptomatic but can cause discomfort due to surface irregularity or it can reduce vision (if it progresses into a band across the pupil). Treatment options include wearing of sunglasses with good side protection, lubricants, or lamellar keratoplasty.

## Salzmann nodular degeneration

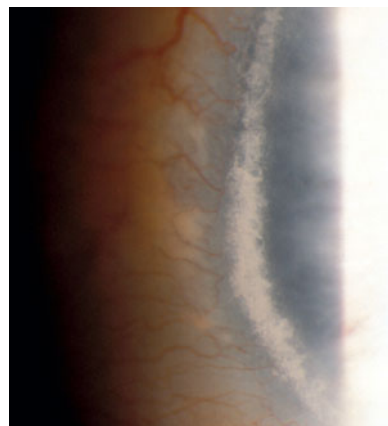This condition occurs due to localized degeneration at the level of Bowman's layer with hyaline and fibrillar material. It can be idiopathic or occur as a late sequel of chronic keratitis (VKC, trachoma). The clinical appearance is classically that of discrete, elevated, grey-white, subepithelial nodules in the paracentral cornea or at the edge of a corneal scar. Treatment for ocular surface discomfort is with lubricants. If vision is affected then superficial keratectomy or lamellar keratoplasty may be required.



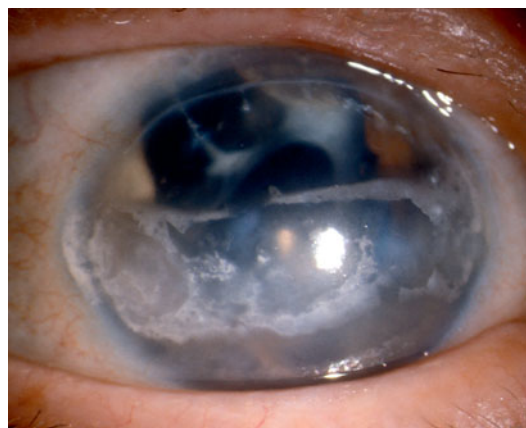**Fig. 1.37** Arcus senilis seen at the superior corneal limbus.



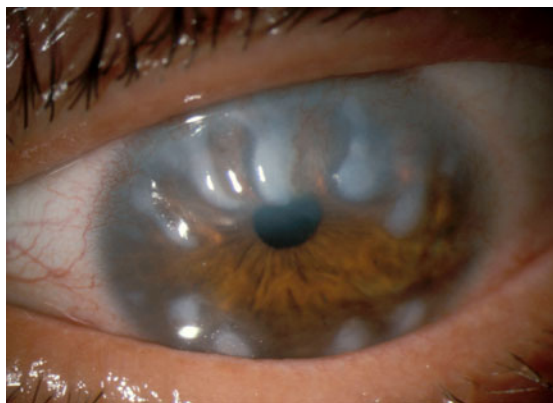**Fig. 1.38** Corneal shagreen seen in the area of diffuse illumination.



**Fig. 1.39** White limbal girdle of Vogt.



**Fig. 1.40** Band keratopathy.



**Fig. 1.41** Salzmann nodular degeneration.

## 1.16 Infectious keratitis I: bacterial

Infectious keratitis is an umbrella term for all cases of keratitis caused by infection (microbial keratitis applies to corneal infections caused by bacteria, fungi, and protozoa but not viruses). There are a wide variety of potential pathogens and host responses involved in this sight-threatening disease. Polymicrobial infections can occur but for the sake of simplicity the major groups of causative organisms will be covered here in turn.

### Bacterial keratitis

This is the most common cause of infectious keratitis. There can be rapid onset and disease progression. Corneal destruction may be complete in less than 24 hours with the most virulent of bacteria.

#### Pathophysiology

Disruption of the corneal epithelial barrier to infection permits entrance of bacteria into the corneal stroma, where they may proliferate. Invading bacteria secrete proteases and neutrophils that migrate into the cornea from the limbal vasculature and tear film. The subsequent release of matrix metalloproteinases breaks down the extracellular matrix, causing inflammatory necrosis. Progressive inflammation may result in corneal perforation and secondary endophthalmitis. When bacterial replication is controlled, wound-healing processes begin, but these may be accompanied by corneal neovascularization and scarring. Bacterial keratitis is rare in the absence of predisposing risk factors such as contact lens wear (especially overnight wear), trauma (including foreign bodies), immunosuppression, corneal surgery, dry eye or other causes of ocular surface disease (herpetic/exposure/neurotrophic/bullous keratopathy). Common causative organisms include *Pseudomonas aeruginosa* (the most common organism in soft contact lens wearers), *Staph. aureus*/*Staph. epidermidis*, *Streptococcus* species, and enterobacteriaceae (*Proteus*, *Enterobacter*, and *Serratia*).

#### Clinical evaluation

##### History

- Typical presentation is with increasing foreign body sensation, pain, photophobia, and reduced vision.

##### Examination

- The typical presentation is with a sharply demarcated epithelial defect (termed ulcer if there is associated stromal tissue loss) and an underlying focal dense white stromal infiltrate consisting of neutrophils and bacteria (stromal abscess) with surrounding stromal oedema.
- Other signs that may be present include intense conjunctival injection, eyelid oedema, an endothelial inflammatory plaque, anterior chamber reaction, hypopyon (normally sterile in the absence of perforation), and corneal thinning.
- Patients who are immunocompromised (including those taking topical steroid medication) presenting with a stromal melt should be suspected of having infectious keratitis until proven otherwise. These patients do not necessarily mount the inflammatory response that is needed to produce the classical signs listed above.
- **Infectious crystalline keratopathy:** this is a specific and rare form of corneal stromal infection. It is typically caused by slow growing beta-haemolytic streptococci (*Streptococcus viridans* species), but it may also be caused by mycobacterium and other organisms. It classically occurs in patients who have undergone corneal graft surgery and who have been on long-term topical steroid treatment, which suppresses the usual response to infection. It presents as densely packed, white, branching aggregates of organisms with an almost complete absence of an inflammatory response.

#### Differential diagnosis

- Other causes of infectious keratitis (fungal, viral, protozoal).
- Sterile keratitis (contact lens-related, marginal keratitis).

#### Investigations

- Corneal cultures should be taken in all cases to provide material for microbiological diagnosis. This may help to remove necrotic tissue and enhance antibiotic penetration.
- Baseline indices of disease such as size of epithelial defect, extent of thinning, and infiltrate size should be recorded.

The technique for corneal scraping is as follows:

- Instil non-preserved topical anaesthetic.
- use several green needles (21G), or no. 15 blades;
- scrape at the edge and the base of the ulcer (avoid the base if there is significant thinning);
- spread material directly on to the culture medium (avoid breaking the surface) as several 'C' shapes;
- use the following culture media: (1) blood agar (most aerobic bacteria, and fungi, will grow on this medium), (2) liquid broths (e.g. thioglycolate broth and cooked meat) will preserve anaerobes, and (3) glass slide for Gram stain.
- Other samples are only necessary if specific organisms are suspected or if initial cultures have been negative: chocolate agar (*Haemophilus*, *Neisseria* species) or Löwenstein–Jensen medium (mycobacteria). Samples for acanthamoeba or fungi will be discussed in the subsequent text.
- Send contact lens and case (if available) for culture.

#### Treatment

The aims are to sterilize the wound and promote healing.

##### Sterilization phase

- Commence intensive broad-spectrum antibiotics. This can be monotherapy with g. levofloxacin 0.5% hourly day and night for 2 days then reducing as signs permit over the next 7 days. Alternatively a fortified cephalosporin (e.g. cefuroxime 5%) and an aminoglycoside (e.g. gentamicin 1.4%) will cover most Gram-positive and Gram-negative pathogens.
- Topical cycloplegic drops for comfort.
- Consider systemic antibiotics (e.g. ciprofloxacin 750 mg BD or moxifloxacin 400 mg once daily (OD)) if there is an actual or threatened perforation to reduce the risk of endophthalmitis.
- Consider admission for intensive treatment if there is concern with compliance or in complicated cases (only eye, etc).
- Re-assess in 48 hours to detect rapidly progressive cases and assess initial culture results. Features suggestive of a positive response to antibiotic treatment include reduction in pain, sharper margins/decreased intensity of the infiltrate, and decreased inflammatory signs. Antibiotic treatment should be re-assessed if there is rapid clinical progression or an organism that is insensitive to the treatment.
- Review as required (e.g. 1 week) to confirm that recovery is progressing. If there is failure to improve, reculture should be considered and specific antibiotic therapy started if resistant organisms isolated. If progression continues and cultures are negative consider a corneal biopsy for culture and histology.

##### Healing phase

The second aim of treatment is to promote healing and re-epithelialization of the ulcer using the following measures.

- Reduction of inflammation: cautious addition of topical steroids, for example prednisolone 0.5% QDS, once it has been confirmed

that the infection is sensitive to the antibiotics (steroid may potentiate herpetic or fungal infection).

- Prevention of drop toxicity: reduce the frequency of aminoglycoside treatment to QDS within 48 hours.
- Treatment of associated ocular surface disease.

### Complications

- Threatened/actual perforation: should be referred urgently to a corneal specialist. Corneal glue may seal a small corneal perforation (see Corneal glue in the practical skills section, below), allowing time for the infection to be controlled and potentially avoiding the need for surgery. Emergency keratoplasty may be necessary but in the presence of active infection the prognosis for graft survival is poor and it should be avoided if possible.
- Endophthalmitis: bacteria, unlike fungi, do not penetrate an intact Descemet's membrane and do not cause endophthalmitis unless there is a concurrent perforation.
- Irregular astigmatism: from stromal loss during infection.
- Scar formation: If the scar results in a significant effect on vision then surgical options such as lamellar or penetrating keratoplasty may need to be considered.

## ✚ Corneal glue

### Background/indication

- Applied to restore the integrity of the globe in corneal perforations up to 1 mm in diameter.
- To avoid or delay more definitive surgery (e.g. keratoplasty) and to gain time while other treatments such as antibiotics and/or immunosuppression take effect.
- Tissue adhesives (e.g. dermabond, Histacryl) are long-chain derivatives of cyanoacrylate. Commercial 'super glue' (methyl cyanoacrylate) is toxic and should not be used.

### Technique

- Apply at a slit lamp or supine under the operating microscope.
- Instil topical anaesthetic. Debride the epithelium over the area to which the glue is to be applied. Dry the area with a cellulose sponge and apply the glue immediately.
- The application technique depends on the size of the perforation. For microperforations (<0.25 mm) the glue can be applied directly with the tip of a 30G needle.
- For larger perforations a patch technique is required. A small disc of polythene from the non-adhesive portion of a sterile surgical drape is cut out with a 3–4 mm skin biopsy trephine (the disc must be large enough to cover the perforation with a 1 mm surround). The patch is placed on top of the wooden end of cotton tipped applicator that has been dipped in K-Y gel (to prevent the patch sticking to the applicator). A very thin layer of glue is applied to the exposed surface of the patch with a 30G needle. The applicator is then used to firmly press the patch on to the cornea. Pressure is maintained until the glue can be seen to 'set.'
- Minimal iris adhesions at the site of perforation can usually be left as they will break when the anterior chamber reforms. If the adhesions are extensive, they may need to be repositioned in theatre.
- Place a bandage contact lens on the cornea for comfort.
- The glue can normally be left *in situ* until it spontaneously detaches as the cornea heals.

## Further reading

Allan BD, Dart JK. 1995. Strategies for the management of microbial keratitis. *Br. J. Ophthalmol.* **79**(8): 777–786.

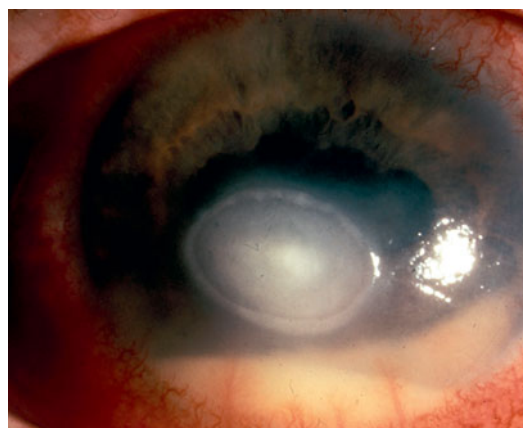

Fig. 1.42 Bacterial keratitis. Note the associated hypopyon.

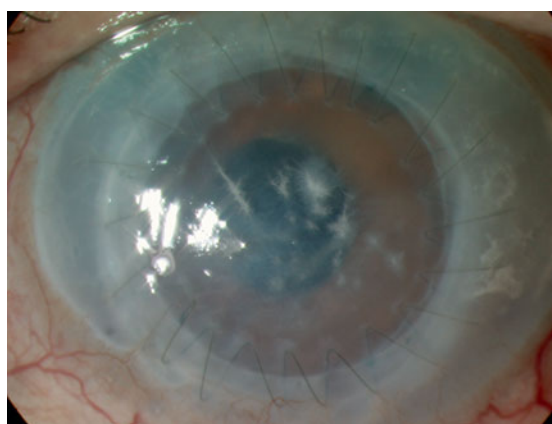


Fig. 1.43 Infectious crystalline keratopathy.

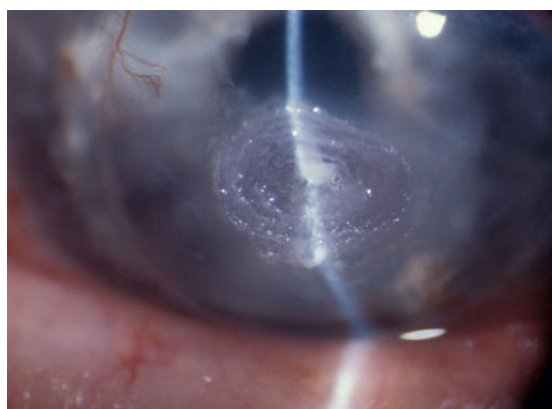


Fig. 1.44 Patch of corneal glue *in situ*.



## 1.17 Infectious keratitis II: protozoal/fungal

### **Acanthamoeba keratitis**

#### **Pathophysiology**

This is a sight-threatening infection caused by a free-living amoeba (a protozoan) found in tap water, swimming pools, fresh water, and soil. *Acanthamoeba* exists in two forms: (1) active trophozoites and (2) dormant cysts. Trophozoites produce enzymes that aid tissue penetration and destruction. Cysts are extremely resilient and are able to survive in unfavourable conditions such as extremes of temperature and chlorine. The major risk factor for developing this infection is contact lens wear, which is implicated in 70–80% of cases in developed countries. Exposure to contaminated water when wearing contact lenses (improper lens storage/disinfection, contaminated solutions, or swimming with lenses) makes individuals particularly susceptible.

#### **Clinical evaluation**

##### **History**

- Gradual increase in discomfort over a course of weeks. Cases are frequently misdiagnosed initially, particularly as herpes keratitis, which delays appropriate treatment.
- Severe pain in some patients (disproportionate to clinical signs), redness, and photophobia.

##### **Examination**

- In early cases the disease is localized to the epithelium with heaped epithelial irregularity, punctate epithelial erosions or irregular-shaped epithelial defects similar to a dendritic ulcer (see HSK below). Corneal sensation may be reduced. Infiltrates around the corneal nerves (radial keratoneuritis) may occur and is pathognomonic.
- Stromal infection normally occurs centrally. Early cases present with grey-white diffuse stromal infiltrate with an overlying epithelial defect. This can progress to an abscess with stromal melting. In advanced cases this area may become surrounded by a characteristic dense ring infiltrate.
- Other possible clinical manifestations that may accompany the above signs include limbitis, diffuse/nodular scleritis, anterior uveitis, and hypopyon.

Note: patients with suspected dendritic or disciform keratitis (see herpes simplex virus (HSV) keratitis) who have recently worn contact lenses should also always be investigated for *Acanthamoeba* infection.

##### **Investigations**

- In early cases the epithelium should be debrided for investigation. Samples of stroma should be taken if there is an abscess. Send contact lenses and solutions if available.
  1. Culture on non-nutrient agar with killed *Escherichia coli* overlay.
  2. Microscopy (Gram/Giemsa/calcofluor white stains).
- Consider performing a corneal biopsy if initial cultures are negative. Send half of any epithelial or stromal biopsy in saline for culture and half in formalin for histopathology.
- *In vivo* confocal microscopy can detect cysts and trophozoites and can be very useful if available.

##### **Treatment**

Early diagnosis and treatment is the most important prognostic indicator for a successful outcome. Cysts are relatively resistant to treatment and clinical signs of infection can re-occur due to reactivation (prolonged treatment for many months is often needed). There are a variety of treatment options. The mainstay of treatment involves hourly application of antiseptics polyhexamethylene biguanide 0.02% or chlorhexidine 0.02% with propamidine isethionate

0.1% (Brolene) or hexamidine initially, followed by a maintenance dose of lower frequency.

Topical steroid should only be used if there is uncontrolled inflammation, stromal melting, or vascularization. However, steroid use may contribute to persistence of viable cysts.

Oral non-steroidal anti-inflammatory drug (NSAID) may help control discomfort.

Keratoplasty is indicated for impending perforation or for significant central corneal scarring once infection has been eradicated.

### **Fungal keratitis**

This is rare in temperate countries, and chronic and difficult to treat. The fungus gains entry through an epithelial defect. The most common pathogens are filamentous fungi (*Fusarium* and *Aspergillus* species) or yeast (*Candida albicans*). Risk factors include agricultural trauma (especially in the tropics), contact lens wear, topical steroid use, immunosuppression, diabetes, chronic keratitis, or eye surgery.

#### **Clinical evaluation**

- Inflammatory manifestations of fungal keratitis are milder in the initial period than those of bacterial keratitis but may progress to signs of intense inflammation. There may be foreign body sensation, watering, pain, photophobia, and a visible dense corneal opacity.
- **Filamentous fungal keratitis** presents as a grey-white infiltrate with irregular feathery margins. The stroma may have a dry, rough texture before melting begins. Additional manifestations include multifocal/satellite lesions, deep stromal infiltrate in the presence of an intact epithelium, endothelial plaque, and/or hypopyon. As the keratitis progresses it becomes clinically indistinguishable from bacterial keratitis. It has the capacity to penetrate Descemet's membrane and enter the anterior chamber to cause endophthalmitis.
- **Yeast keratitis** presents with white infiltrates similar to bacterial keratitis in appearance. Patients often have a history of chronic ocular surface disease treated with topical steroid.

##### **Investigations**

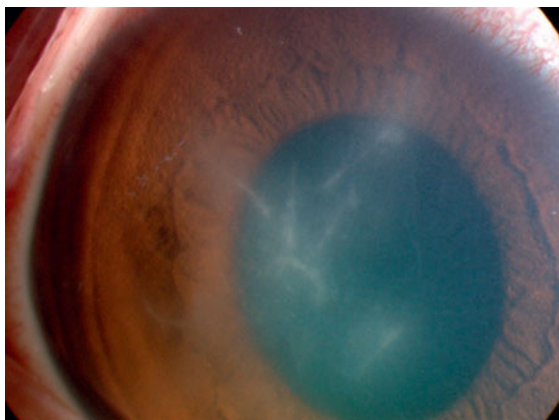
Samples are collected as for bacterial keratitis and should be sent for:

1. stain: fungal cell walls stain with Gomori methenamine silver. Gram stain highlights *Candida* but not filamentary fungal species;
2. culture: blood agar, Sabouraud's agar, and brain-heart infusion media.

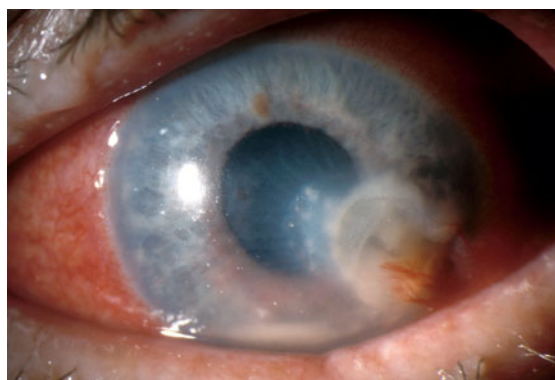Consider corneal biopsy for histology and culture.

##### **Treatment**

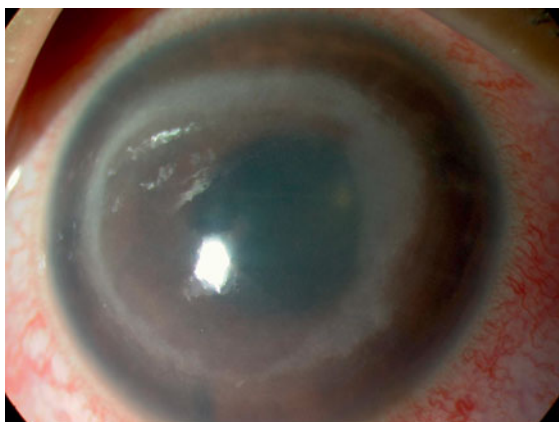
- Superficial corneal debridement is useful to remove the epithelium and aid the penetration of antifungal drugs as well as removing some of the causative organisms.
- Topical therapy is started every hour and tapered slowly over 6–8 weeks. If the patient is already taking a topical steroid then this should be stopped if possible. The following topical therapies are indicated:
  - amphotericin B 0.15% or econazole 1%.
- Severe disease may require adjunctive systemic therapy:
  - oral voriconazole.
- Advice from a microbiologist should be sought once the isolate has been identified.
- A penetrating keratoplasty to excise infected tissue may be required in cases that continue to progress despite maximal medical therapy.



**Fig. 1.45** *Acanthamoeba* keratitis: radial keratoneuritis.



**Fig. 1.47** Fungal keratitis secondary to *Aspergillus*. Note the satellite lesions.



**Fig. 1.46** *Acanthamoeba* keratitis: ring infiltrate.

## 1.18 Infectious keratitis III: viral; herpes simplex

### Pathophysiology

Herpes simplex virus (HSV) is a double-stranded DNA virus. Ocular disease is caused by HSV1, which causes oro-facial (and rarely genital) disease. HSV2 causes genital (rarely oro-facial and ocular) disease.

Primary infection with HSV1 generally occurs in childhood through skin and mucus membrane contact with oral lesions and secretions. Primary infection is normally with a non-specific upper-respiratory-tract infection but can result in oro-facial, ocular (blepharconjunctivitis, rarely keratitis), or rarely systemic (encephalitis, meningitis, myelitis, hepatitis) manifestations. The virus then ascends via sensory nerve axons to establish latent (dormant) infection in the corresponding ganglia (trigeminal ganglion for oro-facial/ocular exposure). Viral reactivation can later occur whereby the virus travels along the nerve axon to the sensory nerve endings and then to the epithelium where it replicates. Various factors including sunlight, trauma, surgery, heat, menstruation, infectious diseases, and emotional stress have all been implicated as potential triggers for reactivation.

HSK can be classified according to the layer of the cornea that is predominantly affected: epithelial, stromal, or endothelial. Epithelial HSK occurs due to reactivation and replication of virus (and rarely as a manifestation of primary infection). The pathophysiology of stromal and endothelial HSK remains poorly understood but is believed to be immune-mediated.

### Epithelial keratitis

#### Clinical evaluation

##### History

- Presentation is with foreign body sensation, watering, redness, blurred vision, and/or photophobia.

##### Examination

- Corneal sensation may be reduced or absent.
- The earliest visible manifestations are areas of punctate epithelial keratitis that coalesce into one or more linear branching dendritic epithelial ulcers with terminal bulbs at the end of each branch.
- There is swollen heaped up epithelium around the edge of the ulcer, which stains with rose bengal. The base of the ulcer stains with fluorescein.
- There may be an anterior stromal infiltrate under the ulcer which normally resolves when the epithelium has healed.
- Particularly with topical steroid therapy, areas of dendritic keratitis can coalesce and enlarge to form a more expansive geographic ulcer.
- Following resolution of the epithelial dendrite, subepithelial scarring may be seen just beneath the area of the prior defect.
- A neurotrophic keratitis may result (see section 1.23).

##### Differential diagnosis

There are a variety of conditions that may result in dendrite-like (dendritiform) lesions. These include:

- varicella zoster virus (VZV),
- rarely adenovirus or EBV,
- line of healing following an epithelial abrasion,
- neurotrophic keratopathy,
- secondary complications of contact lens wear,
- *Acanthamoeba*.

##### Investigations

Diagnosis is clinical. In atypical cases consider viral cultures and/or antigen-detection techniques.

### Treatment

- Epithelial debridement should be performed by gently wiping the surface of the dendrite with a cellulose sponge.
- Topical antiviral, ocular acyclovir 5 times/day, until epithelial healing has occurred. This should normally be discontinued after 10–14 days at which time the treatment can result in toxic keratopathy. Topical alternatives include: gancyclovir gel (0.15%) 5 times/day or trifluorothymidine 1% drops (6 times/day).
- If there are signs of toxicity, an alternative to topical treatment is oral antiviral treatment with acyclovir 400 mg 5 times/day. This is secreted in the tear film but at a lower concentration than with topical therapy.
- Topical steroids may be considered to reduce vascularization of a marginal ulcer after a few days of topical antiviral cover.
- Consider long-term oral acyclovir prophylaxis (400 mg BD) for recurrent epithelial disease (this reduces the risk of recurrence by 50% only while taking the medication).
- Topical corticosteroids are contraindicated in the presence of an active dendrite. If the patient was already taking the topical steroid before the development of the dendrite, the steroids should not be stopped immediately as the rebound inflammatory response may result in more damage. Instead the steroids should be reduced gradually or a weaker preparation used.

### Stromal keratitis

This can be either non-necrotizing stromal (interstitial; see section 1.20) or, rarely, necrotizing stromal keratitis.

#### Herpes simplex interstitial keratitis

This classically presents with pain and decreased vision. On examination there is unifocal or multifocal stromal haze in the absence of epithelial ulceration. There may be mild stromal oedema and an anterior chamber reaction. Long-standing/recurrent cases can result in corneal thinning, scarring, vascularization, and/or lipid keratopathy.

##### Treatment

- Topical steroids such as g. dexamethasone 0.1% QDS (depending on the degree of inflammation) are the mainstay of treatment. The steroids need to be slowly tapered depending on the clinical improvement. A long-term low dose such as g. prednisolone 0.1% daily/alternate days may be required to prevent recurrence of inflammation.
- When topical steroids are used in a patient with a history of HSK it is necessary for the patient to take a prophylactic oral dose of acyclovir 400 mg BD to prevent disease recurrence. This dose can also be used for prophylaxis in recurrent stromal disease.

#### Necrotizing stromal keratitis

This rare condition occurs due to active viral replication together with a host immune response that results in tissue necrosis. The clinical presentation is that of a dense stromal infiltration that may be clinically indistinguishable from bacterial or fungal keratitis and secondary infection must be excluded. The overlying epithelium may be intact or ulcerated. Necrosis and ulceration may result in rapid thinning and perforation.

##### Treatment

- This is with oral acyclovir 400 mg 5 times/day (the potential for corneal drop toxicity makes topical antiviral therapy undesirable in the presence of ulceration and necrosis).
- A low dose of topical steroid such as g. dexamethasone 0.1% BD is usually sufficient to control inflammation.

## Disciform endothelial keratitis

This is a primary inflammation of the endothelium. The exact aetiology is unknown. It may be due to viral infection of endothelial cells or may represent an immune response to viral antigen. It presents with stromal and epithelial oedema in a round/oval distribution. There are keratic precipitates on the endothelium underlying the zone of oedema. There is often a mild associated iridocyclitis and if the trabecular meshwork is also inflamed there may be a raised IOP.

### Treatment

- This is with topical antiviral and topical steroid initially 4 to 6 times a day and then gradually reduced depending on the clinical response. Raised IOP should also be treated. Oral acyclovir should be used if iridocyclitis is suspected.

Note also:

1. if visually significant stromal scarring results from any of the subtypes of HSK, a penetrating or lamellar keratoplasty may be required;
2. herpetic iridocyclitis can occur independently or together with epithelial, stromal, or endothelial inflammation and is discussed in more detail in section 5.7.

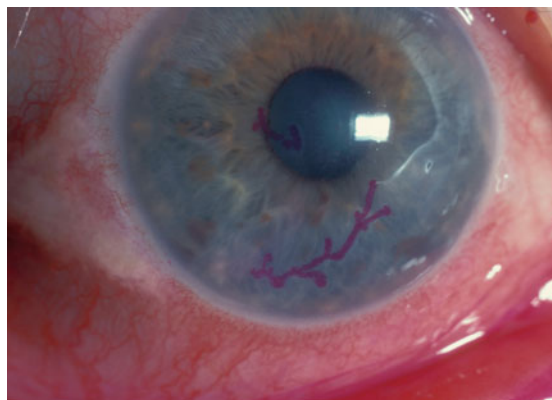
## Further reading

Herpetic eye disease study 1.

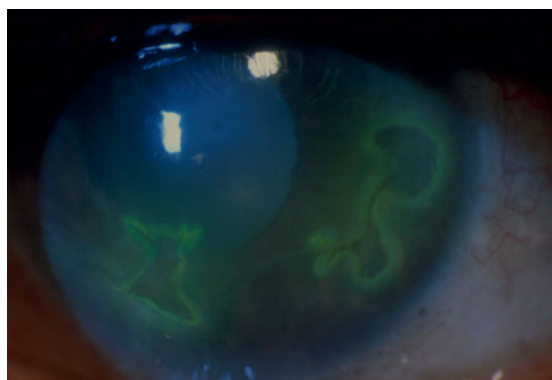
[www.nei.nih.gov/neitrials/static/study37.asp](http://www.nei.nih.gov/neitrials/static/study37.asp)

Herpetic eye disease study 2.

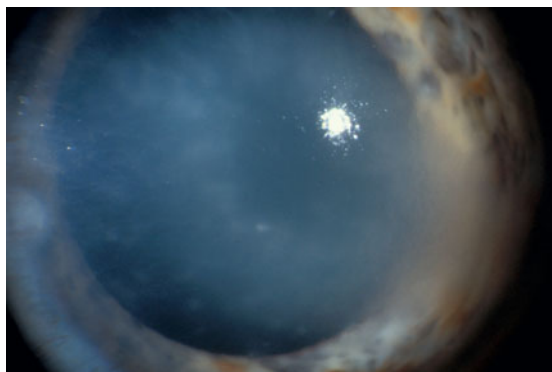
[www.nei.nih.gov/neitrials/static/study38.asp](http://www.nei.nih.gov/neitrials/static/study38.asp)



**Fig. 1.48** Herpes simplex epithelial keratitis: dendrite staining with rose bengal.



**Fig. 1.49** Geographic ulcer staining with fluorescein. Courtesy of John Dart.



**Fig. 1.50** Disciform keratitis.



## 1.19 Infectious keratitis IV: viral; herpes zoster

### Pathophysiology

The double-stranded DNA virus of the herpes family, varicella zoster virus (VZV), causes chicken pox as the primary infection (usually in childhood). The virus then remains latent in the dorsal root ganglion and reactivation causes herpes zoster (shingles). Reactivation most commonly occurs in the thoracolumbar region. Cranial nerve involvement occurs in up to 20% of cases of shingles with the ophthalmic division of the trigeminal nerve ( $V_1$ ) being most commonly involved (herpes zoster ophthalmicus, HZO). The skin manifestations (described more fully in section 2.13) may occur independently of or together with ocular features. The nasociliary branch of  $V_1$  innervates the skin on the tip of the nose as well as intraocular structures. Therefore skin vesicles on the tip of the nose (Hutchinson's sign) are associated with a high risk (50–75%) of ocular involvement. With the exception of eyelid vesicles and follicular conjunctivitis, ocular involvement is uncommon during the primary infection. The ocular manifestations of HZO may follow the acute skin rash by weeks, many months, or even years. Occasionally they can precede the skin rash. Other potential extra-corneal manifestations of HZO include the following.

- **Conjunctiva:** papillary or follicular reaction, membranes, vesicles, haemorrhage, conjunctival scarring, and/or symblepharon.
- **Episclera/sclera:** episcleritis, scleritis, or sclerokeratitis.
- **Other:** uveitis, sectoral iris atrophy, trabeculitis (with ocular hypertension or glaucoma), retinitis, choroiditis, optic neuritis, cranial nerve palsies, encephalitis, and post-herpetic neuralgia.

Risk factors for HZO include increasing age and immunosuppression.

### Epithelial keratitis

This develops within the first few days of the onset of the rash and resolves spontaneously a few days later. It is characterized by punctate epithelial erosions and pseudodendrites (it differs from HSV dendrites in being more superficial with tapered ends that lack terminal bulbs).

### Nummular keratitis

This usually occurs around 10 days after the onset of the rash. It is characterized by multiple round granular subepithelial deposits surrounded by stromal haze. They can resolve spontaneously or become chronically inflamed with vascularization and lipid infiltration.

### Disciform keratitis

This occurs around 3 weeks after the onset of the rash and is usually preceded by nummular keratitis. It is indistinguishable clinically from herpes simplex disciform keratitis. If untreated this becomes chronic.

### Mucus plaque keratitis

This occurs between 3 and 6 months after the onset of the rash. It is characterized by elevated mucus plaques that stain brightly with rose bengal. The plaques can take on a linear, grey branching appearance.

### Other corneal manifestations of HZO

This includes profound corneal anaesthesia and neurotrophic keratitis, exposure keratopathy (due to cicatricial lid changes), or lipid keratopathy.

### Treatment

- Systemic antiviral therapy with acyclovir 800 mg 5 times/day (alternatively valacyclovir 1 g 3 times daily (TDS) or famciclovir 500 mg TDS) for 7 days is indicated as soon as the rash starts. This is particularly effective at reducing the duration of the

disease as well as the potential sequelae if commenced within 72 hours of the onset of the rash. If the patient is systemically unwell, vomiting, and/or immunosuppressed, admission under the care of general physicians for administration of intravenous (IV) acyclovir (15–20 mg/kg per day) may be necessary.

### Epithelial disease

- Topical acyclovir (3%) 5 times/day is only indicated in acute disease.
- Unpreserved lubricants.

### Stromal disease/keratouveitis/disciform keratitis/trabeculitis/sclerokeratitis

- Topical steroids (dose should be tailored to the degree of inflammation), may require low maintenance dose to prevent recurrence. Topical antiviral not indicated.
- Unlike HSK, oral antiviral therapy is not useful in preventing recurrence with HZO and does not need to be given after surgery or along with topical steroid therapy.

### Mucus plaques

- These are treated by gentle removal if possible, lubricants, mucolytics, and—if necessary—topical steroids.

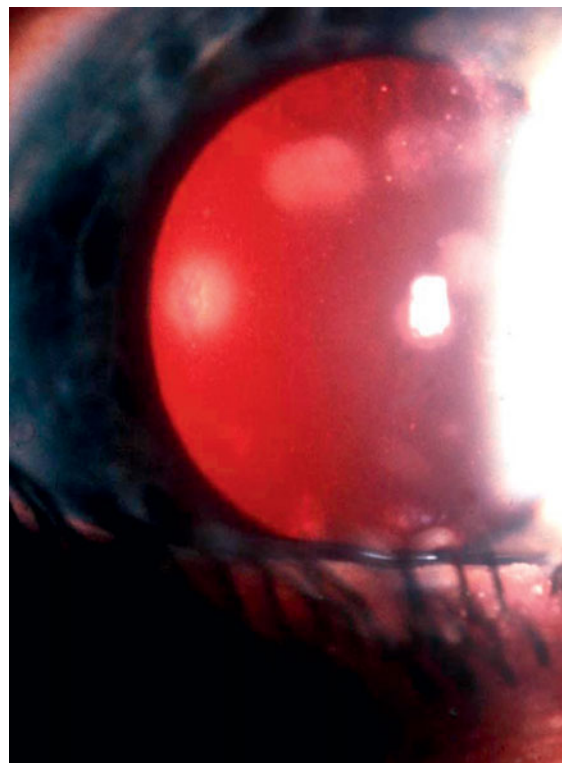
### Neurotrophic keratitis

- See section 1.23.

### Post-herpetic neuralgia

- Topical capsaicin cream (0.025–0.075% TDS/QDS) and amitriptyline 10–25 mg QDS. Refer for specialist pain management early as it can become chronic.

Note: significant corneal scarring may require penetrating or lamellar keratoplasty.



**Fig. 1.51** Nummular keratitis seen on retroillumination. Courtesy of John Dart.

## 1.20 Interstitial keratitis

### Pathophysiology

This is non-ulcerative inflammation of the corneal stroma without significant involvement of the epithelium or endothelium. The inflammation causes focal or diffuse cellular infiltration with/without vascularization. It can be infectious or immune or both and may affect any stromal layer. The distribution and depth of stromal involvement together with any associated systemic signs can be helpful in identifying the cause.

### Aetiology

#### Infectious

- Viral: herpes simplex, herpes zoster, or EBV.
- Bacterial: syphilis, Lyme disease, or brucellosis.
- Mycobacterial: tuberculosis, leprosy, or atypical mycobacteria.
- Parasitic: onchocerciasis, microsporidia, or leishmania.

#### Non-infectious

Phlyctenular keratitis, Cogan's syndrome (see below), sarcoidosis, lymphoma, or contact lens-related.

Many of these conditions are described in more detail in other sections. The remainder of this section will focus on syphilitic interstitial keratitis (the first infection to be linked with interstitial keratitis and a classical example of the disease process) and Cogan's syndrome.

### Syphilitic interstitial keratitis

Most cases are due to congenital syphilis from mothers with primary, secondary, or early latent disease. It occurs rarely in acquired syphilis.

#### Congenital syphilis

##### Pathophysiology

Interstitial keratitis is a delayed immune-mediated response, not a manifestation of active infection. Onset is at around 5–20 years of age.

##### Clinical evaluation

- The interstitial keratitis is usually bilateral.
- Initial symptoms are pain, watering, photophobia, and redness.
- In early disease the clinical manifestations include sectoral superior stromal inflammation and keratic precipitates.
- Later in the disease process, deep stromal vascularization develops. The surrounding inflammatory infiltrate and stromal oedema obscure the outline of the vessels making the stroma appear pink ('salmon patch').
- Sequelae of stromal keratitis include corneal thinning, ghost vessels (when the vessels become non-perfused), stromal opacification, Descemet's membrane scrolls, endothelial cell loss, and reduced vision.
- Pigmentary chorioretinopathy may be present due to prior chorioretinitis.
- Other non-ocular features of congenital syphilis may be seen: deafness, dental abnormalities (notched incisors, mulberry molars), bone and cartilage abnormalities (saddle nose, palatal perforation, frontal bossing), and mental retardation (Hutchinson's triad refers to interstitial keratitis, deafness, and notched teeth).

#### Acquired syphilis

Interstitial keratitis is rare in acquired syphilis. Uveitis and retinitis are more common manifestations of this disease.

### Investigations

Venereal Disease Research Laboratory (VDRL) and rapid plasma reagin tests are positive in active disease while the *Treponema*-specific antibody test (FTA-ABS) remains positive even after treatment.

### Treatment

- Intense topical steroids (e.g. dexamethasone 0.1%/prednisolone 1% 6–8 times/day) can reduce the inflammation, limit the opacification, and improve vision. Tapering steroids may be needed for several months to keep the inflammation under control. Penetrating keratoplasty can be considered in patients with sequelae of interstitial keratitis.
- Systemic treatment with penicillin doesn't treat interstitial keratitis but is used to treat systemic infection or prevent neurosyphilis.
- Physicians should be involved in investigations and treatment of suspected syphilis.

### Cogan's syndrome

This is an idiopathic autoimmune disorder of young adults (mean 30 years) characterized by interstitial keratitis, vertigo, tinnitus, and hearing loss.

Non-specific interstitial keratitis can be the presenting feature or follow the otological symptoms, both usually developing within a few months of each other.

The interstitial keratitis is bilateral and starts as peripheral and superficial nummular lesions (differential diagnosis: adenoviral keratitis) before developing deeper multifocal stromal nodules and later vascularization.

Treatment is with topical steroids.

The diagnosis is one of exclusion and based on positive ocular and otological features. Prompt treatment of otological disease with systemic steroids is essential to prevent hearing loss. Steroid-sparing immunosuppression may be needed.

Ten per cent develop large vessel vasculitis (like polyarteritis nodosa) many weeks or years later.

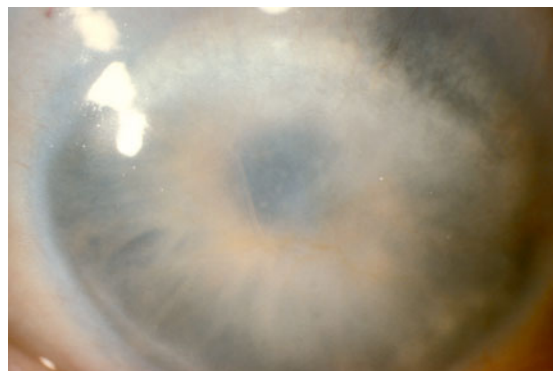

Fig. 1.52 Interstitial keratitis.

## 1.21 Peripheral ulcerative keratitis

This is an uncommon potentially blinding disorder consisting of crescent-shaped destructive inflammation of the peripheral corneal stroma, associated with an overlying epithelial defect.

### Pathophysiology

The peripheral cornea has immunological characteristics that predispose it to inflammation. The peripheral cornea is in close proximity to the limbal vasculature, a source of immunocompetent cells. Any inflammatory stimulus in the peripheral cornea (infection, immune-complex deposition in systemic immune diseases, trauma, malignancy, or dermatologic conditions) can result in neutrophil recruitment and complement activation. This results in the release of enzymes that cause destruction of the corneal stroma, thinning, and eventually perforation.

### Aetiology

There are a variety of conditions that can result in peripheral ulcerative keratitis (PUK):

**Systemic:** Rheumatoid arthritis, systemic vasculitides (relapsing polychondritis, Wegener's granulomatosis, polyarteritis nodosa), inflammatory bowel disease, neoplastic conditions, and infectious conditions (bacillary dysentery, hepatitis C, tuberculosis, or syphilis).

**Ocular:** Mooren's ulcer, rosacea keratitis, trauma, surgery, infectious conditions (herpetic/bacterial/fungal keratitis).

Connective tissue and vasculitic diseases are the major risk factors. Many of the other aetiological conditions are discussed elsewhere in this chapter. This section will focus on PUK with systemic immune-mediated disease and Mooren's ulcer. Other forms of keratitis due to rheumatoid arthritis will also be included in this section.

## PUK with systemic immune-mediated disease

### Pathophysiology

This is mostly explained above. Biopsy specimens of conjunctival tissue adjacent to involved cornea typically show evidence of immune-mediated vaso-occlusive disease.

### Clinical evaluation

#### History

- There is often a history of autoimmune, connective tissue, or vasculitic disease which is normally active if PUK is occurring.
- Ocular symptoms are variable and may be minimal. The most common symptoms are a subacute onset of foreign body sensation with or without eye pain, watering, photophobia, and reduced vision.
- There may be associated scleritis, in which case eye pain may be more pronounced.

#### Examination

- The disease normally presents as a crescent-shaped epithelial defect with variable underlying stromal thinning and infiltrate, often limited to one quadrant of the juxtalimbal cornea. The disease may extend to involve the paralimbal sclera.
- There may be varying degrees of adjacent conjunctival injection.
- Limbal ischaemia due to vasculitic vaso-occlusion may also be present.
- There may be signs of systemic autoimmune disease.

#### Investigations

Corneal scrape (to rule out primary or secondary infection). Investigations to look for systemic immune-mediated disease should be performed in consultation with a rheumatologist and should include: urinalysis (to look for evidence of renal vasculitis), full blood count, erythrocyte sedimentation rate, urea and electrolytes,

rheumatoid factor, anti-nuclear antibodies, anti-neutrophil cytoplasmic antibody (ANCA), VDRL test, hepatitis C serology, and a chest X-ray (CXR).

### Treatment

There are three main aims for treating PUK

1. **Ocular surface wetting:** intensive tear-film supplements are important not only for the treatment of aqueous tear deficiency (which may coexist in rheumatoid arthritis) but also to dilute the effect of inflammatory cytokines in the tear film. Wetting may also help treat a dellen effect in the base of the ulcer.
2. **Re-epithelialization:** lubricants or a bandage contact lens can be utilized for this purpose. Systemic collagenase inhibition with doxycycline may be of some value. A topical broad-spectrum antibiotic is used as prophylaxis against secondary infection.
3. **Systemic immune-suppression:** this is the mainstay of treatment if there is systemic disease. It is necessary not only for the ocular manifestations but also to control the systemic disease. For rapidly progressing cases high-dose oral or IV corticosteroid is necessary and cyclophosphamide should be considered.

For severe disease with actual or impending perforation there are a variety of surgical options to control disease, which include: cyanoacrylate glue (limits ulceration by protecting the ulcer bed from leucocytes present in the tear film), peripheral lamellar keratoplasty, amniotic membrane grafting, and/or adjacent limbal conjunctival excision or recession.

## Mooren's ulcer

This is a rare PUK of unknown aetiology. By definition the diagnosis can only be made after excluding other systemic/ocular causes of PUK (Mooren's is a diagnosis of exclusion).

### Pathophysiology

This has not been fully elucidated. Autoimmune corneal destruction occurs as explained above. This may occur in response to previous infection or trauma which alters the expression of corneal antigens.

### Clinical evaluation

- Mooren's ulcer is a chronic, progressive, painful (often severe) ulceration of peripheral corneal epithelium and stroma.
- The ulceration begins in the corneal periphery before spreading circumferentially and then centrally. The peripheral base of the ulcer becomes vascularized.
- It can be distinguished from other causes of PUK by the absence of scleral involvement. Another distinguishing feature is the leading central edge of the ulcer, which is undermined.
- Two clinical types of Mooren's ulcer have been described. The first is unilateral, which typically occurs in older patients. The second is bilateral, rapidly progressive, and poorly responsive to therapy. This second type typically occurs in younger patients.

### Treatment

This is as for PUK with systemic immune-mediated disease. In addition, topical steroids and/or topical cyclosporine can be used to treat Mooren's ulcer.

## Other forms of keratitis in rheumatoid arthritis

These may take a variety of different forms and includes the following.

- **Limbal guttering:** this is characterized by peripheral stromal thinning without epithelial loss or infiltration. It can occur

without any conjunctival injection or other signs of inflammation. When involving the 360° corneal circumference it resembles a contact lens on the cornea. It may perforate in severe cases.

- **Sclerosing keratitis:** characterized by gradual opacification and neovascularization of peripheral cornea adjacent to an area of scleritis without thinning.
- **Acute stromal keratitis:** this initially presents with stromal infiltrates and oedema with an intact epithelium associated with non-necrotizing scleritis. It can progress to PUK.
- **Acute corneal melting:** this can occur with or without signs of inflammation, especially in the very dry eye. It is characterized by acute stromal thinning beneath an epithelial defect and it usually occurs centrally.

Treatment for all forms is as for PUK with systemic disease.

## Terrien marginal degeneration

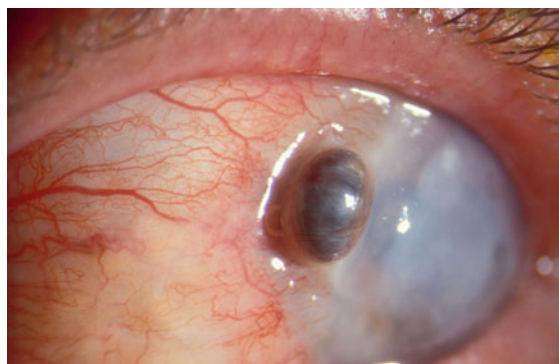This is a rare non-inflammatory condition and is included in this section as it forms an important part of the differential diagnosis for PUK.

It is a slowly progressive idiopathic peripheral corneal thinning disorder occurring mostly in men in the second or third decade of

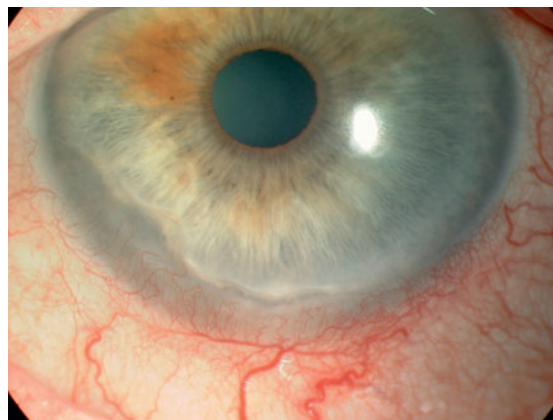
life. It is normally bilateral, though often asymmetrical. It begins superiorly before spreading circumferentially. The earliest sign is peripheral anterior stromal yellow-white deposits that progress to peripheral guttering parallel to the limbus. The guttering has a steep central edge and a shallow sloping limbal edge. The gutter is 1–2 mm wide with an intact epithelium. Fine vessels cover the area of thinning and there is often secondary lipid deposition. Unlike PUK, there is rarely pain or inflammation associated with this disease. Patients may complain of mild irritation and progressive blurred vision due to increasing against-the-rule astigmatism. Spontaneous corneal perforation is rare but can occur secondary to even minor trauma.

### Treatment

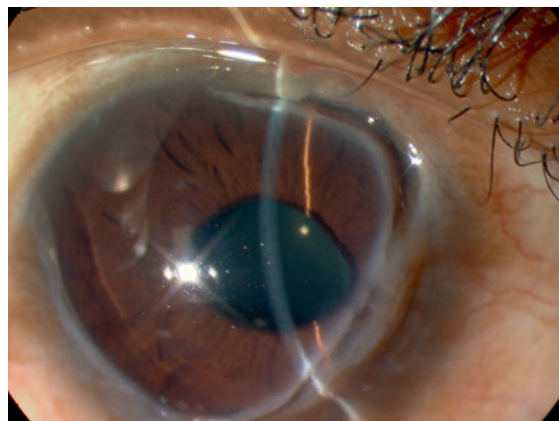
This is only required for disabling astigmatism or perforation. A scleral lens can be used for visual correction. Crescent-shaped lamellar or full-thickness corneo-scleral patch grafts or annular lamellar keratoplasty may be needed depending on the extent and depth of thinning.



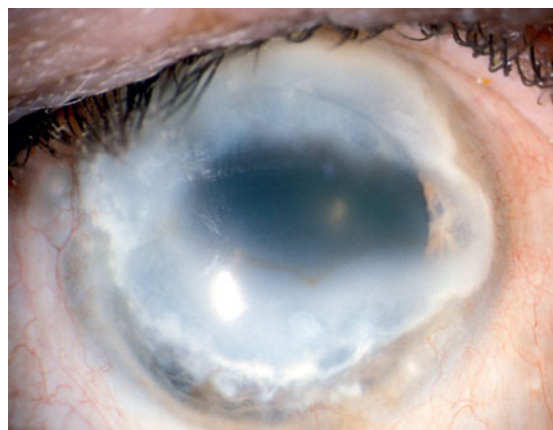
**Fig. 1.53** PUK with systemic immune-mediated disease. Corneal perforation has occurred with iris prolapse.



**Fig. 1.55** Limbal guttering in rheumatoid arthritis.



**Fig. 1.54** Mooren's ulcer. Courtesy of John Dart.



**Fig. 1.56** Terrien marginal degeneration.



## 1.22 Metabolic and drug-induced keratopathies

### Vortex keratopathy (cornea verticillata)

This is characterized by the presence of bilateral, whorl-like grey-brown epithelial deposits in the lower half of the cornea, sparing the limbus. It occurs due to deposition of complex lipids in the basal epithelial layer. Responsible aetiological agents include amiodorone, chloroquine, and chlorpromazine. The deposits are asymptomatic and this condition is not an indication to discontinue the drugs. If the patient does complain of reduced vision, other causes of ocular morbidity associated with these drugs (optic neuropathy with amiodarone and retinopathy with chloroquine) should be sought. If the drugs are discontinued the condition gradually resolves. The condition also occurs in Fabry's disease, an X-linked recessive multi-system disorder (corneal changes occur in both the affected males and carrier females).

### Ciprofloxacin deposits

Topical ciprofloxacin therapy can result in chalky white deposits within an epithelial defect. The deposit is composed of ciprofloxacin crystals and may be irreversible even after cessation of therapy.

### Corneal chrysisis

This refers to the deposition of gold in the cornea which occurs after prolonged administration of systemic gold in the treatment of rheumatoid arthritis. It is characterized by asymptomatic glittering purple granules/dust-like opacities in the corneal stroma.

### Adrenochrome deposition

This results from long-standing administration of topical adrenaline compounds which were used historically to treat glaucoma. It is characterized by dark brown/black granules on Bowman's layer or in conjunctival cysts. It is an innocuous finding.

### Wilson's disease (hepatolenticular degeneration)

This is an autosomal recessive disorder resulting in deficiency of caeruloplasmin and deposition of copper in multiple tissues. Extraocular features include hepatic (cirrhosis, hepatitis, hepatosplenomegaly) and neurological disease (tremors, rigidity, chorea, psychosis).

Corneal involvement in the form of yellow-brown/green deposits (Kayser–Fleischer ring) in the peripheral cornea is the most consistent disease finding (occurs in 95% of cases). The deposits are located at the level of Descemet's membrane in the peripheral cornea (initially at the Schwalbe's line where it can be detected earliest by gonioscopy). When more pronounced it can subsequently be seen on slit lamp, direct ophthalmoscope slit, or torch-light examination. Patients may have associated green anterior capsular cataracts (sunflower cataract). The combination of sunflower cataract and Kayser–Fleischer ring can also occur in association with an intraocular copper foreign body (chalcosis).

### Immunoprotein deposits

This is an uncommon manifestation of several systemic diseases, including multiple myeloma and leukaemia. It is characterized by multiple flake-like opacities deposited in the peripheral stroma. Treatment is directed at the underlying disease.

### Cystinosis

This is a rare autosomal recessive disorder characterized by widespread cystine crystal deposition within tissues. Systemic features include growth retardation, renal failure (Fanconi syndrome), and hepatosplenomegaly. Ocular features include deposition of myriads of minute crystals within the conjunctiva and cornea resulting in photophobia, epithelial erosions, and blurring of vision. Crystals can also be deposited in the iris, lens capsule, and retina. Treatment is with topical 0.2% cysteamine.

### Iron deposition

Epithelial iron deposits manifest as a yellow-brown line and are situated in areas where pooling of tears occur. These are seen in the interpalpebral fissure in normal eyes (Hudson Stahli line), at the head of a pterygium (Stocker's line), around the cone in keratoconus (Fleischer ring), after refractive corneal surgery, or in front of a filtering bleb (Ferry's line). Iron staining can also develop around a metallic corneal foreign body.

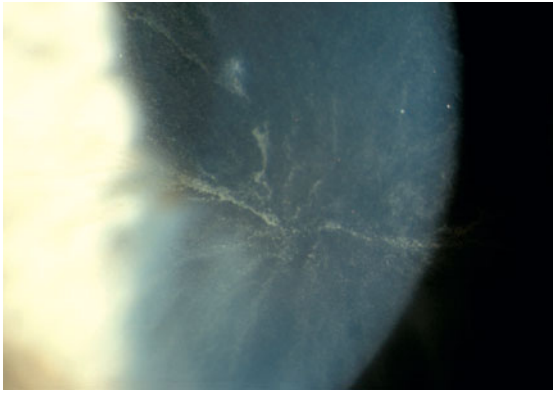
### Siderosis

This occurs secondary to an intraocular iron-containing foreign body. Iron is deposited in intraocular epithelial structures (lens capsule, retina, and iris).

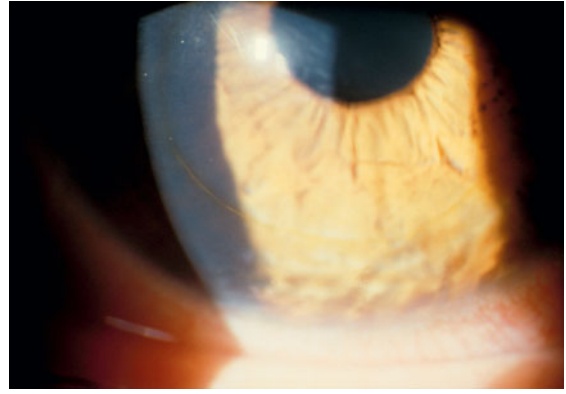
### Mucopolysaccharidoses

These are rare lysosomal storage diseases due to deficiency of enzymes needed for degradation of glycosaminoglycans leading to altered metabolite deposition in various tissues and excretion in urine. Excessive dermatan and keratin sulphate results in corneal stromal clouding.

There are seven distinct types and several subtypes. All have autosomal recessive inheritance except for Hunter syndrome (X-linked recessive). Corneal clouding occurs in all except Hunter and Sanfilippo syndromes. Corneal clouding is particularly severe (onset within first few years in life) in Hurler and Scheie syndromes. Other associated ocular features include pigmentary retinopathy, optic atrophy, and glaucoma. Systemic features include skeletal dysplasia, facial dysmorphism, mental retardation, hepatosplenomegaly, and cardiac disease.



**Fig. 1.57** Vortex keratopathy.



**Fig. 1.58** Iron line around the cone in keratoconus (Fleischer ring).

## 1.23 Miscellaneous keratopathies

### Thygeson's superficial punctate keratitis

This is a condition of unknown aetiology characterized by recurrent episodes of bilateral coarse punctate keratopathy without vascularization or conjunctival injection. Symptoms consist of watering, foreign body sensation, photophobia, and blurred vision. There may be several white-grey superficial slightly elevated epithelial lesions. Each lesion, if untreated, persists for 1–2 months. The overall course of the disease is usually 2–3 years. The lesions stain with fluorescein during the acute exacerbations. During remissions they can disappear completely.

#### Treatment

The lesions resolve with mild topical steroid therapy, which suggests an immune-mediated aetiology. Steroid treatment may prolong the course of the disease and should be used for a short course during acute exacerbations. Topical lubricants, a bandage contact lens, or topical cyclosporin A BD are alternative treatments.

### Exposure keratopathy

#### Pathophysiology

Inability to close the lids (lagophthalmos) leads to corneal drying, epithelial breakdown, secondary infectious keratitis, and even perforation. Lagophthalmos with or without exposure keratopathy can be present at night in some healthy individuals (nocturnal lagophthalmos). Potential causes of exposure keratopathy include:

- facial nerve palsy (eg. Bell's palsy);
- reduced facial nerve tone in comatose/intubated patients (eg. in intensive care unit);
- lid abnormalities: ectropion, floppy eyelid syndrome, iatrogenic (post-surgery), cicatricial lid/conjunctival disease, or proptosis.

#### Clinical evaluation

- Presentation is with irritation, foreign body sensation, burning, and watering, especially upon waking.
- Patients with poor Bell's phenomenon are particularly at risk (see section 2.6). It is also important to assess the degree of lid closure with the eyelids gently closed.
- The classical examination findings are interpalpebral, inferior punctate corneal epitheliopathy with or without conjunctival injection. If severe there can be corneal opacification, ulceration, and even perforation.

#### Treatment

- In mild cases, frequent artificial tears by day with a lubricating ointment at night may suffice. In more severe cases the ointment can be applied hourly by day.
- Exposure may be reduced by temporary measures such as taping the eyelid shut at bedtime, a temporary tarsorrhaphy, or by inducing a ptosis with botulinum toxin injection into the upper lid.
- More permanent measures include lateral and/or medial tarsorrhaphy or gold-weight insertion into the upper lid.
- Prophylactic topical antibiotics should be given in severe cases with intensive treatment if a coexisting infectious keratitis is suspected.

### Neurotrophic keratopathy

#### Pathophysiology

An intact corneal nerve supply is vital for the maintenance of epithelial integrity, reflex tear production, and blinking. Persistent corneal

anaesthesia or hypoaesthesia result in degradation of the epithelial surface and the quality of the tear film. This can lead to epithelial breakdown, stromal lysis, thinning, and perforation (with/without secondary infection).

Causes of reduced corneal sensation include:

- herpes simplex and zoster keratitis;
- fifth cranial nerve damage; for example, with surgery for acoustic neuroma;
- systemic disease (eg. diabetes mellitus);
- iatrogenic-ocular surgery (LASIK, corneal surgery, damage to ciliary nerves by retinal laser and surgery);
- topical medications (eg. anaesthetic abuse);
- chemical burns and chronic epithelial injury or inflammation;
- congenital syndromes (eg. familial dysautonomia).

#### Clinical evaluation

Reduced corneal sensation (may be sectoral in HSK).

Progressive signs include rose bengal staining of the inferior conjunctival surface, punctate corneal staining, acute epithelial loss, and chronic non-healing corneal ulceration with raised rolled edges. Rarely stromal lysis, thinning, and perforation can occur. There can be a secondary microbial keratitis.

#### Treatment

- Treatment of mild cases is as for dry eye: tear supplements, lubricants, and if necessary punctal plugs.
- More advanced cases require further intervention to promote epithelial healing: botulinum-induced ptosis, tarsorrhaphy, and/or autologous serum drops.
- If there is significant stromal lysis: amniotic membrane grafting, penetrating or lamellar corneal grafting, or as a last resort a conjunctival flap may need to be performed (see below).

### Non-healing epithelial defect

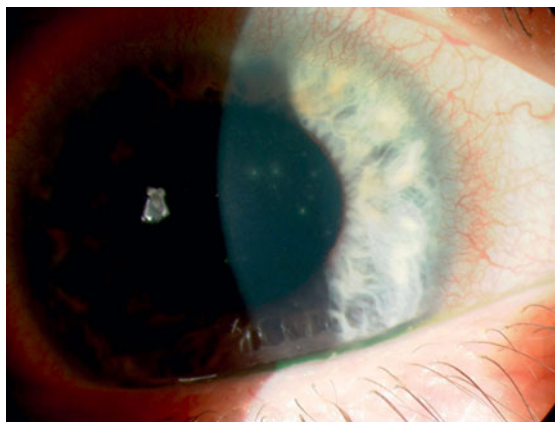
This can be due to a variety of causes, including intrinsic corneal disease (eg. bullous keratopathy), mechanical (eg. trichiasis, exposure, dry eye), chemical (stem cell failure following chemical injury, drop toxicity), neurotrophic, inflammatory, infectious, or neoplastic factors. The cause should be established and treatment aimed at correcting the underlying aetiology and promoting healing (as for neurotrophic keratitis).

### Conjunctival flaps

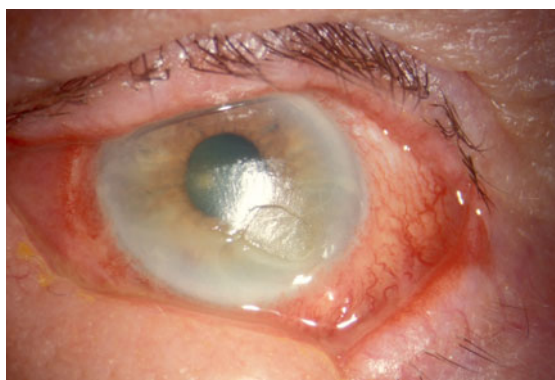
Advancement of the conjunctiva over the cornea can be performed to provide pain relief and/or aid healing in a variety of ocular surface diseases where restoration of vision is not the priority. Such cases include severe neurotrophic keratitis, non-healing epithelial defects, and/or indolent infective keratitis. The flaps can be partial (eg. advancement flaps, single/bi-pedicle) or total. Partial advancement flaps can be helpful in peripheral corneal disease; for example, peripheral melt. Total conjunctival flaps/conjunctival hooding (also referred to as Gundersen's flap) are fashioned by dissecting the superior conjunctiva from the Tenon's capsule and advancing it to the inferior limbus after removing the corneal epithelium and superficial stroma.

## Amniotic membrane transplantation

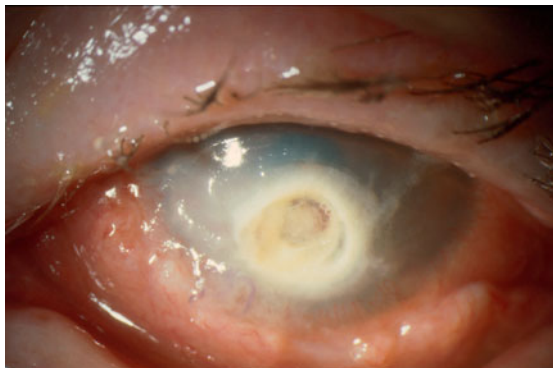Amniotic membrane harvested from placenta is used for surface reconstruction in a variety of ocular conditions, including fornix reconstruction in cicatrizing conjunctivitis, neurotrophic keratitis, and non-healing epithelial defects. It is also used as a base for proliferation and transplantation of autologous limbal cells in ocular surface reconstruction. It reduces inflammation, neovascularization, and scarring and promotes wound healing and epithelialization. The amniotic membrane gets absorbed gradually. Contraindications to its use include severe dry eye, exposure, and severe stromal necrosis.



**Fig. 1.59** Thygeson's superficial punctate keratitis.



**Fig. 1.60** Exposure keratopathy. Note the inferior lid notch causing the exposure.



**Fig. 1.61** Neurotrophic keratopathy with persistent epithelial defect.

## 1.24 Corneal dystrophies I

These are a group of bilateral, normally symmetrical, inherited conditions that result in progressive corneal opacification commencing between the first and fifth decades of life. The dystrophies can be classified according to the anatomical layer of the cornea that is involved. Molecular genetics has led to a re-assessment of the traditional clinical groupings.

### Epithelial dystrophies

#### Epithelial basement membrane dystrophy

This is the most common anterior dystrophy, occurring in over 2% of the general population. It is also known as Cogan's microcystic or map-dot-fingerprint dystrophy.

##### Pathophysiology

There may be autosomal dominant inheritance (often with incomplete penetrance) but most cases are sporadic. Histology shows a thickened and reduplicated basement membrane, absent/abnormal hemidesmosomes on the basal epithelial cells, and fibrillar material between the basement membrane and Bowman's layer. This results in an abnormally weak anchoring of the epithelium to the underlying basement membrane.

##### Clinical evaluation

The onset of disease is in the second decade of life.

- Patients may be asymptomatic or may present with symptoms of recurrent corneal erosions (see end of section 1.25). Clinical manifestations of disease can be asymmetrical.
- Approximately 10% of patients with this dystrophy will develop recurrent corneal erosions and 50% of patients with recurrent corneal erosions have evidence of this dystrophy.
- There are four types of corneal abnormality that are best visualized with sclerotic scatter, retroillumination, or a diffuse tangential beam:
  1. *epithelial microcysts*;
  2. *dots*: collapsed microcysts;
  3. *fingerprint lines*: consist of thickened/multilaminar strips of epithelial basement membrane;
  4. *geographic areas* of thickened and irregular basement membrane deposit.

##### Treatment

No treatment is required in asymptomatic cases. Treatment in the presence of symptoms is as for recurrent corneal erosions.

#### Meesmann dystrophy

This is a rare autosomal dominant dystrophy with onset during early childhood. The disease manifests as discrete, clear epithelial microcysts (best seen with retroillumination). It is usually asymptomatic but can cause mild ocular irritation, photophobia, and reduction of vision. Treatment is usually not required.

### Corneal dystrophy of Bowman's layer (CDB)

#### Reis-Bücklers dystrophy (CDB type 1)

##### Pathophysiology

This is an autosomal dominant dystrophy linked to a mutation of the *TGFBI* gene of chromosome 5. Histologically, degenerative changes can be seen in the deep epithelium. Bowman's layer is disrupted or absent and replaced by irregular bands of collagen that stains blue with Masson trichrome.

##### Clinical evaluation

Onset is in early childhood. Recurrent epithelial erosions, surface irregularity, and anterior stromal scarring/oedema result in progres-

sive grey-white superficial honeycomb-shaped opacification by the first to second decades of life.

##### Treatment

Initial treatment is as for recurrent corneal erosions. More advanced cases require excimer laser phototherapeutic keratectomy or lamellar keratoplasty. Recurrence of disease in the graft is common.

#### Theil-Behnke dystrophy (CDB type 2)

There are two differences between this condition and CDB type 1:

1. the responsible gene usually maps to chromosome 10;
2. there is a different electron microscopic appearance (rod-like granules in Bowman's layer in CDB type 1 and curly filaments in CDB type 2).

Otherwise the two conditions are indistinguishable clinically and the treatment is the same. Inheritance is also autosomal dominant.

### Stromal dystrophies

#### Granular and Avellino dystrophy

##### Pathophysiology

These dystrophies show autosomal dominant inheritance and are linked to the *TGFBI* gene of chromosome 5 along with Reis-Bücklers dystrophy. The different clinical manifestations are the result of distinct changes in adjacent mutation hotspots on the same gene.

##### Clinical evaluation

- Histology shows the granular material within the stroma to be amorphous hyaline deposits that stain bright red with Masson trichrome. Onset is in early life with white, well-demarcated, crumb-like central anterior stromal deposits. There is clear intervening stroma.
- With age the lesions increase in number and depth and spread towards the corneal periphery but do not reach the limbus.
- Anterior lesions can break through Bowman's layer and result in recurrent corneal erosions.
- There is a gradual confluence of lesions which results in decreased vision.
- **Avellino dystrophy**: this is histologically and clinically the same as granular dystrophy with the addition of amyloid deposits typical of lattice dystrophy (see below). It is thus also referred to as granular-lattice dystrophy.

##### Treatment

Superficial symptomatic disease can be treated as for recurrent corneal erosions. Visually significant opacification is treated with deep lamellar keratoplasty or penetrating keratoplasty.

#### Lattice dystrophy

##### Pathophysiology

Inheritance is autosomal dominant. Expression is variable. Light microscopy reveals amyloid deposits primarily located in the anterior stroma. Amyloid may also accumulate beneath the epithelium affecting epithelial adhesion. Amyloid stains orange-red with Congo red dye and it exhibits apple green birefringence with polarized light.

##### Clinical evaluation

The classical clinical appearance is of central anterior stromal fine-branching refractile lattice lines best seen with retroillumination. There is also variable diffuse anterior stromal haze that does not affect the peripheral cornea.



There are three main types of lattice dystrophy, as follows.

- Type 1 (Biber–Haab–Dimmer): this is the most common form of lattice and is autosomal dominant. Onset is within the first decade of life with recurrent corneal erosions that precede the development of corneal opacities and reduction in vision.
- Type 2 (Meretoja syndrome): inheritance is rare and autosomal dominant. There is coexisting systemic amyloidosis. Onset of disease is in the third decade of life. In this form the lattice lines are more peripherally located. Extraocular features include cranial nerve palsies, pendulous ears, dry/lax skin, and a mask-like facial expression.
- Type 3: this is autosomal recessive with onset of symptoms occurring from the fifth decade. The lattice lines are larger than other forms and mid stromal in location.

#### **Treatment**

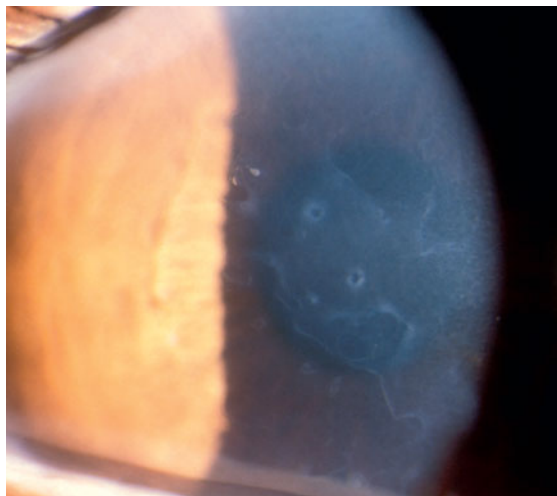
This is as for granular dystrophy.

#### **Macular dystrophy**

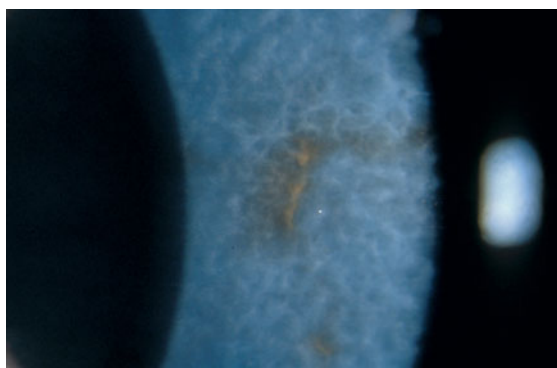
This is less common than the other classic stromal dystrophies described above.

#### **Pathophysiology**

Inheritance is autosomal recessive. The deposits are glycosaminoglycans which stain with alcian blue and colloidal iron.



**Fig. 1.62** Epithelial basement membrane dystrophy.



**Fig. 1.63** Reis–Bücklers dystrophy.

#### **Clinical evaluation**

Onset is in the first decade of life initially with focal grey-white anterior stromal opacities. This progresses to involve the entire stromal thickness, also extending peripherally up to the limbus. The stroma between the opacities is hazy. The cornea is diffusely thinned.

#### **Treatment**

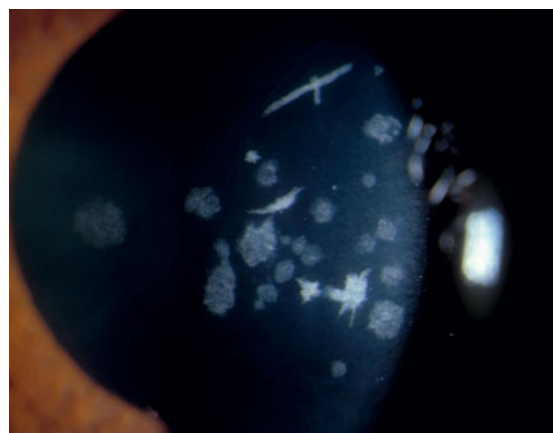
This is as for granular dystrophy.

#### **Schnyder crystalline dystrophy**

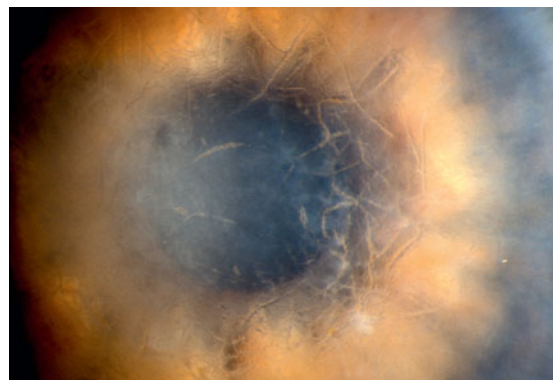
This is a rare autosomal dominant disease. It is thought to result from a local disorder of corneal lipid metabolism. There is a strong association with systemic hypercholesterolaemia. Clinical presentation is in the second decade with central corneal opacification, fine polychromatic cholesterol crystals in the anterior stroma, and a dense corneal arcus. Treatment is with phototherapeutic keratectomy or lamellar keratoplasty.

#### **Gelatinous droplike dystrophy**

This is an autosomal recessive corneal subepithelial amyloidosis. Presentation is in the first decade initially with a band keratopathy-like picture followed by protruding mulberry-like subepithelial deposits. Management is as for granular dystrophy.



**Fig. 1.64** Granular dystrophy.



**Fig. 1.65** Lattice dystrophy.

## 1.25 Corneal dystrophies II

### Endothelial dystrophies

#### Fuchs endothelial dystrophy

This is a very common condition that is more often seen in females than males.

##### Pathophysiology

The condition normally occurs sporadically but can be inherited in an autosomal dominant fashion. Distressed/dystrophic endothelial cells result in the formation of guttata. These guttata are posterior excrescences that form as a result of abnormal collagen deposition on a thickened Descemet's membrane. The reduction in the number and function of endothelial cells and their pump function results in progressive corneal oedema.

##### Clinical evaluation

Onset of the disease is normally after the age of 50. The clinical manifestations of the disease progress through three stages.

Stage 1 is characterized by an asymptomatic increase of central guttata and spread towards the periphery. Confluence of guttata gives rise to a 'beaten-metal' appearance on indirect or retroillumination. Pigment can adhere to the abnormal endothelium.

Stage 2 is characterized by endothelial decompensation and corneal oedema, resulting in blurred vision. This is initially worse on waking and clears as the day progresses. The oedema is initially confined to the stroma with accompanying Descemet's folds. Epithelial microcystic oedema can cause acute discomfort.

Stage 3: persistent epithelial oedema results in bullous keratopathy (see below).

##### Investigations

Endothelial cell density can be measured by specular microscopy. Corneal thickness can be measured by ultrasound pachymetry. Along with clinical features, these parameters can be used to monitor progression of the disease.

##### Treatment

- Topical sodium chloride 5% drops or ointment are useful to increase tonicity of the tear film and dehydrate the cornea. This can also be achieved with warm dry air from a hairdryer held at arm's length from the cornea for a few minutes in the morning.
- Bandage contact lenses provide temporary relief from discomfort by protecting exposed corneal nerve endings.
- Corneal graft surgery is the definitive treatment. This may be by penetrating keratoplasty or deep lamellar endothelial keratoplasty (see section 1.28). Patients with Fuchs dystrophy often have coexisting age-related cataract.
- An amniotic membrane graft or a conjunctival flap can be used to control pain in eyes with poor visual potential.
- Glaucoma or inflammation should be treated if present.

#### Posterior polymorphous dystrophy

This is an autosomal dominant inherited condition. On histology the multilayered endothelial cells have some features normally seen in epithelial cells (e.g. microvillae). On specular microscopy there are isolated grouped vesicles or broad bands with grey scalloped edges. This condition is normally asymptomatic and treatment is not then needed. Astigmatism and corneal decompensation can develop rarely.

### Congenital hereditary endothelial dystrophy (CHED)

This is a bilateral congenital primary dysfunction of corneal endothelial cells that results in corneal opacification. There are two types.

CHED 1 is autosomal dominant and presents in the second year of life with bilateral photophobia, tearing, progressive corneal oedema, increased corneal thickness, and progressive reduction in vision.

CHED 2 is autosomal recessive and presents from birth or within the first few weeks of life. The expression is more severe, showing marked oedema with a greatly increased corneal thickness, and severe decreased vision that can lead to amblyopia and nystagmus.

The differential diagnosis of bilateral early-onset corneal opacification includes congenital glaucoma, forceps injury, congenital infections, early-onset posterior polymorphous dystrophy, and metabolic diseases. Treatment of CHED is with penetrating keratoplasty.

### Clinical syndromes associated with corneal dystrophies

#### Recurrent corneal erosion syndrome

##### Pathophysiology

This common condition occurs either in eyes with a pre-existing corneal dystrophy (especially epithelial basement membrane dystrophy) or in eyes that have suffered a previous traumatic corneal abrasion (especially due to a fingernail injury) that has subsequently healed, or a combination of the two. Poor adhesion of the epithelium is thought to result from abnormalities of the underlying basement membrane and its associated network of attachment complexes (hemidesmosomes, basal lamina, laminin).

##### Clinical evaluation

- Clinical manifestations may occur soon or many years after the initial injury and there may be numerous recurrences.
- Presentation is with the sudden onset of foreign body sensation/pain, lacrimation, photophobia, and redness at night or upon first waking. Symptoms may resolve over a few hours with apparent healing of the epithelium or may be severe and last for several days.
- Upon examination the epithelium may have already healed or there may be a patch of epithelial microcysts and other signs of epithelial basement membrane dystrophy (note: it is important to examine the fellow eye carefully). More severe attacks are characterized by heaped-up loose epithelium with or without an epithelial defect.

##### Treatment

- **Acute stage:** regular prophylactic lubricating antibiotic ointment and topical cycloplegia if there is significant photophobia and pain.
- **Prophylaxis:** tear-film supplements during the day and lubricating ointment at night for 6–12 months to prevent recurrences and allow normal epithelial basement membrane adhesion.
- Hypertonic saline ointment at night is an alternative to lubricating ointment.
- Systemic doxycycline (50 mg BD) is of theoretical benefit to help reduce inflammation, especially if there is coexisting blepharitis (acts by inhibiting matrix metalloproteinase activity).
- Bandage contact lenses are helpful for symptoms as well as promoting epithelial adhesion. They should be used continuously for 2 months for this purpose.



**Interventional options**

These are indicated for severe/recurrent cases that are resistant to other treatment options:

- epithelial debridement in the acute phase if sheets of loose epithelium are present;
- phototherapeutic keratectomy: the epithelium is removed and about 5  $\mu\text{m}$  of the Bowman's layer is ablated with an excimer laser to help adhesion of new epithelium;
- anterior stromal micropuncture can be useful, but only if there is a localized area of abnormal epithelium away from the visual axis. It is performed with the bent tip of a 25G needle. Non-continuous punctures are made in the abnormal area and extending 1–2 mm into the surrounding apparently unaffected cornea.

**Bullous keratopathy****Pathophysiology**

This condition occurs as a result of endothelial decompensation. This results in corneal oedema which progresses from stromal, to epithelial microcystic and then epithelial macrocystic (bullous) oedema. It may occur due to endothelial dystrophy (especially Fuchs) or it may be associated with other/additional factors causing endothelial cell loss. These other causes include:

- intraocular surgery: aphakic and pseudophakic bullous keratopathy occur particularly following complicated cataract surgery with vitreous loss and/or an IOL placed in the anterior chamber;
- endophthalmitis: herpetic (simplex/zoster);
- corneal graft failure/rejection;
- chronic anterior uveitis;
- trauma.

**Clinical evaluation**

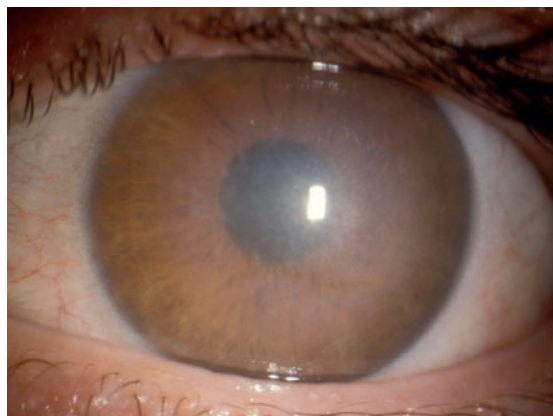Symptoms are worse in the morning and include blurred vision, lacrimation, photophobia, and pain (particularly due to rupture of macrobullae).

On examination there is stromal oedema (Descemet's folds/striate keratopathy) in the initial stages followed by epithelial oedema. In long-standing cases there may be subepithelial scarring with superficial corneal neovascularization.

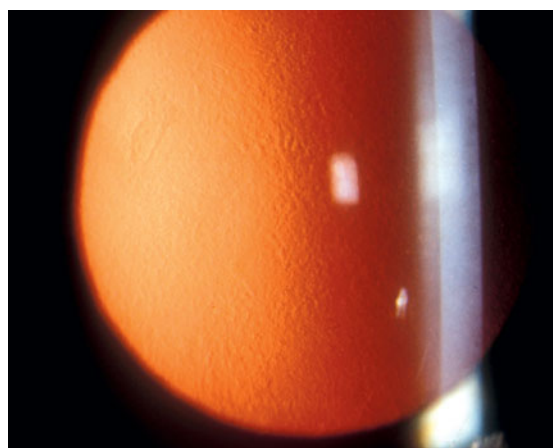
**Treatment**

This is aimed at the underlying cause.

Other treatment options are as for Fuchs endothelial dystrophy. Consider replacing an unstable anterior chamber IOL.



**Fig. 1.66** Macular dystrophy (see section 1.24).



**Fig. 1.67** Fuchs endothelial dystrophy.



**Fig. 1.68** Bullous keratopathy.

## 1.26 Contact lenses

Contact lenses can be used for various optical and therapeutic purposes. There are a variety of complications associated with contact lens wear. Soft contact lenses are the most common type of lens worn. Rigid gas-permeable lenses have a smaller diameter (9–10 mm) and have a variety of indications that are outlined below.

### Optical uses

The majority of contact lenses are used to correct simple refractive error as an alternative to glasses. Contact lenses can also be used to improve visual acuity that cannot otherwise be improved by spectacles in the following circumstances.

**High or irregular astigmatism:** such as that occurring following corneal scar, penetrating keratoplasty, or in keratoconus. Rigid gas permeable lenses are suitable for this purpose.

**Anisometropia:** this occurs due to a significant difference in the refractive error between eyes, for example if one eye is aphakic. Correction with glasses results in aniseikonia (images appear different sizes to each eye). This effect is greatly reduced with contact lenses.

**Superficial corneal irregularities** such as those occurring with superficial corneal scarring can be neutralized with a rigid gas-permeable lens to provide a more optically regular refractive interface.

### Non-optical therapeutic uses

Bandage contact lenses are plano lenses (i.e. no refractive power). Soft lenses are the most frequently used but rigid lenses are occasionally indicated. They can be used for a variety of therapeutic purposes.

**Pain relief:** for example, in bullous keratopathy where the contact lens protects exposed free nerve endings from lid movement.

**Protecting the ocular surface:** for example, after cyanoacrylate corneal glue application, and after corneal or conjunctival surgery.

**Promoting epithelial healing:** for example, with persistent epithelial defects, recurrent corneal erosions, and after surgery (e.g. refractive surgery). In these circumstances the lens acts to protect the healing epithelium from the constant rubbing action of the eyelids.

**Maintaining corneal integrity:** for example, with a descemetocle (corneal thinning down to the level of Descemet's membrane), small corneal perforation, or post-operative wound leak.

### Additional considerations

- Bandage contact lenses are available in various sizes and materials. The design used is determined by the location and nature of the disease process (e.g. large 14 mm lenses for a leaking filtering bleb). Silicone hydrogel lenses have a high oxygen permeability, are suitable for extended wear and are an appropriate first choice for most indications. The lens should centre on the cornea and a good fit is confirmed by judging the degree of movement upon blinking (should be 0.5 mm). In general, a flatter-base-curve lens will move more than a steeper lens.
- Use preservative-free medications where possible (as soft contact lenses retain preservatives and can cause corneal toxicity) and avoid the use of ointments as they will be retained by the lens and blur vision.
- Use topical antibiotics prophylaxis if there is an epithelial defect.
- Warn the patient regarding the risk of infection and replace extended-wear soft lenses every 1–2 months.

### Complications of contact lens wear

#### Microbial keratitis

This is the most serious complication (see sections 1.16–1.17). The risk is least with rigid gas-permeable lenses and maximum with extended-wear soft lenses. The risk is increased by sleeping with the

lenses in as well as with poor lens hygiene. It is important to rule out infection in any patient with an acute painful eye associated with contact lens wear. As most contact lens-associated infections are caused by Gram-negative bacteria do not treat an abrasion or suspected infection in a contact lens wearer with chloramphenicol (ineffective).

#### Epithelial defects

- Mechanical trauma, especially while removing/inserting the lens, can cause micro/macro abrasions.
- Cleaning/disinfectant solutions (hydrogen peroxide, surfactants, enzymes) if inadvertently instilled with the lens can cause diffuse punctate staining (toxic epitheliopathy).
- Tightly fitting lenses or lens overwear can cause corneal hypoxia. There may be discomfort, bulbar conjunctival injection, multiple peripheral corneal, and conjunctival punctate epithelial erosions and microcysts, and even central epithelial necrosis.
- Treatment involves avoiding lens wear until the condition has resolved (may take days to weeks), topical lubricants, prophylactic antibiotics, and ensuring that the lens fit is correct and that the lenses are not being overworn.

#### Sterile keratitis

This condition may occur as a hypersensitivity reaction to bacterial exotoxins. Symptoms consist of an acutely red eye and a foreign body sensation. Clinical signs are characterized by peripheral often multiple epithelial, subepithelial, or anterior stromal, well-demarcated white-grey infiltrates. There is minimal or no overlying epithelial defect. Treatment is as for epithelial defects (above), leaving the lens out, with the additional options of a mild topical steroid when infection has been excluded, and improving lens hygiene.

Note: infectious infiltrates are typically more central than sterile infiltrates, larger with a definite epithelial defect, and have an anterior chamber reaction. If unsure whether an infiltrate is sterile or not treat as infective.

#### Corneal neovascularization

This occurs due to chronic corneal hypoxia. It is most common with soft contact lenses and most pronounced superiorly. It is generally asymptomatic. If deep new vessels grow >2 mm inwards from the limbus then the contact lenses fit must be modified or lens wear discontinued.

#### Allergic conjunctivitis

This occurs due to an allergy to thiomersal (a preservative in contact lens solutions). This condition can occur within days or many months after first exposure to thiomersal. Symptoms of redness, itching, and burning occur soon after lens insertion. On examination there is evidence of papillary conjunctivitis.

#### Giant papillary conjunctivitis

##### Pathophysiology

This condition is thought to occur from the mechanical trauma with the lens on the upper tarsal conjunctiva amplifying a hypersensitivity response to allergens on the lens surface. It occurs with contact lenses (normally soft lenses) but can also be seen as a response to an ocular prosthesis or from protruding corneal sutures.

##### Clinical evaluation

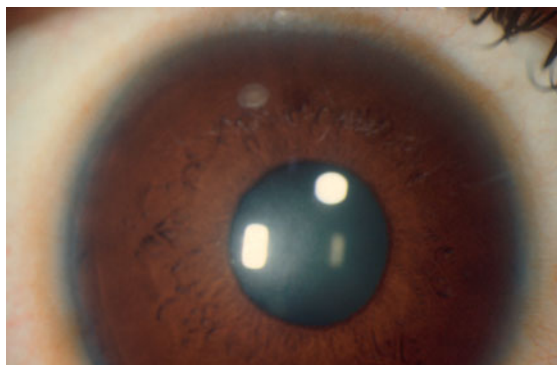
- Presentation may be months or years after commencing lens wear.
- Symptoms include contact lens intolerance, itching, and mucus discharge. Blurred vision may occur due to lens deposits.
- Signs include papillary conjunctivitis (giant papillae of greater than 0.3 mm may be present), conjunctival injection, and in severe cases a mechanical ptosis.

**Treatment**

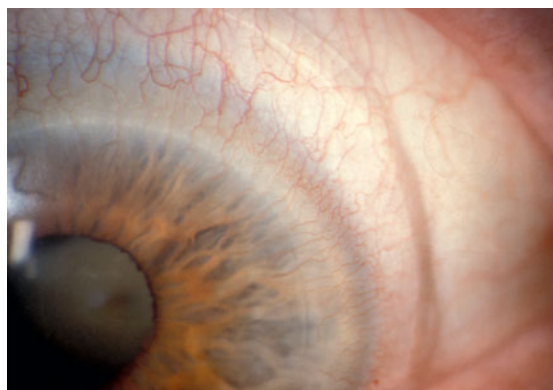This is with a break in contact lens wear or a switch to a different type of contact lens. If there is a non-contact-lens-related cause then this must be addressed (i.e. polish and clean the prosthesis, remove protruding suture). Topical mast-cell stabilizers are useful in mild disease. Topical steroid can be used if there is a prosthesis but should otherwise be reserved for acute severe attacks only.

**Other complications of contact lens wear**

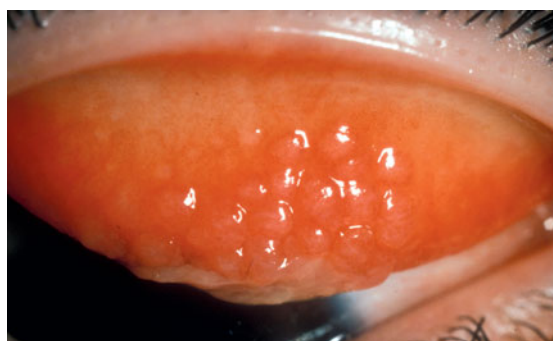- Ptosis: especially with rigid gas-permeable lenses.
- Lost lens: can become decentred, fall out, or migrate into the superior fornix. The problem of a lost lens may be compounded if repeated attempts by the patient to remove the lens cause abrasion to the ocular surface.
- Chronic contact lens use can result in irregular astigmatism due to mechanical moulding of the shape of the cornea (warping). The effect usually regresses after the lens is removed but may take weeks to months to resolve.



**Fig. 1.69** Sterile keratitis. Courtesy of John Dart.



**Fig. 1.70** Corneal neovascularization secondary to soft contact lens.



**Fig. 1.71** Giant papillary conjunctivitis.

## 1.27 Corneal ectasia

The term corneal ectasia refers to progressive thinning, weakness, and protrusion of the cornea. There are a variety of corneal ectatic disorders.

### Keratoconus

This is the most common corneal ectatic disorder, characterized by conical protrusion of the central cornea associated with apical thinning and progressive myopia with irregular astigmatism.

#### Pathophysiology

It is bilateral but usually asymmetrical (a clinically 'normal' eye may have topographic features of keratoconus). Onset is in the teens or twenties with a variable rate of progression. There is no gender predisposition and prevalence is estimated to be 1 in 2000, but it is more common in Asians. The aetiology is unknown but there are both genetic and environmental influences. Eye rubbing (allergic eye disease, Leber's amaurosis, Down syndrome) and connective tissue disorders may be contributory factors. Offspring are affected in about 8% of cases. The inheritance may be autosomal dominant with incomplete penetrance.

#### Associations

Table 1.2 Associations of keratoconus

Ocular	Systemic
VKC and AKC	Atopy: eczema, hay fever, asthma
Retinitis pigmentosa	Down syndrome (15% have signs)
Leber's amaurosis	Connective tissue diseases:
Retinopathy of prematurity	• Ehlers–Danlos syndrome
Floppy eyelids	• osteogenesis imperfecta
	• Marfan syndrome

#### Clinical evaluation

##### History

- Blurred vision that cannot be fully corrected by glasses; the optician may note increasing astigmatism.
- Other features include glare and monocular diplopia.
- A sudden decrease in vision with pain and photophobia may occur in acute corneal hydrops (see below).

##### Examination

- In early disease there may be no clinical signs and the diagnosis may only be made on topographic features (see below).
- Refraction: reveals high myopic astigmatism which is often irregular; that is, the two axes are not 90° apart.
- Retinoscopy: reveals a swirling or scissoring reflex, which is a very early sign of keratoconus.
- Slit lamp examination: central or inferior corneal thinning may be visible in more advanced disease using a thin optical section. Other slit lamp manifestations of keratoconus that may be present in moderate or severe keratoconus include:
  - striae can be seen in the posterior stroma that disappear if the globe is gently pressed (Vogt's striae);
  - fine superficial linear scars (due to breaks in Bowman's layer);
  - Fleischer's ring (epithelial iron deposition at the base of the cone, best seen with cobalt blue light).

Direct ophthalmoscopy reveals an 'oil droplet' reflex.

Munson's sign: this is a protrusion of the lower lid by the cone upon down gaze (a sign of advanced keratoconus).

**Acute corneal hydrops:** is a complication of advanced and rapidly progressive keratoconus. It develops when the Descemet's membrane and endothelium of the ectatic cornea split to allow aqueous to enter the corneal stroma with resultant bullous stromal and epithelial oedema. Acute corneal hydrops normally resolve spontaneously over 2–4 months. Treatment (e.g. hypertonic saline) does not improve outcome, although topical steroid is indicated if there is vascularization. Corneal graft surgery may eventually be indicated but it should be delayed until the optical effect of any corneal scarring can be assessed.

#### Investigations

There are a variety of techniques available to monitor progression and to detect early disease (forme fruste keratoconus). These include:

- keratometry: may reveal irregular high astigmatism. Keratometry values are increased in keratoconus. A value of 47D or greater is suggestive of keratoconus;
- pachymetry: corneal thickness is reduced, especially in the inferior half of the cornea;
- computer-assisted topography: allow quantification and detection of the cone. Computer-based algorithms have been developed to help identify early changes of keratoconus.

#### Treatment

- **Glasses:** are an option for early disease.
- **Contact lenses:** patients with early keratoconus may be able to cope with spherical/toric soft contact lenses, but rigid gas-permeable lenses are the mainstay of treatment. When these are no longer tolerated, some patients can maintain lens wear with a piggyback contact lenses (rigid gas-permeable lens worn on top of a soft lens). Scleral lenses are an option for advanced disease. When contact lenses are no longer tolerated, or if corneal scar reduces corrected vision, surgical options must be considered. Up to 20% of patients with keratoconus will require corneal graft surgery within 20 years of diagnosis. Keratoconus remains the most common worldwide indication for corneal graft surgery. There are two main options for graft surgery in keratoconus:
  - **deep anterior lamellar keratoplasty** for marked astigmatism if there is only superficial scarring;
  - **penetrating keratoplasty** is needed in patients with deep central scarring. There is a very good prognosis for graft survival (>95% with clear grafts at 5 years).

**Intracorneal ring segments:** for example INTACS, act to flatten the cornea and may delay the need for corneal graft surgery in some patients. However, the effect is variable and they have not been widely adopted.

**Riboflavin corneal collagen cross linkage (C3R):** this is a newer treatment which theoretically stabilizes and reduces the progression of keratoconus by cross-linking corneal collagen fibres with ultraviolet light after instillation of riboflavin drops. This treatment can be offered for early keratoconus but the long-term effect is unproven.



### Pellucid marginal degeneration

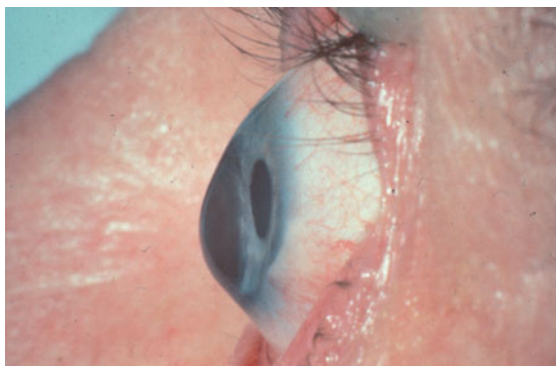This is an uncommon bilateral inferior band of thinning of the cornea, while the central cornea appears normal. It presents in the second to fifth decades of life with reduced vision due to increasing astigmatism. Large-diameter rigid contact lenses or scleral lenses may be required to improve vision. Surgical options include large eccentric lamellar keratoplasty or lamellar excision of a wedge of stroma over the thinned area of cornea.

### Keratoglobus

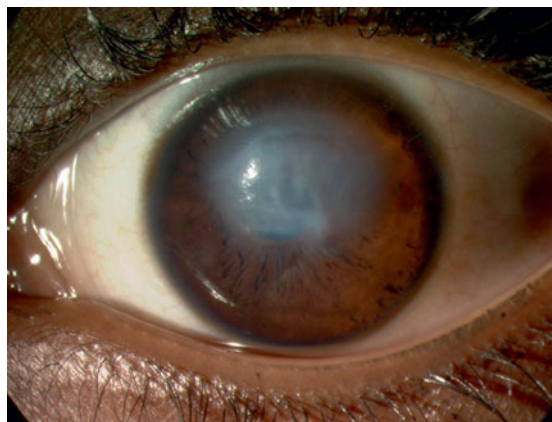
This is a bilateral rare ectatic disorder characterized by marked thinning of the entire cornea. It is susceptible to rupture from minor trauma. Treatment is with protective eyewear, scleral contact lenses, and lamellar keratoplasty. The differential diagnosis includes megalocornea (diameter  $>13$  mm with normal IOP and corneal thickness) and congenital glaucoma (diameter  $>12.5$  mm with raised IOP, Haab's striae, corneal thinning, and secondary corneal oedema).

### Posterior keratoconus

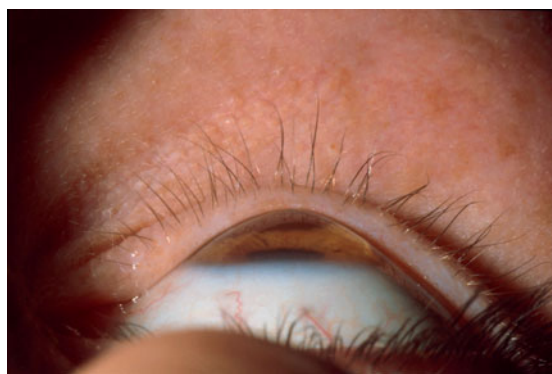This is a very rare developmental, non-progressive, usually unilateral, localized anterior protrusion of the posterior corneal surface with a normal anterior surface. Acquired cases can occur following trauma. Other ocular associations include aniridia, ectropion uveae, anterior lenticonus, and anterior polar cataract. Patients have mild astigmatism or posterior scarring. It usually does not require treatment unless scarring is central, in which case a penetrating keratoplasty may be required.



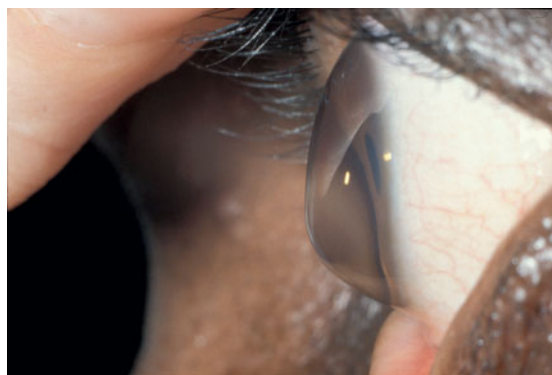**Fig. 1.72** Keratoconus.



**Fig. 1.73** Acute corneal hydrops.



**Fig. 1.74** Munson's sign. Courtesy of John Dart.



**Fig. 1.75** Pellucid marginal degeneration.

## 1.28 Keratoplasty

Keratoplasty (corneal transplantation or grafting) is an operation that replaces abnormal corneal host tissue with healthy cadaveric donor tissue. As the cornea is avascular it is an immunologically privileged site and keratoplasty is thus one of the most successful types of human organ transplant operation. A corneal graft may be full-thickness (penetrating) or partial-thickness (lamellar).

### Penetrating keratoplasty (PKP)

This is the most commonly performed type of corneal transplantation. There are a variety of indications.

- **Optical:** to establish a clear visual axis or reduce distortion that cannot be corrected with other means. Disease indications for this include: keratoconus, bullous keratopathy, Fuchs endothelial dystrophy, other dystrophies, and scarring from trauma or infection.
- **Therapeutic:** removal of diseased tissue may be necessary for advanced microbial keratitis that is not responsive to antimicrobial therapy (e.g. fungal).
- **Tectonic:** to provide structural support with corneal thinning, or imminent or actual perforation.

### Preoperative considerations

It is important to evaluate and treat factors associated with a poor prognosis prior to surgery. These factors include:

- **ocular surface abnormalities:** blepharitis, trichiasis, entropion, ectropion, dry eye disease, and/or conjunctivitis;
- **corneal neovascularization:** the greater the extent (number of involved clock hours and stromal depth of vessels) the worse the prognosis;
- **previous surgery:** particularly a previous failed graft;
- **glaucoma:** should be controlled before surgery;
- **uveitis:** should be well controlled before and after surgery.

Other factors to consider include:

- **visual potential:** check for other conditions that may be responsible for poor vision in the presence of corneal disease (retinal, macular, optic nerve dysfunction);
- **pre-existing cataract:** if this is present consider a triple procedure (PKP, cataract extraction, and IOL insertion).

### Intraoperative management

- Surgery can be performed under local or general anaesthetic (general preferred as less intraoperative orbital pressure).
- Instil topical miotic (e.g. pilocarpine 2%) or mydriatics if combined cataract surgery is planned.
- Inspect the graft material for any obvious defects (media and graft should be clear).
- Consider stabilization of the eye with a scleral fixation ring (e.g. Flieringa ring) if the eye is aphakic (to prevent scleral collapse).
- Select host bed and donor graft size. There is a greater risk of glaucoma, vascularization, and rejection with a larger graft (>8.5 mm) and more astigmatism with smaller grafts (<6.5 mm). In keratoconus the size and location of the cone must be taken into account. In general a 7.5 mm recipient bed size is suitable for most cases, with the graft centred on the cornea. The graft size should be 0.25–0.5 mm larger than the recipient bed.
- Manual or automated trephines are available to prepare the host and donor buttons.
- Suturing of the donor to the graft is carried out as follows: four cardinal sutures are placed at 12, 6, 3 and 9 o'clock with 10/0 nylon. Additional sutures are placed with: either interrupted alone (total of 16–24 bites), continuous running, or a combination of interrupted (8–16) and a continuous running

suture. The depth of the suture should be to 90% corneal thickness. All knots should be buried in the host.

### Postoperative management

#### Medications

- Topical steroids are necessary to reduce the risk of graft rejection. The intensity of treatment should be tailored to the individual and the perceived risk of rejection. Drops are often instilled every 1–2 hours for the first few days after surgery and then reduced to QDS for several weeks and slowly tapered down to stopping over 1 year or more if necessary.
- Prophylactic topical antibiotic drops are necessary in the first few weeks after surgery.
- Oral acyclovir (400 mg BD) is used as prophylaxis in patients who have previously had HSK disease.
- Oral steroid and immunosuppression are used in high-risk cases.

#### Follow-up

This also needs to be tailored to the patient and their disease process. Follow-up is normally day 1 postoperative and then at 1 week, 2 weeks, and 1 month postoperative, monthly for 2–3 months, and then every 3–6 months thereafter. It is important to emphasize to the patient prompt attendance if there are problems postoperatively.

#### Suture removal

Loose or broken interrupted sutures should be promptly removed due to the risk of infection or graft rejection. A broken continuous suture should be spliced if it is too early to remove it. Sutures are normally left *in situ* for at least 1 year when, depending on astigmatism and wound healing, they are removed selectively or completely.

#### Contact lenses

Rigid gas-permeable lenses may be needed to correct high astigmatism once all sutures have been removed. Refractive procedures (see section 1.33) can also be used to reduce post-graft astigmatism.

### Lamellar keratoplasty

This may be indicated in patients who present with corneal tissue disease that does not involve the full thickness of the cornea.

Advantages of lamellar keratoplasty include:

1. shorter rehabilitation time;
2. reduced risk of immunological graft rejection;
3. the eye is stronger and able to resist trauma better;
4. material with a low endothelial cell count unsuitable for PKP can be used for anterior lamellar surgery;
5. less postoperative astigmatism with posterior lamellar grafts.

Disadvantages of lamellar keratoplasty include:

1. lamellar techniques are technically more demanding;
2. there is the risk of interface opacification and final acuity may not be as good as a PKP;
3. posterior lamellar discs can dislocate postoperatively and there is a higher risk of primary graft failure than after PKP due to added manipulation.

There are a variety of techniques for lamellar graft surgery. Current techniques include the following.

- **Deep anterior lamellar keratoplasty:** The anterior corneal lamella (epithelium and ideally all of the stroma) is replaced. Indications for this technique include keratoconus, anterior corneal dystrophies/degenerations, and superficial corneal scarring. Different techniques can be used to separate the host tissue such as manual dissection or air injection. A full-thickness donor is used.

- *Descemet's stripping endothelial keratoplasty*: the host posterior corneal lamella (endothelium and Descemet's membrane) is stripped manually and is replaced by the similar tissue attached to a thin layer of posterior stroma. The main indication for this technique is Fuchs endothelial dystrophy and bullous keratopathy after previous cataract surgery.

## Keratoprotheses

This is an artificial corneal implant that may be used in patients who are unsuitable for keratoplasty. Surgery is technically challenging. The osteo-odonto-keratoprosthesis uses a patient's tooth root and alveolar bone to support the central optical cylinder.

## + Removal of corneal sutures

### Background/indication

Loose sutures can stimulate neovascularization and act as a focus for infection.

**Phaco wound:** remove at the postoperative follow-up visit (1–4 weeks).

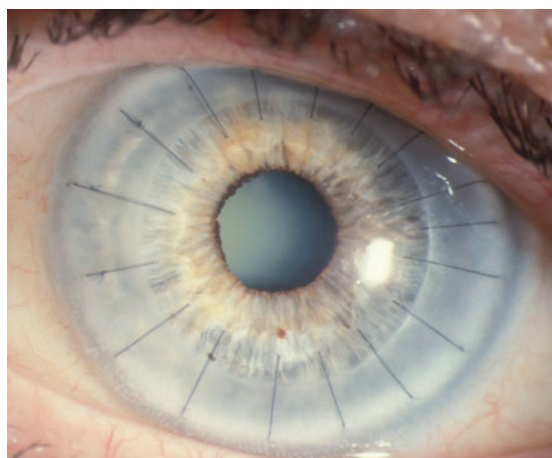
**Extracapsular cataract extraction (ECCE) wound:** remove selective or all sutures after 2 months.

**Keratoplasty:** see under PKP section.

### Technique

- Removal of sutures can be performed at the slit lamp or under the operating microscope.
- Instil topical anaesthetic and diluted betadine (5%).
- Use a 25G needle advanced parallel to the corneal surface to lift and cut the suture.
- Pull the cut end in the direction of the suture (not perpendicular) with fine forcep (e.g. Max Fine). If the suture breaks leave the buried part but remove any exposed ends.
- Apply topical antibiotic immediately. Prescribe topical antibiotic (g. chloramphenicol QDS for 3 days).

In corneal graft patients also give topical steroid (g. dexamethasone 0.1% QDS for 2 weeks then BD for 2 weeks). Warn the patient regarding the risk of infection or rejection.



**Fig. 1.76** Clear corneal graft following penetrating keratoplasty.



## 1.29 Complications of keratoplasty and graft rejection

### Early postoperative complications

**Wound leak:** this presents with a low IOP, a shallow anterior chamber, and a positive Seidel's test. Conservative treatment with a bandage contact lens may suffice but re-suturing is indicated if the leak persists.

**Persistent epithelial defects:** these are common if there is pre-existing ocular surface disease such as dry eye or exposure. If there is also stromal loss it is important to exclude microbial keratitis as a cause. Treatment is with intensive tear-film supplements, bandage contact lens, tarsorrhaphy (including ptosis by botulinum toxin), and treating the underlying cause.

**IOP rise/glaucoma:** this can occur in the immediate postoperative period and/or in the long term. Potential mechanisms include: angle closure, retained viscoelastic in the anterior chamber, inflammation, or suprachoroidal haemorrhage. Treatment should be tailored to the underlying cause (see Chapter 7).

**Suture infiltrates:** these can be either immune-mediated (multiple sutures affected, usually on host side, no epithelial defect) or infectious (solitary with epithelial defect).

**Primary (early) graft failure:** this presents with irreversible corneal oedema in the immediate postoperative period (from day 1–2). It occurs due to inadequate endothelial function which may be pre-existing in the donor graft or induced by surgical trauma. Treatment is with a regraft if the oedema persists.

**Other early complications include:** inflammation and cystoid macular oedema, infection (including endophthalmitis), hyphaema, iris ischaemia with fixed dilated pupil (Urrets-Zavalía syndrome), or loose sutures.

### Late postoperative complications

**Late graft failure:** this is usually due to graft rejection (see below). Other causes of late graft failure include late endothelial failure, recurrence of the primary disease process, (e.g. HSK, corneal dystrophies), infection, or persistent epithelial defect.

**Other late complications** include astigmatism, glaucoma, or retrocorneal membranes.

### Graft rejection

#### Pathophysiology

This occurs due to a type IV immune hypersensitivity reaction. It rarely occurs within 2 weeks of surgery but it can occur at any time after PKP. The vast majority of cases occur within 1 year of surgery and the risk then declines. It occurs in about 30% of all grafts and is the most common cause of graft failure. It can be epithelial, stromal, or endothelial. Most episodes of graft rejection do not cause irreversible graft failure if recognized early and treated aggressively.

#### Risk factors

These include young age, previous graft surgery, preoperative deep stromal vascularization, glaucoma, postoperative loose/broken/vascularized sutures, large/eccentric grafts, and previous/current active inflammation.

#### Clinical evaluation

Symptoms include redness, photophobia, irritation, and/or decreased vision. Rejection episodes may rarely be asymptomatic.

Most episodes are directed against the endothelium, but patients can manifest a combination of epithelial, stromal, and endothelial rejection. For the sake of simplicity it is useful to consider the clinical features of each individually.

#### Epithelial rejection

This is relatively uncommon in isolation and characterized by a linear epithelial ridge that advances centrally. It responds rapidly to topical steroid treatment.

#### Stromal rejection

This normally accompanies endothelial rejection and rarely occurs in isolation. It is characterized by subepithelial circular opacities and there may also be anterior uveitis.

#### Endothelial rejection

This is the most common form of graft rejection. It is the most serious form of rejection as endothelial cells that are destroyed by the host response can only be replaced by a further graft procedure. It may be characterized by an endothelial rejection line (Khodadoust line) that often begins at a vascularized portion of the peripheral graft–host junction and progresses across the endothelial surface over several days. The rejection line consists of white cells that damage endothelial cells as the line sweeps across the endothelium. A mild/moderate anterior chamber reaction is present. The damaged endothelium is unable to properly dehydrate the corneal graft. The donor cornea is clear ahead of the rejection line and is cloudy and oedematous behind it.

Another variant of endothelial rejection is the diffuse formation of keratic precipitates on the donor endothelium with an anterior chamber reaction. In this type of rejection stromal oedema is generalized throughout the graft.

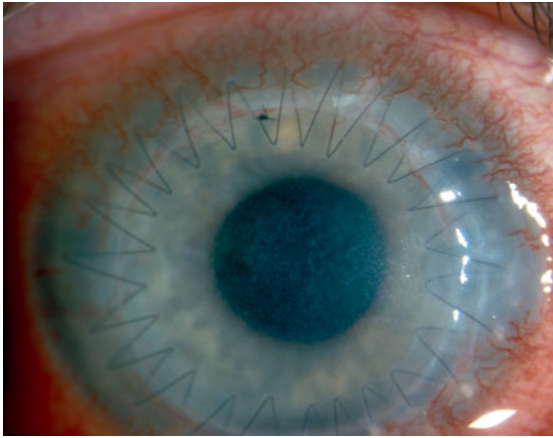
#### Treatment

The clinician should have a low threshold for initiating treatment against graft rejection in any graft patient with significant signs of inflammation.

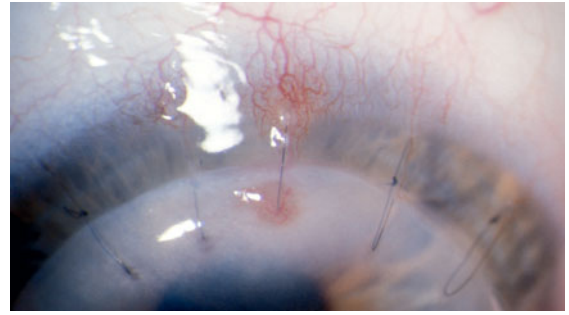
- Intense topical steroids (e.g. g. prednisolone 1% or g. dexamethasone 0.1% hourly) followed by slow tapering depending on the initial response is the mainstay of treatment.
- Consider peri-ocular/systemic steroids in severe cases or if there are doubts about compliance.
- Oral steroid or pulsed steroid are often used but probably do not improve the outcome compared to topical treatment alone.
- Treat inciting factors such as removing loose vascularized sutures.

#### Prognosis

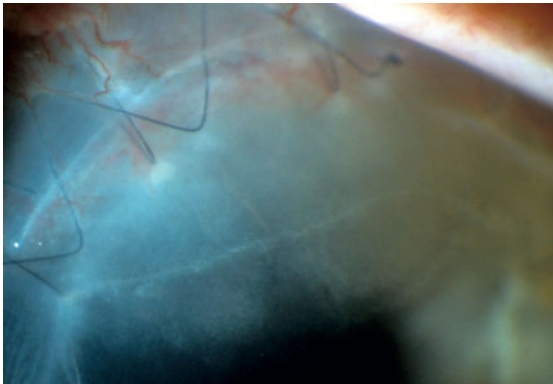
Some 5–10% of all cases of rejection result in graft failure. The earlier and more aggressively the rejection episode is treated, the better the prognosis.



**Fig. 1.77** Endothelial graft rejection. Note the vascularization at the graft–host junction.



**Fig. 1.79** Vascularization associated with a suture.



**Fig. 1.78** Endothelial graft rejection. Note the endothelial rejection line (Khodadoust line).

## 1.30 Anterior uveal tumours

Uveal melanomas are malignant neoplasms that arise from neuroectodermal melanocytes within the iris, ciliary body, and choroid (see Chapter 3 for choroidal melanoma). Uveal melanomas are much more common in Caucasians (blue/grey iris) than Africans and have the potential to metastasize.

### Iris melanoma

Iris melanomas are the least common (approx. 5%) of all uveal melanomas and typically present in the 40s–50s (10–20 years earlier than ciliary body and choroidal melanomas). Histologically, most comprise a mixture of spindle and epithelioid melanoma cells. Risk factors for developing iris melanoma include exposure to ultraviolet light, ocular melanocytosis, and dysplastic naevus syndrome.

#### Clinical evaluation

##### History

- Usually asymptomatic or incidental finding on examination.
- Enlargement/change in pre-existing spot on iris.
- Visual disturbance due to secondary cataract.
- Occasionally pain from raised IOP.

##### Examination

- Pigmented (occasionally non-pigmented) iris lesion, usually well circumscribed with smooth or irregular surface.
- Raised IOP may occur due to pigment clumping in the trabecular meshwork, direct invasion of the angle, or neovascular angle closure (see Chapter 7).
- Spontaneous hyphaema may occur from tumour vessels.
- Features associated with malignant potential include larger size (>3 mm) and thickness (>1 mm), irregularity, vascularity, faster growth, localized cataract, and effect on adjacent structures (pupil distortion, ectropion uveae). However, pupil distortion, ectropion uveae, and failure of the pupil to dilate in the zone of the lesion can also occur with benign naevi.

##### Investigations

- Anterior segment photography (including angle if relevant) to document location, size, shape, colour, and vascularity to monitor growth.
- Ultrasound biomicroscopy to assess size, shape, extension to ciliary body, and internal characteristics. Differentiates solid from cystic lesions and helps to monitor characteristics after treatment.
- Anterior segment fluorescein angiography may be helpful to assess the vascularity of tumour and help differentiate benign from malignant lesions.
- Options for obtaining cells/tissue for diagnosis include fine-needle aspiration cytology, aqueous sampling, and incisional or excisional biopsy.

##### Differential diagnosis

- Iris naevus: small (<3 mm in diameter, <0.5 mm thick) pigmented and well-defined stromal lesion.
- Ciliary body melanoma with iris invasion (see below).
- Lisch nodules: small, multiple, bilateral iris lesions in patients with neurofibromatosis.
- Freckles: smaller than naevi, frequently multiple and bilateral.
- Cysts of iris pigment epithelium: unilateral, solitary, dark-brown cysts that transilluminate.
- Cyst of iris stroma: presents in the first year of life as a solitary unilateral cyst with a translucent anterior wall and contains fluid.

Can remain dormant for many years and later enlarge causing glaucoma/corneal decompensation.

- Metastatic carcinoma to iris: rare, pink/yellow solitary mass/multiple deposits with fast growth. Can cause hyphaema, pseudohypopyon, and raised IOP.
- Leiomyoma of iris: rare benign tumour arising from smooth muscle.
- Juvenile xanthogranuloma: rare dermatological disorder with possible uveal nodules.
- Inflammatory granulomas (e.g. sarcoidosis, tuberculosis).
- Adenoma/adenocarcinoma of iris pigment or ciliary epithelium.

#### Treatment

- Observation of suspicious lesions for growth or for glaucoma indicative of angle invasion.
- Excision: iridectomy for small lesions with iris reconstruction (suturing or prosthesis). Iridocyclectomy for those involving the angle.
- Plaque radiotherapy: with local plaques or external radiation for surgically non-resectable tumours.
- Enucleation: for diffuse tumours, extensive seeding into aqueous, ring angle invasion, trans-scleral extension, or blind, painful eyes due to tumour-related complications.

#### Prognosis

- Most patients who undergo tumour excision do not develop metastatic disease.
- Mortality is 0–3% in the absence of ciliary body involvement.
- Indicators of worse prognosis include large lesions, involvement of the ciliary body, ring angle invasion, and extrascleral extension.
- Need monitoring to look for recurrence or satellite lesions (every 6 months for first 3–5 years, then yearly).

### Ciliary body melanoma

These account for approximately 10% of uveal tumours, most commonly present in the sixth decade, and histologically are more commonly composed of epithelioid melanoma cells than uveal melanomas at other sites. Ciliary body melanomas have the worst prognosis of all uveal melanomas. This may be due to a delay in diagnosis as the tumour is hidden behind the iris as well as the great access for haematogenous spread.

Risks factors include uveal naevus, family history of uveal melanoma, congenital ocular melanocytosis, dysplastic naevus syndrome, and xeroderma pigmentosum.

#### Clinical evaluation

##### History

- Asymptomatic until growth affects neighbouring ocular structures or it impinges on the visual axis.
- Blurred vision from lenticular astigmatism/cataract development or via intraocular haemorrhage.
- Gradual visual loss if posterior extension occurs.
- Pain from acute secondary angle closure glaucoma.
- Red eye from dilated episcleral vessels ('sentinel vessels') in the same region as the tumour.
- Systemic features of malignancy: weight loss and night sweats.

##### Examination

- 'Sentinel vessels'.
- Dark-pigmented mass posterior to the pupil.

- Epibulbar mass due to extraocular extension of the tumour (may mimic conjunctival melanoma).
- Erosion through the iris root (can mimic iris melanoma).
- Pressure on the lens can cause subluxation and/or cataract.
- Raised IOP.

#### Differential diagnosis

- Other ciliary body tumours: medulloepithelioma (from non-pigmented ciliary epithelium), metastases, melanocytoma (benign), adenoma.
- Iridociliary cysts: these have a different ultrasound appearance.
- Uveal effusion syndrome: rare, idiopathic condition with choroidal and exudative retinal detachments.

#### Investigations

- Transillumination through pupil/sclera can help show the extent of the tumour.
- Gonioscopy and dilated fundus examination.
- B scan: solid, acoustically dark mass; can help estimate tumour size and extraocular extension.
- Consider incisional or excisional biopsy.
- Chest X-ray, liver-function test, and liver ultrasound if malignant spread is suspected (although 98% of patients have no detectable extraocular metastatic disease at time of diagnosis of ocular tumour).

#### Treatment

- The following need to be taken into account when planning treatment: general considerations about patient characteristics (age, health, systemic metastasis) and tumour characteristics (size, location, intra/extraocular extension, histology if biopsy taken).
- Observation: if diagnosis uncertain and especially if tumour <2 mm.
- Plaque brachytherapy: for medium-sized tumours (10–15 mm).
- Sclerouvectomy: block excision leaving 2–3 mm clear margin in tumours involving fewer than 4 clock hours circumference.
- External beam irradiation by protons or gamma knife but side effects may be severe: for medium-sized tumours.
- Enucleation (it is uncertain whether this improves survival).
- Exenteration: if extensive extrascleral extension or recurrence after enucleation.

#### Prognosis

- Mortality rate of 30–50% at 10 years from the time of diagnosis.
- Poor prognostic factors include larger size, extrascleral extension, older age, extent of metastatic spread.
- Visual prognosis is guarded.
- Follow-up initially 3 monthly and then 6 monthly with liver-function-test monitoring for metastatic spread.

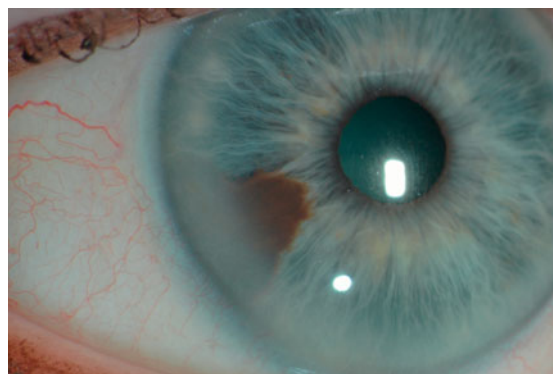


Fig. 1.80 Benign iris naevus.

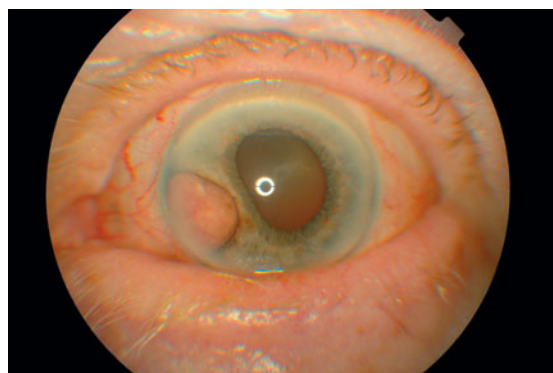


Fig. 1.81 Amelanotic iris melanoma.

## 1.31 Anterior segment trauma

There are a variety of terms used to describe the mechanisms and manifestations of trauma to the globe. These are not necessarily mutually exclusive (for example, a laceration can result in an open injury).

**Closed injury:** an intact corneo-scleral globe wall, usually occurring due to blunt trauma.

**Open injury:** a full-thickness defect in the corneo-scleral wall. This can be due to blunt rupture or a sharp perforating/penetrating/lacerating injury.

**Penetrating injury:** a single, full-thickness defect secondary to an object entering the globe without exiting. This occurs with a retained foreign body.

**Perforating injury:** an object has entered and exited the globe through two separate sites. This occurs with a gun shot/missile injury.

**Laceration:** a partial- or full-thickness defect in the corneo-scleral wall caused by a sharp object at the site of impact.

**Rupture:** where there is a full-thickness defect in the corneo-scleral wall secondary to a blunt injury. The defect is at a weak point (often a previous surgical wound or under the insertion of the rectus muscles), not necessarily at the site of impact.

### Open globe injury

#### Clinical evaluation

Ocular trauma can occur in isolation or it can occur with head and/or systemic injury. The diagnosis and treatment of potentially life-threatening injuries takes precedence over the management of eye injuries.

#### History

Note the exact mechanism of injury. Risk factors for open globe injury include metal striking metal (e.g. hammering, grinding), high-velocity projectile (e.g. squash ball, bullet), lack of eye protection, and/or previous intraocular surgery when the old wound may rupture.

#### Examination

- Evaluate associated facial/orbital injuries (see sections 2.13 and 10.9).
- The visual potential of the eye must be assessed and the visual acuity must be accurately documented. It is also essential to fully examine and document the afferent pupil response as it may not be possible to see the fundus.
- A complete ocular examination should be conducted with particular attention to signs suggestive of an open globe injury. These include full-thickness eyelid laceration, conjunctival laceration, shallow anterior chamber; iridocorneal contact, hypotony, hyphaema, lens-capsule defect, and/or lenticular opacity.
- Signs diagnostic of open globe injury include exposed uvea and/or vitreous, positive Seidel test, and/or visualization of an intraocular foreign body.
- If open globe injury is suspected, it is important to avoid pressure on the globe during examination.

#### Investigations

B-Scan ultrasound scan may be useful if there is no fundal view to assess signs of posterior segment trauma (see section 3.19). It can also be of use for detecting intraocular foreign bodies.

Plain X-ray is a useful test for detecting metallic intraocular foreign bodies. At least two radiographs should be performed in at least two positions of gaze.

Computed tomography (CT) scanning has largely superseded X-rays not only for detecting intraocular foreign bodies but also for looking at the integrity of the surrounding orbital bones.

#### Treatment

##### Preoperative care

If surgery is indicated, it should be performed as soon as practical to reduce pain, devitalization of prolapsed uveal tissue, inflammation, risk of suprachoroidal haemorrhage, and risk of endophthalmitis. The following measures should be taken prior to surgery.

- Provide medication as necessary for pain and to prevent vomiting.
- Provide tetanus prophylaxis if necessary.
- Apply a protective plastic shield (avoid padding due to resultant pressure on the globe).
- Admit and prepare the patient for theatre: make the patient nil by mouth, inform theatres, and inform the anaesthetist.
- Consent: discuss examination under anaesthesia, guarded prognosis for visual recovery, need for evisceration/enucleation if the eye is beyond repair, and need for further treatment/surgery.
- Consider performing biometry (see section 6.11) of the other eye if there is a possibility that lens extraction along with IOL insertion may be considered at the time of primary repair (see discussion below).
- Start systemic antibiotics (e.g. moxifloxacin 400 mg OD or ciprofloxacin 750 mg BD).

##### Non-surgical care

Small, self-sealing, partial-thickness and/or well-opposed wounds can be observed without the need for surgical intervention. Application of a bandage contact lens, topical antibiotic therapy, topical cyclopegia, and close observation are necessary.

##### General principles of primary repair of corneo-scleral lacerations

- The primary goal for initial repair is to restore the integrity of the globe. The secondary goal, which can be achieved at the time of primary repair or during secondary procedures, is to restore vision by means of repairing damaged intraocular structures.
- If there is a very poor prognosis for the restoration of vision, enucleation or evisceration (see section 10.10) must be considered to reduce the risk of sympathetic ophthalmia (see section 5.5). In the vast majority of cases, primary repair is preferable even if only to allow the patient time to come to terms with the possibility of losing the eye (as a secondary procedure within the 12–14 day period before the injured eye can incite sympathetic ophthalmia).
- General anaesthesia is almost always required for repair as periocular anaesthesia will increase the pressure on the open globe.

##### Surgical principles of primary repair of corneo-scleral lacerations

- Place 5% povidone iodine in the conjunctival sac.
- Try to minimize pressure on the globe from the speculum.
- Clean and remove any debris, including foreign bodies, from the periocular area.
- Make a paracentesis and re-form the anterior chamber with viscoelastic.
- The corneal component of the injury should be approached first. If vitreous or lens fragments have prolapsed through the wound, they should be cut flush with the cornea and removed from the wound. If uvea or retina protrudes it should be gently swept back



into the eye via the paracentesis. Only when the uveal tissue is necrotic should it be excised.

- Repair the limbus first (9.0 nylon) then cornea (10.0 nylon interrupted). Bury the knots away from the visual axis.
- The sclera component is approached via a conjunctival peritomy, being careful to visualize the posterior extension of any laceration and exclude a defect in the thin sclera beneath the insertion of the rectus muscles. Repair the sclera with 9.0 nylon or an absorbable suture beginning anteriorly and progressing posteriorly. If the laceration extends underneath a rectus muscle, the muscle must be placed on a suture and disinserted before being re-attached after the sclera has been repaired.
- The conjunctiva should be closed with 8.0 vicryl.
- Once the globe has been repaired, repair of intraocular structures can be carried out either as a primary procedure or as a separate secondary procedure. Potential anterior segment procedures include removal of anterior intraocular foreign bodies, iris repair, lens extraction, anterior vitrectomy, and IOL insertion.
- Administer subconjunctival steroid and antibiotic.
- Intravitreal antibiotic injection should be considered for contaminated wounds involving the vitreous.

#### Postoperative care

Topical steroid, antibiotics, and cycloplegia. Oral antibiotic for open injuries.

## Specific anterior segment injuries

Note: cyclodialysis, angle-recession glaucoma, and hyphaema are not covered here but instead are covered in Chapter 7. Iritis can occur secondary to trauma (traumatic iritis) and the management of this is covered in Chapter 5.

### Subconjunctival haemorrhage

The occurrence of intraconjunctival/subconjunctival blood is often alarming to the patient but generally resolves spontaneously over 10–14 days. Causes include trauma (conjunctival, including eye rubbing; orbital; cranial, base-of-skull fracture), valsalva (vomiting, coughing), ocular/peri-ocular surgery, infectious conjunctivitis (e.g. adenoviral, *Streptococcus*), and systemic disease (bleeding diathesis, hypertension). There is often no positive identifiable predisposing factor. If there is a history of trauma it is important to rule out other ocular injuries (including globe rupture under an elevated subconjunctival haemorrhage). No treatment is generally required except reassurance. Lubrication may be needed to prevent dellen in cases of elevated haemorrhage.

### Conjunctival/corneal foreign body

It is essential to evert the upper eyelid in all patients in whom a foreign body is suspected. Vertical linear superior corneal abrasions are commonly seen when there is a superior subtarsal foreign body. Double eversion of the upper lid with a Desmarres retractor may be necessary to visualize the foreign body if it is high on the tarsus or in the superior fornix. The technique for removal of the foreign body is explained below. After complete removal the patient should be treated with chloramphenicol ointment QDS for 1 week.

### Corneal abrasion

Corneal epithelial injury or loss usually causes acute pain, lacrimation, photophobia, and blepharospasm. Causes include trauma with finger, nail, paper edge, plant, or blunt instrument. It can also be associated with contact lens; for example, tight lens, overwear, and attempts at insertion/removal. Corneal abrasions can occasionally result in recurrent corneal erosions. Corneal abrasions stain brightly with fluorescein and should be examined carefully on the slit lamp to exclude a deeper corneal laceration or a corneal ulcer secondary to infection/inflammation (infiltrate present). Descemet's folds can occasionally be seen secondary to corneal abrasions due to stromal overhydration (in the absence of the normal epithelial barrier that prevents this). Depending on the size (large abrasions take longer

to heal) and location (peripheral abrasions heal more quickly than central ones). Healing normally occurs within 7 days.

#### Treatment

- Topical antibiotics (e.g. chloramphenicol ointment 3–4 times/day) and cycloplegic (e.g. cyclopentolate 0.5–1% BD-TDS).
- Pressure patching delays the time taken for healing to occur and is not of benefit.
- Abrasions related to contact lens wear should be monitored for infection (consider broad-spectrum antibiotics, e.g. ofloxacin).
- Topical anaesthetics should not be used for pain relief (except to facilitate examination) as they interfere with healing.

### Iridodialysis

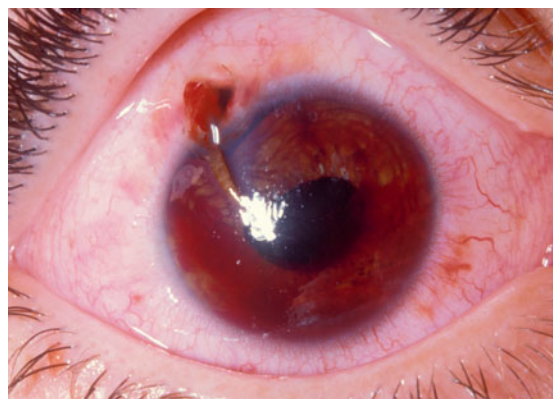Iridodialysis refers to the separation of the iris root from the ciliary body and occurs due to trauma (including surgical trauma). It is usually associated with hyphaema. It may be asymptomatic or may cause glare and/or monocular diplopia. A small dialysis may be left untreated but a large dialysis causing symptoms may need surgical repair. It is important to exclude associated injuries such as angle-recession glaucoma and retinal dialysis.

### Iris sphincter damage

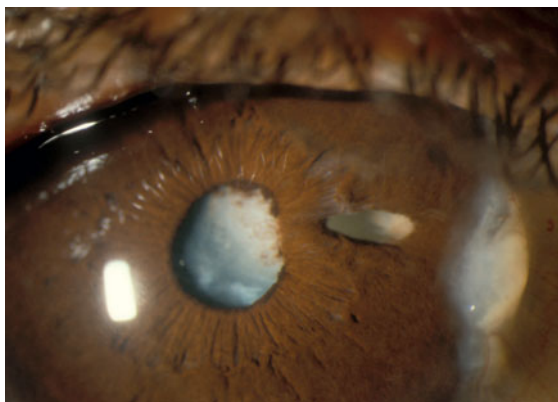
This occurs due to blunt trauma and is characterized by small notches in the pupillary margin representing defects in the sphincter pupillae muscle. This can result in an increase in pupil size (mid-dilated) and/or distortion of the pupil. Usually no treatment is needed except for associated injuries and hyphaema. If there is significant glare from increased pupil size then pilocarpine drops or a painted contact lens are therapeutic options.

## + Removal of corneal foreign bodies

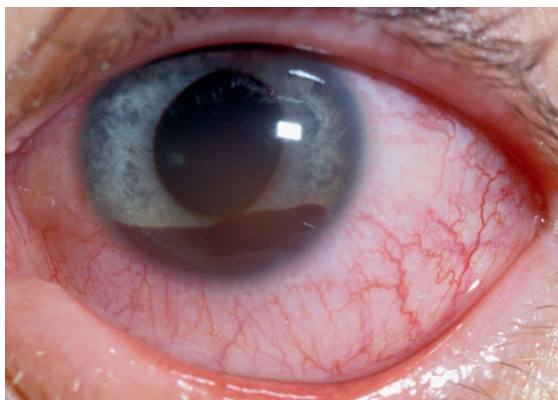
- Instil topical anaesthetic.
- It is important to ensure that the patient is fixating adequately with the non-involved eye before commencing.
- Superficial and loose foreign bodies can be irrigated away with sterile saline or manually removed with a moist cotton bud.
- Impacted/deep foreign bodies can be removed with the tip of a 25G needle. The needle can be mounted on a syringe to allow easier handling. The tip of the needle can be bent over to create a hook by pressing on the inside of the plastic needle sheath.
- Ideally one hand should be used to hold open the eyelids and the needle applicator, leaving the other hand free to control the slit lamp to ensure that adequate focus and illumination are maintained throughout.
- The needle is advanced parallel to the surface of the cornea with the bevel up and the foreign body removed.
- If there is an associated rust ring, it can be removed with a needle if it is very superficial or with a dental burr if the rust has penetrated the anterior stroma.



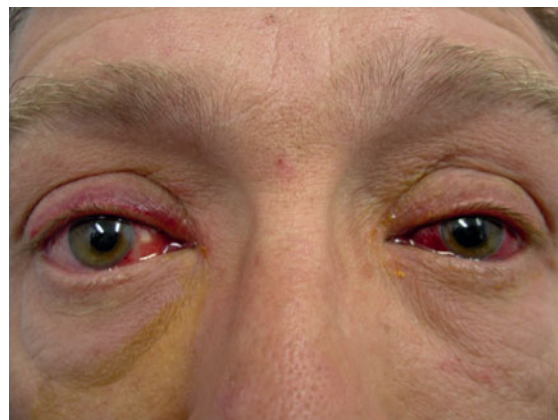**Fig. 1.82** Penetrating globe injury. Note the full-thickness corneo-scleral laceration with iris prolapse.



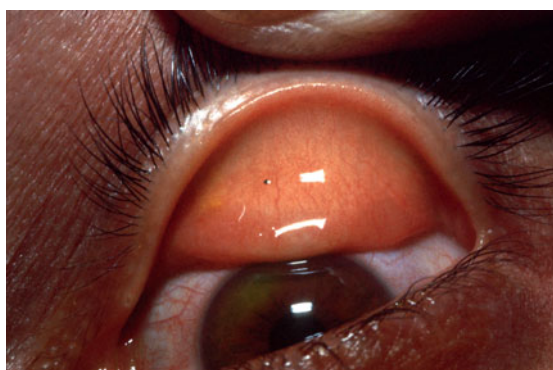**Fig. 1.83** Sequelae of penetrating globe injury. Note the raised corneo-scleral scar, the full-thickness iris defect, and the traumatic cataract.



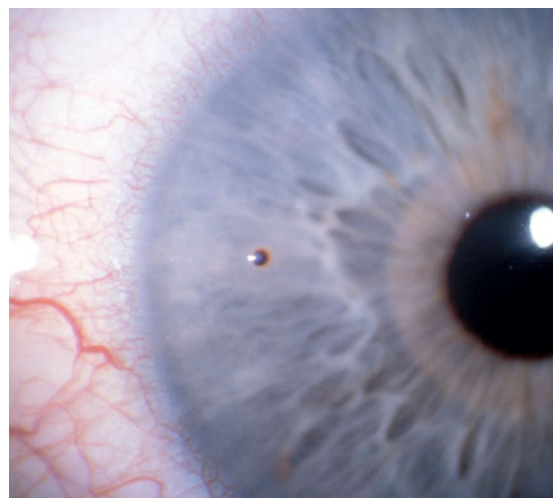
**Fig. 1.84** Hyphaema (also see Chapter 7).



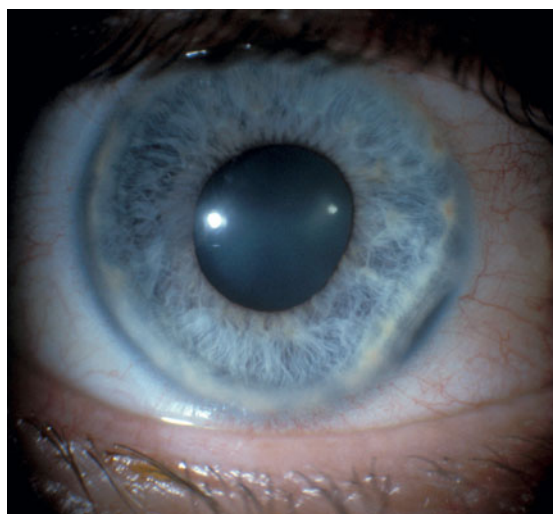
**Fig. 1.85** Bilateral subconjunctival haemorrhage.



**Fig. 1.86** Sub tarsal foreign body.



**Fig. 1.87** Corneal foreign body.



**Fig. 1.88** Iridodialysis.



*This page intentionally left blank*

## 1.32 Chemical injury

Chemical injury is a potentially blinding situation that generally occurs as a result of industrial/domestic accidents or assault. It is a true ophthalmic emergency where prompt early management may improve the long-term prognosis.

### Pathophysiology

The effect of chemicals on the eye depends on the nature (alkali or acid), strength (pH), duration/area of contact, and associated injury (thermal and physical, e.g. exploding battery, concurrent eyelid injury). Alkali injuries are more severe than acid or thermal injuries. Alkalis cause saponification (turning to soap) of the cell membrane, which results in cellular disruption. Once the surface epithelium is damaged, the alkali can penetrate deep into the stroma, destroying the proteoglycan ground substance and collagen fibres of the stromal matrix. The limbal stem cells are also vulnerable. They can be damaged directly or secondarily due to ischaemia after destruction of the vascular endothelium of the blood vessels that supply them. Strong alkalis can also penetrate into the anterior chamber and cause intraocular inflammation and damage. Acids on the other hand cause immediate precipitation of proteins that limit further penetration. Strong acids like sulphuric acid and hydrochloric acid can, however, still cause severe damage.

### Acidic agents

These include:

- sulphuric acid ( $\text{H}_2\text{SO}_4$ ): battery fluid and industrial use;
- hydrochloric acid (HCl): bleach, pool-cleaning fluid, and industrial use;
- hydrofluoric acid (HF): glass/metal manufacturing and semiconductors. It is a weak acid but one of the most destructive agents due to the highly reactive ( $\text{F}^-$ ) anion, and it causes severe ocular and systemic injury.

### Alkali agents

In decreasing order of severity these include:

- ammonia ( $\text{NH}_3$ ): fertilizer, refrigerant and chemical industry;
- sodium hydroxide (NaOH, caustic soda): drain and oven cleaner, soap/detergent, and paper industry;
- potassium hydroxide (KOH, caustic potash): alkaline batteries, soaps/detergent;
- calcium hydroxide ( $\text{CaOH}_2$ , lime): plaster, cement.

### Initial management

- Management should be started immediately at the site of the incident and consists of copious irrigation of the eye with normal saline or an equivalent. The eye should be held open and irrigation continued for at least half an hour during transfer for further assessment. The pH should be determined as soon as possible, upon arrival to the hospital (i.e. before further history and examination are elicited) and further irrigation continued (aided by a lid speculum if necessary) until the pH is normal (pH 7–7.5) and remains so.
- Topical anaesthesia should be applied and particulate matter removed with forceps or a swab. Double-evert the lid to remove debris (cement/lime/plaster) from the fornices.

NB: CS gas (O-chlorobenzylidene malono-nitrile; tear gas) used by police and in assaults should be treated by drying in front of a fan rather than irrigation.

### Clinical evaluation

- Determine the mechanism/nature/duration of chemical injury.
- Corneal epithelial defects can range from scattered superficial punctate epithelial erosions to focal epithelial loss to sloughing of the entire epithelium.

- The cornea is clear in mild injuries and hazy to opaque in more severe injuries.
- There are focal or diffuse areas of conjunctival chemosis and injection in mild injuries. In moderate to severe injuries there are areas of conjunctival blanching and limbal ischaemia (note that the eye may appear white in severe chemical injury due to complete blanching of the vessels). Limbal ischaemia is classified according to the fraction of the entire limbus that is affected.
- There may be anterior chamber inflammation, raised IOP (due to alkali-mediated destruction of the trabecular meshwork) or hypotony (alkali destruction of ciliary body epithelium).
- Note: do not ignore associated facial skin burns and refer promptly for specialist management.

**Table 1.3 Grading of alkali injury (Hughes' classification; can be used for acid injuries as well)**

Grade	Cornea	Limbal ischaemia	Prognosis
I	Clear	None	Good
II	Hazy, iris details visible	<1/3	Good
III	Opaque	1/3–1/2	Guarded
IV	Opaque	>1/2	poor

### Treatment

- In the initial stages the aim is to promote epithelialization, relieve pain, control IOP, and limit damage due to inflammatory mediators.
- Admit if severe injury or concern regarding compliance.
- Use preservative-free drops wherever possible.
- Prophylactic topical antibiotics (e.g. chloramphenicol QDS), g. cyclopentolate (1%, TDS), and oral analgesia.
- IOP control: use aqueous suppressants (e.g. oral diamox, topical timolol).
- Frequent use of preservative-free artificial tears.

### In Grade II injury or worse

Use the measures described above as well as the following:

- topical steroids (e.g. dexamethasone 0.1% 4–8 times/day for a minimum of 10 days);
- topical ascorbate (e.g. sodium ascorbate 10% 1–2 hourly) and oral ascorbic acid (0.1–2g QDS) until epithelialization is complete. Ascorbate acts to promote the synthesis of mature collagen by corneal fibroblasts;
- topical sodium citrate 10% (given 2 hourly for 10 days) inhibits neutrophil activity and migration;
- oral doxycycline may help prevent collagenolysis.

### Additional management

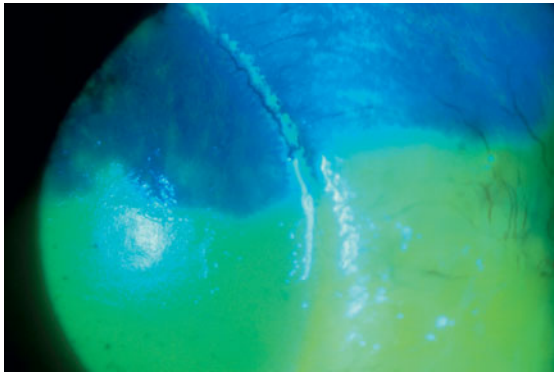
- Amniotic membrane onlay (to help reduce inflammation and promote re-epithelialization).
- Glue, patch graft, tectonic graft to treat melting, and perforation.

### Long-term management

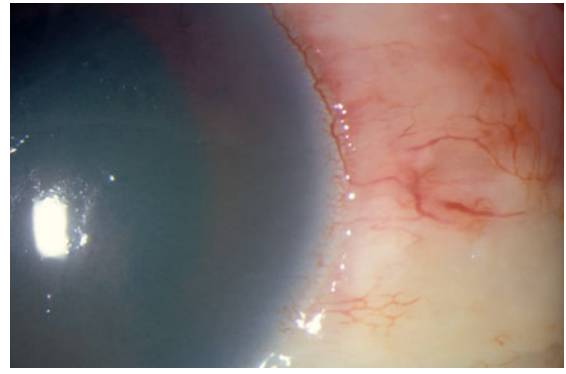
Limbal stem cell transplantation, keratoplasty (poor prognosis), keratoprosthesis, glaucoma control (augmented trabeculectomy, drainage devices).

### Complications

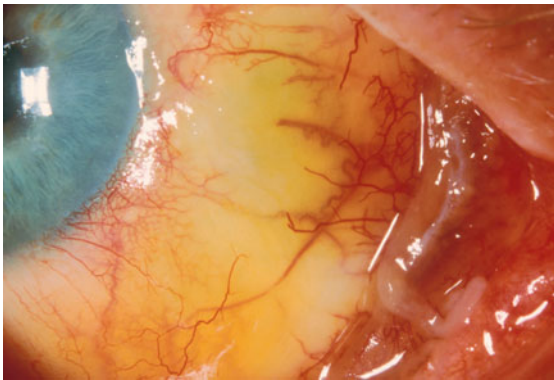
Dry eye, symblepharon, corneal opacification, vascularization, corneal melt, exposure, perforation, glaucoma, and/or cataract.



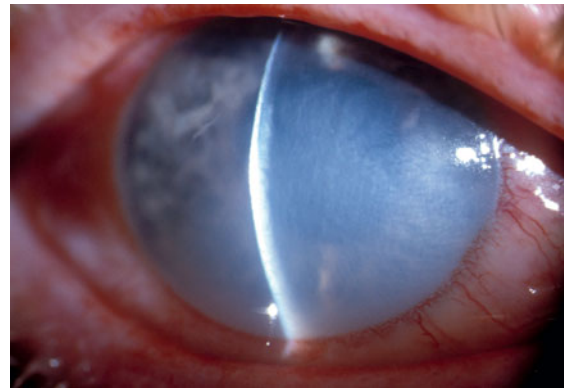
**Fig. 1.89** Corneal and conjunctival epithelial loss secondary to chemical injury, staining brightly with fluorescein.



**Fig. 1.91** Limbal ischaemia in a severe chemical injury.



**Fig. 1.90** Conjunctival blanching.



**Fig. 1.92** Corneal opacification in severe chemical injury.

## 1.33 Refractive surgery

This encompasses any procedure that is used to correct the refractive error of the eye (myopia, hypermetropia, astigmatism, and presbyopia). Techniques involve changing the radius of curvature of the anterior corneal surface, inserting a lens within the eye or replacing the natural lens with a lens of a different power. By far the most commonly performed procedure is laser refractive surgery.

### Classification and terminology

In order to correct **myopia** (short-sightedness) the refractive power of the eye must be decreased either by flattening the cornea or by insertion of an IOL of appropriate power.

To correct **hypermetropia** (long-sightedness) the cornea must be steepened or an appropriate IOL inserted.

To correct **astigmatism** (refractive power of the eye not the same in all meridians) the cornea must be flattened in the axis where the refractive capacity of the eye is relatively great and/or steepened in the axis where it is relatively weak. Alternatively an IOL with appropriate cylindrical correction (toric IOL) can be inserted.

To correct **presbyopia** (reduction of near vision with older age) accommodating or pseudo-accommodating (multifocal) IOLs can be inserted. An alternative to this is monovision where one eye is corrected for distance vision (made emmetropic; i.e. with no refractive error) and the other eye is made or left  $-1.50\text{D}$  myopic to allow the eye to focus on near objects.

### Corneal refractive surgery

#### Corneal ablation by excimer laser (see below for details)

- LASIK (laser-assisted stromal *in-situ* keratomileusis).
- Epi-LASIK (epithelial laser-assisted *in-situ* keratomileusis).
- PRK (photorefractive keratectomy).
- LASEK (laser-assisted subepithelial keratomileusis).

#### Corneal addition procedures (rarely used)

- Intracorneal ring segments (e.g. INTACS): most commonly used to treat keratoconus.
- Epikeratophakia: removal of epithelium and placement of a donor lenticule of Bowman's layer and anterior stroma.
- Keratophakia: intrastromal placement of a donor lenticule of corneal stroma after raising a microkeratome flap or by creating a stromal pocket by lamellar dissection.
- Intracorneal lens: placement of hydrogel lens inside the corneal stroma.
- Compression sutures steepen the cornea to reduce astigmatism.

#### Corneal relaxation procedures

- Radial keratotomy (peripheral deep stromal radial incisions) has been generally abandoned in favour of laser surgery.
- Arcuate keratotomy (paired peripheral stromal incisions parallel to the limbus): most often used to treat astigmatism after corneal graft surgery.
- Limbal relaxing incisions (deep limbal incisions of varying arc) are used during cataract surgery to reduce pre-existing corneal astigmatism.

#### Corneal thermocoagulation

- Thermokeratoplasty (heating the peripheral cornea to shrink collagen and steepen the central corneal curvature) can be used to treat hyperopia or presbyopia.

### Lenticular refractive surgery

#### Refractive lens exchange

- This is extraction of the natural lens and insertion of a posterior chamber IOL; that is, 'cataract surgery' in the absence of a visually significant cataract.

#### Phakic IOL

- This is the insertion of an additional lens in front of the natural lens, placed either in the ciliary sulcus or clipped to iris.

#### Multifocal lens

- These lenses have concentric ring segments that have two different focal lengths for distance and near vision.

#### Toric lens

- These lenses have a cylindrical power to address astigmatism.

## Preoperative evaluation for refractive surgery

The aim is to identify the patient's requirements, expectations (realistic or not), suitability, risk factors, and contraindications in order to select which procedure, if any, is the most suitable.

### History

- Work/leisure/sports vision requirements.
- Lifestyle risks (e.g. flap injury post-LASIK in contact sports).
- Previous ocular history (dry eyes, amblyopia, previous refractive surgery).
- Past medical history (certain connective tissue disorders can result in poor healing after refractive surgery).

### Examination

- Visual acuity (uncorrected and best corrected) after at least 2 weeks without contact lenses.
- Refraction.
- Pupil diameter in the dark (to determine the optimal width of the laser treatment zone).
- Keratometry and topography.
- Wave-front scanning if available (to find higher-order aberrations), although this is of little proven benefit.
- Pachymetry to confirm sufficient depth available for treatment, or placement of corneal rings. A residual stromal thickness of  $250\text{ }\mu\text{m}$  after LASIK is considered necessary to prevent future corneal ectasia.
- Slit lamp examination (particularly tear film, lid margin, corneal dystrophies, corneal degeneration, lens opacities, fundal abnormalities), IOP (may be underestimated after laser treatment due to decreased corneal thickness), anterior chamber depth (for phakic IOLs).
- NB: it is crucial to identify patients with early keratoconus due to the risk of postoperative corneal ectasia with ablation procedures.

## Laser corneal ablation procedures

These involve the removal of varying amounts of central (for myopia) or peripheral (for hypermetropia) corneal stroma ( $12\text{ }\mu\text{m}$  roughly corrects  $1\text{D}$ ). This is achieved with an excimer laser (193nm, ultraviolet laser). Procedures can be broadly categorized as surface treatments or LASIK.

### Surface treatment

These involve debridement of the epithelium (PRK) or removal of a flap of epithelium (LASEK or epi-LASIK) that can be discarded (PRK) or replaced (LASEK or epi-LASIK). After ablation of stroma by laser to correct the refractive error a bandage contact lens is usually worn for several days to help control discomfort until the corneal has re-epithelialized. Mitomycin C (an antiproliferative agent) may be applied at the end of the procedure to reduce the scarring

response. In contrast to LASIK there is no flap cut into the stroma and there is thus no risk of flap-related complications (see below). These procedures are recommended for patients who participate in contact sports (e.g. boxing). There is a greater undisturbed residual stromal bed with surface procedures and thus less risk of ectasia.

### LASIK

This is currently the most commonly performed refractive surgical procedure in the UK. A corneal flap (around 150  $\mu\text{m}$ ) is cut by a blade (microkeratome) or a femtosecond laser. The flap is retracted, the stromal bed is ablated and the flap is then replaced.

#### Advantages over surface treatments

- Less pain, less corneal haze, and faster visual rehabilitation.

#### Complications

- Flap-related: button-holing/tearing/incomplete flap/free flap/thick flap, thin flaps, flap folds or striae, dislodged flaps.
- Epithelial ingrowth, epithelial defects, dry eye.
- Diffuse lamellar keratitis: interface inflammatory process occurs within 1 week of LASIK, characterized by a fine granular opacification at the interface. Treatment is with early intensive topical steroids.
- Haze, halos, glare, night-vision problems.
- Under-/over-corrections.
- Rare complications include recurrent erosions, corneal infiltrates, infectious keratitis, and corneal ectasia.

#### Other considerations

- Glaucoma detection/monitoring can be challenging after laser corneal ablation procedures due to the change in corneal thickness and hysteresis (see section 7.4).
- Selecting an appropriate IOL for cataract surgery in patients who have undergone laser corneal ablation procedures is challenging and the refractive results of surgery less accurate.

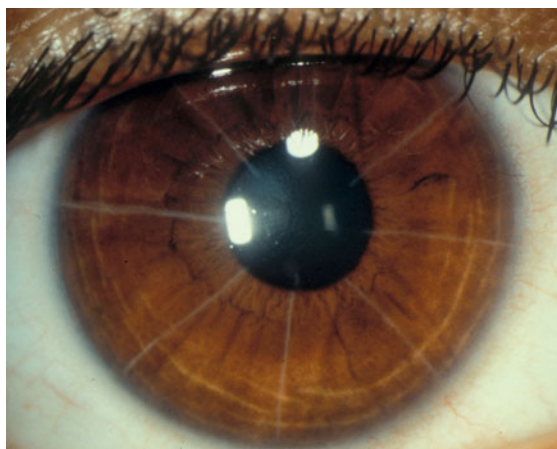


Fig. 1.93 Radial keratotomy scars.

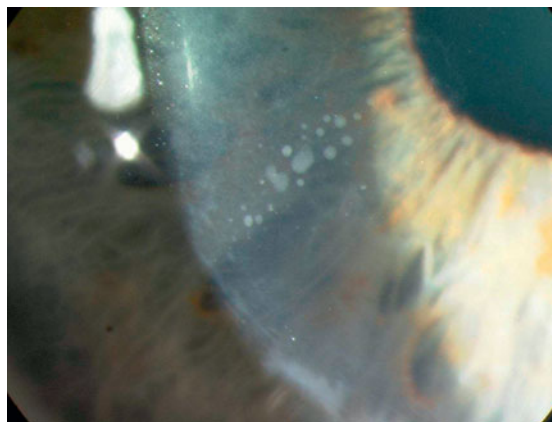


Fig. 1.94 Epithelial ingrowth following LASIK.

## Corneal topography

### Background/indication

- This is performed with computerized videokeratoscopy. A colour-coded map of the corneal surface showing areas with a similar radius of curvature or dioptric power is produced.
- It is useful in the diagnosis of early keratoconus, in pre-/postoperative assessment in refractive surgery, in the evaluation of contact lens-induced warpage (change in shape), in complex contact lens fitting, and to evaluate postoperative changes in corneal shape after grafting or cataract surgery.

### Technique

- Discontinue contact lens use (e.g. 1 week for soft lens, 2 weeks for rigid gas-permeable lenses, and 4 weeks for hard lenses) prior to refractive surgery assessment.

There are a variety of machine types that can be used:

- placido based: project rings on the cornea and analyse the reflected image (e.g. Tomey TMS-2N and Topcon KR-8000 PA);
- elevation based: directly measure the corneal elevation (Orbscan, ET 800);
- three-dimensional topography and anterior segment imaging can be done by Scheimpflug imaging (Pentacam).

## Corneal pachymetry


### Background/indication

- This is a measurement of corneal thickness.
- It can be performed by contact (ultrasound) and non-contact methods (slit lamp optical measurement, Orbscan, optical coherence tomography (OCT), or Scheimpflug imaging).
- There is a wide normal variation. The central cornea is thinnest (0.52 mm) with the peripheral cornea thickest (0.65 mm).
- Measurements are different depending on the technique used and should not be used interchangeably.

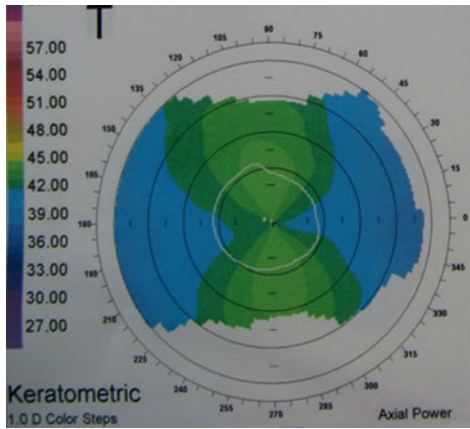
Indications for corneal pachymetry include:

- to evaluate endothelial function, e.g. Fuchs endothelial dystrophy, pseudophakic bullous keratopathy, and endothelial grafts;
- evaluation and preoperative assessment of keratoconus and refractive procedures (placement of intracorneal ring segments, judging the ablation depth);
- part of the evaluation of ocular hypertension and glaucoma (section 7.4);
- the technique for ultrasound pachymetry is described in section 7.4.

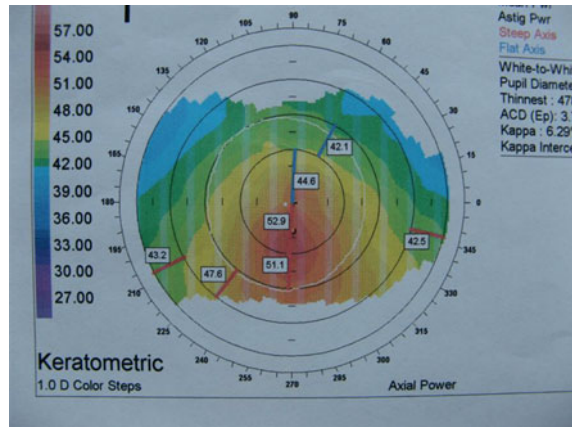




(a)



(b)



(c)

**Fig. 1.95** Corneal topography. (a) Normal. (b) Regular astigmatism with steepest corneal axis at  $100^\circ$ . (c) Keratoconus.



## 1.34 Case-based discussions

### Case 1 Chemical injury

A 4-year-old boy is brought in to the emergency department by his parents complaining of sudden onset of severe pain, watering, and photophobia in both eyes. Prior to the development of the symptoms the boy had been playing with some cleaning fluid.

- 1) What is the first thing that must be done in this situation?
- On examination it is not possible to assess the visual acuity. The left eye is injected and there is an inferior corneal abrasion. The right eye is white, the cornea is cloudy, and flare is visible in the anterior chamber.
- 2) What further signs should be elicited on examination?
- 3) Why is the right eye white?
- 4) What are the initial treatment options?
- 5) What long term complications may arise?

#### Discussion

- 1) It is likely that the boy has sustained an alkali injury. The pH should be tested and copious irrigation performed to both eyes until the pH has normalised.
- 2 and 3) It is important to assess the degree of limbal ischaemia. The right eye is white because of ocular surface ischaemia secondary to severe chemical injury. It is also important to assess the degree of corneal opacification and to check the IOP.
- 4) Intensive treatment will be required for the right eye. The left eye may not require such intensive treatment depending on the clarity of the cornea and the degree of limbal ischaemia. See section 1.32 for details
- 5) Dry eye, symblepharon, corneal opacification, vascularization, corneal melt, exposure, perforation, glaucoma, and/or cataract.

### Case 2 Herpes zoster keratitis

An 84-year-old gentleman presents with a painful rash of 1 day duration across the right side of his forehead. He complains that his right eye is red, watery, and uncomfortable and the vision is a little blurry on this side.

- 1) What is the likely diagnosis?
- 2) What are the potential corneal manifestations?
- 3) Why might the vision be blurry?
- 4) What treatment can you offer for the rash?

#### Discussion

- 1) HZO with secondary epithelial keratitis.
- 2) Other corneal manifestations that may develop include nummular keratitis, interstitial keratitis, disciform keratitis, mucus plaque keratitis, neurotrophic keratitis, exposure keratopathy (due to cicatricial lid changes), or lipid keratopathy.
- 3) The vision may be blurry due to the corneal disease. Other potential causes include uveitis, retinitis, choroiditis, and optic neuritis.
- 4) Systemic antiviral therapy with acyclovir 800 mg 5 times/day (alternatively valacyclovir 1g TDS or famciclovir 500 mg TDS).

### Case 3 Bacterial keratitis

A 26-year-old man who is a contact lens wearer presents with a 2 day history of a red painful right eye with blurred vision. On examination there is a central deep white stromal opacification with an overlying epithelial defect. There is a hypopyon in the anterior chamber.

- 1) What is the likely diagnosis?
- 2) What is the differential diagnosis?
- 3) What investigations are necessary?
- 4) What is the initial treatment strategy?

#### Discussion

- 1) The likely diagnosis is bacterial keratitis with a secondary reactive anterior uveitis.
- 2) Other causes of infectious keratitis (fungal, viral, protozoal).
- 3) Corneal scraping for Gram stain, culture, and sensitivity.
- 4) Commence intensive broad-spectrum antibiotics. This can be monotherapy with g. levofloxacin 0.5% hourly day and night for 2 days then reducing as signs permit over the next 7 days.

*This page intentionally left blank*

# Chapter 2

## Oculoplastics

Allon Barsam and Jimmy Uddin

---

### Basic sciences

- 2.1 Eyelid and nasolacrimal system anatomy 72

---

### Clinical knowledge

- 2.2 Lash abnormality 74
- 2.3 Entropion 76
- 2.4 Ectropion 78
- 2.5 Ptosis I 80
- 2.6 Ptosis II 82
- 2.7 Benign lid lesions 84
- 2.8 Premalignant and malignant lid lesions I 88
- 2.9 Malignant lid lesions II 90
- 2.10 Epiphora 92
- 2.11 Acquired nasolacrimal system abnormalities 94
- 2.12 Congenital abnormalities 96
- 2.13 Miscellaneous 98

---

### Clinical skills

Ptosis examination 82  
Evaluation of the patient with acquired epiphora 92

---

### Practical skills

Incision and curettage of chalazion 84  
Syringing and probing 92  
Botulinum-toxin injections 98

---

### Case-based discussions

- 2.14 Case 1 Epiphora 102
- Case 2 Ptosis 102
- Case 3 Lid lump 102

## 2.1 Eyelid and nasolacrimal system anatomy

### Eyelid anatomy

The function of the eyelids is primarily protection and maintenance of the tear film. They protect the ocular surface from mechanical injury and when closed protect the retina from bright light. During blinking they assist in the distribution of tears across the ocular surface.

#### Gross structure

The lids meet at the lateral and medial canthus. Between the upper and lower lids is the palpebral aperture. From anterior to posterior each eyelid consists of skin, subcutaneous tissue, orbicularis oculi muscle fibres, orbital septum, the tarsal plate (tarsus), and conjunctiva.

#### Eyelid lamellae and grey line

The eyelids can be divided into anterior and posterior lamellae separated by the grey line at the eyelid margin and by the orbital septum beyond the tarsal plate.

##### Anterior lamella

- Skin: very thin, folds easily. No subcutaneous fat
- Orbicularis oculi: this has four portions: orbital, preseptal, pretarsal, and lacrimal.

The three main functions of the orbicularis muscle are:

- 1) closure of the eyelids (mainly pretarsal);
- 2) maintaining the shape and position of the eyelids (including facial expression);
- 3) facilitating the active removal of tears across the ocular surface into the lacrimal sac. The nerve supply is the facial nerve (temporal and zygomatic branches).

##### Orbital septum

- This is an extension of periosteum from the orbital rim to the tarsus. It forms a mechanical and physiological barrier.

##### Posterior lamella

- Tarsal plate: fibrous skeleton of the lids. The upper tarsal plate measures about 10–12 mm centrally and the lower tarsal plate about 5 mm. Both tarsal plates are connected laterally to the marginal tubercle of the zygomatic bone by the lateral palpebral ligament and medially to the anterior and posterior lacrimal crest by the anterior and posterior limbs of the medial palpebral ligament.
- Tarsal conjunctiva: tightly adherent to the tarsus.

#### Glands

- *Meibomian glands*: there are approximately 25 meibomian glands embedded within each tarsus. These glands produce a sebaceous secretion that constitutes the outer lipid layer of the precorneal tear film. The openings are located posterior to the grey line.
- *Glands of Moll*: these are modified sweat glands that open on to the lid margin between the lashes or into a lash follicle.
- *Glands of Zeis*: these are sebaceous glands that open into each follicle.

#### Lashes

Lash roots lie against the anterior surface of the tarsus. The lashes exit the skin at the anterior lid margin. Eyelash misdirection may be due to rotation of the whole lid margin or anterior lamellar slippage.

#### Upper lid elevators

##### *Levator palpebrae superioris*

This striated muscle originates from the lesser wing of the sphenoid above the tendinous ring of extraocular muscles. The muscle belly passes above the superior rectus within the orbit before fanning out

into a broad aponeurosis. The posterior fibres of the aponeurosis join the orbital septum to insert into the upper third of the anterior surface of the tarsus. The anterior fibres attach to the skin to form the primary lid crease. The nerve supply is the superior division of the oculomotor nerve.

There is significant racial variation in positioning of this muscle. Notably, in the Asian eyelid the skin crease is lower due to a more inferior attachment of the septum.

##### *Müller's muscle (superior tarsal muscle)*

This smooth muscle assists the action of the levator. It arises from the inferior aspect of the levator aponeurosis and inserts into the upper edge of the superior tarsal plate. It is innervated by sympathetic fibres from the superior cervical ganglion.

#### Lower lid retractors

There is no exact equivalent muscle to the levator in the lower lid. However, there is a small group of smooth muscle fibres, the inferior tarsal muscle, that originate from the fascial sheath of the inferior rectus and insert into the lower tarsus.

#### Blood supply and lymphatic drainage

*Arterial supply* is via a marginal and peripheral arch formed primarily from the medial and lateral palpebral arteries.

*Venous drainage* occurs medially into the ophthalmic and angular veins and laterally into the superficial temporal vein.

*Lymphatic drainage* from the lateral two-thirds of the upper and lower lids is to the superficial parotid nodes and from the medial angle to the submandibular nodes.

## Nasolacrimal system anatomy

Tear production occurs by the main lacrimal gland and accessory lacrimal glands located in the conjunctiva (see Chapter 1). The nasolacrimal drainage system is a conduit for the flow of tears from the external surface of the eye to the nasal cavity.

#### Lacrimal puncta

These are small openings that lie on the medial aspect of the upper and lower lids. Each punctum sits on an elevated pale mound known as the papilla lacrimalis. The puncta are normally directed posteriorly against the globe where they can drain tears that accumulate within the medial canthal area.

#### Lacrimal canaliculi

The canaliculi begin at the puncta and pass vertically for 2 mm before turning through 90° to pass horizontally and medially for 8 mm before meeting at the common canaliculus. The common canaliculus continues along a medial path until it enters obliquely via the valve of Rosenmüller at the lateral wall of the lacrimal sac. Sometimes the canaliculi enter the sac separately.

#### Lacrimal sac

Measuring 12 mm long, the lacrimal sac is located within the lacrimal fossa in the antero-medial portion of the medial orbital wall between the anterior and posterior lacrimal crests. The lacrimal bone forms the posterior lacrimal crest and posterior part of the fossa. The frontal process of the maxilla forms the anterior lacrimal crest and anterior floor of the fossa. The lacrimal sac is enclosed by lacrimal fascia.

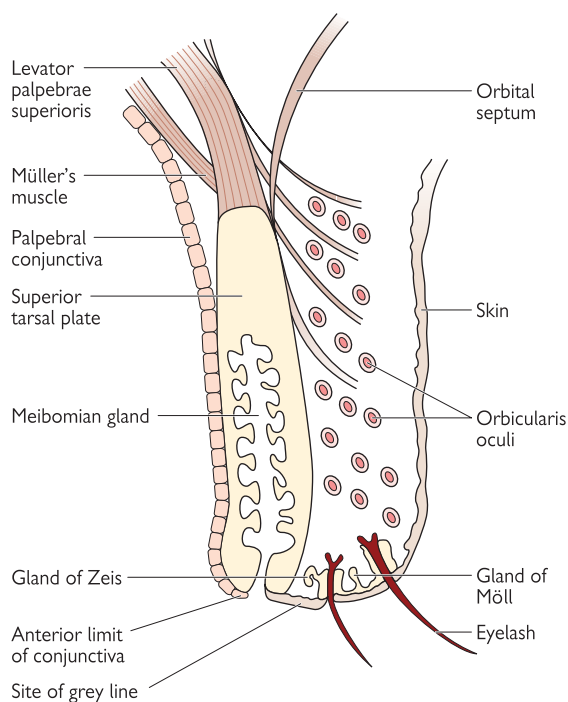
#### Nasolacrimal duct

This connects the lower portion of the lacrimal sac with the nasal cavity. The duct passes inferiorly posteriorly and laterally. The maxilla, the lacrimal bone, and the inferior nasal concha form the canal. The duct opens into the inferior meatus of the nose. A flap of mucus membrane, the valve of Hasner, prevents

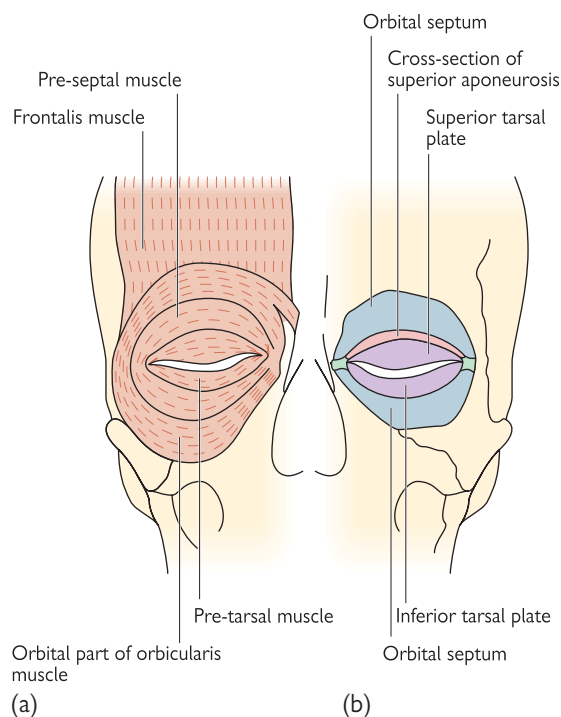
retrograde reflux of nasal contents and is often imperforate at birth, leading to epiphora.

## Physiology

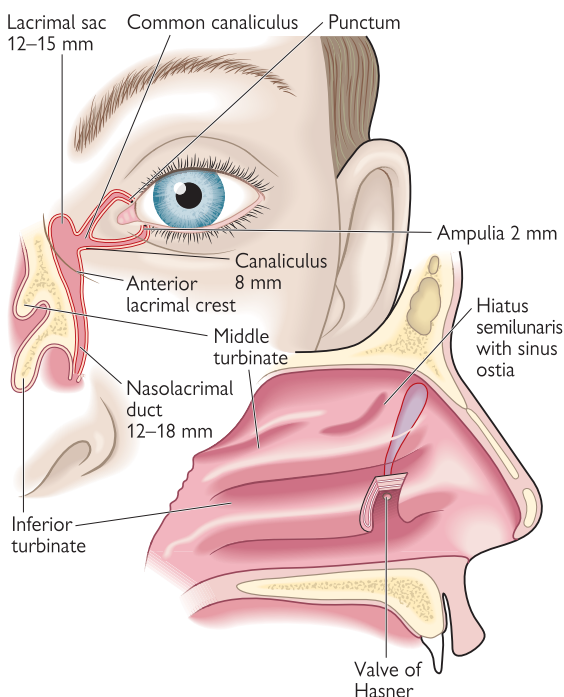
The main and accessory lacrimal glands secrete the tears, 10–20% of which are lost by evaporation. The remainder pass across the ocular surface and across the tear strips on the upper and lower lid margins by capillarity. 80% of drainage occurs via the lower punctum and 20% via the upper punctum. When the eyelids blink closed the orbicularis acts to expand the lacrimal sac and negative pressure sucks the tears into the sac. When the lids open positive pressure is created in the lacrimal sac and tears are forced down the nasolacrimal duct. This cycle involving the orbicularis is often referred to as the lacrimal pump.



**Fig. 2.1** Vertical section of the upper eyelid.



**Fig. 2.2** Anatomy of (a) orbicularis muscle and (b) underlying structures.



**Fig. 2.3** Normal anatomy of the lacrimal excretory system. Measurements are for adults.

## 2.2 Lash abnormality

### Trichiasis

Trichiasis is an acquired posterior misdirection of the eyelashes arising from normally sited hair follicles.

#### Aetiology

- Inflammatory: chronic blepharitis, vernal keratoconjunctivitis, ocular cicatricial pemphigoid, Stevens–Johnson syndrome
- Infective: HZO, trachoma.
- Traumatic: post-eyelid surgery, chemical injuries, thermal injuries.

#### Pathophysiology

In-turned lashes are associated with posterior lamellar scarring.

#### Clinical evaluation

Consequent eyelash trauma to the ocular surface may cause conjunctival injection, punctate epithelial erosions, corneal ulceration, and pannus in chronic cases.

#### Management

As well as treating any underlying conditions management is dictated by the pattern (segmental or diffuse) of the trichiasis and the quality of the posterior lamella.

#### Mechanical epilation

The initial treatment for a few misdirected lashes is removal with fine forceps at the slit lamp. Lash regrowth normally recurs in 3–4 weeks and the short stiff lash cilia can be more irritating to the cornea than mature longer lashes.

#### Electrolysis

Modern electrolysis is delivered via a radiofrequency probe. It is useful for a few isolated lashes. Recurrence rate is high for several reasons, which include the following.

1. Electrolysis is more effective if delivered to the lash follicle at a time in the lash growth cycle when the lashes are actively growing.
2. The tip of the probe may not be correctly positioned in the follicle at the root of the lash (2.4 mm deep for the upper lid follicles and 1.4 mm deep for the lower lid).

Scarring of the conjunctival surface (e.g. ocular cicatricial pemphigoid) can be problematic; a direct cutdown and visualization on to the follicle root before application of electrolysis may be more effective with less collateral damage.

#### Cryotherapy

This can be used if there are many irritating lashes. A solid nitrous oxide cryoprobe is applied in a double freeze–thaw technique. Skin depigmentation, notching of the lid margin, and meibomian gland damage are possible side effects.

#### Argon laser

This is less effective than electrolysis and is not widely used.

#### Surgery

- Full-thickness wedge resection or anterior lamellar excision are useful for segmental trichiasis. Generalized trichiasis may require anterior lamellar repositioning with or without grey-line split.

### Distichiasis

This is a partial or total second row of eyelashes originating in meibomian gland orifices posterior to the grey line. These lashes are usually shorter and finer than normal lashes and tend to be directed posteriorly.

#### Congenital distichiasis

This is rare and can be associated with chronic lymphoedema, spinal arachnoid cysts, and congenital heart defects.

#### Acquired distichiasis

Also known as metaplastic lashes. Causes include cicatrizing conjunctivitis secondary to chemical injury, Stevens–Johnson syndrome, and ocular cicatricial pemphigoid.

#### Treatment

Mild cases can be treated in the same way as trichiasis. More advanced cases require lamellar eyelid division and cryotherapy to the posterior lamella.

### Madarosis

This is a complete loss or decrease in the number of lashes. There are a number of causes.

- Ocular causes: chronic blepharitis, infiltrating eyelid tumours.
- Traumatic: chemical injuries, thermal injuries, trichotillomania (psychiatric disorder of habitual hair removal).
- Iatrogenic: following treatment of trichiasis or distichiasis; radiotherapy or cryotherapy of lid and surrounding facial tumours.
- Systemic causes: psoriasis, generalized alopecia, hypothyroidism, lepromatous leprosy, syphilis, systemic lupus erythematosus.

### Eyelash ptosis

This is a downward misdirection of normally sited upper-lid lashes due to anterior lamellar dissociation and slippage. This condition is normally age-related, but can be associated with dermatochalasis, floppy eyelid syndrome, or facial nerve palsy.

### Hypertrichosis

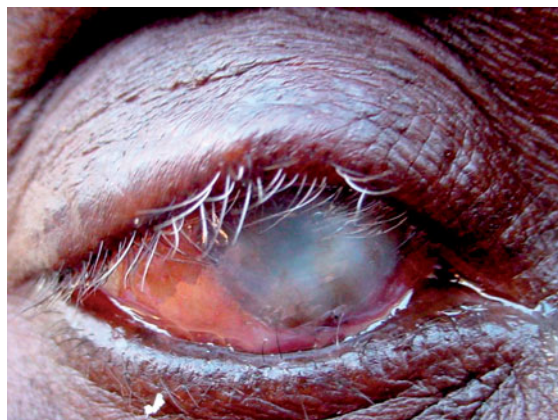This is abnormally long, thick lashes (trichomegaly) or an excess in the number of lashes (polytrichosis). Causes can be congenital and pharmacological (prostaglandin analogues, cyclosporin, and phenytoin).

### Poliosis

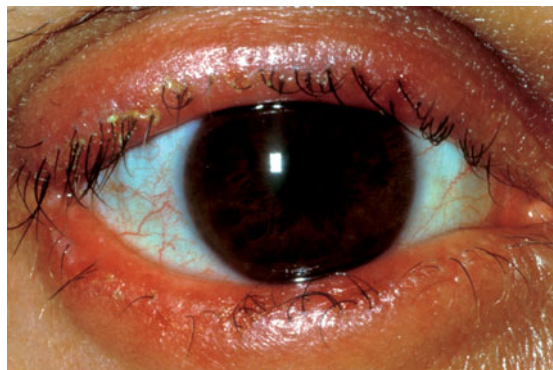This is a premature whitening of hair and can involve the eyelashes as well as the eyebrows.

- Ocular causes: sympathetic ophthalmitis, chronic anterior blepharitis.
- Systemic causes: Vogt–Koyanagi–Harada syndrome, Waardenburg syndrome.

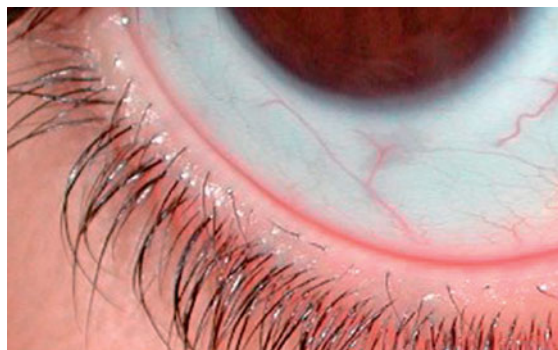



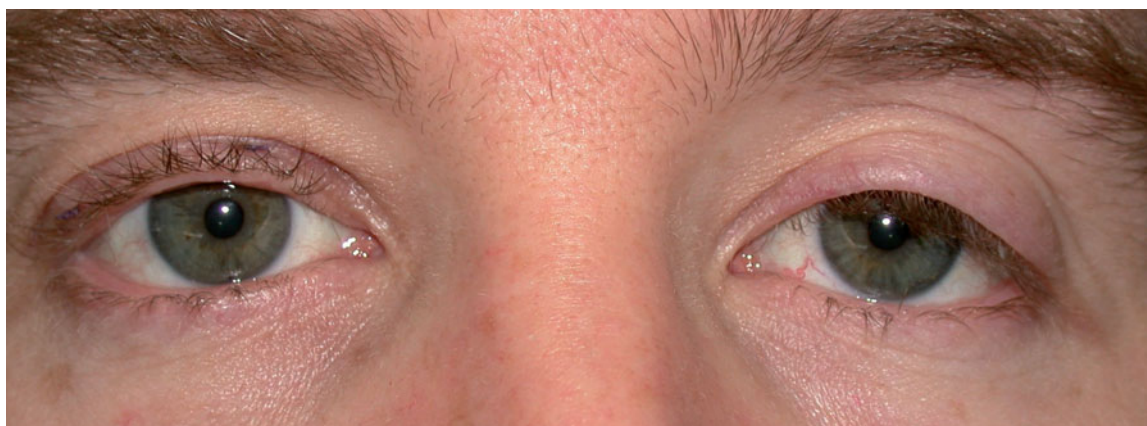**Fig. 2.4** Trichiasis secondary to trachoma. Note the associated corneal opacification. Courtesy of Matthew Burton.



**Fig. 2.7** Madarosis secondary to blepharitis. Note the loss of lashes particularly at the lateral portion of the lower lid.



**Fig. 2.5** Distichiasis.



**Fig. 2.6** Eyelash ptosis of the left eye. The right eye has been repaired with a grey-line split and anterior lamellar repositioning.

## 2.3 Entropion

This is an inward rotation of the eyelid margin. It commonly affects the lower lid, mostly from aging and gravitational effects.

### Clinical evaluation

Eyelash corneal touch may result in punctate epithelial erosions, conjunctival injection, and in severe cases corneal ulceration (see below for cause-specific considerations).

### Aetiology

- Congenital
- Acute spastic
- Involutional
- Cicatricial

### Congenital entropion

This is rare and should be distinguished from epiblepharon (see section 2.12).

### Treatment

Involves excision of a strip of skin and orbicularis and fixation of the skin to the tarsus (Hotz procedure) or everting sutures in less severe cases.

### Acute spastic entropion

This may occur in association with pre-existing mild involutional changes. Ocular irritation causes sustained eyelid orbicularis contraction and resultant inward rotation of the eyelid margin. A cycle of further irritation secondary to the entropion is then established. Treatment involves addressing both the underlying ocular irritation and the entropion.

### Treatment

Taping of the lid to evert the margin, botulinum-toxin injections, and everting suture techniques can offer temporary relief. Additional definitive surgical techniques are needed to address the underlying involutional entropion permanently (see below).

### Involutional entropion

The factors thought to play a role in this condition are:

- 1) horizontal eyelid laxity;
- 2) attenuation or disinsertion of eyelid retractors;
- 3) preseptal orbicularis overriding pretarsal orbicularis.

### Treatment

- Temporary measures such as taping or botulinum-toxin injection can be used while awaiting definitive surgical repair.
- Everting suture techniques (Quickert sutures) are quick and useful temporary measures but used alone are associated with a high recurrence rate.
- Horizontal eyelid tightening improves success rates and can normally be effectively achieved with a lateral tarsal strip procedure which involves shortening and fixation of the lateral tarsus.
- Retractors can be strengthened and directed anteriorly with retractor plication methods such as the Jones procedure. The horizontal incisional scar can help prevent preseptal orbicularis overriding pretarsal orbicularis.

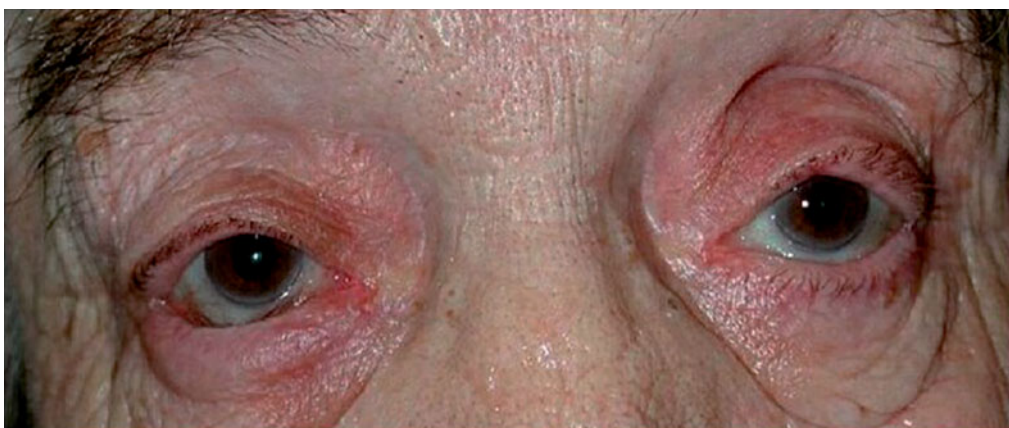### Cicatricial entropion

This is caused by conjunctival scarring and vertical tarsoconjunctival contracture. There are several causes:

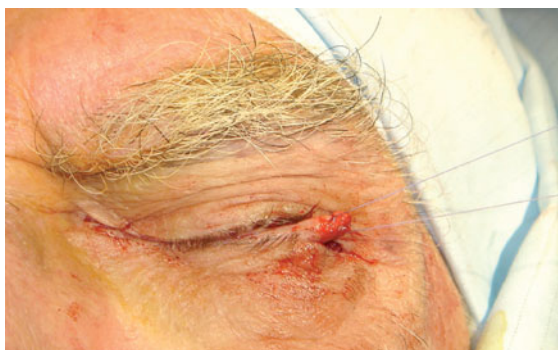- traumatic: chemical or thermal burns, scarring;
- inflammatory: Stevens–Johnson syndrome;
- autoimmune: ocular cicatricial pemphigoid;
- infectious: trachoma, herpes zoster;
- iatrogenic: post-enucleation, post-lid surgery.

### Treatment

Depending on the underlying cause cicatricial entropion normally requires surgery but lubricating ointments and bandage contact lenses can be useful adjuncts. Mild to moderate cases can be treated by anterior lamellar rotation with retractor plication and a grey-line split. Another surgical technique is the tarsal fracture procedure in which a full-thickness horizontal transconjunctival tarsal incision is made to evert the lid. The new position is held in place with everting sutures. There are a number of surgical options for upper-lid cicatricial entropion which involve lamellar division/repositioning and can be augmented with mucus membrane or other spacers.



**Fig. 2.8** Right lower lid involutional entropion.



**Fig. 2.9** Lateral tarsal strip procedure. The strip has been fashioned and is being pulled laterally under tension by the sutures. Note the tightening effect on the lower lid. To complete the procedure these sutures will be fixed to the lateral orbital rim.

## 2.4 Ectropion

This is an outward turning of the eyelid margin.

### Clinical evaluation

Signs depend on the cause and severity of the ectropion. Punctate epithelial erosions from corneal exposure and dryness may occur. There may be conjunctival and lid-margin injection, thickening, and eventual keratinization from chronic conjunctival dryness. Scarring of the skin can be seen in cicatricial ectropion. Facial hemiparesis and lagophthalmos can be seen in paralytic cases.

### Aetiology

- Congenital.
- Paralytic.
- Involutional.
- Cicatricial.
- Mechanical.

### Congenital ectropion

This is rare and is usually associated with the Blepharophimosis syndrome (see section 2.12) or with ichthyosis.

### Treatment

If mild it can be left untreated. If severe it requires treatment as for cicatricial ectropion (see below).

### Paralytic ectropion

This usually follows seventh cranial nerve palsy. Simultaneous lagophthalmos may be present due to paralysis of the orbicularis muscle. This can result in exposure keratopathy (see Chapter 1).

### Treatment

Mild or temporary cases can be treated with lubricating drops, ointments, forced blinking (to enhance lid closure and exaggerate the Bell's phenomenon), and taping up of the lower lid. Permanent or severe cases may require surgical treatment with tarsorrhaphy, medial/lateral canthoplasty, horizontal tightening procedures, dropping of the upper lid by levator recession, or insertion of gold weight into the upper eyelid. More extensive surgery in the form of fascial slings with midface support is sometimes necessary.

### Involutional ectropion

This results from tissue relaxation, usually as a result of a combination of horizontal lid laxity, medial canthal tendon laxity, and lateral canthal tendon laxity. Inferior retractor dehiscence may also play a part. These entities can be distinguished on clinical examination as follows.

- Horizontal lid laxity is present when the lid fails to snap back to its original position after being pulled away from the globe.
- Medial canthal tendon laxity is present when the lower lid punctum can be pulled without significant resistance towards or in severe cases past the medial limbus.

- Lateral canthal tendon laxity is present when the lower lid can be pulled medially without significant resistance.
- Inferior retractor dehiscence can be identified when the lower lid has reduced downward excursion on downgaze.
- The potential treatment modalities depend on the extent as well as the predominant causative laxity type.

### Treatment for medial canthal tendon laxity

In cases of mild medial eyelid ectropion with punctal malposition ('punctal eversion'), a horizontal diamond shape of conjunctiva is excised inferior to the punctum, and the defect is sutured closed, catching the lower lid retractors (medial spindle procedure). If necessary this can be combined with a lid-shortening or -tightening procedure. Retropunctal transconjunctival thermal cautery can be used, but recurrence is common.

### Treatment for horizontal and lateral canthal tendon laxity

Horizontal tightening can be obtained via a full-thickness excision. When combined with the medial spindle procedure this is known as the lazy-T procedure. Another commonly utilized alternative which can address both horizontal and lateral canthal tendon laxity is the lateral tarsal strip procedure. This involves creating and shortening a strip of the lateral tarsus and re-attaching it to the lateral orbital rim.

### Treatment for retractor dehiscence

The retractors are identified from a transconjunctival approach and re-attached to the postero-inferior border of the tarsus. An alternative is inverting sutures. This is usually combined with a lid-tightening procedure.

### Cicatricial ectropion

This is due to a shortened anterior lamella. It may occur secondary to a variety of causes, including sun damage, rosacea, atopic dermatitis, thermal/chemical burns, and trauma (including iatrogenic surgical trauma).

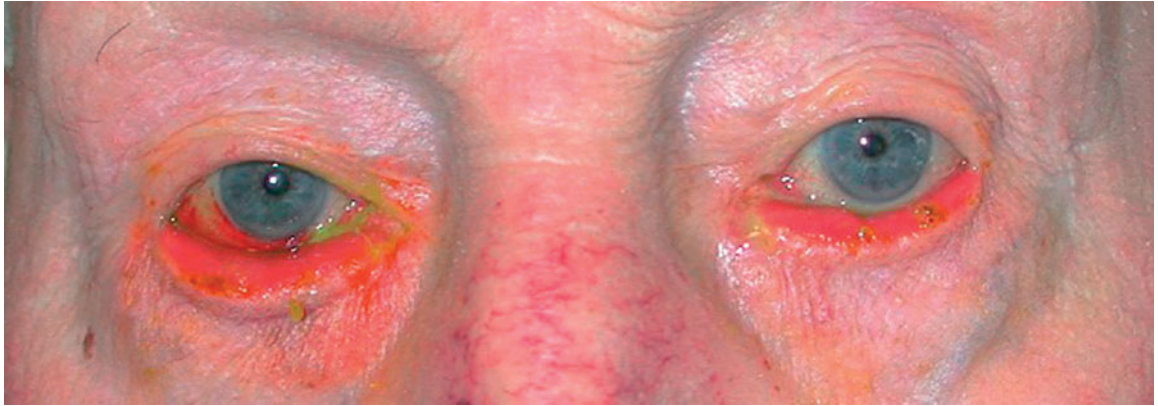
### Treatment

This involves treating the underlying cause along with appropriate protection of the ocular surface. Surgical treatment in localized cases is with a relaxing procedure such as a Z-plasty, once the scar has been removed. More generalized cases may require additional horizontal lid tightening and anterior lamellar lengthening using a skin graft, skin flap, or mid-face lift.

### Mechanical ectropion

This may be caused by bulky tumours on or at the lid margin, or by poorly fitted spectacles.





**Fig. 2.10** Bilateral involutional lower lid ectropion.

## 2.5 Ptosis I

Ptosis refers to a drooping of any anatomical structure. Strictly speaking the term blepharoptosis should be reserved specifically for an abnormally low position of the upper lid with respect to the globe.

### Clinical evaluation

Ptosis can cause functional visual loss such as defects in the superior visual field, astigmatism, and amblyopia in children, depending on the type and severity (see ptosis examination, section 2.6, for further features). Adults may also have the feeling of brow heaviness and ache due to constant frontalis overaction. It may also be aesthetically displeasing to the patient or parent of a child.

### Aetiology

Ptosis may be congenital or acquired. Both can be further subclassified as follows.

#### Neurogenic ptosis

##### Third nerve palsy

This may be congenital or acquired. Causes of acquired third nerve palsies include trauma, intracranial artery aneurysm, vascular disease, demyelination, tumours, infection, and vasculitis. Third nerve palsies can be partial or complete and thus are associated with varying degrees of ptosis, mydriasis, and inability to elevate and adduct the globe. Third nerve palsies can rarely be associated with aberrant regeneration where unusual eyelid movements accompany movements of the eye such as eyelid elevation on adduction.

##### Horner's syndrome

This may be congenital or acquired. Horner's syndrome arises due to an interruption of the sympathetic nerve supply to the head. There are many causes depending on where in the sympathetic pathway the interruption occurs. The ptosis tends to be mild (1–2 mm) as a result of weakness of the Müller's muscle and is associated with miosis, pseudo-enophthalmos (due to upper-lid ptosis and so-called inverse ptosis of the lower lid), and hypohydrosis.

##### Marcus Gunn jaw-winking syndrome

This occurs in some cases of congenital ptosis. It is thought to result from a branch of the mandibular division of the fifth cranial nerve being misdirected to the levator muscle. The clinical manifestation is an elevation of the ptotic eyelid due to opening the mouth, chewing, and/or moving the jaw.

#### Myogenic ptosis

Congenital cases such as blepharophimosis syndrome (see section 2.12) result from dysgenesis of the levator and may be associated with superior rectus weakness. Acquired causes result from localized or diffuse muscular disease. Acquired causes include myasthenia gravis, chronic progressive external ophthalmoplegia, ocular pharyngeal dystrophy, and myotonic dystrophy (see chapter 9).

#### Mechanical ptosis

This is caused by masses and/or swellings weighing down the upper lid or restricting upper-lid elevation. Causes include chalazion, dermatochalasis, eyelid and orbital tumours, and eyelid oedema.

#### Aponeurotic ptosis

Acquired aponeurotic ptosis is the most common form of ptosis. It is caused by a defect in the transmission of power from a functioning levator muscle to the tarsal plate. This can result from congenital defects (rare), trauma, and most commonly from ageing changes (involutional ptosis). The aponeurotic defect can be a localized or generalized attenuation, stretching, dehiscence, or disinsertion. It can occur after any type of eye surgery where the already attenuated aponeurosis is stretched further.

Levator function is usually normal or close to normal despite the presence of ptosis which can range from mild to severe.

Due to poor or raised attachment of the aponeurosis the lid crease is raised or indistinct.

#### Pseudoptosis

This should be differentiated from true ptosis as it is an apparent eyelid drooping. The eyelid can appear to be abnormally low in a variety of conditions which include: hypertropia, contralateral eyelid retraction, volume deficiencies (enophthalmos, microphthalmos, anophthalmos, phthisis bulbi), brow ptosis, and dermatochalasis (where excess upper-eyelid skin can overhang the eyelid margin and give the appearance of a true ptosis) (see section 2.13).

### Management

#### Conservative

In cases where there is no functional visual loss or risk of amblyopia and there is no cosmetic concern there is the option of no treatment. Non-surgical treatment options are impractical and are rarely used today. They include eyelid crutches attached to glasses frames and taping of the upper lid.

#### Surgical

Appropriate surgical procedures for ptosis correction depend on the amount and type of ptosis and the degree of levator function. There are three main approaches to surgical correction.

##### Anterior (transcutaneous/external)

This approach for levator/aponeurosis advancement surgery is particularly useful when levator function is normal (>12–15 mm) and the upper eyelid crease is high. It can be used for all levator resection and aponeurosis advancement procedures and is the most common procedure for aponeurotic ptosis repair. Dermatochalasis can be addressed simultaneously using a blepharoplasty. The procedure involves a lid crease incision and then advancement sometimes with resection of the levator before suturing the levator to the upper tarsus. In ptoses with moderate to poor levator function (5–12 mm), the levator muscle often needs to be resected. The poorer the levator function, the larger the levator resection needed.

##### Posterior (transconjunctival/internal)

This approach is often useful for small degrees of ptosis (<2 mm) for example in Horner syndrome. Müller's muscle resection is a useful technique. Another option is the Fasanella–Servat procedure, which involves removing a small part of the upper border of the tarsus together with the lower border of the Müller muscle and overlying conjunctiva. This procedure makes further ptosis surgery difficult due to reduced tarsus.

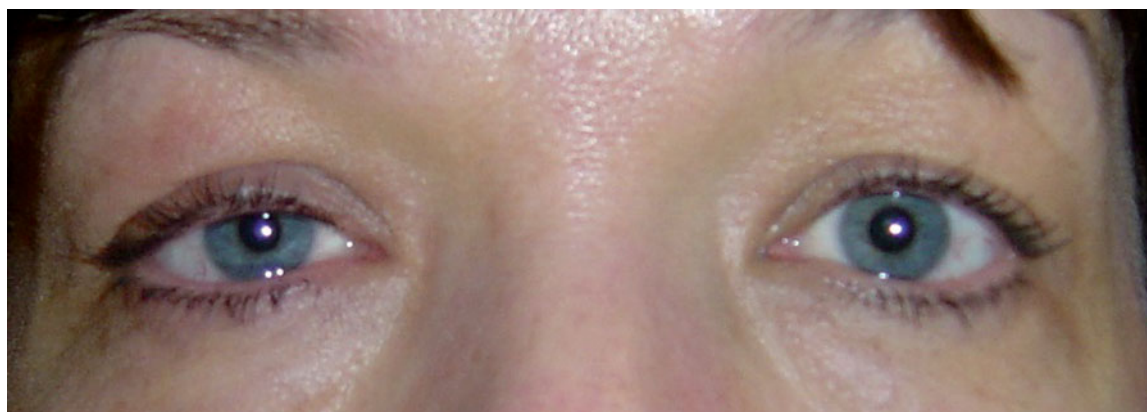##### Brow/frontalis suspension surgery

This approach is useful for severe ptosis with poor levator function (<4 mm). The eyelid is suspended by a sling from the frontalis muscle over the brow, allowing the patient to elevate the eyelid using the frontalis. Synthetic materials (e.g. silicone rods or Supramid sutures) as well as autogenous or banked fascia lata) can be used for the sling.

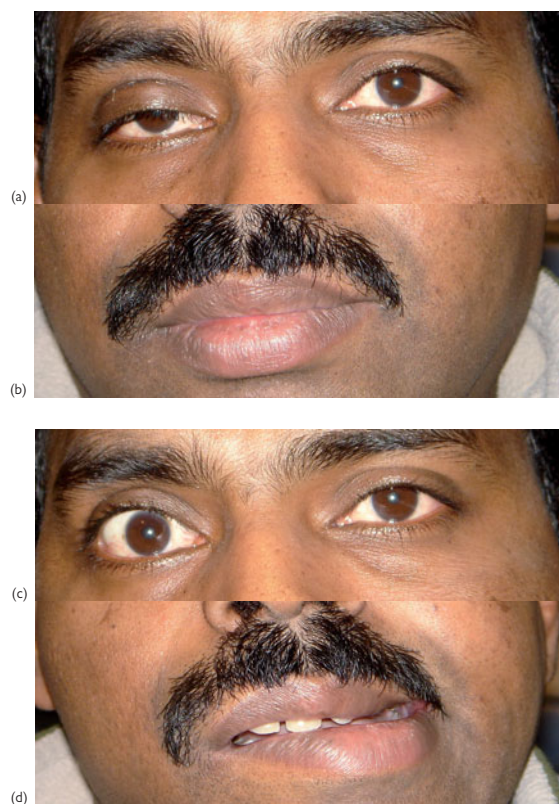
### Complications of ptosis surgery

- Infection and scar (potential complications of all lid surgery).
- Lagophthalmos (inability to close the eyes) and resultant corneal exposure (especially with larger levator resections).
- Over- and under-correction.
- Lid contour defects.
- Contralateral ptosis: Herring's law of equal innervation means that the extra innervation to a ptotic lid and its fellow must be equal and this can mask a ptosis in the fellow eye. Following repair this can be unmasked in the fellow eye.
- Lash ptosis/lash eversion.
- Orbital haemorrhage.

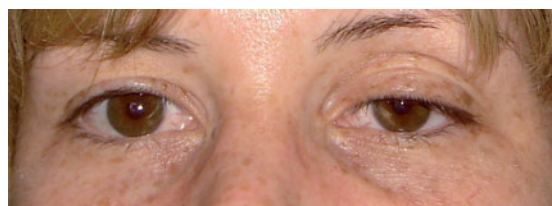



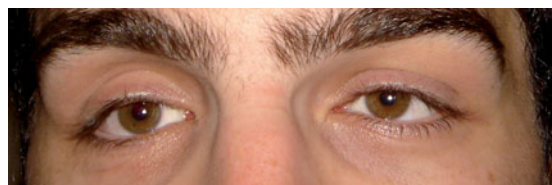**Fig. 2.11** Right Horner's syndrome.



**Fig. 2.12** Marcus Gunn jaw-winking syndrome. (a, b) Right ptosis with mouth closed. (c, d) Right ptotic eyelid is elevated when mouth is opened.



**Fig. 2.13** Aponeurotic ptosis, left eye. Note the high upper-lid skin crease.



**Fig. 2.14** Pseudoptosis, right eye, due to previous orbital-floor fracture, enophthalmos, and hypoglobus.

## 2.6 Ptosis II

### Ptosis examination

#### 1. Introduction

Introduce yourself to the patient.

#### 2. Observation

Look for associated features, such as:

- scars (trauma, surgery),
- general facial asymmetry,
- anisocoria (third nerve palsy, Horner's syndrome),
- heterochromia (congenital Horner's syndrome),
- strabismus (myasthenia gravis, third nerve palsy),
- frontalis overaction (long-standing ptosis),
- chin lift (severe bilateral ptosis with superior visual field defects),
- abnormal facial features (blepharophimosis syndrome, myotonic dystrophy).

If examining a child ask them to chew and protrude their jaw to look for Marcus Gunn jaw-winking syndrome.

#### 3. Measure

- Palpebral aperture in millimetres (in the primary position).
- Skin crease height with patient looking down (distance between the lid margin and the skin crease).
- Upper lid show (distance from the lid margin to the skin fold).
- Upper and lower marginal reflex distance (distance between the centre of a light shone on the pupil and the upper and lower lid margin respectively). These measurements are useful as the palpebral apertures alone may be misleading in the context of, for example, lower-lid ectropion or hypoglobus.
- Levator function. This is done by measuring the excursion of the upper lid as the patient looks from extreme downgaze to extreme upgaze. It is important to place the thumb firmly across the brow to try and prevent frontalis action assisting in the lid excursion.

#### 4. Bell's phenomenon

This is tested by asking the patient to close their eyes while holding the upper lid open. The phenomenon is said to be positive if the eye rolls up under the upper lid. It is useful for assessing the risk of post-operative corneal exposure. A poor or negative Bell's phenomenon is a risk for exposure postoperatively.

#### 5. Lid lift

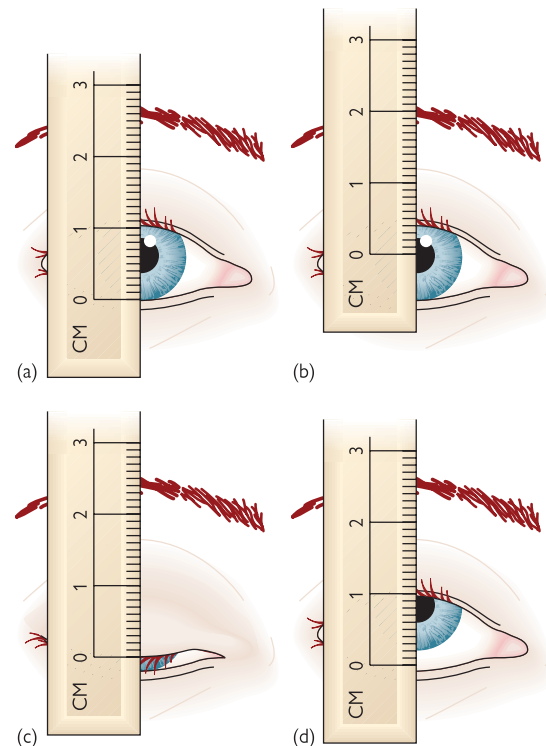
It is important to lift the ptotic eyelid to look for a contralateral ptosis being unmasked in cases of bilateral ptosis where one side is more marked than the other.

#### 6. Fatiguability

This is performed by asking the patient to maintain upgaze for 30 seconds and then observing to see whether the ptosis has weakened (myasthenia gravis). After fatiguing the upper lid, getting the patient to make a quick downwards saccade followed by fixation in the midline can reveal an overshoot of the upper lid with a subtle upwards overexcursion above the midline (Cogan's lid-twitch sign).

#### 7. Evert the upper lid

This is important to exclude mechanical causes of the ptosis and to look for conjunctival scars (trauma, previous surgery). Lifting a dermatochalasis can also give an appreciation of the extent that this contributes to a mechanical ptosis.



**Fig. 2.15** Diagrammatic illustration showing the necessary measurements for ptosis examination. (a) Interpalpebral fissure height, (b) upper-lid-margin–corneal reflex distance, and (c, d) levator function.

*This page intentionally left blank*

## 2.7 Benign lid lesions

### Chalazion

This is a focal inflammatory cyst of the tarsus resulting from obstruction of a meibomian gland. It is associated with posterior blepharitis and rosacea. Histologically it is a chronic lipogranulomatous inflammation.

#### Clinical evaluation

Chalazion may present with acute or chronic eyelid lump, lid swelling, pain, erythema, and/or tenderness. Look for signs of associated blepharitis and rosacea. A large chalazion can induce astigmatism and affect vision. This is especially important in young children at consequent risk of amblyopia.

#### Management

For acute inflammatory chalazion warm compresses, gentle digital massage over the lump, and eyelid hygiene are appropriate. The natural history of chalazion is resolution within weeks to months. This treatment alone may be effective. If the lump remains after several weeks and the patient is troubled by it then surgical treatment can be performed with an incision and curettage procedure:

#### + Incision and curettage

- Mark the skin over the chalazion as the local anaesthetic may subsequently make it difficult to localize.
- Instil topical tetracaine (local anaesthetic) into the fornix.
- Subcutaneous local anaesthesia with 2% xylocaine with adrenaline 1:200,000. Use slow injection to reduce pain. Wait several minutes for the anaesthetic to work.
- Firmly place the tarsal clamp over the chalazion and evert the lid.
- Make a vertical linear or cruciate incision into the tarsus.
- Curettage is performed whereby the contents of the cyst are removed.
- Instil chloramphenicol ointment before removing the clamp and firmly double-padding the eye.
- NB: for recurrent or atypical chalazion a biopsy should be taken to exclude sebaceous gland carcinoma.

### Hordeolum

This is an acute infection that is normally caused by staphylococcal infection of the eyelid glands.

#### External hordeolum (stye)

Involves the glands of Zeis. The infection can often be seen around an eyelash follicle. Treatment is with eyelash epilation to promote drainage as well as warm compresses and topical antibiotics.

#### Internal hordeolum

This involves the meibomian glands and is treated with hot compresses and topical antibiotics. In very rare cases hordeola may be associated with secondary preseptal cellulitis and systemic antibiotics may be required.

### Xanthelasma

These are cutaneous lipid deposits which may be idiopathic or associated with hyperlipidaemia, hypothyroidism, or primary biliary cirrhosis. Treatment for cosmetic reasons is with excision, laser treatment, or trichloroacetic acid application.

### Molluscum contagiosum

This is caused by a poxvirus. It manifests as pale umbilicated nodules often on the eyelid margin, but can occur anywhere on the skin of the eyelid. It can be associated with follicular conjunctivitis. Treatment options are excision, curetting, cauterization, or cryotherapy.

### Other eyelid cysts

#### Apocrine hidrocystoma (cyst of Moll)

This is a common, smooth-walled cyst arising from the gland of Moll at the eyelid margin. These cysts are translucent and may be seen to transilluminate.

#### Eccrine hidrocystoma

This is similar in appearance to the cyst of Moll but is not confined to the eyelid margin.

#### Cysts of Zeis

These are smooth-walled cysts of sebaceous material on the eyelid margin.

#### Milia

These are derived from hair follicle-associated glands. They are visible under the skin as small white superficial cysts.

#### Sebaceous cyst

These are epidermal cysts filled with keratin and may have a small central punctum.

#### Management

As these lesions are benign, surgery is indicated for cosmetic or diagnostic reasons only. For a lower chance of recurrence deroofing of the cyst with thermal cautery to the empty sac or complete cyst excision for larger cysts is effective. Incision and expression of contents is less effective.

### Benign epithelial hyperplasias

#### Seborrheic keratoses

They are classically described as having a smooth, greasy, 'stuck-on mud' appearance. They may be sessile or pedunculated and have varying degrees of pigmentation.

#### Squamous cell papilloma (viral wart)

This can be sessile or pedunculated and has multiple tiny projections giving it a raspberry-like appearance.

#### Exuberant hyperkeratosis (cutaneous horn)

This hyperkeratotic lesion protruding from the skin may be associated with squamous cell carcinoma at its base.

#### Management

All of these lesions can be removed with shave excision at the dermal/epidermal junction. If there is any doubt about the diagnosis then the specimen should be sent for histology. The base of a keratin horn should always be excised and sent for histology.

### Benign melanocytic lesions

#### Naevi

There are three main types of naevus: junctional (arising from the dermal/epidermal junction), compound (arising from both epidermis and dermis), and dermal (arising from the dermis). These lesions are almost always benign but occasionally malignant transformation of junctional or compound naevi may occur.

#### Dermal melanocytosis (naevus of Ota)

This is a congenital diffuse blue/brown naevus of the periocular skin. When associated with patchy slate-grey uveal and episcleral pigmentation, the condition is known as oculodermal melanocytosis. Oculodermal melanocytosis carries a 1 in 400 risk of uveal malignant melanoma.

## Benign vascular lesions

### Pyogenic granuloma

This is a rapidly growing bright red sessile or pedunculated lesion consisting of vascularized proliferation of granulomatous tissue. Causes include prior trauma, surgery, and infection. Treatment is by excision.

### Port-wine stain

This is a congenital subcutaneous cavernous haemangioma. It is normally unilateral, beginning as a pink patch and with age progressing to a darker purple colour. These lesions are seen in Sturge–Weber syndrome. If the periorbital region is involved there is a strong association with glaucoma. Treatment is with erbium laser.

### Strawberry naevus (capillary haemangioma)

This is one of the most common benign tumours of infancy. It usually appears over the first few weeks of life and increases in size until the child can be several years old. Thereafter spontaneous involution occurs in 50% by age 5 and in 75% by age 7. Treatment is indicated if there is a risk of amblyopia from occlusion of the visual axis, anisometropia, or strabismus. Corticosteroid injection can be an effective first-line treatment (intra- and perilesional) but can be

complicated by skin depigmentation, fat atrophy, eyelid necrosis, and rarely central retinal artery occlusion. Oral steroids are also effective but carry their own systemic side effects. Laser treatment and surgical excision can also be used as treatment options, but cosmetic results can be disappointing.

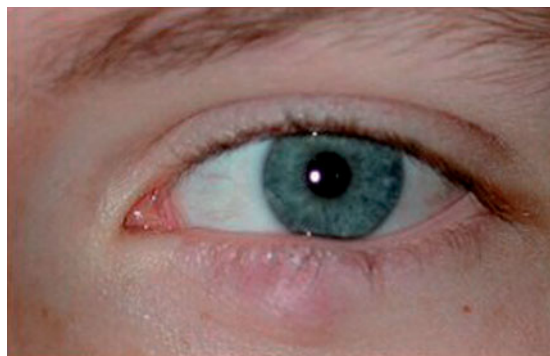


Fig. 2.16 Lower lid chalazion.

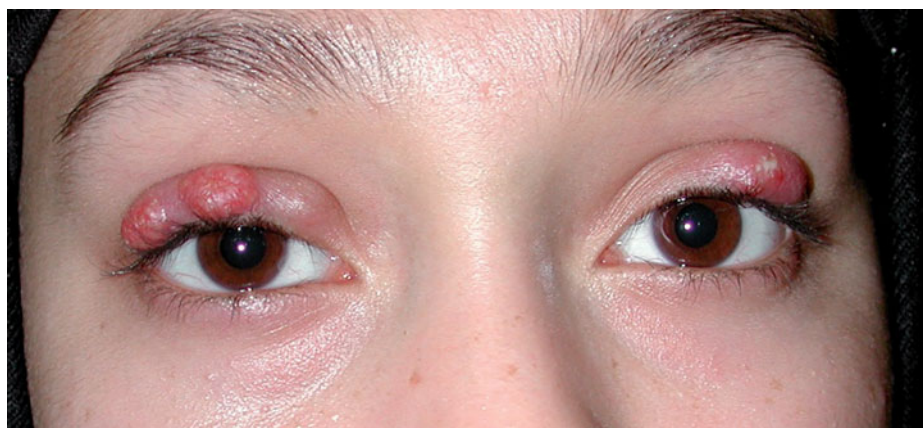

Fig. 2.17 Multiple inflamed chalazia on upper lids.

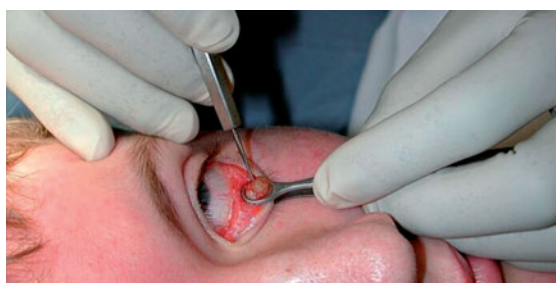
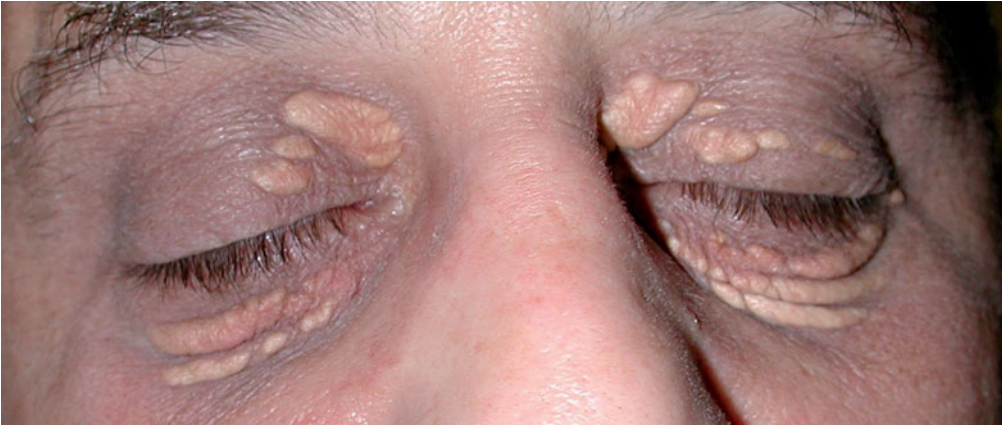
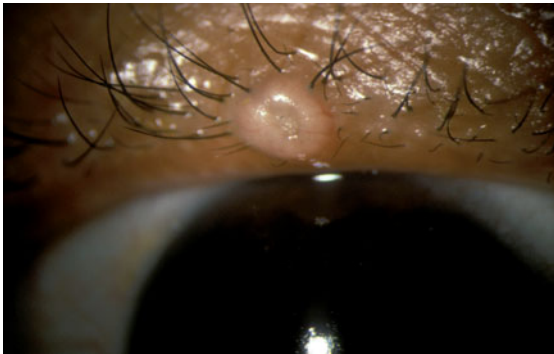


Fig. 2.18 Incision and curettage of chalazion.

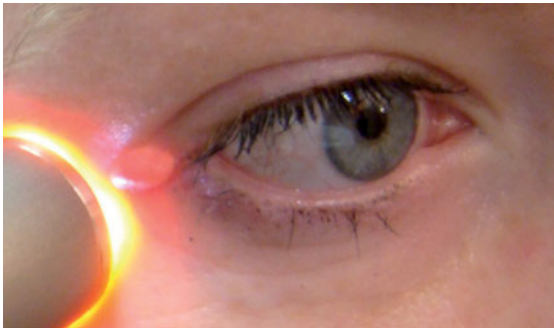



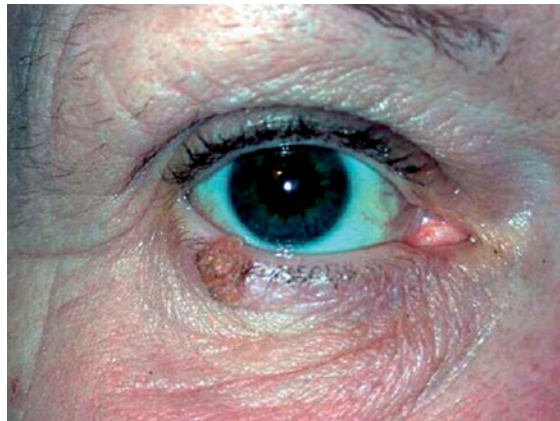
**Fig. 2.19** Multiple xanthelasma.



**Fig. 2.20** Molluscum contagiosum on the lid margin.

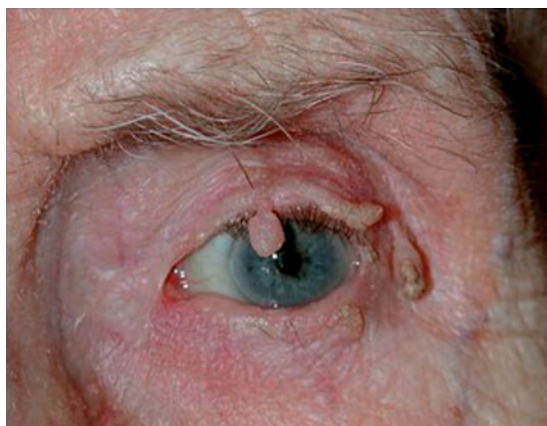

**Fig. 2.21** Transilluminated eccrine hidrocystoma.

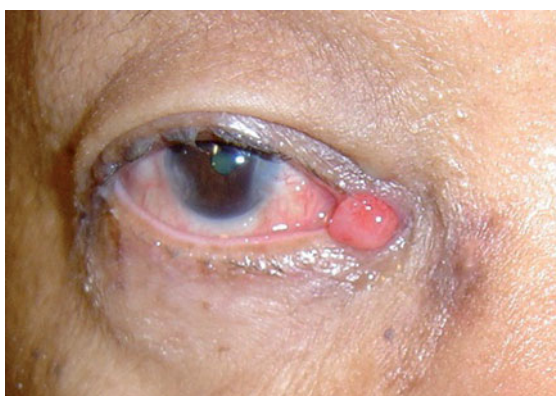


**Fig. 2.22** Seborrheic keratoses.

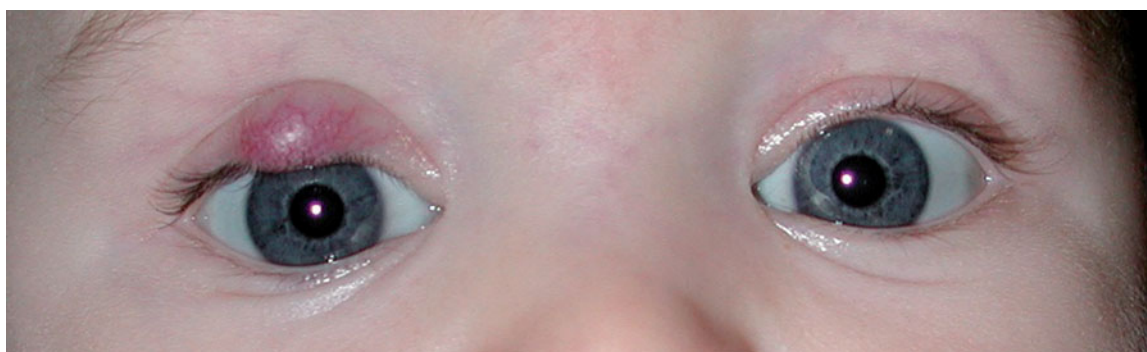



**Fig. 2.23** Papilloma upper lid.



**Fig. 2.24** Pyogenic granuloma.



**Fig. 2.25** Strawberry naevus.

## 2.8 Premalignant and malignant lid lesions I

### Premalignant lesions

#### Actinic keratosis

These are round scaly, keratotic lesions with a rough surface. They usually affect elderly, fair, chronic sun-exposed individuals and are the most common precancerous skin lesion. Individual lesions carry a relatively low risk of malignant transformation but in individuals with multiple lesions there is a 1 in 8 chance of transformation to squamous cell carcinoma. Treatment is with excision or cryodestruction.

#### Bowen disease

This is squamous cell carcinoma *in situ* of the skin. Lesions are non-healing, hyperkeratotic, and often white, but occasionally erythematous. In fewer than 5% of patients squamous cell carcinoma develops. The treatment is therefore complete surgical excision.

#### Keratoacanthoma

This is now considered to be a low-grade form of squamous cell carcinoma. The lesion typically begins as a pink papule that can treble in size within a few days to become a firm, dome-shaped nodule. During a subsequent period of regression a central keratin-filled crater may develop. Treatment is usually complete surgical excision.

#### Lentigo maligna

This is a premalignant melanocytic lesion characterized by being flat, irregularly shaped, unevenly pigmented, and slowly enlarging. Up to 50% of these lesions progress to malignant melanoma. Treatment is excision with adequate margins.

### Basal cell carcinoma

Basal cell carcinoma (BCC) is the most common eyelid malignancy and accounts for up to 95% of malignant eyelid tumours. They occur more frequently on the lower eyelid. The tumour is slow-growing and locally invasive but does not metastasize. Patients at greatest risk are those with fair skin and a history of sun exposure in early life.

#### Clinical evaluation

Patients may present with a painless eyelid nodule or non-healing ulcer that may bleed with minimal trauma. This may be present for months or years. On examination most tumours have the following characteristics: firm, immobile, painless shiny nodule with a raised pearly rolled border and with fine telangiectatic vessels on the surface. They can infiltrate and destroy local tissues, including lashes (resulting in lash loss). In young patients or in those with a positive family history, possible rare systemic associations should be considered, such as:

- *basal cell naevus syndrome (Gorlin syndrome)*, which is an autosomal dominant disorder of multiple BCCs and skeletal abnormalities;
- *xeroderma pigmentosum*, which is an autosomal recessive disorder characterized by extreme sun sensitivity, multiple skin tumours of various types, and typical bird-like facies. Clinically, BCCs can be grouped into three subtypes.

#### Nodular

This is the most common subtype, a slow-growing, well-demarcated, raised pearly nodule with fine telangiectasia. Occasionally this can be mistaken for an eyelid cyst.

#### Nodulo-ulcerative (rodent ulcer)

This is characterized by central ulceration that can be extensive in advanced cases. If left untreated the tumour can erode a large extent of the eyelid and beyond.

#### Sclerosing/morpheaform

This is the least common, but most difficult to manage. The tumour is an indurated plaque with ill-defined borders often making diagnosis difficult. It is sometimes mistaken for chronic blepharitis.

#### Management

An incisional or excisional biopsy is necessary to confirm clinical suspicion of BCC. Once the diagnosis is confirmed there are a variety of treatment options available.

#### Radiotherapy

The recurrence rate is higher than with surgical treatment and can be more difficult to detect after radiotherapy. Complications of this treatment include dry eyes, chronic keratitis, keratinization of the conjunctiva, and dermatitis.

#### Cryotherapy

The recurrence rate with cryotherapy is also high and as for radiotherapy it is thus reserved as treatment for patients who are otherwise unable to tolerate surgery. It is the treatment of choice for multiple BCCs in cases such as Gorlin syndrome.

#### Surgical excision

This is usually the treatment of choice. It allows for complete removal of tumour with histological control of margins. It has a lower recurrence rate than other modalities and normally offers superior cosmetic results. The principles of surgical resection are for complete tumour removal with maximal surrounding tissue preservation. There are several techniques.

*Frozen section:* after the clinically apparent tumour has been excised with apparently clear margins, the edges of the specimen are sectioned and examined by a histopathologist at the time of the surgery for confirmation of tumour-free margins. For this, specimens are usually sent fresh or wrapped in a swab of normal saline.

*Paraffin section:* excision is as for frozen section, but the specimen is sent in formalin. The sections cannot be read at the time but can be read after 24–48 hours. Paraffin sections can allow more accurate assessment than frozen sections.

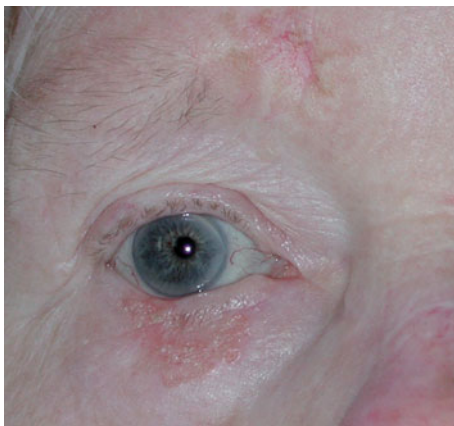
*Moh's micrographic surgery:* this has the lowest recurrence rate of all modalities. The surgical excision is more delicate as it aims to avoid unnecessary tissue loss. This requires special training and usually involves a specialized dermatologist. Tissue is removed in layers to provide three-dimensional mapping of excised tumour. This technique is particularly useful for diffusely growing tumours with indefinite margins and tumours in high-risk areas such as the medial canthus.

*Surgical reconstruction:* when the tumour has been excised there are a variety of options for reconstruction of the resulting eyelid defect depending on the site, size, and depth of the defect, as follows.

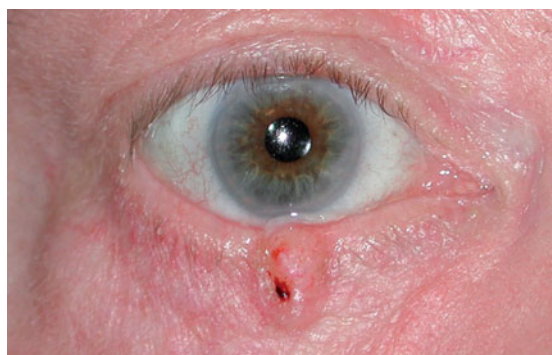- *Small defects:* of less than one-third the length of the eyelid can normally be closed directly. A lateral cantholysis can be created to mobilize additional tissue if necessary.
- *Moderate defects:* of less than one-half of the eyelid can be closed by semicircular flap techniques such as the Tenzel flap.
- *Large defects:* of greater than one-half of the eyelid for the lower lid can be repaired by advancement of a tarsoconjunctival flap from the upper eyelid into the posterior lamellar defect of the lower eyelid. The anterior lamellar is then created with an advancement skin flap or skin graft (modified Hughes procedure). Mustarde cheek-rotation flaps are another option for repairing lower-lid defects. For upper-lid defects a free tarsoconjunctival graft from the contralateral upper eyelid can be used and covered with a skin-muscle flap.

#### Prognosis

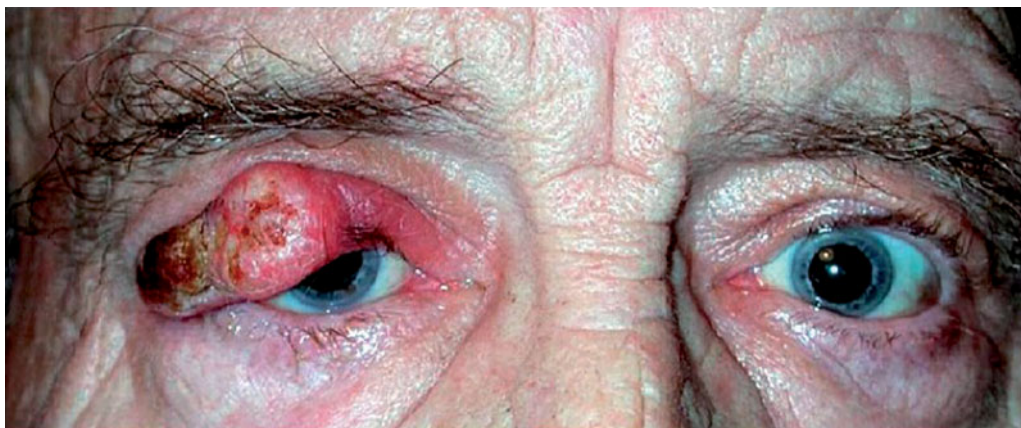The prognosis is excellent with a 95% cure rate at 5 years for BCCs under 10 mm in size.



**Fig. 2.26** Actinic keratosis.



**Fig. 2.27** BCC.



**Fig. 2.28** Keratoacanthoma with squamous cell carcinomatous changes.



## 2.9 Malignant lid lesions II

### Squamous cell carcinoma

This is a relatively uncommon malignant tumour of epithelial cells that typically affects fair-skinned elderly individuals. It can arise *de novo* or from premalignant lesions such as actinic keratosis. It can also occur in patients who have undergone radiotherapy, have genetic predisposition (xeroderma pigmentosum), or have been immunosuppressed (transplant patients). Unlike BCC, squamous cell carcinoma is an aggressive tumour that can invade the orbit and metastasize to lymph nodes and distant sites.

#### Clinical evaluation

Diagnosis can be difficult because benign-appearing lesions can reveal histological evidence of squamous cell carcinoma at deeper levels of sectioning. It is therefore important to have a high index of clinical suspicion. Squamous cell carcinoma may appear as plaques or nodules with varying degrees of scale, crust, ulceration, or keratinization.

#### Management

Management is as for BCC with Moh's micrographic surgery being the treatment of choice. Full multidisciplinary work-up looking for local and metastatic spread should be considered.

### Uncommon malignant lesions

#### Sebaceous gland carcinoma

This is an aggressive tumour arising from meibomian glands of the tarsal plate, from glands of Zeis, from sebaceous glands of the caruncle, or from surrounding skin.

#### Clinical evaluation

These tumours can masquerade as benign lesions such as chalazia, chronic blepharitis, or chronic conjunctivitis (due to intraepidermal pagetoid spread). A high index of clinical suspicion with chronic or recurrent lesions is important. Typically the tumour is associated with effacement of meibomian gland orifices and sometimes loss of eyelashes. Unilateral blepharitis is sebaceous gland carcinoma until proven otherwise.

#### Management

A full multidisciplinary work-up looking for local and metastatic spread is necessary. Wide surgical excision is necessary and caution must be taken as the tumours can grow from multiple sites and spread can be both deep and superficial. Radiotherapy is unhelpful as these tumours are radioresistant.

#### Malignant melanoma

Primary cutaneous malignant melanoma of the eyelids is rare.

#### Clinical evaluation

Lesions typically have variable pigmentation with darker and lighter regions. They normally have irregular borders. If ulcerating and bleeding this would indicate a vertical (deep-invasion) component with a much worse prognosis. There are several forms of cutaneous melanoma.

- *Lentigo maligna melanoma*: this is the invasive malignant growth phase of lentigo maligna (see section 2.8).
- *Superficial spreading melanoma*: this normally manifests as an irregular plaque with variable pigmentation and has no vertical component.
- *Nodular melanoma*: this can be amelanotic but is normally characterized by a pigmented nodule surrounded by normal skin.

#### Management

Treatment is with wide surgical excision with regional lymph node dissection/sentinel lymph node biopsy if there is microscopic evidence of vascular or lymphatic involvement.

#### Merkel cell carcinoma

This is a rare aggressive primary skin tumour. Lesions are typically solitary red or purple dome-shaped nodules or firm plaques. Treatment is with wide local excision but owing to its high malignancy adjunct treatment may be required.

#### Kaposi sarcoma

This is a tumour of probable endothelial cell origin that typically affects patients with AIDS. The lesions are purple or red and highly vascular with surrounding telangiectatic vessels. They may be macular, plaque-like, or nodular. Treatment is by radiotherapy, as these lesions are exquisitely radiosensitive, or by excision.

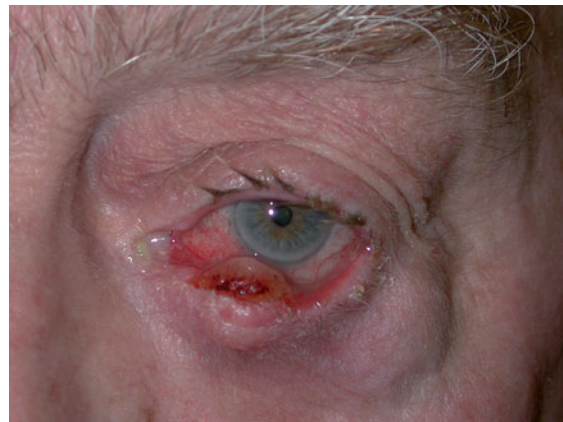

Fig. 2.29 Squamous cell carcinoma.

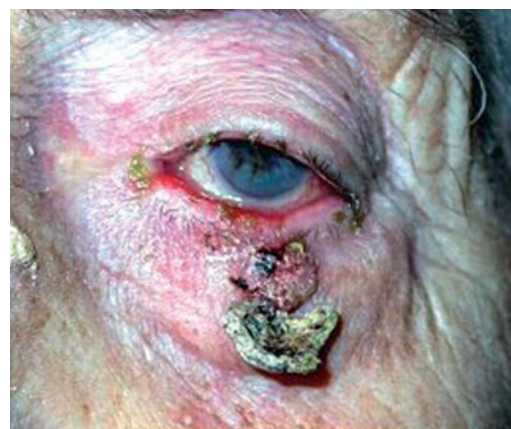
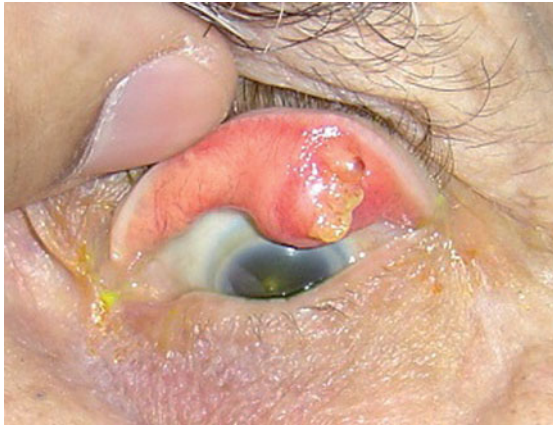
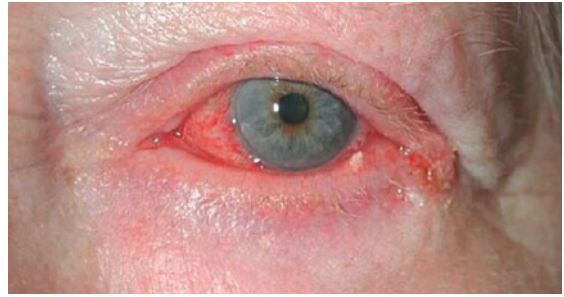Fig. 2.30 Squamous cell carcinoma associated with a cutaneous horn.



**Fig. 2.31** Sebaceous gland carcinoma masquerading as a chalazion.



**Fig. 2.32** Sebaceous gland carcinoma masquerading as chronic blepharoconjunctivitis.

## 2.10 Epiphora

This refers to the symptom of a watery eye and can be caused by overproduction of tears (hyperlacrimation), lid malposition, or outflow obstruction due to a problem with the nasolacrimal system. Hyperlacrimation occurs due to ocular surface problems such as blepharitis and dry eye (see Chapter 1) and will not be discussed in detail here. Lid malpositions are discussed in sections 2.3 & 2.4.

### Evaluation of the patient with acquired epiphora

#### 1. History

**Table 2.1 Symptoms due to hyperlacrimation and outflow obstruction**

Symptoms due to hyperlacrimation	Symptoms due to outflow obstruction
Intermittent symptoms	Constant/intermittent symptoms
Symptoms worse indoors with heating on (dry eyes)	Symptoms worse when outside in the cold and wind
Normally mild tearing	May be severe tearing with tears spilling over on to cheek
Symptoms of associated ocular surface problems: burning, stinging, itching, etc.	Symptoms of previous or current nasolacrimal infection: mucus/purulent discharge

#### 2. Examination

##### *For evidence of ocular surface disease*

Such as trichiasis, blepharitis, rapid tear break-up time, and/or punctate epithelial corneal erosions.

##### *Marginal tear strip*

This can be elevated in outflow obstruction. It can be low, absent, or irregular in dry eyes. This can be further evaluated with instillation of one drop only of 2% fluorescein into the lower fornix. The fluorescein normally disappears after 5 minutes. Prolonged retention of fluorescein can be indicative of reduced drainage.

##### *Puncta and lids*

- Look for evidence of a small, stenosed, inflamed, or occluded punctum.
- Look for punctal eversion or medial ectropion where the puncta sits away from the conjunctival tear lake.
- Look for frank ectropion and entropion.

##### *Lacrimal sac*

Examine for evidence of a visibly distended lacrimal sac due to a mucocele or acute dacryocystitis (see section 2.11).

##### *Jones dye test*

See table 2.2.

In practice both the Jones 1 (primary) and Jones 2 (secondary) tests described here, despite sound clinical principals, give a variable diagnostic yield and so are rarely performed.

##### *Syringing and probing*

See below.

### 3. Investigations

#### *Dacryocystography*

This is not commonly performed but can be useful if the diagnosis is not conclusive from history and examination alone. With this technique the anatomy of the nasolacrimal system can be visualized in great detail. The technique involves irrigating the nasolacrimal system with contrast medium before obtaining radiographs. It provides little information regarding function.

#### *Scintigraphy*

This is a radionuclide test that can be useful in functional obstruction where troublesome symptoms of epiphora are present with no anatomically identifiable blockage.

#### *Computed tomography (CT)*

This can be useful after cases of trauma to the bony surround of the nasolacrimal apparatus or if there is suspected sinus disease or rarely tumour.

### Syringing and probing

This can only be performed if the puncta are patent. The procedure is as follows.

#### *Anaesthetic*

Instil adequate topical anaesthesia.

#### *Punctal dilation*

Using a blunt Nettle ship dilator gently to enlarge the puncta.

#### *Diagnostic probing*

The lower lid should be pulled laterally to straighten the canaliculus prior to probing. Use a 00punctal wire probe which can be smeared with chloramphenicol ointment for lubrication. An attempt is made to carefully advance the probe via the lower punctum until a 'stop' is felt. It is important to feel whether the cannula is resisted by something hard (hard stop) or soft (soft stop).

- *Hard stop*: this occurs if the cannula enters the lacrimal sac and can be advanced up against the medial wall of the sac which lies against the lacrimal bone. This suggests patency of the proximal portion of the nasolacrimal system.
- *Soft stop*: this occurs if the cannula stops at or proximal to the junction of the common canaliculus and the lacrimal sac. This suggests that there is an obstruction of one of the canaliculi or at the opening of the common canaliculus into the lacrimal sac (internal opening).

#### *Irrigation*

This is performed via the lower or upper punctum with a curved, blunt-tipped lacrimal cannula on a 2.5ml syringe filled with saline. The tip of the cannula is gently advanced a few millimetres. Again remember to pull the lid laterally. Saline is gently irrigated. If saline flows freely into the nose then the nasolacrimal drainage system is patent. If there is regurgitation through the opposite punctum then common canaliculus obstruction is likely. If there is regurgitation through the ipsilateral punctum then ipsilateral canaliculus obstruction is likely. If mucus or fluorescein regurgitates, then there is likely to be a dilated lacrimal sac or mucocele.



Table 2.2 Jones dye tests			
Method	Result	Interpretation	
1 2% Fluorescein, instilled into fornix; then at 5 minutes a cotton-tipped applicator is inserted into the nose.	Positive=fluorescein recovered from nose Negative=no fluorescein recovered from nose	Physiologically patent nasolacrimal system Partial lacrimal duct obstruction or lacrimal pump failure	
2 Residual fluorescein flushed by irrigation	Positive (as for Jones 1) Negative with saline alone in nose Negative with regurgitation	Partial nasolacrimal duct obstruction Punctal/canicular stenosis Complete nasolacrimal duct/common canaliculus obstruction	



**Fig. 2.33** Prolonged retention of fluorescein and raised tear film.

## 2.11 Acquired nasolacrimal system abnormalities

### Punctal stenosis

This is identified on examination as a visibly small punctum. Overlying conjunctiva may be visible. Often the punctum is too small to permit introduction of a Nettle ship dilator. If punctal dilation is possible then the patient may report a transient improvement in symptoms after dilation.

#### Treatment

The mainstay of treatment is a punctoplasty two- or three-snip procedure in which the posterior wall of the canaliculus is opened. A triangular wedge of conjunctiva including the posterior wall of the canaliculus is excised with Vanna's scissors.

### Punctal eversion/medial ectropion

Examination here needs to be directed to the extent of punctal malposition. It can be helpful to ask the patient to look up and down as subtle changes in lid position during these movements may reveal the punctal eversion.

#### Treatment

Treatment needs to be planned according to the cause, nature, and extent of the punctal malposition. Inversion of the punctum back into the tear lake may be achieved by removing a diamond-shaped piece of conjunctiva inferior to the lower canaliculus. The wound edges are then approximated with a bite of the lower-lid retractors. More extensive medial ectropion can be managed as above and with additional lid-shortening procedures (see sections 2.3 and 2.4).

### Canalicular obstruction

Causes of canalicular obstruction can be congenital or due to trauma, herpes virus, systemic cytotoxic drugs, or cicatricial conjunctivitis. These factors can also cause solitary punctal stenosis.

#### Treatment

Options depend on the extent of the obstruction. For incomplete obstruction silicone intubation of the nasolacrimal drainage system can be useful but has variable results. More extensive obstruction of the common canaliculus may require a canaliculodacryocystorhinostomy (Lester-Jones tube insertion). Complete obstruction of both the upper and lower canaliculi requires a conjunctivodacryocystorhinostomy or Lester-Jones tube.

### Canaliculitis

This is normally chronic. The most common cause is infection with the anaerobic Gram-negative rod bacterium *Actinomyces israelii*. There may be a history of punctal plug insertion for dry eyes. On examination the patient may have evidence of an inflamed and tender lid margin surrounding the affected canaliculus. There may be a pouting punctum and concretions or stringy discharge can be expressed at the punctum.

#### Treatment

Conservative treatment with warm compresses and medical treatment with topical antibiotics is rarely curative. Definitive treatment is to perform a canaliculotomy, remove any concretions or discharge, and irrigate with penicillin. The canaliculotomy is left to heal by secondary intention.

### Dacryocystitis

This is infection and distension of the lacrimal sac commonly associated with nasolacrimal duct obstruction and subsequent stagnation

of tears, debris, and bacteria in the lacrimal sac. Gram-positive bacteria are the most common cause.

#### Acute dacryocystitis

This presents with epiphora and a red, raised painful lump in the region of the lacrimal sac below the medial canthal tendon. There may be purulent discharge at the puncta. There may be associated cellulitis.

#### Treatment

Irrigation and probing of the canicular system should be avoided. Topical antibiotics alone are not adequate and broad-spectrum oral antibiotics such as augmentin are necessary. In patients with associated cellulitis, intravenous therapy may be indicated. When the acute infection has subsided the definitive treatment is a dacryocystorhinostomy (DCR) procedure (see below).

#### Chronic dacryocystitis

This presents with epiphora and mucus discharge. There may have been a history of previous acute dacryocystitis. There is a painless swelling in the region of the lacrimal sac which represents a mucocele. Gentle pressure on the mucocele normally results in reflux of mucoid material through the puncta or directly on to the skin if a fistula has developed. Treatment is with DCR to prevent recurrent attacks of acute dacryocystitis.

## Dacryocystorhinostomy (DCR)

#### Principle

To create a channel for the flow of tears directly between the lacrimal sac and the nasal cavity.

#### Indications

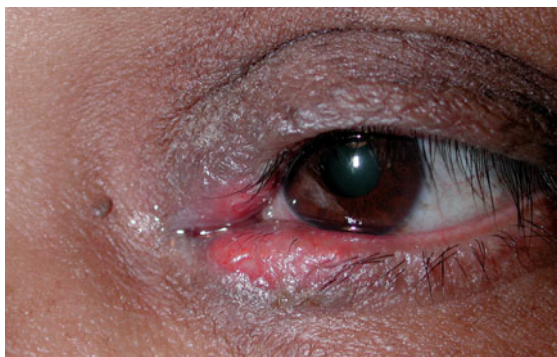- Dacryocystitis.
- Partial or complete nasolacrimal duct obstruction with symptomatic epiphora.

#### External DCR technique

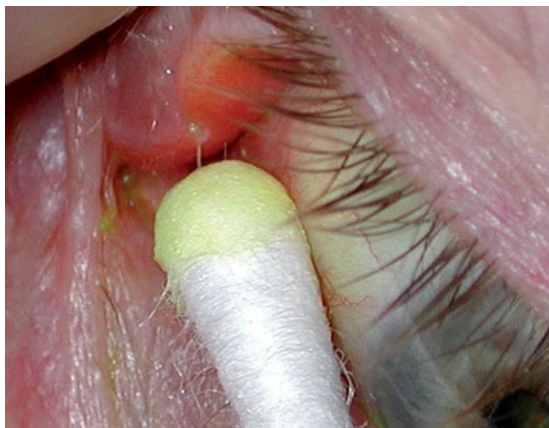
- A skin incision is made medial to the medial canthus on the flat of the nose.
- The superficial part of the medial canthal tendon is divided.
- A bony window (rhinostomy) is created from the floor of the lacrimal fossa to the nasal mucosa.
- Anterior and posterior flaps are fashioned from the nasal mucosa as well as the lacrimal sac.
- The corresponding anterior and posterior flaps are sutured together promoting primary intention healing (and less scar formation).
- Silicone tube intubation of the canalicular system may be performed to prevent excessive scar formation occluding the internal opening of the canaliculus into the sac.
- The skin is sutured closed.

#### Transnasal endoscopic DCR

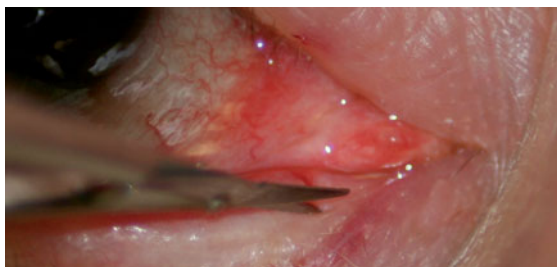This technique has the advantage of not causing a cutaneous scar. It requires more powered instrumentation and an expertise in endoscopic surgery. It relies on secondary intention healing and usually has a slightly lower success rate than external DCR.



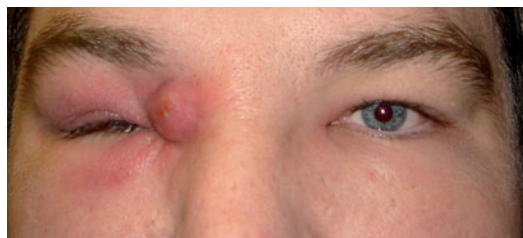**Fig. 2.34** Canaliculitis.



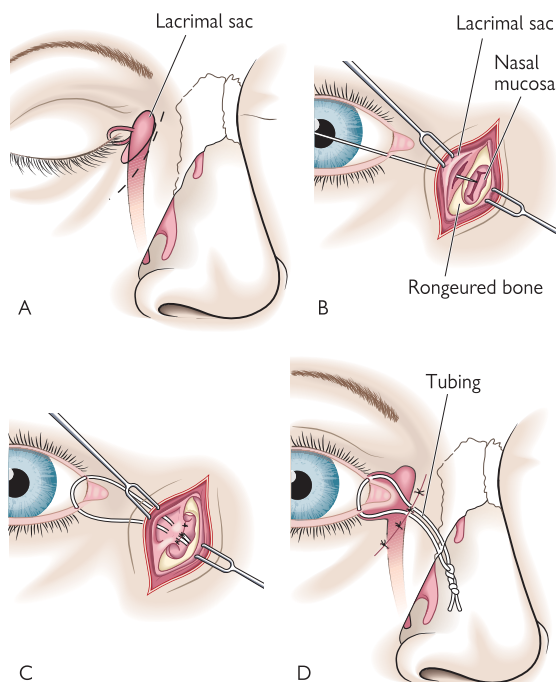
**Fig. 2.35** Canaliculitis with stringy discharge expressed from the punctum.



**Fig. 2.36** Three-snip procedure. The Vanna's scissors are within the lower canaliculus ready to make the horizontal cut. A further vertical cut is then made followed by an oblique joining cut.



**Fig. 2.37** Acute dacryocystitis with secondary preseptal cellulitis.



**Fig. 2.38** External DCR. (A) Incision is marked 10mm from the medial canthus, starting just above the medial canthal tendon and extending inferiorly. (B) Bone from the lacrimal fossa and anterior lacrimal crease has been resected. Flaps have been fashioned in the nasal mucosa. A lacrimal probe extends through an incision in the lacrimal sac. (C) Anterior lacrimal sac flap is sutured to the anterior nasal mucosal flap after a silicone tube is placed. (D) Final position of the silicone tube following closure of the skin incision.

## 2.12 Congenital abnormalities

### Blepharophimosis syndrome

This is a rare autosomal dominant congenital disorder. It is characterized by:

- severe bilateral ptosis,
- telecanthus (widening of intercanthal distance due to long medial canthal tendons),
- epicanthus inversus (a fold of skin extending from the medial portion of the lower lid to the medial portion of the upper lid).

Other features may include lateral lower-lid ectropion, poorly developed nasal bridge, and hyperplasia of the superior orbital rims. Females are infertile.

#### Treatment

- Treating any amblyopia that may be present is essential.
- Surgical treatment in stages usually involves correction of the telecanthus and epicanthus inversus followed by bilateral frontalis suspension procedures for the ptosis.

### Epiblepharon

This condition arises when the lower eyelid pretarsal muscle and skin override the lower eyelid margin to form a horizontal tissue fold, diverting the lower lashes vertically upwards towards the globe. It is most common in children of Asian origin.

#### Treatment

This is normally conservative as the condition tends to resolve as the child grows older. If there is lash–corneal touch then lubricants can be useful. In more advanced cases surgical correction is necessary.

### Epicanthus

This is a normally bilateral medial canthal fold. It can make the affected child seem esotropic because the sclera is covered nasally by the fold. The fold can occur in four configurations:

1. epicanthus tarsalis: fold is most prominent in the upper lid;
2. epicanthus palpebralis: fold is equally distributed across the upper and lower lids;
3. epicanthus inversus: fold is most prominent in the lower lid;
4. epicanthus supraciliaris: fold runs from the eyebrow to the lacrimal sac region.

#### Treatment

Most cases do not require treatment and resolve as the child grows. In cases that do not resolve surgical correction may be considered.

### Eyelid coloboma

This is a partial- or full-thickness embryological eyelid defect. Upper-lid defects that occur medially are normally an isolated anomaly. Lower-lid defects occurring laterally are often associated with systemic conditions such as Treacher Collins syndrome or Goldenhar syndrome.

#### Treatment

For small defects treatment is with primary closure. Larger defects may require lateral canthal semicircular flaps.

### Congenital obstruction of the nasolacrimal system

#### Nasolacrimal duct obstruction

This normally occurs due to delayed canalization of the nasolacrimal duct due to the membranous obstruction at the valve of Hasner.

#### Clinical evaluation

Presentation is with epiphora and matting of the eyelashes. Mucopurulent discharge may be present upon pressure over the lacrimal sac. Acute dacryocystitis is an uncommon association. It is important to rule out other causes of epiphora in infants, especially congenital glaucoma.

#### Treatment

Conservative measures include regular massaging of the lacrimal sac to try and encourage patency through the membranous obstruction. Topical antibiotics are indicated if there is a concurrent bacterial conjunctivitis.

In approximately 90–95% cases spontaneous recanalization of the nasolacrimal duct occurs by the age of 1 year. Therapeutic probing is therefore delayed until the child is 1 year old if symptoms are still present. Probing of the nasolacrimal duct results in perforation of the obstructing membrane and is successful in the vast majority of cases but may need repeating.

#### Dacryocystocele

This is a collection of mucus (mucocele) or amniotic fluid (amniotocoele) in the lacrimal sac due to an imperforate valve of Hasner.

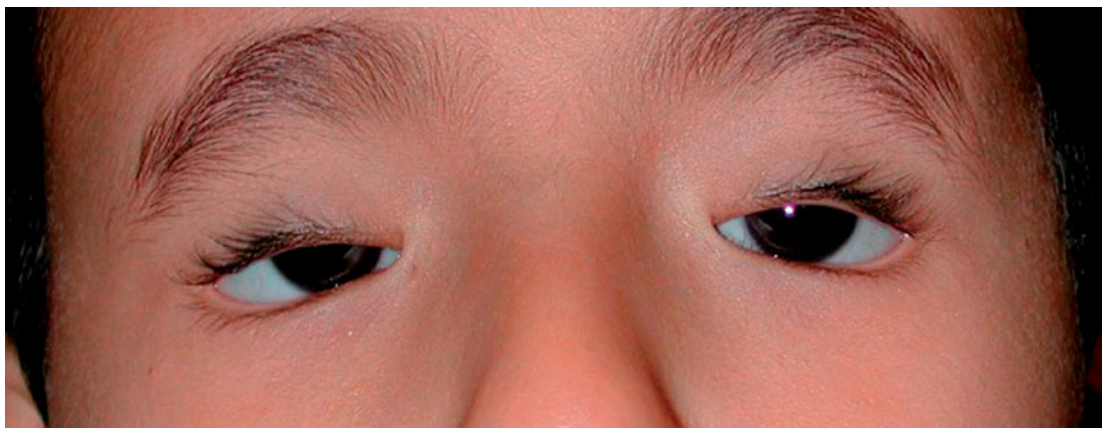#### Clinical evaluation

Patients present in the perinatal period with a dilated swelling below the medial canthal tendon.

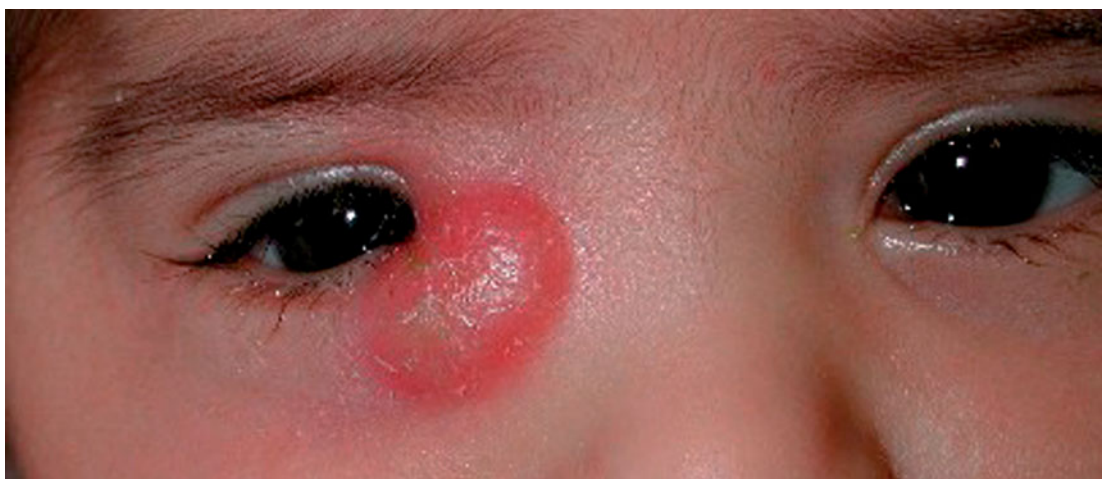#### Treatment

This should be initially conservative with local massage and topical antibiotics. If there is no response within 2 weeks or if infection develops then therapeutic probing may be indicated.





**Fig. 2.39** Blepharophimosis syndrome.



**Fig. 2.40** Acute dacryocystitis secondary to congenital nasolacrimal duct obstruction.



## 2.13 Miscellaneous

### Eyelid trauma

#### Blunt trauma

This type of injury commonly manifests with oedema and echymosis (bruising) of the lids and periorbital region. It is important to exclude associated globe, orbital, or head injuries.

#### Eyelid laceration

Careful exploration of the nature and extent of the wound is necessary as well as removal of all foreign body materials. Laceration involving only the skin and orbicularis normally require skin sutures only.

#### Eyelid-margin lacerations

These injuries require careful approximation of lid-margin edges to prevent notch formation and ocular surface exposure. The procedure for repair involves placing a 6.0 vicryl suture in the grey line. Care must be taken to place this suture quite wide and deep to prevent cheese wiring. Also, 6.0 vicryl should be used for tarsal sutures and lash line sutures. The grey-line suture can then be tied off and buried. The skin can be closed with 7.0 vicryl.

If the canaliculus is involved, a canalicular stent needs to be placed at the same time as primary repair to prevent obstruction of the canalicular system. This stent is left *in situ* for several months.

### Eyelid retraction

This results in exposure of sclera between the corneal limbus and eyelid margin. Lower-lid retraction can be a normal variant but upper-lid retraction is pathological. More severe cases can result in lagophthalmos (an inability to fully close the eyelids). There are many causes of retraction, the most common being:

- thyroid eye disease;
- iatrogenic: over-correction of ptosis/dermatochalasis, following vertical muscle squint surgery;
- over-compensation for a contralateral ptosis;
- pseudoretraction due to a prominent globe;
- shallow orbits as a racial variant.

#### Treatment

This depends on the underlying aetiology. Mild cases can be treated with lubricants and ointments to prevent the risk of exposure keratopathy (see Chapter 1). There are a large variety of surgical options for treatment of more severe retraction depending on the underlying aetiology.

### Lateral tarsorrhaphy

This is indicated in corneal exposure from any cause; for example, lid retraction or seventh cranial nerve palsy. It can be either temporary or permanent. The procedure involves surgically opposing the upper and lower lids at the lateral canthus. However, the cosmetic result is often unacceptable to the patient, which is why a lateral tarsal sling is preferred.

### + Botulinum-toxin injections

Botulinum toxin is used commonly in facial dystonias, including blepharospasm and hemifacial spasm. It can be used in the temporary management of entropion as well as facial asymmetry (e.g. contralateral injection in facial nerve palsy). It can be used to induce a protective ptosis (e.g. for a non-healing corneal ulcer or an acute facial palsy). Temporary paralysis of the levator with botulinum toxin induces a ptosis, which protects the cornea from further exposure. It is only appropriate if the patient is prepared to temporarily lose functional vision in the affected eye.

The procedure for induction of ptosis is as follows:

1. application of topical anaesthesia;
2. the upper eyelid is everted: the toxin is administered via injection above the upper border of the tarsus into the subaponeurotic space lateral to the midline;
3. medical treatment should be continued until the ptosis occurs, which can take up to 3 days.

Potential complications are vertical diplopia if the toxin inadvertently reaches and paralyse the superior rectus.

### Dermatochalasis

This is a common condition normally occurring in elderly patients. It is characterized by excess eyelid skin and may be associated with orbital fat prolapse. It can cause a mechanical ptosis or pseudoptosis. Treatment is for cosmesis or if there is a superior field defect. Treatment is with a blepharoplasty in which the redundant eyelid skin is removed. It is important to assess the brow position as a low brow contributes to dermatochalasis and may need to be corrected first.

### Floppy eyelid syndrome

This condition is characterized by lax upper eyelids that have the propensity to spontaneously evert during sleep. The result of this is exposure of the upper tarsal conjunctiva and chronic papillary conjunctivitis. On examination lateral traction on the upper lid can result in easy eversion. A number of conditions are associated with this syndrome, including obesity, obstructive sleep apnoea, and eye rubbing.

#### Treatment

Conservative treatment options include eyelid patching, an eye shield, and taping of the lids. Surgical treatment is often required and involves upper horizontal lid shortening procedures, canthal stabilization, and occasionally similar surgery to the lower lid.

### Eyelid imbrication syndrome

This condition, like floppy eyelid syndrome, also arises due to upper eyelid laxity. During the blink cycle the upper eyelid overrides the lower lid, resulting in chronic conjunctivitis of the upper eyelid. Conservative treatment is with topical lubricants. Surgical management is with horizontal lid tightening.

### Allergic lid swelling

#### Atopic dermatitis (eczema)

This is often associated with generalized eczema, asthma, and hayfever. Patients complain of itchy/dry/swollen eyelid skin. More severe cases result in thickening and fissuring of the eyelid skin. There may be associated vernal or atopic keratoconjunctivitis. Treatment for mild cases is with allergen avoidance advice together with emollients such as E45 cream. More severe cases will require topical steroids.

#### Contact dermatitis

This manifests in the eyelids as a type IV hypersensitivity reaction to the active ingredient or preservatives of topical medication. Patients present with swelling, erythema, and crusting of the eyelids. Symptoms normally resolve on withdrawal of the cause.

### Acute allergic oedema

This is characterized by acute normally bilateral, painless lid oedema. Causes include angioedema and drug reactions. Treatment is with systemic antihistamines.

### Blepharochalasis

This is a rare variant of angioneurotic oedema that occurs in young patients. It is characterized by idiopathic episodes of acute eyelid oedema. With time the eyelid skin becomes chronically thinned, which can take on the appearance of dermatochalasis.

## Infectious lid swelling

### Herpes simplex

This presents with crops of vesicles, which after a few days will rupture, crust and heal. It can be associated with a variety of ocular surface conditions (see Chapter 1). Treatment is with topical aciclovir ointment.

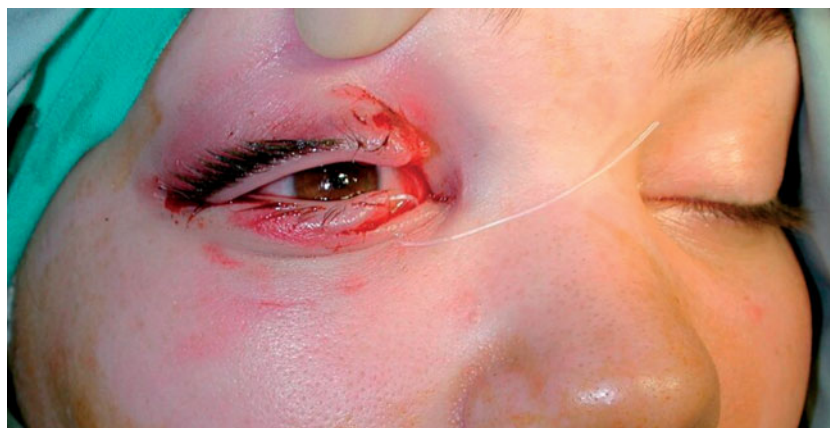### Herpes zoster ophthalmicus (HZO)

This normally affects elderly or immunocompromised individuals. Presentation is with tingling followed by pain in the distribution of the ophthalmic division of the trigeminal nerve (Va). The first signs are normally a raised erythematous rash in the distribution of the Va dermatome. The rash but not necessarily the oedema respects the midline. After a few days vesicles form which eventually crust over. Treatment is with aciclovir 800 mg orally 5 times/day for 1 week.

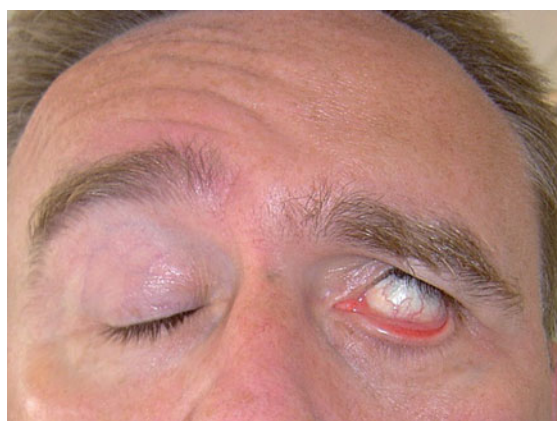### Bacterial causes of lid swelling

There are a number of bacterial infections that can cause eyelid infections, including:

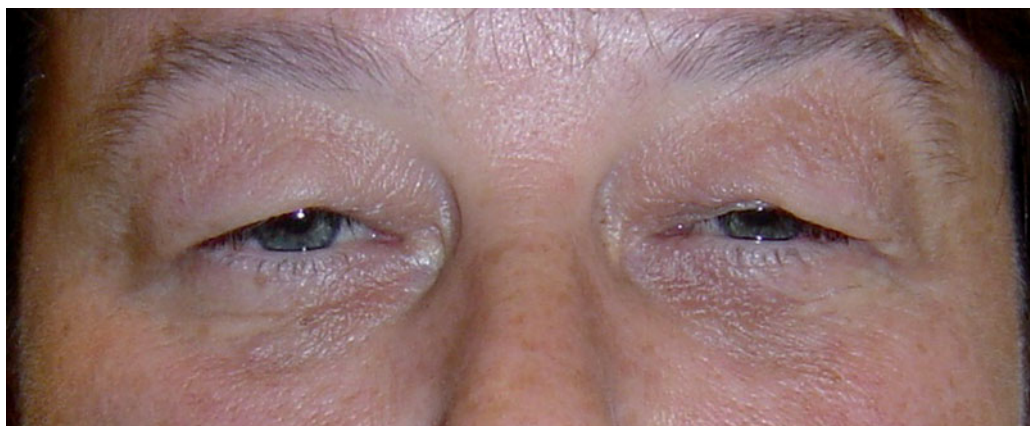- impetigo (*Staphylococcus aureus*, *Streptococcus pyogenes*),
- erysipelas (*Strep. pyogenes*),
- necrotizing fasciitis (*Strep. pyogenes*, *Staph. aureus*).



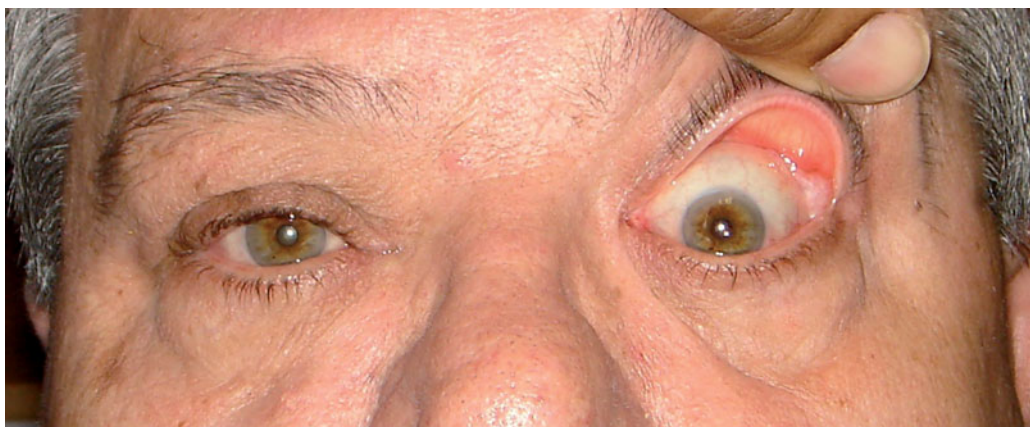**Fig. 2.41** Eyelid lacerations of upper and lower lids involving the canaliculus. Note the canalicular stent *in situ* within the lacerated lower canaliculus. Another stent, for the purpose of illustrating the dimensions, has been placed on the bridge of the nose.



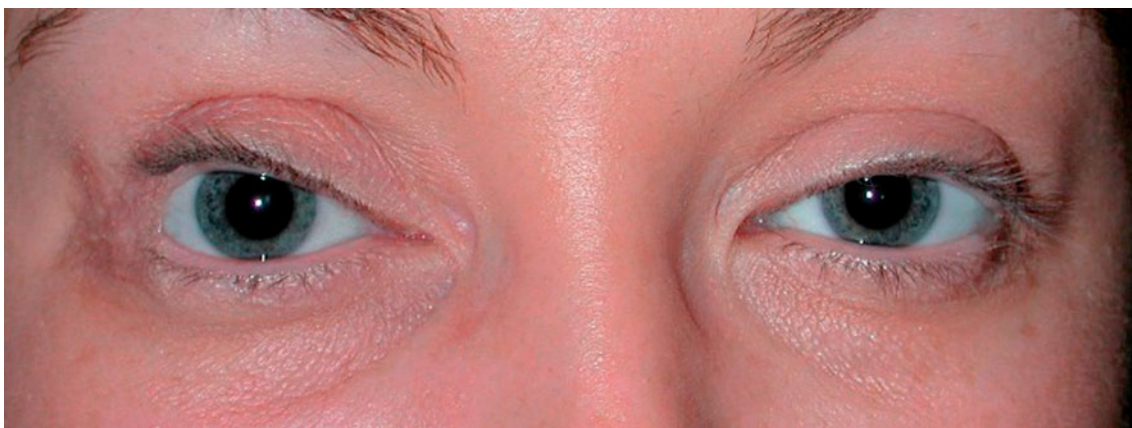**Fig. 2.42** Left facial nerve palsy with severe lagophthalmos and brow ptosis.



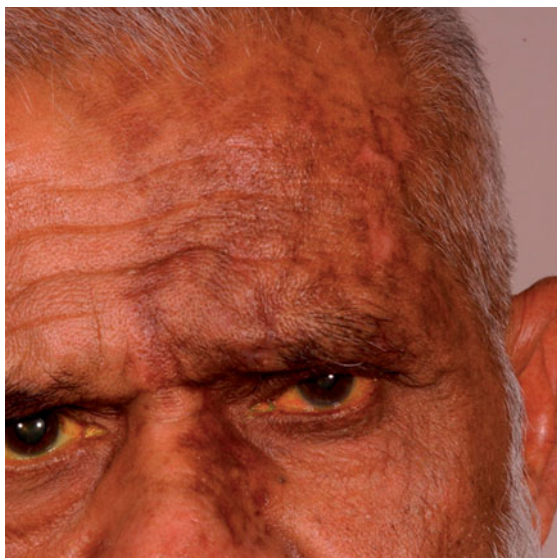
**Fig. 2.43** Dermatochalasis.



**Fig. 2.44** Floppy eyelid syndrome.



**Fig. 2.45** Blepharochalasis with chronic skin changes and stretching of the lateral canthus.



**Fig. 2.46** HZO. Note the characteristic distribution of the skin rash.



## 2.14 Case-based discussions

### Case 1 Epiphora

A 45-year-old man attends the clinic complaining of a watery right eye for several months. He complains that the tears stream constantly down his face. He suffered a cut below the right lower eyelid from an injury with a fishing hook 1 year previously. He was treated for this with steristrips in his local emergency department and discharged.

On examination his visual acuity is 6/6 in both eyes. He has a vertical hypertrophic scar 3 mm below the right lower lid. He has a right ectropion. His nasolacrimal system is completely patent on syringing. The cornea is clear and ocular examination is otherwise unremarkable.

- 1 What is the cause of this gentleman's epiphora?
- 2 What is the likely cause of this gentleman's ectropion?
- 3 Why is syringing and probing indicated in this case?
- 4 What other examination would help confirm the diagnosis?
- 5 What are the treatment options?

#### Discussion

- 1 Ectropion and consequent punctal and lid malposition.
- 2 Cicatricial ectropion due to hypertrophic scar and anterior lamella shortening.
- 3 To exclude any canalicular and nasolacrimal-system obstruction, possibly secondary to the initial injury.
- 4 It is important to test for canthal or horizontal lid laxity as potential causes for ectropion.
- 5 The treatment of choice is a Z-plasty or skin graft to the scar to relieve the tension and consequent ectropion.

### Case 2 Ptosis

An 80-year-old lady presents complaining of a droopy left upper eyelid for several months. She complains that the vision in the left eye has also gone down a little. She has no double vision. On examination she has no anisocoria and her ocular movements are normal. She has a 3 mm left ptosis. Her levator function is 13 mm on the left and 15 mm on the right. She has elevated skin creases bilaterally.

1. What is the most likely cause of this lady's ptosis and why?
2. Why might her vision have gone down?
3. What is the significance of not having anisocoria and having normal eye movements?
4. What are the treatment options?
5. What are the complications of ptosis surgery?

#### Discussion

1. Involutional ptosis is the most common cause in a patient of this age. The diagnosis is further supported by the relatively good levator function and the elevated skin creases.
2. Ptosis can cause superior visual field defects especially if the lid margin covers the pupil margin.
3. It helps to exclude third nerve palsy or Horner's syndrome as a potential diagnosis.
4. No treatment is a possibility but likely to be unacceptable to the patient given the degree of ptosis. Definitive treatment is with an anterior levator aponeurosis repair. There may well be a ptosis on the contralateral side and bilateral surgery should be considered.
5. See section 2.5.

### Case 3 Lid lump

A 70-year-old man presents complaining of a right lower-lid lump that has been present for several months. He has recently noticed crusted blood on the lump. He is otherwise well with no other past ophthalmic or medical history.

On examination he has a raised right lower-eyelid lump with central ulceration. There is telangiectasia on the surface of the lump.

1. What is the likely diagnosis?
2. How can the diagnosis be confirmed?
3. What are the major risk factors for developing this condition?
4. What are the treatment options?

#### Discussion

1. BCC of the eyelid.
2. By punch biopsy or by excisional biopsy.
3. Age and history of sun exposure.
4. Surgical excision, radiotherapy, or cryotherapy.

### Further reading

Colour Atlas of Lacrimal Surgery. J Olver (Butterworth Heinemann 2002).

A Manual of Systematic Eyelid Surgery. J R O Collin (Third Edition, Elsevier 2006).



## Chapter 3

# Vitreoretinal surgery

Fred K. Chen and Simon D.M. Chen

---

### Basic sciences

- 3.1 Retinal anatomy and physiology 104

---

### Clinical skills

- 3.2 Posterior segment history taking and examination 106  
3.3 Diagnostic lenses 108

---

### Practical skills

- 3.4 Optical coherence tomography 110  
3.5 Ultrasonography 112  
3.6 Retinal photocoagulation 114

---

### Clinical knowledge

- 3.7 Vitreous disorders 116  
3.8 Retinal detachment I 118  
3.9 Retinal detachment II 120  
3.10 Peripheral retinal abnormalities 122  
3.11 Macular surgery 124  
3.12 Submacular surgery 126  
3.13 Retinal tumours I 128  
3.14 Retinal tumours II 130  
3.15 Choroidal tumours I 132  
3.16 Choroidal tumours II 134  
3.17 Vitreoretinopathies 136  
3.18 Retinopathy of prematurity 138  
3.19 Posterior segment trauma 140

---

### Case-based discussions

- 3.20 Case 1 Retinal detachment 142  
Case 2 Elevated fundal mass 142

## 3.1 Retinal anatomy and physiology

### Retinal anatomy

#### Embryology

The neurosensory retina (NSR) and retinal pigment epithelium (RPE) are derived from neuroectodermal cells in the forebrain region of the neural plate. They form the inner and outer layers of the optic cup. The hyaloid vascular system nourishes the lens and inner layer of the optic cup, later regressing and leading to formation of the vitreous gel. Condensation of mesodermal and neurocrest-derived cells around the optic cup forms the choroid and sclera. The distal edge of the optic cup forms the pupillary border of the iris. Therefore, the RPE and NSR are continuous with the epithelium of the ciliary body and iris.

#### Vitreous

The vitreous, located between the lens and the retina, occupies the majority (80% or 4 ml) of the globe volume. Although 99% of the vitreous is composed of water, collagen (type II) fibrils and associated hyaluronan impart a gel-like consistency. The patellar fossa is a depression in the anterior vitreous gel, which accommodates the lens. The vitreous base straddles the ora serrata and is strongly adherent to the posterior 2 mm of the pars plana epithelium and 1–4 mm of the anterior retina. Other areas of firm vitreoretinal attachment occur at the margin of the optic disc, major retinal vessels, fovea, and parafoveal regions. Regression of the hyaloid vessel leaves an empty Cloquet's canal, running from the posterior pole of the lens to the optic disc.

#### Neurosensory retina

The NSR is a thin (200  $\mu\text{m}$ ) neural tissue that extends from the ora serrata to the optic disc margin. The NSR has three layers of cells separated by the inner and outer plexiform layers. The outer nuclear layer contains the photoreceptor cell bodies and nuclei. The middle layer of cells, confusingly called the inner nuclear layer, contains the cell bodies of bipolar, horizontal, and amacrine cells. The innermost layer of cells form the ganglion cell layer. The unmyelinated nerve fibres of the ganglion cells extend along the inner retinal surface towards the optic nerve head, forming the nerve fibre layer. Müller cells extend the entire thickness of the NSR with their apical sides extending to the photoreceptor inner segments and their basal sides in contact with the internal limiting membrane, a basement membrane separating the NSR from the vitreous.

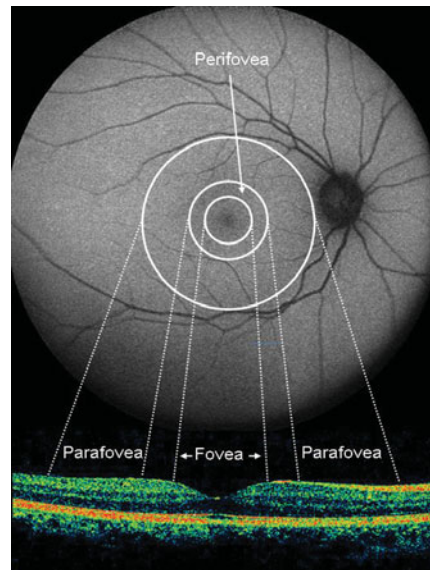
The macular lutea (also called the macular, posterior pole, or area centralis) is an oval retinal area containing yellow xanthophyll pigments and two or more layers of ganglion cells. It measures 5–6 mm in diameter and is located between the temporal retinal vascular arcades. The fovea is a central depression in the macula measuring 1.5 mm in diameter. The foveola is the central floor of the fovea which contains a single layer of NSR consisting of only photoreceptors. The foveal avascular zone is a 250–600  $\mu\text{m}$ -wide area within the central fovea, demonstrable on fluorescein angiography, in which retinal capillaries are absent. The NSR is thickest in the 500  $\mu\text{m}$ -wide rim of retina around the central fovea (parafoveal zone). The remaining rim of macula outside the parafoveal zone is the perifoveal zone.

The extramacular retina is divided into near, middle, and far peripheral retina. The middle peripheral retina is a 3 mm-wide band straddling the equator. The near periphery is a 1.5 mm band, between the arcades and middle periphery and the far periphery is a 6 mm band between the middle periphery and the ora serrata. The posterior limit of the vitreous base and the majority of tractional retinal tears are located in the far periphery.

#### RPE: choroid complex

The RPE is a monolayer of hexagonal cuboidal cells that extends from the ora serrata to the optic disc. The apical side of the RPE is in contact with the photoreceptor outer segments via villous processes. A potential sub-NSR space exists between the photoreceptors and RPE. The basal side of the RPE is attached to Bruch's membrane. This is a five-layer structure composed of the basement membranes of the RPE and choriocapillaris endothelium on the inner and outer sides respectively, and a middle layer of elastic fibres located between an inner and outer layer of collagen. The choriocapillaris is a fenestrated capillary network fed by choroidal arterioles and drained by venules located in the outer layer of the choroidal stroma. The venules converge to form four to six vortex veins. The choroid is loosely attached to the sclera by connective tissue. A potential suprachoroidal space exists between the choroid and sclera.

Submacular RPE cells are taller whereas those in the periphery are flatter and may even contain two nuclei. Specialized proteins found on the apical and basal surfaces of RPE cells have important metabolic and transport functions. Tight, adherens, and gap junctions found at the lateral membrane of the RPE cells are important components of the blood–retinal barrier. Adult RPE cells contain melanin and lipofuscin granules. Fundus autofluorescence imaging utilizes the autofluorescent properties of lipofuscin to image the RPE.



**Fig. 3.1** Fundus autofluorescence image showing absence of autofluorescence at the optic disc, blocked autofluorescence from along the vascular arcade, and reduced autofluorescence in the macular lutea due to xanthophyll pigments. Three zones of the macula are marked and correlated with an image of optical coherence tomography through the foveal centre.

## Retinal physiology

The primary functions of the NSR include phototransduction and initial neural processing of visual information. Prerequisites for normal photoreceptor function include delivery of oxygen and nutrients from choroidal blood flow, metabolic support for photoreceptor outer segments from the RPE, and outer-segment contact with the RPE (an attached retina).

### Visual function

The photoreceptors convert photon energy into a cell membrane potential which leads to reduced release of the neurotransmitter glutamate in the bipolar and horizontal cell synapses in the outer plexiform layer. Visual information is then conveyed to ganglion cells via synapses in the inner plexiform layer and onwards by ganglion cell axons to the lateral geniculate nucleus. Neuromodulation occurs at each synapse, involving cells such as horizontal and amacrine cells.

Cone photoreceptors are concentrated in the fovea whereas rod photoreceptors are concentrated in the parafoveal region. The ratio of cones to rods is 1:20. The photoreceptors contain visual pigments (rhodopsin in rods and iodopsin in cones) which capture photons with varying efficacy dependent upon the energy state of the photon (e.g. green wavelengths in green-sensitive cones). The pigments are localized in the discs of the outer segments for optimal light capture. Light-induced conformational change in the retinal–opsin complex leads to a reduction in cyclic GMP in the cytosol via an amplification cascade involving transducin and phosphodiesterase. In rods, this leads to a reduction in cytosolic calcium concentration and hyperpolarization of the photoreceptor cell. The activation process is rapidly switched off by arrestin and rhodopsin kinase and restored by guanylate cyclase increasing cyclic GMP levels.

Light-sensitive visual pigments contain the 11-*cis* conformation of retinal (an aldehyde of vitamin A) in complex with the opsin protein. Upon stimulation by a photon, the vitamin A converts into the all-*trans* conformation, separates from the opsin and binds to a protein to be transported back to the RPE. The RPE stores the vitamin A and reconverts it to the 11-*cis* form for use by the rod outer-segment opsins. Vitamin A metabolism in cones may be dependent upon the Muller cells. In addition to recycling of vitamin A, the outer segment is constantly regenerated while the distal tip of the outer segment is shed cyclically (rods at dawn and cones at dusk). Rod survival depends upon a balance between these two processes.

### Retinal and choroidal circulation

The retina is supplied by a dual circulation arising from the central retinal artery and the short posterior ciliary arteries. The central retinal artery and its branches are located in the nerve fibre layer. It feeds into a superficial (ganglion cell layer) and a deep (inner nuclear layer) capillary network which has endothelial tight junctions forming the inner blood–retinal barrier. The metabolic requirements of the inner two-thirds of the NSR are supplied by the central retinal artery. The outer third is supplied by the choriocapillaris capillary network from the short posterior ciliary arteries. The outer blood–retinal barrier is formed by intracellular tight junction in the RPE. Up to 75% of retinal oxygen and glucose requirements are supplied by choroidal circulation, reflecting the higher metabolic demand of the outer retina and RPE.

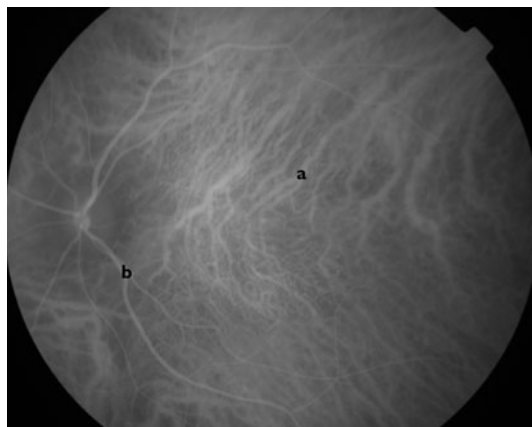
The retinal circulation undergoes autoregulation. Retinal capillary pericytes interact with vascular endothelial cells, providing structural support, assisting in autoregulation and inhibiting endothelial cell proliferation. The pericytes and associated basement membranes are damaged in diabetic retinopathy. The choroidal vasculature is controlled by the autonomic nervous system. The RPE provides trophic support for the choriocapillaris. In age-related macular degeneration (AMD), RPE atrophy leads to choriocapillaris loss and subsequent outer-retinal atrophy.

## Retinal pigment epithelium

Functions of the RPE include maintenance of the outer blood–retinal barrier; vitamin A metabolism, outer-segment phagocytosis, and trophic support for choriocapillaris. RPE also synthesizes melanin which absorbs radiant energy, binds redox-active metal ions, and sequesters reactive chemicals. This underlies the RPE response to laser photocoagulation, siderosis, and drug toxicity. Melanin may have a role in retinal development and the absence of melanin in ocular albinism is accompanied by a lack of foveal development. The RPE expresses class I major histocompatibility complex (MHC) antigens. However, RPE expression of class II MHC antigens can be induced by interferon-gamma, suggesting that the RPE may play a role in autoimmune diseases and contribute to the relative immune privilege of the subretinal space. Through a secretion of a variety of cytokines, the RPE can also modulate the function of macrophages, lymphocytes, and vascular endothelial cells. In addition to secretion of vascular endothelial growth factor (VEGF) which acts on the choriocapillaris, the RPE also secretes other growth factors which have autocrine or paracrine trophic effects on the NSR. RPE cells dedifferentiate during the wound-healing response and may detach from Bruch's membrane, migrate and transform into fibroblast-like and phagocytic cells in response to mechanical, chemical, thermal, or anoxic injury. The RPE may also produce extracellular matrix and metalloproteinases.

### Retinal attachment

Attachment of the NSR to the RPE is a complex physiological process involving RPE metabolic activity (RPE pump), ionic environment modulation by energy-dependent membrane ion channels, specific physico-chemical conditions in the interphotoreceptor matrix, and fluid movement from the vitreous to the choroid. The interdigitation between the tips of the outer-segment and RPE microvilli in combination with adhesive components of the interphotoreceptor matrix contribute to the strength of retinal adhesion.



**Fig. 3.2** Fundus indocyanine angiography demonstrating normal patterns of (a) choroidal and (b) retinal vascular structures.

## 3.2 Posterior segment history taking and examination

### History taking

Diseases affecting the posterior segment can present in a variety of symptoms, which can overlap with optic nerve and other neurological conditions. Accurate history taking is therefore important in eliciting key features and helping to make correct diagnoses.

#### Ocular symptoms

##### Central visual disturbance

- Central visual blurring may occur in a large variety of macular disorders, particularly AMD, central serous chorioretinopathy (CSCR), and macular dystrophies.
- A hypermetropic shift may be seen in association with CSCR, pigment epithelial detachments, or posterior choroido-scleral mass lesions.
- Distortion or metamorphopsia is highly suggestive of macular disease and may occur with choroidal neovascularization (CNV), CSCR, epiretinal membranes, or vitreomacular traction.
- Central or paracentral scotomas occur when areas of photoreceptor loss occur in the macular region.
- Charles Bonnet syndrome is characterized by visual hallucinations (varying from vague unformed images to distinct images of faces or objects). It may occur in association with any cause of visual loss but is most often noticed in patients with AMD.

##### Peripheral visual disturbance

- Visual-field defects may result from central nervous system (CNS) and optic nerve disease, retinoschisis, and retinal detachment.
- Concentric visual-field defects may occur in advanced glaucoma, advanced uveitis, rod dystrophies, and certain drug toxicities.

##### Floater

- Causes include a Weiss ring following posterior vitreous detachment (PVD), vitreous condensations, vitreous haemorrhage, liberated pigment cells associated with retinal tears, inflammatory cells, tumour cells, and asteroid hyalosis.

##### Flashing lights

- Photopsia refers to the perception of light in the absence of a light stimulus. Monocular photopsia is typically due to vitreoretinal pathology whereas binocular photopsia is usually a cortical phenomenon. Causes include:
  1. mechanical retinal stimulation by retinal traction (PVD, retinal tears, flick phosphene), retinal impaction (Moore's streak), or external compression (pressure phosphenes);
  2. subretinal pathology: CNV, uveitis (white dot syndromes), choroidal tumours;
  3. cortical ischaemia (migraine or transient ischaemic attack: scintillations, accompanied by neurological symptoms) or visual hallucinations (Charles Bonnet syndrome).

##### Pain, photophobia

- Posterior segment pathology does not typically produce pain unless associated with anterior segment inflammation, ischaemia, or scleritis.

##### Redness

- Redness is due to conjunctival or scleral vascular engorgement or inflammation, or subconjunctival haemorrhage.

##### Leukocoria

- Leukocoria may be due to lenticular or vitreous opacities, retinal detachment, extensive retinal exudation, or tumour.

#### Colour vision abnormalities

- Colour vision loss is often a feature of optic nerve disease.
- Congenital red-green colour discrimination deficiency is found in 5–8% of males.
- Blue-yellow deficiency is rarely due to congenital colour deficiency. An acquired cause should must be sought.

#### Photoaversion and nyctalopia

- Photoaversion in combination with reduced colour vision and visual acuity may occur in cone dystrophies.
- Nyctalopia with concentric visual-field constriction is characteristic of rod dystrophies.

#### Past ocular history

- Refractive error: myopia is associated with a risk of rhegmatogenous retinal detachment (RRD), some retinal dystrophies and white-dot syndromes. Hypermetropia is common in patients with retinoschisis and choroidal effusions.
- Previous ocular conditions, surgery or trauma should be noted.

#### Past medical history

- Retinal vascular disease may be the presenting feature of diabetes mellitus, hypertension, hyperlipidaemia, sickle cell disease, and prothrombotic states.
- Posterior uveitis, vasculitis, scleritis, and endophthalmitis may be manifestations of systemic infection, systemic autoimmune disease, or malignancy.
- Posterior segment tumours may occur in association with neurophakomatoses, hereditary cancer syndromes, or systemic malignancies.
- Inherited vitreoretinopathies, retinal dystrophies, and choroidal dystrophies may be associated with systemic connective tissue or metabolic disorders.
- A history of medication and drug allergy should be documented.

#### Social history

- Smoking, alcohol, and drug use.
- Recreational and occupational visual tasks, for example reading, driving, flying, and work requiring colour discrimination.

#### Family history

- Important in inherited vitreoretinopathies, retinal dystrophies, and choroid dystrophies.
- May help to distinguish between X-linked, autosomal dominant, or recessive and mitochondrial inheritance patterns.

#### Review of systems

- If an associated systemic condition is thought to be relevant, a full review of systems should be conducted.

### Examination

A methodical and thorough examination of the eye is key to formulating a diagnosis upon which to base further investigations and treatment. Accurate documentation supplemented by imaging investigations provide a baseline for future comparisons. It is important to record both the presence and absence of important clinical signs.

#### Visual function

- Unaided, spectacle-corrected, and pinhole distance visual acuity is commonly measured using a Snellen chart, although in research settings distance best-corrected visual acuity is more appropriately determined using a logMAR acuity chart such as the ETDRS chart.

- Near visual acuity should be documented using a near vision chart.
- Other parameters of visual function may be measured depending upon the clinical situations e.g. central visual field (Amsler grid), colour vision (Ishihara chart), reading speed (MNRead chart), and contrast sensitivity (Pelli–Robson chart).

### External exam

- Note signs of previous periocular disease and treatment (e.g. cancer, trauma, radiation).
- Abnormalities of globe size and ocular alignment.
- Check pupil reflexes, pupil shape, and iris colour.

### Vitreous

- The anterior vitreous is best visualized with dynamic slit lamp biomicroscopy of the retrolental vitreous gel (ask the patient to generate saccadic eye movements before looking into the primary position).
- Document the presence or absence and severity of vitreous cells (inflammatory, neoplastic, or pigmentary cells) or vitreous opacities (asteroid hyalosis, synchysis scintillans, vitreous haemorrhage, foreign body).
- Look for signs of a PVD (Weiss ring, visible posterior hyaloid membrane).
- Qualitative assessment of vitreous anatomy and fibrillar pattern may provide clues to the presence of hereditary vitreoretinopathies, for example Stickler syndrome.

### Retinal vasculature

- Note the appearance of the retinal vessels in terms of vessel calibre, colour, and changes at arteriovenous crossings.
- Arteriolar narrowing may be seen in association with systemic hypertension, vascular occlusions, retinal dystrophies, or drug toxicities.
- Venous dilatation, beading, and loops are commonly seen in severe pre-proliferative and proliferative diabetic retinopathy.
- Arteriovenous nipping may occur with chronic hypertension and arteriosclerosis.
- Retinal neovascularization typically occurs at the junction between non-perfused and perfused retina. Neovascularization may be flat or elevated.
- Intraretinal microvascular abnormalities are a feature of severe non-proliferative diabetic retinopathy appearing as a fine network of vessels forming shunts between retinal arteries and veins found at the junction of non-perfused and perfused retina.
- A variety of arteriolar emboli may be observed including calcium, cholesterol, platelet, talc, or septic emboli.
- Retinal vasculitis is characterized by a white or yellowish sheathing of the vessels. The type of vessel involvement (periarteritis or periphlebitis) should be noted.

### Macular

- Note the presence and quality of the foveal reflex.
- Look for epiretinal membranes and associated changes (retinal vascular distortion, retinal thickening, pseudoholes).
- Retinal thickening and oedema may be assessed with oblique slit beam illumination and high magnification contact lens examination. The location (in relation to the fovea) and extent of retina thickening should be documented. Associated features such as microaneurysms and retinal exudates should also be noted.

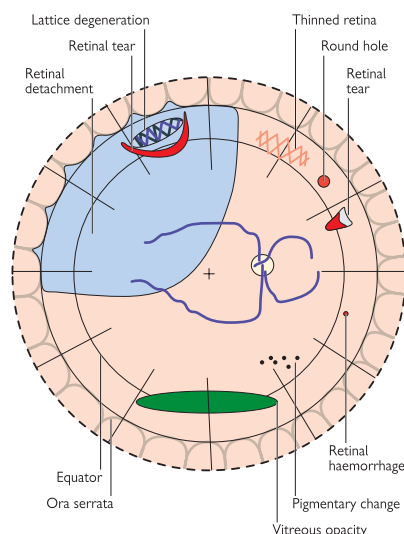
- Subretinal neovascularization may be detected as a greyish subretinal membrane. Associated features may include retinal thickening, subretinal fluid, retinal exudates, or haemorrhage. Note the number, size, and location of any associated drusen, and the presence or absence of RPE changes.
- Other macular signs include non-specific RPE pigment hyperplasia, pigment epithelial detachments, RPE rip, geographic atrophy, Bull's eye maculopathy, vitelliform lesions, pattern dystrophy, telangiectasia, and serous detachment.
- Location and stability of fixation may also be determined.

### Peripheral retina

- The peripheral retina may be visualized using slit lamp non-contact biomicroscopy (e.g. 90D lens), contact biomicroscopy (e.g. Goldmann 3 mirror contact lens), or binocular indirect ophthalmoscopy with scleral indentation (e.g. 20 or 28D lens).
- Detailed assessment of the peripheral retina is important to detect peripheral retinal lesions such as a retinal break (horseshoe tear, atrophic hole, retinal dialysis), retinal detachment, peripheral retina degeneration (e.g. lattice degeneration), tumour (e.g. choroidal melanoma), or inflammation (e.g. snow banking associated with pars planitis).

### Choroid and sclera

- Choroidal lesions include tumours (e.g. choroidal melanoma, choroidal haemangioma) and inflammatory lesions (choroiditis, granulomas). In addition to the size, shape, and location of choroidal lesions, the presence or absence of associated overlying RPE and retinal changes should be documented.
- Posterior scleritis may be associated with an exudative retinal detachment or choroidal folds.
- B-scan ultrasound may be useful in assessment of choroidal and scleral lesions.



**Fig. 3.3** An example of medical notes documenting vitreous and retinal findings.



## 3.3 Diagnostic lenses

Diagnostic lenses enable visualization of the fundus by neutralizing the optical power of the eye (direct lenses) or increasing the refractive power of the eye to create an inverted real image of the fundus anterior to the eye (indirect lenses).

### Direct lenses

These are plano-concave lenses with a negative power. The image produced is upright and not inverted.

#### Non-contact lens

The non-contact Hruby lens enables examination of the posterior pole. The concave surface faces the patient. The  $-55\text{D}$  power of the lens neutralizes the optical power of the eye. The lens is mounted on a slit lamp and aligned with the patient's visual axis in the primary position. The slit lamp illumination is aligned with slit lamp microscope. Through the lens and a dilated pupil, an upright fundus image ( $5-8^\circ$  field) is produced as the distance between the lens and the eye is adjusted. The small limited field of view and reflections within the lens are its main disadvantages and have been overcome by a range of indirect lenses (see below).

#### Contact lens

The Goldmann 3 mirror lens is a contact lens commonly used during slit lamp examination and laser treatment of the posterior pole, peripheral retina, and the anterior chamber angle. It consists of a central  $-64\text{D}$  plano-concave lens which neutralizes the optical power of the eye at the cornea. Three internal mirrors tilted at  $59^\circ$  (thumbnail shape),  $67^\circ$  (barrel shape), and  $73^\circ$  (trapezoid) are used to visualize the angle/far-peripheral retina, mid-peripheral retina/equator, and posterior pole to equator respectively.

After instillation of topical anaesthetic and filling of the lens concavity with a coupling agent (e.g. methyl-cellulose), it is placed on the cornea. A  $30^\circ$  field of the posterior pole is visible through the central lens.

### Indirect lenses

These are double aspheric convex lenses with a positive power. The images produced are vertically and horizontally inverted.

#### Non-contact lenses

These lenses range in power from  $+10\text{D}$  to greater than  $+100\text{D}$ . Lenses of power greater than  $+40\text{D}$  are combined with slit lamp examination whereas lower-power lenses are used with binocular indirect ophthalmoscopy (BIO). The most commonly used lenses for slit lamp examination are the  $+78$  and  $+90\text{D}$  lenses whereas the  $+20$  and  $+28\text{D}$  lenses are used for BIO. Improvements in lens design, manufacturing, and lens coatings have enabled higher-resolution, wide field viewing of the retina with reduced glare and reflections.

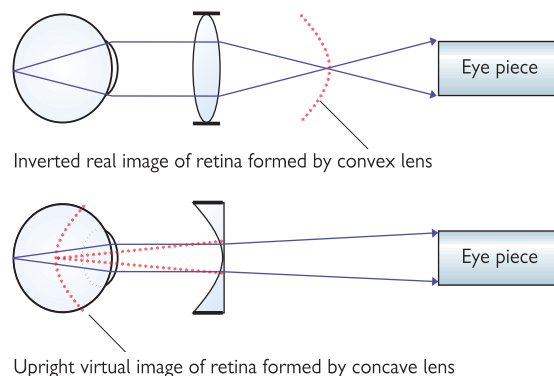
During slit lamp examination, the  $+78$  or  $+90\text{D}$  lens is held approximately 8 or 7 mm anterior to the cornea respectively. An inverted fundus image is brought into focus as the slit lamp is pulled away from the eye. To visualize the peripheral retina, the patient is directed to look in the direction of the area to be examined. The  $+78\text{D}$  lens is best suited for examination of the posterior pole and the  $+90\text{D}$  lens is better for peripheral retinal viewing. A wide variety of recently developed indirect viewing lenses provide superior depth perception, resolution, and fewer reflections.

During BIO, the  $+20$  or  $+28\text{D}$  lens is held approximately 5 or 3.3 cm anterior to the cornea respectively. An inverted fundus image is brought into focus as the BIO (attached to the examiner's head) moves away from the lens. As with slit lamp examination, the peripheral retina is visualized by asking the patient to look in the direction of the area to be examined. The examiner needs to maintain a position in which the centres of the lens, BIO, and pupil are in a straight line with the fundus area being examined. Scleral depression is required to examine the pre-equatorial retina. The  $+20\text{D}$  lens is adequate for visualizing the peripheral retina in adults whereas the  $28\text{D}$  lens is better suited for peripheral retinal examination in infants and patients with small pupils.

#### Contact lenses

Indirect contact lenses are commonly used during laser treatment of the fundus because they provide better image resolution and fewer troublesome reflections, and help to stabilize the eye by restricting ocular movements.

A variety of indirect contact lenses are available ranging from those with image magnification up to  $1.5\times$  and a narrow field of view ( $60^\circ$ ) for macular assessment and laser treatment, to those with image minification up to  $0.5\times$  and a wide field of view (up to  $160^\circ$ ) suited for peripheral laser treatment. These lenses may be coated to reduce reflections during laser treatment. Lenses with redesigned contact surfaces are available to avoid the need for a coupling agent.



**Fig. 3.4** Ray diagrams illustrating the optics of indirect (convex) and direct (concave) non-contact lenses.

Table 3.1 Summary of lens specifications.

Lens	FOV	Mag	WD	Uses
<b>Indirect BIO lenses</b>				
20D	40°	3.13×	5 cm	PP, PR
Pan Retinal® 2.2	56°	2.68×	4 cm	PP, PR
28D	53°	2.27×	33 mm	PR, SP
30D	58°	2.10×	3 cm	PR, SP
Digital ClearField™	55°	2.79×	37 mm	PR
Digital ClearMag™	38°	3.89×	6 cm	PP
<b>Indirect slit lamp examination lenses</b>				
78D	81°	0.93×	8 mm	PP
90D	74°	0.76×	7 mm	PR, SP
Super 66®	80°	1.0×	11 mm	PP
Super Field®	95°	0.76×	7 mm	PR, SP
Digital Wide Field™	103°	0.72×	4–5 mm	PR
Digital High Mag™	57°	1.30×	13 mm	PP
<b>Indirect contact lenses</b>				
Area Centralis®	70°	1.06×	0	PP
Trans Equator®	110°	0.70×	0	PP, SP
QuadrAspheric®	120°	0.51×	0	PR
Super Quad® 160	160°	0.50×	0	PR

FOV, field of view; Mag, magnification; PP, posterior pole; PR, peripheral retina; SP, small pupil; WD, working distance.

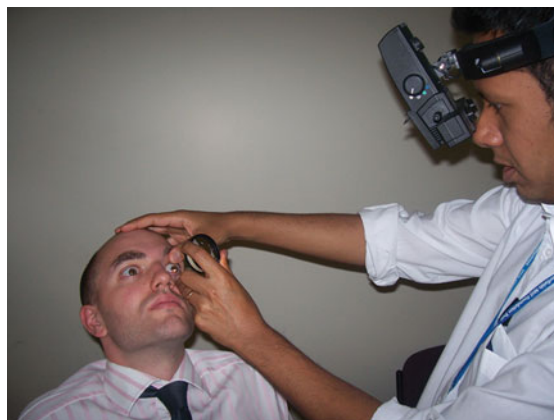

Fig. 3.6 Binocular indirect examination of the fundus.

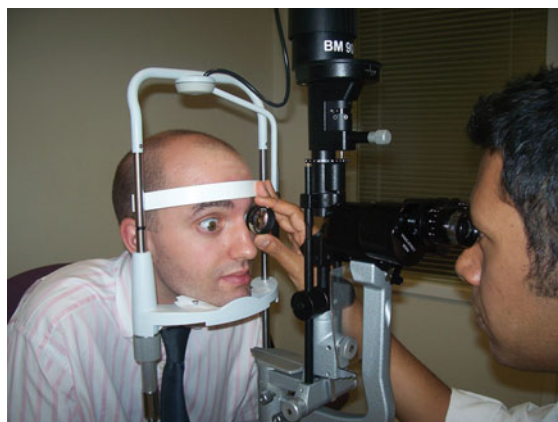

Fig. 3.5 Indirect fundus examination on a slit lamp.

## 3.4 Optical coherence tomography

Optical coherence tomography (OCT) is a non-contact imaging technique that produces micrometre-resolution, cross-sectional images of the retina and vitreoretinal interface. Macular OCT is commonly used for the evaluation of diseases of the vitreoretinal interface, diabetic macular oedema, and AMD.

### Principles and technology

- OCT is based on the principle of low-coherence optical interferometry.
- A light source emits low-coherence near-infrared light (800–850nm) with bandwidth of 20–150nm directed via a beam splitter into the eye and a reference mirror.
- The light reflected from different retinal layers contains signals of varying amplitudes and latencies. This light interacts with light reflected from the reference mirror to produce an interference pattern.
- The depth information is provided by the position of a movable reference mirror in time-domain OCT whereas in frequency or spectral-domain OCT interference formed by a diffraction grating is analysed by Fourier transform to give the depth information. The latter type of OCT can acquire over 20,000 A-scans per second whereas time-domain OCT can only obtain 400 A-scans per second, limited by the frequency of oscillation in the reference mirror.
- As the light source moves across the retina, a two-dimensional image (B-scan) is constructed and displayed in grey or colour scales. White represents areas of high reflectivity whereas black represents areas of low reflectivity.
- Axial resolution is 2–10  $\mu\text{m}$  depending on the bandwidth of the light source and horizontal resolution is 20  $\mu\text{m}$ , limited by the optics of the eye.

### Macular OCT images

- Reconstruction of serial A-scans produces tomographic (cross sectional i.e. B-scan) images of the macula.
- A three-dimensional image of the macula can be reconstructed by using closed-space B-scans obtained in a raster pattern.
- A normal time-domain OCT scan shows a highly reflective external band composed of an outer layer derived from the RPE–Bruch's–choriocapillaris complex and an inner layer representing the boundary between the inner and outer segments of the photoreceptors. The nerve fibre and plexiform layers are moderately backscattering whereas the outer/inner nuclear and ganglion cell layers are weakly backscattering. The vitreous has no reflectivity whereas the choroid reflectivity is masked by the RPE backscatter.
- A macular topography map demonstrates the foveal depression in blue (100–200  $\mu\text{m}$  thick) and perifoveal elevation in green (200–300  $\mu\text{m}$  thick). Computer software can automatically detect an inner boundary at the vitreoretinal interface and the inner and outer segments.  
The retinal thickness is calculated from the distance between the two boundary lines and plotted as a topographic map.

### Vitreoretinal interface pathology

- Epiretinal membrane may be seen as a highly reflective layer on the retinal surface, often associated with a loss of the normal foveal contour and intraretinal cystic spaces due to retinal oedema. Epiretinal membrane, which simulates a macular hole (macular pseudohole), is characterized by steepening of the slope surrounding the foveal depression on OCT.

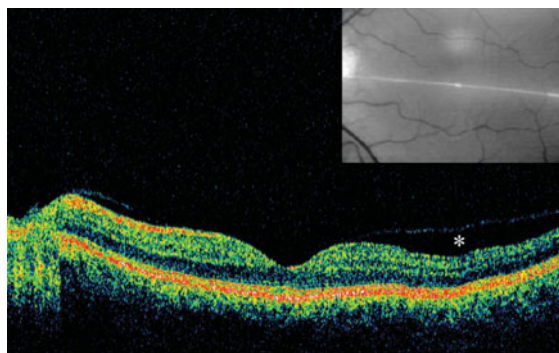
- Vitreomacular traction is usually visible as a reflective posterior vitreous face exerting focal vitreoretinal traction on the retina with associated distortion of the normal retinal contour.
- Macular holes are clearly seen as full-thickness defects in the NSR involving the fovea, often with the posterior vitreous face attached to the edge of the hole. The edges of a full-thickness macular hole are typically elevated from the RPE and demonstrate intraretinal cystic changes.
- Lamellar holes have defects in the inner retinal layers at the fovea with continuous outer retinal layers. There's usually an overhanging inner retinal tissue which may represent part of the roof of an intraretinal cyst.

### Intraretinal pathology

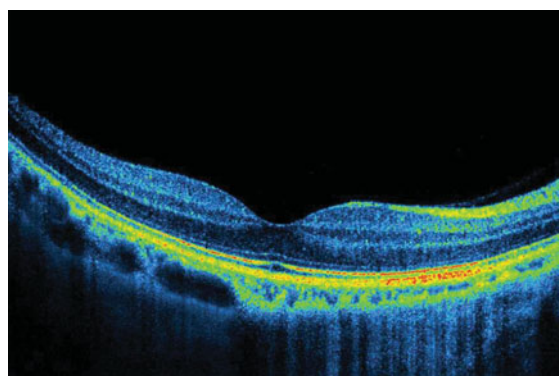
- In retinal oedema cystic spaces of varying sizes are seen in the outer nuclear and plexiform layers. Foveal involvement may be associated with a loss of the foveal contour and an increased foveal thickness.
- Intraretinal changes may be accompanied by hyporeflective spaces between the NSR and RPE, representing subretinal fluid.
- Retinal atrophy may manifest as a reduced retinal thickness. Loss of the outer retinal layers and RPE gives rise to increased backscattering of the choroid.
- Hard exudates are observed as spots of high reflectivity in the inner or outer retina casting shadows of low reflectivity posteriorly.
- In type II idiopathic juxtafoveal telangiectasia, characteristic localized inner or outer retinal cystic defects involving the foveal or juxtafoveal retina may be present with an absence of retinal thickening. Other features may include an extension of the highly reflective band into the retina (representing intraretinal pigment plaques) and a loss of the outer retinal band (due to focal loss of photoreceptors).

### Subretinal pathology


- Pigment epithelial detachments are seen as focal dome-shaped elevations of the highly reflective outer band. Intraretinal and subretinal fluid can often be seen extending beyond the boundaries of the pigment epithelial detachment.
- In RPE tears, the highly reflective band is broken. One edge of the RPE displays a steep ripple-like pattern. As the RPE folds upon itself, the thickened highly reflective band blocks light penetration into the choroid, creating a shadow defect.
- Occult CNV typically shows well-defined irregular elevation of the highly reflective RPE layer with mild choroidal backscattering. Classic CNV typically shows fusiform enlargement, irregularity, and duplication of the highly reflective external band. Actively leaking CNV can be detected by the presence of adjacent subretinal or intraretinal spaces and retinal thickening, representing subretinal fluid and intraretinal oedema.



**Fig. 3.7** Image of normal macular on time-domain OCT. \* Indicates perifoveal vitreous separation from retina.



**Fig. 3.8** Image of normal macular with spectral-domain OCT.



**Fig. 3.9** Three-dimensional reconstruction of raster scans acquired by spectral-domain OCT showing serous retinal detachment.

## 3.5 Ultrasonography

For posterior segment ultrasound imaging, sound frequencies in the range of 8–10 MHz are used. These high frequencies allow visualization of the vitreous, posterior hyaloid face, subhyaloid space, retina, choroid, and sclera with a resolution of approximately 150  $\mu\text{m}$ .

### Indications for posterior segment ultrasound

- Inability to visualize the posterior segment: small pupil, media opacities such as corneal lesions, hyphaema, cataract, vitreous haemorrhage, or inflammation.
- Measurement of intraocular lesions: for example, choroidal tumours.
- To provide diagnostic information: for example, detect scleral thickening in posterior scleritis, PVD, outline posterior staphylomas, identify choroidal effusions, evaluate optic disc drusen, and detect haemolysis of suprachoroidal haemorrhages.

### Principles and technology

- Based on the reflection of acoustic waves at the interface between tissues of different acoustic impedances.
- Ultrasound waves produced by a piezoelectric transducer.
- Echoes, reflected from each intraocular interface (e.g. aqueous–lens or vitreous–retina) return to the transducer. The strength of each echo is dependent on the magnitude of the impedance difference, the shape of the interface, and the extent of sound scattering, absorption, and refraction. The time delay of each echo depends upon the velocity of sound in the different ocular tissues.
- The piezoelectric transducer also detects the reflected sound waves and processes the information to produce a graph of intensity versus time (A-scan). The distance travelled by the sound waves is calculated from the time delay of the echoes.
- Two-dimensional images (B-scans) are reconstructed from multiple A-scans performed at different angles. The echo intensity at each time point is displayed as a dot in grey scale and the location, derived from the time delay and direction of echo, is displayed in two dimensions.
- Doppler technology may be incorporated into the two-dimensional scan (duplex scans) to determine lesion vascularity.

### ⊕ Technique of posterior segment ultrasound

- A- and B-scans should be used concurrently to provide maximal information.
- Screening: set the B-scan on high gain initially (to detect vitreous opacities or gross retinal lesions) then low gain (for flat retinal lesions). The fundus is imaged with the patient looking away from the probe, in the direction of the fundal area to be examined. The probe is orientated transversely (parallel to the limbus) at the limbus to examine the posterior pole. The probe is then shifted from the limbus towards the fornix to screen progressively more peripheral fundus. This process is repeated in all four quadrants before horizontal and vertical axial scans are performed with the patient gazing in the primary position and the probe held in line with the visual axis.
- Topography: the meridional extent (number of clock hours) of a lesion can be determined on transverse scanning. The anteroposterior extent of a lesion can be assessed with longitudinal scanning (probe held perpendicular to limbus).

Axial scans with the probe held over the cornea demonstrate the relationship of the lesion to macular or optic disc. Lesion size and thickness should be measured.

- Quantitative echography: internal reflectivity is best assessed with A-scans. Low internal reflectivity is typically seen in choroidal melanomas due to their regular homogenous cellular structure. High internal reflectivity occurs in choroidal haemangiomas associated with multiple intralésional vascular spaces. Ultrasound attenuation by intraocular calcium or foreign bodies casts an acoustic shadow on B-scan posteriorly.
- Kinetic echography: differences in the movement and attachment of the hyaloid face and detached retina may aid in the differential diagnosis. Internal vascularity can be assessed with Doppler ultrasound techniques.

### Vitreous haemorrhage

- In the presence of a vitreous haemorrhage, ultrasound is useful to detect the presence of large retinal tears or a retinal detachment.
- Detached vitreous gel can typically be seen to be separate from the optic disc whereas detached retina remains attached to the optic disc.

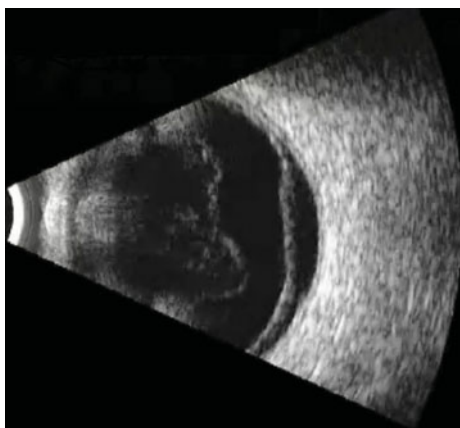
### Intraocular mass lesions

- Typical features of choroidal melanomas include: thickness greater than 3 mm, homogenous appearance with low to medium internal reflectivity and internal vascularity, and choroidal excavation and associated serous retinal detachment. A bumpy irregular surface is more typical of metastatic tumours. A high internal reflectivity is found in choroidal haemangiomas. Subretinal disciform lesions associated with AMD typically have two or more spikes and may reduce in height with time. Posterior scleritis is characterized by thickened sclera, and fluid in the subtenons space (visible as a T-sign on B-scan).
- In children with media opacity, ultrasound is often performed to evaluate the possible presence of a retinoblastoma. Typical features of this tumour include: a solid mass lesion arising from retina with highly reflective internal lesions due to calcification. Stage 5 retinopathy of prematurity (ROP) is characterized by a dense retrolental vitreous opacity associated with a funnel-shaped retinal detachment. Persistent fetal vasculature is associated with a small globe and a band extended between the lens and the optic disc of varying severity. In Coat's disease, multifocal retinal detachment or a large bullous retinal detachment may be associated with subretinal cholesterol deposits.

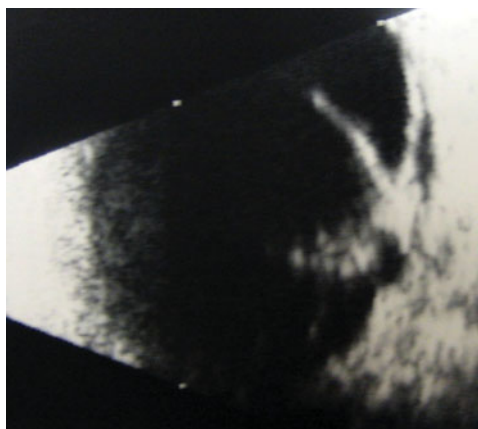### Ocular trauma and suprachoroidal haemorrhage

- Posterior scleral rupture should be suspected when the scleral contour is irregular, often with lower reflectivity detectable at the rupture site. Associated features that may be detected with ultrasound include PVD, vitreous or retinal incarceration, retinochoroid thickening, and intraocular haemorrhage. Intraocular foreign body can be precisely localized by ultrasound.
- A traumatic or iatrogenic suprachoroidal haemorrhage initially demonstrates a dome-shaped choroidal lesion with irregular internal reflectivity. As the clot liquefies, the height of the lesion reduces and the internal reflectivity becomes more regular. This is useful to guide the timing of potential surgical drainage of the suprachoroidal haemorrhage if indicated.

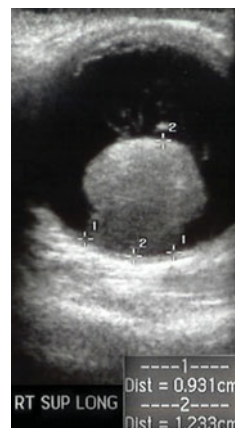



**Fig. 3.10** B-scan of a patient with vitreous haemorrhage and RRD due to PVD.



**Fig. 3.11** B-scan of a patient with vitreous haemorrhage and tractional retinal detachment due to proliferative diabetic retinopathy.



**Fig. 3.12** Typical features of choroidal melanoma are shown: mushroom shape, low internal reflectivity, and measuring 9 mm at base and 12 mm in height.

## 3.6 Retinal photocoagulation

Light from a laser (which stands for light amplification by stimulated emission of radiation) is monochromatic, directional, parallel, and coherent. Argon and diode lasers are the most commonly used types for retinal treatment. Laser delivery is typically via a slit lamp or binocular indirect ophthalmoscope system. Other methods of laser delivery use transcleral or endoscopic laser probes, which are most frequently used during vitreoretinal surgery.

Thermally induced necrosis occurs with intraocular tissue temperatures above 65°C. The temperature correlates directly with the amount of light absorbed by tissues. The retina is vulnerable to light of wavelengths between 400 and 1400nm. The cornea and lens absorb the majority of ultraviolet light (<400nm). The high water content of the ocular media absorbs the majority of infrared light (>750nm). In the retina, three pigments are important in the absorption of light:

- melanin (present in the RPE and choroid) has a broad light-absorption range, spanning the visual spectrum;
- oxyhaemoglobin (present in retinal capillaries) absorbs light with wavelengths of less than 600nm;
- xanthophylls (present in the macular) have moderate absorption of light with wavelengths in the range of 400–500nm.

The extent of tissue injury is also dependent upon the burn duration, laser spot size, and power. Argon green laser (514.5nm) is absorbed by both melanin and oxyhaemoglobin but less so by xanthophylls. However, thermal damage may extend from the RPE into the retina and choroid as the power and duration of laser delivery is increased. Thus diode laser (810nm) may also cause thermal retinal and choroidal damage despite its poor absorption by haemoglobin and xanthophylls.

### ⊕ Panretinal photocoagulation

Panretinal photocoagulation involves laser ablation of the peripheral retina in patients with severe retinal ischaemia and retinal neovascularization. The resultant reduction in VEGF levels usually leads to regression of retinal and optic disc neovascularization.

#### Approach

- Anaesthesia: optional pre-treatment oral analgesia may be given. Topical anaesthetic is usually sufficient. Periocular or general anaesthesia may be necessary in selected patients. Larger burns of longer duration are associated with more discomfort.
- Laser settings vary depending upon the model of laser used and should be titrated to produce a light-grey-white burn.
- Typical settings for slit lamp delivery are:
  - spot size: 200–500 µm (need to take lens magnification into account),
  - duration: 0.05–0.20 seconds,
  - power (variable between lasers): 100–300 mW.
- Laser application:
  1. laser spots are placed one to three burn widths apart. The inferior retina should be treated first in case subsequent vitreous haemorrhage precludes treatment of the inferior retina. The nasal, temporal, and superior retina is then treated, leaving a clear margin of at least three disc diameters temporal to the fovea and one disc diameter nasal to the optic disc. Great care should constantly be taken to ensure awareness of the location of the macular in relation to the laser aiming beam in order to avoid inadvertent foveal burns. Depending upon the severity of the underlying retinal disease severity, two to four treatment sessions are typically required to complete a full

panretinal photocoagulation (400–800 visible burns per session). Fluorescein angiograms should be reviewed to guide the area and extent of treatment.

- Post-laser care: corneal exposure following peribulbar anaesthesia should be avoided by the use of an eye pad.
- Follow up: review in 2–3 weeks +/- further laser, depending on treatment response.

### ⊕ Macular focal and grid photocoagulation

Focal and grid macular laser treatments are most commonly performed for the treatment of macular oedema associated with diabetic maculopathy and branch retinal vein occlusions. Direct ablation of leaky microaneurysms (focal treatment) and mild thermal injury of the RPE to stimulate pumping of subretinal fluid (grid treatment) are thought to be the mechanism of macular photocoagulation in reducing intraretinal oedema.

#### Approach

- Anaesthesia: topical anaesthesia is usually sufficient. Periocular anaesthesia is rarely required for selected patients.
- Laser settings vary depending upon the model of laser used and should be titrated to produce a faint grey-white burn.
- Typical settings for slit lamp delivery are:
  - spot size: 50–200 µm (need to take lens magnification into account),
  - duration: 0.05–0.1 seconds,
  - power (variable between lasers): 50–150 mW.
- Laser application:
  1. review fluorescein angiograms to determine areas of leakage, and margins of the foveal avascular zone;
  2. identify patients fixation point to avoid foveal burn;
  3. focal treatment: directly treat all leaking microaneurysms in areas of retinal thickening 500–3000 µm from the centre of the macular; avoiding burns within 500 µm of the optic disc;
  4. grid treatment: treat all areas with oedema 500–3000 µm from the centre of the macular; avoiding treating within 500 µm of the optic disc. Apply burns two to three spots widths apart;
  5. modified grid treatment: directly treat all leaking microaneurysms and areas with oedema 500–3000 µm from the centre of the macular; avoiding burns within 500 µm of the optic disc. Apply burns two to three spot widths apart.
- Follow up: review within 3 months to assess regression of retinal thickening. Earlier review is required if concurrent retinal ischaemia or proliferative disease requiring panretinal photocoagulation is present.

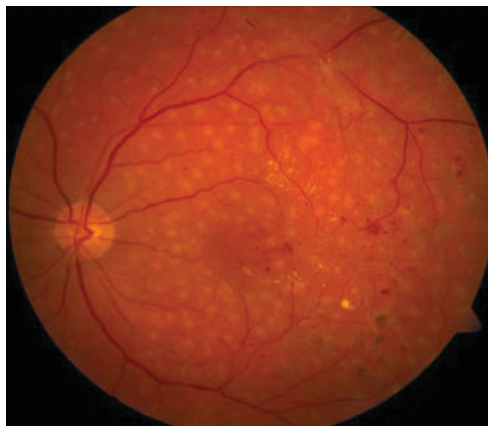### ⊕ Laser retinopexy

Laser retinopexy is performed for the treatment of retinal tears. Formation of a chorioretinal scar is induced with a consequent increased adhesion of the retina to the RPE, which prevents extension of subretinal fluid.

#### Approach

- Anaesthesia: topical anaesthesia is usually sufficient. Periocular or general anaesthesia may be necessary in selected patients, particularly when treatment of anterior retinal pathology involving scleral indentation is required.

- Laser settings vary depending upon the model of laser used and should be titrated to produce confluent white burns. Typical laser settings for slit lamp or binocular indirect ophthalmoscopic delivery are:
  - spot size: 200–1000  $\mu\text{m}$ ,
  - duration: 0.2–0.5 seconds,
  - power (variable between lasers): 100–300 mW,
- Laser application:
  - (i) retinal tears: two or three confluent rows of laser are placed around the retinal tear and any associated subretinal fluid;
  - (ii) retinal dialyses and selected retinal detachments: three confluent rows of laser are placed immediately posterior to the dialysis or detached retina, extending from the ora serrata from one border of the affected area to the other border in order to surround the area.
- Post-laser care: patients should be advised to seek urgent attention if new floaters or a visual-field defect develop.
- Follow up: review in 1 week to detect progression of subretinal fluid or development of new retinal tears and assess the adequacy of the chorioretinal adhesion.
- Exudative retinal or choroidal detachment may cause angle closure and raised IOP following panretinal photocoagulation.



**Fig. 3.13** Colour fundus photograph of posterior pole showing macular grid for treatment of diffuse macular oedema.

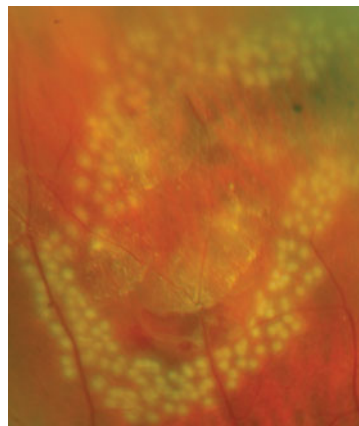
### Complications of laser treatment

#### Anterior segment

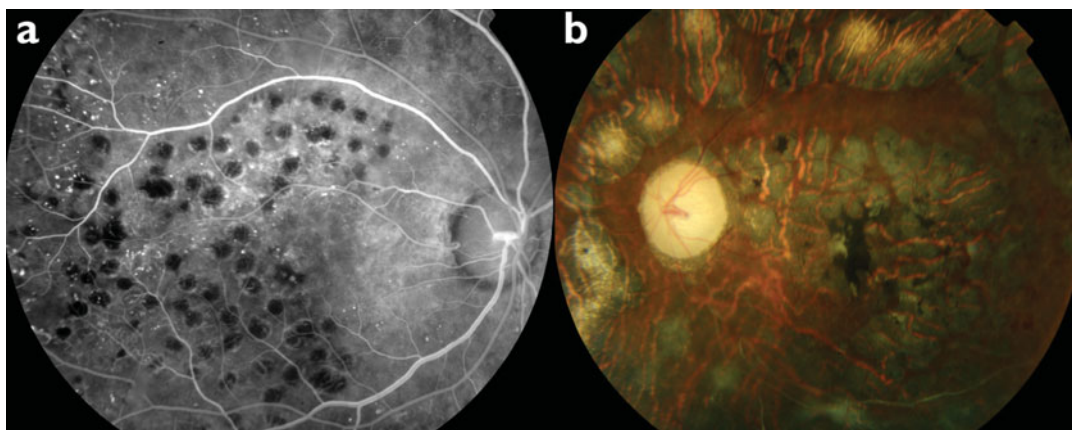
- Corneal: epithelial toxicity from anaesthetics, abrasion from contact lens, and oedema from scleral depression.
- Inadvertant corneal, iris, and lenticular laser burns. Poor pupillary dilatation and accommodation resulting from damage to the long ciliary nerves.

#### Posterior segment

- Foveal burn.
- Haemorrhage: subretinal, preretinal, or vitreous haemorrhage may result from laser-induced vessel-wall rupture.
- Epiretinal membrane.
- CNV: rupture of Bruch's membrane may lead to CNV.
- Extension of RPE atrophy: progressive RPE atrophy associated with juxtafoveal burns may lead to foveal involvement.
- RPE rip may occur following laser treatment over a pigment epithelial detachment.
- Macular oedema may progress following panretinal photocoagulation.



**Fig. 3.14** Confluent laser burns surrounding a retinal horseshoe tear.



**Fig. 3.15** Complications of laser photocoagulation include (a) accidental foveal burn during macular laser and (b) progressive enlargement of laser scars due to heavy laser burns.

## 3.7 Vitreous disorders

The vitreous is a transparent extracellular matrix made up of 99% water and 1% collagen and hyaluronic acid. Occupying 80% (4 ml) of the ocular volume, the vitreous plays important roles during ocular development and in the pathogenesis of many vitreoretinal disorders including retinal tears, retinal detachments, vitreomacular traction syndrome, idiopathic macular holes, epiretinal membranes, and fibrovascular proliferation associated with ischaemic retinopathies. Genetic and environmental factors which modify normal collagen formation and retinovascular development can affect the vitreous structure.

### Pathological processes

- Developmental: persistent hyperplastic primary vitreous, familial exudative vitreoretinopathy, ROP.
- Genetic: Stickler syndrome, Jansen and Wagner disease.
- Vascular: vitreous haemorrhage.
- Inflammatory: intermediate uveitis.
- Neoplastic: vitreous seeding from malignant tumours.
- Iatrogenic: complications of anterior segment surgery.
- Trauma: intraocular foreign body, vitreous prolapse.
- Metabolic: asteroid hyalosis, amyloidosis.
- Degenerative: PVD.

### Posterior vitreous detachment (PVD)

#### Pathophysiology

- During aging, photochemically generated free radicals lead to dissociation between hyaluronan and collagen, causing vitreous liquefaction (synchysis) and collapse (syneresis). This is accompanied by partial separation of the posterior vitreous cortex from the internal limiting membrane of the retina.
- Liquefied vitreous enters the retrohyaloid space through a prepapillary hole (Weiss ring) in the posterior vitreous cortex and saccadic eye movements facilitate further separation of the posterior hyaloid from the retina.
- PVD typically begins in the perifoveal retina, extending to the fovea, optic disc, and peripheral retina to the vitreous base.
- Conditions predisposing to early PVD include myopia, hereditary vitreoretinopathies, trauma, uveitis, vitreous haemorrhage, diabetes, aphakia, and pseudophakia.

#### Anomalous PVD: complications

- Horseshoe retinal tears and retinal detachment: associated with areas of strong vitreoretinal adhesion.
- Vitreous haemorrhage, due to avulsion of retinal vessels (10%).
- Incomplete PVD with persistent vitreous adhesion to the macular (vitreomacular traction syndrome, foveoschisis, macular hole) or optic disc (vitreopapillary traction syndrome).

#### Clinical evaluation

##### History and examination

- Often asymptomatic.
- Floaters and flashing lights (photopsia), located in the temporal visual field.
- Weiss ring, peripapillary glial tissue that remains attached to the posterior vitreous cortex following PVD.
- Posterior hyaloid membrane, visible as a crinkled membrane posterior to the lens on slit lamp examination or with a 90D lens more posteriorly in the vitreous cavity.
- Vitreous pigment deposits (Shafer's sign) indicate a high likelihood of a retinal tear being present.

- Peripheral retinal tears, best detected using BIO with scleral indentation.

#### Differential diagnosis

- Photopsia: migraine, dysphotopsia associated with IOL.
- Floaters: vitreous haemorrhage or vitritis.

#### Management

- No treatment is required for uncomplicated PVD.
- B-scan ultrasonography to exclude retinal detachment if the fundal view is limited by vitreous haemorrhage.
- Follow-up if vitreous haemorrhage or risk factors present for retinal tears (high myopia, family history, retinal detachment in fellow eye).
- Educate the patient regarding symptoms of retinal detachment.
- Laser retinopexy or cryotherapy if retinal tear is present.
- Retinal detachment surgery if retinal detachment is present.

#### Complications

- Retinal break in 10–15% of symptomatic PVDs and higher in those associated with vitreous haemorrhage or vitreous pigment. Secondary vitreous haemorrhage and retinal detachment.

#### Prognosis

- Up to 4% of eyes with initially uncomplicated PVD may develop subsequent retinal tears over 6 weeks' follow-up.
- If not already present, PVD commonly develops in the fellow eye within 3 years.

### Asteroid hyalosis

#### Pathophysiology

- A degenerative process resulting in deposition of calcium hydroxyapatite or calcium phosphate and phospholipid complexes in the vitreous gel.

#### Clinical evaluation

##### History

- Asymptomatic, incidental finding.
- Floater and reduced visual acuity are rare.

##### Examination

- Yellow–white spherical opacities in vitreous gel.
- Suspended opacities move with vitreous motion.
- Usually an attached posterior vitreous cortex.
- Obscured retinal view.

#### Differential diagnosis

- Synchysis scintillans (cholesterol crystal accumulation in vitreous).

#### Management

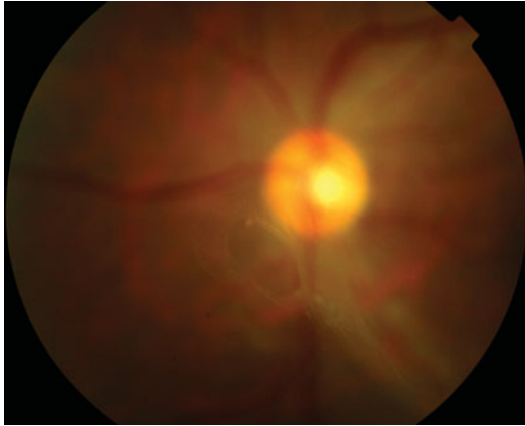
- No treatment is usually required.
- Retinal imaging with ultrasound, fundus fluorescein angiography (FFA), or OCT if fundal view is limited and retinal pathology is suspected.
- Vitrectomy is rarely indicated if there is reduced visual acuity.

#### Complications

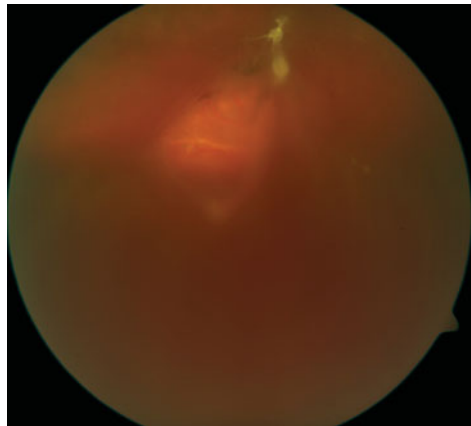
- Late dystrophic calcification of silicone plate IOLs.

#### Prognosis

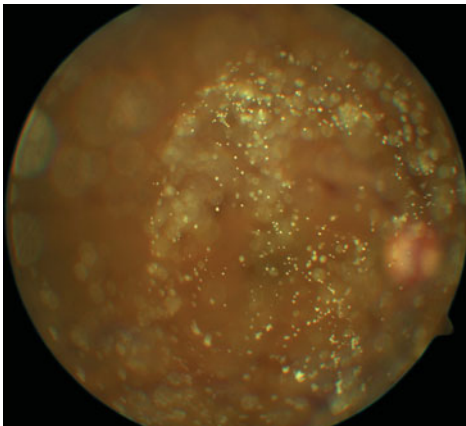
- No long-term sequelae.



**Fig. 3.16** Weiss ring as seen on slit lamp.



**Fig. 3.18** Vitreous haemorrhage due to proliferative diabetic retinopathy.



**Fig. 3.17** Asteroid hyalosis as seen on slit lamp.



## 3.8 Retinal detachment I

A retinal detachment is a separation of the NSR from the RPE. The disruption in the normal apposition of the NSR and the RPE impairs the survival and function of the retinal photoreceptors (see section 3.1).

### Pathogenesis

Retinal detachment occurs when the physiological forces (see section 3.1) maintaining normal apposition of the NSR to the RPE are overcome by one or more of the following processes: (1) fluid flow from the vitreous cavity into the subretinal space via a retinal break held open by vitreoretinal traction, (2) exudation or haemorrhage in the subretinal space due to a compromised blood–retinal barrier associated with inflammation, retinochoroidal vascular abnormalities, or fluid leakage from an optic disc pit, and (3) traction from proliferating membranes on the surface of the retina or associated with an anomalous PVD.

### Pathophysiology

Retinal detachment leads to proliferation and migration of the RPE, recruitment of macrophages into the subretinal space, degeneration of photoreceptors, and secondary inner retinal changes. The degree of visual loss depends upon the duration and the extent of separation of the NSR from the RPE (area and height). Significant visual recovery may occur if timely reattachment of the NSR to the RPE is achieved. In the presence of open retinal breaks, migration and proliferation of RPE, glial, inflammatory and fibroblastic cells with extracellular matrix deposition on the subretinal and epiretinal surfaces may occur leading to proliferative vitreoretinopathy (PVR).

## Rhegmatogenous retinal detachment (RRD)

The Greek word *rhegma* means 'break'. Approximately 6% of all eyes have a retinal break, but fewer than 0.1% of the population will develop a rhegmatogenous retinal detachment (RRD) during their lifetime. Factors important in the development of a RRD include:

- vitreous syneresis and synchysis (associated with aging, inflammation, intraocular surgery, myopia, hereditary vitreoretinopathies),
- full-thickness breaks in the NSR,
- vitreoretinal traction on retinal breaks,
- fluid flow from the vitreous cavity into the subretinal space stimulated by saccadic eye movements.

### Types of retinal break

- Horseshoe tears and operculated tears: induced by PVD and associated with areas of strong vitreoretinal adhesion.
- Giant retinal tears and retinal dialyses: breaks occurring within or at the border of the vitreous base.
- Round holes: breaks in atrophic retina unassociated with vitreoretinal traction.
- Macular holes: breaks in the central macular area associated with abnormal vitreomacular traction.

### Risk factors for RRD

- Ocular: myopia (40% of RRDs), cataract surgery (40% of RRDs), ocular trauma (10% of RRDs), herpetic necrotizing retinitis, miotic eye drops, senile retinoschisis, chorioretinal coloboma.
- Systemic: Stickler syndrome, Marfan syndrome, Goldmann–Favre syndrome, Ehlers–Danlos syndrome.

### Clinical evaluation

#### History

- Photopsia.
- Floaters.

- Visual-field defect.
- Ocular and systemic risk factors.
- Family history of RRD.

#### Examination

- Visual acuity, normal (if macular attached) or reduced (if macular detached).
- Peripheral visual-field defect.
- Relative afferent papillary defect if extensive retinal detachment.
- Reduced IOP.
- Anterior chamber or vitreous pigment deposits.
- Vitreous haemorrhage.
- PVD (usually absent with retinal detachment due to retinal dialysis or atrophic round holes).
- One or more retinal breaks.
- Detached retina: elevated, mobile and corrugated appearance.
- Retinal pigment demarcation line (tide mark).
- Retinal cysts (chronic retinal detachment).

#### Investigations

- B-scan ultrasound if dense vitreous haemorrhage.

#### Differential diagnosis

- PVD.
- Tractional retinal detachment.
- Exudative retinal detachment.
- Retinoschisis.
- Choroidal detachment.

### Management

Treatment varies depending upon the clinical features of the retinal detachment, medical facilities available, and surgeon experience. Surgical repair is recommended for the vast majority of RRDs and involves localization and closure of all retinal breaks by scleral indentation or intraocular tamponade. Permanent closure of the breaks is accomplished with cryotherapy or laser retinopexy.

#### Observation

- Appropriate for selected asymptomatic retinal detachments with signs of chronicity, for example tide marks.
- Most suitable for shallow, inferior, peripheral retinal detachments in patients with easy access to vitreoretinal services.

#### Laser demarcation

- Used in selected asymptomatic macular-sparing retinal detachments, usually associated with atrophic round holes, retinoschisis, or retinal dialysis.
- Two to three rows of confluent laser burns applied along the posterior border of the retinal detachment up to the ora serrata, using an indirect ophthalmoscopic delivery system.
- Maximum chorioretinal adhesion may take up to 2 weeks.

#### Pneumatic retinopexy

- Most often used for superior RRD associated with small breaks confined to one quadrant, located within the superior third of the retina, and without significant vitreoretinal traction or PVR in phakic eyes.
- Performed under local anaesthesia.
- Cryotherapy of the retinal breaks is followed by intravitreal injection of an expansile gas (100% SF<sub>6</sub> or C<sub>3</sub>F<sub>8</sub>). An alternative approach is to perform an initial intravitreal gas injection, followed by laser retinopexy of the retinal breaks the following day, after reattachment of the retina.
- Postoperative posturing is important to ensure adequate tamponade and closure of the retinal breaks.

**Scleral buckling**

- Suitable for most types of RRD without advanced PVR.
- Particularly indicated in young phakic patients with RRD and attached vitreous, for example RRD associated with atrophic round holes or retinal dialysis.
- General anaesthesia is usually used, although local anaesthesia is possible for selected patients.
- Involves conjunctival peritomy, muscle sling, search for scleral thinning, localization of all retinal breaks, cryotherapy, external drainage of subretinal fluid in selected cases, and application of a local or encircling scleral explant to indent the retinal breaks.

**Pars plana vitrectomy**

- Increasingly used for all varieties of retinal detachment associated with a PVD.
- Particularly indicated for pseudophakic RRDs and RRDs associated with PVR.
- Local or general anaesthesia used.
- 20, 23, and 25G vitrectomy systems are available.
- Vitrectomy to relieve vitreoretinal traction, fluid–air exchange with internal drainage of subretinal fluid via retinal breaks, or a retinotomy to reattach the retina, and laser retinopexy or cryotherapy of retinal breaks, followed by exchange of air with a non-expansile concentration of gas (14% C3F8 lasting 6 weeks or 18% SF6 lasting 2 weeks) for postoperative tamponade of retinal breaks.
- Postoperative posturing to facilitate gas tamponade of retinal breaks while retinopexy takes effect.

**Combined vitrectomy and scleral buckling**

- Frequently used to treat RRD associated with inferior retinal tears.
- Particularly indicated for complex RRD (e.g. advanced PVR).

**Adjunctive agents and procedures**

- Silicone oil intraocular tamponade, commonly used for complex RRD associated with PVR.
- Heavy liquids (e.g. perfluoro-*n*-octane and perfluoroperhydrophenanthrene) used to facilitate subretinal fluid drainage via peripheral retinal breaks and to unfold giant retinal tears.
- Epiretinal membrane peeling and retinectomy used for PVR cases.

**Complications**

- Failure of retina to reattach, PVR, and epiretinal membrane.

**Observation and laser demarcation**

- Progression of retinal detachment.

**Scleral buckling**

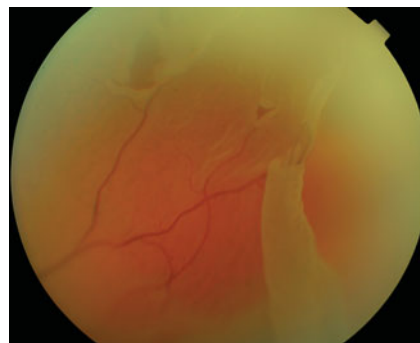
- Explant-related: infection, intrusion, or extrusion, strabismus, ptosis, induced refractive error.
- Subretinal fluid drainage-related: retinal incarceration, choroidal and subretinal haemorrhage, endophthalmitis.

**Vitrectomy**

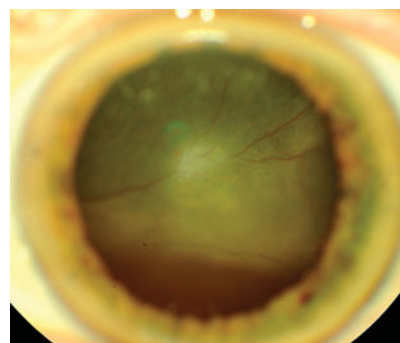
- Cataract.
- Endophthalmitis.
- Gas-related: increased IOP due to expansile gas concentrations, air travel, or nitrous oxide anaesthesia prior to absorption of gas, transient posterior subcapsular cataract, central retinal artery occlusion (CRAO), and angle closure.
- Silicone oil-related: glaucoma, cataract, band keratopathy, emulsification, unexplained visual loss.
- Sympathetic ophthalmia.

**Prognosis**

- The visual outcome after successful retinal reattachment depends whether the macula has been detached or not.
- Macular-on retinal detachment: 90% will retain pre-operative visual acuity, 10% may have suboptimal visual acuity due to macular oedema, persistent subretinal fluid, or epiretinal membrane formation.
- Macular-off retinal detachment: 50% achieve visual acuity of 6/12 or better. Reduced visual acuity is associated with a longer duration and greater height of macular detachment.
- The risk of retinal detachment in the fellow eye increases incrementally with a history of myopic retinal detachment, aphakic retinal detachment, or pseudophakic retinal detachment. The highest risk of fellow eye retinal detachment is associated with a giant retinal tear (up to 48%).



**Fig. 3.19** Giant retinal tear leading to retinal detachment.



**Fig. 3.20** Bullous superior retinal detachment seen behind the lens.

## 3.9 Retinal detachment II

### Exudative retinal detachment

#### Aetiology

- Ocular: primary retinal/choroidal tumours, CNV, central serous retinopathy, optic disc pit, Coats disease, sympathetic ophthalmia, posterior scleritis, cryotherapy, panretinal photocoagulation, scleral buckling, uveal effusion syndrome.
- Systemic: Vogt–Koyanagi–Harada syndrome, metastatic retinal/choroidal tumours, malignant hypertension, eclampsia, hypoproteinaemia.

#### Clinical evaluation

- Associated with underlying ocular or systemic disease.
- Vitreous usually clear except in uveitis.
- Retinal detachment: gravity-dependent, convex, elevated bullae, no break.
- Subretinal fluid: turbid, shifting.

#### Management

- Treat underlying systemic condition.
- Central serous retinopathy: laser to hot spot.
- Optic disc pit: barrier laser around disc and vitrectomy/gas.
- Coats disease: cryotherapy/laser.
- Uveal effusion syndrome: sclerectomy and drainage.

#### Prognosis

- Visual outcome determined by the effect of underlying condition on macular and optic nerve function.

Table 3.2 Grading of proliferative vitreoretinopathy.

Grade	Features
A	Vitreous haze, vitreous pigment clumps, pigment clusters on inferior retina
B	Wrinkling of inner retinal surface, retinal stiffness, vessel tortuosity, rolled and irregular edge of retinal break, decreased mobility of vitreous
C (A or P)	Focal, diffuse, or circumferential full-thickness folds*, subretinal strands*, anterior displacement*†, condensed vitreous with strands†
*Expressed in number of clock hours involved. †Applies only to anterior PVR. A, anterior; P, posterior.	

### Tractional retinal detachment

#### Aetiology

- Ocular: proliferative vitreoretinopathy, penetrating injury, vitreomacular traction syndrome, pars planitis, retinitis.
- Systemic: ischaemic retinopathies associated with retinal neovascularization, for example diabetic retinopathy, ROP, sickle cell retinopathy, radiation retinopathy.

#### Clinical evaluation

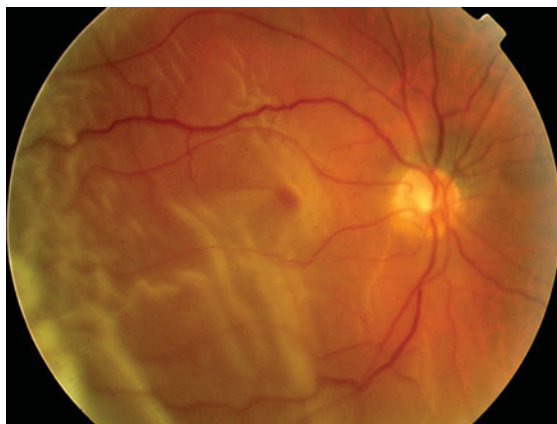- Those associated with underlying ocular or systemic disease.
- Epiretinal and fibrovascular membranes.
- Retinal detachment: immobile retina, concave, areas of visible vitreoretinal traction, may be associated with tractional retinal breaks.

#### Management

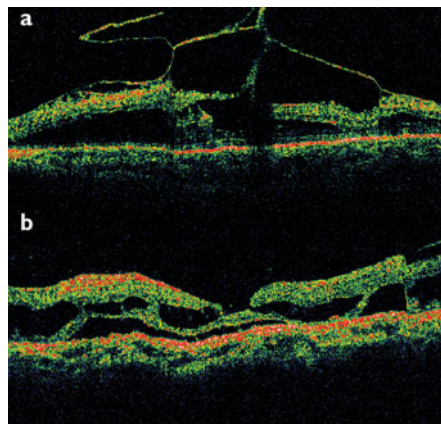
- Treat underlying ocular or systemic condition, for example panretinal photocoagulation for ischaemic retinopathies.
- Observation for non-progressive, extra-macular retinal detachment.
- Vitrectomy with or without scleral buckling if progressive retinal detachment, or if macular is threatened.

#### Complication and prognosis

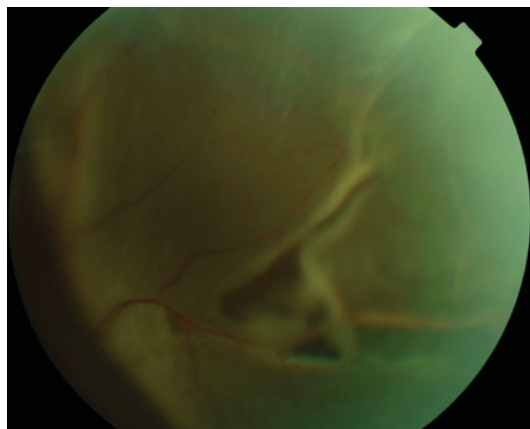
- Progressive retinal traction may cause tractional retinal breaks leading to combined tractional and rhegmatogenous retinal detachments.
- Visual outcome determined by the effect of underlying condition on macular and optic nerve function.



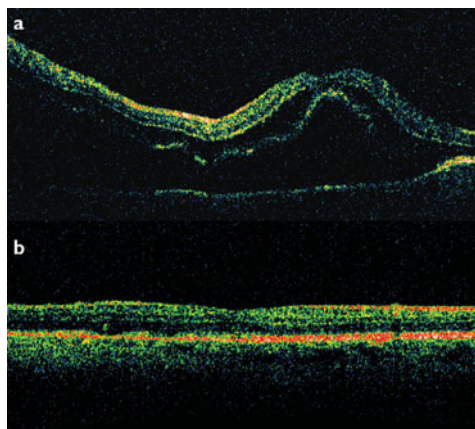
**Fig. 3.21** Temporal retinal detachment extending under the fovea; macular-off retinal detachment.



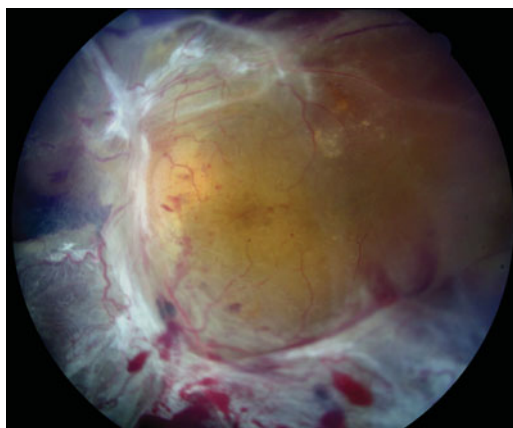
**Fig. 3.24** OCT showing (a) dense preretinal fibrous membrane and (b) tractional schisis.



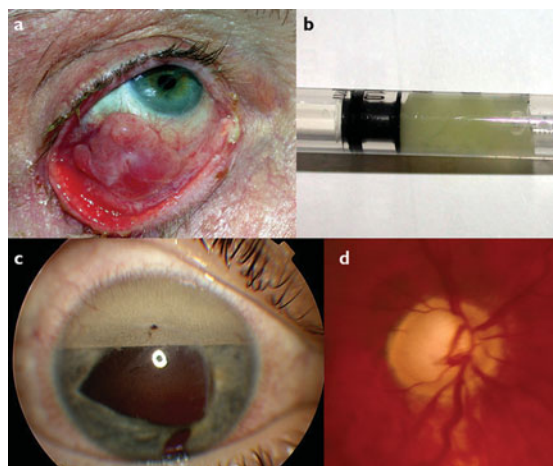
**Fig. 3.22** Tractional retinal tear leading to retinal detachment.



**Fig. 3.25** OCT (a) before and (b) after macular-off retinal detachment repair.



**Fig. 3.23** Colour fundus photograph of tractional retinal detachment in proliferative diabetic retinopathy.



**Fig. 3.26** Complications of vitreoretinal surgery: (a) suture granuloma after scleral buckling, (b) endophthalmitis (vitreous biopsy sample of *Haemophilus* endophthalmitis), (c) silicone oil emulsification (inverse hypopyon), and (d) raised IOP (glaucomatous cupping of disc).



## 3.10 Peripheral retinal abnormalities

Peripheral retinal abnormalities are commonly detected during peripheral retina examination with scleral indentation. The majority of peripheral retinal abnormalities are clinically insignificant but lattice degeneration, degenerative retinoschisis, and peripheral retinal tufts are associated with an increased risk of RRD. However, prophylactic treatment of these changes is generally not indicated except in rare, high-risk cases.

### Developmental changes

During embryonic development, the NSR terminates at the ciliary processes. As the eye enlarges, the sensory retina recedes posteriorly from the pars plicata, forming a boundary with multiple tooth-like (dentate) indentations called the ora serrata. Abnormal recession of the ora serrata leads to formation of meridional folds, meridional complexes, enclosed oral bays, and peripheral retinal tufts.

#### Meridional complexes

These are seen in 16% of autopsy eyes and are formed by elongated dentate process with ciliary process in the same meridian. Over half are bilateral and usually at the nasal ora. They are not associated with retinal breaks.

#### Enclosed oral bays

These are oval islands of pars plana epithelium located posterior to the ora serrata and separated from the pars plana by sensory retina. If incompletely separated, they are called partially enclosed oral bays. They are found in 4% of the general population and occur in 17% of meridionally aligned retinal tears at the posterior border of the vitreous base following PVD.

#### Meridional folds

These are radial folds of retina, usually found in the superonasal retina aligned with dentate processes, meridional complexes, or oral bays. They are found in 26% of autopsy eyes and over half are bilateral. PVD can induce a tear at the posterior border of the fold.

#### Peripheral retinal tufts

These small peripheral retinal elevations are formed by focal vitreous or zonular traction. When the tuft is associated with cystic retinal changes or is contiguous with a thickened zonule at its apex, it may predispose to a retinal break secondary to PVD or cataract surgery.

### Degenerative changes

#### Cobblestone or pavingstone degeneration

This appears as well-defined areas of chorioretinal atrophy located between the equator and the ora serrata. It is found in 22% of adults and has no predisposition to retinal break formation.

#### Ora serrata pearls

These opalescent spheres are located at dentate process and are thought to be analogous to giant drusen. They are found in 20% of autopsy eyes and do not predispose to retinal breaks.

#### Pars plana cysts

These are cystic lesions located anterior to the ora serrata. They may arise from vitreous base or zonular traction but are not associated with retinal breaks. They occur in 18% of autopsy eyes.

#### Peripheral cystoid degeneration

This is characterized by areas of microscopic intraretinal spaces located immediately posterior to the ora serrata. Histologically, the anterior zone has spaces in the mid-retinal layers (typical) whereas the posterior zone, if present, has spaces in the nerve fibre layer

(reticular). These changes are found in all eyes by 8 years of age, progressing posteriorly and circumferentially with time. Both typical and reticular microcystic spaces may coalesce to form a schisis cavity.

#### Degenerative retinoschisis

This is a splitting of the NSR found in 7% of people over 40 years of age. It most frequently involves the inferotemporal retina and is often bilateral. Histologically, acid mucopolysaccharide-filled cavities split the peripheral retina at the outer plexiform layer (typical retinoschisis) or the nerve fibre layer (reticular retinoschisis). A loss of retinal function and associated absolute visual-field defect occurs if the retinoschisis extends posterior to the equator. Potential complications include posterior extension of the retinoschisis cavity and retinal detachment. Treatment for retinoschisis should be limited to patients who develop symptomatic, progressive retinal detachments. Prophylactic treatment is not recommended for asymptomatic patients with retinoschisis with or without outer retinal holes.

#### Posterior extension

Despite producing an absolute visual-field defect, posterior extension of a retinoschisis is usually asymptomatic. Routine treatment of asymptomatic patients with posterior progression is not recommended because this posterior extension frequently stops spontaneously, macular involvement is extremely rare, and demarcation laser treatment may be associated with severe complications.

#### Retinal detachment

Retinal detachment occurs in 0.05% of eyes with retinoschisis and occurs in two forms: a more common localized, relatively stable form with outer leaf breaks only and a rarer symptomatic, rapidly progressive form with retinal breaks in both inner and outer leaves. Treatment is usually required only for the rapidly progressive form of retinal detachment.

#### Lattice degeneration

This is found in 6–10% of autopsy eyes and is characterized by well-demarcated, circumferentially orientated, oval areas of retinal thinning with overlying vitreous liquefaction and exaggerated vitreoretinal attachments along its margin. Other variably present features include lattice-like fine white lines in the crossing retinal vessels, alterations of retinal pigment, small white particles at the margin or surface of the lesion, punched-out areas of retinal thinning, or excavations and atrophic retinal holes. Lattice lesions are commonly located near the vertical meridia between 11 and 1 o'clock and between 5 and 7 o'clock. The lesions are usually anterior to the equator, but can be present posterior to the equator where they are frequently radially orientated. They are bilateral in up to 50% and are more common in myopic patients. Two complications are retinal break and retinal detachment.

#### Atrophic holes and tractional tears

Atrophic retinal holes occur in 20% of eyes with lattice degeneration and are typically small and round. They may cause an asymptomatic localized retinal detachment and rarely, a progressive retinal detachment. Tractional horseshoe-shaped retinal tears develop at the posterior or lateral margins of lattice lesions from vitreous traction following PVD.

#### Retinal detachment

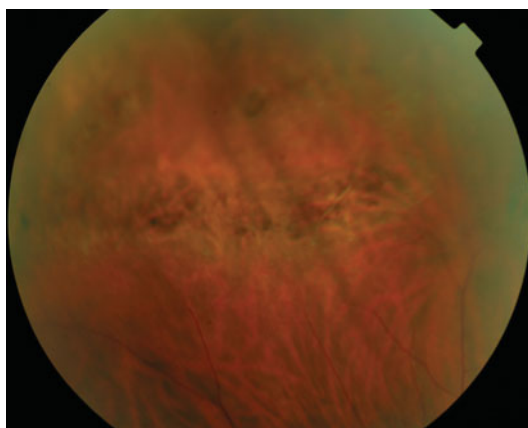
Lattice degeneration is the most important peripheral retinal degeneration that predisposes to RRD, which occurs in 1% of eyes with lattice changes followed for 10 years. Most RRDs associated with lattice degeneration are due to tractional retinal tears following PVD. Prophylactic laser treatment may be considered in fellow eyes with lattice degeneration in patients with a history of RRD in the first eye. However, treatment may not always prevent RRD because



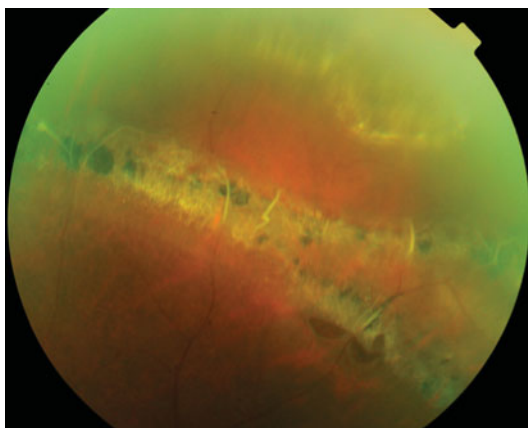
new breaks can occur in areas unaffected by lattice. Although lattice degeneration is a risk factor for development of a RRD, the majority of patients with lattice degeneration do not develop a RRD, and 80% of RRDs are not associated with lattice.

**Table 3.3 Differential features of retinal detachment and retinoschisis.**

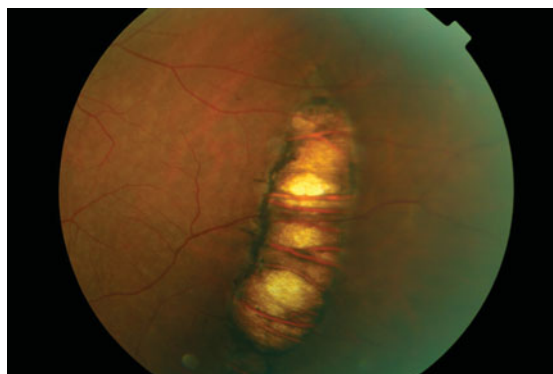
Clinical feature	Retinal detachment	Schisis
Surface	Corrugated	Smooth
Blood or pigment	Present	Absent
Subretinal fluid	Variable shifting	Not shifting
Fields defect	Relative	Absolute
Reaction to laser	Absent	Present if no sub-retinal fluid



**Fig. 3.27** Colour fundus photograph of lattice degeneration.



**Fig. 3.28** Colour fundus photograph of lattice degeneration with retinal breaks.



**Fig. 3.29** Pavingstone degeneration.

### Further reading

Byer NE. 1989. Long-term natural history of lattice degeneration of the retina. *Ophthalmology* **96**: 1396–1402.

## 3.11 Macular surgery

Macular surgery is often performed to relieve traction from the macular surface in conditions such as epiretinal membrane, macular hole, tractional macular detachment, and vitreomacular traction syndrome. Less frequently, macular surgery is performed to remove submacular haemorrhage, CNV, or scar tissue associated with a variety of aetiologies.

### Epiretinal membrane

Epiretinal membrane (also called macular pucker; epimacular proliferation, preretinal macular fibrosis, and cellophane maculopathy) is an avascular, fibrocellular membrane that proliferates on the inner surface of the retina and produces varying degrees of visual impairment. The prevalence of macular epiretinal membrane is 2% in individuals under the age of 60 years and 12% in those over 70 years. Bilateral involvement occurs in 31% of cases.

#### Aetiology

The majority of epiretinal membranes are idiopathic and occur in otherwise normal eyes. Defects in the inner limiting membrane are thought to allow migration of glial cells to the retinal surface. Secondary causes include trauma, retinal breaks, retinal venous occlusions, diabetic retinopathy, uveitis, some congenital conditions, retinal laser treatment, cryotherapy, and intraocular surgery. Epiretinal membranes variably comprise glial cells, RPE cells, macrophages, fibrocytes, and collagen fibres. Different proportions of these components are associated with different aetiologies.

#### Clinical evaluation

Most patients are asymptomatic. The commonest symptoms are decreased visual acuity and metamorphopsia. Less common symptoms include micropsia, macropsia, and monocular diplopia. The severity of symptoms is related to the area of involvement and the thickness of epiretinal membrane. Contracture of the epiretinal membrane causes retinal distortion and may induce macular oedema and a tractional retinal detachment in advanced cases. The peripheral retina should be examined to exclude the presence of retinal breaks. Amsler grid testing can document the degree of metamorphopsia present. FFA may show distortion of retinal vessels and fluorescein leakage. It may help to exclude an underlying retinal vein occlusion. OCT demonstrates a hyper-reflective membrane on the inner retinal surface often associated with retinal thickening, intraretinal oedema, and tractional elevation of the retina.

#### Management

Asymptomatic epiretinal membranes do not require treatment. Patients with severe metamorphopsia due to epiretinal membrane benefit most from vitrectomy and surgical peeling of the epiretinal membrane. In many cases improvement in metamorphopsia is more marked than visual acuity.

#### Prognosis

Epiretinal membranes follow a variable course: most will have static or slow progression. Occasionally, the epiretinal membrane may spontaneously detach from the retina with symptomatic improvement. Without surgery, a quarter will experience loss of two lines of visual acuity. After vitrectomy and epiretinal membrane peeling, patients may have significant improvement in metamorphopsia and acuity.

### Vitreomacular traction syndrome

Vitreomacular traction syndrome is characterized by persistent vitreous attachment and anteroposterior traction in the macula. Associated findings may include epiretinal membrane and varying degrees of macular oedema and tractional macular detachment. The symptoms of metamorphopsia and central scotoma may be progressive but they usually stabilise after 1–2 years.

#### Aetiology

Vitreomacular traction syndrome arises from an incomplete and anomalous PVD which leads to persistent vitreoretinal adhesion in the peripapillary and macular regions.

#### Clinical evaluation

Vitreomacular traction syndrome may cause reduced visual acuity due to retinal distortion, tractional retinal detachment and macular oedema or macular schisis. FFA may demonstrate leakage from the optic disc and macular region. OCT typically shows adhesion of the posterior hyaloid in the macular region, often associated with focal elevation of the retina at points of vitreoretinal attachment. Associated epiretinal membrane and intraretinal cystic spaces may also be visible.

#### Management

If symptomatic, vitrectomy may restore normal foveal anatomy with visual acuity improvement in 70%.

#### Prognosis

Spontaneous separation of the posterior hyaloid can occur with resolution of macular oedema and improvement in visual acuity in 11%. Without complete PVD, acuity may deteriorate in 70%.

### Full-thickness macular hole

The majority of full-thickness macular holes are classified as idiopathic, typically occurring in the sixth to eighth decades. Females are affected more frequently than males, and bilateral involvement eventually occurs in up to 13%. Full-thickness macular holes associated with high myopia tend to occur in patients 10–20 years younger than those with idiopathic macular holes and may be associated with retinal detachment.

#### Aetiology

Idiopathic and myopic full-thickness macular holes are caused by a combination of anteroposterior, oblique, and tangential traction associated with an anomalous perifoveal PVD. Full-thickness macular holes due to ocular trauma may be due to contusion necrosis or vitreoretinal traction. Full-thickness macular holes associated with certain types of laser injury may be caused by vapourization of retinal tissue.

#### Clinical evaluation

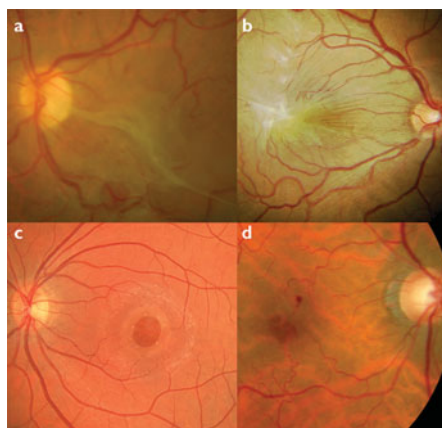
Stage 1 impending macular holes are characterized by foveal detachment and a visible yellow spot (stage 1A) or ring at the fovea (stage 1B). These may progress to a stage 2 full-thickness macular hole with a central round or crescent-shaped full-thickness foveal defect (<400 µm) associated with persistent vitreofoveal traction. Further enlargement of the defect to >400 µm leads to a stage 3 full-thickness macular hole, usually associated with further visual loss. A pre-foveal opacity formed by vitreous condensation with variable amounts of retinal tissue may be visible as the hyaloid separates from the edge of the hole. A stage 4 full-thickness macular hole occurs when a complete PVD is present. The Watzke–Allen test may be useful in confirming the presence of a full-thickness macular hole. It is performed by placing a thin slit beam of light on the macular hole. A positive Watzke–Allen sign occurs when the patients perceives a break in the light beam. An uninterrupted or narrowed beam is negative. FFA demonstrates localized hyperfluorescence at the fovea due to a window defect caused by the macular hole. OCT demonstrates a full-thickness central retinal defect with a surrounding cuff of subretinal fluid and intraretinal cystic spaces at the margins of the hole. The differential diagnosis includes a lamellar macular hole and a pseudohole (due to a focal defect in an epiretinal membrane).

## Management

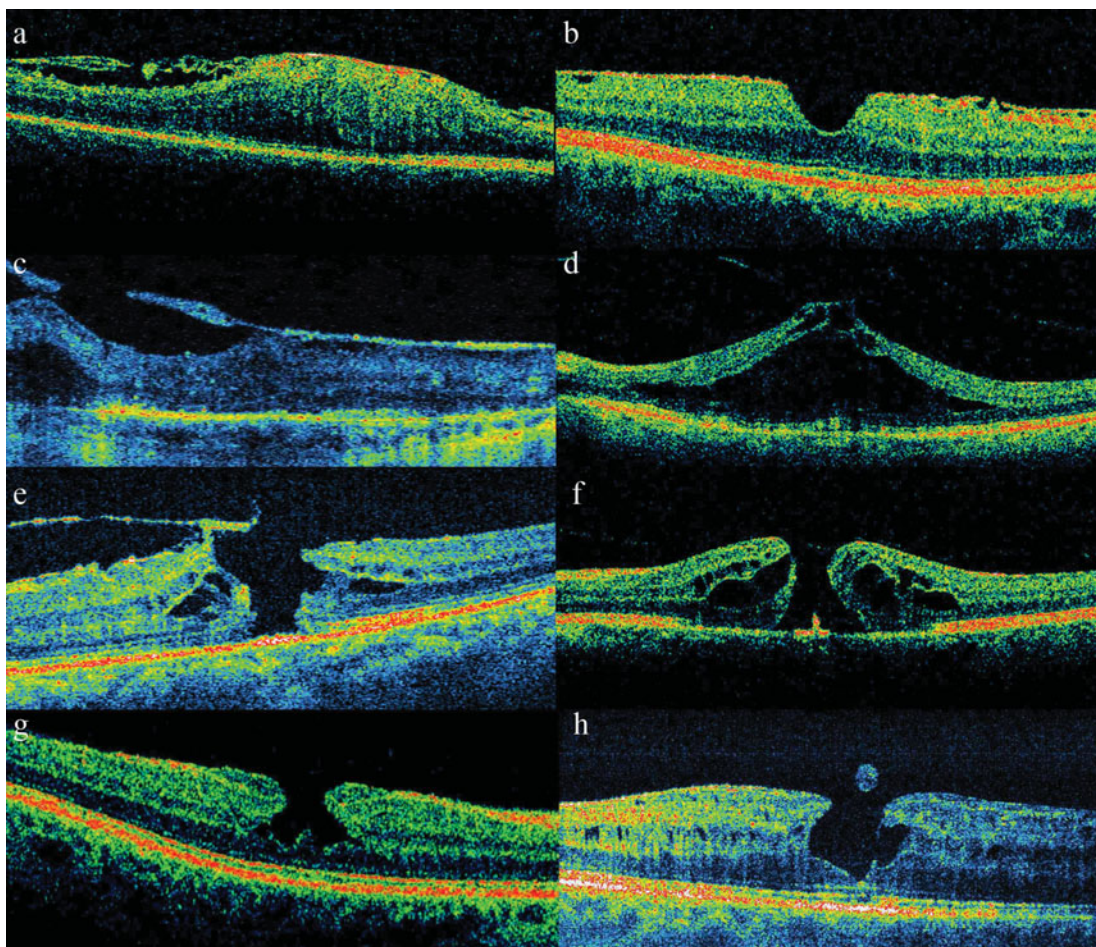
No treatment is indicated for stage 1 'holes' due to the high rate of spontaneous resolution. Stage 2–4 full-thickness macular holes can usually be closed using vitrectomy and gas tamponade followed by a variable period of postoperative prone positioning. Internal limiting membrane peeling with or without indocyanine green (ICG) or trypan blue-assisted staining is a commonly performed adjuvant technique and may increase hole closure rates, particularly in large and chronic holes. There is a general shift away from using ICG due to reported retinal toxicity.

## Prognosis

Spontaneous resolution occurs in up to 50% of stage 1 'holes' due to vitreous separation from the macular. Spontaneous closure of stage 2–4 holes is rare. Unoperated full-thickness macular hole typically have a stable visual acuity of approximately 6/60. Surgical treatment results in anatomical closure in over 80% and an improvement in visual acuity in over 60%. Factors associated with less favourable anatomic and visual results include macular holes of long duration, absent subretinal fluid or intraretinal oedema at the edge of the hole and large hole diameter. Fellow eyes of patients with a full-thickness macular hole in the first eye should undergo OCT imaging to detect the presence of a perifoveal PVD (stage 0 'hole'), which is associated with up to 54% risk of developing a macular hole compared to 4% without a perifoveal PVD. Full-thickness macular holes associated with high myopia can be complicated by retinal detachment.



**Fig. 3.30** Colour fundus photographs of (a) epiretinal membrane, (b) vitreomacular traction syndrome, (c) full-thickness macular hole, and (d) lamellar macular hole.



**Fig. 3.31** OCT images of (a) epiretinal membrane causing diffuse retinal thickening, (b) mild epiretinal membrane causing steepened foveal depression, (c) broad macular; (d) focal foveal attachment of posterior hyaloid in vitreomacular traction syndrome, (e) full-thickness macular hole with and (f) without hyaloid attachment to the hole, and (g and h) lamellar macular holes.



## 3.12 Submacular surgery

Surgical removal of submacular haemorrhage or CNV with associated blood and scar tissue may stabilize or improve visual acuity in selected cases.

### Submacular CNV removal

The visual outcome following submacular surgery depends upon the viability of photoreceptors and the integrity of the underlying RPE. Surgical removal is best suited for type II CNV (located in the subretinal space, above the RPE) because CNV removal may be associated with preservation of the underlying RPE. Type II CNV occurs in localized disease with focal RPE and Bruch's membrane involvement such as in ocular histoplasmosis syndrome, punctate inner choroidopathy, and idiopathic or iatrogenic causes. CNV with extrafoveal ingrowth sites are associated with better visual results. Surgical removal of type I CNV (which are located beneath the RPE) is not recommended due to the risks of removing the overlying RPE. Type I CNV occur in the presence of diffuse RPE and Bruch's membrane pathology and are commonly associated with AMD. The visual results of submacular surgery are often poor, even after successful CNV removal.

The technique of CNV removal involves a pars plana vitrectomy with separation of the posterior hyaloid, followed by a retinotomy to access the subretinal space and allow removal of the CNV using subretinal forceps. A partial fluid–air exchange is performed and the patient postured postoperatively to close the retinotomy. In addition to the usual complications of vitrectomy surgery, submacular surgery carries the risk of perioperative submacular haemorrhage and postoperative recurrence of the CNV. Careful postoperative follow-up is required to detect CNV recurrence.

### Submacular haemorrhage

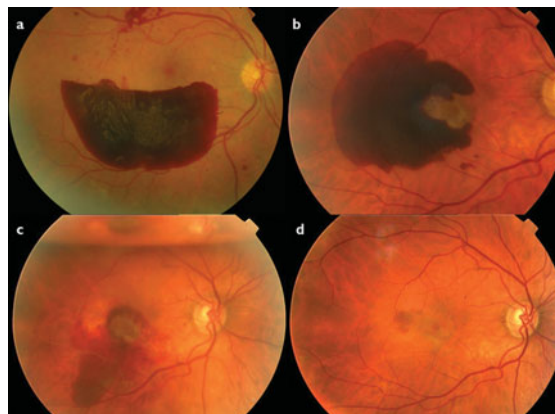
Submacular haemorrhage is toxic to the outer retinal layers and the visual prognosis is worse when the haemorrhage is extensive and thick. Submacular haemorrhage with AMD, carries a poor prognosis, particularly if associated with CNV. Submacular haemorrhage associated with trauma and retinal arterial macroaneurysms carries a more favourable course with spontaneous improvement being common. The surgical technique of submacular haemorrhage removal is similar to that used for CNV removal. After vitrectomy and the creation of a PVD, an access retinotomy is made, followed by injection of tissue plasminogen activator (tPA) subretinally into the area of haemorrhage. After 20–45 minutes, the tPA and liquefied submacular haemorrhage are irrigated out of the subretinal space. A fluid–air exchange is performed and the patient postured postoperatively to close the retinotomy and displace any residual submacular haemorrhage. A less invasive surgical approach suitable for thin submacular haemorrhages is the use of an intravitreal injection of expansile gas often combined with intravitreal tPA and prone positioning to pneumatically displace the submacular haemorrhage.

The results of submacular haemorrhage removal are variable and the ultimate visual acuity is determined by the aetiology. Patients with good pre-haemorrhage visual acuity have a better prognosis. The timing of surgery is important as photoreceptor damage can occur within 1 hour after subretinal haemorrhage, progressing to full thickness retinal degeneration within 2 weeks. Visual outcomes may be better when treatment is performed within 7 days of submacular haemorrhage.

### Submacular RPE reconstruction

Laser, photodynamic therapy (PDT), or anti-VEGF therapies will not affect visual outcome in RPE rip and geographic atrophy. Diseased submacular RPE can be replaced by foveal relocation to an area of

extramacular RPE or by submacular RPE transplantation. Macular translocation with 360° retinotomy followed by counter-rotation extraocular muscle surgery may restore visual acuity in selected patients. Postoperative complications are common and can result in severe visual loss. Autologous equatorial RPE-choroid patch graft to the submacular space has been performed but remains experimental. In both procedures, CNV recurrence can occur in 10–20%, typically within the first 2 years.



**Fig. 3.32** Colour fundus photographs showing (a) subhyaloid haemorrhage from macroaneurysm which is distinguished from (b) submacular haemorrhage by the blood level and preretinal location of the blood in (a); (c) gas displacement of submacular haemorrhage and (d) its resolution.

*This page intentionally left blank*



## 3.13 Retinal tumours I

Primary tumours of the retina can be derived from neural, glial, vascular, or pigment epithelial cells. Although most are present at birth, they are frequently asymptomatic until adulthood. As many of these lesions form part of a hereditary systemic syndrome, a detailed family history, systemic work-up, and examination of family members are important. The retina and choroid can be affected by systemic malignancy indirectly through paraneoplastic syndromes.

### Retinoblastoma

Retinoblastoma is the most common primary intraocular malignancy in childhood.

- Age: birth to 5 years.
- Sex: ♂=♀.
- Ethnic group: any.
- Incidence: 1:15,000 live births

### Aetiology

A mutation in both alleles of the *RB* tumour-suppressor gene (chromosome 13q14) is required for the development of retinoblastoma (Knudson's two-hit hypothesis). In hereditary (germline) retinoblastoma, one mutant allele is inherited, and one normal allele subsequently undergoes mutation following conception. In non-hereditary retinoblastoma, both alleles are normal after fertilization, but spontaneous mutations subsequently inactivate both alleles.

The majority of the mutations in the *RB* tumour-suppressor gene lead to a truncated, unstable protein product and a consequent 50% reduction in the amount of Rb protein. Germline mutation in Rb and possibly other tumour-suppressor proteins may result in retinoblastoma development in early life (with 80–90% penetrance), osteogenic and soft-tissue sarcoma in the teenage years (20–30% risk), cutaneous melanoma and brain tumours in the fourth decade, and lung and bladder carcinoma in later life (60–70% risk). The risk of a child developing retinoblastoma if the parent has a heritable retinoblastoma (germline mutation) is 40–45%.

### Pathology

Retinoblastoma cells are derived from neuroepithelial cells that have the potential to differentiate into rod and cone photoreceptors or Müller cells. The tumour arises from the retina and may invade the vitreous (endophytic growth), the subretinal space (exophytic growth), or the optic nerve. Tumour calcification and necrosis are common. The retinoblastoma cells are highly mitotic, forming retinal structures of increasing maturity (Homer–Wright rosettes, neuroblasts; Flexner–Wintersteiner rosettes, early retinal cells; and fleurettes, immature photoreceptor cells).

### Clinical evaluation

- Can it be something else (e.g. PHPV, cataract, retinal detachment)?
- Germline mutation (second malignancy, siblings at risk, genetic counselling for heritability)?
- Staging (to guide further investigation and treatment).

### History

- Leukocoria (the presenting feature in 60%).
- Strabismus (exotropia or esotropia).
- Painful red eye and/or swollen red eyelids with proptosis.
- Hyphaema, hypopyon, heterochromia.
- Family history of retinoblastoma present in 6% of all new cases. Family history of sarcoma, melanoma, and carcinoma also confer an increased risk of germline mutations.

### Examination

- White intraretinal mass, multifocal or bilateral in 30%.
- Rubeosis, raised IOP, hyphaema, vitreous seeding.
- Preseptal or orbital cellulitis, proptosis.

### Investigations

- Examination under anaesthesia for detailed evaluation of both eyes.
- Ocular ultrasound.
- Magnetic resonance imaging (MRI) head with or without CT orbit.
- Cerebrospinal fluid and bone marrow aspiration.

### Differential diagnosis

- Leukocoria: cataract, PHPV, Coats' disease, toxocariasis, ROP.
- Vitritis: pars planitis, endophthalmitis, leukaemia.
- Retinal mass: astrocytic hamartoma, capillary haemangioma.

### Management

#### Screening of children of parents with heritable retinoblastoma

- Preimplantation genetic diagnosis.
- Regular fundus examination (from birth to 4 years old).

#### Family and genetic counselling

- Identify germline mutations and educate regarding risk to siblings and potential later development of sarcoma, melanoma, or carcinoma.
- Some 30–40% of patients with retinoblastoma have a germline mutation. Those with a family history of retinoblastoma (parent or sibling) or multifocal/bilateral tumours are considered to be due to a germline mutation. A family history of sarcoma, melanoma, carcinoma, or the development of a second tumour also suggest the presence of a germline mutation. Fifteen per cent of sporadic unifocal unilateral tumours are due to a spontaneous germline mutation.

### Treatment

- Traditional approach: external-beam radiation (carries a risk of a secondary skull sarcoma) or enucleation.
- Current approach: primary chemotherapy (carboplatin, etoposide, and vincristine) and focal consolidation with laser or cryotherapy. Focal irradiation with intensity-modulated radiation therapy and plaque brachytherapy are also used.
- Unilateral tumours: group D or worse: enucleation. Group C or better: primary chemotherapy with focal consolidation, focal laser, or cryotherapy only or brachytherapy.
- Bilateral tumours: in asymmetrically affected eyes, the more severe group E eyes still require enucleation whereas eyes in group D or better can be salvaged by focal treatment (including sub-Tenon carboplatin) with or without primary chemotherapy.
- Orbital extension: primary chemoradiotherapy and delayed enucleation or limited exenteration.

### Follow-up and monitoring

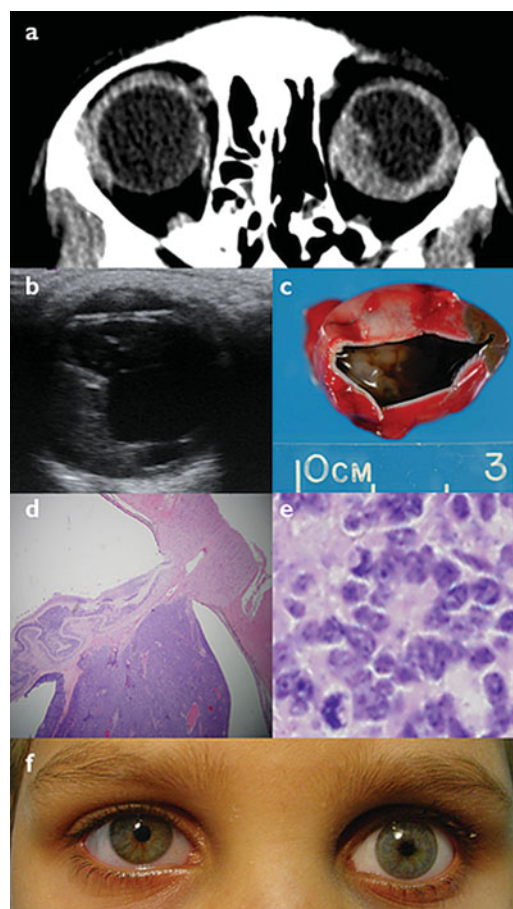
- Response to treatment may follow one of five patterns: complete disappearance, complete calcification, homogenous semi-translucent 'fish-flesh' lesions, a combination of 'fish-flesh' and calcification, or a flat chorioretinal scar with prominent RPE hyperplasia. The last three patterns require further focal consolidation.
- Side effects of treatment: radiation may cause hypoplasia of midface, cataract, radiation retinopathy, retinal detachment, neurocognitive deficits, and second malignancy.

### Complications and prognosis

- Survival rates are improving due to earlier diagnosis, prompt treatment, and reduced rates of treatment failure or tumour recurrence.
- Greater than 90% retinoblastoma-free survival is generally achievable.
- Group A and B eyes are salvaged in more than 90%. Group C, D, and E eyes are salvaged in 70%, fewer than 50%, and 2% of cases, respectively.

**Table 3.4** The ABC classification will replace the Reese–Ellsworth classification, as the former is based on outcome following current therapeutic approaches and the latter on outcome from external beam radiotherapy. (Murphree AL. 2005. Intraocular retinoblastoma: the case for a new group classification. *Ophthalmol. Clin. N. Am.* 18: 41–53).

Group	Description
A	Small tumours away from foveola and disc <ul style="list-style-type: none"> <li>• Tumours &lt;3 mm in greatest dimension confined to the retina</li> <li>• Located at least 3 mm from the foveola and 1.5 mm from the optic disc</li> </ul>
B	All remaining tumours confined to the retina <ul style="list-style-type: none"> <li>• All other tumours confined to the retina and not in group A</li> <li>• Subretinal fluid (without subretinal seeding) &lt;3 mm from the base of the tumour</li> </ul>
C	Local subretinal fluid or vitreous seeding <ul style="list-style-type: none"> <li>• Subretinal fluid alone &gt;3 mm and &lt;6 mm from the tumour</li> <li>• Vitreous or subretinal seeding &lt;3 mm from the tumour</li> </ul>
D	Diffuse subretinal fluid or seeding <ul style="list-style-type: none"> <li>• Subretinal fluid &gt;6 mm from the tumour</li> <li>• Vitreous or subretinal seeding &gt;3 mm from the tumour</li> </ul>
E	Presence of any one or more of these poor prognosis features <ul style="list-style-type: none"> <li>• More than two-thirds of the globe filled with tumour</li> <li>• Tumour in the anterior segment or anterior to the vitreous</li> <li>• Tumour in or on the ciliary body</li> <li>• Iris neovascularization</li> <li>• Neovascular glaucoma</li> <li>• Opaque media from haemorrhage</li> </ul>



**Fig. 3.33** This 4 year-old child presented with unilateral pan-uveitis and no fundus view. (a) CT and (b) ocular ultrasound revealed an intraocular mass arising from the retina with no optic nerve infiltration. (c) Enucleation specimen showed endophytic chalky white retinal mass. (d) Microscopy showed basophilic cells infiltrating the retina but not the optic nerve head. Under higher power (e) retinoblastoma cells formed Homer–Wright rosette with lumen filled with eosinophilic cytoplasmic processes. (f) Left prosthetic eye shell after enucleation.

### Further reading

Shields CL, Shields JA. 2006. Basic understanding of current classification and management of retinoblastoma. *Curr. Opin. Ophthalmol.* 17: 228–234.

## 3.14 Retinal tumours II

### Retinal vascular tumours

Retinal vascular tumours can be classified into four types: (1) retinal capillary haemangioma, (2) retinal cavernous haemangioma, (3) retinal arteriovenous communications (Wyburn–Mason syndrome), and (4) retinal vasoproliferative tumour. The first three lesions are vascular hamartomas (tumorous malformation of tissue normally found at the site).

#### Capillary haemangioma

Forty per cent of these benign congenital vascular tumours are associated with von Hippel–Lindau syndrome. Clinically, the vascular tumour starts as a red dot which enlarges to form a vascular mass, typically located in the periphery or adjacent to the optic disc. Peripheral capillary haemangiomas have dilated retinal feeder and draining vessels. Exudative retinal detachment, macular exudates and tractional retinal detachment may lead to symptoms in the second or third decade of life. FFA shows diffuse mid- and late-phase leakage from the angioma. Systemic assessment for evidence of von Hippel–Lindau is indicated. Conservative management is considered for small and asymptomatic lesions. Laser photocoagulation and cryotherapy are performed for small posterior and larger anterior lesions respectively. PDT, radiotherapy, and anti-VEGF therapies have also been used. Vitrectomy is indicated to treat rhegmatogenous/tractional detachment.

#### Cavernous haemangioma

This benign congenital vascular tumour is occasionally associated with CNS and skin haemangiomas. Clinically, a purplish retinal mass resembling a bunch of grapes may be seen in the peripheral retina or at the optic disc. No feeder vessels are present. Vitreous haemorrhage can occur in 10% of cases. FFA typically reveals early hypofluorescence with late pooling of dye and a meniscus visible at the fluorescein–blood interface within each lobule of the haemangioma. Treatment is not required in the majority of cases.

#### Retinal arteriovenous malformation

This is a benign congenital vascular lesion, also called a racemose haemangioma, characterized by an abnormal arteriovenous communication. Group I is usually asymptomatic with an abnormal capillary plexus between the major vessels. Group II has direct arteriovenous communication without intervening capillaries and group III has a more extensive complex arteriovenous communication often associated with visual loss. Although ocular complications are rare (BRVO), an association with mid-brain lesions (Wyburn–Mason syndrome) is more common in the latter two groups. A vascular malformation in the mandible and maxilla in some cases may complicate routine dental procedures. FFA typically shows no evidence of vascular leakage. Management is generally conservative.

#### Retinal vasoproliferative tumours

These acquired vascular tumours may be primary (idiopathic) or secondary to ocular conditions such as uveitis, retinal detachment, retinitis pigmentosa, toxoplasmosis, and Coat's disease. Clinically, single or multiple yellow or pink retinal nodules are seen in the pre-equatorial retina typically in the inferotemporal retina. Visual loss due to macular exudates, oedema, epiretinal membrane, exudative retinal detachment, vitreous haemorrhage, and rubeotic glaucoma may prompt presentation, usually between ages of 40–60 years. FFA demonstrates profuse leakage from capillary or telangiectatic vessels within the tumour. The differential diagnosis includes eccentric disciform, capillary haemangioma, choroidal

melanoma and choroidal haemangioma. The management is conservative for small asymptomatic peripheral lesions. Cryotherapy, brachytherapy, and PDT have been used with some success. Vitrectomy may be indicated for recurrent vitreous haemorrhage and epiretinal membrane.

### Hamartoma of the RPE and retina

These benign lesions are sometimes associated with a systemic cancer syndrome or phakomatosis.

#### Typical congenital hypertrophy of RPE (CHRPE)

This typically appears as a solitary, round, flat, well-defined, deeply pigmented lesion. With time, depigmentation around or within the lesion may appear forming a halo or lacunae respectively. Although the overlying retina appears normal clinically, histology shows loss of photoreceptors in the area of CHRPE. A 'bear tracks' arrangement of multiple typical CHRPE lesions is not uncommon. Typical CHRPE lesions are not associated with systemic disease.

#### Atypical CHRPE

Atypical CHRPE or 'multiple RPE hamartomas' usually have four or more variably sized lesions in one or both eyes (as small as 50 µm) and are of variable shape (round, oval, comet-shaped, irregular). Larger lesions with depigmented haloes and RPE mottling may be accompanied by small satellite lesions. Atypical CHRPE can occur as an extracolonic manifestation of Gardner syndrome, caused by a germline mutation of the APC gene (5q21). Similar to retinoblastoma, the inheritance of this condition is dominant but its molecular mechanism is recessive. Other extracolonic features may include bone and soft-tissue hamartomas or dental abnormalities.

#### Combined hamartoma of RPE and retina

These lesions may be associated with neurofibromatosis 1 or 2. This tumour is composed of RPE, vascular, and glial tissues forming a solitary elevated lesion in the posterior pole, around the disc or midperipheral retina. Varying pigmentation, vascular tortuosity, and epiretinal membranes are characteristic. Visual loss may be due to direct involvement of the fovea, papillomacular bundle or optic disc, or secondary to epiretinal membrane, vitreous haemorrhage, or CNV.

#### Astrocytic hamartoma

These occur in patients with tuberous sclerosis. It is usually located at or near the optic disc, appearing as a white calcified endophytic nodular mass or flat translucent smooth intraretinal tumour. Visual loss can occur due to vitreous haemorrhage from the tumour or retinal neovascularization. Systemic work-up should include CT head and renal ultrasound. Two genes responsible for tuberous sclerosis are TSC 1 (chromosome 9q34) and TSC 2 (chromosome 16p13).

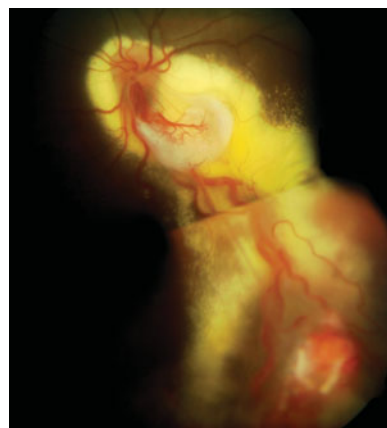
## Posterior segment and paraneoplastic syndrome

### Cancer-associated retinopathy

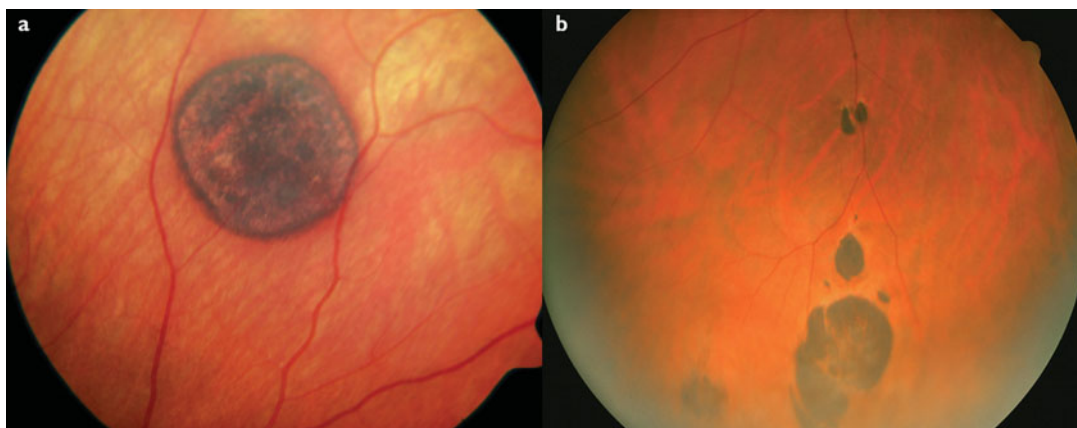
Over half of cancer-associated retinopathies (CAR) are associated with lung carcinomas. Development of anti-recoverin and other anti-retinal autoantibodies may account for the features of photoreceptor loss, progressive visual loss (typically ring scotoma and nyctalopia), vascular attenuation, pigmentary changes, minimal vitritis, and extinguished response on electroretinography (ERG). In melanoma-associated retinopathy, anti-bipolar cell autoantibodies may cause non-progressive central visual loss, nyctalopia, and an electronegative ERG. Visual prognosis is generally poor; with treatment of the primary tumour not appearing to alter the final visual acuity.

### Bilateral diffuse uveal melanocytic proliferation

Bilateral diffuse uveal melanocytic proliferation (BDUMP) is characterized by diffuse uveal thickening, multiple, slightly elevated uveal melanocytic lesions, multiple round or oval red patches at the level of RPE with corresponding angiographic leakage, exudative retinal detachment, and progressive cataract. The onset of these features may predate discovery of malignancy (e.g. ovarian or pancreatic carcinoma) by 3–12 months.



**Fig. 3.34** Composite colour fundus photograph showing capillary haemangioma with extensive exudation in a patient with von Hippel-Lindau syndrome.



**Fig. 3.35** Colour fundus photographs of (a) solitary typical and (b) multifocal atypical CHRPE.



## 3.15 Choroidal tumours I

Primary tumours of the choroid may originate from melanocytic, vascular, neural, or connective tissues cells. Many benign tumours are hamartomas (tumorous malformation of tissue normally found at the site, e.g. melanocytic naevi and haemangioma) or choristomas (tumorous malformation of tissue not normally found at the site, e.g. choroidal osteoma). Neoplastic infiltration of the choroid from systemic malignancy may occur in lymphoma, leukaemia, carcinoma, and melanoma.

### Choroidal naevus

A choroidal naevus is a melanocytic hamartoma composed of naevus cells with limited growth potential. Naevi may rarely transform into melanomas. A melanocytoma is a special subtype of choroidal naevus with distinct epidemiological, clinical, and histological features.

- Age: >30 years.
- Sex: ♂=♀.
- Group: white.
- Prevalence: 1–8%.

### Aetiology

There is increased rate of choroidal naevi in patients with neurofibromatosis and dysplastic naevus syndrome.

### Pathology

Naevus cells are classified into four types: (1) plump polyhedral naevus cells, (2) slender spindle naevus cells, (3) intermediate naevus cells (with features in between type 1 and type 2 cells), and (4) balloon cells (thought to be due to an autoimmune reaction). Melanocytomas are composed exclusively of plump polyhedral naevus cells. Not to be confused with a naevus, ocular melanocytosis is characterized by an increased number of uveal melanocytes rather than naevus cells. Secondary degenerative changes in the choriocapillaris, Bruch's membrane, and the RPE are commonly seen overlying the naevus.

### Clinical evaluation

- Will this lesion grow? (i.e. is it a small melanoma?)
- Is this lesion sight-threatening? (i.e. retinal complication?)

### History

- Field defect.
- Photopsia (consider the possibility of melanoma).

### Examination

- Flat or slightly elevated greyish lesion with well-defined borders.
- Low-risk factors for tumour for growth: small size, overlying drusen, RPE degenerative changes, location greater than two disc diameters from the optic disc.
- High-risk factors for tumour for growth: large diameter, orange pigment, less than two disc diameters from the optic disc, sub-retinal fluid without CNV.

### Investigations

- Ultrasound: less than 2 mm thickness, no internal blood flow.
- Fundus photography: linear dimensions under seven disc diameters.
- FFA: hyperfluorescence associated with RPE defect, RPE leak, CNV, or drusen. Hypofluorescence associated with choriocapillary closure, pigment masking.
- OCT: sub-retinal fluid or retinal oedema.

### Differential diagnosis

- Small melanoma.
- RPE hypertrophy (CHRPE) or hamartoma.

- Choroidal metastasis or haemangioma.

### Management

#### Low risk of growth

- Observation with annual fundus exam or photography.

#### High risk for growth

- Observation with 4–6 monthly examination.
- Consider ultrasound or FFA.

#### Complicated: CNV

- Laser photocoagulation, PDT.

### Complications and prognosis

- Misdiagnosing early melanoma as a naevus.
- CNV formation with subretinal fluid and haemorrhage.
- Optic disc melanocytomas may rarely cause central retinal vein occlusion (CRVO) or anterior ischaemic optic neuropathy (AION).

## Choroidal haemangioma

This is a vascular hamartoma occurring in two distinct forms: (1) circumscribed and (2) diffuse. The latter type is associated with Sturge–Weber syndrome.

### Clinical evaluation

Visual loss due to a circumscribed choroidal haemangioma may be associated with macular oedema or a serous retinal detachment. It is typically found posterior to the equator, usually temporal to the optic disc, with a yellowish or orange-red colour, slight elevation, and associated RPE changes. Subretinal fluid and epiretinal membrane may also affect. Investigation with FFA, ICG angiography, and ultrasound can usually distinguish a choroidal haemangioma from a choroidal melanoma. Diffuse choroidal haemangioma is typically found when screening patients with Sturge–Weber syndrome.

### Management

Asymptomatic lesions do not need treatment. Serous retinal detachment may respond to treatment with radiation (external beam or brachytherapy), laser photocoagulation, transpupillary thermotherapy, or PDT.

### Complications and prognosis

Rarely, significant growth of lesion can occur, especially during pregnancy. In addition to serous retinal detachment, CNV may complicate circumscribed choroidal haemangioma.

## Choroidal osteoma

Choroidal osteoma is typically found in healthy females in their 20–30s. Familial and bilateral cases have been described. Pathological features suggest an osseous choristoma although similar ossification may occur following intraocular inflammation.

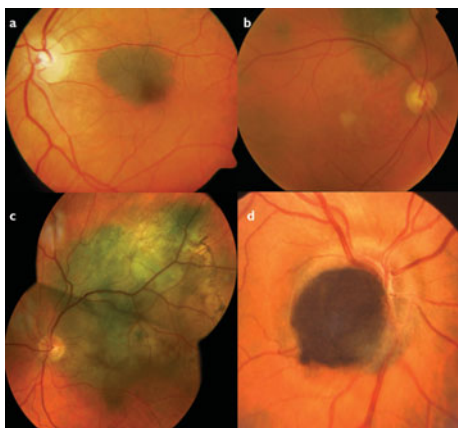
### Clinical evaluation

Visual symptoms may result from an epiretinal membrane or CNV. Typical lesions appear as an oval placoid yellow or orange choroidal mass adjacent to the disc. FFA, ultrasound, and CT scanning of the orbit may differentiate this lesion from melanoma, metastasis, haemangioma, AMD, sclerochoroidal calcification, and posterior scleritis.

### Management and prognosis

The risk of CNV is greater than 50% over 20 years and visual acuity is greater than 6/60 in 40% of patients. Laser, PDT, and surgical excision may be used to treat secondary CNV. There is no risk of systemic dissemination.





**Fig 3.36** Colour fundus photography of (a) submacular choroidal naevus, (b) high-risk choroidal naevus with orange pigmentation and (c) diffuse choroidal melanoma developed from a choroidal naevus with orange pigmentation, (d) optic disc melanocytoma is composed of plump polyhedral naevus cells with no malignant potential.

## 3.16 Choroidal tumours II

### Choroidal melanoma

Choroidal melanoma is the most common intraocular malignancy. Its incidence is one-eighth that of cutaneous melanoma.

- Age: median=55 years.
- Sex: ♂=♀.
- Ethnic group: white.
- Incidence: 6 per million per year.

#### Aetiology

The risk of melanoma is increased in ocular or oculodermal melanocytosis (lifetime risk of 26 per 10,000), and dysplastic naevus syndrome. Familial cases have rarely been reported. ultraviolet exposure may play a role. Assuming all melanomas arise from choroidal naevi, 1 in 5000 naevi per year will transform into melanomas.

#### Pathology

Melanoma cells are derived from neural crest cells. Histological examination of choroidal melanomas show spindle cells, clear cells, balloon cells, epithelioid cells, and areas of necrosis. The presence of the latter two is associated with a higher mortality rate. Other features that correlate with higher mortality are an increased epithelioid cell density, nuclear or nucleolar size, aneuploidy, monosomy 3, duplication of chromosome 8, lymphocytes, and certain extracellular matrix patterns. Secondary RPE transformation to lipofuscin-filled macrophages and migration to the subretinal space gives rise to orange pigment. Exudative retinal detachment is common. Tumour extension through Bruch's membrane gives rise to a mushroom-shaped appearance. Extension through the retina may result in vitreous seeding and melanomalytic glaucoma. Extrascleral extension may account for orbital recurrence after enucleation.

#### Clinical evaluation

- Can it be benign (e.g. melanocytoma/disciform scar)?
- Does it have extra/intraocular extension?
- Risk factors for metastasis?

#### History

- Visual-field defect (associated with the tumour mass or associated exudative retinal detachment).
- Photopsia.
- Painful red eye (acute rise in IOP).

#### Examination

- Elevated dome-shaped lesion with variable pigmentation and vascularity.
- Exudative retinal detachment, macular oedema.
- Low-risk features for metastasis: small size.
- High-risk features: large diameter (>16 mm), orange pigment, anterior location, subretinal fluid without CNV.

#### Investigations

- Fundus photography.
- Ultrasound: tumour height >2 mm, with median internal reflectivity and internal blood flow (high risk of metastasis if >8–10 mm height).
- FFA and ICG angiography are usually not required.
- Systemic work up for metastasis (liver-function test with or without liver ultrasound).

#### Management

- Patient characteristics: age, systemic metastasis, health.
- Tumour characteristics: size and location, intraocular or extraocular extension, cytogenetic risk factors (if biopsy sample available).

- Contralateral visual function: need to conserve vision?

#### Indeterminate melanocytic lesion

- Observation with 4–6 monthly photography and ultrasound.
- High-risk lesions may be treated with transpupillary thermal therapy (<3 mm thick, >3 mm from fovea), or laser.

#### Small-sized melanoma (documented growth)

- Observation (risk of early occult metastasis).
- Transpupillary thermotherapy or laser photocoagulation.

#### Medium-sized melanoma

- Brachytherapy (<sup>106</sup>Ru up to 5 mm or <sup>125</sup>I up to 10 mm).
- Charged particle irradiation.
- Lamellar sclerouvectomy (>6 mm thick, <16 mm base).
- Vitrectomy and endoresection.
- Combination of above.

#### Large-sized melanoma (with or without vitreous seeding, glaucoma)

- Enucleation.

#### Melanoma with extrascleral or optic nerve extension

- Enucleation with or without pre-enucleation external beam radiotherapy.
- Limited exenteration plus pre-enucleation external beam radiotherapy.

#### Melanoma with systemic metastasis

- Enucleation.
- Chemoembolization or resection of solitary hepatic foci.

#### Recurrence from failed-eye-conserving treatment

- Enucleation.

#### Complications and prognosis

- Cataract, vitreous haemorrhage, retinal detachment, radiation retinopathy, optic neuropathy, strabismus, CNV.
- Local tumour recurrence: 5–15% (brachytherapy), 6% (resection), 4% (proton beam).
- Visual function: 50% >6/60 and 30% >6/12 (radiation)
- Metastasis: monitor with 6 monthly liver-function test, clinical metastasis manifest in 3–5 years, predicted by tumour histology and cytogenetics. Mortality: 10% at 5 years and 20% at 10 years.

### Posterior segment metastasis

Ten per cent of patients who die from cancer may have intraocular metastases. Although carcinomatous metastases in the choroid are much more common than retinal, vitreal, ciliary body, or iris metastases, multiple tissue sites may be involved concurrently. In females two-thirds of choroidal metastases are associated with breast carcinoma and in males 40% are associated with lung carcinoma. Despite systemic work-up, 1 in 6 may have no detectable primary malignancy. Leukaemia, CNS lymphoma, and systemic/cutaneous lymphoma may affect the eye in 30–80%, 15–25%, and 7% of patients respectively. These haematological malignancies may present with a masquerade syndrome mimicking pan-uveitis or opportunistic infections.

#### Clinical evaluation

##### Carcinoma and melanoma

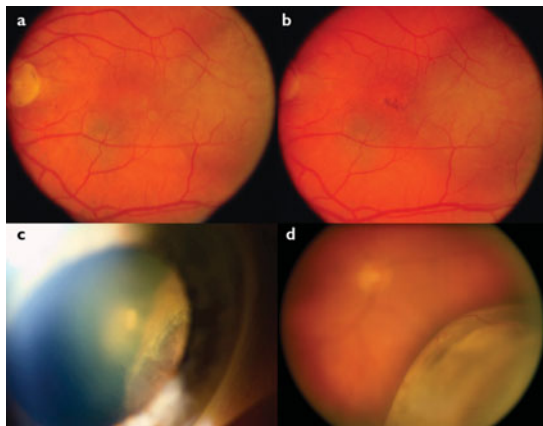
- Carcinoma: multiple cream or yellow choroidal lesions with minimal elevation, some RPE clumping and sub-retinal fluid.
- Melanoma: retinal infiltrates with cells extending into the vitreous forming golden-brown clumps or sheets.

### Leukaemia and lymphoma

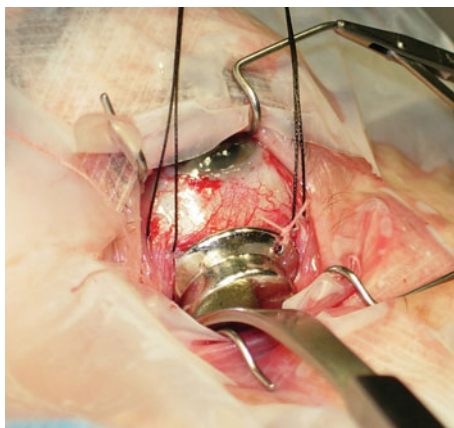
- Leukaemia: retinal and optic disc infiltrates with haemorrhage, vitreous cells, and pseudohypopyon.
- Lymphoma: sub-RPE/choroid yellow infiltrates with vitreous and anterior chamber cells and retinal vascular occlusion.

### Diagnosis and management

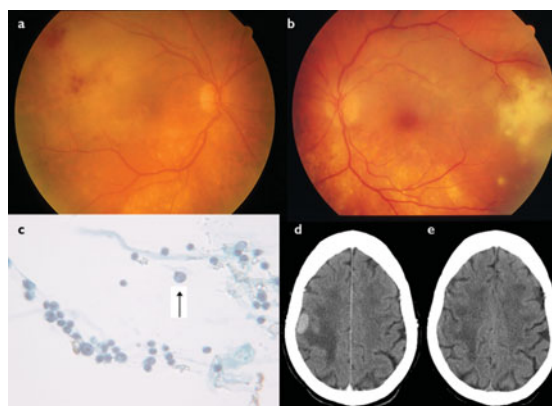
- Systemic work-up (tailored to symptoms and risk factors).
- Tissue diagnosis (vitreous, retinal, or choroidal biopsy).
- Systemic or CNS treatment of primary malignancy.
- Ocular treatment: systemic chemotherapy, radiation, intraocular methotrexate, and rituximab (lymphoma).



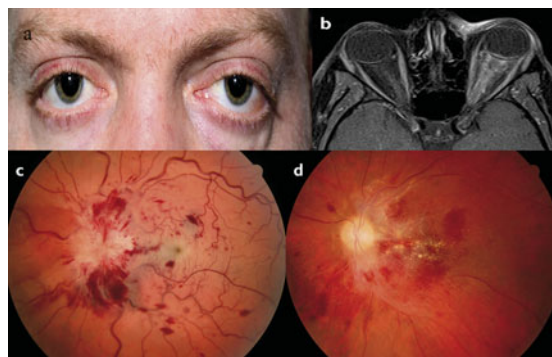
**Fig. 3.37** Colour fundus photographs showing enlargement of choroidal melanoma over a 2 year period from (a) to (b) with development of cystoid macular oedema and macular pigmentary changes. A patient with large anterior choroidal: ciliary body melanoma seen on (c) slit lamp and (d) funduscopy.



**Fig. 3.38** Iodine-seeded plaque being sutured to sclera for brachytherapy of choroidal melanoma.



**Fig. 3.39** Primary CNS lymphoma: sub-RPE infiltrates, vascular occlusion, retinal haemorrhage, and vitreous cells (a, b). (c) Vitreous biopsy showed atypical lymphocytes (arrow). Three months after onset of vitritis, the patient presented with complex partial seizure due to (d) cerebral lymphoma; contrast-enhancing cortical lesion on head CT. (e) After radiotherapy, the cortical lesion reduced in size. Ocular lesions resolved with orbital radiotherapy.



**Fig. 3.40** Ocular leukaemia: (a) left proptosis with perception of light vision, (b) optic nerve thickening on T1-weighted MRI scan of the orbit and brain, and (c) optic nerve head and retinal infiltrates, with combined central retinal vein and artery occlusions. (d) After further chemotherapy, vision did not improve due to severe optic neuropathy.

### Further reading

Singh AD, Kivela T. 2005. The collaborative ocular melanoma study. *Ophthalmol. Clin. N. Am.* **18**: 129–142.

## 3.17 Vitreoretinopathies

Vitreoretinopathy describes a number of pathological processes which have a common association with retinal detachment.

1. Proliferative vitreoretinopathy: a growth and contraction of cellular membranes within the vitreous cavity and on both retinal surfaces leading to traction following RRD.
2. Hereditary vasculoretinopathies or proliferative retinopathies are a group of disorders characterized by an arrest of retinal vasculogenesis which leads to retinal neovascularization, fibrous tissue proliferation, and tractional retinal detachment. Associated systemic manifestations may be present.
3. Hereditary vitreoretinopathies or hyaloideoretinal degenerations refer to a group of disorders characterized by fibrillar or membranous vitreous changes which may lead to an optically empty vitreous, varying degrees of chorioretinal atrophy, myopia, cataract, a risk of RRD, oro-facial malformation, skeletal abnormalities, and hearing loss.

### Hereditary vasculoretinopathies

These disorders are distinguished from one another by inheritance patterns, ophthalmic features, and systemic manifestations.

#### Familial exudative vitreoretinopathy

Familial exudative vitreoretinopathy may be inherited via autosomal dominant, autosomal recessive, or X-linked recessive patterns. Mutation in the *FZD4* or *LRP5* genes have been found in affected individuals. Clinical features vary from asymptomatic temporal retinal vascular insufficiency demonstrable with FFA to bilateral severe fibrovascular proliferation and retinal detachment (in 20%) due to a combination of retinal vascular exudation, vitreoretinal traction, and retinal breaks. Non-progressive falciform retinal folds (typically extending from the optic disc to the inferotemporal retina) are seen in up to 40% of eyes. There are no associated systemic features. Treatment is directed towards reducing VEGF production by laser or cryoablation of avascular retina.

#### Norrie's disease

This X-linked recessive condition is associated with a mutation in the *Norrin* gene which plays a role in retinal vasculogenesis. Affected males are blind at birth due to retinal dysplasia. The presenting feature is often leukocoria caused by bilateral retinal detachments or retrolental masses. Developmental delay and mental retardation occur in up to 50% and during adolescence over 50% develop severe hearing loss. Although no treatment is available, genetic counselling and prenatal diagnosis may be helpful.

#### Incontinentia pigmenti (Bloch-Sulzberger syndrome)

This X-linked dominant disease is due to a mutation in the nuclear factor  $\kappa B$  (NF- $\kappa B$ ) essential modulator (*NEMO*) gene. The condition is lethal in most but not all males. Affected females may develop hyperpigmented skin lesions around 6 months of age, and later develop alopecia, hypodontia, dystrophic nails, cognitive delay, and retinal vascular abnormalities. Visual loss may occur due to retinal neovascularization, tractional retinal detachment, and macular or occipital lobe infarction.

### Hereditary vitreoretinopathies

These disorders are characterized by vitreous degeneration associated with mutations in genes coding for collagen, versican nuclear receptor, or potassium channels.

#### Stickler's syndrome

This autosomal dominantly inherited condition is due to a mutation in genes coding for collagen type II (*COL2A1*) or type XI (*COL11A1*). Diagnostic clinical criteria include: a congenital vitreous anomaly (seen on slit lamp examination as a membranous vitreous structure visible behind the lens or as aggregations of beaded vitreous fibril), and any three of the following: (1) onset of myopia before 6 years of age, (2) RRD or paravascular pigmented lattice changes, (3) joint hypermobility with an abnormal Beighton score, (4) sensorineural hearing loss, and (5) midline clefting. Other ocular findings may include non-progressive cataract, ectopia lentis, glaucoma, and giant retinal tears.

#### Hyaloideoretinal degenerations (Wagner, Jansen)

These are autosomal dominant conditions affecting the vitreous and retina. Wagner syndrome is due to a mutation in the *CSPG2/versican* gene characterized by an optically empty vitreous cavity with thickened and incompletely separated posterior vitreous cortex. Other features include nyctalopia, ring scotoma, mild to moderate myopia, early-onset cataract, peripheral tractional retinal detachment (55%), ectopic fovea, progressive loss of rod and cone ERG responses, and chorioretinal atrophy. Retinal detachment can occur, and no systemic features are present.

#### Goldmann-Favre syndrome

This autosomal recessive condition is characterized by nyctalopia in early childhood, vitreous syneresis with veils and membranes, macular and peripheral retinoschisis, pigmentary retinopathy, hyperopia, an electronegative ERG, and an abnormal electrooculogram (EOG). Mutation in the *NR2E3* gene may affect photoreceptor function leading to increased sensitivity of S cones.

#### Snowflake vitreoretinal degeneration

This autosomal dominant condition, linked to mutation in the *KCNJ13* gene, is characterized by early-onset cataract, fibrillar vitreous degeneration, granular and minute crystalline deposits near the equatorial retina, corneal guttae, and optic nerve head dysplasia. Retinal detachment can occur in 20%, but systemic features are absent. The disease progresses from extensive white-with-pressure to the snowflake features, chorioretinal pigmentary changes and vascular sheathing then finally disappearance of peripheral retinal vessels. In the late stages, the ERG is reduced with visual-field constriction.

#### Collagen disorders associated with retinal detachment

Other systemic disorders associated with vitreous syneresis, myopia, and an increased risk of RRD include: Marfan syndrome, Weil-Marchesani syndrome, spondyloepiphyseal dysplasia, Kniest dysplasia, and Knobloch syndrome.

## Hereditary retinoschisis

This is a disorder of retinal development with secondary retinal, vitreous, and RPE degeneration. The inheritance is classically X-linked although dominant and sporadic cases have been described. Onset is in early childhood.

### Clinical evaluation

Central visual loss is initially mild but progressive due to foveal retinoschisis and late macular pigmentary degeneration. Half of the X-linked forms may have peripheral retinoschisis that can be complicated by (1) retinal detachment from breaks in the inner and outer layers of the peripheral schisis cavity and (2) intraschisis or vitreous haemorrhage from vitreous traction on bridging retinal vessels in the schisis cavity. Ultimately, retinal atrophy replaces the area of foveal and peripheral retinoschisis. Electronegative ERG and mutation in the coding regions of *RS1* gene are characteristic. Differential diagnosis includes cystoid macular oedema, nicotinic acid maculopathy, Goldmann–Favre syndrome, and enhanced S cone syndrome.

### Management

Correct any refractive error and educate patients regarding symptoms of retinal detachment. Surgical treatment is indicated for vitreous haemorrhage and retinal detachment. Genetic counselling is essential as 1 in 2 male offspring of female carriers can be affected in X-linked diseases.



## 3.18 Retinopathy of prematurity

ROP is a condition which may lead to severe visual loss in premature infants and is characterized by incomplete vascularization of the retina. Screening and early treatment of ROP with peripheral retinal ablation is one of the most cost-effective medical interventions. Babies at highest risk have a birth weight of 1500g or less, or gestational age of 32 weeks or less. The incidence of ROP in these babies is 30–60%.

### Embryology

The retinal vessels reach the nasal ora serrata by 32 weeks and the temporal ora by 40 weeks. Therefore, infants born prior to 32 weeks' gestation have a rim of avascular retina behind the ora serrata.

### Pathogenesis

One popular theory suggests that an initially high oxygen tension after birth leads to vasoconstriction and later obliteration of the distal retinal capillaries. The remaining arterioles and venules form shunts at the border of vascular and avascular retina. These shunt vessels enlarge, forming a red ridge (stages 1–2). Vascular endothelium from the shunt may proliferate anteriorly into the avascular retina to complete retinal vasculogenesis (leading to involution of ROP). Alternatively, the endothelium may proliferate along the surface or into the vitreous forming fibrovascular tissue (stage 3). A combination of exudation from the extraretinal new vessels and fibrous traction leads to retinal detachment (stages 4 and 5).

### Clinical evaluation (acute ROP)

- Initial examination: between 4 and 6 weeks old, or 31 weeks post-conception age (whichever is later).
- Zones:
  - I. the area within a circle the radius of which is twice the distance from the disc to the macular;
  - II. the area extending concentrically from the edge of zone I to the nasal ora serrata and to an area near the temporal equator;
  - III. the residual area temporal to zone 2
- Extent: number of clock hours of retinal involvement.
- Stage:
  1. flat demarcation line;
  2. elevated ridge;
  3. ridge with extraretinal fibrovascular proliferation;
  4. subtotal retinal detachment:
    - a. not involving the macular;
    - b. involving the macular;
  5. total retinal detachment.
- Plus disease: pupillary rigidity, vitreous haze, retinal vascular dilatation.

### History

- Birth weight and gestational age.
- Perinatal comorbidities.

### Examination

- Dilate pupils with cyclopentolate 0.2–0.5% with or without phenylephrine 1–2.5% (allow 60 minutes).
- Binocular indirect ophthalmoscope with 28D lens, sterile lid speculum, and neonatal scleral depressor.
- Nursery staff present for restraint and monitoring of vital signs.
- Determine presence of plus disease, zone, extent, and stage of ROP.

### Investigations

- Ultrasound: if no fundus view.
- Fundus imaging: digital wide-field photography (e.g. RetCam) or video BIO.

### Differential diagnosis (all in full-term infants)

- Retinoblastoma (retinal mass on ultrasound).
- Familial exudative vitreoretinopathy (dominant family history).
- Incontinentia pigmenti (female, X-linked dominant).
- Norrie's disease (male, X-linked recessive).
- Congenital cataract (examination).
- Persistent fetal vasculature (unilateral, microphthalmia).

### Management

- If retina is vascularized in zone I only: re-examine in 1 week.
- If retinal vascularization has reached zone II only: re-examine in 2 weeks.
- If retinal vascularization reaches zone III without previous zone I or II ROP: acute screening may cease.

### Less than high-risk prethreshold retinopathy

- Zone I with stage 1 or 2: re-examine twice weekly.
- Zone II, stage 1: examine in 2 weeks; stage 2: examine in 1 week; stage 3 (no plus) or stage 1 with plus: examine twice weekly.

### High-risk prethreshold ROP

Early Treatment for Retinopathy of Prematurity (ETROP) study guidelines suggest laser photocoagulation or cryotherapy of avascular retina if there is:

1. any stage of ROP in zone I with plus disease;
2. stage 3 ROP in zone I with or without plus disease;
3. stage 2 or 3 ROP in zone II with plus disease.

### Threshold ROP

This is defined as stage 3 ROP in zone I or II occupying at least five contiguous clock hours or eight non-contiguous clock hours of retina. Laser photocoagulation or cryotherapy of avascular retina are indicated.

### Stage 4 or 5 ROP

- Better surgical outcomes associated with prior laser treatment, vascularly quiet eyes, and attached macular (stage 4A).
- In exudative retinal detachment (no traction): laser and wait.
- Surgical options include scleral buckling and/or lens-sparing vitrectomy.

### Treated ROP

- After laser or cryotherapy re-examine in 1 week: if not regressed, undertake additional ablation of untreated avascular retina.
- After vitrectomy: once subretinal fluid is reabsorbed (may take 2–4 months), correct refractive error and commence amblyopia treatment.

### Regressed ROP

- Acute angle-closure glaucoma: peripheral iridotomy or lensectomy for ciliary block.
- Myopia (up to 25%): spectacle correction.
- Amblyopia: occlusion therapy.
- Strabismus (up to 30%): observe during first year.
- Late-onset RRD: scleral buckling or vitrectomy.
- Acute retinal screening may cease if postmenstrual age of 45 weeks and no previous prethreshold disease.

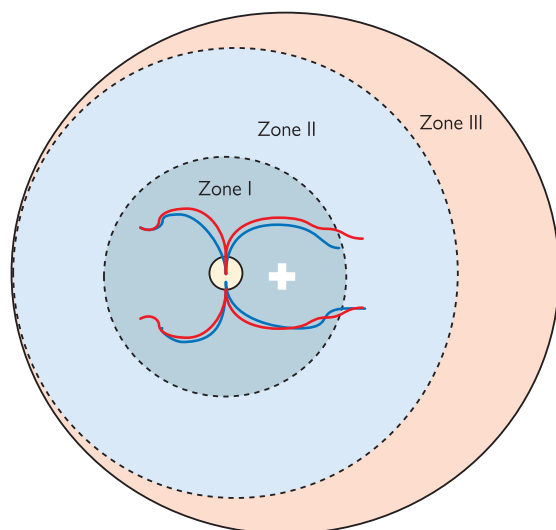
### Complications

- ROP examination in infant may cause apnoea, and retinal or vitreous haemorrhage. Topical anaesthetics may cause epithelial toxicity. General anaesthesia may have mortality due to systemic comorbidities.
- Cryotherapy may lead to anterior segment ischaemia, delayed RRD, and cataract.

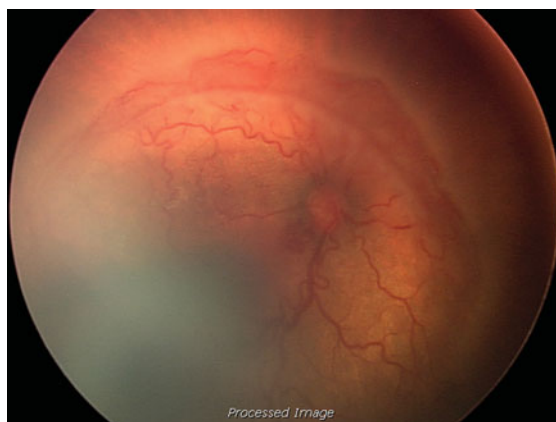
- Laser photocoagulation may cause anterior segment ischaemia or cataract. Five per cent progress to stage 4 disease despite treatment at threshold level.

### Prognosis

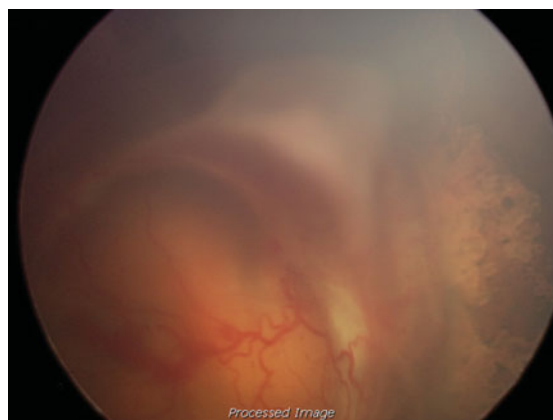
- Functional visual acuity (4/60 or better) in approximately 85% at 9 years and favourable anatomical outcome in approximately 90% at 2 years with laser treatment at prethreshold level.
- Untreated threshold disease is associated with unfavourable anatomical outcomes in 48% at 10 years.
- Vitrectomy in stage 4A ROP may prevent progression to stages 4B or 5.



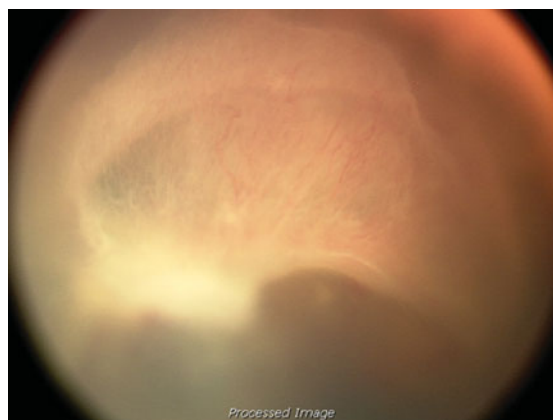
**Fig. 3.41** Diagram showing ROP zones.



**Fig. 3.42** Stage 3 ROP with plus disease, manifesting as posterior-pole vascular dilatation and tortuosity.



**Fig. 3.43** Stage 4 disease with laser scars in the avascular zone.



**Fig. 3.44** Stage 4 disease showing extraretinal neovascularization.

### Further reading

Good WV, Early Treatment for Retinopathy of Prematurity Cooperative Group. 2004. Final results of the Early Treatment for Retinopathy of Prematurity (ETROP) randomized trial. *Trans. Am. Ophthalmol. Soc.* **102**: 233–248.

## 3.19 Posterior segment trauma

The posterior segment may be involved in both ocular and systemic injuries. Direct ocular trauma is the cause of a significant proportion of blindness in young adults.

### Aetiology

#### Ocular injuries involving the posterior segment

- Mechanical trauma:
  - closed-globe injury: contusion, lamellar laceration with or without a superficial foreign body;
  - open-globe injury: penetrating (full-thickness entry wound) or perforating (full-thickness entry and exit wounds) injury with or without an intraocular foreign body, globe rupture (full-thickness wound from blunt force).
- Electromagnetic radiation:
  - radiation retinopathy and optic neuropathy,
  - retinal laser burns,
  - solar maculopathy,
  - lightning retinopathy

#### Systemic injuries affecting the posterior segment

- Shaken-baby syndrome.
- Terson syndrome.
- Purtscher's retinopathy.

### Pathophysiology

#### Blunt ocular injury

Blunt globe trauma may cause a rupture of the sclera at its weakest locations (rectus muscle insertions, optic nerve head, or previous surgical wound). Even in the absence of a scleral rupture, vitreoretinal traction induced by compression and decompression of the globe can cause a retinal dialysis (disinsertion of retina at ora serrata), avulsion of vitreous base, retinal tears, or a macular hole. The choroid may rupture, typically in a circumferential pattern around the optic nerve head. The photoreceptor–RPE complex can be sheared resulting in commotio retinae. With severe trauma, the retina and choroid can undergo contusional necrosis (retinitis sclopetaria).

#### Penetrating ocular injury

A sharp object may penetrate or perforate the globe causing a retinal break, retinal detachment, or vitreous haemorrhage. Intraocular foreign bodies with a significant copper or iron content can cause chalcosis or siderosis respectively. The risk of endophthalmitis is 10% and the onset is usually acute.

#### Systemic trauma

In shaken-baby syndrome increased intracranial pressure and vitreoretinal traction may lead to multiple retinal haemorrhages, vitreous haemorrhage, and circular retinal folds. In Terson syndrome, a subarachnoid haemorrhage causes an acute rise in intracranial pressure with a resultant acute reduction in retinal venous outflow, damage to peripapillary tissues, rupture of retinal capillaries and vitreous haemorrhage. Purtscher's retinopathy is due to embolic occlusion of the pre-capillary arterioles typically occurring following visceral or orthopaedic injury. A similar Purtscher's like retinopathy may occur in association with pancreatitis.

### Clinical evaluation of ocular injuries

#### History

- Timing and mechanism of injury (nature of object, infection or likelihood of retained foreign body).
- Circumstance of the injury (compensation claim).
- Eye protection worn at the time of injury.
- Immediate ophthalmic treatment.

- Previous ocular surgery.
- Associated maxillofacial, neurologic, and systemic injuries.

#### Examination

- Inspection of periocular skin for puncture wounds.
- Document visual acuity and pupil responses.
- Careful inspection to identify corneal, limbal, or scleral wounds which may be small and self-sealing.
- Deep anterior chamber with very low IOP: suspect posterior rupture.
- Visualize the posterior segment.
- Need to distinguish between closed- and open-globe injuries.
- Exclude intraocular foreign body and endophthalmitis in open-globe injuries.

#### Investigations

- Document injuries with photographs (important in cases of subsequent medicolegal action).
- B-scan is useful in detecting posterior scleral rupture, retinal detachment, choroidal detachment, and intraocular foreign body when associated anterior segment pathology or vitreous haemorrhage prevents fundal visualization.
- CT scan and facial X-ray may be indicated to assess for orbital injuries and may detect an intraocular foreign body.

### Management

#### Initial management

- If endophthalmitis is suspected or present: systemic and intravitreal (during globe repair) antibiotics. Need to cover *Bacillus cereus* (25% of cases) with vancomycin.
- Intraocular foreign body: systemic antibiotics and removal of intraocular foreign body.
- Open-globe injury: examination under anaesthetic with primary repair, disinsert rectus muscles if unable to visualize posterior limit of scleral wounds. A primary enucleation or evisceration is generally avoided unless primary repair is impossible.
- Closed-globe injury: no immediate specific treatment required for choroidal rupture, sclopetaria, or macular hole. Laser retinopexy is required for new retinal tears.

#### Review

- After open-globe repair, monitor daily for any wound leak, onset of infection, or retinal detachment.
- Secondary repair if required, is usually performed 4–10 days after initial injury.
- In closed-globe injury, monitor for raised IOP, cataract, lens dislocation, and PVD-induced retinal tear.
- Delayed complications: macular pigmentary changes from commotio retinae, epiretinal membrane, retinal detachment, sympathetic ophthalmia, CNV, traumatic macular hole, non-clearing vitreous haemorrhage, siderosis, chalcosis.

### Complications

- Failure to diagnose an open-globe injury, especially when the entry wound is small or imaging is not performed in the presence of a poor fundal view.
- Missed intraocular foreign body may lead to chronic chalcosis or siderosis years later which may cause irreversible visual loss despite removal of intraocular foreign body.
- Retinal dialysis and retinal detachment: scleral buckling surgery.
- Non-clearing vitreous haemorrhage and persistent macular hole: vitrectomy. The timing of surgery is controversial.

### Prognosis

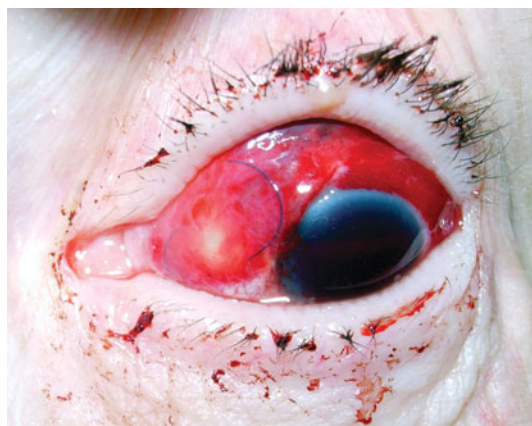- Closed-globe injury: prognosis depends upon the macular status. Poor outcome associated with choroidal rupture underlying the fovea.
- Open-globe injury: posterior limit of scleral wound determines visual outcome. High rate of proliferative vitreoretinopathy limits success of retinal detachment surgery.

**Table 3.5 Comparison between siderosis and chalcosis.**

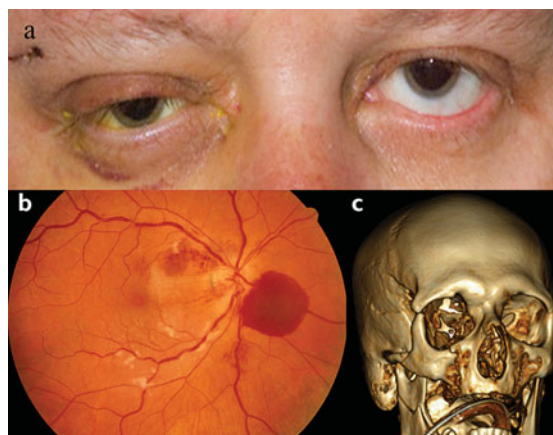Ocular features	Chalcosis	Siderosis
Acute reaction	Pan-ophthalmitis	Non-specific inflammation
Affinity for tissue	Basement membrane	Neuro-epithelial cells
Cornea	Descemet membrane deposit, Kayser–Fleischer ring	Deposit in corneal endothelium and stroma, angle damage
Iris	None	Deposit in iris stroma and epithelium causing brown iris and tonic pupil
Lens	Lenticular capsule deposit forming sun flower cataract	Deposit in lens epithelium forming yellow cataract
Vitreous	Fibrotic mass encapsulating intraocular foreign body	Metallic intraocular foreign body
Retina-RPE	Internal limiting membrane deposit	Deposit in RPE causing atrophy and visual-field loss; reduction in B-wave may be reversible

### Further reading

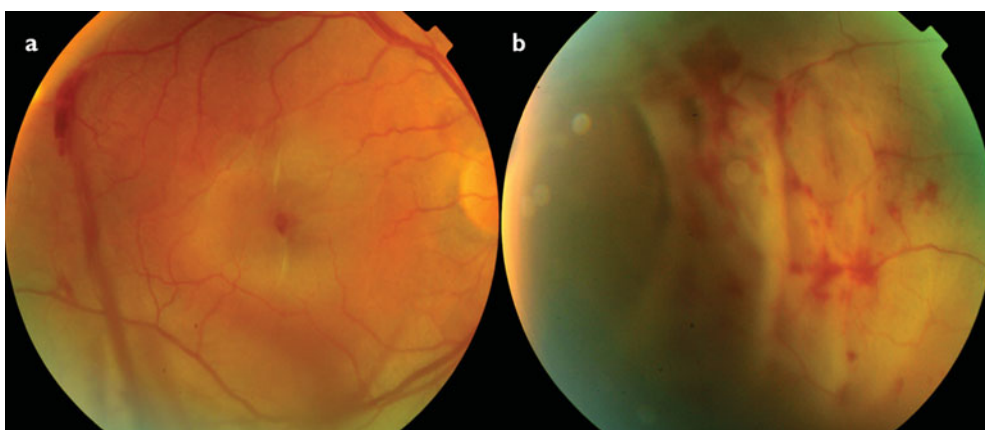
Pieramici DJ, Sternberg Jr P, Aaberg Sr TM et al. 1997. A system for classifying mechanical injuries of the eye (globe). The Ocular Trauma Classification Group. *Am. J. Ophthalmol.* **123**: 820–831.



**Fig. 3.46** Blunt ocular injury resulting in globe rupture and extrusion of IOL.



**Fig. 3.47** A 53 year-old man sustained severe head injury resulting in (a) right traumatic oculomotor nerve palsy, (b) Purtscher's retinopathy, with cotton wool spots, retinal and preretinal haemorrhages, and macular branch retinal artery occlusion, and (c) severe craniofacial fractures complicated by intracranial haemorrhage.



**Fig. 3.45** Blunt ocular injury resulting in (a) macular hole and (b) retinal detachment secondary to retinal dialysis.



## 3.20 Case-based discussions

### Case 1 Retinal detachment

A 62-year-old male presents with a 4-week history of floaters and flashing lights in the right eye, associated with a 2 week history of acute right visual loss. He sustained blunt ocular trauma to the right eye 30 years previously and underwent uncomplicated right cataract extraction and IOL implantation 2 years previously. The left eye is amblyopic. His father had bilateral retinal detachments. He is otherwise well with no history of joint disease or hearing loss.

1. What ocular and systemic risk factors would you look for in a patient presenting with a RRD?

Examination reveals best-corrected visual acuities of hand motions in the right eye, and 6/24 in the left eye. His refractive error is plano/−1.00×75 OD, and −8.00/−2.00, ×90 in the left eye. Both corneas are clear and the pupils dilate well. A well centred right IOL is present. The posterior capsule has been opened by a previous Nd:YAG laser capsulotomy. Vitreous strands and pigment cells are visible. The posterior hyaloid membrane is detached. A total retinal detachment is present with an area of focal preretinal fibrosis in the inferior mid-peripheral retina, subretinal fibrosis, and five horseshoe retinal tears distributed throughout each quadrant adjacent to areas of lattice degeneration. The retina is immobile and the edges of the retinal tears are rolled. The contralateral eye has an early cataract, PVD, and extensive lattice degeneration. A small round hole is visible inferiorly with no subretinal fluid. Scleral depression did not reveal any other break.

2. What is the mechanism of retinal detachment in this patient?
3. What poor prognostic features are present?
4. What would you tell the patient regarding the natural history of untreated retinal detachment and the likely outcome of treatment for his right eye?
5. What would you tell the patient about the natural history of the untreated round hole in his left eye and the outcome of laser treatment of the round hole and/or lattice degeneration in the left eye?

With fully informed consent, the patient underwent a right pars plana vitrectomy with removal of preretinal membranes, silicone oil tamponade, laser retinopexy of all retinal breaks, and additional 360° laser retinopexy.

6. What additional perioperative procedure could have been performed to reduce vitreous base traction in this case and what potential complications would this entail?
7. What examination features would you look for during the postoperative visit the following day?
8. How would you advise the patient to posture?

On the following day, the right cornea was clear, the IOP was 25 mmHg, and the retina was attached. Three months later, the silicone oil was removed without complication. The right visual acuity recovered to 6/24 at 6 months after the initial surgery.

9. What acute and chronic postoperative problems may arise from the presence of intraocular silicone oil?
10. What alternatives exist for intraocular tamponade and what are their limitations?
11. What advice would you give the patient before discharge?

#### Discussion

This case illustrates some of the challenges in the management of a complex retinal detachment in the better-seeing eye and the incidental finding of an asymptomatic retinal break in an amblyopic fellow eye.

1. Myopia, previous trauma, prior intraocular surgery, PVD, peripheral retinal degeneration, systemic features of Marfan and Stickler syndromes.
2. Primarily rhegmatogenous, with an element of secondary traction.
3. Macular involvement, duration, PVR, multiple breaks.
4. Untreated retinal detachment, little prospect of visual improvement, visual loss may progress to perception of light or no perception of light. Total retinal detachment can be reattached in over 80% and vision can be improved in over 50%.
5. Untreated inferior round hole in a myopic eye with PVD has a small risk of retinal detachment. Laser retinopexy may secure the inferior break but will not prevent further breaks from forming.
6. Encircling band and/or localized scleral buckle. Complications include diplopia, induced refractive error, scleral penetration, subsequent buckle exposure.
7. Intraocular pressure, extent of oil fill, anterior chamber depth and activity, presence of subretinal fluid.
8. Face down or alternating right and left cheeks down will allow tamponade of all breaks while retinopexy takes effect.
9. Acute: raised IOP, pupil block; chronic: glaucoma, adhesion to silicone IOL, band keratopathy, cataract, oil emulsification, failure to tamponade.
10. Air, gas, and perfluorocarbon liquids. Air has a short half-life. Gas provides tamponade for up to 2 months. Perfluorocarbon needs to be removed within 2 weeks and exchanged for oil or gas to provide further tamponade.
11. Education about the symptoms of a retinal detachment should be given to all patients following vitreoretinal procedures: return to casualty if any increase in floaters, new onset photopsia, or a field defect is noted.

### Case 2 Elevated fundal mass

A 50-year-old male presents with a 6 week history of central blurring in the left eye. He is fit and well and has no relevant ocular history except for a having been told that he has a 'birth mark on the back of the left eye'. He has no significant past medical history.

Examination reveals visual acuities of 6/5 right eye and 6/36 left eye. He has no significant refractive error. The pupil responses and anterior segment findings are normal. The IOP is 15 mmHg in both eyes. There are no aqueous or vitreous cells visible. An elevated, round, brown pigmented subretinal mass is present in the superior equatorial fundus. Orange pigment is seen on the surface of the lesion. There is an associated retinal detachment involving the macular and inferior retina. The subretinal fluid shifts to posterior pole when the patient is lying down. No retinal break is detected with scleral indentation.

1. What is the mechanism of retinal detachment in this patient?
2. What features suggest that this lesion has growth potential?
3. What diagnostic tests can be performed?
4. What systemic work up is required?

On further enquiry, the patient denies a history of recent weight loss or systemic malignancy. Systemic examination reveals no evidence of lymphadenopathy, hepatosplenomegaly, or any pigmented skin lesions. Investigations including a liver-function test, bilirubin levels, and a liver ultrasound are all normal. B-scan ultrasonography



demonstrates a mushroom-shaped choroidal mass with low internal reflectivity and adjacent retinal detachment. The lesion measures 5 mm in height and 10 mm in basal diameter.

5. What is the differential diagnosis?
6. Is a biopsy to provide a histopathological diagnosis warranted?
7. What are the treatment options?

One week later, the patient underwent brachytherapy with a ruthenium plaque.

8. What are the chances that the vision in the treated eye will recover to 6/12 or better?
9. What are the potential causes of subsequent visual loss in the treated eye and when are they most likely to occur?
10. What are the chances of losing the eye due to ocular recurrence after this mode of therapy?
11. What is the tumour-associated mortality rate in this case?

### Discussion

This patient's left visual acuity improved in association with resolution of the exudative retinal detachment. The ultrasound measured dimensions of the tumour decreased in size over a follow-up period of 2 years. Six-monthly liver enzyme tests and bilirubin measurements remained normal.

1. Exudative retinal detachment.
2. Visual symptoms, orange pigmentation, serous detachment, and lack of RPE change.
3. Preoperative diagnosis for choroidal melanoma is generally based on clinical appearance and ultrasound features. Histological confirmation in atypical cases can be obtained by transvitreal needle aspiration biopsy.

4. Systemic work up includes liver ultrasound and liver function blood test. Additional imaging is guided by other symptoms present.

5. Choroidal melanoma is the most likely diagnosis. The clinical features are not consistent with choroidal naevus (flat, pigmented lesion), disciform lesion (fibrotic with haemorrhage and exudate), metastatic carcinoma (flat and multiple pale lesions), and metastatic melanoma (primary tumour outside the eye present),

6. Not if the clinical features are typical.

7. Treatment options for medium-sized choroidal melanoma include brachytherapy with iodine or ruthenium plaque, proton-beam irradiation, local resection, or enucleation. Observation is not advisable in this case due to typical features.

8. Ten per cent chance of achieving and maintaining 6/12 or better after 3 years. There is however, a 40–50% chance of poor outcome (<20/200) after 3 years following brachytherapy.

9. Tumour recurrence and enucleation. Macular detachment, radiation maculopathy and optic neuropathy if globe conserved. These can occur any time after brachytherapy.

10. 10–15% after 5 years.

11. 15–20% cumulative all-cause mortality at 5 years. Almost half of these will have evidence of metastasis from choroidal melanoma at the time of death.

*This page intentionally left blank*

## Chapter 4

# Medical retina

Bheema Patil and Pankaj Puri

---

### Clinical skills

- 4.1 Fundus fluorescein angiography 146
- 4.2 Abnormal fluorescein angiography 148
- 4.3 Indocyanine green angiography 150
- 4.4 Electrophysiology 152

---

### Clinical knowledge

- 4.5 Diabetic retinopathy I 156
- 4.6 Diabetic retinopathy II 160
- 4.7 Hypertensive retinopathy 162
- 4.8 Retinal vein occlusion I 164
- 4.9 Retinal vein occlusion II 166
- 4.10 Retinal artery occlusions 168
- 4.11 Age-related macular degeneration I 170
- 4.12 Age-related macular degeneration II 172
- 4.13 Intravitreal anti-VEGF injections 176
- 4.14 Central serous chorioretinopathy 178
- 4.15 Retinal vascular anomalies 180
- 4.16 Retinal dystrophies I 182
- 4.17 Retinal dystrophies II 184
- 4.18 Choroidal dystrophies 188

---

### Case-based discussions

- 4.19 Case 1 Gradual visual loss 190
- Case 2 Central visual loss 190
- Case 3 Visual loss in a hypertensive patient 190
- Case 4 Sudden, painless visual loss 190
- Case 5 Diabetic retinopathy 191
- Case 6 Difficult night vision 191
- Case 7 Visual loss in child 191
- Case 8 Macular lesion 191

## 4.1 Fundus fluorescein angiography

### Anatomy

Fundus fluorescein angiography (FFA) is type of fundal photography performed in rapid sequence following intravenous injection of fluorescein sodium. FFA is done to image both the retinal and choroidal circulation.

### General principles

Fluorescence is the property of certain molecules to emit light energy of a longer wavelength when stimulated by light of a shorter wavelength. Fluorescein sodium is an orange, water-soluble dye that, when injected intravenously, remains largely intravascular and circulates in the bloodstream. About 70–85% of injected fluorescein binds to serum proteins (bound fluorescein) and the remainder remains unbound (free fluorescein). Choriocapillaries allow free fluorescein to pass through them (the walls of the choriocapillaries are extremely thin and contain multiple fenestrations) whereas the inner blood–retinal barrier does not allow any physiological fluorescein leakage. The excitation peak for fluorescein is 490 nm and the emission is at 530 nm.

### Purpose of the test

- To confirm diagnosis in many common diseases; for example, diabetic retinopathy, cystoid macular oedema, central serous retinopathy, AMD, and venous occlusive diseases.
- In planning laser procedures.

### Contraindications

- Known allergy to fluorescein.
- Renal impairment.

### Procedure

- Check which eye priority.
- Patient preparation:
  - explain procedure,
  - discuss risks and benefits,
  - formal consent,
  - dilate pupils,
  - check blood pressure,
  - intravenous cannulation/access,
  - make sure resuscitation trolley available,
  - seat patient comfortably and align camera,
  - ask patient to focus on fixation target in camera.
- Take colour and 'red-free' fundal photographs.
- Inject intravenous fluorescein (5 ml of 20%) rapidly; followed by saline flush through the cannula.
- Early rapid-sequence photographs (1 second intervals for 25–30 seconds).
- Less rapid sequences between 5 and 10 min.
- Late images at 10–20 minutes.

### Side effects

- Mild:
  - skin discoloration,
  - urine discoloration,
  - nausea and vomiting,
  - pruritis.
- Moderate:
  - urticaria (1:82),
  - syncope (1:340).

- Severe:
  - severe anaphylaxis (1:1900),
  - seizures (1:14,000),
  - fatal anaphylaxis (1:220,000).

### Phases of the normal angiogram

Fluorescein enters the eye through the ophthalmic artery, passing into the choroidal circulation through the short posterior ciliary arteries and into the retinal circulation through the central retinal artery. The choroidal circulation is filled 1 second earlier than the retinal circulation because of the longer route to the retinal vasculature. Angiograms should be read sequentially according to their phases, as follows.

#### Comment on the red-free photograph

Ensure that the red-free photograph is assessed prior to proceeding to comment upon the rest of the examination.

#### Choroidal (pre-arterial) phase

- Occurs 8–12 seconds after injection.
- Patchy filling of the choroid due to leakage of free fluorescein through the fenestrated choriocapillaries. A cilioretinal artery, if present ( $\approx 20\%$  of the population), will fill at this time because it is derived from the posterior ciliary circulation.

#### Arterial phase

- The retinal arteries show filling with fluorescein while the choroidal filling continues.

#### Arteriovenous (capillary) phase

- This phase shows complete filling of the arteries and capillaries with early lamellar flow in the veins (dye seen along lateral walls of veins).
- Choroidal filling continues; choroidal fluorescence increases as free fluorescein leaks from choriocapillaries.

#### Venous phase

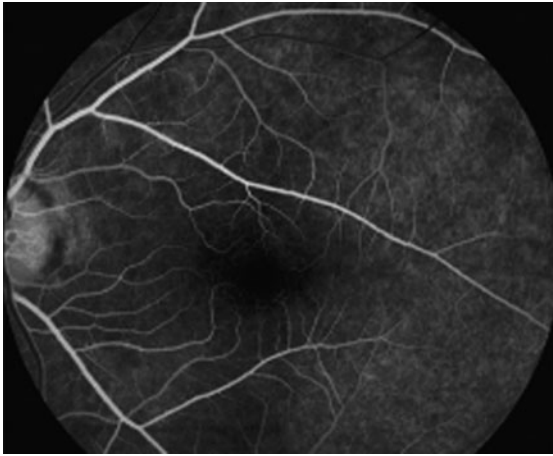
- Early venous: complete arterial and capillary filling, more marked lamellar venous flow.
- Mid venous: almost complete venous filling.
- Late venous: complete venous filling with reduced arterial concentration of dye.

#### Late (elimination) phase

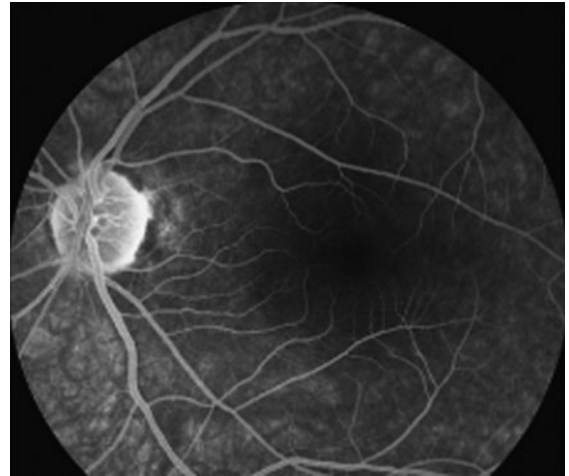
- Dilution and elimination of the dye.
- Late staining of optic disc is normal.
- Fluorescein is normally absent from the angiogram after 5–10 minutes.

#### Why is the fovea dark?

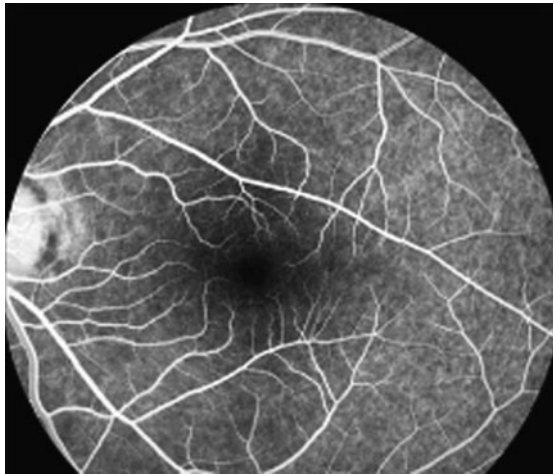
- Avascularity of the foveal avascular zone.
- Blockage of background choroidal fluorescence due to increased density of xanthophyll pigment at the fovea.
- RPE cells are larger and contain more melanin at the fovea.



**Fig. 4.1** Arterial phase of an angiogram showing filling of arterioles.



**Fig. 4.3** Late-venous phase of an angiogram.



**Fig. 4.2** Arteriovenous phase of an angiogram showing filling of arterioles and early filling of veins.



## 4.2 Abnormal fluorescein angiography

While reporting an angiogram it is important to recognize areas of abnormal fluorescence and determine whether they are hyperfluorescent or hypofluorescent.

### Hyperfluorescence

Increased fluorescence is seen as a result of pseudofluorescence, autofluorescence, RPE window defects, leakage, pooling or staining of dye.

#### Pre-injection fluorescence

- Pseudofluorescence: occurs when the blue exciter and green barrier filters overlap; the overlapping light passes through the system, reflects off highly reflective surfaces and stimulates the film; for example, scar tissues and exudates.
- Autofluorescence: emission of fluorescent light from ocular structures in the absence of fluorescein sodium; for example, optic nerve head drusen and astrocytic hamartoma.

#### Transmitted fluorescence (RPE window defect)

- RPE atrophy causes unmasking of normal background choroidal fluorescence.
- Characterized by early hyperfluorescence which increases in intensity and then fades without changing in size or shape.
- Examples: macular hole and geographic AMD.

#### Leakage of dye

- This is due to the dye leaking into the extravascular space.
- May occur from:
  - abnormal retinal or disc vasculature; for example, PDR,
  - abnormal choroidal vasculature; for example, choroidal neovascular membrane,
  - breakdown in the inner blood–retinal barrier; for example, cystoid macular oedema.
- Normally fluorescein empties almost completely from the retinal and choroidal circulations in about 10–15 minutes after injection. Any fluorescence that remains in the fundus after the retinal and the choroidal vessels have emptied of fluorescein is extravascular fluorescence and represents leakage.
- Either or both of the two vascular systems of the fundus can produce abnormal late fluorescence: there is leakage if defects are present beyond their respective barriers to fluorescein:
  - the barrier to the retinal vascular system is the endothelial cells of the retinal vessels,
  - the barrier to the choroidal circulation is the RPE.
- Characterized by hyperfluorescence that increases in intensity and size.

#### Pooling of dye

- Defined as leakage of fluorescein into a distinct anatomic space, due to breakdown of the outer blood–retinal barrier.
- Into the sub-RPE space: as in pigment epithelial detachment, it is characterized by early hyperfluorescence that increases in intensity but not in size.
- Into the subretinal space: as in CSCR, it is characterized by early hyperfluorescence that increases in both size and intensity.

#### Staining of dye

- Defined as leakage of fluorescein into tissue or material.
- Characterized by late hyperfluorescence which does not increase in size and has clear margins.
- Examples: disciform scars and drusen.

### Hypofluorescence

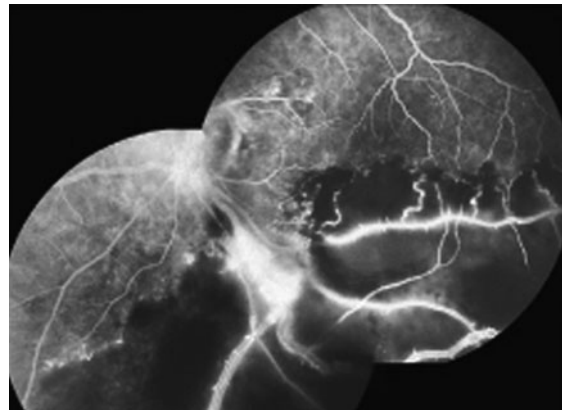
Reduction or absence of fluorescence in the angiogram may be due to blockage (masking) of a normal quantity of fluorescein or due to filling defects.

**Blocked fluorescence:** the fluorescence can be blocked by lesions at various levels in the fundus; this appears dark throughout the angiogram:

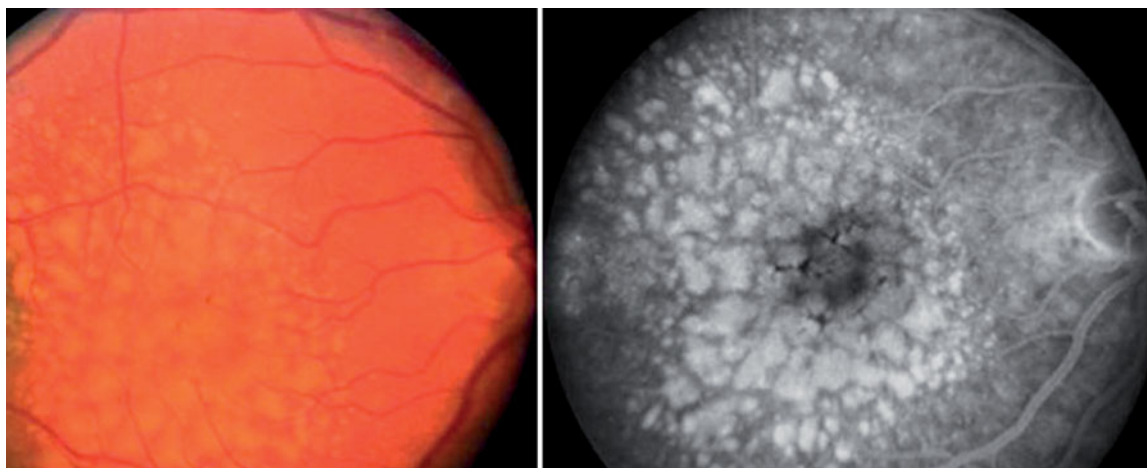
- pre-choroidal lesions: subretinal blood, pigment (choroidal naevi), lipid;
- intraretinal lesions: haemorrhages, lipid;
- preretinal lesions: media opacity, haemorrhage.

**Filling defects:** may result from:

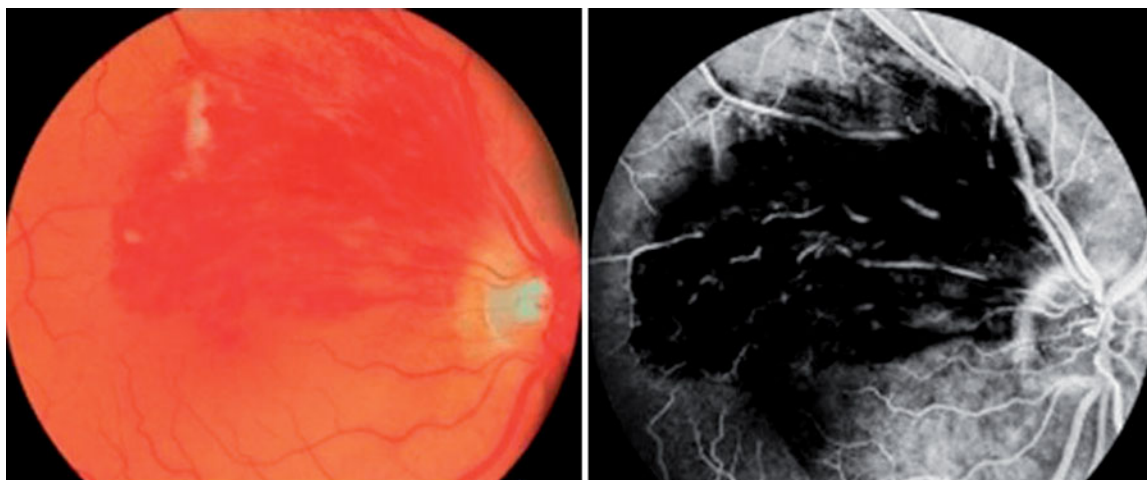
- vascular occlusion: may involve the retinal or the choroidal vasculature; for example, retinal artery occlusions, capillary drop-outs seen in diabetic retinopathy, and choroidal infarcts secondary to accelerated hypertension.



**Fig. 4.4** Angiogram showing hypofluorescence due to filling defects and hyperfluorescence due to leakage from retinal neovascularization.



**Fig. 4.5** Left: colour photograph showing drusen. Right: angiogram showing staining of drusen.



**Fig. 4.6** Left: colour photograph showing retinal haemorrhages. Right: blocked fluorescence.

## 4.3 Indocyanine green angiography

Indocyanine green (ICG) is a dye which was first used in the photographic industry. Its first use in ophthalmology was by Flower and Hochheimer in the early 1970s to image the choroidal circulation, but it was only in early 1990s that it became an established method of investigation. Fluorescence efficiency is 25 times less than FFA. ICG dye is 98% bound to proteins and as a result the amount of leakage through the fenestrated choriocapillaries is minimized, allowing an enhanced delineation of choroidal circulation.

### Technique

ICG, a tricarboyanine dye, is injected intravenously and is imaged as it passes through ocular vessels. An excitation filter with a peak at 805 nm and a barrier filter with a transmission peak of 835 nm, corresponding to the maximum fluorescence emitted by the dye in whole blood, are required. The standard technique is to slowly inject 25 mg of ICG dye in 5 ml of water. The circulating dye is rapidly excreted by the biliary system. In addition to the early photographs, late images at 5, 10, 15, and 20 minutes are taken.

### Normal angiogram

- Early phase: 1 minute after injection.
  - Dye in larger and middle-sized choroidal vessels.
  - Middle phase: 5–15 minutes after injection.
- Diffuse homogenous choroidal fluorescence.
- Late phase: after 15 minutes.
  - No details of retinal or choroidal circulation.
  - CNV is seen as a hyperfluorescent lesion in the late phase.

### Adverse reactions

- Safe and well tolerated, less common than with FFA.
- Minor (1:666): nausea, vomiting, sneezing, transient itching, discomfort, dye extravasation.
- More severe: urticaria, syncope, fainting, and pyrexia.
- Severe (1:1900): hypotensive shock and anaphylaxis.

### Contraindications

- Known allergy to the dye.
- Iodine allergy.
- Liver disease.
- Seafood allergies.
- Uraemia.
- Pregnancy.

### Main indications and features

- Patient allergic to fluorescein.
- Choroidal lesions.
- Inflammatory choroidal disorders.
- When large haemorrhagic lesions of retina preclude view of the choroid.

### *Birdshot chorioretinopathy*

Multiple hypofluorescent lesions aligned along choroidal vessels.

### *Multifocal choroiditis*

- Hypopigmented lesions in the late stages.
- Zone of peripapillary hypofluorescence.

### *Multiple evanescent white dot syndrome*

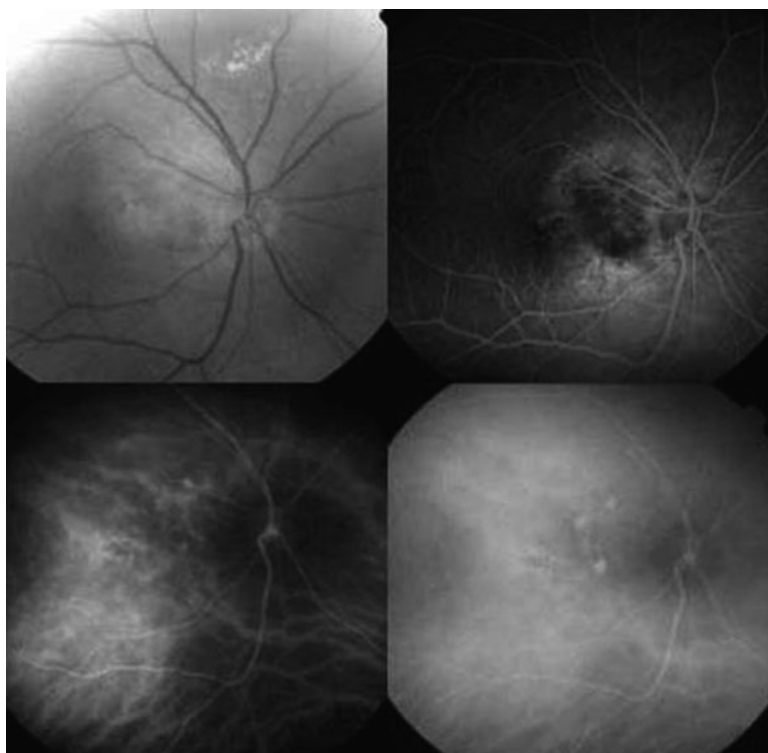
Peripapillary area with lace-like circumferential border; dots and spots configuration: small hypofluorescent spots on larger hypofluorescent areas.

### *Acute zonal occult outer retinopathy*

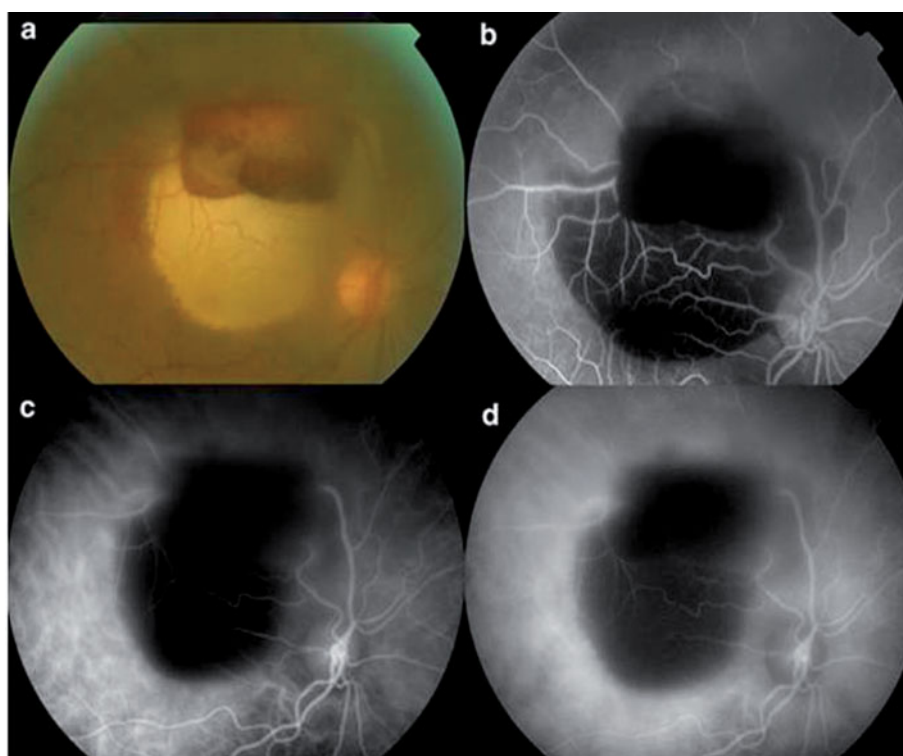
- Delineate well-demarcated zonal abnormalities.
- Multiple hypofluorescent spots.
- Serpiginous choroiditis.
- Occult satellite lesions.

### *Vogt-Koyanagi-Harada syndrome*

Exudative detachments.



**Fig. 4.7** Idiopathic choroidal polypoidal vasculopathy. Top left: red-free image showing pale lesion adjacent to disc. Top right: fluorescein angiogram shows non specific hypofluorescent lesion with non-specific hyperfluorescence. Bottom left: early ICG image showing choroidal vessels. Bottom right: late ICG image showing vascular choroidal polyps.



**Fig. 4.8** (a) Colour fundus picture on presentation showing the trilaminar submacular haemorrhage extending up to the superior arcade. (b) Fluorescein angiography showing an area of hypofluorescence corresponding to the haemorrhage. (c, d) ICG angiogram showing an area of hypofluorescence corresponding to the haemorrhage but no underlying neovascularization.

## 4.4 Electrophysiology

Electrophysiological examination of the visual system provides objective information in relation to the function of the visual pathways by measuring and documenting electrical currents, potentials, and transmissions within and from the eye.

### ERG

#### Full-field (Ganzfield) ERG

This is the mass response of the action potential produced by the retina when it is stimulated by light of an adequate intensity. The recording is made between an active electrode embedded in the contact lens placed on the patient's cornea and a reference electrode placed on the patient's forehead. The ERG is recorded in both light-adapted (photopic) and dark-adapted (scotopic) states.

#### Components of normal ERG

- Initial negative a wave: photoreceptor cell activity.
- Subsequent positive b wave: bipolar and horizontal cells.
- Final prolonged positive c wave: RPE cells.
- Electrical events within the ganglion cells or optic nerve fibres do not contribute to the ERG. Thus disorders such as glaucoma and various types of optic atrophy, which selectively affect ganglion cells or optic nerve, do not necessarily decrease the ERG response.
- Any retinal disorder which prevents generation of the normal a wave will also affect development of the b wave; for example, retinitis pigmentosa, retinal detachment, ophthalmic artery occlusion.
- Disorders that cause diffuse degeneration or dysfunction of cells in the inner nuclear layer (Müller or bipolar cells) can selectively decrease the ERG b wave without affecting the a wave; for example, CRAO.
- To reduce a and b wave amplitudes, the disorder must affect a large area of retinal tissue.

#### Standard recording protocol

Recordings should be done according to standards set by the International Society for Clinical Electrophysiology of Vision: pupil dilatation and dark-adaptation for 20 minutes.

1. Rod: very dim flash of white light or a blue light to elicit a rod response.
2. Standard combined: bright white flash to elicit the combined rod and cone response (maximal response); oscillations on the upper limb of b wave are called oscillatory potentials, which are reduced in diabetic retinopathy or vigabatrin toxicity.
3. Higher intensity: a new addition to the protocol; uses a higher-intensity stimulus which gives a better indication of how photoreceptors are working.

Light-adapted for 10 minutes.

1. Single flash cone response: a single bright light on a rod-suppressing background elicits only cone responses.
2. 30Hz flicker: this frequency of flickering light suppresses rod function further and elicits a pure cone response.

#### Interpreting ERG results

- Reduced a and b wave:
  - retinitis pigmentosa,
  - ophthalmic artery occlusion,
  - cancer- and melanoma-associated retinopathy.
- Normal a wave and reduced b wave:
  - congenital stationary night blindness,
  - X-linked juvenile retinoschisis.

- Abnormal photopic, normal scotopic ERG:
  - cone dystrophy,
  - achromatopsia.
- Reduced oscillatory potentials
  - diabetic patients with an increased risk of proliferative changes.

#### Pattern ERG

- Retinal response to a structured stimulus, such as reversing black and white chequerboard or grating covering 16° of central visual field.
- Therefore this response is generated primarily in the macular region by virtue of its stimulus placement and size.
- Allows objective evaluation of inner macular function and a direct assessment of retinal ganglion cell function.
- As it is a small response, recording is technically more difficult; the patient needs to be optimally refracted, and be able to fixate, concentrate, and relax.
- Main waveforms: P50 and N95.
- Pattern ERG is a quick way to determine the site of the visual problem; that is, whether it is inner macular dysfunction or the retinal ganglion cells. Selective reduction of P50 indicates macular dysfunction whereas a normal P50 and reduced N95 indicates retinal ganglion cells/optic nerve pathology.

#### Multifocal ERG

- Relatively new technique.
- Useful for revealing the extent central retinal dysfunction.
- Simultaneous stimulation of multiple retinal areas.
- Fast stimulation rates (75Hz) using a rapid random stimulator.
- Both eyes are tested simultaneously.
- Takes time and demanding for the patient; requires good fixation, concentration, and relaxation.
- Applications:
  - retinal dystrophies,
  - macular disease,
  - inflammatory disorders,
  - retinal toxicities,
  - trauma,
  - retinal vascular disorders.

### EOG

EOG measures the standing potential between the electrically negative back of the eye and the electrically positive cornea. It reflects the activity of the retinal pigment epithelium and the photoreceptors. Diffuse and extensive disease of the retinal pigment epithelium is needed to affect the EOG response significantly. An eye blinded by lesions proximal to the photoreceptors (e.g. optic nerve pathology) will have a normal EOG.

Example of abnormal EOG: Best's disease

#### Technique

- EOG is performed in both dark- and light-adapted states.
- Electrodes are attached to the skin near the medial and lateral canthi.
- Patient is asked to look rhythmically from side to side. Each time the eye moves the cornea makes the nearest electrode positive with respect to the other.
- The potential difference between the two electrodes is amplified and recorded.



- The data are analysed by dividing the height of the potential in the light (light peak) by the height obtained in the dark (dark peak) and expressed as the Arden ratio (percentage). The normal value is over 1.85 (185%)

## Visual-evoked potentials

Visual-evoked potential is a gross electrical response recorded from the visual cortex in response to a changing visual stimulus, such as multiple flash (flash visual-evoked potential) or chequerboard pattern (pattern-onset/-reversal visual-evoked potential) stimuli. Pattern-reversal visual-evoked potential requires good fixation and concentration by the patient. If the patient is unable to fixate properly then pattern-onset visual-evoked potential is preferred. Flash visual-evoked potential is not very commonly done nowadays but can still be useful when a patient cannot comply with a pattern visual-evoked potential test.

### Indications

- Optic nerve disease, particularly demyelination.
- Chiasmal and retrochiasmal dysfunction.
- Non-organic visual loss.

### Normal SERG

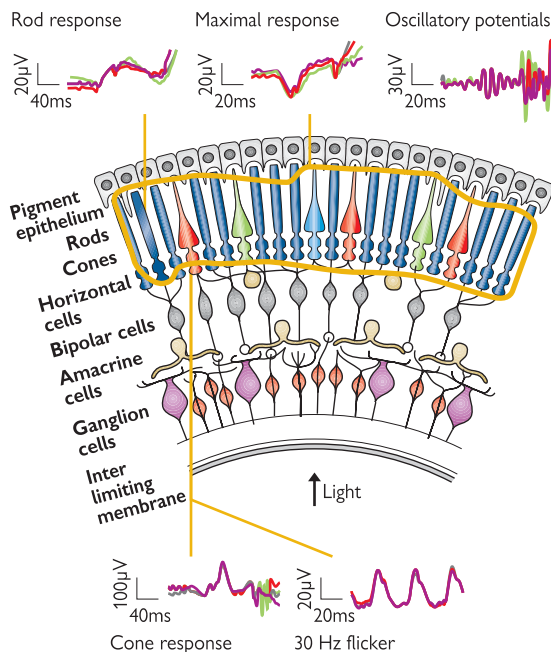


Fig. 4.9 Normal ERG showing the five components.

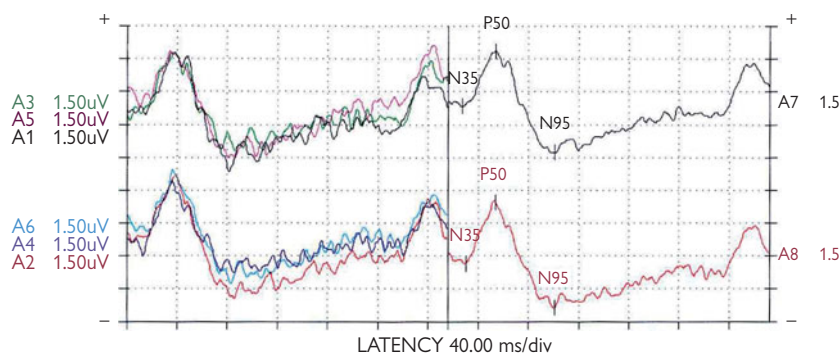


Fig. 4.10 Normal pattern ERG.

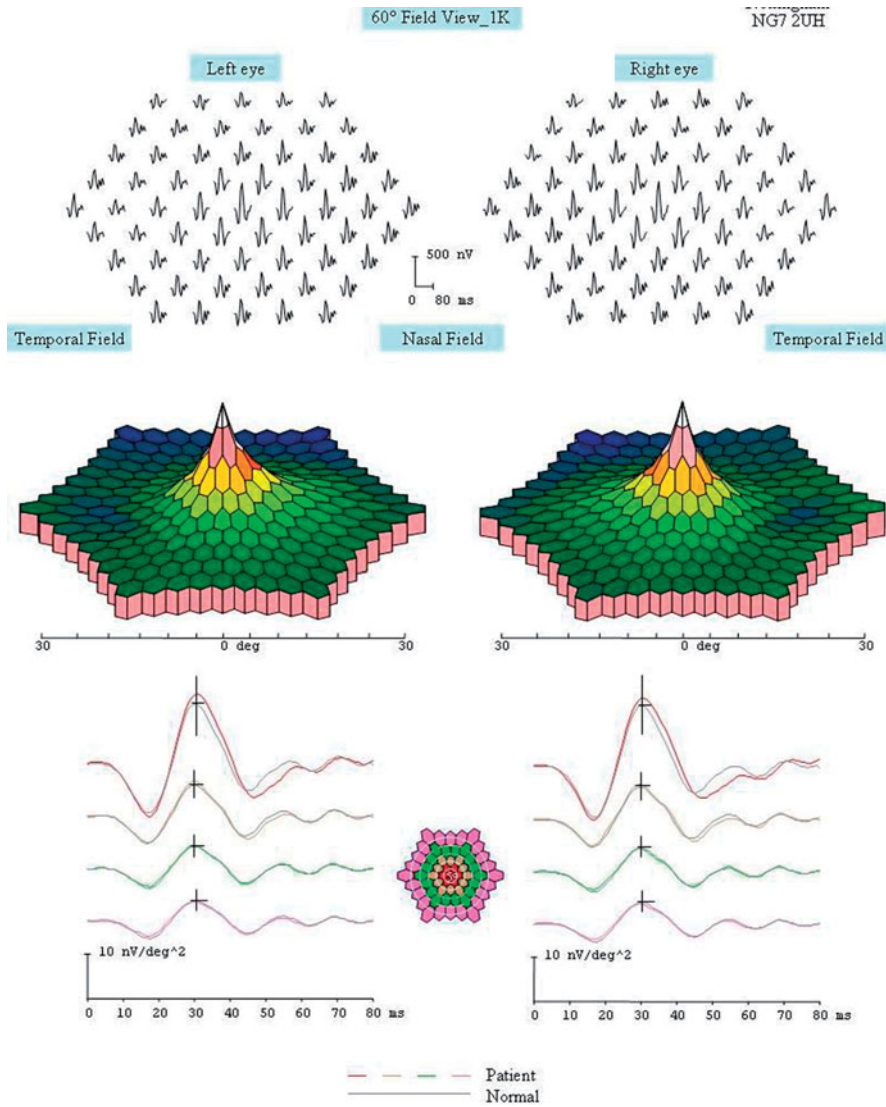


Fig. 4.11 Multifocal ERG: normal.

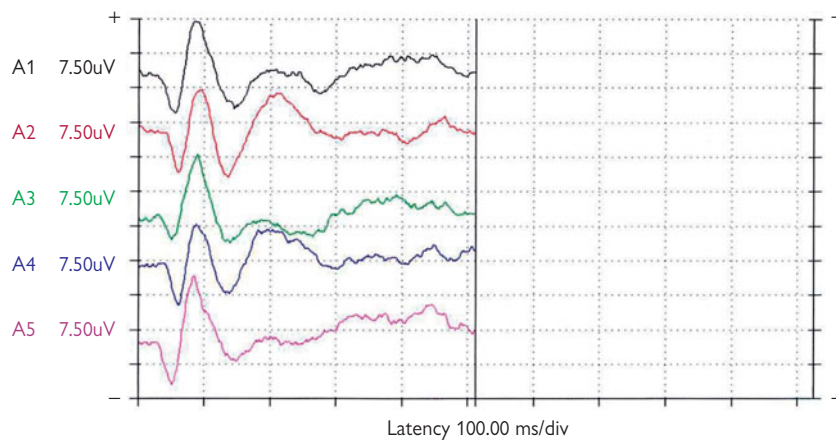


Fig. 4.12 Normal pattern-reversal visual-evoked potential.

*This page intentionally left blank*

## 4.5 Diabetic retinopathy I

Diabetes mellitus is estimated to affect 200 million people worldwide and is the commonest cause of blindness in the working population. Diabetes mellitus is divided into type 1 (insulin-dependent) and type 2 (non-insulin-dependent). Type 1 is juvenile-onset and is due to insulin deficiency, whereas type 2 is typically of adult-onset and is due to acquired insulin resistance. The best predictor of diabetic retinopathy is the duration of the disease. It is very rare to develop diabetic retinopathy before puberty.

### Prevalence of diabetic retinopathy

- Type 1: rare at diagnosis and 90% at 15 years.
- Type 2: 20% at diagnosis and 60% at 15 years.

### Risk of retinopathy

- Increased duration of diabetes.
- Poor glycaemic control is less important than the duration, but is relevant to the development and progression of retinopathy.
- Hypertension, if poorly controlled, is associated with worsening of retinopathy.
- Hypercholesterolaemia.
- Nephropathy, if severe, is associated with worsening of retinopathy.
- Pregnancy is sometimes associated with rapid progression of retinopathy.
- Obesity.

### Pathogenesis

Diabetic retinopathy is a microangiopathy primarily affecting pre-capillary arterioles, capillaries, and post-capillary venules. Features are of microvascular occlusion and leakage.

- Microvascular occlusion: loss of pericytes, thickening of basement membrane, damage to and proliferation of endothelial cells, deformation of red blood cells, and increased platelet stickiness and aggregation. This leads to occlusion with subsequent non-perfusion and hypoxia, which leads to formation of arteriovenous shunts and neovascularization.
- Microvascular leakage: this is due to breakdown of inner blood–retinal barrier leading to formation of microaneurysms, haemorrhages, exudates, and oedema.
- Microaneurysms: ischaemia causes weakening of the walls of the capillaries due to necrosis of the supporting cells (pericytes) resulting in out-pouching or blow-outs in the capillary wall, seen as white dots on FFA. With time these microaneurysms may fill with basement membrane deposits and consequently may disappear on FFA.
- Hard exudates: underperfusion of the vascular bed and damage to the endothelium of the deep capillaries leads to plasma leakage into the outer plexiform layer, clinically seen as yellow and well-circumscribed deposits. Histologically, 'hard' exudates are eosinophilic masses, and contain foamy macrophages with lipid in the cytoplasm.
- Haemorrhage: breakdown of vessel walls leads to leakage of red cells and can take several forms in the retina:
  - flame haemorrhages are in the nerve fibre layer;
  - dot haemorrhages are in the outer plexiform layer;
  - blot haemorrhages are larger than dot, and represent bleeding from capillaries with tracking between the photoreceptors and the RPE;
  - intraretinal microvascular abnormalities are new vessels growing from the venous side of the capillary bed within an area of arteriolar non-perfusion.
- Cotton-wool spots are fluffy white areas of swelling in the retina and represent microinfarctions of the nerve fibre layer.

### Stages of diabetic retinopathy

The staging of diabetic retinopathy is important in understanding its severity, in order to stratify patients who are at low/moderate/high risk of visual loss. This helps in the tailoring of appropriate management and follow-up.

#### Non-proliferative diabetic retinopathy (NPDR)

- Mild NPDR: microaneurysms only.
- Moderate NPDR: microaneurysms, dot and blot haemorrhages, hard exudates, cotton-wool spots.
- Severe: one feature of the 4-2-1 rule:
  - intraretinal haemorrhages in all four quadrants,
  - venous beading in two quadrants,
  - intraretinal vascular abnormalities in one quadrant.
- Very severe: two features of 4-2-1 rule.

#### Proliferative diabetic retinopathy (PDR)

- Low risk: neovascularization of the optic disc (NVD) less than one-quarter to one-third disc areas with no vitreous haemorrhage.
- High risk:
  - mild NVD with vitreous haemorrhage,
  - moderate to severe NVD (more than one-quarter to one-third disc areas),
  - new vessels elsewhere (NVE) more than one-half disc areas with vitreous haemorrhage.

#### Diabetic maculopathy

- Involvement of the fovea by oedema and hard exudates or ischaemia is the most common cause of visual impairment in diabetic patients; particularly those with type 2 diabetes.

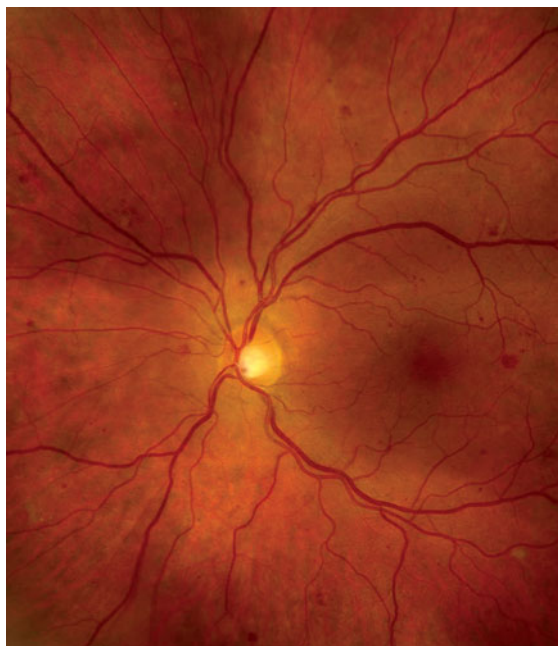
#### Classification

- Focal oedema: well-circumscribed retinal leakage associated with complete or incomplete rings of perifoveal hard exudates; FFA shows late, focal hyperfluorescence due to leakage and good macular perfusion.
- Diffuse oedema: diffuse retinal thickening with severe oedema; FFA shows widespread spotty hyperfluorescence of microaneurysms and late diffuse hyperfluorescence due to leakage.
- Ischaemic: decreased vision with relatively normal macular appearance; capillary non-perfusion at the fovea on FFA.
- Mixed: features of oedema and ischaemia at the macula.
- Clinically significant diabetic macular oedema:
  - thickening of the retina at or within 500 µm of the centre of the macula;
  - hard exudates at or within 500 µm of centre of macula; if associated with the thickening of adjacent retina (not residual hard exudates remaining after the disappearance of retinal thickening);
  - a single zone or multiple zones of retinal thickening one disc area or larger, any part of which is within one disc diameter of the centre of macula.

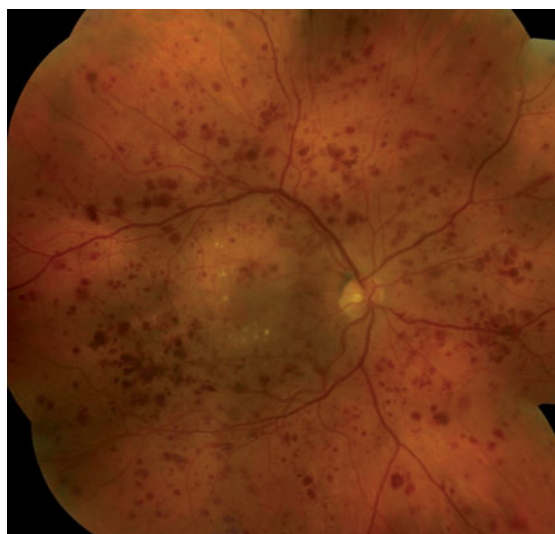### Systemic complications of diabetes mellitus

Microvascular: neuropathy, nephropathy.

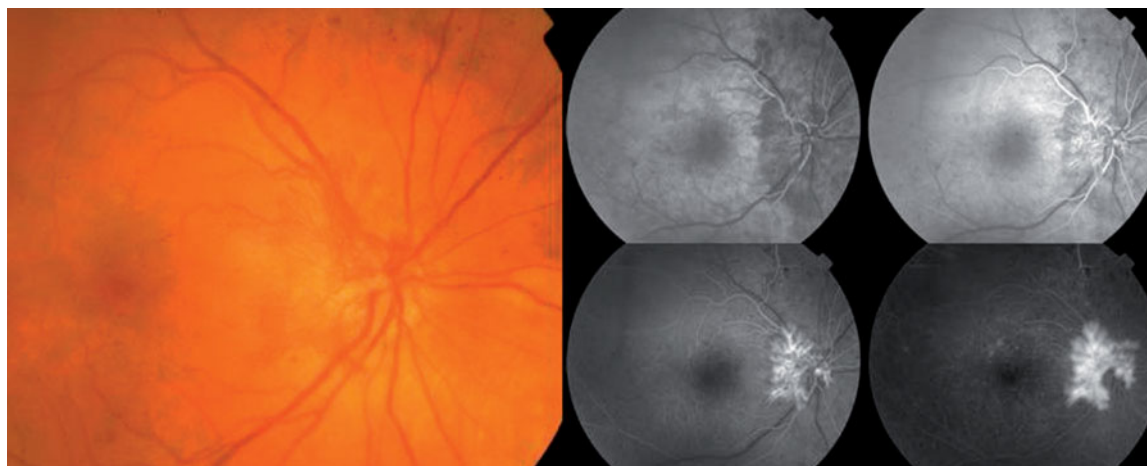
Macrovascular: stroke, myocardial infarction, peripheral vascular disease.



**Fig. 4.13** Colour fundus photograph of left eye showing microaneurysms and dot haemorrhages.

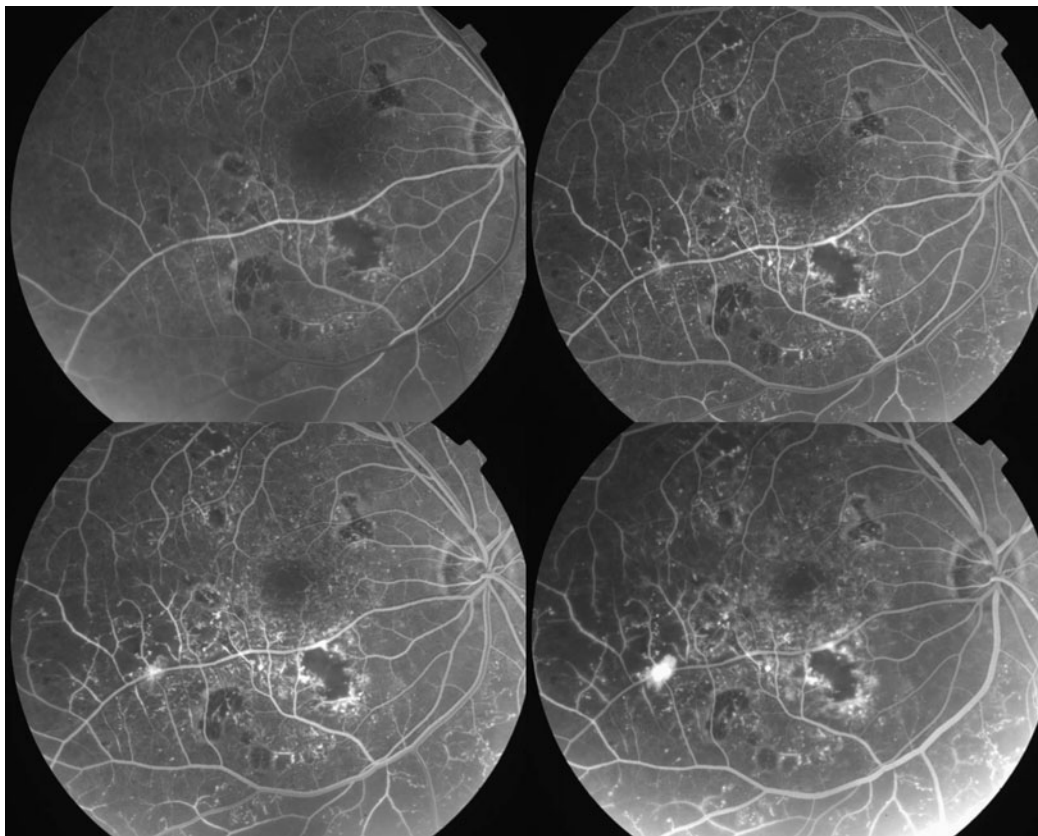


**Fig. 4.14** Colour fundus photograph of right eye showing severe NPDR.

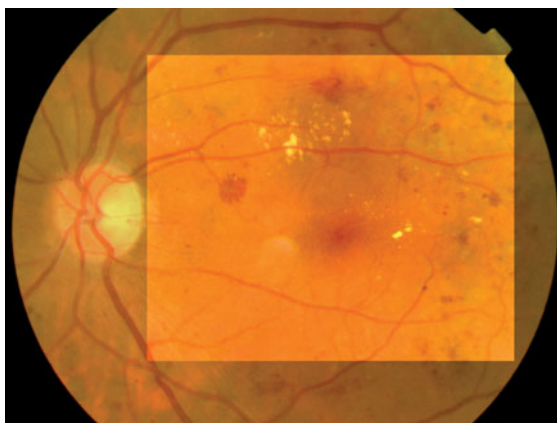


**Fig. 4.15** Left: colour fundus photograph of left eye showing new vessels on optic disc. Right: four progressive frames of FFA showing leakage from new vessels on optic disc.





**Fig. 4.16** Progressive frames of fundus fluorescein angiogram of right eye showing capillary drop-outs and leaking new vessels elsewhere (hyperfluorescence in bottom right).



**Fig. 4.17** Colour fundus photograph of left eye showing diabetic maculopathy: hard exudates and dot and blot haemorrhages.

*This page intentionally left blank*

## 4.6 Diabetic retinopathy II

### Management

An optimal diabetic care is best achieved by a multidisciplinary approach comprising primary care physician, diabetologists, nephrologists, ophthalmologists, and other specialists as needed. Patient education and self-management are critical.

#### General measures

Lifestyle changes:

- cessation of smoking,
- regular exercise, more than 30 min/day,
- weight control.

Glycaemia control:

- aim for HbA1c of 6.5–7.0%.

Blood-pressure control:

- aim for blood pressure less than 130/80 mmHg, or 125/75 mmHg in patients with proteinuria.

Cholesterol control:

- aim for lipid reduction if risk of coronary heart disease,
- a statin is the drug of choice.

Support renal function:

- angiotensin-converting enzyme (ACE) inhibitors preferred,
- microalbuminuria is indicative of early nephropathy.

#### Ophthalmic management

##### Retinopathy

- No retinopathy: discharge to community screening service for annual review/
- Mild NPDR: discharge to community screening service for annual review or 9–12 month hospital review if severe systemic disease.
- Moderate NPDR: review at 6 months, disease progression is common; one study on type 1 diabetics showed 16% progression to PDR in 4 years; laser treatment and FFA are not indicated in this group.
- Severe NPDR: review at 4 monthly intervals as risk of progression to PDR is high; 50% will develop early PDR and 15% high-risk PDR in 1 year.
- Very severe NPDR: review at 3 monthly intervals as 75% will develop PDR and 45% high-risk PDR in 1 year.
- Early Treatment Diabetic Retinopathy Study (ETDRS) suggested no laser treatment for mild to moderate NPDR; consider laser photocoagulation for severe or very severe NPDR if follow-up cannot be maintained; and definite pan-retinal photocoagulation (PRP) for high-risk PDR.
- High-risk PDR:
  - PRP divided in two or more sessions: 2000–3000 burns in a scatter pattern, extending from the posterior fundus to cover the peripheral retina;
  - argon green laser, adjust power and duration to get pale white burn;
  - review 4–6 weeks later.
- Regressed PDR: review 4–6 monthly.

##### Maculopathy

- Patients with clinically significant diabetic macular oedema should be considered for laser treatment (ETDRS). Appropriate macular laser photocoagulation reduces the risk of moderate visual loss by more than 50% when compared with no treatment at all. The goal of treatment is to stabilize vision, although vision improves in a minority of patients. Macular oedema, which is not clinically significant, should be closely monitored for progression. OCT can be useful in diagnosis and monitoring of macular oedema.

##### Focal leakage

- Focal argon laser photocoagulation to centre of leakage or to individual microaneurysms.
- 50–100  $\mu$ m spot size  $\times$  0.05–0.1 seconds; adjust power to achieve mild blanching.
- Review 3–4 monthly.

##### Diffuse leakage

- Grid argon laser photocoagulation to areas of diffuse retinal thickening located more than 500  $\mu$ m from centre of fovea.
- 100–200  $\mu$ m spot size  $\times$  0.1 seconds; adjust power.
- Review in 3–4 months.

##### Ischaemic

- FFA to confirm diagnosis.
- Laser photocoagulation is not indicated.

##### Persistent maculopathy

- Consider intravitreal triamcinolone 4 mg.
- May need to be repeated.
- Watch IOP.

##### Resolved maculopathy

- Watch 4–6 monthly.

##### Rubeosis (iris neovascularization)

- With clear media: urgent PRP.
- With vitreous haemorrhage: vitrectomy plus endolaser.
- Rubeotic glaucoma: urgent PRP with or without procedures to decrease IOP.
- There are early reports of the use of anti-VEGF agents in rubeotic glaucoma.

##### Vitreous haemorrhage

- Adequate view of fundus: PRP.
- No view of fundus: repeated ultrasounds to ensure no retinal detachment.
- Persistent (1 month in type 1 and 3–6 months in type 2 diabetics): consider vitrectomy plus endolaser.

##### Pars plana vitrectomy: indications

- Persistent vitreous haemorrhage (1 month in type 1 and 3–6 months in type 2 diabetics).
- Tractional retinal detachment threatening or involving macular.
- Combined tractional and rhegmatogenous retinal detachment.
- Premacular subhyaloid haemorrhage.
- Aggressive NVE.
- Uncontrolled PDR in spite of full PRP.
- Refractory diabetic macular oedema.

##### Intravitreal anti-VEGF

There are some early reports (no randomized controlled trials) on the use of intravitreal anti-VEGF agents for diabetic maculopathy and PDR. Data are limited and the agents are currently not licensed for such treatment. Early anecdotal evidence appears to be encouraging. The three agents used are:

- Macugen (Pegaptanib),
- Lucentis (Ranibizumab),
- Avastin (Bevacizumab).

#### Complications of laser photocoagulation

##### PRP

Pain and discomfort, loss of peripheral visual field, with possible loss of driving licence, temporary worsening of central vision, decreased contrast sensitivity, decreased night vision, loss of colour vision, vitreous haemorrhage.

**Macular/focal laser**

Extension of laser scar under fovea, inadvertent laser injury to fovea, small paracentral scotoma.

**Trials in diabetic retinopathy****DCCT: Diabetes Control and Complication Trial**

- Purpose: to determine whether intensive blood glucose control (versus a standard control) slows the progression of diabetic eye, kidney, and nerve disease in type 1 diabetics.
- Conclusions: in type 1 diabetics tight control (HbA1c 7.2 versus 9.0%) was associated with a 76% reduction in retinopathy, 60% reduction in neuropathy, and 54% reduction in nephropathy.

**UKPDS: United Kingdom Prospective Diabetic Study**

- Purpose:
  1. to determine whether intensive blood glucose control reduced the risk of complications in type 2 diabetes;
  2. to determine whether tight blood-pressure control reduced the risk of complications in type 2 diabetes.
- Conclusions in type 2 diabetics:
  1. tight glycemic control (HbA1c 7 versus 7.9%) reduces the risk of major diabetic eye disease by a quarter and early kidney damage by a third;
  2. tight blood pressure control reduces the risk of strokes, serious visual loss, and death from long-term complications of diabetes by a third.

**DRS: Diabetic Retinopathy Study**

- Purpose: to determine whether photocoagulation helps prevent severe visual loss from PDR and also to determine whether there was any difference in the efficacy and safety of argon versus xenon photocoagulation for PDR.
- Conclusion: in patients with high-risk PDR both argon and xenon laser photocoagulation reduced the risk of severe visual loss by more than 50%.

**ETDRS: Early Treatment Diabetic Retinopathy Study**

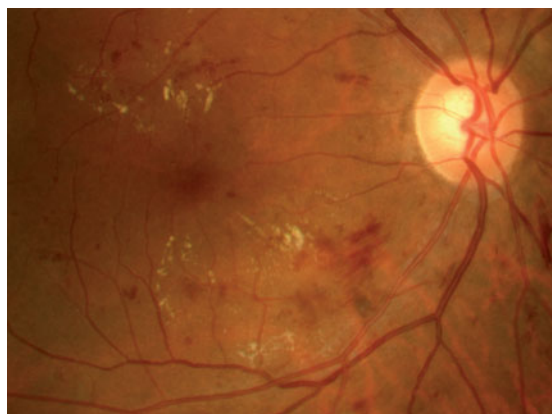
- Purpose:
  1. Is photocoagulation beneficial for diabetic macular oedema?
  2. When in the course of the disease is the best time to begin photocoagulation for diabetic retinopathy?
  3. Does aspirin treatment alter the progress of diabetic retinopathy?
- Conclusions:
  1. focal photocoagulation for macular oedema reduces the risk of moderate visual loss and should be considered for eyes with clinically significant macular oedema;
  2. scatter photocoagulation reduces the risk of severe visual loss. Provided adequate follow-up can be managed, it is safe to defer scatter photocoagulation until retinopathy reaches the high-risk stage;
  3. aspirin (650 mg/day) has no significant effect on diabetic retinopathy progression.

**DRVS: Diabetic Retinopathy Vitrectomy Study**

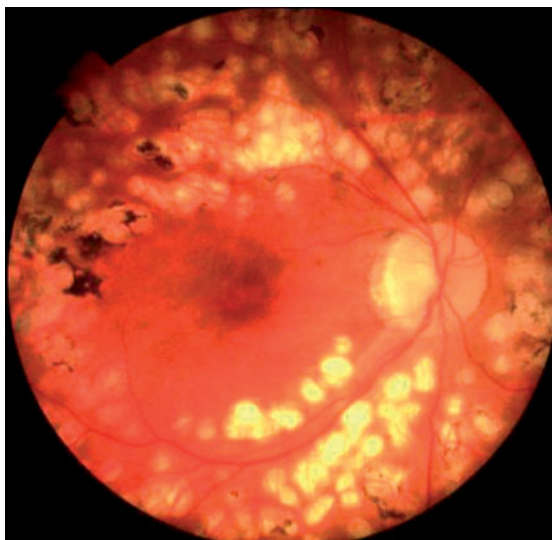
Purpose: to compare early vitrectomy with conventional management (vitrectomy if vitreous haemorrhage fails to clear in 6–12 months) of recent severe vitreous haemorrhage secondary to diabetic retinopathy.

Conclusions:

- early vitrectomy group did better (visual acuity 6/12 or better) than conventional group (25 versus 15%);
- the advantage of early vitrectomy was greater in type 1 diabetics (36 versus 12%);
- at 4 year follow-up conclusions were largely the same.



**Fig. 4.18** Colour fundus photograph of right eye showing diabetic maculopathy: hard exudates and dot haemorrhages.



**Fig. 4.19** Colour fundus photograph of right eye showing pan retinal photocoagulation laser treatment done for PDR.

## 4.7 Hypertensive retinopathy

Systemic hypertension is the leading cause of morbidity and mortality worldwide. It affects 60% of people over 60 years old in the Western world. Hypertensive retinopathy represents the ophthalmic findings of end-organ damage secondary to systemic arterial hypertension.

### Risk factors

- Increasing age.
- Gender (males > females).
- Ethnicity (blacks > whites).
- Society (industrialized > agricultural).

### Types

- Chronic 'essential' hypertension represents the majority; it causes both sclerosis and narrowing of retinal as well as choroidal arterioles.
- Acute or 'accelerated'/'malignant' hypertension accounts for about 1% of cases; it causes fibrinoid necrosis of arterioles and accelerated end-organ damage.

### Essential hypertension

- Unknown cause.
- Diagnosed when blood pressure over 140 mmHg systolic and/or over 90 mmHg diastolic on two or more occasions.

### Systemic features

- Usually asymptomatic.
- End-organ damage: cardiovascular, cerebrovascular, renal, peripheral vascular.

### Ophthalmic features

- Narrowing of arterioles.
- Arteriovenous crossing changes (nipping).
- Flame haemorrhages.
- Cotton-wool spots: small areas of yellowish-white coloration in the retina, which occur due to localized nerve fibre layer infarcts.
- Complications: retinal vein occlusions, macroaneurysms, non-arteritic anterior ischaemic optic neuropathy, retinal artery occlusions.

### Investigations and treatment

- Liaise with physicians for monitoring and lowering of blood pressure.
- Lifestyle changes:
  - cessation of smoking,
  - exercise,
  - weight control.

### Accelerated or malignant hypertension

#### Systemic features

- Severe raised blood pressure (>220 mmHg systolic or >120 mmHg diastolic).
- Headache.
- End-organ damage: myocardial infarction, stroke, encephalopathy, cardiac failure, renal failure.

#### Ophthalmic

- Dimness in vision, double vision, photopsia.
- Retinopathy:
  - focal arteriolar narrowing,
  - cotton-wool spots,
  - hard exudates,

- macular oedema,
- retinal haemorrhages: flame-shaped.
- Choroidopathy:
  - Elschnig's spots: punctate, tan-white lesions that leak on fluorescein and ICG; necrosis and atrophy of RPE due to focal occlusion of choriocapillaries;
  - Siegrist's streaks: linear pigmentation along the choroidal arteries;
  - serous retinal detachments;
  - hypertensive optic neuropathy: disc swelling with or without macular oedema.

### Investigations and treatment

This condition is a medical emergency; refer to medical team for admission and cautious lowering of blood pressure.

## Classifications

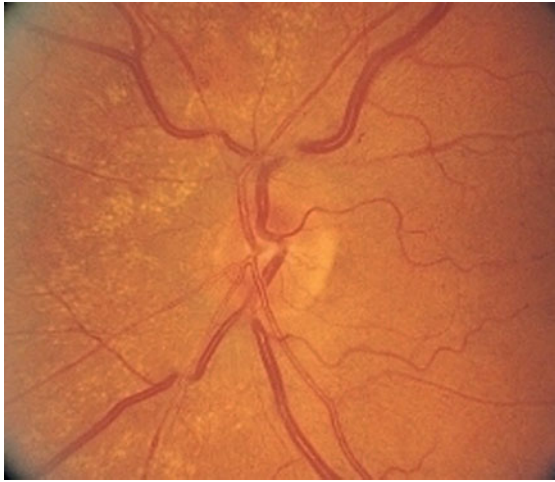
**Table 4.1 Keith–Wagner–Barker classification: combines findings of arteriosclerosis and hypertension**

Grade 1	Mild to moderate arteriolar narrowing
Grade 2	Moderate to severe arteriolar narrowing; exaggerated light reflex; arteriovenous crossing changes
Grade 3	Retinal arteriolar narrowing and focal constriction Retinal oedema Retinal haemorrhage Cotton-wool spots
Grade 4	All the above with papilloedema

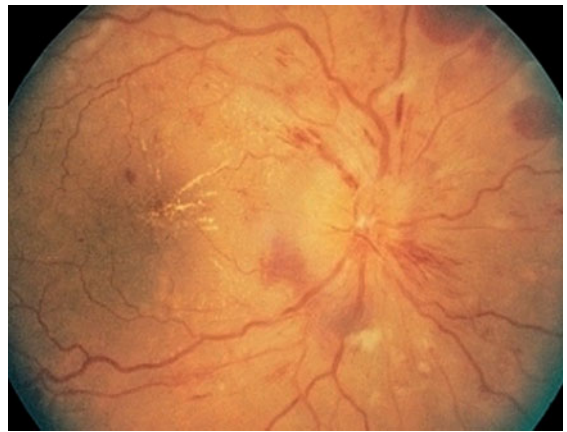**Table 4.2 Scheie classification: keeps findings of arteriosclerosis and hypertension separate**

Hypertension	
Grade 0	No changes
Grade 1	Minimal arteriolar narrowing
Grade 2	Obvious arteriolar narrowing with focal irregularities
Grade 3	Arteriolar narrowing with retinal haemorrhages and exudates
Grade 4	Above with papilloedema
Arteriosclerosis	
Grade 0	No changes
Grade 1	Minimal light reflex changes
Grade 2	Increased light reflex
Grade 3	Copper-wire arterioles
Grade 4	Silver wire arterioles

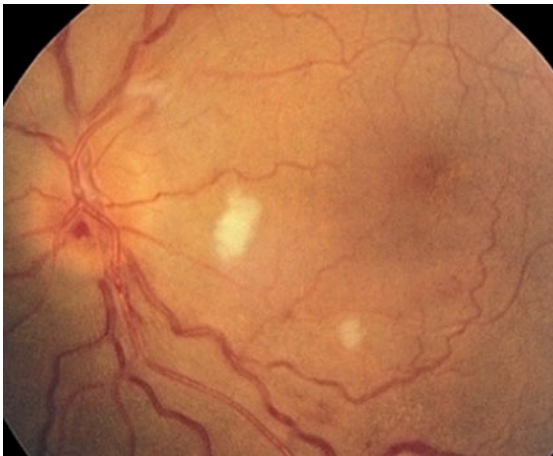




**Fig. 4.20** Colour photograph showing arteriolar narrowing and arteriovenous crossing changes.



**Fig. 4.22** Colour photograph showing arteriolar narrowing, cotton-wool spots, blot haemorrhages, macular star; and optic disc swelling.



**Fig. 4.21** Colour photograph showing cotton-wool spots.

## 4.8 Retinal vein occlusion I

Retinal vein occlusions are relatively common, second only to diabetic retinopathy in incidence. They occur at any age, but typically affect patients older than 50 years.

### Classification

Retinal venous obstructions are classified according to whether the central retinal vein or one of its branches is obstructed. Central retinal vein and branch retinal vein occlusion can differ with respect to pathophysiology, underlying systemic associations, clinical course and therapy.

- Central retinal vein occlusion (CRVO):
  - non-ischæmic CRVO,
  - ischaemic CRVO.
- Branch retinal vein occlusion (BRVO).
- Hemispheric retinal vein occlusion.

### Central retinal vein occlusion

CRVO is found most commonly in individuals over 50 years old. Diabetes mellitus, systemic hypertension, and atherosclerotic cardiovascular disease are the most common systemic associations. Completely normal medical and laboratory findings are found in about a quarter of patients with CRVO. Patients with primary open-angle glaucoma (POAG) are five times more likely to sustain a CRVO than those who do not.

The pathogenesis of CRVO remains obscure, but the obstruction is believed to be due to a thrombus in the central retinal vein. Arteriosclerosis of the neighbouring central retinal artery causing turbulent venous flow and endothelial cell damage is often thought to be the underlying pathology. The retinal venous circulation is a relatively high-resistance, low-flow system; thus it is particularly sensitive to haematological factors.

CRVO is divided into non-ischæmic and ischaemic variants. This division is important because nearly two-thirds of those who have an ischaemic CRVO develop complications such as iris neovascularization and neovascular glaucoma.

#### Non-ischæmic CRVO

- More common (75–80% of all CRVOs).
- Painless, mild to moderate decrease in vision (usually better than 6/60), intermittent blurring or transient visual obscuration.
- Normal pupil or mild afferent pupillary defect.
- Variable number of retinal haemorrhages present in all four quadrants, engorgement and tortuosity of retinal veins, mild optic nerve head swelling, few cotton-wool spots, and/or macular oedema.
- Most retinal findings may resolve in 6–12 months.
- Neovascularization of anterior or posterior segment is rare in true non-ischæmic CRVO (<2% incidence).
- The Central Retinal Vein Occlusion Study noted a conversion rate of 34% of non-ischæmic CRVO to ischaemic CRVO within 3 years.
- Recovery to normal vision is seen in fewer than 10% of cases.

#### Ischaemic CRVO

- Less common (20–25% of all CRVOs).
- Acute, marked, painless decrease in vision (usually <6/60).
- Prominent relative afferent pupillary defect (RAPD).
- Extensive retinal haemorrhages in all four quadrants, most notably at posterior pole; widespread cotton-wool spots (>10 is significant); rarely, breakthrough vitreous haemorrhage; serous retinal detachment; massive lipid exudation; severe macular oedema; oedematous optic disc.

- Progression to rubeosis (iris neovascularization) is high: 37% by 4 months (so-called 100 day glaucoma).

#### Associations of CRVO

##### Atherosclerotic

- Hypertension.
- Diabetes mellitus.
- Raised cholesterol.
- Smoking.

##### Inflammatory conditions

- Sarcoidosis.
- Behcet's disease.
- Systemic lupus erythematosus.
- Polyarteritis nodosa.

##### Blood dyscrasias

- Protein S deficiency.
- Protein C deficiency.
- Antithrombin deficiency.
- Antiphospholipid syndrome.
- Hyperhomocysteinaemia.
- Multiple myeloma.

##### Ophthalmic

- POAG.
- Orbital pathology.

#### Investigations

- Check blood pressure.
- Full blood count (FBC), erythrocyte sedimentation rate (ESR), glucose, lipid profile, urea and electrolytes, thyroid function tests, protein electrophoresis, electrocardiogram.
- Further investigation may be directed by clinical indications.
- FFA: to determine extent of capillary non-perfusion if in doubt.
- OCT: for objective diagnosis and monitoring of macular oedema.

#### Treatment

- Lifestyle changes: cessation of smoking, control of systemic and ocular risk factors.
- Lower IOP if raised.
- Watch non-ischæmic CRVO for ischaemic transformation.
- Close observation of ischaemic CRVO: look for evidence of rubeosis (gonioscopy essential to look for new angle vessels) and dilated funduscopy.

#### Central Retinal Vein Occlusion Study

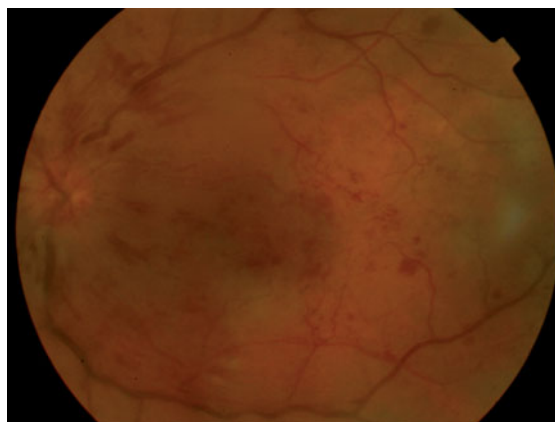
- Purpose:
  1. to determine whether photocoagulation therapy can help prevent iris neovascularization in eyes with CRVO and evidence of ischaemic retina;
  2. to assess whether macular grid laser photocoagulation will reduce loss of central visual loss due to macular oedema secondary to CRVO.
- Conclusions:
  1. prophylactic PRP for ischaemic CRVO (10 or more disc areas of retinal capillary non-perfusion on FFA) did not prevent the development of iris neovascularization. This demonstrates that it is safe to wait for the development of early iris neovascularization and then apply PRP;
  2. macular grid photocoagulation was effective in reducing angiographic evidence of macular oedema but did not improve visual acuity in eyes with reduced vision due to macular oedema from CRVO.

### Newer treatments

- There are numerous studies/reports showing intravitreal triamcinolone to be effective in reducing macular oedema and improving visual acuity, but the effect is transient and repeat injections may be necessary. Also, the risk of glaucoma is significant.
- Anti-VEGF bevacizumab injected intravitreally: there are few reports to show its effectiveness in reducing macular oedema and improving visual acuity. The follow-up is short. No randomized controlled trials are available to date.
- Others: isovolemic haemodilution, radial optic neurotomy, laser chorioretinal anastomosis: no definite proven efficacy.

### Complications

- Chronic macular oedema.
- Neovascular glaucoma.
- Blind, painful, or pthysical eye.



**Fig. 4.23** Colour photograph showing retinal haemorrhages in all four quadrants: CRVO.

## 4.9 Retinal vein occlusion II

### Branch retinal vein occlusion

Branch retinal vein occlusion (BRVO) is a common retinal vascular disorder of the elderly, which occurs when one of the branches of the central retinal vein is obstructed. It is three times more common than CRVO. Men and women seem to be equally affected with a usual age of onset between 60 and 70 years. BRVO almost always occurs at arteriovenous crossings, where the artery and vein share a common adventitial sheath. It is postulated that the rigid artery compresses the retinal vein, which results in turbulent flow and endothelial damage, followed by thrombosis and obstruction of the retinal vein. BRVO is superotemporal in more than 60% of cases, supposedly due to the increased number of arteriovenous crossings in that quadrant. Hypertension is the most common association of BRVO.

#### Clinical evaluation

##### History

- May be asymptomatic, dependent upon location of occlusion; variable decrease in vision; distortion; visual field defect/positive scotoma.

##### Examination

- Acute stage (in the affected quadrant): dot, blot, or flame-shaped retinal haemorrhages; dilated and tortuous veins with retinal oedema; cotton-wool spots; with or without macular oedema.
- Chronic: venous sheathing, retinal exudation, pigment disturbance, collateral vessel formation, with or without macular oedema. The fundus may eventually look normal.

##### Investigations

- As for CRVO (may not be necessary in all cases).
- FFA: at 3 months if vision is less than 6/12 or if uncertain of diagnosis.
- OCT: for objective detection and monitoring of macular oedema when clinically subtle.

#### Branch Vein Occlusion Study

- Purpose:
  1. Can macular argon laser photocoagulation improve visual acuity in eyes with macular oedema reducing vision to 6/12 or worse?
  2. Can peripheral scatter argon laser photocoagulation prevent the development of retinal neovascularization?
  3. Can peripheral scatter argon laser photocoagulation prevent vitreous haemorrhage?
- Conclusions:
  1. macular grid laser photocoagulation is effective for macular oedema and improves visual acuity in eyes with visual acuity of 6/12–6/60;
  2. scatter laser photocoagulation could prevent the development of both neovascularization and vitreous haemorrhage to a significant degree. The data accumulated suggested that peripheral scatter laser be applied after, rather than before, the development of neovascularization.

#### Treatment

##### General

- Lifestyle changes: smoking, exercise, weight control.
- Blood-pressure control.

##### Ophthalmic

- Macular oedema persisting after 3–4 months with visual acuity less than 6/12 (confirm with FFA and rule out macular non-perfusion).
- Macular grid laser: as per Branch Vein Occlusion Study.
- Retinal neovascularization: sector PRP (as per Branch Vein Occlusion Study).
- Persistent vitreous haemorrhage: vitrectomy plus endolaser.

##### Newer treatments

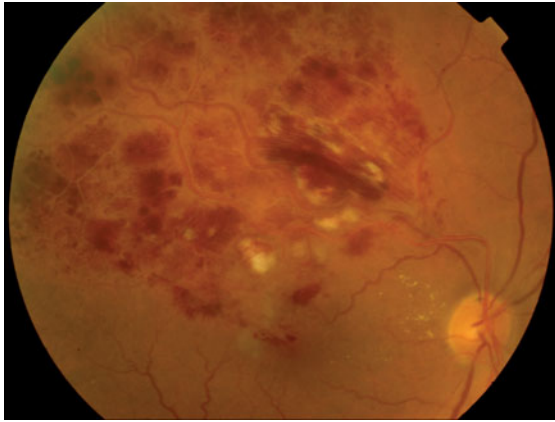
- Intravitreal triamcinolone: reports suggest that it reduces macular oedema and improves visual acuity, but the effect is transient and repeat injections may be required; glaucoma is a significant problem.
- Intravitreal anti-VEGF: early reports look encouraging in reducing macular oedema and improving visual acuity.
- Arteriovenous sheathotomy: no definite efficacy is noted; some reports suggest better visual outcomes with early surgical intervention.

##### Prognosis

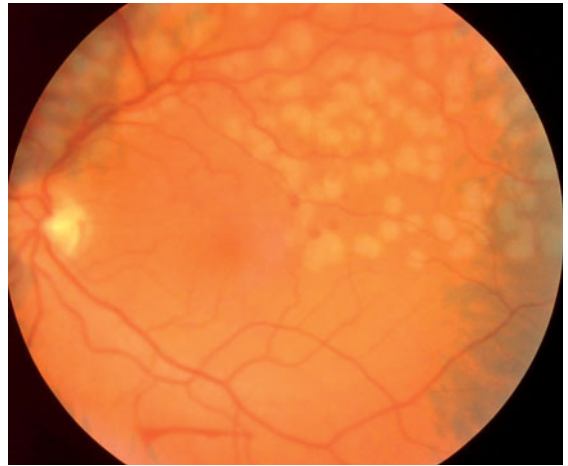
- In BRVO overall 50–60% of cases retain a visual acuity of 6/12 or better in 1 year.
- Rubeosis in 1% of BRVO cases.

### Hemispheric retinal vein occlusion

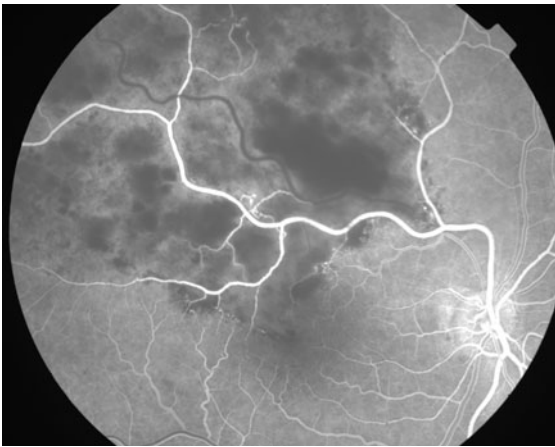These are generally regarded as a variant of CRVO. They can also be of ischaemic and non-ischaemic variety and the risk and treatment is intermediate between CRVO and BRVO.



**Fig. 4.24** Colour photograph showing retinal haemorrhages in the superotemporal quadrant in BRVO.



**Fig. 4.26** Colour photograph showing sector PRP for retinal neovascularization in BRVO.



**Fig. 4.25** Fluorescein angiogram showing blocked hypofluorescence with capillary shut down.



## 4.10 Retinal artery occlusions

Retinal artery obstructions are divided into central and branch depending on the site of obstruction.

### Central retinal artery occlusion

Central retinal artery occlusion (CRAO) is an abrupt reduction in the blood flow through the central retinal artery severe enough to cause ischaemia of the inner retina (the outer retina receives its blood supply from the choriocapillaries). The most common site of obstruction of the central retinal artery is behind the lamina cribrosa; thus the precise site of the occlusion is generally not visible on ophthalmoscopy. Men are more commonly affected than women. The mean age at onset is 60 years and bilateral involvement occurs in a small percentage (1–2%). CRAO is more often due to thrombosis (atherosclerosis) within the central retinal artery, while embolic causes (carotid artery disease) constitute around a third of cases of CRAO. In younger patients, the likely causes are migraine, trauma, and coagulation disorders. Experiments have shown that the critical period after which irreversible damage occurs is 90–100 minutes.

#### Causes

##### *Atherosclerotic*

- Hypertension.
- Diabetes mellitus.
- Smoking.
- Raised serum cholesterol.

##### *Embolic sources*

- Carotid artery disease.
- Aortic artery disease.
- Cardiac valve vegetations.
- Cardiac tumours.

##### *Haematological*

- Protein S and protein C deficiency.
- Antiphospholipid syndrome.
- Lymphoma, leukaemia.

##### *Inflammatory*

- Giant cell arteritis (GCA).
- Polyarteritis nodosa.
- Systemic lupus erythematosus.
- Wegener's granulomatosis.

##### *Infective*

- Syphilis.
- Toxoplasmosis.

##### *Medications*

- Oral contraceptive pills.

##### *Other causes*

- Trauma.
- Migraine.
- Optic disc drusen.

### Clinical evaluation

#### *History*

- Abrupt painless loss of vision.
- Amaurosis fugax precedes loss of vision in 10% of patients.
- Ask for symptoms of GCA: temple tenderness, jaw claudication, muscle weakness, fever.

#### *Examination*

- Typically visual acuity 6/240 or worse.
- Swollen white retina with cherry red spot, arteriolar attenuation, 'box-carring' of both arteries and veins.

- A patent cilioretinal artery results in a small area of retina that appears normal with or without preserved central vision.
- 4–6 weeks after obstruction, retinal whitening usually resolves, optic disc develops pallor, and arterial collaterals may form on the optic disc.

#### *Investigations*

- Urgent priority is to rule out GCA:
  - raised ESR, C-reactive protein (CRP), plasma viscosity;
  - temporal artery biopsy.
- Other investigations when indicated, for example:
  - blood tests: FBC, blood sugar, lipid profile (for atherosclerosis); clotting screen, antiphospholipid antibodies; serum protein electrophoresis (for coagulopathies);
  - carotid ultrasound imaging to evaluate atherosclerosis;
  - cardiac investigation: electrocardiogram, echocardiogram.

#### *Treatment*

- Decrease IOP with intravenous acetazolamide 500 mg with or without anterior chamber paracentesis.
- Ocular massage: for at least 15 minutes, intermittent direct pressure for 5–15 seconds per minute.
- Treat underlying GCA urgently.

#### *Complications*

- Neovascular glaucoma (18%).
- Optic atrophy.

#### *Prognosis*

- 35% of cases achieve 6/60 or better; 20% achieve 6/12 or better.

### Branch retinal artery occlusion

Branch retinal artery occlusion (BRAO) is defined as an abrupt reduction of blood flow through a branch of the central artery severe enough to cause ischaemia of the inner retina in the territory of the affected vessel. It is less common than CRAO. Overall, men are more commonly affected than women. The right eye is affected more commonly (60%) than the left eye and the temporal circulation is more often affected than nasal. Most BRAOs are due to emboli and three main types have been identified clinically:

- cholesterol (Hollenhorst plaque): small, yellow-orange, refractile, does not always result in blockage, typically arises from atheromatous carotid plaques;
- fibrinoplatelet: long, smooth, white, intraretinal plugs that may be mobile or break up in time, usually seen with cardiac and carotid thrombosis;
- calcific: solid, white, non-refractile plugs associated with calcification of heart valves or the aorta.

#### *Clinical features*

##### *History and examination*

- Sudden, painless, unilateral altitudinal field defect.
- White swollen retina in the area of the arterial supply; branch arteriolar attenuation with cattle tracking; visible emboli in over 60% of cases.

##### *Investigations*

- Usually a clinical diagnosis,
- Identify underlying cause (as for CRAO).

##### *Treatment*

- There is no proven treatment for BRAO.
- Try ocular massage or paracentesis.

### Prognosis

- 80% recover to 6/12 or better.
- Retinal new vessels rare; rubeosis does not occur.

### Ophthalmic artery occlusion

This is characterized by acute, simultaneous occlusion of retinal and choroidal circulations. This can be differentiated clinically from CRAO by the following features:

- severe visual loss, bare or no light perception;
- intense ischaemic retinal whitening extending beyond macular area;
- little to no cherry red spot;
- marked choroidal perfusion defects on FFA;
- non-recordable ERG;
- late RPE alterations.

### Cilioretinal artery occlusion

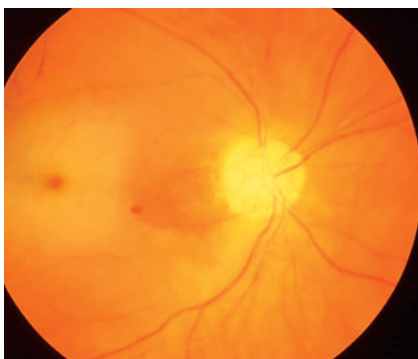
A cilioretinal artery exists in about 30% of individuals and arises directly from posterior ciliary circulation and not from the central retinal artery. Obstruction exists in three clinical situations:

- isolated, at a young age, associated with systemic vasculitis, good prognosis;
- with CRVO, at a young age, prognosis like non-ischaemic CRVO;
- with anterior ischaemic optic neuropathy (AION), in elderly patients, usually associated with GCA; poor prognosis.

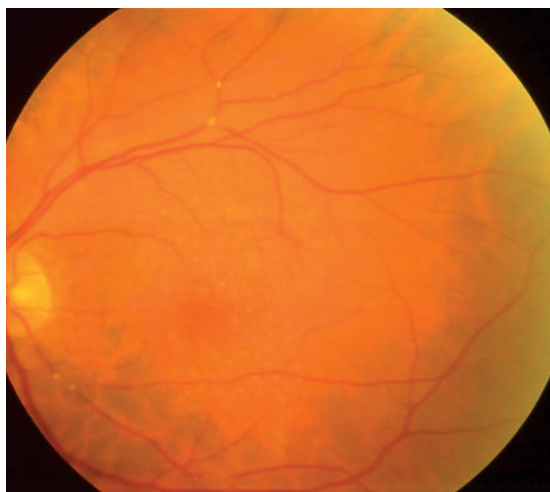
### Ocular ischaemic syndrome

This occurs as a result of chronic ocular hypoperfusion secondary to severe carotid artery obstruction (atherosclerosis).

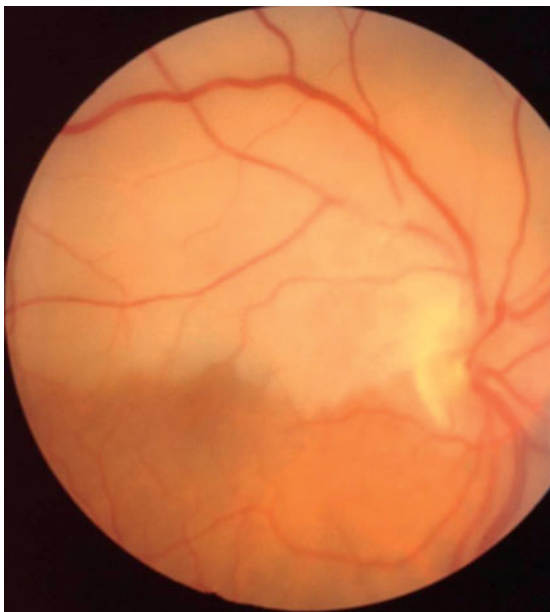- Mean age of onset 65 years; men > women.
- Unilateral in 80% of cases.
- 5% of patients who have haemodynamically significant carotid artery disease develop ocular ischaemic syndrome.
- Variable loss of vision; dull ache on eye or brow ('ocular angina'), corneal striae and oedema, neovascular glaucoma, anterior chamber flare and cells, anterior uveitis, retinal arterial narrowing, venous dilatation without tortuosity, retinal hemorrhages, microaneurysms, NVD/NVE, cherry red spot, cotton-wool spots, ischaemic optic neuropathy.
- FFA: delay with a well-demarcated leading edge of fluorescein in retinal artery.



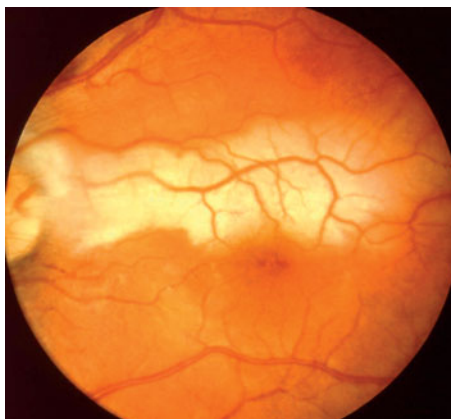**Fig. 4.27** Colour photograph showing 'cherry-red spot' with pale retina (oedema) in CRAO.



**Fig. 4.28** Colour photograph showing arterial emboli.



**Fig. 4.29** Colour photograph showing pale, oedematous superior retina in BRAO.



**Fig. 4.30** Colour photograph showing cilioretinal artery occlusion.

## 4.11 Age-related macular degeneration I

Age-related macular degeneration (AMD) may cause severe visual loss and is the most common cause of blindness in persons more than 50 years old in the Western world. It is a degenerative process limited to the macula. The prevalence of AMD in Caucasians aged 40 years and above in Europe, North America, and Australia has been estimated at 1.5% (95% confidence interval, 1.4–1.6%).

Two main forms of AMD occur: dry and wet.

### Risk factors

- Increasing age is the main risk factor for AMD. 0.2% of women and 0.3% of men have AMD at ages 50–54 compared with 1.5% of women and 2.0% of men in the 70–74 year age group.
- Gender (female > male): many prevalence studies show a higher prevalence in women. However, this can be attributed to increased longevity in females
- Tobacco smoking is the main modifiable risk factor. Current smokers have a 2–3-fold-increased risk of developing AMD and there is a dose–response relationship with pack-years of smoking.
- Cardiovascular disease: raised blood pressure has been associated with AMD in some but not all studies. Some studies have found inflammatory markers (CRP) to be associated with AMD. Genetic factors also point to a possible inflammatory role in AMD with complement factor H gene implicated in the pathogenesis of AMD. HMG-CoA (3-hydroxy-3-methylglutaryl-CoA) reductase inhibitors (statins) protect against cardiovascular disease by reducing dyslipaemia, but there is inconsistent evidence for association between statins and AMD.
- Alcohol intake has damaging oxidative effects on many organs of the body. Observed associations between alcohol consumption and AMD have been weak or no association has been seen.
- Hypermetropia has been suggested as a risk factor. Positive findings in cross-sectional studies have not been confirmed by the results of larger population-based prospective studies.

### Dry (non-neovascular) AMD

Dry AMD accounts for 90% of AMD.

#### Pathogenesis

- Loss of RPE/photoreceptors.
- Thinning of the outer plexiform layer.
- Thickening of the Bruch's membrane.
- Atrophy of choriocapillaries.

#### Clinical evaluation

##### History

- Gradual onset decreasing central vision.
- Inability to read and recognize faces.
- Central scotoma.

##### Examination

- Drusen: yellow, round spots predominantly found in the central macula. Asymptomatic patients in the early stages of AMD have evidence of drusen. They represent an abnormal thickening of the inner aspect of Bruch's membrane. Hard drusen (less than 63 µm and well-defined) do not appear to increase with age and do not appear to predispose an eye to advanced AMD. Soft drusen (greater than 63 µm with ill-defined borders of variable size and shape) often increase in size and number with increasing age. Soft drusen are a hallmark of AMD and their presence is a significant risk factor for the development of advanced AMD.

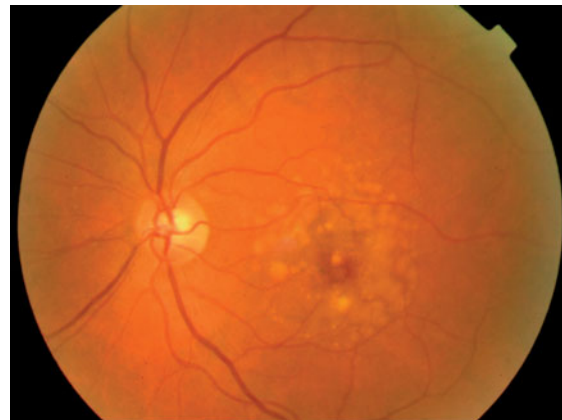- Focal hyperpigmentation: represents clumps of pigmented cells at the level of the retinal pigment epithelium. The presence of focal hyperpigmentation, as well as a history of systemic hypertension, is additional risk factor for development of neovascular AMD.
- Geographic atrophy: late stages of dry AMD, areas of RPE atrophy.

#### Investigation

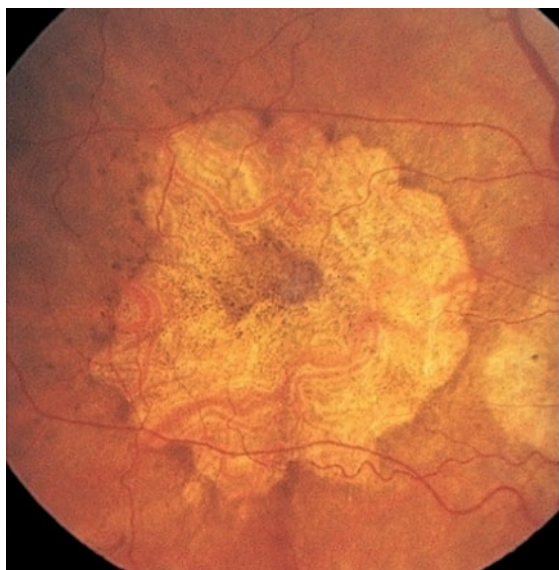- FFA is usually not necessary unless there is doubt about the presence of a choroidal neovascular membrane.

#### Treatment

- Supportive:
  - counselling.
  - linking to support groups/social services.
- Amsler grid: regular use allows the patient to detect new or progressive distortion in vision, prompting urgent ophthalmic review.
- Lifestyle changes:
  - cessation of smoking,
  - vitamin supplementation (Age-related Eye Disease Study, see below).
- Low visual assessment and aids.
- Registration:
  - sight-impaired,
  - severely sight-impaired.



**Fig. 4.31** Colour fundus photograph of the left macula showing the typical appearance of soft drusen.



**Fig. 4.32** Colour fundus photograph of right eye showing a large area of geographical atrophy at the macula.

### ⊕ Amsler grid

Amsler grid testing subjectively evaluates central  $10^\circ$  of the visual field surrounding fixation and is useful both for screening and monitoring macular disease. These are a series of charts, each consisting of a 10 cm square. Chart 1 is suitable for most patients. It consists of a  $20 \times 20$  grid of 5 mm squares, each representing  $1^\circ$  of central field (viewed at 33 cm).

### Procedure

- View at 33 cm (reading distance) and with reading glasses.
- Ask the patient to occlude one eye and fixate on the central dot and comment on whether any of the small squares are missing or distorted. Chart 2 helps those who find it difficult to fixate.

**Table 4.3** Amsler charts

Chart	Design	Use
1	Standard grid White on black	Most of patients
2	Grid with diagonals White on black	Diagonal lines aid in fixation in patients unable to see central dot
3	Standard grid Red on black	Red squares helpful in detecting colour desaturation in optic nerve lesions
4	Random dots White on black	Tests scotoma only
5	Horizontal lines White on black	Detect metamorphopsia in specific meridian
6	Horizontal lines Black on white	Similar to chart 5 but has white background and central lines are closer

## 4.12 Age-related macular degeneration II

### Wet (neovascular) AMD

Wet macular degeneration is less common than dry and accounts for 10–15% of all AMD. It tends to develop quickly and is also known as neovascular AMD. It is characterized by choroidal neovascularization (CNV), an ingrowth of permeable and fragile new vessels from the choroid into the retinal pigment epithelial and subretinal spaces. It is thought to be stimulated by the pathological secretion of VEGF. These vessels can bleed, eventually causing macular scarring resulting in profound loss of central vision (disciform scars). In the UK, CNV causes severe visual impairment or blindness in around 3.5% of people aged 75 or more.

#### Clinical evaluation

##### History

- Usually sudden-onset, with a rapid decrease in central vision.
- Metamorphopsia (distorted vision).
- Central scotoma.

##### Examination

- Grey or yellow-green plaque-like membrane.
- Retinal, subretinal, or sub-RPE haemorrhage.
- Subretinal fluid.
- Macular oedema.
- Retinal or subretinal lipid exudates.
- Retinal pigment epithelial detachment.
- RPE tear.
- Subretinal fibrosis or disciform scar.
- Associated features of non-neovascular AMD.

##### Investigations

- Urgent FFA: vital for diagnosis and assessment for treatment, identifying type of CNV, and monitoring progress.
- OCT: detects macular oedema, subretinal fluid, pigment epithelial detachment.
- ICG: useful for identifying feeder vessels and subclassifying occult CNV. Also assists in diagnosis of idiopathic polypoidal choroidal vasculopathy and retinal angiomatous proliferation.
- Features/types of choroidal neovascular membrane (CNV) based on position:
  - extrafoveal: lesion located 200–2500  $\mu\text{m}$  from centre of foveal avascular zone as per the Macular Photocoagulation Study (see below);
  - juxtafoveal: lesion located 1–199  $\mu\text{m}$  from centre of foveal avascular zone as per the Macular Photocoagulation Study;
  - subfoveal: lesion located under the fovea.
- Based on type:
  - classic: early well-demarcated lacy hyperfluorescence with progressive leakage in mid and late frames which obscures the boundaries of the lesion;
  - predominantly classic: an area of classic CNV occupying >50% of the total area of the lesion at baseline;
  - minimally classic: an area of classic CNV occupying less than 50% but more 0% of the area of the entire lesion at baseline;
  - occult: no classic CNV.

There are two types of occult CNV:

1. Fibrovascular pigment epithelial detachment (PED): PED with CNV;
2. late leakage of indeterminate origin: poorly demarcated boundaries, fluorescein leakage from undetermined source in the late phase of the angiogram.

#### Treatment

- Laser/PDT/anti-VEGF injections—see below.

#### Supportive

- Counselling.
- Linking to support groups/social services.
- Low-visual assessment and aids.
- Blind registration (Certificate of Visual Impairment, CVI).
- Lifestyle changes: cessation of smoking, vitamin supplementation.

#### Age-related Eye Disease Study

- Purpose:
  1. to evaluate the effect of high doses of antioxidants and zinc on the progression of AMD and cataract;
  2. to learn more about the natural history and risk factors of AMD and cataract.
- Conclusions: high levels of antioxidants and zinc significantly reduced the risk of advanced AMD and its associated vision loss, but had no significant effect on the development or progression of cataract.

#### Laser Photocoagulation/Macular Photocoagulation Study

- Purpose: to evaluate laser treatment of CNV secondary to AMD, presumed ocular histoplasmosis syndrome and idiopathic CNV, through three sets of randomized controlled trials, as follows.
  - Argon study: Argon laser for extrafoveal CNV (200–2500  $\mu\text{m}$  from centre of foveal avascular zone).
  - Krypton study: Krypton laser for juxtafoveal CNV (1–199  $\mu\text{m}$  from centre of foveal avascular zone).
  - Foveal study: laser photocoagulation for subfoveal CNV.
- Results: the Argon study saw dramatically reduced severe visual acuity loss, and patients were discharged after 5 years of follow-up. The Krypton study showed beneficial effect in eyes with AMD.
- Guidelines: eyes with well-demarcated, classic, extrafoveal or juxtafoveal CNV, due to AMD, ocular histoplasmosis or idiopathic CNV, have better visual prognosis when treated with laser photocoagulation, performed according to Macular Photocoagulation Study guidelines, than when managed by observation. Eyes with large subfoveal neovascular lesions and good initial visual acuity are not good candidates for focal laser.

### Verteporfin PDT

Before the year 2000, treatment for neovascular AMD was limited to laser photocoagulation based on the Macular Photocoagulation Study. PDT with verteporfin (introduced in 2000) was the first treatment proven to reduce risk of visual loss in subfoveal CNV. However, its efficacy was limited to classic or small CNV and it failed to improve vision in clinical trials.

#### Indications for use

- Classic with no occult subfoveal CNV.
- Predominantly classic CNV.
- Small occult CNV (fewer than four disc areas) with evidence of recent disease progression.

#### Mechanism of action

- Verteporfin is a photo-activated dye which binds to the lipoproteins and becomes concentrated in the proliferating vascular bed of the CNV.
- Activated by laser light of 689 nm for 83 seconds.



- Forms free-radical singlet oxygen.
- Causes local endothelial cell death and occlusion of blood supply to CNV.

### Procedure

- Infuse dye for 10 minutes+5 minutes accumulation phase.
- Calculate spot size: it is equal to greatest linear diameter+1000  $\mu$ m.
- Activate laser.
- Follow-up: review with FFA at 12 weeks.
- Side-effects:
  - injection-site reactions: inflammation, leakage, hypersensitivity,
  - back pain: 2%,
  - transient visual disturbance,
  - significant visual loss: 4%.

### Contraindications

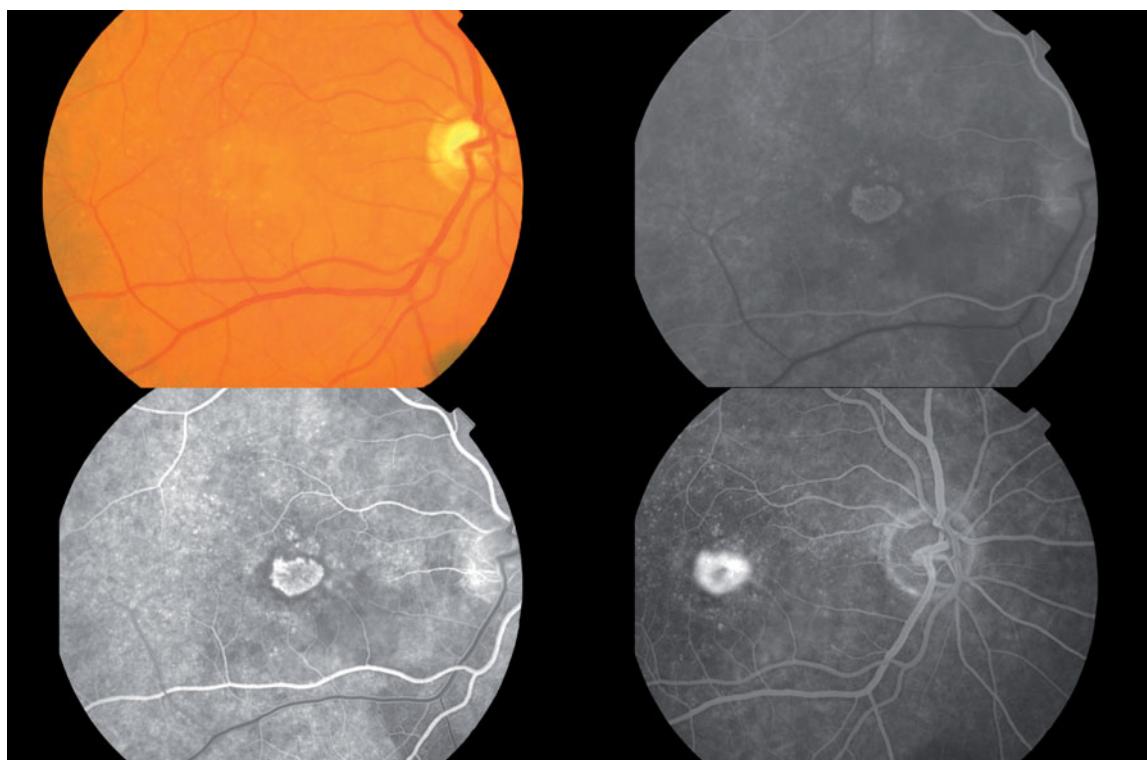
- Porphyria.
- Liver failure.

### Patient advice regarding PDT after procedure

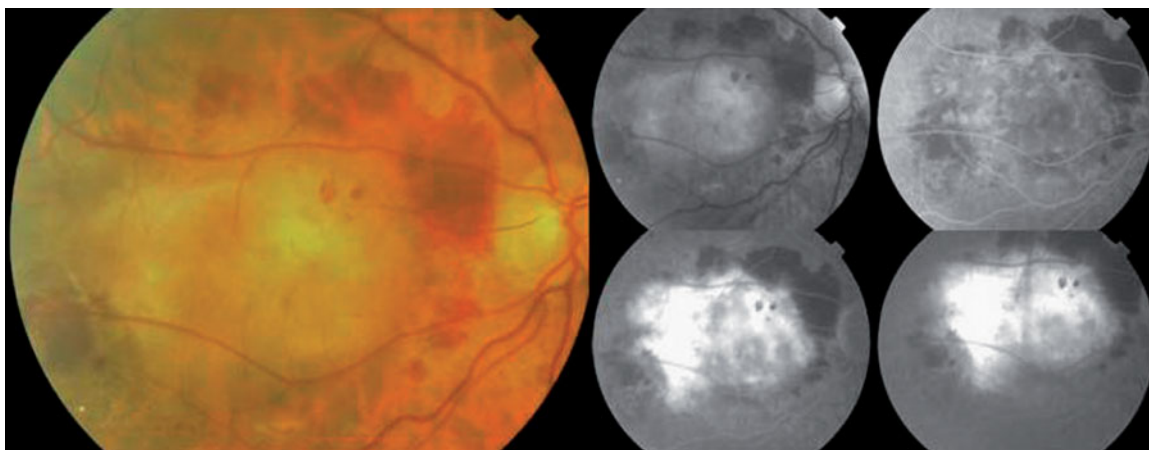
- Avoid direct sunlight for 48 hours.
- Hat, sunglasses, long sleeves, and trousers.

### Treatment of AMD with Photodynamic Therapy (TAP study)

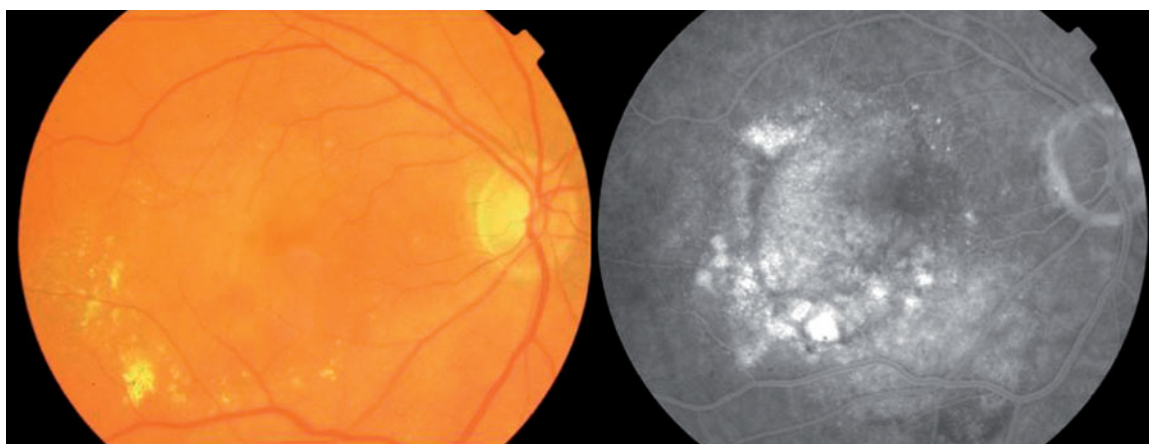
- Purpose: to study the effect of verteporfin PDT on subfoveal CNV in AMD.
- Results: for predominantly classic lesions moderate visual loss (<15 letters lost) was prevented in 67% of treated patients compared with 39% in untreated group at 12 months and in 59% (treated) compared with 31% (untreated) at 24 months.



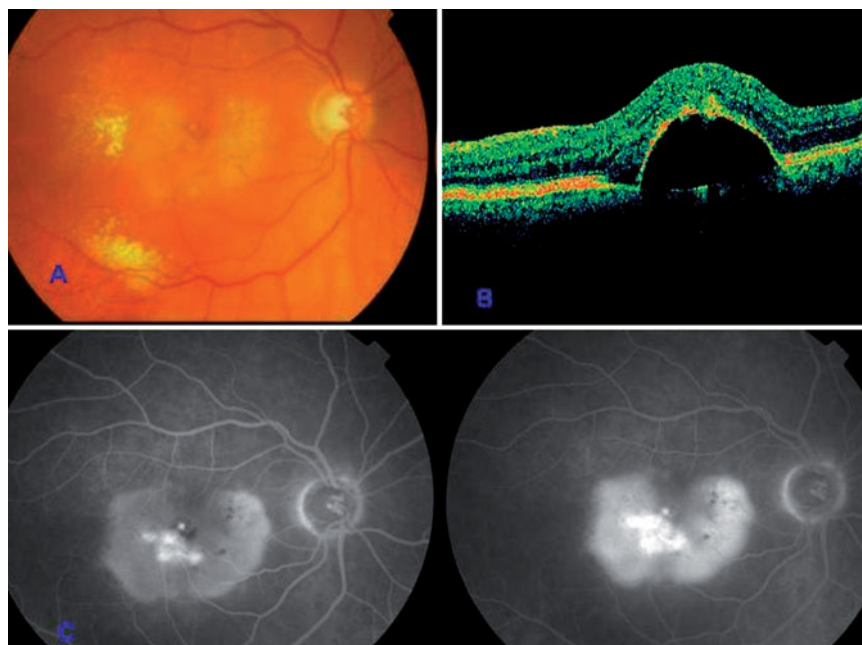
**Fig. 4.33** Colour fundus photograph showing haemorrhagic lesion in right fovea. Three progressive frames of FFA showing early well-localized hyperfluorescence with late leakage: classic CNV.



**Fig. 4.34** Left: colour fundus photograph showing large, elevated, grey lesion with haemorrhage. Right: four frames of FFA showing occult CNV.



**Fig. 4.35** Colour photograph showing a large macular elevated lesion with exudation. FFA shows late stippled hyperfluorescence: occult CNV.



**Fig. 4.36** Colour fundus photograph, OCT image and FFA of fibrovascular PED: occult CNV.

*This page intentionally left blank*

## 4.13 Intravitreal anti-VEGF injections

Vascular endothelial growth factor (VEGF) has been strongly implicated in pathological ocular neovascularization, including the process of CNV. Intravitreal injection of anti-VEGF has been shown to effectively block the effects of VEGF and thus it has been used effectively in treating CNV. This has been a major breakthrough in the management of neovascular AMD. The following agents have been used.

### Pegaptanib sodium (Macugen)

This was the first anti-VEGF agent shown to be beneficial in treating neovascular AMD. It is a synthetic pegylated anti-VEGF aptamer (a single-stranded DNA or RNA molecule constructed to bind a ligand) with a molecular weight of 20kDa. It specifically binds to isoform 165 of VEGF and is usually administered every 6 weeks via intravitreal injection. In the USA the Food and Drug Administration approved it in December 2004 whereas the European Medicines Agency licensed it in February 2006 at a 0.3 mg dose. It was launched in the UK in May 2006.

#### VISION study

- All types of CNV were included in the study.
- Visual acuity 6/12–4/60.
- Lesion size less than 12 disc areas
- Macugen (0.3, 1.0, 3.0 mg) versus sham injections every 6 weeks.
- Prior PDT allowed.
- Was found to be efficacious in preventing moderate visual loss at all doses.
- Moderate visual loss was significantly less in the 0.3 mg group at 1 year: 70% versus 55%.
- Only 6% showed visual gain versus 2% of controls.
- 2 year results were similar; patients who had injections for 2 years did better than those who had them for 1 year.

### Ranibizumab (Lucentis)

Ranibizumab is a humanized recombinant antibody fragment designed to recognize all five human isoforms of VEGF (i.e. non-selective). It has a molecular weight of 48kDa and is licensed for intravitreal use in AMD. In the USA it was licensed in 2006 and in the European Union and the UK this occurred in February 2007. This is the first treatment with which about a third of patients actually gained vision and the effect was sustained over the course of its treatment (1–2 years).

#### MARINA study

- Minimally classic/occult with no classic CNV included.
- Visual acuity 6/12–6/96.
- Lucentis (0.3, 0.5 mg) versus sham injections every 4 weeks for 24 months.
- PDT allowed if they converted to predominantly classic lesions.
- At 2 years 90% in the 0.5 mg group lost fewer than 15 letters versus 54% in the sham group.
- The secondary end-point was a gain in vision (>15 letters gained): 25–35% versus 5% (sham group).
- Ocular adverse reactions:
  - minor: subconjunctival haemorrhage, eye pain, vitreous floaters.
  - major: uveitis (<1%), endophthalmitis (<1%).

#### ANCHOR study

- Predominantly classic lesions.
- Visual acuity 6/12–6/96.

- Lucentis (every 4 weeks) versus PDT (every 3 months).
- At 1 year, 94–96% lost fewer than 15 letters in the Lucentis group compared with 64% (PDT group).
- A gain in vision was seen in 36–40% (Lucentis) versus 6% (PDT group).
- Severe visual loss: 0% (Lucentis) versus 13% (PDT).

#### FOCUS study

- Lucentis+PDT (combined) versus PDT alone.
- 90% lost less than 15 letters in the Lucentis+PDT group compared with 68% in the PDT alone group.

#### PIER study

- Variable dosing of Lucentis.
- Lucentis monthly for 3 months, then 3 monthly for 2 years versus sham injections.
- Patients did better than the sham group, but not as good as monthly Lucentis throughout, as in MARINA.

#### PRONTO study

- Variable dosing of Lucentis guided by OCT.
- Three monthly injections.
- Examined monthly thereafter with OCT; FFA every 3 months.
- Re-injection if:
  - OCT shows increase in central macular thickness by 100 µm or more;
  - OCT shows persistent or recurrent fluid in or under the retina;
  - OCT shows increase in height or breadth of RPE detachment;
  - loss of five or more letters since last visit;
  - New haemorrhage; new classic CNV.
- After 12 and 24 months, the results in this study were similar to the MARINA and ANCHOR studies; patients needed an average of five injections per year for 2 years.

### Bevacizumab (Avastin)

Bevacizumab is a humanized monoclonal antibody with a size three times that of Ranibizumab that, like Ranibizumab, also binds all isoforms of VEGF. It is licensed for systemic use in colorectal cancers; however, ophthalmic use remains off-label. It contains no preservative and so has a limited shelf life. No pre-clinical trial data exist for use of Avastin in retinal therapy. The half-life of Avastin is different from that of Lucentis, in that it clears from the system 100 times more slowly. This is important for cancer use, but remaining in the eye for that length of time could be harmful.

Avastin contains full-length antibodies, which can cause inflammation. Since the antibody fragments in Lucentis are one-third the size of Avastin antibodies, they are capable of better penetration into the retinal layers. Avastin is also currently cheaper than Lucentis.

No randomized controlled trial data are available for Avastin use in AMD; however, small reports have shown it to be effective in the short term.

### Intravitreal triamcinolone

The pathophysiology of neovascularization in AMD involves the presence of an angiogenic stimulus (VEGF) and inflammation, which are synergistic in their effects. Both VEGF and inflammatory pathways increase vascular permeability, which contributes to the foveal oedema seen in neovascular AMD. Intravitreal triamcinolone use is off-label, but has been increasingly utilized in neovascular AMD for

its anti-inflammatory, anti-angiogenic, and anti-vascular permeability properties. Case series and non-randomized comparative investigations have suggested that intravitreal triamcinolone was associated with better visual results than the natural course of the minimally classic and occult lesions of AMD. Some of the side effects encountered are increased IOP (40%), cataract formation, and endophthalmitis (which can be sterile or infectious).

---

## Combination treatment

There are various reports of combination treatments; for example, intravitreal anti-VEGF plus intravitreal triamcinolone and verteporfin PDT, in various combinations. Reports are still short-term, but have been shown to be effective.



## 4.14 Central serous chorioretinopathy

Central serous chorioretinopathy (CSCR) is a disease in which a serous detachment of the neurosensory retina occurs over an area of leakage from the choriocapillaries through the retinal pigment epithelium. CSCR may be divided into two distinct clinical presentations. Classically, CSCR is caused by one or more discrete isolated leaks at the level of the RPE as seen on FFA. However, it is now recognized that CSCR may present with diffuse RPE dysfunction (e.g. diffuse retinal pigment epitheliopathy, chronic CSCR, decompensated RPE) characterized by neurosensory retinal detachment overlying areas of RPE atrophy and pigment mottling. During FFA, broad areas of granular hyperfluorescence that contain one or more subtle leaks are seen.

### Risk factors

- Young adult males, typically 20–50 years.
- Type A personalities.
- Stress.
- Pregnancy.
- Cushing's disease.
- Medications, mainly corticosteroids in any form, including inhalers and skin creams.

### Clinical evaluation

#### History

- Unilateral sudden painless decrease in central visual acuity.
- Metamorphopsia (distortion).
- Increased hypermetropia.
- Positive scotoma.

#### Examination

- Shallow detachment of sensory retina at the posterior pole.
- May have RPE detachments.
- Pigmentary changes suggest chronicity.
- Occasionally fluid tracks down inferiorly to cause non-rhegmatogenous inferior retinal detachments.
- Chronic CSCR occurs in 5%; mostly in older patients.
- Recurrent episodes occur in 45%.

#### Investigations

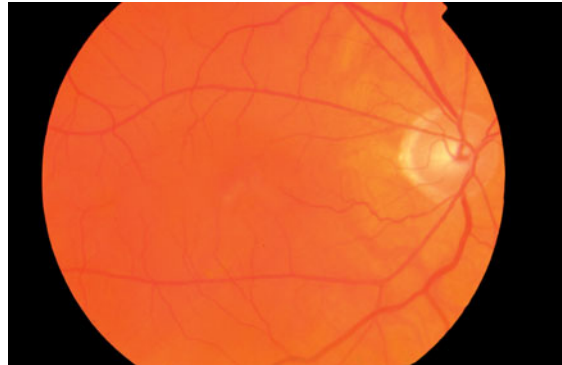
- FFA: leakage in 'smoke-stack' or 'ink-blot' fashion.
- OCT: shows subretinal fluid/detachment of sensory retina.
- ICG: shows bilateral multifocal hyperfluorescence.

### Treatment

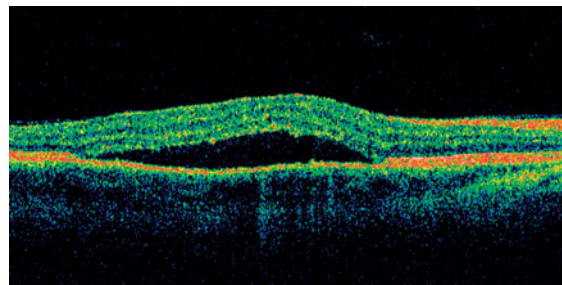
- Reduce or stop corticosteroids if possible.
- 80% show spontaneous resolution in about 6 months, subtle metamorphopsia may persist.
- Indications for argon laser treatment:
  - persistence: more than 6 months,
  - multiple recurrences,
  - occupational needs.
- PDT
  - Recent case series suggest that it may be beneficial in those patients with chronic CSCR.
- Systemic  $\beta$ -blockers are being investigated: there is some suggestion that  $\beta$ -blockers may have a calming effect on CSCR sufferers.

### Morbidity/mortality

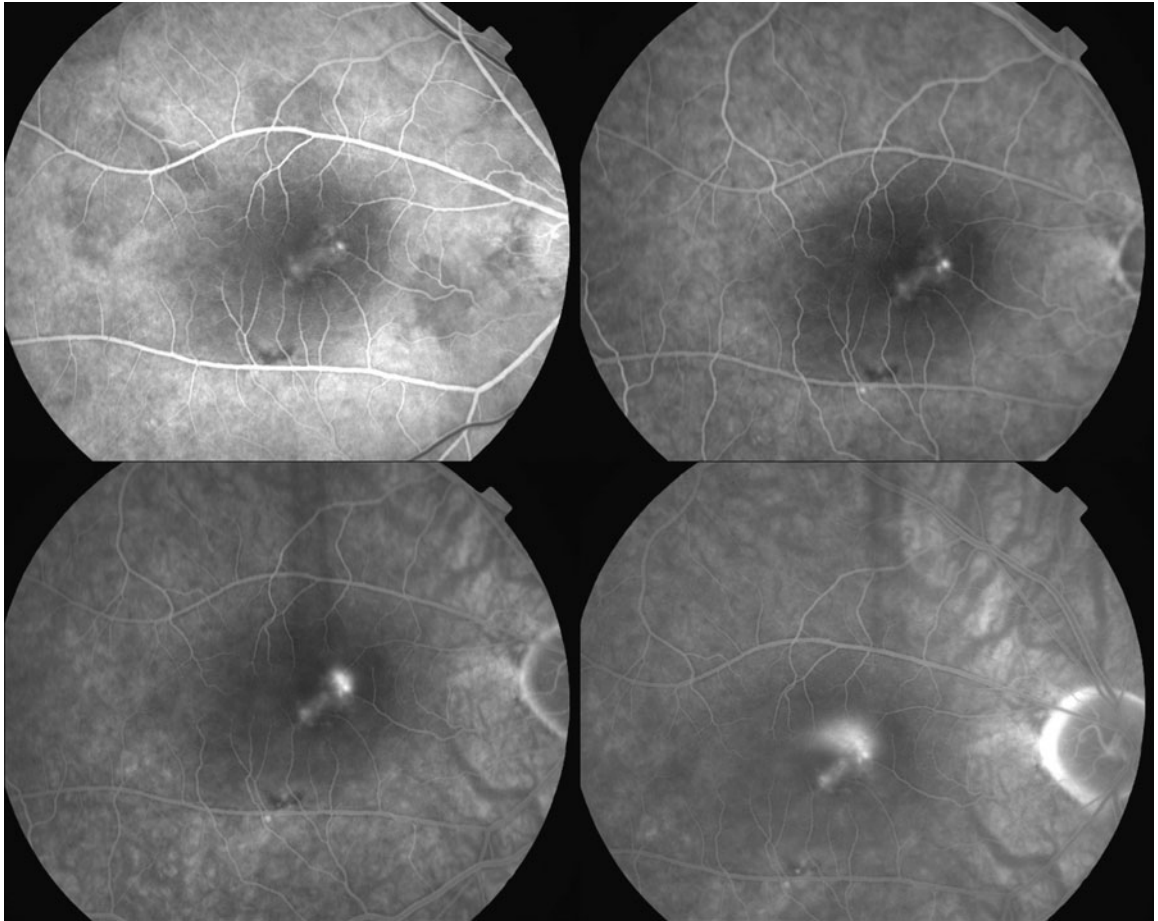
- Patients with classic CSCR (characterized by focal leaks) have a 40–50% risk of recurrence in the same eye.
- Risk of CNV from previous CSCR is small (<5%).
- A small percentage of patients (5–10%) may fail to recover 6/12 or better visual acuity. These patients often have recurrent or chronic serous retinal detachments, resulting in progressive RPE atrophy, and permanent visual loss to 6/60 or worse.



**Fig. 4.37** Colour fundus photograph showing elevation in the macular region.



**Fig. 4.38** OCT showing subretinal fluid (fluid between retina and RPE).



**Fig. 4.39** Four frames of progressive fluorescein angiograms showing leakage.

## 4.15 Retinal vascular anomalies

### Retinal telangiectasias

These are abnormalities of retinal vasculature in the form of irregular dilatation of the capillary bed, and segmental dilatation of neighbouring arterioles and venules. They can be:

- congenital or primary: representing a spectrum of disease:
  - Coats' disease,
  - Leber's military aneurysm,
  - idiopathic juxtafoveal telangiectasia;
- secondary to other retinal disorder: for example, CRVO.

#### Coats' disease

This is an uncommon condition which is the most severe form of retinal telangiectasia. It manifests as multiple saccular out pouches of predominantly the venous and capillary systems. There is no hereditary link and it affects mainly males (in a male/female ratio of 3:1). The usual age of onset is 8–16 years but it may remain asymptomatic until the 30s. Ten per cent of cases are bilateral and it affects mainly superotemporal circulation.

#### Clinical evaluation

- Generally progressive.
- Maybe asymptomatic, decrease vision, leukocoria, strabismus.
- Telangiectatic vessels, 'light bulb' aneurysms, capillary drop-out, massive retinal exudation, vitreous cells commonly seen, scarring.
- Complications: exudative retinal detachment, neovascularization, vitreous haemorrhage, rubeosis, cataract, glaucoma, phthisis.

#### Investigations

- FFA: shows abnormal vessels, extensive leakage and areas of capillary drop-out.

#### Treatment

- Consider argon laser photocoagulation or cryotherapy of leaking vessels; aim to treat directly rather than a scatter approach.
- For significant exudative retinal detachment consider scleral buckling surgery and drainage of subretinal fluid.

#### Leber's military aneurysms

This is a localized, less severe form of Coats' disease, presenting in adults. It presents with a unilateral decrease in visual acuity. Examination reveals fusiform and saccular aneurysmal dilatation of retinal vessels with local exudation. Direct photocoagulation of leaking vessels is beneficial.

#### Idiopathic juxtafoveal retinal telangiectasia

Originally described by Gass and Oyakawa in 1982 this condition is rare and presents in adults with mild decrease in vision and local retinal exudation.

#### Subtypes

##### Group 1A Exudative

- Unilateral parafoveal telangiectasia of temporal macular; middle-aged males; visual acuity approximately 6/12; treatment may be effective

##### Group 1B

- Unilateral parafoveal telangiectasia of less than 1 clock hour at the edge of the foveal avascular zone; middle-aged males; visual acuity approximately 6/7, laser not indicated.

##### Group 2 Occult: often only shows up on FFA

- Bilateral symmetrical parafoveal telangiectasia; late middle age; gradual decrease in visual acuity due to foveal atrophy or CNV.

##### Group 3 Occlusive

- Bilateral perifoveal telangiectasia, adults; gradual decrease in vision due to capillary occlusion.

### Retinal macroaneurysm

Robertson in 1973 first coined the term macroaneurysm to describe an acquired focal dilatation of a retinal artery within the first three orders of bifurcation. Macroaneurysms vary in size from 100 to 250  $\mu\text{m}$  in diameter, are saccular or fusiform in shape, and are differentiated from retinal microaneurysms, which are usually smaller than 100  $\mu\text{m}$  in diameter. It tends to occur in older people, in females more than males. It is typically unilateral and the most consistent association is systemic hypertension.

#### Clinical evaluation

- Often asymptomatic or decreased vision.
- Saccular or fusiform dilatation of artery, often near an arteriovenous crossing; haemorrhage (tri-layered) and exudation.

#### Investigation

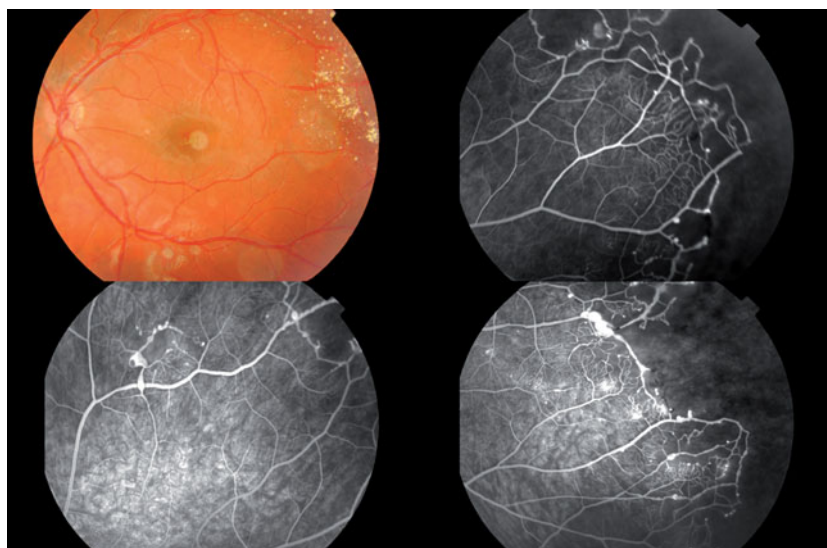
- FFA: to confirm diagnosis, but usually a clinical diagnosis

#### Treatment

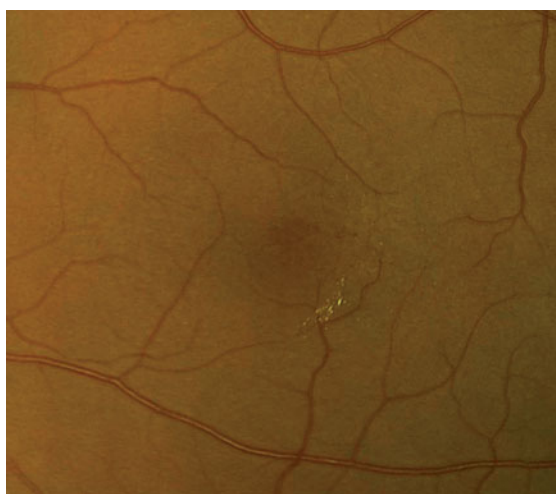
- High rate of spontaneous resolution, in particular haemorrhagic ones with respect to exudative types.
- Laser photocoagulation (direct or to surrounding bed) if symptomatic.
- Vitrectomy: for non-clearing vitreous haemorrhage.

### Idiopathic polypoidal choroidal vasculopathy

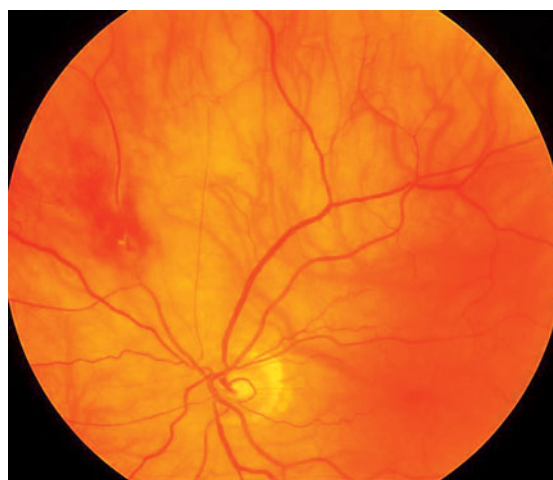This is a rare abnormality characterized by polypoidal aneurysmal dilatation of choroidal vasculature usually around the posterior pole. It is commonly seen in hypertensive women and was first described in Afro-Caribbeans, but now recognized to occur in any race and sex. Clinically it presents as recurrent multiple serous or haemorrhagic retinal detachments in the absence of features of AMD or intraocular inflammation.



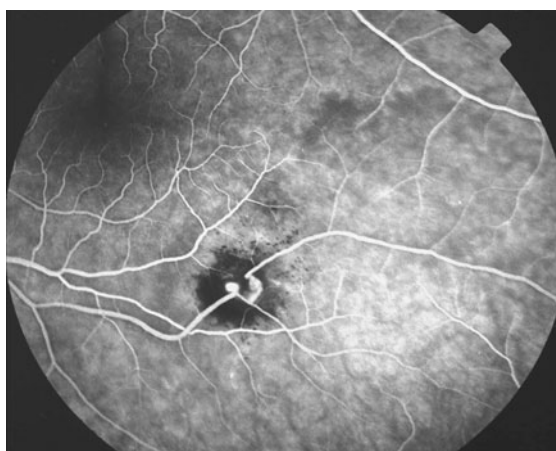
**Fig. 4.40** Top left: colour photograph showing peripheral exudation. Three frames of fluorescein angiogram showing peripheral capillary shut-down with light-bulb-like aneurysms: Coats' disease.



**Fig. 4.41** Colour photograph showing telangiectasia of perifoveal vessels with exudation.



**Fig. 4.42** Colour photograph showing retinal macroaneurysm in superonasal quadrant.



**Fig. 4.43** Fluorescein angiogram showing retinal macroaneurysm.



## 4.16 Retinal dystrophies I

Retinal dystrophies are the major causes of incurable blindness in the Western world. Our insight into their aetiology has improved remarkably over the past decade and a number of key genes have been identified. Together with a more detailed understanding of disease processes, this knowledge has stimulated new approaches to therapeutic strategies involving gene therapy, growth factors, and retinal cell transplantation.

### Retinitis pigmentosa

The term retinitis pigmentosa refers to a broad category of diseases that include many different forms of primary photoreceptor abnormality: some affect rods first and cones later (rod-cone dystrophy) or cones first and then rods (cone-rod dystrophy). Rod-cone dystrophy is typically characterized by progressive night blindness and tunnel vision. Cone-rod dystrophy causes day-vision problems of reduced acuity, colour-vision deficits, and photophobia. They typically progress over many years to an advanced stage and result in global reduction and loss of vision. It is the most common of the retinal dystrophies, affecting about 1:3000 to 1:5000. It may be sporadic or inherited (autosomal dominant, autosomal recessive, or X-linked). Autosomal disease is most common whereas X-linked is most severe. A number of specific syndromes are known to be associated with retinitis pigmentosa.

#### Clinical evaluation

- Age of onset varies. Usually diagnosed in young adulthood.
- Mid-peripheral 'bone-spicule' retinal pigmentation.
- Waxy pallor of optic disc.
- Retinal arteriolar attenuation.
- Posterior subcapsular cataract.
- Bull's eye maculopathy in cone-rod dystrophy.
- Ocular associations: keratoconus, myopia, POAG.
- Complication: cystoid macular oedema.

#### Associations of retinitis pigmentosa

- Usher syndrome: accounts for 5% of all cases of deafness in children and is responsible for half of all the cases of deafness and blindness. Systemic features are divided into two main clinical types:
  - type 1: congenital profound deafness plus abnormal vestibular function,
  - type 2: associated with less severe deafness,
  - progressive pigmentary retinopathy develops before puberty.
- Bardet–Beidl syndrome: mental handicap, polydactyly, obesity, hypogenitalism, and renal involvement. Bull's eye retinopathy develops in most cases and a few have retinitis pigmentosa.
- Laurence–Moon syndrome: mental handicap, hypogenitalism, spastic paraplegia; less common than Bardet–Beidl syndrome. Retinopathy is either retinitis pigmentosa or choroidal atrophy.
- Kearns–Sayre syndrome: this is a mitochondrial cytopathy characterized by chronic progressive external ophthalmoplegia, ptosis, and heart block. The condition usually becomes manifest before the age of 20 years and in some cases may be associated with short stature, muscle weakness, cerebellar ataxia, neurosensory deafness, mental handicap, and delayed puberty. Pigmentary retinopathy principally affects the central fundus.
- Friedreich's ataxia: posterior column disease, ataxia, and nystagmus.
- Refsum disease: due to defective metabolism of phytanic acid, which infiltrates many body tissues including the eye. Systemic features: hypertrophic peripheral neuropathy, deafness, cerebellar ataxia, ichthyosis, cardiac arrhythmias. Pigmentary retinopathy causing night blindness is always the presenting

feature. The retinal findings are usually of a generalized 'salt-and-pepper' type rather than the classic bone-spicule retinopathy. Cataracts are common. Treatment: phytanic acid-free diet and plasma exchange.

#### Variants of retinitis pigmentosa

- Sectoral or central retinitis pigmentosa: retinitis pigmentosa in the sectoral or posterior pole.
- Retinitis punctata albescens: scattered white dots, most numerous in the posterior pole and equator.

#### Investigations

- Visual fields: ring scotoma initially, later tunnel vision.
- ERG: scotopic affected before photopic; b waves affected before a wave; useful for monitoring the disease.

#### Treatment

- General supportive:
  - counselling,
  - low-vision aids,
  - social services.
- Medical:
  - acetazolamide for cystoid macular oedema;
  - vitamin A palmitate (15,000IU/day) appears to slow disease progression:
    - needed long-term,
    - yearly liver-function tests,
    - stop if pregnancy expected,
    - modest benefit noted.
- Cataract surgery: reduce operating light, prophylaxis against postoperative cystoid macular oedema.
- Treatments under investigation:
  - RPE transplants,
  - retinal prosthesis,
  - gene therapy.

### Congenital stationary night blindness

This is a group of diverse disorders, the hallmark of which is early onset non-progressive night blindness. The disorders are conveniently divided into the following.

#### Congenital stationary night blindness with normal fundi

- Autosomal dominant: non-progressive night blindness with near-normal visual acuity, no significant refractive error; ERG shows Riggs abnormality (very small a and b waves).
- Autosomal recessive and X-linked: night blindness plus poor vision, nystagmus, high myopia; ERG shows Schubert–Bronschein abnormality (electronegative ERG: normal or near-normal a wave and attenuated b wave).

#### Congenital stationary night blindness with abnormal fundi

- Oguchi's disease: rare autosomal recessive, non-progressive night blindness, Mizuo phenomenon (abnormal golden-yellow fundus reflex which normalizes in dark adaptation); delay in dark adaptation; abnormal rod function; cone function normal.
- Fundus albipunctatus: autosomal recessive; multiple tiny white dots involving posterior pole sparing the macula and extend into mid-periphery; non-progressive night blindness, delayed dark adaptation.



## Stargardt's disease

Stargardt's disease is one of the most common forms of inherited juvenile macular degeneration and is symptomatically similar to senile AMD. It affects approximately one in 10,000 children. It is almost always inherited as an autosomal recessive trait (mutation in the ABCR gene *ABCA4*); however, autosomal dominant (10%) inheritance (mutation in *ELOVL4* gene) has also been described.

### Clinical evaluation

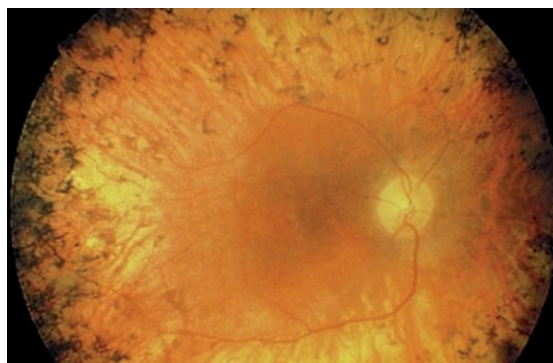
- Onset in childhood, usually under age 20.
- Rapid decrease in central visual acuity (6/18–6/60).
- May experience difficulty in reading and seeing in dim lighting, and distortion.
- Fundus in patients with early Stargardt's disease shows simple macular degeneration.
- As the disease progresses, lipid-rich deposits accumulate in the RPE beneath the macular. This lipofuscin appears as yellow pisciform flecks in the posterior pole.
- In advanced Stargardt's disease, the build-up of lipofuscin causes atrophy of the macular and the underlying RPE: so-called beaten-metal atrophy; pigmentary disturbance.
- The visual acuity is variable and can start at 6/12 and decrease rapidly (especially in children) to 6/60 (legal blindness).
- By age 50, approximately 50% of all those studied in clinical trials had visual acuities of 6/60–6/120.
- Fundus flavimaculatus:
  - usually in adults,
  - more widespread pisciform yellow flecks throughout fundus,
  - relative preservation of vision.

### Investigations

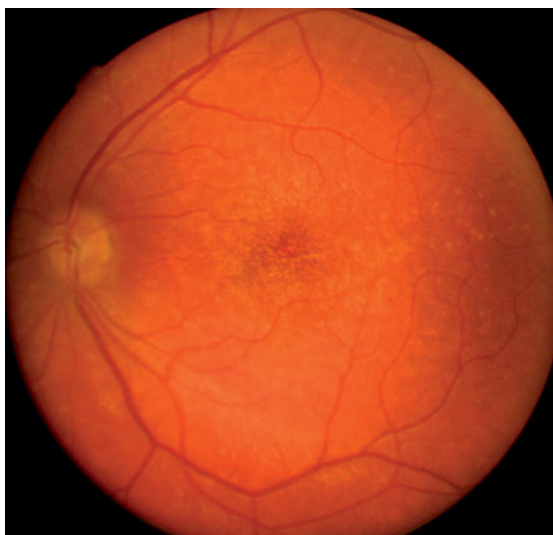- Fundus autofluorescence: central oval area of reduced autofluorescence, often surrounded by more irregular autofluorescence.
- FFA: dark choroids (due to blockage by abnormal lipofuscin-like deposit); not seen in about 25% of Stargardt's disease cases.
- ERG and electrooculogram (EOG): normal early on, mild changes later.

### Treatment

- Supportive; low-vision aids.
- Vitamin A supplements might make the disease worse in *ABCA4* mutation.
- Reduce light exposure (UV-protective sunglasses).



**Fig. 4.44** Colour photograph showing arteriolar attenuation, bone-spicules, and pale optic disc.



**Fig. 4.45** Colour photograph showing yellow pisciform flecks in the posterior pole in Stargardt's disease.

## 4.17 Retinal dystrophies II

### Best's disease and adult vitelliform macular degeneration

This is an extremely rare, autosomal, dominantly inherited disorder that shows variable clinical expression. Several mutations have been found in the bestrophin gene (*VMD2*).

#### Best's disease

Onset is in childhood between the ages of 3 and 15 years (average age of 6 years). There is no gender predilection and it is usually asymptomatic in early stages, but manifests as decreased vision as the disease progresses. Usually there is bilateral symmetrical involvement. Lesions evolve through several stages over many years, with increasing potential for adverse visual outcome.

#### Staging of Best's disease

1. Previtelliform: visual acuity 6/6; normal macula; EOG abnormal.
2. Vitelliform: well-circumscribed, 0.5–5 mm, round, yellow or orange, egg-yolk-like macular lesion, usually centred on the fovea; can be multifocal, rest of fundus normal; visual acuity 6/6 to 6/12–6/18.
3. Pseudohypopyon: visual acuity 6/6 to 6/12–6/18; yellow material can break through the RPE and accumulate in the subretinal space in a cyst with a fluid level formed; the material can shift with extended changes in position (60–90 minutes); this stage is seen mostly in teenage years;
4. Vitelloeruptive: visual acuity 6/6 to 6/30; scrambled-egg appearance due to the break-up of the uniform vitelliform lesion; pigment clumping and early atrophic changes may be seen.
5. Atrophic stage: yellow material disappears over time, RPE atrophy remains; visual acuity less than 6/60.
6. CNV can develop, leading to disciform scarring.

#### Investigations

- The hallmark of Best's disease is an abnormal EOG; reduced Arden ratio (<150%).
- Full-field ERG usually normal.
- Multifocal ERG may be abnormal.

#### Treatment

- No definite treatment.
- CNV: argon laser; intravitreal Avastin.

#### Prognosis

- Mixed progression.
- Some carriers will never phenotypically express their disorder.
- Some will not progress beyond the earliest stages and maintain visual acuity better than 6/12 in both eyes.
- In general, most people will maintain reading vision in at least one eye throughout life.
- In one study, 88% of patients retained 6/12 or better, and only 4% of them had 6/60 or worse, in the better eye.

#### Adult vitelliform macular degeneration

- Described by Gass.
- Adult-onset.
- Minimal symptoms.
- Smaller lesions than seen in Best's disease.
- Normal EOG.

### Familial drusen

- Rare, autosomal dominant with variable expression.
- Onset in third to fourth decades.
- Minimal symptoms of decreased vision.

- Yellow white drusen at the posterior pole, often confluent.
- Later atrophy of RPE, choriocapillaries, and large choroidal vessels.
- ERG normal, EOG near-normal.

### Pattern dystrophy

- Rare group of disorders.
- Autosomal dominant.
- Reticular pigmentation at RPE.
- May take on characteristic clinical pattern; for example, butterfly dystrophy.
- Usually mild symptoms.

### Dominant cystoid macular oedema

- Autosomal dominant; extremely rare.
- Selectively affects Müller's cells causing multi-lobulated cysts in the macula; later atrophy; clinically and on FFA like typical cystoid macular oedema.
- No effective treatment.

### Sorsby's macular dystrophy

- Rare, autosomal dominant.
- Due to mutations in a regulator of extracellular matrix (TIMP3, chromosome 22).
- Usually a significant decrease in visual acuity from the 40s onwards.
- Exudative maculopathy, subsequent scarring, atrophy and CNV.

### North Carolina macular dystrophy

- Rare, autosomal dominant, initially described in North Carolina.
- Links to MCDR1, chromosome 6q.
- Onset is at birth.
- Variable phenotype from 6/6 visual acuity with few drusen to 6/60 with macular coloboma or CNV.

### Progressive bifocal chorioretinal atrophy

- Rare, autosomal dominant, links to Ch6q.
- Described in the UK.
- Onset at birth.
- Visual loss severe.
- Progressive chorioretinal atrophy which spreads from two foci located just temporal and just nasal to the optic disc.

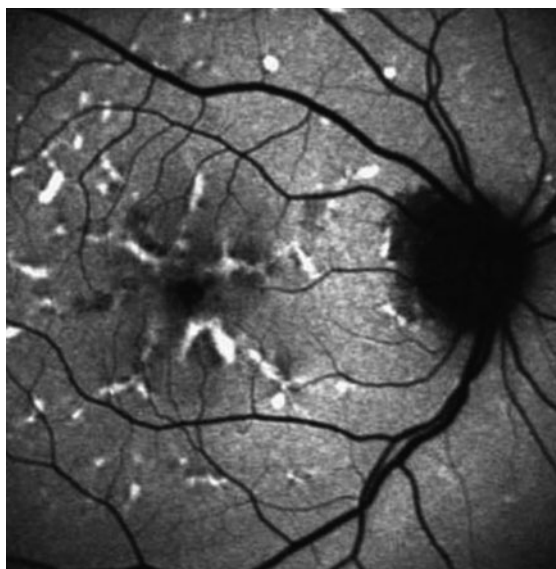
### Maternal inherited diabetes and deafness

- May present with diabetes mellitus, neurosensory hearing loss, and retinal dystrophy.
- Caused by mitochondrial DNA point mutation A3243G; the same mutation has been linked to MELAS (mitochondrial myopathy, encephalopathy, lactic acidosis, and stroke-like episodes).
- Found in 1–2% of the diabetic population, first reported in 1992.
- Retinal findings range from mildly abnormal pigmentation to extensive atrophy of the RPE at the posterior pole.

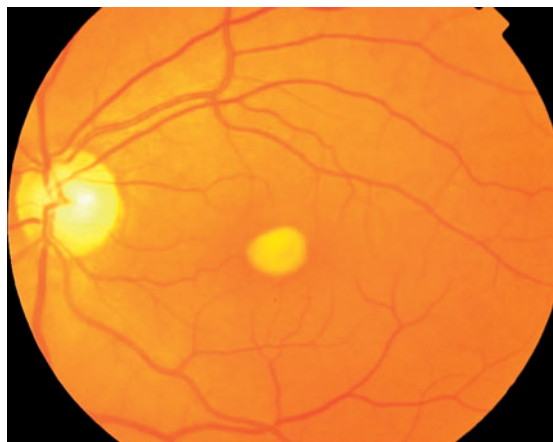
- An early report suggested a specific fundus autofluorescence pattern, which showed an irregular increased fundus autofluorescence signal adjacent to and between areas of RPE atrophy.
- Pathogenesis is unclear.
- Multifocal ERG will show abnormality.

### Juvenile X-linked retinoschisis

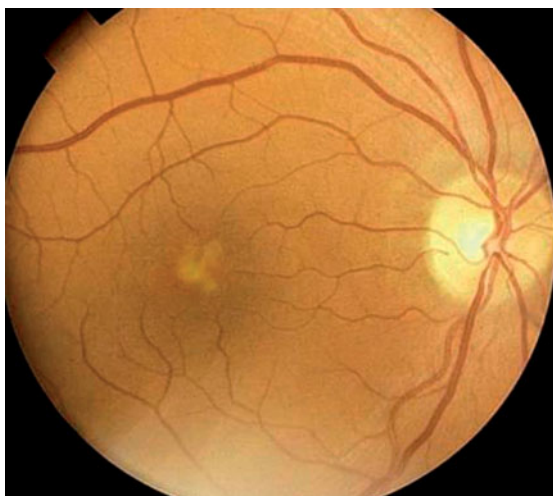
- X-linked.
- Affects only males.
- Females are carriers.
- Ocular features:
  - stellate, cystic foveal schisis/oedema, which does not leak on FFA,
  - peripheral retinoschisis: split in the inner nerve fibre layer, bilateral in 40%.
- Diagnosis:
  - clinical appearance,
  - FFA: no leakage,
  - ERG: selective loss of b wave,
  - visual fields: central scotoma.
- No systemic associations.
- Treatment:
  - prophylactic treatment of holes in schisis not recommended,
  - combined retinoschisis/retinal detachment needs treatment,
  - genetic counselling,
  - children need frequent examinations for amblyopia, vitreous haemorrhage, and retinal detachments.



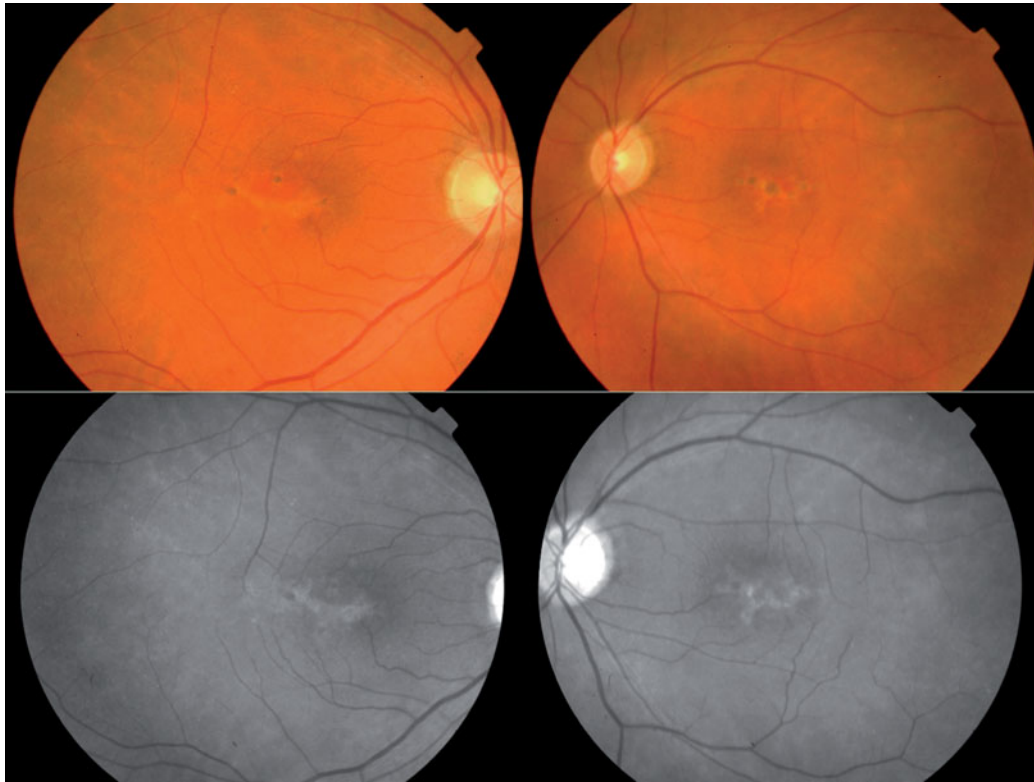
**Fig. 4.46** Fundus autofluorescence in Stargardt's macular dystrophy.



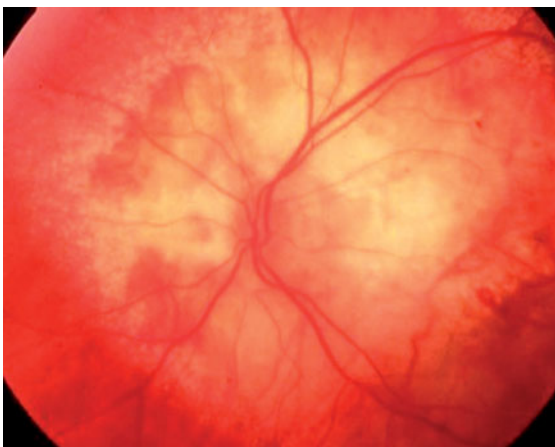
**Fig. 4.47** Colour photograph showing egg-yolk-like lesion in Best's disease.



**Fig. 4.48** Adult vitelliform macular degeneration.



**Fig. 4.49** Top: colour photograph showing pattern dystrophy in both eyes. Bottom: fluorescein angiogram showing pattern hyperfluorescence.



**Fig. 4.50** Colour photograph showing severe exudation in Sorsby's dystrophy.

*This page intentionally left blank*



## 4.18 Choroidal dystrophies

These are a group of progressive, hereditary disorders that are characterized by clinically apparent retinal pigment epithelial and choroidal atrophy, and are potentially blinding.

### Choroideraemia

This is an X-linked recessive disorder that affects young males (first decade). It is usually asymptomatic in female carriers, resulting in a 'moth-eaten' mid-peripheral pigmentary disturbance.

#### Clinical evaluation

- Progressive night blindness.
- Mid-peripheral visual-field loss (ring scotoma).
- Visual loss by fifth decade or later.
- RPE/choroidal atrophy: initially mid-peripheral, later central and diffuse.
- Macular spared until late.
- Cataract (posterior subcapsular).
- Fine, fibrillar vitreous degeneration at an early age.
- Retinal arterioles attenuated only in late stages of disease; the optic disc does not tend to become pale and waxy as in retinitis pigmentosa.

#### Investigations

- ERG: rod responses affected more than cone responses.
- EOG: abnormal in men with choroideraemia.
- Dark adaptation shows elevated thresholds.
- FFA usually not useful in diagnosis.

#### Treatment

- No definite treatment; invariably progressive.
- Supportive.
- Genetic counselling.

### Gyrate atrophy

- Autosomal recessive, slowly progressive chorioretinal atrophy.
- Due to mutation in the OAT gene, which codes for ornithine aminotransferase, which with cofactor B6 catalyses the conversion of ornithine to glutamic- $\gamma$ -semialdehyde, and thence to proline.
- Two clinical subtypes:
  - B6 responders,
  - B6 non-responders.
- Onset is in the second or third decade.

#### Clinical evaluation

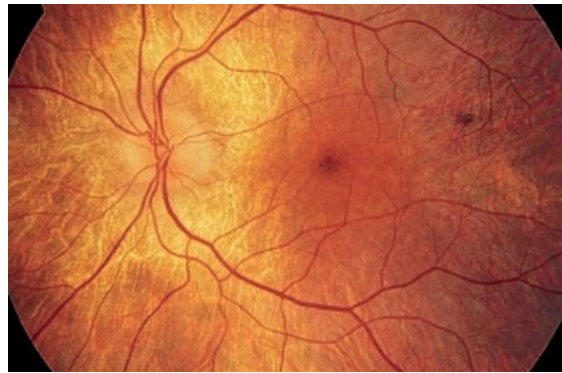
- Slowly progressive night blindness.
- Decrease in visual acuity.
- Peripheral field loss.
- Usually starts with sharply demarcated scalloped areas of chorioretinal atrophy in mid-peripheral and peripheral areas in a garland-shaped fashion, which then progresses centrally and peripherally, ultimately involving the entire fundus.
- Relative sparing of the macula.
- Myopia, cataract, cystoid macular oedema, epiretinal membrane.

#### Investigations

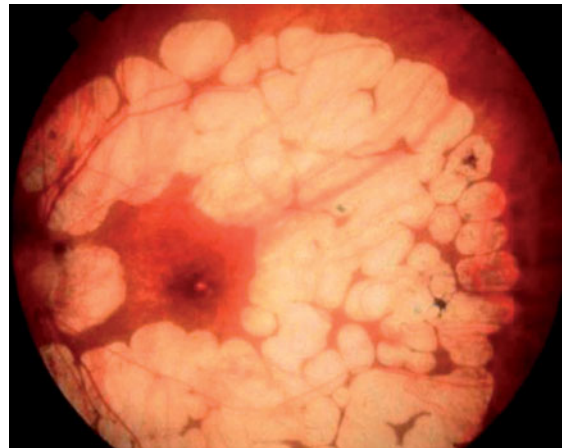
- ERG: rod responses affected more severely than cone responses in the early stages, but later both rods and cones become affected; there are less-marked changes in the B6-responsive group.
- EOG: affected mildly.
- Plasma ornithine levels: 10–20 times the normal levels; also elevated in urine and cerebrospinal fluid.

#### Treatment

- Low-protein diet with arginine elimination.
- Vitamin B6 for the responders.



**Fig. 4.51** Colour fundus photograph showing RPE/choroidal atrophy in choroideraemia.



**Fig. 4.52** Colour photograph showing sharply demarcated scalloped areas of chorioretinal atrophy in gyrate atrophy.

*This page intentionally left blank*

## 4.19 Case-based discussions



### Case 1 Gradual visual loss

Mr Smith, an 80-year-old gentleman, is referred by his optician with gradually decreasing visual acuity in both eyes with difficulty in reading.

1. Given this information, what else will you ask for in the history?

He does not have significant cataracts. Both maculae show atrophic areas with focal RPE hyperpigmentation.

2. What else will you look for?

3. How will you investigate and what tests will you ask for?

Patient has an OCT and an FFA.

4. How will you manage a patient with dry age-related maculopathy?

5. How will you follow these patients?

#### Discussion

1. Is there any distortion in vision?

2. Elevated retinal lesion, retinal haemorrhage, exudates.

3. FFA and OCT if any doubt of choroidal neovascular membrane.

4. A patient with dry age-related maculopathy needs to be advised about lifestyle changes like stopping smoking and good diet, including vitamin supplementation; registration for visual impairment (if appropriate) and referral to social services; regular Amsler chart monitoring for any new-onset distortion in vision and low-vision aid assessments.

### Case 2 Central visual loss

Mrs Brown, an 85-year-old lady, is referred from her GP to your casualty department with a rapid decrease in her left central vision.

1. What history will you take?

2. What examination will you do?

She has had her cataracts extracted and the posterior capsule is clear. Her left macular shows a small greyish raised lesion with surrounding haemorrhage.

3. How will you investigate this lady?

She has an OCT and an FFA done urgently. OCT shows some intraretinal oedema with subretinal fluid and localized hyper-reflectivity of the RPE. FFA shows a well-localized small lesion with early lacy hyperfluorescence and late leakage from edges.

4. What is your likely diagnosis?

5. How will you manage this lady?

6. What other treatment options do you have?

7. How will you follow-up this patient?

#### Discussion

1. Distortion in vision; inability to read and recognize faces.

2. Check pupils for afferent papillary defect, cataracts, dilated fundal examination.

3. An urgent FFA and OCT.

4. Classic with no occult subfoveal choroidal neovascular membrane: wet AMD.

5. This is within the guidelines for PDT with verteporfin (verteporfin PDT).

6. Intravitreal injections: Macugen, Lucentis, Avastin (off-licence), triamcinolone (off-label).

7. 3 monthly if PDT; 6 weekly for Macugen and 4 weekly for Lucentis and Avastin. Repeat treatment if lesion still active (decided on OCT and FFA).

### Case 3 Visual loss in a hypertensive patient

A 78-year-old woman is sent to you by her GP with blurred vision. She is hypertensive on treatment.

1. What relevant history will you take?

Her visual acuity is 6/18 in the right and 6/6 in the left eye. Anterior segments are normal and dilated fundal examination shows retinal haemorrhages in the superotemporal quadrant.

2. What is your likely diagnosis?

3. What investigations will you do?

She is seen in the clinic after 3 months and her vision in right eye is still 6/18.

4. What other investigations will you ask for?

FFA shows macular oedema with no evidence of ischaemia.

5. What will you do for the macular oedema?

6. How will you arrange follow-up?

After 7 months you notice an area of NVE in the right eye.

7. What will you do?

8. What are the causes of poor vision in BRVO?

#### Discussion

1. Onset, unilateral or bilateral, blurred or complete loss, total or segmental.

2. BRVO.

3. Usually not necessary, routine bloods if necessary, check blood pressure.

4. FFA and OCT, looking for macular oedema and extent of retinal ischaemia.

5. Macular grid laser (as per Branch Vein Occlusion Study), intravitreal injections.

6. Continue regular follow-up, monitoring macular oedema, and looking for signs for retinal neovascularization.

7. Repeat FFA, sector PRP.

8. Chronic macular oedema and macular ischaemia.

### Case 4 Sudden, painless visual loss

A 76-year-old lady comes with sudden painless loss of vision in her right eye. Her visual acuity is hand motion in the right eye.

1. What relevant history will you take?

Her retina is white with a cherry red spot at the macula.

2. What is your diagnosis?

3. What emergency measures will you take?

4. What are the common causes of CRAO?

5. In what percentage of the population do you see cilioretinal artery?

6. What is the risk of neovascular glaucoma in CRAO?

#### Discussion

1. History: previous episodes of visual loss, history suggestive of GCA.

2. CRAO.

3. Decrease IOP with intravenous acetazolamide 500 mg with or without anterior chamber paracentesis; ocular massage: for at least 15 minutes, intermittent direct pressure for 5–15 seconds per minute; treat underlying GCA urgently.

4. Mainly thrombosis (atherosclerosis).

- About 20% of the population has a cilioretinal artery which arises from the ciliary vessels, protects part of the papillomacular bundle allowing relatively good vision.
- Roughly 18%.

### Case 5 Diabetic retinopathy

A 36 year-old man has been referred to you by the diabetic clinic for examination with regard to diabetic retinopathy.

- What specific risk factors will you ask for in the history?
- What will you look for in the anterior segment?

He has no rubeosis or cataracts. You dilate the pupils to examine the posterior segment.

Dilated fundal examination shows dot and blot retinal haemorrhages, hard exudates, and new vessels on the disc with inferior vitreous haemorrhage.

- How will you grade this diabetic retinopathy?
- What are the systemic complications of diabetes mellitus?
- How will you manage this patient who has high-risk PDR?

You decide to perform a PRP procedure on this patient.

- How will you counsel the patient for this type of laser?

The patient asks you whether there are any other options for treatment.

- What other treatments (adjunctive) are you aware of?
- What are the long-term complications of PDR?

#### Discussion

- Hypertension, raised cholesterol, duration of diabetes, glycaemic control.
- Iris neovascularization, cataracts.
- PDR (high risk).
- Neuropathy, nephropathy.
- Pan-retinal argon laser photocoagulation.
- Explain treatment; side effects: pain and discomfort, loss of peripheral visual field with possible loss of driving license; need for further laser treatments or surgery.
- Intravitreal anti-VEGF injections.
- Vitreous haemorrhage, retinal detachments.

### Case 6 Difficult night vision

A 40 year-old man is seen with decreasing visual acuity and problems seeing in dark. He tells you it is gradually getting worse.

- What is the likely diagnosis?
- What else will you ask specifically in history?

His father also suffered from night blindness and decreased visual acuity in mid-life. One of his brothers is also having similar problems.

This patient's dilated fundus examination shows mid-peripheral bone-spicule retinal pigmentation and the discs are pale.

- Describe other features of retinitis pigmentosa.
- Describe the inheritance of retinitis pigmentosa.
- What typical field defects will you find?
- What syndromes are associated with retinitis pigmentosa?
- How will you manage this condition?

#### Discussion

- Retinitis pigmentosa.
- Family history.
- Arteriolar attenuation, cataracts.
- Inherited or sporadic. Inheritance can be autosomal (dominant or recessive) or X-linked. Autosomal disease is most common, less severe and X-linked is most severe and less common.
- Ring scotoma, tunnel vision.

- Usher syndrome, Bardet–Beidl syndrome, Lawrence–Moon syndrome, Refsum disease.
- Counselling, low-vision aids, sight-impaired registration, acetazolamide for cystoid macular oedema, vitamin A supplementation, care during cataract surgery (high incidence of cystoid macular oedema).

### Case 7 Visual loss in child

A 14 year-old girl complains of a rapid decrease in her visual acuity in both eyes. She has no other symptoms. Her visual acuity is 6/24 in both eyes and pupils are reacting well. Her mother had some visual problems when she was young.

Dilated fundal examination shows retinal pigmentary disturbance with 'yellowish flecks' in the posterior pole. The macula also shows 'beaten-bronze' atrophy.

- What is your likely diagnosis?
- How will you investigate this girl?

Electrophysiology shows mild reduction. FFA shows 'dark' choroids.

- What is the cause for 'dark' choroids in Stargardt's disease?
- What is the inheritance of Stargardt's disease?

#### Discussion

- Stargardt's macular dystrophy.
- FFA, electrophysiology
- Due to blockage of choroidal fluorescence by abnormal deposits (lipofuscin-like).
- Mostly autosomal recessive, can be autosomal dominant.

### Case 8 Macular lesion

A 19 year-old girl is sent to you by the optician with a yellow macular lesion. The visual acuity is 6/9 bilaterally. Her father has had some eye problems and has poor vision now. Dilated fundus examination shows round, yellow, yolk-like lesion in both maculae.

- What is your likely diagnosis?
  - What one electrophysiological test will you ask for?
- She has EOG done and is reduced to 125%.
- What are the stages of Best's disease?
  - How will you differentiate from adult vitelliform macular degeneration?

#### Discussion

- Best's macular dystrophy.
- EOG.
- Previtelliform, vitelliform, pseudohypopyon, vitelliruptive, end-stage.
- Older patients, smaller lesions, normal EOG.

*This page intentionally left blank*



## Chapter 5

# Medical ophthalmology

Edward Hughes and Miles Stanford

---

### Basic sciences

- 5.1 Uveal anatomy 194

---

### Clinical knowledge

- 5.2 Anterior uveitis 196  
5.3 Intermediate uveitis 198  
5.4 Posterior uveitis 200  
5.5 Specific non-infectious posterior uveitides I 202  
5.6 Specific non-infectious posterior uveitides II 204  
5.7 Viral infectious uveitis 206  
5.8 Parasitic infectious uveitis 208  
5.9 Fungal infectious uveitis 210  
5.10 Bacterial infectious uveitis 212  
5.11 HIV-related disease 214  
5.12 Uveitis: systemic associations I 216  
5.13 Uveitis: systemic associations II 220  
5.14 Scleritis and episcleritis 222  
5.15 Systemic treatment of ocular inflammatory disorders 224  
5.16 Biological agents and periocular treatments of ocular inflammatory disorders 226  
5.17 Intraocular treatments of ocular inflammatory disorders 227  
5.18 Rheumatological disease 228  
5.19 Vasculitis 230  
5.20 Cardiovascular disease and the eye 232  
5.21 Endocrine diseases in ophthalmology 234  
5.22 Respiratory and skin diseases in ophthalmology 235

---

### Practical skills

- Orbital-floor injection 226  
Posterior sub-Tenon injection 226  
Intravitreal injection 227

---

### Case-based discussion

- 5.23 Case 1 Scleritis 236

## 5.1 Uveal anatomy

The uvea derives its name from the Latin meaning 'grape', after its appearance when hanging from the optic nerve following dissection from the sclera. It is a highly vascular, pigmented layer of loose connective tissue lying within the corneo-scleral coating of the eye. Macroscopically the elements of the uvea are black or very dark owing to the numerous melanin-laden melanocytes within the stroma and melanosomes within the pigmented epithelial layer.

The uvea may be divided into three anatomically and functionally distinct but structurally contiguous parts:

- the iris,
- the ciliary body,
- the choroid.

### The iris

The iris is a thin, contractile diaphragm with a central aperture (the pupil). It is an anterior extension of the ciliary body and lies anterior to the lens with which it makes light contact centrally. The iris is thickest 2 mm from the pupil margin and thinnest at its peripheral extent (ciliary margin). The thickest point is marked by a circular ridge (the collarette) which divides the iris into pupillary and ciliary zones. The iris stroma consists of fibroblasts, melanocytes, blood vessels, and collagen with both radial and circumferential muscle fibres. The radial fibres (dilator pupillae: myoepithelial processes originating from the pigmented iris epithelium) are sympathetically innervated and located in the ciliary zone, being responsible for pupil dilatation (mydriasis), whereas the circumferential fibres (sphincter pupillae) are arranged around the pupil margin and under parasympathetic control of pupillary constriction (miosis). The vasculature derives from the anterior ciliary circulation and runs radially apart from at the collarette where the circumferential minor arterial/venous circle is located. The vascular endothelium under normal conditions contains tight junctions, thus forming part of the blood–ocular barrier. The stroma is bare anteriorly where crypts may be evident on slit lamp examination (Fuchs crypts). Posteriorly it is bordered by the bilayered iris epithelium: this is pigmented anteriorly and non-pigmented posteriorly.

### The ciliary body

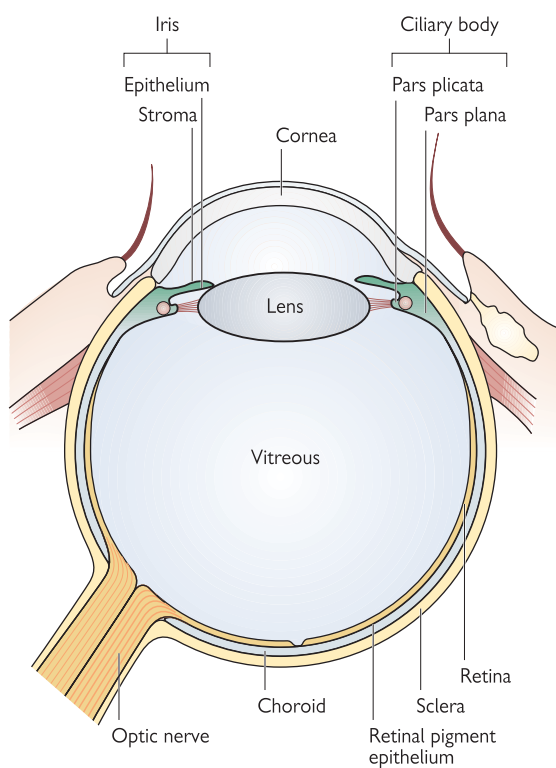
The ciliary body, a circumferential structure surrounding the lens and the vitreous base and bordered externally by the sclera, is responsible for aqueous production and accommodation. It may be divided into a corrugated part anteriorly (pars plicata, ciliary processes), which gives rise to the lens zonule, and a flattened part posteriorly (pars plana). The highly vascular and pigmented stroma contains muscle fibres arranged radially (these alter trabecular pore size by inserting into the scleral spur), circumferentially (these relax the zonular fibres to allow accommodation), and longitudinally. The epithelium is bilayered: an innermost non-pigmented layer (representing an anterior extension of the neurosensory retina) and a pigmented layer (an anterior continuation of the retinal pigment epithelium). The epithelium covering the ciliary processes is thought to be responsible for aqueous production which then flows anteriorly via the posterior chamber, through the pupil, and into the anterior chamber.

### The choroid

The choroid is a thin, highly vascular layer lying between the retina internally and the sclera externally. It has a vital role in the functioning of the outer retinal layers including vascular supply (vascular plexus) and maintenance of photoreceptor disc and visual pigment recycling (retinal pigment epithelium), as well as forming the blood–retinal barrier (tight junctions of the retinal pigment epithelium). The stroma contains an outermost vessel layer consisting of large and medium-sized arteries and veins originating from the posterior ciliary arteries and draining via the vortex veins. Internal to this and just beneath Bruch's membrane is the capillary layer: wide-bore capillaries with fenestrated epithelium. Bruch's membrane is a 2–4 µm-thick layer of both collagen and elastic fibres which forms the basement membrane layer of the choroidal capillaries externally and the retinal pigment epithelium internally. It plays an important role in anatomically separating the choroidal vasculature from the retina and its pigment epithelium. The RPE is the epithelial layer of the choroid: a monolayer of hexagonal cells with microvilli at their apical surface which surround the photoreceptor outer segments. Junctions between RPE cells are 'tight', thus forming the outer blood–retinal barrier (the inner barrier being formed by retinal vascular endothelium).

### Uveal immunology

The human uvea contains small numbers of antigen presenting cells (dendritic cells and macrophages) and the ability to generate immune responses may differ from other tissues. Ocular immune privilege has been proposed by some authors following observations of anergic responses to novel antigens first delivered to the anterior chamber, and because of the tight blood–ocular barrier. The immune system may indeed be naïve to certain antigens within the confines of the blood–ocular barrier and some of these antigens have been proposed as the target of autoimmune attack in non-infectious uveitis (putative autoantigens, e.g. interphotoreceptor retinoid-binding protein). However, it is clear that once inflammation begins the eye is no longer a 'sanctuary site' as the blood–ocular barrier becomes porous to both protein and cells (see anterior chamber flare, section 5.2).



**Fig. 5.1** Gross uveal anatomy

## 5.2 Anterior uveitis

Anterior uveitis is an inflammation of the iris and ciliary body, usually resulting in pain, photophobia, and blurring of vision. The idiopathic form usually affects young adults.

### Aetiology

#### Non-infectious

- Idiopathic (most common).
- Human leucocyte antigen (HLA) B27-associated (sero-negative arthritis, inflammatory bowel disease).
- Sarcoidosis, Behcet's disease.
- Juvenile idiopathic arthritis.
- Other: traumatic, Fuchs heterochromic cyclitis, hypermature cataract.

#### Infectious

- HSV/herpes zoster virus (HZV).
- Tuberculosis, syphilis, Lyme disease.
- Delayed postoperative endophthalmitis (see section 6.6).

### Pathophysiology

Multiple underlying causes including immune dysregulation and infection. Common end-points: most are predominantly T-lymphocyte- and macrophage-mediated. Blood–ocular barrier breakdown leads to protein (seen as flare) and cells in aqueous. Clinical correlations include granulomatous and non-granulomatous types, which may aid diagnosis.

### Clinical evaluation

#### History

- Pain (aching) and photophobia are typical (NB: occasionally painless; for example, Fuchs heterochromic cyclitis- and juvenile idiopathic arthritis-associated uveitis).
- Blurred vision.
- Epiphora.

#### Examination

- Red eye: often circumcorneal injection.
- Cornea: endothelial white-blood cell deposits (keratic precipitates), hazy stroma; look for signs of herpetic keratitis (including sensation). Keratic precipitates may be large, so-called mutton fat type seen in granulomatous uveitis (e.g. sarcoid, tuberculosis, syphilis, Lyme disease).
- Iris: vascular congestion, nodules in granulomatous disease (Koeppe: pupillary margin; Busacca: ciliary zone), posterior synechiae (irido-lenticular adhesions), fibrin, transillumination (herpetic), heterochromia (Fuchs heterochromic cyclitis). Look for signs of anterior bowing (bombe) when posterior synechiae are extensive.
- Anterior chamber: cells and flare (grade 0 to 4+), fibrin, hypopyon.
- Pupil: miosis, irregularity due to posterior synechiae.
- IOP: may be low (ciliary body 'shut-down' or failure), normal or high (perform gonioscopy: synechial angle closure/iris bombe).
- Lens assessment: check for capsular abscess (white deposits) in recent pseudophakia.
- Dilated posterior segment examination: it is *mandatory* to exclude signs of posterior segment inflammation (including vitritis), retinal detachment and other pathology.

**Table 5.1 The grading of anterior chamber activity according to the Standardization of Uveitis Nomenclature (SUN) group (Jabs et al. 2005. *Am. J. Ophthalmol.* 140(3): 509–516). In practice, counting cells would be tedious and an estimate is usually made.**

Cells (in 1mm×1mm beam)	Grade	Flare
<1	0	None
1–5	0.5+	–
6–15	1+	Faint
16–25	2+	Moderate
26–50	3+	Marked (iris details hazy)
>50	4+	Intense (fibrin/plastic aqueous)

### Differential diagnosis

- Endophthalmitis.
- Pan-uveitis/posterior segment intraocular inflammation.
- Keratitis (examine whole cornea).
- Retinal detachment (may cause anterior chamber reaction).
- Microhyphaema (red blood cells suspended in aqueous).
- Pigment dispersion (iris transillumination, Krukenburg spindle).
- Scleritis.

### Investigations

- These should be tailored to the clinical history including systems review, high-risk behaviour (suspicion of HIV, intravenous-drug use), tuberculosis exposure.
- In straightforward cases of non-granulomatous inflammation without systemic symptoms/signs, no laboratory or radiological investigations are indicated.
- If there is clinical suspicion of infectious aetiology or associated systemic disease, consider targeted investigation:
  - CXR (tuberculosis, sarcoid),
  - syphilis serology,
  - serum ACE, Ca<sup>2+</sup> (sarcoid),
  - FBC,
  - inflammatory markers: ESR, CRP,
  - Mantoux test (tuberculosis),
  - HLA B27.

### Treatment

#### Initial

1. *Cycloplegia*: relieves pain, prevents posterior synechiae; for example, g. cyclopentolate 1% TDS or g. atropine 1%. NB: blurs vision.
2. *Topical corticosteroid treatment*: the great majority of cases will respond to topical corticosteroids (e.g. g. dexamethasone 0.1% or g. prednisolone 1%) which may have to be given hourly day and night in severe cases. Steroid ointment may be used at night to allow sleep when control is achieved.

#### Alternatives

- Subconjunctival delivery (e.g. 1 ml betamethasone 0.1%) for severe cases.
- Periocular steroid (sub-Tenon/orbital floor): very rarely indicated.
- Systemic steroid: very rarely indicated
- 3. Ocular hypotensive treatment: if necessary.
- 4. Appropriate antimicrobial treatment in infectious cases.

#### Later

Gradual tapering of topical steroid is necessary to avoid recurrence/rebound of inflammation. Should be tailored according to case but a

four week taper may be suitable in most cases. Some require chronic therapy (e.g. sarcoid, juvenile idiopathic arthritis).

### Complications

#### Posterior synechiae

Adhesions between iris and anterior lens surface. If acute may be broken with cycloplegia: intensive drops, hot pad, or subconjunctival mydraine. 360° posterior synechiae (seclusio pupillae) may lead to acute angle closure through iris bombe (shallow anterior chamber; iris bowing forward; see below).

#### Cataract

#### Secondary glaucoma

- Steroid response.
- Cellular trabecular block.
- Synechial angle closure.
- Acute angle closure 2° iris bombe: dilate pupil. May need iridotomy or intracameral tPA.

#### Ocular hypotension (hypotony)

Usually resolves with adequate control of inflammation, but if chronic may lead to maculopathy and phthisis. No specific treatment except eye shield if severe.

#### Cystoid macular oedema

Seen with severe anterior uveitis, especially associated with HLA B27 and juvenile idiopathic arthritis. Consider oral acetazolamide or peri-ocular steroid if no resolution with topical treatment.

#### Band keratopathy

Commonly seen in chronic anterior uveitis associated with juvenile idiopathic arthritis.

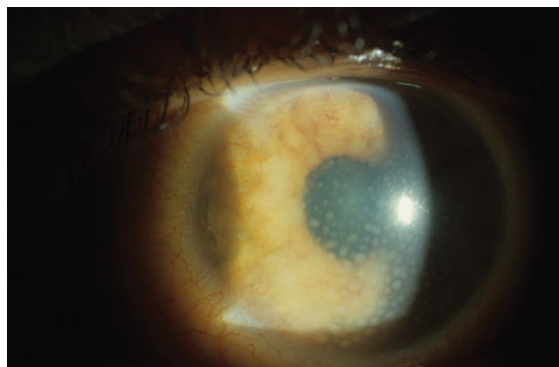
### Prognosis

#### Recurrence/relapse

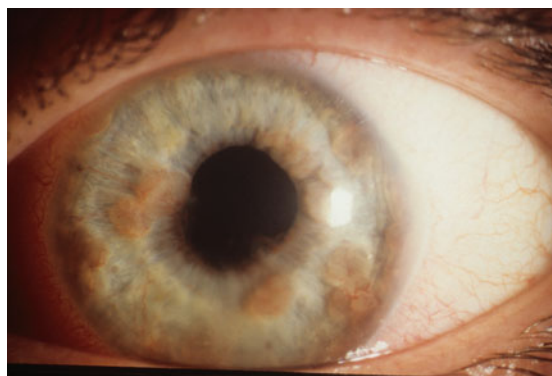Anterior uveitis is most commonly an acute condition but recurrence is common (66%). The condition may be chronic, requiring long-term topical therapy.

#### Visual loss

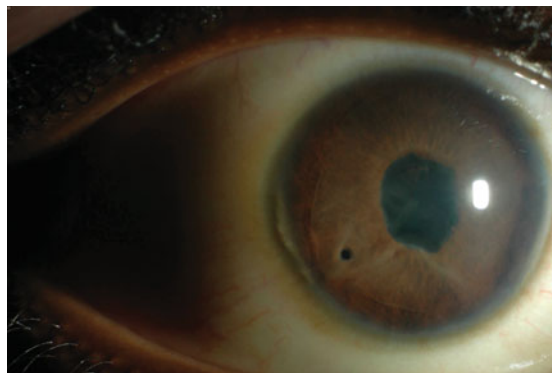
Significant, irreversible visual loss is very uncommon in the acute, relapsing form of anterior uveitis. It is more commonly seen in chronic anterior uveitis (approximately 10% severe visual loss in at least one eye). Juvenile idiopathic arthritis-associated uveitis carries a worse prognosis with up to 25% developing significant visual loss.



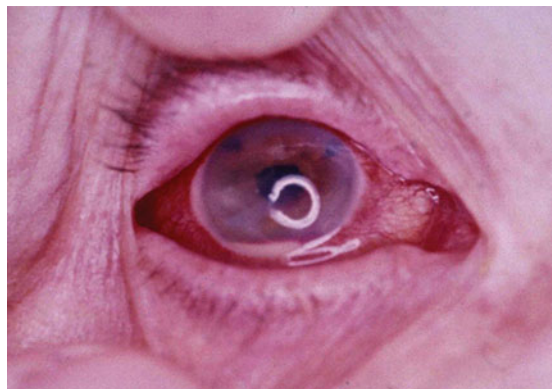
**Fig. 5.2** Mutton fat keratic precipitates in a case of granulomatous anterior uveitis.



**Fig. 5.3** Posterior synechiae and iris granulomata (Busacca nodules).



**Fig. 5.4** Fibrinous anterior uveitis and seclusion pupillae (360° posterior synechiae) treated by laser iridotomy (ideal position for the iridotomy is superiorly in most cases).



**Fig. 5.5** Severe anterior uveitis with hypopyon.



## 5.3 Intermediate uveitis

Intermediate uveitis is a type of posterior segment intraocular inflammation predominantly involving the vitreous body (vitritis), with minimal or no anterior segment and chorioretinal signs. It is most commonly seen in young adults and is usually bilateral but often asymmetric. The combination of vitritis, peripheral retinal vasculitis, and pars plana exudation (previously known as pars planitis) probably represents the severe end of the spectrum of intermediate uveitis.

### Aetiology

Intermediate uveitis is usually an idiopathic condition with a presumed immunological basis. Similar features may be found in association with infectious and other aetiologies (see differential diagnosis, below).

### Pathophysiology

Predominantly T-lymphocytic infiltration of the vitreous and pars plana is found on pathological studies performed *post mortem* or following enucleation.

### Clinical evaluation

#### History

- Symptoms usually subacute/chronic.
- Painless.
- Blurred vision.
- Floaters.

#### Examination

- Typically a lack of conjunctival injection or severe anterior segment inflammatory signs (i.e. no keratic precipitates, posterior synechiae).
- Cells in the vitreous (differentiate from anterior vitreous spill over in severe anterior uveitis), vitreous haze.
- Pars plana exudation ('snow banking').
- Preretinal inflammatory aggregates inferiorly ('snow balls').
- Peripheral retinal vascular cuffing/sheathing.
- Absence of choroidal pathology (e.g. scars/choroiditis).
- Macular oedema: a common complication.
- Optic disc swelling: especially with severe inflammation.
- Optic disc or retinal neovascularization.
- Occasional association with retinoschisis.

**Table 5.2 The binocular indirect ophthalmoscopy score (Nussenblatt et al. 1985. Standardization of vitreal inflammatory activity in intermediate and posterior uveitis. *Ophthalmology* 92(4): 467–471), a useful grading system for severity of vitritis.**

Bio score	Fundus details
0	Clear view
1	Haze, but vessel details visible
2	Vessels visible but no detail
3	Disc, but not vessels, is visible
4	No view (disc or vessels)

### Differential diagnosis

- Multiple sclerosis.
- Sarcoidosis.
- Lymphoma.
- Fuchs heterochromic cyclitis (usually unilateral with other signs including 'stellate' keratic precipitates, iris stromal atrophy).
- Infectious: syphilis, tuberculosis, Lyme disease, Whipple's disease, endophthalmitis, immune recovery uveitis in HIV.

- Anterior vitreous cells spill over in severe anterior uveitis.
- Vitreous syneresis, haemorrhage, or pigment (retinal tear/detachment, Shafer's sign).

### Investigations

- Tailor to clinical history. Carry out a systems review but ask specifically for symptoms suggestive of sarcoid (dry cough, weight loss, rashes, etc.), multiple sclerosis, and tuberculosis.
- Investigations are not mandatory in intermediate uveitis and in straightforward cases may not be necessary. If undertaken they may include (according to clinical suspicion):
  - CXR (tuberculosis, sarcoid),
  - syphilis serology,
  - serum ACE, Ca<sup>2+</sup> (sarcoid),
  - FBC,
  - inflammatory markers: ESR, CRP,
  - Mantoux test (tuberculosis),
  - Borrelia burgdorferi serology (lyme disease).
- OCT helps to identify and monitor macular oedema.
- FFA identifies macular oedema, capillary non-perfusion, and neovascularization.
- Consider vitreous biopsy for cytology in older patients with new-onset intermediate uveitis or those not responding to systemic corticosteroid (lymphoma).

### Treatment

- Observation for mild or moderate cases with good visual function.
- Treatment indicated for cases with reduced vision (usually cystoid macular oedema, see below) or severe floaters is as follows.

#### Topical corticosteroids

- These rarely provide any benefit but may be worth a brief trial.

#### Periocular corticosteroids

- Sub-Tenon or orbital-floor depot steroid injections: particularly useful for unilateral or asymmetric disease.

#### Intraocular corticosteroids

- By injection or slow-release implant/pellet, this approach is being used with increasing frequency, particularly for unilateral or asymmetric disease.

### Systemic therapy

- Bilateral severe/sight-threatening disease may necessitate systemic treatment, initially with corticosteroids. Second-line drugs (see section 5.15) may be required as steroid-sparing agents or to obtain control of inflammation.

### Surgery

Vitrectomy may be useful in intermediate uveitis for:

- removal of visually significant vitreous opacity not responding to medical treatment,
- vitreous haemorrhage,
- epiretinal membrane,
- improved control of inflammation (controversial).

## Complications

### Cystoid macular oedema

A major cause of visual loss in intermediate uveitis. Detectable clinically and confirmed with OCT or FFA. Often rapidly responsive to treatment in acute stages but less so if chronic; therefore treat early (peri/intraocular or systemic steroids).

### Retinal neovascularization/vitreous haemorrhage

Neovascularization on the optic disc or peripheral arcades may occur due to inflammation or capillary non-perfusion. Predominantly 'inflammatory' new vessels may regress with adequate control of inflammation alone. Extensive ischaemia may prompt targeted retinal photocoagulation. Vitreous haemorrhage from vitreous traction on new vessels may necessitate vitrectomy if recurrent or dense.

### Cataract

### Secondary glaucoma

- Steroid response.
- Cellular trabecular block.

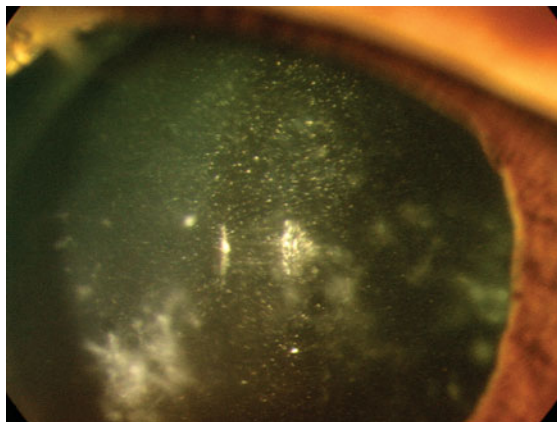
### Ocular hypotension (hypotony)

### Retinal tear and detachment

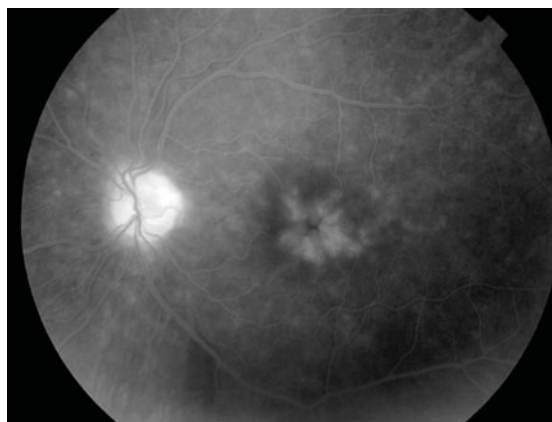### Epiretinal membrane/macular pucker

### Prognosis

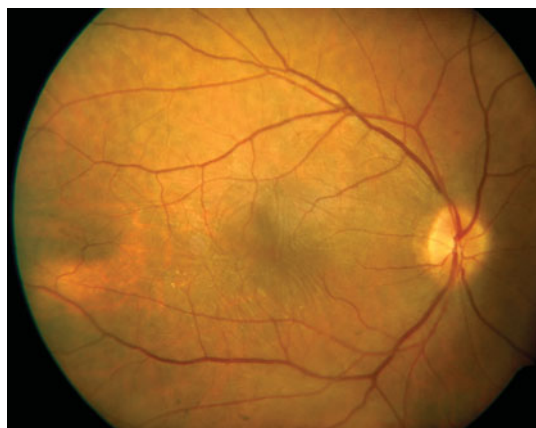
Visual prognosis is largely determined by state of the macula. The condition may remain mild, requiring no treatment, but severe disease is associated with a poor visual outcome ( $\leq 6/60$ ) in 20% eyes. Spontaneous remission after several years often occurs. Development of multiple sclerosis occurs in approximately 15% with long-term follow-up.



**Fig. 5.6** Vitreous opacities and cells in intermediate uveitis.



**Fig. 5.7** Cystoid macular oedema demonstrated by fluorescein angiography.



**Fig. 5.8** Right macular epiretinal membrane causing wrinkling of the retina.

## 5.4 Posterior uveitis

The term posterior uveitis encompasses a broad and diverse spectrum of intraocular inflammation primarily affecting the retina and choroid, but not infrequently with associated involvement of the vitreous and anterior uvea, when the term pan-uveitis may be used. Inflammatory changes may appear to principally target the tissues themselves (choroiditis, retinitis, papillitis) or the vasculature (retinal vasculitis, choroidal vasculitis, optic disc vasculitis) or both. The main distinction to be made clinically is between cases of immune-mediated aetiology and those of an infectious or neoplastic nature, since this will direct appropriate treatment.

### Aetiology

Posterior uveitis may be infectious, immunological (non-infectious), or neoplastic ('masquerade'). Infectious cases may be bacterial, viral, or fungal whereas non-infectious cases may or may not be a manifestation of an underlying systemic disease.

**Table 5.3 Posterior uveitis: aetiology**

Non-infectious	Infectious
<b>Retinal vasculitis</b>	<b>Viruses</b>
Primary retinal vasculitis	(typically retinitis)
Sarcoidosis	Cytomegalovirus (CMV), HSV, HZV, EBV
Behcet's disease	HIV
Multiple sclerosis	<b>Fungi</b>
<b>Choroiditis</b>	(typically chorioretinitis)
Sarcoidosis	<i>Candida</i>
Multifocal choroiditis	<i>Aspergillus</i>
Birdshot chorioretinopathy	<i>Cryptococcus</i>
Vogt–Koyanagi–Harada syndrome	Histoplasmosis
Punctate inner choroidopathy	<b>Protozoa/nematodes</b>
Acute posterior multifocal placoid pigment epitheliopathy	(typically chorioretinitis)
Multiple evanescent white-dot syndrome	<i>Toxoplasma gondii</i>
Sympathetic ophthalmia	<i>Toxocara canis</i>
Serpiginous choroidopathy	<b>Bacteria</b>
	(variable presentation)
	Tuberculosis
	Syphilis
	<i>Lyme (B. burgdorferi)</i>
	Endogenous endophthalmitis (endocarditis/sepsis)
	Postoperative (e.g. cataract surgery)
	Post-traumatic

### Pathophysiology

The concept that the eye harbours uveitogenic proteins or peptides has been supported by animal studies in which subcutaneous vaccination distant from the eye, with proteins such as S antigen (arrestin) or interphotoreceptor retinoid-binding protein, induces experimental uveitis. These models have been very useful in the study of non-infectious posterior uveitis and have shown in general that CD4+ T-lymphocytes and monocytes/macrophages are the pre-eminent cellular components in the acute stages. The trigger for immune dysregulation towards uveal/retinal peptides is unknown, although molecular mimicry may play a role. In some instances a clear genetic predisposition has been demonstrated (e.g. birdshot chorioretinopathy, HLA A29).

### Clinical evaluation

#### History

- Symptoms may be acute or chronic.
- Usually painless except when anterior uveitis coexists.

- Blurred vision.
- Floaters.
- Photopsia, nyctalopia, dyschromatopsia in some cases.

#### Examination

- Anterior uveitis may be present (see above), and may give a clue to aetiology (e.g. sarcoid, Behcet's disease, infectious).
- Vitritis (cells and haze).
- Choroiditis: active ('fluffy', white/grey, sometimes raised) or inactive (sharp borders, flat, often with pigment), granuloma (tuberculosis).
- Retinal vascular inflammatory changes: cuffing, attenuation, dilatation, closure, neovascularization. Associated haemorrhages and cotton-wool spots.
- Macular oedema.
- Retinitis (e.g. infectious or Behcet's disease): pale/white areas within retina, may be associated with haemorrhage if retinal necrosis is present (viral, bacterial).
- Optic nerve head swelling/infiltration.
- Exudative retinal detachment (e.g. Vogt–Koyanagi–Harada syndrome).

#### Differential diagnosis

The wide differential for posterior uveitis is evident and identifying infectious or neoplastic aetiologies is key to correct management. A high index of suspicion for infectious aetiology is necessary in patients at risk of HIV/AIDS or on immunosuppression/chemotherapy, those from tuberculosis-endemic areas, and intravenous-drug users.

#### Investigations

A thorough history and examination is mandatory and will enable targeted investigation to discern between likely diagnoses. The only mandatory test is syphilis serology since syphilis may present in such a wide variety of ways and is easily treatable. Other investigations facilitating diagnosis may include:

- blood tests: biochemistry (e.g. serum ACE, renal function, calcium, CRP, liver-function test), haematology (e.g. FBC, ESR, T-cell subsets), immunology (e.g. antinuclear antibody (ANA), anti-neutrophil cytoplasmic antibody (ANCA), anti-cardiolipin/lupus anti-coagulant), microbiology (e.g. blood culture, serology for *Toxoplasma*, syphilis, HIV, *Toxocara*, herpes viruses, Lyme disease), and HLA typing (e.g. HLA A29 in birdshot chorioretinopathy).
- Imaging studies: may include CXR or chest CT (sarcoid, tuberculosis), CT or MRI brain (depending on clinical need), and gallium scanning (sarcoid).
- Blood pressure, urinalysis.
- Skin testing: Mantoux for tuberculosis. Cerebrospinal fluid or aqueous/vitreous analysis: viral/bacterial PCR or cytology.
- Biopsy: for example conjunctiva or lacrimal gland (sarcoid), chorioretinal tissue (lymphoproliferative disease), and enlarged lymph node (tuberculosis).
- Ancillary ophthalmic tests for diagnosis and monitoring: OCT, FFA, ICG angiography, ultrasound, electrophysiology.

#### Treatment

- Observation for mild or moderate cases of non-infectious aetiology with good visual function.
- Treatment: assessing risk of bilateral visual loss and potential reversibility of established visual loss is a fundamental part of treatment planning, as described below.

**Appropriate antimicrobial treatment**

For infectious aetiologies.

**Topical corticosteroids**

For anterior uveitis if present.

**Periocular, intraocular, and systemic corticosteroids**

As for intermediate uveitis (see section 5.3): dependent upon severity, laterality, and patient factors (e.g. obesity and diabetes mellitus exacerbated by systemic steroids).

**Second-line immunosuppressants/immunomodulatory drugs/biologicals**

See section 5.15.

**Complications**

Posterior uveitis is a sight-threatening condition. Visual loss may be reversible or irreversible, with irreversible loss often resulting from involvement of the macular or optic nerve head.

**Potentially reversible visual loss**

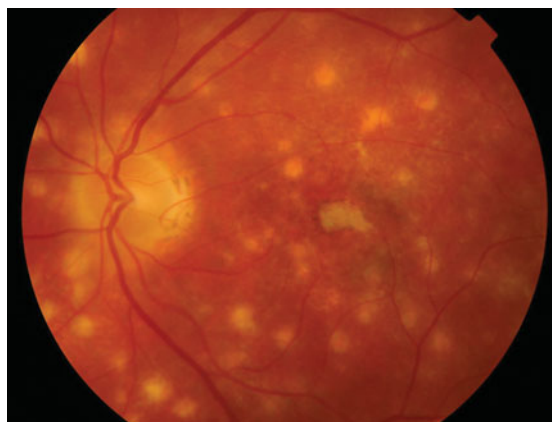
- Media opacity (corneal oedema, cataract, vitreous inflammation/haemorrhage).
- Macular oedema, sub-macular fluid.
- Some sub-macular lesions (e.g. CNV secondary to choroidal scar, pigment epitheliitis).
- Papillitis.
- Transient hypotony.
- Retinal detachment (rhegmatogenous, tractional, or exudative).

**Irreversible visual loss**

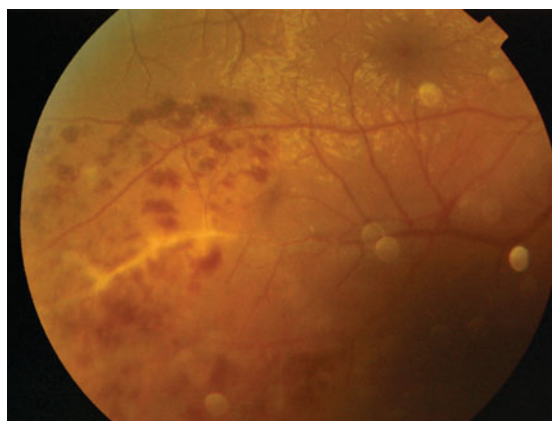
- Macular ischaemia/infarction/necrosis.
- Submacular fibrosis (following CNV).
- Choroiditis or choroidal infarction involving macular.
- Infarction of optic disc.
- Secondary glaucoma.
- Irreversible hypotony/phthisis.

**Prognosis**

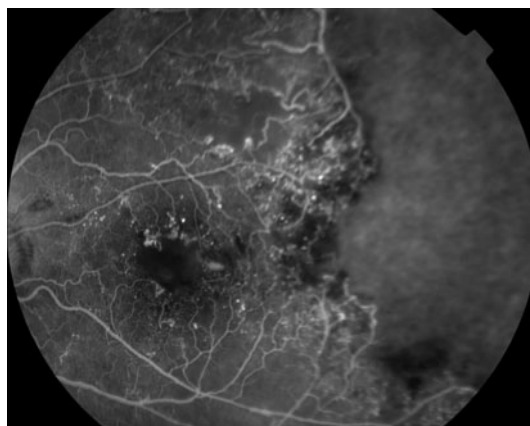
The visual prognosis varies with the diagnosis but overall posterior segment intraocular inflammation accounts for over 10% of blind registrations in the USA and is, along with diabetes, a leading cause of blindness in the working-age population with obvious socio-economic implications. With appropriate treatment 50% of eyes will retain 6/9 vision in the longer term.



**Fig. 5.9** Multiple choroidal lesions in a case of multifocal choroiditis involving the fovea. Established/old lesions are discreet, pale, well demarcated and atrophic in appearance, whereas fresh/active lesions tend to be cream-coloured and have an indistinct margin.



**Fig. 5.10** Localized venous occlusion due to retinal periphlebitis as seen by the yellowish venous cuffing.



**Fig. 5.11** Fluorescein angiographic demonstration of capillary closure temporal to the macular in a patient with idiopathic ischaemic retinal vasculitis.



## 5.5 Specific non-infectious posterior uveitides I

### Sympathetic ophthalmia

A bilateral chronic granulomatous pan-uveitis following previous penetrating trauma or surgery to an eye. The condition may arise many years after the 'exciting' event but 90% will occur within 1 year.

#### Pathophysiology

Exposure of components of the immune system to intraocular peptides breaks tolerance and initiates an autoimmune attack on the uvea of both eyes. A characteristic but not universal pathological finding is the Dalen–Fuchs nodule (histiocytes and RPE cells) and lymphocytic infiltration of the choroid.

#### Clinical evaluation

##### History

- History of previous penetrating ocular injury or surgery (typically multiple posterior segment procedures).
- Floaters, blurred vision, pain.

##### Examination

- Granulomatous anterior uveitis (mutton fat keratic precipitates).
- Vitritis.
- Multifocal choroiditis (lesions may look raised).

##### Investigations

- Fluorescein angiography may help (lesions block early and stain late).

##### Treatment

Treatment is as for non-infectious posterior uveitis. Second-line immunosuppressant (e.g. cyclosporin) is often needed, depending on severity. It is often a chronic condition. Prevention by prompt surgical repair of penetrating ocular injuries reduces the risk. Enucleation of the 'exciting' eye after the onset of the condition has been performed in the past without scientific basis, but has no role in current practice.

### Vogt–Koyanagi–Harada syndrome

A syndrome of intraocular inflammation with cutaneous depigmentation, hearing loss, and meningism was first described in the early twentieth century. Harada described similar ophthalmic features in the absence of systemic manifestation in 1926 (Harada's disease). It is more common in certain racial groups (Japanese, Hispanics) and rare in northern Europeans.

#### Pathophysiology

It is thought by some to involve specific immune attack on melanocytes. Association with HLA DR4.

#### Clinical evaluation

##### History

- Bilateral blurred vision, floaters.
- Hearing loss, headache, and hair/skin depigmentation.

##### Examination

- Poliosis, vitiligo, alopecia, meningism.
- Granulomatous anterior uveitis (mutton fat keratic precipitates, iris nodules).
- Posterior synechiae.
- Exudative retinal detachment (main clue to diagnosis).
- Focal choroiditis.
- Retinal and optic disc oedema.
- Occasional neovascularization.

- 'Sunset glow' fundus: orangey appearance in later stages due to choroidal and RPE changes.

##### Investigations

- A clinical diagnosis.
- Exclude other conditions, for example tuberculosis, syphilis, and sarcoid.
- Enquire about risks for sympathetic ophthalmia (penetrating injury/surgery).

##### Treatment

Systemic treatment is required: it is usually responsive to corticosteroids. See section 5.15.

### Birdshot chorioretinopathy

A painless bilateral posterior uveitis syndrome that is more common in women, usually presenting in the third to sixth decades. There are no confirmed systemic features. It is named after the appearance of the choroidal lesions spreading out from the disc, like shot from a shotgun.

#### Clinical evaluation

##### History

- Painless, floaters, blurring, nyctalopia.

##### Examination

- Colour vision often defective, even with good visual acuity.
- Typically anterior segments are quiet.
- Vitritis, retinal vascular cuffing.
- Indistinct, pale (without pigment) choroidal lesions radiating out from the disc.
- Cystoid macular oedema.

##### Investigations

- Clinical diagnosis supported by HLA A29 genotype (strongly associated: over 90%).
- Visual electrophysiology and fields are necessary as a baseline and for monitoring.
- OCT or FFA for macular oedema.

##### Treatment and prognosis

A chronic condition with variable response to immunosuppression. Second-line immunosuppression is often required. Visual loss is usually due to cystoid macular oedema but macular atrophy, choroidal neovascularization, and vitreous haemorrhage also occur. 20–30% of eyes are 6/60 or worse by 5 years.

### White-dot syndromes

A group of posterior segment intraocular inflammatory disorders characterized predominantly by a multifocal choroiditis. Visual loss mainly occurs when the fovea is involved either by choroiditis or consequent subretinal neovascularization. Certain distinct clinical entities exist, including the following.

#### Acute posterior multifocal placoid pigment epitheliopathy

This condition presents with an acute onset of blurring and flashes in a young patient, often following a prodromal viral illness. It is usually bilateral with at most mild anterior segment and vitreous inflammation. Typical lesions are multiple, creamy, flat plaques of varying size at the level of the RPE. Lesions block fluorescence early on FFA and fluoresce late. Spontaneous resolution after a few weeks is the norm, with good visual outcome. Treatment is not usually required.

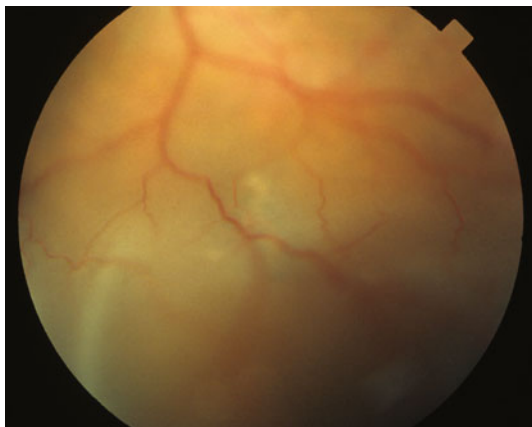


### Multiple evanescent white-dot syndrome

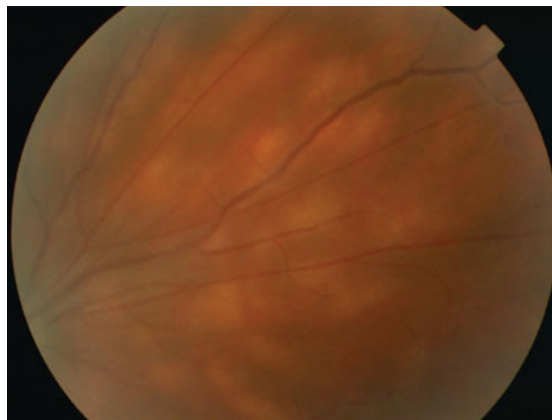
Again, this affects mainly young adults (usually female) but without prodrome. Acute-onset blurring of vision is the main symptom. Examination reveals mild to moderate vitritis, occasional retinal vascular cuffing and typical discrete small white lesions at the posterior pole (RPE level) but usually sparing the fovea. The lesions are transient (hence 'evanescent') and usually resolve within 2 months with return of good vision. Treatment is required only rarely.

### Punctate inner choroidopathy

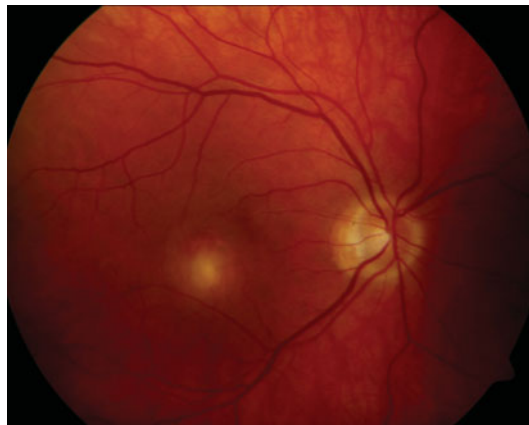Young myopic women are characteristically affected by punctate inner choroidopathy, a central choroiditis causing a central or para-central scotoma. The creamy yellow lesion often responds to systemic corticosteroids, leaving a scar which is prone to either reactivation or subretinal neovascularization.



**Fig. 5.12** Exudative inferior retinal detachment in Vogt-Koyanagi-Harada syndrome.



**Fig. 5.13** Typical indistinct and unpigmented choroidal lesions in birdshot chorioretinopathy. Note the subtle retinal venous cuffing commonly seen with the condition.



**Fig. 5.14** Punctate inner choroidopathy with a fresh juxtafoveal lesion in the right eye.

## 5.6 Specific non-infectious posterior uveitides II

### Serpiginous choroidopathy

This is a poorly understood condition mainly seen in white, middle-aged patients, characterized by choroidal lesions (not dissimilar to those seen in acute posterior multifocal placoid pigment epitheliopathy) of presumed inflammatory origin that progress at the posterior pole in a serpentine fashion. Usually commencing in the peripapillary region, the lesions may cause slight retinal elevation and predispose to subretinal neovascularization. There may be an associated vitritis. The disease is progressive and chronic with variable response to immunosuppressive treatment.

### Retinal vasculitis

Retinal vascular inflammation most commonly affects the venous circulation (phlebitis, periphlebitis). Systemic associations are common and include sarcoidosis, Behcet's disease, and multiple sclerosis. Predominantly arterial inflammation (arteritis) is typically seen with infectious uveitis. Some connective tissue diseases and systemic vasculitides, including systemic lupus erythematosus and polyarteritis nodosa, do not manifest with visible retinal arterial inflammation but may cause retinal arterial occlusions. Idiopathic retinal vasculitis may be diagnosed when systemic and infectious disease (e.g. tuberculosis) has been excluded.

#### Clinical evaluation

##### History

Table 5.4 Conditions associated with retinal vasculitis		
Systemic disease	Infectious	Ocular disease
Sarcoidosis	Tuberculosis	Birdshot chorioretinopathy
Behcet's disease	Syphilis	Intermediate uveitis
Multiple sclerosis	Toxoplasmosis	Eales' disease
Systemic lupus erythematosus	Herpes viruses	
Polyarteritis nodosa	Whipple's disease	
Wegener's granulomatosis	Lyme disease	
Crohn's disease		

Painless blurring of vision or scotoma is the norm, sometimes with associated floaters. Asymptomatic if the posterior pole is spared.

##### Examination

- Cuffing or sheathing of retinal vessels (usually venules).
- Branch or central vascular occlusion: haemorrhages (venous occlusion).
- Vitritis.
- Retinal neovascularization.
- Other signs may give clues to diagnosis, for example granulomatous anterior uveitis (sarcoid, tuberculosis) or retinal infiltrates (Behcet's disease).

##### Investigations

Investigate potential cause with usual blood tests and CXR (see 5.4). If arterial disease include ANCA and ANA. Blood pressure and urinalysis are mandatory.

Fluorescein angiography may be useful in demonstrating the extent of involvement and ischaemia, and in identifying early neovascularization. Vessel staining, leakage, and closure are common angiographic features.

##### Treatment

- Systemic immunosuppression may be necessary for sight-threatening disease or underlying disease once an infectious cause has been excluded.

- Laser treatment has been used to ablate ischaemic retina when vitreous haemorrhage occurs from new vessels.
- Surgery for complications, which include cataract, glaucoma, vitreous haemorrhage, and tractional retinal detachment.

### Eales' disease

Henry Eales described a condition in which recurrent vitreous haemorrhage occurred in young men in 1880. Eales' disease is now recognized as an obliterative retinal vasculitis, commencing peripherally, usually in the absence of significant vitritis. New vessels will often form, hence the vitreous haemorrhage. An association with tuberculosis has evolved in Eales' disease, which is particularly common on the Indian subcontinent. This association is based on the frequency of positive tuberculin tests and the finding of increased frequency of *Mycobacterium tuberculosis* DNA in vitreous and epiretinal membranes from Eales' patients using PCR.

### Masquerade syndromes

Posterior uveitis presenting in older patients should raise suspicion of a masquerade, most commonly primary intraocular non-Hodgkin's lymphoma.

#### Aetiology

- Non-Hodgkin's lymphoma: most commonly primary CNS non-Hodgkin's lymphoma presenting within the eye (well patient). Rarely it is systemic non-Hodgkin's lymphoma metastasized to the eye (sick patient).
- Leukaemia.
- Metastatic carcinoma.
- Hodgkin's lymphoma: rarely metastasizes to the eye.

#### Clinical evaluation

Ocular lymphoma usually (but not always) presents in older patients (>50 years) with painless floaters and blurred vision. Subretinal infiltrates and vitritis are the common signs.

#### Investigations

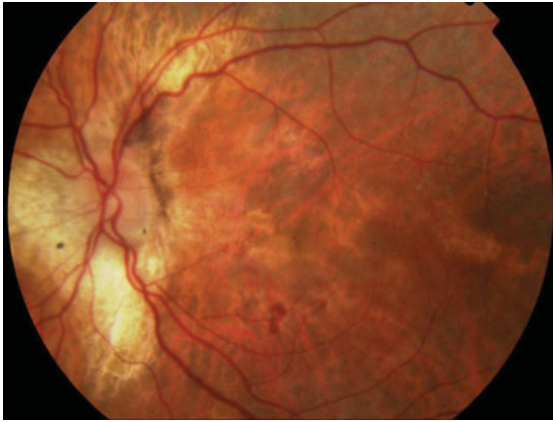If suspicion is high then MRI brain and cerebrospinal fluid sampling may provide the diagnosis; otherwise, vitrectomy and cytological analysis of vitreous cells may be required. Multiple vitreous samples (at different times) may be necessary before a diagnosis is made. Liaise with the oncology service.

#### Treatment

This depends on stage and grade. Ocular treatments include intravitreal methotrexate and ocular radiotherapy. Systemic chemotherapy is commonly employed.

#### Prognosis

An initial response is often good but recurrence is common. CNS non-Hodgkin's lymphoma has a 5 year survival rate of 5%.



**Fig. 5.15** Extensive peripapillary atrophy and scarring in the later stages of serpiginous choroidopathy.

## 5.7 Viral infectious uveitis

Intraocular viral infection is most commonly due to the herpes viruses, including HSV1 and 2, VZV, CMV, and more rarely EBV. In the anterior segment, herpes simplex and zoster viruses may manifest with a keratitis, uveitis, or keratouveitis. The classical presentation in the posterior segment is retinitis with retinal necrosis.

### HSV keratouveitis

This is most commonly seen with HSV stromal keratitis, rare with just epithelial disease.

#### Aetiology

HSV keratitis is discussed in section 1.18. It occurs due to reactivation of latent infection in the trigeminal ganglion. It is unclear whether uveitis is due to active viral infection of the iris or a reaction to corneal stromal infection.

#### Clinical evaluation

##### History

- May have had recurrent corneal disease.
- Pain, photophobia, blurred vision.

##### Examination

- Corneal stromal opacity or oedema with or without keratic precipitates.
- Corneal stromal vascularization, reduced sensation.
- Aqueous cells and flare.
- Regional iris transillumination, posterior synechiae.
- Reduced corneal sensation.

##### Differential diagnosis

- HZV.
- Bacterial/fungal/acanthamoeba keratitis.

##### Investigations

- Consider corneal scrape to exclude bacterial keratitis.

##### Treatment

- Aciclovir ointment for epithelial disease.
- Topical steroid for uveitis (consider delaying until epithelial disease treated).
- Role of oral antiviral drugs is unclear but some use aciclovir 400 mg BD for several weeks/months for chronic disease or recurrence prevention.

##### Complications

Glaucoma and cataract are common.

### Herpes zoster uveitis

#### Aetiology

This is usually directly preceded by HZO. There may be concurrent or antecedent corneal epithelial and/or stromal VZV disease.

#### Clinical evaluation

##### History

- Painful forehead rash in V<sub>1</sub> distribution.
- Pain, photophobia, blurred vision.

##### Examination

- Vesicular unilateral rash in V<sub>1</sub> distribution.
- Ocular signs are similar to HSV keratouveitis, although sector iris atrophy is more prominent and corneal opacity may be absent.

##### Differential diagnosis

- HSV keratouveitis.
- Chronic idiopathic anterior uveitis.

#### Investigations

- Consider investigating for immunocompromise (e.g. HIV) if there is severe disease in a young patient.

#### Treatment

- HZO should be treated with an oral antiviral agent such as aciclovir 800 mg five times per day or famciclovir 500 mg TDS for 7 days. If commenced early in the disease (within 3 days of rash) this may reduce risk of complications such as uveitis and post-herpetic neuralgia.
- Uveitis is treated in the usual way with topical corticosteroid and cycloplegia.
- Topical ocular hypotensives are frequently needed and the inflammation may be prolonged, necessitating slow tapering of topical corticosteroid.

#### Complications

- Dry eye, corneal opacity, neurotrophic cornea.
- Glaucoma, cataract.

### Retinitis

Viral retinitis has been described with somewhat confusing nomenclature, including the pathology-based terms acute retinal necrosis and progressive outer retinal necrosis (PORN), and the aetiology-based term CMV retinitis. Acute retinal necrosis is usually caused by HSV or VZV in immunocompetent individuals, whereas PORN (HSV or VZV) and CMV retinitis are seen in the immunocompromised. CMV and PORN disease are discussed in section 5.11.

#### Acute retinal necrosis

A necrotizing herpetic retinopathy usually presenting unilaterally in a well individual, but progressing to bilateral disease in one-third of patients within 6 weeks (although second-eye involvement may be delayed by many years).

##### Aetiology

DNA from HSV1 and 2 and VZV has been found in the vitreous of patients with acute retinal necrosis by PCR and both electron microscopy and immunohistochemistry have shown herpes virus within retinal biopsies. These viruses appear likely to be the cause of the disease. EBV may be an infrequent cause.

##### Pathophysiology

T- and B-lymphocyte infiltration, arteritis with vascular closure, and full-thickness retinal necrosis. Abrupt demarcation with healthy retina.

#### Clinical evaluation

##### History

- Usually well but some have recent history of varicella/shingles/herpes.
- Pain, red eye, floaters, blurred vision.

##### Examination

- Anterior uveitis, granulomatous keratic precipitates.
- Vitritis.
- White-yellow retinal lesions, becoming coalescent, often multifocal, usually mid-peripheral.
- Arteritis, occasionally haemorrhages.
- Disc swelling.

##### Differential diagnosis

- CMV retinitis/PORN (immunocompromise).
- *Toxoplasma* (pigmented scars, choroidal involvement).
- Syphilis.
- Lymphoma.

- Endogenous bacterial/fungal endophthalmitis.
- Behcet's disease (retinal infiltrates).
- Commotio retinae.

#### Investigations

- Appropriate history and investigation for potential immunocompromise, for example HIV.
- Syphilis serology.
- Most perform diagnostic vitreous biopsy with PCR for herpes viruses.

#### Treatment

May reduce retinal damage and risk of contralateral eye involvement.

- Intravitreal foscarnet (if vitreous biopsy taken).
- Traditionally then treated with intravenous aciclovir 10 mg/kg TDS for 10 days, followed by oral aciclovir 800 mg 5 times per day for 6 weeks (NB: watch renal function).
- Oral valacyclovir may be as effective and avoids prolonged hospital admission (e.g. 1 g TDS 6 weeks, followed by 500 mg for 6 weeks).
- Adjunctive oral prednisolone (0.5–1 mg/kg per day) may be used for the inflammatory component, commencing 24–48 hours after antiviral treatment, tapering according to clinical signs.
- Laser prophylaxis may reduce risk of retinal detachment.

#### Complications

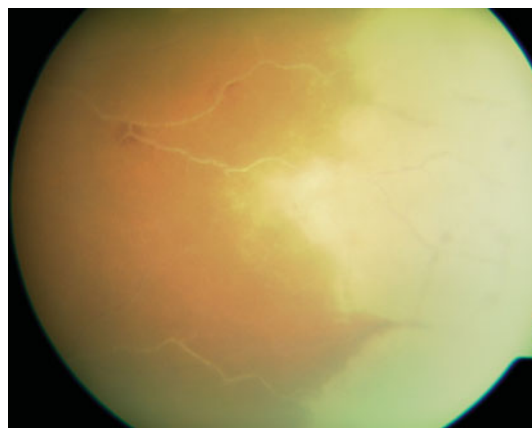
- Retinal detachment is common.
- Optic neuropathy (poor prognosis).
- Contralateral eye involvement.

#### Prognosis

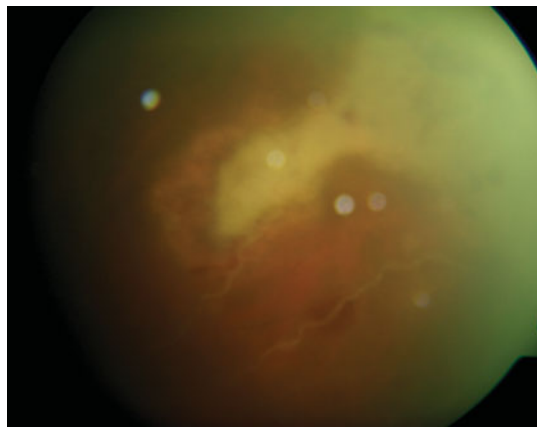
Retinal detachment (up to 84% patients) and optic neuropathy are the major causes of sight loss. Contralateral eye involvement is approximately halved (from 75 to 35%) at 2 years by antiviral treatment. 48% of eyes finish with a visual acuity of 6/60 or worse.

#### Other viral retinitis

CMV retinitis and PORN will be discussed in section 5.11.



**Fig. 5.16** A large confluent area of peripheral retinal necrosis due to herpes zoster retinitis in a renal transplant patient on high-dose immunosuppression. Note the associated retinal arterial sheathing.



**Fig. 5.17** Healing retinal necrosis from viral retinitis is seen as a margin of pigment epithelial atrophy at the leading edge. The retinal arterial changes have persisted.



## 5.8 Parasitic infectious uveitis

### **Toxoplasma retinochoroiditis**

Infection by the protozoan parasite *Toxoplasma gondii* results in disseminated infection which is often asymptomatic in adults but may have profound effects upon the developing foetus in the event of congenital (trans-placental) infection or in the immunosuppressed. The parasite has a predilection for muscle and the CNS where it is thought to lie dormant in tissue cysts for many years. Besides the syndrome of congenital toxoplasmosis, human infection-related morbidity is mainly restricted to retinochoroiditis resulting from reactivation in immunocompetent individuals and CNS manifestations in the presence of immunocompromise.

#### **Aetiology**

The definitive host is the cat in whose intestinal mucosa the parasite undergoes sexual reproduction. Human infection is acquired following ingestion of cysts, initially shed in cat faeces, which may contaminate drinking water or meat from animals ingesting ground-dwelling cysts. Thorough cooking destroys the cysts.

#### **Pathophysiology**

Retinochoroiditis occurs as a result of *Toxoplasma* tachyzoite proliferation either with primary infection (congenital or acquired) or delayed (often by many years) when bradyzoites within tissue cysts transform to the tachyzoite stage. Intense inflammatory responses are seen in immunocompetent individuals dominated by the CD4+ T-lymphocytes. Tissue damage (necrosis) is extensive and a full-thickness chorioretinal scar develops after conversion back to the encysted bradyzoite stage. Recurrent episodes of reactivation, typically at the margin of a scar, is a common feature but the cause of reactivation is unknown.

#### **Clinical evaluation**

##### **History**

- Particularly common in patients from West Africa and South America.
- May have had previous uveitis episodes.
- Pain, blurred vision, floaters.

##### **Examination**

- Aqueous cells and flare, large keratic precipitates.
- IOP often raised in acute stage.
- Vitritis, vitreoretinal adhesions.
- Fluffy yellow/white chorioretinal infiltration often at the margin of an established chorioretinal scar (typically pigmented).
- Retinal vascular (arterial or venous) cuffing/sheathing.

##### **Differential diagnosis**

- Viral, fungal, or bacterial retinitis.
- *Toxocara* retinitis.

##### **Investigations**

- Usually a clinical diagnosis.
- Serology may be useful for suspected primary infection (IgM-positive, no pigmented scar) or to exclude *Toxoplasma* (IgG-positive state does not confirm the diagnosis).
- Vitreous biopsy for PCR with or without IgG in suspicious cases.
- Consider HIV testing if severe/progressive disease.

##### **Treatment**

No randomized controlled trials proving benefit of treatment. Peripheral lesions may be left to spontaneously remit. Lesions threatening or involving the macular or optic disc or a major arcade vessel should be treated with one of the following regimens:

- clindamycin with or without sulphadiazine,
- trimethoprim plus sulphamethoxazole (Septrin),

- pyrimethamine plus sulphadiazine plus folinic acid (check FBC),
  - azithromycin with or without sulphadiazine.
- Treatment is usually combined with prednisolone (e.g. 0.5 mg/kg) commencing 24 hours after the first dose of antibiotic. Treatment should generally continue for 3 weeks at least.

#### **Complications**

- Transiently raised IOP.
- Cataract.
- Chronic vitreous opacities/floaters.
- Macular scar.
- Papillitis, retinal vascular occlusion.
- Epiretinal membrane.
- Retinal tear, vitreous haemorrhage, retinal detachment (due to abnormal vitreoretinal adhesion).

#### **Prognosis**

24% of cases have a visual acuity of less than 6/60 in the affected eye. Bilateral severe visual loss is rare (about 1%).

---

### **Toxocariasis**

The parasitic nematode *Toxocara canis* infects humans via ingestion of its eggs, found in dog faeces (puppies in particular). Larvae invade the intestine and migrate via the bloodstream throughout the body, often causing an acute systemic manifestation, visceral larva migrans.

#### **Pathophysiology**

The presence of a *Toxocara* worm in the eye causes an initial intense eosinophilic inflammatory response followed by a granulomatous reaction.

#### **Clinical evaluation**

Typically affects children (mean age 7.5 years) and is a cause of leukocoria. May be asymptomatic or cause red eye, pain, blurred vision, and strabismus.

##### **Examination**

- Typically causes raised, white chorioretinal granuloma at posterior pole or periphery. May be large.
- Usually accompanied by intense vitritis and anterior uveitis in active stage. Occasionally hypopyon.
- May present with retinitis or optic nerve disease (rare).

##### **Differential diagnosis**

- Retinoblastoma, *Toxoplasma*.
- Persistent hyperplastic primary vitreous.
- Coat's disease.
- Retinopathy of prematurity.

**Investigations**

- Serology.
- Ultrasound.

**Treatment**

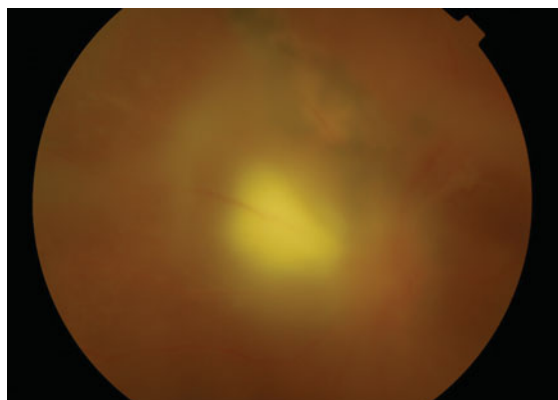
Consult paediatricians/physicians. Involves anti-helminthic (e.g. thia-bendazole) and topical and systemic corticosteroids for inflammatory response.

**Complications**

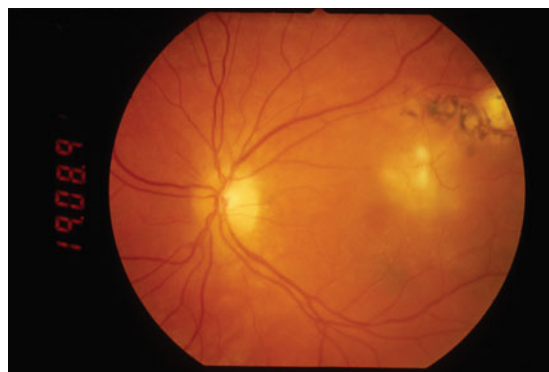- Tractional retinal detachment.
- Epiretinal membranes.
- Macular granuloma.

**Other parasitic causes of uveitis**

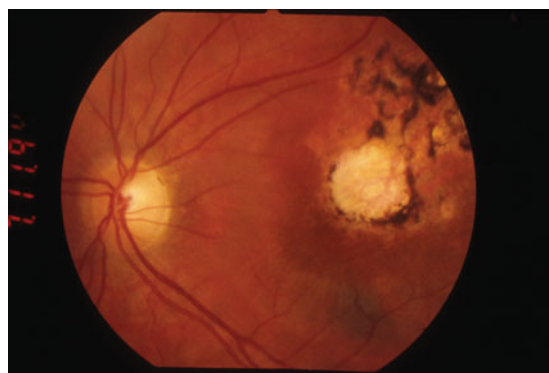Onchocerciasis ('river blindness') is a major cause of blindness in endemic areas (mainly central Africa). The causative nematode *Onchocerca volvulus* is transmitted by a bite from the infected *Simulium* black fly. Adult worms then form nodules throughout the body but especially in the skin. Microfilariae are the main cause of the ocular pathology, typically a sclerosing keratitis (the main cause of visual loss), and anterior uveitis. Cataract, glaucoma, vitritis, and choroiditis may develop. Traditionally diagnosed on 'skin snip' but newer methods (serology and antigen dipstick) are available. Treated by physicians specializing in infectious diseases.



**Fig. 5.18** 'Headlight in the fog': an active *Toxoplasma* retinochoroiditis lesion at the margin of a pigmented scar (seen superior to the fluffy white full-thickness infiltrate).



(a)



(b)

**Fig. 5.19** (a) Two small foci of active *Toxoplasma* retinochoroiditis adjacent to an old scar. (b) The full extent of the lesion is evident by the size of the resulting scar after resolution of the inflammation.

## 5.9 Fungal infectious uveitis

### Endogenous endophthalmitis

Blood-borne spread of fungi from distant sites to the eye is a rare but important cause of endophthalmitis as it benefits from early recognition and treatment. Typical sites of primary infection include indwelling urinary and venous catheters (particularly patients requiring prolonged hospital care) and injection sites of intravenous-drug abuse. Immunocompromised individuals are at particular risk (including those receiving systemic corticosteroids).

#### *Candida*

*Candida albicans* is the most common cause of fungal endophthalmitis, usually seen in intravenous-drug users and the chronically ill (as above). *Candida* may contaminate the lemon juice from a plastic container used as a solvent for diamorphine.

#### Clinical evaluation

##### Examination

- Acute or subacute; floaters, blurring of vision, pain.
- Susceptible individual.
- May be asymptomatic: found on screening of patients in the intensive care unit.

##### Signs

- Anterior uveitis (occasionally hypopyon), vitritis.
- Fluffy white 'puff balls' originating in the choroid and migrating through the retina and into the vitreous.
- Occasionally retinal haemorrhages and vascular cuffing.

##### Differential diagnosis

- *Toxoplasma* (look for pigmented scars, choroidal involvement).
- Bacterial endophthalmitis (tends to progress much faster).
- Viral retinitis.
- Syphilis.
- Lymphoma.
- Sarcoid.

##### Investigations

- Serology to exclude differential diagnoses.
- Cultures from blood and likely sources of fungaemia.
- Other investigations to identify source (e.g. abdominal ultrasound, echocardiogram).
- Vitrectomy and removal of vitreous infiltrates may be necessary to confirm diagnosis (e.g. if cultures are negative from blood and other sites), debulk infection, deliver intravitreal amphotericin.

##### Treatment

- Intravitreal 5–10µg amphotericin B (if vitreous sample taken).
- Intravenous/oral fluconazole or intravenous amphotericin B (watch renal function).
- Flucytosine may be used but resistance is not uncommon.

##### Complications

- Retinal detachment.
- Progressive infection.
- Complications of disseminated fungal infection.

#### *Aspergillus*

*Aspergillus* species are ubiquitous, filamentous fungi which may cause invasive human disease at any site but in particular the lungs. Immunocompromised hosts are at greatest risk, as are intravenous-drug users.

#### Clinical evaluation

The clinical features and context will be similar to *Candida* endophthalmitis. Unlike allergic bronchopulmonary aspergillosis, serology is of limited value in invasive *Aspergillus* disease.

#### Treatment

Consult the infectious diseases team. Give intravitreal and intravenous amphotericin B depending on general condition, renal status, and site of primary infection. Oral imidazoles may be an alternative.

#### Prognosis

The systemic prognosis with invasive *Aspergillus* is poor, as is the ocular prognosis, particularly if diagnosis and treatment are delayed.

### Presumed ocular histoplasmosis

*Histoplasma capsulatum*, a fungus endemic to the mid-western USA has been associated with a specific form of posterior uveitis found most commonly in that region, but rarely elsewhere in the world. Although *Histoplasma* has been recovered from eyes in the rare event of endogenous *Histoplasma* endophthalmitis, this has not been the case for the ocular histoplasmosis syndrome, hence use of the term presumed. An association with HLA B7 has supported the concept that the syndrome represents a form of hypersensitivity reaction to *Histoplasma* antigens.

#### Clinical evaluation

The typical findings are multiple discreet choroiditis lesions which predispose to subretinal neovascularization, macular pigmentary disturbance, peripapillary atrophy, and clear ocular media.

#### Treatment

Antifungal treatment is of no benefit and treatment is aimed at controlling the choroiditis with immunosuppression and dealing with the subretinal neovascularization, which is often amenable to surgical membrane removal.

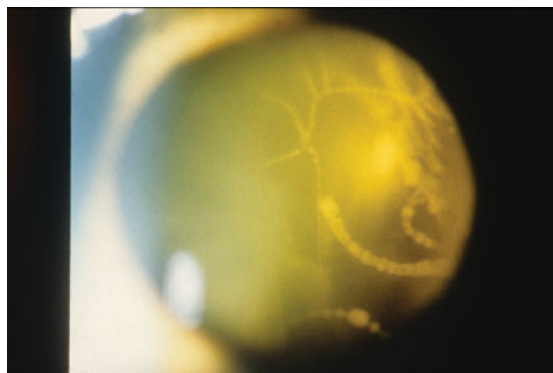
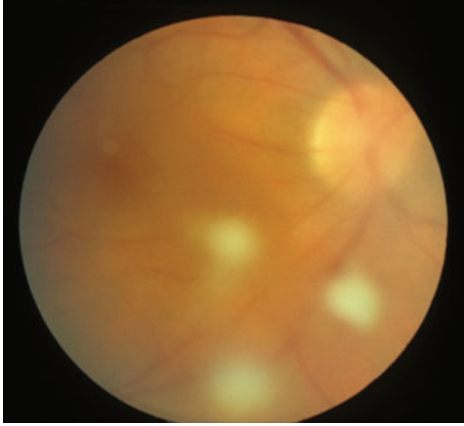


Fig. 5.20 'String of pearls' in the vitreous in *Candida* endophthalmitis.



**Fig. 5.21** Retinal and preretinal 'puff-balls' in Candida infection.

## 5.10 Bacterial infectious uveitis

### Tuberculosis

*Mycobacterium tuberculosis* infection should be considered in almost any form of ocular and adnexal inflammation. The condition is amenable to definitive (curative) antibiotic treatment, whereas injudicious immunosuppressive treatment has the potential to exacerbate ocular and systemic disease with potentially fatal consequences.

#### Pathophysiology

Primary ocular tuberculosis affects the ocular surface and adnexae as a result of direct (exogenous) infection. Secondary ocular tuberculosis occurs following haematogenous dissemination from a distant source of primary infection (commonly the lung) and most typically affects the deeper ocular structures and optic nerve. Tuberculous uveitis may result from active mycobacterial infection of the eye (e.g. choroidal tubercle) or as part of an immunological reaction (e.g. retinal vasculitis, phlyctenular conjunctivitis). Granulomatous inflammation is the hallmark of tuberculous disease.

#### Clinical evaluation

Patients originating from tuberculosis-endemic areas, and those with known tuberculosis (past or present) or tuberculosis contacts should raise suspicion. There is a wide spectrum of clinical presentation. Systemic symptoms (e.g. fever, weight loss, malaise, lymphadenopathy, cough) may or may not be present.

#### Ophthalmic presentations

These include:

- eyelid tubercle,
- phlyctenular conjunctivitis,
- interstitial keratitis,
- scleritis,
- granulomatous anterior uveitis/pan-uveitis,
- retinal periphlebitis (venous inflammation with haemorrhagic veno-occlusion),
- choroidal granuloma (fluffy, pale, raised subretinal lesion with or without subretinal fluid),
- optic neuropathy/orbital apex syndrome.

#### Investigations

- CXR, lymph node biopsy.
- FBC, CRP, ESR, liver-function test, renal profile.
- Serum ACE (sarcoid) plus syphilis serology (differential diagnoses).
- Tuberculin skin test or new *in vitro* lymphocyte stimulation tests (e.g. Quantiferon).

#### Treatment

Consult the infectious diseases/respiratory medicine team. Antituberculous treatment (e.g. rifampicin, pyrazinamide, isoniazid) for 6–12 months, usually combined with systemic corticosteroid to suppress inflammatory component and potential Jarisch–Herxheimer reaction (exaggerated inflammatory response due to massive bacterial lysis on commencing antibiotics). Topical corticosteroid as clinically indicated.

### Syphilis

The classical systemic manifestations of *Treponema pallidum* infection, almost exclusively sexually transmitted, can be sub-divided into four phases:

- **primary syphilis:** the chancre, a painless ulcer, usually on the genitalia, occurring 4 weeks after infection;

- **secondary syphilis:** 4–10 weeks later; generalized maculopapular rash, fever, headache, malaise, joint pain, lymphadenopathy; condylomata lata;
- **latent syphilis:** spontaneous remission of symptoms after 6–12 months, with occasional relapse; 30% progress to tertiary phase;
- **tertiary syphilis:** benign (gummas), cardiovascular, and neurosyphilis; neurosyphilis presents in a variety of ways including aseptic meningitis, encephalitis, tabes dorsalis, cranial nerve palsies and Argyll Robertson pupils (small, irregular with light-near dissociation).

#### Clinical evaluation

Ophthalmic manifestations are seen with congenital syphilis (interstitial keratitis, pigmentary retinopathy, glaucoma) and all the phases of acquired disease, although primary disease is limited to chancres of the lids and conjunctiva. Syphilis may cause almost any inflammatory ophthalmic disease, including dacryoadenitis, conjunctivitis, scleritis/episcleritis, keratitis, uveitis, and optic neuropathy. The typical features of syphilitic intraocular inflammation are a granulomatous anterior uveitis (mutton fat keratic precipitates, iris nodules), vitritis, choroiditis, retinal vasculitis, neuroretinitis, and macular oedema.

#### Investigations

Serological tests, for example VDRL test and rapid plasma reagin. Be cautious about false-positive results (e.g. other spirochetal disease, connective tissue disease, pregnancy). Neurosyphilis is confirmed on cerebrospinal fluid sampling.

#### Treatment

Penicillin is the mainstay of treatment, which should be overseen by an infectious diseases specialist. The Jarisch–Herxheimer reaction (see tuberculosis treatment, above) may complicate initial antibiotic therapy.

#### Prognosis

Syphilis usually responds well to appropriate treatment.

### Lyme disease

Lyme disease is caused by the spirochaete *B. burgdorferi*, transmitted by the bite of *Ixodes* ticks which commonly parasitize deer. Patients may recall a tick bite and will usually have been in parkland or woodland containing deer. The characteristic first symptom is a spreading rash called erythema chronicum migrans. Later features include fever, arthralgia, cardiac involvement, meningitis, and cranial nerve palsies. The eyes may be affected by seventh nerve palsy, conjunctivitis, episcleritis, anterior uveitis, choroiditis, and retinal vasculitis. Diagnosis is made serologically and treatment with oral tetracycline or amoxicillin usually effective. Severe neurological or uveal involvement may necessitate intravenous penicillin/cephalosporin treatment.

### Endogenous bacterial endophthalmitis

The clinical presentation of endophthalmitis (severe, painful intraocular inflammation with or without hypopyon) in the absence of exogenous source (e.g. surgery, penetrating injury, or suture abscess) should prompt the diagnosis of endogenous (blood-borne) intraocular infection. The presentation may, however, not be as florid and subtle signs such as Roth spots (white centred retinal haemorrhages representing microabscesses) should also raise the same suspicion. Common sources include endocarditis, urinary infection, intravenous lines, intravenous-drug use, skin infection, pneumonia, and abdominal abscess.



## Clinical evaluation

### History

There may be an obvious source of infection or fever. Ask about infective symptoms and intravenous-drug use.

### Examination

- Varied findings.
- Mild to severe intraocular inflammation.
- Hypopyon not uncommonly seen.
- Typical posterior segment findings are vitritis and areas of white retina (retinitis/retinal necrosis).
- Severe infections may evolve into pan-ophthalmitis (involving ocular adnexae).

### Investigations

- Thorough clinical examination for source of sepsis (including the entire skin).
- Cultures of urine, blood, intravenous catheters, etc., with or without vitreous.
- Imaging (e.g. echocardiography, CXR, abdominal ultrasound/CT).
- Involve general physicians.

### Treatment

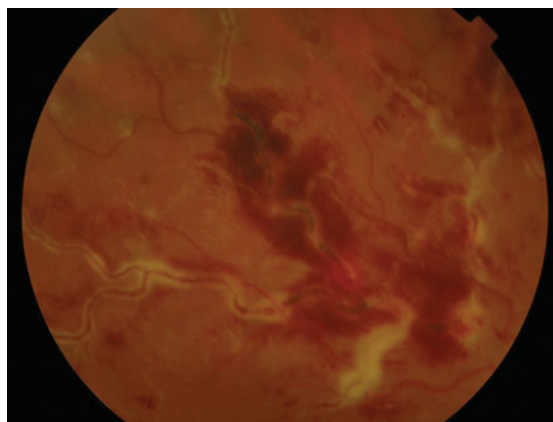
Dependent upon clinical scenario. Intravitreal antibiotics should be given if vitreous sampling is performed (e.g. ceftazidime and vancomycin). Broad-spectrum intravenous antibiotics should be given until culture and sensitivities available. Evisceration may be required in severe cases. Topical steroid and cycloplegia.

### Prognosis

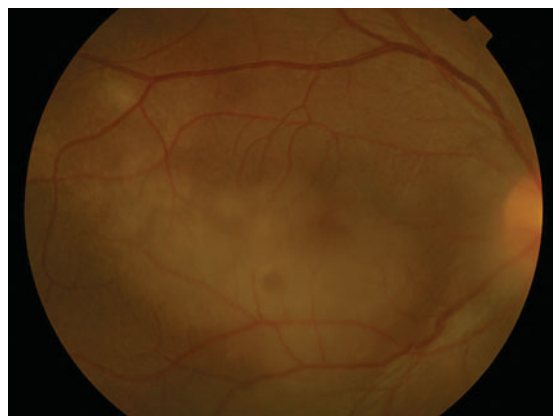
Very poor in severe cases.

## Exogenous bacterial endophthalmitis

This is the result of infection introduced locally to the eye, most commonly after surgery (e.g. after cataract surgery) or trauma, but also following ocular surface infections such as microbial keratitis or blebitis. Postoperative endophthalmitis is discussed in section 6.6. Vitreous sampling and injection of intravitreal antibiotics are important to identify the infecting organism and its sensitivity to antibiotics and to deliver high-dose antibiotic in an attempt to limit the damage caused by the infection are also necessary. Topical antibiotics and topical steroids with cycloplegia. Some use systemic steroids from 24–48 hours after commencing antibiotic.



**Fig. 5.22** Tuberculosis hypersensitivity occlusive retinal periphlebitis: venous cuffing and associated haemorrhagic occlusion.



**Fig. 5.23** A syphilitic choroidal plaque.

## 5.11 HIV-related disease

Much of the contents of this section may be applied to patients without HIV/AIDS but with immunocompromise for other reasons (e.g. lymphoproliferative/bone marrow disease, immunosuppressive drugs).

### HIV

HIV1 and 2 are retroviruses which ultimately cause severe immunocompromise mainly through infection and depletion of CD4+ T cells. Infection is transmitted most commonly through sexual intercourse although vertical transmission and needle-sharing by intravenous-drug users is another common route.

#### Clinical evaluation

Many individuals will experience an acute viral syndrome within 6 weeks of acquiring the infection. Fever, rash, pharyngitis, myalgia, and headache are common. The disease is then typically asymptomatic for several years before the onset of AIDS when low CD4+ counts lead to opportunistic infections such as *Pneumocystis carinii* (pneumonia), *Cryptococcus* (e.g. meningitis), and CMV (e.g. retinitis) or malignancy such as Kaposi sarcoma and lymphoma. HIV may cause an encephalopathy, sometimes leading to dementia and a progressive multifocal leucoencephalopathy (PML) may also be seen due to a papovavirus known as JC virus. This condition has no known therapy other than to improve the immunocompromise.

#### Treatment

Highly active antiretroviral therapy (HAART) has revolutionized the management and outlook for patients with HIV and AIDS. HAART usually consists of triple (or quadruple) therapy usually including reverse transcriptase inhibitors with or without protease inhibitors. The decision to commence treatment depends upon the CD4+ count, viral load and presence of opportunistic infections.

### Ophthalmic manifestations of HIV/AIDS

#### Lids

Molluscum, Kaposi sarcoma.

#### Conjunctiva/cornea

Kaposi sarcoma, HSV/HZV infection, microsporidial conjunctivitis/keratitis, dry eye (common).

#### Posterior segment

- Retinal microvasculopathy (common).
- Opportunistic infections:
  - CMV retinitis (common),
  - PORN (usually HZV),
  - Syphilis, tuberculosis,
  - *Toxoplasma* (more severe than in immunocompetency),
  - cryptococcal or pneumocystis choroidopathy,
  - *Candida*.
- Intraocular non-Hodgkins lymphoma.
- Optic neuropathy:
  - acute, inflammatory during seroconversion,
  - chronic atrophy (possibly ischaemic) during later stages,
  - infiltrative/infective (cryptococcal, syphilis, tuberculosis).
- Herpetic acute retinal necrosis (may have normal CD4+ count).

#### Retinal microvasculopathy

This is the most common ocular manifestation of HIV, occurring in 40–60% patients, more commonly seen with lower CD4+ counts.

#### Aetiology

The exact cause is unknown. Hypotheses include immunoglobulin deposition and endothelial cell HIV infection.

#### Clinical evaluation

Usually asymptomatic, but may cause scotoma or blurring.

#### Signs

Multiple cotton-wool spots and occasionally microaneurysms. No vitreous inflammation.

#### Treatment

Not indicated.

### CMV retinitis

Rare in immunocompetent individuals but common in AIDS (up to 40% before the availability of HAART). CD4+ counts are usually fewer than 50 cells/ $\mu$ L. Also a recognized complication of organ transplantation with antirejection therapy.

#### Aetiology

Either haematogenous spread to the retina or reactivation of latent infection due to immunocompromise.

#### Pathophysiology

Viral proliferation within the sensory retina causing retinal necrosis and retinal vasculitis.

#### Clinical evaluation

##### History

Subacute presentation with blurring, field loss. May be asymptomatic.

##### Examination

- Mild vitritis (unlike acute retinal necrosis in immunocompetent patients).
- May be peripheral or posterior pole, multifocal or unifocal.
- Initially small white retinal infiltrates (similar to a cotton-wool spot).
- Spreading white areas of retina (necrosis) with associated intraretinal haemorrhage (so-called pizza fundus).
- Retinal vascular cuffing (especially arterial).
- Rarely frosted branch angiitis (widespread arterial cuffing).
- RPE atrophy/granularity in areas of clearing.
- Progression is usually slow.

#### Differential diagnosis in a known HIV+ patient

- HSV/VZV retinitis, syphilis, *Toxoplasma*.
- Retinal microvasculopathy.
- Lymphoma.

#### Investigations

- Usually HIV/low CD4+ count will have already been diagnosed: a clinical diagnosis can usually be made in typical cases.
- HIV test and CD4+ count if not already done.
- Liaison with HIV physician.
- Vitreous sampling rarely needed unless diagnosis is in doubt.

#### Treatment

Previously intravenous ganciclovir or foscarnet and intravitreal ganciclovir implants were the mainstay.

Contemporary management depends upon the location of the lesion and immediate threat to vision. HAART may be used to control the disease in the absence of anti-CMV treatment with peripheral lesions, but response may take months so close observation is necessary. For sight-threatening disease HAART should be combined with anti-CMV treatments which may include:

- ganciclovir IV (watch for neutropenia, may be combined with granulocyte colony-stimulating factor), or implant,
- foscarnet (watch renal function and electrolytes),

- cidofovir (watch renal function),
- valganciclovir (orally administered pro-drug of ganciclovir),
- fomivirsen intravitreal injections.

### Complications

- Macular or optic nerve involvement.
- Retinal detachment.
- Cystoid macular oedema (reversible).

### Screening

Since patients with early CMV retinitis may be asymptomatic, some recommend screening of all patients with CD4+ counts of fewer than 50 cells/ $\mu$ l every 3–4 months.

### Immune recovery uveitis

A non-infectious intraocular inflammation developing in a patient with CMV retinitis (may be inactive) in whom HAART causes a rise in CD4+ count. Thought to represent an appropriate immune attack upon viral antigens. Usually manifests with vitritis and anterior uveitis. May require treatment with topical, periocular, or intraocular steroid (avoid systemic treatment if possible).

## Other posterior segment manifestations

### Progressive outer retinal necrosis (PORN)

The use of terms like PORN may be less useful than simply viral retinitis since these conditions have overlap and whereas most cases of PORN have been shown to be due to VZV, HSV has also been found. PORN represents a manifestation of herpetic retinitis in the immunocompromised, although classical acute retinal necrosis may also be seen.

### Clinical evaluation

#### History

Blurring and floaters.

#### Examination

Deep retinal white patches which spare the inner retina and retinal vessels initially. Usually multifocal and at posterior pole.

### Treatment

Systemic acyclovir or valaciclovir and HAART. Variable response to treatment.

### Toxoplasma retinochoroiditis

More severe in immunocompromised hosts than healthy individuals (see section 5.8), often presenting bilaterally. Tends not to spontaneously regress, with progressive disease causing extensive tissue destruction. Treatment in immunocompromised individuals differs from the normal situation: antibiotic therapy *without* corticosteroid for all lesions, often with a good response.

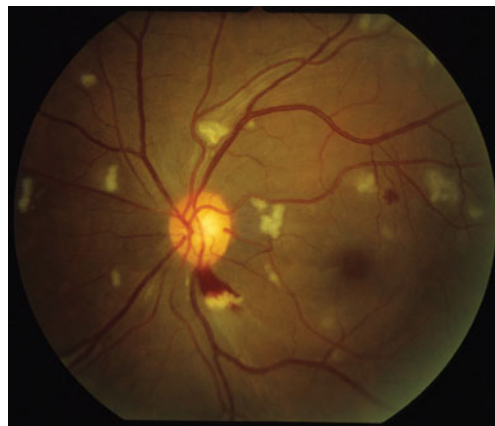### Choroiditis

Choroiditis due to opportunistic infection by either *P. carinii* or *Cryptococcus* are relatively unusual presentations (*Pneumocystis* choroiditis is more common). Typically presenting as a multifocal choroiditis without significant vitritis, patients will usually be severely immunocompromised, and may have disseminated infection. *Pneumocystis* may respond to systemic pentamidine or co-trimoxazole, whereas cryptococcal disease requires amphotericin B followed by fluconazole.

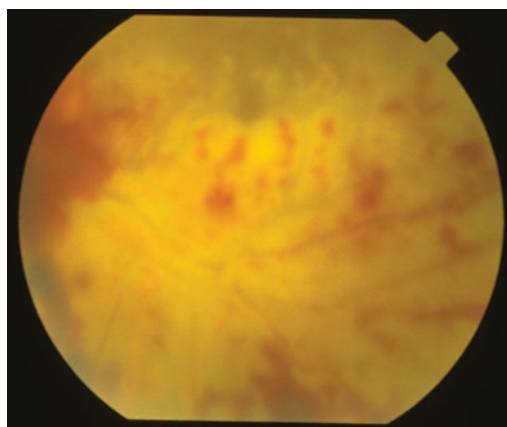
### Optic neuropathy

- Acute painful retrobulbar optic neuropathy has been described during HIV seroconversion. This may respond to corticosteroid.
- Other optic neuropathies in HIV-positive patients, particularly in the immunocompromised, should prompt a search for an infective cause. MRI is helpful to exclude perineuritis, often seen with syphilis, tuberculosis, and *Cryptococcus*:
  - exclude syphilis (serology),

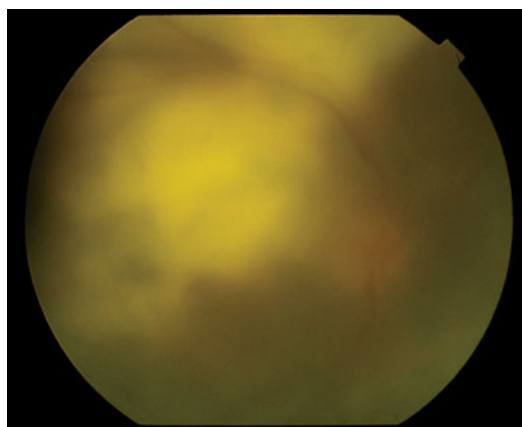
- consider CMV (serology, serum DNA quantification),
- consider tuberculosis (CXR, Mantoux test, MRI),
- consider *Cryptococcus* (MRI with or without cerebrospinal fluid).
- Chronic optic atrophy: may be due to microvasculopathy.



**Fig. 5.24** Asymptomatic retinopathy in HIV infection (HIV microangiopathy). Cotton-wool spots are typical but haemorrhages may occur also.



**Fig. 5.25** Typical haemorrhagic retinal necrosis seen in CMV retinitis in AIDS (CD4+ count usually <50 cells/ $\mu$ l).



**Fig. 5.26** Extensive, progressive *Toxoplasma* retinochoroiditis in AIDS.

## 5.12 Uveitis: systemic associations I

### Sarcoidosis

Sarcoidosis is a chronic, multisystem, granulomatous inflammatory disease affecting almost any organ but most typically the lungs, skin, and eyes. It is most common in Afro-Caribbeans.

#### Aetiology

The cause remains unknown although various hypotheses have developed over the years. The most credible of these include the involvement of an infectious agent, either persisting intracellularly (e.g. mycobacteria, *Propionibacterium acnes*) or causing sensitization after a previous infection. Disease clustering geographically (e.g. outbreak on the Isle of Man, UK) and seasonally (most commonly presents in spring/summer) support an environmental agent.

#### Pathophysiology

Non-caseating granulomata composed of macrophages and T-lymphocytes are seen on histology. Depressed cell-mediated immunity may be seen, potentially causing anergic responses on skin testing with tuberculin.

#### Clinical evaluation

##### Non-ocular

- Constitutional: patients with active sarcoidosis may complain of fever, sweats (particularly at night), and weight loss.
- Thoracic (90% patients): bilateral hilar lymphadenopathy is common and in the absence of parenchymal lung disease is described as stage I on CXR staging. Parenchymal lung disease (stage II with bilateral hilar lymphadenopathy, stage III without bilateral hilar lymphadenopathy) may progress to pulmonary fibrosis with bullae and bronchiectasis (stage IV). Symptoms are breathlessness and a persistent dry cough.
- Cutaneous: erythema nodosum (tender, red/dark nodules on the lower leg), cutaneous granulomata, lupus pernio (superficial, blue/purple patched often on nose and cheeks).
- Lymphadenopathy.
- Musculoskeletal: arthralgia, dactylitis, lytic bone lesions
- Neurosarcoid: CNS parenchymal and meningeal disease, cranial neuropathies.
- Cardiac: conduction block, cardiomyopathy, cor pulmonale.
- Gastrointestinal: liver granulomas are common but bowel involvement is rare.
- Renal: stones due to hypercalcaemia, nephritis.
- Other: parotid, submandibular and lacrimal gland involvement.

##### Ocular (25–75% of patients)

- Lacrimal gland: enlargement, dry eye.
- Conjunctiva: granulomata (biopsy of these may confirm diagnosis).
- Uvea: granulomatous uveitis is the typical finding in ocular sarcoidosis:
- anterior uveitis may be chronic or acute, painful or painless; iris nodules, posterior synechiae, and mutton fat keratic precipitates are all common.

##### Posterior segment findings

These include:

- vitritis: commonly forms inferior 'snowballs',
- retinal vasculitis: typically a periphlebitis with 'skip' lesions. Occasionally marked perivenous granuloma/exudation 'taches de bougie' or 'candle wax dripping'. May cause retinal ischaemia and neovascularization,

- cystoid macular oedema,
- retinal granulomata are uncommon; preretinal granulomata (Lander's sign),
- choroidal disease can be varied: choroidal granulomata, atrophy, subretinal neovascularization,
- optic disc: swelling (function usually preserved), infiltration, and papillitis (function affected).
- Optic nerve: optic neuropathy from perineural/dural involvement or parenchymal granuloma.

#### Investigations

Presumptive diagnosis may be based on findings of CXR/high-resolution chest CT and raised serum ACE but definitive diagnosis requires histological confirmation. Common biopsy sites include transbronchial, conjunctival, lacrimal gland, lymph node, or skin (in the presence of a rash). Kveim test (intradermal injection of sarcoid tissue) is no longer used in routine practice. Supportive investigation findings include hypercalcaemia, lymphopenia, polyclonal hypergammaglobulinaemia, pathological uptake on gallium scanning, and anergy on tuberculin testing.

#### Treatment

May be dictated by ocular or systemic morbidity and patients are usually best managed in conjunction with a respiratory physician. Topical, periocular, and systemic corticosteroids are frequently used for ocular disease and are usually effective. Second-line agents may be necessary.

#### Prognosis

The ocular prognosis is variable and dependent on clinical features. Secondary glaucoma, macular involvement (oedema or choroiditis), and optic neuropathy are common causes of irreversible visual loss. Systemic sarcoidosis spontaneously resolves within 5 years in 60%.

### Behcet's disease

This is a chronic multisystem vasculitis characterized by oro-genital ulceration associated most commonly with inflammatory lesions of the eyes, skin, and joints. CNS and gastrointestinal involvement and thrombo-occlusive events are also seen and can prove fatal. The disease is notable for its geographic variation with predilection for countries of the Mediterranean Basin and the Far East with the highest prevalence found in Turkey (42/10,000 population). The disease is slightly more common in males, in whom it tends to be more severe.

#### Aetiology

The aetiology of Behcet's disease remains unclear but environmental factors such as infectious triggers are likely to be involved in conjunction with a background of genetic susceptibility. In particular there has been interest in the role of microbial heat-shock proteins, which have sequence homology with human mitochondrial heat-shock proteins. A well-documented association exists between Behcet's disease and HLA-B 51.

#### Pathophysiology

The pathological basis for Behcet's disease appears to be a vasculitis with lymphocytes, macrophages, and neutrophils infiltrating vessel walls and perivascular space. Neutrophil hyperreactivity and abnormal T-lymphocyte homeostasis are found.



## Clinical evaluation

**Table 5.5 Diagnostic criteria of the Behcet Disease, Research Committee of Japan (1987 revision). Complete Behcet's disease requires all four major criteria. Incomplete Behcet's disease needs three major or two major with two minor criteria, or typical ocular disease with either one other major criterion or two minor criteria.**

Major criteria	Minor criteria
Recurrent oral ulceration	Arthritis
Skin lesions: - erythema nodosum, - pathergy, - folliculitis	Intestinal involvement Vascular occlusion Epididymitis Neuropsychiatric
Genital ulceration	
Ocular inflammation (uveitis)	

The International Study Group for Behcet Disease proposed a similar set of classification criteria in 1990 but stipulated the absolute need for recurrent oral ulceration to make the diagnosis. Recurrent oral ulceration is the hallmark of Behcet's disease and may be found on the gums, lips, tongue, palate, or pharynx. Cutaneous hypersensitivity is a common finding, with patients often describing a pustule forming at sites of skin injury (e.g. needle-entry site), so called pathergy. Major morbidity and mortality are the result of vascular occlusions (e.g. hepatic portal vein, cerebral venous sinus) and CNS involvement.

### Ocular disease

- Anterior uveitis, typically painless. Hypopyon common. Painless hypopyon is almost pathognomonic of Behcet's disease.
- Posterior segment signs:
  - vitritis,
  - occlusive retinal periphlebitis (may mimic BRVO),
  - retinal infiltrates,
  - papillitis, disc swelling,
  - retinal (with or without anterior segment) neovascularization.

### Investigations

Behcet's disease is a clinical diagnosis. HLA testing (for B51) is rarely contributory because of the low specificity and sensitivity.

### Management

Management is best carried out in a multidisciplinary fashion, including rheumatologists and oral physicians.

### Common medications

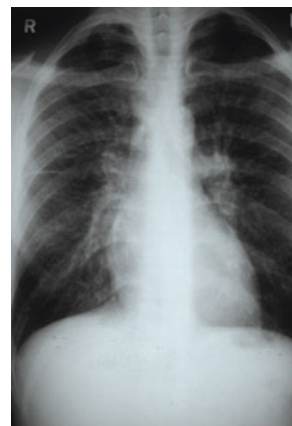
- Colchicine: particularly used for mucocutaneous disease.
- Systemic corticosteroid: may be useful for acute exacerbations but rarely practical as a single therapy.
- Cyclosporin and azathioprine: evidence of benefit, often used in conjunction with steroid. Tacrolimus and mycophenolate may be used in the same way.
- Cyclophosphamide.
- Interferon  $\alpha$ : expensive and with significant side effects, but shown to be particularly efficacious.
- Anti-tumour necrosis factor  $\alpha$  (TNF $\alpha$ ) treatments may be effective.

### Complications

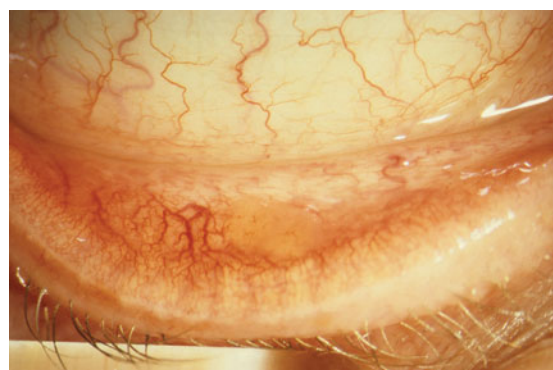
Ischaemic complications are the main cause of visual loss, including BRVO or CRVO, optic atrophy, and neovascularization causing vitreous haemorrhage, tractional detachment, or glaucoma.

## Prognosis

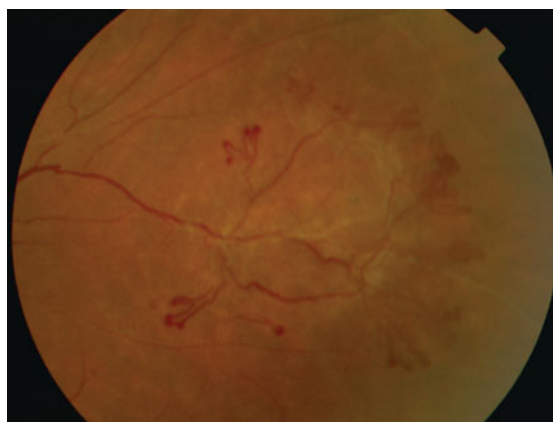
In the past severe visual loss was seen in over 50% of males, but in an era of greater treatment options this has reduced to about 25% becoming blind in one or both eyes.



**Fig. 5.27** Bilateral hilar lymphadenopathy in sarcoidosis.

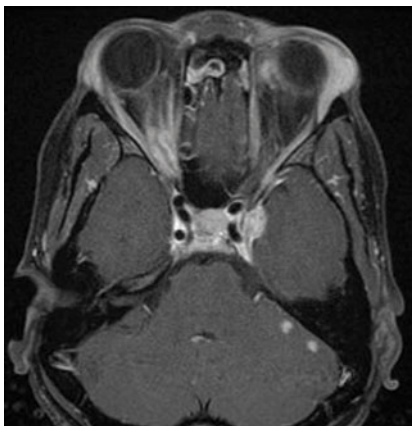

**Fig. 5.28** Conjunctival granuloma in sarcoidosis.

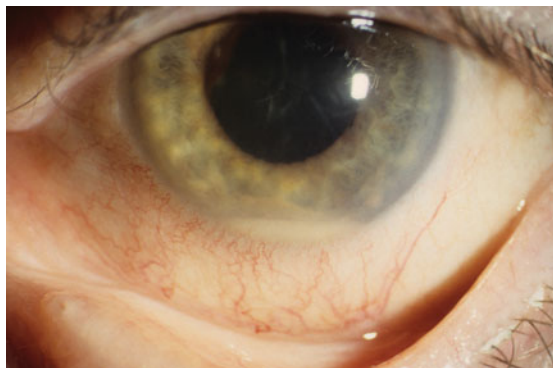


**Fig. 5.29** Peripheral new vessels in ischaemic retinal vasculitis due to sarcoidosis.

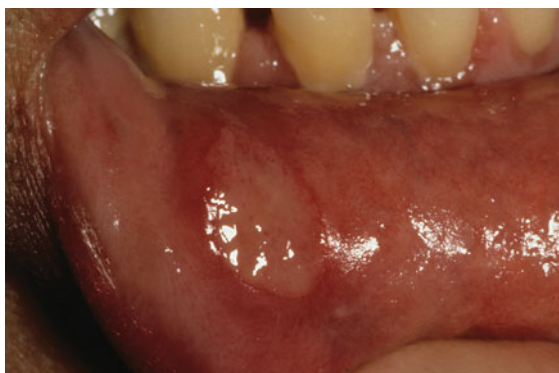



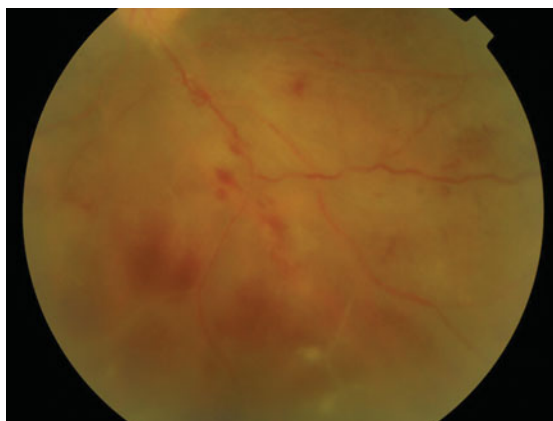
**Fig. 5.30** Optic nerve sheath disease on the right side in sarcoidosis shown in this contrast enhanced T1-weighted MRI.



**Fig. 5.32** Severe, but painless anterior uveitis causing a hypopyon in Behcet's disease.



**Fig. 5.31** Aphthous ulceration of the oral mucosa in Behcet's disease.



**Fig. 5.33** Vitritis, occlusive retinal phlebitis and retinal infiltrates (inferiorly) in Behcet's disease.

*This page intentionally left blank*

## 5.13 Uveitis: systemic associations II

### Multiple sclerosis

Multiple sclerosis is a neuroinflammatory disorder characterized by demyelination of CNS axons. Onset is usually in the third to fifth decades in persons spending their childhood in temperate regions of the northern hemisphere (e.g. northern Europe, North America). The condition is associated with intermediate uveitis (pars planitis) and retinal vasculitis.

#### Aetiology

The aetiology of multiple sclerosis remains unclear although environmental and genetic factors are likely to be involved. The increased prevalence further from the equator is supportive evidence for an environmental trigger with hypotheses including a persistent viral infection or antecedent infection causing autoimmunity through molecular mimicry. First-degree relatives of multiple sclerosis patients have an increased risk of the disease.

#### Pathophysiology

CNS lesions or plaques consist of axonal demyelination with predominantly lymphocytic infiltration. Within the retina a segmental perivenous lympho-plasmacytic infiltrate is seen.

#### Ophthalmic features

The foremost ophthalmic manifestation of multiple sclerosis is an acute demyelinating optic neuropathy and ocular motility disturbances which are discussed in detail in section 9.9. Retinal periphlebitis is relatively common (approximately 10%) and often asymptomatic with rare visual morbidity. Intermediate uveitis and anterior uveitis are both seen more commonly in multiple sclerosis patients. Vitreous haemorrhage may occur in those with intermediate uveitis and retinal periphlebitis due to retinal neovascularization.

#### Investigations and management

The investigations for multiple sclerosis are discussed further in section 9.9. Management of the uveitis does not differ from other cases of non-infectious anterior and intermediate uveitis, although anti-TNF $\alpha$  treatment should be avoided because of reports that it may exacerbate multiple sclerosis.

### Seronegative arthritides

This group of rheumatoid factor-negative conditions is associated with HLA B27 and predisposes to ocular inflammation, which is usually an anterior uveitis. In the UK 52% of anterior uveitis patients are HLA B27-positive.

#### Ankylosing spondylitis

A chronic, painful arthritis, predominantly affecting the spine and sacroiliac joints, often causing eventual fusion (so-called bamboo spine). Males more commonly affected (3:1), with onset usually between 16 and 40 years. Other large joints may be affected (e.g. hips, knees). Approximately 90% are HLA B27-positive. Extra-articular manifestations include anterior uveitis, aortitis (leading to aortic regurgitation), and pulmonary fibrosis. The diagnosis is usually made on the basis of a sacroiliac X-ray. Management usually involves physiotherapy and NSAIDs.

#### Ophthalmic features

Recurrent non-granulomatous anterior uveitis is common, typically acute rather than chronic, unilateral (alternating) and often severe (occasional hypopyon) and painful with high incidence of posterior synechiae. Cystoid macular oedema is not uncommon.

#### Reiter syndrome

Hans Reiter described an acute febrile illness with arthritis, conjunctivitis, and urethritis following an episode of bloody diarrhoea in 1916.

The disease classically follows an infection of the bowel (e.g. *Shigella*, *Campylobacter*, *Salmonella*) or genital tract (*Chlamydia*), which is thought to trigger autoimmunity through molecular mimicry in susceptible individuals. Approximately 60% are HLA B27-positive.

#### Systemic features

Unlike ankylosing spondylitis, Reiter syndrome has an acute onset often with associated fever.

#### Cardinal features

- **Arthritis:** pauciarticular, usually affecting the sacroiliac joints and larger joints of the lower limb.
- **Urethritis** will be sterile unless the trigger was *Chlamydia*. A circinate balanitis (ulceration of the glans penis) may be present.
- **Conjunctivitis:** sterile and bilateral.
- Other systemic features include keratoderma blennorrhagica: pustular rash usually on palms and soles; oral ulcers, onycholysis, and aortitis.

#### Ophthalmic features

The conjunctivitis is non-cicatrizing, mucopurulent, and usually mild and self-limiting. There may be papillary change. A keratitis has been reported. Acute anterior uveitis with Reiter syndrome behaves in a similar way to that seen with ankylosing spondylitis with acute, painful non-granulomatous recurrences.

#### Psoriatic arthritis

Arthritis is seen in 10% of patients with psoriasis, a common (2% prevalence) inflammatory skin condition characterized by scaly plaques. Those with nail changes are more predisposed to arthritis which may be an asymmetric oligoarthritis (similar to other seronegative arthritides) or symmetric polyarthritis sometimes causing a severe destructive picture (arthritis mutilans). Psoriasis patients with arthritis appear to be more prone to anterior uveitis than arthritis-free psoriasis sufferers. In comparison with ankylosing spondylitis and Reiter syndrome, the rate of HLA B27 positivity is lower (30–40%) and the uveitis less frequent (7%) and more likely to be chronic and involve the vitreous.

#### Inflammatory bowel disease

Some 2% patients with inflammatory bowel disease (Crohn's disease and ulcerative colitis) will develop uveitis. Although this is most commonly a recurrent anterior uveitis similar to that seen in ankylosing spondylitis, these patients may also develop posterior segment inflammation including vitritis and retinal periphlebitis.

### Juvenile idiopathic arthritis

A chronic arthritis in children who are normally rheumatoid factor-negative. Disease may be pauciarticular (four or fewer joints in first 6 months) or polyarticular. Females with pauciarticular disease and positive ANA are at greatest risk of uveitis. Uveitis is rare in juvenile arthritis presenting with systemic disease (fever, rash, hepatosplenomegaly).

#### Clinical evaluation

##### History

Uveitis is usually chronic, bilateral, and painless. Blurring of vision may be noticed incidentally, or the parents may notice a strabismus or altered pupil (synechiae or dense cataract). However, many are referred for screening via paediatricians. The lack of redness and pain and the unreliability of symptom reporting in children necessitate screening of juvenile idiopathic arthritis patients depending on risk.

**Examination**

- Cells and flare in anterior chamber.
- Posterior synechiae.
- Vitreous cells and macular oedema occasionally.

Later:

- band keratopathy,
- cataract,
- glaucoma or hypotony.

**Investigations**

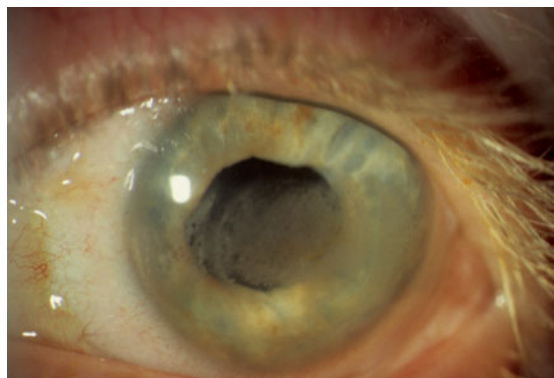Refer to paediatrician if undiagnosed joint symptoms. Exclude other causes of uveitis (e.g. juvenile sarcoid, *Toxocara*, tuberculosis, HLA B27). Frequent review (at least 3 monthly) in those with identified uveitis.

**Screening**

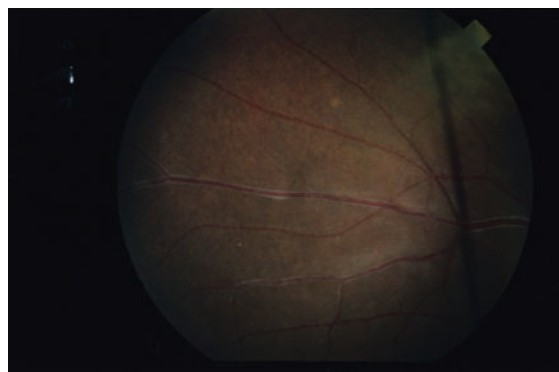
Uveitis is more common in pauciarticular (20%) than polyarticular (5%) arthritis. Due to the asymptomatic nature screening is necessary and frequency depends on type, age of onset, and ANA positivity. Current recommendations from the UK Royal College of Ophthalmologists propose 2 monthly examinations from onset of arthritis for 6 months, then 3–4 monthly screening for up to 8 years depending on age of onset and type. Others suggest screening all until 12 years of age.

**Treatment**

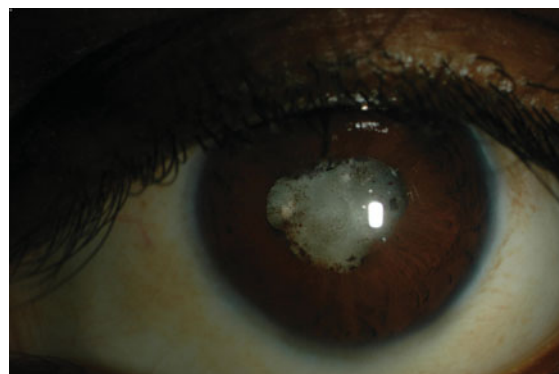
- Topical steroids: mainstay of treatment (check pressure).
- Methotrexate.
- Surgery for cataract, band keratopathy, and glaucoma.
- Anti-TNF $\alpha$  agents (etanercept, infliximab).



**Fig. 5.36** Band keratopathy from chronic uveitis in juvenile idiopathic arthritis.



**Fig. 5.34** Asymptomatic retinal periphlebitis associated with multiple sclerosis.



**Fig. 5.35** Extensive posterior synechiae and a white cataract secondary to chronic uveitis in juvenile idiopathic arthritis.

## 5.14 Scleritis and episcleritis

Episcleritis is an acute, relatively mild, and non-sight-threatening inflammation involving the episclera (loose vascular connective tissue between Tenon's capsule and the surface of the sclera). In contrast, scleritis is usually a chronic and frequently severe sight-threatening inflammation of the sclera often associated with systemic diseases which themselves may carry significant morbidity and mortality. Clinical distinction between the two is important because of the implications for management and prognosis.

### Aetiology

Whereas both scleritis and episcleritis may have infectious aetiology, both conditions are usually immune-mediated. Episcleritis is more commonly idiopathic but shares many of the systemic associations of scleritis, which is a manifestation of a systemic disease in 50% cases.

**Table 5.6 Aetiology and associated diseases of episcleritis and scleritis**

Non-infectious	Infectious
Rheumatoid arthritis	Syphilis
Wegener's granulomatosis	HZV
Gout	Tuberculosis
Sero-negative arthropathy (including Reiter syndrome)	Hepatitis B
Relapsing polychondritis	Lyme disease
Polyarteritis nodosa	
Systemic lupus erythematosus	
Sarcoidosis	
Inflammatory bowel disease	
Surgically induced	

### Pathophysiology

The strong association between scleritis and systemic vasculitides, connective tissue disorders, and arthritides implies a primary immunological basis for most cases which may be both cell- and immune complex-mediated. Histopathologic studies have shown chronic inflammatory changes with combined lymphocytic and macrophage infiltration of the sclera and in some aetiologies granulomata will be present. Severe scleritis additionally involves fibrinoid necrosis with consequent tissue loss seen clinically as scleral thinning (scleromalacia).

### Clinical evaluation

The distinction between episcleritis and scleritis is made purely on clinical grounds and is based both on a careful history and examination. Particular attention should be paid to the severity and character of the pain and the presence of any systemic symptoms.

### History

#### Episcleritis

- Mild or no discomfort: often gritty/at most a mild ache.
- Pain may be worse on ocular movement.
- Vision unaffected.

#### Scleritis

- Usually severe 'boring'/aching pain (except for scleromalacia perforans):
- often disturbs sleep,
- often radiates to brow,
- may be worse on ocular movement.
- Tender globe, nausea.
- Vision may be affected (especially posterior scleritis).

- Redness may be diffuse, regional, or absent (posterior scleritis, scleromalacia perforans).

### Examination

Examining in natural light (naked eye) and red-free light (slit lamp) is very helpful to distinguish the blueish-red discoloration and deep vascular involvement seen with scleritis.

#### Episcleritis

- Vasodilatation of superficial episcleral plexus vessels (usually radially oriented, *blanching with topical 10% phenylephrine*).
- Episcleral oedema (occasionally nodules).
- Globe usually non-tender.
- No intraocular signs.

#### Scleritis

- Blueish-red tinge in natural light.
- Tender.
- Vasodilatation of deep and superficial episcleral plexus vessels (red-free light).
- Scleral oedema, nodules.
- Corneal changes (infiltrates, thinning).
- Intraocular inflammation.
- Raised IOP.
- Chorioretinal folds, exudative retinal detachment, disc swelling, proptosis (posterior scleritis).
- Look for *capillary closure and areas of necrosis/thinning*.
- Scleromalacia perforans: distinct type of painless, necrotizing scleritis without inflammation seen in rheumatoid arthritis.

**Table 5.7 Classification of scleritis and episcleritis**

Episcleritis	Scleritis
Simple	Anterior
Nodular	Diffuse
	Nodular
	Necrotizing:
	- with inflammation,
	- without inflammation
	(scleromalacia perforans)
	Posterior

### Differential diagnosis

#### Episcleritis

- Dry eye, blepharitis, conjunctivitis.
- Superior limbic keratoconjunctivitis.
- Foreign body granuloma (nodular episcleritis).
- Inflamed pingueculum.
- Phlyctenulosis.
- Lymphoma.

#### Scleritis

- Episcleritis.
- Anterior uveitis (more photophobia and anterior chamber reaction).
- Acute glaucoma (based on symptoms).
- Orbital inflammation/cellulitis (posterior scleritis).
- Optic neuritis (posterior scleritis).
- Orbital myositis (posterior scleritis).
- Posterior uveitis, uveal effusion, sympathetic ophthalmia, choroidal tumour (posterior scleritis).
- Lymphoma.



## Investigations

Systemic history and examination. Look for signs of associated systemic diseases, especially rheumatoid arthritis and Wegener's granulomatosis (cough, sinus symptoms, nose bleeds).

### Episcleritis

Investigations are not necessary in simple episcleritis unless as-yet-undiagnosed systemic disease is suspected.

### Scleritis

Scleritis may be the presenting feature of a potentially fatal systemic disease so all new cases should be investigated, preferably targeted by systemic history and examination:

- rheumatoid factor, ANA, ANCA, double-stranded DNA,
- FBC, urea and electrolytes, ESR, CRP, urate, syphilis serology,
- urinalysis (look for casts) and blood pressure,
- ultrasound may be very useful in confirming the presence of posterior scleritis (scleral thickening, fluid in sub-Tenon space),
- orbital imaging (MRI/CT) may be necessary to exclude orbital disease.

## Management

### Episcleritis

For mild or moderate cases no treatment may be necessary.

Short courses of topical corticosteroid or systemic NSAIDs (e.g. flurbiprofen, indomethacin) will usually prove effective if treatment is required (if not consider revising diagnosis).

### Scleritis

Requires systemic treatment with either NSAIDs (flurbiprofen, indomethacin), corticosteroids, or other immunosuppression (including azathioprine, cyclosporin A, methotrexate, and cyclophosphamide). The treatment should be tailored to the individual patient and will depend upon severity and any associated disease. Surgery is indicated if the diagnosis is in doubt (e.g. biopsy for lymphoma/masquerade) or to repair complications such as perforations and glaucoma.

## Complications

- Scleral necrosis, thinning, perforation.
- Keratitis/keratolysis.
- Uveitis, cataract, secondary glaucoma.

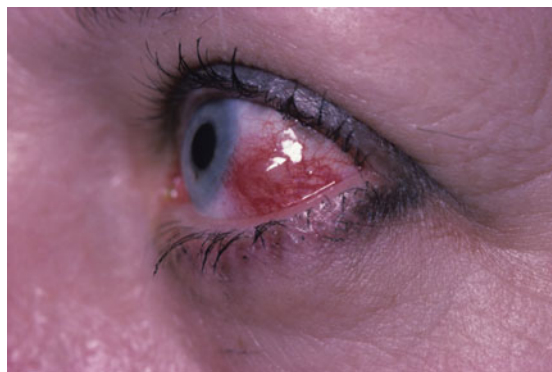### Posterior segment

- Exudative retinal detachment.
- Macular oedema.
- Disc oedema/atrophy.

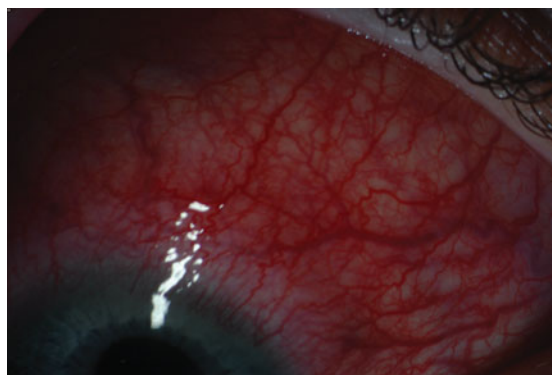
## Prognosis

Episcleritis is benign, does not result in long-term complications or visual loss but is often recurrent. Treatment is usually effective but may need to be given long-term for chronic or frequently recurrent cases.

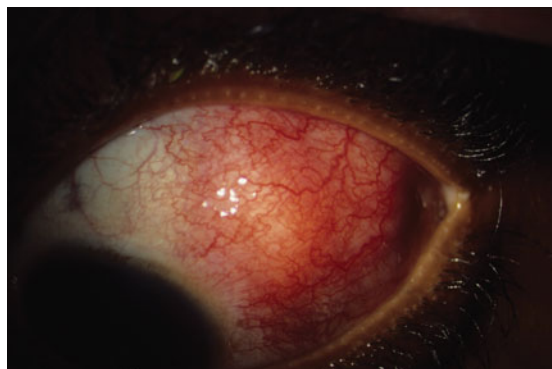
The prognosis of scleritis is variable and involves both ocular and systemic morbidity (and mortality). Diffuse anterior scleritis not associated with systemic disease usually carries a better prognosis, whereas necrotizing scleritis has the worst ocular outcome.



**Fig. 5.37** Nodular episcleritis: injection of the radially oriented superficial episcleral plexus vessels.



**Fig. 5.38** Beefy redness in diffuse anterior scleritis.



**Fig. 5.39** Nodular scleritis.

## 5.15 Systemic treatment of ocular inflammatory disorders

Posterior segment intraocular inflammation and scleritis are sight-threatening diseases in which topical corticosteroids are generally ineffective. Since 50% are linked to systemic multisystem diseases, such as sarcoidosis, Behcet's disease, or systemic vasculitis, systemic immunosuppression may be necessary both for the eyes and their extraocular disease manifestations. For posterior segment intraocular inflammation without systemic manifestations, periocular and intraocular drug delivery may be an effective option.

Corticosteroids have been the mainstay of systemic therapy for ocular inflammation and are usually very effective but may require high doses. However, supplementary immunosuppression may be required when:

- disease control is inadequate with corticosteroids alone.
- steroid side effects necessitate a steroid-sparing agent.

Under these circumstances, other immunosuppressive agents (e.g. cyclosporin A, mycophenolate mofetil (Cellcept), azathioprine, and tacrolimus) or newer 'biological' treatments have a role to play. The use of corticosteroids and immunosuppressants carries with it the risk of serious and sometimes life-threatening side effects and these should be discussed with the patient at the outset and weighed against the perceived benefits. Exclusion of infective causes of ocular inflammation and latent tuberculosis infection is important prior to considering systemic immunosuppression.

The decision to commence immunosuppression and the choice of which drugs to use will depend upon numerous factors which should be discussed with the patient, as follows.

### General health and state of the patient

- Corticosteroids may have particular hazards in the very young and the very old, the obese, diabetics, and those with osteoporosis. Local therapies may be considered.
- Cyclosporin may be nephrotoxic so is relatively contraindicated in those with renal disease, and can cause hirsutism so may be best avoided in young females.

### Location, nature, and severity of the inflammation

- Mild symptoms may not warrant the risks of immunosuppression unless the risk of irreversible visual loss is high (e.g. Behcet's disease or other).
- Unilateral disease with good contralateral vision may be considered inappropriate for the risks of heavy immunosuppression.
- Experience may dictate preference for a choice of drug with proven efficacy in a particular disease.

### Reversibility

- Established, irreversible causes of visual loss (e.g. macular ischaemia, optic atrophy) will not benefit from treatment.
- Vitritis and macular oedema of recent onset are typical causes of reversible visual loss.

### Patient reliability and follow-up potential

- Compliance with treatment and regular monitoring is essential for patients taking these potentially dangerous drugs.

### General monitoring

Baseline assessment of patients prior to commencement of immunosuppression should include:

- weight, blood pressure, urinalysis,
- appropriate blood tests (see under individual drugs),
- discussion of potential risks and benefits,
- patient information sheets provided where possible,
- other investigations as required; for example, CXR to exclude tuberculosis.

## Systemic corticosteroids (e.g. prednisolone)

### Indications

First-line therapy for most patients with sight-threatening or severe ocular inflammation

### Cautions

- Diabetes.
- Obesity.
- Osteoporosis.
- Concurrent infection or previous tuberculosis.
- Peptic ulceration.

### Dosage

- Maximum adult oral dose is 1–2 mg/kg per day, 'pulsed' intravenous methylprednisolone 0.5–1 g over 1 hour usually given daily for 3 days.
- Taper slowly to a maintenance dose (adult): less than 10 mg/day if possible.
- *Abrupt discontinuation can lead to Addisonian crisis.*

### Important side effects

- Weight gain, cushingoid appearance, fluid retention.
- Osteoporosis.
- Hypertension, hyperglycaemia, hyperlipidaemia.
- Peptic ulceration, pancreatitis.
- Sleep disturbance, elation and steroid psychosis.
- Acne, skin thinning and bruising.
- Susceptibility to infection.

### Monitoring

- Blood pressure, weight, urinalysis (especially glycosuria)
- Occasional lipid levels.
- Dual-energy X-ray absorptiometry (DEXA) bone scan.

### Sensible precautions when prescribing steroids

- Provide a steroid card for information.
- Ask about tuberculosis exposure/symptoms, consider CXR.
- Ask about chicken pox history: if negative consider checking VZV IgG levels (VZV-naïve patients on prednisolone are at risk of disseminated VZV infection which can be fatal; they should be warned to seek VZV immunoglobulin if they come into contact with chicken pox or exposed shingles).
- Consider gastric protection in those with a history of dyspepsia (e.g. proton-pump inhibitor/H<sub>2</sub> antagonist) and try to avoid NSAIDs, especially if on warfarin (risk of gastrointestinal bleeding).
- Regular DEXA scans, treat if osteopenic on DEXA and consider osteoporosis prophylaxis (e.g. alendronate 70 mg/week) in those at risk, for example:
  - more than 7.5 mg prednisolone/day for more than 6 months,
  - age more than 65 years,
  - post-menopausal/amenorrhoea,
  - history of fractures,
  - immobility.

## Cyclosporin A and tacrolimus (FK506)

### Mechanism of action

Calcineurin inhibition, inhibiting interleukin (IL)-2 production and T-helper cell function. Cyclosporin A is a natural product of fungi

and tacrolimus is a macrolide antibiotic produced by *Streptomyces tsukubaensis*.

### Contraindications/cautions

Renal impairment, uncontrolled hypertension, pregnancy (advise barrier contraception), breast-feeding, recent live vaccinations, malignancy, diabetes (tacrolimus). Cyclosporin A and tacrolimus work in a similar way and should not be prescribed together.

### Dosage

- **Cyclosporin A:** initially 2.5 mg/kg given in divided doses, increasing to 5 mg/kg depending on clinical need.
- **Tacrolimus:** initially 0.03 mg/kg increasing to 0.08 mg/kg depending on clinical response.
- Higher doses used in transplantation (increased risk of nephrotoxicity).

### Important side effects

- Renal impairment, hypertension.
- Infections (e.g. respiratory-tract infections).
- Nausea, vomiting, headache.
- Tremors, paraesthesiae, cramps.
- Hirsutism, gingival hyperplasia (cyclosporin A).
- Hyperlipidaemia, hypomagnesaemia.
- Hyperglycaemia (tacrolimus).
- Cancer (especially lymphoma, skin cancers).

### Monitoring

- Blood pressure, weight, urinalysis (especially glycosuria).
- FBC, urea and electrolytes, liver-function testing at 2 weeks, 4 weeks, then 4–8 weekly.
- Lipids and serum magnesium every 3–6 months.

## Antimetabolites: azathioprine and mycophenolate mofetil (Cellcept)

### Mechanism of action

Inhibition of T- and B-lymphocyte function by interfering with nucleotide synthesis.

### Contraindications

- Pregnancy and breast-feeding.
- Recent live vaccinations.
- Liver impairment.
- Malignancy.
- Mycophenolate and azathioprine work by similar mechanisms and should not be prescribed together.

### Dosage

- **Azathioprine:** depends on thiopurine methyltransferase level, which should be checked prior to starting. There are genetically determined variations in activity, with low levels predisposing to bone marrow suppression. In the presence of normal thiopurine methyltransferase the usual dose is 50–100 mg/day for uveitis. Reduced dose is required when thiopurine methyltransferase is low or when taken with allopurinol.
- **Mycophenolate:** usually 1 g twice daily up to a maximum of 3 g/day if tolerated.

### Important side effects

- Gastrointestinal symptoms (nausea, diarrhoea, vomiting, ulceration, and haemorrhage).
- Abnormal liver-function tests/hepatotoxicity.
- Leucopenia, bone marrow suppression.
- Infections, malignancy.

### Monitoring

- FBC should be checked at weeks 1, 2, and 4 after commencement, then 1–2 monthly.
- Urea and electrolytes, liver-function test checked at each clinic visit.

## Antimetabolites: methotrexate

A favoured drug for children and in rheumatoid disease.

### Mechanism of action

Methotrexate is a folate analogue; it impairs nucleotide synthesis.

### Contraindications

- Pregnancy, breast-feeding.
- Recent live vaccinations.
- Liver disease (abstain from alcohol).

### Dosage

- Weekly dosing, oral or intramuscular.
- Gradually increase from 7.5 mg/week, watching FBC/liver-function test.
- Range is 7.5–25 mg/week, usually 15 mg/week.
- Prescribe folic acid 1–5 mg/day.

### Important side effects

- Gastrointestinal symptoms (nausea, diarrhoea, vomiting, ulceration and anorexia).
- Abnormal liver-function tests/hepatotoxicity.
- Leucopenia, bone marrow suppression.
- Pneumonitis.
- Infections, malignancy.

### Monitoring

- FBC should be checked at weeks 1, 2, and 4 after commencement, then 1–2 monthly.
- Urea and electrolytes, liver-function test checked at each clinic visit.

## Alkylating agents: cyclophosphamide and chlorambucil

### Mechanism of action

Impairment of DNA synthesis and repair by crosslinking DNA strands.

### Indications

Chlorambucil is commonly used in Behcet's disease where it is effective for mucosal ulceration. Cyclophosphamide is generally reserved for severe inflammatory conditions, particularly those associated with systemic vasculitis (e.g. Wegener's granulomatosis or systemic lupus erythematosus) where it may be administered in 'pulsed' intravenous doses every 2 weeks or an oral daily dose (1–3 mg/kg per day).

### Side effects

The major side effects of cyclophosphamide are bone marrow suppression, infertility, and haemorrhagic cystitis. Mesna may be prescribed to reduce the cystitis and cryopreservation of eggs/sperm may be necessary.

## 5.16 Biological agents and periocular treatments of ocular inflammatory disorders

### Biological agents

There has been a recent explosion of interest and research into the use of so-called biological agents for inflammatory diseases. Greatest experience is in conditions such as rheumatoid arthritis and inflammatory bowel disease where some startling success has been seen. Evidence for beneficial use in ocular inflammatory disease is, at the time of writing, limited and in some cases absent. Most experience is with infliximab (refractory uveitis) and interferon- $\alpha$  (Behcet's disease); both agents have shown promising results. Like established immunosuppressants, these agents have their drawbacks, which include the risk of opportunistic infection (e.g. tuberculosis reactivation), hypersensitivity reactions, cardiac failure, malignancy, and paradoxical autoimmune disease. Furthermore these agents are at present very expensive. Nevertheless, in certain situations, particularly when conventional immunosuppression fails due to inadequate effect or intolerable side effects, they may be of great clinical benefit. Examples of biological strategies currently available are outlined below, some of which may be useful in ocular inflammation.

- Anti-TNF $\alpha$  treatments:
  - infliximab and adalimumab: monoclonal antibodies binding TNF $\alpha$  to prevent receptor binding,
  - etanercept: fusion protein binds TNF $\alpha$ .
- Monoclonal antibodies directed against CD25, the IL-2 $\alpha$  receptor (daclizumab and basiliximab), thus preventing IL-2-mediated lymphocyte activation.
- Monoclonal antibodies targeting CD52 (CAMPATH-1H) a T-cell surface antigen, causing T-cell depletion.
- IL-1 inhibition by anakinra, a recombinant IL-1-receptor antagonist.
- B-cell depletion using an anti-CD20 monoclonal antibody (rituximab).
- Recombinant human interferon- $\alpha$  2a (rhIFN $\alpha$ -2a): this has shown great promise in ocular and systemic Behcet's disease.

### Peri-ocular drug delivery

Peri-ocular depot steroid injection may be particularly useful when avoidance of systemic side effects is desired or when ocular inflammation is unilateral or asymmetric. This approach may even be combined with systemic therapy, for unilateral relapses. A common indication is the development of cystoid macular oedema, for example in intermediate uveitis. However, these approaches do not prevent systemic steroid effects as some systemic absorption occurs that can, for example, affect glycaemic control in diabetics. Furthermore, periocular steroid use may be complicated by ocular hypertension, glaucoma, orbital fibrosis, and accidental globe perforation.

Various steroid preparations are available, but 40mg triamcinolone (Kenalog) or methylprednisolone (Depo-medrone) are commonly used, either as an orbital-floor injection or into the sub-Tenon space. Pre-injection OCT is helpful if given for macular oedema, for later comparison.

#### + Orbital-floor injection

This injection is placed inferotemporally within the orbit, extra-orbitally. It may be given trans-cutaneously or trans-conjunctivally.

1. Apply topical anaesthetic if a trans-conjunctival approach is planned. Clean the lower-lid skin with, for example, an alcohol swab for trans-cutaneous injections.

2. Draw up the steroid injection and ensure adequate mixing to avoid excessive drug deposits being left within the syringe at the end of the injection.
3. Give the patient a fixation point, keeping the eye in a neutral position within the orbit.
4. Remix the suspension and inject using a 25 G needle into the extraconal space inferotemporally, posterior to the equator of the globe. Avoid injecting under the periosteum (painful).
5. Carefully withdraw the needle.
6. Patients rarely need a pad or analgesia.

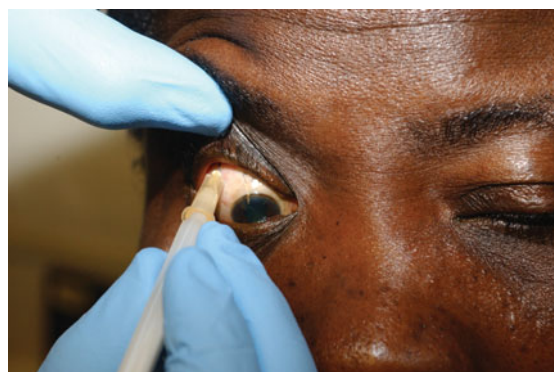
#### + Posterior sub-Tenon injection

Whereas sub-Tenon anaesthesia is usually given by a blunt cannula through a small inferonasal conjunctival incision, sub-Tenon steroid injections tend to be given by sharp needle superotemporally. This is thought to allow depot steroid to settle behind the posterior pole of the eye and avoids excessive regurgitation of the drug from the conjunctival entry site and unsightly steroid-filled chemosis.

1. Apply topical anaesthetic by drops and then using an anaesthetic-soaked cotton-tipped applicator placed temporally under the upper lid. This may be left for 5 minutes to ensure adequate anaesthesia.
2. In the meantime draw up the steroid injection, ensuring adequate mixing (see above).
3. Remove the cotton-tipped applicator
4. While the patient looks down, elevate the upper lid to expose the superotemporal bulbar conjunctiva.
5. Insert the 25 G needle bevel down under the superotemporal bulbar conjunctiva posteriorly and advance in the subconjunctival space. Small, gentle horizontal movements of the needle tip while advancing ensures that the sclera has not been engaged (ensure the globe does not move with the needle). Inject posterior to the equator.
6. Slowly remove the needle, avoiding excessive regurgitation of drug.

#### Follow-up

Patients should be followed-up 2–4 weeks after the injection to assess response and check IOP.



**Fig. 5.40** Peri-ocular depot steroid injection: posterior sub-Tenon approach.



## 5.17 Intraocular treatments of ocular inflammatory disorders

More recently there has been interest in the delivery of corticosteroids intraocularly, not only for intraocular inflammation but also for postoperative macular oedema (Irvine–Gass syndrome), diabetic macular oedema, and exudative macular degeneration. There have also been recent uncontrolled case series in which anti-VEGF treatments (originally developed for exudative macular degeneration) have been used for uveitic macular oedema.

Intravitreal steroid injection has the advantage of delivering drug to the site of action, thus maximizing the concentration and reducing the systemic side effects. Rather inevitably, the ocular steroid side effects are maximized, with cataract and glaucoma being particularly prevalent following this approach. Furthermore, each injection carries a small risk of endophthalmitis, retinal detachment, and even lens trauma. The following approaches have been used.

### Steroid implant

Implantation of a slow-releasing steroid device in the vitreous cavity. Trials of a fluocinolone device implanted through a pars plana incision in non-infectious posterior segment intraocular inflammation showed great promise in terms of efficacy: 87% eyes showing stable or improved visual acuity during the 34 weeks following implantation with reduced inflammation recurrence rates and reduced need for systemic immunosuppression. The implant is thought to work for 2.5–3 years. However a high incidence of glaucoma and ocular hypertension needing treatment (>50%), trabeculectomy (approximately 30% at 2 years), cataract (nearly 100% at 2 years), and uncertainties about long-term safety have limited their acceptance. The fluocinolone implant can be removed and on the positive side those eyes requiring trabeculectomy rarely experience bleb failure due to the profound suppressive effect of the locally high steroid levels on healing. Ongoing studies will be needed to confirm a favourable risk/benefit profile.

Trials of an injectable, biodegradable dexamethasone pellet injected intravitreally for posterior segment intraocular inflammation are currently underway. This approach has had some success in the treatment of diabetic macular oedema.

### Intravitreal steroid injection

Trans-scleral intravitreal injection of triamcinolone acetonide has become a frequently used (but unlicensed) treatment for a wide variety of posterior segment pathologies resulting in macular oedema including diabetic maculopathy, retinal vein occlusion, sub-retinal neovascularization, Irvine–Gass syndrome, and posterior segment intraocular inflammation. The effects are not as long-lasting as the fluocinolone implant, with triamcinolone crystals remaining for 3–4 months in the vitreous cavity. As with the fluocinolone implant glaucoma and cataract are the main complications, with approximately 50% requiring topical antihypertensives. Bacterial endophthalmitis (0.1%), sterile endophthalmitis (0.9%), and pseudohypopyon (crystalline deposits in anterior chamber; 0.8%) may also occur post-operatively. The sterile endophthalmitis may represent a hypersensitivity reaction and usually occurs in the first two postoperative days. Later presentations should raise suspicion of bacterial endophthalmitis which may present with little pain and redness (presumably due to the immunosuppressive effect of the intraocular steroid).

#### Intravitreal triamcinolone in uveitis

The main indication is macular oedema, although vitritis may also improve and the approach has been used in serpiginous choroiditis, Behcet's disease, Vogt–Koyanagi–Harada syndrome, and sympathet-

ic ophthalmia. Intravitreal triamcinolone acetonide (2–4 mg) has a beneficial effect on macular oedema (100% resolution in one study of 12 patients) and 75–83% of patients experience an improvement in visual acuity, although re-injection was necessary to maintain the improvement. Those patients with macular oedema for more than 12 months were less likely to benefit.

#### ⊕ Intravitreal injection

Appropriate pre-injection counselling of the patient should include the risks of endophthalmitis, glaucoma, cataract, and retinal detachment.

- Apply copious amounts of topical anaesthetic (an anaesthetic-soaked cotton-tipped applicator may be used over the site of injection).
- Prepare the intravitreal injection with, for example, an insulin syringe and ensure adequate mixing of drug suspension.
- Apply povidone iodine to the lids and conjunctival sac and leave for several minutes before sterile draping and insertion of a speculum.
- Most will inject a small amount of subconjunctival anaesthetic (e.g. 1% lidocaine) over the injection site (usually inferotemporally).
- Using a calliper measure from the limbus: 4 mm for phakic eye, 3–3.5 mm for pseudophakic eye.
- Remix the drug suspension and using an insulin syringe/27 G needle enter the conjunctiva a few millimetres away from the sclerotomy so that any vitreous wick is less likely to emerge on to the conjunctival surface.
- Pass the needle perpendicularly through the sclera into the vitreous, aiming towards the posterior pole and inject (usually 0.1 ml).
- Wait for a few seconds before withdrawing the needle so that the drug dissipates into the vitreous and is not all regurgitated.
- A cotton-tipped applicator may be placed over the sclerostomy when the needle is withdrawn to prevent regurgitation.
- Confirm at least hand-motion vision and check the fundus by indirect ophthalmoscopy. Some always perform a paracentesis, but most will only do this if the central retinal artery is closed or there is no light perception after injection.
- Prescribe topical antibiotic for 1–2 weeks.
- Some recommend checking the IOP after half an hour.

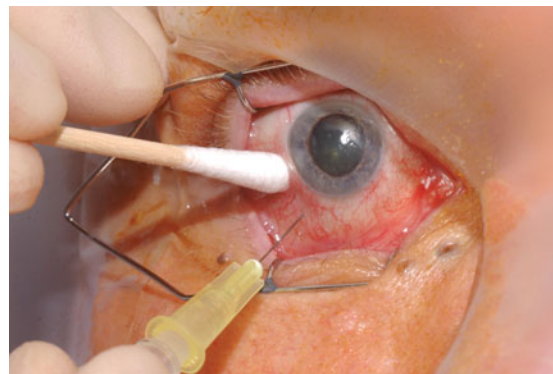


Fig. 5.41 Intravitreal injection.



## 5.18 Rheumatological disease

A broad spectrum of disease may present to a rheumatologist besides those manifesting with joint disease. So-called connective tissue diseases and vasculitides may also be classed as rheumatological diseases, although they may present to other medical departments as well. Many of these conditions have manifestations within the eye and ocular adnexae.

### Systemic lupus erythematosus

A multisystem autoimmune disease typically affecting young women (the female/male ratio is 6:1). Afro-Caribbeans and Chinese are particularly affected.

#### Aetiology

There are various theories, with evidence for both environmental (drug-induced/viruses) and genetic influences. There is 60% concordance of systemic lupus erythematosus in monozygotic twin studies.

#### Pathophysiology

Type III (immune complex) and possibly type II (antigen-specific antibody-binding) hypersensitivity appear to be involved. Immune complexes are found on glomerular basement membrane in glomerulonephritis. Widespread small- and medium-vessel vasculitis. Autoantibodies are the hallmark of systemic lupus erythematosus (ANA, anti-double-stranded DNA, anti-extractable nuclear antigens, antiphospholipid antibodies).

#### Clinical evaluation

Multisystem involvement (a great imitator of other disease).

**Table 5.8 Multisystem involvement in systemic lupus erythematosus**

<b>General</b>	Fever, malaise, weight loss
<b>Mucocutaneous</b>	Photosensitive, 'butterfly'/malar rash Discoid lupus Alopecia Livedo reticularis Mouth ulcers
<b>Musculoskeletal</b>	Non-erosive arthritis: symmetrical, small joints Proximal myopathy
<b>Renal</b>	Membranous glomerulonephritis Nephrotic syndrome, renal failure
<b>Cardiac</b>	Pericarditis/myocarditis Arrhythmias Hypertension (renal involvement) Libman-Sacks (sterile) endocarditis
<b>Respiratory</b>	Pleurisy, pneumonitis
<b>CNS</b>	Headache, seizures, cranial nerve palsy Chorea, psychiatric disorders
<b>Blood</b>	Leucopenia, thrombocytopenia Haemolytic and normochromic anaemia

#### Ophthalmic manifestations of systemic lupus erythematosus

- Lid erythema in malar rash.
- Keratoconjunctivitis sicca.
- Episcleritis/scleritis.

- Uveitis is rare.
- Retinal arterial involvement: occlusive arteritis manifesting usually with cotton-wool spot retinopathy but also occasionally as choroidal ischaemia or large retinal arteriolar occlusion.

#### Investigations

Diagnosis is usually made clinically with supportive serological tests:

- ANAs (including anti-double-stranded DNA, anti-extractable nuclear antigens),
- antiphospholipid antibodies, false-positive VDRL,
- low serum complement.

If the diagnosis is suspected (e.g. cotton-wool spots in fundus) it is mandatory to check the *blood pressure* and dip the *urine*. Rheumatological input is essential.

#### Treatment

The treatment usually involves a combination of hydroxychloroquine, corticosteroids, and other immunosuppressants (e.g. azathioprine, cyclophosphamide) depending on severity of organ involvement.

#### Antiphospholipid syndrome

A disorder related to systemic lupus erythematosus in which antiphospholipid antibodies predispose to recurrent abortion and arterial/venous thromboses which may affect the eye. Other features include thrombocytopenia and haemolytic anaemia. Diagnosis is made by the detection of anticardiolipin antibodies and a coagulation assay called the lupus anticoagulant test.

### Rheumatoid arthritis

Rheumatoid arthritis is a common, chronic, inflammatory joint disease characterized by a symmetrical polyarthritis usually affecting the joints of the hand, wrists, knees, and ankles, although any synovial joint can be affected. There are numerous extra-articular manifestations of rheumatoid arthritis, including several recognized ocular complications. The condition typically affects females (three times more than men) between 25 and 60 years of age, but it may begin at any age.

#### Aetiology

Like most autoimmune diseases, there appear to be genetic (HLA DR4/DR1) and environmental (possibly prior exposure to bacteria or viruses) influences.

#### Pathophysiology

Synovial attack by T-cells, macrophages, and ultimately fibroblasts with consequent destruction of cartilage and bone by proteolytic enzymes resulting in pain, loss of function, and deformity. Extra-articular involvement may be inflammatory, drug-induced, amyloid-related, or due to immobility (e.g. osteoporosis).

#### Clinical evaluation

- *Articular*: symmetric polyarthritis (painful joint swelling) most commonly involving hands, wrists, and knees. Typical deformity results in the hands (e.g. swan neck, boutonniere, ulnar deviation) with muscle wasting and loss of function.

**Table 5.9 Extra-articular manifestations of rheumatoid arthritis**

<b>General</b>	Fever; malaise, weight loss, anaemia, osteoporosis, lymphadenopathy
<b>Cutaneous</b>	Ulceration, nodules, vasculitis
<b>Renal</b>	Drug-induced nephropathy: NSAIDs, gold, chloroquine; amyloid
<b>Cardiac</b>	Pericarditis, myositis
<b>Respiratory</b>	Pleural effusions, fibrosing alveolitis
<b>Peripheral nervous system</b>	Entrapment neuropathies, mononeuritis multiplex, glove and stocking sensorimotor neuropathy
<b>Gastrointestinal</b>	Splenomegaly, peptic ulceration (NSAIDs); bowel infarction; amyloid; xerostomia (Sjogren's)

**Ophthalmic manifestations of rheumatoid arthritis**

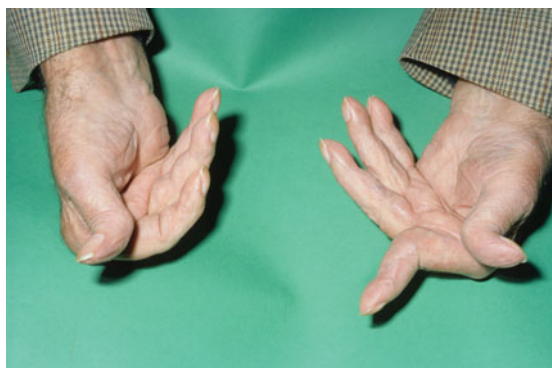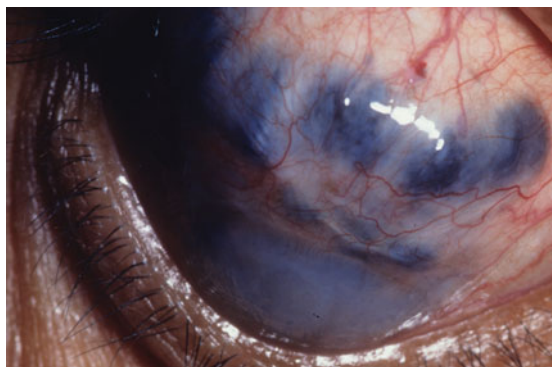- **Dry eye:** may be part of Sjogren's syndrome (inflammatory destruction of lacrimal and salivary glands, usually confirmed with anti-SSA(ro) and anti-SSB(la) antibodies). Dry eye in rheumatoid arthritis may be severe and lead to corneal epithelial defects, stromal melting and perforation. These are discussed further in section 1.6.
- **Episcleritis and scleritis** (the most common systemic association of scleritis): scleritis may present painlessly with a white eye and scleromalacia (scleromalacia perforans). Patients with scleromalacia perforans remain asymptomatic until either astigmatism or an incidental finding of a blue patch on the eye is made. Contrary to the name, perforation is uncommon in the absence of trauma. No medical treatment is effective or indicated.
- Posterior segment disease is rare in rheumatoid arthritis but retinal arteritis and ischaemic optic neuropathy (presumed vasculitic) may occur.
- Nodular involvement on the superior oblique tendon or inflammation of the trochlea may produce a Brown's syndrome (see section 8.17).

**Management**

Rheumatoid factor is an antibody directed against the Rc fragment of IgG and is found in 80% patients with rheumatoid arthritis. It may be present in other connective tissue diseases and infection, so is not 100% specific. X-ray of the hands may show a typical erosive arthritis with soft-tissue changes. Systemic treatment has traditionally involved corticosteroids, NSAIDs, hydroxychloroquine, gold, sulphasalazine, penicillamine, and methotrexate. Methotrexate is commonly used for chronic scleritis when associated with rheumatoid arthritis. Newer biological agents (e.g. infliximab) have been very successful. Dry eye treatment is discussed in section 1.6.

**Seronegative arthritis**

These conditions, including ankylosing spondylitis, Reiter syndrome, juvenile idiopathic arthritis, and psoriatic arthritis have an established, strong association with uveitis and are discussed further in section 5.13

**Fig. 5.42** Severe joint deformity in rheumatoid arthritis.**Fig. 5.43** Scleromalacia perforans in rheumatoid arthritis: severe scleral thinning causing a staphyloma in the absence of overt inflammation. Contrary to the name, perforation is rare.

## 5.19 Vasculitis

A group of presumed autoimmune conditions in which the primary target organ is blood vessels.

### Large-/medium-vessel vasculitis

This group includes Takayasu's arteritis and GCA (temporal or cranial). Both may result in arterial complications affecting the eye.

#### Takayasu's arteritis (pulseless disease)

A polyarteritis with predilection for the aorta and its main branches. Mainly affects young women and children. Manifestations within the eye mainly reflect carotid involvement: typically ocular ischaemic syndrome.

#### GCA

A disease of the older age group (>55 years), more commonly affecting women. Affects medium-sized arteries, particularly branches of the external carotid. Associated with a spectrum of disease including polymyalgia rheumatica (proximal muscle pains and weakness, fever). Typical symptoms of GCA are headache (scalp tenderness), jaw pain and claudication, fever, malaise, weight loss and, of course, sudden visual loss due to ischaemic optic neuropathy or (more rarely) CRAO. Diagnosis is made on clinical grounds, with the support of raised ESR and/or CRP and confirmed by typical findings on temporal artery biopsy (chronic intimal inflammation with fragmentation of the elastic lamina). The condition and its ophthalmic manifestations are described in more detail in Chapter 9.

### Small-/medium-vessel vasculitis

This group of conditions is uncommon and often severe with life-threatening multisystem involvement. Necrotizing arteritis is a frequent feature.

#### Wegener's granulomatosis

A necrotizing, granulomatous arteritis mainly affecting the upper and lower respiratory tract and kidneys. Middle-aged males are most frequently affected.

##### Common features

- Nasal symptoms are common and may be first feature: rhinitis, nose bleeds, and sinusitis. Collapse of the nasal bridge. Middle-ear involvement may lead to deafness.
- Pulmonary involvement: breathlessness, haemoptysis, and pleurisy.
- Renal disease: focal and segmental glomerulonephritis, present in 80% often leading to renal failure.
- Multisystem effects: pyrexia, arthritis, purpurae, cutaneous vasculitis, and neuropathy.

##### Ophthalmic involvement (up to 58%)

- Adnexae: proptosis, orbital inflammation (may mimic orbital cellulitis), nasolacrimal obstruction.
- Conjunctivitis, episcleritis, peripheral keratitis/melts.
- Scleritis, particularly the necrotizing variety.
- Retinal: rarely an occlusive retinal arteritis.
- Neuro-ophthalmic: optic neuropathy (may be ischaemic), cranial nerve palsies.

##### Investigations

In approximately 16% cases of Wegener's granulomatosis the presenting feature will be ophthalmic (e.g. scleritis, orbital inflammation). This is a serious, life-threatening disease with 80% mortality in the

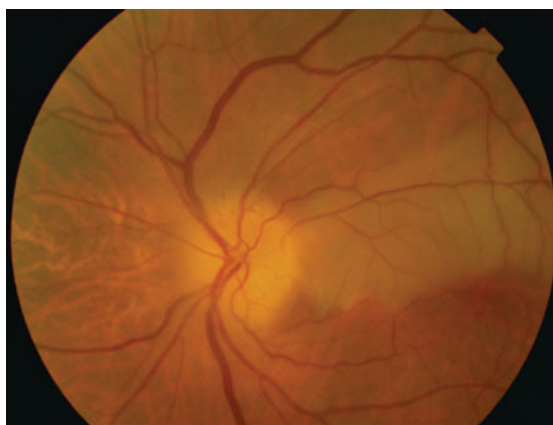first year if left untreated. Maintaining a high index of suspicion is necessary, with appropriate history taking and investigation. ANCA are present in most cases and are of the cytoplasmic type. Inflammatory markers are usually raised and the CXR may be abnormal. Check the blood pressure and urinalysis.

##### Treatment

Treatment is usually managed by rheumatologists and nephrologists. Usually involves high-dose corticosteroids and cyclophosphamide. Scleritis activity may be gauged clinically and treatment adjusted accordingly. In the event of unilateral visual loss due to optic neuropathy, lengthy immunosuppression is likely to be needed to protect the other eye even in the absence of other symptoms or signs.

#### Polyarteritis nodosa, microscopic polyarteritis, and Churg–Strauss syndrome

These small-vessel vasculitides may all be associated with the presence of ANCA with a perinuclear staining pattern. Polyarteritis nodosa and microscopic polyarteritis are a spectrum of conditions presenting with fever and weight loss and renal, cutaneous, and neurological (mononeuritis multiplex) manifestations. Churg–Strauss syndrome primarily affects the pulmonary arteries causing pulmonary eosinophilia. All these conditions may, rarely, cause scleritis, occlusive retinal/choroidal vasculitis, ischaemic optic neuropathy, and cranial nerve palsies.



**Fig. 5.44** Pale disc swelling and associated regional retinal pallor due to arteritic anterior ischaemic optic neuropathy and cilioretinal artery occlusion in GCA.

*This page intentionally left blank*

## 5.20 Cardiovascular disease and the eye

Hypertension, atheromatous disease, and embolic phenomena may affect the eye in a variety of ways. Many of these are discussed in chapter 4.

### Systemic hypertension

There are various definitions for systemic hypertension but arterial blood pressure of more than 139/89 mmHg may be considered to be hypertensive and 120–139/80–89 mmHg has been described as pre-hypertension. Prevalence may be as high as 44% in Europe in people over 35 years.

#### Aetiology

May be essential or secondary.

*Essential:* 30% heritability. Multiple environmental factors including salt intake, obesity, exercise, stress, smoking, etc.

*Secondary:* multiple causes which should be excluded in suspicious cases (young patients, resistant hypertension). Causes include:

- renal disease (including renal artery stenosis),
- endocrine disease (Cushing's/Conn's syndromes),
- tumours (phaeochromocytoma),
- coarctation of the aorta,
- pregnancy-induced,
- drug-induced (e.g. prednisolone, cyclosporin A).

#### Systemic effects

Asymptomatic until organ damage occurs.

- Cardiac: left-ventricular hypertrophy, heart failure.
- Vascular: contributes to atheromatous diseases.
- Stroke (ischaemic and haemorrhagic).
- Nephropathy.

#### Ophthalmic effects

Hypertensive retinopathy (see Chapter 4), choroidal infarction, main cause of BRVO, contributor to CRVO, non-arteritic ischaemic optic neuropathy, microvascular cranial nerve palsies.

#### Malignant (accelerated-phase) hypertension

Severe hypertension causing rapid organ damage in eyes, brain, lungs, and kidneys due to fibrinoid necrosis of vessels. Blood pressure usually more than 200/140 mmHg.

- Pulmonary oedema.
- Cardiac ischaemia.
- CNS: headache, vomiting, cerebral infarction, encephalopathy.
- Acute renal failure.
- Papilloedema, optic neuropathy, and retinopathy.

#### Management

A wide variety of medications is available, including diuretics,  $\beta$ -blockers, calcium-channel blockers, ACE inhibitors, angiotensin II antagonists, and centrally acting drugs.

#### Malignant hypertension

Emergency admission under medical team for cautious control of blood pressure and investigation of cause. It is important not to lower the blood pressure precipitously since this may exacerbate the organ damage (e.g. acute visual loss, stroke) due to loss of autoregulation.

### Atheromatous disease

A major cause of morbidity and mortality in the developed world. Atherosclerosis is the term used to describe arterial changes (including luminal narrowing) due to atheromatous plaque, which should be distinguished from arteriosclerosis: a loss of elasticity and thickening of the wall due to collagen and hyaline deposition.

#### Aetiology

Increasing age, male gender, smoking, diabetes mellitus, hypertension, genetic influences, hypercholesterolaemia, obesity, and hypothyroidism are known risk factors.

#### Pathophysiology

Initially a sub-intimal fatty streak. Involvement of macrophages which phagocytose lipid (foam cells), smooth muscle proliferation, ongoing cholesterol deposition, and calcification. Inflammatory component. Luminal narrowing occurs and occlusion may be gradual, or sudden if rupture occurs within the atheromatous plaque.

#### Major effects

- Coronary artery disease (myocardial infarction, angina, ischaemic cardiomyopathy).
- Cerebrovascular disease (cerebrovascular accident, transient ischaemic attacks, multi-infarct dementia).
- Peripheral vascular disease: lower-limb ischaemia.
- Mesenteric vascular disease: bowel ischaemia and infarction.

#### Ophthalmic presentations

Atherosclerosis may affect the ophthalmic, posterior, and anterior ciliary and central retinal arteries. This may lead to arterial insufficiency and occlusion (ophthalmic artery occlusion, CRAO, ischaemic optic neuropathy, cilioretinal artery occlusion). In addition, thickening of the arterial wall is thought to cause BRVO and potentially contribute to CRVO. These are discussed in chapter 4. As previously discussed ischaemic disease may also affect the third, fourth, and sixth cranial nerves (chapter 9).

#### Carotid disease

This may manifest within the eye in two ways: embolic phenomena (CRAO, BRAO, and amaurosis fugax) and with vascular insufficiency (ocular ischaemic syndrome). A bruit may or may not be heard (occluded carotid arteries have no flow) in the neck.

#### Ocular ischaemic syndrome

This may present in a number of ways but common features are:

- anterior segment: uveitis, rubeosis, neovascular glaucoma, cataract;
- posterior segment: arteriolar narrowing, venous dilatation, mid-peripheral retinal blot haemorrhages, neovascularization of the disc; digital ophthalmodynamometry (gentle pressure on the globe during fundoscopy) may demonstrate an easily collapsible central retinal artery.

Carotid ultrasound studies may show stenosis which is usually severe on at least one side (not necessarily the side of the eye signs). If no stenosis is found and suspicion is high, then angiography may be necessary to further investigate. Ophthalmic artery disease may be a major contributor in these cases.

#### Management of carotid artery disease affecting the eye

Immediate measures for amaurosis fugax are the exclusion of other causes such as hyperviscosity and GCA, antiplatelet therapy (assuming no contraindication), and addressing of risk factors such as hypertension, smoking, diabetes, and cholesterol. Medical treatment of neovascular glaucoma and uveitis in ocular ischaemia may be necessary. The decision to perform carotid endarterectomy is a complex one and for ophthalmic presentations in the absence of cerebral events there are conflicting views on the benefits of surgery. Improvements in ocular ischaemia have been seen following endarterectomy. The involvement of a neurologist or stroke physician is recommended.

### Other causes of retinal emboli

Emboli appearing in the retinal circulation are most commonly from the internal or common carotid arteries (cholesterol or platelet emboli) but may also originate from the aorta and from the heart due to *valvular disease* or *arrhythmia* or from the systemic circulation in the event of an atrial septal defect (*paradoxical embolism*).



### Valvular disease

Degenerative, rheumatic, and congenital valve disease may predispose to embolic phenomena. Degenerative valvular disease may lead to calcific emboli seen in the retinal circulation as white, non-scintillating specks, usually at a branching point. These tend to be larger than platelet or cholesterol emboli. Rheumatic mitral valve disease often leads to atrial fibrillation and left-atrial dilatation which predisposes to thrombus formation and subsequent embolism. Opinions are required from specialists in echocardiography and cardiology.

### Endocarditis

Infection of the heart valves usually occurs in the presence of pre-existing valvular disease. Common organisms include:

- $\alpha$ -haemolytic streptococci (viridans group): usually following dental work; typically subacute presentation;
- other streptococci: *Streptococcus faecalis*, *Streptococcus pneumoniae*;
- *Staphylococcus aureus*: typically acute presentation, may be on normal valve, usually intravenous drug user or diabetic;
- *Staphylococcus epidermidis*;
- *Pseudomonas*.

Vegetations on the valve leaflets may dislodge, causing embolic phenomena anywhere in the body, including septic cerebral infarctions.

Common systemic features include heart murmur, fever, weight loss, splinter/nail-bed infarcts, vasculitic skin lesions (Janeway lesions, Osler's nodes), and haematuria.

### Ophthalmic manifestations

Retinal artery occlusion is very rare but retinal microabscesses (Roth spots, white-centred haemorrhages), may be seen as well as areas of retinitis and/or frank endogenous endophthalmitis.

### Investigations

Have a high index of suspicion in anyone with a fever and uveitis or retinal haemorrhages. Listen to the heart carefully. Involve cardiologists. Arrange admission if suspicion is high.

Investigations include:

- blood pressure, urinalysis, FBC, urea and electrolytes, liver-function test, CRP, ESR, 3×blood cultures,
- echocardiography: transthoracic with or without trans-oesophageal.

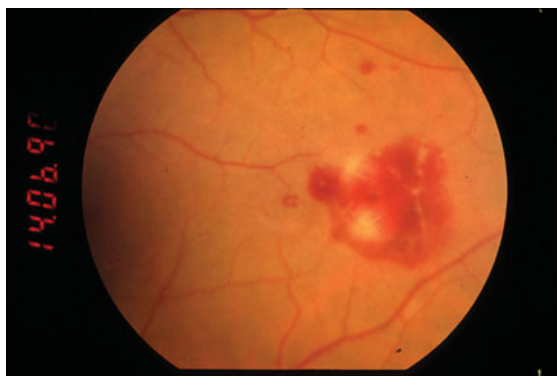### Treatment

Involves prolonged (usually 6 weeks) intravenous antibiotics with or without surgical intervention to repair or replace the affected valve.

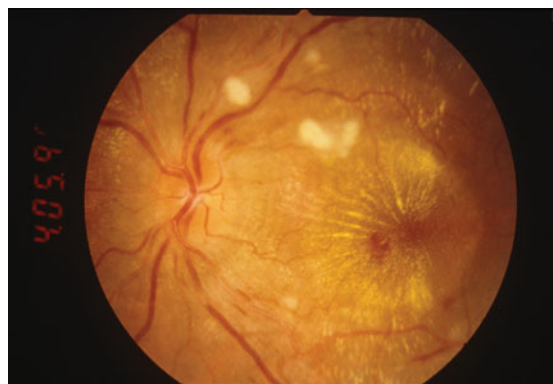NB: bacterial endocarditis has significant mortality and can lead to rapid clinical decline. Do not delay investigations.

### Atrial fibrillation

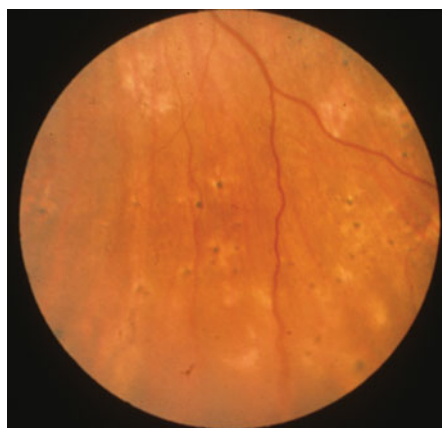
The presence of retinal artery occlusion or a history of amaurosis fugax should always prompt an assessment of the pulse and questions about palpitations. Uncoagulated patients in atrial fibrillation presenting with embolic phenomena should be admitted immediately for formal anticoagulation by the medical team on the assumption of a cardiac source for the embolus. A left atrial thrombus carries the risk of major embolic vessel occlusion.



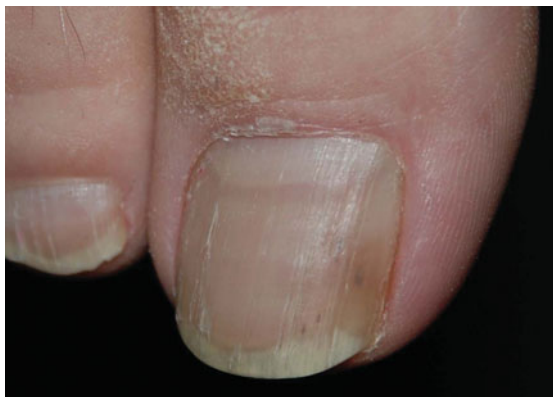**Fig. 5.45** A haemorrhagic retinal microabscess (Roth spot, white-centred haemorrhage) due to a septic embolus in bacterial endocarditis.



**Fig. 5.46** Accelerated-phase hypertension causing optic disc swelling, cotton-wool spots, and a macular star (oedema).



**Fig. 5.47** Elschnig spots: old choroidal infarcts secondary to severe hypertension.



**Fig. 5.48** Toenail-bed infarction (splinter haemorrhages) in bacterial endocarditis.

## 5.21 Endocrine diseases in ophthalmology

Diabetes mellitus (diabetic retinopathy, cataract) and autoimmune thyroid disease (thyroid eye disease, superior limbic keratoconjunctivitis) have well-characterized ophthalmic presentations which are discussed in Chapters 4 and 10 respectively. A brief description of the systemic aspects of diabetes mellitus is given.

### Diabetes mellitus

#### Definition

Fasting venous blood glucose concentration of more than 6.9 mmol/L, or blood glucose more than 11.0 mmol/L either on random test or 2 hours following 75 g oral glucose load.

Types I (usually young at onset) and II (usually older at onset) and gestational diabetes.

#### Aetiology

*Type I:* autoimmune destruction of pancreatic islet cells. Genetic (HLA DR3/4) and environmental (?viral) influences.

*Type II:* combination of reduced insulin secretion and insulin resistance (involving insulin receptor). Genetic influences and obesity are important.

#### Complications

##### Acute

- Ketoacidosis (type 1) and non-ketotic coma (type 2).
- Hypoglycaemia.

##### Chronic:

- Microvascular complications including nephropathy, peripheral neuropathy, and retinopathy.
- Macrovascular complications relating to contribution of hyperglycaemia to atherosclerosis: ischaemic heart disease, cerebrovascular disease, and peripheral vascular disease.

#### Treatment

Traditional division into insulin-dependent (type 1) and non-insulin-dependent (type 2) has blurred. Whereas all type 1 diabetics require insulin, more and more type 2 diabetics are prescribed insulin in addition to or instead of oral hypoglycaemics to improve glycaemic control.

#### Reducing the burden of microvascular complications

##### Glycaemic control

The Diabetes Control and Complications Trial (DCCT) demonstrated the benefit of tight glycaemic control on retinopathy (76% reduction in onset, 56% reduction in need for laser treatment), nephropathy (50% reduction), and peripheral neuropathy (60% reduction) in type 1 diabetics. The UK Prospective Diabetes Study (UKPDS) confirmed the benefit of tight glycaemic control in type 2 diabetics with a 25% reduction in microvascular complications.

##### Hypertension

UKPDS (type 2 diabetics) demonstrated a relationship between hypertension and diabetic retinopathy and the benefit of tighter control with a reduction in retinopathy progression and laser of 34% and in worsening visual loss by 47% with blood pressure of less than 150/85 mmHg. This study, in whom the mean blood pressure in the tight control group was 144/82 mmHg, also found a 44% reduction in stroke in this group. Blood pressure targets are now lower in diabetics with many physicians aiming for lower than 130/80 mmHg to prevent long-term complications. ACE inhibitors have an established role in delaying the onset of proteinuria in diabetics.

#### Lipid profile

The Collaborative Atorvastatin for Diabetes Study (CARDS) showed a non-significant, minor reduction in the need for laser treatment in type 2 diabetics receiving 10 mg atorvastatin for primary prevention of coronary heart disease, which resulted in a 26% drop in total cholesterol and a 40% drop in low-density lipoprotein cholesterol. Treatment duration was 4 years. Significant reductions in coronary events and stroke were noted. Further studies of the role of cholesterol lowering on retinopathy are awaited, but there are anecdotal reports of exudate regression in diabetic maculopathy on commencing statins.

#### Developing strategies

Oral inhibitors of protein kinase C such as ruboxistaurin are currently under trial for diabetic microvascular complications. Hyperglycaemia-induced activation of protein kinase C $\beta$  appears to be important in the intracellular signalling of VEGF, a principal mediator of retinal neovascularization and permeability in diabetes. Intravitreal VEGF blockade using monoclonal antibodies (ranibizumab) and oligonucleotides (pegaptanib) are also being studied for diabetic macular oedema with promising initial results, as discussed in section 4.9.

### Grave's disease

Autoimmune thyroid disease due to antibodies targeting the thyroid-stimulating hormone receptor. Other antibodies such as to thyroglobulin and thyroid hormones T<sub>3</sub> and T<sub>4</sub> may also be seen but the primary disease is thought to be an organ-specific (type 2) hypersensitivity reaction. The disease usually affects women (female/male ratio 7:1) in the third to fifth decades. Eye involvement is believed to result from an antigen common to the thyroid gland and the extraocular muscles. The eye disease is discussed in section 10.8.

The clinical presentation is usually of hyperthyroidism: weight loss, palpitations, insomnia, irritability, heat intolerance, diarrhoea, and amenorrhoea. Occasionally eye symptoms are the presenting feature. Pretibial myxoedema and thyroid acropachy (similar to finger-nail clubbing) may develop and are specific to Grave's disease.

#### Management (co-ordinated by endocrinologist)

- Anti-thyroid drugs, for example carbimazole (danger of agranulocytosis), propylthiouracil.
- 'Block and replace' strategy: carbimazole and thyroxine.
- $\beta$ -Blockers for symptomatic relief.
- Radioiodine.
- Thyroid surgery.

#### Eye disease

May be exacerbated by smoking, radioiodine (temporarily), and hypothyroidism (raised thyroid-stimulating hormone).

## 5.22 Respiratory and skin diseases in ophthalmology

### Respiratory disease and ocular inflammation

In patients presenting with inflammatory eye disease and respiratory symptoms consider the following unifying diagnoses.

- **Sarcoidosis:** dry cough, breathlessness, weight loss, fever.
- **Tuberculosis:** productive cough, haemoptysis, weight loss, lymphadenopathy, travel/from endemic area.
- **Wegener's granulomatosis:** nasal/ear symptoms, haemoptysis, breathlessness.
- **Churg–Strauss syndrome:** wheeze, cough, weight loss.
- **Pneumonia:** acute presentation, fever, cough, breathlessness, pleuritic pain. Consider the possibility of immunocompromise (e.g. *Pneumocystis* in HIV/AIDS/other) or endogenous endophthalmitis (e.g. pneumococcal).

### Respiratory disease and papilloedema

#### Obstructive sleep apnoea

An association exists between obstructive sleep apnoea and intracranial hypertension (discussed in section 9.11). Snoring, nocturnal restlessness, morning headache, and excessive daytime somnolence are key features of this condition, which is probably underdiagnosed. Periods of apnoea during sleep with relative upper-airway obstruction by collapse of soft tissues (e.g. pharynx/palate) occur. Patients tend to be overweight (large collar size) adults, although children with enlarged adenoids and tonsils and those with reduced tone (e.g. Down's syndrome) may also be affected. In those with 'idiopathic' intracranial hypertension, formal sleep studies may be indicated if there is a history suggestive of sleep apnoea. Various interventions are available, including continuous positive airway pressure masks for sleep and surgery for structural airway abnormalities.

#### Chronic obstructive pulmonary disease

In a patient with severe emphysema or chronic bronchitis, papilloedema may result from hypoxia/hypercapnia in the absence of raised intracranial pressure.

### Skin disease and ocular inflammation

Several vesicular/bullous rashes may be associated with ocular inflammation.

#### Bullous pemphigoid

Usually seen in patients over 60 years old, bullous pemphigoid is a rare, chronic, autoimmune, blistering skin disease. It is caused by IgG autoantibodies specific for hemidesmosomal antigens in the skin basement membrane. Most commonly presents with intact, tense bullae particularly over flexural surfaces. Mucous membrane pemphigoid may develop in association or in isolation: the cicatrizing conjunctivitis is discussed in section 1.11. Diagnosis is confirmed by skin or conjunctival biopsy.

#### Erythema multiforme/Stevens–Johnson syndrome

An acute blistering skin disease with target lesions (erythema multiforme) and mucous membrane ulceration (Stevens–Johnson syndrome). Most common in the second to fourth decades. Immune-complex-mediated hypersensitivity reaction to drugs (e.g. penicillin, sulphur-containing drugs), infection (e.g. HSV, *Mycoplasma*, tuberculosis, streptococci) and malignancy. There is significant mortality—up to 30% in the most severe cases—and significant ocular morbidity with chronic dry eye and keratinization resulting from severe conjunctival disease (discussed in section 1.11). Urgent in-patient medical care is needed for many cases, involving fluid resuscitation and immunosuppression/intravenous immunoglobulin.

#### Epidermolysis bullosa acquisita

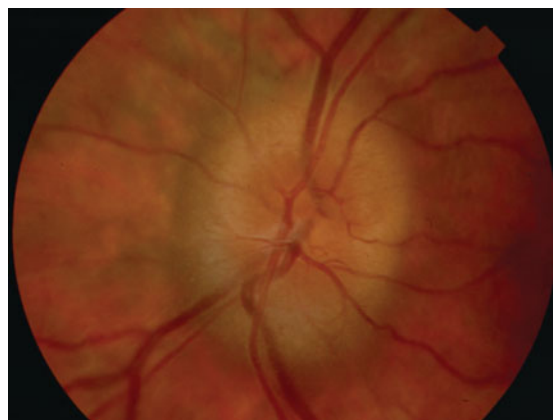
Unlike other inherited forms of epidermolysis bullosa, epidermolysis bullosa acquisita is acquired and commences in adult life. Blistering skin lesions may be associated with cicatrizing conjunctival inflammation.

#### Herpes simplex and zoster

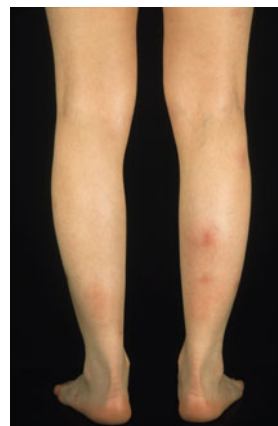Herpetic vesicular rashes around the eye are usually easily recognized. Herpes simplex of the lids may be associated with a conjunctivitis, as may chicken pox and HZO (ophthalmic shingles). Anterior uveitis is a rare feature of chicken pox and will usually respond well to topical steroid. Chronic anterior uveitis is a common complication of HZO.

### Erythema nodosum

The association between erythema nodosum and tuberculosis, sarcoidosis, and Behcet's disease warrants a brief description. Erythema nodosum is an inflammation of the subcutaneous fat (panniculitis). It causes tender, red nodules that are usually seen on both shins. It is an immunological response to a variety of different causes. Other than the above, other causes include drugs (sulphonamides, penicillin), inflammatory bowel disease, pregnancy, and infections including streptococci and *Mycoplasma*.



**Fig. 5.49** Chronic papilloedema in idiopathic intracranial hypertension, which may be associated with obstructive sleep apnoea.



**Fig. 5.50** Erythema nodosum: raised, tender erythematous lesions on the right lower leg.

## 5.23 Case-based discussion ➔

### Case 1 Scleritis

#### Presenting complaint

A 42-year-old male solicitor presented to the emergency services with a 3 day history of a severe, aching pain in and above the right eye. The pain was slightly worse on ocular movement and the eye was exquisitely tender. His sleep had been disturbed by the pain which was unresponsive to paracetamol. There was mild photophobia and the eye was red but vision was unaffected.

#### Past medical history

- Sinusitis.
- Nosebleeds.
- Hayfever.
- Wheezing in spring.
- No joint disease/rash.

#### Past ocular history

- Low myopia.

#### Medications

- Antihistamines and inhalers in spring.

#### Examination

Visual acuities were 6/5 corrected right and left.

The right eye was diffusely injected but in particular superonasally. This area was very tender. There was no proptosis, chemosis, or limitation of ocular movements. Slit lamp examination using diffuse illumination and red-free light demonstrated deep episcleral plexus injection superonasally with scleral oedema. There was no sign of vascular closure or scleral necrosis. The deep episcleral injection did not blanch with phenylephrine. There was a mild anterior uveitis and a normal IOP. Dilated fundal examination revealed no abnormality. The left eye was normal.

#### 1. What is the provisional diagnosis?

A clinical diagnosis of diffuse, non-necrotizing anterior scleritis was made.

#### 2. What investigations are necessary?

Blood pressure was 120/70 mmHg, urinalysis showed microscopic haematuria. FBC, urea and electrolytes, liver-function test and serum urate were normal but ESR (34 mm/hour) and CRP (27 mg/L) were raised.

Requests for the following investigations were made: CXR, ANA, rheumatoid factor, and ANCA. Formal urine microscopy and culture.

#### 3. What initial treatment would be appropriate?

He was prescribed flurbiprofen 100 mg BD orally and g. dexamethasone 0.1% QDS. Review was arranged for 1 week later.

#### Progress

One week later he reported moderate benefit from the flurbiprofen, but still complained of pain and was aware of a similar pain in his other eye. The left eye now had a similar area of tender injection superiorly.

#### Results

Urine microscopy showed red cell casts. CXR showed nodular shadowing in both lung fields. ANA and rheumatoid factor were negative, as was ANCA.

Referral to renal and respiratory teams were made. CT thorax showed cavitating nodules in both lungs. CT scanning of the sinuses

showed marked pansinusitis with some bony destruction. Transbronchial biopsy showed granulomatous inflammation with areas of necrosis.

#### 4. What is the definitive diagnosis?

#### 5. What further management is necessary?

A diagnosis of *Wegener's granulomatosis* was made and he was commenced on oral prednisolone and cyclophosphamide with an excellent clinical response (including resolution of the scleritis).

#### Discussion

As discussed in section 5.19, Wegener's granulomatosis is a serious, life-threatening disease with significant mortality. Scleritis may be the presenting feature, although chronic sinus and nasal symptoms are commonly overlooked. Anti-neutrophil cytoplasmic antibodies with a cytoplasmic staining pattern (cytoplasmic ANCA) are found in 90% of multisystem Wegener's and less than 50% in 'limited' (single-organ) disease. Pulmonary involvement is seen in up to 70% with cavitating lung nodules a common finding. These may lead to significant haemorrhage. Renal involvement (80%) is usually a necrotizing glomerulonephritis leading to renal failure if untreated. Due to the severity of the disease, aggressive immunosuppression is required. Therefore, even in the presence of a positive cytoplasmic ANCA, histological confirmation is usually desired. This may be from any involved site, but most commonly the lung or kidney.

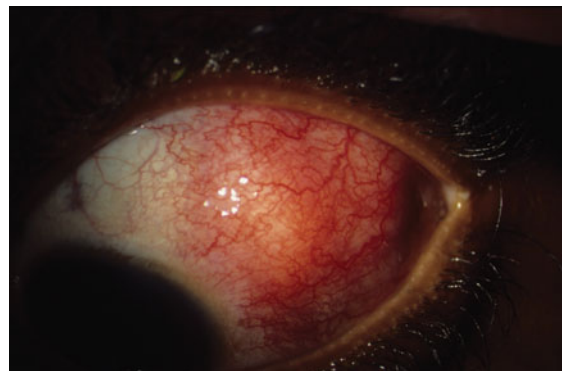

Fig. 5.51 Superotemporal scleral injection and nodule formation.

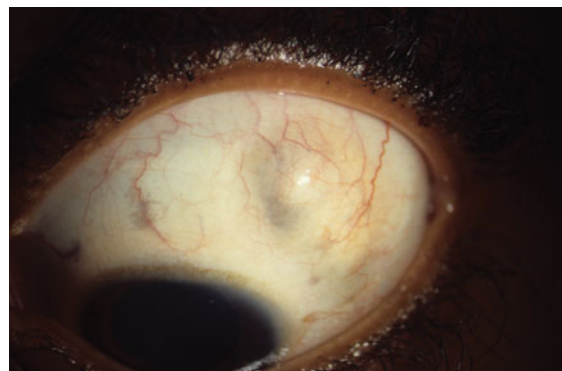


Fig. 5.52 Complete resolution of scleral inflammation after treatment.



# Chapter 6

## Cataract

Georgia Cleary and David Spalton

---

### Basic sciences

- 6.1 Lens anatomy and embryology 238

---

### Clinical knowledge

- 6.2 Acquired cataract 240  
6.3 Clinical evaluation of acquired cataract 244  
6.4 Treatment for acquired cataract 246  
6.5 Intraoperative complications of cataract surgery 250  
6.6 Infectious postoperative complications of cataract surgery 252  
6.7 Non-infectious postoperative complications of cataract surgery 254  
6.8 Congenital cataract 256  
6.9 Management of congenital cataract 258  
6.10 Lens dislocation 260

---

### Practical skills

- 6.11 Biometry 262  
6.12 Local anaesthesia 266  
6.13 Operating microscope and phacodynamics 268  
6.14 Intraocular lenses 270  
6.15 Nd:YAG laser capsulotomy 272

---

### Case-based discussions

- 6.16 Case 1 Age-related cataract 274  
Case 2 Postoperative endophthalmitis 274  
Case 3 Posterior capsular opacification 274



## 6.1 Lens anatomy and embryology

Cataract is the pathological opacification of the crystalline lens. Cataract derives from *cataracta*, Latin for waterfall. Cataract is an important cause of visual impairment and blindness worldwide, in both developed and developing countries. According to the latest World Health Organization (WHO) estimates, age-related cataract accounts for 48% of world blindness, amounting to approximately 18 million people. Fortunately, acquired cataract is a reversible cause of visual impairment.

The majority of cataracts are age-related. In developed countries, cataract surgery is the most commonly performed elective surgical procedure. Cataract surgery incurs considerable cost to health services, and this cost will rise as populations continue to age. In some developing countries, many remain blinded by cataract due to lack of access to ophthalmic services.

### Lens anatomy

The function of the crystalline lens is to focus images on to the retina. After the cornea, it is the second most powerful refractive structure in the human eye.

The crystalline lens undergoes considerable changes with age. At birth, the crystalline lens measures 6.5 mm in diameter, and is 3.5–4.0 mm thick. It is a highly elastic structure, and is capable of changes in shape and thus refractive power. The ability of the eye to change focus from distance to near is known as accommodation, and this is achieved by an increase in the axial thickness of the lens, and steepening of its anterior and posterior radii of curvature.

The axial thickness of the lens increases throughout life. Its diameter stabilizes in early adulthood at 9–10 mm. With increasing age, there is progressive hardening of the crystalline lens. This process is accompanied by loss of accommodation and therefore loss of clear near vision. This usually begins in the fifth decade, and is called presbyopia.

### Macroscopic anatomy

The crystalline lens lies posterior to the iris, and anterior to the vitreous body. It is a transparent, biconvex disc. Fine glycoprotein fibres, the zonules, support the lens within the eye. They insert on to the lens equator circumferentially, and are attached to the ciliary body via the ciliary processes.

The lens is surrounded by a capsule, which is thinnest posteriorly. Beneath the capsule lies the lens cortex. The most central portion of the lens is referred to as the nucleus.

### Microscopic anatomy

The entire crystalline lens is composed of cells of a single type. Lens fibres arise from the anterior lens epithelium, and are progressively laid down throughout life. As they mature, these cells lose their nuclei and become densely packed with lens proteins called crystallins. Each lens fibre is conserved throughout life, and it is the stability, resilience, and precise organization of the crystallins that allows the lens to remain transparent into adult life. The oldest, most differentiated cells lay deep within the lens nucleus, whereas the youngest cells are most superficial (see lens embryology, below).

The basement membrane of the lens epithelial cells forms the lens capsule, which surrounds the lens completely, and provides a surface for insertion of the zonular fibres.

### Lens embryology

The crystalline lens arises from surface ectoderm.

#### Day 27

A small region of surface ectoderm overlying the optic vesicle thickens, to form the lens placode.

#### Day 29

The lens placode invaginates the underlying retinal disc, to form the lens vesicle and lens pit.

#### Day 33

The lens pit closes, and the lens vesicle moves into the developing eye, forming the embryonic lens. The lens vesicle is surrounded by a basal lamina, the future lens capsule. All cells are orientated with their base adherent to the lens capsule, and their apices towards the lens cavity.

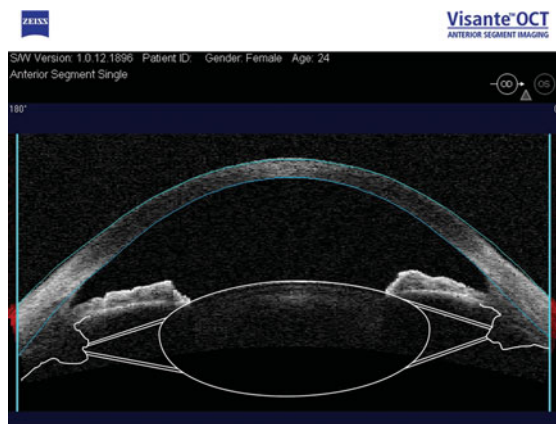
#### Days 33–47

Anterior and posterior cells of the lens vesicle display different behaviours.

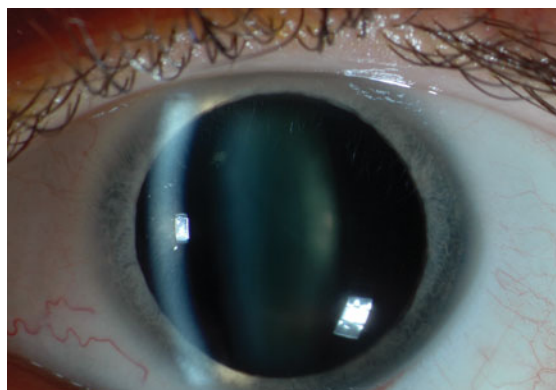**Posterior cells** elongate and grow anteriorly, closing the lens cavity and forming the primary lens fibres. Nuclei of these elongated cells migrate anteriorly to form the lens bow.

**Anterior cells** form the anterior lens epithelium, the source of secondary lens fibres. Secondary lens fibres originate from anterior lens epithelium at the lens equator. Each lens fibre grows anteriorly and posteriorly, meeting with other lens fibres at the anterior and posterior surfaces of the lens to form the Y-sutures.

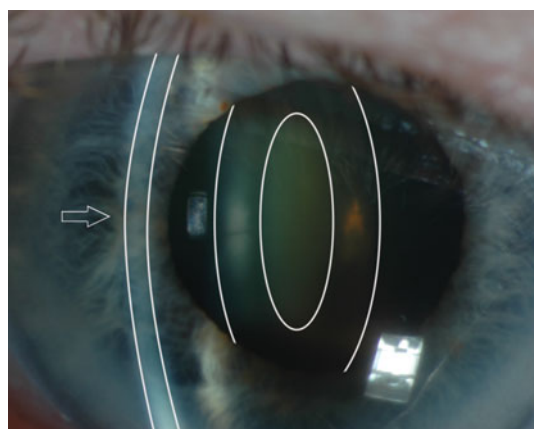
Sequential lamellae of secondary lens fibres are laid down throughout embryonic development, and this continues throughout life.



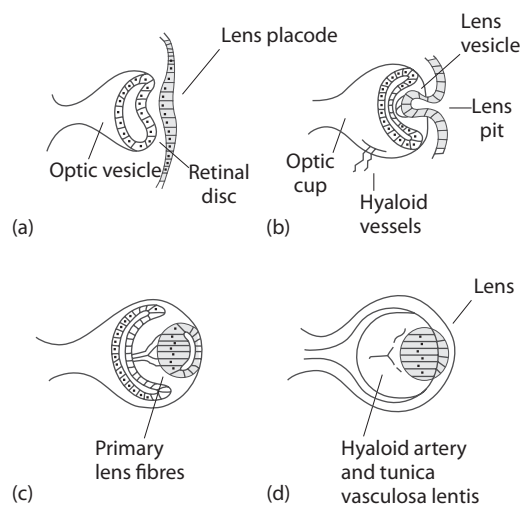
**Fig. 6.1** Anterior segment anatomy, superimposed on an anterior segment OCT scan.



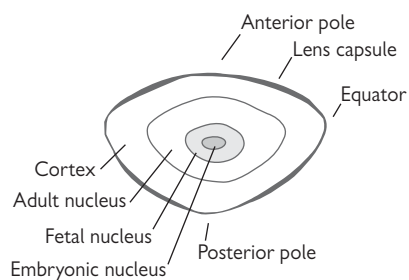
**Fig. 6.2** Clear crystalline lens.



**Fig. 6.3** Crystalline lens, including lens nucleus, as seen during slit lamp examination (arrow indicates direction of light).



**Fig. 6.4** Crystalline lens embryology.



**Fig. 6.5** Parts of the crystalline lens.

## 6.2 Acquired cataract

Broadly, cataract aetiology can be divided into congenital and acquired causes. The majority of cataracts encountered in clinical practice are acquired, and most acquired cataracts are age-related.

### Clinical classification

Acquired cataracts may be classified in terms of morphology, aetiology, and maturity.

#### Morphology

A morphological classification is used commonly in the clinic setting, and provides useful information when planning for cataract surgery.

##### **Nuclear cataract**

Nuclear cataract is a common type of senile cataract, and may be associated with increasing myopia as the cataract progresses. Also referred to as nuclear sclerosis, these cataracts may be very hard when advanced, requiring high amounts of phaco power during cataract extraction. They may progress to be brown in colour (brunescant).

##### **Cortical cataract**

The opacities in cortical cataracts are often arranged radially, in the softer outer cortical zone of the lens.

##### **Subcapsular cataract**

Posterior subcapsular cataracts lie just anterior to the posterior capsule, and often occur as a side effect of corticosteroid use. Small, central posterior subcapsular cataracts can be highly symptomatic, due to their proximity to the nodal point of the eye. Anterior subcapsular cataracts are less common.

Various formal classification systems have been described to objectively grade cataracts; for example, the Lens Opacities Classification System III (LOCS III). They are utilized primarily as a research tool.

#### Aetiology

- Age-related (senile).
- Drugs:
  - corticosteroids: topical or systemic,
  - chlorpromazine,
  - amiodarone,
  - aspirin,
  - topical glaucoma medications,
  - miotic agents (e.g. pilocarpine).
- Trauma:
  - iatrogenic (e.g. vitrectomy, trabeculectomy),
  - penetrating injury,
  - blunt injury,
  - chemical injury,
  - electrocution,
  - irradiation (e.g. X-rays).
- Secondary to systemic disease:
  - diabetes mellitus,
  - myotonic dystrophy,
  - Wilson's disease (sunflower cataract),
  - atopic dermatitis,
  - neurofibromatosis type 2,
  - Fabry's disease.
- Secondary to ocular disease:
  - uveitis,
  - myopia,

- acute angle-closure glaucoma,
- retinal dystrophies (e.g. retinitis pigmentosa).

#### Maturity

##### **Immature cataract**

Most cataracts seen in UK practice are immature, characterized by incomplete opacification of the lens.

##### **Mature cataract**

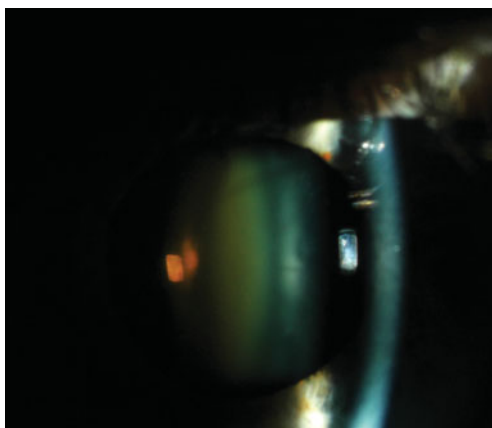
A dense, white cataract, which obstructs the red reflex and the view of the fundus.

##### **Hyper mature cataract**

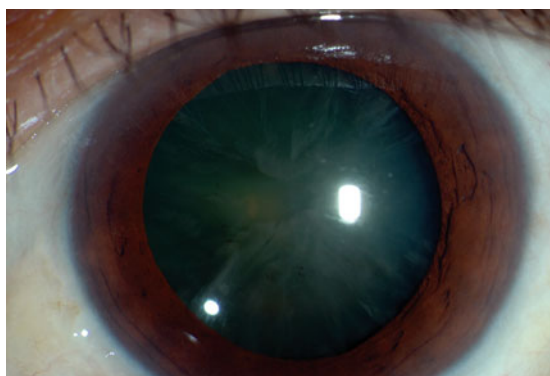As a mature cataract continues to age, water leaks from the lens, accompanied by shrinkage and wrinkling of the capsule.

##### **Morgagnian cataract**

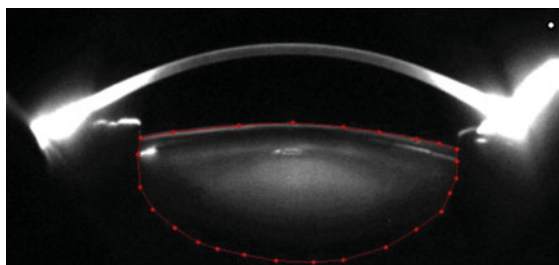
With further progression from hyper maturity, the cortical lens matter liquefies, with inferior displacement of the nucleus in the capsular bag.



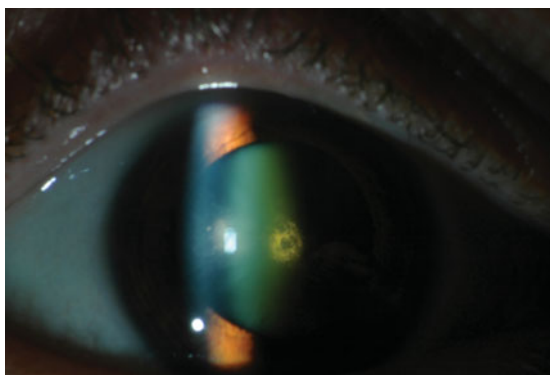
**Fig. 6.6** Nuclear cataract.



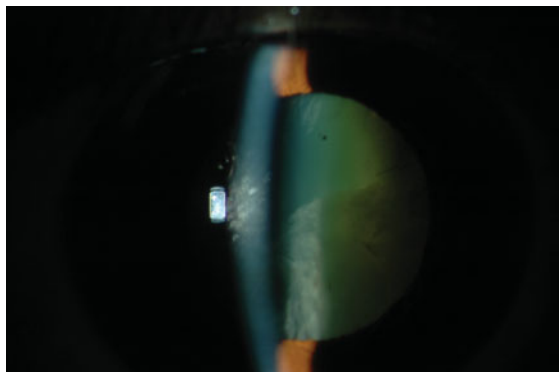
**Fig. 6.9** Cortical cataract, demonstrating a radial spoke-like configuration of opacities.



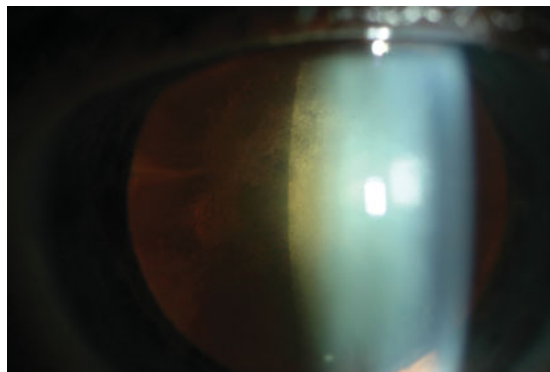
**Fig. 6.7** Nuclear cataract, imaged with a Scheimpflug camera (courtesy of L. Pelosini).



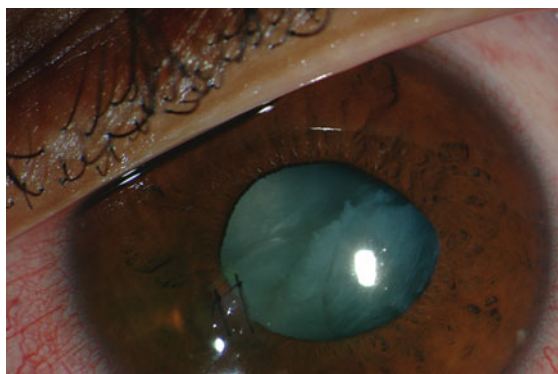
**Fig. 6.10** Small posterior subcapsular cataract.



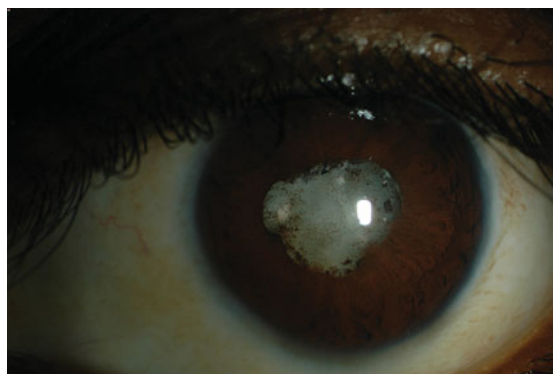
**Fig. 6.8** Cortical cataract, wedge-shaped.



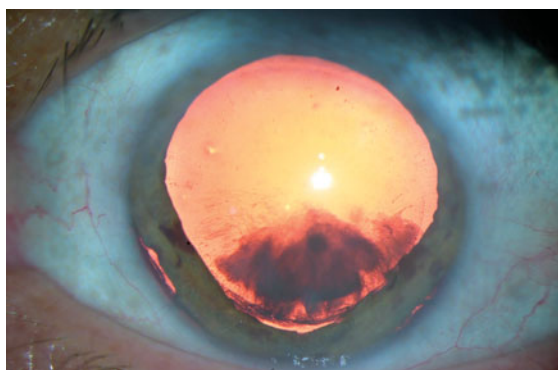**Fig. 6.11** Large posterior subcapsular cataract.



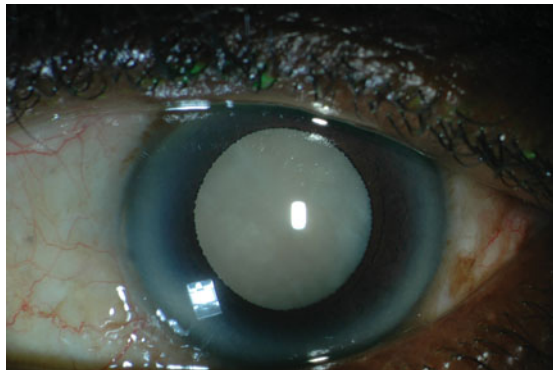
**Fig. 6.12** Traumatic cataract due to penetrating trauma, with associated corneal wound.



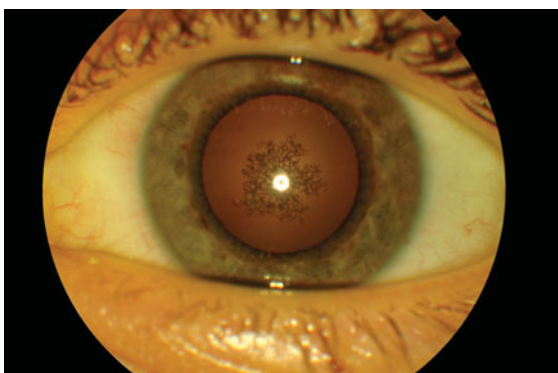**Fig. 6.15** Uveitic cataract.



**Fig. 6.13** Traumatic cataract due to blunt trauma, with associated iris dialysis. Visualized with retroillumination.

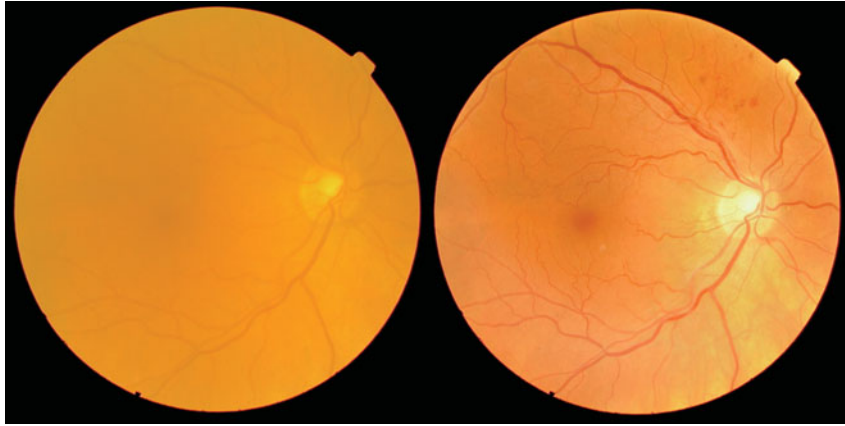


**Fig. 6.16** Mature, white cataract.



**Fig. 6.14** Electric cataract caused by lightning strike (courtesy of S. Rajak).





**Fig. 6.17** Screening photographs for diabetic retinopathy. The same eye is imaged before and after cataract surgery.

## 6.3 Clinical evaluation of acquired cataract

In clinical practice, patients are often referred by their optician specifically for management of cataract. Cataract is a clinical diagnosis, and the decision to list a patient for surgery is based in most cases on history and examination findings alone.

Cataract surgery involves removal of the opacified crystalline lens, and implantation of an intraocular lens (IOL). Most cataract surgery is performed under local anaesthesia as a daycase procedure. Despite this, a careful medical history should be obtained from all patients, in order to establish any general factors that may increase the risks of cataract surgery (Box 6.1).

### Clinical evaluation

#### History

- Age.
- Previous ophthalmic history.
- Previous medical history.
- Medications.
- Allergies (e.g. sulpha drugs; acetazolamide is used by some surgeons perioperatively).
- Family history of eye disease.
- Driving status.
- Social history, including occupation and hobbies.

#### Ask about cataract symptoms

- Blurred vision.
- Glare (in strong sunlight or headlights).
- Haloes or starbursts.
- Night driving problems.
- Increasing short-sightedness (myopia).
- Yellow/brownish discoloration of vision (more apparent when one eye has been operated).

#### Examination

##### Before pupil dilation

- Visual acuity:
  - unaided,
  - best spectacle-corrected or pinhole acuity.
- Assess for a relative afferent papillary defect. Cataract does not cause a relative afferent papillary defect. If present, suspect optic nerve or significant retinal disease.
- Cover test.
- IOP.
- Careful slit lamp examination, with attention to ocular factors that may render cataract surgery technically difficult or risky, or limit the visual outcome of surgery (see Box 6.1).

##### After pupil dilation

- Assess cataract morphology.
- Fundus examination.

#### General

Blood pressure.

#### Investigations

Investigations are not required to diagnose cataract per se. Dense cataracts may preclude a clear view of the fundus, and in some cases a B-scan ultrasound may be helpful to evaluate the posterior segment for coexistent pathology, for example retinal detachment.

An IOL is implanted during cataract surgery, and the IOL power must be tailored to each eye. Precise measurements of the eye are taken preoperatively to calculate the required IOL power. These measurements are known as biometry (section 6.11).

Patients taking warfarin should have their international normalized ratio (INR) measured, to ensure that it does not exceed their therapeutic range. Those few patients undergoing cataract surgery under general anaesthesia require appropriate anaesthetic work-up.

### Indications for cataract surgery

#### Improve vision

There is no universally agreed visual acuity threshold for undertaking cataract surgery. Worldwide, there is a trend towards removal of progressively lower grades of cataract, and it is not uncommon for patients with 6/6 Snellen visual acuity to undergo cataract surgery. In general, surgery should aim to achieve an appreciable improvement in measured visual acuity and/or subjective quality of vision.

#### Urgent treatment of vision-threatening ocular disease

The crystalline lens itself may occasionally be responsible for acute ocular disease:

- phacomorphic glaucoma: a large, cataractous lens causes shallowing of the anterior chamber, and secondary angle-closure glaucoma;
- phacolytic glaucoma: lens proteins, leaked from a hypermature cataract, obstruct the trabecular meshwork, causing secondary open-angle glaucoma.

#### Improve retinal visualization

It is critical to maintain a clear view of the fundus when evaluating and treating retinal diseases. Cataracts may obscure the view of the fundus, making clinical evaluation and photographic screening difficult and less specific in conditions such as diabetic retinopathy.

#### Cosmesis

Cataract extraction is occasionally performed in a blind eye with a white cataract for cosmetic reasons alone. As with all surgical procedures, the decision to proceed to cataract surgery should follow careful consideration of the risks and benefits involved.

**Box 6.1 Ocular factors that may contribute to adverse outcomes of cataract surgery**

Structure	Pathology	Risk	Action/possible surgical strategies
Lids	Blepharitis	Endophthalmitis	Treat blepharitis prior to surgery
Lids	Conjunctivitis	Endophthalmitis	Treat infection prior to surgery
Cornea	Guttata/Fuchs endothelial dystrophy	Corneal decompensation	Counsel preoperatively, shortest possible surgical time, use of dispersive viscoelastic and balanced salt plus
Cornea	Corneal opacity/scar	Poor visualization during surgery	Consider penetrating keratoplasty if view severely obscured
Cornea	High corneal astigmatism	Residual postoperative astigmatism	Placement of incision along steepest meridian, additional corneal procedure to treat astigmatism, toric IOL
Cornea	Previous laser refractive surgery	Postoperative refractive error if standard formula used	Acquire pre-refractive surgery biometry if available, use appropriate IOL power calculation formula
Anterior chamber	Shallow	Corneal endothelial trauma, technically difficult surgery	Cautious surgery, use of dispersive viscoelastic
IOP	Uncontrolled IOP	Iris prolapse, suprachoroidal haemorrhage	Treat IOP prior to surgery
Pupil	Posterior synechiae	Poor visualization during surgery	Synechiolysis, sphincterotomy, pupil stretching, iris hooks as required
Pupil	Poor pupil dilation	Poor visualization during surgery	Pupil stretching, iris hooks
Lens	Instability/phacodonesis (e.g. pseudoexfoliation)	Zonular dehiscence, IOL decentration	Capsular tension ring, sulcus fixation of IOL
Lens	Very dense cataract	Difficult visualization of capsule for continuous curvilinear capsulorhexis (CCC)	Stain capsule with trypan blue
Lens	Very dense cataract	High level of phaco power needed	Cautious surgery, use of dispersive viscoelastic
Lens	Posterior polar cataract	Posterior capsular rupture during hydrodissection	Hydrodelinate, avoid hydrodissection
Vitreous	Previous vitrectomy	Unstable anterior chamber	Cautious surgery, low vacuum levels, iris hooks
Vitreous	Silicone oil in vitreous cavity	Postoperative refractive error due to incorrect axial length measurement	Use of conversion factor for ultrasound biometry, or appropriate settings on IOL Master
Retina	Visually significant retinal or macular disease (e.g. AMD)	Limited improvement in vision	Preoperative counselling regarding limited visual improvement from surgery
General	Active uveitis	Persistent postoperative uveitis, cystoid macular oedema	Treat uveitis prior to surgery, may require perioperative systemic steroids
General	Heterotropia	Postoperative diplopia	Counsel preoperatively
Axial length	High myopia/long axial length	Retinal detachment	Counsel preoperatively, educate regarding retinal detachment symptoms
Axial length	High myopia/long axial length	Postoperative refractive error	Counsel preoperatively, careful choice of IOL power

## 6.4 Treatment for acquired cataract

### Conservative

Early cataracts may be simply observed, and visual acuity corrected effectively with spectacles. In eyes with minimal lens opacity and good corrected visual acuity, the risks of cataract surgery may outweigh its benefits. Such cases should be deferred until the cataract progresses further in terms of symptoms, measured visual acuity, or clinical signs.

### Surgical

Contemporary surgical management of cataract is by phacoemulsification and IOL implantation. Phacoemulsification was first performed in 1967, and has been considerably refined since then. It has largely superseded extracapsular cataract extraction in the developed world. The bulk of cataract surgery is performed under local anaesthesia (section 6.12).

### Phacoemulsification and IOL implantation

In Greek *phakos* means lentil, an object similar in shape to the human crystalline lens. Phacoemulsification is removal of the crystalline lens using ultrasonic energy. The basic steps that comprise phacoemulsification cataract surgery are consistent worldwide. However, the techniques utilized for each step vary among individual surgeons.

#### Step 1 Preparation of skin and the conjunctival sac

Local anaesthetic drops (e.g. tetracaine 1%) are instilled into the conjunctival sac. Povidone-iodine 5% is used to wash the lids, lashes, and conjunctival sac, staying in contact with the sac for at least 2 minutes. The area is then carefully dried.

#### Step 2 Draping

A sterile drape with a transparent, adhesive central window is placed over the eye, taking care to direct the lashes away from the eye. A small incision is made in the drape, directly over the eye, and a speculum is inserted to keep the eye open. The surgical field should be free of lashes.

The microscope can now be positioned over the eye, and surgery commenced.

#### Step 3 Primary incision

The main incision into the anterior chamber may be corneal, limbal, or scleral, and may be located temporally, superiorly, or along the steepest corneal meridian. It must be sized according to the phaco probe in use, to achieve a good fit. Corneal wounds are constructed to be self sealing. The keratome blade penetrates the corneal epithelium peripherally, and enters the anterior chamber through the corneal endothelium more centrally.

#### Step 4 Secondary incision (side port)

A smaller second incision is made, to accommodate the 'second instrument' during phacoemulsification, or to facilitate bimanual surgery.

#### Step 5 Viscoelastic insertion

The anterior chamber is filled and deepened with a high-molecular-weight, transparent, viscous gel. This stabilizes the anterior chamber for the subsequent step, capsulorhexis, and protects the corneal endothelium from mechanical trauma and ultrasound energy during phacoemulsification.

#### Step 6 Continuous curvilinear capsulorhexis (CCC)

The anterior lens capsule is punctured centrally, and a flap of capsule is fashioned. This flap is then carefully advanced, tearing a circular hole in the anterior capsule. The CCC should be constructed centrally,

be smaller in diameter than the IOL optic, and completely overlay the optic.

#### Step 7 Hydrodissection

Balanced salt solution is gently injected beneath the anterior lens capsule, underneath the capsulorhexis edge. This gently dissects the lens capsule away from its contents, freeing the lens to rotate within the capsule in preparation for phacoemulsification.

#### Step 8 Phacoemulsification (phaco)

The phaco probe is inserted into the eye with the bevel of the needle facing down. The bevel of the needle is turned to face anteriorly and a central groove is sculpted into the lens nucleus. Axial movement of the phaco needle at ultrasonic frequency results in cavitation of lens matter at the tip of the needle. Constant aspiration removes emulsified lens matter, while constant irrigation with balanced salt solution maintains anterior chamber depth and IOP.

A second instrument is then inserted into the eye via the side-port incision. Commonly used second instruments include choppers and nucleus rotators. Using both the phaco probe and the second instrument, the lens nucleus is rotated and broken into fragments, which are sequentially emulsified. Common techniques for fragmentation of the nucleus include 'divide and conquer' and 'stop and chop'.

#### Step 9 Irrigation and aspiration

Residual soft lens matter is aspirated from the lens capsule.

#### Step 10 Viscoelastic insertion

Further viscoelastic is inserted into the capsular 'bag', reopening the bag and creating space for IOL insertion.

#### Step 11 IOL insertion

A foldable IOL is advanced into the eye via an injector, or forceps. The IOL is placed into the capsular bag, where it unfolds.

#### Step 12 Viscoelastic removal

Viscoelastic is removed using the irrigation and aspiration probe, taking care to remove all viscoelastic from behind the IOL. Centration of the IOL can be assessed at this stage.

#### Step 13 Anterior chamber refilling and intracameral antibiotic

The anterior chamber is refilled with balanced salt solution until the globe is firm. Cefuroxime (1mg in 0.1 mL) is injected into the anterior chamber with a cannula.

#### Step 14 Wound closure

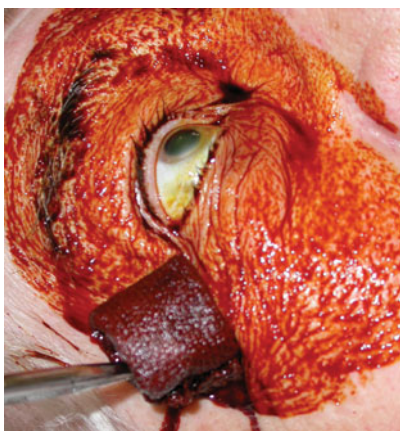Corneal oedema is induced at the wound edge by injecting balanced salt solution into the corneal stroma. This results in tighter apposition of the wound edges. Incisions should be checked meticulously for leaks. Suturing is rarely required.

### Extracapsular cataract surgery

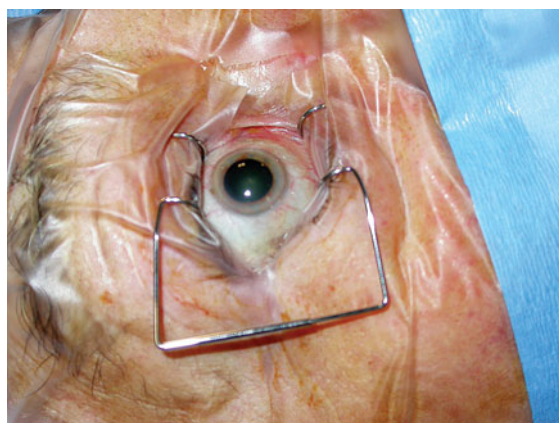
This technique is still used as the primary technique for cataract surgery in some parts of the developing world. Rarely it may be useful in cases where the nucleus is deemed too hard for phaco. Phaco cases that are complicated by extensive tearing of the anterior capsule can be 'converted' to an extracapsular cataract extraction. More recently the technique has been modified to reduce the size of the wound (small-incision extracapsular cataract extraction). The standard technique is as follows.

- 1) A large stepped wound is created at the superior limbus (for small-incision extracapsular cataract extraction, a scleral tunnel is created). The wound needs to be large enough to accommodate the whole lens nucleus.

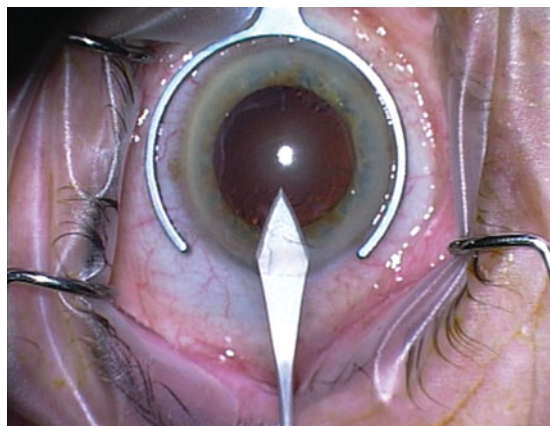
- 2) Viscoelastic is inserted.
- 3) A CCC is made.
- 4) Two or three small relieving incisions are made in the capsule perpendicular to the CCC edge.
- 5) The nucleus is 'expressed' using a squint hook placed on the inferior sclera just posterior to the lens. Gentle pressure is applied with the squint hook and the nucleus is 'delivered' out of the capsular bag, through the wound, and out of the eye.
- 6) The soft lens matter is aspirated.
- 7) An IOL is inserted and the viscoelastic is removed.
- 8) The wound is sutured with continuous or interrupted 10.0 nylon sutures.



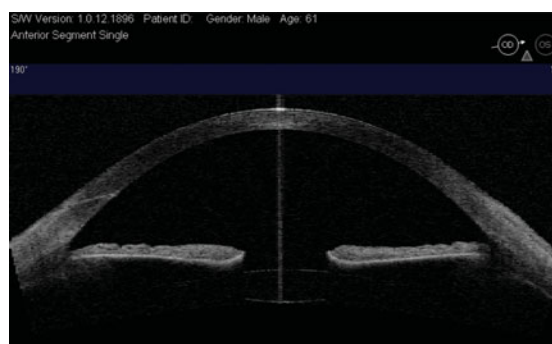**Fig. 6.18** Skin preparation.



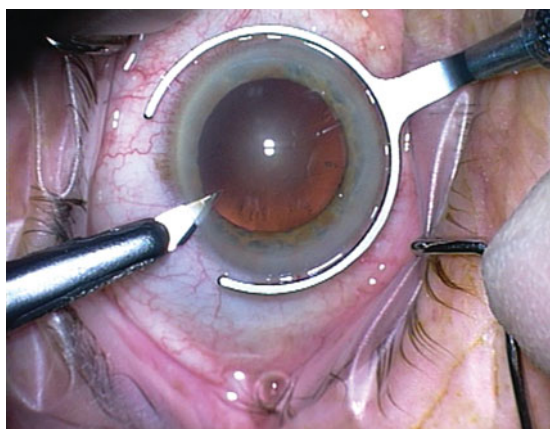
**Fig. 6.19** Draped eye with speculum *in situ*.



**Fig. 6.20** Primary corneal incision.

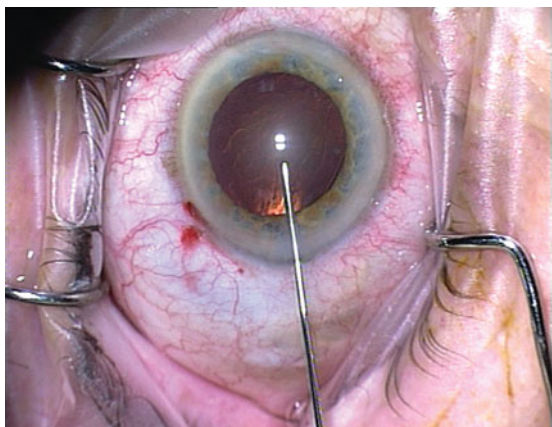


**Fig. 6.21** Corneal incision visible postoperatively with OCT.

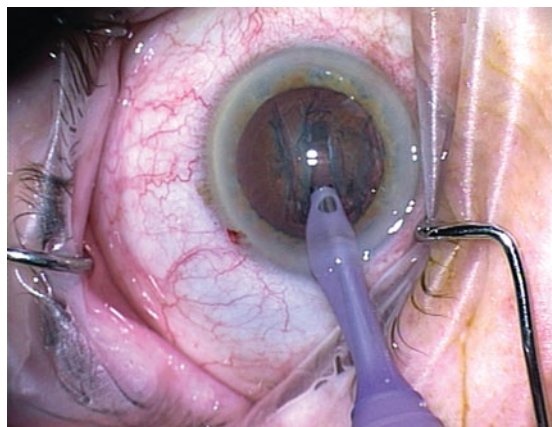


**Fig. 6.22** Second incision.

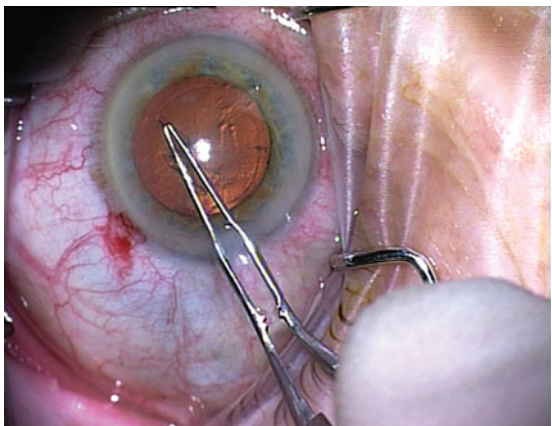




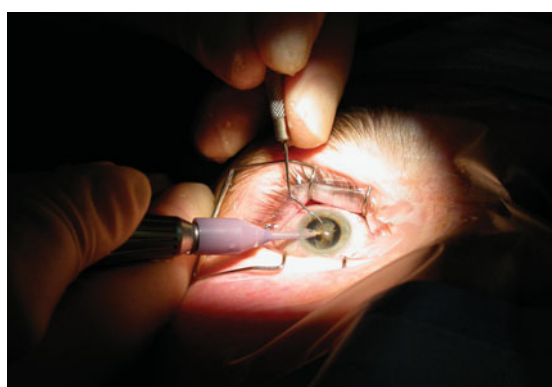**Fig. 6.23** Viscoelastic insertion.



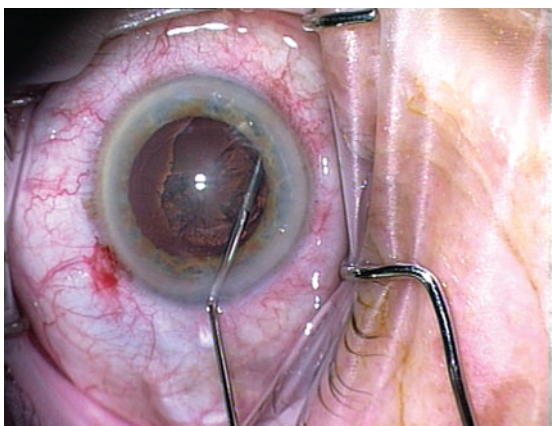
**Fig. 6.26** Phacoemulsification: sculpting a central groove in the lens nucleus.



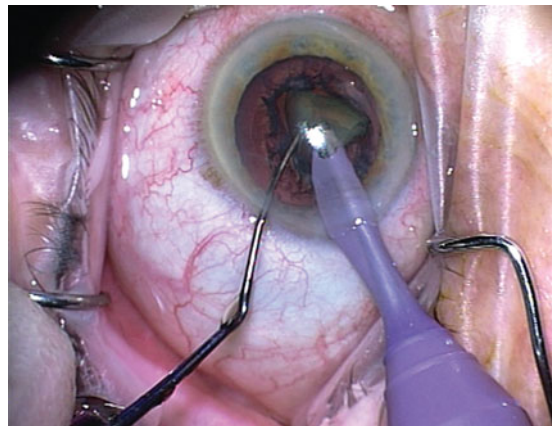
**Fig. 6.24** CCC



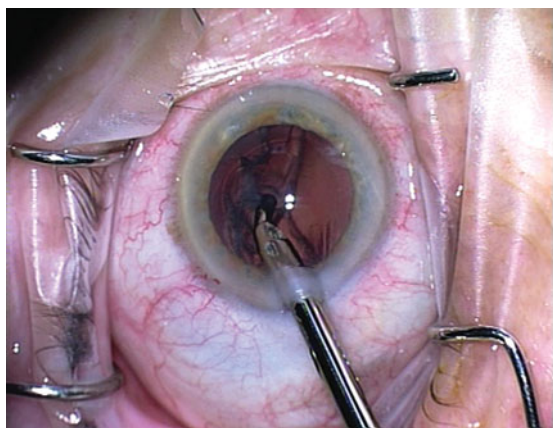
**Fig. 6.27** Phaco probe and chopper within the eye.



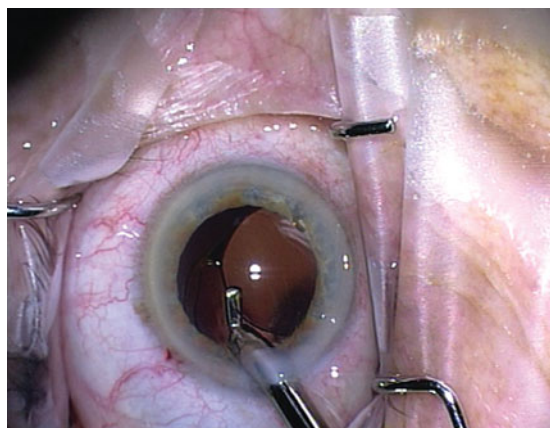
**Fig. 6.25** Hydrodissection.



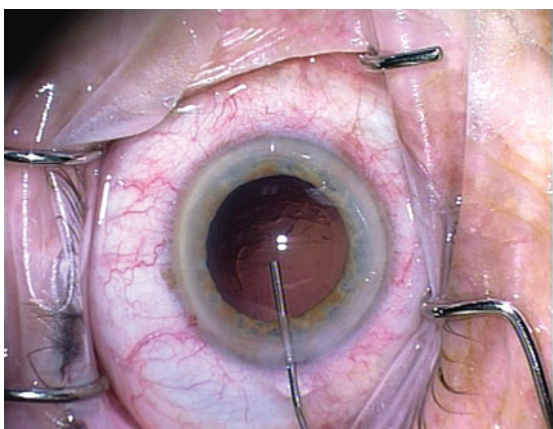
**Fig. 6.28** Removal of nuclear segment.



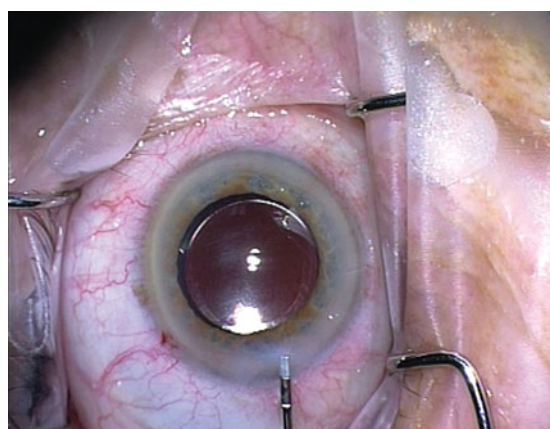
**Fig. 6.29** Irrigation and aspiration.



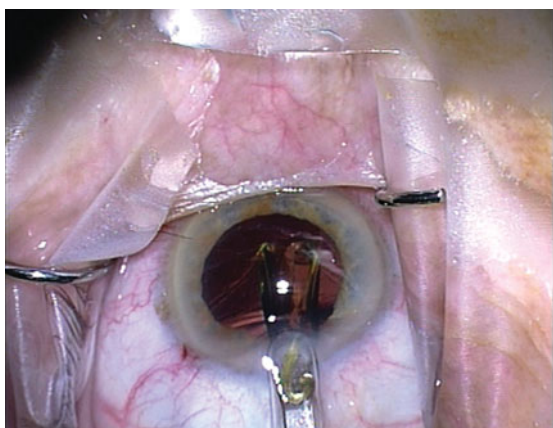
**Fig. 6.32** Viscoelastic removal.



**Fig. 6.30** Further viscoelastic insertion.



**Fig. 6.33** Wound hydration.



**Fig. 6.31** IOL insertion.



## 6.5 Intraoperative complications of cataract surgery

Contemporary cataract surgery yields high success rates, and as a result patient's expectations for excellent visual outcomes have risen. However, serious complications of cataract surgery continue to occur, and have the potential to cause complete loss of sight in the operated eye, or even loss of the eye itself.

Many potential complications of cataract surgery can be prevented by:

- careful preoperative assessment,
- surgical planning, and
- meticulous perioperative and intraoperative technique.

### Loss of the capsulorrhexis

The capsulorrhexis may tear out towards the lens equator, potentially extending posteriorly to involve the posterior capsule. This may occur when learning the procedure and should be recognized before it becomes irretrievable.

### Posterior capsular rupture

Rupture of the posterior capsule usually occurs during phacoemulsification or irrigation and aspiration, when a surgical instrument inadvertently comes into contact with the thin posterior capsule.

#### Rupture without vitreous loss

When the posterior capsule defect is small and vitreous is not lost, surgery may proceed relatively normally, with cautious implantation of the IOL in the capsular bag.

#### Rupture with vitreous loss

When a large posterior capsule defect exists, vitreous may advance anteriorly through the defect, requiring anterior vitrectomy. When IOL implantation into the capsular bag is not possible, it may be placed in the ciliary sulcus. Retinal detachment and cystoid macular oedema rates are higher in eyes in which vitreous is 'lost', than in those undergoing uncomplicated cataract surgery.

#### Dropped nucleus

If the posterior capsule is breached before phacoemulsification is complete, the nucleus may fall posteriorly into the vitreous cavity, in part or in its entirety. Referral to a vitreoretinal surgeon for vitrectomy and fragment removal is necessary. Failure to remove residual lens matter results in intraocular inflammation and raised IOP. Lens fragments may occasionally be retained in the anterior chamber. These also require surgical removal.

## Surgical trauma to ocular tissue

### Corneal trauma

Direct mechanical contact between surgical instruments or nuclear fragments and the corneal endothelium may occur, particularly if the anterior chamber is very shallow. Corneal wound burns may occur if high phaco energy is utilized; however, this is less common with improvements in phaco technology.

### Iris trauma

The soft, friable iris may be inadvertently aspirated into the phaco or irrigation and aspiration tip. Iris prolapse into one or both of the surgical wounds may occur as part of intraoperative floppy iris syndrome (IFIS). This is observed in some patients taking  $\alpha$ -antagonists, particularly Tamsulosin.

The characteristic triad of IFIS is:

- floppiness and billowing of the iris,
- iris prolapse into one or both of the surgical wounds,
- progressive pupillary constriction.

Iris trauma is evident postoperatively as transillumination defects.

### Zonular dehiscence

This is more likely in eyes with underlying zonular instability, for example Marfan's syndrome, pseudoexfoliation syndrome, or previous ocular trauma. IOL implantation in the capsular bag may be impossible, or result in poor IOL centration.

### Suprachoroidal haemorrhage

Risk factors for this feared complication include:

- age,
- high myopia,
- glaucoma or raised IOP,
- posterior capsule rupture,
- elective extracapsular cataract extraction or phaco conversion to extracapsular cataract extraction,
- diabetes,
- hypertension.

### Pathophysiology

Haemorrhage into the suprachoroidal space occurs after rupture of a short or long ciliary artery. In mild cases, the haemorrhage is small and localized. In severe cases progressive haemorrhage generates high IOP, displacing the intraocular contents from the globe. This is referred to clinically as an expulsive haemorrhage.

### Clinical evaluation

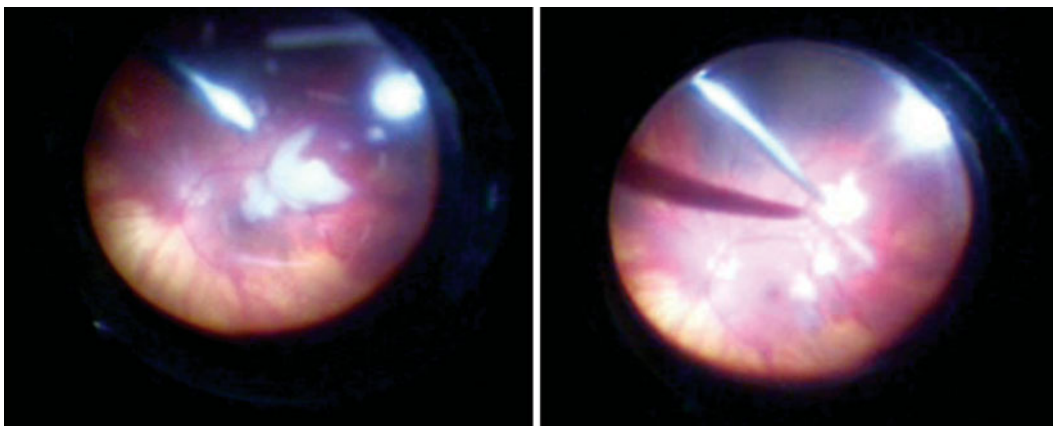
The globe becomes hard, the anterior chamber becomes more shallow, and the posterior capsule bulges anteriorly. A dark shadow may be evident within the pupil, obscuring the red reflex, which may be lost entirely if the haemorrhage progresses. Intraocular contents are extruded from the eye: first the iris, and in advanced cases lens, vitreous, and retina.

### Immediate management

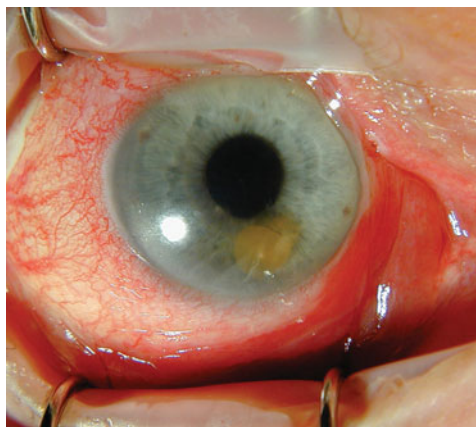
Surgical instruments should be withdrawn from the eye, and the wound closed immediately.

### Subsequent management

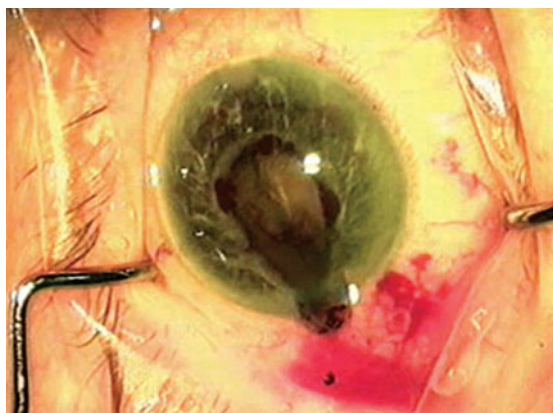
In cases of limited suprachoroidal haemorrhage the eye may be observed, monitoring reabsorption of the haemorrhage clinically and with B-scan ultrasound. Drainage sclerostomy may be performed to evacuate clot, and secondary anterior segment procedures may be required, for example secondary IOL implantation.



**Fig. 6.34** Dropped nuclear fragments, seen during secondary surgical procedure: vitrectomy and fragment removal (courtesy of R. Wong).



**Fig. 6.35** Nuclear fragment retained within the anterior chamber (courtesy of C. Jenkins).



**Fig. 6.36** Intraoperative iris prolapse.

## 6.6 Infectious postoperative complications of cataract surgery

### Acute postoperative endophthalmitis

Acute postoperative endophthalmitis is a sight-threatening medical emergency. Collection of diagnostic specimens followed by administration of intravitreal antibiotics should be performed in the operating theatre within 1 hour of diagnosis.

#### Incidence

Rates have fallen since the introduction of phacoemulsification. Reports vary from 0.015 to 0.5% of all cataract surgeries (European Society of Cataract and Refractive Surgeons Endophthalmitis Study Group 2007).

#### Risk factors

- Age.
- Vitreous loss.
- Non-use of intracameral cefuroxime.
- Clear corneal and temporal incisions (versus scleral tunnel incisions).
- Silicone (versus acrylic) IOL material.

#### Aetiology

Bacteria are inoculated into the eye during (or shortly after) cataract surgery via the surgical wound(s). The most common causative organisms are Gram-positive:

- coagulase-negative staphylococci,
- *Staphylococcus aureus*,
- *Streptococcus pneumoniae*,
- $\beta$ -haemolytic streptococci,
- viridans-group streptococci,
- Enterococci.

Gram-negative organisms are occasionally isolated:

- *Haemophilus influenzae*,
- *Pseudomonas aeruginosa*,
- *Escherichia coli*,
- *Serratia marcescens*,
- *Klebsiella*, *Moraxella*, and *Proteus* spp.

#### Pathogenesis

The presence and proliferation of bacteria within the eye incites a florid intraocular inflammatory response.

#### Clinical evaluation

##### History

Symptoms develop between 1 day and 2 weeks after cataract surgery:

- pain,
- redness,
- watering,
- photophobia,
- decreased vision,
- discharge.

##### Examination

- Reduced visual acuity.
- Relative afferent papillary defect.
- Loss of red reflex.
- Lid oedema.
- Proptosis.
- Chemosis and conjunctival congestion.
- Corneal oedema, infiltrate or abscess.
- Intense anterior chamber activity, with cells, flare, hypopyon, keratic precipitates, and fibrinous membrane on the IOL surface.

- Vitritis.
- Blurred or absent fundus view.

#### Differential diagnosis

- *Retained lens matter*: fragments of nuclear material or soft lens matter within the anterior chamber; capsular bag, or vitreous incite postoperative inflammation, and usually require removal.
- *Postoperative uveitis*: inflammation may be exaggerated in eyes with previous uveitis, or following lengthy or complicated surgery.
- *Toxic anterior segment syndrome*: this acute, sterile anterior uveitis typically occurs 12–24 hours after surgery. Inflammation is caused by contamination of fluids or instruments used in cataract surgery, and thus cases tend to occur in outbreaks. Endotoxins have been isolated in previous outbreaks. Treatment is with intensive steroid therapy.
- *Acute bacterial keratitis*.

#### Investigations

Diagnostic specimens for microbiological investigation must be taken:

- anterior chamber tap,
- vitreous sample obtained with vitreous cutter or portable vitrector. Gram stain, culture, sensitivities, and PCR should be performed on these specimens.

#### Management

- Intravitreal antibiotics:
  - ceftazidime 2mg in 0.1 mL or amikacin 0.4mg in 0.1 mL,
  - vancomycin 1mg in 0.1 mL.

Ceftazidime and vancomycin are physicochemically incompatible and should be administered in a separate needle and syringe.

- Intravitreal unpreserved steroid: dexamethasone 400  $\mu$ g in 0.1 mL, again with a separate needle and syringe.
- Vitrectomy if visual acuity perception of light or worse (Endophthalmitis Vitrectomy Study Group 1995).
- Systemic antibiotics in cases of acute virulent endophthalmitis, with the same antibiotics administered intravitreally.
- Consider systemic steroids in severe cases.
- Topical unpreserved fortified antibiotics.
- Topical unpreserved steroid.
- Topical unpreserved atropine.
- Admission to hospital in most cases.

Ongoing antibiotic therapy should be tailored to microscopy, culture, and sensitivity findings.

Cataract surgery pathways now incorporate steps specifically aimed at endophthalmitis prophylaxis.

#### Preoperative assessment

Lids should be evaluated closely for signs of infection and blepharitis. If present, infection should be treated and surgery rescheduled.

#### Operating theatre and surgical instruments

Operating theatres should ideally be equipped with appropriate air-flow design. All surgical instruments should be sterile. Single-use instruments are preferable when cost allows.

#### Surgical technique

Meticulous attention to skin preparation and draping, ensuring the surgical field is free from lashes. There is evidence for the use of povidone-iodine 5%. Surgical wound construction should generate a self-sealing incision; if not, suturing is required at the end of the procedure. Few instruments should be inserted into the eye, as few times as possible, and surgery should not be prolonged unnecessarily.



### Antibiotic prophylaxis

Various regimes are in use:

- preoperative topical antibiotic, for example levofloxacin,
- intraoperative intracameral cefuroxime (1mg in 0.1 mL),
- antibiotic in irrigating fluid, for example vancomycin,
- subconjunctival antibiotic, for example cefuroxime.

Use of intracameral cefuroxime at the end of surgery is advised by the European Society of Cataract and Refractive Surgeons Endophthalmitis Study Group.

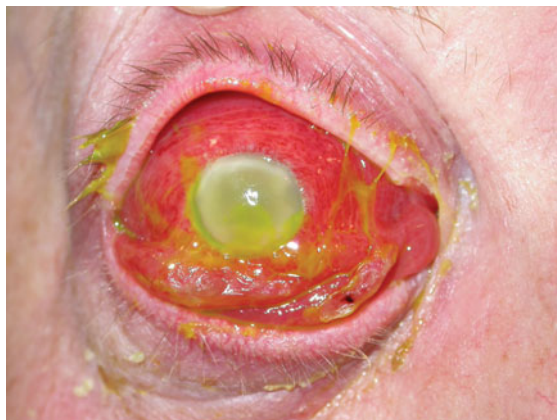### Chronic postoperative endophthalmitis

Rarely, endophthalmitis may present weeks or even years after uncomplicated cataract surgery with anterior uveitis, and associated vitritis. Initial response to steroids is good, and so diagnosis of endophthalmitis may be delayed. The clinical course is indolent, as causative organisms are of low virulence. Sequestration of bacteria within the capsular bag also contributes to the chronicity of these infections, and to their refractoriness to treatment. Inflammation may develop after Nd:YAG posterior capsulotomy, which 'releases' bacteria from the capsular bag.

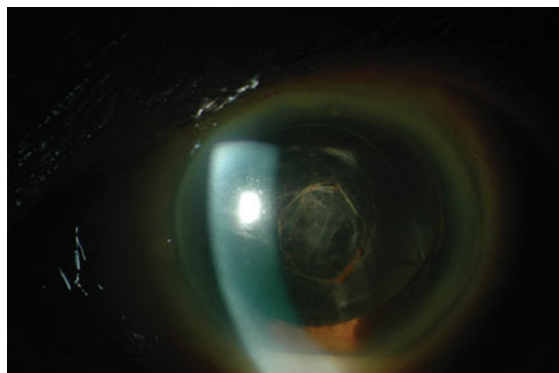
#### Aetiology

- *Propionibacterium acnes*.
- *Staphylococcus epidermidis*.
- Viridans-group streptococci.
- Gram-negative rod bacteria.

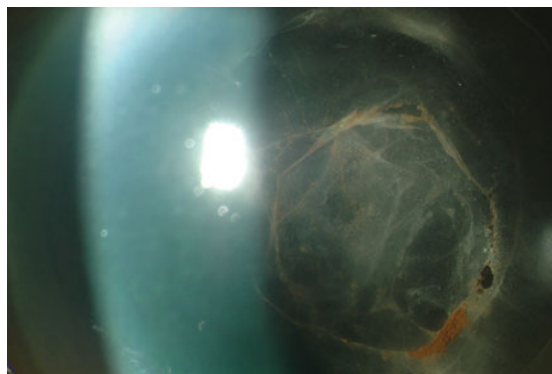
Eradication of infection is difficult, and in some cases requires IOL explantation and capsulectomy.



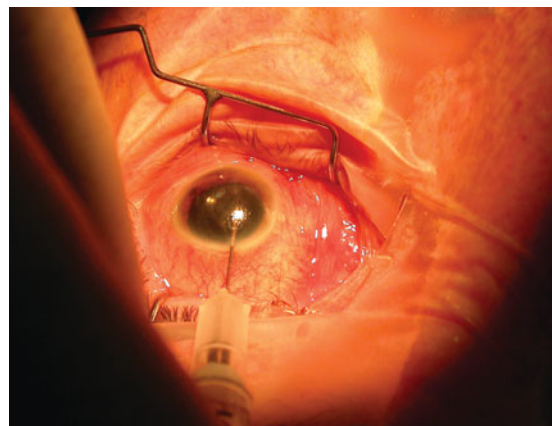
**Fig. 6.37** Severe postoperative endophthalmitis (courtesy of B. Dong).



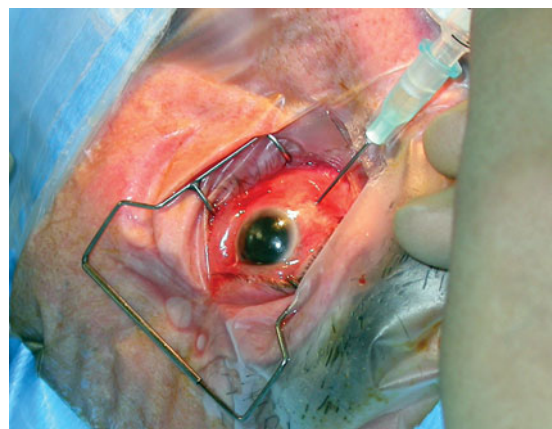
**Fig. 6.38** Postoperative endophthalmitis, with hypopyon and fibrous deposits on the anterior IOL surface.



**Fig. 6.39** Fibrin on anterior IOL surface.



**Fig. 6.40** Anterior chamber tap for diagnostic specimen.



**Fig. 6.41** Intravitreal antibiotic administration.

### Further reading

Endophthalmitis Vitrectomy Study Group. 1995. Results of the Endophthalmitis Vitrectomy Study. A randomized trial of immediate vitrectomy and of intravenous antibiotics for the treatment of postoperative bacterial endophthalmitis. *Arch. Ophthalmol.* **113**(12): 1479–1496.

Endophthalmitis Study Group, European Society of Cataract & Refractive Surgeons. 2007. Prophylaxis of postoperative endophthalmitis following cataract surgery: results of the ESCRS multicenter study and identification of risk factors. *J. Cataract Refract. Surg.* **33**(6): 978–988.

## 6.7 Non-infectious postoperative complications of cataract surgery

### Corneal decompensation/pseudophakic bullous keratopathy

Corneal clarity is maintained by the corneal endothelium. The endothelium may be compromised during cataract surgery by direct mechanical trauma, or by phaco energy, resulting in decompensation.

Factors predisposing to corneal decompensation include:

- Fuchs endothelial dystrophy,
- corneal guttata,
- age (endothelial cell density declines with age),
- prolonged or complicated surgery,
- high phaco energy.

### Cystoid macular oedema

Clinical cystoid macular oedema is the most common cause of adverse visual outcomes following cataract surgery, occurring in 0.1–1.0% of cases. Angiographic evidence for cystoid macular oedema is found in a much greater proportion of patients; however, most are asymptomatic.

#### Risk factors

- Pre-existing systemic disease; for example diabetes or hypertension.
- Pre-existing ocular disease; for example, uveitis or diabetic retinopathy.
- Surgical complications; for example, vitreous loss.

### IOL malposition

IOLs may be decentred, tilted, subluxated, or completely dislocated into the anterior chamber or vitreous cavity. This may result from:

- zonular instability or dialysis,
- inadequate capsular support, for example poor capsulorrhexis construction or posterior capsular defect,
- poor intraoperative IOL placement.

Mild decentration may be observed. Dislocated IOLs may cause reduced visual acuity, inflammation, raised IOP, cystoid macular oedema, and retinal detachment. Treatment options include:

- IOL repositioning (with or without suturing),
- IOL exchange,
- IOL removal.

### Retinal detachment

#### Incidence

Cumulative risk of retinal detachment continues for up to 20 years following cataract surgery. The risk is up to 1.79% after 20 years.

#### Risk factors

- Patient factors: male sex, older than 65 years.
- Ocular factors: axial length greater than 23 mm.
- Surgical factors: posterior capsule tear/vitreous loss, zonular dehiscence.

#### Management

Referral to a vitreoretinal service for retinal detachment repair.

### Posterior capsule opacification (PCO)

PCO results in reduced visual acuity following cataract surgery, and is referred to as 'after cataract' by some.

#### Incidence

PCO is the most common complication of cataract surgery. Incidence rates for PCO are highly variable, depending on patient, surgical, and IOL factors.

Nd:YAG capsulotomy rates are often utilized as a proxy measure for PCO, and cumulative incidence rates as high as 33% have been reported. However, this has fallen significantly since the introduction of hydrophobic acrylic, square-edged IOLs.

#### Risk factors

- Patient factors: young age, uveitis.
- Surgical factors: residual cortical lens matter, incomplete overlap of the capsulorrhexis on the IOL optic, sulcus fixation of the IOL.
- IOL factors: IOLs without a square posterior edge have a higher rate of PCO, hydrophilic acrylic IOLs have higher rates of PCO than hydrophobic acrylic.

#### Pathogenesis

PCO results from proliferation of lens epithelial cells on to the posterior capsule.

#### Management

PCO is treated in the outpatient clinic with Nd:YAG laser posterior capsulotomy (section 6.15).

### Anterior capsule opacification

In the months following cataract surgery, the anterior capsule may opacify, and the capsulorrhexis contract (anterior capsular phimosis). Contraction of the anterior capsule may adversely affect IOL position, while opacification precludes a complete view of the retina.

#### Risk factors

- High myopia.
- Pseudoexfoliation.
- Uveitis.
- Retinitis pigmentosa.
- Diabetes mellitus.

#### Management

Phimosis may be treated with Nd:YAG laser anterior capsulotomy.

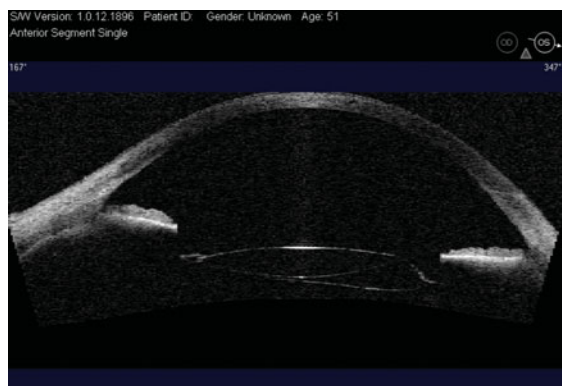### Postoperative refractive error

A 'refractive surprise' may result from:

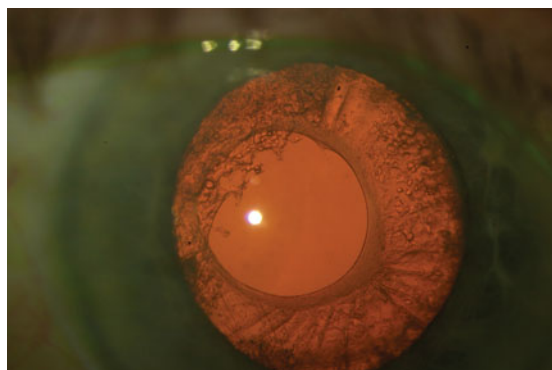
- errors in IOL choice; for example, utilizing biometry for the wrong eye,
- inaccurate biometry, for example posterior staphyloma, underestimation of axial length by A-scan ultrasound,
- previous corneal refractive surgery,
- long axial length, causing unpredictability of refractive outcome.

#### Management

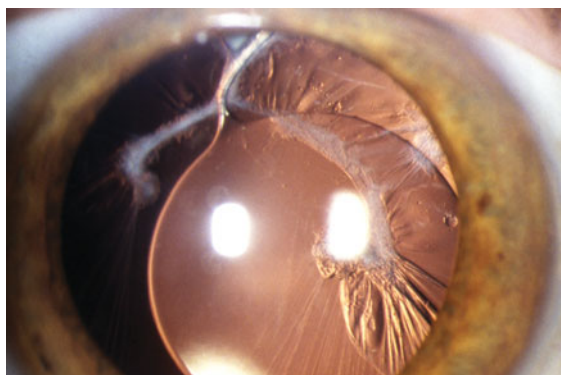
- Spectacle or contact lens correction of refractive error.
- IOL exchange.
- Corneal refractive surgery.



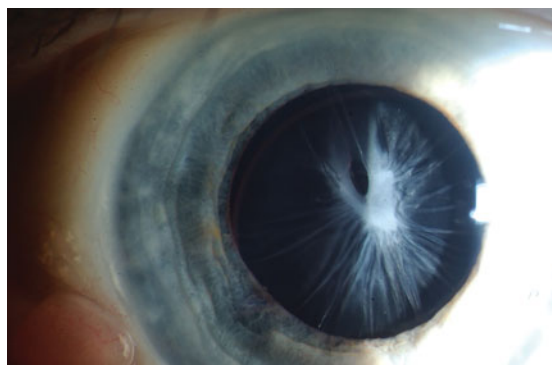**Fig. 6.42** Tilted IOL, demonstrated with OCT.



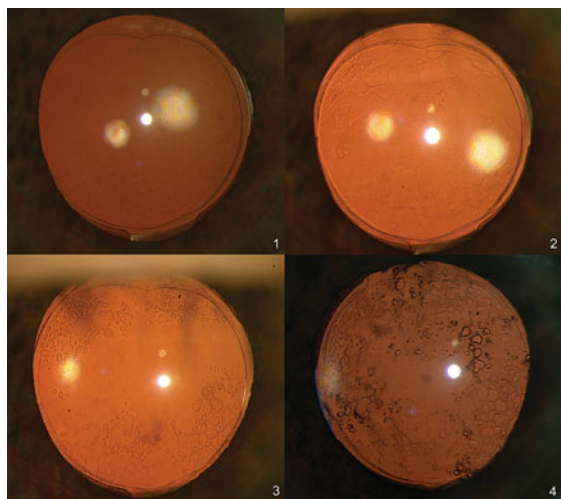
**Fig. 6.45** Anterior capsule opacification and fibrosis.



**Fig. 6.43** Subluxated IOL.



**Fig. 6.46** Severe anterior capsule opacification and fibrosis (courtesy of E. Hughes).



**Fig. 6.44** Progression of PCO.

## 6.8 Congenital cataract

Bilateral congenital cataract is the most common cause of treatable childhood blindness. The management of congenital cataract is considerably different to that of acquired cataract in adults. The most critical difference is that congenital cataracts carry a risk of stimulus-deprivation amblyopia, and must be treated urgently. Incidence is approximately 3 per 10,000 population.

### Aetiology

#### Bilateral cataract

- Idiopathic.
- Hereditary, with no associated systemic disease.
- Associated with systemic disease.
- Metabolic:
  - galactosaemia (oil droplet cataracts),
  - galactokinase deficiency,
  - Lowe's syndrome,
  - hypocalcaemia (diffuse lamellar punctate cataract),
  - hypoglycaemia.
- Chromosomal:
  - Down syndrome (trisomy 21; snowflake cataract),
  - Turner syndrome,
  - Patau syndrome (trisomy 13),
  - Edward syndrome (trisomy 18).
- Intrauterine infections (toxoplasmosis, rubella, CMV, herpes simplex, and HIV; also known as TORCH):
  - rubella,
  - CMV,
  - toxoplasmosis
  - HSV,
  - VZV
  - syphilis.
- Associated with ocular disease:
  - aniridia,
  - coloboma (lens and/or iris),
  - Peter's anomaly.

#### Unilateral cataract

- The majority of cases are idiopathic.
- Association with systemic disease is uncommon.
- May be associated with other lens abnormalities:
  - lenticonus,
  - lentiglobus,
  - persistent foetal vasculature.

May actually be bilateral congenital cataracts, with asymmetric severity.

### Clinical evaluation

#### History

History obtained from parents may include:

- family history of congenital cataract,
- observation of a white pupil,
- squint,
- abnormality found at a routine health check.

#### Examination

##### General inspection

- Presence of dysmorphic features suggesting a systemic association.
- Leukocoria (white pupil).

##### Visual function assessment

- Does the child fix and follow?
- Visual interaction with faces, especially parents.

- Preferential looking tests in infants (Cardiff and Teller acuity cards).
- Picture cards (Kay cards), letters (Sheridan–Gardiner) in older children.
- Objection to occlusion of either eye.

##### Ocular examination

It may be necessary to examine the child under sedation or general anaesthesia.

Prior to pupil dilation, assess for:

- nystagmus,
- strabismus,
- the red reflex, with a direct ophthalmoscope,
- IOP, with a tonopen or air puff tonometry,
- corneal diameter.

After pupil dilation, assess for:

- the red reflex,
- presence of congenital cataract in the fellow eye,
- careful anterior and posterior segment examination, looking for coexisting ocular disease, for example persistent hyperplastic primary vitreous, coloboma.

##### Assessment of cataract density

- Visually insignificant cataract: retinal vessels are visible with the direct and indirect ophthalmoscope.
- Visually significant cataract: retinal vessels are visible with the indirect ophthalmoscope, but not the direct ophthalmoscope.
- Dense cataracts preclude all retinal view.

## Common morphological types

### Nuclear cataract

- Located in the centre of the crystalline lens, in the embryonic and foetal nuclei.
- Often very dense centrally.
- Present at birth.
- Non-progressive.
- Bilateral in 80% of cases.
- Autosomal dominant inheritance.
- Surgery for dense nuclear cataracts is essential.

### Posterior cataract

- Associated with persistent hyperplastic primary vitreous, posterior lenticonus, posterior lentiglobus.
- Abnormal retrolental vasculature results in abnormal posterior lens development.
- Develops after 2–3 months of age.
- Usually unilateral.
- Sporadic.
- Risk of posterior capsular defects and haemorrhage from abnormal vasculature during surgery.

### Lamellar cataract

- Opacity occurs in the layer between the nucleus and cortex.
- Bilateral.
- Develops after fixation is established.
- Progressive.
- Autosomal dominant inheritance.

### Other less common types

- Sutural cataract.
- Anterior polar cataract.
- Blue dot cataract.



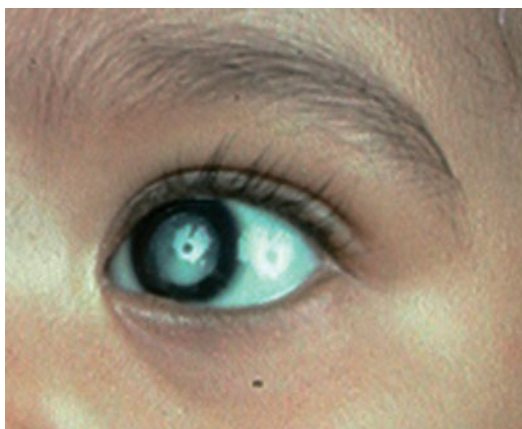
- Coronary cataract.
- Membranous cataract.

#### Investigations

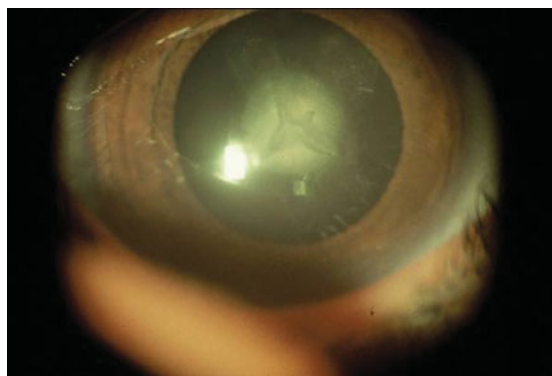
Paediatric referral for underlying systemic disease may be necessary.

Investigations include:

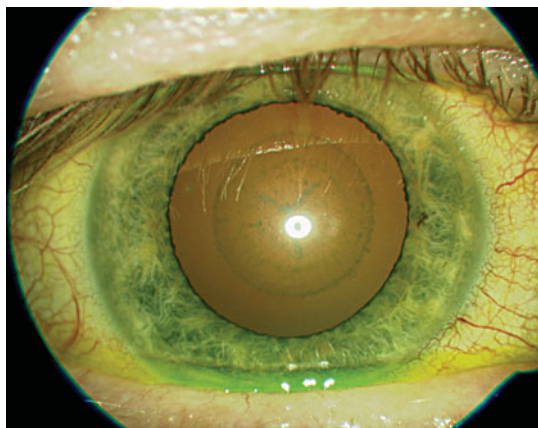
- serology for intrauterine infections (toxoplasmosis, rubella, CMV, herpes simplex, and HIV; TORCH),
- chromosomal analysis,
- blood sugar and calcium.
- Urine tests for reducing substances after milk feeding (galactosaemia), amino acids (Lowe's syndrome).
- B-scan ultrasound if the fundus cannot be visualized.



**Fig. 6.47** Congenital cataract: leucocoria (courtesy of L. Amaya).



**Fig. 6.49** Congenital cataract: sutural morphology (courtesy of L. Amaya).



**Fig. 6.48** Congenital cataract: lamellar morphology (courtesy of E. Hughes).



## 6.9 Management of congenital cataract

The main aim of congenital cataract treatment is the prevention of stimulus-deprivation amblyopia. If untreated, amblyopia may be dense and permanent, with associated nystagmus.

The critical period for visual development is in the first 2 months of life. Visual deprivation during this period can result in profound and irreversible amblyopia. After 2–3 months, amblyopia is reversible to some degree with treatment. After 6–7 years, the visual system is no longer susceptible to amblyopia.

### Management options

Management depends on cataract location, density, and whether the cataract is bilateral or unilateral.

#### Incomplete 'visually insignificant' cataracts

When the retinal vasculature is visible though the central portion of a cataract it may be considered visually insignificant.

- Bilateral cases can be managed with close monitoring.
- Unilateral cases can be managed with occlusion therapy (patching).

#### Visually significant cataracts

Congenital cataracts with the following properties are considered visually significant and amblyogenic. They require surgical removal.

- Dense central cataracts more than 3.0 mm in diameter.
- Dense nuclear cataracts.
- Cataracts obscuring the retinal vasculature with either the direct or indirect ophthalmoscope.
- Cataracts associated with strabismus.

Surgery is only the beginning of congenital cataract management. Many challenging years of occlusion therapy, contact lenses, spectacles, and possibly further surgical procedures may follow. It is imperative that parents are educated and prepared for this.

### Surgical technique for congenital cataracts

Surgical management of paediatric cataract is more difficult than adult cases. Reasons for this include the following.

- Smaller dimensions of paediatric eyes. The anterior chamber is shallow, and this is further exacerbated by higher vitreous pressure.
- The lens capsule is highly elastic, making CCC more difficult.
- Significantly higher rates of PCO occur in paediatric eyes. Thus both anterior and posterior capsulorhexes are performed in most cases.
- Postoperative inflammation is more pronounced.

Surgery is performed under general anaesthesia.

The steps commonly performed in paediatric cataract surgery are described here.

#### Step 1 Incisions

The cataract is approached via limbal or pars plana incisions.

#### Step 2 Viscoelastic insertion

A high-viscosity viscoelastic is inserted to maintain the anterior chamber.

#### Step 3 Anterior capsulorhexis

Manual tearing of the anterior CCC is used most often, although other techniques are described (diathermy and vitrectorhexis). A circular hole is torn into the elastic capsule. If an IOL is to be implanted the CCC should be well centred and smaller than the IOL optic.

#### Step 4 Hydrodissection

This must be undertaken with great caution, or even avoided in the presence of posterior polar cataract.

#### Step 5 Irrigation and aspiration

Phacoemulsification is generally not required in paediatric cataracts, which are soft and can be aspirated. Occasionally, very dense cataracts require phaco power. Lens matter should be removed meticulously, due to risks of postoperative inflammation and PCO.

#### Step 6 Posterior capsulorhexis

This is performed after refilling the capsular bag with viscoelastic. The posterior capsule is thinner than the anterior; and may be torn or cut.

#### Step 7 Anterior vitrectomy

Posterior capsulorhexis does not guarantee PCO prevention, as lens epithelial cells can grow across the anterior hyaloid face. For this reason anterior vitrectomy is often performed.

#### Step 8 IOL insertion

The IOL may be inserted into the capsular bag if it is implanted on the day of cataract extraction, or it may be placed in the ciliary sulcus at a later date, leaving the eye temporarily aphakic (see below).

#### Step 9 Viscoelastic removal

#### Step 10 Pupil constriction

Acetylcholine (Miochol) is administered into the eye. The anterior chamber can be checked for residual vitreous, which will 'peak' the pupil if present.

#### Step 11 Suturing of surgical wound

#### Step 12 Antibiotic and anti-inflammatory drugs

Intracameral antibiotic and subconjunctival steroid may be administered.

### Complications of congenital cataract surgery

In principle, all of the complications of adult cataract surgery apply to paediatric cataract surgery.

Some complications are exaggerated in paediatric eyes.

#### PCO

80% of paediatric eyes with an intact posterior capsule develop PCO. This complication is addressed by performing a posterior capsulorhexis and anterior vitrectomy in young children, and those children who are unlikely to cooperate with Nd:YAG laser capsulotomy. In older, more cooperative children, the posterior capsule may be left intact, and laser capsulotomy performed in the outpatient clinic at a later date. PCO can recur despite Nd:YAG capsulotomy, and sometimes secondary surgical interventions are required.

#### Postoperative uveitis

Inflammation following cataract surgery is higher in children than in adults, with a risk of posterior synechiae. Topical postoperative steroids are more intensive (e.g. 8–10 times per day) and are tapered for longer periods. Mydriatic drops are also administered in the early postoperative period to prevent posterior synechiae.

#### Glaucoma

Risk is greatest in eyes operated in the first 9 months of life, and those that remain aphakic. Glaucoma may not develop for many years and thus monitoring is required for life.

### Postoperative ametropia

Ametropia must be addressed immediately after surgery, especially in aphakic eyes. Contact lenses may be inserted in the operating theatre. Implantation of an IOL reduces the strength of refractive correction required. Regular refraction and monitoring for amblyopia is required.

## Timing and choice of IOL implant

### Timing

In the past, IOL implantation was performed as a secondary procedure in children. Increasingly, IOLs are implanted during the primary cataract extraction procedure. Primary IOL implantation allows IOL fixation within the capsular bag (versus sulcus fixation).

### IOL power

The globe continues to grow until approximately 10 years of age. Implantation of an IOL of fixed power results in dynamic changes in refractive status with ocular growth. As with adult cataract surgery, refractive outcomes can be planned.

### Hypermetropia at the time of IOL implantation

This option is used in cases of unilateral or bilateral cataract and, and allows the globe to 'grow into' the refractive power of the IOL, aiming for emmetropia when ocular growth is complete.

Normograms are available to predict the IOL power required.

Hypermetropia is treated with spectacles or contact lenses in the interim.

These children are likely to require bifocal spectacles throughout life.

### Emmetropia at the time of IOL implantation

This strategy may be utilized in cases of unilateral cataract. It allows optimum vision at a time when amblyopia risk is high.

Progressive myopia ensues with ocular growth, requiring spectacle or contact lens correction.

Myopia may be surgically addressed at a later date, and possible treatment options include:

- corneal refractive procedures,
- piggyback IOL implantation.

### IOL biomaterial

Hydrophobic acrylic IOLs are soft, foldable, and have demonstrated good biocompatibility, including good PCO performance. Their use is increasing.

Heparin surface modified polymethylmethacrylate IOLs have been used for many years. They display good biocompatibility, but are not foldable, and thus must be inserted via a larger wound.

Silicone IOLs show a tendency towards capsular contraction.

### Contraindications to IOL implantation

Microcornea, microphthalmos, and uveitis are contraindications to IOL implantation.

## 6.10 Lens dislocation

### Lens dislocation

Displacement of the crystalline lens from its normal location within the eye is also known as ectopia lentis. It may be incomplete (subluxation) or complete (luxation).

#### Aetiology

Congenital:

- Marfan's syndrome,
- familial ectopia lentis,
- ectopia lentis et pupillae,
- homocystinuria,
- Weill–Marchesani syndrome,
- spherophakia,
- Ehlers–Danlos syndrome,
- hyperlysinaemia,
- aniridia,
- Stickler syndrome.

Acquired:

- trauma,
  - pseudoexfoliation,
  - uveal tumours.
- Idiopathic.

#### Pathogenesis

Loss of zonular support for the crystalline lens results in dislocation.

#### Clinical evaluation

##### Subluxed lens

- Visual acuity may be normal or reduced.
- The lens equator and zonular fibres, usually obscured by the iris, are visible through a dilated pupil.
- With progressive subluxation, the lens equator approaches the optical axis and may be visible through an undilated pupil.
- Phacodonesis and iridodonesis are present.
- The direction of subluxation varies with aetiology:
  - Marfan's syndrome: typically superotemporal,
  - homocystinuria: inferonasal,
  - familial ectopia lentis: superotemporal.

##### Luxated (dislocated) lens

- Anterior chamber dislocation: the entire lens is visible anterior to the iris. There may be associated corneal decompensation due to endothelial touch, uveitis and raised IOP. Incarceration in the pupillary aperture may result in pupil block and acute glaucoma.
- Posterior capsule dislocation: the crystalline lens may be visualized free in the vitreous cavity, either directly or with indirect ophthalmoscopy. There may be associated uveitis, retinal tears, or retinal detachment.

#### Management

Management is determined by the degree of subluxation and visual acuity. There is a risk of ametropic or meridional amblyopia in children with subluxed lenses, and these cases require close observation and early intervention when visual acuity is impaired.

##### Mild subluxation with normal visual acuity

Observation.

##### Moderate to severe subluxation

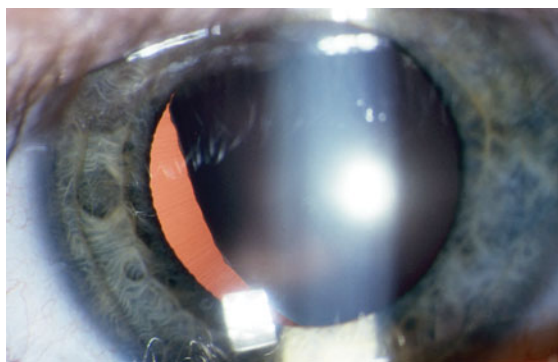
With progressive displacement, the lens periphery and equator approach the optical axis, resulting in refractive error, aberrations, edge effects, and reduced visual acuity. The lens may dislocate beyond the visual axis, making the eye optically aphakic.

- Conservative management: refractive correction with contact lenses or spectacles.
- Surgical management: usually involves extraction of the crystalline lens, and IOL implantation. Compared to standard cataract surgery, additional measures are required to stabilize the IOL implant within the capsular bag:
  - capsular tension ring insertion (with or without scleral fixation),
  - scleral IOL fixation,
  - anterior chamber IOL implantation.

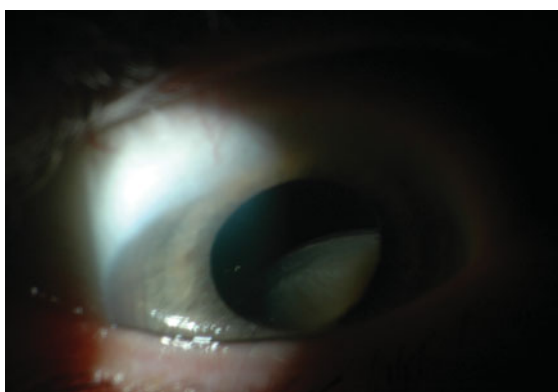
##### Luxation

- Anterior chamber dislocation: pupillary dilation and supine posturing can return the lens to the retropupillary plane. Endothelial touch, uveitis, and acute glaucoma are indications for lens extraction.
- Posterior capsule dislocation requires a vitreoretinal referral for pars plana vitrectomy and lens extraction.

IOL implantation may be performed at the time of lens extraction, or as a secondary procedure at a later date.



**Fig. 6.50** Subluxated crystalline lens, associated with Marfan's syndrome. Zonules are visible.



**Fig. 6.51** Luxated crystalline lens, associated with Marfan's syndrome.

## 6.11 Biometry

Contemporary cataract surgery improves vision by removal of the opaque crystalline lens. The procedure also provides an opportunity to correct existing spherical refractive errors (myopia and hypermetropia). Thus, in the absence of coexisting ocular disease, good uncorrected distance visual acuity should be achieved.

### IOL power calculations

In order to achieve target refraction, an IOL of correct power must be implanted. The original SRK formula (after Sanders, Retzlaff, and Kraff) described the relationship between refractive outcome, IOL power, axial length, and keratometry values.

$$P = A - B(AL) - C(K)$$

where  $P$  = IOL power (in dioptres, D),  $A$  = constant specific to an individual IOL's design and its axial position within the eye,  $B$  = multiplication constant for axial length measurement,  $AL$  = axial length (mm),  $C$  = multiplication constant for keratometry measurement, and  $K$  = average keratometry measurement (in dioptres).

#### For emmetropia

$$P = A - 2.5(AL) - 0.9(K)$$

#### For non-emmetropic refractive targets

$$P = A - 2.5(AL) - 0.9(K) - D(R)$$

where  $D$  = multiplication constant for target refraction and  $R$  = target refraction (in dioptres).

Note that errors in axial length measurement are multiplied by a factor of 2.5, and thus can have a considerable effect on refractive outcome.

The SRK formula itself is no longer in use; it has been superseded by more accurate formulae. Formulae in widespread use include:

- SRK II,
- SRK/T,
- Holladay,
- Haigis (also requires anterior chamber depth).

### Obtaining measurements for IOL power calculation

Accurate IOL power calculations are dependent on accurate  $AL$  and  $K$  measurements.

Devices in use for obtaining these biometric data:

- IOL Master (Zeiss),
- applanation A-scan ultrasound,
- immersion A-scan ultrasound.

#### IOL Master

##### Principle used

- Partial coherence interferometry. Uses  $AL$ ,  $Ks$ , and anterior chamber depth.

##### Advantages

- Rapid.
- High accuracy ( $\pm 0.02$  mm).
- Reproducible.
- Non-contact.
- Measures along the visual axis.
- One device for all measurements.

##### Disadvantages

Difficulty obtaining  $AL$  measurements with very dense cataracts, especially posterior subcapsular cataracts.

#### Applanation A-scan ultrasound

##### Principle used

10MHz ultrasound, probe contacts (and slightly indents) the cornea directly. Uses  $AL$  and anterior chamber depth.

##### Advantages

Can obtain  $AL$  measurement despite dense cataract.

##### Disadvantages

- Less accurate than IOL Master or immersion ultrasound.
- Corneal indentation during applanation may result in underestimation of  $AL$  and a myopic refractive outcome.
- Directly contacts the cornea, thus requires topical anaesthetic drops, and carrying infection risks.
- Measurement is not always along the visual axis.
- Risk of  $AL$  overestimation in the presence of posterior staphyloma.
- Keratometry data must be obtained on another device.
- Correction factor required when silicone oil is present within the eye.

#### Immersion ultrasound

##### Principle used

- 10MHz ultrasound, probe contacts the eye via a coupling fluid. Uses  $AL$  and anterior chamber depth.

##### Advantages

- Able to obtain  $AL$  measurements despite dense cataracts.
- Measures along the visual axis.
- Contacts via a coupling fluid, therefore does not indent the cornea.
- Immersion vector A-scan/B-scan can be combined to image the eye two-dimensionally, of use when posterior staphyloma is present.

##### Disadvantages

- Less accurate than IOL Master ( $\pm 0.10$ – $0.12$  mm).
- Keratometry must be measured on another device.
- Correction factor required when silicone oil is present in the eye.

#### Pentacam

##### Principle used

Images the anterior segment of the eye by capturing multiple cross-sectional images with a rotating Scheimpflug camera. Three-dimensional images and measurements of the anterior chamber are generated. Uses  $Ks$ .

##### Advantages

- Generates data from both anterior and posterior corneal surfaces, thus calculating the 'True Net Power' of the cornea.
- Useful for calculating IOL power in eyes with abnormal corneal shape, for example ectasia, post-LASIK.
- Useful for evaluating anterior chamber dimensions before phakic IOL implantation.

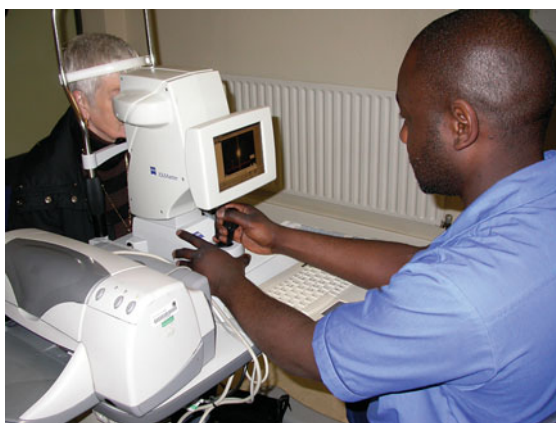##### Disadvantages



Axial length must be measured on another device.



**Table 6.1 Checklist for selecting IOL power**

Is it the correct patient?
Is it the correct eye?
Keratometry <ul style="list-style-type: none"> <li>Do the three measurements agree?</li> <li>Select location for on-axis corneal incisions if appropriate.</li> </ul>
Axial length <ul style="list-style-type: none"> <li>Is the signal curve valid?</li> <li>Signal-to-noise ratio (SNR): clear signal SNR &gt;2, very good signal SNR &gt;10.</li> <li>Morphology of signal curves: clear peaks (maxima) on a low baseline.</li> </ul>
Are the axial lengths of the two eyes similar (within 0.5 mm)? If not, is the difference supported clinically by anisometropia?
What IOL type will be implanted? Is the A constant correct?
For second-eye surgery <ul style="list-style-type: none"> <li>What IOL was implanted into the first eye?</li> <li>Was the refractive target met?</li> <li>If not, why not?</li> </ul>
What is the refractive target?
Pitfalls <ul style="list-style-type: none"> <li>Is there silicone oil in the vitreous cavity?</li> <li>Is there a history of corneal refractive surgery?</li> </ul>

**Fig. 6.52** Optical biometry measurement with IOL Master.

Name: <b>CLEARY, GEORGIA</b>				Date of Birth: <b>05/11/1976</b>							
ID: _____				Exam Date: <b>09/11/2007</b>							
OD (right)		axial length values				OS (left)					
AL	SNR	AL	SNR	AL	SNR	AL	SNR				
24.45 mm	2.1	24.49 mm	3.1	24.33 mm	5.3	24.36 mm	2.8				
24.48 mm	2.8	24.48 mm	6.0	> 24.30 mm < 11.1		24.31 mm	6.2				
24.53 mm	2.8			24.28 mm	2.9	24.26 mm	7.5				
24.51 mm	7.2			24.32 mm	3.9	24.28 mm	1.6				
24.47 mm	2.5			24.32 mm	2.6	24.30 mm	2.9				
24.49 mm	6.2			24.27 mm	4.8						
> 24.49 mm < 10.7				24.32 mm	6.5						
24.48 mm	4.0			24.30 mm	6.8						
24.47 mm	4.1			24.29 mm	2.7						
24.51 mm	9.5			24.27 mm	7.6						
average AL: 24.49 mm				average AL: 24.30 mm							
											
OD (right)		corneal curvature values				OS (left)					
K1: 44.06 D @ 7°	7.66 mm	K1: 43.60 D @ 1°	7.74 mm			K1: 43.60 D @ 1°	7.74 mm				
K2: 45.18 D @ 93°	7.47 mm	K2: 45.30 D @ 91°	7.45 mm			K2: 45.30 D @ 91°	7.45 mm				
AD: +1.12 D @ 93°		AD: +1.70 D @ 91°				AD: +1.70 D @ 91°					
K1: 43.95 D @ 17°	7.68 mm	K1: 43.72 D @ 6°	7.72 mm			K1: 43.72 D @ 6°	7.72 mm				
K2: 45.06 D @ 107°	7.49 mm	K2: 45.30 D @ 96°	7.45 mm			K2: 45.30 D @ 96°	7.45 mm				
AD: +1.11 D @ 107°		AD: +1.58 D @ 96°				AD: +1.58 D @ 96°					
K1: 43.66 D @ 1°	7.73 mm	K1: 43.49 D @ 4°	7.76 mm			K1: 43.49 D @ 4°	7.76 mm				
K2: 45.49 D @ 91°	7.42 mm	K2: 45.24 D @ 94°	7.46 mm			K2: 45.24 D @ 94°	7.46 mm				
AD: +1.83 D @ 91°		AD: +1.75 D @ 94°				AD: +1.75 D @ 94°					
n: 1.3375		n: 1.3375				n: 1.3375					
OD (right)		anterior chamber depth values				OS (left)					

**Fig. 6.53** Biometry data from IOL Master.

Name: <b>CLEARY, GEORGIA</b>		ID:	
Date of Birth: <b>05/11/1976</b>		Eye Surgeon: <b>St. Thomas'</b>	
Exam Date: <b>09/11/2007</b>		Formula: <b>SRK/T</b>	
Preoperative Data:			
AL: <b>24.49 mm</b>	Refraction:	<b>OD</b> right	
K1: <b>43.66 D @ 1°</b>	Visual Acuity:		
K2: <b>45.49 D @ 91°</b>	Eye Status: <b>phakic</b>		
opt. ACD:	Target Ref: <b>plano</b>		
acrysof SA60			
A Const: 118.8	A Const: 118.4	A Const: 118.8	A Const: 118.9
IOL (D) REF (D)	IOL (D) REF (D)	IOL (D) REF (D)	IOL (D) REF (D)
18.5 -1.11	18.0 -1.05	18.5 -1.11	18.5 -1.03
18.0 -0.77	17.5 -0.71	18.0 -0.77	18.0 -0.70
17.5 -0.44	17.0 -0.38	17.5 -0.44	17.5 -0.37
17.0 -0.12	16.5 -0.05	17.0 -0.12	17.0 -0.05
16.5 0.21	16.0 0.28	16.5 0.21	16.5 0.27
16.0 0.52	15.5 0.61	16.0 0.52	16.0 0.58
15.5 0.84	15.0 0.93	15.5 0.84	15.5 0.90
Preoperative Data:			
AL: <b>24.30 mm</b>	Refraction:	<b>OS</b> left	
K1: <b>43.49 D @ 4°</b>	Visual Acuity:		
K2: <b>45.24 D @ 94°</b>	Eye Status: <b>phakic</b>		
opt. ACD:	Target Ref: <b>plano</b>		
acrysof SA60			
A Const: 118.8	A Const: 118.4	A Const: 118.8	A Const: 118.9
IOL (D) REF (D)	IOL (D) REF (D)	IOL (D) REF (D)	IOL (D) REF (D)
19.0 -0.88	19.0 -1.18	19.0 -0.88	19.5 -1.14
18.5 -0.54	18.5 -0.83	18.5 -0.54	19.0 -0.80
18.0 -0.21	18.0 -0.49	18.0 -0.21	18.5 -0.47
17.5 0.11	17.5 -0.16	17.5 0.11	18.0 -0.14
17.0 0.44	17.0 0.18	17.0 0.44	17.5 0.18
16.5 0.76	16.5 0.51	16.5 0.76	17.0 0.50
16.0 1.07	16.0 0.83	16.0 1.07	16.5 0.82

**Fig. 6.54** IOL calculations from IOL Master.

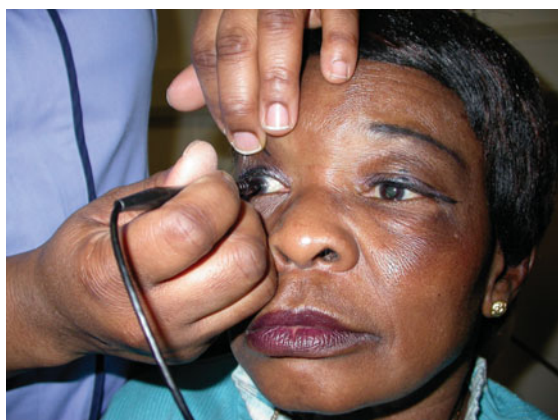


Fig 6.55 Axial length measurement with applanation ultrasound.

## LEFT

AUT02 Dense Cataract  
Velocity :Avg 1548 m/s  
Velocity :LENS 1629 m/s  
Gain : 7

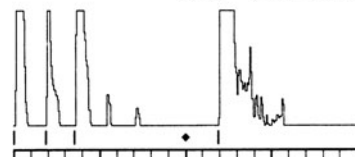
Avg AXIAL: **24.24 mm**

SD : 0.04 mm RANGE : 0.11 mm

Avg ACD : 3.71 mm

Avg LENS : 5.60 mm

NO. 10 AXIAL :24.19 mm  
ACD : 3.66 mm  
LENS : 3.65 mm



## SRK/T

### Input Parameters

AXIAL : 24.19 mm

K1 : 43.37 D

K2 : 45.00 D

Ds Ref : 0.00 D

	A	B	C
A-const. :	118.40	118.80	115.30
Power :	17.80	18.22	14.98

A		B	
IOL	Ref.	IOL	Ref.
16.50	0.86	16.50	1.11
17.00	0.53	17.00	0.79
17.50	0.20	17.50	0.47
<b>18.00</b>	<b>-0.14</b>	<b>18.00</b>	<b>0.14</b>
18.50	-0.48	18.50	-0.19
19.00	-0.82	19.00	-0.52
19.50	-1.17	19.50	-0.86

C	
IOL	Ref.
13.50	1.13
14.00	0.75
14.50	0.37
<b>15.00</b>	<b>-0.02</b>
15.50	-0.41
16.00	-0.80
16.50	-1.21

Fig 6.56 A-scan trace.

*This page intentionally left blank*

## 6.12 Local anaesthesia

According to a 2003 UK survey, 95% of cataract surgeries are performed under local anaesthesia. General anaesthesia is thus the exception, and indications for general anaesthesia include:

- young age,
- anxiety,
- claustrophobia,
- inability to lie flat,
- inability to lie still.

There are various modalities of local anaesthesia in use. Earlier forms of local anaesthesia for cataract surgery aimed for complete akinesia, in addition to anaesthesia. However, retrobulbar and peribulbar anaesthesia carry the risk of serious complications, and their use is declining. There is a trend towards less invasive methods of local anaesthesia, which provide anaesthesia with less effective or no akinesia. While a mobile eye may be considered problematic by inexperienced cataract surgeons, it can also be of benefit, as changes in ocular position can make some surgical manoeuvres easier.

### Topical anaesthesia

#### Technique

Drops of a topical local anaesthetic agent, for example tetracaine 1.0%, are administered into the conjunctival fornix preoperatively.

#### Advantages

- Fast.
- Rapid visual recovery.
- No postoperative diplopia.

#### Disadvantages

- Ocular motility preserved.
- Limited anaesthesia of intraocular structures, for example iris.

### Topical-intracameral anaesthesia

This technique begins with topical anaesthesia, supplemented with intracameral anaesthetic solution.

#### Technique

Topical anaesthesia is administered as above. The first corneal incision is made, then a preservative-free local anaesthetic solution, for example lignocaine 1.0%, is injected into the anterior chamber using a blunt-tipped a cannula.

#### Advantages

- Fast.
- Rapid visual recovery.
- No postoperative diplopia.
- Good anaesthesia of intraocular structures.

#### Disadvantages

Ocular motility preserved.

### Sub-Tenon anaesthesia

Sub-Tenon anaesthesia is widely used in the UK.

#### Technique

After topical administration of local anaesthesia (e.g. tetracaine 1.0%) the conjunctival sac is irrigated with an antiseptic solution. A speculum is then inserted into the lids. The conjunctiva and Tenon's capsule are grasped with forceps, and a small incision is made with scissors, 5 mm from the limbus. A local anaesthetic solution is injected into the sub-Tenon space with a flat, blunt-tipped sub-Tenon

cannula. The solution may comprise a mixture of agents, for example lignocaine, bupivacaine, and hyalase.

#### Advantages

- Good anaesthesia.
- Provides effective postoperative analgesia if long-acting local anaesthesia utilized (marcaine).

#### Disadvantages

- Subconjunctival haemorrhage.
- Chemosis if local anaesthesia solution is inadvertently injected into the subconjunctival space.
- Variable akinesia.

### Peribulbar anaesthesia

Anaesthetic is injected into the orbit, outside the extraocular muscle cone.

#### Technique

Using a 25 mm needle, local anaesthesia solution is injected below the globe, via the skin or conjunctiva. The solution may contain a mixture of agents like the sub-Tenon's mixture.

#### Advantages

- Effective analgesia and akinesia.
- Useful for uncooperative or senile patients.
- Useful for complex cases of long duration.

#### Disadvantages

- Slower than the above techniques, as local anaesthesia requires time to diffuse.
- Slower visual recovery.
- Chemosis.
- Postoperative diplopia, ptosis.
- Risk of retrobulbar haemorrhage.
- Risk of perforation of globe.
- Risk of brainstem anaesthesia.

### Retrobulbar anaesthesia

This technique is used infrequently, due to its potential for serious complications.

#### Technique

Using a long needle (38 mm), local anaesthetic solution is injected behind the globe, within the extraocular muscle cone.

#### Advantages

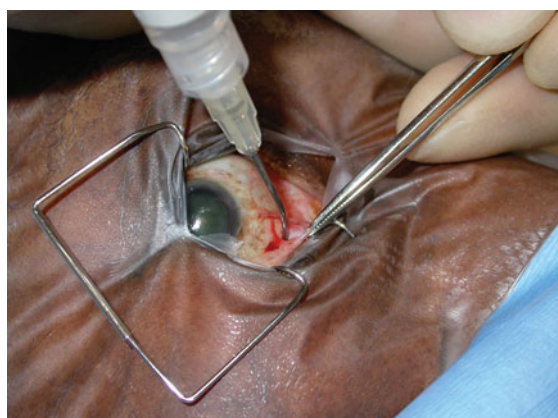Very effective analgesia and akinesia.

#### Disadvantages

- Slower visual recovery due to postoperative diplopia, ptosis, and optic nerve anaesthesia.
- Risk of direct optic nerve trauma.
- Risk of intravascular injection.
- Risk of retrobulbar haemorrhage.
- Risk of perforation of globe.
- Risk of brainstem anaesthesia.
- Contraindicated in high myopes (long axial length).

**Box 6.2** General factors that may contribute to adverse outcomes of local anaesthetic/daycase cataract surgery. LA, local anaesthesia; GA, general anaesthesia.

History	Factor/pathology	Risk	Action
Age	Young age	Unable to tolerate LA	Consider GA
Past medical history	Anxiety	Unable to tolerate LA	Consider GA
Past medical history	Claustrophobia	Unable to tolerate LA/lay beneath drape	Consider GA, or use a clear drape
Past medical history	Marked tremor	Unable to lay still	Consider GA, akinesia can be helpful in these cases
Past medical history	Persistent cough	Unable to lay still	Cautiously consider GA
Past medical history	Impaired lung function or heart failure	Unable to lay flat	Cautiously consider GA
Past medical history	Uncontrolled hypertension	Suprachoroidal or expulsive haemorrhage	Treat prior to surgery
Medication	Anticoagulants	Suprachoroidal or expulsive haemorrhage	Ensure INR in therapeutic range
Medication	Tamsulosin	IFIS	Cautious surgery, dispersive viscoelastic, iris hooks, intracameral mydriatic (e.g. phenylephrine)



**Fig. 6.57** Sub-Tenon anaesthetic administration.



## 6.13 Operating microscope and phacodynamics

### Operating microscope

Contemporary cataract surgery is performed with an operating microscope. This facilitates:

- good illumination, producing a bright red reflex,
- variable magnification (zoom),
- variable focus,
- hands-free motorized control of magnification, focal plane, and X–Y position.

Both hands are utilized for the phacoemulsification surgical procedure. Thus control of the microscope is via a foot pedal. Microscopes may be wall- or ceiling-mounted.

A beam splitter within the device allows attachment of a co-observation eyepiece. This affords a stereoscopic view of the surgical field, essential for teaching and supervising intraocular surgery.

Video cameras are frequently coupled to the microscope, allowing real-time viewing of the surgical procedure on a monitor within the operating theatre. This is useful for teaching, although depth cannot be appreciated as with the co-observation eyepiece. The monitor also allows the scrub nurse to observe the procedure as it progresses.

### Phacodynamics

Phacoemulsification has revolutionized cataract surgery, allowing cataract extraction via increasingly smaller incisions. The precise fit of the phaco probe into the surgical incision ‘seals’ the anterior chamber during phacoemulsification, allowing tight maintenance of fluids and IOP during the procedure. Many phaco parameters can be modified and customized to each surgeon, and to particular cataract types.

#### Phacoemulsification handpiece

To remove a cataract through a small incision, the cataract must be broken into small pieces. Phacoemulsification is achieved by a inserting a hollow needle into the eye via a small incision.

The cataract is broken up by axial ultrasonic movement of the needle, which causes mechanical cutting and possibly cavitation of the lens matter at its tip. Oscillation frequencies are usually in the range of 35,000–45,000 Hz. Oscillations are generated by piezoelectric or magnetostrictive systems within the handpiece. Newer phaco technologies include rotational oscillations of a curved phaco tip, requiring lower axial phaco power (Ozil, Alcon Laboratories).

The needle is surrounded by an irrigating sleeve, through which irrigating fluid flows into the eye. This helps to maintain pressure within the anterior chamber, and also provides an insulating layer around the needle, preventing corneal wound burns. Fluid and lens matter is evacuated through the hollow centre of the needle.

#### Phaco power

The power generated by the phaco tip is determined by the following.

##### Oscillation frequency

This remains constant for a particular instrument, although it varies between manufacturers.

##### Stroke length

This is excursion of the phaco tip with each oscillation, and can be modified.

When set to 100% phaco power, the tip may travel through the full stroke length.

When set to 60% phaco power, the tip travels through up to 60% of its stroke length.

Most phaco machines have maximum stroke lengths in the range of 0.05–0.10 mm.

#### Irrigation

Irrigation via the phaco sleeve is gravity-dependent, and is determined by the bottle height, typically 65 cm above the patient's eye level. Bottle height may be adjusted; raising the bottle deepens the anterior chamber.

Flow of irrigating fluid into the eye is proportional to the rate of fluid leaving the eye, via:

- aspiration through the phaco tip,
- leak from surgical wounds.

#### Aspiration and vacuum

Fluid and lens matter is withdrawn from the eye under the influence of two factors.

- *Aspiration rate*: the rate at which fluid and lens matter are evacuated from the eye through the unoccluded phaco tip.
- *Vacuum*: this is a suction force exerted at the phaco tip, which allows nuclear fragments to be engaged, and subsequently phacoemulsified. Maximum vacuum limits can be specified.

Aspiration rate and vacuum are linked in Venturi and diaphragmatic pumps (vacuum transfer pumps). In peristaltic pumps they are independent.

#### Venturi pumps

A vacuum is generated within the phaco machine, and this is transferred to the handpiece tubing. This drives the flow of fluid from the eye, down a pressure gradient and into the cassette. Because flow is generated by the vacuum the aspiration rate cannot be independently changed.

#### Peristaltic pumps

Tubing originating from the phaco handpiece is stretched over rollers. The rollers within the pump softly roll over and compress the flexible tubing, pushing fluid away from the handpiece and generating negative pressure. This pressure draws fluid from the eye through the phaco tip. Increasing the speed of rotation increases the aspiration rate.

#### Rise time

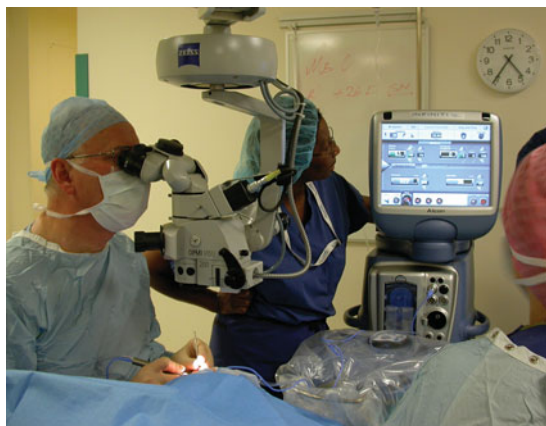This is the time taken for the vacuum to reach its maximum setting in the presence of tip occlusion.

### Foot-pedal control of phacoemulsification

Phacoemulsification is controlled by a foot pedal, on which there are three sequential positions:

- position 1: irrigation,
- position 2: irrigation plus aspiration,
- position 3: irrigation plus aspiration plus ultrasound.


Sound generated by the phaco machine provides feedback for the position in use.



**Fig. 6.58** Operating microscope.



**Fig. 6.59** Phaco machine and operating microscope foot pedals.



**Fig. 6.60** Phaco probe.

## 6.14 Intraocular lenses

The first intraocular lens (IOL) was implanted in 1949. Prior to this, eyes were rendered aphakic by cataract extraction, and required contact lenses or heavy spectacles for refractive correction.

IOLs solve the problem of aphakia, and provide superior optical correction to contact lenses or spectacles. They are now routinely implanted at the time of cataract extraction in adults, and in most children over the age of 12 months.

### IOL design

The basic design of an IOL comprises a central optic, attached at its periphery to the haptic(s).

#### Optic

- The optic imparts the optical power of the IOL.
- Optical power may be built into the anterior or posterior surface of the IOL, or both.
- Most implanted IOLs have a monofocal optic.
- Cylindrical power may be built into the IOL optic (toric IOL).

#### Haptic(s)

- The haptics centre the IOL along the optical axis, and in its correct axial position within the eye.
- Most IOLs have two or four haptics.
- They may lie in the plane of the optic, or are angulated, pushing the IOL posteriorly into the capsular bag.

Common optic-haptic configurations include:

- single-piece IOLs: the IOL is manufactured in one piece; optic and haptic are thus composed of identical material;
- multiple-piece IOLs: optic and haptic are manufactured separately, and are often composed of different materials.

### IOL biomaterial

#### Acrylic

Most contemporary cataract surgeons utilize acrylic IOLs. They are soft, foldable, and can be injected into the eye via a small incision. They unfold slowly within the eye after insertion, and are easy to position. Acrylic IOLs have demonstrated low rates of PCO. Acrylic IOLs may be:

- hydrophobic,
- hydrophilic.

#### Silicone

Silicone IOLs are also foldable. They unfold rapidly within the eye. They are associated with contraction of the capsular bag.

#### Polymethylmethacrylate

Polymethylmethacrylate is a hard and brittle, and is thus not foldable. It must be inserted through a large incision. It was widely utilized until the turn of the century, when soft, foldable IOLs gained popularity. Polymethylmethacrylate has proven biocompatibility and is cheap to manufacture. It remains in widespread use in the developing world.

A UV filter is usually incorporated into the IOL optic material. Blue-light filtering IOLs are favoured by some surgeons, for the purpose of retinal photoprotection. These IOLs are yellow.

### Site of implantation

#### Posterior chamber

The vast majority of IOLs are implanted into the posterior chamber.

#### Posterior chamber IOLs

- 'In-the-bag' implantation, into the intact capsule, is the norm.
- Sulcus implantation is usually performed in the context of complicated cataract surgery, when the capsule is not intact, or zonular support is questionable. The haptics rest in the sulcus between the iris and ciliary body.

#### Anterior chamber IOLs

- Iris-fixated IOLs utilize 'claws' that enclavate iris tissue, holding the iris in place.
- Angle-supported IOLs are stabilized by haptics which rest in the iridocorneal angle.

### Presbyopia-correcting IOLs

Standard cataract surgery with monofocal IOL implantation typically results in good unaided distance vision; however, glasses are required for reading.

Many IOLs have been designed to achieve good unaided visual acuity for both distance and near, allowing patients (in theory) to be spectacle-free. Presbyopic IOLs are the subject of much research effort and commercial interest.

#### Multifocal IOLs

The optics of these IOLs have two focal lengths: distance and near. Concentric optical zones alternate between the two focal lengths. Light entering the eye is divided between the two optical zones. Problems reported with these IOLs include:

- loss of contrast sensitivity,
- poor intermediate visual acuity (e.g. for computer use),
- haloes,
- glare.

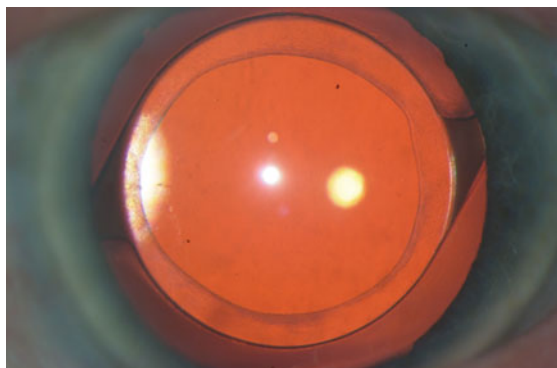
#### Accommodating IOLs

Accommodation is the ability of the youthful crystalline lens to change focus from distance to near. Hardening of the crystalline lens results in loss of accommodation with age. However, the ciliary muscles, which facilitate accommodation, continue to function.

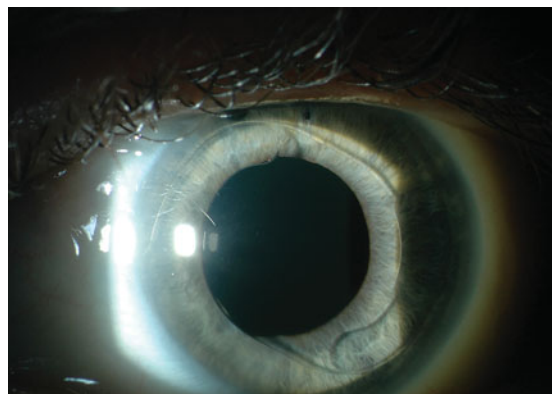
Accommodating IOLs are implanted into the capsular bag, and utilize the action of the ciliary muscle. They are designed to move forwards within the eye with accommodative effort. Forward movement of the IOL within the eye results in a more myopic refractive status, thus facilitating near vision. This is known as the focus-shift principle.

### Phakic IOLs


IOLs are occasionally inserted into the eye in the presence of the crystalline lens. These are usually inserted for the treatment of high refractive errors, usually myopia.



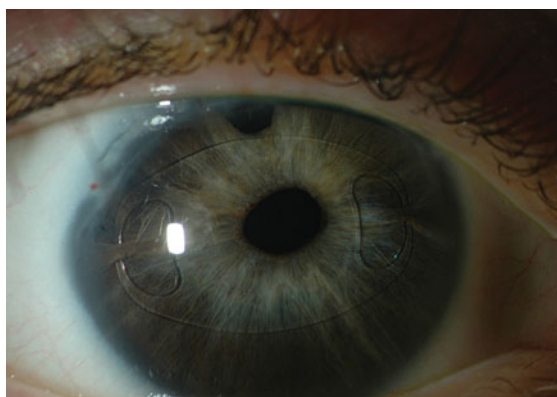
**Fig. 6.61** Single-piece IOL.



**Fig. 6.64** Angle-supported anterior chamber IOL.



**Fig. 6.62** Three-piece IOL.



**Fig. 6.63** Iris-fixated anterior chamber IOL.

## 6.15 Nd:YAG laser capsulotomy

### The Nd:YAG laser

Infrared radiation at 1064nm is generated from neodymium (Nd) suspended in a yttrium-aluminium-garnet (YAG) crystal. Pulsed laser radiation strips electrons from atoms, forming a gaseous state of ions and electrons called plasma. Plasma expands rapidly, creating shock and acoustic waves. This causes mechanical disruption to adjacent tissues, creating a defect or hole. Because the 1064nm wavelength is invisible, the laser device is also fitted with a red helium/neon aiming beam.

Nd:YAG laser capsulotomy is a common, elective procedure performed in the clinic for:

- PCO,
- anterior capsule opacification (rarely),
- anterior capsular phimosis (rarely).

### Indications for Nd:YAG posterior capsulotomy

#### Visual impairment

- Reduced visual acuity.
- Glare.
- Monocular diplopia.

The threshold for Nd:YAG posterior capsulotomy may be lower with multifocal IOLs.

#### To improve retinal visualization

For example, for diabetic retinopathy screening.

### Complications of Nd:YAG laser posterior capsulotomy

- Raised IOP.
- Uveitis.
- Lens effects:
  - pitting,
  - cracking,
  - posterior movement,
  - dislocation.
- Cystoid macular oedema.
- Posterior vitreous detachment.
- Retinal breaks.
- Retinal detachment.
- Chronic endophthalmitis.

### Performing Nd:YAG posterior capsulotomy

After obtaining informed consent:

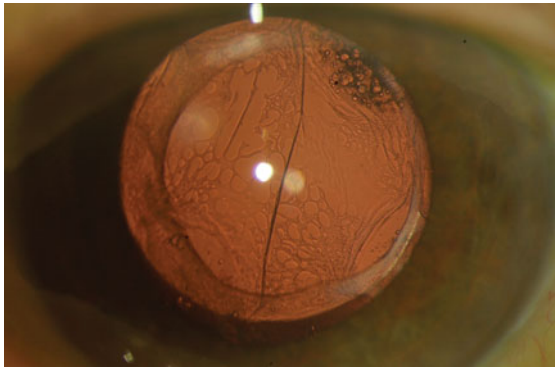
- the pupil is dilated;
- local anaesthetic drops are administered;
- initial laser settings are confirmed:
  - posterior focus,
  - approximately 1.0mJ per pulse (may be increased);
- the patient is positioned comfortably at the slit lamp, and instructed to look towards a fixation light with their fellow eye;
- a capsulotomy contact lens is held against the cornea, using a viscous coupling fluid (e.g. viscotears);
- using the focusing beam, the laser is focused on or immediately posterior to the posterior capsule;
- the laser is fired.

Various configurations for constructing the capsulotomy have been described; for example, cross, spiral, and inverted 'U' types. Adjacent capsular defects created by the laser coalesce to form an opening in the posterior capsule, ideally 3–4 mm.

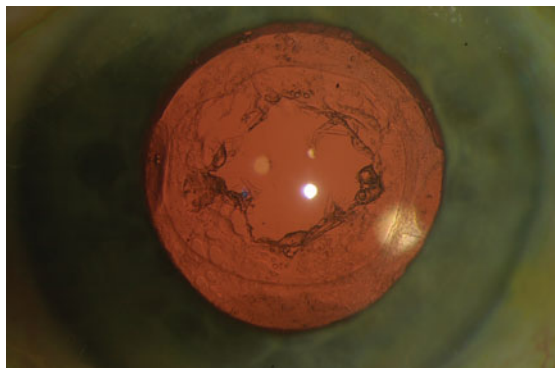
Additional management varies among centres, but may include:

- immediate g. iopidine 1.0%, pre- or post-laser;
- a short course of steroid, for example g. prednisolone 0.5% TDS for 1 week,
- review in clinic to evaluate visual acuity, and assess for complications.





**Fig. 6.65** PCO.



**Fig. 6.66** Posterior capsule following Nd:YAG laser capsulotomy.

## 6.16 Case-based discussions

### Case 1 Age-related cataract

Mr Smith, a 78 year-old man, is referred to the primary care clinic by his GP. He has recently seen his optometrist, who has observed a progressive myopic shift in his prescription, and bilateral cataracts.

- 1) What morphological type of cataract does a myopic shift suggest, and why does this occur?

A myopic shift suggests a nuclear cataract. Nuclear cataract formation is associated with an increase in the refractive index of the crystalline lens nucleus, which results in an increase in refractive power. This causes a myopic shift, moving the image plane anteriorly from the retina into the vitreous cavity.

#### History

General history reveals that Mr Smith has hypertension, and symptoms of prostatic hypertrophy. He is taking tablets for both conditions.

- 2) What specific class of drugs should be asked about?  
 $\alpha$ -Antagonists, for example tamsulosin, doxazosin, and terazosin.
- 3) What is the relevance of these drugs to cataract surgery?  
 $\alpha$ -Antagonists, particularly tamsulosin, are associated with IFIS.
- 4) What is the characteristic triad of this condition?
- Intraoperative iris floppiness and billowing.
  - Iris prolapse into the surgical wounds.
  - Progressive pupillary constriction.

#### Examination

Best-corrected visual acuity is 6/12 in both eyes. The pupils dilate poorly; however, bilateral moderate nuclear cataracts are evident. After discussing the risks and benefits of surgery, a date is planned.

- 5) What additional surgical steps should be considered?

Once a history of  $\alpha$ -antagonist use has been established, surgery can be carefully planned. Preoperative discontinuation of the  $\alpha$ -agonists does not reduce the risk of IFIS.

Strategies to reduce the risk of intraoperative complications include:

- preoperative topical atropine 1%,
- intracameral mydriatic agents, for example phenylephrine or adrenaline,
- iris hooks,
- pupil expansion ring,
- dispersive viscoelastic.

### Case 2 Postoperative endophthalmitis

A 65 year-old female attends the eye casualty at 9am, complaining of severe pain in her left eye. She has been unable to sleep. She had cataract surgery to her left eye 3 days previously.

#### Examination

She is distressed. Visual acuity is 6/6 unaided in the right eye, and counting fingers in the left eye. There is marked left-sided lid oedema and conjunctival congestion. The cornea is oedematous, with a small infiltrate associated with the wound. There is a 2 mm hypopyon.

- 1) What is the most likely diagnosis?

Acute postoperative endophthalmitis.

- 2) What are the differential diagnoses?

Acute postoperative endophthalmitis is by far the most important and likely diagnosis. Potential differential diagnoses include:

- retained lens matter,
- postoperative uveitis,

- toxic anterior segment syndrome,
- acute bacterial keratitis.

#### Investigations

She is taken urgently to the operating theatre for collection of diagnostic specimens and intravitreal antibiotic administration.

- 3) What specimens should be taken?

Microbiological specimens should be obtained from both the anterior chamber and the vitreous cavity. The microbiologist should be informed that the sample is *en route* immediately before the specimens are collected.

A needle or cannula is inserted into the anterior chamber via the surgical wound, and infected aqueous is aspirated. A vitreous biopsy is collected using a vitreous cutter or portable vitrector, inserted 3.5 mm posterior to the limbus.

- 4) Is there an indication for vitrectomy?

There is evidence for vitrectomy if visual acuity is perception of light or worse at the time of presentation (Endophthalmitis Vitrectomy Study Group 1995).

- 5) What antibiotics should be administered?

Ceftazidime (2mg in 0.1 mL) or amikacin (0.4mg in 0.1 mL) and vancomycin (1mg in 0.1 mL). Ceftazidime and vancomycin are physico-chemically incompatible and should be administered by a separate needle and syringe.

### Case 3 Posterior capsular opacification

Mr Jones is an 83 year-old man. Four years previously he underwent uncomplicated cataract surgery. He was very pleased with the results of surgery. However, over the past year he has noticed that the vision in his right eye is blurred compared with his left. His general health is good, and he takes no regular medication.

- 1) What are the most likely causes of blurred vision in this man?

Pathology of any ocular structure may cause blurred vision. However, the most likely causes are:

- PCO,
- AMD.

#### Examination

Best-corrected visual acuity is 6/18 in the right eye and 6/9 in the left eye. His pupils are dilated, and right-sided PCO is evident.

- 2) What is the procedure of choice?

Nd:YAG laser posterior capsulotomy.

- 3) What are the risks of this procedure?

- Raised IOP.
- Uveitis.
- Lens effects:
  - pitting,
  - cracking,
  - posterior movement,
  - dislocation.
- Cystoid macular oedema.
- Posterior vitreous detachment.
- Retinal breaks.
- Retinal detachment.
- Chronic endophthalmitis.

# Chapter 7

## Glaucoma

Julie Huntbach and Amar Alwitry

---

### Basic sciences

- 7.1 Optic nerve head anatomy 276
- 7.2 Aqueous fluid dynamics 277

---

### Clinical skills

- 7.3 Optic nerve head assessment in glaucoma 278
- 7.4 Tonometry and pachymetry 282
- 7.5 Gonioscopy 284
- 7.6 Perimetry I 286
- 7.7 Perimetry II 288

---

### Clinical knowledge

- 7.8 Ocular hypertension 290
- 7.9 Primary open-angle glaucoma 291
- 7.10 Acute angle closure 292
- 7.11 Normal-tension glaucoma 294
- 7.12 Steroid-induced glaucoma 295
- 7.13 Traumatic glaucoma 296
- 7.14 Inflammatory glaucomas 298
- 7.15 Pseudoexfoliative and pigmentary glaucoma 300
- 7.16 Neovascular glaucoma 302
- 7.17 Malignant glaucoma 304
- 7.18 Iridocorneal endothelial syndrome and iridocorneal dysgenesis 306
- 7.19 Ocular hypotensive agents I 308
- 7.20 Ocular hypotensive agents II 310
- 7.21 Laser therapy for glaucoma 312
- 7.22 Glaucoma surgery 316

---

### Case-based discussions

- 7.23 Case 1 Open-angle glaucoma 318
- Case 2 Angle closure glaucoma 318
- Case 3 Steroid glaucoma 318

## 7.1 Optic nerve head anatomy

The optic nerve head (ONH) or optic disc represents the area where approximately 1 million axons from retinal ganglion cells turn from the retinal plane by 90° to leave the eye through the scleral canal. As these axons enter the scleral canal, they fill it to form the ONH and ultimately the optic nerve. The mean area of the optic disc is  $2.2 \pm 0.5 \text{ mm}^2$ . Hypermetropic eyes with their shorter axial lengths tend to have small discs with more 'crowding' of the structures whereas large discs are typical of myopic eyes with increased axial length. In general, the optic disc is 12% larger in black populations.

### Retinal nerve fibre layer (RNFL)

The RNFL (made up of retinal ganglion cell axons) follows a specific pattern: retinal nerve fibres from the nasal, superior, and inferior retina take a direct route to the ONH, while fibres arising between the disc and fovea (papillomacular bundle) pass directly. Fibres from areas temporal to the fovea take arcuate paths around the papillomacular bundle and enter the ONH at its upper and lower margins. There is also spatial order within the ONH: ganglion cells from central retina have axons near the centre of the nerve and those from peripheral retina are found in the nerve's periphery.

### Zones of the ONH

The outermost part of the sclera is reflected backwards at the ONH to become continuous with the dura mater around the nerve, whereas the inner part is modified to form the lamina cribrosa. This structure provides mechanical support for the axons as they pass through the scleral shell and also provides a passageway for retinal blood vessels. Its presence allows the ONH to be divided into three distinct regions: prelaminar zone, laminar zone, and postlaminar zone.

### Blood supply

The main arterial supply of the ONH is via the posterior ciliary arteries derived from the ophthalmic artery. The anatomy is variable but in general 10–12 short posterior ciliary arteries pierce the sclera close to the optic nerve, forming the circle of Zinn, and one or two long posterior ciliary arteries pierce it further away. The most superficial part of the ONH is supplied by the central retinal artery. Venous drainage is via the central retinal vein and also by drainage into the peripapillary choroid.

### Neuroretinal rim

The neuroretinal rim is the tissue between the outer edge of the cup and the disc margin. It is made up of retinal ganglion cell axons which will eventually pass through the lamina cribrosa and form the optic nerve. A plentiful blood supply and the presence of axoplasm gives the healthy rim an orange-red appearance. Glial cells and astrocytes provide the connective-tissue support for these fibres. The neuroretinal rim has a characteristic configuration obeying the ISNT rule: the inferior rim is thickest, the next thickest rim is superior followed by nasal, then temporal. If this rule is not obeyed then a pathological condition such as glaucoma is a possibility.

### Optic cup

This is a three-dimensional pale depression, either round or horizontally ovoid, in the centre of the ONH not occupied by axons. The scleral canal varies in size depending on the overall size of the globe. As there are a relatively constant number of axons in the retina and thus ONH, this means they will occupy a similar area of the ONH. Larger discs tend to have large cups and smaller discs have smaller cups. The cup is pale due to central exposure of the lamina cribrosa and loss of glial tissue. There are three variations of the cup in a normal ONH: small dimple-like central cup, punched-out deep central cup, and cup with sloping temporal wall.

The cup is assessed by comparing its vertical height with that of the optic disc: expressed as the cup/disc ratio (CDR). In normal

eyes, this ratio is below 0.5 and there is symmetry between the eyes. This rule cannot be applied to all discs, however. A larger CDR is acceptable and 'normal' in larger discs whereas a smaller disc may have a CDR of 0.5, which is actually pathological.

### Retinal blood vessels

These vessels enter the disc centrally from the optic nerve and then course nasally, following the cup's edge. The central retinal artery tends to be found nasal to the vein. Cilioretinal arteries occur in about 25% of the population, most arising from the temporal rim.

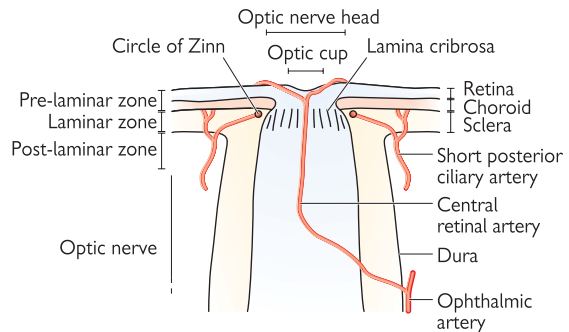


Fig. 7.1 Diagram of ONH anatomy.

## 7.2 Aqueous fluid dynamics

Aqueous humour is a transparent, colourless fluid continually produced by the ciliary body. It is similar to plasma although it has lower glucose, lower protein (assuming an intact blood–aqueous barrier), and higher ascorbate and lactate levels. It provides structural support and is responsible for providing nutrients to the avascular cornea and lens and for removing metabolic waste products in addition to its role in the maintenance of IOP by the balance between its production and outflow.

### Aqueous production

The anterior pars plicata of the ciliary body has 70 radially oriented processes which project into the posterior chamber. Each ciliary process is lined by pigmented epithelium and non-pigmented epithelium and has a central arteriole ending in a rich, highly fenestrated capillary network. Tight junctions between the non-pigmented layer cells constitute the blood–aqueous barrier.

Aqueous is formed at a rate of 2–3  $\mu\text{L}/\text{minute}$  (higher during waking hours) by a combination of active secretion (70%), ultrafiltration (20%), and diffusion (10%).

The active secretion process involves three sequential steps, as follows:

1. Uptake of plasma-derived ions from ciliary stroma across the basolateral surface of the pigmented epithelium.
2. Movement of ions from pigmented epithelium to non-pigmented epithelium via gap junctions.
3. Active transport of ions from the non-pigmented epithelium into the posterior chamber by maintenance of a transepithelial potential dependent on several enzyme systems including the  $\text{Na}^+/\text{K}^+$ -ATPase pump, ion transport by symports and antiports, calcium- and voltage-gated channels, and carbonic anhydrase.

Active secretion is thus reduced by inhibition of active metabolism, for example hypoxia and hypothermia, but is independent of IOP.

Ultrafiltration and diffusion are passive secretory processes dependent on the level of capillary hydrostatic pressure, the oncotic pressure, and the level of IOP.

After secretion into the posterior chamber, aqueous then passes around the lens equator and flows through the pupil into the anterior chamber where it circulates due to convection currents derived from temperature differences between the cornea and iris.

### Aqueous outflow

#### Conventional (trabecular) route

This passive pressure-sensitive route represents the primary means of outflow (90%). Aqueous passes first through the trabecular meshwork, a sieve-like structure at the anterior chamber angle made up of three anatomically distinct portions: uveal meshwork (innermost), corneo-scleral meshwork, and juxtacanalicular or endothelial meshwork (outermost). This outer layer adjoining Schlemm's canal poses the majority of resistance to outflow (75%). Transport into Schlemm's canal is by transcellular channels in the form of 'giant vacuoles' of fluid crossing the inner wall. The outer wall of the canal contains the openings of collector channels which leave at oblique angles to connect either directly or indirectly with episcleral veins.

#### Alternative (uveoscleral) route

The remaining 10% of aqueous outflow passes across the iris root and the face of the ciliary body, passing between the muscle fibres into the supraciliary and suprachoroidal spaces where it is drained by the choroidal circulation. This route is not pressure-dependent and in younger individuals can account for up to 30% of outflow.

### IOP

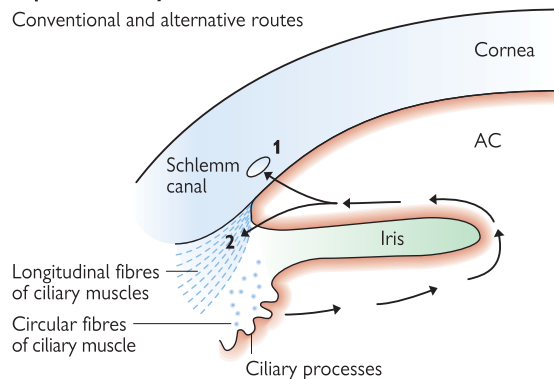
The rate of aqueous outflow is proportional to the difference between the intraocular and episcleral venous pressure:

$$F = C(P_o - P_e)$$

where  $F$  = rate of aqueous outflow,  $C$  = facility of aqueous outflow (normal value 0.2  $\mu\text{L}/\text{minute}$  per mmHg),  $P_o$  = IOP, and  $P_e$  = episcleral venous pressure (normal value 10 mmHg).

### Aqueous fluid dynamics

Conventional and alternative routes



- 1 Conventional (trabecular) pathway – 90% outflow
- 2 Alternative (uveoscleral) pathway – 10% outflow

**Fig. 7.2** Diagram of aqueous fluid dynamics showing normal flow from the ciliary body through from the posterior chamber to the anterior chamber and then the angle.



## 7.3 Optic nerve head assessment in glaucoma

Glaucoma is most accurately described as an optic neuropathy which leads to characteristic visual-field defects and optic-disc changes with raised IOP as the most clearly defined risk factor. Accurate assessment of the optic nerve head (ONH) to detect the early signs of this neuropathy is therefore of paramount importance in the diagnosis. This is performed mainly by clinical assessment through a dilated pupil using a direct ophthalmoscope, or, preferably, on the slit lamp using either indirect fundus lenses (e.g. 78D or 90D) or contact lenses. Careful documentation by means of detailed disc drawings in the notes is mandatory for comparative purposes. Increasingly, modern optic-nerve imaging techniques are also used as an adjunct to provide more quantitative measurements.

### Optic-disc features

#### Cup/disc ratio (CDR)

As a general rule, the greater the vertical CDR the greater the likelihood of glaucoma. CDR is highly variable (normal range 0–0.8) but asymmetry between the CDR of fellow eyes should not exceed 0.2 (assuming equal refractive status).

#### Disc diameter

CDR also depends on the size of the disc (larger discs have larger cups), so an assessment of disc diameter is required to determine whether a particular CDR value is pathological. This can be estimated using the number of arterial blood vessel widths that can fit across the horizontal dimension (average 10–12), or more accurately by projecting a narrow, bright beam from the slit lamp to measure the vertical dimension of the disc as this slit overlies it. This measurement is multiplied by a corrective factor depending on the lens used (a super 66D lens measure 1:1). Larger discs are allowed a larger cup. Thus a CDR of 0.7 may be normal (physiological cupping) in a large disc but highly pathological in a small disc.

#### Neuroretinal rim width

Neuroretinal rim size correlates with optic-disc area: larger discs have larger rims.

The ISNT rule determines normal configuration: the thickest rim expected inferiorly, then superiorly, then nasally, then temporally. If this rule is not followed, the disc is likely to be glaucomatous with early loss most commonly found at the infero- and supero-temporal regions.

Sometimes optic discs are tilted due to oblique insertion of the optic nerve. In such discs the neuroretinal rim is extremely difficult to assess accurately.

#### Notching

An increase in cup size may occur by enlargement in a concentric manner or in loss of neuroretinal rim locally. Diffuse loss over a local area is termed erosion whereas focal loss is known as a notch (like a 'bite taken from the inside of the rim'). A notch may indicate an area of the disc in which circulation has been compromised, resulting in focal thinning that outpaces generalized rim loss. Notching occurs most frequently inferiorly.

#### Saucerization

Saucerization describes a gentle concavity extending over most of the disc diameter resulting in indiscernible cup edges.

#### Pallor

Care should be taken not to ascribe the central area of disc pallor (due to loss of non-collagenous material) to the cup. The cup can often be much larger and should be assessed by following the path of the retinal vessels as they dip into it. Conversely, any pallor of the neuroretinal rim qualitatively indicates focal damage at that region. Pallor of the neuroretinal rim is not a sign of glaucoma. Pallor within

the cup and pallor of the rim may indicate a non-glaucoma cause for the optic neuropathy.

#### Laminar dot sign

Loss of neuroretinal tissue in advanced glaucoma results in a deepening of the optic cup which can expose the underlying pores of the lamina cribrosa, giving rise to the laminar dot sign.

#### Vascular signs

##### Optic-disc haemorrhage

Optic-disc haemorrhages are found in 4–7% of glaucomatous eyes, most frequently in areas of focal neuroretinal rim loss seen in normal-tension glaucoma. They can be located either on the optic disc itself where they appear blot-like, as small splinter haemorrhages, or in the immediate peripapillary area with a flame-shaped configuration due to their occurrence within the RNFL. They may be hard to see and are best detected after dilated fundoscopy. Visualization is best with red-free (green) light which shows up an optic-disc haemorrhage as a dark area. They are most often found in the infero- or supero-temporal regions and can take 6 weeks to 9 months to clear. Presence of an optic-disc haemorrhage indicates likely progression of the patient's glaucoma. Its site should be carefully documented as it can represent a marker for future focal disc damage and thus concurrent visual-field defect developing up to several years later.

##### Nasalization

The central retinal vessels emerge in the centre of the optic disc and initially course nasally. Therefore, if the nasal rim becomes eroded as cupping increases, these vessels will follow the erosion and thus appear to become displaced nasally. Nasalization is a non-specific sign indicating a moderate degree of glaucoma.

##### Bayoneting

In a healthy disc, vessels pass over the sloping rim of the cup to pass on to the retina which leads to a mild kink or change in direction of the vessel. However, in advanced glaucomatous excavation, a vessel will pass into the recess below the rim before climbing over on to its surface and hence the retina. This double angulation results in an apparent z bend which appears like a bayonet.

#### Peripapillary atrophy (PPA)

Chorioretinal atrophy surrounding the ONH consists of two zones: an inner  $\beta$  zone, with visibility of the sclera and large choroidal vessels, and an outer  $\alpha$  zone, displaying variable irregular hyper- and hypopigmentation of the RPE. In normal eyes, the area of atrophy is usually small and is rarely circumferential but in glaucoma the  $\beta$  zone is larger and the  $\alpha$  zone is both larger and occurs more frequently.

$\beta$ -Zone peripapillary atrophy may be associated with the onset of glaucoma and it may enlarge in area as the glaucoma worsens. Theoretically the lack of a barrier to the diffusion of vasoactive mediators from the choroidal circulation to the peri-papillary vessels may have an adverse effect on nerve fibre perfusion.

#### RNFL

Loss of nerve fibres leading to thinning of the neuroretinal rim may initially manifest as visible defects in the RNFL. These appear as slits or wedge-shaped defects in the usual uniformly reflective sheen of the RNFL. These defects follow the pattern of retinal striations and are best seen at the transition point between normal and abnormal areas of the peripapillary RNFL using red-free (green) illumination. Diffuse defects can be harder to visualize although comparing the two eyes or even superior and inferior peripapillary RNFL in the same eye can be helpful. Vessels which run within the RNFL will also become more visible with diffuse thinning.

## Optic-nerve imaging techniques

### Colour stereophotography

Stereoscopic colour photography provides high-resolution images of the optic disc and peripapillary retina, creating a permanent record for comparative purposes. A dilated pupil and clear media are required for quality photographs and it should be appreciated that evaluation of glaucomatous progression will be subjective, with both inter- and intra-observer variability, even when using highly trained glaucoma experts.

### Confocal scanning laser ophthalmoscopy

The Heidelberg retinal tomograph is a scanning laser ophthalmoscope which utilizes a confocal scanning diode laser to provide topographic measurements of the optic disc and peripapillary retina. Pupil dilation and a completely clear media are not essential. Once the scan is complete, the operator draws a line manually around the disc and a reference plane is dropped 50  $\mu\text{m}$  deep to the temporal disc edge. Everything within the disc outline deep to the plane is denoted the cup and above it is the neuroretinal rim. Computer software then analyses these values and produces three-dimensional reconstructions of the disc and retina, produced by quantitative measurements.

A more advanced version, the Heidelberg retinal tomograph II, includes software that allows statistical analysis to facilitate longitudinal study. The disc is analysed by segments and compared with a database of normal values, producing a probability map indicating whether the disc is normal or abnormal.

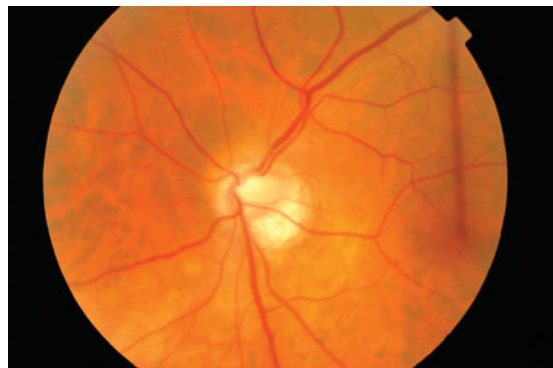The Heidelberg retinal tomograph III uses new software with an enlarged race-specific database and includes the calculation of the Glaucoma Probability Score (GPS), a new automated algorithm to provide a probability score of having glaucoma by measuring horizontal and vertical RNFL curvature, cup size and depth, and neuroretinal rim steepness.

### Scanning laser polarimetry

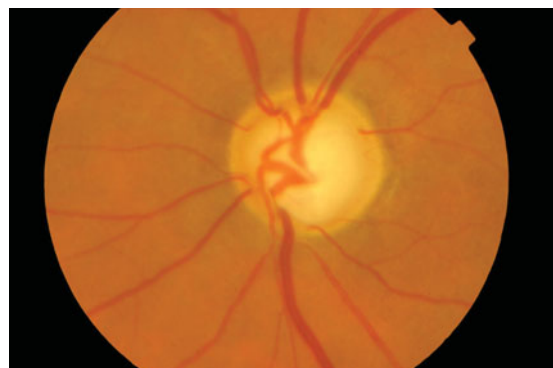The GDx is a scanning laser polarimeter designed to assess the thickness of the peripapillary RNFL by measuring retardation values or phase shifts caused by its birefringent properties (due to the linear orientation of the axons which form the RNFL). These retardation values relate directly to the thickness of the RNFL. Pupil dilation and a clear media are not essential. The latest model is the GDx VCC (variable corneal compensation) which eliminates corneal birefringence, which was a source of previous inaccuracies. A print-out displays the fundus image, an RNFL thickness map, and a TSNIT graph (thickness in temporal, superior, nasal, inferior, and temporal quadrants), which is characteristically a 'double hump' in normal cases. Software automatically calculates and classifies the RNFL thickness as being within normal limits, borderline, or outside normal limits.

## OCT

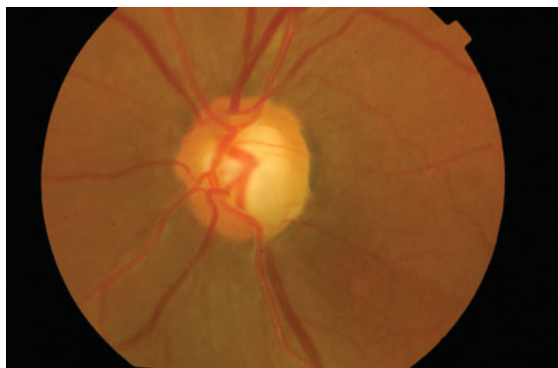
OCT uses low-coherence interferometry, a principle similar to ultrasoundography except that light is used rather than sound. A scan is performed on the retina with a near-infrared (low-coherence) light beam through a dilated pupil to provide cross-sectional images. When assessing the optic disc multiple radial linear scans are taken to provide data on cupping and neuroretinal rim. Assessment of the peripapillary RNFL is by a single circular scan taken at a radius of 1.7 mm from the ONH centre which is then unwound and presented as a linear result.



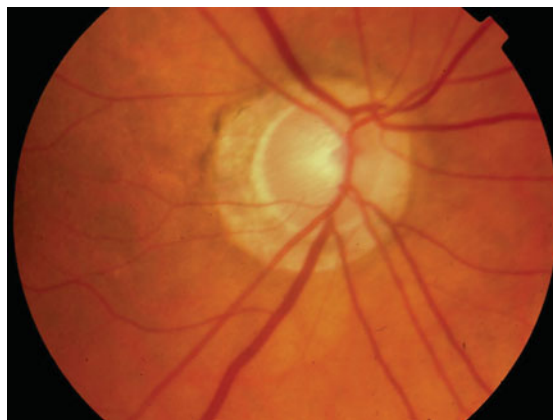**Fig. 7.3** Colour fundus photograph showing a tilted ONH. The neuroretinal rim is hard to assess accurately.



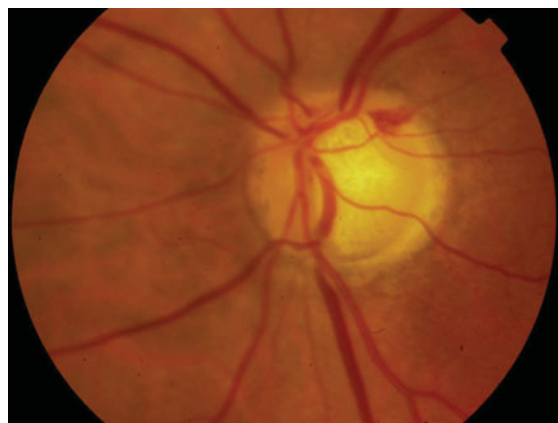
**Fig. 7.4** Colour fundus photograph showing diffuse thinning of the neuroretinal rim and significant glaucomatous cupping.



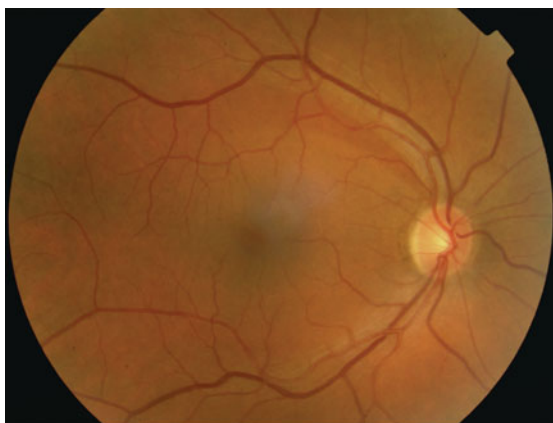**Fig. 7.5** Colour fundus photograph showing a focal notch of the inferior neuroretinal rim.



**Fig. 7.7** Colour fundus photograph showing peripapillary atrophy around a glaucomatous optic disc.



**Fig. 7.6** Colour fundus photograph showing an optic-disc haemorrhage at the superior pole of the disc.



**Fig. 7.8** Colour fundus photograph showing an RNFL defect as a dark band extending from the optic disc supero-temporally.

*This page intentionally left blank*

## 7.4 Tonometry and pachymetry

### Tonometry

Tonometry is the clinical measurement of IOP. It can be carried out using a range of different instruments. All follow a similar principle in that the higher the pressure in a sphere, the greater the force will be required to indent it. Tonometry measures IOP by quantifying the deformation of the globe and equating it to the force responsible for this shape change. This is carried out either by contact, from the tonometer apparatus, or by non-contact, from a stream of air.

The accuracy of any device to measure IOP assumes that all eyes have a similar ocular rigidity, corneal thickness, and ocular blood flow.

We now understand that corneal thickness may not be a true measure of how the cornea behaves and that factors such as corneal hysteresis (a measurement of the dynamic properties of the cornea) may play a greater role in IOP measurement accuracy. New devices such as the Pascal Dynamic Contour Tonometer and the Ocular Response Analyser are thought to offer more accurate measures of IOP independent of corneal thickness. The gold-standard method in clinical practice currently is Goldmann applanation tonometry; however, this may change as technology advances and the limitations of the Goldmann technique are further understood.

#### Goldmann applanation tonometry (GAT)

Basic theory of GAT is based upon the Imbert–Fick principle: when a flat surface is applanated against the cornea, IOP ( $P$ ) may be calculated by the force applied ( $F$ ) divided by the area of contact ( $A$ ) (thus  $P=F/A$ ). Goldmann calculated that a circular area of 3.06 mm diameter should be used to balance the elastic repulsive force of the cornea against the attractive force of the tear-film capillary action.

The GAT consists of a prismatic doubling device in the centre of a cone-shaped 3.06 mm plastic head mounted on a metal rod which is attached to a coiled spring. This spring may be adjusted by a dial to change the forward force of the biprism head. It is mounted on a slit lamp, aligned so the examiner looks down the barrel of the tip which is obliquely illuminated by a cobalt-blue light. When fluorescein (and topical anaesthesia) are instilled and the Goldmann tip comes into contact with the cornea two yellow-green semi-circles are seen due to the image of the tear-film meniscus surrounding the biprism head being split in two.

The dial is altered until the inner margins of the semi-circles just touch, which represents an applanation area of exactly 3.06 mm diameter. The semi-circles may oscillate with each ocular pulse in which case the reading is taken when the inner borders meet at the midpoint of the movement. The grams of force applied (read from the dial) are multiplied by 10 to give a reading in millimetres of mercury.

Compensation for corneal astigmatism of more than 3D is achieved by placing the flattest corneal meridian at 45° to the axis of the cone.

#### Sources of error with GAT

Overestimates of true IOP:

- examiner pressing on globe while holding lids,
- wide meniscus (excessive fluorescein or tears),
- unequal semi-circles due to misalignment,
- against-the-rule astigmatism,
- thick cornea,
- patient squeezing (apprehension or blepharospasm),
- valsalva manoeuvre (breath holding),
- restrictive clothing around neck (tie, shirt collar),
- eccentric gaze (accentuated in restrictive orbital disease).

Underestimates of true IOP:

- thin meniscus (too little fluorescein or poor tear film),
- thin cornea,
- corneal oedema (easier to indent),
- ocular 'massage' (gonioscopy or repeated measurements),

Poor or infrequent calibration of instrument.

Inter-observer variability.

#### Other problems with GAT

- Infection risk: need strict adherence to hygiene and sterilization protocols.
- Disposable prisms in known infection (particularly prion protein diseases).
- Corneal abrasion: possible with inappropriate or repeated measures.

#### Perkins tonometry

- Uses same principles as GAT.
- Hand-held battery powered applanation tonometer with Goldmann prism.
- Portable forehead-supported version.
- Applanation force varied by rotating calibrated dial.
- Technique more difficult therefore less accurate.
- Can be used in vertical or supine position.
- Useful for bed-bound or anaesthetized patients and those unable to position on slit lamp.

#### Tono-Pen

- Battery-powered device held like a pen.
- A microprocessor within the device is connected to a strain-gauge transducer which measures the force of the 1.02 mm-diameter central plate as it applanates the corneal surface.
- Several measurements taken which are averaged, giving a digital readout.
- Useful in eyes with a distorted or oedematous cornea or through bandage contact lens.
- Slightly overestimates at low IOPs and underestimates at high IOPs.
- Disposable latex sleeve to prevent infection.

#### Non-contact tonometry

- Uses the same principles as GAT.
- Puff of air used to flatten cornea.
- Force of air flow required to flatten is proportional to IOP.
- There is no requirement for topical anaesthetic so this is the instrument of choice for non-ophthalmologists.
- Only accurate within low to middle IOP range.



## Pachymetry

Pachymetry is the measurement of corneal thickness: 'The measurement of central corneal thickness (CCT) aids in the interpretation of IOP measurement results and the stratification of patient risk for glaucoma' (from the American Academy of Ophthalmologists' Glaucoma Guidelines, 2005). The mean CCT is 550  $\mu\text{m}$  whereas the peripheral cornea can measure up to 1 mm.

The Ocular Hypertension Treatment Study (OHTS) showed CCT to be a powerful independent predictor for the development of glaucoma (eyes with CCT <555  $\mu\text{m}$  are at three times greater risk of developing glaucoma than those with a CCT >588  $\mu\text{m}$ ). Part of this finding is attributed to the inaccuracies induced in IOP measurement due to varying CCT. Thinner corneas underestimate the IOP due to increased deformability whereas thicker corneas overestimate IOP due to extra rigidity.

Pachymetry can be performed using ultrasonic or optical techniques. Although there are slight differences between the two methods of measurement, for the purposes of clinical practice they are equally efficacious.

The most user-friendly and thus most commonly used method is that of ultrasound. This method has a range of 280–1000  $\mu\text{m}$ , and a clinical accuracy of  $\pm 5 \mu\text{m}$ . Ultrasound energy is emitted from the probe tip and some of the energy is reflected back towards the probe in the form of an echo at the first tissue interface it reaches (i.e. endothelium to aqueous). Measurement data are then calculated on the time it takes for the echo to travel back to the probe.

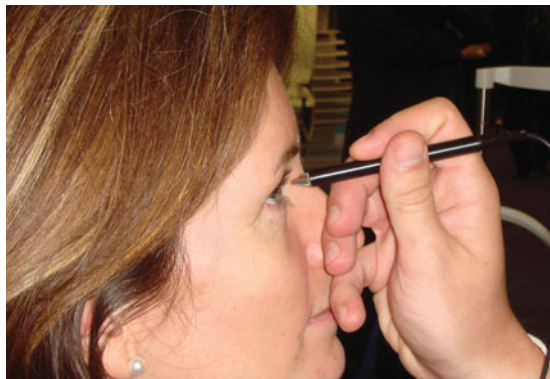### Method

- The eye is anaesthetized with drop of local anaesthetic.
- Patient is asked to look straight ahead.
- It may be necessary to hold open the lids.

- Probe is touched lightly against the central cornea several times, ensuring perpendicular alignment throughout testing.
- The device will usually indicate when the measurement has been successful.
- Read off the digital measurement and record in notes.
- Repeat for the fellow eye.

Most machines use 10 measurements to provide an average.

The accuracy of ultrasonic pachymetry is dependent upon the perpendicularity of the probe to the cornea, while the reproducibility relies on probe placement at the exact corneal centre.



**Fig 7.9** Use of a pachymeter: The eye is anaesthetized and the probe placed on to the cornea centrally.

## 7.5 Gonioscopy

The anterior chamber angle contains all the structures between the posterior corneal surface and that of the anterior iris, including those responsible for the outflow of aqueous. The angle, however, cannot be visualized directly due to total internal reflection of light by the peripheral cornea. Gonioscopy is a technique which allows visualization of the angle structures by replacing the tear-film–air interface with a new tear-film–goniolens interface. The use of gonioscopy is of utmost importance in the differentiation between open- and closed-angle glaucomas, as well the identification of a variety of pathological findings in the angle.

### Direct gonioscopy

Direct goniolenses or goniosprisms are used to allow direct visualization of the angle. There are two types (Koeppel and Swan–Jacob lenses) and their main use is in the visualization of the angle in the operating room for surgical procedures (e.g. goniotomy or synechiolysis). The technique requires high magnification with illuminated loupes, a portable slit lamp or operating microscope, and the patient to be lying supine.

### Indirect gonioscopy

Indirect goniolenses or goniomirrors are used to provide a mirror image of the opposite angle and are used in conjunction with a slit lamp. There are two main types: the Goldmann and Zeiss lenses.

#### Goldmann lenses

- Single or double mirror lens with contact-surface diameter of 12 mm (greater than cornea).
- Concave surface of lens is steeper than that of the cornea so a coupling agent is required to bridge the gap (may cause temporary blurring of vision afterwards and interfere with further examination).
- Stabilizes the globe.
- Excellent view of angle structures and if convex iris obscures view, one can still see 'over the hill' if the patient looks in the direction of the mirror (take care not to indent the peripheral cornea as this will result in iatrogenic narrowing or closure of the angle).
- Lens requires rotation to visualize individual quadrants.
- Relatively easy technique.

#### Method

- Instil topical anaesthetic (e.g. benoxinate).
- Ensure lens is disinfected with appropriate solution.
- Instil coupling agent (e.g. viscotears or methylcellulose) in lens concavity.
- Dim room lights and position patient on slit lamp.
- Hold down lower lid and ask patient to look up.
- Insert lens with mirror at 12 o'clock position and ask patient to look straight ahead.
- Use 2 mm slit beam with axis perpendicular to mirror.
- Rotate lens clockwise until all quadrants are viewed.
- Document findings in notes.

#### Zeiss lenses

- Four-mirror lens on a handle with a contact-surface diameter of 9 mm (less than cornea).
- Curvature is flatter than the cornea, so no coupling agent is required.
- Can be used for indentation gonioscopy: axial pressure on the central cornea by lens will cause flattening of the anterior chamber and force aqueous into the angle, thus opening it if

possible (allowing distinction between appositional and synechial closure and identification of plateau).

- Entire circumference of angle visualized with minimal rotation.
- Faster and more comfortable examination but requires more practice.

#### Method

As above, but tear film is adequate as a coupling agent and the lens is placed directly on the centre of the cornea. Minimal or no rotation is required. It is important not to press too firmly until indentation is desired, as this will artificially open the angle. The aim is to hold the lens in gentle apposition with the cornea so that the contact meniscus is occasionally lost. If corneal tension lines are seen, too much force is being applied. Indentation is achieved by anterior–posterior force.

### Identification of angle structures

#### Schwalbe's line

- This is the most anterior angle structure, representing the peripheral termination of Descemet's membrane and the anterior limit of the trabeculum.
- Circumferential whitish, glistening ridge, occasionally pigmented (Sampaolesi line).
- Identified using corneal light wedge and should be the first thing looked for during gonioscopy as it will expose the false pigment line in narrow angles that is often mistaken for pigmented trabecular meshwork: project thin slit beam at 15–45° into the angle.
- Two linear reflections will be seen from external and internal surfaces of cornea: these two reflections meet at Schwalbe's line, forming the apex of a 'wedge'.

#### Trabeculum

- Extends from Schwalbe's line to the scleral spur with a 'ground glass' appearance.
- Anterior portion is non-pigmented.
- Pigmented posterior functional portion adjacent to scleral spur is grey-blue.
- Pigmentation increases with age and is most marked inferiorly.
- Increased pigmentation may be evident in pigment dispersion syndrome or pseudoexfoliation.

#### Schlemm's canal

- Occasionally seen as a slightly darker line deep to posterior trabeculum.
- Blood seen in canal with raised episcleral venous pressure (compression by goniolens or pathological process).

#### Scleral spur

- Narrow whitish band posterior to the trabeculum.
- Represents the most anterior projection of the sclera and is the site of attachment of the ciliary body longitudinal muscle.

#### Ciliary body

- Brown-grey circumferential band.
- Iris root inserts into anterior portion.
- Width variable depending on iris insertion: narrow in hyperopes, wide in myopes.

#### Iris processes

- Small extensions of iris inserting at level of the scleral spur.
- Present in one-third of normal eyes.

#### Blood vessels

- These form a radial pattern at the base of the angle recess and as a general rule do not cross the scleral spur.

- Pathological vessels follow a random pattern, beginning as fine lacy fronds and are later accompanied by a fibrous 'scaffold'.

### Shaffer grading system

In practice, this is graded 0–4 according to visibility of the most posterior angle structure visualized.

If three quadrants (i.e. 270°) are grade 2 or above, the angle is assumed to not be occludable. It is also useful to note the shape and contour of the peripheral iris, the amount of trabecular pigmentation, and the presence of any peripheral anterior synechiae (PAS).

**Table 7.1 The Shaffer grading system**

Grade	Angle size	Angle structure seen	Angle description
4	35–45°	Ciliary body	Wide open
3	20–35°	Scleral spur	Open
2	20°	Trabeculum	Moderately narrow
1	10°	Schwalbe's line	Very narrow
0	0°	No structures visible	Closed

### Van Herick's technique

Another useful tool in the assessment of the anterior chamber angle is van Herick's technique, which does not require the use of a gonioscope and can be performed quickly without additional stress to the patient.

On the slit lamp, a narrow slit of bright light is projected at 60° off axial on to the temporal cornea as close to the limbus as possible. The resulting slit image of the cornea is used as a reference for the anterior chamber depth at this point (represented by the optically empty gap between the posterior corneal surface and the iris).

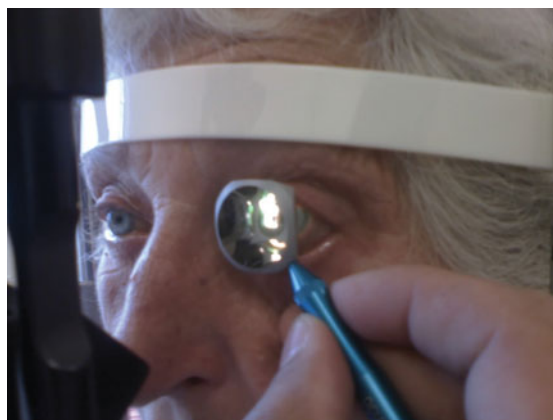In a recent study, almost 15,000 patients were shown to have good correlation between this technique and angle grading by formal gonioscopy. However, for results equivalent to Shaffer angle 2 or less, it is advisable to perform confirmatory gonioscopy.

**Table 7.2 Judging anterior chamber angle by van Herick's technique**


Relation between corneal slit image and anterior chamber depth	Equivalent Shaffer grade
1:1 or higher	4
1:1/2	3
1:1/4	2
1:<1/4	1
Closed	0



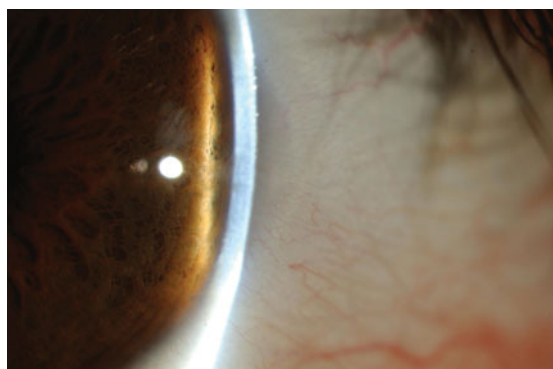
**Fig. 7.10** Examples of two gonioscopy lenses.



**Fig. 7.11** The technique of gonioscopy. The patient is seated at the slit lamp and the lens is applied while the patient looks up. Once the lens is in position the patient looks ahead and the angle is examined with a small short slit of light. The room lights should be reduced to minimal levels to try and minimize pupil miosis which can artificially open an angle.



**Fig. 7.12** Van Herick's assessment of the angle. The clear gap behind the cornea is one-quarter the width of the cornea, indicating a potentially occludable angle.



**Fig. 7.13** Van Herick's assessment of the angle. The clear gap behind the cornea is almost the width of the clear cornea. This is a wide open angle.

## 7.6 Perimetry I

Perimetry is a psychophysical test to formally evaluate a patient's 'visual field'. This aids in the diagnosis and management of glaucoma as typical glaucomatous field defects are produced due to specific patterns of damage. Serial field testing can then be utilized to assess progression and thus the effectiveness of treatment. Perimetry is also valuable in the identification and monitoring of certain neurological diseases.

### Visual field

Traquair described the visual field as 'an island of vision surrounded by a sea of darkness'. This island is depicted as a hill with maximum height at fixation due to the high density of photoreceptors at the fovea. Visual acuity decreases towards the periphery in a steep fashion nasally and more gradually temporally. There is a 'blind spot' 10–20° temporal to fixation which corresponds to the ONH. The normal visual field extends 60° superiorly, 60° nasally, 80° inferiorly, and 90° temporally.

An overall reduction in field sensitivity (e.g. cataract) will make the hill flatter. A localized defect is known as a scotoma, which can be 'absolute' (total loss of vision) or 'relative' (area of partial visual loss with reduced sensitivity).

### Kinetic perimetry

This can be performed by simple confrontation, a tangent (Bjerrum) screen, Lister perimeter, or Goldmann perimeter. It provides a two-dimensional measure of the boundary of the hill of vision by the steady movement of a stimulus of fixed size and intensity from a non-seeing to a seeing area of the field along set meridians at 15° intervals. The points at which the stimulus is perceived are plotted on a chart and joined by a line or isopter. Using stimuli of different intensities will provide a contour map of the visual field.

#### Goldmann perimeter

- Most commonly used kinetic perimeter.
- Useful for patients unable to perform reliable automated perimetry, for visual acuity of less than 6/18 and if neurological defect is suspected.
- The patient sits one side of the bowl and presses a button when a stimulus is seen; the examiner sits at the other side to present targets and record responses.
- Roman numerals 0–V represent target size.
- Arabic numerals 1–4 represent light intensity.
- Lower-case letters represent the use of filters (a = darkest; e = brightest).
- Advantages: test can be carried out at any speed; the examiner can dynamically assess patient responses and thus adapt to them.
- Disadvantages: may miss relative scotomas; results depend on skill of examiner; no statistical analysis is made.

### Static perimetry

Automated static perimetry uses a number of machines with pre-set programmes including Henson, Octopus, and Humphrey perimeters. It provides a three-dimensional measure of the vertical boundaries of the visual field. Size and location of the target are constant but a varying luminance of the target is used to determine 'threshold' retinal sensitivity at different locations of the field. The Humphrey is the most frequently used analyser in the UK. It consists of a hemispherical bowl onto which the target is projected and the patient presses a button when the target is seen. A background luminance of 31.5asb is used. A monitor on the side of the machine allows the examiner to choose from a 'menu' of testing strategies including suprathereshold and full threshold tests.

### Suprathereshold testing

Used mainly for screening. Points of light at luminance levels 2–6dB above the expected normal threshold values are presented at various locations in the visual field. Missed targets will reflect areas of decreased sensitivity which can be further analysed later if required.

120 Point screening can be used by the Humphrey analyser whereby a positive test is defined by a total of 17 missed points in total or 8 missed points in any quadrant.

### Threshold testing

Used for more detailed assessment by plotting threshold luminance values and comparing with age-matched normal values. The Humphrey analyser increases the intensity of its stimulus by 4dB steps until a threshold is crossed. This is then re-checked by decreasing the intensity by 2dB steps.

#### Full threshold 30-2

- Tests 76 points (6° apart) in central 30° of field.
- Long and laborious test.

#### Full threshold 24-2

- Tests 54 points (6° apart) in central 24° of field.
- Cuts test time by one-fifth.
- Gold standard for monitoring glaucoma.

#### Full threshold 10-2

- Tests 68 points (2° apart) in central 10° of field.
- Used in advanced glaucoma where fixation is threatened.

All the above tests can also be performed with FASTPAC, SITA (Swedish Interactive Thresholding Algorithm) Standard, or SITA Fast programs.

#### FASTPAC

- Alternative strategy using 3dB steps (instead of 4dB).
- Once the patient cannot see the light, the machine accepts that value rather than retesting that point.
- Test time reduced by 40% (but less accurate).

#### SITA Standard

- Uses computerized algorithms based upon a normative database.
- Utilizes threshold values of adjacent points to determine starting points, thus saving time by asking fewer 'questions'.

#### SITA Fast

- Same method as SITA Standard but less scrutiny at each point.
- Faster but less reliable than standard test.

All of these automated test procedures have a significant learning curve which should be taken into account. Often three to four consecutive tests are required before reliable fields are obtained.

### Esterman visual-field testing

An Esterman chart/programme using static perimetry forms is part of the UK's Driver and Vehicle Licensing Authority (DVLA) visual standards for driving.

Group 1 (ordinary licence) standard specifies a field of at least 120° on the horizontal measured using a white target equivalent to the Goldmann III4e settings. In addition, there should be no significant defect in the binocular field which encroaches within 20° of fixation above or below the meridian.

Acceptable central loss includes scattered single missed points or a single cluster of up to three contiguous points.

Those who have been driving for many years with static defects and non-progressive eye conditions can be considered on an individual basis.

Group 2 (vocational licence) standard requires a 'normal binocular visual field' with no provision for exceptional cases.

## Humphrey analyser displays

### Numerical

- Gives threshold (dB) for each point.
- Figures in parentheses for the same point are checked a second time.

### Greyscale

- Decreasing sensitivity represented by darker tones.
- Scale at bottom displays corresponding values of greyscale symbols.
- Useful for examining gross shape of field defect.

### Total deviation

- Represents the deviation of a patient's result from age-matched controls.
- Upper numerical and lower greyscale displays.

### Pattern deviation

- Total deviation adjusted for generalized depression in overall field.
- Can correct for diffuse loss such as that induced by the presence of cataract.
- Upper numerical and lower greyscale displays.

### Probability values

- $p$  indicates the significance of defects (lower  $p$  values = more significant).
- Shown as <5%, <2%, <1%, and <0.5%.

### Glaucoma hemifield test (GHT)

- Assesses asymmetry between the top and bottom halves of the field (one hemifield tends to be damaged first in glaucoma).
- Results displayed as outside normal limits, borderline, or within normal limits.

## Humphrey analyser reliability indices

### Fixation losses

- Stimuli are presented within the blind spot.
- If seen by the patient, they are clearly not fixating correctly.
- If losses exceed 20–30% reliability should be questioned.

### False positives

- 'Trigger-happy' patients who press the button with no stimulus present.
- Greyscale printout is abnormally pale.
- Should be <10% for reliability.

### False negatives

- Test points of known sensitivity are rechecked with a brighter stimulus.
- If not seen by patient, may be due to inattention or fatigue.
- Greyscale printout with a high number of false negatives has a cloverleaf pattern.
- Should be <20% for reliability.

## Humphrey analyser global indices

### Mean deviation

- Mean elevation or depression of the field compared with age-corrected normal.
- May be due to overall defect or localized loss.

### Pattern standard deviation

- Degree to which the shape of the field differs from age-corrected normal.
- Measures focal loss or variability within the field accounting for any generalized depression.

### Short-term fluctuation

- Indicates intra-test consistency.
- Ten pre-selected points are tested twice.

### Corrected pattern standard deviation

- Measures variability within the field after correction for intra-test variability (i.e. pattern standard deviation + short-term fluctuation).
- This removes patient bias, revealing only true field loss.

For all of the above, a  $p$  value is given if significant.

## Sources of error in perimetry

### Poor reliability or performance by patient

- Check reliability indices.

### Incorrect date of birth

- Threshold testing takes patient age into account.

### Miosis

- Apparent loss of peripheral field (dilate if <3 mm).

### Media opacities

- Overall depression of whole field (corrected by pattern standard deviation plot).

### Uncorrected refractive error

- Overall depression, particularly central sensitivity.
- Greater than one-diopter cylinder uncorrected may cause peripheral scotoma.
- Testing should be performed with near-vision correction after the age of 40 or in aphakes/pseudophakes.

### Spectacles

- Can cause rim artefacts (concentric scotoma).

### Ptosis/blepharochalasis

- Superior field defects (tape lids up during test).

### Facial anatomy

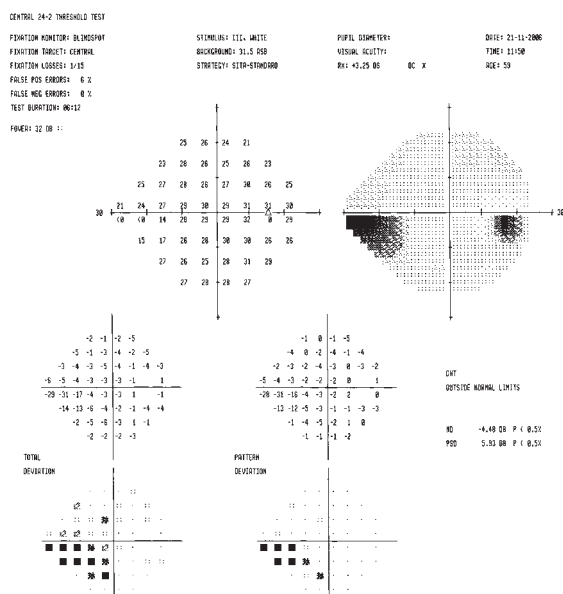
- Large nose or protruding supraorbital margins may cause pseudodeficits.

## Visual field practicalities

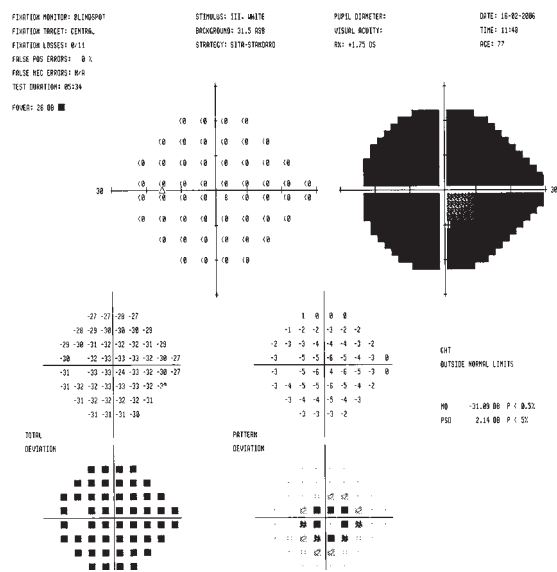
- Watch for a 'learning effect'.
- A visual-field defect should only be considered real after repeat testing.
- Disc features should match the visual-field defects.
- Other causes of visual-field defects should be ruled out, for example chorioretinal lesions and tilted discs.



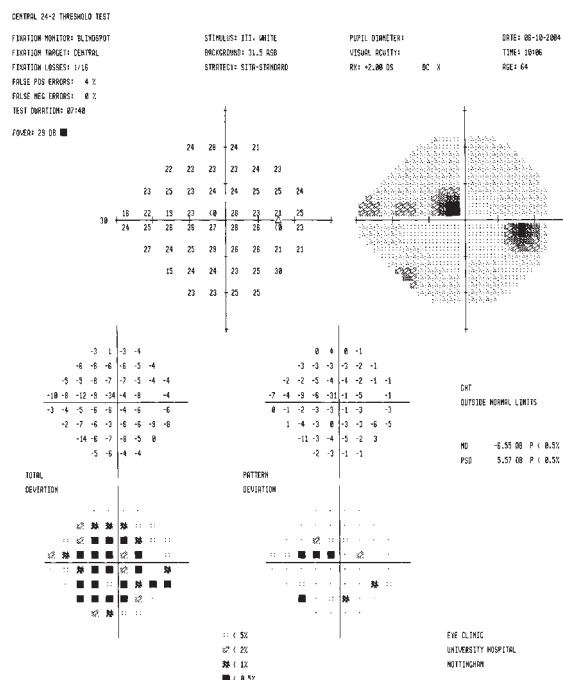
**Fig. 7.14** Humphreys visual-field (24-2) printout showing a typical inferior arcuate visual-field defect.



**Fig. 7.15** Humphreys visual-field (24-2) printout showing a typical nasal step visual-field defect.



**Fig. 7.17** Humphreys visual-field (24-2) printout showing end-stage glaucoma. Such patients should be assessed using a 10-2 programme.



**Fig. 7.16** Humphreys visual-field (24-2) printout showing a dense paracentral scotoma.

## 7.8 Ocular hypertension

Ocular hypertension is a condition characterized by consistently raised IOP with anatomically open angles in which the optic nerve and visual field show no signs of glaucomatous damage. Patients with this condition can be described as either having ocular hypertension or being suspected of glaucoma.

### Prevalence

Population studies show that IOPs have a normal distribution with the curve skewed to the right, as more normal people have an IOP above rather than below the mean pressure of 16 mmHg. The upper limit for 'normal' IOP is 21 mmHg, which is two standard deviations above the mean value.

### Risk factors

- Increased age.
- Female.
- Ethnic origin (black African or Caribbean more at risk).
- Systemic hypertension.
- Corticosteroid use (oral or inhaled).
- Diabetes mellitus.
- Positive family history of glaucoma.

### Clinical evaluation

#### History

- Asymptomatic.
- Family history of glaucoma.

#### Examination

- Applanation tonometry.
- Gonioscopy.
- Pachymetry.
- Optic-disc evaluation.
- Visual-field assessment.

### Management

Anti-hypertensive treatment is indicated only in those individuals with a high presenting IOP who are recognized to be at increased risk of conversion to open-angle glaucoma. The aim is to assess the risk of glaucomatous damage to that particular individual at that IOP in that eye.

The Ocular Hypertension Treatment Study (OHTS) trial from 2002 provided some useful guidelines. This was a multi-centre, prospective, randomized clinical trial where patients with ocular hypertension were assigned to either close observation or topical medications to lower IOP 20% from the baseline. The cumulative probability of developing glaucoma over 60 months for the treated group was 4.4% compared with 9.5% in the observed group. They concluded that treatment should be considered for individuals with ocular hypertension who are at moderate to high risk for developing glaucoma, although when to start treatment still remains controversial. Those with CCT measurements of less than 555  $\mu\text{m}$  were three times more likely to develop glaucoma and there is still much to be learnt about the biomechanical properties of the cornea, such as hysteresis, which are independent of CCT.

### Risk factors for conversion to glaucoma

#### Ocular risk factors

- High presenting IOP.
- Large vertical CDR.
- CDR asymmetry  $>0.2$ .
- Disc haemorrhage.
- RNFL defect.
- Thin cornea.

#### Systemic risk factors

- Age.
- Family history.
- Black African or Caribbean origin.

Another consideration is the risk of CRVO. Any IOP of more than 30 mmHg should be treated for this reason and it would be reasonable to treat an IOP over 25 mmHg in a patient with other cardiovascular risk factors predisposing to CRVO or in whom CRVO has already occurred in the fellow eye.

The decision to treat patients with ocular hypertension must also take into account the risk/benefit ratio of treatment to include side effects of medication and the individual's life expectancy, with the probability of functional visual loss occurring within the patient's lifetime.

Treatment is usually with topical ocular hypertensives such as prostaglandin analogues or  $\beta$ -blockers. The aim is to lower the IOP to a safe level for the individual patient, which should be at least a 20% reduction.

### Follow-up

Depending on the risk factors present, follow-up is normally 6–12 monthly in the outpatient department with annual optic-disc imaging and/or nerve-fibre layer analysis. However, if there are no signs of progression after several consecutive visits, it would be reasonable to discharge to the community for optometric follow-up on a 1–2 yearly basis.

### Prognosis

Approximately 10% of individuals with persistent ocular hypertension will convert to glaucoma over a 10 year period without treatment.

## 7.9 Primary open-angle glaucoma

Primary open-angle glaucoma (POAG) is a progressive optic neuropathy characterized by excavation of the optic disc with reduced visual function as a result of specific visual-field defects. Its inheritance is multifactorial. The exact cause is unknown; however, it is known that raised IOP plays some role in pathogenesis, either directly or indirectly.

### Pathogenesis

POAG patients have increased resistance to aqueous outflow associated with an elevated IOP. The development of visual-field defects is related to progressive loss of axons within the ONH. However, no single mechanism seems to be responsible. The final common pathway, though, is the death, by necrosis or usually apoptosis, of retinal ganglion cells. There are two main theories for this.

1. **Ischaemic theory:** whereby there is compromise of the microvasculature of these axons.
2. **Direct mechanical theory:** where there is direct damage to the retinal nerve fibres by elevated IOP as they pass through the lamellar cribrosa.

### Prevalence

POAG is the most prevalent of all the glaucomas and is the world-wide third leading cause of blindness. It occurs in approximately 1% of the general population over the age of 40, increasing with age to over 4% of those over 80. The incidence is similar in males and females.

### Risk factors for development of POAG

- Factors increasing risk for the conversion of ocular hypertension to glaucoma (see section 7.8).

Also:

- Positive family history in a first-degree relative (risk is doubled for a parent, quadrupled for a sibling): probable lifetime risk of POAG in siblings is 20%.
- High myopia.
- Diabetes mellitus.

### Risk factors for blindness in POAG

- Advanced disease at presentation.
- Sub-optimal IOP control.
- Black African or Caribbean race.
- Low socio-economic status.

### Clinical evaluation

#### History

- Asymptomatic until there is significant loss of the visual field (damage results in negative scotomas): early visual-field loss tends to involve the nasal field that is covered by the fellow eye.
- Difficulty in moving from bright to darker rooms and in judging steps and kerbs may be elicited.
- Younger patients, in particular, may experience transient blurring of vision or haloes around lights if the IOP is particularly high.

#### Examination

- Visual acuity.
- Goldmann applanation reveals a raised IOP, usually in the region of 24–32 mmHg.
- Fluctuations in IOP (90% have diurnal variations up to 5 mmHg).
- Open angle with normal appearance: this is a key feature in making this diagnosis.
- Glaucomatous optic-disc cupping: asymmetric disc appearances may be a feature. Document by means of drawings or optic-disc photography.
- Glaucomatous visual-field defects on static or kinetic perimetry.

### Screening

Screening should be routinely performed in the community for patients over the age of 40 who have first-degree relatives with POAG. Free eye tests on the UK National Health Service are available for this group and for all individuals over 60. If IOP is normal, screening should occur at 2 yearly intervals until age 50, then annually thereafter.

### Management

The aim of treatment in POAG is to preserve visual function in an individual patient. This is achieved by controlling the IOP while minimizing any adverse effects of treatment. It is important to realize that POAG cannot be cured but that control of IOP can prevent progression of damage. There is always a risk-versus-benefit assessment for treatment in an individual patient.

Some clinicians use a target pressure which should be calculated based upon the IOP at initial presentation and the IOP where documented damage has occurred. Some, however, prefer a reduction of 20–30% depending upon the pre-existing damage rather than a 'target' IOP. Most importantly, the IOP level should be re-evaluated at each visit in light of the visual field and optic disc.

The Advanced Glaucoma Intervention Study (AGIS) showed that low IOP is associated with reduced progression of a visual-field defect.

The Early Manifest Glaucoma Trial (EMGT) showed that lowering IOP by 25% and to below 25 mmHg delays the onset of visual-field defect progression. In addition, each higher (or lower) mmHg of IOP on follow-up was associated with an approximate 10% increased (or decreased) risk of progression.

Ideally if logistics allow, one eye should be treated initially as a therapeutic trial with the fellow eye as the control. A reduction in IOP of more than 3 mmHg is significant, after which treatment should commence in the fellow eye also. Remember that  $\beta$ -blockers have a contralateral effect even with treatment being used to only one eye.

The target IOP is an individualized clinical tool which is applicable to that patient at that time. It may be revised up or down, depending on the clinical picture.

Specific pharmacological and surgical management options are discussed in later chapters.

### Follow-up

After decision to treat, re-assessment of IOP should be performed within 6 weeks and any side effects evaluated. If IOP reduction is satisfactory this interval may be extended to 3 months and thereafter at 6 monthly intervals with annual visual-field assessment.

## 7.10 Acute angle closure

Acute angle closure is one of few ophthalmic emergencies, because, left untreated, it can result in irreversible visual loss within hours due to the high level of IOP.

### Pathophysiology

Angle closure occurs when the iris moves forward to the extent that it blocks the trabecular meshwork and subsequent aqueous fluid outflow. The iris can either be pushed forward as in cases of pupil block and plateau iris (primary angle closure), or can be pulled towards the trabecular meshwork in inflammatory conditions (secondary angle closure). The loss of vision is due initially to corneal oedema but later related to an irreversible glaucomatous optic neuropathy.

### Primary angle closure

A physiological situation of relative pupillary block occurs in all eyes. It occurs due to contact between the pupil margin and the anterior lens surface, resulting in resistance to aqueous flow from the posterior chamber to the anterior chamber. A pressure differential then results, which causes the peripheral iris to bow forwards (iris bombé). If the angle structure is prone the drainage angle may become blocked and aqueous outflow blocked.

This chain of events usually starts due to anatomic predisposition involving a relative anterior location of the iris-lens diaphragm, a shallow anterior chamber, and a narrow chamber angle. Environmental stimuli can trigger an attack of primary angle closure by affecting the pupil size: the degree of iridolenticular contact is at its maximum with a mid-dilated pupil found in conditions of dim lighting, mental stress, fatigue, trauma, following use of mydriatics and even during respiratory infections. Pupil block may also cause a secondary angle closure due to a tumescent cataract pushing against the iris: a condition known as phacomorphic glaucoma.

Primary angle closure can occur without pupil block by angle crowding and occlusion of the drainage angle by thick iris folds or as a manifestation of the plateau iris configuration. In this condition, the central anterior chamber depth is normal and the iris plane is flat rather than convex, until a steep insertion into the ciliary body at the periphery.

### Primary angle closure glaucoma

Primary angle closure glaucoma occurs when the raised IOP due to angle closure has resulted in glaucomatous optic neuropathy.

#### Prevalence

Primary angle closure glaucoma accounts for less than 10% of all diagnosed cases of glaucoma, although in high-risk groups such as Inuit, the overall incidence can be as high as 10% in those over 40 years.

The prevalence of narrow angles in the general population is 1% and that of occludable angles is 0.64%.

#### Risk factors

- Increased age.
- Female (4:1).
- Race (common in Inuit and Far-Eastern populations, rare in black populations).
- Positive family history.
- Hypermetropia.
- Shallow anterior chamber.
- Narrow drainage angle.
- Relative anterior location of iris-lens diaphragm.
- Nanophthalmos.

- Plateau iris.
- Medication (e.g. sympathomimetics, anti-cholinergics).

#### Clinical evaluation

##### History

- May be asymptomatic in chronic primary angle closure glaucoma.
- Severe ocular pain.
- Red eye.
- Tearing.
- Haloes around lights.
- Reduced vision.
- Nausea.
- Vomiting.
- Headache.
- Previous intermittent episodes of blurred vision and ocular pain (sub-acute events).

##### Examination

- Ciliary injection.
  - Corneal oedema (fine ground glass) and epithelial bullae.
  - Shallow anterior chamber (distance from iris to peripheral cornea is less than one-quarter of the corneal width on slit lamp exam).
  - Aqueous flare with and without cells.
  - Stromal iris atrophy with a spiral-like configuration.
  - Fixed/sluggish mid-dilated pupil (vertically oval).
  - IOP greater than 40 mmHg (can be up to 100 mmHg).
  - Occluded angle on gonioscopy.
  - Glaucomflecken (small gray-white anterior subcapsular opacities: indicate previous episodes of markedly raised IOP).
  - Optic-disc oedema and hyperaemia.
- Gonioscopic examination of the fellow eye is essential to look for an occludable angle (less than 90° of the posterior trabecular meshwork visible).

#### Differential diagnosis

- POAG with unusually high IOP.
- Glaucomatocyclitic crisis.
- Neovascular glaucoma.
- Plateau iris syndrome (recurrent angle-closure glaucoma in the presence of a patent peripheral iridotomy).
- Malignant glaucoma.
- Pigment dispersion syndrome/glaucoma.
- Anterior chamber angle tumour or mass.
- Uveitic glaucoma.
- Iridocorneal endothelial (ICE) syndrome.
- Other causes of ocular pain (migraine, cluster headache).

#### Management

##### Initial

Urgent reduction of IOP.

- Acetazolamide 500 mg intravenous followed by oral acetazolamide 250 mg QDS.
- G. pilocarpine 2% to both eyes QDS (when IOP <40 mmHg, otherwise the iris is too ischaemic and would not respond)
- G. Dexamethasone 1% QDS.
- G. Timolol 0.5% BD.
- G. Iopidine 1% immediately.



**After 1 hour**

Recheck IOP and if still more than 35 mmHg:

- mannitol 20% (1–2 g/kg) intravenous over 45 minutes,
- or oral glycerol 50% (1–1.5 g/kg) in lemon juice.

Be cautious when using mannitol/glycerol in elderly patients with cardiovascular and/or renal disease.

**After further 1 hour**

- If adequate corneal view, attempt laser peripheral iridotomy. Glycerine may be required to clear the cornea.
- If IOP fails to reduce despite all the above measures, then discuss with a consultant and consider corneal indentation, laser iridoplasty, or a surgical peripheral iridotomy.

**Other**

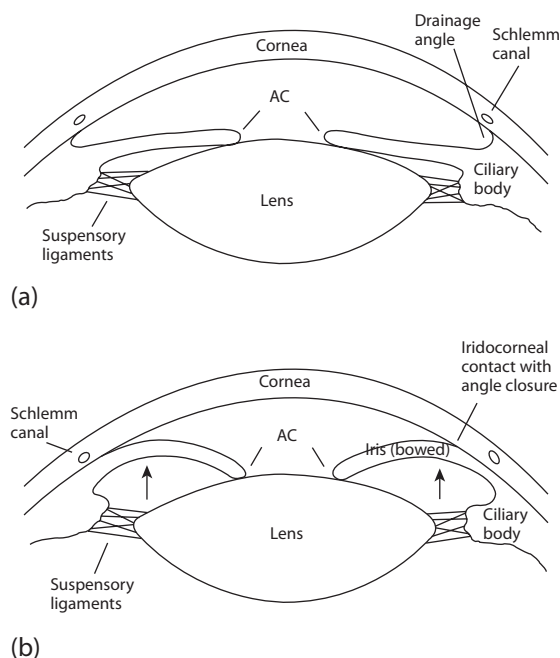
Laser peripheral iridotomy is indicated in the fellow eye if gonioscopy has revealed an occludable angle. More than 50% will develop symptoms in the second eye if left untreated.

**Follow-up**

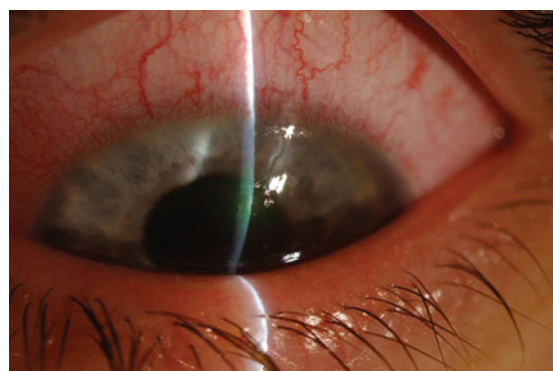Once the IOP is reduced and the pupil has miosed patients can be discharged on the topical medications used to treat the initial attack, and followed-up daily until the IOP has normalized with open angles. Longer-term follow-up includes IOP measurements, checks on the patency of the peripheral iridotomy, and repeat gonioscopy to ensure that the angle remains open. Repeating the gonioscopy post-procedure is vital as 10–20% of patients will have a residual narrow angle, often with a degree of plateau configuration or phacomorphic component.

**Prognosis**

Prognosis depends on duration and severity of attack. Prompt IOP lowering is essential in preventing irreversible ONH damage. Chronic angle closure can result following appositional closure of the angle following the acute event. The IOP could insidiously rise over time due to trabecular damage sustained in the acute attack. The IOP may also spike once more due to recovery of temporary ciliary body shut-down, which resulted from ischaemia induced by the high IOP.



**Fig. 7.18** Diagram of the mechanism of pupil block.



**Fig. 7.19** Colour anterior segment photograph showing the eye of a patient in acute angle closure glaucoma. There is ciliary injection, the pupil is mid-dilated and the cornea is slightly oedematous.

## 7.11 Normal-tension glaucoma

Normal-tension glaucoma (also referred to as low-tension glaucoma) is a form of open-angle glaucoma characterized by a peak IOP that is consistently within the statistically normal range. Features of the optic nerve and visual field suggestive of glaucomatous optic neuropathy are found with an IOP of less than 21 mmHg in the absence of a secondary cause. It can therefore be considered a diagnosis of exclusion.

### Pathogenesis

Although IOP remains a significant factor, non-pressure-dependent processes also have an important role. Reduced blood flow to the ONH appears to be particularly important and there is building evidence that systemic vascular dysregulation and localized vasospasm play a major role.

### Prevalence

Although once thought to be uncommon, up to one-third of patients with open-angle glaucoma can be classified as having normal-tension glaucoma (Beaver Dam Study) and, although more common in the elderly, up to 30% of patients are under 50 years. Overall prevalence is estimated at 0.15% of the general population.

### General risk factors for normal-tension glaucoma

- IOP (susceptibility of the optic nerve to damage at relatively low levels of IOP).
- Thin central cornea.
- Increased age.
- Female (2:1).
- Race (two-thirds of Japanese glaucoma is normal-tension glaucoma).
- Positive family history.
- Diabetes mellitus.
- Myopia.

### Risk factors for reduced blood flow to ONH

- Vasospastic tendencies (history of migraine or Raynaud phenomenon).
- Hypercoagulability.
- Nocturnal hypotension.
- Autoimmune disorders.

### Clinical evaluation

#### History

Need to specifically enquire about risk factors for reduced blood flow.

#### Examination

- As for ocular hypertension/POAG.
- Phasing (diurnal IOP curve) to elucidate any IOP spikes.

Specific clinical features for normal-tension glaucoma:

- visual-field defects appear more localized, deeper, steeper and closer to fixation,
- amount of visual-field loss is greater than expected on optic-disc appearance,
- localized (slit or wedge) defects of RNFL,
- increased propensity for optic-disc haemorrhages,
- thinner neuroretinal rim,
- larger, shallower optic cup,
- acquired optic-disc pits,
- peripapillary atrophy more common.

#### Further investigations (as appropriate)

- Blood pressure, blood glucose level, serum autoantibodies, ESR, CRP.

- 24 hour blood-pressure monitoring.
- Laboratory testing for infectious or inflammatory conditions.

### Neuroimaging if compressive disease suspected

- Younger than 50 years.
- Poor visual acuity.
- Pallor of neuroretinal rim.
- Discrepancy between disc cupping and visual-field loss.
- Visual-field loss which respects the midline.

### Differential diagnosis

- POAG with diurnal fluctuations.
- Intermittent angle closure glaucoma.
- Hereditary optic neuropathy.
- Compressive lesions of anterior visual pathway.
- Acquired optic neuropathies (ischaemic, toxic, drug-induced, or nutritional optic neuropathy).
- Systemic disorders (syphilis, tuberculosis, sarcoidosis, and multiple sclerosis).
- Hypoperfusion (including history of large-volume blood loss).
- Optic-disc anomalies (drusen, large pits, colobomas).

### Management

First, treat any underlying medical conditions.

The Collaborative Normal Tension Glaucoma Study (CNTGS) showed that lowering IOP by 30% significantly reduced the rate of progression of normal-tension glaucoma. However, two-thirds of patients in the control arm did not progress, despite not receiving any therapy. This suggests that an initial 'watch without treatment' approach is appropriate. All cases are treated on an individual basis though so if an individual has visual-field loss close to fixation, it would be prudent to initiate treatment at the outset.

#### Medical

- Prostaglandin analogues (greater IOP-lowering effect at night).
- $\alpha$ -2 Agonists (may have additional neuroprotective effects).
- Carbonic anhydrase inhibitors (may increase ocular blood flow).
- $\beta$ -Blockers (however, theoretical adverse effects on ONH perfusion).
- Systemic calcium-channel blockers (may decrease vasospasm and increase capillary dilatation); use with caution. Note, there is no level 1 evidence for using these.

#### Surgical

- Laser trabeculoplasty.
- Trabeculectomy.

### Follow-up

As for POAG.

## 7.12 Steroid-induced glaucoma

Raised IOP may be induced following corticosteroid administration in so-called 'steroid responders' and eventually result in a secondary open-angle glaucoma. This is most commonly seen following use of topical steroid such as dexamethasone or prednisolone. With the increasing use of peri- and intra-ocular depot steroid injections this problem will probably increase in magnitude and severity.

Steroid response is reasonably common and is usually self-limiting on cessation of the treatment; however, when the optic nerve becomes compromised the clinical picture changes to that of steroid-induced glaucoma.

### Pathophysiology

The condition is not completely understood, but steroids are known to have several effects on the trabecular meshwork, all of which contribute to an increased outflow resistance and hence increased IOP. These include an increase in trabecular meshwork glycosaminoglycans, decreased membrane permeability, reduced breakdown of extracellular and intracellular structural proteins, and a reduced local phagocytic activity by cells that filter and clean debris from the aqueous. These effects usually take about 2 weeks to cause a rise in IOP but may only manifest at a much later stage. Ongoing research has shown that several genes are responsible for these effects, the most extensively studied is that represented by the protein myocilin (also known as the trabecular meshwork-inducible glucocorticoid response or *TIGR* gene product). This *TIGR*/MYOC protein is induced in human cultured trabecular meshwork cells after exposure to dexamethasone for 2–3 weeks and thus appears to fit with the time scale for steroid-induced raising of IOP.

### Risk factors

- Past or current steroid use of any type (asthma, skin disorders, allergies, autoimmune disease, uveitis).
- Endogenous elevation of steroid (Cushing's syndrome).
- POAG or pigmentary glaucoma.
- Family history of glaucoma.
- Age over 40.
- Diabetes mellitus.
- High myopia.
- Connective tissue disease.

### Prevalence of steroid response

Eighteen to thirty-six per cent of general population; 46–92% of POAG patients.

### Clinical evaluation

#### History

- Use of topical, intraocular, periocular, inhaled, nasal, oral, intravenous, or dermatological steroid.
- Presence of known risk factors.

#### Examination

- Usually unremarkable; chronicity tends to prevent corneal oedema.
- Contralateral steroid challenge may confirm the diagnosis.

### Management

- A baseline measurement of IOP should be taken prior to starting steroid therapy.
- Discontinue steroids if IOP rises.
- Use weaker or less-pressure-inducing ocular steroids, for example fluorometholone (FML™) or rimexolone (Vexol™).
- IOP-lowering therapy as for POAG.

- If induced by a depot steroid then surgical removal may be indicated.

### Follow-up

- Need careful monitoring of patients at risk due to insidious nature.
- Topical therapy: measure IOP a few weeks after start of therapy then at regular intervals.
- Intravitreal injections: need monitoring for several months and up to a year after injection.
- Patients on long-term systemic steroids should visit their own optician for regular IOP checks.

### Prognosis

IOP usually returns to normal within 1–4 weeks of cessation of treatment; however, the steroid response may be irreversible in about 3% of cases, resulting in eventual glaucoma.

## 7.13 Traumatic glaucoma

Blunt ocular trauma results in ocular indentation and a sudden expansion of the tissues in the opposite plane. As the vitreous offers some form of resistance, most of the transmitted force is directed along the iris towards the trabecular meshwork, ciliary body, and zonules, which can result in tearing of these tissues in addition to tearing of associated blood vessels causing a hyphaema. Penetrating trauma may lead to direct damage to all the ocular structures. The overall result can be a secondary open- or closed-angle glaucoma due to a variety of mechanisms.

### Pathophysiology

#### Early-onset traumatic raised IOP

- Trabecular meshwork obstruction with fresh red blood cells and fibrin (red cell glaucoma).
- Pupillary block by blood clot.
- Haemolytic glaucoma (due to breakdown products).
- Steroid-induced glaucoma due to treatment.

#### Late traumatic glaucoma

- Angle recession (tear in ciliary body between longitudinal and circular muscle layers): indicator for direct trabecular meshwork damage (not the direct cause of the raised IOP).
- Ghost cell glaucoma (degenerate red blood cells from vitreous).
- Peripheral anterior synechiae (PAS) formation.
- Posterior synechiae formation with iris bombe.
- Haemosiderotic or haemolytic glaucoma.

### Prevalence

- In those with hyphaema filling up to half of the anterior chamber: 13.5%.
- In those filling greater than half of the anterior chamber: 27%.
- With total hyphaema: 52%.
- Of those with greater than 180° of angle recession: 10%.
- Glaucoma risk is increased in rebleeds and sickle cell patients.

### Risk factors for raised IOP

- Younger age.
- Male sex (3:1).
- Black populations and Hispanics (related to the presence of sickle cell disease or trait):
  - rigid cells more easily trapped in trabecular meshwork,
  - vascular occlusion and optic-nerve damage at lower IOP.
- Predisposition to POAG.
- Antiplatelet or anticoagulant therapy (including alcohol).
- Larger initial hyphaema.
- Eight-ball hyphaema (total black hyphema clot: black colour related to ischaemic environment in the anterior chamber).
- Delayed presentation.
- Rebleed.

### Clinical evaluation

#### History

- Details of injury (exact time, type of injury).
- Family history of a bleeding disorder or sickle cell disease.
- Drug history (aspirin, NSAIDs, anticoagulants, alcohol).
- Previous history of trauma (chronic glaucoma).
- May be asymptomatic or have decreased vision, photophobia, pain, nausea, or vomiting.

#### Examination

- Subconjunctival haemorrhage.
- Hyphaema (or microhyphaema).
- Anterior chamber may be deeper than fellow eye.

- Iris sphincter tear or iridodialysis.
- Gonioscopy:
  - angle recession (see below),
  - cyclodialysis cleft (see below),
  - PAS.
- Lens subluxation, cataract, or phacodonesis.
- Vitreous haemorrhage.
- Choroidal rupture.
- Retinal dialysis or detachment; commotio retinae.

### Investigations

- B-scan ultrasonography (if no view of posterior pole).
- CT scan (if suspect orbital fracture or intraorbital foreign body).
- Haemoglobin electrophoresis (if suspected sickle cell disease).

### Management of traumatic hyphaema

#### General

- Protective eye shield.
- Bed rest.
- Elevation of head.
- Anti-emetics.
- Systemic blood-pressure control.
- Avoid antiplatelet and anticoagulant drugs.

#### Medical

- Topical cycloplegic and corticosteroid.
  - The use of cycloplegic agents is controversial. Movement of the iris may theoretically predispose to dislodgement of the clot and a rebleed.
  - Consider an antifibrinolytic drug in high-risk patients.
  - Topical aqueous suppressants.
  - Systemic carbonic anhydrase inhibitors and hyperosmotics (contraindicated in sickle cell patients as they may exacerbate sickling and compound trabecular meshwork obstruction).
- Avoid miotics and prostaglandin analogues (may increase inflammation).

#### Surgical

- Anterior chamber washout may be required if IOP is uncontrolled.
- Anterior vitrectomy.
- Trabeculectomy with antimetabolite.
- Surgery indicated with healthy optic nerve if:
  - IOP of more than 50 mmHg for 5 days,
  - IOP of more than 35 mmHg for 7 days: both increase risk of irreversible corneal blood staining.
- Sickle cell patients if IOP of more than 24 mmHg for 24 hours.

Earlier intervention is advised if the optic nerve is compromised or there is endothelial dysfunction.

### Management of angle-recession glaucoma

Angle recession occurs when the ciliary body is separated. It is diagnosed by an irregular widening of the ciliary body band on gonioscopy.

#### Treatment

- Aqueous suppressants.
- Hyperosmotics.
- Trabeculectomy.
- Argon laser trabeculoplasty has limited success and may exacerbate angle damage.

### Management of cyclodialysis cleft

A cyclodialysis cleft is a focal detachment of the ciliary body from its insertion at the scleral spur. It is diagnosed by a deep angle recess with a gap between the sclera and ciliary body on gonioscopy.

A traumatic cyclodialysis cleft will usually result in a soft eye unless measures are directed to closing it:

- topical atropine,
- argon laser,
- cryotherapy,
- most require surgical closure.

Following closure:

- aqueous suppressants,
- hyperosmotics.

### Follow-up

- Daily monitoring is necessary until the hyphaema clears (rebleed risk highest at 2–5 days after injury).
- Gonioscopy performed 4–6 weeks after injury (to look for angle recession).

- Glaucoma may develop weeks to years after event: such patients should have annual IOP checks at their local opticians.
- After cleft closure, IOP can increase dramatically so close monitoring is initially required.

### Prognosis

The prognosis is highly dependent upon the degree of initial damage and the amount of disruption to the trabecular meshwork. Rebleeds tend to result in more IOP-related problems than the initial bleed.

In high-risk patients with markedly uncontrolled IOP the visual prognosis may be guarded.



## 7.14 Inflammatory glaucomas

Inflammation within the anterior segment caused by uveitic conditions can result in raised IOP; that is, secondary ocular hypertension. If this raised IOP then results in glaucomatous optic-nerve damage or visual-field defects it is known as inflammatory or uveitic glaucoma.

### Pathophysiology

Ocular inflammation causes breakdown of the blood–aqueous barrier, resulting in liberation of protein and inflammatory cells into the aqueous.

### Secondary open-angle glaucoma

- Obstruction of the trabecular meshwork by cellular debris, protein, or macrophages.
- Inflammation and oedema of the trabecular meshwork itself (trabeculitis) with a secondary reduction of intertrabecular pores or formation of precipitates on the trabecular meshwork.
- Prostaglandins involved in the inflammatory process may indirectly contribute to raised IOP through their action on the blood–aqueous barrier.

### Secondary angle closure glaucoma

#### With pupil block

Anterior segment inflammation may result in formation of 360° posterior synechiae causing iris bombe. The shallowing of the anterior chamber caused by this may then result in appositional angle closure by the development of PAS.

#### Without pupil block

- In chronic anterior uveitis, contraction of inflammatory debris within the angle can pull peripheral iris over the trabeculum, causing gradual but progressive synechial angle closure.
- Angle neovascularization from retinal or iridial ischaemic processes may also result in formation of PAS.
- Ciliary body swelling due to intraocular inflammation may result in the forward rotation of the ciliary body, causing angle closure.

### Prevalence

Twenty-five per cent of all chronic uveitis patients will develop increased IOP at some time.

### Risk factors

- Pre-existing POAG.
- Presence of narrow angles.
- Post-surgery.
- Post-trauma.
- Rigid anterior chamber IOL (uveitis–glaucoma–hyphaema or UGH syndrome).
- Presence of uveitic conditions associated with secondary glaucoma:
  - juvenile rheumatoid arthritis,
  - ankylosing spondylitis,
  - Reiter's syndrome,
  - psoriatic arthritis,
  - herpetic uveitis (HSV, VZV, rubella, mumps),
  - lens-induced uveitis (phacoanaphylactic, phacolytic, lens particle),
  - sarcoidosis,
  - Vogt–Koyanagi–Harada syndrome,
  - Behcet's syndrome,
  - sympathetic ophthalmia,
  - syphilis,
  - tuberculosis.

- Primary ocular disorders:
  - Fuchs heterochromic iridocyclitis,
  - Posner–Schlossman syndrome.

### Clinical evaluation

#### History

- Symptoms of acute uveitis.
- Previous history of uveitic episode.
- Systemic history of associated disorder.

#### Examination

- Signs of acute or chronic uveitis or of previous uveitic episode.
- The signs present will depend on the primary cause of the uveitis.
- Gonioscopy is most important as it will elucidate the primary mechanism and thus the treatment.

#### Investigations

- Basic uveitic screen, including bloods and CXR.
- Additional tests appropriate to suspected uveitic process.

### Management

- For all mechanisms, find and treat any cause for the uveitis:
  - control intraocular inflammation,
  - topical, periocular, or sub-Tenon corticosteroid,
  - oral corticosteroid (up to 1 mg/kg per day depending on severity),
  - steroid-sparing agents (cyclosporine, methotrexate, azathioprine, mycophenolate).
- Prevent and break synechiae, and relieve ciliary and iris sphincter spasm (regular cycloplegics):
  - reduction of IOP,
  - aqueous suppressants (  $\alpha$ -blockers,  $\beta$ -agonists, topical carbonic anhydrase inhibitors),
  - systemic carbonic anhydrase inhibitor (acetazolamide),
  - hyperosmotic agents (mannitol, glycerol),
  - avoid prostaglandins in uveitic cases for fear of inducing cystoid macular oedema.
- For secondary angle closure with pupil block:
  - laser iridotomy (several large openings),
  - surgical iridectomy (if iridotomies close).
- For secondary angle closure without pupil block:
  - trabeculectomy (with adjunctive antimetabolites),
  - glaucoma drainage devices,
  - cyclodestructive procedures.

### Follow-up

It is extremely important to monitor these patients closely as there may be permanent compromise of the outflow facility.

Additionally there may have been a temporary decrease in aqueous secretion due to inflammation of the secretory epithelium or ciliary body shutdown, which would pose the risk of increased IOP after the inflammation has resolved.

### Prognosis

Depends on the extent of permanent damage to the drainage mechanism and the recurrent nature of the uveitic condition.

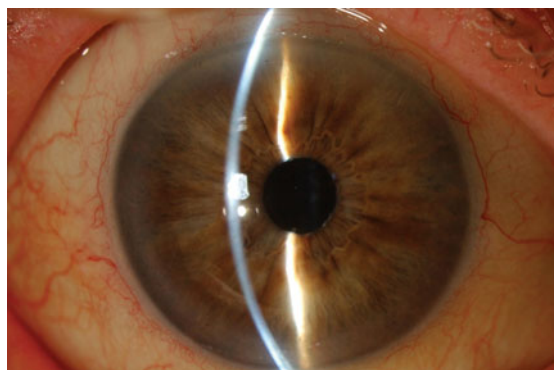
## Specific inflammatory glaucoma syndromes

### Posner–Schlossman syndrome

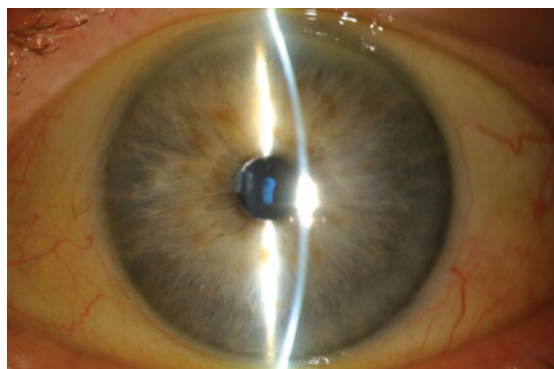
Also known as glaucomatocyclitic crisis, this is a condition in which there are recurrent episodes of unilateral mild anterior uveitis associated with marked elevation of IOP (40–80mmHg) thought to be due to a trabeculitis. Patients tend to be asymptomatic.

### Fuchs heterochromic iridocyclitis

Also known as Fuchs uveitis syndrome, this is a unilateral, mild, chronic, anterior uveitis associated with secondary cataract and glaucoma. The classic presentation is of stellate keratic precipitates scattered throughout the endothelium. The iris may be hypochromic. Initially the rise in IOP is intermittent before becoming chronic and causing glaucoma in approximately 30% of cases. This is probably as a result of trabecular sclerosis due to the unremitting low-grade inflammatory process.



(a)



(b)

**Fig 7.20** Colour anterior segment photographs of both eyes of the same patient showing marked heterochromia.

## 7.15 Pseudoexfoliative and pigmentary glaucoma

### Pseudoexfoliative glaucoma

Pseudoexfoliation syndrome is a systemic condition thought to be a generalized basement-membrane disorder which results in the deposition of a dandruff-like material within the anterior segment of the eye with weakness of the zonules. This pseudoexfoliation material can impair aqueous outflow, resulting in raised IOP and secondary open-angle glaucoma: pseudoexfoliative glaucoma.

#### Pathophysiology

Pseudoexfoliation material is composed of filamentous proteoglycosaminoglycans, which aggregate to form granular, electron-dense grey/white fibrillar deposits due to abnormal protein synthesis. Within the eye, it is believed to be produced by the lens epithelium, iris pigmented epithelium, and non-pigmented epithelium of the ciliary body. Pathological material has been found on the iris, lens, ciliary body, trabecular meshwork, anterior vitreous face, corneal endothelium, conjunctiva and endothelial cells of blood vessels within the eye and orbit. In addition, this fibrillar material has been found in skin, myocardium, lung, liver, gall bladder, kidney, and cerebral meninges, suggesting that pseudoexfoliation is an ocular manifestation of a systemic disorder.

Increased IOP is due to 'clogging' of the trabecular meshwork by both pseudoexfoliation material and pigment released from the iris as a result of pathological friction against the rough deposits on the anterior lens capsule. In addition, trabecular endothelial dysfunction is found, all of which increases outflow resistance in the trabecular meshwork and raises IOP.

#### Prevalence

- Pseudoexfoliation syndrome (Framingham Eye Study):
  - 0.6% of people aged 52–64 years,
  - 5% of people aged 75–85 years.
- The risk of glaucoma is five times greater than in the normal population (Blue Mountains Eye Study).
- Overall approximately 25% open-angle glaucoma worldwide is pseudoexfoliation-related.
- Prevalence is population-dependent (near zero in Inuit; 75% in Sweden).

#### Risk factors

- Age.
- Female (3:2) for pseudoexfoliation syndrome (males=females for pseudoexfoliative glaucoma).
- Race (Scandinavian).

#### Clinical evaluation

##### History

- Rarely symptomatic.
- May have foreign-body sensation (possibly due to subclinical involvement of conjunctiva).
- History of complicated cataract surgery.

##### Examination

- Signs may be unilateral or bilateral with asymmetry.
- Deposition of pseudoexfoliation flakes or pigment within anterior segment.
- IOP spikes may occur following pharmacological mydriasis.
- Patchy increase in trabecular pigmentation.
- Sampaolesi's line may be present.
- Peripupillary iris transillumination defects.
- Depigmented (moth-eaten) pupillary ruff.

- Classic concentric deposition on anterior lens capsule:
  - central translucent zone,
  - clear zone (pseudoexfoliation rubbed off by pupil movement),
  - peripheral granular zone.
- Nuclear sclerotic cataract.
- Lens subluxation.
- Phacodonesis.

#### Management

- Medical therapy is as for POAG although pseudoexfoliative glaucoma is more resistant.
- Laser trabeculoplasty is particularly effective (possibly due to trabecular hyperpigmentation resulting in a better uptake of laser energy).
- Trabeculectomy has the same success rate as in POAG.
- Pseudoexfoliation ocular hypertension does not exist: these patients progress to rapid field loss and warrant IOP lowering therapy.

#### Follow-up

- 9–12 monthly follow-up for pseudoexfoliation syndrome alone.
- Otherwise as for POAG.

#### Prognosis

Poorer prognosis than POAG due to high IOP at the time of diagnosis, significant diurnal IOP fluctuation, and often a rapid progression of glaucomatous damage

### Pigmentary glaucoma

Pigment dispersion syndrome is a bilateral condition characterized by dislodgement of pigment from the posterior iris pigment epithelium resulting in classic mid-peripheral transillumination defects. These pigment particles are then carried by aqueous convection currents and deposited on structures throughout the anterior segment. Obstruction of the trabecular meshwork by pigment can result in increased IOP and a secondary open-angle glaucoma known as pigment dispersion or pigmentary glaucoma.

#### Pathophysiology

Pigment dispersion syndrome may be inherited as an autosomal dominant trait with variable penetrance. The anterior chamber is deeper in these eyes and the iris appears to bow posteriorly in a concave configuration due to a reverse pupil block caused by a relative increase in pressure in the anterior chamber. Chafing of the iris posterior pigment layer against the lens zonules occurs as a result of this excessive posterior bowing of the mid-peripheral iris, releasing pigment granules into the anterior chamber whenever the pupil reacts, particularly so during mydriasis or strenuous exercise when a 'pigment storm' can result in excessively high IOP spikes.

Obstruction of the intertrabecular spaces by pigment can occur with reduced outflow facility and also damage to the trabecular meshwork due to denudation, collapse, and sclerosis.

#### Prevalence

About one-third of patients with pigment dispersion syndrome develop pigment dispersion glaucoma. This accounts for 1–1.5% of all glaucomas.

#### Risk factors

- Age 20–45 years (later in females).
- Male (2:1).
- Race (Caucasian).
- Myopic.

## Clinical evaluation

### History

- Usually asymptomatic.
- May have blurred vision, haloes, or headache during 'pigment storm', for example after exercise.

### Examination

- Krukenberg spindle (vertical deposition of pigment on corneal endothelium).
- Deep anterior chamber.
- Small pigment specks floating within the anterior chamber.
- IOP may be normal or high.
- Gonioscopy:
  - wide open angle,
  - concavity of iris near insertion,
  - diffuse trabecular hyperpigmentation,
  - Sampaolesi's line (pigmented Schwalbe's line).
- Iris transillumination defects (mid-peripheral radial spokes).
- Pigment on anterior surface of iris (preferentially within furrows).
- Pigment on anterior and posterior lens surface.
- Glaucomatous optic atrophy.
- Lattice degeneration (full-thickness retinal holes and retinal detachment).

### Differential diagnosis

- POAG with hyperpigmented trabeculum.
- Pseudoexfoliative glaucoma.
- Pseudophakic pigmentary glaucoma (rubbing of haptics/optics against posterior iris).
- Uveitis.
- Melanoma.
- Iris and ciliary body cysts.
- Trauma.

### Management

- Medical therapy as for POAG.
- Miotics (if tolerated) will decrease irido-zonular contact in addition to increasing aqueous outflow.
- Laser trabeculoplasty (most effective in younger patients).
- Trabeculectomy (success rate similar to POAG).

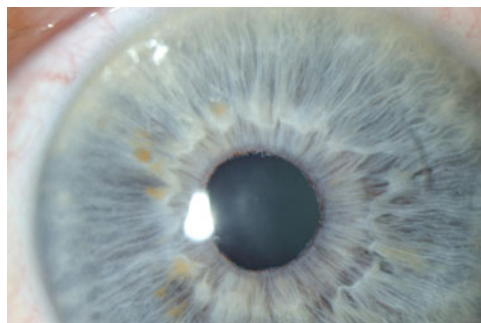Prophylactic laser peripheral iridotomy in pigment dispersion syndrome can theoretically be used to relieve reverse pupil block responsible for the posterior bowing of iris. Long-term benefits in the prevention of glaucoma are, however, still not proven and the treatment is controversial as yet.

### Follow-up


Patients with pigment dispersion syndrome and a normal IOP with no signs of glaucoma need regular IOP checks only, which can be done by their own optician; otherwise, follow-up is as for POAG.

### Prognosis

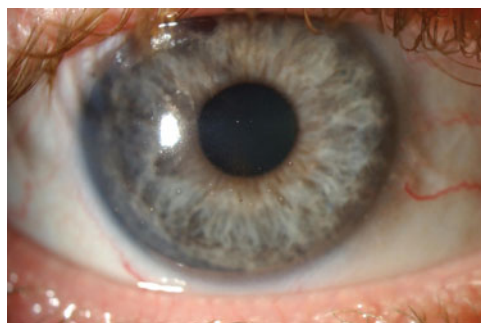Long-term prognosis is good. Pigment dispersion tends to decrease with age due to miosis and gradual lens enlargement, which increases relative pupil block thus lifting the peripheral iris away from the zonules. In a few cases, there is even spontaneous resolution of glaucoma.



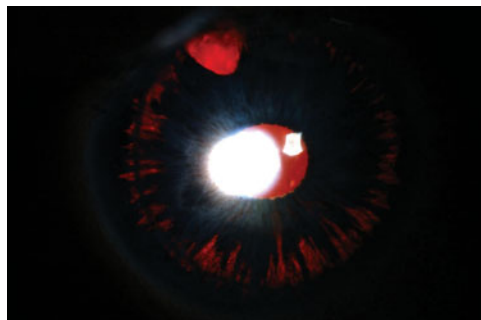
**Fig. 7.21** Colour anterior segment photograph showing pseudoexfoliative material at the pupil margin.



**Fig. 7.22** Colour anterior segment photograph showing the three zones on the anterior surface of the lens. There are peripheral and central deposits separated by a clear band where the pupil has rubbed the deposits off.



**Fig. 7.23** Colour anterior segment photograph showing the presence of pigment on the corneal endothelium forming a Krukenberg spindle.



**Fig. 7.24** Colour anterior segment photograph showing typical slit-like iris transillumination defects. The patient has also had a trabeculectomy and has a superior peripheral iridotomy.

## 7.16 Neovascular glaucoma

Rubeosis iridis can be initiated by any process causing widespread posterior segment hypoxia with subsequent raised levels of VEGF. Neovascularization of the angle may occur and, if treatment is not initiated in the early stages, this will result first in a type of secondary open angle and the eventually lead to a secondary angle closure glaucoma known as neovascular glaucoma.

### Pathophysiology

In an attempt to revascularize itself, ischaemic retina will produce vasoproliferative factors (such as VEGF) which diffuse throughout the eye and into the anterior segment, resulting in neovascularization. The process usually starts with endothelial budding from capillaries at the pupil margin (although this can also start within the angle). The new vessels then grow in an irregular pattern towards the angle over the iris surface. This neovascular tissue then invades the angle and can arborize to form a fibrovascular membrane along with proliferating connective tissue and myofibroblasts. This membrane can block the trabecular meshwork, causing a rise in IOP and thus an open-angle glaucoma. The condition is reversible initially; however, if untreated, the myofibroblasts, which have smooth muscle characteristics, will contract and pull peripheral iris over the trabecular meshwork in a zip-like manner, resulting in PAS and an angle closure glaucoma. The underlying aetiology for the initial hypoxic stimulus varies but all these pathological entities have the same common final pathway. The severity and extent of ischaemia simply determines the rapidity of onset of neovascular glaucoma.

### Prevalence

- Ischaemic CRVO: 16–60% develop neovascular glaucoma (depending on the extent of capillary non-perfusion).
- Proliferative diabetic retinopathy: approximately 20% of type 1 diabetes mellitus patients with proliferative diabetic retinopathy eventually develop neovascular glaucoma
- CRAO: approximately 18%.

### Risk factors

- Ischaemic CRVO (most common cause of unilateral neovascular glaucoma):
  - age,
  - systemic hypertension,
  - ocular hypertension/POAG,
  - hypercoagulable state,
  - vasculitis,
  - drugs (ocular cicatricial pemphigoid, diuretics),
  - retrobulbar external compression (thyroid eye disease, orbital tumour).
- Diabetes mellitus (most common cause of bilateral neovascular glaucoma).
- Ocular ischaemic syndrome.
- BRVO.
- CRAO/BRAO.
- Chronic retinal detachment.
- Sick cell retinopathy.
- Ocular neoplasm.
- Chronic uveitis.
- Endophthalmitis.
- Sympathetic ophthalmia.
- Radiation retinopathy.

### Clinical evaluation

#### History

- Presence of the risk factors above.
- Asymptomatic in early stages.

- Ocular pain or photophobia.
- Red eye.
- Reduced vision.

#### Examination

- Congestion of globe.
- Corneal oedema.
- Raised IOP.
- Aqueous flare.
- Possible hyphaema.
- Rubeosis iridis (it is vital to also check the angle gonioscopically prior to dilation).
- Synechial angle closure on gonioscopy.
- Distorted pupil with ectropion uveae.

#### Differential diagnosis

- Angle closure glaucoma.
- Post-vitrectomy inflammation.

#### Management

- PRP (eliminates stimulus): this should be done as soon as rubeosis is detected; it should not be deferred to a routine laser list.
- Injection of anti-VEGF agents may be a promising new technique for the future.
- Aqueous suppressants (reduce IOP).
- G. Atropine 1% BD (increases uveoscleral outflow).
- Topical corticosteroid (controls congestion and inflammation).
- Trabeculectomy (with antimetabolite; guarded prognosis).
- Glaucoma drainage device.
- Cyclodestructive procedure (cyclodiode).
- Enucleation.

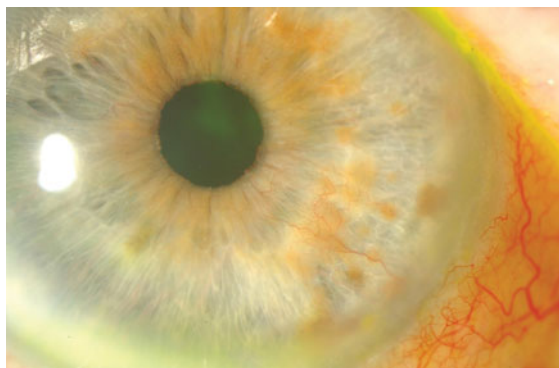
#### Follow-up

- Close follow-up is crucial as neovascular glaucoma can be reversible in early stages.
- Fill-in PRP is applied as required.
- An ischaemic CRVO can cause neovascular glaucoma within 3 months (so-called 90 day glaucoma) or up to 2 years later.

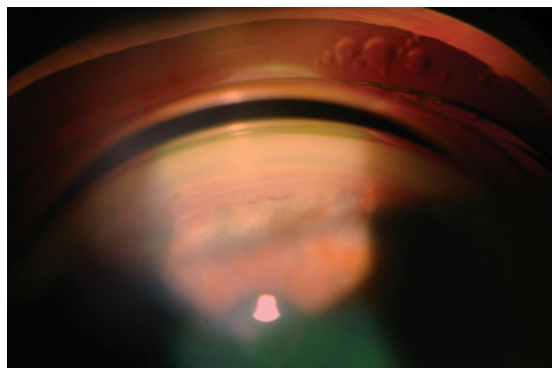
#### Prognosis

- Excellent if fully treated in early stages.
- Extremely poor once synechial angle closure has occurred (treatment is to keep eye comfortable and maintain cosmesis).





**Fig. 7.25** Colour anterior segment photograph showing new iris vessels.



**Fig. 7.26** Colour anterior segment photograph showing the gonioscopic view of new vessels within the angle.

## 7.17 Malignant glaucoma

Malignant glaucoma, also known as ciliary block glaucoma or aqueous misdirection syndrome, is a type of secondary angle closure glaucoma. The condition usually follows penetrating surgery of eyes that are anatomically predisposed to aqueous misdirection. There is a decreased space between the ciliary body and the adjacent lens, facilitating the formation of a seal between the anterior hyaloid and the ciliary body. It has also, however, been known to occur spontaneously or after anterior segment laser procedures.

### Pathophysiology

Surgical intervention in the eye causes a not fully understood initiating event (postulated to be sudden anterior chamber decompression) which can change the direction of aqueous flow, causing entry into the vitreous rather than the usual flow forwards around the pupil, into the anterior chamber. This leads to physical alteration of the vitreous with increased volume and compaction resulting in increased posterior segment pressure and anterior movement of the lens-iris diaphragm. The outcome of this is shallowing of the anterior chamber both axially and peripherally with angle closure.

### Prevalence

Malignant glaucoma is much less common nowadays due to improved techniques.

### Risk factors

- Filtration surgery (particularly for chronic primary angle closure glaucoma).
- Cataract surgery.
- Post-Nd:YAG capsulotomy or laser iridotomy
- Nanophthalmos (small globe with normal lens size).
- Increased age or cataract (increased lens size).
- Trauma or pseudoexfoliation (decreased anterior–posterior lens position due to weak or ruptured zonules).
- Inflammation or vascular engorgement (swelling of the ciliary body).
- Chronic miotic use.

### Clinical evaluation

#### History

- Recent eye surgery (but can be up to months postoperatively).
- Blurred vision.
- Usually no pain.

#### Examination

- Shallow anterior chamber (central and peripheral).
- No iris bombé.
- High IOP (or relative increase after filtration surgery; i.e. >10 mmHg).
- Corneal oedema (if IOP high or lens–endothelial contact).
- Patent peripheral iridotomy (if present).
- Normal posterior segment anatomy (no choroidal effusions).

#### Investigations

Undertake ultrasound biomicroscopy looking for flattening of ciliary body processes in the absence of choroidal effusions.

### Management

#### Medical

- Topical cycloplegics/mydriatics.
- Topical aqueous suppressants.
- Oral or systemic hyperosmotic agents.
- Topical corticosteroids.
- Discontinue miotics.

#### Laser

- Disruption of the anterior hyaloid face using argon or Nd:YAG capsulotomy.

#### Surgical

- Any procedure to create a defect in the anterior hyaloid face.
- Aspiration of vitreous: pars plana or anterior vitrectomy.

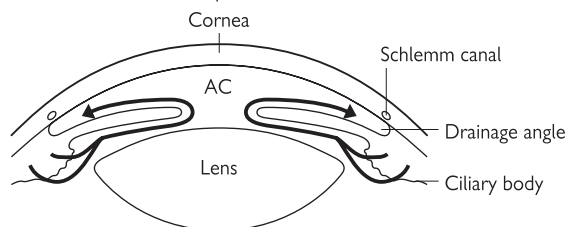
#### Follow-up

- Initial follow-up to ensure resolution.
- Prophylaxis for malignant glaucoma should be instigated in the fellow eye with cycloplegics and osmotic agents if any surgery is planned.

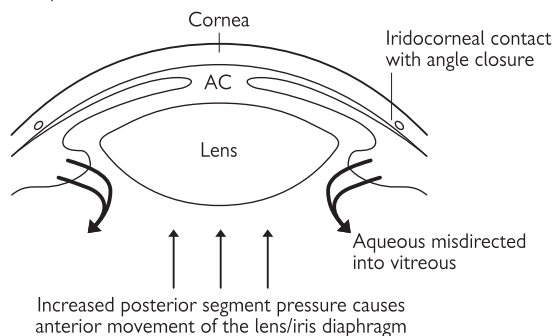
#### Prognosis

Poor: the term 'malignant' glaucoma was coined because of the poor prognosis and unsatisfactory response to medical treatment.

## 1 Normal direction of aqueous flow



## 2 Aqueous misdirection

**Key features:**

Shallow AC (central and peripheral)  
 No iris bombé  
 High IOP

**Fig. 7.27** Diagram showing the mechanism of malignant glaucoma. Key features: shallow anterior chamber (central and peripheral), no iris bombé, and high IOP.

## 7.18 Iridocorneal endothelial syndrome and iridocorneal dysgenesis

### Iridocorneal endothelial syndrome

Iridocorneal endothelial (ICE) syndrome or primary proliferative endotheliopathy consists of three separate entities with overlapping features: essential iris atrophy, Chandler's syndrome, and Cogan–Reese syndrome. These have in common an abnormal corneal endothelial cell layer which forms a membrane over the angle structures and iris initially causing a secondary open-angle glaucoma but eventually leading to a secondary angle closure glaucoma due to contraction of the membrane.

#### Pathophysiology

Endothelial cells in ICE syndrome have been found to be morphologically similar to epithelial cells, thus suggesting an embryological ectopia or metaplastic process. HSV has been implicated as its DNA has been found in a large number of these corneal specimens by PCR; however, a definite link is not proven. The pathological membrane complex formed migrates over the drainage angle, causing obstruction and secondary angle closure with formation of PAS. Tractional forces may cause distortion of the iris in opposing quadrants. Corneal opacity/oedema is also a feature due to increased IOP and reduced endothelial cell count.

#### Prevalence

- Rare; exact incidence is not known.
- Approximately 50% of ICE syndrome patients develop glaucoma.
- The Cogan–Reese variant is at greatest risk of developing raised IOP.

#### Risk factors

- Age (20–50 years).
- Sex (female).
- History of HSV.
- Race (Caucasian).

#### Clinical evaluation

##### History

- Asymptomatic in early stages (often incidental finding).
- Later:
  - decreased vision,
  - ocular pain,
  - red eye,
  - iris abnormalities.

##### Examination

The three entities are based on signs present in early stages of the disease. During the later stages, they can be indistinguishable. Signs are always unilateral: examination of the other eye clinches the diagnosis.

Common signs:

- corectopia (distortion of pupil),
- pseudopolycoria ('extra' pupils),
- iris atrophy (moth-eaten iris of varying severity),
- 'hammered silver' appearance to endothelium,
- broad-based PAS.

#### Chandler's syndrome (most common)

- Characterized by severe corneal changes.
- Blurred vision and haloes.

#### Progressive iris atrophy

- Characterized by severe iris changes.
- Corectopia, pseudopolycoria, atrophy, and ectropion uveae.

### Cogan–Reese (iris naevus) syndrome

- Characterized by the presence of iris nodules.
- Sheet of membrane-like material covering the iris.
- Naevi caused by iris tissue protruding through.
- Iris has a flattened appearance.

#### Management

- Topical therapy:
  - as for POAG (ineffective in majority),
  - hypertonic saline (corneal oedema).
- Trabeculectomy plus antimetabolite filtration site must be in area free of membrane, aberrant tissue, or PAS:
  - high failure rate due to membrane growing over sclerostomy,
  - greater degree of postoperative inflammation.
- Glaucoma drainage devices.
- Cyclodestructive therapy.
- Penetrating keratoplasty for corneal changes.

Argon laser trabeculoplasty is not recommended as it increases the formation of PAS.

#### Follow-up

To assess corneal clarity and development of glaucoma.

#### Prognosis

Poor due to resistance to therapy. The saving grace of this eventually blinding disorder is that it is unilateral.

## Aniridia

### Pathophysiology

It is a bilateral, congenital condition due to mutations in the PAX6 gene on chromosome 11.

### Classification

- AN1: familial aniridia (autosomal dominant), no systemic associations; most common variant.
- AN2: non-familial (sporadic); associated with Wilm's tumour (nephroblastoma) in 30% before the age of 5. Association higher (50%) with genitourinary malformations and mental retardation.
- AN3: Gillespie syndrome autosomal recessive with mental retardation and cerebellar ataxia.

### Clinical features

- There is a spectrum of disease from complete absence of the iris, partial absence, mild stromal hypoplasia (transillumination defects), to a normal looking pupil. Even in total clinical aniridia a peripheral frill of iris is seen with gonioscopy.
- May present at birth with absence of iris (large pupil/prominent red reflex, nystagmus) or later in life with keratopathy.
- Aniridic keratopathy: secondary to stem cell failure, results in progressive conjunctivalization and vascularization of cornea, eventually leading to subepithelial fibrosis and stromal scarring. This causes recurrent erosions, corneal ulcers, and pain.
- Other features include photophobia, reduced vision, nystagmus, glaucoma (synechial angle closure or trabecular meshwork abnormalities), iris defects, cataracts (including superior subluxation), and foveal and optic-nerve hypoplasia.

### Investigations

- Corneal impression cytology (conjunctival phenotype in epithelium with the presence of goblet cells).
- Testing for mutation of the PAX6 gene.

**Differential diagnosis**

- Loss of iris secondary to trauma,
- Stem cell failure due to chemical/thermal injury, Stevens–Johnson syndrome, ocular cicatricial pemphigoid, contact lens, surgery.

**Treatment**

- Conservative management: for example, goggles, wide-brimmed hat, lubricants, painted contact lens, tarsorrhaphy, and bandage contact lens in the early stages.
- Treat glaucoma medically (usually inadequate in most cases). Surgery may be required often in the form of glaucoma drainage device insertion. Cycloablation may be necessary.
- In the late stages of stem cell failure keratolimbal graft/stem cell transplantation with/without penetrating graft may be needed to restore vision.
- Cataract extraction can be combined with implantation of iris prosthesis or painted IOL to reduce the photophobia.

**Axenfeld–Riegers syndrome****Pathophysiology**

Represents a spectrum of anterior segment mal-development of the angle with or without iris and systemic abnormalities.

Genetics: it is typically autosomal dominant with mutations described in the *PITX2* gene (chromosome 4q25), *FOXC1* gene (chromosome 6p25), and on chromosome 13q.

**Clinical features****Corneal**

The hallmark is the presence of a white line in the peripheral cornea (partial or 360°) due to an anteriorly displaced Schwalbe's line (seen on slit lamp examination in most or by gonioscopy) called posterior embryotoxon.

NB: Posterior embryotoxon is seen in 15% of normal eyes and is not associated with glaucoma if present in isolation.

**Angle abnormalities**

Iris processes/bands/sheets extend across the angle to the trabecular meshwork or even up to the posterior embryotoxon. High insertion of iris can obscure the scleral spur.

**Iris abnormalities**

May be absent. Include iris hypoplasia with easily visible iris sphincter, corectopia (displaced pupil), and polycoria (iris holes).

**Glaucoma**

There is a 50% risk of raised IOP with possible subsequent glaucoma. Usually develops in second or third decade (very rarely in infancy). Patients with high iris insertion are more prone to developing glaucoma.

**Non-ocular features**

- *Facial*: maxillary hypoplasia, broad nasal bridge, telecanthus, prominent lower lip, micro/hypodontia.
- *CNS*: mental retardation, empty sella syndrome.
- *Genital*: hypospadias.
- *Endocrine*: growth hormone deficiency.

**Treatment**

- Consider physician referral.
- Treat glaucoma as in POAG: medically initially then filtering surgery (trabeculectomy/glaucoma drainage devices). Laser trabeculoplasty not possible/contraindicated due to angle abnormalities.

**Peter's anomaly****Pathophysiology**

Rare disease in which patients are born with opaque cornea.

**Genetics**

Most cases are sporadic (a few are autosomal recessive and autosomal dominant). Mutations described include *PAX6* (gene for aniridia), *PITX2* and *FOXC1* (genes for Axenfeld–Riegers syndrome), and *CYP11B1* (gene for primary congenital glaucoma).

**Clinical features**

Bilateral in 80%.

**Cornea**

Central white opacity of variable density, iridocorneal adhesions at margin of opacity and posterior corneal defect involving posterior stroma/Descemet's membrane and endothelium.

**Lens**

Cataract with corneal–lens touch or even with lens in normal position.

**Glaucoma**

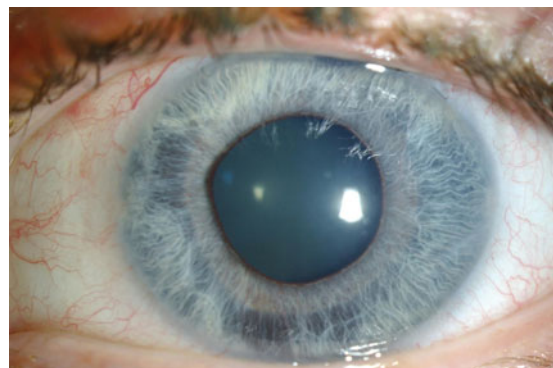
Occurs in 50–70%. Mostly infantile but can develop at any time of life. Most have a normal trabecular meshwork.

**Other ocular abnormalities**

- Microphthalmia.
- Persistent primary hyperplastic vitreous.
- Systemic abnormalities (developmental delay, congenital heart disease, CNS, genitourinary, etc.) have been described.

**Treatment**

- Main problem is amblyopia due to opaque cornea.
- Keratoplasty is required but has poor prognosis.
- Manage glaucoma medically or with surgery: difficult to control.



**Fig. 7.28** Colour anterior segment photograph showing mild corectopia in ICE syndrome.



## 7.19 Ocular hypotensive agents I

### Prostaglandin analogues

#### Mechanism of action

Prostaglandin  $F_2$ - $\alpha$  agonists increase extracellular matrix turnover in the ciliary body face, thus increasing uveoscleral outflow. They often achieve IOP reduction in an excess of 30% of cases.

#### Side effects

##### Local

- Stinging.
- Tearing.
- Hyperaemia.
- Darkening of the iris.
- Thicker and longer lashes.
- Cystoid macular oedema.
- Anterior uveitis.

##### Systemic

- Upper-respiratory-tract infection.
- Backache.
- Chest pain.
- Myalgia.
- Exacerbation of angina and new shortness of breath.

#### Contraindications

- Pregnancy.
- Inflammatory conditions including post-surgical (aphakic and pseudophakic with posterior capsule breaks at greatest risk).

#### Preparations

- Latanoprost (Xalatan): available as 0.005%.
- Travoprost (Travatan): available as 0.004%.
- Bimatoprost (Lumigan): available as 0.03%.
- Generally used as a first-line therapy due to proven efficacy and tolerability.
- All have a duration of action of 24 hours.
- All have once-daily dosing (usually at night).

### $\beta$ -Blockers

#### Mechanism of action

$\beta$ -Adrenergic antagonists block the  $\beta$  receptors of the ciliary body, thus decreasing aqueous production. They can be non-selective, acting on both  $\beta$ -1 and  $\beta$ -2 receptors, or cardioselective and thus more potent at  $\beta$ -1 receptors.

#### Side effects

- Most occur within the first week.

##### Local

- Stinging.
- Dry eye.
- Hyperaemia.

##### Systemic

- Bradycardia or heart block.
- Bronchospasm.
- Fatigue.
- Mood change.
- Impotence.

#### Contraindications

- Asthma, chronic obstructive pulmonary disease, bradycardia (resting heart rate of less than 60bpm), heart block, congestive cardiac failure.
- Patients already on systemic  $\beta$ -blockade or calcium-channel blockers should be monitored for potential additive toxicity.

#### Preparations

##### Timolol maleate (Timoptol)

- Non-selective.
- Majority achieve 20% IOP reduction but 10% of the population are unresponsive.
- Effectiveness can diminish in the first 2 weeks (short-term escape).
- Further diminishing efficacy may occur within 3 months (long-term drift).
- Onset of action within 30 minutes, peak at 2 hours, duration up to 24 hours.
- Available as 0.25 and 0.5% (similar efficacy, therefore 0.25% should be first choice).
- Twice-daily dosing.

##### Timolol LA

- Long-acting variant.
- Changes from liquid to gel-like state when instilled.
- Once-daily dosing (gives 24 hour coverage).
- Available as 0.25 and 0.5%.
- Transient blurring for up to 5 minutes often occurs.

##### Levobunolol (Betagan)

- Non-selective.
- Onset of action within 1 hour; peak at 2–6 hours, duration up to 24 hours.
- Available as 0.25 and 0.5%.
- 0.5% once-daily dosing.
- 0.25% twice-daily dosing.

##### Betaxolol (Betoptic)

- Selective  $\beta$ -1 blocker.
- Use with great care in patients with respiratory conditions.
- Cardiac patients still contraindicated.
- Onset of action within 30 minutes, peak at 2 hours, duration up to 12 hours.
- Available as 0.5%.
- Twice-daily dosing.

### $\alpha$ -Agonists

#### Mechanism of action

$\alpha$ 2-Adrenergic agonists act on  $\alpha$  receptors in the ciliary body to inhibit aqueous secretion.

#### Side effects

##### Local

- Irritation.
- Allergy.
- Dry eye.

**Systemic:**

- Dry mouth.
- Hypotension.
- Sedation.

**Contraindications**

- Monoamine oxidase inhibitor use, children under 2 years (apnoea risk).

**Preparations****Brimonidine (Alphagan)**

- Also acts to increase uveoscleral outflow.
- Animal studies suggest that there are also neuroprotective properties.
- Peak effect at 2 hours, duration of action 12 hours.
- Available as 0.2%.
- Twice-daily dosing.
- Allergy can occur in 10% on long-term therapy, presenting sometimes months later.

**Apraclonidine (Iopidine)**

- Onset of action within 1 hour, duration of at least 2 hours.
- Available as 0.5% (27% IOP reduction) or 1% (37% IOP reduction).
- Causes allergic conjunctivitis in 9% within 3 months and 50% long term.
- Exhibits tachyphylaxis (rapidly decreased therapeutic response following initial doses).
- Its main use is thus in the prevention of IOP spikes in the short term, for example after anterior segment laser and in angle-closure glaucoma patients. It also plays a role in those already on maximal medical therapy who are unsuitable for surgery.

**Cholinergic agents****Mechanism of action**

Cholinergics act on muscarinic receptors of the ciliary muscle. This causes the ciliary body to contract and pull on the trabecular meshwork, thus increasing outflow.

**Side effects****Local**

- Brow ache.
- Accommodative spasm.
- Variable myopia.
- Retinal tear/detachment.
- Decreased peripheral and night vision.

**Systemic**

- Gastrointestinal upset.
- Abdominal cramping.
- Salivation.
- Potential heart block.

**Contraindications**

- Peripheral retinal pathology.
- Central media opacity.
- Young age (increased myopic effect),
- Uveitic patients.
- Less effective in patients with damaged trabecular meshworks.

Chronic use can result in permanent miosis (problems with dilated fundoscopy).

**Preparations**

- Pilocarpine.
- Onset of action within 20 minutes, peak at 2 hours, duration up to 6 hours.

- Available as 0.5, 1, 2, 3, and 4%.
- Administered 4 times daily (short duration of action).
- Dosage increased in stepwise increments.
- Maximum concentrations usually 2% for light irides, 4% for brown/dark irides.

**Topical carbonic anhydrase inhibitors****Mechanism of action**

- Inhibition of the enzyme carbonic anhydrase decreases aqueous production in the ciliary body.
- Achieves a 20% reduction in IOP.

**Side effects****Local**

- Mild hyperemia.
- Stinging.
- Bitter taste.

**Systemic**

- Diuresis.
- Fatigue.
- Gastrointestinal upset.
- Stevens–Johnson syndrome.
- Aplastic anaemia.

**Contraindications**

- Sulphonamide sensitivity.
- Use with caution in corneal decompensation (carbonic anhydrase is important enzyme in the corneal endothelial pump).

**Preparations****Dorzolamide (Trusopt)**

- Available as 2%.
- Dose 3 times daily alone, or twice daily with concurrent  $\beta$ -blocker use.

**Brinzolamide (Azopt)**

- Available as 1%.
- Twice-daily dosing.
- Suspension form allows drug to be buffered at physiological pH (therefore more comfortable with fewer allergic reactions).

## 7.20 Ocular hypotensive agents II

### Systemic carbonic anhydrase inhibitors

#### Mechanism of action

- As for topical treatment.
- Oral or intravenous administration will also cause dehydration of the vitreous.

#### Side effects

- As for topical carbonic anhydrase inhibitors.
- Additional systemic concerns: hypokalaemia, renal stones, paraesthesia (tingling of hands and feet), nausea, cramps, malaise, depression, impotence

#### Contraindications

- Sulphonamide sensitivity.
- Hyponatraemia.
- Hypokalaemia.
- Renal stones.
- Use of thiazide diuretics or digitalis.
- Pregnancy.

#### Preparations

##### Acetazolamide (*Diamox*)

- IOP reduction up to 35%.
- Available as 125 or 250 mg tablets or 250 mg slow-release (SR) capsules orally, or 500 mg vial for use intravenously.
- Dosing 4 times daily for tablets, twice daily for capsules (SR), or stat dosing as required for intravenous use.
- Maximum dosage 1000 mg in 24 hour.

### Hyperosmotic agents

#### Mechanism of action

Dehydrates the vitreous and reduces intraocular volume by increasing plasma osmolality, thereby drawing fluid into the intravascular space.

#### Side effects

- Diuresis, cardiac failure, urinary retention (in men), backache, headache, myocardial infarction, confusion.
- Also, vomiting with glycerin.

#### Contraindications

- Congestive cardiac failure, pre-existing dehydration.
- Also watch for diabetic ketoacidosis with glycerin (broken down to glucose).
- Caution in elderly patients and those with renal disease.
- Only used when rapid reduction is required when IOP is dangerously high.

#### Preparations

##### Glycerin

- Oral agent in 50% solution.
- Needs rapid ingestion to maximally change osmolality.
- Serve mixed with orange juice or over ice to reduce vomiting.

##### Mannitol

- Drug of choice as no penetration into vitreous cavity.
- Dosage 1–2 g/kg of 20% solution given intravenously over 45 minutes.

not be used as first-line therapy and only utilized when the efficacy and tolerability of the individual components have been established.

#### Preparations

##### Cosopt

- 0.5% Timolol and 2% Dorzolamide.
- Twice-daily dosing.

##### Combigan

- 0.5% Timolol and 0.2% Brimonidine.
- Twice-daily dosing.

##### Xalacom/DuoTrav/GanForte

- 0.5% Timolol and Xalatan/Travatan/Lumigan respectively.
- Once-daily dosing (morning or night).

### Topical combination therapy

The use of two drops in one improves patient compliance and decreases the preservative load upon the eye. These agents should

*This page intentionally left blank*

## 7.21 Laser therapy for glaucoma

### Argon laser trabeculoplasty

Argon laser trabeculoplasty involves the application of discrete laser burns to the trabecular meshwork and was demonstrated in the Glaucoma Laser Trial (1990) to be as effective as topical medications for the initial treatment of glaucoma. The mean IOP is lowered by approximately 22% and the incidence of diurnal IOP spikes is also reduced. The effectiveness does, however, decrease with time. Approximately 19% fail after 1 year and an additional 10% fail each year thereafter, reaching a 65% failure rate at 5 years.

There are two main theories as to its mode of action: mechanical and cellular. According to the mechanical theory, argon laser trabeculoplasty causes coagulative damage to the trabecular meshwork, resulting in collagen shrinkage and scarring and thus exerting traction on the adjacent trabecular meshwork and opening intertrabecular spaces. The cellular theory suggests that in response to induced coagulative necrosis there is migration of macrophages into the trabecular meshwork which then phagocytose any debris present, thus improving aqueous outflow.

#### Indications

- POAG, pigmentary and pseudoexfoliative glaucoma.
- Most effective in the elderly.
- Ineffective in paediatric and secondary glaucoma.
- Should not be attempted in patients with angle abnormalities.

#### Laser settings

- Vary with different machine models.
- 50 µm spot size, 0.1 second duration, 500–1000 mW power.
- Start with low power setting and increase by 200 mW if reaction is inadequate (heavily pigmented trabecular meshwork requires less power).

#### Method

- Gain patient consent (including advising on failure and complications).
- Instil apraclonidine (iopidine) 1% (to prevent IOP spike).
- Instil topical anaesthetic (e.g. benoxinate).
- Set laser (less energy required for more pigmented trabecular meshwork).
- Position patient.
- Insert gonioscopes at 12 o'clock position (inferior angle is easiest to visualize).
- Identify trabeculoplasty site (anterior border of pigmented trabecular meshwork).
- Focus aiming beam perpendicular to trabecular meshwork (round spot with clear edge).
- Fire laser (success indicated by mild blanching or small bubble).
- Place 50 equally spaced shots over 180° (or entire circumference with 100 burns).
- Instil further apraclonidine 1%.
- Document procedure in patient notes and local laser logbook.

#### Post-procedure

- Prescribe topical steroid QDS for 1 week.
- Continue usual glaucoma medication.
- Arrange follow-up in 2–6 weeks.
- Taper glaucoma medication if IOP reduction is satisfactory.
- If IOP reduction is inadequate after 180° treatment, consider argon laser trabeculoplasty for remaining superior 180°.
- Retreatment after 360° argon laser trabeculoplasty is unlikely to be beneficial and may even result in further loss of IOP control.

#### Complications

- Peripheral anterior synechiae: if burns applied too posteriorly or energy too high.
- Bleeding: if blood vessels inadvertently treated (apply pressure with gonioscopes).
- IOP spike.
- Anterior uveitis.

### Selective laser trabeculoplasty

This is a relatively new procedure which is employed in a similar manner as argon laser trabeculoplasty but uses a Q-switched, frequency-doubled Nd:YAG laser with a frequency of 532 nm. A pulse duration of 3 nanoseconds is used (argon laser trabeculoplasty is 0.1 seconds).

Theoretically the low power and short duration of this laser can selectively target pigmented trabecular meshwork cells as the energy is deposited more rapidly than it can diffuse away, thus sparing adjacent tissues from collateral thermal damage. The exact mechanism of action is unknown but appears to be cellular rather than mechanical.

Initial results show it to be as effective as argon laser trabeculoplasty with the added benefit that retreatment is possible.

### Cyclodiode laser

Cyclodiode procedures lower IOP by destroying part of the ciliary body, thus reducing aqueous inflow. The most common method at present is that of trans-scleral diode laser.

The success rate is dependent on the type of glaucoma treated and the procedure often has to be repeated.

#### Indications

- Uncontrolled end-stage secondary glaucoma mainly for pain relief.
- Patients with multiple previous failed glaucoma procedures.
- May be considered as a primary procedure in certain eyes where surgery is inappropriate.
- To reduce IOP as a temporizing measure before undertaking surgery.

#### Method

- Gain patient consent (including advising on failure/retreatment and complications).
- Administer sub-Tenon or peribulbar anaesthetic.
- Patient is laid flat and eyelid speculum inserted.
- Typical settings for laser are 1.5–2 second duration and 1500–2000 mW power.
- Ensure normal anatomy: use transillumination through pupil to confirm dark area of ciliary body 0.5–2 mm from limbus. This is an important step as abnormal eyes or eyes that have undergone multiple previous surgeries may have abnormally placed ciliary bodies or even areas where the ciliary body is absent. Naturally such areas should not be treated.
- Place the diode probe against the globe with the heel to limbus.
- Place burns circumferentially using five shots per quadrant, avoiding 3 and 9 o'clock (positions of posterior ciliary nerves).
- Treat 270°, sparing one quadrant (total of 15 burns).

#### Post-procedure

- Prescribe topical steroid (e.g. dexamethasone 0.1%) QDS for 1 week.
- Continue all usual glaucoma medication.
- Arrange follow-up in 1–2 weeks.



## Complications

- Conjunctival burns.
- Localized scleral thinning.
- Corneal decompensation.
- Anterior uveitis.
- Bleeding (hyphema or vitreous haemorrhage).
- Hypotony.
- Phthisis bulbi.
- Malignant glaucoma.
- Cataract.
- Retinal or choroidal detachment.
- Sympathetic ophthalmitis.

## Peripheral iridotomy

Peripheral iridotomy involves the formation of a conduit for aqueous fluid flow via a laser-induced puncture within the peripheral iris substance. This allows for the free passage of aqueous between the posterior and anterior chambers. It is usually performed using the Nd:YAG laser. The position of the iridotomy should be within the superior iris so it is covered by the upper lid to minimize risk of monocular diplopia, as peripheral as possible to prevent damage to the lens and within an iris crypt to minimize the laser energy required.

### Indications

#### Treatment

- Primary angle closure glaucoma (acute, intermittent, or chronic).
- Secondary angle closure (pupil-block mechanism).

#### Prophylaxis

- Occludable angles.
- Fellow eye in angle closure.

### Laser settings

- Vary with different machine models.
- Generally it is preferable to use a single burst of higher energy to create a hole in the iris. Only one pulse per burst is required: multiple pulses are ineffective.
- Powers of between 4 and 8mJ are effective (depending on the thickness of iris and the pigmentation).

### Method

- Gain patient consent (including advising on risks of failure/need for retreatment; also see complications below).
- Gonioscopy should be carried out before the procedure by the person undertaking the laser and the findings documented in the clinical notes.
- Instil pilocarpine 2% (miosis will 'unfold' peripheral iris).
- Instil apraclonidine (iopidine) 1% (to prevent IOP spike).
- Instil topical anaesthetic (e.g. benoxinate).
- Set laser (thin blue irides low power; thick brown irides higher power).
- Position patient.
- Insert contact lens, such as an Abraham iridotomy lens, using a coupling agent (e.g. viscotears gel).
- Select suitable site (superior iris, peripheral, within crypt, ideally between 11 and 1 o'clock).
- Angle laser beam so it is non-perpendicular (reduces chance of macular burn).
- Focus and fire laser (look for and document presence of 'pigment gush': this indicates successful penetration). Instil further apraclonidine 1%.

- Gonioscopy should be repeated to detect any deepening in the angle and to exclude residual narrowing due to phacomorphic or plateau iris components or significant PAS.
- Document procedure and gonioscopic findings in patient notes and local laser logbook.

### Pre-treatment with argon laser

- Should be considered for patients with thick brown irides.
- Low-power argon is first applied to create a circular area of pitted iris stroma followed by high-power argon to form a punched-out crater at the level of the radial muscle fibres.
- Iridotomy is then completed with low-energy Nd:YAG laser.

### Post-procedure

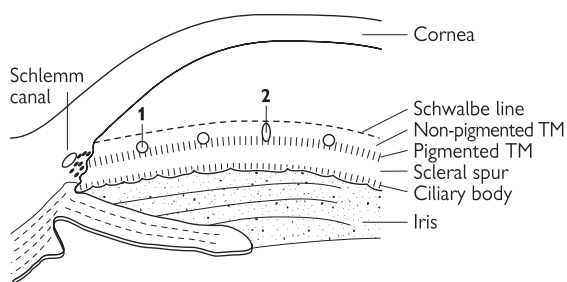
- Prescribe topical steroid (e.g. dexamethasone 0.1%) 2 hourly for 1 week to limit inflammatory response, which could lead to a possible increase in PAS if the residual angle is narrow.
- Arrange follow-up for 1 week to check IOP and assess patency of peripheral iridotomy.

### Complications

- Bleeding: occurs in approx. 50%; apply pressure on lens to stop it if persistent.
- Anterior chamber inflammation: increase topical steroid.
- Increased IOP: tends to be within 1 hour but mild and transient due to use of apraclonidine.
- Corneal burns: increased risk with shallow anterior chamber.
- Lens opacities: can occur at treatment site but tend to be localized and non-progressive.
- Visual effects: if peripheral iridotomy is not sited beneath the upper lid glare and monocular diplopia may ensue.
- Macular damage: theoretical risk if beam is aimed perpendicularly.

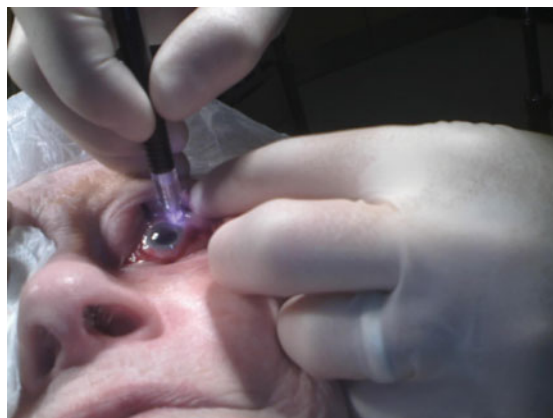
## Argon laser peripheral iridoplasty

- Argon laser is used to shrink peripheral iris to widen the angular approach for plateau iris syndrome. It has also been used as a treatment for *acute* primary angle closure and primary angle closure glaucoma.
- A contact lens (e.g. Abraham) is used to direct laser to the far periphery of the iris where 20–50 burns are applied over 360°.
- Laser settings: 200–500 µm spot size, 0.2–0.5 seconds duration, 200–400 mW power.



Laser is aimed at the junction of pigmented and non-pigmented TM (i.e. the anterior border of pigmented TM).

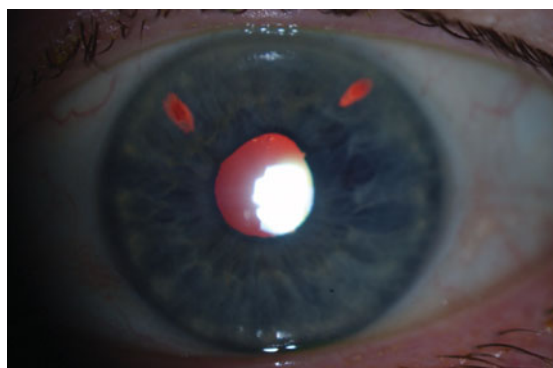**Fig. 7.29** Diagram showing the technique of argon laser trabeculoplasty. Laser is aimed at the junction of pigmented and non-pigmented trabecular meshwork (TM) (i.e. the anterior border of pigmented trabecular meshwork). (1) Evenly spaced, round spots of blanching with clear edges with or without a small bubble is the ideal reaction. (2) Production of an oval spot means the aiming beam is not perpendicular to the TM and thus requires refocusing.



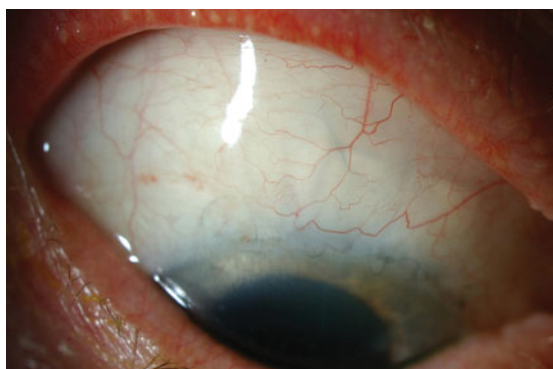**Fig. 7.31** The technique of cyclodiode laser. The probe is placed vertically on the anaesthetized eye with the base of the probe against the limbus.



**Fig. 7.30** Selective laser trabeculoplasty machine.



**Fig. 7.32** Colour anterior segment photograph showing the transillumination defects seen after laser peripheral iridotomies.



**Fig. 7.33** Colour anterior segment photograph showing an eye that has had a trabeculectomy. There is a diffuse, well-vascularized bleb. The scleral flap is visible through the conjunctiva and the loops of three releasable sutures are seen in the peripheral clear cornea. (See section 7.22)

*This page intentionally left blank*

## 7.22 Glaucoma surgery

There are a number of surgical procedures available to lower IOP which should be considered if the patient fails to achieve their target pressure despite maximal medical therapy. The type of surgery selected should be tailored to suit the individual and each has its own specific complications and thus the risk/benefit ratio which should be discussed appropriately.

The most common procedure undertaken currently is that of trabeculectomy with or without adjunctive antifibrotics, which can achieve success rates of 80–90% in phakic POAG.

### Indications

When IOP is not satisfactorily controlled with medications and/or laser, where the latter are contraindicated, or where compliance is a problem.

### Trabeculectomy

The Moorfields Safe Surgery technique has been established to provide a template for safe and effective glaucoma surgery.

A fistula is created, 'guarded' by a superficial scleral flap. This allows aqueous to flow from the anterior chamber to the sub-Tenon space, forming a 'bleb' of fluid which is then absorbed into the episcleral vessels.

There are many different methods and a precise understanding of each variant is unnecessary. One technique is described below (the precise details will vary between specialists).

### Method

1. Traction suture into superior cornea.
2. Fashion a fornix-based conjunctival flap.
3. Clear episcleral tissue and cauterize the proposed flap area.
4. Incise through two-thirds of the scleral thickness to create a rectangular, triangular, or square 'trap door'.
5. Dissect the scleral flap forwards along its posterior and lateral aspects until clear cornea is reached.
6. Perform a superotemporal paracentesis and place an anterior chamber maintainer.
7. Make an incision into the anterior chamber with a keratome.
8. Complete sclerostomy posteriorly using a Kelly punch.
9. Perform peripheral iridectomy.
10. Suture the scleral flap at its posterior corners (fixed, releasable, or adjustable sutures).
11. Adjust the height of the fluid bag attached to the anterior chamber maintainer to titrate flow via the scleral flap.
12. 'Watertight' closure of the conjunctiva.
13. Instil atropine 1%.
14. Inject steroid/antibiotic subconjunctivally.

### Postoperative

- Topical steroid 2 hourly for 2–4 weeks then QDS for further 2 months.
- Topical antibiotic QDS for 1 month.
- Follow-up at 1 day and 1 week thereafter according to the result.

### Augmented trabeculectomy

Adjunctive antifibrotic agents or antimetabolites are used to inhibit the natural healing response, thus helping to prevent scarring and thus failure of the drainage bleb.

Agents include 5-fluorouracil, dose 50mg/ml, which inhibits DNA synthesis and mitomycin C, dose 0.2–0.4mg/ml, which alkylates DNA.

Relative risk factors for scarring include neovascular glaucoma, previous failed trabeculectomy, secondary glaucomas, for example inflammatory, post-traumatic and ICE syndrome, topical hypotensive agent use for over 3 years, previous conjunctival or cataract surgery,

black race, and age under 40 years. NB: some specialists use mitomycin C routinely.

If an augmented trabeculectomy is performed, sponges are soaked in the agent of choice and placed under the conjunctival flap (with or without scleral flap) for 5 minutes (5-fluorouracil) or 1–5 minutes (mitomycin C). Great care should be taken to avoid contact with cornea or the conjunctival wound edge. The area is then thoroughly irrigated with balanced salt solution before completion of the trabeculectomy.

Postoperatively, 5-fluorouracil can also be administered adjacent to the bleb to modify the healing response.

Complications include corneal epithelial defects, postoperative wound leaks, and cystic thin-walled blebs which predispose to chronic hypotony, late-onset bleb leak, and endophthalmitis. But these can largely be avoided by a meticulous technique, for example the Moorfields Safe Surgery system.

### Early postoperative complications

#### Shallow anterior chamber

- Wound leak (low IOP, Seidel positive, peripheral iridotomy patent, bleb poor/flat).
- Ciliary body shutdown (low IOP, Seidel negative, peripheral iridotomy patent, bleb poor/flat).
- Overfiltration (low IOP, Seidel negative, peripheral iridotomy patent, bleb good/large).
- Pupil block (high IOP, Seidel negative, peripheral iridotomy non-patent, bleb flat).
- Malignant glaucoma (high IOP, Seidel negative, peripheral iridotomy patent, bleb flat).
- Suprachoroidal haemorrhage (variable IOP, Seidel negative, peripheral iridotomy patent, bleb variable).

Specific treatment depends on cause but if there is a risk of corneal decompensation due to lenticulo-corneal touch the anterior chamber needs to be reformed urgently (use balanced salt solution, viscoelastic, or gas).

#### Low IOP/hypotony

- IOP less than 8mmHg, shallow anterior chamber, choroidal detachment, suprachoroidal haemorrhage.
- IOP less than 4mmHg, and also hypotonous maculopathy, corneal oedema.
- *Management:* taper or stop topical steroid, apply cycloplegic to prevent shallowing of anterior chamber; consider reformation of anterior chamber and drainage of (usually kissing) choroidal effusion.

#### Wound leak

- Apply bandage contact lens.
- Taper or stop steroids.
- May require suturing.

#### Overfiltration

- Topical atropine to prevent shallowing of anterior chamber.
- Aqueous suppressants to assist spontaneous healing of fistula by temporarily reducing aqueous flow through it.
- Pressure patching or scleral shell.
- Autologous blood injection into bleb.
- Bleb revision with resuturing of sclera flap.

#### Pupil block

- Caused by a non-patent peripheral iridotomy (incomplete or blockage by inflammatory material).
- Nd:YAG laser peripheral iridotomy (new or complete old peripheral iridotomy).

**Suprachoroidal haemorrhage**

Drainage may be necessary as a matter of urgency to preserve sight.

**Filtration failure**

- Vascularized bleb due to episcleral fibrosis.
- Encapsulated bleb (Tenon's cyst): firm, dome-shaped cavity made of hypertrophied Tenon capsule with engorged surface vessels: tends to develop 2–8 weeks postoperatively. May or may not result in raised IOP.
- Obstruction of the sclerostomy or scleral flap.
- *Management:* suture manipulation (removal of releasable sutures, loosening of adjustable sutures, or argon laser lysis of fixed sutures). Needling of encapsulated bleb with or without 5-fluorouracil.

**Blebitis**

- *Symptoms:* red, uncomfortable eye.
- *Signs:* 'milky' bleb.
- *Management:* admit, conjunctival swab, topical ofloxacin/cefuroxime hourly, oral ciprofloxacin 750 mg BD for 5 days.

**Endophthalmitis**

- *Symptoms:* red, painful eye with reduced vision.
- *Signs:* 'milky' bleb, severe anterior uveitis with or without hypopyon, vitritis.
- *Management:* As for blebitis but also requires urgent vitreous tap and intravitreal amikacin/vancomycin.

**Visual loss**

- 'Wipe-out' of visual field.
- Hypotonous maculopathy.

**Late postoperative complications****Filtration failure**

- 10% in 1 year; 25% in 5 years.
- Repeat surgery in the form of mitomycin C trabeculectomy or glaucoma drainage device may be required.

**Subconjunctival fibrosis ('ring of steel')**

- May be amenable to treatment with needling and 5-fluorouracil.

**Leaking bleb**

- Key concern is the development of infective endophthalmitis from organisms on the ocular surface.
- Suturing may not be possible and bleb revision may be required.
- 'Sweating' blebs may then be treated by compression sutures to delimit the leaking area.
- Full-thickness holes require surgical revision (e.g. conjunctival advancement, free patch autograft, or sclera allograft patching).

**Visual loss**

- Surgically induced cataract.

**Bleb dysesthesia**

- 10% risk.
- May require bleb revision.

**Non-penetrating surgery**

This is a relatively new and evolving technique. Two scleral flaps are fashioned and the deep flap excised to leave a thin membrane consisting of trabecular meshwork/Descemet's membrane which allows diffusion of aqueous from anterior chamber into subconjunctival space.

More technically challenging than penetrating surgery such as trabeculectomy, and the reduction in IOP is less. Minimizes the risks associated with penetration into the eye.

**Deep sclerectomy**

Descemet's 'window' created as above; results in a shallow filtration bleb.

**Viscocanalostomy**

As above but additionally Schlemm's canal is dilated with high-density viscoelastic and the superficial scleral flap is sutured tightly to minimize bleb formation.

**Drainage implants**

These consist of a silicone tube attached to a posterior episcleral explant and are used to form a direct communication between the anterior chamber and sub-Tenon space. IOP reduction is by passive, pressure-dependent outflow of aqueous and some devices also have regulatory valves. Devices include Molteno, Baerveldt and Ahmed tubes.

The indications and threshold for using these devices is currently being re-evaluated in light of the TVT (Tube vs Trabeculectomy) study in patients who have had previous ocular surgery. It is suggested that we should be using them more often in those with previous conjunctival surgery and even in pseudophakia.

**Indications**

- Uncontrolled glaucoma despite previous surgery.
- Secondary glaucoma where trabeculectomy is likely to fail; for example, neovascular and post-traumatic.
- Presence of severe conjunctival scarring.

**Complications**

- Over-drainage.
- Malposition (endothelial or lenticular touch).
- Erosion/exposure of tube.
- Failure of drainage (blocked tube or encapsulation of bleb over footplate).

**Other surgical procedures for glaucoma****Peripheral iridectomy**

- To relieve pupil block when laser peripheral iridotomy not possible.

**Goniotomy**

- Indicated for primary congenital glaucoma to open the abnormal angle.

**Trabeculotomy**

- Indicated for congenital glaucoma to open Schlemm's canal directly to the anterior chamber.



## 7.23 Case-based discussions



### Case 1 Open-angle glaucoma

Mr Brown, a 49-year-old man, is referred to your outpatient clinic by his optometrist as he was found to have raised IOPs during a routine annual check. He is asymptomatic and has no previous ocular history except mild myopia. He is otherwise well and takes no regular medication. His mother was diagnosed with glaucoma several years ago.

1. What features in the above history are risk factors for the development of glaucoma?

Examination revealed quiet eyes, with deep anterior chambers, open angles on gonioscopy and IOPs of 23 mmHg right, 25 mmHg left on Goldmann applanation tonometry. CCT was 530 µm right and 510 µm left. Dilated funduscopy revealed CDR 0.5 right and 0.7 left.

2. What is the significance of the CCT?
3. Are these CDRs normal?
4. Is there sufficient information to make a diagnosis of glaucoma?

A visual-field test shows there to be an early arcuate scotoma on the left. It is decided to commence treatment with a prostaglandin analogue in the left eye only in the first instance and a review is arranged for 6 weeks' time.

5. What advice would you give the patient about use of the drops?

On his follow-up visit, Mr Brown is happy with the medication and his IOP is 18 mmHg right, 19 mmHg left.

6. What action would you now take?

#### Answers

1. Myopia, a positive family history, and a raised IOP are all risk factors for glaucoma.
2. The CCT may indicate that our IOP readings are artificially low; that is, we are underestimating the true IOP. The Ocular Hypertension Study showed that a thin CCT was an independent risk factor for the development of glaucoma.
3. It is impossible to say whether these CDRs are abnormal or not. The measurement of disc size plays an important part in interpretation of disc cupping. A large disc may have a 'physiological' large cup whereas a small disc may be highly pathological with even a small amount of cupping. The asymmetry between the two sides is an important finding and, assuming that the discs are the same size, the disc with the larger cup may be glaucomatous.
4. No: although the diagnosis can be suspected we need all the available information before making a diagnosis and commencing treatment. We need a visual field before we make a diagnosis. Any visual-field defect should correlate with the disc changes seen.
5. Use the drops every night. Get a repeat prescription before they run out. Be aware that the eyes may be transiently red after starting such treatment; however, this usually settles with persistence. Patients should be warned about the incidence of lash thickening and elongation and the pigmentation changes within the iris. These changes will be more obvious with unioocular treatment.
6. The IOP in the left eye has come down from 25 to 19 mmHg. There appears to be a nice pressure reduction; however, the right eye IOP has also come down from 23 to 18 mmHg. It is important to recognize that there is diurnal variation in IOP. The first clinic appointment may have been in the morning whereas the second attendance may have been in the afternoon. The patient's pressures are lower in the afternoon as part of their normal diurnal IOP fluctuation. Actually the patient has not responded to the medication at all. There is a small but

significant non-response rate to prostaglandin analogues. The drop should be stopped and treatment switched to another class. This is the benefit of a unioocular drug trial.

### Case 2 Angle closure glaucoma

Mrs Smith, a 40-year-old woman, attended Eye Casualty with a 1 day history of blurred vision associated with red eyes, headache, nausea, and photophobia. Examination revealed grossly reduced visual acuity (right 6/60, left hand motion). Both conjunctivae were injected and corneas were cloudy with microcystic oedema. Anterior chambers were shallow and IOP raised at 42 mmHg right and 46 mmHg left. Pupils were fixed and mid-dilated. Gonioscopic and fundal views were not possible due to the corneal oedema.

1. What is the likely diagnosis?
2. What treatment would you initiate?

Mrs Smith is not hypermetropic with a previous medical history of epilepsy for which she was recently started on Topiramate (Topamax) at a dose of 25 mg OD. She has a history of allergy to penicillin, lamotrigine, Tegretol, and phenytoin.

3. What do you think is the likely cause of Mrs Smith's condition?
4. What further investigations would you like to perform to confirm this diagnosis?
5. What medications do you know which may cause a similar reaction?

#### Answers

1. Bilateral acute angle closure.
2. Urgent lowering of IOP: acetazolamide 500 mg intravenous followed by oral acetazolamide 250 mg QDS; g. dexamethasone 1% QDS both eyes; g. timolol 0.5% BD both eyes; g. pilocarpine 2% both eyes (when IOP <40 mmHg).
3. Use of Topiramate (Topamax): secondary angle closure is a known adverse reaction to this medication.
4. B-scan ultrasound of the eyes: forward movement of the lens-iris diaphragm secondary to supraciliary effusion is the pathogenic mechanism.
5. (a) Topical mydriatics/cycloplegics including anticholinergic drops (e.g. atropine, cyclopentolate, hyoscine, and tropicamide) and sympathomimetic drops (e.g. adrenaline, phenylephrine, cocaine, and hydroxyamphetamine).  
(b) Systemic anticholinergics including atropine, amitriptyline, procyclidine, ipratropium, paroxetine, and pizotifen.  
(c) Systemic sympathomimetics including adrenaline, ephedrine, and pseudoephedrine (cough mixture), and oxymetazoline (nasal spray).  
(d) Other medications include levodopa, St John's wort, and trimethoprim.

### Case 3 Steroid glaucoma

Mrs Jones is a 63-year-old woman with type 2 diabetes mellitus who is being followed in the Medical Retina Clinic. She had refractory diabetic macular oedema in her left eye despite three previous sessions of grid laser. An OCT was performed which showed a grossly thickened and oedematous macula. Based on these findings she received 4 mg intravitreal triamcinolone. IOP 60 minutes later was 17 mmHg and a further IOP check 2 weeks later remained normal. Six weeks post-injection she attended a clinic review. She was asymptomatic. Left IOP was 35 mmHg with normal pressure in the fellow eye.

1. What is the likely diagnosis?
2. What risk factors did Mrs Jones have for developing this condition?

Treatment was commenced with g. Cosopt BD and she was reviewed 3 days later. IOP had reduced to 22 mmHg and after a further week of therapy IOP was 18 mmHg.

3. How long would you continue treatment with anti-glaucoma medication?
4. What therapeutic measure would be considered if maximal medical therapy failed?
5. What advice would you give this patient with regard to any future treatment with steroids?

#### Answers

1. Steroid-induced glaucoma.
2. Recent use of intravitreal steroid; age over 40; diabetic.

3. For a minimum period of 3 months, thereafter depending on IOP when tailing off.
4. Trabeculectomy.
5. Avoid it unless there is a clinical need with no alternative, in which case ophthalmic follow-up for IOP monitoring should be arranged. This advice applies to the use of steroid in any form, including drops, inhalers, nasal spray, tablets, intravenous, or even skin cream.

*This page intentionally left blank*

## Chapter 8

# Strabismus and oculomotility

Rebecca Ford and Moneesh Patel

---

### Basic sciences

- 8.1 Anatomy and actions of the extraocular muscles 322
- 8.2 Central control of ocular motility 324

---

### Clinical skills

- 8.3 Patient assessment I: history, general examination, and cover testing 325
- 8.4 Patient assessment II: other methods of measuring ocular deviation 326
- 8.5 Assessment of ocular movements 327
- 8.6 Visual acuity testing 328
- 8.7 Tests of stereopsis and binocular single vision 330
- 8.8 Tests of retinal correspondence and suppression 331
- 8.9 Hess charts 332

---

### Clinical knowledge

- 8.10 Amblyopia 334
- 8.11 Binocular vision and stereopsis 335
- 8.12 Concomitant strabismus I: heterophorias 336
- 8.13 Concomitant strabismus II: esotropia 338
- 8.14 Concomitant strabismus III: exotropia 340
- 8.15 Incomitant strabismus 341
- 8.16 Restrictive ocular motility disorders 342
- 8.17 Complex ocular motility syndromes 343
- 8.18 Vertical deviations 344
- 8.19 Alphabet patterns 346

---

### Practical skills

- 8.20 Principles of strabismus surgery I: indications and types 348
- 8.21 Principles of strabismus surgery II: complications 350
- 8.22 Other procedures in strabismus 351

---

### Case-based discussions

- 8.23 Case 1 Myopic anisometropia 352
- Case 2 Esotropia 352
- Case 3 Infantile esotropia 352
- Case 4 Orbital floor fracture 353
- Case 5 Consecutive exotropia 353

## 8.1 Anatomy and actions of the extraocular muscles

The bony orbit is pyramidal in shape with the medial wall lying parallel to the sagittal plane with medial and lateral walls forming a 45° angle at their apex. The central orbital axis therefore forms an angle of 22.5° with the medial and lateral walls and with the visual axis in primary position.

The eyes make yaw, pitch, and roll movements, which can be considered as rotations around the axes of Fick, with the globe moving up and down around the horizontal X axis, rotating left and right around the vertical Z axis, and making torsional movements around the Y axis which runs from front to back of the eye. The extraocular muscles act in consort to produce eye movements and the action of the individual muscles depend on the position of the eye at the start of muscle contraction.

### Origins

The four recti originate from a ring of condensed orbital fascia at the orbital apex called the *annulus of Zinn*. The superior oblique originates from the back of the roof of the orbit above and medial to the optic foramen. However, it passes through the trochlea anteriorly at the junction of the roof and medial wall of the orbit, and this alters its direction of action and provides its effective origin. The inferior oblique muscle originates from a tubercle on the anterior orbital floor just lateral to the lacrimal fossa.

### Insertions and the spiral of Tillaux

The extraocular muscles insert partially into a fibromuscular pulley system formed by the fascia of the orbit, and partially into sclera. The insertions of the rectus muscles into the sclera form an anti-clockwise spiral known as the *spiral of Tillaux*, with the medial rectus insertion closest to the limbus (5.5 mm behind the limbus), followed by the inferior (6.5 mm), lateral (6.9 mm), and superior (7.7 mm) recti. The obliques insert behind the equator in much more variable positions than the recti. The superior oblique inserts in the posterior upper temporal quadrant of the globe, while the inferior oblique inserts in the lower posterior quadrant close to the macula.

### Nerve supply

The trochlear (fourth) cranial nerve supplies the superior oblique and the abducens (sixth) cranial nerve supplies the lateral rectus. The other extraocular muscles are all innervated by the oculomotor (third) cranial nerve, with the superior division of the third supplying the superior rectus and the inferior division the inferior rectus, medial rectus, and inferior oblique.

### Blood supply

The extraocular muscles all receive their blood supply from the ophthalmic artery. In turn the blood supply of the anterior segment arises from that of the four recti via the anterior ciliary arteries. The lateral rectus provides one anterior ciliary artery and the other recti have two each. Hence surgery to two or more recti, particularly the vertical recti, can lead to anterior segment ischaemia.

### Actions of the extraocular muscles

To achieve a wide range of coordinated eye movements each extraocular muscle must interact with the others in the same eye and the fellow eye in a number of ways, as follows.

- **Synergists** are pairs of muscles in the same eye that move the eye in the same direction; for example, left inferior rectus and left superior oblique for depression of the left eye.
- **Agonist–antagonist pairs** are muscles in the same eye that have opposing actions; for example, for right adduction the right medial rectus is the agonist and the right lateral rectus its antagonist.

- **Yoke muscles** are pairs of muscles in opposite eyes that move the two eyes in the same direction; for example, the right superior rectus is the yoke muscle of the left inferior oblique, both acting in dextro-elevation.

The actions of the individual extraocular muscles are as follows:

#### Medial rectus

- Adducts the eye.
- Synergists are superior rectus and inferior rectus (tertiary actions).
- Antagonist is ipsilateral lateral rectus.
- Yoke muscle is contralateral lateral rectus.

#### Lateral rectus

- Abducts the eye.
- Synergists are superior oblique and inferior oblique (tertiary actions).
- Antagonist is ipsilateral medial rectus.
- Yoke muscle is contralateral medial rectus.

#### Superior rectus

- Primary action is elevation (isolated when the optical and orbital axes are aligned at 23° abduction).
- Secondary actions are intorsion (maximized in adduction and isolated at 67° adduction when the optical and orbital angles are at 90°) and adduction.
- Synergist is inferior oblique (for elevation).
- Antagonist is ipsilateral inferior rectus.
- Yoke muscle is contralateral inferior oblique (for elevation in abduction).

#### Inferior rectus

- Primary action is depression (isolated with eye in 23° abduction).
- Secondary actions are extorsion (isolated in position of 67° of adduction) and adduction.
- Synergist is superior oblique (for depression).
- Antagonist is ipsilateral superior rectus.
- Yoke muscle is contralateral superior oblique (for depression in abduction).

#### Superior oblique

- Primary action is intorsion.
- Secondary actions are depression (isolated at 51° adduction, where the optical axis of the globe is aligned with the direction of pull of the muscle) and abduction.
- Synergist is superior rectus (for intorsion).
- Antagonist is ipsilateral inferior oblique.
- Yoke muscle is contralateral inferior rectus (for depression in abduction). Note that for incyclotorsion the superior oblique and the superior rectus can also be considered yoked to the contralateral inferior oblique and inferior rectus acting for contralateral excyclotorsion.

#### Inferior oblique

- Primary action is extorsion (isolated at 39° abduction).
- Secondary actions are elevation (isolated at 51° adduction) and abduction.
- Synergist is inferior rectus (for extorsion).
- Antagonist is ipsilateral superior oblique.
- Yoke muscle is contralateral superior rectus (for elevation in adduction).



## Types of eye movement and laws of ocular motility

### Ductions

Ductions are monocular movements around the axes of Fick. They comprise abduction (outward), adduction (inward), elevation (upward), depression (downward), intorsion (limbus rotates inwards), and extorsion (limbus rotates outwards.)

### Versions

Versions are conjugate bilateral eye movements; that is, both eyes move in the same direction. They bring the eyes into six cardinal positions: the secondary positions of gaze (dextroversion or right gaze, laevoversion or left gaze, elevation and depression) and the tertiary positions of gaze (dextroelevation and dextrodepression, laeoelevation and laeodepression.) They also include dextrocyclotorsion (upper limbus rotates right) and laeocyclotorsion (upper limbus rotates left).

### Vergences

These are disjunctive bilateral eye movements; that is, the eyes move in opposite directions. They are convergence (eyes turn inwards) and divergence (eyes turn outwards). Divergence movements are fusional, triggered by binasal retinal image disparities. Convergence may be *tonic*, induced by awareness of a near object (*proximal*), *fusional* in response to bitemporal image disparity, or *accommodative* as part of the synkinetic near reflex.

### Sherrington's law of reciprocal innervation

This states that increased innervation to any extraocular muscle is accompanied by decreased innervation to its antagonist; for example, contraction of medial rectus is accompanied by simultaneous relaxation of the ipsilateral lateral rectus. The law applies to versions and vergences.

### Hering's law

This states that during conjugate eye movements the yoke muscles receive equal and simultaneous innervation; for example, contraction of the medial rectus is accompanied by equal contraction of the contralateral lateral rectus. If both muscles are normal equal movements of the two eyes will occur. However, if one muscle is weak the extra drive for this muscle to contract is also applied to the synergist muscle in the other eye, which will tend to overact; for example, a right sixth nerve palsy causing right lateral rectus weakness also tends to cause left medial rectus overaction.

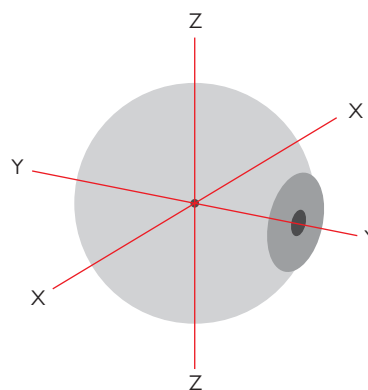


Fig. 8.1 Fick's axes.

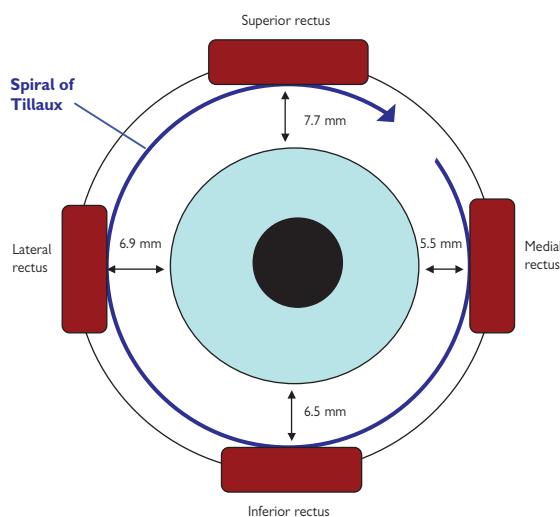


Fig. 8.2 The spiral of Tillaux.

## 8.2 Central control of ocular motility

The ocular muscles, like other muscles, are under both reflex and voluntary control. The frontal eye fields in the frontal cortex are thought to regulate voluntary initiation of eye movements while the occipital cortex and superior colliculus serve as coordinating centres for reflex movements.

Supranuclear ocular motor control can be considered to consist of four separate subsystems:

1. saccadic (fast fixation) system,
2. pursuit (tracking) system,
3. vergence system,
4. vestibular system.

However, these systems feed into a shared final common pathway and may represent different outcomes from a cascade of related sensory-motor functions, rather than acting as truly distinct neural systems.

### Saccadic

Saccades are fast, fixating eye movements which rapidly place the object of interest onto the fovea or switch fixation from one object to another. They must be fast (around 600°/second), brief (30–100 milliseconds) and accurate to support clear vision. They are triggered by an object in the peripheral visual field and may be under voluntary or reflex control.

Initiation of voluntary saccades occurs in the contralateral premotor frontal cortex, from which impulses pass down to the midbrain via the anterior limb of the internal capsule to synapse in the brainstem. However, the saccades themselves are generated in the brainstem reticular formation, with the paramedian pontine reticular formation in the pons predominantly controlling horizontal saccades and the rostral interstitial nuclei of the medial longitudinal fasciculus in the midbrain controlling vertical and torsional movements.

Two types of burst neurons in the brainstem control saccades. Glutamatergic *excitatory* burst neurons trigger saccades and project to the cranial nerve nuclei III, IV, and VI, as well as having projections via the medial longitudinal fasciculus to coordinate with the other eye. *Inhibitory* burst neurons are glycinergic in the horizontal system and GABAergic in the vertical system, and fire to inhibit the antagonist muscles during a saccade (hence they tend to mediate Sherrington's law of reciprocal innervation).

Other structures that influence saccades include the basal ganglia, the superior colliculus, which consists of neurons laid out in a retinotopic map and seems to be involved in selecting a target for fixation, and the cerebellum, which plays a role in steering and stopping saccades and thus influencing their accuracy.

### Pursuit

Pursuit movements are slow, smooth eye movements that maintain fixation on a target once it has been foveated by the saccadic system. They match gaze velocity to target velocity. Smooth pursuit is a continuous movement that slowly rotates the eyes to compensate for motion of the viewed object, minimizing blur that might otherwise compromise visual acuity. The major stimulus for pursuit movements is movement of the image near the fovea. They have faster latency than saccades (125 milliseconds) but the velocity is much slower, at 20–70°/second.

Pursuit movements are initiated from the occipital striate cortex, which receives input from the lateral geniculate nucleus. The cortex projects via the dorsolateral pontine nuclei to the flocculus and ventral paraflocculus of the cerebellum and then to the motor nuclei of cranial nerves III, IV, and VI.

### Vergence

These are smooth disconjugate movements of convergence and divergence, meaning that one eye moves independently of the other to maintain fixation and fusion. The stimulus is target displacement or motion along the visual Z axis (toward or away from the observer).

The higher control areas for the generation of vergence eye movements are poorly understood. However, vergence movements may take the form of saccadic or pursuit movements. Therefore, cortical areas involved in these movements may be responsible. They have a latency of about 160 milliseconds and a velocity of 20°/second.

### Vestibular eye movements

Vestibular movements compensate for changes in head and body position allowing fixation to be maintained despite head and body movement. They are conjugate, smooth movements with a latency of 10–100 milliseconds and a peak velocity of 300°/second.

Head movement stimulates the vestibulo-ocular response via inputs from the:

- semicircular canals, with output from the horizontal canals producing lateral eye movements, the posterior canals producing vertical movements, and the anterior canals producing rotary movements;
- neck proprioceptors.

Afferent fibres synapse in the vestibular nuclei and then pass to the third, fourth, and sixth nerve nuclei.

## 8.3 Patient assessment I: history, general examination, and cover testing

### History

A careful history is crucial for appropriate diagnosis and management of strabismus. In particular, enquire about the following aspects.

- **Duration/age of onset:** this can give an indication of the nature of the strabismus.
- **Variability:** intermittent deviations suggest some degree of binocularity. Variation with near and distance fixation suggests an accommodative element or convergence disorder.
- **Laterality:** a constant squint with one eye indicates high risk of amblyopia in a child; alternating fixation suggests equal acuities.
- **Diplopia:**
  - constant or intermittent?
  - monocular or binocular?
  - horizontal, vertical, or torsional?
  - exacerbated by particular positions of gaze?
- **Previous treatment:** including spectacles, patching, and surgery.
- **Medical history.**
- **Family history.**
- In adults, occupation, hobbies, and driving history may all have a bearing on decisions about strabismus management.
- In children, birth and developmental history are important.

### General examination

A number of general examinations should be made to supplement the more specific strabismus examinations:

- **Observation:** for abnormal head posture, facial and orbital abnormalities, etc.
- **Visual acuity.**
- **Refraction:** to identify any accommodative or ametropic strabismic drive.
- **Fundoscopy:** this is mandatory to identify any underlying pathology; for example, macular scars, optic nerve hypoplasia, and retinoblastoma. Cycloplegic refraction and fundoscopy may need to be performed at the end of the examination when drops can be instilled, but must not be forgotten.

### Examination for ocular deviation: cover tests

These are accurate and objective tests of ocular deviation. They should be performed with near and distance fixation and with and without any spectacle correction. They require an attentive patient who can maintain fixation, and give information, including:

- presence of any heterophoria or heterotropia,
- size of deviation,
- effect of accommodation.

Cover tests are most often performed in the primary position, but in incomitant squints it may be helpful to use it to assess the deviation in other positions of gaze.

Orthoptists are expert in identifying and measuring ocular deviations, but ophthalmology trainees should learn to perform and interpret cover tests.

#### Cover-uncover test

This has two elements.

#### Cover test

This test looks for *manifest* deviations. One eye is covered with an opaque occluder and the *other* eye is observed. If the uncovered eye moves to take up fixation, a manifest deviation is present in that eye.

- **Temporal** movement indicates an *esotropia*.
- **Nasal** movement indicates an *exotropia*.
- **Downward** movement indicates a *hypertropia*.
- **Upward** deviation indicates a *hypotropia*.

If no movement occurs, there is either no manifest deviation or there is eccentric fixation.

#### Uncover test

This test looks for *latent* deviation. One eye is covered and then the *same* eye observed as the cover is removed for any corrective movement.

- **Temporal** movement indicates an *esophoria*.
- **Nasal** movement indicates an *exophoria*.
- **Downward** movement indicates a *hyperphoria*.
- **Upward** deviation indicates a *hypophoria*.

#### Alternate cover test

This dissociates the eye to reveal the full deviation (phoria plus tropia). The cover is placed over each eye in turn at about 2-second intervals and movement of the eye being uncovered noted as the cover moves to the other eye. Patients with heterophoria may break down to a manifest deviation after dissociation during this test.

Dissociated vertical deviation (DVD) and manifest latent nystagmus may also become apparent during cover testing.

#### Prism cover test

This is used to measure the total angle of deviation, and is usually performed with fixation at 0.33m, 6m, and far distance. The alternate cover test is performed and prisms of increasing power placed in front of one eye until the deviation is neutralized. The end point occurs when no further movement of the uncovered eye occurs. To neutralize a deviation the apex of the prism should point in the direction of the deviation.

- For *esotropia* the prisms are held *base-out*.
- For *exotropia* they are held *base-in*.
- For *hypertropia* they are held *base-down*.
- For *hypotropia* they are held *base-up*.

## 8.4 Patient assessment II: other methods of measuring ocular deviation

Various ways of measuring ocular deviations are available in addition to the prism cover test, and these can be divided into objective and subjective tests.

### Objective

- Hirschberg test.
- Prism reflection test.
- Krimsky test.
- Synoptophore.

### Subjective

- Maddox rod.
- Maddox wing.
- Synoptophore.

### Hirschberg test (corneal light reflexes)

This is an objective test that can give an estimate of the angle of a squint in small children who are uncooperative or have poor fixation. A penlight is shone at the eyes, and when the child views the light, the corneal light reflex should be in the centre of the fixing pupil. If both reflexes are centred and symmetrical then no deviation is present. In a manifest deviation, the distance of the light reflex from the centre of the pupil of the deviating eye gives an idea of the size of the strabismus, with each 1 mm of deviation equivalent to  $15\Delta$  in adults and  $20\text{--}22\Delta$  in children.

As a rough guide, if the corneal reflex falls at the pupil margin the deviation is  $20\text{--}30\Delta$ , and if it falls at the limbus the deviation is about  $90\Delta$ .

### Prism reflection test

In this test, prisms are placed over the deviating eye until the corneal reflexes appear straight, giving an approximate magnitude of the squint.

### Krimsky test

This is similar to the prism reflection test, but the prisms are placed over the fixing eye and the eye actually moves to take up fixation. When the appropriate prism neutralizes the deviation, the corneal light reflexes appear symmetrical and there is no fixation movement.

### Maddox rod

The Maddox rod is a subjective dissimilar image test used to measure the angle of a heterophoria, provided normal retinal correspondence is present. The test should be performed with and without spectacles at 0.33 and 6 m, and with each eye fixating. It consists of a series of fused cylindrical red glass rods, mounted in a trial lens or handheld frame. When placed over one eye it converts the appearance of a viewed white spot of light into a red streak. The streak is at  $90^\circ$  to the long axis of the rods; that is, when the rods are held horizontally the streak will be vertical. The Maddox Rod effectively dissociates the eyes since dissimilar images are presented to the eyes, removing the stimulus to fuse.

#### To assess horizontal heterophorias with the Maddox rod

The rod is placed horizontally in front of the right eye. The patient is asked to fixate on a distant spot of white light. They should see a red line and a white spot. If there is no phoria the line will pass

straight through the spot. If the line is to the left of the spot (crossed) there is an exophoria, and to the right (uncrossed) there is an esophoria. The phoria is then quantified by finding the prism required to neutralize it.

#### To assess vertical heterophorias with the Maddox rod

The rod is rotated vertically and the procedure repeated to identify any vertical heterophoria. If the line appears below the spot there is a hyperphoria and vice versa. This is again quantified by neutralizing with prisms.

### Maddox wing

This is another dissimilar image method of measuring heterophorias in the presence of normal retinal correspondence. The device dissociates the eyes for near fixation (0.33 m). The patient (wearing their usual reading correction) looks through the apertures and a septum dissociates the eyes so that the left sees a vertical and horizontal numerical scale and the right sees a white vertical and red horizontal. Horizontal deviation is measured by asking the patient to which number the white arrow points; an even number indicates an exotropia and an odd number an esotropia. Similarly, the number indicated by the red arrow indicates a vertical deviation.

Cyclophoria can also be assessed with the Maddox wing. The patient is asked whether the red arrow is parallel to the white line of numbers. If it is not, it can be moved until parallel and the amount of torsion in degrees read from a scale.

### The synoptophore

This is a haploscopic device in which the two eyes are dissociated so that each eye views a picture on a different slide on a plane mirror. The eyepieces contain +6.5 D lenses to mimic distance viewing. There are various slides to test aspects of simultaneous perception, fusion, and stereopsis.

A full discussion of the synoptophore is outside the scope of this text, but its uses include:

- measurement of interpupillary distance,
- measurement of angle of deviation,
- assessment of retinal correspondence, simultaneous perception, and stereoacuity,
- assessment of anisokonia,
- measurement of angle kappa (the angle between the pupillary and optical axes).

## 8.5 Assessment of extraocular movements

Once any deviation in primary position has been noted using the cover tests (and measured if desired), extraocular movements should be examined.

### Versions

Versions are tested with both eyes open in the eight main diagnostic positions of gaze (the six cardinal positions (see section 8.1), plus up- and downgaze, for example to look for A and V patterns). They are usually assessed by asking the patient to follow a visual target while keeping the head still. This examines smooth pursuit movements. Saccades can be examined by asking the patient to move fixation rapidly from one given target to another. Versions can also be elicited voluntarily, acoustically, or by doll's head movements.

### Ductions

Ductions are assessed with the other eye occluded, and should be examined if versions are limited in any direction. They are often graded from 0 (normal) through -1 to -3 (reduced) to -4 (no movement in that direction).

### Convergence

The near point of convergence can be examined, and acts as an indicator of the strength of a patient's binocular single vision (BSV). A fixation target is placed about 40 cm in front of the patient. The patient is instructed to keep looking at the target as it is moved slowly towards them, and to indicate when it becomes blurred, jumps, or appears double. The examiner observes for when convergence breaks and one of the eyes diverges again. The normal near point of convergence is around 6 cm. The RAF rule can be used for more accurate measurement of the near point of convergence.

### AC/A ratio

It may be valuable in patients with esotropias and exotropias that differ with near and distance fixation to measure the accommodative convergence/accommodation ratio (AC/A ratio). This is a measure of the amount of convergence induced (in prism dioptres) by 1D of accommodation. This ratio remains fixed for a given individual throughout their life unless altered by treatments such as surgery, and a normal range is 2:1 to 4:1.

AC/A ratio may be calculated by a number of methods.

- *Gradient method:* this method can be performed with either near or distance fixation. It is quite easy to perform and more accurate than the heterophoric method. With near fixation, a prism cover test is performed and then repeated with +3 lenses over both eyes to reduce accommodation. For distance, a prism cover test (PCT) is performed with and without -3 lenses to induce accommodation. The AC/A is then calculated by the formula:

$AC/A = (PCT \text{ with accommodation} - PCT \text{ without accommodation}) / \text{amount of accommodation exerted, i.e. 3D}$

- *Heterophoric method:* in this method, a PCT is performed with near and distance fixation. The interpupillary diameter (IPD; in cm) must be known. The AC/A can then be calculated by the following formula, using a positive sign for esodeviations and a negative for exodeviations:

$AC/A = IPD + \text{near PCT} - \text{distance PCT} / \text{amount of accommodation exerted}$

### Fusional amplitudes

Fusional vergences are vergence movements used to eliminate horizontal, vertical, or torsional image disparity. Fusional amplitudes can be measured using the synoptophore, or with a prism bar, gradually increasing the prism power until diplopia occurs or a corrective eye movement is no longer made, indicating that the prism can no longer be overcome by motor fusion.

Fusional amplitudes may be affected by:

- compensation for deviations: as tendency to deviate develops, a patient may show a compensatory increased fusional amplitude for that deviation; for example, congenital vertical deviations frequently lead to increased vertical fusion range;
- state of awareness: tiredness, illness, hypoxia, etc. may decrease fusional reserves; for example, converting a phoria to a tropia;
- visual acuity: fusional amplitudes increase with better visual acuity;
- orthoptic exercises may increase fusional amplitudes.



## 8.6 Visual acuity testing

Measurement of visual acuity is a key part of the assessment of patients with strabismus and amblyopia, and indeed with any eye condition. For testing to be meaningful, the test chosen must be appropriate to the patient's age and level of literacy.

### Definition

Visual acuity is a measure of spatial discrimination; that is, the ability to distinguish two visual stimuli separated in space. However, it is only one aspect of visual function. To fully assess visual function other factors, such as contrast sensitivity, colour vision, visual fields and motion detection, must be considered.

Principles of visual acuity measurement:

- acuity is determined by the smallest retinal image whose form can be appreciated;
- this is usually quantified by the minimum angle of separation (subtended at the nodal point);
- the normal minimum angle of separation is considered to be 1 minute of arc or less, which corresponds to a Snellen acuity of 6/6, but under optimal conditions a healthy eye may discriminate 0.5 minutes of arc.

### Visual acuity testing in infants

Quantifying visual acuity in pre-verbal children (usually 0–2 years) may be extremely difficult. In children with strabismus it is most important to assess whether the acuity is equal in both eyes or whether amblyopia is present. A number of techniques can be used, as follows.

- **Occlusion:** if a child objects strongly to occlusion of one eye this suggests poorer acuity in the uncovered eye.
- **Fixing and following:** fixation behaviour can be examined using a toy or light as a fixation target. Searching, unsteady movements, nystagmus, or inability to follow a moving target may indicate poor vision. Any fixation preference for one eye should be noted; in infants with strabismus alternating fixation suggests equal vision in the two eyes.
- **16Δ base-down prism fixation test:** in this test, a 16Δ base-down prism is placed over one eye and the other occluded. The eye under the prism is forced to move to take up fixation. Quality of fixation is noted; monocular fixation should be central, steady, and maintained. The other eye is then uncovered. Ability to maintain fixation through the prism is observed. If fixation immediately switches to the uncovered eye the acuity of the eye beneath the prism is impaired. If fixation is maintained through a blink then acuity is good.
- **Preferential looking:** infant attention is attracted more by patterned than homogeneous surfaces, provided the pattern is above the visual acuity threshold. Test cards such as Teller and Cardiff cards have been designed with gratings or pictures of varying spatial frequencies but equal contrast to the background. The grating or picture is on one half of the card and the other is plain. The cards are held 50–100 cm from the infant and the observer watches the child's eyes and head for fixation movements indicating that the grating or optotype is detected.
- **Optokinetic nystagmus:** an optokinetic nystagmus drum with stripes of varying spatial frequency can be used to estimate visual acuity. *Rotation testing* is a gross test of integrity of fixation, attention, and motor responses with both eyes open. The observer holds the child facing her and rotates quickly through 360°. If vision is normal, optokinetic nystagmus movements should be seen during the rotation as the infant fixates objects behind the examiner and should stop when rotation ceases as

fixation suppresses post-rotatory nystagmus. The *Catford drum* works on a similar principle: black dots on a white drum are seen to oscillate when the drum is rotated. If the child can see the spots a corresponding series of optokinetic nystagmus eye movements can be observed. The smaller the dots seen the better is the acuity.

- **Hundreds and thousands:** if a child can see and pick up these tiny sweets at 33 cm then visual acuity is at least 6/24. This method is suitable for children over 9 months who have developed sufficient manual dexterity; younger children with good vision will show visually directed reaching for larger objects of interest.

### Visual acuity testing in verbal children and adults

Whenever possible the visual acuity should be measured with each eye in turn and binocularly, with and without glasses, and with a pinhole. A number of methods are in common use.

#### Picture and optotype matching

From the age of 2 years most children can undertake picture naming or matching tests such as *Kay's pictures*. By 3 years they can go on to matching single-letter optotypes such as the *Sheridan–Gardiner test*, in which the child views single letters presented at 6m and points to the matching letter on a printed card.

Single-picture or optotype tests may overestimate visual acuity due to the *crowding phenomenon*, whereby symbols of a given size become more difficult to recognize when they are surrounded by similar symbols, such as full rows of letters on a Snellen chart. This is thought to be because the receptive fields of neurons in the amblyopic visual system are abnormally large. Crowded versions of the *Kay's pictures* and *Sheridan–Gardner tests* are available to try to compensate for this, but it is best to switch to a linear test as soon as possible for children with amblyopia.

#### Snellen chart

This is a widely used chart in which letters of diminishing sizes are used to test minimum resolvable acuity. The test can be used by literate adults and children, who can usually manage to read the Snellen chart from about 4 years of age onwards.

Each Snellen letter subtends an angle of 5 minutes (5') of arc at the retina and the gaps between the letter components 1' of arc when viewed at a distance specified at 60m, and the smaller ones when viewed at 36, 24, 18, 12, 9, 6, 5, and 4m respectively. The acuity is expressed as a Snellen fraction: distance at which the chart is read/distance at which the smallest optotype read subtends 5' arc; for example, 6/60 if only the top line is read. The normal eye has a Snellen acuity of 6/6 or better.

#### LogMAR chart

These charts are designed to record the *logarithm* of the mean angle of resolution. The original Bailey–Lovie chart is not widespread in clinical practice and it is the ETDRS version that is most commonly used. It has a number of advantages over the Snellen chart:

- every line has five letters proportionally spaced to minimize crowding,
- all letters are equally legible,
- there is a logical progression in size of letters in each successive line,
- the space between each letter is equal to the width of one letter and the spacing between rows is equal to the height of one letter in the smaller row.

The chart is usually read at 4 m. Each correct line (worth 0.1 units) or each correct letter (worth 0.02 units) is subtracted from 1.0 to give the LogMAR acuity; an acuity of 0.0 approximates 6/6 Snellen. This test is considered one of the more accurate forms of visual acuity assessment and lends itself to research and statistical analysis.

#### **Acuity tests for illiterate adults**

Optotype matching can test patients who are illiterate or unable to read the chart due to a language barrier. Tests have also been devised based on Snellen or LogMAR charts with Es (illiterate E test) or Cs (Landholt C test) in varying orientations. The patient indicates the direction of the prongs of the Es or gap in the C rings.

#### **Near acuity tests**

A number of tests exist for near vision testing. They are usually designed to be read at 30 cm and acuity recorded as N plus the point size of the print being read (tests usually range from N48 to N5).

## 8.7 Tests of stereopsis and binocular single vision

### Stereopsis tests

Stereopsis is the perception of the relative depth of objects on the basis of binocular disparity. Stereoacuity is the angular measurement of minimal resolvable binocular disparity at which stereopsis is appreciated. It is measured in seconds of arc ( $1^\circ = 60'$  of arc;  $1' = 60$  seconds ( $60''$ ) of arc). The normal value for those with normal visual acuity is  $40''$ . A number of tests are in widespread use to assess stereopsis.

#### Titmus test

This test uses the principle of linear polarization and consists of three-dimensional polaroid vectographs made up of two plates in the form of a booklet viewed through polaroid spectacles. It is performed at a distance of 16 inches and has three components, as follows.

#### Wirt Fly

This tests gross stereopsis ( $3000''$  of arc). It is very useful in children; if stereopsis is present, the fly will appear solid and the child can be asked to pick up one of its wings. In the absence of gross stereopsis the fly will appear flat.

#### Animals

This section consists of three rows of animals, one of which should appear to stand out from the page and can be pinpointed by patients with stereopsis. The degree of disparity tested ranges from  $400$  to  $100''$ .

#### Circles

The most finely discriminating part of the test consists of nine sets of four circles. One of the circles in each set has a degree of disparity and should be seen standing out from the page. The degree of disparity tested ranges from  $800$  to  $40''$ .

False positives are possible with the Titmus test, as it contains some monocular clues.

### Random-dot stereogram tests

#### TNO test

This consists of seven plates of red and green dots. Spectacles are worn with a red filter over one eye and green over the other. The plates contain various shapes (squares, circles, etc.) created by random dots in complimentary colours. Some shapes can be seen without the spectacles whereas others are 'hidden', and only become visible to someone with stereopsis who is wearing the red/green glasses.

The first three plates establish the presence of stereopsis and subsequent plates quantify it, ranging from  $480$  to  $15''$ . This test is also useful because there are no monocular clues to produce false positives.

#### Lang test

This does not require special spectacles because the targets are seen disparately by each eye through intrinsic cylindrical lens elements in the test plates. Two strips of an image exist beneath each vertical cylinder such that one is seen by the right eye and the other by the left. The patient is asked to name or point to a simple shape on the card.

This test is useful in assessing very young children and babies, as they will instinctively reach out and touch the pictures. The degree of disparity ranges from  $1200$  to  $550''$ .

#### FRISBY

This consists of three transparent plastic plates of 6, 3, and 1 mm thickness. On the surface of each plate are printed four squares of small random shapes. One of the plates contains a hidden circle, in which the random shapes are printed on the reverse of the plate. The patient is asked to identify the hidden circle. The test does not require special spectacles as the disparity is created by the thickness of the plate. The degree of disparity ranges from  $600$  to  $15''$  of arc.

### Base-out prism test

This is a relatively quick and easy method for detecting binocular single vision (BSV) in children who are too young or cannot perform the stereo tests above.

A  $16\Delta$  base-out prism is placed in front of one eye, displacing the image and causing diplopia. If the prism is placed in front of the right eye, the following movements should be observed:

- shift of right eye to the left to establish fixation,
- Hering's law causes a matching shift of the left eye to the left,
- the left eye will then make a convergent movement to re-fixate,
- a child with good BSV should have enough fusion to overcome  $16-20\Delta$  base-out.



Fig. 8.3 Wirt Fly test.



Fig. 8.4 TNO test.

## 8.8 Tests of retinal correspondence and suppression

These tests are particularly useful if patients are found to have poor or absent stereopsis and give an idea of whether lower levels of binocular vision are present.

### Bagolini glasses test

This is a diplopia-based test of retinal correspondence. Glasses are worn in which the lens have fine parallel striations at  $45^\circ$  in one eye and  $135^\circ$  in the other. The patient views a spotlight through the glasses and the glasses convert the spot of light into lines perpendicular to the striations. They are asked to describe the appearance of the lines and lights seen. They may see the following results.

- One light with two lines crossing in the middle of the light: this indicates that retinal correspondence is present (but could be normal or abnormal).
- One light with two lines crossing in the middle, with a gap in one of the lines around the light: this indicates a suppression scotoma.
- Two lights and two separate lines: this indicates a manifest deviation with diplopia. If the lights become one and the lines form a cross when the deviation is corrected with prisms, it suggests that normal retinal correspondence is present.
- One light with only one line: this demonstrates suppression of one eye.

### Worth's four-dot test

This is another test of visual alignment, suppression, dominance, and diplopia. The patient wears glasses with a red filter over one eye and a green filter over the other. They are asked to view a target consisting of four lights: an uppermost red light, two green lights, and a lowermost white light. If the other eye is occluded, the eye with the green filter can potentially see three lights (the two green lights plus the white light, which is perceived as green by that eye). The eye with the red filter will see two lights (the red light plus the white light, which is perceived as red through the filter) if the other is covered.

The patient is asked how many lights they can see, and of which colours. If the right eye looks through the red filter and the left the green, results are interpreted as follows.

- If there is orthophoria with bifoveal fixation, four lights are seen: the red at the top, two green, and then the white light, which may be perceived as red (if the right eye is dominant), green (if the left eye is dominant), alternate between the two, or appear mixed.
- If the left eye is suppressing, two red lights are seen.
- If the right eye is suppressing, three green lights are seen.
- If five lights are seen, there is either double vision or rapidly alternating suppression. If the images are crossed (red lights on the left), there is an exodeviation, and if uncrossed (red lights on the right) there is an esodeviation.

### After-image test

This test utilizes after-images to produce bifoveal stimulation with dissimilar images. A horizontal line of bright light is shone on the fixing eye to leave an after-image and immediately afterwards a vertical line of light (which is harder to suppress) is shone on the deviating eye. The patient is asked to draw the appearance of the after-images. Results may be as follows:

- The two after-images may be seen as a cross; this usually indicates normal retinal correspondence, but may also occur with eccentric fixation.
- If the two images do not cross, the foveae do not project to the same point in space and abnormal retinal correspondence is present.

### Area and depth of suppression

The area of suppression and the angle of anomaly of any abnormal retinal correspondence can be measured using the *synoptophore* with simultaneous perception slides.

The depth or density of suppression is measured using a *Sbiza bar* (or Bagolini filter bar), which contains a series of red filters of increasing densities. The bar is held in front of the fixing eye and a white light viewed through increasingly dense red filters. The red filter will eventually reduce the illumination to the fixing eye enough to switch fixation to the deviating eye, hence causing diplopia. The filter strength is increased until the patient sees two lights, one red and one white. The filter strength at this point gives a measure of density of suppression.

## 8.9 Hess charts

### Principles

Hess charts are used in the investigation and monitoring of incomitant strabismus and diplopia to assess the paretic component. If the two eyes are dissociated it is possible to indicate the position of the non-fixing eye when the other eye is fixing in specific positions of gaze. A field is plotted separately with each eye fixing. Each point on the inner field represents fixation at 15° from the primary position, whereas the outer field represents 30° from the primary position. The Hess chart may not pick up defects present more than 30° from primary.

Hess charts can be a valuable diagnostic tool, but results must be interpreted alongside assessment of ocular movements. They are particularly useful for documenting changes over time and responses to any treatment.

Patients must have normal retinal correspondence and central fixation in order for interpretation to be accurate.

### Methods

Hess charts can be plotted by dissociating the eyes in one of two ways.

#### Hess screen

This consists of a screen displaying a tangent pattern on a dark grey background. Each small square subtends an angle of 5° at the 50 cm working distance. The patient should be seated squarely 50 cm from the screen with the head centred on the central fixation spot. Dissociation is achieved by means of complimentary colours; the patient wears glasses with a red filter in front of the fixing eye and green in front of the other eye.

The examiner projects a vertical slit of red light onto the screen from a red laser pointer. This can only be seen by the fixing eye (red filter). The patient holds a green laser pointer and is asked to superimpose their horizontal slit of green light (visible only to the non-fixing eye) onto the red light. The examiner plots a chart of the indicated positions for the non-fixing eye. In orthophoria the two lights are more or less superimposed in all nine positions of gaze.

#### Lees screen

This consists of two opalescent white screens placed at 90° apart with a two-sided plane mirror at 45° between the two to dissociate the eyes. The screens can each display a tangent grid as for the Hess screen. The examiner projects the grid on the screen for the fixing eye and indicates a point on the grid. The patient must use a pointer to indicate where on the other screen they perceive the point to be. The examiner compares the perceived point to the expected point and marks this on the Hess chart.

- A positive or outward displacement indicates an overacting muscle.

#### Hess chart characteristics of neurogenic defects

- Muscle sequelae are seen to a greater or lesser extent dependent on the duration of the condition. The fields may become more concomitant with time.
- The largest underaction is normally in the direction of action of the paretic muscle and the largest over-action usually represents the contralateral synergist.
- There is proportional spacing between the inner and outer fields.
- The deviation in primary position reflects the extent of the palsy.

#### Hess chart characteristics of mechanical defects

- The affected eye shows a compressed field (vertically or horizontally).
- Muscle sequelae are usually limited to marked overaction of the contralateral synergist.
- There may be no deviation in primary position; the deviation in primary does not represent the extent of the defect.

### Interpretation of Hess charts

There are a number of basic rules for interpreting a Hess plot.

1. Compare the fields with each other.
  - The smaller field represents the eye with the defect.
  - If one field is considerably smaller, this suggests a recent-onset paresis. The fields may become more comparable in size as sequelae take effect.
  - Sloping sides to fields indicate an A or V pattern.
2. Compare each field with the normal field represented by the grid.
  - The displacement in the primary position is the primary deviation.
  - The greatest negative or inward displacement represents the muscle with the primary underaction.






Fig. 8.5 Lees screen.

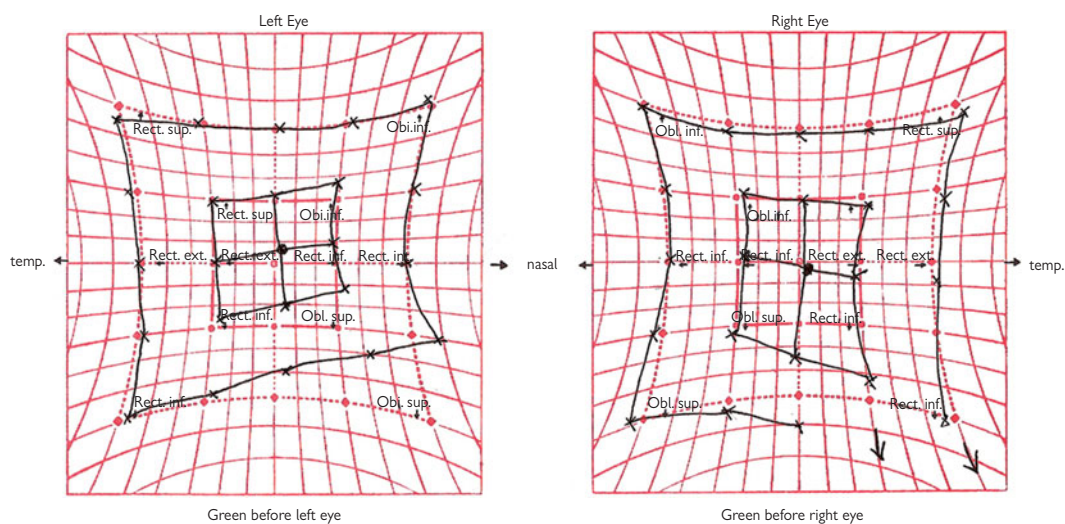


Fig. 8.6 Hess chart of neurogenic defect: left fourth nerve palsy.

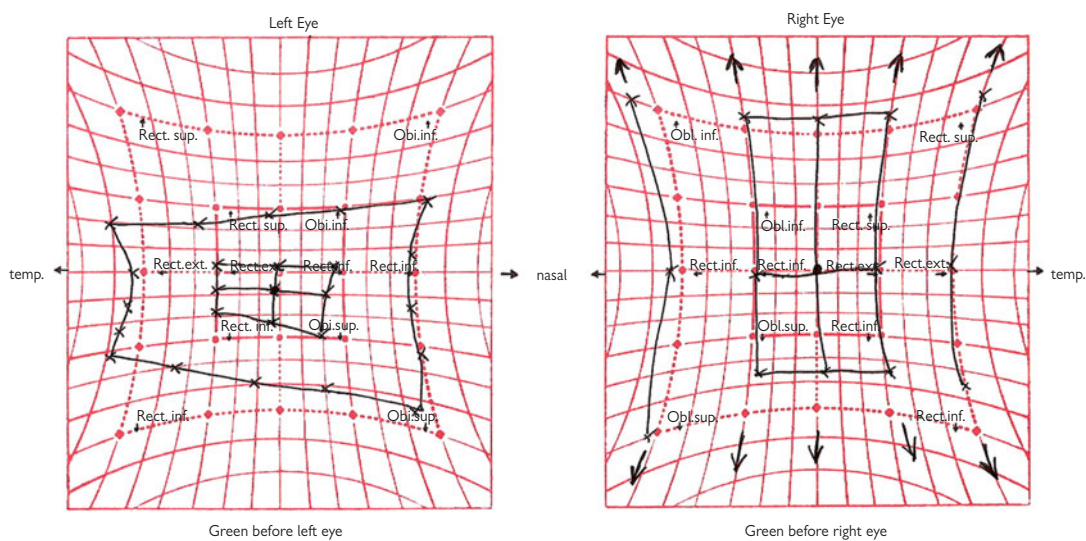


Fig. 8.7 Hess chart of mechanical defect: left orbital floor fracture.

## 8.10 Amblyopia

Amblyopia is a reduction in visual capacity due to interruption of the developing visual system during the sensitive period in childhood. This produces decreased visual acuity via a defect of central visual processing in the absence of any demonstrable abnormality of the optic pathways. Amblyopia has an estimated prevalence of 1.2–4.4% in childhood depending on the defining criteria used. Prevention and treatment of amblyopia forms the bulk of the workload of most children's eye services. The condition carries an increased lifetime risk of serious visual loss in the fellow eye.

### Aetiology and classification

Normal development of the visual system and central visual processing requires bilateral focused foveal images with retinal correspondence during a critical period lasting until around 8 or 9 years of age. Any interruption to such stimulation can lead to amblyopia. The degree of amblyopia varies depending on the child's age and the severity of the interruption, with severe reductions in stimulation before the age of 2 years producing the most profound amblyopia. Amblyopia is usually unilateral, but bilateral degradation of visual stimuli may lead to bilateral amblyopia.

Amblyopia can be classified according to its aetiology.

#### Stimulus deprivation

- Occurs when no image or a degraded image forms at the fovea; for example, due to congenital cataract or ptosis.
- Constant monocular loss of visual stimulation for more than 1 week per year of life produces a high risk of amblyopia in children younger than about 6 years.

#### Anisometropic

- Differences in refractive error interrupt normal binocular interaction by simultaneous stimulation of the two eyes with differently focused and aniseikonic images.
- Amblyopia occurs in the eye receiving the most consistently blurred image, typically the more hypermetropic eye.
- As little as 1D sphere or 0.75D cylinder difference in refractive error can produce amblyopia, although it is more common with more than 2.5D of anisometropia.
- Frequently associated with microstrabismus.
- May coexist with strabismic amblyopia.

#### Ametropic

- Bilateral amblyopia may occur with high refractive errors, typically more than +5D or less than -10D. This is due to form vision deprivation and is more common in hypermetropia, as myopes receive some focused retinal images from near stimulation.

#### Strabismic

- This occurs due to abnormal binocular interactions during the critical period of visual development. During this period ocular misalignment results in suppression of the deviating eye rather than diplopia. If one eye is preferred for fixation there is continued monocular suppression of the deviating eye and the risk of amblyopia is significant. If fixation alternates freely between both eyes the risk of amblyopia is low. In strabismic amblyopia the amblyopic eye has reduced visual acuity even if forced to fixate.

### Clinical diagnosis

#### Visual acuity

- Is reduced with no other detectable organic cause and despite full refractive correction.

- The crowding phenomenon may be exaggerated; visual acuity is better with single optotype letters than with charts where letters are in rows or otherwise crowded.

#### Neutral-density filters

- May help to differentiate amblyopia from organic causes of reduced visual acuity. Visual acuity is measured with and without the filter placed over the eye. Acuity is reduced significantly less for a given filter in amblyopia than in organic lesions.

### Management

Amblyopia must be treated before the end of the sensitive period of visual development (about age 8–9). In the UK a multidisciplinary approach is taken to amblyopia management, with orthoptists and optometrists having key roles.

#### Prevention

Many countries now have screening programmes to identify amblyopia in preschool children.

#### Correct remediable underlying causes

Any refractive error should be corrected with full-time spectacle wear and any amblyogenic stimuli, such as cataract or ptosis, ameliorated as soon as possible.

#### Occlusion

Patching of the better-seeing eye to encourage use of the amblyopic eye is the mainstay of treatment. Full-time patching is not usually required, and the amount needed varies with:

- age at onset of amblyopia; response to patching is quicker in younger children,
- age at presentation,
- severity of the acuity deficit,
- initial response to treatment,
- compliance with prescribed treatment.

Careful monitoring is essential as excessive patching may induce amblyopia in the better eye, particularly in very young children (usually under 2 years of age).

#### Atropine penalization

Atropine 1% drops can be given to blur the vision in the better eye to around 6/18. This technique may be useful where compliance with patching is difficult, and is effective for milder amblyopia (visual acuity better than 6/24), particularly if associated with hypermetropia. Penalization does not work as quickly as occlusion and must be used with caution in very young children due to possible toxic effects of atropine.

## 8.11 Binocular vision and stereopsis

Binocular single vision (BSV) is the ability to use both eyes simultaneously and to fuse the two separate images centrally to form a single visual percept. Absence of BSV may prevent an individual pursuing certain occupations.

Development of BSV in infancy requires:

- similar image clarity in both eyes,
- overlap of visual fields,
- correct neuromuscular development so that both visual axes can be aligned with the object to allow motor fusion,
- correct central development capable of image interpretation to allow sensory fusion,
- corresponding retinal areas; for example, normal foveal position in both eyes.

This permits *normal retinal correspondence*, whereby viewing an object will produce an image at anatomically corresponding points on each retina, triggering stimulation of corresponding points in the occipital cortex to form a single perception of the object.

### Levels of BSV

BSV can be graded as the following.

#### 1. Simultaneous perception

An image is perceived simultaneously on each retina.

#### 2. Fusion

Fusion is the unification of images falling on corresponding retinal points of the two eyes as a single percept. If we consider the field of vision at a given fixation distance as a plane, the plane composed of all object points in the visual space that are imaged on corresponding retinal elements at that fixation distance is termed the *Horoptyer*, or horizon of vision. Fusional processes allow objects on the plane of the Horoptyer to be seen as a single visual perception.

Fusion has two components:

- *sensory fusion* is the central process by which similar images from the two eyes are interpreted as one;
- *motor fusion* is the ability to align the eyes so that sensory fusion can be maintained; for example, by convergence movements when fixing on a target moving towards the viewer.

#### 3. Stereopsis (disparity sensitivity)

Objects viewed at a distance produce images with a slight horizontal disparity between the two eyes due to the horizontal separation of the eyes in the skull. Fusion of these slightly disparate images and processing of the disparity gives a three-dimensional perception of depth. Fusion is not limited solely to objects confined to the Horoptyer. There exists a narrow region just in front of and behind the Horoptyer in which, despite disparity, points will be seen as single. This is called *Panum's fusional area*. Objects falling within this area are seen singly and stereoscopically. Objects falling outside Panum's area produce physiological diplopia.

### Abnormalities of BSV

#### Confusion

This occurs when corresponding retinal points are stimulated by dissimilar stimuli and fusion cannot occur. The two images may appear to be on top of one another, or retinal rivalry may occur, with one image being suppressed.

#### Diplopia

The stimulation of non-corresponding retinal points by the same image produces diplopia, or double vision, whereby the same object is perceived twice.

### Adaptations to abnormalities of BSV

If abnormal BSV arises before the age of 6–8 years, plasticity of the developing visual system may produce adaptations to prevent perception of confusion and diplopia. This may be done by suppression or abnormal retinal correspondence. Some adults who develop sudden-onset strabismus, for example in cranial nerve palsies, may also be able to ignore the second image and not complain of diplopia.

#### Suppression

This is a cortical mechanism to ignore one of the images causing diplopia or confusion. Physiological suppression occurs normally in BSV to allow concentration on a viewed object and suppress physiological diplopia from perception of surrounding objects behind or in front of Panum's area. If the image from the dominant eye always predominates, continued *monocular* suppression can lead to diplopia. If suppression is *alternating* amblyopia does not occur. Suppression may be *obligatory*, occurring at all times, or in strabismus it may be *facultative*, occurring only when the eyes are in the deviated position.

#### Abnormal retinal correspondence

If the fovea of one eye is paired with a non-foveal area of retina in a deviating fellow eye, some binocular vision with limited fusion may occur by abnormal retinal correspondence despite a manifest deviation. In abnormal retinal correspondence stimulation of non-corresponding retinal points with a stable relationship leads to stimulation of functionally corresponding cortical points to produce a single percept. It is most common in constant small-angle esotropias. The disadvantage of abnormal retinal correspondence is that after attempted surgical correction the strabismus may revert to the pre-surgical state in an effort to regain BSV.

#### Abnormal head posture

This occurs as a motor adaptation to diplopia in adults who cannot suppress, or in people with strabismus who have good binocular potential. Diplopic adults may turn the head to maximize separation of the images so that one can be ignored. Individuals with strabismus and BSV may turn the head to bring the object of regard into the field of BSV. Horizontal deviations produce face-turns horizontally, vertical deviations result in elevation or depression of the chin, and torsional deviations cause a head tilt to one or other shoulder.

## 8.12 Concomitant strabismus I: heterophorias

The term *concomitant strabismus* describes cases in which the angle of deviation of the eyes remains constant in all positions of gaze. These are divided into phorias and tropias.

- *Phorias* are latent deviations that can be controlled by motor and sensory fusion when both eyes are open. Phorias may decompensate and become manifest in situations where fusion cannot be maintained; for example, tiredness, illness, certain visual tasks, or when the eyes are dissociated.
- *Tropias* are manifest deviations present even with both eyes open. The patient may have a variable degree of control over the deviation.

It should be noted that these conditions are not absolute; individuals may exhibit a phoria in one situation (e.g. distance fixation) and a tropia in another (e.g. near fixation).

Phorias and tropias are further classified into:

- horizontal deviations:
  - convergent or esodeviations,
  - divergent or exodeviations;
- vertical deviations:
  - upward or hyperdeviations,
  - downward or hypodeviations.

### Esophoria and exophoria

#### Esophoria

This is a latent convergent squint. It is controlled by adequate negative fusional vergence (the motor ability to diverge) so BSV is achieved and amblyopia is not induced. Esophoria is demonstrated with the alternate cover test (see section 8.3).

Esophoria may be:

- larger for near: symptoms are more likely to develop during close work,
- larger for distance: symptoms are more likely during distance activities,
- non-specific and equal for near and distance.

Aetiology of esophorias include:

- accommodative and refractive, due to superable hypermetropia and anisometropia,
- convergence excess with high AC/A ratio,
- relatively weak negative fusional reserves, demonstrated by reduced ability to overcome base-in prisms,
- anatomical features such as narrow interpupillary distance, orbital abnormalities, and extraocular muscle abnormalities.

Differential diagnosis of an esophoria includes convergence excess esotropia, fully accommodative esotropia, and decompensating micro-esotropia.

#### Exophoria

This is a latent divergent squint. It is controlled by adequate positive fusional vergence (the motor ability to converge) so BSV is achieved and amblyopia is not induced. Again it may be larger for near or distance fixation and is demonstrated by the alternate cover test.

Aetiology of exotropias includes:

- accommodative and refractive due to myopia and anisometropia,
- divergence excess,
- relatively weak positive fusional reserves, demonstrated by reduced ability to overcome base-out prisms,
- increasing age,
- anatomical features such as wide interpupillary distance, orbital abnormalities, and extraocular muscle abnormalities.

The main differential diagnosis of exophoria is primary intermittent exotropia.

#### Management of phorias

Phorias are asymptomatic in most cases and BSV is maintained by adequate fusional vergence. Hence no treatment is required in the majority of cases.

*Decompensation* of phorias is usually spontaneous, but may be precipitated by an increase in visual demands, illness, or a change in refractive status or spectacle correction. Exophoria is more common with increasing age and correction of presbyopia may sometimes precipitate the development of symptoms. Decompensation may be demonstrated by a reduced rate of recovery of exophoria after dissociation of the eyes, or even absent recovery in fully decompensated cases.

#### Indications

Indications for treatment of phorias may be:

- symptoms (eyestrain, blurring, diplopia),
- loss of stereopsis in young children,
- achievement of standards for certain careers.

#### Management

Management of phorias may include the following options.

- Correction of refractive error, particularly full hypermetropic correction in esophorias.
- Orthoptic exercises to improve fusional amplitude and convergence exercises in exotropias.
- Prisms for short-term control (base-in for exotropia and base-out for esotropia). These may be particularly useful for adults who decompensate into diplopia when unwell.
- Botulinum toxin injections to horizontal recti (lateral rectus for exotropia and medial for esotropia). Reducing the angle of the deviation can restore binocular function and stimulate improvement in the motor fusion range, resulting in benefits long after the pharmacological effect of the toxin has worn off.
- Surgery to horizontal recti if persistently symptomatic. This should be done using an adjustable technique where possible.

*This page intentionally left blank*



## 8.13 Concomitant strabismus II: esotropia

Esotropia, or manifest convergent strabismus, is the most common form of strabismus.

### Pseudo-esotropia

Some children presenting with suspected convergent squints do not have true strabismus, but in fact have anatomical variations that mimic esotropias; for example:

- epicanthic folds,
- large negative angle kappa (the angle between the pupillary and optical axes),
- narrow interpupillary distance,
- facial asymmetry,
- globe and orbit abnormalities,
- pupil abnormalities; for example, corectopia.

### Classification of esotropia

Several classifications have been described, but a simple one is as follows.

- *Primary* esotropia: may be intermittent or constant, accommodative or non-accommodative.
- *Secondary or sensory* esotropia: for example, due to poor vision in the converging eye.
- *Consecutive* esotropia: following previous exotropia, with or without prior surgery.

### Primary constant non-accommodative esotropias

#### Infantile esotropia

This is an esotropia presenting before 6 months of age. It may represent a neurodevelopmental anomaly, though association with other CNS abnormalities is relatively unusual. Clinical features are:

- no significant refractive error,
- no limitation of abduction (bilateral congenital sixth nerve palsy is a differential diagnosis),
- large stable angle ( $>30^\circ$ ),
- cross fixation and free alternation are typical, so amblyopia is uncommon,
- no binocular function,
- asymmetry of optokinetic nystagmus,
- DVD (upward deviation of eye on occlusion) and/or inferior oblique overaction may be present,
- manifest-latent nystagmus may be present (a horizontal conjugate jerk nystagmus worsened by occluding the fixing eye).

Treatment is surgical, although any amblyopia and refractive error should also be addressed. Bilateral recession of the medial recti is the standard procedure, and may be augmented by conjunctival recession and resection of one lateral rectus for very large deviations. If DVD is present it can be treated by inferior oblique weakening. Amblyopia treatment often needs to continue after surgery, as loss of alternating fixation may actually promote amblyopia.

Timing of surgery in infantile esotropia is controversial. Some experts favour early surgery at 9–18 months in the hope of developing some binocularity, and others believe that better long-term results are achieved with later surgery at around 4 years of age.

Management of infantile esotropia with botulinum toxin injections to both medial recti has also been described. This aligns the eyes and may allow sufficient development of fusion to maintain alignment in the long term.

#### Basic and sudden-onset constant esotropias

This is a constant esotropia developing after 6 months of age. There is no significant refractive error and deviation is constant for near and distance. Treatment is surgical. A sudden-onset constant esotropia may sometimes be seen in 4–12 year olds. This may be precipitated by a minor head injury or temporary occlusion with reduced vision in one eye. In these cases, neurological investigation may be required if there is incomitance, A or V pattern, nystagmus or any other possible neurological signs. If neurology is normal, prompt botulinum toxin injection to the medial rectus may restore alignment permanently.

#### Nystagmus block esotropia

This develops in patients with congenital nystagmus in whom convergence may dampen the nystagmus and improve visual acuity.

#### Microtropia (or monofixation syndrome)

This is a squint of very small angle ( $8^\circ$  or less) in which some abnormal binocular function is present. It may not be detectable with cover testing. It is quite common (around 1% of population) and is amblyogenic. Clinical features are as follows.

- *Central suppression scotoma* within the deviating eye prevents diplopia. This may be detected with *Bagolini striated glasses*, with which a cross is seen with a gap at the point of intersection, or *4 Δ base-out prism test*. A 4 Δ prism placed in front of a normal eye displaces the image to a point just temporal to the fovea, eliciting a refixation movement. In a micro-esotropic eye, the 4 Δ prism will displace the image into the parafoveal suppression scotoma and no movement is seen.
- Reduced stereopsis (worse than  $300^\circ$  arc).
- Amblyopia in the affected eye.
- Abnormal retinal correspondence.
- Normal or almost normal peripheral fusional amplitudes.

A small recession of medial rectus with resection of lateral rectus may be used to correct the deviation.

### Primary constant esotropias with accommodative element

#### Partially accommodative esotropia

This is a constant esotropia that is worse for near fixation and improves but is not abolished when full hypermetropic correction is prescribed. It may be the primary presentation or develop secondary to a longstanding or partially treated fully accommodative esotropia (see below).

Clinical features are:

- onset at 2–5 years of age,
- hypermetropia with or without anisometropia,
- constant esotropia (usually unilateral) that persists with full hypermetropic correction,
- BSV poor or absent for near and distance, and the converging eye is usually amblyopic,
- familial tendency.

Initial treatment is with glasses prescribed to the full cycloplegic refraction and treatment of amblyopia. Surgery is usually for cosmesis, although it may promote a degree of abnormal binocular function in younger children. Medial rectus recession and lateral rectus resection is performed on the converging eye.

## Intermittent accommodative esotropias

These are the most common group of esotropias. Convergent strabismus is secondary to high accommodative drive due to one or both of:

- uncorrected hypermetropia (refractive),
  - high AC/A ratio (convergence excess, non-refractive).
- Presentation is between 1 and 5 years of age. The esotropia is usually first noticed when the child views near objects. It becomes more apparent with tiredness or illness and may eventually become constant.

### Fully accommodative esotropia

Clinical features:

- AC/A ratio normal,
- hypermetropia (usually +4 to +7D),
- accommodation to overcome hypermetropia stimulates convergence resulting in esotropia,
- no residual esotropia for near or distance when full hypermetropic correction is worn,
- normal BSV develops if child wears appropriate spectacles,
- amblyopia is unusual unless anisometropic,
- positive family history is common.

Treatment is with full hypermetropic spectacle correction and treatment of any amblyopia. Surgery is rarely needed; this must be carefully explained to parents, who may find it difficult to understand why surgical correction is not desirable. If esotropia does become constant despite full hypermetropic correction, the aim of any surgery should be to correct only the residual deviation present when glasses are worn, as the refractive error will still require correction after surgery.

### Convergence excess esotropia

This is an intermittent near esotropia that occurs due to high AC/A ratio. Clinical features are:

- high AC/A ratio (higher than 5:1),
- manifest esotropia for near, straight, or small esophoria for distance,
- often low hypermetropia or anisometropia,
- amblyopia is rare; BSV is reduced for near but normal for distance.

Treatment can often be achieved without surgery. *Executive bifocals* have an intersection in which the visual axis is bisected by the top of the lower segment crossing the lower portion of the pupil. The upper segment should contain correction for any hypermetropic refractive error. The lower segment contains the minimum amount of extra 'plus' needed to relax the drive for accommodative convergence at near; allowing the child to maintain fusion at near fixation. They are most useful once children are old enough to read.

*Miotic therapy* with pilocarpine or ecothiopate drops can increase accommodation without inducing accommodative convergence. They are little used now and do not provide a long-term solution.

*Surgery* may be chosen if it is not possible to reduce the power of the bifocal segment as the child gets older. Bilateral medial rectus recessions are then indicated.

## Other intermittent esotropias

### Near esotropia

This is a concomitant esotropia that is manifest for near but straight or latent for distance with normal AC/A ratio and insignificant refractive error. Treatment is surgical with bilateral medial rectus recessions.

### Cyclical esotropia

This is an esotropia affecting 3–6 year olds that is intermittent in time. The angle is equal for near and distance, and the squint tends to be manifest for 24 hours and then disappear for 24 hours or similar cycle. Treatment is with surgery (medial rectus recession and lateral rectus resection) before the esotropia becomes constant with the aim of preserving binocularity.

## Secondary and sensory esotropia

A *sensory esotropia* may develop due to poor vision in the converging eye, usually in children (e.g. congenital cataracts, macular scars, optic atrophy), so full ocular examination is essential as for all cases of strabismus. If it is not possible to improve the vision, treatment for social and cosmetic benefit can be achieved with botulinum toxin injections or horizontal rectus surgery.

*Divergence paralysis* due to intracranial tumour, trauma, or stroke may produce a secondary esotropia. This can be differentiated from sixth nerve palsy, as the angle is constant or even reduced on lateral gaze.

*Convergence spasm* may also produce a secondary esotropia associated with accommodative spasm (which may produce pseudomyopia) and miosis. Treatment is with cycloplegia and correction of any hypermetropia.

## Consecutive esotropia

This can occur at any time after an exotropia, but is usually seen after exotropia surgery and may cause diplopia in adults. If esotropia occurs in the post-operative period after exotropia correction, it may be treated with prisms for diplopia, bifocal spectacles to reduce the angle for near, or botulinum toxin injection to medial rectus. However, surgery is required if esotropia persists for more than 6–9 months.

## 8.14 Concomitant strabismus III: exotropia

Exotropia is a manifest divergent squint. It may present in a variety of patterns.

### Pseudo-exotropia

Anatomical variations may mimic exotropias:

- large positive-angle kappa,
- wide interpupillary distance,
- facial asymmetry,
- globe and orbit abnormalities,
- pupil abnormalities; for example, corectopia.

### Classification of exotropia

Several classifications have been described, but a simple one is as follows.

- *Primary* exotropia: intermittent or constant, may be worse for near, distance, or non-specific.
- *Secondary* or *sensory* exotropia: due to poor vision in the diverging eye.
- *Consecutive* exotropia: following previous esotropia, with or without prior surgery.

### Primary intermittent exotropia

#### Distance intermittent exotropia

This usually presents before the age of 2 years. The cause is unknown, but it may be supranuclear in origin. Clinical features are:

- angle of deviation is greater for distance by  $>10\Delta$ ; at near there may just be exophoria,
  - exotropia may be precipitated by bright light, and the child may close the affected eye in bright conditions,
  - refractive errors and amblyopia are unusual,
  - stereoaucuity is typically preserved for near, but motor fusion range reduced for near,
  - dense suppression is present for distance.
- Divergence excess may be true or simulated, and the two types require different surgical approaches.
- In *true divergence* excess the near angle is consistently less than the distance angle and AC/A ratio is normal. This responds to bilateral lateral rectus recessions.
  - In *simulated divergence* excess the underlying angle is the same for near and distance but is partially controlled by accommodative or fusional convergence for near fixation. The near angle will measure less than the distance with both eyes open, but if +3.0 lenses are placed over both eyes to interrupt accommodative convergence, or one eye occluded to interrupt fusional convergence the near angle increases. This type responds better to unilateral medial rectus resection and lateral rectus recession in the diverging eye.

#### Near intermittent exotropia

This typically presents in teenagers or young adults with headaches, 'eyestrain' symptoms, or diplopia for near. It may be due to a low AC/A ratio or associated with poor fusional convergence. Clinical features are:

- near-angle measures at least  $10\Delta$  more than distance,
- equal visual acuities but limited binocular function and poor convergence,
- associated with acquired myopia,
- may become constant with time.

Any myopia should be corrected. Convergence exercises and base-in prisms may help control. However, surgery may be required to preserve binocular function for near and distance, and uni- or bilateral medial rectus resection is the usual technique.

### Non-specific intermittent exotropia

This is very similar to distance intermittent exotropia but the child intermittently manifests an exotropia of the same angle for near and distance. Treatment, if needed, is usually with lateral rectus recession and medial rectus resection in the affected eye.

### Primary constant exotropia

This presents early in life. Infantile cases presenting at  $<6$  months are associated with a high incidence of ocular and CNS abnormalities. True primary congenital constant exotropia is quite rare. Clinical features are:

- constant large angle for near and distance,
- usually alternates so amblyopia may be absent,
- binocular function generally absent,
- refractive error is unusual,
- may be associated with facial and developmental abnormalities,
- may develop DVD.

Binocular function usually cannot be established but surgery is often desirable for social and cosmetic reasons. Unilateral lateral rectus recession and medial rectus resection is the typical procedure, but surgery to the fellow eye may also be needed for large deviations.

### Secondary exotropia

An exotropia may develop due to loss of vision in the diverging eye, usually in adults. If it is not possible to improve the vision, treatment for social and cosmetic benefit can be achieved with botulinum toxin injections or horizontal rectus surgery.

### Consecutive exotropia

This can occur at any time after an esotropia, but usually has a gradual onset years to decades after surgery. Binocular function is usually weak or absent and amblyopia from the preceding esotropia is common. Diplopia is rare, but orthoptic testing should be done to establish the risk of postoperative diplopia before any surgery is attempted. Horizontal rectus surgery can be used if risk of diplopia is low; if risk of diplopia is high management by botulinum toxin to the lateral rectus is preferred.

## 8.15 Incomitant strabismus

In *incomitant strabismus* the angle of deviation differs depending on the direction of gaze or on which eye is fixing. It may be associated with restriction or paralysis of ocular movements in given directions. These conditions are often classified as *neurogenic*, *restrictive* (mechanical), or *myogenic*, and may be congenital or acquired. Patients may have *ophthalmoplegia*; that is, paresis of two or more extraocular muscles.

### Neurogenic incomitant strabismus

Neurogenic incomitant strabismus may be caused by any pathology of cranial nerves III, IV, or VI or their nuclei (see also Chapter 9). This may be congenital—for example, developmental hypoplasia of cranial nerve nuclei—or acquired.

Clinical features are as follows.

- Ductions are greater than versions.
- Saccades are slow in the paretic direction.
- Full sequelae develop in agonist and antagonist muscles with time.
- IOP is stable in all positions of gaze.
- The Hess chart shows proportional inner and outer fields. The smaller field indicates the affected eye, although this may reduce with time as sequelae develop.
- Forced duction testing shows full passive movement, though antagonists of the affected muscle(s) may show contracture.

### Restrictive incomitant strabismus

This occurs when there is a mechanical limitation restricting eye movement in the affected direction(s).

Clinical features are as follows.

- Ductions and versions are of equal magnitude.
- Saccades are of normal speed but come to an abrupt stop at a point of restriction.
- Attempted eye movements may be painful.
- IOP increases with attempted gaze in paretic direction.
- The globe may retract on looking in the paretic direction.
- The inner and outer fields of the Hess chart are compressed in the paretic direction.
- Forced duction testing shows reduced passive movement in the direction of limitation.

Causes of mechanical incomitant strabismus include congenital disorders such as developmental abnormalities, fibrosis, or adhesions of the extraocular muscles (e.g. Brown's syndrome), or acquired causes such as trauma to the orbit or extraocular or iatrogenic adhesions after previous surgery (see also sections 8.16 and 8.17).

### Myogenic incomitant strabismus

This may be due to abnormalities in the neuromuscular junction or in the extraocular muscles.

#### Myasthenic

Myasthenia gravis, an autoimmune disorder of the neuromuscular junction, can cause ocular dysmotility of virtually any pattern. It may mimic other ocular motility disorders, but the dysmotility is characteristically variable and fatigable (see chapter 9).

Clinical features are as follows.

- Fatigability demonstrated by sustained upgaze of more than 1 minute, or rapid saccades.
- Hess chart may show high variability.
- May have associated ptosis.

- Full passive movement on forced duction test.
- Cogan's twitch: after looking down for 20 seconds then returning to primary position of gaze the upper lid may initially overshoot.
- May have systemic involvement.

#### Myopathic

Inherited myopathies such as chronic progressive external ophthalmoplegia may cause gradual symmetrical non-fatigable loss of ocular motility. Other disorders of extraocular muscles such as thyroid eye disease and myositis generally cause a mechanical pattern of incomitant strabismus.

**Table 8.1 Differences between incomitant strabismus of neurogenic and restrictive (mechanical) aetiology**

	Neurogenic	Restrictive
Ductions/versions	Ductions>versions	Ductions=versions
Saccade velocity	Slow in paretic direction	Normal with sudden stop
Sequelae	Full sequelae with time	Sequelae limited to overaction of contralateral synergist
IOP change	IOP may go up or down but it stays constantly up or down, no change with direction of gaze	IOP increases in direction of limitation
Globe	No change	May retract on movement in direction of limitation
Hess/Lees	Inner and outer fields are proportional. The smaller field is of the affected eye	Inner and outer fields are compressed in direction of limitation
Forced duction testing	Full passive movement	Reduced passive movement in direction of limitation

## 8.16 Restrictive ocular motility disorders

The features of restrictive strabismus are as described in 8.15. Presentations may be very varied, from complex incomitant patterns to signs mimicking concomitant strabismus or cranial nerve palsies. A variety of disorders can cause restrictive ocular dysmotility.

### Thyroid eye disease

Thyroid eye disease affects the extraocular muscles in two phases. Initially there is an *inflammatory phase* in which they become swollen and infiltrated with inflammatory cells. Eye movements may be very variable in this phase but immunosuppressive treatment may be effective. This is followed by a *cicatricial phase*, in which the inflammation subsides leaving affected muscles scarred, fibrotic, and tight. This can lead to any pattern of dysmotility, but the most common are:

- restriction of upgaze (tight inferior rectus),
- restriction of abduction (medial rectus involvement),
- combination of vertical and horizontal restriction (inferior rectus and medial rectus),
- restriction of depression (superior rectus restriction).

It is essential to ensure that the disease is stable and the patient euthyroid before any squint surgery is considered. Until then any diplopia can be managed conservatively with prisms. If orbital decompression is required it must be done before squint surgery.

The aim of squint surgery in restrictive thyroid eye disease is to improve function by maximizing the field of BSV in primary position, downgaze, and to each side.

### Orbital blowout fractures

Fractures to the bony orbit can affect extraocular muscle actions in a number of ways:

- incarceration of muscles within a fracture (especially inferior rectus in orbital floor fractures),
- entrapment of orbital fibrous septae,
- haemorrhage or oedema of extraocular muscles,
- muscle ischaemia via a compartment syndrome-type mechanism,
- damage to nerve supply of the muscle.

All patients sustaining an orbital fracture must be examined for ocular motility defects and diplopia. The most common defect is restriction of upgaze (plus or minus limited downgaze) due to incarceration of the inferior rectus or the surrounding orbital fibrous septae in an orbital floor fracture.

CT scanning should be performed to identify the cause of the dysmotility. Fracture repair should be performed before squint surgery if indicated. Extraocular muscle restriction after blowout fractures often resolves spontaneously as soft-tissue swelling reduces, but if diplopia in primary position or downgaze persists beyond about 6 months after the injury then surgery may be required.

*Forced duction tests* (see 8.22) should be performed to identify the pattern of restriction.

Surgical techniques which may be required to correct diplopia after blowout fractures include:

- inferior rectus recession, if there is hypotropia in primary position with restricted upgaze,
- Faden procedure to weaken contralateral inferior rectus, if there is reduced downgaze with diplopia due to inferior rectus palsy, but no deviation in primary position.

A wide variety of other techniques may be needed if there are more complex patterns of dysmotility with involvement of other orbital walls or extraocular muscles.

### Other restrictive disorders

#### Strabismus following retinal detachment surgery

Retinal detachment surgery may restrict ocular movements due to direct damage to extraocular muscles or pressure on a muscle from an explant. This often improves spontaneously, but treatment with prisms, botulinum toxin injections, or surgery may be required.

#### Myopic restrictive strabismus

In large highly myopic eyes the lateral rectus may slip down or up over the globe, leading to reduced abduction and rotation of the eye up or downwards. This causes a large-angle esotropia acquired in adult life. Treatment is with medial rectus recession. (Brown's syndrome and congenital fibrosis also cause restrictive dysmotility and are discussed in 8.17.)

### Surgical principles in management of restrictive strabismus

A number of principles should be borne in mind when considering surgery for restrictive strabismus.

- Differentiate restricted muscles from weak muscles using the forced duction test and checking for raised IOP on muscle contraction.
- Always recess restricted muscles, as resection can reduce their action.
- Recession of overacting ipsilateral antagonists may also be required.
- Use *adjustable sutures* as results may be unpredictable.
- Consider leaving restriction of upgaze untreated if there is no deviation in primary position.
- Problems on downgaze lead to disabling diplopia; for example, when reading or walking downstairs, and need particularly careful evaluation and management.



## 8.17 Complex ocular motility syndromes

A number of syndromic patterns of restricted ocular motility that are uncommon causes of strabismus are described. These disorders show high inter-individual variation and treatment may be difficult.

### Duane's syndrome

This is a congenital 'miswiring' syndrome in which lateral rectus is aberrantly innervated by the third nerve, leading to co-contraction of lateral and medial rectus and retraction of the globe on attempted adduction. The sixth nerve nucleus may be hypoplastic. It occurs more commonly in girls (60%) and in the left eye (60%), and 20% of cases are bilateral. It accounts for about 1% of strabismus.

Clinical features are:

- limitation of adduction, abduction, or both,
- esotropia is most common in primary, but can be exotropic or straight,
- abnormal head posture: face turn towards direction of most limited movement,
- globe retraction on attempted adduction,
- narrowing of palpebral fissure on adduction and widening on abduction,
- usually suppress in lateral gaze so BSV is preserved in primary position and diplopia rare,
- amblyopia is seen in about 20%,
- up or downshoots on attempted adduction.

The most widely used classification is that of Huber:

- *type I* (about 80%): limited abduction, esotropia or straight in primary position, mild retraction on attempted adduction;
- *type II*: limited adduction, exotropic, or straight in primary position, severe retraction;
- *type III*: limited abduction and adduction, esotropic or straight in primary position, moderate retraction.

Around 30% have associated systemic abnormalities:

- deafness: perceptive with associated speech disorders;
- Goldenhar syndrome: abnormalities of external ear, hemifacial microsomia, dermoids, and scoliosis; may have learning disability;
- Klippel–Feil syndrome: short, webbed neck, decreased range of movement of cervical spine, low hairline.

The combination of Duane's, Klippel–Feil, and deafness is termed *Kirkham's triad*; Duane's plus Goldenhar and deafness is *Wilderwank syndrome*.

Treatment of Duane's syndrome is not usually necessary, but may be desirable for abnormal head posture, disfiguring up/downshoots or severe retraction, or loss of BSV in primary or manifest deviation in primary. Surgery is with a combination of horizontal muscle recessions; resections should be avoided as they may exacerbate the retraction.

### Brown's syndrome

In this syndrome movement of the superior oblique tendon through the trochlea is limited. It may be congenital or acquired.

- *Congenital*: most cases. Due to abnormal development of superior oblique muscle/tendon or trochlea. Often improves or resolves by age 12. A click may be felt as the tendon moves through the trochlea.
- *Acquired*: due to trauma, surgery, or inflammation (e.g. rheumatoid arthritis, sinusitis).

Clinical features include:

- reduced elevation in adduction, usually straight in primary position,
- usually unilateral,
- minimal muscle sequelae,

- abnormal head posture: chin up with face turn away from the affected eye,
- positive forced duction test.

Treatment is not usually required unless there is hypotropia in primary, in which case superior oblique tenotomy or disinsertion can be performed.

### Möbius syndrome

This is a very rare congenital syndrome of varying degrees of loss of motor function in cranial nerves VI–XII.

Ocular features are:

- bilateral sixth nerve palsies; 50% are esotropic in primary; cross fixation may develop since convergence is intact,
- about 50% have a horizontal gaze palsy.

Other features:

- lack of facial expression due to bilateral upper motorneuron VII palsies,
- paresis of ninth and eleventh nerves can cause feeding and swallowing difficulties, and some affected children die in infancy,
- IQ usually low,
- abnormal digits.

## Congenital fibrosis syndromes

### Congenital fibrosis of the extraocular muscles (CFEOM)

These are non-progressive rare congenital eye movement disorders due to dysfunction of the third nerve.

- CFEOM1 (autosomal dominant) causes bilateral restrictive ophthalmoplegia and ptosis, with impaired elevation.
- CFEOM 2 (autosomal recessive) restricts horizontal motility and causes a large exotropia plus ptosis.
- CFEOM 3 causes more variable motility anomalies.

### Strabismus fixus

This is a very rare congenital condition in which the eyes are fixed tightly in convergence or divergence by fibrosis in and around the horizontal rectus muscles.

## 8.18 Vertical deviations

Primary isolated vertical strabismus is less common than horizontal squint. However, vertical deviations may be seen in the form of primary overaction of the oblique muscles and dissociated vertical deviation (DVD), each of which are commonly associated with coexisting horizontal strabismus. Third and fourth nerve palsies may also cause congenital or acquired vertical deviations (see Chapter 9).

### Inferior oblique overaction

This is the most common type of vertical strabismus. Inferior oblique overaction may be a sequela of weakness of its ipsilateral antagonist (superior oblique, e.g. in fourth nerve palsy) or contralateral synergist (superior rectus). It may also be seen as a primary condition.

Clinical features of primary inferior oblique overaction include:

- elevation (upshoot) of the affected eye on adduction; there may be a vertical deviation in primary position (hyper/hypotropia),
- often bilateral but often asymmetrical,
- associated V pattern (see section 8.19),
- no ipsilateral superior oblique or contralateral superior rectus weakness,
- often associated with early-onset esotropia,
- Bielchowsky head tilt test negative.

Treatment of inferior oblique overaction:

- if there is no deviation in primary position, treatment may not be necessary; inferior oblique overaction tends to become less apparent as children get older,
- surgery may be desirable if development of BSV is disturbed or there are concerns about cosmesis,
- inferior oblique disinsertion or recession is the procedure of choice in most cases.

### Superior oblique overaction

This is usually primary, as inferior rectus underaction is uncommon. It may occur due to an abnormally sagittal insertion of the superior oblique tendon and is common in craniofacial dysostoses where there may be excyclotorsion of the whole orbit.

Clinical features are:

- depression of the affected eye in adduction,
- may have a vertical deviation in primary position but this is unusual,
- no weakness of ipsilateral inferior oblique weakness or contralateral inferior rectus,
- may be associated with a horizontal deviation,
- associated A pattern may result in compensatory head posture,
- usually bilateral.

Treatment of superior oblique overaction is as follows.

- Treatment may frequently not be required. In cases of craniofacial dysostosis treatment may not be effective due to the abnormal muscle anatomy.
- As for superior oblique overaction intervention may be indicated for abnormal head posture or if BSV is threatened.
- Surgery is posterior tenotomy of the superior oblique, usually bilaterally.

### Dissociated vertical deviation (DVD)

This is an up-drift of the non-fixing eye that occurs when the eyes are dissociated or the patient is not concentrating. It is frequently associated with infantile esotropia and latent nystagmus. It may be supranuclear in origin, possibly as a means of suppressing latent nystagmus.

Clinical features are as follows.

- Usually becomes apparent between 18 months and 3 years of age.
- A slow updrift and excyclotorsion of the non-fixing eye. The eye is densely suppressed during this movement and patients are not aware of it, though it may be obvious to onlookers.
- It may be latent, provoked by dissociation of the eyes including covering the deviating eye, or manifest spontaneously; for example, during daydreaming or when one eye is occluded by the nose during lateral gaze.
- The eye typically returns slowly to primary position by dipping slightly below the midline and intorting.
- Usually bilateral but may be asymmetrical.
- It can be distinguished from inferior oblique overaction because it does not change with position of horizontal gaze; inferior oblique overaction is more marked on adduction. Also inferior oblique overaction is associated with a V pattern, whereas an A pattern is more common in DVD.

Treatment of DVD is often not required, but may be indicated for cosmetic reasons. The first-choice surgical procedure is usually anteriorization of the inferior obliques to make them passive restrictors of upgaze, though posterior fixation suture (Faden procedure) of the superior rectus or superior rectus recession on hangback sutures to weaken upgaze may also be used.

### Other causes of vertical deviations

- Thyroid eye disease, orbital traumas, and other restrictive disorders.
- Brown's syndrome.
- Previous strabismus surgery.
- Previous intraocular surgery.
- Third nerve palsy.
- Double elevator palsy (inability to look up with one eye, probably supranuclear origin).

*This page intentionally left blank*

## 8.19 Alphabet patterns

Alphabet patterns are horizontal deviations that vary in magnitude according to vertical position. They can therefore be considered incomitant. The deviation is measured for distance fixation in primary position, 30° upgaze, and 30° downgaze.

### A pattern

This is a horizontal deviation in which there is relative convergence on upgaze and relative divergence on downgaze, with a minimum of 10Δ difference between the two. The deviation in primary position may be an esotropia that increases in angle on upgaze and decreases on downgaze, or an exotropia that increases in angle on downgaze and decreases on upgaze.

*A-pattern esotropia* may induce a chin-up compensatory head posture to maintain binocular vision. There is an association with mongoloid slant to the palpebral fissure, possibly due to related variation in the rectus muscle insertions.

*A-pattern exotropia* may lead to a chin-down head posture. It is less common than A-pattern esotropia.

#### Causes

- *Superior oblique overaction* is the most common cause. It is usually associated with exodeviation in the primary position. Superior oblique overaction is usually primary since inferior oblique weakness is uncommon. It may occur due to an abnormally sagittal insertion of the superior oblique tendon and is common in craniofacial dysostoses where there may be excyclotorsion of the whole orbit.
- *Inferior oblique underaction*.
- *Inferior rectus underaction*.
- *Horizontal rectus dysfunction*: abnormal action or insertion of medial and/or lateral recti, spontaneously or after surgery.

#### Management

Treatment is only required in symptomatic cases, where there is either abnormal head posture or disruption of binocular function, or if cosmetically unacceptable. Surgical choices depend on underlying cause, as follows.

- *Posterior tenotomy of superior oblique*: selectively weakens the posterior portion of the muscle to reduce its depressor action but preserve the torsional component. This is effective if there is evidence of oblique dysfunction (superior oblique overaction or inferior oblique underaction).
- *Inferior rectus strengthening* if inferior rectus underaction is the cause; this must be done with caution to avoid inducing vertical deviation in primary position.
- *Horizontal rectus surgery* is appropriate if no dysfunction of obliques or inferior rectus is found. Recession/resection of these muscles can be used to address any eso- or exotropia in primary. In bilateral horizontal rectus surgery the muscle insertions can be moved according to the acronym MALE: medial rectus insertion moved towards the apex of the A (upwards), lateral rectus insertion towards the ends of the A (downwards). The most common procedure is bilateral medial rectus recessions with upward transposition of the insertions. In single-eye surgery a similar effect can be achieved by placing the lower margin of the medial rectus insertion in a weaker position than the upper, and the upper margin of lateral rectus in a weaker position than the lower.

### V pattern

This is the opposite of the A pattern: there is relative divergence on upgaze and relative convergence on downgaze. A slight physiological

V pattern is normal, so it is only considered clinically significant if divergence increases by 15Δ or more in upgaze.

*V-pattern esotropia* may lead to a compensatory chin-down head posture. It can be associated with antimongoloid palpebral fissures.

*V-pattern exotropia* is usually due to inferior oblique overaction and may induce a chin-up head posture. It may also be associated with craniofacial abnormalities with shallow orbits.

#### Causes

- *Superior oblique underaction*, including fourth nerve palsy. The eyes may be straight in upgaze but have marked esodeviation in downgaze. Primary superior oblique underaction is often seen in infantile esotropia.
- *Inferior oblique overaction*: this may be primary or a sequela of fourth nerve palsy.
- *Vertical rectus dysfunction*: superior rectus weakness, tight inferior rectus (e.g. in thyroid eye disease).
- *Horizontal rectus muscle dysfunction*: abnormal action or insertion of medial/lateral recti.
- May be seen in *Brown syndrome*.

#### Management

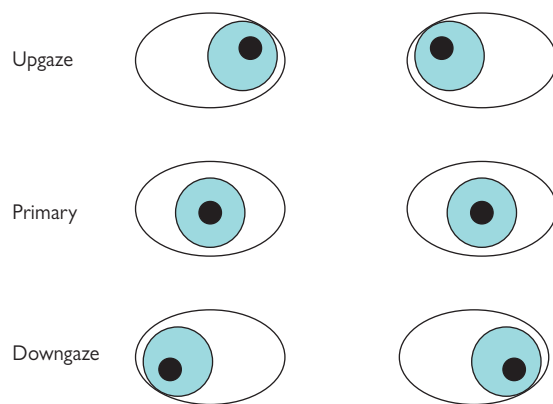
This is again required only in symptomatic cases or for cosmesis and depends on underlying aetiology.

- *Inferior oblique weakening* by disinsertion or recession; effective if there is oblique dysfunction (inferior oblique overaction/superior oblique weakness).
- *Inferior rectus recession* with or without lateral transposition of insertion: for tight inferior rectus. This may be done on adjustable sutures to minimize risk of inducing vertical deviation in primary position or downgaze.
- *Horizontal rectus surgery* if no oblique or vertical rectus dysfunction. Recession/resection techniques are used to address the primary exo- or esotropia. Again the acronym MALE applies as above; lateral rectus insertions are moved up and medial down. In single-eye surgery the lower margin of the lateral rectus insertion can be placed in a weaker position than the upper and vice versa for the medial rectus.

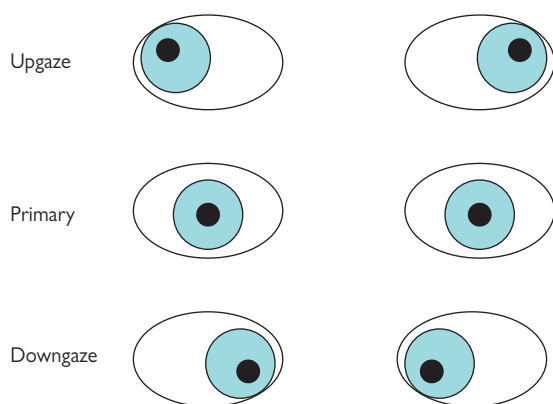
### Other patterns

Other 'alphabet patterns' have been described but are less commonly of clinical significance:

- *Y pattern*: relative divergence on upgaze but no difference between the primary position and down gaze; usually due to inferior oblique overaction;
- *λ pattern*: relative divergence on downgaze with no difference between the primary position and upgaze;
- *X pattern*: relative divergence in upgaze and downgaze but straight in the primary position.



**Fig. 8.8a** A pattern.



**Fig. 8.8b** V pattern.



## 8.20 Principles of strabismus surgery I: indications and types

### Indications for strabismus surgery

A full work-up is required before a patient is listed for strabismus surgery to detect any underlying neurological or ocular pathology. Non-surgical treatments such as correction of refractive error, prisms, and botulinum toxin injections should be considered before proceeding with surgery, and better understanding of these techniques has meant that surgery may be avoided for many patients. Amblyopia should also be addressed wherever possible before any surgery.

Surgery is still, however, a mainstay of treatment for squint and may be performed for functional or cosmetic reasons.

#### Functional indications

- To promote or restore development of BSV in children.
- To eliminate diplopia.
- To restore and maximize BSV in patients who previously had established BSV.

#### Cosmetic indications

A manifest strabismus may be cosmetically displeasing to patients, and may even lead to disadvantage in social interactions and loss of self confidence. Surgery may be desirable to improve the cosmesis of the squint or to improve an abnormal head posture. Surgery should usually only be undertaken after a full assessment and treatment of any significant refractive error or amblyopia has taken place. Once maximal visual potential is reached, and the deviation is stable over time, the residual deviation can be surgically treated.

Squint surgery is preferably carried out under general anaesthetic, since it is more comfortable for the patient and allows the anaesthetist to monitor and treat any episodes of bradycardia induced by the oculo-cardiac reflex (which occur quite commonly when extraocular muscles are pulled or handled).

Surgical procedures for strabismus can be divided into three main categories:

1. weakening,
2. strengthening,
3. transposition (change of direction of muscle action).

### Weakening procedures

#### Recession

The muscle is detached at its insertion and moved towards its origin to weaken its effect. This operation is most commonly used to weaken the medial rectus in esotropias or the lateral rectus in exotropias, often in combination with resection of the ipsilateral antagonist.

An outline for the procedure of recession of a rectus muscle is as follows.

- The eye is draped and conjunctival peritomy performed overlying the appropriate muscle.
- The muscle is exposed by blunt dissection and hooked with a squint hook.
- The muscle is spread on a Chavasse hook and 6:0 absorbable sutures passed through the outer third of the muscle. Each suture is passed through a partial-thickness and a full-thickness bite and securely knotted. Alternatively a single double-ended suture is utilized if an adjustable technique is to be used.
- The muscle is disinserted from its scleral insertion using Westcott scissors.
- The desired amount of recession is measured with calipers and marked.

- The muscle is resutured on to sclera at the marked distance posterior to the original insertion, or alternatively secured with adjustable hangback sutures to its initial insertion.

- The conjunctiva is closed.

This technique can be adapted to the inferior oblique by using an inferotemporal fornix incision. The muscle is usually resutured 2 mm postero-temporal to the temporal edge of inferior rectus insertion. Studies have suggested that this technique is no more or less effective than disinsertion.

#### Myectomy (disinsertion) and tenotomy

Myectomy is the disinsertion of muscle without formal reattachment. It is usually used for inferior oblique overaction; the inferior oblique is disinserted and allowed to reattach itself at a recessed position on the globe.

Tenotomy is the division of the tendon of a muscle to weaken its action. Posterior tenotomy of the superior oblique involves the disinsertion of the posterior 80% of the tendon fibres. It is used in A-pattern exotropia with superior oblique overaction to weaken the depressor action of the muscle while preserving intorsion. Free tenotomy of the whole superior oblique tendon is sometimes performed to treat Brown's syndrome.

#### Posterior fixation suture (Faden procedure), myectomy, and Scott procedure

In certain incommittant situations it may be desirable to weaken or limit the action of a muscle without affecting primary position; for example:

- the medial recti in convergence excess esotropia,
- the contralateral inferior rectus after blowout fracture if there is persistent diplopia in downgaze despite good depression in the affected eye,
- the contralateral medial rectus in recovered sixth nerve palsy if diplopia persists in abduction,
- the contralateral medial rectus for diplopia on contralateral gaze following surgery for exotropia.

This weakening of a muscle without affecting primary position can be achieved with several procedures.

#### Faden procedure, or posterior fixation suture

In this operation a non-absorbable suture is passed through the belly of the muscle and tethers it to the sclera in a post-equatorial position. This should have no effect in primary position, but the muscle action becomes progressively weaker as it moves into its direction of action. It works most successfully on the medial or inferior recti; it can be difficult to perform on the superior rectus and is not very effective for the lateral rectus. Patients should be warned that it might be more uncomfortable postoperatively than other strabismus operations.

#### Scott procedure

This achieves a similar result by combining recession and resection of the same muscle; a portion of the muscle is resected but, rather than suturing it back to its insertion, it is recessed. This technique has the advantage that it can be done with adjustable sutures to avoid precipitating any deviation in primary position.

#### Myotomy

In myotomy procedures a muscle is weakened by partially transecting it with an incision through about 80% of the width of the muscle. This technique may be useful if the sclera is very thin, or other factors make alternative operations very difficult.

## Strengthening procedures

### Resection

Resection involves the excision of a length of a rectus muscle, hence tightening it and strengthening its action. It is commonly combined with recession of the ipsilateral antagonist, although it should be avoided in strabismus with restrictive aetiology.

The technique starts similarly to that for recession, with identification and exposure of the muscle. However, sutures are placed a measured distance back from the insertion and the intervening portion of muscle is excised. The remaining muscle is then resutured to the insertion.

### Advancement

Advancement is used to strengthen a muscle that has previously been recessed if the patient subsequently develops a consecutive deviation opposite to the original squint; for example, medial rectus advancement for consecutive exotropia following medial rectus recession for childhood esotropia.

The muscle is identified in its recessed position and the insertion moved anteriorly. It should be noted when calculating the amount of surgery to be performed that advancement has a slightly greater effect per millimetre of surgery than resection, and an adjustable technique may be desirable.

### Tucking

This procedure is specific to the superior oblique, and involves tightening a lax superior oblique tendon to improve both the depression and intorsion function of the muscle. It is most useful for congenital superior oblique underaction. The tendon is identified and folded over and a non-absorbable suture placed around the tuck to hold it in place. Care must be taken not to induce an iatrogenic Brown's syndrome.

## Transposition procedures

A number of procedures have been devised that transpose rectus muscles away from their usual positions and recruit them to take over some of the function of another weak or paretic muscle. If more than two muscles are involved in the procedure these operations carry a risk of anterior segment ischaemia. It should be noted that transposition techniques are for weak muscles; they will not be effective if the limitation of movement is restrictive in aetiology. Examples include the following.

### To improve abduction

For example, in sixth nerve palsy. Here the challenge is to improve abduction without doing such extensive surgery that anterior segment ischaemia is induced. Techniques have been devised that try to minimize disruption to the anterior ciliary arteries:

- *toxin transposition*: the vertical recti are transposed temporally in conjunction with weakening the medial rectus with botulinum toxin;
- *Hummelsheim procedure*: the muscles are split and only the lateral halves of superior and inferior rectus are disinserted and reattached to the superior and inferior margins of the paretic lateral rectus muscle. The medial rectus may also be recessed. Results of this operation are generally poor;
- *Jensen procedure*: the superior and inferior recti are split along their lengths and attached to the belly of the lateral rectus, which is also split lengthways. Medial rectus must also be recessed.

### To improve elevation

For example, for double elevator palsy.

- *Knapp procedure*: the horizontal recti are disinserted and transposed upwards to the superior rectus insertion.

### To improve depression

- *Inverse Knapp procedure*: the horizontal recti are disinserted and transposed downwards to the inferior rectus insertion.

### To improve intorsion

For example, for superior oblique paresis with excyclotorsion, especially when bilateral.

- *Harada-Ito procedure* (Fells modification): the superior oblique tendon is split and the anterior half advanced temporally and sutured to the sclera as close as possible to the upper aspect of the lateral rectus. Leaving the posterior fibres in place prevents an iatrogenic Brown's syndrome. This procedure is most commonly performed bilaterally.

## 8.21 Principles of strabismus surgery II: complications

Serious complications are fortunately rare in strabismus surgery. Problems that may occur can be divided into preoperative, early postoperative, and late postoperative complications.

### Peroperative complications

#### Surgery to wrong muscle

If a clearly written operative plan is visible during surgery and the correct eye marked, this complication should not arise due to poor surgical planning. It may happen if one muscle is mistaken for another due to poor exposure and identification of anatomy (usually confusion between inferior oblique and the nearby lateral or inferior rectus). This can be avoided by checking the action of a muscle intraoperatively by pulling on it, and by methodically identifying the adjacent muscles. As soon as such a mistake is identified, the operation should be reversed or other corrective procedure performed as required.

#### Globe perforation

This is rare but may occur during muscle detachment or when suturing muscles to sclera. It is avoided by careful technique; for example, not tenting up the scleral insertion when detaching a muscle, and by use of hangback sutures during recessions if access for suturing posteriorly is difficult or sclera is especially thin. If perforation occurs, dilated funduscopy should be performed after the surgery to look for retinal breaks, but routine cryotherapy is not required.

#### Haemorrhage

Some bleeding is common during squint surgery, but haemorrhage rarely causes an adverse outcome. It can be minimized by preoperative vasoconstrictor drops (adrenaline or phenylephrine), judicious use of diathermy, and careful avoidance of vortex veins. Inferior oblique surgery is particularly prone to haemorrhage.

#### Lost muscle

A muscle may be lost and retract back down its sleeve if it has no controlled attachments anteriorly; for example, if it slips off its sutures or if the body of a flimsy muscle tears. This usually occurs during surgery, but may occur in the early postoperative period. It is avoided by good surgical technique. A lost muscle can be extremely difficult to correct and requires the urgent surgical attention of a strabismus expert.

### Early postoperative complications

#### Immediate undercorrection

This may occur for a number of reasons:

- surgery performed was insufficient for the angle of the squint,
- restriction due to scarred muscles if this was not the first surgery to the eye,
- slipped muscle,
- ongoing excessive drive to squint; for example, high AC/A ratio, nystagmus block.

Undercorrection may often be avoided if it is possible to use adjustable sutures.

#### Immediate overcorrection

A small overcorrection is often the desired result immediately postoperatively. However, unplanned amounts of overcorrection may occur due to:

- excessive surgery for the angle of deviation,
- resection or advancement of a scarred, tight muscle,
- slipped muscle,

- ongoing controlling drive despite correction of an intermittent strabismus.

#### Diplopia

Despite preoperative assessment of BSV, suppression and likelihood of postoperative diplopia, some patients do experience unpredicted diplopia after surgery. This may be due to inability to suppress or unmasking of an unsuppressed area of retina. If it does not resolve, further treatment with botulinum toxin or surgery may be indicated.

#### Infection

Inflammatory conjunctivitis is quite common after surgery but postoperative topical antibiotics usually prevent infectious conjunctivitis. Orbital cellulitis and endophthalmitis have been reported after squint surgery but are rare.

#### Anterior segment ischaemia

This occurs if blood supply to the anterior segment is compromised when surgery is performed to three or more rectus muscles (with their associated anterior ciliary arteries). It presents with pain, visual blurring, corneal oedema and thickening, and anterior chamber flare. It is managed with topical steroids and analgesics, but rarely persists as blood supply is restored within a few months by hypertrophy of the remaining long posterior ciliary arteries.

### Later complications

#### Suture granuloma

This is a raised red area in the region of a suture. It is less common with modern absorbable sutures than in the past when catgut sutures were used. It may resolve with topical steroids but often requires surgical excision.

#### Recurrent or consecutive deviation

Patients or their parents should be warned when consented that consecutive deviations are common and may occur many years after the primary surgery. Earlier reoperation may be needed if there is persistent over or undercorrection.

## 8.22 Other procedures in strabismus

### Forced duction and generation tests

#### Forced duction test

This is often performed during surgery, but may also be done under local anaesthetic in adults. It is used to assess the passive range of movement of the globe when active movement is limited.

- The eye is grasped with two pairs of toothed forceps at the limbal conjunctiva.
- The eye is moved as far as possible in the direction of interest.
- If passive movement is full, there is weakness of the muscle(s) moving the eye in that direction.
- Resistance and limitation of passive movement indicates restrictive pathology.

#### Forced generation test

This is used to differentiate muscle paresis (partial weakness) from palsy by evaluating the amount of contraction force generated by the weak muscle. It is done under local anaesthetic as patient cooperation is required.

- The patient is asked to move the eye as far as they can in the direction of limited movement.
- The anaesthetized conjunctiva is gripped with toothed forceps and the examiner attempts to move the eye in the opposite direction.
- If the eye can be moved but resistance is felt, there is muscle paresis.
- If the eye can be moved without resistance, this implies palsy of the muscle.

### Adjustable suture techniques

Surgery with adjustable sutures is increasingly popular for operations to the rectus muscles in adults and cooperative older children. The amount of surgery performed is the same as for non-adjustable techniques, but the muscles are sutured to the sclera in such a way that the sutures can be manipulated under local anaesthetic postoperatively to recess or advance the muscles to adjust for any immediate under or over correction. Adjustable techniques are particularly useful in situations where the outcome may be unpredictable; for example:

- nerve palsies,
- restrictive strabismus,
- re-operations,
- those with risk of postoperative diplopia,
- any complex strabismus.

### Botulinum toxin in strabismus management

Injection of botulinum toxin into extraocular muscles is a useful and reversible tool in diagnosis and treatment of strabismus. It should be noted that, while widely accepted, these techniques are an off-licence use of the drug and should be given on a 'named patient' basis.

#### Injection technique

- Topical anaesthetic is preferable for adults.
- Electrodes are connected to the skin to monitor an EMG signal.
- The patient looks in the opposite direction to that of action of the muscle to be injected.
- The needle, connected to another EMG electrode, is passed towards the muscle via a transconjunctival approach (or transcutaneous for the inferior rectus).

- The patient looks in the direction of action of the muscle and an EMG signal should be detected if the needle is correctly positioned in the muscle.
- The toxin is injected.

#### Indications

##### Diagnostic

Examples include the following.

- To assess likelihood of postoperative diplopia; for example, if the orthoptic postoperative diplopia test is positive but the patient is keen for surgery. An injection is used to mimic the effects of surgery temporarily to see whether symptomatic diplopia is induced.
- To align the eyes to look for useful binocular function.

##### Therapeutic

Examples include the following.

- To improve the ocular deviation in a squint if no further surgery is possible (e.g. due to scarring) or desirable. This may need to be repeated every 4–6 months.
- As a functional cure of strabismus in patients who have binocular function but have a motor cause for the strabismus; for example, decompensating phorias, sudden-onset childhood esotropia.
- To manage strabismus which is not stable in the long term; for example, in early thyroid eye disease.
- To treat small postoperative overcorrections if they result in diplopia.
- To treat deviations secondary to poor vision; for example, if an eye is too phthisical for surgery.

## 8.23 Case-based discussions

### Case 1 Myopic anisometropia

A 6-year-old boy is having difficulty reading the blackboard from the back of the class and his teacher reports this to his parents. His GP refers him to the ophthalmologist after noticing that his visual acuity is 6/18 right and less than 6/60 left. On arrival in clinic, these acuities are confirmed by the orthoptist, who finds no squint. A cycloplegic refraction reveals a refractive error of  $-1.50/-0.50 \times 180$  in the right eye and  $-5.0/-0.75 \times 180$  in the left. With this correction he can see 6/6 right and 6/36 left.

1. What is the most likely diagnosis?
2. What other examinations would you perform?
3. Why is it important that the refraction is performed with cycloplegia in this case?
4. How would you treat this boy?
5. What factors might you consider if the treatment is not working?

#### Discussion

1. It appears that this boy has myopic anisometropia with anisometropic amblyopia in the left eye.
2. It is important to check for other possible causes of amblyopia and reduced vision. Ocular alignment is normal, but his eyes must be examined for causes of stimulus deprivation such as cataract. Dilated fundoscopy is mandatory to check for posterior pathology.
3. Cycloplegia will help to achieve an accurate refraction in this case. Six-year olds have large accommodative reserves, and overestimation of myopia is easy if a subjective refraction is attempted in this age group.
4. The first treatment is with full-time spectacle wear, which may be enough to improve vision in the left eye. However, if the left visual acuity has not responded within a couple of months, the left amblyopia should be treated with patching therapy of the right eye.
5. Lack of compliance with treatment is unfortunately a relatively common occurrence in amblyopia treatment, as children may object to wearing patches and spectacles. However, if treatment is not working, consideration must be given to other causes and the eyes re-examined for subtle pathologies such as optic nerve hypoplasia. It may also be desirable to obtain electrodiagnostic tests to give an objective assessment of integrity of the visual pathways.

### Case 2 Esotropia

#### Part 1

The parents of a 3-year-old girl notice that one of her eyes turns inwards some of the time. This happens mostly when she is concentrating on small near objects and is worse when she is tired. Her parents think it can be either eye that turns inwards. She is otherwise very well and developmentally normal for her age.

1. What are the possible diagnoses?
2. Is she likely to have amblyopia?
3. Is she likely to have BSV?

#### Discussion of Part 1

1. She appears to have an intermittent esotropia with the angle worse for near. This may be fully or partially accommodative, or of a non-refractive convergence excess type.
2. She may well have no amblyopia, as intermittent and freely alternating types of strabismus may allow equal vision to develop in both eyes.

3. She is quite likely to have at least some degree of binocular vision, as her squint is intermittent.

#### Part 2

Refraction reveals hypermetropia of  $+6.0\text{DS}$  (Dioptres sphere) in both eyes, with visual acuity 6/5 with this correction. Prism cover testing reveals a deviation of  $30\Delta$  for near and  $8\Delta$  for distance without her glasses, but this is reduced to a small esophoria with the spectacles.

4. Her parents would like to know whether she should have surgery at any stage, and whether she will always need to wear glasses. What would you tell them?

#### Discussion of Part 2

4. She appears to have a fully accommodative esotropia. The treatment for this is correction of the refractive error, and surgery should not be necessary. If surgery is performed in these circumstances, the risk of inducing an exotropia is high, especially if refractive correction continues to be worn. With this degree of hypermetropia it is likely that she will always need to wear glasses to achieve good visual acuity as well as for control of the strabismus, although parents are often reassured to hear that the squint may get better as she gets older and that contact lenses will be an option when she is old enough.

### Case 3 Infantile esotropia

A mother has noticed that her baby's left eye has turned inwards since soon after birth. He was born by emergency Caesarean section at full term, but is now thriving. They attend the clinic when he is 6 months old, and the orthoptist finds a large ( $50\Delta$ ) constant left esotropia with cross fixation.

1. What is the diagnosis?
2. What could be one differential diagnosis, and how might you examine for this?
3. Is he likely to develop amblyopia?
4. Is he likely to develop BSV?
5. What other associated signs may develop in this condition?
6. Is he likely to need surgery?

#### Discussion

1. This child appears to have a left infantile esotropia.
2. One differential diagnosis that must be excluded is a congenital sixth nerve palsy. In such cases, the child will be unable to abduct the eye even when the other eye is occluded. However, children who cross fixate may be unwilling to abduct the affected eye even in the absence of a sixth nerve palsy. If abducens nerve palsy is suspected, a CT scan of the heads and orbits should be considered.
3. Cross fixation is often protective against amblyopia in infantile esotropia. Such children must be monitored closely for development of amblyopia after surgery changes the ocular alignment.
4. Infantile esotropia is generally incompatible with BSV. Even with early corrective surgery, development of BSV is often disappointingly poor.
5. DVD and manifest latent nystagmus commonly develop even if they are not present at diagnosis.
6. Surgery is recommended in infantile esotropia to correct the cosmetically very noticeable deviation and in an attempt to trigger development of BSV. Bilateral recession of the medial recti is most commonly performed.



## Case 4 Orbital floor fracture

A 23 year-old man presents via casualty 1 week after being punched in the right eye during a bar fight. He reports that even though the swelling is starting to go down, he is experiencing double vision in both up- and downgaze. On examination, visual acuity is normal but there is slight enophthalmos of the right eye.

1. What is the likely diagnosis?
2. Is the deviation concomitant or incomitant?
3. What investigations would you request? What might they show?
4. Is he likely to need surgery?

### Discussion

1. He has probably sustained an orbital floor fracture. Diplopia is due to entrapment of the inferior oblique or its surrounding tissues in the defect.
2. Incomitant.
3. A CT scan would confirm the fracture and give an idea of which tissues are entrapped. A Hess chart would document the incomitant deviation; it would show smaller fields on the right with compression of the upper part of the field and overaction of the left elevators. This is a mechanical pattern. A forced duction test could be performed to confirm which muscles are restricted.
4. The diplopia could be monitored with sequential Hess charts and surgery in the early phase is not essential, especially since there is no diplopia in primary. Diplopia in upgaze is infrequently disabling, but if the diplopia in downgaze persists he is likely to benefit from orbital floor fracture repair. This may also help cosmetically if enophthalmos persists. Squint surgery is sometimes required if diplopia persists after repair of the fracture.

## Case 5 Consecutive exotropia

A 45 year-old woman is concerned that her left eye has become divergent over the past year or so. She had squint surgery and some patching as a child but cannot recall what type of strabismus she had

or what surgery was performed. On examination she has a left exotropia of 30Δ. Visual acuity is good at 6/6 right and 6/9 left. Her exotropia is now constant and she is keen for surgical correction.

1. What is the diagnosis and what type of squint was she most likely to have had as a child?
2. What signs might give a clue to her previous surgery?
3. Is postoperative diplopia a possibility and how might you check this before surgery?

### Discussion

1. This is a consecutive exotropia. It is most likely that her original surgery was for an esotropia.
2. Signs of scarring from previous surgery may sometimes be seen on the conjunctiva overlying the muscles involved. This can help in understanding what has been done previously; for example, in this case, she might have scars of a previous recess/resect procedure, or bimedial recessions if she had infantile esotropia. It is helpful when planning surgery to know whether any of the muscles on which you plan to operate have had previous surgery and could have surrounding scar tissue.
3. Postoperative diplopia is a possibility, especially if she is found to have limited binocular function, as surgery might move an eye out of its area of suppression. The postoperative diplopia test can check for this: the patients fixates a penlight and prisms are gradually introduced until the deviation is slightly overcorrected. If the patient notices diplopia at any point then postoperative diplopia is a possibility. If this is the case, a botulinum toxin injection could be given to the left lateral rectus to see whether temporary correction of the deviation produces significant diplopia for the patient.

*This page intentionally left blank*

## Chapter 9

# Neuro-ophthalmology

Venki Sundaram and John Elston

---

### Basic sciences

- 9.1 Visual pathway and pupil reflex anatomy 356
- 9.2 Cranial nerve anatomy 358

---

### Clinical skills

- 9.3 Neuro-ophthalmology history taking 360
- 9.4 Neuro-ophthalmology examination I 362
- 9.5 Neuro-ophthalmology examination II 364
- 9.6 Neuroimaging 366

---

### Clinical knowledge

- 9.7 Chiasmal visual pathway disorders 368
- 9.8 Retrochiasmal visual pathway disorders 370
- 9.9 Optic nerve disorders I 372
- 9.10 Optic nerve disorders II 374
- 9.11 Papilloedema and idiopathic intracranial hypertension 376
- 9.12 Congenital optic nerve disorders 378
- 9.13 Cranial nerve palsies I 380
- 9.14 Cranial nerve palsies II 382
- 9.15 Nystagmus 386
- 9.16 Supranuclear eye movement disorders 388
- 9.17 Pupil abnormalities 390
- 9.18 Headache 392
- 9.19 Non-organic visual loss 393
- 9.20 Neuromuscular junction disorders 394
- 9.21 Ocular myopathies 395

---

### Case-based discussions

- 9.22 Case 1 Acute visual loss 396
- Case 2 Sudden-onset diplopia 396
- Case 3 Headache 396
- Case 4 Anisocoria 397
- Case 5 Nystagmus 397

## 9.1 Visual pathway and pupil reflex anatomy

### Visual pathway anatomy

The visual pathway extends from the globe through to the visual cortex. As the anatomy of various aspects of the globe are covered elsewhere, this section focuses on the visual pathway from the optic nerve to the visual cortex.

#### Optic nerve

The optic nerve extends from the globe to the optic chiasm, and can be divided into four parts: intraocular, intraorbital, intracranial, and intracranial. The intraocular part is 1 mm long and includes the optic disc. It contains retinal ganglion cell axons and exits posteriorly through the lamina cribrosa. The intraorbital part is 25 mm long and has myelinated covering. It exceeds the distance from the globe to the optic foramen by 8 mm, thus allowing free ocular movement except in severe proptosis. The intracranial part is 5 mm long and begins at the optic foramen (within the lesser wing of the sphenoid bone). The nerve does not move freely within the optic canal and is particularly vulnerable to intracranial and traumatic lesions. The intracranial part is 12–16 mm long and passes upward, backward, and medially to reach the optic chiasm. Blood supply of the intraocular part is from the short posterior ciliary arteries, via the anastomotic circle of Zinn. The rest of the optic nerve receives its blood supply from the ophthalmic artery via the pial plexus, with the intracranial part also receiving supply from the superior hypophyseal artery.

#### Optic chiasm

The optic chiasm lies approximately 10 mm above the pituitary gland (which sits in the sella turcica of the sphenoid bone) with the cerebrospinal fluid-filled space in between called the suprasellar cistern. Although in the majority of cases, the chiasm is situated directly above the sella turcica, its position may be variable depending on the length of the intracranial part of the optic nerves. In 10% of cases the chiasm is prefixed (due to short optic nerves) and instead overlies the tuberculum sellae. The chiasm is postfixed in another 10% of cases and overlies the dorsum sellae. This is clinically relevant as pituitary tumours that would compress the chiasm in normal chiasmal position may instead compress the optic tract in prefixed cases, and optic nerves in postfixed positions.

The supraclinoid segments of the carotid arteries are directly lateral to the chiasm and the cavernous sinuses lie inferolaterally. Posteriorly the chiasm forms the anterior wall of the third ventricle and its blood supply is from a pial plexus via the circle of Willis.

#### Optic tracts

The optic tracts connect the optic chiasm to the lateral geniculate nuclei. Each optic tract conveys nerve fibres from the ipsilateral temporal retina and contralateral nasal retina. Lesions in the optic tract therefore produce homonymous hemianopias, which are not congruous (similar), as the optic tracts do not maintain strict retinotopic architecture. Blood supply is from pial arteries with branches from the anterior choroidal, posterior communicating, and middle cerebral arteries.

#### Lateral geniculate nuclei

The lateral geniculate nuclei are situated on the under surface of the pulvinar of the thalamus. The nuclei are divided into six neuronal layers, with axons from the contralateral eye synapsing in layers 1, 4, and 6; and from the ipsilateral eye synapsing in layers 2, 3, and 5. The layers are further divided into magnocellular (fast motion/low fine detail) and parvocellular (slow motion/high fine detail) layers for further visual information processing. Each lateral geniculate nucleus therefore receives information from both retinas. Blood supply is via middle and posterior cerebral arteries.

#### Optic radiations

The optic radiations convey information from the lateral geniculate nuclei to the visual cortex. Superior optic radiations (carrying inferior retinal fibres) pass through the parietal lobe and terminate on the superior lip of the calcarine fissure in the visual cortex. Inferior optic radiations (carrying superior retinal fibres) pass inferiorly and laterally through the temporal lobe and terminate in the inferior lip of the calcarine fissure. Macular fibres pass between the superior and inferior optic radiations. Anteriorly the optic radiations are supplied by the anterior choroidal branch of the internal carotid artery, and posteriorly by the middle and posterior cerebral arteries.

#### Visual cortex

The visual cortex is situated in the occipital lobe and is divided into primary and secondary visual areas. Each primary visual area represents the contralateral visual field. Furthermore, the upper visual field is represented below the calcarine sulcus and the lower visual field above it. The anterior part of the primary visual cortex represents the visual periphery and is supplied by the posterior cerebral artery. Macular function is represented posteriorly just lateral to the tip of the calcarine fissure, and is supplied by the middle cerebral artery. The secondary visual areas surround the primary visual areas on the medial and lateral surfaces of each hemisphere. They assist in the interpretation and recognition of images.

## Pupil reflex pathways

Pupil response to light, near target, and sympathetic stimulation occur via different anatomical pathways.

### Parasympathetic pathway (light reflex)

1. Afferent impulses originate from the retina and travel to the pretectal nucleus, which lies close to the superior colliculus. Nasal retinal impulses from each eye are conveyed by neurons that decussate at the chiasm, terminating in the contralateral pretectal nucleus. Temporal retinal impulses terminate in the ipsilateral pretectal nucleus.
2. Each pretectal nucleus connects with both Edinger–Westphal nuclei (parasympathetic nuclei) of the oculomotor nerve. This allows bilateral pupil constriction on unocular light stimulation.
3. Parasympathetic preganglionic fibres travel through the inferior division of the oculomotor nerve, reaching the ciliary ganglion in the orbit.
4. Postganglionic parasympathetic fibres pass through the short ciliary nerves to innervate the constrictor pupillae muscles of the iris.

### Parasympathetic pathway (near reflex)

1. Afferent impulses pass from the retina, through the visual pathway to the visual cortex. The visual cortex is connected to the frontal eyefield, from where cortical fibres descend through the internal capsule to the oculomotor nuclei in the midbrain.
2. The oculomotor nerve travels to supply the medial recti allowing convergence, with some fibres synapsing with the Edinger–Westphal nuclei and contributing towards pupil constriction. Accommodation is also stimulated through impulses from the short ciliary nerves.

### Sympathetic pathway

1. Impulses originate in the posterior hypothalamus and descend the brainstem to the ciliospinal centre of Budge, in the intermediolateral horn of the spinal cord, around T1.
2. Preganglionic neurons then carry signals to the superior cervical ganglion, in the upper part of the neck.
3. Postganglionic neurons travel along the internal carotid artery, entering the cavernous sinus to join the ophthalmic division of the trigeminal nerve. Sympathetic fibres then reach the ciliary body and dilator pupillae muscles via the nasociliary and long ciliary nerves.

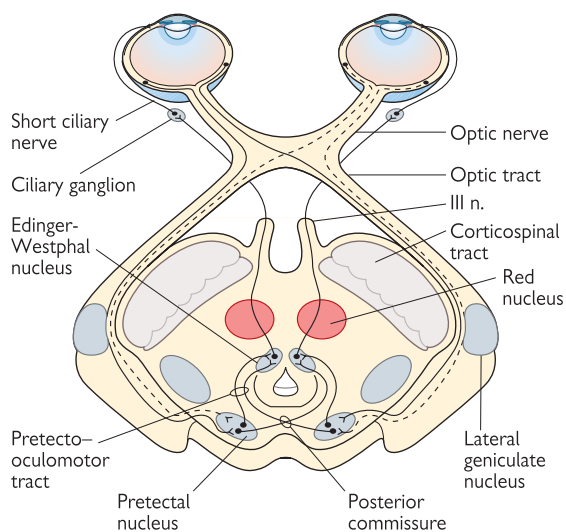


Fig. 9.1 Light reflex pathway.

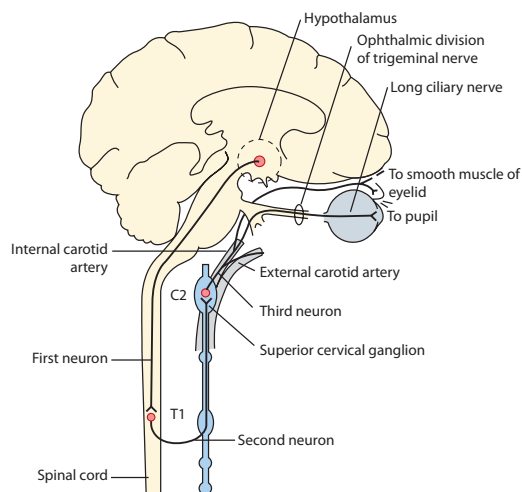


Fig. 9.2 Sympathetic pupil pathway.



## 9.2 Cranial nerve anatomy

Aside from the optic nerve, the other cranial nerves that are most relevant in ophthalmology are the third (oculomotor), fourth (trochlear), and sixth (abducens) nerves. An understanding of the anatomy and function of these cranial nerves is helpful in recognizing clinical signs and using these to locate underlying pathology.

### Third cranial nerve

The third nerve (also known as nerve III) supplies all the extraocular muscles, except the superior oblique and lateral rectus. It also gives innervation to the levator palpebrae superioris and carries pupillary fibres.

#### Nuclei

The third nerve has two motor nuclei: the main motor nucleus and the accessory parasympathetic nucleus (Edinger–Westphal nucleus).

The main motor nucleus is situated in the midbrain, at the level of the superior colliculus. It is subdivided into the following subnuclei:

- central caudal nucleus: this single nucleus innervates both levator palpebrae superioris,
- superior rectus subnuclei: each subnucleus innervates the contralateral superior rectus,
- medial rectus, inferior rectus and inferior oblique subnuclei: provide innervation to their respective extraocular muscles.

The accessory parasympathetic nucleus is situated posterior to the main motor nucleus and receives fibres from the pretectal nucleus for the light reflexes, and corticonuclear fibres for the accommodation reflex.

#### Course

The fascicles of the third nerve leave the nuclei and pass through the midbrain, traversing the medial longitudinal fasciculus, red nucleus, substantia nigra, and crus cerebri before emerging into the subarachnoid space from the anterior aspect of the midbrain, medial to the cerebral peduncle. It then moves forward and laterally, passes between the posterior cerebellar and superior cerebellar arteries, and runs alongside the posterior communicating artery. On the lateral side of the anterior clinoid process, the third nerve perforates the dura mater, entering the cavernous sinus, where it runs along the lateral wall, superior to the fourth nerve. In the anterior cavernous sinus, the third nerve divides into superior and inferior divisions, both of which enter the orbit through the superior orbital fissure (within the tendinous ring). The superior division ascends lateral to the optic nerve, supplies the superior rectus and then terminates by supplying the levator palpebrae superioris. The inferior division divides into three branches to supply the medial and inferior recti, and inferior oblique muscles. The nerve to inferior oblique gives rise to a further branch that carries parasympathetic fibres to the ciliary ganglion.

### Fourth cranial nerve

The fourth cranial nerve (nerve IV) supplies the contralateral superior oblique muscle. It is the thinnest cranial nerve with the longest intracranial course, and is the only one to exit from the dorsal brainstem.

#### Nuclei

The fourth cranial nerve nuclei lies inferior to the third nerve nuclei, at the level of the inferior colliculus in the midbrain. It receives input from the vestibular system and medial longitudinal fasciculus.

#### Course

The fascicles of the fourth nuclei travel dorsally and exit the midbrain, just caudal to the inferior colliculus. The nerve immediately

decussates and passes forwards and laterally within the subarachnoid space, around the cerebral peduncle. It runs along with the third nerve, between the posterior and superior cerebellar arteries, and pierces the dura mater just below the free border of the tentorium cerebelli. It then passes forward along the lateral wall of the cavernous sinus, lying below the third nerve and above the ophthalmic division of the fifth cranial nerve. It enters the orbit through the superior orbital fissure (outside the tendinous ring) and passes medially above the origin of levator palpebrae superioris before reaching the superior oblique muscle.

### Sixth cranial nerve

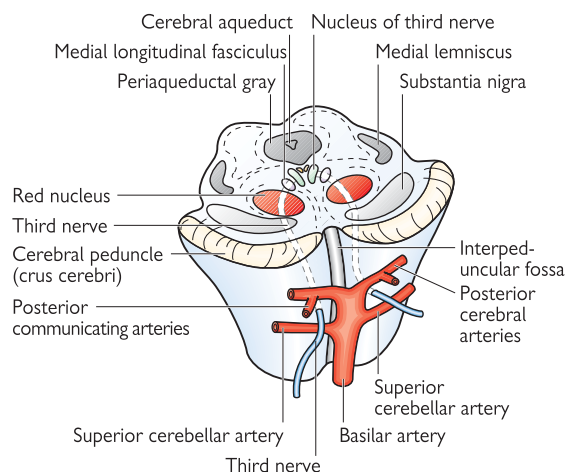
The sixth cranial nerve (nerve VI) supplies the ipsilateral lateral rectus muscle. However, 40% of cells in its nuclei are interneurons which project (via the medial longitudinal fasciculus) to the contralateral medial rectus subnucleus.

#### Nuclei

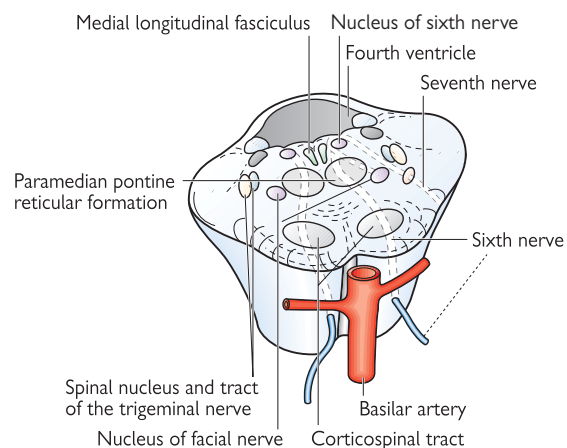
The sixth nerve nuclei lie in the pons, just beneath the floor of the upper part of the fourth ventricle. The fasciculus of the seventh cranial nerve wraps around the sixth nerve nuclei, and damage in this area can result in an associated facial palsy.

#### Course

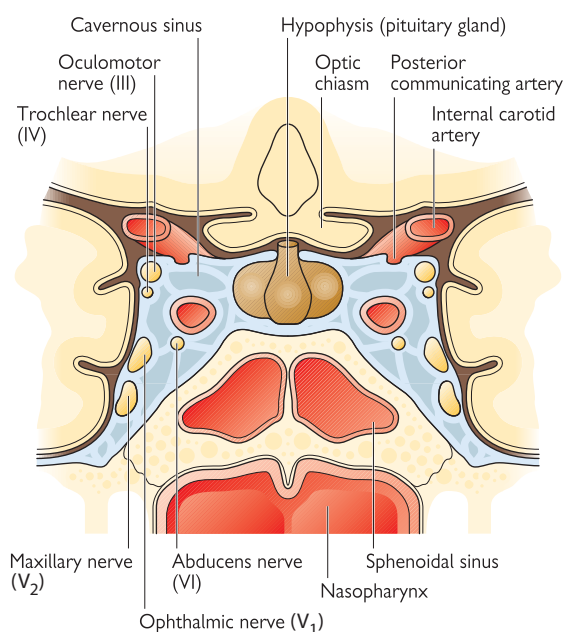
The sixth nerve fascicles traverses the paramedian pontine reticular formation (involved in horizontal eye movement) and corticospinal tract, before leaving the anterior surface of the brain between the lower pons and medulla oblongata. The nerve then runs upwards, forward, and laterally, piercing the dura mater just lateral to the dorsum sellae of the sphenoid bone. Here it makes an acute bend forward across the sharp upper border of the petrous part of the temporal bone, near its apex. It then passes forward within the cavernous sinus, running inferolateral to the internal carotid artery. It enters the orbit through the superior orbital fissure, between the two divisions of the third nerve, and terminates on the medial surface of the lateral rectus.



**Fig. 9.3** Anatomy of third nerve nuclei within the midbrain. Adapted from Yanott and Duker (2004) *Ophthalmology*, 2nd Edition, with kind permission of Elsevier.



**Fig. 9.4** Anatomy of sixth nerve nuclei within the pons. Adapted from Yanott and Duker (2004) *Ophthalmology*, 2nd Edition, with kind permission of Elsevier.



**Fig. 9.5** Relationship of cranial nerves within the cavernous sinus (coronal section).

## 9.3 Neuro-ophthalmology history taking

### Introduction

The optic nerve and visual pathways are potentially subject to a variety of ocular, intracranial, and systemic pathology. Although a high proportion of ophthalmic conditions can be diagnosed on clinical examination alone, accurate history taking is of particular importance in neuro-ophthalmic disorders as several different conditions may present with similar clinical signs (e.g. in optic neuropathies). Good history taking is more likely to help reach the correct diagnosis with the avoidance of unnecessary investigations.

### Presenting complaint

Symptoms that could indicate a neuro-ophthalmic aetiology include visual disturbance, diplopia, headache, and pain on eye movements.

#### Visual disturbance

Key aspects to elicit from a history of visual disturbance include the following.

##### *Unilateral or bilateral visual disturbance*

Unilateral visual loss is suggestive of ocular or optic nerve pathology whereas binocular visual disturbance occurs following lesions at or posterior to the optic chiasm.

With binocular loss it is important to ascertain whether it is bitemporal (in chiasmal disorders) or homonymous (retrochiasmal lesions). Patients with a homonymous hemianopia may complain of difficulty reading as they are unable to follow lines of text. Patients with advanced bitemporal loss may mention that they are not aware of objects coming towards them from the side, until late.

##### *Extent of visual loss*

Severe visual loss, affecting the majority of the unilateral visual field can occur with optic neuropathies. Altitudinal visual-field loss is common with anterior ischaemic optic neuropathy. Unilateral, segmental visual loss is more common with retinal disorders such as retinal detachment and branch retinal or vein occlusion.

##### *Speed of onset*

Sudden onset visual disturbance suggests an ischaemic cause and gradual onset is more typical of compressive causes. Visual loss progressing over a few hours to days can occur in optic neuritis.

##### *Duration of visual loss/any recovery*

Visual recovery occurs within several weeks in typical cases of optic neuritis, whereas spontaneous improvement in vision is less common with ischaemic optic neuropathies.

##### *Disturbance of colour vision*

Optic nerve disorders typically result in decreased colour vision, and this may be disproportionate to the level of visual acuity loss. Patients may complain of a 'greying' of their vision.

##### *Positive or negative scotomas*

Positive scotomas, where patients are aware of a particular part of the visual field being obstructed, occur in retinal lesions. In contrast, with negative scotomas, patients are not specifically aware of an area of diminished vision and this may only be identified with visual-field testing.

##### *Associated pain*

Retrobulbar pain and pain on eye movements can occur in optic neuritis.

##### *Transient visual loss*

Transient visual loss is most commonly due to thromboembolic disease. However, important neuro-ophthalmic associations include temporal arteritis and papilloedema, which can both cause intermittent episodes of visual disturbance prior to more permanent visual loss.

### Visual loss in children

Children are commonly referred to ophthalmologists regarding concerns about their visual development. Assessment can be difficult as children rarely complain of even severe unilateral visual loss, up to the age of approximately 10 years. In addition, bilateral visual loss may not be symptomatic until very advanced. A full pregnancy, birth, developmental, and family history is essential. In older children, one should ask about specific symptoms of headache, diplopia, and pain on eye movement.

### Diplopia

With diplopia it is important to ascertain whether it is binocular or more rarely monocular, when it is likely to be due to a refractive cause.

Other aspects of diplopia to enquire about include the following.

#### *Vertical or horizontal diplopia*

Vertical diplopia is usually a result of vertical recti or oblique muscle disorders (e.g. in fourth nerve palsies where patients can have difficulty while looking down when descending stairs). Horizontal diplopia typically arises following horizontal recti involvement (e.g. in sixth nerve palsies where patients have horizontal diplopia that is worse when looking to the side of the affected muscle).

#### *Speed of onset*

Diplopia of abrupt onset is more likely to be vascular in origin, whereas progressive diplopia suggests a compressive cause.

#### *Variability*

Variability of diplopia may occur in myasthenia gravis and is typically worse with fatigue. Breakdown of phorias and thyroid eye disease can also give intermittent diplopia.

#### *Pain*

Diplopia associated with pain can occur in compressive third nerve lesions, cranial nerve infarction in temporal arteritis, and inflammatory orbital conditions such as myositis and pseudotumour.

#### *Pupil involvement*

A dilated pupil in the presence of diplopia should raise suspicion of a compressive third nerve lesion. Patients may also have a new-onset ptosis and headache.

#### *Associated neurology*

Diplopia in the context of multiple cranial nerve palsies implies either brainstem disease or peripheral lesions such as cavernous sinus or orbital apex pathology. Symptoms of weakness, dizziness, bladder dysfunction, and hearing problems should also be enquired about.

### Headache

Headache (see section 9.18) is a common presenting complaint, with a wide differential diagnosis, but features that are of particular concern include:

- temporal headache with other symptoms of jaw ache, malaise, and joint pains (e.g. in temporal arteritis),
- headache worse in morning and associated with nausea and vomiting (e.g. in raised intracranial pressure),
- associated with visual disturbance (e.g. intermittent visual loss in papilloedema),
- sudden-onset and severe headache (may represent an intracranial aneurysm or bleed),
- systemic features such as weight loss, night sweats, or fever.

Other features of headache to consider include the following.

**Red eye versus white eye**

A wide range of ocular conditions can give rise to headache in the presence of a red eye, providing clues to the diagnosis. Non-ocular conditions such as cluster headache can similarly produce headache with a red eye. In addition, early iritis and ocular ischaemia can sometimes be missed when assessing patients with headache who have a seemingly normal ocular examination.

**Localized versus generalized headache**

Frontal, localized headache may occur with ocular use (e.g. refractive errors, convergence spasm) or without ocular use (e.g. tension headaches, sinus-related pain). Unilateral headache can occur with migraine, neuralgia, and importantly in temporal arteritis. Generalized headache may result from intracranial lesions, trauma, tension, and depression. Irrespective of the location of the headache it is essential to be aware of the possibility of potentially life-threatening conditions being present.

**Past medical history**

Enquire about any atherosclerotic risk factors that are common in vascular neuro-ophthalmic conditions (e.g. ischaemic optic neuropathies, visual pathway infarctions). Ask about any history of cancer, which may be relevant in space-occupying intracranial lesions or compressive optic neuropathies. Previous trauma or surgery to the head and neck region should also be elicited. Any psychiatric history may be relevant in functional visual loss.

**Drug history**

A variety of medications can result in optic neuropathy including ethambutol, isoniazid, amiodarone and cyclosporin. Recreational drug use should also be asked about, especially in the context of atypical pupil abnormalities.

**Family history**

A family history of multiple sclerosis is common in patients with optic neuritis and often patients are particularly anxious about this association. Congenital optic disc disorders may also have a family association, and enquiring about other family members can help reveal inheritance traits that can be helpful in future genetic counselling.

**Social history**

Alcohol and tobacco consumption are relevant in nutritional causes of optic neuropathy. Previous exposure to toxins such as lead and carbon monoxide can also cause optic nerve dysfunction. Occupation is important as visual loss may severely affect eligibility to continue working in certain professions. Sexual behaviour may need to be enquired about if neuro-ophthalmic manifestations of sexually transmitted diseases (e.g. syphilis, AIDS) are present.

**Systems enquiry**

- Multiple sclerosis may also have symptoms of weakness, paraesthesia, and bladder dysfunction.
- Thyroid eye disease can result in optic nerve compression and patients may have symptoms of hyperthyroidism with heat intolerance, weight loss, irritability, and anxiety.
- Proximal weakness, dysphagia, and worsening of fatigue towards the end of the day can occur in myasthenia gravis.
- Emboli may occur in patients with atherosclerotic disease and MRI is contraindicated in patients with pacemakers.
- Hypertensive or diabetic nephropathy may be relative contraindications to the use of contrast in CT scanning.
- Hearing loss, tinnitus, and balance problems may occur in conditions such as acoustic neuroma, and often have neuro-ophthalmic manifestations.
- Joint pains and skin rashes may occur in underlying rheumatological and collagen vascular diseases.

## 9.4 Neuro-ophthalmology examination I

### Visual-fields examination

A thorough visual-fields examination is important in identifying any defects, which can help to locate important intracranial pathology. Lesions at various parts of the visual-field pathway tend to produce characteristic field defects. Visual-field defects detected by confrontation should be confirmed using formal perimetry.

#### Examination routine

1. Observe the patient generally for any signs of a stroke (e.g. hemiplegia) or pituitary lesion (e.g. features of acromegaly).
2. Sit approximately 1m away from patient with eyes at a similar level.
3. Ask patient to cover their left eye (with palm of their hand) and to look at your face. Enquire whether any face parts are missing or blurred to detect any gross visual abnormality in the right eye.
4. Test peripheral visual field of right eye using a white pin. While the patient looks at your left eye, bring the white pin in from the periphery and ask the patient to say 'yes' when the white pin first comes into view. Repeat for each of the four quadrants. If a field defect is detected, map out the defect by moving the white pin into the defect area from an adjacent normal area, asking when the white pin disappears. Pay attention to the size of the defect and whether it crosses the vertical or horizontal midline. Repeat steps 3 and 4 with the patient's left eye.
5. Test the central (30°) visual field of the right eye using a red pin. With their left eye covered, ask the patient to again look at your left eye with their right eye. Show them the red pin and confirm that they can see it as being red. Now bring the red pin in from the periphery and ask the patient to say 'yes' when they first see the pin as being red (not just when they first see it). Continue moving the red pin towards the centre, checking whether they still see the pin as red. Repeat for each of the four quadrants and then test the other eye.
6. Test the patient's blind spot using the red pin, by comparing it with the size of your own blind spot. Move the red pin in nasally from the periphery until the patient's blind spot is located. Then move the red pin slowly upwards, downwards, left, and right and each time ask the patient to say 'gone' when the pin disappears and 'back' when it returns to view. Repeat for other eye.
7. If no peripheral or central field defect has been found, test for red desaturation (which is present in early chiasmal compression). Hold up two red pins either side of the vertical midline. Ask the patient whether both pins are the same shade of red, or is one pin less red than the other.

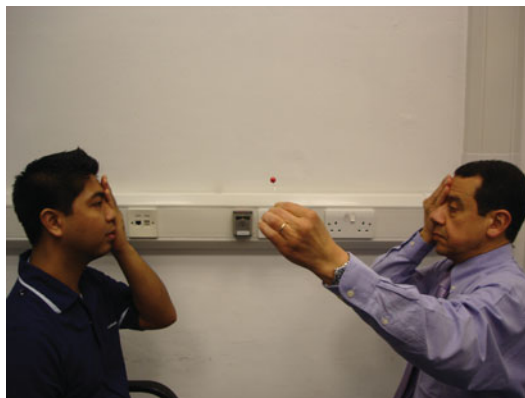


Fig. 9.6 Photograph demonstrating examination of the visual field.



## Optic nerve assessment

Optic nerve disease can result in loss of visual acuity, colour vision, and visual fields. An accurate assessment of the optic nerve is important in identifying and monitoring any dysfunction that may be due to serious local and systemic causes.

### Examination routine

1. Measure visual acuity for distance and near (acuity can be affected by a variable amount depending on the underlying pathology).
2. Measure colour vision (Ishihara colour plates most commonly used for convenience):
  - perform the test in adequate light (daylight if possible),
  - start with the test plate (first plate) and allow several seconds to read each of the subsequent 16 plates. Record number of correct plates read (out of 17).
3. Check for a relative afferent pupillary defect (RAPD).
4. Examine the optic disc looking for any disc swelling, haemorrhage, atrophy, collateral vessels, and cupping.

Visual-field defect	Causes
Central scotoma	Demyelinating optic neuropathy
	Compressive optic neuropathy
	Toxic/nutritional optic neuropathy
Enlarged blind spot	Papilloedema
	Congenital disc anomalies
Resecting horizontal midline, e.g. altitudinal, arcuate, nasal step	Anterior ischaemic optic neuropathy
	Glaucoma
	Optic nerve drusen
Bitemporal (not resecting vertical midline)	Tilted optic discs
Junctional scotoma	Anterior chiasmal lesion

5. Perform perimetry (confrontation, manual, automated) to detect any characteristic field defects.
6. Other tests: visual-evoked potential may detect any subtle optic nerve impairment.

### Other colour vision tests

- Farnsworth–Munsell 100-hue test: the most sensitive and time-consuming colour vision test, involving 85 coloured caps which the patient arranges by hue between two reference tiles.
- Farnsworth D15 test: similar to the Farnsworth–Munsell 100-hue test but only uses 15 caps.
- City University test: consists of 10 plates containing a central colour and four peripheral colours. Subjects are asked to match which peripheral colour most closely matches the central colour.

### Differentiating optic nerve from macular disease

Macular disease can similarly result in reduced visual acuity and colour vision, so it can sometimes have overlapping presentations with optic nerve disease. Features that can help differentiate between the two include:

Feature	Optic nerve	Macular
Main complaint	Dark/grey cloud	Distortion
Pain	Sometimes on eye movement	Never
Scotoma	Negative	Positive
Vision	Variably ↓	Very ↓
Colour vision	Very ↓	Normal/mild ↓
RAPD	Present	Absent
Refractive error	Unchanged	Sometimes towards hyperopia
Perimetry	Variable	Central scotoma
Amsler chart	Central scotoma	Distortion
Visual-evoked potential latency	Large delay	Small delay




Fig. 9.7 Ishihara colour vision plates.

## 9.5 Neuro-ophthalmology examination II

### Pupil examination

Pupil abnormalities can result from a variety of conditions, and include irregular pupil size or impaired reflexes to light and accommodation. A thorough pupil examination can help to identify and locate important underlying causes.

#### Examination routine

1. Ask the patient to fixate on a distant target.
2. General observation: look for any anisocoria, heterochromia, ptosis, or ocular deviation.
3. Dark response: measure pupil sizes with ruler and then dim room lights and repeat measurements. If anisocoria is present, the larger pupil in bright conditions is likely to be the abnormal one and vice versa in darker light.
4. Check direct pupil light response: shine torch into one eye and observe the pupil reaction in that eye. Repeat for other eye.
5. Check consensual pupil response: shine torch into one eye, and observe the pupil reaction in the other eye.
6. Check for a relative afferent pupillary defect (RAPD): shine the light into one eye for 2–3 seconds and then quickly swing the light into the other eye. Observe for any initial pupillary dilatation, representing an afferent visual pathway defect.
7. Check accommodation reflex: hold up an accommodative target (e.g. a letter) in front of the patient and observe for pupil constriction as they look from a distant object to the near target.
8. Other: examine patient on the slit lamp, looking for vermiform iris movements (in Adie pupil). Perform eye-movements examination looking for associated nerve palsies. Assess optic nerve function in presence of an RAPD. Perform full neurological examination, particularly checking for decreased deep tendon reflexes (in Holmes–Adie syndrome).

#### Relative afferent pupil defect

When light is shone into the normal eye, both pupils constrict normally. However, when the light is swung into the affected eye both pupils will initially dilate (swinging flashlight test). This is because the stimulus from withdrawing light from the normal eye is greater than that from the light stimulus shone into the affected eye.

An RAPD can still be detected if one eye is pharmacologically dilated. Observation should be on the undilated pupil to assess whether an initial dilatation occurs.

Bilateral APD can also occur which may be symmetrical or asymmetrical depending on the extent of afferent visual pathway damage.

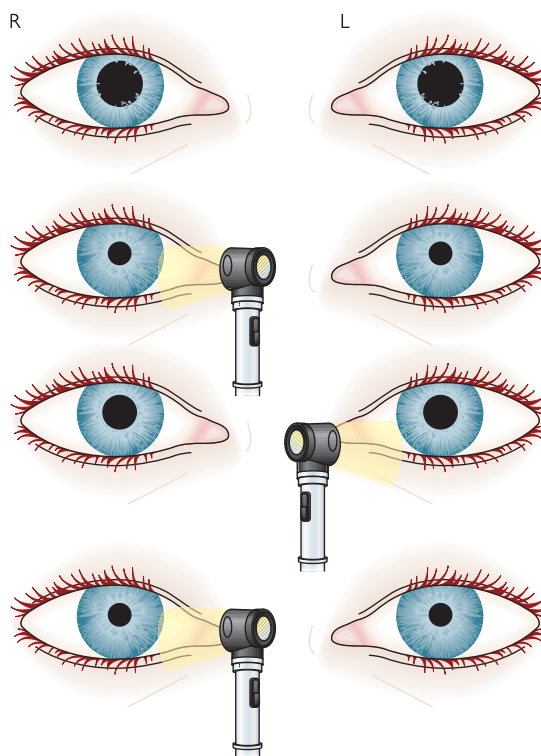


Fig. 9.8 Swinging flashlight test showing a left RAPD.

## Nystagmus examination

The examination of patients with nystagmus or other abnormalities of fixation can initially be daunting and confusing. Using a systematic approach, while considering important questions during the examination process can help to identify the key features, and aid the diagnosis of underlying pathology.

### Examination routine

1. Observe the patient generally, looking for any:
  - abnormal head posture (in congenital causes),
  - signs of visual developmental disorders (e.g. oculocutaneous albinism, aphakic glasses in congenital cataracts),
  - signs of vestibular disease (hearing aids, associated facial nerve palsies),
  - cerebellar signs.
2. Carefully observe the eyes in the primary position and consider whether the nystagmus is:
  - unilateral or bilateral,
  - conjugate (both eyes move in the same direction) or disconjugate,
  - symmetrical (both eyes involved to the same degree) or asymmetrical,
  - jerk (slow initial movement followed by fast recovery movement) or pendular (initial and recovery movements are of equal speed),
  - of other patterns (e.g. see-saw or periodic alternating).
 Also, evaluate the frequency and amplitude of nystagmus, and if jerk nystagmus is present assess which direction is the fast-phase movement.
3. Observe the eyes in all cardinal positions of gaze, checking whether the nystagmus:
  - only occurs on gaze (gaze-evoked nystagmus),
  - occurs equally in all positions of gaze, or whether there is a position where the nystagmus reduces (null point).
4. Check whether nystagmus alters with near fixation.
5. If no obvious nystagmus is present, perform a cover test in each position of gaze checking for latent nystagmus.

## 9.6 Neuroimaging

A wide variety of intracranial pathology can manifest with neuro-ophthalmic features. Neuroimaging, in conjunction with a thorough history and examination, can provide further information on diagnosis, and aid further management. The two most common forms of neuroimaging are CT and MRI.

### CT

CT works by assessing the X-ray attenuation of different tissues. It involves an X-ray tube and detectors which rotate around a patient, allowing images to be acquired at different levels, in coronal or axial cuts. The attenuation of tissues is represented on a greyscale image with structures of high attenuation (e.g. bone, fresh blood) appearing whiter, and tissues of lower attenuation (e.g. fat, soft tissue) appearing greyer.

#### Indications for CT

CT is of particular use in:

- evaluation of bony lesions (trauma, erosion),
- orbital inflammation (thyroid eye disease),
- acute haemorrhage,
- detecting intraocular calcification (retinoblastoma, optic nerve drusen),
- when MRI is contraindicated (metallic foreign bodies).

#### Disadvantages of CT

- Radiation exposure (as opposed to MRI).
- No direct sagittal imaging.
- Bony artefacts can occur.
- Possible adverse reaction to contrast.

### MRI

MRI involves the use of magnetic fields to disrupt the alignment of hydrogen atoms within tissues. Strong magnetic fields cause hydrogen atoms to become more uniformly aligned, parallel to the magnetic field. A radio-frequency pulse is then applied causing the hydrogen atoms to change their alignment. When the radio-frequency pulse is terminated, the hydrogen atoms return to their previous position and, in doing so, emit magnetic energy which is picked up by receivers surrounding the patient. Computer analysis then converts these signals into information on signal intensity and spatial location.

#### Signal intensity

The signal intensity of tissues refers to whether the structure appears bright (high signal) or dark (low signal). This is dependent on the weighting of the scan (T1 or T2), which refers to the method of measuring relaxation times of excited hydrogen atoms.

T1-weighted scans give better anatomical detail, in which cerebrospinal fluid and vitreous emit a low-intensity signal and therefore appear dark, whereas fat appears bright.

T2-weighted scans are considered better for assessing pathological detail as most pathology is associated with surrounding oedema which appears white, as does cerebrospinal fluid and vitreous in these scans.

#### Fat suppression

Fat-suppression techniques (e.g. short time inversion recovery, STIR) are particularly useful when imaging the orbits, as the high signal emitted from orbital fat can obscure adjacent structures, making interpretation difficult.

**Table 9.3 Appearance of different tissues on T1- and T2-weighted scans**

Body tissue	Appearance in T1 scan	Appearance in T2 scan
Bone	Dark	Dark
Vitreous	Dark	Bright
Cerebrospinal fluid	Dark	Bright
White matter	Bright	Dark
Grey matter	Dark	Bright

#### Gadolinium enhancement

Gadolinium is a paramagnetic agent that is used as contrast medium in T1-weighted scans. It is able to pass through breakdowns in the blood–brain barrier, and is therefore used to help detect tumours and other vascular lesions. Side effects of gadolinium use include nausea, vomiting, and hypotension. Contraindications to its use include pregnancy, and haemolytic and sickle cell anaemia.

#### Indications for MRI

MRI is more useful in the evaluation of soft-tissue pathology, including:

- optic nerve (e.g. pathology glioma),
- pituitary tumours,
- demyelinating disease,
- intracranial aneurysms.

#### Disadvantages of MRI

- Contraindicated in patients with metallic objects (e.g. pacemakers, aneurysm clips, foreign bodies).
- Noisy and patients can feel claustrophobic.
- Requires patient to remain motionless.
- Recent haemorrhage can be missed.
- More expensive than CT.

### Magnetic resonance angiography

Magnetic resonance angiography (MRA) is a non-invasive way of imaging the intracranial and extracranial circulations, and assesses signal differences between moving blood and stationary tissue. It is useful in detecting pathology such as aneurysms, arteriovenous malformations, and carotid stenosis. A disadvantage of MRA, however, is that it is poor at detecting aneurysms that are less than 5 mm in diameter.

### Magnetic resonance venography

Magnetic resonance venography (MRV) is similar to MRA, but is more effective in evaluating venous flow, and is particularly useful for identifying venous sinus thromboses.

## System for evaluating ophthalmic-related neuroradiology images

### A. Basics

- Check name, age, and sex of patient, and scan date.
- Confirm whether it is a CT (bone is white) or MRI scan.
- Check whether it is a T1 or T2 image (in MRI scans) and whether contrast has been used.

### B. Assess the following

- Globe: present/enucleated, phakic/aphakic, vitreous opacities, retinal calcification.
- Optic nerve: demyelination, compressive lesions, trauma.
- Extraocular muscles: enlargement, tendon involvement, entrapment.
- Orbit: masses, vascular lesions, wall fractures.
- Other bony structures: sphenoid wing.
- Pituitary region: enlargement, masses, infarction.
- Posterior visual pathway: space occupying lesions/vascular lesions in optic radiations/occipital cortex.

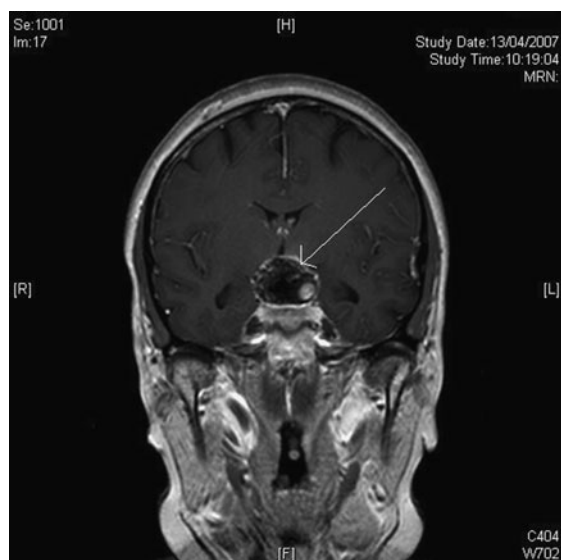

Fig. 9.9 T1-weighted MRI scan showing treated suprasellar aneurysm.

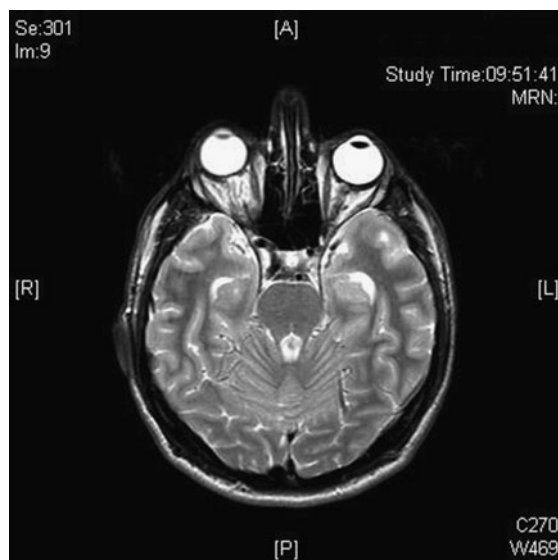


Fig. 9.10 T2-weighted MRI scan showing right optic nerve meningioma.

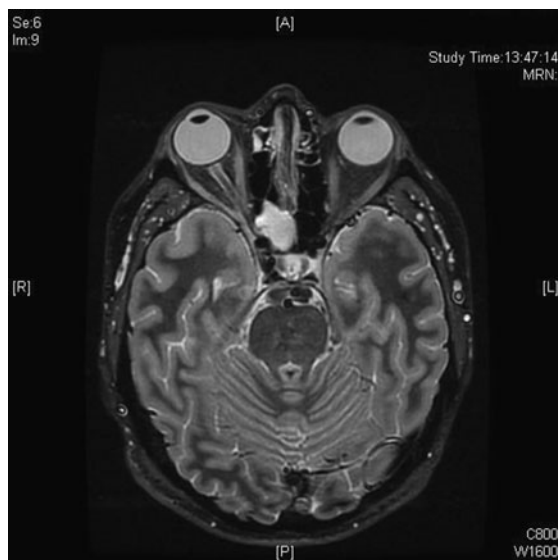

Fig. 9.11 Fat-suppressed MRI scan showing posterior ethmoid sinus lymphoma.

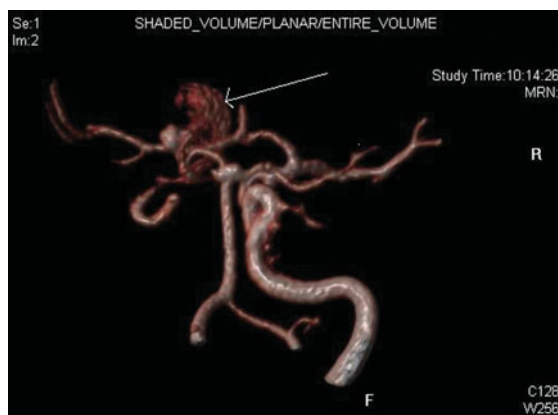


Fig. 9.12 MRA scan of panophthalmic artery aneurysm.



## 9.7 Chiasmal visual pathway disorders

Lesions occurring in the visual pathway from the optic chiasm to the occipital cortex can result in characteristic visual-field defects, providing information about the likely anatomical site of underlying pathology. An awareness of the various patterns of visual-field defect and possible causative lesions is an important part in the evaluation of visual-field disorders.

### Optic chiasm lesions

Chiasmal lesions typically produce a bitemporal hemianopia (which respects the vertical midline) as a result of compression of decussating nasal fibres. However, different clinical presentations may occur depending on the specific site and type of lesion.

#### Aetiology

Causes of chiasmal lesions include:

- tumours:
  - pituitary adenomas,
  - craniopharyngiomas,
  - meningiomas,
  - gliomas,
  - lymphoma,
  - metastases.
- vascular:
  - aneurysms (internal carotid artery),
  - pituitary apoplexy,
  - cavernous haemangiomas.
- trauma.
- demyelination.
- post-radiation.
- inflammation (e.g. sarcoidosis).
- others: Rathke pouch cysts, sphenoid sinus mucocoeles, arachnoid cysts.

#### Clinical evaluation

Patients are often asymptomatic (especially in early stages of disease), however, they may have the following:

#### History

- Symptoms of raised intracranial pressure (headache, nausea, vomiting, pulsatile tinnitus).
- Symptoms of pituitary dysfunction (see Table 9.5).

#### Examination

- Bitemporal field defects (the nature and extent will depend on the precise location of lesion (see Table 9.4).
- Central visual loss if macular fibres affected.
- Post-fixation blindness (disappearance of objects during close work as object is then projected into an area of blindness).
- Diplopia (may arise in patients with pre-existing phoria as separation of hemifields can occur).
- Involvement of other cranial nerves (e.g. III, IV, and VI in cavernous sinus lesions).
- Colour desaturation.
- Optic atrophy.
- See-saw nystagmus.

#### Localization of visual-field defect patterns

Table 9.4 shows the different types of visual-field defects arising from chiasmal lesions, with the corresponding anatomical lesional site and possible causative conditions:

**Table 9.4 Visual-field defects resulting from chiasmal lesions**

Visual-field defect	Lesion site
Superior bitemporal	Inferior chiasmal, e.g. pituitary adenoma (initially compresses inferonasal fibres)
Inferior bitemporal	Superior chiasmal, e.g. craniopharyngioma (initially compresses superonasal fibres)
Junctional scotoma	Anterior chiasmal lesion ipsilateral to side of central scotoma, e.g. sphenoid meningioma
Bitemporal central hemianopic scotomas	Posterior chiasmal, e.g. hydrocephalus
Binasal	Lateral chiasmal, e.g. medial sphenoidal ridge meningioma

### Pituitary adenomas

Pituitary adenomas account for 15% of intracranial tumours and can be functioning or non-functioning. Functioning adenomas often produce systemic symptoms and signs (depending on the resulting hormonal secretion) prior to the onset of visual-field defects. Non-functioning pituitary adenomas are usually larger than 10 mm and have extended beyond the suprasellar cistern before they result in visual-field defects.

**Table 9.5 Clinical features of the various types of functioning pituitary adenomas**

Pituitary adenoma type	Clinical features
Prolactinoma (↑ prolactin)	Women: ↓ libido, weight gain, amenorrhoea Men: impotence, galactorrhoea, ↓ facial hair
Somatotrophic adenoma (↑ growth hormone)	Acromegaly: deep voice, large hands and tongue, prognathism, teeth spacing
Corticotrophic adenoma (↑ adrenocorticotrophin)	Cushing's features: ↑ weight, moon face, central obesity, purple striae
Thyrotrophic adenoma (↑ thyroid-stimulating hormone)	Sweating, anxiety, ↑ appetite, ↓ weight, heat intolerance
Gonadatrophic adenomas (↑ leuteinizing/ follicle-stimulating hormone)	Infertility, obesity, hirsutism

### Pituitary apoplexy

Pituitary apoplexy occurs when infarction or haemorrhage causes sudden enlargement of a pituitary adenoma. It can present with features such as acute headache, vomiting, reduced vision, superior bitemporal field loss, and ophthalmoplegia. Predisposing factors include pregnancy, trauma, diabetes mellitus pituitary irradiation, and obstetric haemorrhage. This life-threatening condition requires treatment with high-dose corticosteroids and hormone-replacement therapy. Trans-sphenoidal tumour decompression may be required if no improvement occurs within 48 hours.

### Craniopharyngiomas

Craniopharyngiomas arise from vestigial epithelial remnants of Rathke's pouch (an embryonal precursor to the adenohypophysis). They are slow-growing tumours occurring mostly in children and occasionally in adults. Treatment is with surgical resection (with or without radiotherapy); however, recurrences are frequent.

## Meningiomas

Sphenoid meningiomas causing optic chiasm compression can arise specifically from the tuberculum sellae, resulting in compression of the junction of the anterior chiasm and optic nerve, with a subsequent junctional scotoma. Meningiomas can also arise superiorly from the olfactory groove, laterally from the medial sphenoidal ridge and posteriorly from the diaphragma sellae.

### Investigations

- Formal visual-field testing to assess field loss at presentation, with repeat testing often required to monitor progress.
- Endocrinology assessment and appropriate pituitary function tests are required if a pituitary adenoma is suspected.
- Urgent MRI scanning (discuss with radiologist) is required in suspected chiasmal involvement, although CT may show bony involvement more clearly.

### Management

This will depend on the underlying cause, with options including:

- medical treatment of pituitary tumours (e.g. bromocriptine use in prolactin-secreting tumours),
- hormone replacement,
- high-dose steroids (in pituitary apoplexy),
- surgical resection,
- trans-sphenoidal decompression,
- radiotherapy,
- gamma knife radiosurgery.

## 9.8 Retrochiasmal visual pathway disorders

Retrochiasmal lesions of the visual pathway result in homonymous hemianopic field defects as each side carries ipsilateral temporal and contralateral nasal hemifield nerve fibres. Homonymous hemianopic defects may be complete or incomplete, depending on the extent of the underlying lesion. They may also be described as congruous (similar) or incongruous, with more posterior lesions resulting in greater congruity as retinotopic arrangements become more manifest towards the posterior visual pathway.

Retrochiasmal visual-field defects are most commonly due to vascular events (e.g. strokes) and tumours, with other causes including trauma, demyelination, abscesses, and migraine. Retrochiasmal lesions can be separated into the specific part of the visual pathway affected (optic tract, lateral geniculate nucleus, optic radiation, and visual cortex) and may result in other neurological features as nearby structures can also be affected.

### Optic tract lesions

Features of a left optic tract lesion can include:

- right incongruous homonymous hemianopia,
- right RAPD (in complete lesions),
- optic atrophy,
- Wernicke's pupil (abnormal pupil reflex when light shone into affected hemiretina).

### Lateral geniculate nucleus lesions

Features of a left lateral geniculate nucleus lesion include:

- right congruous 'wedge' shaped horizontal sectoranopia,
- no RAPD or optic atrophy,
- contralateral mild hemiparesis.

### Optic radiation lesions

The optic radiations carry neurons from the lateral geniculate nuclei to the visual cortex. Inferior retinal fibres travel via the temporal lobe radiations, and superior retinal fibres travel via the parietal lobe radiations to the visual cortex.

Features of a left temporal radiation lesion include:

- right superior incongruous homonymous hemianopia ('pie in the sky' defect);
- associated neurological features:
  - seizures,
  - hallucinations (auditory, olfactory, gustatory, and formed visual),
  - memory loss.

Features of a left parietal radiation lesion include:

- right inferior incongruous homonymous hemianopia ('pie on the floor' defect);
- associated neurological features:
  - contralateral hemiparesis and hemianaesthesia (posterior limb of internal capsule damage),
  - agnosias,
  - impaired pursuit movement to left,
  - optokinetic nystagmus asymmetry when drum rotated to left.

### Visual cortex lesions

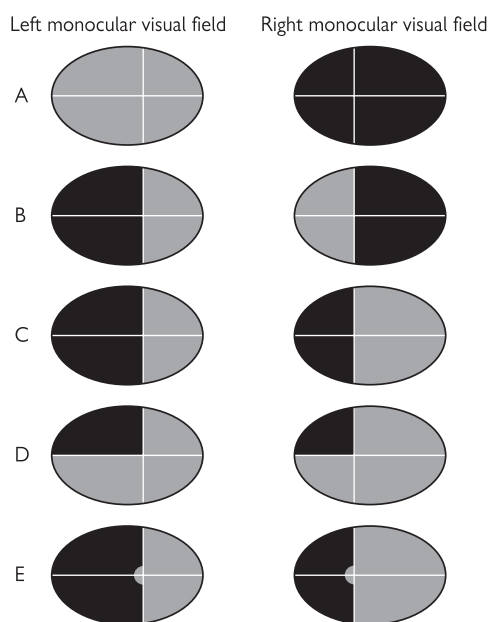
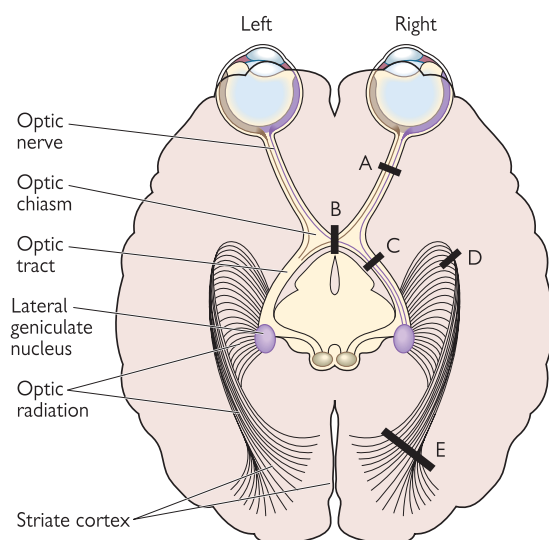
Visual cortex lesions result in a congruous homonymous hemianopia, which may be macular-sparing or macular-involving. The anterior visual cortex represents the peripheral visual fields and is supplied by the posterior cerebral artery, with impairment of its blood supply, resulting in a macular-sparing homonymous hemianopia. The lateral side of the posterior tip of the visual cortex represents central macular function and is supplied by the middle cerebral artery, with interruption of this blood supply causing a macular-involving homonymous hemianopia. A contralateral temporal-field defect (temporal crescent) may occur following a lesion to the most anterior part of the visual cortex, as this region normally represents the extreme temporal field in the contralateral eye.

Associated features of visual cortex lesions include:

- ocular apraxia (eyes can move spontaneously but not on command),
- visual inattention,
- Anton's syndrome (denial of blindness),
- Riddoch's phenomenon (can see moving but not stationary targets).

### Management

- Full neuro-ophthalmic history and examination.
- Investigate for any vascular risk factors.
- Urgent neuroimaging.
- Referral to stroke, neurosurgical, or oncology teams depending on cause.



**Fig. 9.13** Visual-field defects caused by lesions at various parts of the visual pathway.

## 9.9 Optic nerve disorders I

### Optic neuritis

This is inflammation of the optic nerve and is more specifically termed papillitis when the nerve head is swollen; retrobulbar neuritis if the nerve head appears normal and neuroretinitis when retinal nerve fibre layer involvement occurs. The most common form is acute demyelinating optic neuritis, but infective, compressive, and other inflammatory causes exist.

### Acute demyelinating optic neuritis

This condition may occur in isolation, but more commonly occurs in the context of multiple sclerosis. Incidence is 5/100,000 in the general population but occurs in 70% of patients with multiple sclerosis.

#### Risk factors

- Female sex (3:1, female/male).
- Age 20–50 years.
- Caucasian.
- Living in temperate climate.

#### Clinical evaluation

##### History

- Retrobulbar pain (may be worse on eye movement)\*.
- Usually unilateral sudden worsening of vision\*.
- Recovery may start within 2 weeks\*.
- Worsening of symptoms following exercise (Uhthoff's phenomenon).
- May have weakness, numbness, tingling, and other symptoms of multiple sclerosis.

##### Examination

- Reduced colour vision.
- Vision usually decreased but can vary between 6/6 to no perception of light.
- RAPD\* (may be symmetrical in bilateral cases).
- Reduced colour vision and contrast sensitivity\*.
- Visual-field defect: central, caecocentral, arcuate, or altitudinal.
- Normal optic disc appearance in two-thirds of cases (as retrobulbar).
- Papillitis in one-third of cases.

\*Represents the typical features.

##### Differential diagnosis

Other causes of optic neuropathy:

- anterior ischaemic optic neuropathy,
- compressive lesion (e.g. meningioma),
- Leber's hereditary optic neuropathy,
- infections (e.g. syphilis, Lyme disease),
- sarcoidosis,
- toxic/nutritional (e.g. vitamin B12, folate deficiency),
- post-viral.

##### Investigations

If the episode is typical then diagnosis can be made on clinical grounds. However, MRI is useful in determining whether patients are at high risk of developing multiple sclerosis, with two or more white-matter lesions present on scanning being highly predictive of developing clinically definite multiple sclerosis in the future.

If atypical features are present (e.g. not improving after 2 weeks) then the following tests may be required to exclude other serious underlying pathology:

- bloods: FBC, ESR, CRP, urea and electrolytes, glucose, vitamin B12/folate, ACE, ANA, ANCA, VDRL, and mitochondrial DNA analysis (Leber's hereditary optic neuropathy),
- CXR and lumbar puncture.

### Management

In most cases, spontaneous visual improvement occurs with the majority of patients obtaining at least 6/9 vision, although persistent visual disturbances (such as reduced colour vision) may occur.

The Optic Neuritis Treatment Trial (ONTT) has shown that visual recovery may be hastened by giving intravenous methylprednisolone (1 g/day for 3 days) followed oral prednisolone (1 mg/kg for 11 days, then a 4 day taper). This regime has no effect on final visual outcome and is therefore usually only recommended in cases when there is pre-existing poor vision in the other eye.

The ONTT also showed that intravenous methylprednisolone can reduce the rate of development of clinically definite multiple sclerosis in patients with two or more white-matter MRI lesions, but only during the first 2 years of follow-up.

The Controlled High-Risk Avonex Multiple Sclerosis Prevention Study (CHAMPS) showed that interferon  $\beta$ -1a use following an acute episode (or other initial demyelinating event) significantly reduced the 3 year rate of clinically definite multiple sclerosis development in patients with two or more white-matter lesions.

Similarly the Early Treatment of Multiple Sclerosis Study (ETOMS) showed reduced development rate of clinically definite multiple sclerosis (in the first 2 years) in patients who received interferon  $\beta$ -1a within 3 months of an initial demyelinating event.

### Prognosis

- Patients with a normal MRI at presentation have a 16% chance of developing clinically definite multiple sclerosis at 5 years.
- Patients with two or more white-matter lesions on initial MRI scanning have a 51% chance of developing clinically definite multiple sclerosis at 5 years.

### Further reading

Comi G, Fillippi M, Barkhof F *et al.* 2001. Effect of early interferon treatment on conversion to definite multiple sclerosis: a randomised study. *Lancet* **357**: 1576–1582.

Jacobs LD, Beck RW, Simon JH *et al.* 2000. Intramuscular interferon  $\beta$ -1a therapy initiated during a first demyelinating event in multiple sclerosis. *N. Engl. J. Med.* **343**: 898–904.

Optic Neuritis Study Group. 1997. Visual function five years after optic neuritis: experience of the Optic Neuritis Treatment Trial. *Arch. Ophthalmol.* **115**: 1545–1552.



## Compressive optic neuropathies

Intrinsic optic nerve compression is most commonly caused by optic nerve gliomas and optic nerve sheath meningiomas, with other causes being lymphoma, leukaemia, and metastatic tumours. Extrinsic compression can arise from thyroid eye disease and other orbital conditions (see chapter 10).

Patients typically present with a progressive visual loss and may notice reduced colour vision. A RAPD is usually present and the optic disc may appear normal, atrophic or swollen with optociliary shunt vessels. Central scotomas are common.

MRI scanning is needed to evaluate extent of lesion and, in particular, whether intracranial extension has occurred.

With optic nerve gliomas and optic nerve sheath meningiomas, if the vision is good and only intraorbital involvement is present, observation with regular visual-field testing and MRI scanning is appropriate. Other, more aggressive tumours may require urgent radiotherapy or neurosurgical intervention.

## Nutritional/toxic optic neuropathies

This typically presents with a bilateral, painless, and gradual loss of vision. Optic discs can be normal at presentation, or show temporal pallor. Reduced colour vision and bilateral central/centrocaecal visual-field defects are characteristic.

Nutritional causes are commonly due to chronic alcohol and tobacco abuse leading to vitamin B and folate deficiencies. Treatment involves thiamine, folate, vitamin B12, and multivitamin replacements, in addition to reducing alcohol intake and eating a healthier diet.

Causes of toxic optic neuropathy include drugs such as ethambutol, isoniazid, and amiodarone. Visual recovery following cessation of the offending agent can be variable and may be dependent on dose and duration of taking the drug.

## Traumatic optic neuropathies

Head and facial trauma may result in optic nerve damage through primary and secondary mechanisms. Primary causes include direct transection of the optic nerve by orbital bony fragments, or optic nerve ischaemia following avulsion of its nutrient vessels. Secondary mechanisms include optic nerve compression from oedema and haemorrhage surrounding the nerve.

Full ocular examination is warranted to exclude a penetrating eye injury or globe rupture, and a new RAPD (not accounted for by any other ocular pathology) is essential for diagnosis.

High-resolution CT scanning is helpful in determining the precise nature of the injury.

Primary traumatic optic nerve injuries are not treatable and treatment of secondary traumatic optic neuropathies is debatable, with megadose corticosteroids and orbital decompression being used. Evidence from large-scale randomized controlled trials is lacking; however, the International Optic Nerve Trauma Study (comparative,

non-randomized) showed no significant benefit of these treatments, compared to no treatment. Poor prognostic features include loss of consciousness at presentation and blood seen in the posterior ethmoid spaces.

### Further reading

Levin LA, Beck RW, Joseph MP et al. 1999. The treatment of traumatic optic neuropathy: the International Optic Nerve Trauma Study. *Ophthalmology* **106**(7): 1268–1277.

## Leber's hereditary optic neuropathy

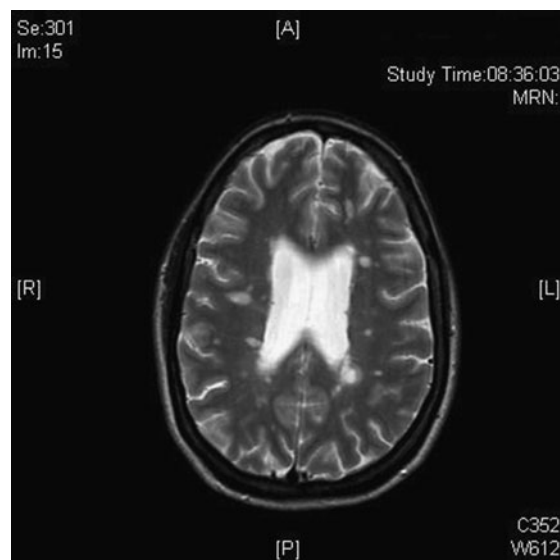
This rare disorder resulting from mutations in maternal mitochondrial DNA typically affects males aged 15–30, although it can occur at any age, and women are also affected. Transmission is by women to all offspring, with up to 70% of sons and 15% of daughters manifesting the disease.

Presentation is usually with an acute, unilateral, and painless visual loss, with the other eye becoming affected within days or weeks.

Vision is typically 6/60 to hand movements, with central scotomas. The optic disc may be normal or show mild disc swelling with telangiectatic vessels, progressing to optic atrophy over weeks.

Blood tests for mitochondrial DNA analysis should be performed, with 11778 being the commonest mutation.

No effective treatment is available and visual recovery is usually poor. Genetic counselling should be offered.



**Fig. 9.14** T2-weighted MRI showing multiple periventricular white-matter lesions.

## 9.10 Optic nerve disorders II

### Anterior ischaemic optic neuropathy

This is a potentially sight-threatening condition caused by giant cell arteritis (GCA) and typically affects people over 50 years of age, with incidence (1/100,000) peaking in the eighth decade.

#### Pathophysiology

GCA is a systemic granulomatous inflammatory disorder affecting large and medium-sized arteries, causing destruction of the internal elastic lamina and vessel occlusion. The superficial temporal, ophthalmic, and posterior ciliary arteries are particularly at risk, resulting in arteritic anterior ischaemic optic neuropathy (AION).

#### Clinical evaluation

##### History

- Sudden, severe, unilateral visual loss (which may be preceded by transient visual disturbances).
- Associated symptoms of GCA: scalp tenderness, temporal headache, jaw claudication, malaise, joint pains, weight loss, and fever.

##### Examination

- Reduced visual acuity.
- RAPD.
- Pale, swollen disc with flame haemorrhages.
- Temporal tenderness and often non-pulsatile temporal artery.
- Optic atrophy in chronic cases.
- May have associated CRAO, cranial nerve palsies, and altitudinal field defects.

##### Differential diagnosis

- Non-arteritic AION.
- Other causes of acute optic neuropathy (see section 9.9).
- Other causes of acute visual loss (CRVO, CRAO).

##### Investigations

- Increased ESR ( $>47$  mm/hour) and increased CRP ( $>2.45$  mg/dL) has a 97% specificity for GCA.
- Platelet count may also be raised.
- Temporal artery biopsy is the gold-standard test for GCA, with focal areas of granulomatous arteritis seen. A negative biopsy doesn't exclude GCA, as skip lesions along the temporal artery may be present. Ideally a temporal artery biopsy should be performed within 3 days of presentation (although biopsy may remain positive for several weeks after) and treatment should not be withheld, pending a biopsy.

##### Management

High-dose systemic corticosteroids are required to prevent visual loss in the unaffected eye and to prevent systemic disease progression. The following steroid regime is recommended:

- intravenous methylprednisolone 1 g/day for 3 days, followed by
- 1–2 mg/kg oral prednisolone daily and reduced by 5 mg weekly depending on reduction in ESR, CRP, and symptoms,
- low-dose steroid maintenance for several years is often required so osteoporosis prophylaxis is important.

##### Prognosis

- Visual recovery in the affected eye is generally poor.
- Untreated, the fellow can be affected in up to 95% of cases with this reducing to 13% on steroid treatment.

### Non-arteritic anterior ischaemic optic neuropathy

This is the most common acute optic neuropathy (incidence 10/100,000, peaking in seventh decade) and results from occlusion of the short posterior ciliary arteries.

#### Pathophysiology

It is proposed that atherosclerotic changes in the short posterior ciliary arteries, particularly in the context of a crowded optic nerve head, results in infarction of the anterior optic nerve.

#### Risk factors

- Hypertension.
- Diabetes.
- Crowded disc with small cup.
- Anaemia.
- Smoking.
- Hyperlipidaemia.
- Hypotensive events.
- Collagen vascular disorders.

#### Clinical evaluation

##### History and examination

- Sudden, painless loss of vision (may occur overnight and can be progressive).
- RAPD.
- Diffuse/sectoral disc swelling or pallor (splinter haemorrhages may be present).
- Visual-field defect: typically altitudinal.

##### Investigations

- ESR/CRP to investigate for GCA.
- Check for atherosclerotic risk factors: blood pressure, FBC, glucose, cholesterol.
- Collagen vascular screen in younger patients.

##### Management

- No proven effective treatment.
- Consider aspirin.
- Treat any underlying abnormalities.

##### Prognosis

- 40% of patients improve vision by two or more Snellen lines.
- 19% chance of other eye being affected by 5 years.

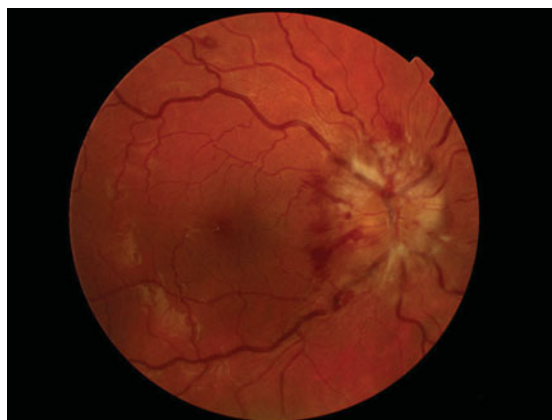## ⊕ Temporal artery biopsy

The frontal branch of the superficial temporal artery is commonly chosen because of its accessibility and high degree of involvement in GCA. The artery lies in the superficial temporal fascia, just deep to the subcutaneous fat.

Complications of this procedure include bleeding (intra- and postoperatively), stroke, facial nerve damage, and scar formation.

### Procedure

- Identify site for biopsy: use signs of temporal artery tenderness, skin erythema, absent pulsations, and arterial nodularity as guide.
- Mark the biopsy site: mark the course of the vessel on the skin with a pen. Hair may need to be shaved off and occasionally Doppler ultrasound may be required to aid identification.
- Anaesthetize the skin using 1% lignocaine with adrenaline.
- Make skin incision: use a number 15 blade to incise just into the subcutaneous fatty layer.
- Exposing the artery: lift up wound edges and use blunt dissection to expose at least 3mm of the artery from surrounding connective tissue.
- Removing the artery: tie a single throw of a knot of 4'0 Vicryl to the proximal end of the artery and check that the patient can still speak and move fingers and toes (i.e. cerebral ischaemia has not been precipitated). Tie the knot fully and place a further knot on the distal end. Tie off any additional branches. Then cut the artery and remove, being careful to avoid crushing artefact; send for histology.
- Closure: use 5'0 Vicryl for deep layers and 6'0 silk for skin closure. Apply pressure dressing for 24 hours.



**Fig. 9.15** Disc swelling and haemorrhage in AION. Courtesy of Masoud Teimory.

## 9.11 Papilloedema and idiopathic intracranial hypertension

### Papilloedema

Papilloedema is optic disc swelling secondary to raised intracranial pressure, and is usually bilateral. Its presence should raise the suspicion of serious intracranial pathology.

#### Pathophysiology

The optic nerve sheath is continuous with the subarachnoid space. As intracranial pressure rises, pressure is exerted onto the optic nerve, causing impairment of axoplasmic flow. This leads to build-up of axoplasmic material at the level of the lamina cribrosa, and subsequent optic disc swelling.

#### Aetiology

Causes of raised intracranial pressure are listed in Table 9.6.

Table 9.6 Causes of raised intracranial pressure	
Cause	Clinical features
Space-occupying lesions (mass effect)	Tumours
	Haemorrhage
	Haematoma
Increased cerebrospinal fluid production	Choroid plexus tumour
Reduced cerebrospinal fluid resorption	Venous sinus thrombosis
	Arachnoid villi damage (meningitis, subarachnoid haemorrhage)
	Aqueduct/foramen stenosis
	Idiopathic intracranial hypertension

#### Clinical evaluation

##### History

Symptoms are usually those of raised intracranial pressure and include:

- headache: typically worse in the mornings, and increased by coughing/Valsalva manoeuvres,
- nausea and vomiting.

Visual symptoms may also occur and include:

- transient visual obscurations (e.g. momentary loss/greying of vision and may be precipitated by change of posture),
- diplopia (if sixth nerve involved),
- blurring of vision/reduced colour vision.

##### Optic disc signs of the different stages of papilloedema

- Early: hyperaemia, blurred margins, swelling, blurring of nerve fibre layer.
- Fully developed: gross elevation of nerve head, engorged veins, peripapillary splinter haemorrhages, retinal folds may develop.
- Chronic: reduced hyperaemia and haemorrhages, optic cup is obliterated, hard exudates within nerve head occur.
- Atrophic: reduced disc swelling, retinal arteriole narrowing, disc appears pale and atrophic.

##### Differential diagnosis

- Optic neuropathies with papillitis.
- Pseudopapilloedema (e.g. drusen, hypermetropic discs, tilted discs).
- Malignant hypertension.
- Uveitis causing optic disc vasculitis.

- Graves' compressive ophthalmopathy.

#### Investigations

- Urgent neuroimaging with magnetic resonance venography to exclude venous thrombosis.
- Lumbar puncture if cause unclear (exclude space occupying lesions first).
- B-scan to exclude drusen.
- Visual-field testing (enlarged blind spots, altitudinal field loss, generalized constriction).
- FFA: late leakage of dye seen in early papilloedema.

#### Management

Depends on the underlying cause and referral to neurosurgery/neurology is usually required.

### Idiopathic intracranial hypertension

Idiopathic intracranial hypertension (also known as benign intracranial hypertension and pseudotumour cerebri) is a common cause of papilloedema, and a diagnosis of exclusion. The pathophysiology of idiopathic intracranial hypertension is unclear, although resistance to cerebrospinal fluid absorption across arachnoid villi is thought to occur.

#### Aetiology

Idiopathic intracranial hypertension typically affects young (in their third decade), obese women. Associated risk factors include:

- recent, substantial weight gain,
- drugs: tetracyclines, steroid withdrawal,
- obstructive sleep apnoea,
- intracranial venous thrombosis.

#### Clinical evaluation

Clinical features are similar to the other causes of raised intracranial pressure.

#### Investigations

Criteria for diagnosing idiopathic intracranial hypertension include:

- symptoms and signs of raised intracranial pressure,
- normal neuroimaging,
- raised cerebrospinal fluid pressure ( $>25 \text{ cmH}_2\text{O}$  in obese) with normal composition.

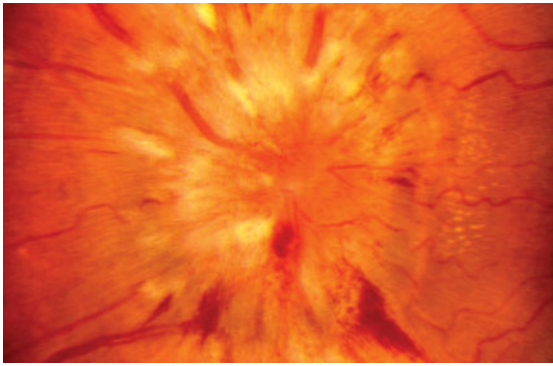
#### Management

The aims of treatment are to relieve headaches and prevent irreversible optic nerve impairment. Options include:

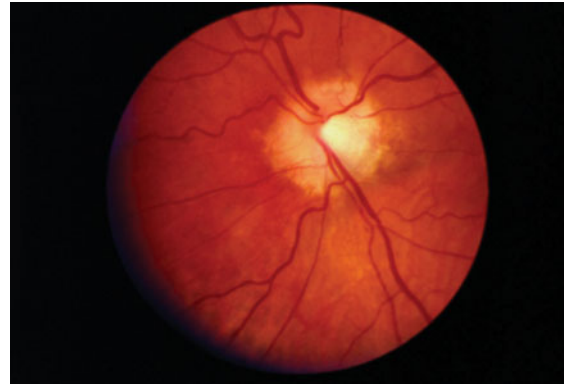- reducing weight if obese,
- medically reducing intracranial pressure: acetazolamide, diuretics, corticosteroids (use with caution),
- optic nerve sheath fenestration if vision is threatened,
- lumboperitoneal shunts in severe, resistant headache.

#### Prognosis

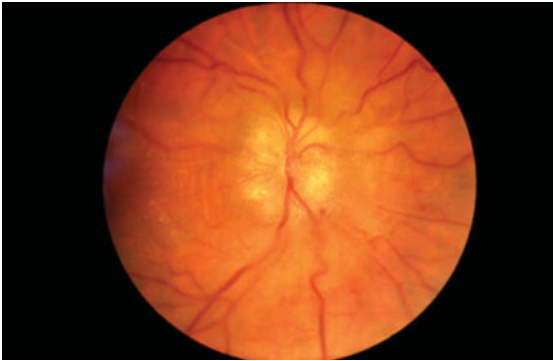
- Idiopathic intracranial hypertension is a usually a self-limiting condition, but can last up to several years with recurrences.
- Visual prognosis is good in appropriately managed patients and therefore regular optic nerve assessment is important.



**Fig. 9.16** Fully developed papilloedema.



**Fig. 9.18** Optic atrophy.



**Fig. 9.17** Chronic papilloedema.



## 9.12 Congenital optic nerve disorders

Congenital optic nerve disorders include a range of conditions that can affect visual function to varying degrees, and may be associated with systemic abnormalities.

### Optic disc pit

An optic pit appears as a small depression in the optic disc, and is usually located temporally. Histologically, there is herniation of retina and surrounding fibrous tissue into a depression within the optic nerve.

Patients may be asymptomatic, although 45% develop macular retinoschisis and subsequent serous retinal detachments, with the subretinal fluid thought to arise from the vitreous or subarachnoid space surrounding the nerve.

Vitrectomy with gas tamponade may be required when spontaneous resolution of the maculopathy does not occur. Visual-field defects may also be present and may not necessarily correlate with the location of the pit.

### Congenital tilted disc syndrome

This normally bilateral condition is due to an oblique entry of the optic nerve through the scleral canal. The inferonasal disc is displaced posteriorly and thinning of the adjacent retinal pigment epithelium may also be present.

Visual-field defects are common, affecting the superotemporal quadrants. These tend not to progress or respect the vertical midline and may often be eliminated after correcting for any myopic refractive error, which is associated with this condition.

### Optic nerve hypoplasia

This unilateral or bilateral condition may have systemic associations and is characterized by a reduced number of optic nerve axons. Risk factors for developing optic nerve hypoplasia include young maternal age, maternal smoking, alcohol use during gestation, and preterm birth.

Vision can be normal; however, optic nerve hypoplasia is a common cause of blindness in children. On examination a small, grey disc is seen and this is often surrounded by a yellow peripapillary halo, flanked on either side by a ring of pigment (double-ring sign).

Systemic associations include de Morsier syndrome (septo-optic dysplasia), which comprises optic nerve hypoplasia, absence of the septum pellucidum, and partial or complete agenesis of the corpus callosum. Other associations include pituitary dysfunction and cerebral hemispheric abnormalities.

### Optic disc coloboma

In this unilateral or bilateral condition, the optic disc appears as a clearly demarcated bowl-shaped excavation that is usually decentred and thinner inferiorly. It arises from abnormal fusion of the two sides of proximal end of the optic cup. It may occur sporadically or be inherited in an autosomal dominant pattern, and can be associated with multiple congenital abnormalities.

Visual acuity is reduced depending on the degree of foveal involvement by the coloboma. Visual-field defects may be present superiorly and other ocular features can include colobomas of the iris, ciliary body, and fundus.

Systemic associations include CHARGE syndrome, Aicardi syndrome, Goldenhar syndrome, Goltz syndrome, and Meckel–Gruber syndrome.

### Morning glory anomaly

This rare, sporadic condition is usually unilateral and characterized by a funnel-shaped excavation of the optic disc with central glial tissue and chorioretinal pigmentary disturbance surrounding the disc. Retinal blood vessels are increased in number, arise from the disc periphery, and run an abnormally straight course over the peripapillary region.

The pathogenesis is unknown, although one theory is that this condition arises from failure of closure of the foetal fissure, and is possibly a variant of coloboma. Visual acuity is usually poor and serous retinal detachments occur in one third of patients.

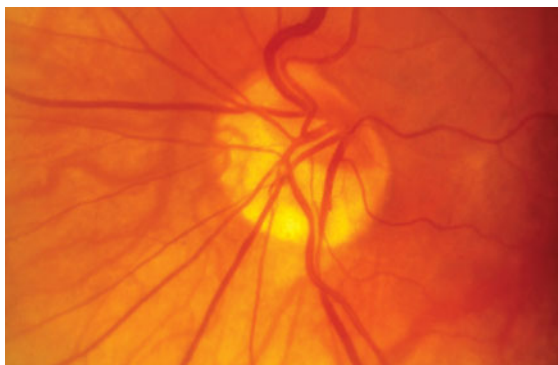
This condition can be associated with transphenoidal encephalocele and hypopituitarism, with patients displaying hypertelorism, a wide head, and flattened nasal bridge. Also, hypoplasia of ipsilateral intracranial vasculature may be present.

### Optic disc drusen

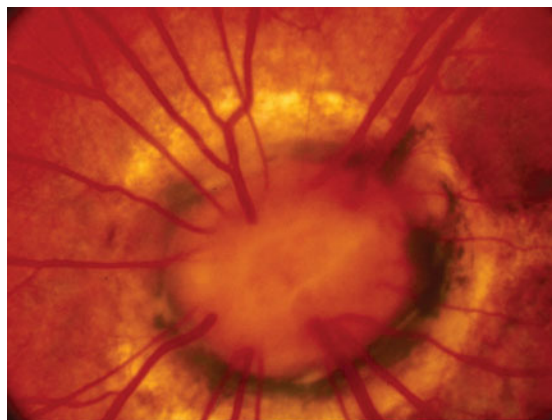
Optic disc drusen are refractile, often calcified bodies within the substance of the optic nerve, possibly arising from abnormalities in axoplasmic flow. In children they may mimic papilloedema as the drusen may lie beneath the disc surface. The disc can therefore appear elevated, with a 'scalloped' margin and minimal cup. Anomalous retinal vessels with increased branching and tortuosity may accompany the disc changes. Disc drusen usually become more obvious in the early teen years, when they appear as waxy, yellow irregularities on the disc surface.

Visual-field defects may accompany disc drusen as a result of nerve fibre bundle defects. Rarely, visual acuity can be affected by the development of juxtapapillary choroidal neovascular membrane formation.

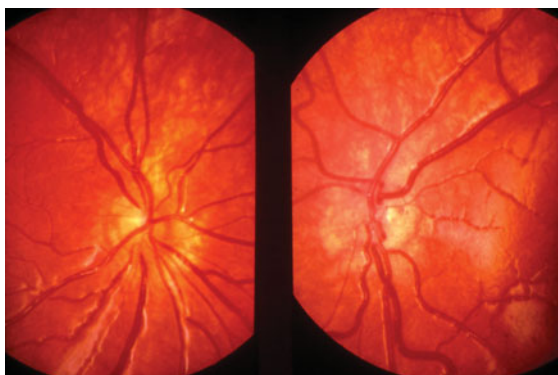B-scan ultrasound is particularly useful in detecting the calcific elements of disc drusen. FFA can show autofluorescence (prior to dye injection) and late disc staining, although these features may be less apparent in buried drusen. Retinitis pigmentosa and angioid streaks are associated with optic disc drusen.



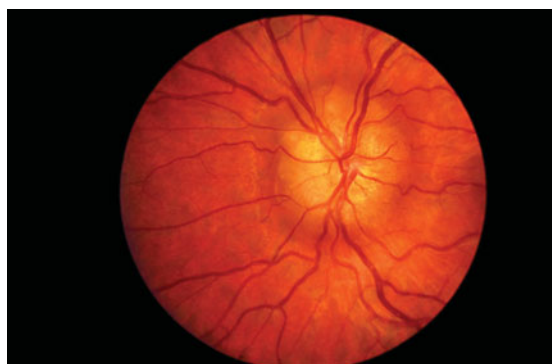**Fig 9.19** Tilted disc.



**Fig 9.21** Morning glory anomaly. Courtesy of Masoud Teimory.



**Fig 9.20** Optic nerve hypoplasia.



**Fig 9.22** Optic disc drusen.

## 9.13 Cranial nerve palsies I

Eye movement disorders and other ocular abnormalities can arise from lesions to the third, fourth, and sixth cranial nerves. Lesions can occur anywhere from the nuclei, to the fasciculus (as the nerve passes through the brainstem), to the peripheral nerve. As cranial nerves lie in close proximity to one other, other neurological manifestations can arise, resulting in particular presentations that can help locate the underlying lesion. A full cranial nerve and neurological examination is therefore mandatory in patients presenting with ophthalmic cranial nerve problems.

### Third nerve palsies

#### Aetiology

Causes include:

- microvascular disease (diabetes, hypertension),
- trauma (e.g. extradural/subdural haematomas),
- aneurysm (e.g. posterior communicating aneurysm at junction with internal carotid artery),
- tumour,
- demyelination,
- vasculitis (e.g. GCA),
- idiopathic.

#### Clinical evaluation

As the third nerve supplies the levator muscles, and all the extraocular muscles (except the lateral rectus and superior oblique), the following features can be present to varying degrees, depending on whether the nerve damage is partial or complete:

- diplopia is usually the primary symptom,
- ptosis,
- affected eye abducted and usually depressed (due to unopposed lateral rectus and superior oblique action),
- reduced action in all other gaze movements,
- pupil dilatation (in compressive lesions),
- reduced accommodation,
- aberrant regeneration (with recovery following trauma or compressive lesions):
  - lid-gaze dyskinesia: lid elevation on attempted adduction or depression,
  - pupil-gaze dyskinesia: pupil constriction on attempted adduction or depression.

#### Pupil involvement versus pupil-sparing lesions

As a general rule, 'surgical' causes of third nerve lesions (e.g. aneurysms, trauma, tumours) result in pupil dilatation, as compression of pial blood vessels that run superficially along the third nerve occurs, which normally gives vascular supply to parasympathetic pupillary fibres.

'Medical' causes of third nerve lesions (e.g. diabetes, hypertension) typically spare pupil involvement as the resulting ischaemia only affects the central vascular supply of the nerve, thus sparing superficial pupillary fibres.

However, absence of pupil involvement on presentation does not exclude a compressive cause, as the lesion may be evolving and yet to manifest pupillary signs.

#### Localizing lesions

In addition to ipsilateral third nerve involvement, the following features can give information on the likely anatomical site of nerve lesion.

#### Nuclear lesions

- Bilateral ptosis (levator subnucleus).
- Contralateral superior rectus weakness (superior rectus subnucleus).

#### Fasciculus lesions

- Contralateral tremor and ataxia (red nucleus lesion in Benedikt's syndrome).
- Contralateral hemiparesis (cerebral peduncle lesion in Weber's syndrome).

#### Subarachnoid lesions

- Headache, pain, neck stiffness (and other signs of meningism) following aneurysm rupture.

#### Intracavernous lesions

- Fourth, fifth, and sixth nerve involvement may occur due to their close proximity in the cavernous sinus.

#### Intraorbital lesions

- Isolated elevation defect and ptosis (superior division lesion).
- Adduction and depression deficits with mydriasis (inferior division lesion).

#### Investigations

- Urgent MRI/MRA and neurosurgical review if an aneurysm or other compressive lesion is suspected.
- Blood pressure and bloods for vascular risk factors (FBC, glucose, lipids, ESR, CRP).

#### Management

Depends on the underlying cause. Options include:

- posterior communicating aneurysms require endovascular coiling,
- diplopia may be controlled using patching, inducing ptosis (if not already present) or fresnel prisms,
- strabismus and lid surgery may be required if spontaneous improvement has not occurred (after 12 months).

#### Prognosis

- Spontaneous recovery rate is high in ischaemic causes.
- Recovery (or partial recovery) is also common in compressive cases but is variable depending on the underlying cause and may take longer.

## Fourth nerve palsies

Each fourth cranial nerve supplies the contralateral superior oblique muscle, which intorts, depresses and abducts the eye. Nerve palsies usually present with binocular vertical diplopia, with torsion. These may arise from congenital or acquired causes and be unilateral or bilateral, which can have differing clinical features.

### Aetiology

- Congenital.
- Acquired:
  - trauma (often causes bilateral features),
  - microvascular disease,
  - demyelination,
  - idiopathic,
  - vasculitis (e.g. GCA),
  - tumour.

### General clinical features

- Diplopia (vertical, torsional, or oblique), which is usually worse on:
  - downgaze,
  - looking in the direction of the unaffected eye.
- Affected eye is hypertropic, which increases when:
  - looking in the direction of the unaffected eye,
  - the head is tilted towards the ipsilateral shoulder.
- Limited depression in adduction with excyclotorsion.
- Compensatory head tilt (to relieve diplopia) may be present with:
  - head tilt towards contralateral shoulder,
  - face turn towards unaffected side,
  - chin depression.

### Congenital features

Congenital fourth nerve palsies may be present in children or only become apparent in adulthood following decompensation. Patients typically develop large vertical fusional ranges and can develop concomitance, with muscle sequelae. Abnormal head postures may have developed, of which patients are sometimes unaware.

### Acquired features

Usually there is more sudden and recent onset of symptoms, which also tend to be more severe. A history of trauma is common, with the fourth nerve being particularly vulnerable as it passes close to the rigid tentorial edge.

### Bilateral features

Bilateral fourth nerve palsies are usually caused by trauma. Other features include:

- chin-down position,
- small vertical deviation in primary position,
- V pattern,
- alternating adduction hypertropia,
- large excyclotorsion ( $>10^\circ$ ).

## Parks–Bielschowsky three step test

This test is useful for identifying the underacting muscle in vertical deviations and is therefore helpful in the diagnosis in superior oblique palsies. It involves performing cover tests in the following positions (in the example of a right superior oblique palsy):

### 1. Assess which eye is hypertropic in the primary position

Right hypertropia implies that the following four muscles could be impaired:

- right superior oblique or inferior rectus,
- left superior rectus or inferior oblique.

### 2. Assess in which lateral gaze direction the hypertropia is worse

Right hypertropia worse on left gaze implies that the following two muscles could be impaired:

- right superior oblique,
- left superior rectus.

### 3. Assess in which head-tilt position the hypertropia is worse

Right hypertropia worse on right head tilt implies that the right superior oblique is affected.

### Investigations

- Look at old photographs to check for congenital causes.
- Blood pressure and blood tests to exclude vascular causes.
- Consider neuroimaging in cases with no vascular risk factors, trauma, or congenital causes.

### Management

Aside from treating any underlying causes, options include:

- occlusion or prisms to control diplopia,
- strabismus surgery in non-resolving palsies (after 12 months). Options include:
  - inferior oblique weakening,
  - superior oblique tuck,
  - contralateral inferior rectus recession.

### Prognosis

- Spontaneous recovery is high in microvascular cases, with complete resolution occurring often occurring within 2–3 months.
- Full recovery is less common in traumatic cases, although over 50% of patients show some improvement.

## 9.14 Cranial nerve palsies II

### Sixth nerve palsies

The sixth cranial nerve supplies the ipsilateral lateral rectus muscle, resulting in abduction defects when innervation is impaired. Lesions to the sixth nerve can occur at various sites along its course, producing localizing signs. Various other conditions can also result in abduction defects and therefore imitate a sixth nerve palsy.

#### Aetiology

- Microvascular disease.
- Raised intracranial pressure.
- Tumour (acoustic neuroma, nasopharyngeal tumours, cavernous sinus masses, pontine gliomas in children).
- Trauma (basal skull fractures).
- Idiopathic.
- Demyelination.
- Vasculitis (e.g. GCA).
- Congenital (rare).

#### Clinical evaluation

- Typical presentation is with binocular, horizontal diplopia that is worse for looking into the distance and in the direction of affected muscle.
- Esotropia of affected eye in primary position.
- Limitation of abduction.
- Compensatory face turn to the ipsilateral side to relieve diplopia may be present.

#### Differential diagnosis

The following conditions can also cause reduced abduction:

- thyroid eye disease (look for other signs),
- myasthenia gravis (variability of symptoms, especially towards end of the day),
- medial-wall blow-out fracture,
- Duane's syndrome (narrowing of palpebral fissure and globe retraction on adduction),
- orbital inflammatory disease (proptosis, chemosis, pain),
- convergence spasm.

#### Localizing lesions

In addition to an ipsilateral abduction defect, the following features can give information on the likely site of underlying pathology.

#### Nuclear lesions

The sixth nerve nucleus lies in the pons, in close association to the seventh nerve fasciculus, the paramedian pontine reticular formation (horizontal gaze centre), and first-order sympathetic fibres which travel in the pons. In addition, the sixth nerve nucleus provides innervation to the contralateral medial rectus via the medial longitudinal fasciculus. Pontine lesions can therefore cause:

- ipsilateral gaze palsies,
- one-and-a-half syndrome (ipsilateral gaze palsy+ipsilateral internuclear ophthalmoplegia),
- ipsilateral facial weakness,
- Foville's syndrome (dorsal pontine infarct involving first-order sympathetic fibres and fifth nerve nucleus):
  - ipsilateral gaze palsy,
  - ipsilateral facial weakness,
  - ipsilateral facial analgesia (fifth nerve damage),
  - Horner's syndrome,
  - deafness (eighth nerve damage).

#### Fasciculus lesions

These involve sixth nerve damage as it passes through the pyramidal tract and can be associated with:

- Millard–Gubler syndrome:
  - ipsilateral sixth nerve palsy,
  - ipsilateral facial weakness,
  - contralateral hemiplegia.

#### False localizing signs

Raised intracranial pressure (e.g. from posterior fossa tumours) may result in downward displacement of the brainstem, causing pressure on the sixth nerve as it passes over the petrous bone, leading to unilateral or bilateral sixth nerve palsies.

#### Investigations

- Blood pressure and blood tests to exclude vascular causes.
- ESR+CRP in older patients to exclude GCA.
- Consider MRI if:
  - other cranial nerve/brainstem abnormalities are present,
  - palsy is not resolving after 3 months,
  - patients are under 40 years old.
- Consider lumbar puncture and cerebrospinal fluid examination if no cause found.

#### Management

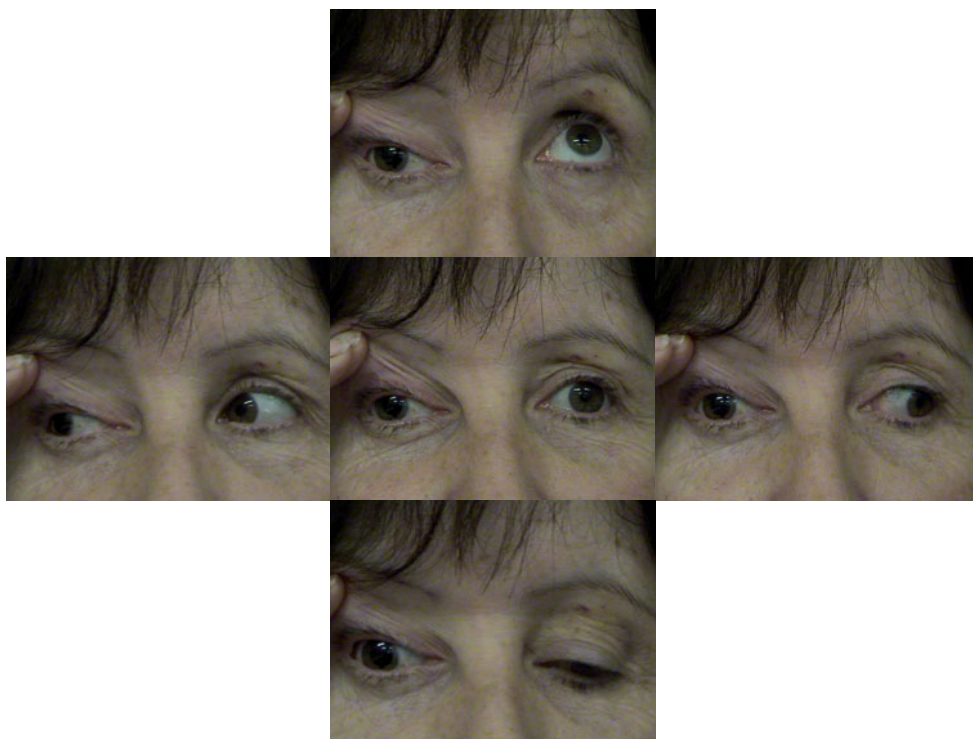Aside from treating any underlying causes, options include:

- occlusion or prisms to control diplopia,
- botulinum toxin to ipsilateral medial rectus,
- strabismus surgery in non-resolving palsies (after 12 months):
  - resect/recession surgery may be sufficient in partial sixth nerve palsies,
  - vertical muscle transposition surgery is often needed in complete sixth nerve palsies.

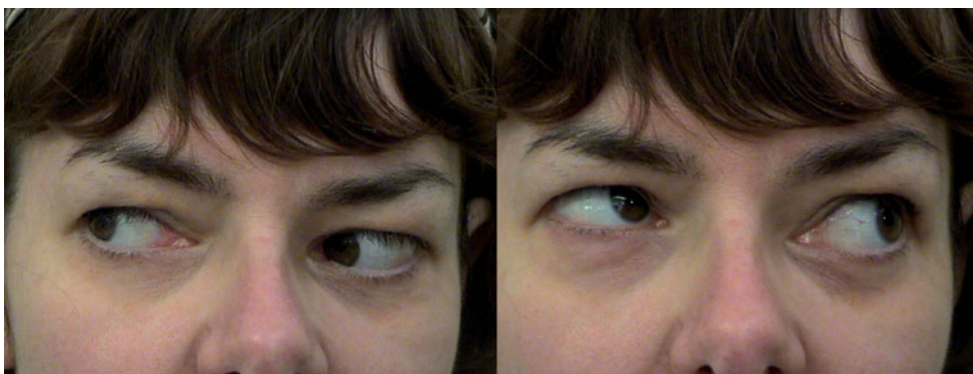#### Prognosis

Depends on underlying cause with full recovery being high in microvascular causes.





**Fig. 9.23** Right third nerve palsy looking in different positions of gaze.

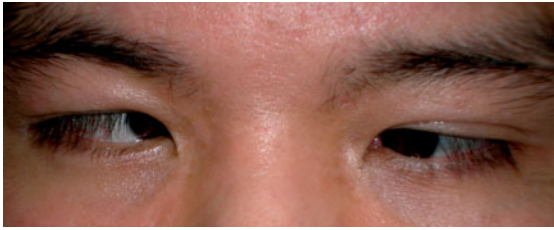


(a)

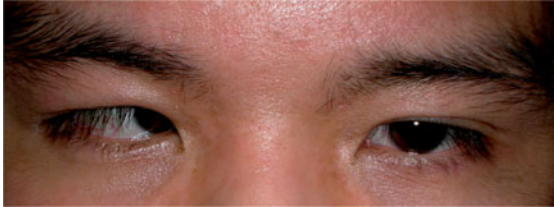

(b)

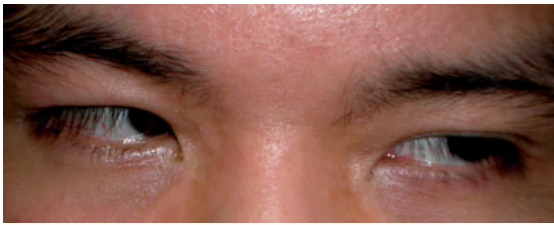**Fig. 9.24** Right superior oblique palsy with increased right hypertropia on (a) left gaze and (b) head tilt to right.



(a)



(b)



(c)

**Fig. 9.25** Right sixth nerve palsy on (a) right gaze, (b) primary position, and (c) left gaze.

*This page intentionally left blank*

## 9.15 Nystagmus

Nystagmus is an involuntary, rhythmic oscillation of the eyes, arising from congenital and acquired causes. It can be further classified depending on the predominant direction of movement (e.g. downbeat nystagmus) and whether the movements have a fast beating component (jerk nystagmus), or whether the speed of movement is equal in both directions (pendular nystagmus).

### Pathophysiology

Highest visual acuity requires images to be held steady over the fovea, and is dependent on three mechanisms: fixation, the vestibulo-ocular reflex, and the neural integrator. Fixation refers to (a) the visual system's ability to detect drift of retinal images and instigation of corrective eye movements and (b) suppression of unwanted movements that would take the eyes off the target. The vestibulo-ocular system helps generate compensatory eye movements in response to changes in head position. The neural integrator (comprising of cerebellum, ascending vestibular pathways, and ocular motor nuclei) maintains eccentric eye positions despite the globe's muscles and suspensory ligaments wanting to return the eye to the primary position. Lesions affecting any of these three mechanisms can result in the various types of nystagmus.

### Downbeat nystagmus

This is usually caused by posterior fossa lesions at the level of the craniocervical junction (e.g. Arnold–Chiari malformations, demyelination, infarction). Features include:

- nystagmus in primary position with fast phase beating downwards,
- maximum nystagmus on lateral and slightly inferior gaze.

### Upbeat nystagmus

This can be caused by cerebellar, medulla, and thalamic lesions and produces a nystagmus in the primary position, with the fast phase beating upwards.

### See-saw nystagmus

This usually results from large parasellar tumours, and can also arise from infarction and trauma to the upper brainstem. Features include a pendular nystagmus with one eye elevating and intorting while the other eye depresses and extorts, in one half of the cycle, followed by a reversal in direction in the second half of the cycle.

### Periodic alternating nystagmus

This is normally a result of cerebellar disease and its features include:

- horizontal jerk nystagmus with fast-phase beating in one direction for about 90 seconds (amplitude gradually increases and decreases during this period),
- intervening neutral period of about 10–20 seconds,
- nystagmus commences again with fast beat now in the other direction,
- alternating cycle repeats itself.

### Gaze-evoked nystagmus

Gaze-evoked (end-point) nystagmus may be physiological or due to cerebellar disease and CNS depression (e.g. from anticonvulsants and alcohol). Features include a horizontal jerk nystagmus on eccentric gaze, with the fast phase being in the direction of gaze. Physiological end-point nystagmus usually only becomes apparent at

gazes of 45–50°, so gaze-evoked nystagmus occurring at a lesser angle is more likely to be pathological.

### Vestibular nystagmus

Eye movements are intricately linked to the vestibular system, and both central and peripheral vestibular lesions can produce nystagmus with differing features.

#### Central vestibular nystagmus

Arises from lesions in the vestibular nuclei, cerebellum, or their interconnections. Features include:

- horizontal, vertical, or torsional nystagmus,
- unilateral or bilateral nystagmus,
- fast phase in direction of gaze,
- nystagmus not inhibited by fixation.

#### Peripheral vestibular nystagmus

Features include:

- horizontal jerk nystagmus, worsening with gaze in direction of the fast phase (Alexander's law),
- fast phase beats away from side of lesion in destructive disorders (e.g. labyrinthitis),
- fast phase beats towards side of lesion in irritative disorders (e.g. Meniere's disease).

### Congenital nystagmus

Congenital nystagmus usually presents in the first few months of life and can be idiopathic (autosomal dominant, autosomal recessive, or X-linked inheritance) or secondary to visual-development-impairing disorders (e.g. albinism, congenital cataracts, congenital glaucoma, foveal/optic nerve hypoplasia) with both resulting in similar features:

- horizontal and usually jerk nystagmus (although may be pendular),
- increases with fixation,
- may be dampened by convergence,
- a null point (where nystagmus movement is least) may be present in a particular position of gaze,
- an altered head position may be adopted to facilitate the null point.

### Latent nystagmus

This is associated with strabismus (usually infantile esotropia) with the nystagmus only becoming apparent when one (any) eye is occluded. This produces a horizontal jerk nystagmus, with the fast phase in the direction of the uncovered eye.

### Spasmus nutans

This rare condition comprises the triad of nystagmus, head nodding, and torticollis. It usually presents within the first year of life and resolves spontaneously by 2–3 years. The nystagmus is typically horizontal, with high frequency and low amplitude. The cause is normally idiopathic, although chiasmal and third ventricular gliomas can produce similar features.

---

## Management of nystagmus

- A thorough neuro-ophthalmic history and examination is essential in eliciting any possible causes or associations.
- Consider neuroimaging when other neurological deficits are present or when no attributable cause is found.

Treatment can include:

- refractive correction and amblyopia treatment (if needed) in children,

- prisms may help to induce convergence and move the null point into the primary position in congenital cases,
- baclofen may help reduce periodic alternating nystagmus,
- retrobulbar or intramuscular botulinum injections may be helpful in severe cases,
- surgery is generally reserved for congenital cases where extraocular muscle adjustments to shift the null position into the primary position can help reduce the nystagmus. However, the null position may again become eccentric.



## 9.16 Supranuclear eye movement disorders

Coordination of eye movements originates at a supranuclear level (i.e. above ocular motor nuclei) and involves gaze centres for the control of horizontal and vertical movements. In addition, saccadic movements (which bring an object of interest on to the fovea) and pursuit movements (that maintain fixation on a target) are initiated supranuclearly. This section briefly describes the pathways of these eye movements and the disorders associated with them.

### Horizontal gaze palsies

For horizontal gaze, impulses originate in the pontine paramedian reticular formation, adjacent to the sixth nerve nucleus. The pontine paramedian reticular formation activates the ipsilateral sixth nerve nucleus and thereby innervates the lateral rectus. The sixth nerve nucleus also communicates with the contralateral medial rectus subnucleus, via the medial longitudinal fasciculus. Horizontal gaze disorders include the following:

#### Horizontal gaze palsy

Pontine paramedian reticular formation lesions produce a gaze palsy to the affected side. This can be differentiated from a gaze palsy occurring in sixth nerve nucleus lesions by oculoccephalic and caloric testing, which produce vestibular input at the nuclear level, and are therefore normal in pontine paramedian reticular formation lesions.

#### Internuclear ophthalmoplegia

This results from medial longitudinal fasciculus lesions (e.g. demyelination, vascular disease, trauma, brainstem tumours) and features of a right internuclear ophthalmoplegia include:

- adduction deficit of right eye on attempted left gaze,
- horizontal jerk nystagmus of abducting left eye,
- normal right gaze,
- upbeat and torsional nystagmus may be present,
- convergence preserved.
- skew deviation.

Bilateral internuclear ophthalmoplegia is usually due to demyelination, with upbeat nystagmus on upgaze and downbeat nystagmus on downgaze a constant feature. A variant is the WEBINO syndrome (wall-eyed bilateral internuclear ophthalmoplegia) due to large exotropias that can feature.

#### One-and-a-half syndrome

This is caused by pontine paramedian reticular formation lesions (or sixth nerve nucleus lesions) extending to the ipsilateral medial longitudinal fasciculus lesions. Features of a right sided one-and-a-half syndrome include:

- gaze palsy on attempted right gaze,
- adduction deficit on attempted left gaze,
- abduction of the left eye is the only normal horizontal movement.

### Vertical gaze palsies

Vertical eye movements are generated in the rostral interstitial nucleus of the medial longitudinal fasciculus, which consists of paired nuclei, with the lateral portion of each initiating upgaze, and the medial portion initiating downgaze. Vertical gaze disorders include the following.

#### Parinaud's dorsal midbrain syndrome

This syndrome occurs in dorsal midbrain lesions that involve the rostral interstitial nucleus of the medial longitudinal fasciculus and third nerve nuclear complex. Causes include demyelination, vascular

disease, aqueduct stenosis, arteriovenous malformations, and tumours. Clinical features include:

- upgaze disturbance,
- convergence-retraction nystagmus,
- light-near dissociation,
- lid retraction (Collier's sign),
- convergence paralysis.

#### Progressive supranuclear palsy

This is a progressive neurodegenerative condition affecting the elderly and initially impairs downgaze. Subsequently upgaze also becomes affected, followed by loss of horizontal, then saccadic and pursuit eye movements. Patients may also develop pseudobulbar palsy, Parkinsonism, and dementia.

#### Skew deviations

These are usually small vertical tropias that can occur following brainstem or cerebellar lesions. The vertical deviation is usually comitant and ipsilateral to the side of the lesion. They are usually associated with other features that allow localization, e.g. unilateral internuclear ophthalmoplegia in pontine lesions, or Horner's syndrome plus lateropulsion in medullary lesions.

### Saccadic movement disorders

Saccades are fast eye movements (up to 800° per second) that can occur in any direction, and may be voluntary or involuntary. They require an initial strong *pulse* signal to overcome orbital viscous forces, followed by a *step* signal to maintain the eye in its new position. The pathway for horizontal saccades originates in the frontal eye fields and superior colliculus, and from here signals pass to the contralateral pontine paramedian reticular formation. Vertical saccades originate in either the frontal eye fields or superior colliculus and impulses then pass to the contralateral rostral interstitial nucleus of the medial longitudinal fasciculus. Saccadic disorders can arise from:

- frontal lobe lesions: can cause difficulty in generating horizontal saccades and result in a preferential gaze to the ipsilateral side;
- cerebellar disease: can cause hypometric saccades where the eye fails to reach its new target, or hypermetric saccades when overshoot of initial target occurs;
- degenerative conditions such as Huntington's disease, olivopontocerebellar degeneration, and Wilson's disease.

#### Square-wave jerks

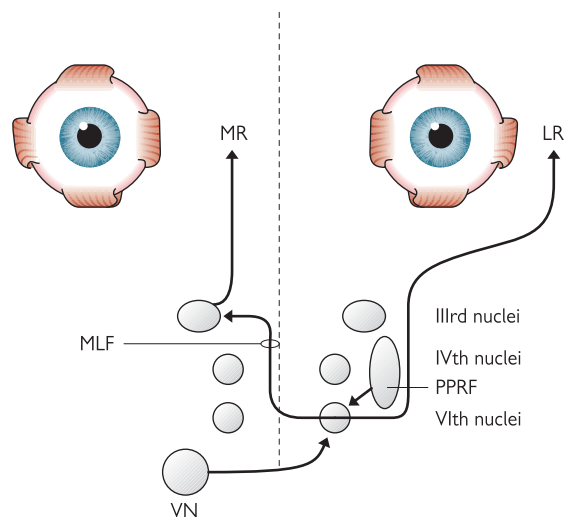
These are sporadic saccades away from the fixation point, followed by a corrective saccade between 100 and 200 milliseconds later. They are named after their appearance on eye-movement recordings and are usually pathological if the jerks are greater than 1°, and suggestive of cerebellar disease.

#### Ocular flutter and opsoclonus

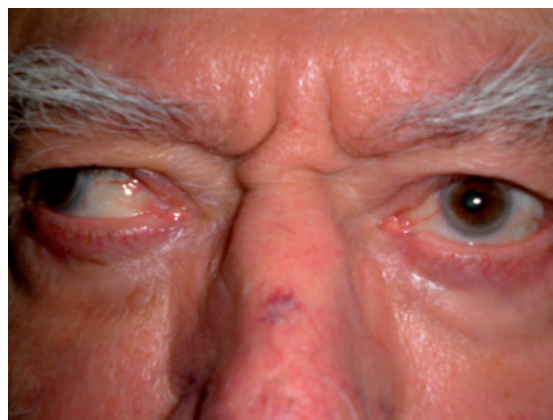Ocular flutter consists of intermittent, rapid horizontal oscillations around a fixation point, and can also occur in cerebellar disease. However, they differ from square-wave jerks as no pause interval between saccades occurs. Opsoclonus are similar to ocular flutter, although the saccades can occur in any direction, and is caused by posterior fossa lesions. Both ocular flutter and opsoclonus are due to antibodies against prenuclear saccadic pause cells and are either post-infectious (often in childhood) or paraneoplastic (mostly in adults). They are usually associated with ataxia.

## Pursuit movement disorders

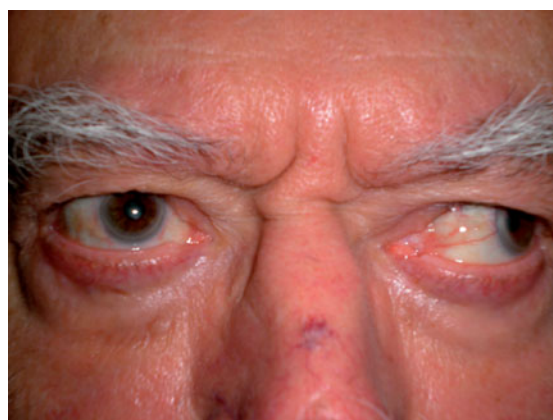Pursuit movements allow tracking of visual targets and are integrated with the vestibular system. They consist of smooth conjugate movements from 20 to 70° per second. The pathway is complex but thought to originate in the parieto-occipito-temporal junction and then projects to the ipsilateral pontine paramedian reticular formation. Lesions to the pursuit pathway can be demonstrated by failure to follow an optokinetic nystagmus drum when rotated to the side of the lesion.



**Fig 9.26** Control of horizontal eye movements. LR, lateral rectus; MLF, medial longitudinal fasciculus; MR, medial rectus; MVN, medial vestibular nucleus; PPRF, paramedian pontine reticular formation; VN, vestibular nucleus.



(a)



(b)

**Fig. 9.27** Bilateral internuclear ophthalmoplegia: (a) right gaze and (b) left gaze.

## 9.17 Pupil abnormalities

Pupillary disorders can be divided into two main groups: afferent and efferent defects. Afferent pupillary defects are due to an interruption of light stimulus in the anterior visual pathway (retina to pretectal area), resulting in decreased contraction of both pupils when light is shone into the affected eye. Efferent pupillary defects affect contraction or dilatation of the pupil, due to damage to the midbrain, or nerves supplying the iris muscles (or the iris muscles themselves), often resulting in anisocoria.

### Afferent pupillary defects

#### Relative afferent pupillary defects

This results from lesions in the anterior visual pathway. Causes include:

- gross retinal pathology (e.g. CRVO, retinal detachment),
- optic neuropathy (e.g. optic neuritis, compressive lesions),
- optic chiasm and tract lesions (infarcts, demyelination),
- midbrain tectal lesions.

#### Absolute afferent pupillary defect

This occurs following a complete optic nerve lesion. Both pupils will constrict normally when light is shone into the healthy eye, but neither pupil will constrict when light is shone into the affected eye.

### Efferent pupillary defects

#### Horner's syndrome

This syndrome results from an interruption (at any level) of the sympathetic nerve supply to the eye.

#### Aetiology

1. First-order neuron (central) lesions:
  - basal skull tumours,
  - syringomyelia,
  - brainstem disease (vascular, demyelination),
  - Arnold–Chiari malformations.
2. Second-order neuron (preganglionic) lesions:
  - apical lung tumours (Pancoast's tumour),
  - neck disorders (trauma, surgery, tumour),
  - carotid and aortic aneurysms/dissection,
  - cervical rib.
3. Third-order neuron (postganglionic) lesions:
  - internal carotid artery dissection,
  - middle ear disease (otitis media, herpes zoster),
  - cavernous sinus disease (thrombosis, mass),
  - headaches (cluster, migraine).

#### Clinical features

- Miosis with anisocoria, which is more apparent in darker conditions.
- Normal pupil reactivity to light and near.
- Mild upper-lid ptosis (reduced innervation of Müller's muscle).
- Apparent enophthalmos: due to slight elevation of inferior eyelid (inferior tarsal muscle weakness).
- Ipsilateral facial anhidrosis in first- and second-order lesions.
- Iris hypochromia in congenital lesions.

#### Investigations

Pharmacological pupil tests can help to confirm a diagnosis of Horner's syndrome and identify the location of underlying lesion.

#### Cocaine 4% confirms the diagnosis

- **Method:** instil two drops in each eye and measure pupil sizes after 60 minutes.
- **Findings:** only the normal pupil will dilate.
- **Reason:** cocaine blocks the reuptake of noradrenaline at nerve endings, causing pupil dilation. In Horner's syndrome, no noradrenaline is secreted and therefore cocaine has no effect

#### Hydroxyamphetamine 1% identifies level of the underlying lesion

- **Method:** instil two drops in each eye (at least 48 hours after the cocaine test) and measure pupil sizes after 60 minutes.
- **Findings:** in first- and second-order neuron lesions the Horner's pupil will dilate similarly to the normal pupil. In third-order neuron defects the abnormal pupil will dilate poorly.
- **Reason:** hydroxyamphetamine potentiates the release of noradrenaline from postganglionic nerve endings which are damaged in third-order neuron lesions, and poor dilatation therefore results.

Further investigations including CXR, carotid dopplers, CT, and MRI may be warranted to diagnose the underlying cause, and subsequent treatment will be dependent on this.

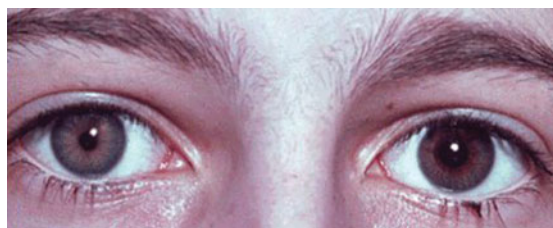

Fig. 9.28 Right Horner's pupil.

**Adie's (tonic) pupil**

Adie's pupil results from denervation of the parasympathetic supply from the ciliary ganglion to the iris and ciliary muscle. Young women are mostly affected and onset may follow a viral illness.

**Clinical features**

- Large pupil with poor reactivity to light.
- Exaggerated response to near stimuli with miosis persisting for longer, and slower re-dilation (tonic pupil) than the normal pupil.
- Vermiform iris movements seen at the slit lamp.
- Affected pupil can become smaller of the two in chronic cases.
- Diminished deep tendon reflexes in Holmes–Adie syndrome.

**Investigations**

Dilute (0.125%) pilocarpine can be used to confirm the diagnosis.

- Instil one drop into each eye and measure pupil sizes after 30 minutes.
- The abnormal pupil will constrict because of denervation hypersensitivity.

**Argyll Robertson pupil**

Small and irregular pupils that react poorly to light, but accommodate. It occurs secondary to neurosyphilis (which causes damage to the midbrain tectum region) but diabetes and alcohol abuse can produce similar pupils. Appropriate management should be undertaken to assess whether active syphilitic disease is present.

**Anisocoria**

Physiological anisocoria occurs in approximately 20% of the population. Here the anisocoria is usually less than 1 mm, which remains constant in light and dark conditions, with pupil reactivity also being normal. Non-physiological causes of anisocoria include the following.

**Abnormal pupil is constricted**

- Horner's syndrome.
- Chronic Adie's pupil.
- Unilateral miotic use.
- Iritis.
- Argyll Robertson pupil.

**Abnormal pupil is dilated**

- Adie's pupil.
- Iris trauma.
- Mydriatic agent.
- Pupil-involving third nerve palsy.

**Light-near dissociation**

This is when the pupil reaction to near objects is greater than from light stimulus. Causes include:

- afferent conduction defect (e.g. optic neuropathy),
- Adie's pupil,
- aberrant regeneration of third nerve,
- Argyll Robertson pupil,
- dorsal midbrain syndrome,
- chronic alcohol use.

## 9.18 Headache

### Headache

Headache is one of the most common clinical complaints, and patients are often referred for an ophthalmological opinion. The ophthalmologist's role in such cases is first to diagnose any ocular cause of the headache and second to help distinguish between benign causes of headache and those due to serious intracranial/systemic conditions.

#### Aetiology

Causes of headache include:

- raised intracranial pressure\*,
- GCA\*,
- malignant hypertension\*,
- subarachnoid haemorrhage\*,
- migraine,
- tension headache,
- cluster headache.

\* These are serious/life-threatening causes.

#### General considerations

Although the majority of headaches are caused by benign conditions that can be elicited with a thorough history taking, clinical features that suggest serious intracranial/systemic pathology include:

- headache characteristics:
  - new onset in previously asymptomatic patient,
  - new pattern/type of headache,
  - severe ('worst headache I've ever had'),
- focal neurological signs,
- change in personality/mental status,
- recent head trauma,
- signs of meningism,
- temporal tenderness.

### Migraine

Migraine is a common, recurrent condition affecting up to 20% of males and 40% of females, with the initial episode occurring before 10 years of age in 25% of patients. The pathogenesis of migraine is not fully understood, with theories including alterations in cerebral blood flow following aberrant neuronal activity and release of various neuropeptides and vasoactive substances.

Migraine incorporates a variety of symptoms and has been classified into (1) migraine without aura and (2) migraine with aura, by the International Headache Society:

#### Migraine without aura

This usually begins with a prodrome phase of symptoms such as mood alterations, food cravings, and drowsiness, lasting for hours to days. A unilateral, throbbing headache then normally follows, building in intensity over 1–2 hours and can last for several days. Photophobia, phonophobia, and nausea are common with the headache. Termination of the headache is followed by a postdrome phase, characterized by fatigue.

#### Migraine with aura

In this form of migraine, headache (which is similar to that in migraine without aura) usually follows an aura that can last from several minutes up to one hour. Most auras are visual, occurring in 99% of cases of migraine with aura, but other types include somatosensory (tingling, numbness), motor (hemiparesis), and speech (dysarthria) auras.

Visual auras are unilateral in 70% of cases and may consist of positive and negative visual phenomena. Symptoms can include foggy

vision, tunnel vision, hemianopia, and even complete blindness. However, the most commonly described form of visual aura is the 'fortification scotoma', features of which include:

- central visual disturbance evolving into a scotoma in several minutes,
- multiple silver, coloured, or zig-zag lines surrounding the scotoma,
- enlargement and temporal migration of the visual aura,
- aura seen with eyes either open or closed.

**Table 9.7 Other classifications of migraine by the International Headache Society**

Migraine type	Features
Migraine with prolonged aura	Aura lasting >60 minutes, with full recovery
Migraine aura without headache	Aura with no headache: diagnosis of exclusion
Ophthalmic migraine	Usually affects third nerve, occurs before age 10 Nerves IV and VI also rarely affected, with recovery over weeks
Retinal migraine	Transient, uniocular visual disturbance Variable scotoma with retinal vessel narrowing during attack
Basilar migraine	Headache follows bilateral visual disturbance, dizziness, weakness
Complications of migraine	Aura lasting >1 week resulting in permanent neurological defect (migrainous infarction)
Atypical migraine	Migraine not filling other criteria

Although migraine is normally a benign condition, it has been associated with ophthalmic complications such as retinal artery occlusion, ischaemic optic neuropathy, and normal tension glaucoma.

#### Investigations

Migraine can often be diagnosed with history taking, in the presence of a normal neurological examination. Cases with atypical clinical features require referral to a neurologist, with further work-up possibly including vasculitic screen, carotid dopplers, and neuroimaging.

#### Management

- Avoid triggering factors (e.g. certain food types, flickering lights).
- Acute attacks: rest in dark/quiet room, 5-hydroxytryptamine agonists (e.g. sumatriptan) in severe episodes.
- Recurrent episodes: prophylaxis with  $\beta$ -blockers, calcium-channel blockers, or anticonvulsants.



## 9.19 Non-organic visual loss

Non-organic visual loss refers to visual loss that is not attributable to any organic cause, and is therefore a diagnosis of exclusion. It is divided into two types: conversion reaction (previously known as hysterical blindness) and malingering. In conversion reaction disorders, patients truly believe they have lost vision and this is usually associated with environmental stresses (e.g. impending exams) and is considered to be a method of coping with such pressures. Malingering patients, however, consciously mimic visual loss to obtain an external secondary benefit such as financial or legal gain. Malingers can be uncooperative during the examination process and may even try to actively deceive the examiner.

Although the ophthalmologists' role in patients with non-organic visual loss is to exclude any attributable, organic cause for their visual symptoms, it is important to remember that non-organic visual loss can coexist with genuine pathology, and have caution in making a diagnosis of non-organic visual loss in children.

### Differential diagnosis

Ocular pathologies that may have subtle clinical signs and should therefore be considered in the differential diagnosis of unexplained visual loss include:

- amblyopia,
- keratoconus,
- retrobulbar neuritis,
- cone-rod dystrophy,
- cortical blindness,
- early chiasmal tumours.

### Clinical evaluation

Non-organic visual loss may affect one or both eyes, and be of total or near total blindness. Suspicion should be raised in patients who claim total visual loss, yet can navigate smoothly around the hospital and cannot perform tests of proprioception (e.g. touching index fingers together or signing one's name).

Further ways of assessing the validity of claimed total visual loss include:

- response to a visual threat indicates some degree of vision,
- mirror test: rotating a mirror before a patient and observing for pursuit movements,
- optokinetic nystagmus elicited with a rotating drum indicates a visual acuity of 6/60 or better.

### Investigations

The following tests can also be useful in the assessment of non-organic visual loss.

- Fogging test: plus lenses of progressively increasing power are placed in front of the 'good' eye and visual acuity is measured. This is repeated until a plus lens will sufficiently blur the vision in the 'good' eye, so that the patient must have been reading from their 'bad' eye.
- Prism shift test: a 4D base-out prism is placed in front of the 'bad' eye while the patient fixates on a Snellen chart. Any movement detected or acknowledged diplopia equates approximately to the acuity of the Snellen letter read.
- Stereoscopic tests: patients with 40 seconds of arc stereopsis must have at least have a visual acuity of 6/6.
- Preferential looking: the patient's fixation is observed while various grating acuity cards are shown to them.
- Goldmann visual-field testing: visual-field defects in non-organic visual loss typically remain the same size irrespective of the test distance (spiralling VF).

- Electrophysiological testing: electroretinography and visual-evoked potential tests should be performed if the diagnosis remains in doubt.
- Neuroimaging may be required to further investigate reproducible visual-field defects or suspected cortical blindness.

### Management

- Reassurance that no abnormality with the eyes or brain is present, and that a full visual recovery is expected, is important.
- Psychiatric assessment may be indicated in some cases, although non-organic visual loss alone is not sufficient for referral.

### Prognosis

Good prognostic factors include:

- young age,
- absence of any psychiatric disease.

## 9.20 Neuromuscular junction disorders

### Myasthenia gravis

Myasthenia gravis is an autoimmune disorder of neuromuscular transmission, characterized by fatigability and weakness of muscles, and can include ocular and systemic features. Myasthenia gravis can occur at any age, although incidence peaks in the third decade for females, and sixth and seventh decades for males.

#### Pathophysiology

Antibodies are directed against the postsynaptic acetylcholine receptors, resulting in a decreased number and altered structure of these receptors. The amount of acetylcholine released from the presynaptic terminal normally decreases with successive nerve impulses (presynaptic rundown) and this, combined with the reduced function of the postsynaptic membrane, results in muscle fatigability. Myasthenia gravis is associated with thymoma (in 10–15% of cases), thymic hyperplasia (85% of cases), and other autoimmune disorders such as hyperthyroidism and pernicious anaemia.

#### Clinical evaluation

##### History and examination

Weakness in myasthenia gravis typically increases during the day and improves with rest. Systemic features include dysphagia, dysarthria, and facial and limb weakness. Myasthenic crisis with severe respiratory difficulty is rare, but can result in death.

Ocular features are present initially in 70% of patients with myasthenia gravis and later develop in up to 90% of cases. These include:

- diplopia: variable and can result from weakness of one or more extraocular muscles;
- ptosis:
  - unilateral or bilateral,
  - most prominent on sustained upgaze,
  - in unilateral ptosis, lifting the ptotic lid may induce ptosis in the contralateral lid (due to Hering's law of equal innervation),
  - Cogan's lid twitch sign may be present where overshoot of the upper eyelid occurs when the patient attempts to look in the primary position after prolonged downgaze of 10–20 seconds.

##### Investigations

- Ice-pack test: ice placed over a ptotic lid for 2 minutes, with a 2 mm or more reduction in ptosis considered significant.
- Tensilon test: used to assess whether any improvement in ptosis or diplopia occurs following edrophonium injection. Heart block can occur rarely during this test so cardiac monitoring and immediately available intravenous atropine (0.5–1 mg) are essential. Intravenous edrophonium (2 mg) is initially given and if no improvement (or adverse effect) occurs after 1 minute, up to 8 mg of edrophonium can be further given.
- Anti-acetylcholine receptor antibody assays are positive in 50% of patients with ocular myasthenia gravis and in 80% of patients with generalized myasthenia gravis.
- Antistriated muscle antibody is present in 84% of patients with thymoma aged less than 40 years old.
- Chest CT to investigate thymic involvement.
- Repetitive supramaximal nerve stimulation produces a progressive decremental response in action potential.
- Single-fibre electromyography produces a characteristic 'jitter'.

### Management

Treatment depends on the severity of symptoms. If disturbing, options include:

- pyridostigmine (anticholinesterase inhibitor): 30–60 mg every 4 hours initially, increasing up to 120 mg TDS,
- immunosuppression with agents including corticosteroids, azathioprine, and cyclosporin may be needed in patients not managed with anticholinesterase inhibitors,
- thymectomy: indicated in all patients with a thymoma, and improvement even occurs in most patients (<55 years) with generalized myasthenia gravis who do not have a thymoma,
- plasma exchange is effective in myasthenic crisis and prior to thymectomy.

#### Prognosis

- In patients with ocular myasthenia gravis, 10–20% undergo spontaneous remission, whereas 50–80% go on to develop generalized myasthenia gravis, usually within 2 years.
- Risk factors for poor prognosis include older age, thymoma, and a short history of progressive disease.

### Lambert–Eaton myasthenic syndrome

Lambert–Eaton myasthenic syndrome occurs as a result of impaired acetylcholine release at the neuromuscular junction, following an autoimmune attack on presynaptic calcium channels. Nearly 50% of cases are associated with small-cell carcinoma of the lung.

Patients can develop proximal muscle weakness and autonomic dysfunction including dry mouth, constipation, and postural hypotension. Ocular features may include dry eye resulting from reduced lacrimation, and intermittent ptosis and diplopia.

Investigations should include imaging of the chest to exclude any lung carcinoma, and calcium-channel antibodies are present in over 50% of cases. In contrast to myasthenia gravis, repetitive nerve stimulation produces increased muscle contractions.

Aside from removal of any underlying carcinoma, treatment options include anticholinesterases and immunosuppressive agents to help increase muscle strength.

## 9.21 Ocular myopathies

Ocular myopathies can cause disorders of ocular motility and ophthalmoplegia, and arise from pathology affecting the extraocular muscles. Acquired causes such as thyroid eye disease and other orbital inflammatory conditions are covered elsewhere, with this section focusing on inherited causes.

### Chronic progressive external ophthalmoplegia

Chronic progressive external ophthalmoplegia is a rare condition, characterized by a slowly progressive paralysis of the extraocular muscles. It occurs as a result of mutations in mitochondrial DNA, leading to impaired protein synthesis within these mitochondria. Chronic progressive external ophthalmoplegia can occur in isolation, but can also occur with systemic features as in Kearns–Sayre syndrome.

#### Clinical evaluation

Ptosis is usually the first clinical sign and is typically bilateral and symmetrical. A reduction in ocular motility then follows, although patients are often not aware of any diplopia, as the impairment is normally symmetrical. Downgaze is usually last to be affected, and saccadic delay also occurs.

Kearns–Sayre syndrome includes the triad of chronic progressive external ophthalmoplegia, pigmentary retinopathy (typically salt-and-pepper RPE changes occurring at the macula) and heart block. Patients may also have proximal muscle weakness, endocrine dysfunction, and deafness.

#### Investigations

- Muscle biopsy is the definitive test with 'ragged red fibres' seen when using a modified Gomori trichrome stain.
- ECG to exclude any conduction defects.
- PCR may reveal mitochondrial DNA mutations.
- Blood lactate and pyruvate levels are usually raised in Kearns–Sayre syndrome.

#### Management

- Ptosis may be helped with lid crutches or surgery.
- Diplopia may be resolved with strabismus surgery.
- Cardiac pacemaker insertion may be required in conduction defects.
- Coenzyme Q10 has been of some benefit with the systemic features in Kearns–Sayre syndrome, although the effects are often transient.

#### Prognosis

- Poor in Kearns–Sayre syndrome, with death commonly occurring in the third to fourth decades.
- In women with Kearns–Sayre syndrome there is an approximately 1 in 24 chance of having affected offspring.

### Myotonic dystrophy

This is an uncommon autosomal dominant condition, characterized by a delay in muscle relaxation following contraction. It arises following a genetic defect on chromosome 19 that results in a triple repeat sequence of CTG nucleotides.

#### Clinical evaluation

Ocular features include:

- bilateral ptosis,
- polychromatic 'Christmas tree' or posterior subcapsular cataracts,
- external ophthalmoplegia,
- pigmentary retinopathy (rarely).

Systemic features include:

- mournful facial expression due to bilateral weakness of facial muscles,
- muscle weakness and difficulty in releasing grip following handshake,
- slurred speech from weakness of tongue and pharyngeal muscles,
- premature frontal baldness and testicular atrophy in males,
- cardiomyopathy that can lead to cardiac failure.

#### Investigations

- DNA analysis.
- Electromyography shows spontaneous, high-frequency discharges.
- Muscle biopsy reveal characteristic changes including rows of nuclei down the centre of muscle fibres.
- Serum creatine kinase is mildly elevated.

#### Management

The treatment of muscle weakness is mainly supportive, with a multidisciplinary approach including neurologists, cardiologists, physiotherapists, and speech therapists often required to manage the systemic features. Genetic counselling should be offered and cataract surgery if symptomatic.

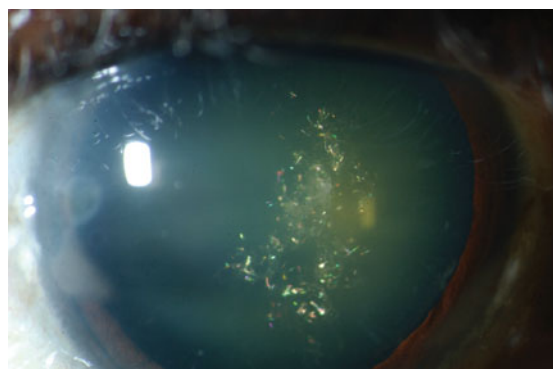


Fig. 9.29 Christmas tree cataract.

### Case 1 Acute visual loss

A 74 year-old man presents with sudden visual loss in his left eye. On further questioning he reveals that he has been feeling unwell in the preceding 3 weeks, with headaches, shoulder pains, and loss of appetite. He is on medication for hypertension, and was previously a heavy smoker and continues to have a high alcohol intake.

On examination his vision is right 6/6, left hand motion. There is a left RAPD. Anterior segments are otherwise normal and his left fundus shows a pale, swollen disc with flame haemorrhages. He is tender over his left temporal region and both temporal arteries are palpable. His blood pressure is 145/98 mmHg.

1. What is the differential diagnosis of visual loss in this gentleman?
2. What investigations would you request?

Results from blood tests show a raised ESR of 86 mm/hour; CRP of 37 mg/l and platelets of  $493 \times 10^9/L$ .

3. How would you now manage this patient?
4. What is the risk of visual loss to the unaffected eye with and without treatment?

A temporal artery biopsy is performed the following day, and the result comes back as positive.

5. What pathological changes would one expect to see with a positive temporal artery biopsy?
6. What are the possible reasons for a negative result?
7. Would a negative biopsy result change the treatment plan in this case?

The patient is discharged from hospital on oral steroids.

8. What factors are important in deciding the duration and dose of steroid intake in the future?
9. What is the visual potential in the affected eye?

#### Discussion

This gentleman has GCA with AION and although other causes of optic neuropathy and acute visual loss can be considered, it is imperative that possible GCA is treated initially. He was commenced on high-dose intravenous methylprednisolone for 3 days, followed by oral prednisolone. His oral steroids were tapered over the following months according to his systemic symptoms and ESR/CRP. His visual potential in the affected eye is poor. If a negative biopsy result occurred, a contralateral biopsy should be considered, but in view of the typical features of his presentation, steroid treatment should not be withheld.

### Case 2 Sudden-onset diplopia

A 53 year-old man attends eye casualty after experiencing double vision for the last 6 hours and has also noticed that his right upper eyelid is beginning to droop. He also mentions that he has had a headache for a day. He has no previous ocular or medical history and smokes 10–15 cigarettes per day.

On examination, there is a near complete ptosis on the right side. Pupils are of equal size and reacting normally. The right eye is depressed and abducted in the primary position. Eye movements of the right eye are moderately reduced in all directions except for abduction and downgaze, and horizontal diplopia is present in all positions of gaze. The rest of the ocular and cranial nerve examination is normal. His blood pressure is 155/91 mmHg.

1. What is the differential diagnosis of this presentation?
2. What investigations would you perform?
3. When would you arrange for the patient to be reviewed and what further advice would you give?

The following day, the patient returns and claims that his pupils are of different sizes. While raising his right upper lid, it is evident that his right pupil is dilated and has a reduced reactivity to light.

4. What condition must be excluded and what investigations would help to do this?

Investigations reveal the presence of a posterior communicating artery aneurysm and the patient undergoes endovascular coiling of the lesion.

5. What is the prognosis for recovery of his diplopia and ptosis?
6. What options are available to help manage any residual diplopia or ptosis?

#### Discussion

This patient presents with a pupil-sparing third nerve palsy. An ischaemic aetiology is initially considered with blood tests including FBC, glucose, and cholesterol tests performed. Another important differential is an evolving compressive third nerve lesion, which become manifest the next day and an urgent MRA confirms the presence of an aneurysm. Recovery from compressive third nerve lesions is variable and can take many months. Therapeutic options for diplopia include patching, prisms, botulinum toxin, and strabismus surgery. Ptosis surgery should be deferred until after any strabismus surgery is carried out, with a frontalis sling procedure helpful to counteract the lack of levator muscle function.

### Case 3 Headache

A 29 year-old female is referred because she has been experiencing headache for the last 2 weeks. On further questioning she mentions that the headache has worsened over this period and is been worse in the morning in the last few days. Her vision has generally been normal, although she has had two brief episodes of blurred vision following bending down to reach objects. She has suffered from migraines in the past, and puts her current symptoms down to stress at work. Her only regular medication is the oral contraceptive pill.

On examination she is overweight, normotensive, and her vision is 6/5 in both eyes, with normal colour vision. There is no RAPD, and she has full extraocular movements with no diplopia. Anterior segments and normal and optic nerves appear swollen. Visual fields are full.

1. What is the differential diagnosis of this lady's presentation?
2. What investigations would you arrange at this stage?
3. What is the diagnosis?
4. What treatment options are available?
5. What ophthalmic complications can arise from this condition?

Neuroimaging is normal and a lumbar puncture is performed, which has an opening pressure of 31 cmH<sub>2</sub>O and normal composition.

3. What is the diagnosis?
4. What treatment options are available?
5. What ophthalmic complications can arise from this condition?

#### Discussion

This lady presents with features of raised intracranial pressure and therefore urgent neuroimaging is mandatory to exclude a space-occupying lesion or cerebral venous sinus thrombosis. In view of normal imaging and raised cerebrospinal fluid with normal composition, a diagnosis of idiopathic intracranial hypertension is made. Treatment options to relieve her headaches include weight loss, medically reducing intracranial pressure (acetazolamide, diuretics), and lumboperitoneal shunting. Optic nerve sheath fenestration may be required if optic nerve function becomes compromised.

### Case 4 Anisocoria

A 65-year-old male is referred by his optician who noticed him to have asymmetrical pupil sizes. The patient has no visual complaints and no past ocular history. He is generally fit and well, although he mentions he has had a cough for the last 6 weeks. He is on no regular medication and has smoked 15–20 cigarettes per day for the last 40 years.

On examination, visual acuity is 6/6 in both eyes. The pupil sizes are asymmetrical with the right pupil appearing smaller than the left, and this discrepancy increases when the room lights are dimmed. Both pupils have normal reactivity. There is a slight ptosis of the right upper lid. Ophthalmic and cranial nerve examination is otherwise unremarkable. Chest examination reveals percussion dullness and crackles in the right upper lobe.

1. What condition is this gentleman likely to have?
2. What pharmacological tests would help to confirm the diagnosis?
3. What investigations would help to identify the underlying cause?

Pharmacological tests confirm a preganglionic sympathetic lesion, and CXR shows a right-sided apical lung mass. He is referred to the chest team for further management.

#### Discussion

This patient presents with features of a right-sided Horner's syndrome. Cocaine 4% can confirm the diagnosis with hydroxyamphetamine helpful in identifying the level of the underlying lesion. His history of smoking and chest signs should alert the possibility of an apical lung mass (preganglionic lesion), which is subsequently discovered.

### Case 5 Nystagmus

A 42-year-old man is referred by his GP after noticing his eyes moving in an increasingly odd manner in the last 2 months. He has no past ocular or medical history. He has been having increasing headache and balance difficulties recently and mentions that an uncle of his died from 'some brain problem' in his early fifties.

On examination, visual acuity is 6/5 in both eyes. He has a bilateral, symmetrical, jerky nystagmus, with the fast phase beating downwards. The nystagmus increases upon lateral gaze and is not dampened by convergence. Ocular and cranial nerve examination are otherwise normal.

1. What is the name given to this type of nystagmus?
2. What is the most likely site of pathology and what are the most common causes?
3. What investigations would be helpful?

Neuroimaging reveals a mass like lesion in the craniocervical junction region, and he is referred to neurosurgery for further management.

#### Discussion

This patient has downbeat nystagmus which is usually caused by posterior fossa lesions at the level of the craniocervical junction. Causes include Arnold–Chiari malformations, demyelination and infarction, and neuroimaging is required to identify the underlying cause.



*This page intentionally left blank*

## Chapter 10

# Orbit

Claire Daniel, Venki Sundaram, and Jimmy Uddin

---

### Basic sciences

- 10.1 Orbital anatomy 400

---

### Clinical skills

- 10.2 Orbital history and examination 402

---

### Clinical knowledge

- 10.3 Orbital infections 404  
10.4 Orbital inflammatory disease 406  
10.5 Orbital vascular malformations 408  
10.6 Orbital tumours I 410  
10.7 Orbital tumours II 412  
10.8 Thyroid eye disease 414  
10.9 Orbital fractures and trauma 416  
10.10 Orbital surgery 418

---

### Case-based discussions

- 10.11 Case 1 Childhood proptosis 420  
Case 2 Non-axial proptosis 420  
Case 3 Traumatic proptosis 420  
Case 4 Orbital pain 420  
Case 5 Diplopia following trauma 420

## 10.1 Orbital anatomy

### Bony and soft-tissue anatomy

The orbit is a pyramid shape with the apex posterior-medially conducting the optic nerve. The orbital rim is made of thick bone, but the walls are thinner and more likely to fracture with a direct blow to the globe. Inferiorly the orbital floor is made from the maxilla, palatine, and zygomatic bones. The lateral wall of the orbit consists of the greater wing of sphenoid posteriorly and the zygomatic bone anteriorly. The frontal bone provides the roof of the orbit. The medial orbital wall is thinnest and is made up from the ethmoidal, lacrimal, and maxillary bones. The ethmoidal bone along the medial wall is paper-thin and is perforated by many foramina for blood vessels and nerves. This is a common entry site for infection from the ethmoid sinus, causing orbital cellulitis.

The optic canal is contained within the lesser wing of sphenoid and connects the middle cranial fossa with the orbit. It transmits the optic nerve, ophthalmic artery, and sympathetic plexus within the surrounding dural-arachnoid sheath.

The superior orbital fissure is a slit-like division between the greater and lesser wing of sphenoid. The superior part of the fissure contains the lacrimal frontal and trochlear nerves and the superior ophthalmic vein. Inferiorly the fissure contains the oculomotor, abducens, and nasociliary nerves along with sympathetic fibres. Any disease at the apex or involving the superior orbital fissure can therefore result in ophthalmoplegia, proptosis, and chemosis due to venous congestion.

The inferior orbital fissure divides the greater wing of sphenoid and maxilla. It connects the orbit to the pterygopalatine and infratemporal fossae. It transmits the maxillary/infraorbital nerve, the zygomatic nerve, and branches of the pterygopalatine ganglion and the inferior ophthalmic vein. Orbital lymphoma and fungal infections may infiltrate this area.

The soft-tissue structures covering the anterior orbit can be divided into skin, orbicularis muscle, septum, preaponeurotic fat, eyelid retractors, tarsus, and conjunctiva. The septum is a fibrous sheet attached to the orbital rim periosteum peripherally and attaches to the tarsus in the upper and lower lids. It is an important structure as it limits spread of infection into the orbit and can trap retrobulbar haemorrhage in the orbit, causing optic nerve compromise. (The extraocular muscles and lid anatomy are dealt with in separate chapters.)

The lacrimal gland is situated in the upper temporal anterior orbit (in the lacrimal fossa) and is divided by the lateral horn of the levator aponeurosis into the orbital and palpebral lobes. Tears are drained from the eye via the lower (80%) and upper (20%) punctum into the lower and upper canaliculi. These join to form the common canaliculus which drains into the lacrimal sac lying in the lacrimal sac fossa. The nasolacrimal duct drains tears into the nose via the inferior meatus, which lies under the inferior turbinate.

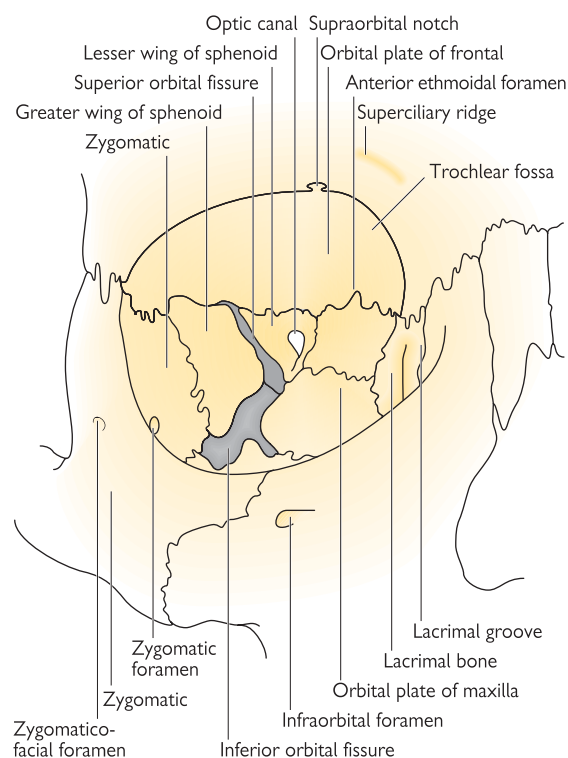
### Orbital blood supply

The ophthalmic artery is a branch from the internal carotid and enters the orbit through the optic canal, usually inferolateral to the optic nerve. It is the main arterial supply to the orbit and globe. It is encased within the dural sheath of the optic nerve until it exits from the optic canal and travels anteriorly in the orbit.

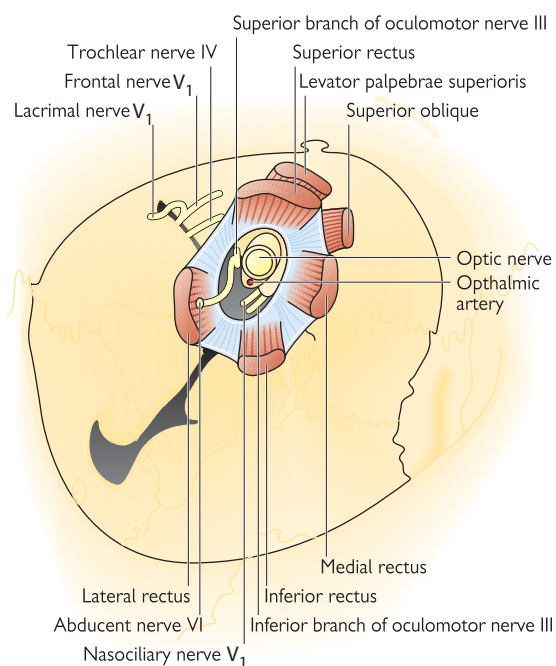
The veins of the eyelids drain into the ophthalmic and angular veins medially and the superficial temporal vein laterally. Infection can spread to the cavernous sinus through the anastomosis of the angular and supraorbital veins with the superior orbital vein or via the deep facial vein anastomosis to the pterygoid plexus.

### Orbital nerve supply

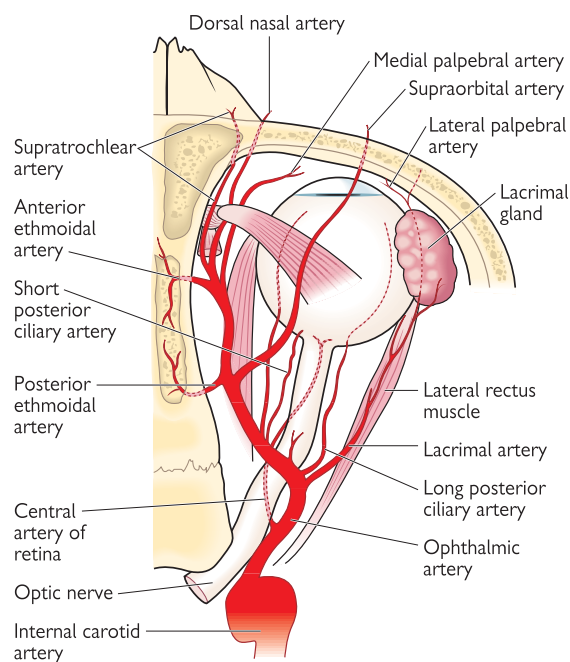
The motor supply of the extraocular muscles is from the oculomotor, trochlear, and abducens nerves. The oculomotor and abducens nerve enter the orbit via the apex within the fibrous ring of the origins of the recti muscles and travel anteriorly within the cone of recti muscles. The oculomotor nerve supplies all the extraocular muscles apart from the superior oblique and the lateral rectus. The abducens nerve supplies the lateral rectus muscle. The trochlear nerve enters the orbit through the superior orbital fissure, superior to the fibrous ring, and has a short course anteriorly to the superior oblique muscle. The sensory nerves within the orbit apart from the optic nerve are the first and second branches of the trigeminal nerve, which are the ophthalmic and maxillary nerves respectively. The ophthalmic nerve gives off the lacrimal, frontal, and nasociliary nerves, whereas the infraorbital and zygomatic branches arise from the maxillary nerve.



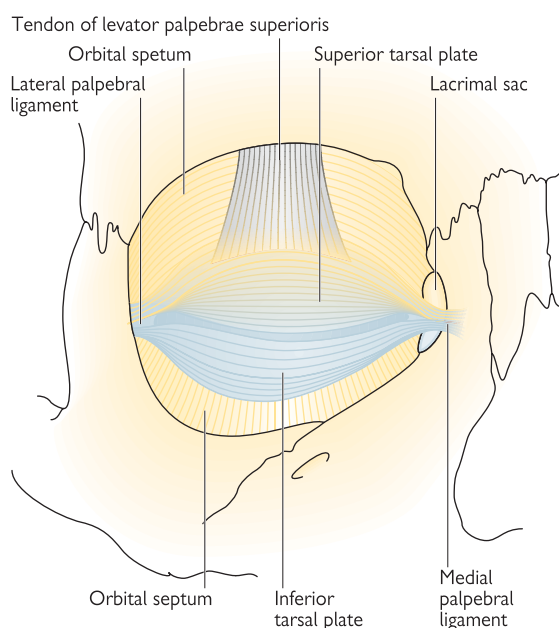
**Fig. 10.1** Bony anatomy of the orbit.



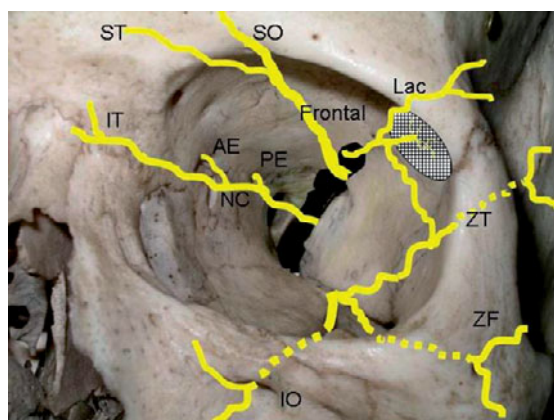
**Fig. 10.2** Superior orbital fissure.



**Fig. 10.4** Arteries within the orbit.



**Fig. 10.3** Septum and soft-tissue structures surrounding the orbit.



**Fig. 10.5** Orbital sensory nerve supply. AE, anterior ethmoidal nerve; IO, infraorbital nerve; IT, infratrochlear nerve; Lac, lacrimal nerve; NC, nasociliary nerve; PE, posterior ethmoidal nerve; SO, supraorbital nerve; ST, supratrochlear nerve; ZF, zygomaticofacial nerve; ZT, zygomaticotemporal nerve. Shaded area is the lacrimal gland. Cambridge Ophthalmology Symposium. 2006. *Update on orbital anatomy*. Reprinted with kind permission of Nature Publishing and Mr Cornelius René.

## 10.2 Orbital history and examination

### History taking

#### Presenting complaint

When taking a history for orbital disease it is vital to ascertain any change in optic nerve function (decreased visual acuity, colour vision, field loss), speed of symptom onset, pain, and the presence of diplopia. Pain may support a diagnosis of inflammatory disease (but is not synonymous) and is also present in destructive lacrimal gland carcinoma. Paraesthesia and pain may indicate nerve involvement in carcinoma or a neuroma. Examination of old photographs is often useful in ascertaining premorbid appearance and onset of symptoms (especially longstanding lesions such as pleomorphic adenoma).

#### Past ophthalmic history

Enquire about previous surgery or trauma that may result in facial asymmetry, enophthalmos or other globe displacement.

#### Past medical history

Include direct questions about any history of thyroid dysfunction (even if this has not been clinically diagnosed): ask for loss or gain of weight, flushing, tremor, palpitations, sweating or intolerance of heat, and loss of hair. A patient with thyroid eye disease may be euthyroid, hypothyroid, or hyperthyroid. Smoking history is relevant as this greatly aggravates thyroid eye disease. Orbital inflammatory disease may be associated with a systemic inflammatory condition such as sarcoidosis and vasculitides (patients with Wegener's granulomatosis may have nasal symptoms).

Primary tumours may invade from adjacent structures; for example, nasopharyngeal carcinoma with associated sinus symptoms. Metastatic orbital disease often has a history of carcinoma (e.g. breast, lung, bowel), chemotherapy, or radiotherapy, and recurrence of the tumour elsewhere.

#### Drug history

Medications: long-term steroids or other immunosuppression may mask inflammatory lesions, and anticoagulants can lead to bleeding within the orbit from vascular lesions. If the patient is dysthyroid it is important to know their systemic thyroid status and stability (on their current medication).

#### Family history

It is important to determine idiopathic familial proptosis, strabismus, telecanthus, etc.

### Examination of orbit

Firstly assess vision and optic nerve function (indicated by \* in the list below). The following must always be included in an orbital examination:

- best-corrected visual acuity\*,
- presence of an afferent pupillary defect\*,
- colour vision\*,
- visual fields (to confrontation)\*,
- facial appearance; for example, orbital dystopia, hemifacial asymmetry, scars,
- proptosis (see exophthalmometry, below),
- non-axial proptosis: hyper- or hypoglobus,
- palpable masses, especially superotemporal; for example, lacrimal gland and medial canthal (e.g. mucocele),
- localized swelling (colour, e.g. haemangioma may be bluish), fixation to tissue (bony or skin), variability with Valsalva manoeuvre,
- tenderness and ease of retropulsion of the globe,
- bony rim in trauma,

- upper lid position and function (see 2.6): marginal reflex distance, levator function, skin-crease height,
- lower lid malposition, especially inferior scleral show and displacement (the most reliable sign for relative proptosis),
- diplopia and its pattern (in any of the nine positions of gaze),
- ocular motility (especially limitation),
- conjunctival vessels for evidence of abnormal orbital flow,
- IOP in primary position and on upgaze (IOP increases in restrictive disease),
- fundoscopy for disc swelling/pallor/venous congestion, and retinal/choroidal folds,
- lymphadenopathy,
- sensation; for example, infraorbital nerve with blow-out fracture, supraorbital in infiltrative disease.

### Exophthalmometry

Exophthalmometry is an assessment of the position of the globe in relation to the lateral orbital rim. The type of proptosis is important in deciding the site of the orbital lesion. Axial proptosis is indicative of lesions within the muscle cone (intraconal) and of the muscle itself. Causes include cavernous haemangioma, gliomas, metastases, and meningiomas but more commonly thyroid eye disease.

Lesions outside the extraocular muscle cone (extraconal) can lead to displacement of the globe away from the lesion. Dermoid cysts and lacrimal gland tumours such as pleomorphic adenomas cause displacement of the globe inferomedially. Sinus disease may cause displacement of the globe superiorly if it originates from the maxillary sinus, laterally if the ethmoidal sinus or inferiorly if the frontal sinus is involved. Bilateral disease suggests thyroid eye disease, lymphoma, vasculitis, and idiopathic orbital inflammation. Enophthalmos (displacement of the globe posteriorly) is caused most commonly by orbital fractures, and rarely by scirrhous inflammation or carcinoma.

There are several different exophthalmometers, which vary in how measurements are taken and ease of use, with the basic routine as follows.

1. Sit opposite the patient at a similar eye level.
2. Place lateral processes on patient's lateral orbital rim and note horizontal width.
3. Close your right eye and ask patient to look at your left (open) eye.
4. Align parallax marker on exophthalmometer and measure where patient's right corneal apex appears on the scale.
5. Repeat for the left eye.


#### Non-axial proptosis

To measure horizontal globe displacement, a ruler is placed horizontally over the bridge of the nose at the lateral canthi level. Measure the corneal light reflection in both eyes from the centre of the nasal bridge.


Vertical displacement is measured using a second ruler aligned vertically against the horizontal ruler, and measuring the corneal light reflection from a fixed point on the vertical ruler.

Bilateral proptosis is suspected if the reading is over 22 mm in Caucasians and 24 mm in Afro-Caribbean populations. The difference between the two eyes is normally equal or less than 2 mm. Pseudoproptosis may be caused by ptosis or enophthalmos of the contralateral eye, facial asymmetry, axial myopia or buphthalmos, or upper or lower eyelid retraction of the ipsilateral eye.





(a)



(b)

**Fig. 10.6** Exophthalmometer measurement: (a) positioning exophthalmometer and (b) aligning parallax marker.

## 10.3 Orbital infections

### Preseptal cellulitis

The orbital septum is a tough fibrous structure which can limit the spread of infection from the skin and subcutaneous tissues from entering the orbit proper. However, this is less true in children in whom infection can spread rapidly and cause the more serious orbital cellulitis.

#### Aetiology

Most common cause of preseptal cellulitis is *Staphylococcus aureus* or *Streptococcus pyogenes* from the skin, meibomian glands, nasolacrimal sac, or sinusitis.

#### Clinical evaluation

##### History

- Acute over a matter of days.
- Pain, swelling, tenderness, and redness over the upper/lower lid.
- Importantly there is no deterioration in vision, diplopia, or conjunctival hyperaemia or congestion.

##### Examination

- Overlying skin is red, tender, hot, and oedematous.
- Lids should be opened and the ocular movements should appear normal with no sign of diplopia and no restriction of motility.
- Conjunctiva may or may not be inflamed.
- Optic nerve functions should be normal.
- No proptosis.

#### Treatment

- Oral antibiotics are required for 10 days, for example co-amoxycylav (Augmentin) 250 mg QDS in adults and children over 6, and 125 mg QDS suspension for children of 6 or under.
- In children regular review is essential. Have a low threshold for admission for intravenous cephalosporin antibiotics as infection can progress rapidly.

### Orbital (postseptal) cellulitis

This is a much more serious problem and can be life-threatening due to spread into the meninges. Ocular complications include raised IOP, occlusion of the central retinal artery or vein, keratopathy due to corneal exposure, and endophthalmitis. If this condition is suspected then a full ophthalmic and systemic assessment is essential.

#### Aetiology

- Most common organisms are *Staph. aureus*, *Streptococcus pneumoniae*, *Strep. pyogenes*, and *Haemophilus influenzae* (less now with Hib vaccination).
- The infection most commonly spreads from the adjacent sinuses, but may result from preseptal cellulitis, dacryoadenitis, dacryocystitis, or trauma; for example, from an orbital fracture.

#### Clinical evaluation

##### History

- Onset is acute over a few days with systemic upset, nausea, vomiting, and general malaise.
- May have preceding coryzal symptoms
- Fever, pain, visual deterioration, and diplopia are typical.

##### Examination

- Pyrexial.
- Examination of a child may be difficult and make definitive assessment impossible.
- Eyelids are red, tender, and swollen.

- Conjunctival chemosis may be present.
- Potential optic nerve function compromise.
- Proptosis may or may not be present; however, this is often difficult to judge to the swelling of the surrounding tissues.
- Fundoscopy may reveal disc swelling and or retinal venous congestion.
- Diplopia and pain on eye movement are common.
- Ear, nose, and throat examination from ENT colleagues as sinus disease is the most common cause.

#### Investigations

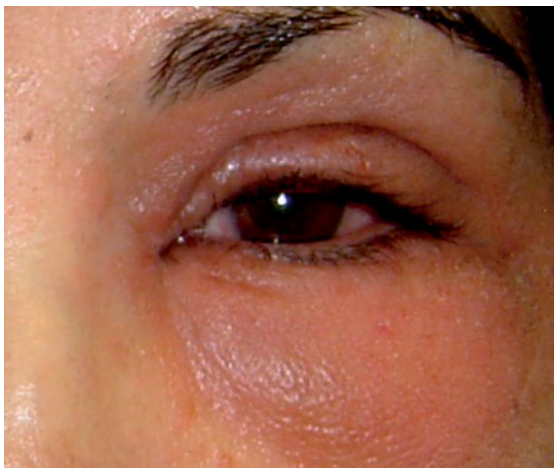
- Swab purulent discharge.
- Bloods: FBC, cultures, CRP.
- Urgent CT scan of the orbits and brain.

#### Treatment

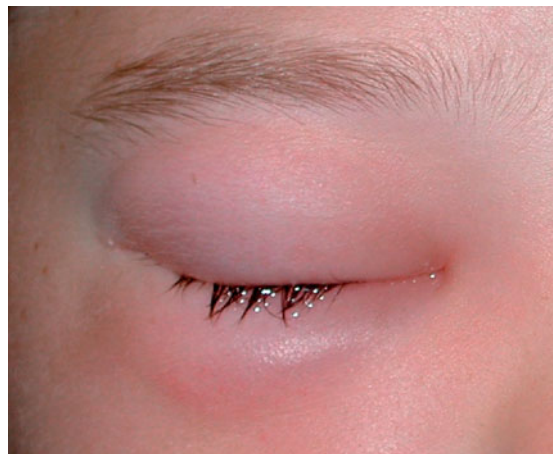- Admission with a multidisciplinary team (including paediatricians, ENT, microbiology) and immediate intravenous antibiotics are essential. Usually intravenous ceftazidime (1g TDS) and metronidazole (500 mg TDS) are the antibiotics of choice (vancomycin if penicillin allergy).
- Regular 4 hourly recording of visual acuity, colour vision, and pupillary defect are essential to look for progression until infection subsides.
- Surgical drainage may be necessary if there is no response to antibiotic therapy or large abscess formation.
- Patient under the age of 9 usually respond to antibiotics. Older children and adults have more severe aetiology and often need surgical intervention.

### Mucormycosis

This is a rare, opportunistic, life-threatening, fungal infection which may affect immunocompromised or diabetic patients. It often presents with discharge around the periorbital tissues with black eschars along with orbital cellulitis signs. Treatment involves intravenous amphotericin, daily wound cleaning, and surgical debridement of the wound with hyperbaric oxygen.



**Fig. 10.7** Preseptal cellulitis.



**Fig. 10.8** Orbital cellulitis.

## 10.4 Orbital inflammatory disease

### Idiopathic/non-specific orbital inflammatory disease

Presentation varies according to its anatomical origin within the orbit. Diffuse soft-tissue inflammation and lacrimal gland involvement are common. Tolosa Hunt syndrome refers to idiopathic inflammation in the orbital apex, superior orbital fissure or anterior cavernous sinus causing painful ophthalmoplegia. It affects both children and adults.

#### Aetiology

- Inflammation of the orbital tissues of unknown cause.
- Histological appearance of pleomorphic cellular infiltrate lymphocytes, plasma cells, and eosinophils leading to a reactive fibrosis.

#### Clinical evaluation

##### History

- Symptoms depend on the area of the orbit affected.
- Usually present with acute or subacute onset orbital pain, diplopia, and proptosis.
- Chronic fibrosing disease may have less pain.
- May often have recurrent episodes.
- Vision may be affected.

##### Examination

- Eyelids appear variably red and swollen along with conjunctival chemosis and soft-tissue swelling.
- May have reduced vision.
- Systemic signs and fever also suggest infective process.
- Concurrent sinusitis is common. Not always painful; sometimes chronic fibrosing disease.

##### Differential diagnosis

- Orbital cellulitis.
- Orbital vasculitis.
- Orbital myositis.
- Dacryoadenitis.
- Ruptured dermoid cyst.
- Cavernous sinus thrombosis.
- Arteriovenous fistula.
- Orbital tumour (lymphoma).
- Lacrimal gland tumour.
- Mucormycosis.
- Thyroid eye disease.

##### Investigations

- CT scan may show diffuse or local involvement. Orbital fat may be more streaky, lacrimal gland may be enlarged (e.g. dacryoadenitis), and thickening of extraocular muscles and sclera may be present. Bone destruction is rare.
- B-scan may show concomitant scleritis with scleral thickening and an acoustic hollow due to oedema in Tenon's capsule.
- Raised ESR and white cell count are common.
- Bilateral orbital inflammation is suggestive of a systemic inflammation. Causes include vasculitis or lymphoproliferative disease, although in children one-third of cases are bilateral, and are rarely associated with systemic vascular disease.
- FBC with differential (especially eosinophilia), ESR, CRP, ANA, ACE, ANCA, and CXR.
- Biopsy may be necessary for confirmation and to exclude other pathology such as lymphoma (although biopsy is sometimes inconclusive).

#### Management

- NSAIDs are effective in milder cases.
- High-dose systemic steroids give a prompt response in idiopathic inflammatory disease, but beware as this is also the case initially with lymphoma, metastases, ruptured dermoid cysts, and cellulitis. Consider biopsy first.

### Orbital myositis

#### Aetiology

- Idiopathic inflammation of extraocular muscles.
- Variant of idiopathic orbital inflammatory disease.

#### Clinical evaluation

- More common in young adults.
- Acute periocular pain, especially on eye movement of the affected muscle.
- Periocular swelling and conjunctival chemosis.
- Diplopia.
- Ptosis.
- Proptosis if severe.

#### Investigations

- CT and ultrasound show fusiform enlargement of the involved extraocular muscles, usually with involvement of the muscle tendons.

#### Management

- Biopsy if diagnosis in doubt.
- NSAIDs for mild disease.
- Oral steroids for moderate to severe disease. The disease may recur once steroids are tapered and second-line immunosuppression should be considered.
- Radiotherapy for chronic severe disease may be beneficial.

### Vasculitis

These are type III hypersensitivity reactions, where the vessel walls are infiltrated with inflammatory cells.

#### Wegener's granulomatosis

This is a systemic small-vessel vasculitic disease process characterized by necrotizing granulomatous inflammation in the respiratory tract and necrotizing glomerulonephritis, although the vasculitis may affect any organ. Presents at any age but more commonly in the fifth decade. Orbital involvement occurs by direct sinus mucosa inflammation with bone erosion, generalized orbital soft-tissue inflammation, peripheral retinal arteritis, or nasolacrimal duct obstruction. Up to 25% of patients with Wegener's granulomatosis have an associated scleritis.

Histologically there is a typical picture of vasculitis, granulomas, and tissue necrosis. Cytoplasmic ANCA can be present in 80% of patients with Wegener's granulomatosis and higher if there is active disease. Treatment is with systemic steroids and or cyclophosphamide under the care of a rheumatologist.

#### Polyarteritis nodosa

Polyarteritis nodosa is a vasculitis that affects any small and medium-sized arteries and rarely the orbit. More common in women and tends to present in middle age.

Histologically there is fibrinoid necrosis of the muscularis layer within the vessel walls and infiltration of neutrophils and eosinophils leading to thrombosis and infarction.

Polyarteritis nodosa may affect the orbit by generalized orbital inflammation, a vasculitic rash on the skin, and scleritis. Can also cause retinal periarteritis and keratitis.

Investigations show anaemia and raised inflammatory markers, eosinophilia, and hypergammaglobulinaemia. Perinuclear ANCA may be positive in 15–20% of cases.

Treatment is with immunomodulatory therapy such as systemic steroids along with rheumatological referral.

### Systemic lupus erythematosus

Systemic lupus erythematosus is a multisystem vasculitic disorder causing arthralgia, rashes, and cerebral and renal disease. Typically presents in the third to fifth decades and is more common in women.

Systemic lupus erythematosus may rarely affect the orbit by involving the lids in the typical butterfly rash, madarosis (loss of lashes), or if the lacrimal gland becomes involved this can lead to keratoconjunctivitis sicca (dry eyes).

### Thrombophlebitis of the orbital vein

Thrombophlebitis of the orbital vein is an unusual condition characterized by congestion pain and varicosities of the eyelids. Also may cause diplopia and decreased vision. Causes are idiopathic or associated with spread of orbital infection from the angular vein of the cavernous sinus via the supraorbital veins.

## Dacryoadenitis

Dacryoadenitis is an acute or chronic inflammation of the lacrimal gland.

### Aetiology

- Inflammatory: mostly idiopathic and acute.
- Viruses: herpes zoster; influenza, mumps, infectious mononucleosis.
- Bacteria: *Staph. aureus*, *Neisseria gonorrhoeae*, streptococci, syphilis, tuberculosis.
- Lymphoproliferative disorders.
- Sarcoidosis.

### Clinical evaluation

- Presents as redness, pain, and swelling originating in the lateral upper lid.
- Typically occurs in children and young adults.
- 25% of patients who present with idiopathic orbital inflammation have dacryoadenitis.

### Differential diagnosis

Ruptured dermoid cyst, adenoidcystic carcinoma, malignant pleomorphic adenocarcinoma, plasmocytoma.

### Investigations

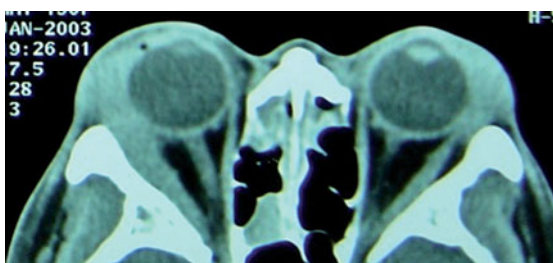
- Conjunctival swabs.
- FBC with differential, ESR and CRP, ANA.
- CT: especially if associated with proptosis or diplopia.
- CXR and serum ACE, VDRL, FTA-ABS, Mantoux test, EBV serology.
- Biopsy may be necessary if a malignancy is suspected or if diagnosis is uncertain.
- Biopsy is not recommended if pleomorphic adenoma or if dermoid is suspected: lesion should be removed in total instead.

### Treatment

- Inflammatory cases treated with NSAIDs or steroids.
- Acute infective dacryoadenitis: augmentin 250 mg TDS by mouth in adults and 20–40 mg/kg per day in three divided doses in children. Or, if severe, intravenous cefuroxime 750 mg QDS adults and 60 mg/kg per day in three divided doses in children.
- Analgesia.

### Differential diagnosis of lateral orbital swellings

- Dacryoadenitis.
- Lacrimal gland tumour, for example pleomorphic adenoma, lymphoma, lacrimal gland carcinoma.
- Idiopathic orbital inflammatory disease.
- Dermoid cyst.
- Preseptal and orbital cellulitis.
- Dacryops.
- Neurofibroma.
- Thyroid eye disease.



**Fig. 10.9** CT showing diffuse enlargement of lacrimal glands in dacryoadenitis.



## 10.5 Orbital vascular malformations

### Capillary haemangioma

#### Aetiology

- A type of congenital hamartoma and a common, benign vascular tumour in children.
- Can be superficial (also known as 'strawberry naevus' and confined to dermis) or deep (usually posterior to orbital septum).
- Undergo episodic periods of growth but mostly eventually begin to involute after the age of 2 years.
- 75% of superficial lesions will have resolved by the age of 4.

#### Clinical evaluation

- Superficial lesions often present from birth, or a few weeks later, as a small red mark in the lid. Usually grow significantly in the first year and may have similar haemangiomas elsewhere on the body.
- Deep lesions may cause proptosis, globe displacement, and increase in size with Valsalva manoeuvres or crying.
- May lead to anisometropia and amblyopia.

#### Investigations

- Ultrasound to exclude rhabdomyosarcoma (by showing vascularity).
- Regular refraction and repeated ultrasound to determine progression.
- MRI shows a well-defined intra- or extraconal lesion in deep lesions.

#### Treatment

- Conservative, unless amblyopia is developing in which case intralesional steroid injections or oral steroid (2 mg/kg) can be useful.
- Repeated steroid injections in and around the lesion may be necessary depending on response.

### Cavernous haemangioma

#### Aetiology

- A hamartoma and the most common benign vascular neoplasm in the adult orbit.
- More common in middle-aged women.
- Can occur anywhere but commonly in the retrobulbar space.
- Histology: blood-filled spaces separated by thin fibrous septae, lined by endothelium.

#### Clinical evaluation

- 70% develop slowly progressive proptosis, but may accelerate in pregnancy.
- May cause hyperopia, retinal striae, optic neuropathy, raised IOP, and strabismus.

#### Investigations

- Ultrasound with Doppler, CT, MRI with contrast.

#### Treatment

- Surgical excision if there is ocular dysfunction.

### Arteriovenous malformations

#### Carotid-cavernous fistula

##### Aetiology

*High-flow (direct) carotid-cavernous fistula*

- Direct communication between intracavernous internal carotid artery and cavernous sinus.
- Usually arises from direct trauma such as basal skull fracture.

*Low-flow (indirect) carotid-cavernous fistula*

- Communication with meningeal branches of the internal, external (or both) carotid arteries with the cavernous sinus.
- Arises from spontaneous fistula formation following degenerative processes in patients with systemic hypertension and arteriosclerosis.

##### Clinical evaluation

*High-flow*

- Pulsatile proptosis with bruit, reduced visual acuity.
- Engorged tortuous epibulbar vessels, chemosis, raised IOP.
- Ocular ischaemia from steal of arterial blood.
- Variable ophthalmoparesis although increased pressure in cavernous sinus and apex syndrome.

*Low-flow*

- Slower onset with orbital congestion, proptosis, and mild pain.
- Patients tend to develop a chronic red eye and asymmetrical elevation of IOP.

##### Investigations

- CT shows enlarged extraocular muscles and engorgement of superior ophthalmic vein.
- Ultrasound shows enlarged superior ophthalmic vein.
- MRI/MRA.
- Angiography.

##### Treatment

- High-flow carotid-cavernous fistulas require radiological interventional closure with coils or embolization.
- Low-flow carotid-cavernous fistulas often close spontaneously but closure may be required if complications arise.

### Primary varices

Primary varices are dilatations of pre-existing venous channels within the orbital venous system. They enlarge with increased venous pressure and can therefore present with proptosis or visible varices with Valsalva or head-down posture. Complications include haemorrhage and thrombosis.

Contrast-enhanced CT is helpful in delineating the varices and phleboliths (calcium deposition) may be present.

Treatment is usually conservative, with surgery only if vision is threatened from optic nerve compression or severe proptosis. Surgery is difficult as varices are often intertwined with orbital tissues and direct communication with cavernous sinus.

### Lymphangioma

These are hamartomatous, congenital malformations of the lymphatic system that involves skin and subcutaneous tissue. Histologically they comprise of large serum-filled spaces lined with flattened, delicate endothelial cells.

##### Clinical evaluation

- Uncommon and usually present in childhood.
- Superficial lesions present as cystic spaces with clear fluid (or partially filled with blood) on the lid or conjunctiva. Can enlarge with Valsalva manoeuvre, head-down posture, or during upper-respiratory-tract infections.
- Deep lesions may cause gradual proptosis, or spontaneous haemorrhage (with loculated, blood-forming 'chocolate cysts') may occur, resulting in sudden enlargement, orbital pain, and visual loss.

##### Investigations

- Ultrasound, CT, or MRI.

### Treatment

- Spontaneous regression often occurs.
- Intralesional haemorrhage may need emergency surgical drainage but there is a high incidence of recurrence of spontaneous haemorrhage.
- If there is diffuse infiltration of the orbit, causing reduced function of orbital tissues, then debulking may be necessary but difficult.



Fig. 10.10 Capillary haemangioma.

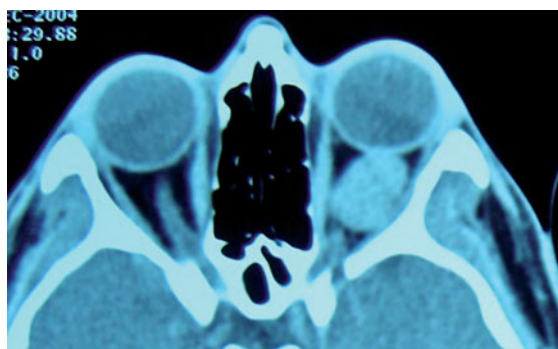

Fig. 10.11 CT of intraconal cavernous haemangioma.

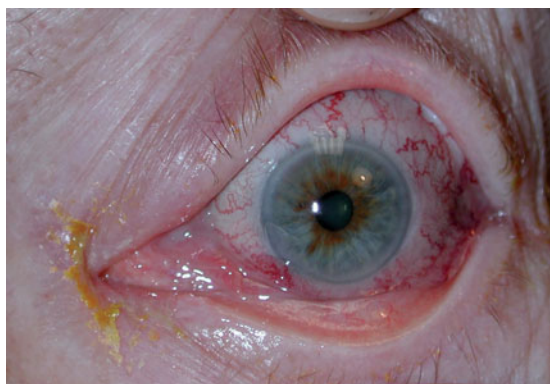

Fig. 10.12 Low-flow carotid-cavernous fistula.

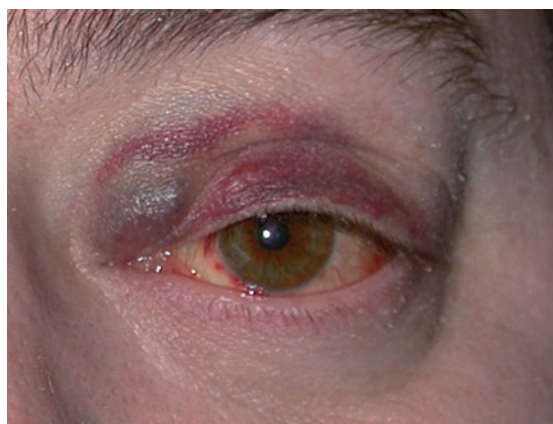

Fig. 10.13 Primary varices with recent bleeding.

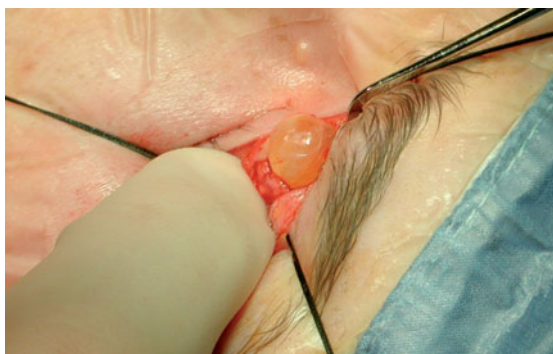


Fig. 10.14 Orbital lymphangioma: perioperative picture.

## 10.6 Orbital tumours I

### Glioma

Optic nerve gliomas are slow-growing pilocytic astrocytomas and represent 4% of orbital tumours. They are commonly associated with neurofibromatosis-1.

#### Clinical evaluation

- Usually presents at the end of the first decade and is slightly more common in females.
- Causes slowly progressive visual loss and later proptosis.
- Swollen ONH, then later pallor and optociliary shunt vessels can occur.
- Possible intracranial spread to chiasm and beyond.

#### Investigations

- CT and MRI shows fusiform enlargement of optic nerve.

#### Treatment

- Observation if slow growth with good vision.
- Surgery for severe proptosis, visual loss or if posterior extension is threatened.
- Radiotherapy with adjunctive chemotherapy for intracranial extension.

#### Prognosis

- Poor visual prognosis. Higher mortality with posterior extension.

Glioblastomas or malignant optic nerve gliomas are very rare, occurring mostly in middle-aged males, and can present with symptoms of optic neuritis. These require more aggressive management.

### Meningioma

Meningioma is an invasive tumour arising from the arachnoid villi either locally in the orbit or intracranially, with secondary extension through bony erosion, or via the superior orbital fistula or optic canal. Histologically, the two most common types are meningothelial and psammomatous (containing pink-staining 'psammoma' bodies). Incidence increases with age.

#### Clinical evaluation

- Symptoms vary on position of tumour.
- Primary orbital meningiomas from the arachnoid of the optic nerve sheath will affect vision early.
- Tumours arising from posterior end of sphenoparietal fissure and lateral wing of sphenoid produce temporal fossa mass and proptosis.
- Lid oedema and proptosis are common.

#### Investigations

- CT: tumour has a radiolucent centre (compared with optic nerve glioma, which has a dense centre). Also shows hyperostosis (thickening of bone and abnormal calcification within the tumour). Occasional bone absorption and destruction.
- MRI can be helpful outlining extent of tumour.

#### Treatment

- Observation if vision is good.
- Surgery carries a high risk of blindness; therefore deferred until intracranial structures are threatened or severe proptosis occurs.

#### Prognosis

- Good prognosis for life but visual prognosis is typically poor.
- Optic nerve sheath meningiomas in childhood are more aggressive and lethal than in adults.

### Neurofibroma

#### Plexiform (diffuse) neurofibroma

Appears almost exclusively with neurofibromatosis-1 in early childhood with periorbital swelling hypertrophy of the periocular tissues. Neurofibromas can cause a mechanical ptosis and S-shaped deformity of the upper eyelid, appearing like a 'bag of worms'. They may be associated with congenital aplasia of the greater wing of sphenoid. Surgical excision is difficult and repeated debulking may be necessary.

#### Isolated neurofibroma

Associated with neurofibromatosis-1 in 10% cases. Presents in adulthood with mildly painful, gradual proptosis. Surgical excision is usually straightforward.

### Rhabdomyosarcoma

Rhabdomyosarcoma is the most common primary orbital malignancy in childhood. It usually presents late in the first decade (but can occur at any age) and boys are affected more than girls (5:3).

Histologically it can be divided into three main categories.

- **Embryonal:** most common type. Usually superonasal with tumour consisting of abnormally shaped rhabdomyoblasts with little evidence of cross striations.
- **Alveolar:** most malignant form. Usually in the inferior orbit, and malignant cells are confined by circular fibrous septae, resembling lung alveoli.
- **Pleomorphic:** rarest but best prognosis. Most differentiated, with rhabdomyoblasts closely resembling striated muscle fibres. Usually affects older children.

#### Clinical evaluation

- Acute/subacute proptosis, lid oedema, ptosis.
- May present as orbital cellulitis and mimic other orbital inflammatory conditions.
- 25% are in the superior orbit and palpable upper lid mass may be present.

#### Investigations

- USS: usually well circumscribed.
- MRI/CT: may show bony destruction.
- Urgent biopsy to confirm diagnosis.
- Full work up for metastases (liaison with paediatric oncologists).

#### Treatment

- Surgical excision if well circumscribed.
- Radiotherapy and chemotherapy often required.

#### Prognosis

- 95% 5year survival if tumour is confined to orbit.

### Lymphoproliferative tumours

Lymphoproliferative disorders represent a continuous spectrum of benign to malignant disease, and mainly affect the elderly. Orbital imaging typically shows a mass that is classically described as 'moulding' around the globe. Diffuse changes may also be present.

They broadly divided into three categories:

#### Benign reactive lymphoid hyperplasia

This benign proliferation of lymphoid follicles and polyclonal colonization most commonly occurs in the anterior-superior orbit, and involves the lacrimal gland in 15% of cases. Presentation is with a gradual prognosis, often with a palpable firm, rubbery mass beneath the orbital rim. Treatment is with systemic corticosteroids

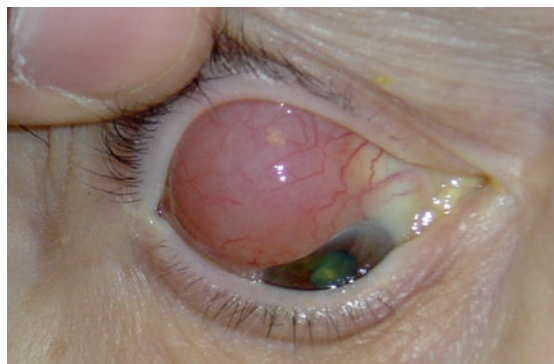
or local radiotherapy. Progression to systemic lymphoma occurs in about 15% of cases by 5 years.

### **Atypical lymphoid hyperplasia**

This is an intermediate between benign reactive lymphoid hyperplasia and malignant lymphoma, with histology showing sheets of lymphocytes and an absence of plasma cells. Its presentation is similar to benign reactive lymphoid hyperplasia, although it is less responsive to corticosteroids.

### **Malignant orbital lymphoma**

This is a low-grade proliferation of monoclonal B cells (non-Hodgkin's) arising in the orbit. Presentation is usually in older age groups (50–70 years) with gradual proptosis and possibly an anterior orbital palpable mass. 25% of cases are bilateral and 40% are associated with systemic disease at presentation. Radiotherapy or chemotherapy is required in poorly differentiated cases or with systemic involvement. 60% develop systemic lymphoma within 5 years.



**Fig. 10.15** Salmon-coloured subconjunctival anterior orbital lymphoma.



## 10.7 Orbital tumours II

### Lacrimal gland lesions

Lacrimal gland swelling is usually due to idiopathic inflammation, which responds to non-steroidal anti-inflammatory treatment. However, lymphoproliferative disorders and tumours can also present with primary lacrimal gland swelling. The majority of lacrimal gland neoplasms are epithelial tumours, with 50% being benign, and 50% malignant.

CT is very helpful at distinguishing lacrimal gland enlargement. Inflammatory and lymphoproliferative lesions tend to cause diffuse enlargement and elongation of the gland, but neoplasms appear as isolated globular masses.

### Epithelial tumours

#### Benign mixed tumour/pleomorphic adenoma

This is the most common epithelial lacrimal gland tumour (50%). Histologically they are comprised of epithelial and mesenchymal elements (hence the term benign mixed tumour), and are typically circumscribed by a pseudocapsule.

They usually present in the fourth or fifth decades, with a mass effect of painless axial proptosis and downward, medial displacement of the globe. A firm palpable mass in the lacrimal gland may be present.

Diagnosis with CT scan shows slightly nodular enlargement of lacrimal gland and expansion of the lacrimal gland fossa.

Treatment is by complete, intact surgical excision. If the capsule is incised there is a significant risk of seeding and recurrence, which is difficult to manage, hence biopsy is contraindicated. Prognosis is good.

#### Malignant mixed tumour

Malignant mixed tumour is similar to the benign mixed form, but has areas of malignant change. It typically arises from long-standing pleomorphic adenomas and has a morbidity of 50% even with exenteration.

#### Adenoid cystic carcinoma

Adenoid cystic carcinoma accounts for 25% of lacrimal gland tumours and is highly malignant. Histology shows hyperchromatic cuboidal cells proliferating around cystic spaces, giving an appearance like Swiss cheese.

It commonly presents in the fourth decade with rapid onset (less than 1 year) of proptosis, diplopia, ophthalmoparesis, and orbital pain from perineural invasion.

CT shows a poorly demarcated lesion with possible bone destruction.

Treatment is with high-dose radiotherapy. Radical orbitectomy is debatable and prognosis is poor.

### Metastatic tumours and sinus invasion

#### Adults

Orbital metastases in adults are rare, although they may be the initial manifestation of an underlying tumour. Presentation is with a rapid proptosis and ophthalmoparesis may develop. Schirrous carcinoma of the breast or stomach may cause enophthalmos because of orbital tissue contraction. Other primary sources include lung, prostate, gastrointestinal tract, and kidney. Occasionally no source is found.

Orbital invasion by sinus tumours is rare, but carries a poor prognosis unless diagnosed early. The maxillary sinus is the most common primary site and causes facial pain, congestion, epistaxis, and nasal discharge. Upward globe displacement, diplopia, and epiphora can occur. Ethmoidal carcinoma can cause lateral dystopia and nasopharyngeal carcinoma has proptosis as a late finding.

#### Children

##### Neuroblastoma

This is the most common tumour during infancy and arises from primitive neuroblasts in the sympathetic nervous system. The tumour has already spread in 50% of cases at the time of diagnosis. Orbital metastases present with rapid proptosis, lid swelling, and superior orbital mass.

##### Granulocytic sarcoma

This is a localized tumour comprised of malignant cells of myeloid origin. It may occur as a manifestation of established systemic myeloid leukaemia or it may precede the disease, in which diagnosis can be difficult. Children and young adults are mostly affected, and rapid proptosis, chemosis, and lid swelling are common.

##### Langerhans cell histiocytosis/eosinophilic granuloma

Langerhans cell histiocytosis (also known as histiocytosis X) is a rare group of disorders, characterized by the proliferation of bone marrow-derived Langerhans cells and mature eosinophils.

Eosinophilic granuloma is the most common and benign form of this group of disorders and mainly affects children and teenagers. Orbital involvement is common and includes rapid onset proptosis and supero-temporal, osteolytic lesions. Local involvement is treated with surgical excision and intralesional steroids (or radiotherapy) and chemotherapy indicated in systemic involvement. Life prognosis is good.

### Cystic lesions

#### Dermoid and epidermoid cysts

Dermoid and epidermoid cysts are developmental choristomas and are both lined with keratinizing epithelium. Dermoid cysts also contain hair follicles and sebaceous glands. They may be superficial or deep.

- **Superficial lesions:** typically present in early infancy with a slow-growing, painless mass superiorly.
- **Deep lesions:** usually present later with gradual proptosis and globe restriction. They are associated with orbital bony sutures and may extend into adjacent temporal fossa, frontal sinuses, or cranium.

If the entire extent of cyst is not palpable then CT may be helpful to look for intracranial extension, especially for medial dermoids.

Treatment is by complete excision. Cysts can rupture after trauma or during surgery and may lead to an acute inflammatory response.

#### Dacryops

This is a ductal cyst of the palpebral portion of the lacrimal gland and contains clear fluid. The cyst is often visible through the conjunctiva and treatment is by aspiration, de-roofing, or marsupialization.

#### Sinus mucoceles

These occur following obstruction to paranasal sinus drainage. Causes include congenital, trauma, sinusitis, and tumour. Most arise from the frontal or ethmoidal sinus and present with headache and gradual non-axial proptosis, and an upper-lid swelling may be palpable.

CT shows soft-tissue mass with thinning of bony wall of the sinus.

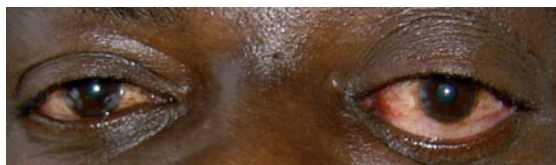Treatment involves surgical drainage with re-establishing sinus drainage or obliteration of the sinus cavity.

#### Encephalocele

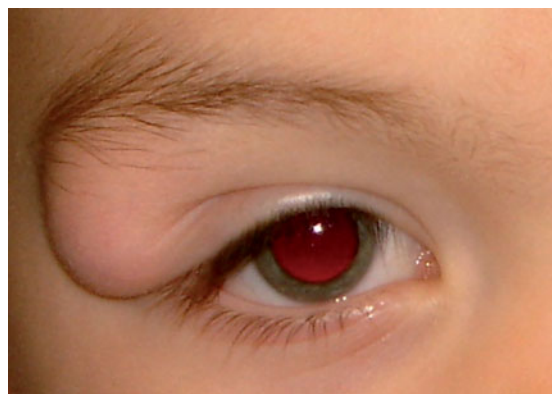These are congenital defects in the skull allowing herniation of intracranial contents into the orbit. Anterior orbital encephaloceles are due to fronto-ethmoidal bony defects and may cause displacement of



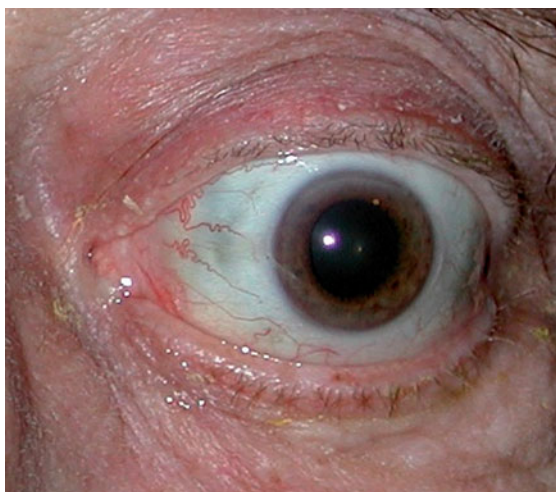the globe forwards and temporally. They are associated with other craniofacial abnormalities (e.g. hypertelorism) and ocular abnormalities (e.g. colobomas). Posterior orbital encephaloceles displace the globe forwards and downwards. These are associated with neurofibromatosis-1. Both types may exhibit pulsatile proptosis, without a bruit.



**Fig. 10.16** Lacrimal gland swelling and proptosis caused by pleomorphic adenoma.



**Fig. 10.18** Superficial dermoid.



**Fig. 10.17** Proptosis caused by orbital metastasis.

## 10.8 Thyroid eye disease

Thyroid eye disease—also known as Graves' eye disease, dysthyroid eye disease, or thyroid ophthalmopathy—is an autoimmune disorder which is commonly linked to dysthyroidism. Twenty-five to fifty per cent of patients with thyroid eye disease have Graves' disease and the majority of patients have a concurrent or recent (within 2 years) history of thyroid abnormalities, before onset of orbital disease. However, 10–20% of patients with thyroid eye disease have no evidence of systemic thyroid disease.

Thyroid eye disease usually occurs between the ages of 25 and 50 and women are much more commonly affected than men (4:1), but men presenting over age 50 tend to develop a more severe compressive disease. It is the most common cause of unilateral or bilateral proptosis in adults and the diagnosis is made on clinical grounds. Smoking and poor thyroid control worsens disease.

### Pathogenesis

Thyroid eye disease is thought to be related to T-cells reacting against thyroid follicular cells, which share antigenic epitopes in the orbit. It is unclear whether this is a humoral response or T-cell mediated and the primary antigen has not yet been determined. Histology of extraocular muscles shows oedema, pleomorphic cellular infiltration, and necrosis. Also, orbital fat, connective tissue, and lacrimal glands become infiltrated with inflammatory cells, glycosaminoglycan deposition, and oedema secondary to an increased osmotic load. The muscles or orbital fat swell, causing proptosis and potentially compress the optic nerve. Later in the disease the muscle fibres fibrose, leading to restriction of extraocular muscles. The most important preventable causes of visual loss in this condition are corneal exposure and optic nerve compression.

### Clinical evaluation

- Thyroid eye disease typically has an inflammatory (active/'wet') and then a quiescent (inactive/'burnt-out') phase.
- During the inflammatory phase the orbits become congested, swollen, and painful.
- Main complaints are dry-eye symptoms, photophobia, and retrobulbar pain. Patients may notice periorbital oedema, lacrimal gland swelling, and fat prolapse.
- Other symptoms and signs include:
  - conjunctival chemosis.
  - proptosis.
  - eyelid retraction and lid lag.
  - superior limbal keratopathy.
  - corneal exposure.
  - diplopia.
  - compressive optic neuropathy.
- The disease may be very asymmetrical.

### Differential diagnosis

- Myositis.
- Idiopathic inflammatory orbital disease.
- Orbital mass (e.g. cavernous haemangioma).
- Low-flow carotid-cavernous fistula.
- Myasthenia gravis.
- Cranial nerve palsies.
- Chronic progressive external ophthalmoplegia.

### Investigations

- If clinical features are not typical of thyroid eye disease, diagnosis is supported by CT of the orbits showing enlargement of extraocular muscles.
- Usually the inferior and medial recti are the primary muscles involved, followed by the superior rectus.

- Thyroid function may be high, low, or euthyroid.
- Thyroid antibodies are commonly elevated.

### Treatment

#### Conservative

- Cessation of smoking.
- Lubrication with artificial tears is almost always required during the day and ointment at night due to lagophthalmos.

#### Medical

- Treat any thyroid dysfunction.
- NSAIDs can be useful in mild disease to control symptoms of periocular discomfort.
- High-dose systemic steroids (80 mg prednisolone for 3 days then taper or intravenous pulsed methylprednisolone) with or without other immunomodulators (cyclosporine, methotrexate) are indicated if:
  1. there are signs of optic nerve compromise (if there is no significant response in days, then urgent surgical decompression should be considered),
  2. there are significant soft-tissue signs (proptosis, periorbital swelling, chemosis) or motility problems.

#### Radiotherapy

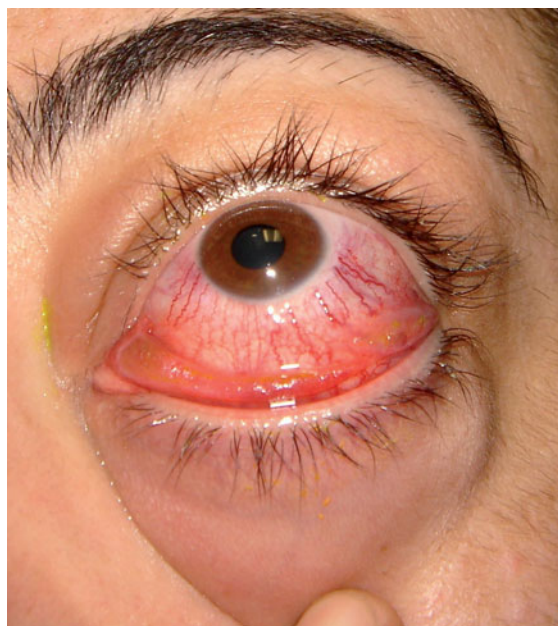- Radiotherapy may be a beneficial adjunctive therapy in the early stages of the disease. Radiotherapy starts to take effect after 4 weeks.

#### Surgery

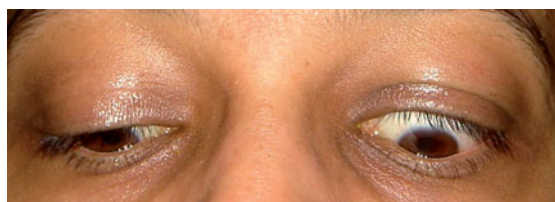- Surgical decompression is indicated if optic nerve compression is unresponsive to high-dose steroid. Also if there is severe corneal exposure secondary to proptosis.
- Aesthetic rehabilitative surgery may be required when the disease is quiescent. Usually wait for at least 6 months of stability of thyroid eye disease.
- Decompression is the most effective treatment for proptosis and is done first. Usually the lateral wall is removed with or without the medial and inferior walls. Medial wall removal is the most effective for optic neuropathy.
- After decompression, strabismus surgery may be needed, which typically involves rectus recession.
- The patient may later require lid surgery to correct upper or lower lid retraction and fat prolapse.

### Prognosis

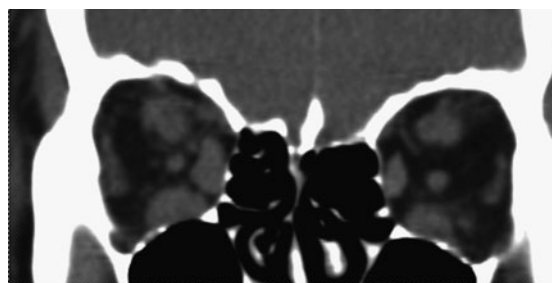
- Episodes of active disease are typically from 6 to 18 months. If untreated, this results in progressive disease.
- Recurrence is uncommon and may be associated with recent unstable systemic thyroid activity.



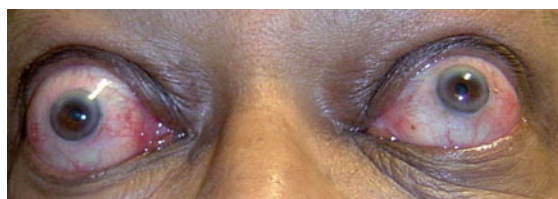**Fig. 10.19** Thyroid eye disease with chronic conjunctival chemosis and lid oedema.



**Fig. 10.21** Lid lag on downgaze.



**Fig. 10.22** CT showing extraocular muscle enlargement in thyroid eye disease.



**Fig. 10.20** Active thyroid eye disease with proptosis, lid retraction, and extreme scleral shown.

## 10.9 Orbital fractures and trauma

Fractures to orbital bones most commonly occur following assault, falls, road traffic accidents, and sports injuries. Depending on the point of traumatic impact, a variety of orbital fractures can occur. These can be broadly divided into three types: blow-out, orbito-zygomatic, and naso-orbito-ethmoid fractures. Thirty per cent of orbital fracture cases have intraocular complications; therefore, a complete ocular examination is mandatory in all cases of orbital trauma. CT is the investigation of choice in orbital fractures to aid diagnosis and assist surgical planning.

### Blow-out fractures

These are fractures of the orbital walls and may or may not be associated with fracture of the stronger, orbital rim. Blow-out fractures usually affect the orbital floor and medial wall and there are two theories accounting for these types of fracture. One theory is that compression of the orbital rim results in direct buckling of the orbital floor; and another is that increased orbital pressure causes orbital bones to break at their weakest points.

#### Clinical evaluation

- The patient is typically a young male and has been punched or hit directly in the eye.
- Usually presents with pain, swelling of the lids (which may make ocular examination difficult), diplopia, and occasionally crepitus (due to air flow back from the sinus, with nose blowing).
- Diplopia can be in any position of gaze but more commonly upgaze or downgaze.
- Lower-lid hypoaesthesia due to infraorbital nerve damage associated with floor fractures.
- Stepping of the orbital rim if fractured and flattening of the malar with tripod fractures.

#### Investigations

- Measurement of enophthalmos/proptosis and complete ocular examination for other injuries.
- Orthoptic assessment with Hess chart documentation at a later date (usually 2 days later) once the eye can be opened.
- CT of orbits if limitation of eye movement and suspected muscle entrapment (especially under 18 years) and foreign body.
- Forced duction testing (performed if restriction exists beyond 1 week) reveals resistance when moving the globe away from the affected muscle if entrapment has occurred.

#### Treatment

- Oral antibiotics, for example cephalexin 250 mg QDS for 10 days.
- Avoid nose blowing for 2 weeks.
- Ice packs for 48 hours.
- Surgical repair (usually within 2 weeks) is considered in patients who have persistent diplopia in primary position or upgaze, large fractures, or significant enophthalmos.
- Also early repair is recommended if the patient is suffering from nausea, vomiting, and oculocardiac reflex; that is, bradycardia dependent on ocular movements.
- Fractures involving the rim and orbital walls may need joint care with the maxillofacial team.

#### Complications of blow-out fractures

- Orbital cellulitis.
- Enophthalmos.
- Diplopia.

#### *“Trapdoor” or “white-eye” blow-out fractures in children*

This category of fracture usually only occurs in children and young adults, due to the more elastic nature of their orbital bones. The fracture cracks open and as the flexible floor returns to its normal position, a ‘trapdoor’ effect occurs, trapping orbital contents in the fractured area.

Aside from a marked restriction in upgaze, persistent nausea, vomiting, and excessive pain are indicative of this type of fracture. Radiology may not always confirm muscle entrapment and restriction in upgaze is sometimes the only sign. More urgent surgical repair (within a few days) is usually required to prevent long-term extraocular muscle damage.

### Orbito-zygomatic fractures

The zygoma has a prominent position in the facial skeleton and blows to the side of the face makes it prone to fracture. Moderate trauma usually results in minimally or non-displaced fractures, whereas more severe force tends to result in displaced fractures which can involve the orbital rim and floor.

Clinical features include diplopia, trismus (pain on mastication due to masseter spasm or bony impingement of the coronoid process), pain on palpation, crepitus, parasthesia, and step deformities.

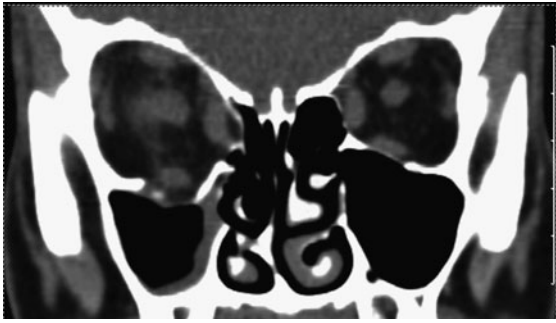
Surgical management of these fractures depends on the amount of zygoma displacement. Non-displaced fractures can be observed and patients should be advised to avoid nose blowing. Open reduction techniques through infraciliary or transconjunctival approaches are more favoured for displaced and comminuted fractures. Extraocular muscle entrapment and rarely retrobulbar haemorrhage can occur following fracture repair.

### Naso-orbito-ethmoid fractures

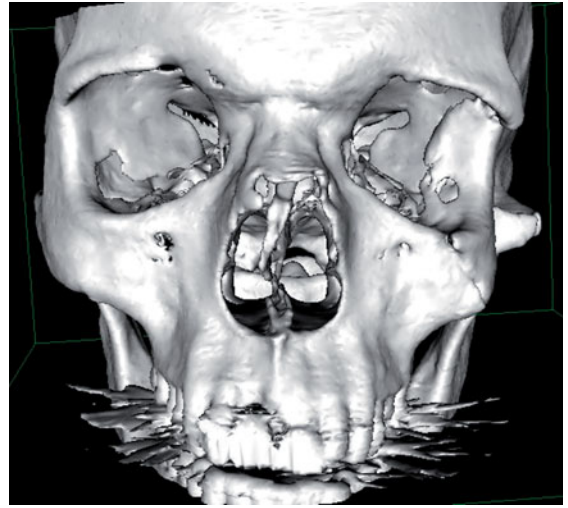
The naso-orbito-ethmoid complex is the meeting point of the frontal and ethmoidal sinuses, anterior cranial fossa, and frontal, nasal, and orbital bones. Trauma involving this region can therefore result in complex fractures, making repair difficult. Fractures can be classified according to whether they are comminuted and whether medical canthal tendon disruption has occurred.

Clinical features of these fractures include nasal/forehead swellings; eye, forehead, or nose pain; forehead parasthesia; diplopia; tel-ecanthus; and CSF rhinorrhoea.

Prompt surgical repair by maxillofacial surgeons, usually through combined coronal, oral, and transconjunctival approaches, is required for optimal outcome.



**Fig. 10.23** CT showing right inferior blow-out fracture.



**Fig. 10.24** Three-dimensional CT reconstruction showing left zygomatic fracture.



## 10.10 Orbital surgery

### Surgical approaches to the orbit

Orbital surgery is performed for the diagnosis and treatment of orbital disease, restoration of anatomy following trauma, and cosmetic improvement of congenital or acquired deformities.

Prior to any surgery, a full preoperative assessment should include thorough history taking and orbital, facial, and systemic examination. Photographic assessment and documentation is useful. Imaging with CT (including three-dimensional reconstruction) or MRI can give important information regarding the specific location of lesions and their relationship to adjacent structures.

The specific approach to the orbit depends on the presumed diagnosis, location of pathology, involvement of adjacent structures, and need for adequate exposure allowing wide surgical margin clearance. Orbital approaches include the following.

#### Anterior orbitotomy

##### Superior approach

A superior approach is most commonly used for lacrimal gland biopsy and other lesions located in the superio-anterior orbit. The upper lid skin crease is incised and the septum is then identified and incised, with careful avoidance of levator and superior oblique muscle. This approach can also be used for exposure of the orbital rim laterally, with subperiosteal dissection allowing access to the extraconal and intraconal spaces, as well as the extraocular muscles.

##### Inferior approach

An inferior approach provides good access to the orbital floor and extraconal and intraconal spaces. Usually a transconjunctival route is used with a lateral canthotomy (swinging lid approach). The inferior orbital rim may be exposed to dissect under the periosteum for repair of orbital floor fractures. Transcutaneous incision via subciliary or lid crease is also used.

##### Medial approach

A medial approach provides excellent access to the medial wall (useful for orbital decompression in thyroid eye disease) and to the medial apex. Transconjunctival, transcaruncular, or transcutaneous (modified DCR incision) routes can be used. Requires careful dissection to avoid the medial canthal tendon, lacrimal sac and canaliculi, superior oblique tendon, and medial rectus.

##### Lateral orbitotomy

This approach is used for deeper orbital lesions (i.e. behind globe equator) or lesions within the muscle cone that cannot be approached by anterior or medial routes. Also indicated in lacrimal gland fossa lesions, when lesions need to be removed intact (e.g. pleomorphic adenoma).

The lateral orbital rim is exposed via a lateral canthotomy and the periosteum is retracted back. The lateral wall is removed with an oscillating saw and the orbital rim may also be removed to increase the access, or left as a bony strut.

### Orbital decompression

This is mainly performed in cases of thyroid eye disease that develop optic nerve compression or have severe exophthalmos. The aim is removal of all or a combination of the lateral and medial wall, and orbital floor, allowing extra space within the orbit.

#### Technique

Approach via a swinging lid (i.e. canthotomy and cantholysis), upper lid skin crease or transconjunctival inferior forniceal incision. Removal of lateral wall allows prolapse of orbital tissue into temporal fossa; floor removal allows expansion into the maxillary sinus and medial wall removal allows prolapse into the ethmoidal sinus.

Medial wall removal can also be carried out endonasally by ENT surgeons.

#### Complications

- Visual loss through optic nerve injury.
- Postoperative orbital haematoma (may require immediate decompression).
- CSF leak.
- Diplopia.
- Lid malpositions.

### Evisceration, enucleation, and exenteration

These are procedures which involve removal of a patient's eye. Preoperative counselling is of paramount importance in these difficult situations and extreme thoroughness should be employed to avoid operating on the wrong eye.

#### Evisceration

This involves surgical removal of the entire contents of the globe, leaving behind a scleral shell with extraocular muscles attached.

#### Indications

- Blind, painful eye.
- Phthisis bulbi.
- Endophthalmitis.
- Cosmetic deformity.

#### Technique

Removal of the cornea and scraping out the intraocular contents with an evisceration spoon is the simplest technique. A spherical implant can be fitted in the scleral shell. Pressure dressing should be applied for 2–5 days and fitting of an artificial eye can be done after 4 weeks.

#### Advantages

- Minimal soft-tissue disruption.
- Better prosthesis motility and cosmetic appearance.

#### Complications

- Higher theoretical risk of sympathetic ophthalmia due to possible incomplete removal of choroidal antigens and evisceration is contraindicated in cases of intraocular tumours.
- Implant extrusion.
- Postoperative pain.

#### Enucleation

This involves surgical removal of the entire globe, including sclera.

#### Indications

Indications for enucleation are as for evisceration but also include intraocular tumours and severe trauma with risk of sympathetic ophthalmia.

#### Technique

Technique involves disinsertion of the rectus muscles and cutting of the optic nerve with scissors or a Foster snare. Ball implants can be fitted within or behind Tenon's capsule, in the muscle cone, which is reattached to the implant. Acrylic implants are commonly used, but other materials include hydroxyapatite or Medpor. Hydroxyapatite implants have the disadvantage of being incorporated into donor tissue, making them difficult to remove or replace. However, they have better motility potential if pegged. Pressure padding is applied for several days and an artificial eye can be applied after 4 weeks.

**Complications**

- Implant extrusion.
- Post-enucleation socket syndrome (volume deficiency resulting in enophthalmos, upper lid ptosis, and a deep upper lid sulcus).
- Lower lid laxity.
- Mucoid discharge.

**Exenteration**

This involves removal of the whole orbit, including globe, orbital contents, with or without eyelids, and is usually performed for malignant tumours.

**Indications**

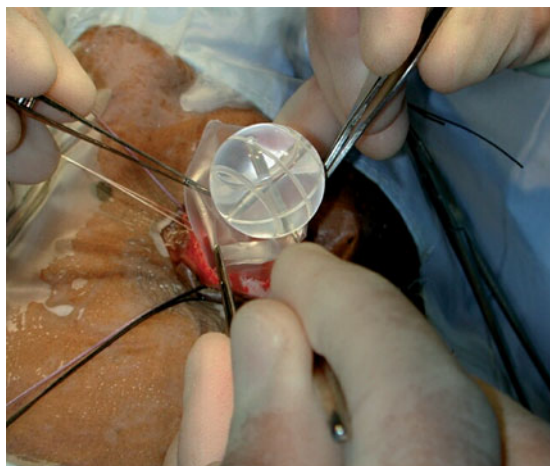
- Cutaneous tumours with orbital invasion.
- Mucormycosis.
- Lacrimal gland malignancies.
- Extensive conjunctival malignancies.
- Other orbital malignancies.

**Technique**

This depends on the tumour locality (i.e. anterior or posterior orbital involvement). Generally the technique involves a skin incision at about the orbital rim to the periosteum and its reflection back from the orbital rim, continuing posteriorly within the orbit to behind the globe. The entire orbital contents including the eyelids, globe, and muscles are removed to the apex, including the periosteum. Healing by granulation tissue occurs within 3–4 months, but results in a shallower socket than with split-skin grafting. With eyelid-sparing exenteration, the eyelid skin is preserved to allow quicker healing of the socket. A cosmetic patch or prosthesis can be used when healing has occurred. Osteointegration is a two-stage procedure where implants are inserted into the bone and then magnetic abutments are fitted later to allow a prosthesis to be magnetically held in place.

**Complications**

- Severe blood loss.
- CSF fluid leak through intraoperative damage to adjacent sinus walls.
- Fistula formation.
- Infection.



**Fig. 10.25** Acrylic spherical ball implant being placed in an eviscerated eye with a polythene conduit.

## 10.11 Case-based discussions ➡

### Case 1 Childhood proptosis

A 7 year-old boy is referred because of increasing right-sided lid swelling and proptosis over the last week. On examination his vision is normal and there is obvious lid swelling, ptosis, and chemosis. His eye movements are limited in upgaze and pupil reactions are normal. Fundi are healthy and he is systemically well.

1. What is the differential diagnosis?
2. How would you manage this patient?

An MRI is performed showing a well-defined anterior orbital mass without bony erosion. A biopsy reveals rhabdomyosarcoma of embryonal histology.

3. What are the treatment options?

4. What is the prognosis

The child is referred to the paediatric oncologists who exclude any extraorbital sites of rhabdomyosarcoma involvement. Surgical excision of the lesion is performed with adjunctive chemotherapy.

#### Discussion

The differential diagnosis of rhabdomyosarcoma is wide and includes most causes of proptosis in childhood. Urgent imaging is required in all cases of rapid onset proptosis, with additional biopsy if the diagnosis remains uncertain. Surgical excision is possible in well-circumscribed lesions, with radiotherapy, enucleation, or exenteration options in more advanced disease. Collaboration with oncology teams is essential and the 5-year survival rate is 95% when the tumour is confined to the orbit.

### Case 2 Non-axial proptosis

A 47 year-old male is referred by his GP because of right-sided proptosis. He has noticed that his eye has looked 'odd' for several months and has no visual disturbance. On examination visual acuity is normal and there is obvious right proptosis with inferonasal globe displacement. No palpable mass is felt.

1. What is the differential diagnosis?
2. What investigations would be helpful?

CT scan shows a well-circumscribed enlargement of the lacrimal gland with expansion of the lacrimal gland fossa.

3. What is the likely diagnosis?
  4. What are the treatment options and particular considerations?
- He undergoes complete surgical excision of the lesion with histology confirming the diagnosis.

#### Discussion

This patient has a lacrimal gland pleomorphic adenoma, typically presenting with painless proptosis and inferonasal globe displacement. Biopsy of the lesion is contraindicated due to risk of seeding and complete surgical excision is required.

### Case 3 Traumatic proptosis

A 37 year-old male is an inpatient on an orthopaedic ward, recovering from multiple fracture repairs following a motor vehicle accident 6 weeks ago. He is referred because of increasing swelling and redness in his right eye.

On examination his vision is 6/18 right and 6/6 left. There is gross chemosis, proptosis, and dilated episcleral vessels in the right eye. He has diplopia on right lateral gaze, with limited movement in this direction.

1. What is the differential diagnosis?
  2. What other features would you look for on examination?
- Colour vision is reduced in the right eye, with mild disc swelling but no RAPD. An audible bruit is present and IOP is normal.

3. What investigations would help?

4. What treatment is indicated?

CT scan shows enlargement of extraocular muscles and dilation of the right superior ophthalmic vein. Later that day he undergoes angiography with embolization of the vascular lesion. His bruit resolves immediately and over the next few days his chemosis and episcleral vessel engorgement reduces and vision improves.

#### Discussion

This man has a high-flow carotid-cavernous fistula following trauma. Gross chemosis, proptosis, and dilated episcleral vessels are common, with an audible bruit a classic feature. Optic nerve function and IOP measurement are important. Angiography is the definitive test with closure of the fistula essential if orbital signs are progressing or optic nerve function is becoming compromised.

### Case 4 Orbital pain

A 32 year-old female is referred because of increasing pain and swelling around her left eye over the last month, and has noticed double vision in the last few days. Systemically she feels well, although she mentions that she possibly had a fever last week.

On examination vision is 6/6 right and 6/9 left, with no RAPD. There is moderate left proptosis and ptosis, with reduced left-eye movements and diplopia in lateral and downgaze. No orbital masses are palpable and she is afebrile.

1. What is the differential diagnosis?
2. What other specific features in the history would you enquire about and check on examination?

3. What investigations would be useful?

She has had no recent weight loss, night sweats, or symptoms of thyroid dysfunction. Her pulse is normal and she has no goitre. Biochemically she is euthyroid, although her white cell count and ESR are mildly raised. ACE, ANCA, glucose, urine, and CXR are normal. CT scan shows diffuse thickening of extraocular muscles and sclera, and orbital fat prominence.

4. What is the likely diagnosis?
5. How would you treat this patient?

A presumptive diagnosis of idiopathic orbital inflammatory disease is made and she is commenced on 80mg oral prednisolone. She is initially reviewed daily and over the next few weeks, her steroid dose is tapered as her symptoms and signs resolve.

6. What are the concerns about using steroids in this case?
7. When is orbital biopsy indicated in such cases?

#### Discussion

A diagnosis of idiopathic orbital inflammatory disease is made in view of the lack of clinical features and investigations indicating another cause. This disease typically shows a rapid response to steroid treatment, but this is not diagnostic as other conditions such as thyroid eye disease and malignant orbital tumours can show similar improvement. Biopsy is indicated in cases unresponsive to steroids, when there is a history of cancer, or the presentation is atypical.

### Case 5 Diplopia following trauma

An 8 year-old boy is accidentally elbowed in the right eye while playing football. He presents to eye casualty with pain and says he is seeing double.

On examination, his eye is white with minimal bruising. There is marked limitation and diplopia in right upgaze, with this movement exacerbating his pain and making him feel nauseous.

1. What are your concerns?
2. How would you manage this child?

An urgent CT scan is performed which shows entrapment of the inferior rectus muscle within the orbital floor. He undergoes immediate repair of the floor defect with release of the extraocular muscle.

### **Discussion**

This child has a 'trapdoor' orbital floor blow-out fracture. It can present with a 'white eye', although restricted upgaze exacerbating pain and nausea are common. Urgent release of the trapped muscle is important in preventing irreversible muscle impairment.

*This page intentionally left blank*



## Chapter 11

# Professional skills and behaviour

Matthew Gardiner and Venki Sundaram

---

### Professional skills

- 11.1 Good medical practice 424
- 11.2 Communication 425
- 11.3 Judgement and decision-making 426
- 11.4 Clinical governance and patient safety 427
- 11.5 Audit, appraisal, and revalidation 428
- 11.6 Consent and confidentiality in the UK 429
- 11.7 Education, training, and research 430
- 11.8 Child protection in the UK 431
- 11.9 NHS structure and economics 432
- 11.10 The Ophthalmic Trainees' Group  
(by Jonathan Ross) 433

---

### Clinical skills

- Breaking bad news 425
- Dealing with complaints 425

## 11.1 Good medical practice

*Good Medical Practice* (2006), published by the General Medical Council (GMC), outlines the standards that all doctors should strive to uphold in their clinical practice. It is based on seven key areas, which are summarized below.

### 1. Good clinical care

- Good medical practice should deliver high-quality patient care according to priority and in a timely, safe, and competent manner.
- Emergency care should be provided promptly in an appropriate setting. Patient transfer to another unit should be considered and unfamiliar operations only performed if there is no clinical alternative.
- Working with children should be confined to those with appropriate training and ongoing experience.
- Organ and tissue transplantation should be carried out within the law and on the basis of clinical priority. Fully informed consent must be acquired from the donor.
- Be aware of your limitations and use the expertise of others.
- Medical records should be accurate and contemporaneous.

### 2. Maintaining good medical practice

- Doctors must maintain knowledge and expertise in their chosen field. This can be achieved through personal development, attending conferences, courses, and keeping up to date with the relevant literature.
- Clinical audit and appraisal are mechanisms for assessing and improving performance.
- Use of innovations in practice is encouraged but must have the relevant regulatory and ethical approval. Patient safety is paramount. Adverse events should be identified and reported.

### 3. Teaching, training, appraising, and assessing

- Learning continues throughout a doctor's career. During this time they will also be expected to create an environment in which students and trainees can also learn and be trained.
- Consultants should take responsibility for their trainees, including teaching, supervision, and assessment.

### 4. Relationships with patients

- The doctor–patient relationship is based on trust. Good communication, informed consent, and awareness of particular cultural needs of patients are part of developing and maintaining this relationship.
- Consent should be sought for all procedures and follow the Department of Health guidelines (Topic 1.6).
- Communication (Topic 1.2) should involve active listening with respect for patients and their supporters' views. Enough time should be made available to fully inform the patient of their diagnosis and treatment. Doctors must also recognize the varying needs of patients for information and explanation.

### 5. Working with colleagues

- Effective team working improves patient care and is built on good communication and leadership.
- Doctors should actively participate in delivering multi-disciplinary care where appropriate.

### 6. Probity

- Probity is 'complete and confirmed integrity; uprightness'. It can be achieved by following the tenants of good medical practice and maintaining an honest and objective view of oneself and colleagues.
- Probity should be carried through into any private practice and research.

### 7. Health

- Doctors have a duty of care to their patients that not only covers their clinical practice but their own health and well being.
- Doctors must be fit to practice and not be compromised by ill health, fatigue, drugs, or alcohol.
- Exposure-prone procedures put doctors at risk of acquiring or transmitting serious communicable diseases.
- In the event of a needle-stick injury doctors must follow the relevant local guidelines. The relevant authority must be informed if they suspect they may be carrying a communicable disease.

### Duties of a doctor registered with the GMC

Patients must be able to trust doctors with their lives and health. To justify that trust, you must show respect for human life and you must do the following.

1. Make the care of your patient your first concern.
2. Protect and promote the health of patients and the public.
3. Provide a good standard of practice and care.
  - Keep your professional knowledge and skills up to date.
  - Recognize and work within the limits of your competence.
  - Work with colleagues in the ways that best serve patients' interests.
4. Treat patients as individuals and respect their dignity.
  - Treat patients politely and considerately.
  - Respect patients' right to confidentiality.
5. Work in partnership with patients.
  - Listen to patients and respond to their concerns and preferences.
  - Give patients the information they want or need in a way they can understand.
  - Respect patients' right to reach decisions with you about their treatment and care.
  - Support patients in caring for themselves to improve and maintain their health.
6. Be honest and open and act with integrity.
  - Act without delay if you have good reason to believe that you or a colleague may be putting patients at risk.
  - Never discriminate unfairly against patients or colleagues.
  - Never abuse your patients' trust in you or the public's trust in the profession.

### Further reading

General Medical Council. 2006. *Good Medical Practice*. General Medical Council, London.

General Medical Council, [www.gmc-uk.org/guidance/index.asp](http://www.gmc-uk.org/guidance/index.asp)

## 11.2 Communication

Good professional–patient and healthcare team communication results in increased patient satisfaction and improved delivery of healthcare. In contrast, poor communication is frequently cited as the reason for complaints and litigation.

### Importance of effective communication

In many situations healthcare provision has a safety critical element to it, much like the airline industry and other high-reliability organizations. This is especially true of surgery where safety critical communications are commonplace and so poor communication is dangerous.

#### ABC of clear communication

- **A**ccurate.
- **B**rief (although ensure sufficient information is conveyed).
- **C**lear.

#### Safety critical communications

- Speak up if you feel something is going wrong. Many errors are a result of communication never happening.
- Address the correct person.
- Time the communication so that you have the full attention of the receiver and do not interrupt a critical activity (unless it is an absolute emergency).
- Use correct grammar.
- Read back the message or paraphrase it to confirm you received the correct message.
- Summarize the message to confirm your understanding and double check the required course of action.

### Doctor–patient relationship

The doctor–patient relationship is different to normal social interactions. Within a short space of time doctors have to gain a patient's trust and develop an effective rapport.

- *Good interpersonal relationship* is the foundation for what follows. It should be patient-centred, open, and involve active listening.
- *Exchange of information* is a two-way activity. The doctor needs to gather diagnostic information and the patient needs to be kept informed to enable joint decision-making.
- *Decision-making* has traditionally been paternalistic. The doctor led and the patient followed. This has moved towards a shared process in which active discussion and patient participation in decision-making is encouraged.

### Doctor–patient communication

Doctor–patient communication can be complex. Values that create a solid foundation from which to base any consultation include understanding, truth, respect, empathy, and confidentiality.

Doctors should be aware of and try and overcome any barriers to effective communications. These difficulties may include sensory or speech impairment, language barriers, and the cultural needs of patients from different ethnic backgrounds.

### Documentation and record-keeping

Accurate documentation and record-keeping is important for both clinical and legal reasons. Records provide a means of communication and a description of events.

- Patient records should be factual, consistent, and accurate.
- Write during or as soon as possible after the event with dates and timings.

- Write clearly, legibly, and preferably with a black ink pen, which will be readable on a photocopy and will not degrade with time.
- Avoid personal slurs and value judgements.
- Sign and clearly identify the author.

### Dealing with complaints

A formal complaint can be oral or in writing and is an expression of dissatisfaction from a patient or third party, requiring a formal response. Complaints differ from comments or moans (e.g. 'I was hoping to see the Consultant'), which can be resolved there and then with a quick explanation.

#### Managing patient dissatisfaction

Not all episodes of patient dissatisfaction result in a formal complaint. Techniques to help avoid formal complaints include the following.

1. Keep calm and avoid making comments that escalate the situation.
2. Acknowledge any feelings of frustration and anger with empathic statements.
3. Repeat a summary of what comments have been made to show that you are carefully listening to any grievances.
4. Apologise for anything that has not gone to plan and recognize that saying 'sorry' is not an admission of liability.
5. Involve the Patient Advocacy and Liaison Service (PALS) who can help to resolve problems as quickly as possible.

#### Formal complaints procedure

Once a complaint has been made, a formal complaints procedure involves the following.

##### Stage 1 Local resolution

The Trust will acknowledge a complaint within two working days of receipt. An investigation into the circumstances giving rise to the complaint is carried out. A reply will be sent to the complainant within 25 days.

##### Stage 2 Independent review by the Healthcare Commission

Complainants may ask the Healthcare Commission to review a complaint that has not been satisfactorily resolved. Requests should be made within 6 months of the Trust's final response.

##### Stage 3 Parliamentary and Health Service Ombudsman

Complainants who remain unhappy with the Healthcare Commission's review have the right to approach the Ombudsman.

#### Breaking bad news

Breaking bad news is difficult for everyone concerned. However, doing it badly makes a bad situation worse. Below are some factors to consider when breaking bad news.

- **Environment:** quiet, private area with no interruptions. Include relatives and supporters if appropriate. Involve nursing staff and choose an area that is free for the patient to stay in for longer.
- **Establish the patient's current understanding of the situation and their desire for further information.**
- **Share the bad news and start to inform the patient of the consequences from their starting point.**
- **Take time, speak clearly, and avoid jargon.**
- **Recognize the patient's feelings and respond to any questions or concerns.**
- **Plan the future care and follow-up.**

## 11.3 Judgement and decision-making

Good judgement and decision-making are cornerstones of medical practice and make significant contributions to clinical performance. Most doctors have little formal training in judgement and decision-making but acquire these skills during their career.

### Judgement

Judgement is defined as 'the ability to judge, make a decision, or form an opinion objectively, authoritatively, and wisely, especially in matters affecting action'. Attributes of good medical judgement include:

- accurate risk assessment,
- managing probabilities,
- managing uncertainty,
- integrating the above with patient preferences,
- reaching good decisions.

### Decision-making

*'Good decision-making comes from experience, but often experience comes from bad decision-making'*

Doctors, like other professionals in high-reliability organizations, are called upon to make potentially important decisions with uncertain outcomes under pressure. The pressured environment is a result of limited information, lack of time, and distractions.

#### Novice versus expert

There is a transition seen from novice to expert decision-making. Novices have a tendency towards in-depth analysis. They will consider and attempt to weigh the possible pros and cons of a decision, all of which takes time.

Experienced decision-makers are more intuitive. They appear to have a more 'subconscious' approach with the individual steps in the thought process skipped, thus shortening the time to a final decision.

#### Top-down versus bottom-up

Clinical decision-making is driven by top-down processing, such as pattern recognition and goal-directed strategies, or bottom-up processing, which tends to be data-driven. Cognitive factors (see Heuristics and biases, below) influence these processes to shape the final decision.

#### Decision-making strategies

Below are some of the decision-making strategies that apply to clinical practice (Croskerry 2002).

##### Pattern recognition

A combination of patient-derived information is combined with clinical experience of similar circumstances to reach a decision. This is a good example of both bottom-up and top-down information being combined.

As with other strategies pattern recognition is open to biases including the clinician's previous experience and misleading clinical signs.

##### Worst-case scenarios

Ruling out worst-case scenarios is a strategy to exclude critical diagnoses that must not be missed. Although it is a 'safe' strategy it is much more resource-intensive and may bias towards overdiagnosis.

Clinical guidelines attempt to streamline this process to make the most efficient use of resources.

##### Goal-directed

Goal-directed diagnosis involves establishing a differential list early on during the clinical assessment and then attempting to eliminate

or refine the order in response to further assessment and investigation.

#### Exhaustive review

Novice decision-makers tend to take an exhaustive ('no stone unturned') approach to collecting clinical information before making a decision. More experienced clinicians are able to elicit focused data that is directly relevant to the decision in hand.

#### Heuristics and biases

Heuristics are a set of rules learned 'on the job'. They provide short cuts in decision-making that are usually successful but can go wrong. When this occurs they are referred to as biases. Over 20 heuristics have been described; some of the more common ones are described below.

- **Availability** is the tendency to favour more common diagnoses or those that 'come to mind'. The opposite is the 'zebra retreat'. A rare diagnosis (the zebra) may be a differential but the clinician lacks courage of conviction to pursue it, leading to a delay in diagnosis.
- **Confirmation** bias is the tendency to accept information that confirms a hypothesis but ignore that which refutes it. This is done to avoid going 'back to square one'.
- **Hindsight** bias ('retrospectroscope') distorts the perception of the previous decision-making and may under- or overestimate its success.
- **Overconfidence** places too much belief in one's own opinions with decisions made on insufficient information and instead relying on 'inherent ability' and hunch.
- **Omission** bias (watchful waiting) is the general preference for inaction rather than active treatment. This fits with the maxim 'do no harm' and may avoid blame, which is often assigned to the last person to touch the patient.
- **Representativeness**: 'if it looks like a duck, walks like a duck, and quacks like a duck, it's a duck' – or is it? In this heuristic clinicians rely too much on identifying clinical features that represent a condition. It mainly affects cases which present with atypical features that do not fit the doctor's mental template of a condition.

#### Improving decision-making

Attempts have been made to improve and support clinical decision-making. Strategies include:

- decision-making tools such as PROACT (Hammond *et al.* 1999),
- computerized decision support,
- de-biasing: this is training that aims to overcome the cognitive biases discussed above.

### Further reading

Croskerry P. 2002. Achieving quality in clinical decision-making: cognitive strategies and detection of bias. *Acad. Emerg. Med.* **9**: 1184–1204.

Hammond JS, Keeney RL, Raiffa H. 1999. The hidden traps in decision-making. *Clin. Lab. Manage. Rev.* **13**(1): 39–47.

## 11.4 Clinical governance and patient safety

### Clinical governance

*'A framework through which NHS organizations are accountable for improving the quality of their services and safeguarding high standards of care by creating an environment in which excellence in clinical care will flourish.'*

Sally and Donaldson 1998

The fundamental aim of clinical governance is to continually improve the quality of healthcare by generating effective change, and therefore ensuring that patients receive the highest possible quality of care.

The seven key aspects, or pillars, of clinical governance are as follows.

1. **Clinical effectiveness:** making use of evidence-based medicine and guidelines to ensure that patients are receiving appropriate levels of care.
2. **Clinical audit:** review of clinical practice against agreed standards.
3. **Education and training:** supporting continued professional development so that staff are up to date with developments in their field.
4. **Patient and public involvement:** respecting patients' views on how treatment and services are provided.
5. **Risk management:** ensures systems are in place to monitor and minimize risks occurring to patients and staff. Adverse events are encouraged to be reported, with the emphasis on learning from these situations.
6. **Staff management:** includes recruitment, management, and development of staff, with promotion of good working conditions.
7. **Using information:** the safe and efficient use of patient information.

For more information visit the Clinical Governance Support Team's website (see Further reading, this section).

### Patient safety

Patient safety encompasses identifying, reporting, analysing, and preventing adverse events in healthcare. It is estimated that 10% of hospital patients in the UK will be subject to an adverse event during their stay. Fifty per cent of these errors are probably avoidable.

Patient safety has only recently been identified as an area in which significant gains can be made in preventing morbidity and mortality of patients. It is estimated that annually almost 100,000 deaths in the USA are the result of medical error.

#### Sources of error

There are often multiple factors involved in medical error; examples include:

- *human factors:* poor training, lack of experience, and fatigue,
- *medical factors:* complex procedures and drug errors,
- *systems failures:* poor communication, cost cutting, lack of safety culture.

#### Improving patient safety

Patient safety is becoming a major priority in the delivery of healthcare. In the UK there are a number of organizations involved including the National Patient Safety Agency and the Medicines and Healthcare products Regulatory Agency. Strategies to improve safety have included the following.

- Learning from other high-reliability organizations such as the airline industry.
- Encouraging incident and near-miss reporting.
- Fostering a safety culture through education and training.
- Technological innovations such as electronic health records and electronic prescribing and dispensing.

- Standard operating procedures and guidelines (encompassing evidence-based medicine).
- Clinical governance.

#### National Patient Safety Agency

The aim of the National Patient Safety Agency (NPSA) is to identify problems relating to patient safety and to implement appropriate solutions. It oversees a number of confidential enquires into particular aspects of clinical care and also runs campaigns to improve safety, such as the Clean Your Hands campaign.

#### Medicines and Healthcare Products Regulatory Agency

The Medicines and Healthcare Products Regulatory Agency (MHRA) is a government body set up to regulate medicines and medical devices and equipment in healthcare. It also collates and investigates incidents related to these products and has the power to prosecute.

#### Further reading

Department of Health. 1998. *A First Class Service: Quality in the New NHS*. Department of Health, London.

HMSO. 2007. *Trust, Assurance and Safety - The Regulation of Health Professionals in the 21st Century*. HMSO, London.

Clinical Governance Support Team, [www.cgsupport.nhs.uk](http://www.cgsupport.nhs.uk)

Medicines and Healthcare Products Regulatory Agency, [www.mhra.gov.uk](http://www.mhra.gov.uk)

National Patient Safety Agency, [www.npsa.nhs.uk](http://www.npsa.nhs.uk)



## 11.5 Audit, appraisal, and revalidation

### Clinical audit

'Clinical audit is a quality improvement process that seeks to improve patient care and outcomes through systematic review of care against explicit criteria and the implementation of change.'

*Principles for Best Practice in Clinical Audit, NICE/CHI (2002)*

#### The audit cycle

Clinical audit is a continuous process often described as a cycle or spiral.

##### 1. Identify the question

The audit question is often in response to a particular problem encountered during clinical practice or where current clinical practice can be compared with accepted guidelines.

##### 2. Select criteria

The outcomes that are going to be measured have to be clearly defined. A criterion can be defined as a 'systematically developed statement that can be used to assess the appropriateness of specific healthcare decisions, services, and outcomes' (Institute of Medicine 1999).

##### 3. Measure performance

Data collection needs to be accurate and as complete as possible. The sample group and data items should be clearly defined. Ethical and confidentiality issues surrounding audit should be considered.

##### 4. Compare performance with standards

The data are compared with the predefined criteria and performance outcomes. This identifies areas for improvement and helps to guide the implementation.

##### 5. Make improvements

Implementation of change is often hard work. There are many potential barriers including staff behaviour, lack of resources and/or expertise, poor communication, and organizational issues. A working environment with a positive attitude towards audit and change coupled with strong leadership help implementation.

##### 6. Sustain improvement

Once the changes have been implemented the cycle starts again. The interventions need to be evaluated and if successful should be sustained. Demonstration of the improvements and the benefits they provide help to reinforce the audit environment and the continuing cycle of improvement.

- team working and 360° appraisal,
- publications and presentations,
- attendance at courses and educational meetings,
- employment history,
- occupational health.

An effective appraisal meeting generally incorporates the following.

1. **Setting the agenda:** establishing aims and key areas of discussion.
2. **Review of past performance:** opportunity to explore strengths and weaknesses of performance.
3. **Identify current learning needs:** the trainee should have identified areas in need of development and modified if necessary through discussion.
4. **Set future learning objectives:** these should be specific, measurable, attainable, realistic, and timed.
5. **Agree a date for the next appraisal.**

### Revalidation

Revalidation is a process to 'quality assure' the medical profession. Revalidation occurs every 5 years and is mandatory for all fully trained doctors. It examines their fitness to practice with reference to *Good Medical Practice* (GMC 2006). Annual appraisal and evidence of continuing professional development will usually be sufficient evidence for revalidation. It does not currently involve any further examinations or practical assessments of clinical competence.

### Further reading

Department of Health. 2006. *Safety First. A Report for Patients, Clinicians and Healthcare Managers*. Department of Health, London.

Institute of Medicine. 1999. *To Err is Human: Building a Safer Health System*. Institute of Medicine, Washington DC.

National Centre for Health and Clinical Excellence. 2002. *Principles for best practice in clinical audit*. National Centre for Health and Clinical Excellence, London.

Modernising Medical Careers, [www.mmc.nhs.uk](http://www.mmc.nhs.uk)

Royal College of Ophthalmologists, <http://curriculum.rcophth.ac.uk/assessments>

### Appraisal

Appraisal aims to provide feedback on doctors' performance, record their continuing professional development, and identify future educational and developmental goals. As appraisal focuses on a trainee's developmental needs, it differs from assessment, which measures progress based on set criteria (e.g. exams). Also, appraisal is usually a confidential process and encourages trainees to feel able to discuss their developmental concerns and future plans.

Appraisal is based around the core headings in *Good Medical Practice* published by the GMC (2006; Topic 1.1) and is tailored to an individual doctor's area of practice and needs of the organization they work for.

All doctors in training must maintain a portfolio of evidence related to these core topics. Evidence may include:

- educational achievements related to the Royal College of Ophthalmologists' curriculum and examinations,
- clinical assessments (e.g. mini-CEX),
- personal development plans,
- evidence of reflective learning,

## 11.6 Consent and confidentiality in the UK

### Consent

Valid consent should always be obtained before treatment or examination of a patient. Consent should be performed by a clinician who is suitably trained and qualified. It is good practice for this to be the clinician providing the treatment but it can be delegated to someone with appropriate experience.

#### Valid consent

Ask the following questions when deciding whether consent is valid.

#### *Does the patient have capacity?*

For a patient to have sufficient capacity they must be able to comprehend and retain information relevant to making the decision.

#### *Is the consent given voluntarily?*

The decision to consent has to be made voluntarily and freely by the patient. Relatives, friends, and healthcare professionals must not unduly influence or coerce the patient into making a decision.

#### *Is the patient sufficiently informed?*

Patients need to be informed of the nature and purpose of the procedure or examination and any other relevant information, such as the possible risks and adverse outcomes. This enables the patient to make a balanced judgement.

The legal standard for deciding what is sufficient information is based on what would be considered appropriate by a responsible body of medical opinion (the Bolam test) used in medical negligence cases. The *Sidaway* case (see Further reading) challenged this and stated that it would be negligent not to provide information about a significant risk even if a responsible body of medical opinion might not think it necessary. Clinicians are therefore guided to include any 'significant risk which would affect the judgement of a reasonable patient'.

### Consent in different patient groups

#### *Competent adults (over 18 years old)*

- Competent adults may refuse treatment. The only exception is when the patient is detained under the Mental Health Act (1983).
- A competent pregnant woman may refuse any treatment even if detrimental to the foetus.

#### *Incompetent adult*

- Incompetent patients must be treated in their best interests, which does not necessarily equate to their best medical interests. Nobody can give or withhold consent on their behalf. The professional judgement should stand up to the Bolam test (reasonable body of medical opinion).
- Patients with fluctuating competence should have their views assessed when competent. If the incapacity is temporary then non-urgent treatments should be delayed until capacity is regained.
- Advanced care directives and living wills are legally binding and should be followed.

#### *Children and young people (under 18 years old)*

- Competent children over 16 years can give consent but can have a decision to refuse treatment overruled if they are at risk of suffering 'grave and irreversible mental or physical harm'. Children under 16 years can technically give consent if competent (Gillick competence). They may have this competence for some procedures but not others. Under Scottish law, young people age 16 or over have the same right to consent or refuse as adults.
- Children under 16 years or 16–17 years old but incompetent generally need a parent or guardian to give consent.

- Refusal of treatment by a competent child under 16 years does not necessarily overrule parental consent to proceed. This is a rare situation.
- Refusal of treatment by the parents of a child which is deemed in the child's best interest may need a second opinion and referral to the courts.

#### *The Mental Health Act (1983)*

There are some circumstances in which patients held under the Mental Health Act can have their mental disorder treated without their consent. It does not apply to any physical disorders they may have, for which the usual rules of consent apply.

### Confidentiality

As a doctor you are entrusted with sensitive information by patients. This disclosure of information by the patient confers a duty of confidence which is a legal obligation and part of the professional code of conduct. Confidential information covers any patient identifiable information such as name, address, date of birth, clinical photographs, and identifiable National Health Service (NHS) codes.

#### *Caldicott Report 1997 and the Data Protection Act 1998*

The Caldicott Report 1997 referred specifically to patient-identifiable information. It made a number of recommendations, including the appointment of a Caldicott Guardian for each NHS organization to oversee the use of confidential information.

The Data Protection Act 1998 lays out a framework for processing identifiable information. This includes holding, obtaining, recording, using, and disclosing information. It covers all forms of media such as paper and images. It is good practice for all those processing confidential information to notify the Information Commissioner.

#### *Using or disclosing confidential information*

Case law has established that information given in confidence cannot be used or disclosed beyond the original understanding of the confider or without further permission (bar exceptional circumstances).

#### *When do I have to ask for consent for use or disclosure?*

Use of confidential information that contributes directly to audit or the patient's care carries implied consent although every effort should be taken to inform the patient of this. Generally any other uses require explicit consent.

#### *When is disclosure allowed without consent?*

Statute law requires or permits the disclosure of confidential information in some circumstances. Disclosure is permitted if it is 'in the public interest' or to protect the public. This most frequently applies to serious crime or to prevent abuse or serious harm.

### Further reading

Department of Health. 2001. *Reference Guide to Consent for Examination or Treatment*. Department of Health, London.

Department of Health. 2003. *Confidentiality NHS Code of Practice*. Department of Health, London.

*Bolam v Friern Hospital Management Committee* 1957

*Gillick v West Norfolk and Wisbech AHA* 1986

*Sidaway v Board of Governors of the Bethlem Royal Hospital* 1985

Information Commissioner's Office, [www.ico.gov.uk](http://www.ico.gov.uk)

## 11.7 Education, training, and research

### Education and training

Medical training is often thought of as an apprenticeship. In the past trainees acquired knowledge and skills on the job with no formal framework. Modern medical education has formalized this structure. Trainees are now required to follow a defined curriculum and record their achievements as they progress through the scheme.

#### Learning opportunities

Learning opportunities are broadly divided into three areas.

1. Learning from practice is probably the most significant and includes almost all clinical situations. Initially trainees will be 'watching' but progress to 'doing' as they become more proficient.
2. Formal situations include teaching sessions, courses, and the increasing use of 'wet-labs'.
3. Self-directed learning.

#### Assessment

Assessment is a process of evaluation ensuring that sufficient knowledge, skills, and experience have been acquired to allow progression to the next phase of training. The standardized methods of assessment used in Specialty Training are Direct observation of procedural skills (DOPS), Case-based discussions (CbD), Clinical evaluation exercises (mini-CEX), and Multisource feedback (MSF).

#### Ophthalmic Specialist Training Curriculum

The Ophthalmic Specialist Training Curriculum (or OSTC) is a comprehensive web-based training system that lays out the knowledge and skills that trainees should acquire at each stage of their training. However, it is not intended to be exhaustive as the opportunity for further learning and reading is unlimited.

An e-portfolio allows trainees to record their training achievements and reflective learning.

#### Postgraduate Medical Education and Training Board

The Postgraduate Medical Education and Training Board is currently an independent regulatory body (although due to merge with the GMC) responsible for postgraduate medical education and training in the UK.

It approves specialist training curricula, such as the Ophthalmic Specialist Training Curriculum, ensures that the quality of the training programmes is maintained, and certifies trainees so that they can be added to the specialist register held by the GMC.

#### Continuing professional development

One of the defining aspects of a profession is the acquisition and maintenance of a body of knowledge. Continuing professional development formalizes this concept and sets the standards for doctors to continue their learning and adapt to change following their formal period of postgraduate education. Continuing professional development should include all areas of Good Medical Practice and contributes to the process of revalidation.

### Research

Medical research makes significant contributions to improvement in human health. The focus is increasingly on 'translational' research in which discoveries at the laboratory bench are converted into effective treatments at the bedside. The UK has a strong track record in biomedical research. However, the career of a clinical academic has often been difficult, with a lack of structure and support. The new career structure aims to address these issues by identifying potential clinical academics early in their careers and enabling them to follow an explicit academic training pathway.

#### Funding and support

There are many sources of funding and support in the UK. Further information can be found on the Modernising Medical Careers web-

site. Other organizations directly involved in fostering UK biomedical research include the UK Clinical Research Collaboration, National Coordinating Centre for Research Capacity Development (or NCCRC) and the Academy of Medical Sciences (for URLs, see Further reading, this section).

Research funding comes from many different sources including the Medical Research Council (government body), charitable organizations (e.g. The Wellcome Trust), and industry.

#### Ten steps in the research process

The general steps involved in developing and performing research are outlined below. See [www.rdfunding.org.uk](http://www.rdfunding.org.uk) for further information.

1. Develop a research question.
2. Review the literature.
3. Design the study and methodology.
4. Write the research proposal.
5. Apply for funding.
6. Obtain ethical and local research and development (R&D) approval.
7. Collect data (see consent and confidentiality).
8. Analyse the data.
9. Determine the impact of the data.
10. Report and disseminate your findings.

#### National Research Ethics Service

It is likely that you will be involved with some form of research or investigation during your career. It is important that this is done ethically and with patients' best interests at heart. The National Research Ethics Service (or NRES) maintains the framework for research ethical review in the UK.

#### Ethical considerations

There are six values commonly applied to medical ethics.

1. Beneficence: always act in the patient's best interest.
2. Non-maleficence: 'first, do no harm' (*primum non nocere*).
3. Autonomy: respect the patient's right to refuse or choose their treatment.
4. Justice: limited healthcare resources should be distributed fairly.
5. Dignity: both patients and doctors have the right to dignity.
6. Truthfulness and honesty: encompasses the concept of informed consent and patient education.

### Further reading

Academy of Medical Sciences, [www.acmedsci.ac.uk](http://www.acmedsci.ac.uk)

Medical Research Council, [www.mrc.ac.uk](http://www.mrc.ac.uk)

Modernising Medical Careers, [www.mmc.nhs.uk](http://www.mmc.nhs.uk)

National Coordinating Centre for Research Capacity Development, [www.nccrcd.nhs.uk](http://www.nccrcd.nhs.uk)

Royal College of Ophthalmologists, [www.rcophth.ac.uk/education/new-curriculum](http://www.rcophth.ac.uk/education/new-curriculum) and <https://portfolio.rcophth.ac.uk>

Postgraduate Medical Education and Training Board, [www.pmetb.org.uk](http://www.pmetb.org.uk)

The Wellcome Trust, [www.wellcome.ac.uk](http://www.wellcome.ac.uk)

UK Clinical Research Collaboration, [www.ukcrc.org](http://www.ukcrc.org)

## 11.8 Child protection in the UK

A number of high-profile child-abuse cases and subsequent inquiries (such as the Victoria Climbié inquiry) have reinforced the importance of having systems in place to detect and manage suspected child abuse. The annual incidence is approximately 3 in 1000 children in the UK, with over 80 deaths a year related to child abuse.

### Types of abuse

There can be overlap, with a child being subjected to more than one type of abuse.

- **Physical** abuse includes hitting, shaking, throwing, and poisoning, causing either physical harm or illness.
- **Sexual** abuse includes inappropriate physical contact, involvement in viewing adult material, or encouraging sexually inappropriate behaviour.
- **Neglect** is a failure of the child's carer to meet the child's physical and/or psychological needs, resulting in poor health and/or development. This may include inadequate shelter, food, clothing, and access to medical care.
- **Emotional** abuse involves the persistent denigration of a child's emotional state through psychological ill treatment. It is always present to a certain degree in the other forms of abuse.

### Risk factors

These can be child- or adult-related. Preterm babies and infants under 1 year old are at greatest risk. Teenage mothers, single-parent families, mental health problems, drug and alcohol misuse, and domestic violence are all factors that increase the risk of an adult committing child abuse.

### Clinical assessment

#### General

- Identify the adult accompanying the child and their relationship to the child.
- Identify who has parental responsibility.
- Check details of GP, school and health visitor, or social worker.
- Check the child protection register.

#### History

- Try to take the history directly from the child without influence from the carers. Children may disclose information suggesting they have been subject to abuse.
- Delayed presentation or failure to seek healthcare following injury, multiple presentations with different injuries.
- Poor explanation for an injury.
- History not consistent with the injuries sustained.

#### Examination

- Poor personal hygiene and dress.
- Physical signs of abuse include slap marks and unusual bruising.
- Injury patterns inconsistent with the history.
- Unusual behavior or interaction with carers and other adults.

### Investigations

In most cases investigations are not routinely indicated other than for the suspected underlying condition or injury.

- Urinalysis to exclude urinary-tract infection.
- FBC, urea and electrolytes, clotting in cases with bruising.
- Plain radiographs to exclude fractures. A skeletal survey may be indicated in exceptional circumstances.
- CT brain scan if intracranial haemorrhage is suspected.

### Management

Doctors with child patients have a duty to act 'single-mindedly in the interests of the child' and not the parents (House of Lords). Generally concerns should be discussed with the responsible adult only if this will not put the child at a greater risk of significant harm.

Keep good notes of the initial assessment and all subsequent communications with the parents and healthcare professionals involved in the case.

Any suspicion of child abuse should be brought to the attention of the local named healthcare professionals for child-protection issues (paediatrician and paediatric nurse). They will be able to offer advice with regards to the Local Safeguarding Children Board child-protection procedures.

### Further reading

Department of Health. 2003. What to do if you're worried a child is being abused. Department of Health, London.

HMSO. 2002. *The Victoria Climbié Inquiry: Report of an Inquiry by Lord Laming*. HMSO, London.

Royal College of Nursing. 2005. *Child protection – every nurse's responsibility*. Royal College of Nursing, London.

## 11.9 NHS structure and economics

### NHS structure

The NHS is one of the largest-employing agencies in the world, with over 1 million people currently working for it. Although aspects of the structure of the NHS are changed on a fairly regular basis (and can differ between individual countries), a brief overview of how the current structure stands is as follows:

#### Department of Health

This is led by the Secretary of State for Health and is responsible for the health of the nation. It negotiates NHS funding with the treasury, provides strategic direction, and sets national standards for the health service.

#### Special Health Authorities

These are 19 independent bodies (although still subject to ministerial direction) and provide a service to the whole of the NHS in England, rather than at a local level. Examples include the National Blood Authority, National Institute for Health and Clinical Excellence, and the National Patient Safety Agency.

#### Strategic Health Authorities

There are currently 10 Strategic Health Authorities who act at a local level and are responsible for determining strategy and monitoring and improving performance of local Primary Care Trusts and NHS Trusts. Strategic Health Authorities link back to the Department of Health.

#### Primary Care Trusts

Primary Care Trusts are accountable to their Strategic Health Authority and are responsible for managing healthcare at a local level. They develop primary care services, ensure that social care services are in place, and are also responsible for planning secondary care. Primary Care Trusts work closely with NHS Trusts so that acute and specialist services are available to meet the needs of the local community. A typical Primary Care Trust board comprises of executive and non-executive members from medical and non-medically trained backgrounds.

#### NHS Trusts

Secondary care is generally provided by hospitals working within NHS Trusts and Trusts employ most of the NHS workforce. Examples of NHS Trusts include acute care trusts (i.e. district general hospitals and some specialty units), mental health trusts, ambulance trusts, and integrated service trusts (which may provide community services). Trust board members make decisions about policy and strategic direction although trusts are directly accountable to the Secretary of State, who appoints the chair of each trust.

#### NHS Foundation Trusts

These differ from traditional NHS as they are freestanding hospitals, and free from direction by the Secretary of State. They are accountable to local people who can become members and governors. They are independently regulated (by Monitor) and have freedom to sell land to invest in new patient services, borrow for investment in services instead of receiving a central allocation, and freedom to use local pay awards to incentivize staff.

### NHS economics

The cost of running the NHS has increased significantly over recent years, with the projected NHS expenditure in 2007/2008 being over £100 billion. Over three-quarters of this funding comes from general taxation, with approximately 10% of funds being raised from National Insurance contributions and the remainder from patient charges.

### Distribution of funds

Strategic Health Authorities allocate 75% of the NHS budget to Primary Care Trusts to fund local services. NHS Trusts obtain most of their income from service-level agreements with their local Primary Care Trust on a payment-by-results basis (see below).

#### Public Service Agreements

These identify the main areas of improvement that the government and patients can expect to be achieved from the distribution of funds within a finite time period.

Examples of Public Service Agreements include:

- **18 week patient pathway:** to deliver a maximum wait of 18 weeks from GP referral to hospital treatment, by the end of 2008.
- **Choose and book:** patients are given a choice of at least four healthcare providers, at a time and date that suits their convenience.

#### Payment by results

This has been introduced to improve efficiency within the NHS. Healthcare providers are paid a standard fixed rate (national tariff) for a particular procedure (e.g. cataract surgery, hip replacement) and will therefore receive greater income if they are able to carry out more procedures or at a lower cost than the national tariff.

#### Private Finance Initiative

The Private Finance Initiative is a scheme where private companies are involved in the development of major healthcare projects (e.g. building and maintenance of new hospitals). The public sector repays the costs plus interest to these private consortiums, usually over a long period, such as 30 years.

Benefits of Private Finance Initiative include the ability to raise the capital for funding of major new healthcare products that would have been difficult using public finances alone, although concerns have been raised about the overall cost to the taxpayer in the long term.

#### Independent-Sector Treatment Centres

These are private-sector-owned treatment centres that carry out elective surgical and diagnostic procedures. They work on central government bulk contracts which are paid in advance, irrespective of the number of patients actually treated.

### Further reading

Gatrell J, White T. 2006. Understanding the NHS. In *The Specialist Registrar and New Consultant Handbook*, chapter 8. Radcliffe Publishing, Oxford.

Gatrell J, White T. 2006. Funding and the NHS. In *The Specialist Registrar and New Consultant Handbook*, chapter 9. Radcliffe Publishing, Oxford.



## 11.10 The Ophthalmic Trainees' Group

by Jonathan Ross

### Introduction

The Ophthalmic Trainees' Group (OTG) is the voice of UK ophthalmic trainees within the Royal College of Ophthalmologists. It consists of elected trainees from 11 regions of the UK, as well as an overseas representative and a College Officer such as the President. From within the OTG a chairperson and a deputy chair are agreed by internal ballot. The OTG currently meet in London quarterly and at the time of writing are investigating more regular videoconferencing. In addition they provide trainee representation at all other College committees with the OTG chairperson attending College Council.

Through this system all ophthalmic trainees have the opportunity to express their views and concerns to the College on matters relating to the quality and standards of their training (note that all the Medical Royal Colleges are obliged by the terms of their Royal Charters not to engage in employment-related issues such as on-call pay-band disputes).

### Academy of the Medical Royal Colleges

The Medical Royal Colleges of the UK seek to promote the highest standards of quality in medicine. Their collective voice is expressed through the Academy of the Medical Royal Colleges which is based at the Royal Society of Medicine in London. The Academy provides an interface for continuous dialogue on healthcare policy between the Royal Colleges, the Department of Health, and other stakeholders.

### Academy Trainee Doctors Group

Other Royal Colleges have a comparable trainee representation structure to the Royal College of Ophthalmologists, and in parallel to the Royal Colleges and Academy, the chairpersons of all the trainee groups meet at the Academy to form the Academy Trainee Doctors Group. This committee allows medical trainees as a whole to lobby the Department of Health on matters relevant to trainees within the brief of the Royal Charters. The Academy Trainee Doctors Group meets quarterly, has internally appointed chair and deputy chair positions, and gives trainee representation to other groups within the Academy. For example, the chairman of the Ophthalmic Trainees Group recently attended the Academy Foundation Programme Committee and contributed to the development of the Foundation Programme Curriculum.

### The British Medical Association Junior Doctors Committee

The Junior Doctors Committee also represents the interests of medical trainees to the Department of Health and other stakeholder organizations. It is quite separate from the Royal Colleges and does not operate within the constraints of a Royal Charter. On occasions Junior Doctors Committee members and Royal College Trainee committee members attend each others' meetings to facilitate good communication.

### ORYCLE

The OTG organizes an annual educational event entitled Ophthalmic Registrars and Young Consultants Learning the Essentials (ORYCLE). This meeting is non-clinical and is intended to cover areas relevant to starting in the business of providing a hospital-based clinical service. Recent topics have included medico-legal issues, writing business cases, community-based ophthalmology, and surviving the first year as a consultant. This event is always well attended and an opportunity to meet with colleagues at a similar stage in their career development.

### OTG Forum

Each year at Royal College of Ophthalmologists' Congress the OTG provides a forum for trainees to meet the OTG and raise issues in an informal environment. These events are also attended by senior College officers who have made themselves available for trainees who may wish to discuss issues in confidence.

### Sharing information

The OTG are developing a new website with the objective of developing faster and easier communication with all trainees. It can be found at [www.ophthalmictrainee.com](http://www.ophthalmictrainee.com). The OTG plan to use this website to organize information relevant to the ophthalmic trainee. The aim is to provide all regional postgraduate teaching programmes and Ophthalmological Society links online so that trainees can monitor teaching activity around the UK for the first time. Furthermore, there is now an online discussion forum where trainees can share information and ideas with each other and with the OTG. The website also provides links to national and international subspecialty associations so that trainees can conveniently plan their diaries for the forthcoming year. In the near future the aim is to deliver detailed workforce planning information, subspecialty fellowship reports from the UK and abroad and useful information on non-clinical educational opportunities. Ultimately the OTG and its website exist to serve the interests of trainees. It is constantly looking to deliver more and welcomes your ideas and suggestions. There is also a section in the Royal College website (at [www.rcophth.ac.uk/training/otg](http://www.rcophth.ac.uk/training/otg)). In time these two sites will be amalgamated as part of a new College website.

*This page intentionally left blank*

# Index

4Δ base-out prism test 338, 393  
16Δ prism tests 328, 330  
100 day glaucoma 164

## A

A pattern 346, 347  
A-scan ultrasonography  
  intraocular lens power calculations 262, 264  
  principles and technology 112  
ABC classification, retinoblastomas 129  
abducens cranial nerve see sixth cranial nerve  
abrasion, corneal 61  
absolute afferent pupillary defect 390  
abuse, child 431  
Academy of the Medical Royal Colleges 433  
Academy Trainee Doctors Group 433  
*Acanthamoeba* 34, 35  
accelerated hypertension 162  
accelerated-phase (malignant) hypertension 162, 232, 233  
accommodation 238  
accommodative convergence/accommodation ratio 327  
acetazolamide 310  
acid injuries 64  
acquired cataract see cataract, acquired  
acquired distichiasis 74  
actinic keratosis 88, 89  
acute angle closure 292–3  
  glaucoma 292–3  
    case-based discussion 318  
acute dacryocystitis 94, 95, 97  
acute demyelinating optic neuritis 372  
acute postoperative endophthalmitis 252–3, 274  
acute retinal necrosis 206–7  
acute spastic entropion 76  
acute stromal keratitis 41  
acute zonal occult outer retinopathy 150  
adalimumab 226  
adenoid cystic carcinoma 412  
adenomas  
  benign mixed tumour/pleomorphic 412, 413  
    case-based discussion 420  
  pituitary 368–9  
adenoviral conjunctivitis 14–15  
adenoviral keratitis 14, 15  
Adie pupil 364, 391  
adjustable suture techniques, strabismus 351  
adnexa, slit lamp examination 6  
adrenochrome deposition 42  
adult inclusion conjunctivitis 16  
adult vitelliform macular degeneration 184, 185  
advancement, strabismus surgery 349  
afferent pupillary defects 390  
after-image test 331  
age-related cataract, case-based discussion 274  
age-related macular degeneration see macular degeneration, age-related  
agonist–antagonist pairs, extraocular muscles 322  
Ahmed tube 317  
AIDS see HIV/AIDS  
alkali injuries 64  
  case-based discussion 69  
alkylating agents 225  
allergic conjunctivitis 18–19  
  as contact lens wear complication 50  
α-agonists 308–9  
alphabet patterns 346–7  
Alphagan 309  
alternate cover test 325  
amblyopia 334  
ametropia 259  
ametropic amblyopia 334  
amiodarone 42  
amniotic membrane transplantation 44–5  
Amsler grid testing 171  
anaesthesia  
  local 266–7  
  peribulbar 266  
  retrobulbar 266

sub-Tenon 266, 267  
topical 266  
  abuse 20  
topical-intracameral 266  
anakinra 226  
angle closure  
  acute see acute angle closure  
  glaucoma  
    case-based discussion 318  
    primary 292–3  
    secondary 298  
  primary 292  
  secondary 292  
angle-recession glaucoma, traumatic 296  
animals test 330  
aniridia 306–7  
anisocoria 391  
  case-based discussion 397  
anisometropia  
  case-based discussion 352  
  contact lenses 50  
anisometropic amblyopia 334  
ankyloblepharon 22  
ankylosing spondylitis 220  
annulus of Zinn 322  
anterior blepharitis see blepharitis, anterior  
anterior capsule opacification 254, 255  
anterior chamber  
  activity, grading of 196  
  slit lamp examination 6  
anterior ischaemic optic neuropathy 374, 375  
  case-based discussion 396  
  non-arteritis 374  
anterior orbitotomy 418  
anterior segment  
  disease, history taking 4–5  
  examination 5–7  
  injuries 61  
  see also external eye disease  
anterior uveal tumours 58–9  
anterior uveitis 196–7  
anterior vitreous, slit lamp examination 6  
antibiotic prophylaxis, cataract surgery 253  
antimetabolites 225  
antiphospholipid syndrome 228  
anti-VEGF agents, intravitreal 160, 176–7  
Anton's phenomenon 370  
apnoea, obstructive sleep 235  
apocrine hidrocystoma 84  
aponeurotic ptosis 80, 81  
apoplexy, pituitary 368  
applanation A-scan ultrasound 262, 264  
applanation tonometry, Goldmann 282  
appraisal 428  
apraclonidine 309  
aqueous fluid dynamics 277  
aqueous misdirection syndrome see glaucoma, malignant  
aqueous outflow 277  
aqueous production 277  
arcuate keratotomy 66  
arcus senilis 30, 31  
argon laser  
  peripheral iridoplasty 313  
  trabeculoplasty 312, 314  
Argyll Robertson pupil 391  
arteriosclerosis 162  
arteriovenous malformations  
  retinal 130  
  orbital 408, 409  
  case-based discussion 420  
arteritis, giant cell see giant cell arteritis  
arthritis  
  juvenile idiopathic 220–1  
  psoriatic 220  
  rheumatoid 228–9  
  seronegative 220, 229  
*Aspergillus* 210  
asteroid hyalosis 116, 117  
astigmatism  
  contact lenses 50, 51  
  corneal topography 68  
  refractive surgery 66

astrocytic hamartoma 130  
atheromatous disease 232  
atopic conjunctivitis 18–19  
atopic dermatitis  
  eyelid swelling 98  
  keratoconjunctivitis 18  
atopic keratoconjunctivitis 18–19  
atrial fibrillation 233  
atrophy  
  optic 377  
  peripapillary 278, 280  
  progressive bifocal chorioretinal 184  
  progressive iris 306  
atropine penalization, amblyopia 334  
atypical lymphoid hyperplasia 411  
audit, clinical 428  
augmented trabeculectomy 316  
autofluorescence 148  
Avastin 176  
Avellino dystrophy 46  
Axenfeld–Riegers syndrome 307  
azathioprine 225  
Azoft 309

## B

B-scan ultrasonography  
  open globe injury 60  
  optic disc drusen 378  
  principles and technology 112  
bacterial conjunctivitis see conjunctivitis, bacterial  
bacterial endophthalmitis see endophthalmitis, bacterial  
bad news, breaking 425  
Baerveldt tube 317  
Bagolini filter bar 331  
Bagolini glasses test 331  
Bailey–Lovie chart 328  
band keratopathy 30, 31  
  as complication of anterior uveitis 197  
Bardet–Beidl syndrome 182  
basal cell carcinoma 88, 89  
  case-based discussion 102  
basal cell naevus syndrome 88  
basal ganglia 324  
base-down prism tests 320  
base-out prism tests 330, 338, 393  
basic constant esotropia 340  
basiliximab 226  
bayoneting, optic nerve head 278  
Behcet's disease 216–17, 218  
Bell's phenomenon 82  
benign epithelial hyperplasias 84  
benign intracranial hypertension 376  
benign iris naevi 59  
benign melanocytic lesions 84–5  
benign melanosis 28  
benign mixed tumour (pleomorphic) adenoma 412, 413  
  case-based discussion 420  
benign reactive lymphoid hyperplasia 410–11  
Best's disease 184, 185  
  case-based discussion 191  
  electrooculography 152  
β-blockers 308  
Betagan 308  
betaxolol 308  
Betoptic 308  
bevacizumab 176  
biases, decision-making 426  
Biber–Haab Dimmer lattice dystrophy 47  
bifocal chorioretinal atrophy, progressive 184  
bilateral diffuse uveal melanocytic proliferation 131  
bimatoprost 308  
binocular indirect ophthalmoscopy 198  
binocular single vision 335  
  abnormalities, and adaptations to 335  
  assessment 327  
  levels 335  
  tests 330  
biological agents 226  
biometry 262–4  
biopsy, temporal artery 375

- birdshot chorioretinopathy 150  
 blanching, conjunctival 64, 65  
 blepharitis 8–9  
 blepharochalasis 99, 101  
 blepharoconjunctivitis  
   herpes simplex 16  
   *Staphylococcus aureus* 16  
 blepharophimosis syndrome 96, 97  
   ptosis 80  
 blepharoplasty 98  
 blepharoptosis see ptosis  
 Bloch–Sulzberger syndrome 136  
 blow-out orbital fractures 416, 417  
   case-based discussion 421  
 blurred vision 4  
 Bolam test 429  
 botulinum-toxin injections 98  
   strabismus management 351  
 Bowen disease 88  
 Bowman's layer  
   corneal dystrophy of 46, 47  
   histology 2, 3  
   slit lamp examination 6  
 brachytherapy 59  
 branch retinal artery occlusions 168–9  
 branch retinal vein occlusions 166, 167  
   case-based discussion 190  
 brimonidine 309, 310  
 brinzolamide 309  
 British Medical Association Junior Doctors  
   Committee 433  
 Brown's syndrome 343  
   rheumatoid arthritis 229  
 Bruch's membrane 104  
 buckling, scleral 119  
 bulbar conjunctiva 3  
 bullous keratopathy 49  
 burning eye 4
- C**  
 Caldicott Report (1997) 429  
 canalicular obstruction 94  
 canaliculitis 94, 95  
 canaliculodacryocystorhinostomy 94  
 canaliculotomy 94  
 canaliculus 98, 99  
*Candida* 210, 211  
 capillary haemangioma 130, 131, 408, 409  
   strawberry naevi 85, 87  
 capsular rupture, posterior 250, 251  
 capsulorrhexis  
   congenital cataract surgery 258  
   continuous curvilinear 246, 248  
   loss 250  
 carbonic anhydrase inhibitors  
   systemic 310  
   topical 309  
 carcinoma  
   adenoid cystic 412  
   basal cell 88, 89  
   case-based discussion 102  
   *in situ* 26  
   Merkel cell 90  
   metastatic see metastatic tumours  
   posterior segment metastasis 134  
   sebaceous gland 90, 91  
   squamous cell  
     Bowen disease 88  
     conjunctival 26  
     eyelids 88, 90  
 Cardiff cards 328  
 cardiovascular disease 232–3  
 carotid disease 232  
 carotid-cavernous fistula 408, 409  
   case-based discussion 420  
 caruncle 2  
 cataract  
   acquired 240–3  
     case-based discussion 274  
     clinical evaluation 244–5  
     treatment 246–9  
   age-related, case-based discussion 274  
   biometry 262–4  
   Christmas tree 395  
   as complication  
     of anterior uveitis 197  
     of intermediate uveitis 199  
   congenital 256–7  
     management 258–9  
     cortical 240, 241  
     electric 242  
     extraction 55  
   hypermaturation 240  
   immature 240  
   lamellar 256, 257  
   lens  
     anatomy 238, 239  
     dislocation 260–1  
     embryology 238, 239  
     intraocular 270–1  
   local anaesthesia 266–7  
   mature 240, 242  
   Morgagnian 240  
   Nd:YAG laser capsulotomy 272–3  
   nuclear 240, 241, 256  
     case-based discussion 274  
     operating microscope 268, 269  
   phacodynamics 268, 269  
   posterior 256  
   posterior capsular opacification 254, 255  
     case-based discussion 274  
   as side effect of intraocular treatments 227  
   subcapsular 240, 241  
   surgery 244, 246–9, 258–9  
     adverse outcomes, contributory  
       factors 245, 267  
     extracapsular 246–7  
     indications 244  
     infectious postoperative complications 252–3, 274  
     intraoperative complications 250–1  
     local anaesthesia 266–7  
     non-infectious postoperative  
       complications 254–5  
     see also phacoemulsification; lens, intraocular  
     implantation  
       traumatic 242  
       uveitic 242  
 Catford drum 328  
 cavernous haemangioma 130, 408, 409  
 Cellcept 225  
 cellophane maculopathy see epiretinal membrane  
 cellulitis  
   orbital (postseptal) 404, 405  
   preseptal 404, 405  
 central retinal artery occlusions 168, 169  
   case-based discussion 190–1  
 central retinal vein occlusions 164–5  
 central serous chorioretinopathy 178–9  
 central visual disturbance 106  
 cerebellum 324  
 chalazia 84, 85  
 chalcosis 43  
   and siderosis, comparison between 141  
 Chandler's syndrome 306  
 Charles Bonnet syndrome 106  
 chemical injuries 64–5  
   case-based discussion 69  
 chiasm, optic  
   anatomy 356  
   lesions 368  
 chiasmal visual pathway disorders 368–9  
 child protection 431  
 chlamydial conjunctivitis 16, 17  
 chlamydial ophthalmia neonatorum 16  
 chlorambucil 225  
 chloroquine 42  
 chlorpromazine 42  
 cholinergic agents 309  
 choriocapillaris  
   anatomy 104  
   physiology 105  
 chorioretinal atrophy, progressive bifocal 184  
 chorioretinopathy  
   birdshot 202, 203  
   indocyanine green angiography 150  
   central serous 178–9  
 choristomas, epibulbar 28–9  
 choroid  
   anatomy 104, 194, 195  
   circulation 105  
   examination 107  
 choroidal dystrophy 188  
 choroidal haemangiomas 132  
 choroidal melanoma 133, 134, 135  
   case-based discussion 143  
   ultrasonography 112, 113  
 choroidal naevi 132, 133  
 choroidal neovascularization  
   submacular removal 126  
   wet age-related macular degeneration 172  
 choroidal tumours 132–5  
 choroideaemia 188  
 choroiditis  
   HIV-related 215  
   multifocal 150
- choroidopathy  
 punctate inner 203  
 serpiginous 204, 205  
 choristomas, epibulbar 28–9  
 chronic dacryocystitis 94  
 chronic obstructive pulmonary disease 235  
 chronic postoperative endophthalmitis 253  
 chronic progressive external ophthalmoplegia 395  
 chrysiasis, corneal 42  
 Churg–Strauss syndrome 230  
   respiratory disease 235  
 cicatricial ectropion 78  
   case-based discussion 102  
 cicatricial entropion 76  
 cicatrizing conjunctival disease see conjunctival  
   disease, cicatrizing  
 ciliary block glaucoma see glaucoma,  
   malignant  
 ciliary body  
   anatomy 194, 195  
   gonioscopy 284  
   melanoma 58–9  
 cilioretinal artery occlusion 169  
 ciprofloxacin deposits 42  
 circles test 330  
 City University colour vision test 363  
 climatic keratopathy 30  
 clinical audit 428  
 clinical care, good 424  
 clinical governance 427  
 Coats' disease 180, 181  
   ultrasonography 112  
 cobblestone degeneration, peripheral  
   retina 122, 123  
 cobblestone papillae 18, 19  
 Cogan–Reese syndrome 306  
 Cogan's lid-twitch sign 82  
 Cogan's microcystic dystrophy see dystrophy,  
   epithelial basement membrane  
 Cogan's syndrome 39  
 coloboma  
   eyelids 96  
   optic disc 378  
 colour vision  
   assessment 363  
   disturbance 106, 360  
 combigan 310  
 communication 425  
 complaints, dealing with 425  
 complex strabismus 343  
 compressive optic neuropathy 373  
 computed tomography 366  
 epiphora 92  
 keratoconus 52  
 open globe injury 60  
 concomitant strabismus see strabismus,  
   concomitant  
 concretions 24  
 cone photoreceptors 105  
 cone-rod dystrophy 182  
 confidentiality 429  
 confusion, binocular single vision 335  
 congenital cataract 256–7  
   management 258–9  
 congenital distichiasis 74  
 congenital ectropion 77  
 congenital entropion 76  
 congenital epithelial melanosis 28  
 congenital nystagmus 386  
 congenital stationary night blindness 182  
 congenital tilted disc syndrome 378, 379  
 conjunctiva  
   anatomy and physiology 2–3  
   autografting 24  
   blood supply and lymphatic drainage 3  
   bulbar 3  
   degeneration 24–5  
     concretions 24  
     conjunctivochalasis 24  
     cysts, inclusion 24  
     lyphangiectasia 24  
     pingueculae 24  
     pterygia 24, 25  
   foreign bodies 61  
   forniceal 3  
   gross anatomy 2–3  
   histology 3  
   lymphoma 26, 27  
   neoplasia 26–9  
   non-Hodgkin lymphoma 26  
   palebral 2  
   papilloma 26, 27  
   slit lamp examination 6

- conjunctival disease, cicatrizing 22–3  
 graft-versus-host disease 23  
 OCP 22, 23  
 Stevens–Johnson syndrome 22–3
- conjunctival flaps 44
- conjunctival intraepithelial neoplasia 26, 27
- conjunctivitis  
 adenoviral 14–15  
 adult inclusion 16  
 allergic 18–19  
   as contact lens wear complication 50  
 atopic 18–19  
 bacterial 16–17  
 chlamydial 16, 17  
 classification 14  
 factitious keratoconjunctivitis 20  
 follicular 14  
 giant papillary 50–1  
 herpes simplex 16  
 molluscum contagiosum 16  
 mucus fishing syndrome 20  
 other infectious causes 16–17  
 Parinaud's oculoglandular syndrome 20  
 perennial allergic 18  
 seasonal allergic 18  
 superior limbic 20, 21  
 topical anaesthetic abuse 20  
 toxic keratoconjunctivitis 20  
 vernal keratoconjunctivitis 18, 19
- conjunctivochalasis 24
- conjunctivodacryocystorhinostomy 94
- consecutive esotropia 339
- consecutive exotropia 340  
   case-based discussion 353
- consent 429
- constant esotropia 340
- contact dermatitis 98
- contact lenses 50–1  
   bandage 50  
   complications of wear 50–1  
   diagnostic 108–9  
   keratoconus 52  
   keratoplasty, postoperative management 54  
   lost 51  
   non-optical therapeutic uses 50  
   optical uses 50
- continuing professional development 430
- continuous curvilinear capsulorhexis 246, 248
- convergence, assessment 327
- convergence excess esotropia 339
- conversion reaction disorders 393
- cornea  
   ablation by excimer laser 66–7  
   abrasion 61  
   anatomy and physiology 2, 3  
   chrysis 42  
   decompensation 254  
   degeneration 30–1  
   dystrophy 46–9  
     associated syndromes 48–9  
   ectasia see ectasia, corneal  
   endothelium see endothelium, cornea  
   epithelium see epithelium, cornea  
   foreign bodies 61, 62  
     removal 61  
   gross anatomy 2  
   histology 2, 3  
   innervation 2  
   irregularities, superficial 50  
   light reflexes (Hirschberg test) 326  
   limbal stem cells 2  
   melting, acute 41  
   nutrition 2  
   opacification 64, 65  
   pachymetry 67  
     keratoconus 52  
   precorneal tear film 2, 3  
   refractive surgery 66  
   relaxation procedures 66  
   slit lamp examination 5–7  
   sutures see sutures, corneal  
   thermocoagulation 66  
   thickness, pachymetry 283  
   topography 67, 68  
   transplantation see keratoplasty  
   trauma 250
- cornea verticillata see keratopathy, vortex
- corneal addition procedures 66
- corneal erosion syndrome, recurrent 48–9
- corneal glue 33
- corneal graft surgery see keratoplasty
- corneo-scleral lacerations 60–1
- correspondence, abnormal 335
- cortical cataract 240, 241
- corticosteroids  
   glaucoma, steroid-induced 295  
     case-based discussion 318–19  
   implants 227  
   intraocular treatments 227  
   intravitreal injection 227  
   ocular inflammatory disorders 224
- cosmesis  
   cataract surgery 244  
   strabismus surgery 348
- cosopt 310
- counselling, family and genetic 128
- cover tests 325
- cover–uncover test 325
- cranial nerves  
   anatomy 358–9  
   palsies 380–4
- craniopharyngiomas 368
- crowding phenomenon, visual acuity testing 328
- cryotherapy 88
- crystalline keratopathy, infectious 32, 33
- CS gas 64
- cup/disc ratio 276  
   glaucoma 278
- cutaneous horn 84
- cyclical esotropia 339
- cyclodialysis cleft 297
- cyclodiode laser 312–13, 314
- cyclophoria 326
- cyclophosphamide 225
- cyclosporin A 224–5
- cystic lesions 412–13
- cystinosis 42
- cystoid degeneration, peripheral 122
- cystoid macular oedema see macular oedema, cystoid
- cysts  
   dermoid 412, 413  
   epidermoid 412  
   eyelid 84  
   inclusion 24  
   of Moll see hidrocystoma, apocrine  
   pars plana 122  
   sebaceous 84  
   of Zeis 84
- D**
- daclizumab 226
- dacryoadenitis 407
- dacryocystitis 94, 95, 97
- dacryocystoceles 96
- dacryocystography 92
- dacryocystorhinostomy 94, 95
- dacryops 412
- Dalen–Fuch's nodule 202
- Data Protection Act (1998) 429
- de Morsier syndrome 378
- deafness  
   Duane's syndrome 343  
   retinal dystrophies 184–5
- decision-making 426
- decompression, orbital 418
- deep anterior lamellar keratoplasty 52
- degenerative retinoschisis 122, 123
- dehiscence, retractor 78
- dellen 13
- demyelinating optic neuritis, acute 372
- Department of Health 432
- dermal melanocytosis 84–5  
   ipsilateral 28
- dermatitis  
   atopic 18, 98  
   contact 98
- dermatochalasis 98, 100
- dermoid cysts 412, 413
- dermoids, epibulbar 28–9
- dermolipomas 29
- Descemet's membrane  
   histology 2, 3  
   slit lamp examination 6
- dexamethasone  
   glaucoma, steroid-induced 295  
   implant 227
- diabetes, maternal inherited 184–5
- diabetes mellitus 156, 234  
   systemic complications 156
- diabetic hypertension 234
- diabetic maculopathy 156, 158, 160, 161
- diabetic retinopathy see retinopathy, diabetic
- diagnostic lenses 108–9
- diameter, optic nerve head 278
- Diamox 310
- diffuse illumination, slit lamp technique 5, 7
- diffuse neurofibroma 410
- diplopia  
   binocular single vision 335  
   myasthenia gravis 394  
   neuro-ophthalmology history taking 360  
   as strabismus surgery complication 350  
   sudden-onset 396  
     following trauma 420–1
- direct focal illumination, slit lamp technique 5, 7
- direct gonioscopy 284
- discharge, history taking 4
- disinsertion 348
- dislocated lens see lens, dislocation
- dissociated vertical deviation 344
- distance intermittent exotropia 340
- distichiasis 74, 75
- doctor–patient communication 425
- doctor–patient relationship 424, 425
- documentation 425
- dominant cystoid macular oedema 184
- Doppler technology, ultrasonography 112
- dorzolamide 309, 310
- double elevator palsy 344
- downbeat nystagmus 386  
   case-based discussion 397
- drainage implants 317
- driving licences 286
- drug history  
   anterior segment disease 4  
   neuro-ophthalmology history taking 361  
   orbit 402
- drug-induced keratopathy 42–3
- drusen  
   familial 184  
   optic disc 378, 379
- dry age-related macular degeneration 170–1, 190
- dry eye disease 12–13  
   dellen 13  
   rheumatoid arthritis 229
- Duane's syndrome 343
- ductions 323  
   assessment 327
- DuoTrav 310
- duplex-scan ultrasonography 112
- dyes 7
- dynamics, aqueous fluid 277
- dysfunctional tear syndrome see dry eye disease
- dysthyroid eye disease see thyroid eye disease
- dystrophies  
   Avellino 46  
   Biber–Haab Dimmer lattice 47  
   choroidal 188  
   Cogan's microcystic see dystrophy, epithelial  
     basement membrane  
   cone-rod 182  
   corneal 46–9  
     associated syndromes 48–9  
   endothelial 48, 49  
   epithelial 46, 47  
   epithelial basement membrane 46, 47  
   gelatinous droplike 47  
   granular 46, 47  
   granular-lattice 46  
   lattice 46–7  
   macular 47, 49  
   map-dot-fingerprint see dystrophy, epithelial  
     basement membrane  
   Meesmann 46  
   North Carolina macular 184  
   of Bowman's layer, corneal 46, 47  
   pattern 184, 186  
   posterior polymorphous 48  
   Reis–Bücklers 46, 47  
   retinal 182–6  
   rod-cone 182  
   Schnyder crystalline 47  
   Sorsby's macular 184, 186  
   stromal 46–7  
   Theil–Behnke 46
- E**
- Eales' disease 204
- eccrine hidrocystoma 84
- echography 112
- ectasia, corneal 52–3  
   keratoconus 52, 53  
     posterior 53  
   keratoglobus 53  
   pellucid marginal degeneration 53
- ectopia lentis see lens, dislocation



- ectropion 77–8  
 case-based discussion 102  
 cicatricial 78  
   case-based discussion 102  
 congenital 77  
 involutional 78  
 mechanical 78  
 medial 94  
 paralytic 78  
 eczema 98  
 education 430  
 efferent pupillary defects 390–1  
 electric cataract 242  
 electrooculography 152–3  
 electrophysiology 152–4  
 electroretinography 152, 153–4  
   full-field (Ganzfield) 152  
   multifocal 152, 154  
   pattern 152, 153  
 emboli, retinal 232–3  
 embryology  
   retinal anatomy 104  
   retinopathy of prematurity 138  
 emmetropia  
   intraocular lens power calculations 262  
   at time of intraocular lens implantation 259  
 encephalocele 412–13  
 end-point nystagmus 386  
 endocarditis 233  
 endocrine diseases 234  
 endogenous endophthalmitis 210, 211  
 endophthalmitis  
   acute postoperative 252–3, 274  
   as glaucoma surgery complication 317  
   bacterial  
     endogenous 212–13  
     exogenous 213  
     as side effect of intraocular treatments 227  
   chronic postoperative 253  
   endogenous 210, 211  
   postoperative 213  
 endothelial dystrophy *see* dystrophy, endothelial  
 endotheliopathy, primary proliferative *see*  
   iridocorneal/endothelial syndrome  
 endothelium, cornea  
   histology 2, 3  
   slit lamp examination 6  
 entropion 76–7  
   acute spastic 76  
   cicatricial 76  
   congenital 76  
   involutional 76  
 enucleation 418–19  
   melanoma  
     ciliary body 59  
     iris 58  
 eosinophilic granuloma 412  
 epiblepharon 96  
 epibulbar choristomas 28–9  
 epibulbar dermoids 28–9  
 epicanthus 96  
 epidemic keratoconjunctivitis 14  
 epidermoid cysts 412  
 epidermolysis bullosa acquisita 235  
 epikeratophakia 66  
 epimacular proliferation *see* epiretinal membrane  
 epiphora 92–3  
   case-based discussion 102  
   evaluation 92  
   syndring and probing 92  
 epiretinal membrane  
   as complication of intermediate uveitis 199  
   surgery 124, 125  
 episclera, slit lamp examination 6  
 episcleritis 222–3  
   rheumatoid arthritis 229  
 epithelial basement membrane dystrophy 46, 47  
 epithelial defects  
   chemical injury 64, 65  
   as contact lens wear complication 50  
   as keratoplasty complication 56  
   non-healing 44  
 epithelial dystrophy 46, 47  
 epithelial hyperplasias, benign 84  
 epithelial melanosis, congenital 28  
 epithelial neoplasia 26, 27  
 epithelial tumours 412  
 epitheliopathy 202  
 epithelium, cornea  
   histology 2, 3  
   slit lamp examination 6  
 erysipelas 99  
 erythema multiforme 235  
 erythema nodosum 235  
 esophoria 336  
 esotropias 338–9  
   alphabet patterns 346  
   case-based discussion 352  
   consecutive 339  
   cyclical 339  
   infantile 352  
   intermittent 339  
     case-based discussion 352  
     near 339  
   nystagmus block 340  
   primary constant  
     with accommodative element 338  
     non-accommodative 338  
   secondary 339  
   sensory 339  
   sudden-onset constant 340  
 essential hypertension 162  
 Esterman visual-field testing 286  
 etanercept 226  
 evanescent white dot syndrome, multiple 150, 203  
 evisceration 418, 419  
 excimer laser, corneal ablation by 66–7  
 exenteration 419  
   melanoma, ciliary body 59  
 exhaustive review, decision-making 426  
 exophoria 336  
 exophthalmometry 402–3  
 exotropias 340  
   alphabet patterns 346  
   case-based discussion 353  
   consecutive 340  
     case-based discussion 353  
   distance intermittent 340  
   near intermittent 340  
   non-specific intermittent 340  
   primary constant 340  
   primary intermittent 340  
   secondary 340  
 exposure keratopathy 44, 45  
 external beam irradiation 59  
 external eye disease  
   anterior segment disease, history taking 4–5  
   blepharitis 8–9  
   chemical injury 64–5  
     case-based discussion 69  
   conjunctival anatomy and physiology 2–3  
   conjunctival degeneration 24–5  
   conjunctival disease, cicatrizing 22–3  
   conjunctivitis  
     adenoviral 14–15  
     allergic 18–19  
     classification 14  
     miscellaneous 20–1  
     other infectious causes 16–17  
   contact lenses 50–1  
   corneal anatomy and physiology 2, 3  
   corneal degeneration 30–1  
   corneal foreign bodies, removal of 61  
   corneal glue 33  
   corneal pachymetry 67  
   corneal sutures, removal of 55  
   corneal topography 67, 68  
   dry eye disease 12–13  
   dystrophies, corneal 46–9  
   ectasia, corneal 52–3  
   examination of anterior segment 6–7  
   graft rejection 56–7  
   keratitis, infectious  
     bacterial 32–3, 69  
     fungal 34–5  
     protozoal 34, 35  
     viral; herpes simplex 36–7  
     viral; herpes zoster 38, 69  
   keratitis, interstitial 39  
   keratitis, peripheral ulcerative 40–1  
   keratopathies  
     metabolic and drug-induced 42–3  
     miscellaneous 44–5  
   keratoplasty 54–5  
     complications 56, 57  
   neoplasia, conjunctival 26–9  
   refractive surgery 66–8  
   staphylococcal hypersensitivity disorders 10–11  
   trauma, anterior segment 60–2  
   tumours, anterior uveal 58–9  
 external ophthalmoplegia, chronic  
   progressive 395  
 extraocular muscles  
   actions 322–3, 324  
   assessment 327  
   anatomy 322  
   congenital fibrosis of the 343  
   exuberant hyperkeratosis 84  
 exudative vitreoretinopathies, familial 136  
 eye movements *see* oculomotility  
 eyelashes  
   abnormality 74–5  
   anatomy 72  
   metaplastic *see* distichiasis, acquired 74, 75  
 eyelid imbrication syndrome 98  
 eyelids  
   anatomy 72, 73  
   benign lesions 84–7  
   blood supply 72  
   coloboma 96  
   grey line 72  
   gross structure 72  
   lacerations 98, 99  
   lamellae 72  
   lower lid retractors 72  
   lumps, case-based discussion 102  
   lymphatic drainage 72  
   malignant lesions 88–91  
   premalignant lesions 88, 89  
   retraction 98  
   swelling  
     allergic 98–9  
     bacterial causes 99  
     infectious 99, 101  
   trauma 98  
   upper lid elevators 72

## F

- Fabry's disease 42  
 factitious keratoconjunctivitis 20  
 Faden procedure 342, 344, 348  
 familial drusen 184  
 familial exudative vitreoretinopathies 136  
 family history  
   anterior segment disease 4  
   neuro-ophthalmology 361  
   orbit 402  
   posterior segment 106  
   retinoblastomas 128  
 farinata, corneal 30  
 Farnsworth D15 test 363  
 Farnsworth–Munsell 100-hue test 363  
 Fasanella–Servat procedure 80  
 FASTPAC 286  
 fat-suppression techniques, MRI 366  
 Fells modification, Harada–Ito  
   procedure 349  
 fibrosis  
   ocular motility 343  
   periretinal macular *see* epiretinal membrane  
 Fick, axes of 322, 323  
 filamentary keratopathy 12, 13  
 fistula, carotid-cavernous 408, 409  
   case-based-discussion 420  
 fixing and following, visual acuity testing 328  
 FK506 *see* tacrolimus  
 flashing lights 106  
 Fleischer ring  
   keratoconus 43, 52  
   Wilson's disease 42  
 floaters 106  
 floppy eyelid syndrome 98, 100  
 fluid dynamics, aqueous 277  
 fluocinolone implant 227  
 fluorescein 7  
   *see also* fundus fluorescein angiography  
 flutter, ocular 388  
 focus-shift principle 270  
 fogging test 393  
 follicles, conjunctiva 3  
 follicular conjunctivitis 14  
 forced duction test  
   orbital blowout fractures 342  
   strabismus 351  
 forced generation test 351  
 foreign bodies  
   conjunctival 61  
   corneal 61, 62  
   sensation of 4  
   subtarsal 62  
 fornical conjunctiva 3  
 fortification scotoma 392  
 fourth cranial nerve  
   anatomy 358  
   palsies 381, 383  
 fovea  
   anatomy 104  
   fundus fluorescein angiography 146  
 foveola 104  
 fractures, orbital 416–17  
   case-based discussion 421

freckle, conjunctival 28  
 frequency-doubling perimetry 288  
 Friedrich's ataxia 182  
 FRISBY test 330  
 frozen sections, basal cell carcinoma 88  
 Fuch's heterochromic iridocyclitis (Fuch's uveitis syndrome) 299  
 full-field electroretinography 152  
 fully accommodative esotropia 339  
   case-based discussion 352  
 fundal mass, elevated 142–3  
 fundus, examination 108, 109  
 fundus albipunctatus 182  
 fundus fluorescein angiography 146–7  
   abnormal 148–9  
   optic disc drusen 378  
 fusion 335  
 fusional amplitudes 327

## G

gadolinium enhancement, MRI 366  
 GanFort 310  
 Ganzfield electroretinography 152  
 gaze palsies 388, 389  
 gaze-evoked nystagmus 386  
 gelatinous droplike dystrophy 47  
 General Medical Council 424  
 giant cell arteritis 230  
   anterior ischaemic optic neuropathy 374  
   case-based discussion 396  
 giant papillary conjunctivitis 50–1  
 Gillespie syndrome 306  
 Gillick competence 429  
 glaucoma  
   100 day 164  
   acute angle closure 292–3  
   case-based discussion 318  
   angle-recession 296  
   aniridia 306–7  
   aqueous fluid dynamics 277  
   Axenfeld–Riegers syndrome 307  
   as cataract surgery complication 258  
   field defects 288–9  
   gonioscopy 284–5  
   hemifield test 287  
   hypertension, ocular 290  
   hypotensive agents, ocular 308–10  
   inflammatory 298–9  
   iridocorneal endothelial syndrome 306, 307  
   as keratoplasty complication 56  
   laser therapy 312–14  
   low-tension 294  
   malignant 304–5  
   neovascular 302–3  
   normal-tension 294  
   optic nerve head  
     anatomy 276  
     assessment 278–80  
   pachymetry 283  
   perimetry 286–9  
   Peter's anomaly 307  
   phacomorphic 292  
   pigmentary 300–1  
   primary open-angle 291  
   case-based discussion 318  
   central retinal vein occlusion 164  
   pseudoexfoliative 300, 301  
   secondary, as complication of anterior uveitis 197  
   secondary open-angle 298  
   as side effect of intraocular treatments 227  
   steroid-induced 295  
   case-based discussion 318–19  
   surgery 316–17  
   tonometry 282  
   traumatic 296–7  
 Glaucoma Probability Score 279  
 glaucomatocyclitic crisis 299  
 gliomas 410  
 glue, corneal 33  
 glycerin 310  
 goal-directed decision-making 426  
 Goldenhar syndrome  
   dermoids, epibulbar 28  
   Duane's syndrome 343  
   eyelid coloboma 96  
 Goldmann 3 mirror lens 108  
 Goldmann applanation tonometry 282  
 Goldmann–Favre syndrome 136  
 Goldmann lenses 284  
 Goldmann perimeter 286  
 Goldmann visual-field testing 393  
 gonioscopy 284–5  
 goniotomy 317  
 gonococcal bacterial conjunctivitis 16  
 gonococcal ophthalmia neonatorum 17  
 good medical practice 424  
 Gorlin syndrome 88  
 governance, clinical 427  
 gradient method, AC/A ratio calculation 327  
 graft failure 56  
 graft rejection 56–7  
 graft-versus-host disease 23  
 granular dystrophy 46, 47  
 granular-lattice dystrophy 46  
 granulocytic sarcoma 412  
 granuloma  
   eosinophilic 412  
   suture 350  
 Graves' disease see thyroid eye disease  
 Gundersen's flap 44  
 gyrate atrophy 188

## H

haemangiomas  
   capillary 130, 131, 408, 409  
   strawberry naevi 85, 87  
   cavernous 130, 408, 409  
   choroidal 132  
   racemose see arteriovenous malformations, retinal  
 haemorrhage  
   optic disc 278, 280  
   subconjunctival 61, 62  
   submacular 126  
   suprachoroidal  
     as cataract surgery complication 250  
     ultrasonography 112  
   vitreous 117  
     as complication of intermediate uveitis 199  
     diabetic retinopathy 160  
     ultrasonography 112, 113  
 hamartoma  
   astrocytic 130  
   retinal pigment epithelium and retina 130, 131  
 Harada–Ito procedure 349  
 Hasner, valve of 72–3  
 hay fever 18  
 head posture, binocular single vision  
   abnormalities 335  
 headache 392  
   case-based discussion 396  
   history taking 360–1  
 Healthcare Commission, independent review  
   by the 425  
 Heidelberg retinal tomographs 279  
 hemifield test, glaucoma 287  
 hemispheric retinal vein occlusions 166  
 Henson perimeter 286  
 hepatolenticular degeneration 42  
 Herbert's pits 17  
 hereditary optic neuropathy, Leber's 373  
 hereditary retinoschisis 136–7  
 hereditary vasculoretinopathies 136  
 hereditary vitreoretinopathies 136  
 Hering's law 323  
 herpes simplex  
   blepharoconjunctivitis 16  
   conjunctivitis 16  
   eyelid swelling 99  
   inflammation, ocular 235  
   keratitis see keratitis, herpes simplex  
 herpes zoster  
   eyelid swelling 99, 101  
   inflammation, ocular 235  
   keratitis see keratitis, herpes zoster  
   trabeculitis 38  
   uveitis 206, 207  
 Herring's law of equal innervation 80  
 Hess charts 332–3  
 Hess screen 332  
 heterochromic iridocyclitis, Fuch's 299  
 heterophorias 336  
   assessment 326  
 heterophoric method, AC/A ratio calculation 327  
 heuristics, decision-making 426  
 hydrocystoma  
   apocrine 84  
   eccrine 84, 86  
 Hirschberg test 326  
 histiocytosis X (Langerhans cell histiocytosis) 412  
 Histoplasma 210  
 histoplasmosis, presumed ocular 210  
 history taking  
   anterior segment disease 4–5  
   cataract 244  
   neuro-ophthalmology 360–1  
   orbit 402  
   retinoblastomas 128  
   strabismus 325  
 HIV/AIDS 214–15  
   ophthalmic manifestations 214  
   retinitis, cytomegalovirus 214–15  
 Hodgkin's lymphoma 204  
 Holmes–Adie syndrome 364  
 hordeola 84  
 horizontal gaze palsies 388, 389  
 Horner's syndrome 388, 390  
   case-based discussion 397  
   ptosis 80, 81, 82  
 Horner–Trantas dots 18, 19  
 Hotz procedure 76  
 Hruby lens 108  
 Hughes' classification 64  
 Hughes procedure, modified 88  
 Hummelshiem procedure 349  
 Humphrey perimeter 286, 287, 288–9  
 hundreds and thousands, visual acuity testing 328  
 Hurler syndrome 42  
 hyaloideoretinal degenerations 136  
 hydrops, corneal 52, 53  
 hyperfluorescence 148  
 hyperkeratosis, exuberant 84  
 hyperlacrimation 92  
 hypermature cataract 240  
 hypermetropia  
   history taking 106  
   optic nerve head 276  
   refractive surgery 66  
   at time of intraocular lens implantation 259  
 hyperosmotic agents 310  
 hyperplasias  
   atypical lymphoid 411  
   benign epithelial 84  
   benign reactive lymphoid 410–11  
   lymphoid 26  
   reactive 26  
 hypertension 162  
   accelerated or malignant 162  
   classifications 162  
   diabetic 234  
   essential 162  
   intracranial see intracranial hypertension  
   malignant (accelerated-phase) 232, 233  
   ocular 290  
   retinopathy 162–3  
   case-based discussion 190  
   systemic 232, 233  
 hypertrichosis 74  
 hyphaema 62  
   indodialysis 61  
   traumatic 296  
 hypofluorescence 148  
 hypoplasia, optic nerve 378, 379  
 hypotension, ocular  
   as complication of anterior uveitis 197  
   as complication of intermediate uveitis 199  
 hypotensive agents, ocular 308–10  
 hypotony see hypotension, ocular  
 hysterical blindness 393

## I

ice-pack test, myasthenia gravis 394  
 idiopathic intracranial hypertension 376  
 idiopathic juxtafoveal retinal telangiectasia 180  
 idiopathic orbital inflammatory disease 406  
 illiterate adults, acuity tests for 329  
 Imbert–Fick principle 282  
 immature cataract 240  
 immersion ultrasonography 262  
 immune-mediated disease, systemic 40, 41  
 immunoprotein deposits 42  
 impetigo 99  
 implants 227  
 inclusion conjunctivitis 16  
 incomitant strabismus 341  
 incontinentia pigmenti 136  
 Independent-Sector Treatment Centres 432  
 indirect gonioscopy 284–5  
 indirect illumination, slit lamp technique 7  
 indocyanine green angiography 150–1  
 infantile esotropia 340  
 infection, history taking 4  
 infectious crystalline keratopathy 32, 33  
 infectious keratitis see keratitis, infectious  
 infectious uveitis see uveitis, infectious  
 inferior oblique 322  
   overaction 344

- inferior rectus 322  
 inflammatory bowel disease 220  
 inflammatory disease, orbital 406  
   case-based discussion 420  
 inflammatory disorders, ocular  
   biological agents 226  
   intraocular treatments 227  
   periocular treatment 226  
   respiratory disease 235  
   skin disease 235  
   systemic treatment 224–5  
 inflammatory glaucoma 298–9  
 infliximab 226  
 injuries  
   anterior segment 61  
   blunt ocular 140, 141  
   chemical 60, 64–5  
   case-based discussion 69  
   closed 60  
   globe 141  
   open 60  
   globe 60–2, 141  
   penetrating 60, 140  
   perforating 60  
   see also trauma  
 interferon- $\alpha$  226  
 intermediate uveitis 198–9  
 intermittent esotropia 339  
   case-based discussion 352  
 internuclear ophthalmoplegia 388  
 interstitial keratitis see keratitis, interstitial  
 intracorneal lens 66  
 intracorneal ring segments 66  
   keratoconus 52  
 intracranial hypertension  
   case-based discussion 396  
   causes 376  
   idiopathic (benign) 376  
   obstructive sleep apnoea 235  
 intraepithelial neoplasia, conjunctival 26, 27  
 intraocular lenses see lenses, intraocular  
 intraocular mass lesions 112, 113  
 intraocular pressure  
   corneal thickness 283  
   glaucoma  
     inflammatory 298–9  
     laser therapy 312–13  
     normal-tension 294  
     pigmentary 300–1  
     primary angle closure 294  
     primary open-angle 291  
     pseudoxfoliative 300  
     steroid-induced 295  
     surgery 316–17  
     traumatic 296–7  
   hypertension 290  
   hypotensive agents 308–10  
   rise, as keratoplasty complication 56  
   tonometry 282  
 intraocular treatments, ocular inflammatory  
   disorders 227  
 intraretinal pathology, optical coherence  
   tomography 110  
 intravitreal anti-VEGF agents 160  
 intravitreal injection 227  
 inverse Knapp procedure 349  
 involutional ectropion 78  
 involutional entropion 76  
 involutional ptosis 80  
   case-based discussion 102  
 IOL Master 262, 263  
 loperidine 309  
 ipsilateral dermal melanocytosis 28  
 iridectomy  
   melanoma, iris 58  
   peripheral 317  
 iridocorneal/endothelial syndrome 306, 307  
 iridocyclotomy 58  
 iridocyclitis, Fuch's heterochromic 299  
 iridodialysis 61, 62  
 iridoplasty 313  
 iridotomy 313, 314  
 iris  
   anatomy 194, 195  
   bombé 292  
   melanoma 58, 59  
   naevi, benign 59  
   processes 284  
   progressive atrophy 306  
   slit lamp examination 6  
   sphincter damage 61  
   trauma 250, 251  
 iris naevus syndrome 306  
 iron deposition 42  
 ischaemia  
   anterior segment 350  
   limbal 64, 65  
   case-based discussion 69  
 ischaemic optic neuropathy, anterior see anterior  
   ischaemic optic neuropathy  
 ischaemic syndrome, ocular 232  
 Ishihara colour plates 363  
 ISNT rule 278  
 isolated neurofibroma 410  
 itchy eye 4
- J**  
 Jansen syndrome 136  
 Jarsch–Herxheimer reaction 212  
 jaw-winking syndrome 80, 81, 82  
 Jensen procedure 349  
 Jones dye tests 92, 93  
 judgement 426  
 juvenile idiopathic arthritis 220–1  
 juvenile X-linked retinoschisis 185  
 juxtafoveal retinal telangiectasia, idiopathic 180
- K**  
 Kaposi sarcoma 29, 90  
 Kay's pictures 328  
 Kayser–Fleischer ring see Fleischer ring  
 Kearns–Sayre syndrome  
   chronic progressive external ophthalmoplegia 395  
   retinitis pigmentosa 182  
 Keith–Wagner–Barker classification 162  
 keratectomy, phototherapeutic 30  
 keratitis  
   *Acanthamoeba* 34, 35  
   acute stromal 41  
   adenoviral 14, 15  
   herpes simplex 36–7  
   disciform 37  
   epithelial 36, 37  
   stromal 36  
   herpes zoster 38  
   case-based discussion 69  
   disciform 38  
   epithelial 38  
   nummular 38  
   stromal 38  
   infectious  
     bacterial 32–3, 69  
     fungal 34–5  
     protozoal 34, 35  
   viral; herpes simplex 36–7  
   viral; herpes zoster 38, 69  
   interstitial 39  
   Cogan's syndrome 39  
   herpes simplex 36  
   syphilitic 39  
   marginal 10  
   microbial 50  
   Mooren's ulcer 40, 41  
   mucus plaque 38  
   necrotizing stromal 36  
   nummular 38  
   peripheral ulcerative 40–1  
   with systemic immune-mediated disease 40, 41  
   rheumatoid arthritis 40–1  
   rosacea 10–11  
   sclerosing 41  
   sterile 50, 51  
   terrien marginal degeneration 41  
   Thygeson's superficial punctate 44, 45  
 keratoacanthoma 88, 89  
 keratoconjunctivitis  
   atopic 18–19  
   epidemic 14  
   factitious 20  
   superior limbic 20, 21  
   toxic 20  
   vernal 18, 19  
 keratoconjunctivitis sicca see dry eye disease  
 keratoconus 52, 53  
   associations 53  
   corneal topography 68  
   Fleischer ring 43  
   posterior 53  
 keratoconus keratometry 52  
 keratoglobus 53  
 keratometry, keratoconus 52  
 keratopathy  
   amniotic membrane transplantation 44–5
- band 30, 31  
   as complication of anterior uveitis 197  
 bullous 49  
   pseudophakic 254  
 climatic 30  
 conjunctival flaps 44  
 drug-induced 42–3  
 dry eye disease 12  
 epithelial defect, non-healing 44  
 exposure 44, 45  
 filamentary 12, 13  
 infectious crystalline 32, 33  
 keratoconjunctivitis, vernal 18  
 lipid 30  
 metabolic 42–3  
 neurotrophic 44, 45  
 vortex 42, 43  
 keratophakia 66  
 keratoplasty 54–5  
   complications 56–7  
   early postoperative 56  
   graft rejection 56–7  
   late postoperative 56  
   deep anterior lamellar 52  
   Descemet's stripping endothelial 55  
   hydrops, acute corneal 52  
   keratitis  
     *Acanthamoeba* 34  
     bacterial 33  
     fungal 34  
   keratoconus 52  
   keratoglobus 53  
   keratoprosthesis 55  
   lamellar 54–5  
     deep anterior 52, 54  
     keratoglobus 53  
     pellucid marginal degeneration 53  
   pellucid marginal degeneration 53  
   penetrating 54, 55  
   intraoperative management 54  
   keratoconus 52  
   postoperative management 54  
   preoperative considerations 54  
 keratoprosthesis 55  
   OCP 22  
 keratosis  
   actinic 88, 89  
   seborrhoeic 84, 86  
 keratotomy  
   arcuate 66  
   radial 66, 67  
 keratouveitis  
   herpes simplex virus 206  
   herpes zoster infection 38  
 Khodadoust line 56, 57  
 kinetic echography 112  
 kinetic perimetry 286  
 Kirkham's triad 343  
 Klippel–Feil syndrome 343  
 Knapp procedure 349  
 Knist dysplasia 136  
 Knobloch syndrome 136  
 Knudson's two-hit hypothesis 128  
 Koeppe lenses 284  
 Krinsky test 326
- L**  
 lacerations 60  
   corneo-scleral 60–1  
   eyelids 98, 99  
 lacrimal canaliculi 72  
 lacrimal duct obstruction 12  
 lacrimal gland  
   anatomy 400  
   disease 12  
   lesions 412  
   tumours 412, 413  
   case-based discussion 420  
 lacrimal puncta 72  
 lacrimal sac 72  
 lagophthalmos  
   ectropion, paralytic 78  
   exposure keratopathy 44  
   eyelid retraction 98, 99  
 $\lambda$  pattern 346  
 Lambert–Eaton myasthenic syndrome 394  
 lamellar cataract 256, 256  
 lamellar keratoplasty see keratoplasty, lamellar  
 laminar dot sign 278  
 Lang test 330  
 Langerhans cell histiocytosis 412  
 laser techniques

- capsulotomy, Nd:YAG 272–3  
 corneal ablation 66–7  
 demarcation, retinal detachment 118, 119  
 glaucoma therapy 312–14  
 LASIK 67  
 photocoagulation see photocoagulation, laser  
 polarimetry, scanning 279  
 retinopexy 114–15  
 trabeculoplasty 312, 314  
 lashes see eyelashes  
 LASIK 67  
 latanoprost 308  
 latent nystagmus 386  
 lateral geniculate nuclei  
 anatomy 356  
 lesions 370  
 lateral orbitotomy 418  
 lateral rectus 322  
 lateral tarsorrhaphy 98  
 lattice degeneration 122–3  
 lattice dystrophy 46–7  
 Laurence–Moon syndrome 182  
 laxity  
 horizontal canthal tendon 78  
 lateral canthal tendon 78  
 medial canthal tendon 78  
 Leber's hereditary optic neuropathy 373  
 Leber's miliary aneurysms 180  
 Lees screen 332, 333  
 lens exchange, refractive 66  
 lenses  
 anatomy 238, 239  
 dislocation 260–1  
 embryology 238, 239  
 contact see contact lenses  
 diagnostic 108–9  
 goniolenses 284, 285  
 intracorneal 66  
 intraocular 270–1  
 accommodation 270  
 anterior chamber 270, 271  
 biomaterial 270  
 design 270  
 multifocal 270  
 phakic 66, 270  
 posterior chamber 270  
 power calculations 262–4  
 presbyopia-correcting 270  
 intraocular implantation  
 acquired cataract 246, 249  
 biomaterial 259  
 congenital cataract 258, 259  
 contraindications 259  
 malposition 254, 255  
 site 270  
 multifocal 66  
 slit lamp examination 6  
 toric 66  
 lenticular refractive surgery 66  
 lentigo maligna 88  
 Lester–Jones tube insertion 94  
 leukaemia  
 posterior segment metastasis 135  
 as posterior uveitis masquerade syndrome 204  
 leukocoria 106  
 levator palpebrae superioris 72  
 levobulolol 308  
 lids see eyelids  
 light–near dissociation 391  
 light reflex pathway 357  
 limbal girdle of Vogt, white 30, 31  
 limbal guttering 40–1  
 limbal ischaemia 64, 65  
 case-based discussion 69  
 limbus 2  
 lipid keratopathy 30  
 lipid profile 234  
 lipodermoids 29  
 Lister perimeter 286  
 local anaesthesia 266–7  
 LogMAR chart 328–9  
 Lucentis 176  
 Lumigan 308, 310  
 Lyme disease 212  
 lymphangiectasia 24  
 lymphangioma 408–9  
 lymphoid hyperplasia 26  
 atypical 411  
 benign reactive 410–11  
 lymphoma  
 conjunctival 26, 27  
 Hodgkin's 204  
 malignant orbital 411  
 non-Hodgkin  
 conjunctival 26  
 as posterior uveitis masquerade syndrome 204  
 posterior segment metastasis 135  
 lymphoproliferative tumours 410–11
- M**  
 macroaneurysms 180, 181, 183  
 Macugen 176  
 macula lutea 104  
 macular  
 disease 363  
 dystrophies 47, 49, 184, 186  
 examination 107  
 fibrosis, preretinal see epiretinal membrane  
 focal and grid photocoagulation 114, 115  
 holes  
 full-thickness 124–5  
 lamellar 125  
 optical coherence tomography 110, 111  
 pucker see epiretinal membrane  
 surgery 124–5  
 macular degeneration  
 adult vitelliform 184, 185  
 age-related 170–4  
 anti-VEGF injections 176–7  
 dry (non-neovascular) 170–1, 190  
 retinal pigment epithelium 105  
 wet (neovascular) 172, 176–7, 190  
 macular oedema  
 cystoid  
 as complication of anterior uveitis 197  
 as complication of cataract surgery 254  
 as complication of intermediate uveitis 199  
 diabetic 227  
 dominant cystoid 184  
 maculopathy  
 cellophane see epiretinal membrane  
 diabetic 156, 158, 160, 161  
 madarosis 74, 75  
 Maddox rod 326  
 Maddox wing 326  
 magnetic resonance angiography 366, 367  
 magnetic resonance imaging 366–7  
 magnetic resonance venography 366  
 malignant glaucoma 304–5  
 malignant hypertension 162, 232, 233  
 malignant melanoma 90  
 malignant orbital lymphoma 411  
 malingering 393  
 mannitol 310  
 map-dot-fingerprint dystrophy see dystrophy,  
 epithelial basement membrane  
 Marcus Gunn jaw-winking syndrome 80, 81, 82  
 Marfan syndrome  
 lens dislocation 261  
 retinal detachment 136  
 marginal keratitis 10  
 masquerade syndromes, posterior uveitides 204  
 mature cataract 240, 242  
 mechanical ectropion 78  
 mechanical ptosis 80  
 medial ectropion 94  
 medial rectus 322  
 medical history  
 anterior segment disease 4  
 neuro-ophthalmology history taking 361  
 orbit 402  
 posterior segment 106  
 medical practice, good 424  
 Medical Royal Colleges 433  
 Medicines and Healthcare Products Regulatory  
 Agency 427  
 Meesmann dystrophy 46  
 meibomian glands 72  
 hordeola 84  
 melanocyte-associated neoplasia 28, 29  
 melanocytic lesions, benign 84–5  
 melanocytosis  
 dermal 84–5  
 ipsilateral dermal 28  
 ocular 28, 29, 132, 133  
 oculodermal 28  
 melanokeratosis 28  
 melanomas 28, 29  
 choroidal 133, 134, 135  
 case-based discussion 143  
 ultrasonography 112, 113  
 ciliary body 58–9  
 enucleation  
 ciliary body 59  
 iris 58  
 iris 58, 59  
 lentigo maligna 90  
 malignant 90  
 nodular 90  
 posterior segment metastasis 134  
 superficial spreading 90  
 melanosis  
 benign 28  
 congenital epithelial 28  
 primary acquired 28, 29  
 meningiomas 369, 410  
 Mental Health Act (1983) 429  
 Meretoja syndrome 47  
 meridional complexes 122  
 meridional folds 122  
 Merkel cell carcinoma 90  
 metabolic keratopathy 42–3  
 metastasis, posterior segment 134–5  
 metastatic tumours  
 as posterior uveitis masquerade  
 syndrome 204  
 neoplasia, conjunctival 29  
 orbit 412, 413  
 ultrasonography 112  
 methotrexate 225  
 methylprednisolone 226  
 microbial keratitis 50  
 microtropia 340  
 microvasculopathy, retinal 214  
 migraine 392  
 milia 84  
 Möbius syndrome 343  
 Moh's micrographic surgery  
 basal cell carcinoma 88  
 squamous cell carcinoma 90  
 Moll, cyst of see hidrocystoma, apocrine  
 Moll, glands of 72  
 molluscum contagiosum 16, 84, 86  
 Molteno tube 317  
 monofixation syndrome 340  
 Mooren's ulcer 40, 41  
 Morgagnian cataract 240  
 morning glory anomaly 378, 379  
 motor fusion 335  
 mucocoeles 412  
 mucopolysaccharidoses 42  
 mucormycosis 404  
 mucus fishing syndrome 20  
 mucus plaque keratitis 38  
 Müller cells  
 cone photoreceptors 105  
 neurosensory retina 104  
 Müller's muscle 72  
 resection 80  
 multifocal electroretinography 152, 154  
 multifocal lens 66  
 multiple evanescent white dot  
 syndrome 150, 203  
 multiple sclerosis  
 optic neuritis 372  
 uveitis 220, 221  
 Munson's sign 52, 53  
 Mustarde cheek-rotation flaps 88  
 myasthenia gravis 394  
 myasthenic incontinent strabismus 341  
 mycophenolate mofetil 225  
 myectomy 348  
 myogenic incontinent strabismus 341  
 myogenic ptosis 80  
 myopathic incontinent strabismus 341  
 myopathies, ocular 395  
 myopia  
 history taking 106  
 optic nerve head 276  
 refractive surgery 66  
 myopic anisometropia 352  
 myopic restrictive strabismus 342  
 myositis, orbital 406  
 myotomy 348  
 myotonic dystrophy 395
- N**  
 naevi  
 basal cell naevus syndrome 88  
 benign iris 59  
 choroidal 132, 133  
 eyelids 84–5  
 iris naevus syndrome 306  
 neoplasia, melanocyte-associated 28, 29  
 of Ota see melanocytosis, dermal  
 strawberry 85, 87  
 nasalization, optic nerve head 278

- nasolacrimal duct 72–3  
 anatomy 400  
 obstruction 96  
 nasolacrimal system  
 acquired abnormalities 94–5  
 anatomy 72–3  
 congenital obstruction 96, 97  
 physiology 73  
 naso-orbito-ethmoid fractures 416  
 National Health Service  
 economics 432  
 Foundation Trusts 432  
 structure 432  
 Trusts 432  
 National Patient Safety Agency 427  
 National Research Ethics Service 430  
 Nd:YAG laser capsulotomy 272–3  
 near acuity tests 329  
 near esotropia 339  
 near intermittent exotropia 340  
 near reflex pathway 357  
 necrosis  
 acute retinal 206–7  
 progressive outer retinal 206  
 HIV-related 215  
 necrotizing fasciitis 99  
 necrotizing stromal keratitis 36  
 neoplasia  
 choristomas, epibulbar 28–9  
 conjunctival 26–9  
 intraepithelial 26, 27  
 epithelial 26, 27  
 lymphoma 26, 27  
 melanocyte-associated 28, 29  
 metastatic tumours 29  
 vascular lesions 29  
 neovascular age-related macular degeneration 172, 176–7, 190  
 neovascular glaucoma 302–3  
 neovascularization  
 choroidal  
 submacular removal 126  
 wet age-related macular degeneration 172  
 corneal 50, 51  
 iris see rubeosis  
 retinal 107  
 as complication of intermediate uveitis 199  
 subretinal 107  
 neuralgia, post-herpetic 38  
 neuritis  
 optic 372  
 acute demyelinating 372  
 retrobulbar 372  
 neuroblastoma 412  
 neurofibroma  
 isolated 410  
 orbital 410  
 plexiform 410  
 neurogenic comitant strabismus 341  
 neurogenic ptosis 80  
 neuroimaging 366–7  
 neuromuscular junction disorders 394  
 neuro-ophthalmology  
 anisocoria, case-based discussion 397  
 chiasmal visual pathway disorders 368–9  
 congenital optic nerve disorders 378–9  
 cranial nerve anatomy 358–9  
 cranial nerve palsies 380–4  
 diplopia, sudden-onset: case-based discussion 396  
 examination 362–5  
 headache 392  
 case-based discussion 396  
 history taking 360–1  
 idiopathic intracranial hypertension 376–7  
 neuroimaging 366–7  
 neuromuscular junction disorders 394  
 non-organic visual loss 393  
 nystagmus 386–7  
 nystagmus, case-based discussion 397  
 ocular myopathies 395  
 optic nerve disorders 372–5  
 papilloedema 376, 377  
 pupil abnormalities 390–1  
 pupil reflex pathways 357  
 retinohypothalamic visual pathway disorders 370–1  
 supranuclear eye movement disorders 388–9  
 visual loss, acute: case-based discussion 396  
 visual pathway anatomy 356, 357  
 neuropathies, optic see optic neuropathies  
 neuroretinal rim  
 anatomy 276  
 assessment 278, 279, 280  
 width 278  
 neuroretinitis 372  
 neurosensory retina  
 anatomy 104  
 detachment see retinal detachment  
 embryology 104  
 physiology 105  
 neurotrophic keratopathy 44, 45  
 night blindness  
 case-based discussion 191  
 congenital stationary 182  
 nodular melanoma 90  
 non-arteritic anterior ischaemic optic neuropathy 374  
 non-Hodgkin's lymphoma  
 conjunctival 26  
 as posterior uveitis masquerade syndrome 204  
 non-infectious posterior uveitis 202–5  
 non-neovascular (dry) age-related macular degeneration 170–1, 190  
 non-organic visual loss 393  
 non-Sjögren syndrome, dry eye disease 12  
 non-specific intermittent exotropia 340  
 non-specific orbital inflammatory disease 406  
 normal-tension glaucoma 294  
 Norrie's disease 136  
 North Carolina macular dystrophy 184  
 notching, optic nerve head 278, 280  
 nuclear cataract 240, 241, 256  
 case-based discussion 274  
 nummular keratitis 38  
 nutritional optic neuropathy 373  
 nyctalopia 106  
 nystagmus 386–7  
 case-based discussion 397  
 congenital 386  
 downbeat 386  
 case-based discussion 397  
 end-point 386  
 examination 365  
 gaze-evoked 386  
 latent 386  
 management 387  
 periodic alternating 386  
 see-saw 386  
 upbeat 386  
 vestibular 386  
 visual acuity testing 328  
 nystagmus block esotropia 340
- O**  
 oblique muscles 322  
 overaction 344  
 obstructive sleep apnoea 235  
 occlusion  
 amblyopia 334  
 visual acuity testing 328  
 see also retinal artery occlusions; retinal vein occlusions  
 occult outer retinopathy, acute zonal 150  
 OCP 22, 23  
 Octopus perimeter 286  
 ocular deviation, assessment 325–6  
 ocular disease, cataract surgery 244  
 ocular flutter 388  
 ocular histoplasmosis, presumed 210  
 ocular history taking, posterior segment 106  
 ocular hypertension 290  
 ocular hypotension see hypotension, ocular  
 ocular hypotensive agents 308–10  
 ocular inflammatory disorders see inflammatory disorders, ocular  
 ocular ischaemic syndrome 232  
 ocular melanocytosis 28, 29  
 ocular myopathies 395  
 Ocular Response Analyser 282  
 ocular symptoms, history taking 106  
 oculoauriculovertebral dysplasia 28  
 oculodermal melanocytosis 28  
 oculomotility  
 alphabet patterns 346–7  
 amblyopia 334  
 assessment 325–7  
 binocular single vision 335  
 tests 330  
 central control 324  
 complex syndromes 343  
 extraocular muscles  
 action 322–3  
 anatomy 322  
 Hess charts 332–3  
 restrictive disorders 342  
 retinal correspondence and suppression tests 331  
 stereopsis 335  
 tests 330  
 strabismus see strabismus  
 supranuclear disorders 388–9  
 vertical deviations 344  
 visual acuity testing 328–9  
 oculomotor cranial nerve see third cranial nerve  
 oculoplastics  
 botulinum-toxin injections 98  
 chalazion 84  
 incision and curettage 84, 85  
 congenital abnormalities 96–7  
 dermatochalasis 98, 100  
 ectropion 78–9  
 entropion 76–7  
 epiphora 92–3  
 case-based discussion 102  
 evaluation 92  
 eyelash abnormality 74–5  
 eyelid anatomy 72, 73  
 eyelid imbrication syndrome 98  
 eyelid lesions  
 benign 84–7  
 malignant 88–91  
 premalignant 88, 89  
 eyelid lump, case-based discussion 102  
 eyelid retraction 98  
 eyelid swelling  
 allergic 98–9, 100  
 infectious 99, 100  
 eyelid trauma 98  
 floppy eyelid syndrome 98, 100  
 nasolacrimal system abnormalities, acquired 94–5  
 nasolacrimal system anatomy 72–3  
 probing 92  
 ptosis 80–1  
 case-based discussion 102  
 examination 82  
 syringing 92  
 tarsorrhaphy, lateral 98  
 oedema  
 acute allergic 99  
 dominant cystoid macular 184  
 macular see macular oedema  
 Oguchi's disease 182  
 onchocerciasis 209  
 one-and-a-half syndrome 388  
 opacification  
 anterior capsule 254, 255  
 corneal 64, 65  
 posterior capsule  
 as cataract surgery complication 254, 255, 258, 274  
 Nd:YAG laser capsulotomy 273  
 operating microscope 268, 269  
 ophthalmia, sympathetic 202  
 ophthalmia neonatorum  
 chlamydial 16  
 gonococcal 17  
 ophthalmic artery occlusion 169  
 ophthalmic history, orbit 402  
 Ophthalmic Registrars and Young Consultants  
 Learning the Essentials 433  
 Ophthalmic Specialist Training Curriculum 430  
 Ophthalmic Trainees' Group 433  
 ophthalmology, medical  
 cardiovascular diseases 232–3  
 endocrine diseases 234  
 episcleritis 222–3  
 HIV-related disease 214–15  
 intravitreal drug administration 227  
 ocular inflammatory disorders  
 biological agents 226  
 intraocular treatments of 227  
 periocular treatment of 226  
 systemic treatment of 224–5  
 orbital-floor drug administration 226  
 posterior sub-Tenon drug administration 226  
 respiratory diseases 235  
 rheumatological disease 228–9  
 scleritis 222–3  
 case-based discussion 236  
 skin diseases 235  
 uveal anatomy 194–5  
 uveitis  
 anterior 196–7  
 infectious, bacterial 212–13  
 infectious, fungal 210–11  
 infectious, parasitic 208–9  
 infectious, viral 206–7  
 intermediate 198–9  
 posterior 200–1



- posterior, non-infectious 202–5  
systemic associations 216–21  
vasculitis 230
- ophthalmoplegia  
chronic progressive external 395  
internuclear 388
- ophthalmoscopy  
binocular indirect  
fundus examination 108, 109  
score 198  
confocal scanning laser 279
- opsoclonus 388
- optic atrophy 377
- optic chiasm  
anatomy 356  
lesions 368
- optic cup 276
- optic disc see optic nerve head
- optic nerve  
anatomy 356  
assessment 363  
disease 363  
disorders 372–5  
congenital 378–9  
hypoplasia 378, 379  
imaging techniques 279
- optic nerve head (optic disc)  
anatomy 276  
assessment in glaucoma 278–80  
coloboma 378  
drusen 378, 379  
haemorrhage 278, 280  
nasalization 278  
pit 378
- optic neuritis 372
- optic neuropathies  
anterior ischaemic 374, 375  
case-based discussion 396  
non-arteritic 374  
compressive 373  
HIV-related 215  
Leber's hereditary 373  
nutritional 373  
toxic 373  
traumatic 373
- optic radiations  
anatomy 356  
lesions 370
- optic tracts  
anatomy 356  
lesions 370
- optical coherence tomography  
intraretinal pathology 110  
macular images 110, 111  
optic nerve imaging 279  
posterior segment 110–11  
principles and technology 110  
subretinal pathology 110  
vitreoretinal interface pathology 110
- optokinetic nystagmus 328
- optotype matching, visual acuity 328
- ora serrata
- pearls 122  
peripheral retinal abnormalities 122
- oral bays, enclosed 122
- orbicularis muscle 73
- orbit  
anatomy 400–1  
cellulitis 404, 405  
decompression 418  
examination 402–3  
fractures 416–17  
blowout 342  
orbital floor 353  
history taking 402  
infections 404–5  
inflammatory disease 406–7  
case-based discussion 420  
idiopathic/non-specific 406  
lymphoma, malignant 411  
meningiomas 410  
myositis 406  
neuroblastoma 412  
neurofibroma 410  
pain, case-based discussion 420  
proptosis, case-based discussions 240  
septum 72  
surgery 418–19  
thyroid eye disease 414–15  
trauma 416–17  
case-based discussion 420–1  
tumours 410–13  
vascular malformations 408–9
- orbital-floor injection 226
- orbital vein, thrombophlebitis of the 407
- orbito-zygomatic fractures 416, 417
- orbitotomy 418
- ORCYCLE 433
- osteoma, choroidal 132
- Ota, naevus of see melanocytosis, dermal
- outer retinal necrosis, progressive 206  
HIV-related 215
- outer retinopathy, acute zonal occult 150
- outflow obstruction 92
- ## P
- pachymetry 67, 283  
keratoconus 52
- pain, history taking  
anterior segment disease 4  
neuro-ophthalmology history taking 360  
posterior segment 106
- palisades of Vogt 2
- pallor, optic nerve head 278
- palpebral conjunctiva 2
- palsies  
cranial nerves 80, 380–4  
double elevator 344  
gaze 388, 389
- panretinal photocoagulation 114
- Panum's fusional area 335
- pan-uveitis 200
- papilla lacrimalis 72
- papillae  
cobblestone 18, 19  
conjunctiva 3
- papillitis 372
- papilloedema 376, 377  
respiratory disease 235
- papilloma  
conjunctival 26, 27  
squamous cell 84, 87
- paraffin sections, 88
- parafoveal zone 104
- paralytic ectropion 78
- paraneoplastic syndrome 131
- parasympathetic pupil reflex pathways 357
- Parinaud's dorsal midbrain syndrome 388
- Parinaud's oculoglandular syndrome 20
- Parks–Bielschowsky three step test 381
- Parliamentary and Health Service Ombudsman 425
- pars plana vitrectomy see vitrectomy, pars plana
- partially accommodative esotropia 338
- Pascal Dynamic Contour Tonometer 282
- patellar fossa 104
- patient safety 427  
communication 425
- pattern dystrophy 184, 186
- pattern electroretinography 152, 153
- pattern recognition, decision-making 426
- pavingstone degeneration, peripheral retina 122, 123
- pegaptanib sodium 176
- pellucid marginal degeneration 53
- pemphigoid, bullous 235
- penetrating keratoplasty see keratoplasty, penetrating
- Pentacam 262
- perennial allergic conjunctivitis 18
- peribulbar anaesthesia 266
- perifoveal zone 104
- perimetry 286–9  
frequency-doubling 288  
kinetic 286  
short-wavelength 288  
static 286–7
- periocular treatments, ocular inflammatory disorders 226
- periodic alternating nystagmus 386
- peripapillary atrophy 278, 280
- peripheral iridectomy 317
- peripheral iridoplasty, argon laser 313
- peripheral iridotomy 313, 314
- peripheral retinal tufts 122
- peripheral ulcerative keratitis 40–1  
with systemic immune-mediated disease 40, 41
- peripheral visual disturbance, history taking 106
- peristaltic pumps 268
- Perkins tonometry 282
- Peter's anomaly 307
- phaco wound, suture removal 55
- phacodynamics 268, 269
- phacoemulsification  
acquired cataract 246, 247–9  
foot-pedal control 268, 269  
handpiece 268
- phacomorphic glaucoma 292
- phakic intraocular lens 66
- pharyngoconjunctival fever 14
- phlyctenulosis 10
- photoaversion, history taking 106
- photocoagulation  
laser  
branch retinal vein occlusion 166  
central retinal vein occlusion 164  
diabetic retinopathy 160–1  
wet age-related macular degeneration 172
- macular focal and grid 114, 115
- panretinal 114
- retinal 114–15
- photodynamic therapy 172–3
- photophobia, history taking  
anterior segment disease 4  
posterior segment 106
- photopsia 106
- photoreceptors 105
- phototherapeutic keratectomy 30
- picture matching, visual acuity testing 328
- pigment dispersion syndrome 300
- pigmentary glaucoma 300–1
- pilocarpine 309
- pingueculae 24
- pingueculitis 24
- pituitary adenomas 368–9
- pituitary apoplexy 368
- pleomorphic adenoma 412, 413  
case-based discussion 420
- plexiform neurofibroma 410
- plica semilunaris 2
- pneumatic retinopathy 118
- pneumonia 235
- polarimetry, scanning laser 279
- poliosis 74
- polyarteritis, microscopic 230
- polyarteritis nodosa 230, 406–7
- polymorphous dystrophy, posterior 48
- polytrichosis 74
- port-wine stain 85
- Posner–Schlossman syndrome 299
- posterior blepharitis 8–9
- posterior capsule  
opacification  
as cataract surgery complication 254, 255, 258, 274  
Nd:YAG laser capsulotomy 273  
rupture 250, 251
- posterior cataract 256
- posterior keratoconus 53
- posterior polymorphous dystrophy 48
- posterior segment  
disease 229  
examination 106–7  
history taking 106  
metastasis 134–5  
syndrome 131
- ultrasonography see ultrasonography, posterior segment  
see also vitreoretinal surgery
- posterior synechiae 197
- posterior uveitis 200–1  
non-infectious 202–5
- posterior vitreous detachment 116
- Postgraduate Medical Education and Training Board 430
- post-herpetic neuralgia 38
- postoperative endophthalmitis 213
- cataract surgery 252–3, 274
- postseptal (orbital) cellulitis 404, 405
- precorneal tear film 2, 3
- slit lamp examination 6
- prednisolone  
glaucoma, steroid-induced 295  
ocular inflammatory disorders 224
- preferential looking 328, 393
- prematurity, retinopathy of 138–9
- ultrasonography 112
- preretinal macular fibrosis see epiretinal membrane
- presbyopia 238  
intraocular lens 270  
refractive surgery 66
- presenting complaints  
anterior segment disease 4  
neuro-ophthalmology 360–1  
orbit 402
- preseptal cellulitis 404, 405
- presumed ocular histoplasmosis 210
- primary acquired melanosis 28, 29
- primary angle closure 292
- Primary Care Trusts 432
- primary esotropia 338

primary exotropia 340  
 primary open-angle glaucoma 291  
   case-based discussion 318  
   central retinal vein occlusion 164  
 primary Sjögren syndrome 12  
 primary varices 408, 409  
 prism cover test 325  
 prism reflection test 326  
 prism shift test 393  
 prism tests  
   base-down 320  
   base-out 330, 338, 393  
 Private Finance Initiative 432  
 probing, epiphora 92  
 probity 424  
 professional skills and behaviour  
   appraisal 428  
   audit, clinical 428  
   bad news, breaking 425  
   child protection 431  
   clinical governance 427  
   communication 425  
   complaints, dealing with 425  
   confidentiality 429  
   consent 429  
   decision-making 426  
   education 430  
   good medical practice 424  
   judgement 426  
   NHS  
     economics 432  
     structure 432  
   Ophthalmic Trainees' Group 433  
   research 430  
   revalidation 428  
   safety of patients 427  
   training 430  
 progressive bifocal chorioretinal atrophy 184  
 progressive external ophthalmoplegia, chronic 395  
 progressive iris atrophy 306  
 progressive outer retinal necrosis 206  
   HIV-related 215  
 progressive supranuclear palsy 388  
 proliferative vitreoretinopathies 136  
   grading 120  
 ptosis  
   case-based discussions 420  
   exophthalmometry 402  
   thyroid eye disease 414, 415  
 prostaglandin analogues 308  
 pseudo-esotropia 338  
 pseudoexfoliation syndrome 300  
 pseudoexfoliative glaucoma 300, 301  
 pseudo-exotropia 340  
 pseudofluorescence 148  
 pseudophakic bullous keratopathy 254  
 pseudopterygia 24  
 pseudoptosis 80, 81  
 pseudotumour cerebri see intracranial hypertension  
 psoriatic arthritis 220  
 pterygia 24, 25  
   excision surgery 24  
 ptosis 80–1  
   aponeurotic 80, 81  
   case-based discussion 102  
   as contact lens wear complication 51  
   examination 82  
   eyelash 74, 75  
   involutional 80  
     case-based discussion 102  
   mechanical 80  
   myasthenia gravis 394  
   myogenic 80  
   myotonic dystrophy 395  
   neurogenic 80  
   surgery complications 80  
 Public Service Agreements 432  
 pulmonary disease, chronic obstructive 235  
 pulseless disease 230  
 punctal eversion 94  
 punctal stenosis 94  
 punctate keratitis, Thygeson's punctate 44, 45  
 punctoplasty 94  
 pupils  
   abnormalities 390–1  
     examination 364  
     reflex pathways 357  
   pursuit movements 324  
   disorders 389  
 Purtscher's retinopathy 140, 141  
 pyogenic granuloma 85, 87  
   neoplasia, conjunctival 29

## Q

quantitative echography 112  
 Quicker's sutures 76

## R

racemose haemangioma see arteriovenous malformations, retinal  
 radial keratotomy 66, 67  
 radiotherapy, basal cell carcinoma 88  
 ranibizumab 176  
 Rathke's pouch 368  
 reactive hyperplasia 26  
 reactive lymphoid hyperplasia, benign 410–11  
 recession, strabismus surgery 348  
 record-keeping 425  
 rectus muscles 322  
   strengthening procedures 349  
   transposition procedures 349  
   weakening procedures 348  
 recurrent corneal erosion syndrome 48–9  
 red eye  
   headache 361  
   history taking  
     anterior segment disease 4  
     posterior segment 106  
 Reese–Ellsworth classification, retinoblastomas 129  
 refraction, history taking 4  
 refractive error, post-cataract surgery 254  
 refractive surgery 66–8  
   classification and terminology 66  
   corneal 66  
   corneal pachymetry 67  
   corneal topography 67, 68  
   laser corneal ablation procedures 66–7  
   lenticular 66  
   preoperative evaluation 66  
 refsum disease 182  
 Reis–Bücklers dystrophy 46, 47  
 Reiter syndrome 220  
 relationship with patients 424, 425  
 relative afferent pupillary defects 390  
   assessment 364  
 research 430  
 resection, strabismus surgery 349  
 respiratory diseases 235  
 restrictive concomitant strabismus 341  
 restrictive strabismus 342  
 retina  
   age-related macular degeneration 170–4  
   anatomy 104  
   anti-VEGF injections, intravitreal 176–7  
   attachment 105  
   blood vessels 276  
   chorioretinopathy, central serous 178–9  
   circulation 105  
   correspondence, tests of 331  
   degenerative changes 122–3  
   developmental changes 122  
   diabetic retinopathy 155–61  
     case-based discussion 191  
   dystrophies  
     choroidal 188  
     retinal 182–6  
   electrophysiology 152–4  
   fundus fluorescein angiography 146–7  
     abnormal 148–9  
   hamartoma 130  
   hypertensive retinopathy 162–3  
   indocyanine angiography 150–1  
   macular lesion 191  
   microvasculopathy 214  
   neovascularization 107  
     as complication of intermediate uveitis 199  
   night vision difficulties 191  
   peripheral  
     abnormalities 122–3  
     examination 107  
   physiology 105  
   retinal artery occlusions 168–9  
   retinal vascular anomalies 180–1  
   retinal vein occlusions 164–7  
     suppression, tests of 331  
   tear, as complication of intermediate uveitis 199  
   tufts, peripheral 122  
   tumours 128–31  
   vascular anomalies 180–1  
   vascular tumours 130, 131  
   vasculature, examination 107  
   vasculitis 107, 204  
   vasoproliferative tumours 130  
   visual function 105  
 visual loss  
   central 190  
   in a child 191  
   gradual 190  
   in a hypertensive patient 190  
   sudden, painless 190–1  
 visualization 243, 244  
 retinal artery occlusions 168–9  
   branch 168–9  
   central 168, 169  
     case-based discussion 190–1  
   cilioretinal artery 169  
   ocular ischaemic syndrome 169  
   ophthalmic artery 169  
 retinal detachment 118–21  
   case-based discussions 142–3  
   collagen disorders associated with 136  
   as complication of cataract surgery 254  
   as complication of intermediate uveitis 199  
   degenerative retinoschisis 122  
   exudative 120  
     case-based discussion 143  
   lattice degeneration 122–3  
   optical coherence tomography 110, 111  
   rhegmatogenous 118–19, 122–3  
     case-based discussion 142  
   surgery, strabismus following 342  
   tractional 120, 121  
   ultrasonography 113  
 retinal dystrophies 182–6  
 retinal necrosis  
   acute 206–7  
   progressive outer 206  
     HIV-related 215  
 retinal nerve fibre layer  
   anatomy 276  
   assessment in glaucoma 278, 279, 280  
 retinal photocoagulation 114–15  
 retinal pigment epithelium  
   anatomy 104, 194  
   congenital hypertrophy of 130, 131  
   detachment see retinal detachment  
   embryology 104  
   fundus fluorescein angiography 148  
   hamartoma 130, 131  
   physiology 105  
   submacular reconstruction 126  
 retinal telangiectasia, idiopathic juxtafoveal 180  
 retinal vein occlusions 164–5  
   branch 166, 167  
     case-based discussion 190  
   central 164–5  
     ischaemic 164  
     non-ischaemic 164  
   classification 164  
   hemispheric 166  
 retinitis 206–7, 215  
   cytomegalovirus 206  
     HIV-related 214–15  
   retinitis pigmentosa 182  
     case-based discussion 191  
 retinitis punctata albescens 182  
 retinoblastomas 128–9  
   classification 129  
   ultrasonography 112  
 retinochoroiditis, *Toxoplasma* 208, 209  
   HIV-related 215  
 retinopathy  
   acute zonal occult outer 150  
   cancer-associated 131  
   diabetic 156–61  
     case-based discussion 191  
   cataract surgery 243, 244  
   non-proliferative 156, 157, 160, 161  
   proliferative 156, 160  
   stages 156  
   trials 161  
   hypertensive 162–3  
     case-based discussion 190  
   of prematurity 138–9  
   ultrasonography 112  
 Purtscher's 140, 141  
 retinopathy  
   laser 114–15  
   pneumatic 118  
 retinoschisis  
   degenerative 122, 123  
   hereditary 136–7  
   juvenile X-linked 185  
 retinotomy  
   choroidal neovascularization removal 126  
   submacular haemorrhage 126  
 retractor dehiscence 78

- retrobulbar anesthesia 266
- retrobulbar neuritis 372
- retrochiasmal visual pathway disorders 370–1
- retroillumination, slit lamp technique 5, 7
- revalidation 428
- rhabdomyosarcoma 410
  - case-based discussion 420
- rheumatoid arthritis 228–9
  - keratitis 40–1
- rheumatological disease 228–9
- riboflavin corneal collagen cross linkage 52
- Riddoch's phenomenon 370
- ring segments, intracorneal 66
  - keratoconus 52
- rituximab 226
- rod-cone dystrophy 182
- rod photoreceptors 105
- rosacea keratitis 10–11
- rose bengal 7
- rotation testing, visual acuity 328
- Roth spots 212
- rubeosis
  - central retinal vein occlusion 164
  - diabetic retinopathy 160
  - glaucoma, neovascular 302
- ruptures 60
- S**
- saccades 324
  - assessment 327
  - disorders 388
- safety of patients 427
  - communication 425
- Salzmann nodular degeneration 31
- Sampaolesi line 284
- Sanfilippo syndrome 42
- sarcoidosis
  - respiratory disease 235
  - uveitis 216, 217–18
- sarcoma, granulocytic 412
- sauzerization, optic nerve head 278
- Sbiza bar 331
- scanning laser polarimetry 279
- Scheie classification 162
- Scheie syndrome 42
- Schirmer tests 12
- Schlemm's canal 284
- Schnyder crystalline dystrophy 47
- Schwalbe's line 284
- scintigraphy 92
- sclera, examination 6, 107
- scleral buckling 119
- scleral spur 284
- sclectomy 317
- scleritis 229
  - case-based discussion 236
- scleritis 222–3
- sclerokeratitis 38
- scleromalacia 222
- scleromalacia perforans 229
- sclerosing keratitis 41
- sclerosis, nuclear see cataract, nuclear
- sclerotic scatter, slit lamp technique 5, 7
- sclerouvectomy 59
- scotomas
  - fortification 392
  - neuro-ophthalmology history taking 360
- Scott procedure 348
- screening 128
- seasonal allergic conjunctivitis 18
- sebaceous cysts 84
- sebaceous gland carcinoma 90, 91
- seborrhoeic keratosis 84, 86
- secondary angle closure 292
- secondary esotropia 339
- secondary exotropia 340
- secondary glaucoma
  - as complication of anterior uveitis 197
  - open-angle 298
- secondary Sjögren syndrome 12
- see-saw nystagmus 386
- Seidel's test 7
- selective laser trabeculoplasty 312, 314
- sensory esotropia 339
- sensory fusion 335
- septum, orbital 72
- seronegative arthritides 229
  - uveitis 220
- serous chorioretinopathy, central 178–9
- Shaffer grading system 285
- shagreen, corneal 30, 31
- shaken-baby syndrome 140
- Sheridan–Gardner test 328
- Sherrington's law of reciprocal innervation 323
  - saccades 324
- shield ulcers 18, 19
- short-wavelength perimetry 288
- Sidaway case 429
- siderosis
  - and chalcosis, comparison between 141
  - keratopathy 42
- sinus invasion, orbital tumours 412
- sinus mucocoeles 412
- SITA Fast 286
- SITA Standard 286
- sixth cranial nerve
  - anatomy 358, 359
  - palsies 382, 384
- Sjögren syndrome
  - dry eye disease 12
  - rheumatoid arthritis 229
- skew deviations 388
- skin diseases 235
- sleep apnoea 235
- slit lamp techniques
  - anterior segment examination 5–7
  - fundus examination 108, 109
- Snellen chart 328, 329
- snowflake vitreoretinal degeneration 136
- social history
  - anterior segment disease 4
  - neuro-ophthalmology history taking 361
  - posterior segment 106
- sore eye, history taking 4
- Sorsby's macular dystrophy 184, 186
- spasmus mutans 386
- spastic entropion, acute 76
- Special Health Authorities 432
- specular reflection, slit lamp technique 5, 7
- spiral of Tillaux 322, 323
- spondyloepiphyseal dysplasia 136
- squamous cell carcinoma
  - Bowen disease 88
  - conjunctival 26
  - eyelids 88, 90
- squamous cell papilloma 84, 87
- square-wave jerks 388
- squint see strabismus
- staphylococcal anterior blepharitis 8, 9
- staphylococcal hypersensitivity disorders 10–11
- staphylococcal hypersensitivity syndrome 10
- Staphylococcus aureus* 16
- Stargardt's disease 183, 185
  - case-based discussion 191
- static perimetry 286–7
- stationary night blindness, congenital 182
- stenosis, punctal 94
- stereogram tests, random-dot 330
- stereophotography, colour 279
- stereopsis 335
  - tests 330
- stereoscopic tests 393
- sterile keratitis 50, 51
- steroids see corticosteroids
- Stevens–Johnson syndrome 22–3, 235
- Stickler's syndrome 136
- stimulus deprivation amblyopia 334
- Stocker's line 24
- strabismic amblyopia 334
- strabismus
  - alphabet patterns 346–7
  - assessment 325–7
  - binocular single vision abnormalities 335
  - case-based discussions 352–3
  - complex 343
  - concomitant
    - esotropias 338–9, 352
    - exotropias 340
    - heterophorias 336
  - following retinal detachment surgery 342
  - incomitant 341
  - myogenic incomitant 341
  - myopathic incomitant 341
  - myopic restrictive 342
  - neurogenic incomitant 341
  - procedures 351
  - surgery 348–50
  - restrictive 342
  - surgery 342
  - surgery
    - complications 350
    - indications 348
    - types 348–9
  - vertical deviations 344
- strabismus fixus 343
- Strategic Health Authorities 432
- strengthening procedures, strabismus surgery 349
- striate melanokeratosis 28
- stroma
  - histology 2, 3
  - slit lamp examination 6
- stromal dystrophy 46–7
- stromal keratitis
  - acute 41
  - necrotizing 36
- Sturge–Weber syndrome
  - choroidal haemangioma, diffuse 132
  - port-wine stain 85
- stye 84
- subcapsular cataract 240, 241
- subconjunctival haemorrhage 61, 62
- submacular
  - haemorrhage 126
  - surgery 126
- subretinal neovascularization 107
- subretinal pathology, optical coherence tomography 110, 111
- subtarsal foreign bodies 62
- sub-Tenon injection 226
  - cataract surgery 266, 267
- sudden-onset constant esotropia 340
- superficial corneal irregularities 50
- superficial punctate keratitis, Thygeson's 44, 45
- superior colliculus 324
- superior limbic conjunctivitis 20, 21
- superior limbic keratoconjunctivitis 20, 21
- superior oblique 322
  - overaction 344
- superior rectus 322
- superior tarsal muscle see Müller's muscle
- suppression
  - area and depth of 331
  - binocular single vision abnormalities 335
- suprachoroidal haemorrhage
  - as cataract surgery complication 250
- ultrasonography 112
- suprathreshold testing, perimetry 286
- surgical trauma, cataract surgery 250, 251
- sutures
  - compression 66
  - corneal
    - infiltrates 56
    - keratoplasty, penetrating 54
    - removal 55
  - entropion, involutional 76
  - eyelid-margin lacerations 98, 99
  - Quickert's 76
- Swan–Jacob lenses 284
- swinging flashlight test 364
- symphepharon 22, 23
- sympathetic ophthalmia 202
- sympathetic pupil reflex pathway 357
- synechia, posterior 197
- synergists, extraocular muscles 322
- synoptophore 326, 331
- syphilis 212, 213
- syringing 92
- systemic carbonic anhydrase inhibitors 310
- systemic hypertension 232, 233
- systemic lupus erythematosus 228, 407
- systemic treatments
  - history taking 5
  - ocular inflammatory disorders 226
- systems enquiry
  - neuro-ophthalmology 361
  - posterior segment 106
- T**
- tacrolimus 224–5
- Takayasu's vasculitis 230
- tarsorrhaphy, lateral 98
- tear break-up time 12
- tear film 2, 3
  - slit lamp examination 6
- tears
  - aqueous tear deficiency 12
  - artificial 12
  - evaporative tear dysfunction 12
  - hyperlacrimation 92
- telangiectasias, retinal 180, 181
- Teller cards 328
- temporal artery biopsy 375
- tenotomy 348
- tension test 394
- Tenzel flap 88
- terrien marginal degeneration 41
- Terson syndrome 140

Theil-Behnke dystrophy 46  
 thermocoagulation, corneal 66  
 thermokeratoplasty 66  
 third cranial nerve  
   anatomy 358, 359  
   palsies 80, 380, 383  
     case-based discussion 396  
 threshold testing, perimetry 286  
 thrombophlebitis of the orbital vein 407  
 Thygeson's superficial punctate keratitis 44, 45  
 thyroid eye disease (thyroid ophthalmopathy) 234, 342, 414–15  
 Tillaux, spiral of 322, 323  
 tilted disc syndrome, congenital 378, 379  
 timolol LA 308, 310  
 timolol maleate 308  
 Timoptol 308  
 titmus test 330  
 TNO test 330  
 Tolosa Hunt syndrome 406  
 tonic pupil 391  
 tonometry 282  
 Tono-Pen 282  
 topical anaesthesia 266  
   abuse 20  
 topical carbonic anhydrase inhibitors 310  
 topical-intracameral anaesthesia 266  
 topical medications, history taking 5  
 topography  
   corneal 67, 68  
   posterior segment ultrasound 112  
 toric lens 66  
 toxic keratoconjunctivitis 20  
 toxic optic neuropathy 373  
 toxocariasis 208–9  
*Toxoplasma* retinochoroiditis 208, 209  
   HIV-related 215  
 trabeculectomy 316–17  
 trabeculitis 38  
 trabeculoplasty 312, 314  
 trabeculum 284  
 trachoma 16, 17  
 training 430  
 transillumination, slit lamp technique 7  
 transposition procedures, strabismus surgery 349  
 trapdoor blow-out fractures 416  
   case-based discussion 421  
 trauma  
   anterior segment 60–2  
   blunt ocular 296  
   cornea 250  
   eyelids 98  
   history taking 4  
   iris 250, 251  
   open globe injury 60–2  
   optic neuropathy 373  
   orbit 416–17  
     case-based discussions 420–1  
   posterior segment 140  
   surgical 250, 251  
   systemic 140  
   ultrasonography 112  
   see also injuries  
 traumatic glaucoma 296–7  
 traumatic hyphaema 296  
 Travatan 308, 310  
 travoprost 308  
 Treacher Collins syndrome 96  
 triamcinolone 176–7, 226, 227  
 trichiasis 74, 75  
 trichomegaly 74  
 trochlear cranial nerve see fourth cranial nerve  
 Trospopt 309  
 tuberculosis  
   respiratory disease 235  
   uveitis 212, 213  
 tucking, strabismus surgery 349  
 tufts, peripheral retinal 122  
 tumours  
   choroidal 132–5  
   hamartoma of the retinal pigment epithelium and retina 130, 131  
   orbital 410–13  
   retinal 128–31  
   vascular 130, 131  
   vasoproliferative 130

## U

ulcerative keratitis, peripheral 40–1  
 with systemic immune-mediated disease 40, 41

ultrasonography  
 pachymetry 283  
 posterior segment 112–13  
   indications 112  
   intraocular mass lesions 112, 113  
   ocular trauma and suprachoroidal haemorrhage 112, 113  
   principles and technology 112  
   technique 112  
   vitreous haemorrhage 112, 113  
 see also A-scan ultrasonography; B-scan ultrasonography; duplex-scan ultrasonography; immersion ultrasonography  
 upbeat nystagmus 386  
 Usher syndrome 182  
 uvea  
   anatomy 194–5  
   immunology 194  
   tumours, anterior 58–9  
 uveitis  
   anterior 196–7  
   Fuch's uveitis syndrome 299  
   herpes zoster 206, 207  
   immune recovery 215  
   infectious  
     bacterial 212–13  
     fungal 210–11  
     parasitic 208–9  
     viral 206–7  
   intermediate 198–9  
   non-infectious posterior 202–5  
   post-cataract surgery 258  
   posterior 200–1  
   systemic associations 216–21  
   triamcinolone, intravitreal 227

## V

V pattern 346, 347  
 valvular disease 233  
 van Herick's technique 285  
 varices, primary 408, 409  
 vascular endothelial growth factor 176  
 anti-VEGF injections, intravitreal 160, 176–7  
 vascular lesions  
   benign 85  
   neoplasia, conjunctival 29  
 vasculitis 230, 406–7  
   retinal 107, 204  
 vasculopathy 180  
 vasculoretinopathies, hereditary 136  
 Venturi pumps 268  
 vergences 323, 324  
   assessment 327  
 vernal keratoconjunctivitis see keratoconjunctivitis, vernal  
 versions 323  
   assessment 327  
 verteporfin 172–3  
 vertical deviations 344  
 vertical gaze palsies 388, 389  
 vestibular eye movements 324  
 vestibular nystagmus 386  
 viral retinitis 206–7, 215  
 viral warts (squamous cell papilloma) 84  
 viscocanalostomy 317  
 visual acuity testing 328–9  
 visual cortex  
   anatomy 356  
   lesions 370  
 visual disturbance  
   blurred vision 4  
   central 106  
   neuro-ophthalmology history taking 360  
   peripheral 106  
   see also visual loss  
 visual-evoked potentials 153, 154  
 visual field 286  
   defects  
     glaucoma 288–9  
     optic nerve disorders 363  
   evaluation see perimetry  
   examination 362  
 visual function, examination 106–7  
 visual loss  
   acute 396  
   central 190  
   in a child 191, 360  
   gradual 190  
   in a hypertensive patient 190  
   neuro-ophthalmology history taking 360

non-organic 393  
 sudden, painless 190–1  
 visual pathway  
   anatomy 356, 357  
   chiasmal disorders 368–9  
   retrochiasmal disorders 370–1  
 vitelliform macular degeneration 184, 185  
 vitrectomy, pars plana  
   choroidal neovascularization removal 126  
   diabetic retinopathy 160, 161  
   retinal detachment 119  
   submacular haemorrhage 126  
 vitreomacular traction syndrome 124, 125  
 vitreoretinal degeneration, snowflake 136  
 vitreoretinal interface pathology 110  
 vitreoretinal surgery  
   choroidal tumours 132–5  
   diagnostic lenses 108–9  
   elevated fundal mass, case-based discussion 142–3  
   macular surgery 124–5  
   optical coherence tomography 110–11  
   peripheral retinal abnormalities 122–3  
   photocoagulation, retinal 114–15  
   posterior segment  
     history taking and examination 106–7  
     trauma 140–1  
   retinal anatomy and physiology 104–5  
   retinal detachment 118–21  
     case-based discussion 142  
   retinal tumours 128–31  
   retinopathy of prematurity 138–9  
   submacular surgery 126  
   ultrasonography 112–13  
   vitreoretinopathies 136–7  
   vitreous disorders 116–17  
 vitreoretinopathies 136–7  
   familial exudative 136  
   hereditary 136  
   proliferative 136  
   grading 120  
 vitreous  
   anatomy 104  
   detachment, posterior 116  
   disorders 116–17  
   examination 107  
   haemorrhage 117  
     as complication of intermediate uveitis 199  
     diabetic retinopathy 160  
     ultrasonography 112, 113  
   pathological processes 116  
 vitritis 198  
 Vogt's striae 52  
 Vogt-Koyanagi-Harada syndrome 202, 203  
 von Hippel-Lindau syndrome 130, 131  
 vortex keratopathy 42, 43  
 Vot-Koyanagi-Harada syndrome 150

## W

Wagner syndrome 136  
 warfarin 244  
 warts, viral (squamous cell papilloma) 84  
 watery eye, history taking 4  
 Watzke-Allen test 124  
 weakening procedures, strabismus surgery 348  
 WEBINO syndrome 388  
 Wegener's granulomatosis 230, 406  
   case-based discussion 236  
   respiratory disease 235  
 Weil-Marchesani syndrome 136  
 Weiss ring 116, 117  
 wet (neovascular) age-related macular degeneration 172, 176–7, 190  
 white-dot syndromes 202–3  
   multiple evanescent 150, 203  
 white eye 361  
   blow-out fractures 416  
 white limbal girdle of Vogt 30, 31  
 Wilderwank syndrome 343  
 Wilson's disease 42  
 Wirt Fly test 330  
 worst-case scenarios, decision-making 426  
 Worth's four-dot test 331  
 wound leak, as keratoplasty complication 56  
 Wyburn-Mason syndrome 130

## X

X-linked retinoschisis, juvenile 185

X pattern 346  
X-rays, open globe injury 60  
xalacom 310  
Xalatan 308, 310  
xanthelasma 84, 86  
xeroderma pigmentosum 88

## Y

Y pattern 346  
yoke muscles, extraocular 322

## Z

Zeis, cysts of 84  
Zeis, glands of 72  
  stye 84  
Zeiss lenses 284  
Zinn, annulus of 322  
zonal occult outer retinopathy,  
  acute 150  
zonular dehiscence 250  
zygomatic fractures 416, 417