

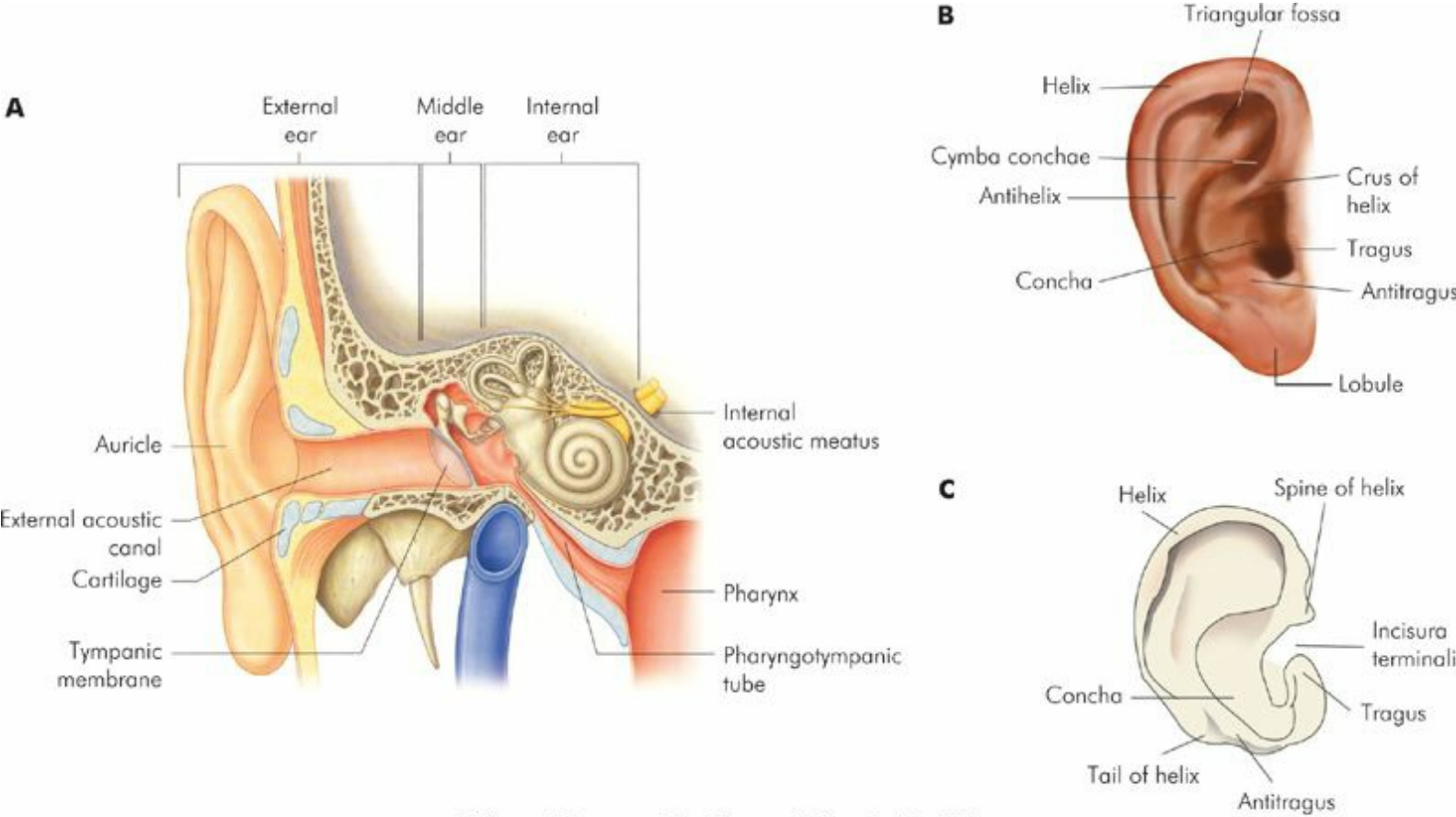
# 1 Anatomy of Ear

The ear is divided into:

- 1. External ear
- 2. Middle ear
- 3. Internal ear or the labyrinth.

# THE EXTERNAL EAR

The external ear consists of the (i) auricle or pinna, (ii) external acoustic canal and (iii) the tympanic membrane (Fig. 1.1A).



Dhingra: Diseases of Ear Nose and Throat, 5th Edition  
Copyright © 2010 Elsevier. All rights reserved.

Figure 1.1 (A) The ear and its divisions. (B) The elevations and depressions on the lateral surface of pinna. (C) The auricular cartilage.

# 1. Auricle or Pinna

The entire pinna, except its lobule, and the outer part of external acoustic canal are made up of a framework of a single piece of yellow elastic cartilage covered with skin. The latter is closely adherent to the perichondrium on its lateral surface while it is slightly loose on the medial surface. The various elevations and depressions seen on the lateral surface of pinna are shown in Fig. 1.1B.

page 3

page 4

There is no cartilage between the tragus and crus of the helix, and this area is called the *incisura terminalis* (Fig. 1.1C). An incision made in this area will not cut through the cartilage and is used for endaural approach in surgery of the external auditory canal or the mastoid (see page 410). Pinna is also the source of several graft materials for the surgeon. Cartilage from the tragus, perichondrium from the tragus or concha, and fat from the lobule are frequently used for reconstructive surgery of the middle ear. The conchal cartilage has also been used to correct the depressed nasal bridge while the composite grafts of the skin and cartilage from the pinna are sometimes used for repair of defects of nasal ala.

## 2. External Acoustic (Auditory) Canal

It extends from the bottom of the concha to the tympanic membrane and measures about 24 mm along its posterior wall. It is not a straight tube; its outer part is directed upwards, backwards and medially while its inner part is directed downwards, forwards and medially. Therefore, to see the tympanic membrane, the pinna has to be pulled upwards, backwards and laterally so as to bring the two parts in alignment.

The canal is divided into two parts: (a) cartilaginous and (b) bony.

### (a) Cartilaginous Part

It forms outer one-third (8 mm) of the canal. Cartilage is a continuation of the cartilage which forms the framework of the pinna. It has two deficiencies-the "*fissures of Santorini*" in this part of the cartilage and through them the parotid or superficial mastoid infections can appear in the canal, or vice versa. The skin, covering the cartilaginous canal is thick and contains ceruminous and pilosebaceous glands which secrete wax. Hair is only confined to the outer canal and therefore furuncles (staphylococcal infection of hair follicles) are seen only in the outer one third of the canal.

### (b) Bony Part

It forms inner two-thirds (16 mm). Skin lining the bony canal is thin and continuous over the tympanic membrane. It is devoid of hair and ceruminous glands. About 6 mm lateral to tympanic membrane, the bony meatus presents a narrowing called the *isthmus*. Foreign bodies lodged medial to the isthmus, get impacted, and are difficult to remove. Antero-inferior part of the deep meatus, beyond the isthmus, presents a recess called the *anterior recess* which acts as a cesspool for discharge and debris in cases of external and middle ear infections. Antero-inferior part of the bony canal may present a deficiency (*foramen of Huschke*) in children up to the age of four or sometimes in adults, permitting infections to and from the parotid.

### 3. Tympanic Membrane or the Drumhead

It forms the partition between the external acoustic canal and the middle ear. It is obliquely set and as a result, its posterosuperior part is more lateral than its antero-inferior part. It is 9-10 mm tall, 8-9 mm wide and 0.1 mm thick. Tympanic membrane can be divided into two parts:

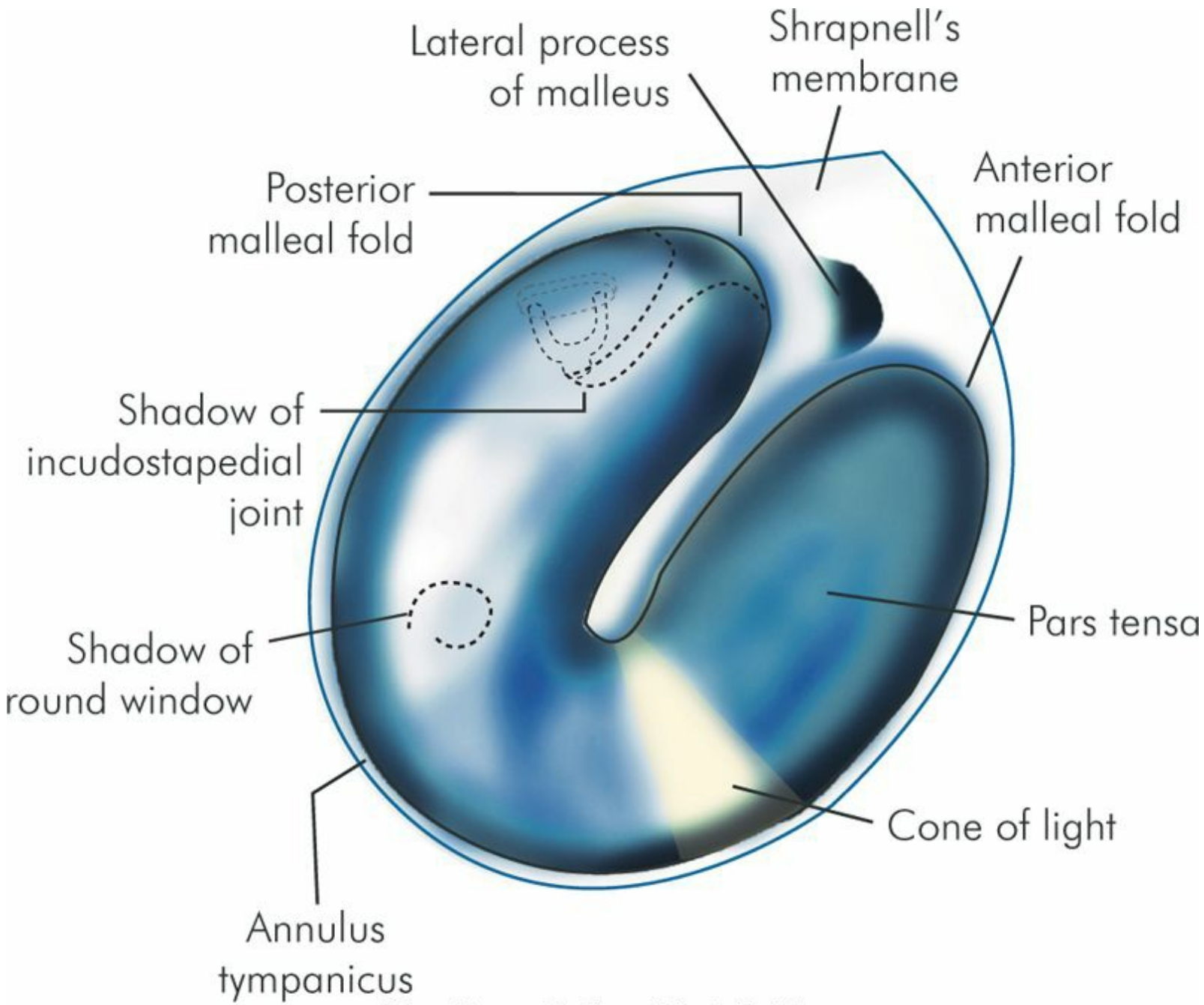
#### (a) Pars Tensa

It forms most of tympanic membrane. Its periphery is thickened to form a fibrocartilaginous ring called the *annulus tympanicus* which fits in the tympanic sulcus. The central part of pars tensa is tented inwards at the level of the tip of malleus and is called the *umbo*. A bright cone of light can be seen radiating from the tip of malleus to the periphery in the anteroinferior quadrant (Fig. 1.2).

#### (b) Pars Flaccida (Shrapnel's Membrane)

This is situated above the lateral process of malleus between the notch of Rivinus and the anterior and posterior malleal folds (earlier called the malleolar folds). It is not so taut and may appear slightly pinkish. Various landmarks seen on the lateral surface of tympanic membrane are shown in Fig. 1.2.

#### Layers of Tympanic Membrane



Dhingra: Diseases of Ear Nose and Throat, 5th Edition  
Copyright © 2010 Elsevier. All rights reserved.

Figure 1.2 Landmarks of a normal tympanic membrane of right side.

Tympanic membrane consists of three layers:

- **(i)** Outer epithelial layer, which is continuous with the skin lining the meatus.
- **(ii)** Inner mucosal layer, which is continuous with the mucosa of the middle ear.
- **(iii)** Middle fibrous layer, which encloses the handle of malleus and has three types of fibres-the radial, circular and the parabolic.

Fibrous layer in the para flaccida is thin and not organised into various fibres as in pars tensa.

## Relations of External Acoustic Meatus

- Superiorly: Middle cranial fossa
- Posteriorly: Mastoid air cells and the facial nerve
- Inferiorly: Parotid gland
- Anteriorly: Temporomandibular joint

Posterosuperior part of deeper canal near the tympanic membrane is related to the mastoid antrum. "Sagging" of this area may be noticed in acute mastoiditis (see page 86).

# Nerve Supply of the External Ear

## Pinna

- (i) Greater auricular nerve ( $C_{2,3}$ ) supplies most of the medial surface of pinna and only posterior part of the lateral surface (Fig. 1.3).
- (ii) Lesser occipital ( $C_2$ ) supplies upper part of medial surface.
- (iii) Auriculotemporal ( $V_3$ ) supplies tragus, crus of helix and the adjacent part of the helix.
- (iv) Auricular branch of vagus (CN X), also called Arnold's nerve, supplies the concha and corresponding eminence on the medial surface.
- (v) Facial nerve, which is distributed with fibres of auricular branch of vagus, supplies the concha and retroauricular groove.

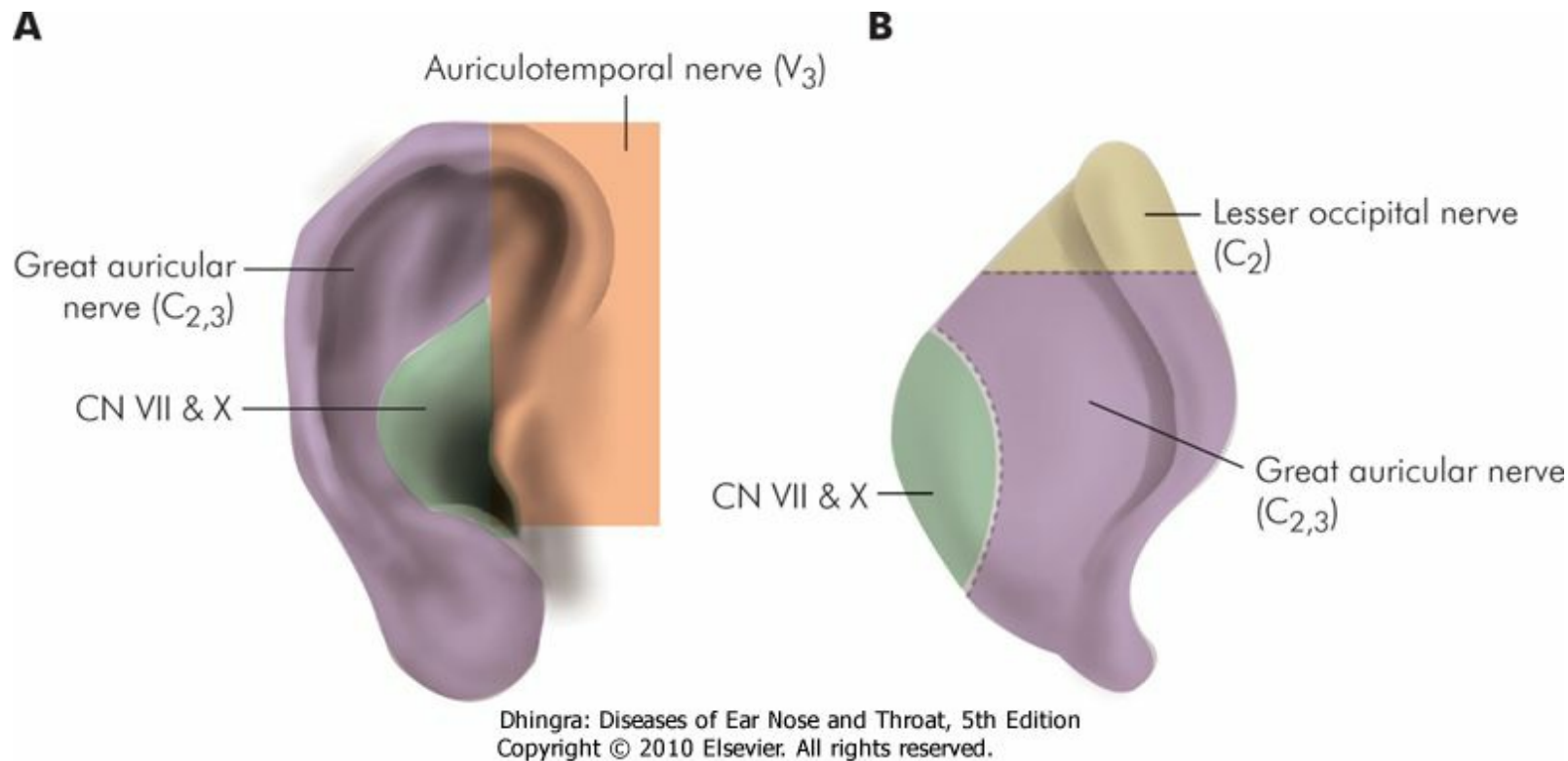


Figure 1.3 Nerve supply of pinna. (A) Lateral surface of pinna. (B) Medial or cranial surface of pinna.

## External Auditory Canal

- (i) Anterior wall and roof: auriculotemporal ( $V_3$ ).
- (ii) Posterior wall and floor: auricular branch of vagus (CN X).
- (iii) Posterior wall of the auditory canal also receives sensory fibres of CN VII through auricular branch of vagus (see Hitzelberger sign on page 124).

## Tympanic Membrane

- (i) Anterior half of lateral surface: auriculotemporal ( $V_3$ ).
- (ii) Posterior half of lateral surface: auricular branch of vagus (CN X).
- (iii) Medial surface: Tympanic branch of CN IX (Jacobson's nerve).



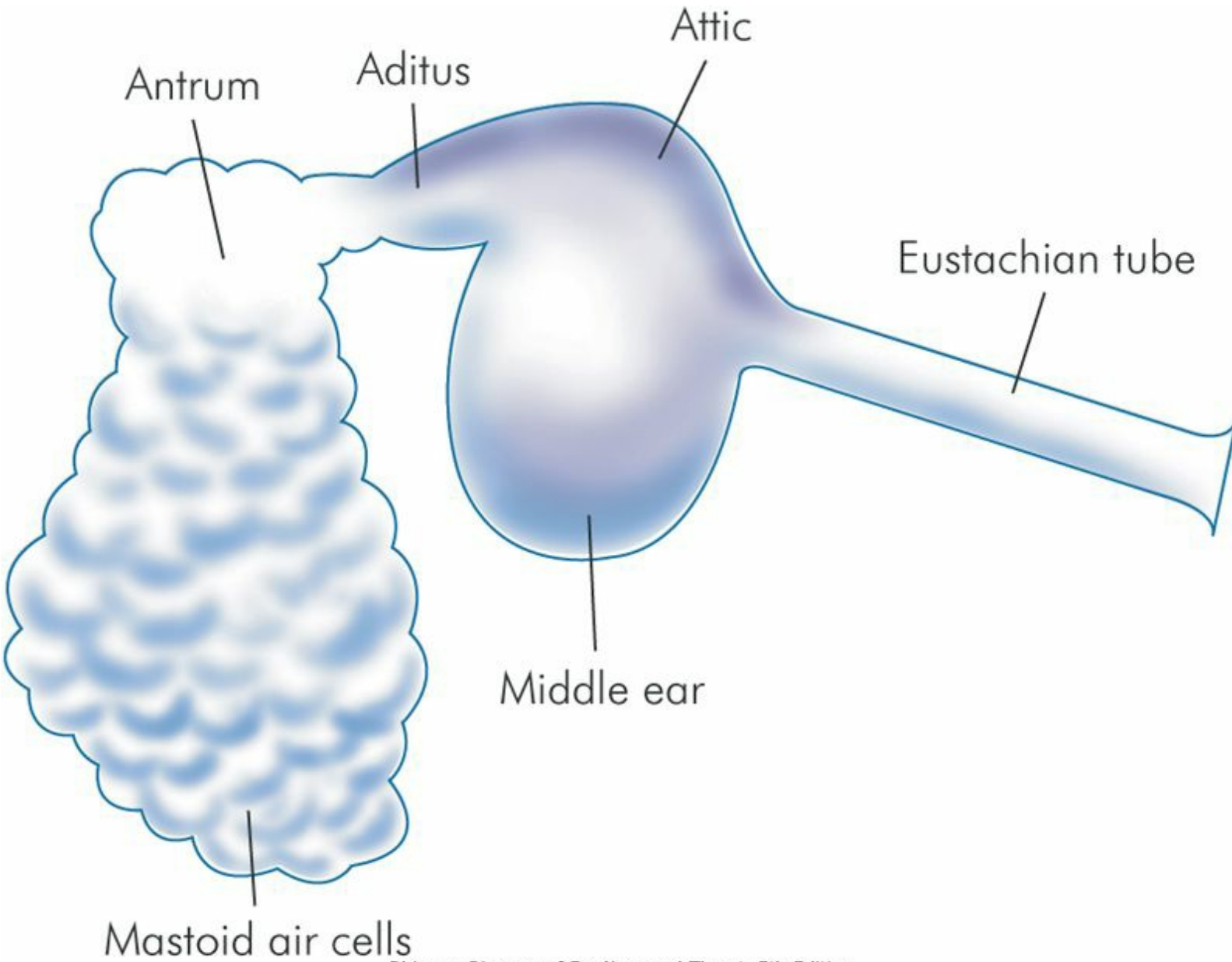
# THE MIDDLE EAR

The middle ear together with the eustachian tube, aditus, antrum and mastoid air cells is called the *middle ear cleft* (Fig. 1.4). It is lined by mucous membrane and filled with air.

The middle ear extends much beyond the limits of tympanic membrane which forms its lateral boundary and is sometimes divided into (i) *mesotympanum* (lying opposite the pars tensa), (ii) *epitympanum* or the attic (lying above the pars tensa but medial to Shrapnell's membrane and the bony lateral attic wall), (iii) *hypotympanum* (lying below the level of pars tensa) (Fig. 1.5). The portion of middle ear around the tympanic orifice of the eustachian tube is sometimes called the *protympanum*.

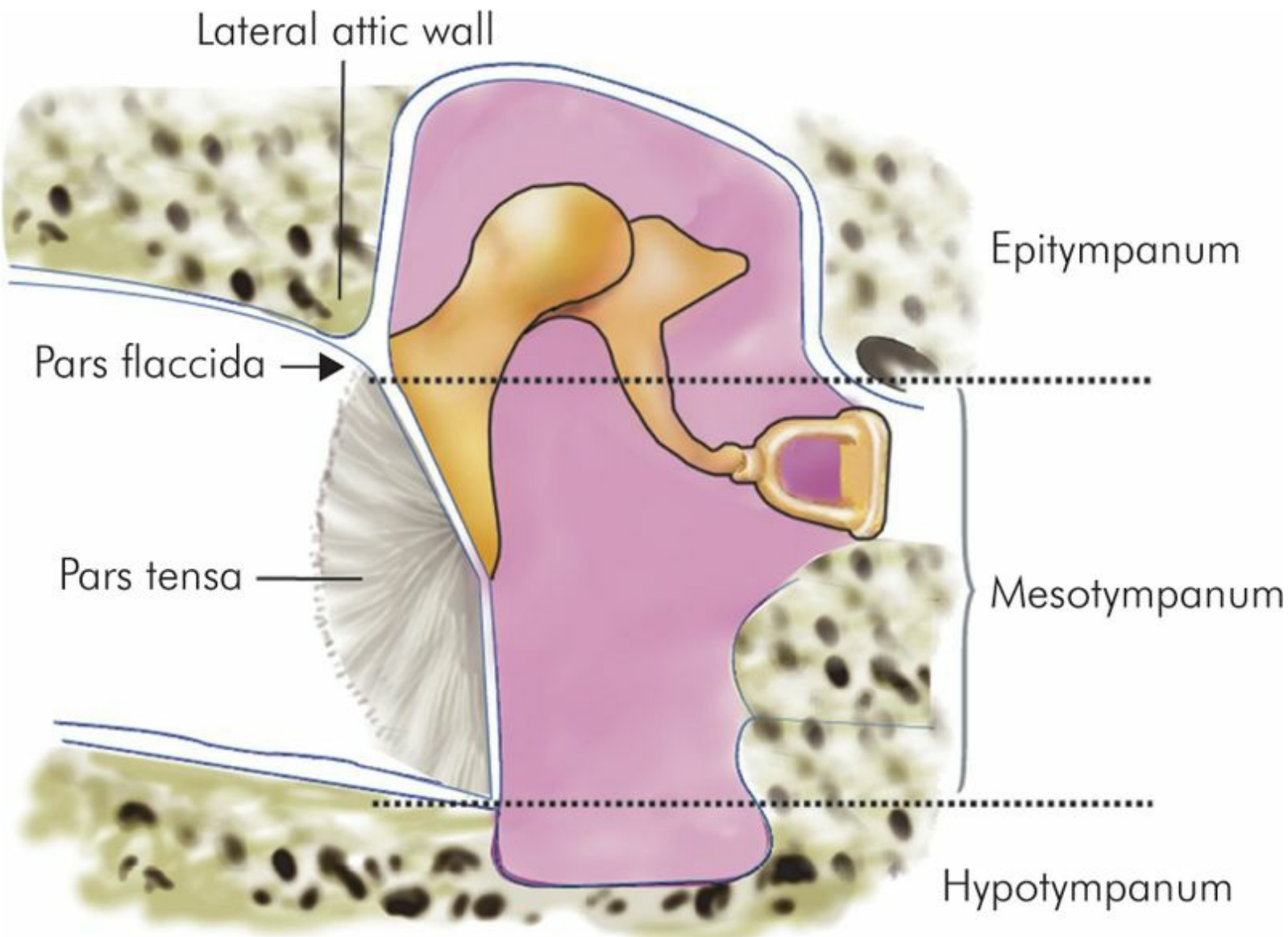
Middle ear can be likened to a six-sided box with a roof, a floor, medial, lateral, anterior and posterior walls (Fig. 1.6).

page 5  
page 6



Dhingra: Diseases of Ear Nose and Throat, 5th Edition  
Copyright © 2010 Elsevier. All rights reserved.

Figure 1.4 Middle ear cleft.



Dhingra: Diseases of Ear Nose and Throat, 5th Edition  
 Copyright © 2010 Elsevier. All rights reserved.

Figure 1.5 Divisions of middle ear into epi-, meso- and hypotympanum.

***The roof***

is formed by a thin plate of bone called tegmen tympani. It also extends posteriorly to form the roof of the aditus and antrum. It separates tympanic cavity from the middle cranial fossa.

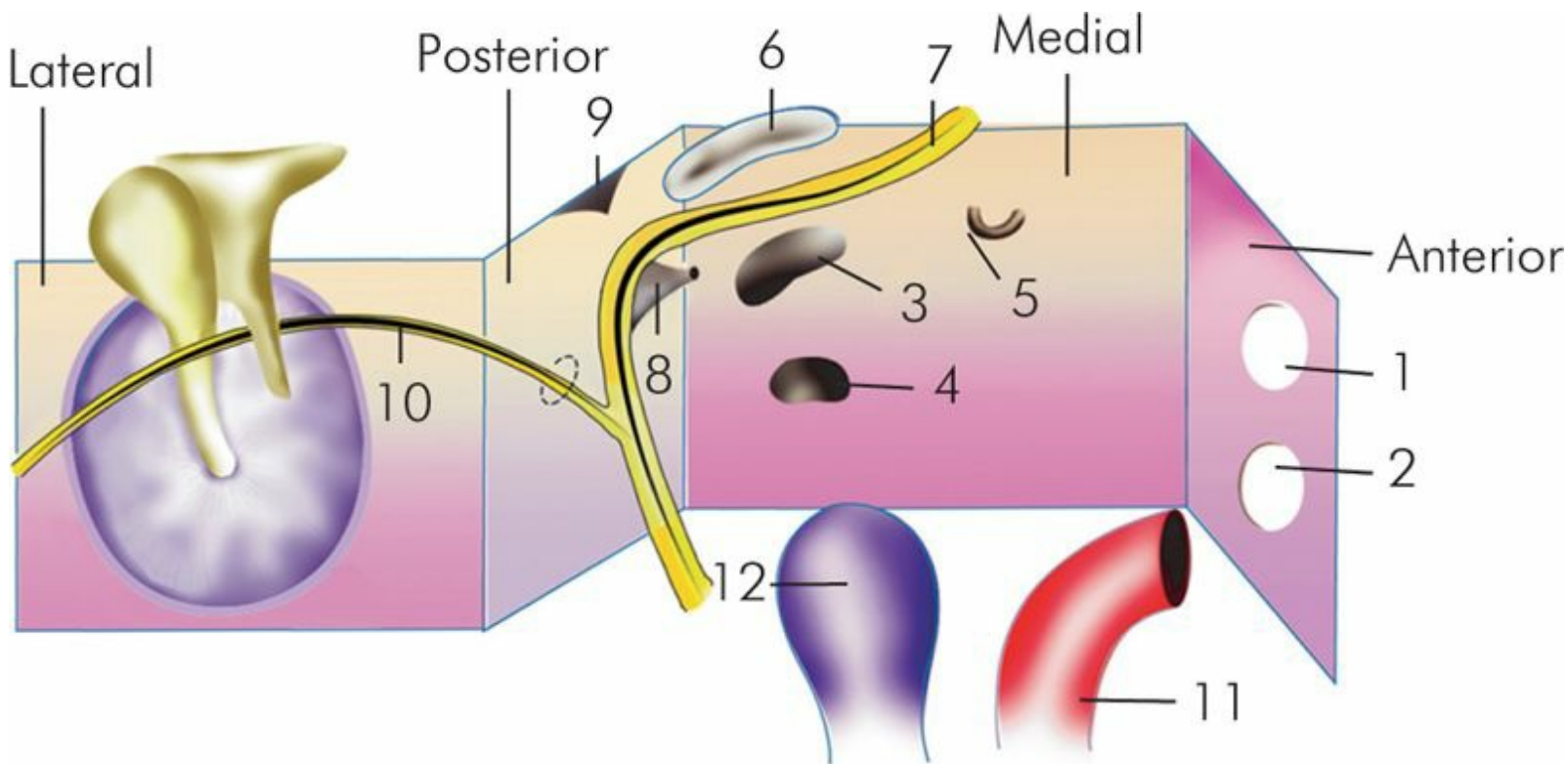
***The floor***

is also a thin plate of bone which separates tympanic cavity from the jugular bulb. Sometimes, it is congenitally deficient and the jugular bulb may then project into the middle ear; separated from the cavity only by the mucosa.

***The anterior wall***

has a thin plate of bone which separates the cavity from internal carotid artery. It also has two openings; the lower one for the eustachian tube and the upper one for the canal of tensor tympani muscle.

***The posterior wall***



Dhingra: Diseases of Ear Nose and Throat, 5th Edition  
Copyright © 2010 Elsevier. All rights reserved.

Figure 1.6 Walls of middle ear and the structures related to them.

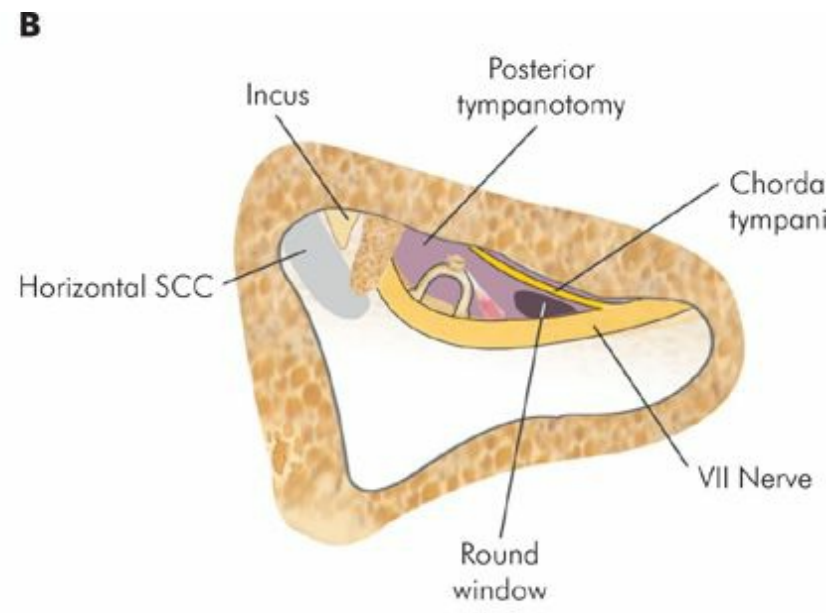
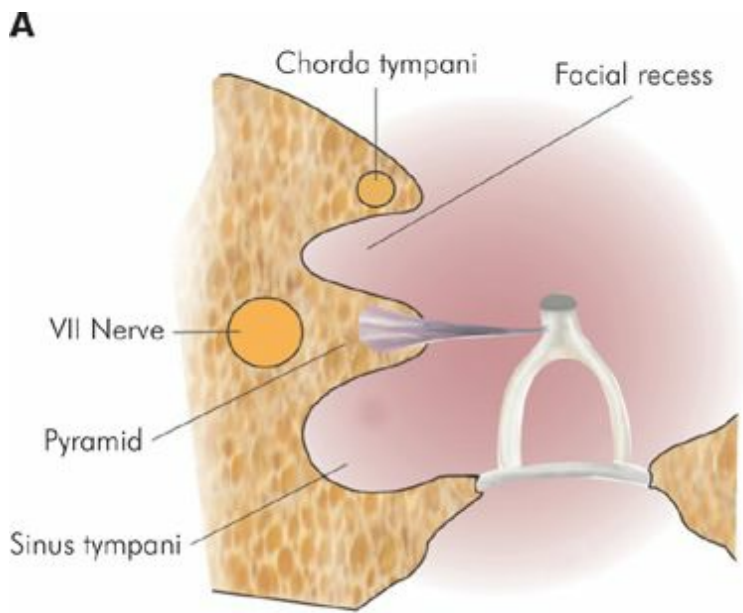
- |     |                            |
|-----|----------------------------|
| 1.  | Canal for tensor tympani   |
| 2.  | Opening of eustachian tube |
| 3.  | Oval window                |
| 4.  | Round window               |
| 5.  | Processus cochleariformis  |
| 6.  | Horizontal canal           |
| 7.  | Facial nerve               |
| 8.  | Pyramid                    |
| 9.  | Aditus                     |
| 10. | Chorda tympani             |
| 11. | Carotid artery             |
| 12. | Jugular bulb               |

lies close to the mastoid air cells. It presents a bony projection called the *pyramid* through the summit of which appears the tendon of the stapedius muscle to get attachment to the neck of stapes. *Aditus*, an opening through which attic communicates with the antrum, lies above the pyramid. Facial nerve runs in the posterior wall just behind the pyramid. *Facial recess* or the *posterior sinus* is a depression in the posterior wall lateral to the pyramid. It is bounded medially by the vertical part of VIth nerve, laterally by the chorda tympani and above, by the fossa incudis (Fig. 1.7). Surgically, facial recess is important, as direct access can be made through this into the middle ear without disturbing posterior canal wall (intact canal wall technique, see page 82).

### The medial wall (Fig. 1.8)

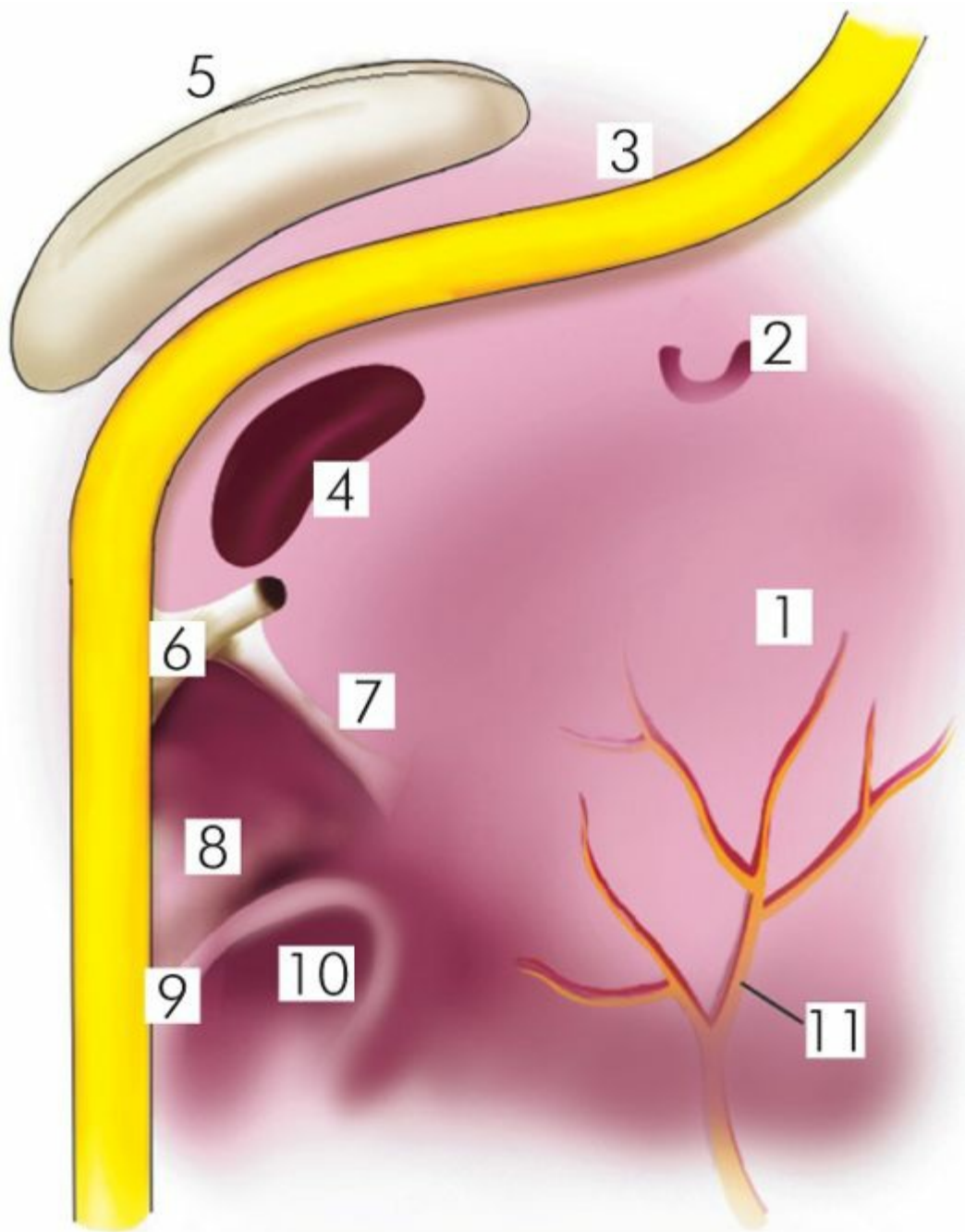
is formed by the labyrinth. It presents a bulge called *promontory* which is due to the basal coil of cochlea; *oval window* into which is fixed the footplate of stapes; *round window* or the fenestra cochleae which is covered by the secondary tympanic membrane. Above the oval window is the *canal for facial nerve*. Its bony covering may sometimes be congenitally dehiscant and the nerve may lie exposed making it very vulnerable to injuries or infection. Above the canal for facial nerve is the prominence of lateral semicircular canal. Just anterior to the oval window, the medial wall presents a hook-like projection called the *processus cochleariformis*. The tendon of tensor tympani takes a turn here to get attachment to the neck of malleus. The cochleariform process also marks the level of the genu of the facial nerve which is an important landmark for surgery of the facial nerve. Medial to the pyramid is a deep recess called *sinus tympani* which is bounded by the *subiculum* below and the *ponticulus* above (Fig. 1.7).

### The lateral wall



Dhingra: Diseases of Ear Nose and Throat, 5th Edition  
Copyright © 2010 Elsevier. All rights reserved.

Figure 1.7 (A) Facial recess lies lateral and sinus tympani medial to the pyramidal eminence and vertical part of the facial nerve. (B) Exposure of facial recess through posterior tympanotomy as seen at mastoid surgery.

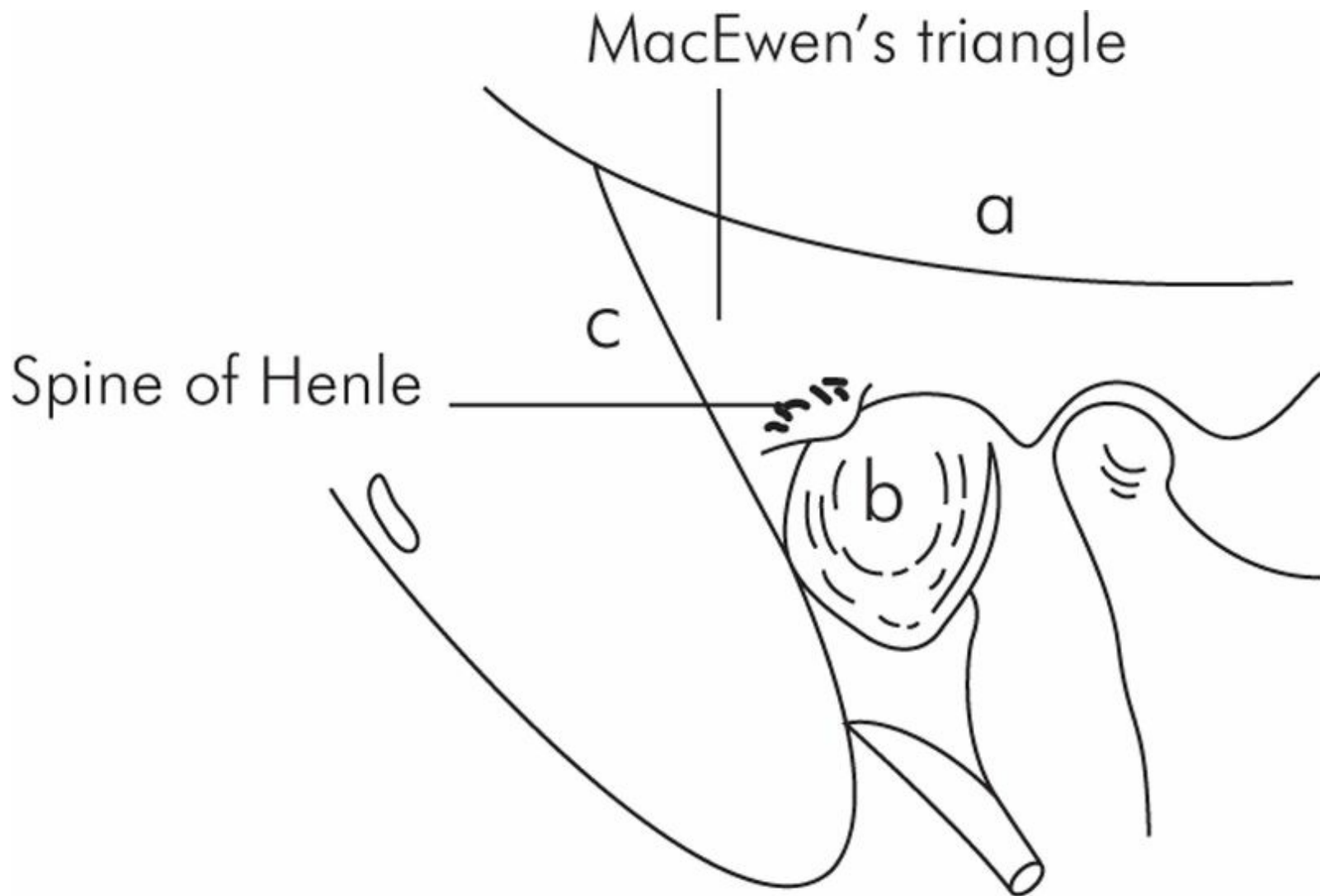


Dhingra: Diseases of Ear Nose and Throat, 5th Edition  
 Copyright © 2010 Elsevier. All rights reserved.

Figure 1.8 Medial wall of middle ear.

- |     |                           |
|-----|---------------------------|
| 1.  | Promontory                |
| 2.  | Processus cochleariformis |
| 3.  | CN VII                    |
| 4.  | Oval window               |
| 5.  | Horizontal canal          |
| 6.  | Pyramid                   |
| 7.  | Ponticulus                |
| 8.  | Sinus tympani             |
| 9.  | Subiculum                 |
| 10. | Round window              |
| 11. | Tympanic plexus           |

is formed largely by the tympanic membrane and to a lesser extent by the bony outer attic wall called the *scutum*. The tympanic membrane is semitransparent and forms a 'window' into the middle ear. It is possible to see some structures of the middle ear through the normal tympanic membrane, e.g. the long process of incus, incudostapedial joint and the round window.



Dhingra: Diseases of Ear Nose and Throat, 5th Edition  
Copyright © 2010 Elsevier. All rights reserved.

Figure 1.9 MacEwen's (suprameatal) triangle. It is bounded by temporal line (a), posterosuperior segment of bony external auditory canal (b) and the line drawn as a tangent to the external canal (c). It is an important landmark to locate the mastoid antrum in mastoid surgery.

It is a large, air-containing space in the upper part of mastoid and communicates with the attic through the aditus. Its roof is formed by the *tegmen antri* which is a continuation of the tegmen tympani and separates it from the middle cranial fossa. The lateral wall of antrum is formed by a plate of bone which is on an average 1.5 cm thick in the adult. It is marked externally on the surface of mastoid by *suprameatal (MacEwen's) triangle* (Fig. 1.9).

## Aditus ad Antrum

Aditus is an opening through which the attic communicates with the antrum. The bony prominence of the horizontal canal lies on its medial side while the fossa incudis, to which is attached the short process of incus, lies laterally. Facial nerve courses just below the aditus.

## The Mastoid and Its Air Cell System (Fig. 1.10)

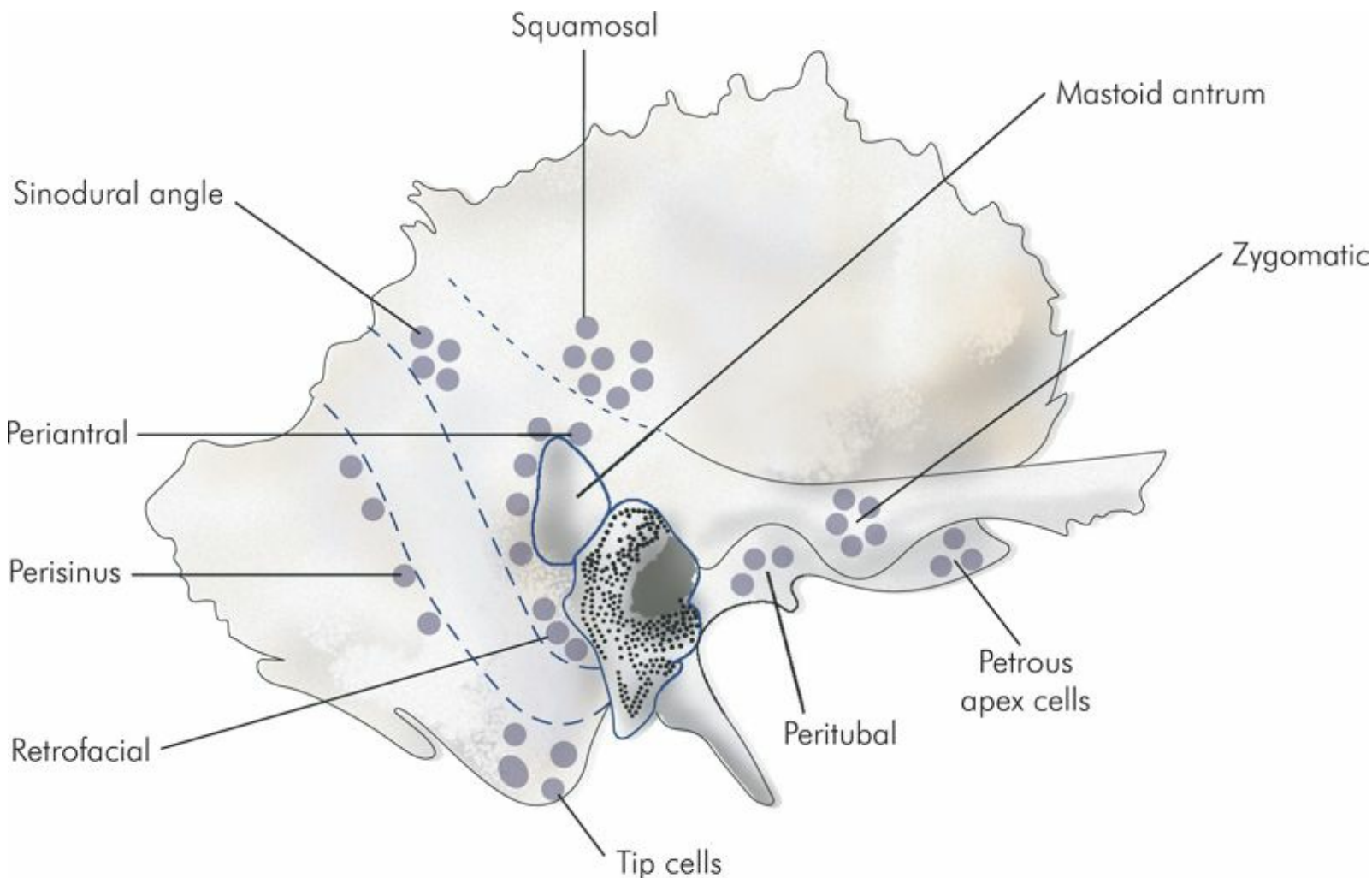
The mastoid consists of bone cortex with a "honeycomb" of air cells underneath. Depending on development of air cell, three types of mastoid have been described.

- (i) *Well-pneumatised or cellular*. Mastoid cells are well developed and intervening septa are thin.
- (ii) *Diploetic*. Mastoid consists of marrow spaces and a few air cells.
- (iii) *Sclerotic or acellular*. There are no cells or marrow spaces.

With any type of mastoid pneumatisation, antrum is always present. In sclerotic mastoids, antrum is usually small and the sigmoid sinus is anteposed.

Depending on the location, mastoid air cells are divided into:

- (i) zygomatic cells (in the root of zygoma).
- (ii) tegmen cells (extending into the tegmen tympani).
- (iii) perisinus cells (overlying the sinus plate).
- (iv) retrofacial cells (round the facial nerve).
- (v) perilabyrinthine cells (located above, below and behind the labyrinth, some of them pass through the arch of superior semicircular canal. These cells may communicate with the petrous apex).
- (vi) peritubal (around the eustachian tube. Along with hypotympanic cells they also communicate with the petrous apex).
- (vii) tip cells which are quite large and lie medial and lateral to the digastric ridge in the tip of mastoid.
- (viii) marginal cells (lying behind the sinus plate and may extend into the occipital bone).
- (ix) squamosal cells (lying in the squamous part of temporal bones).



Dhingra: Diseases of Ear Nose and Throat, 5th Edition  
Copyright © 2010 Elsevier. All rights reserved.

Figure 1.10 Air cells in the temporal bone.

Abscesses may form in relation to these air cells and may sometimes be located far from the mastoid region.

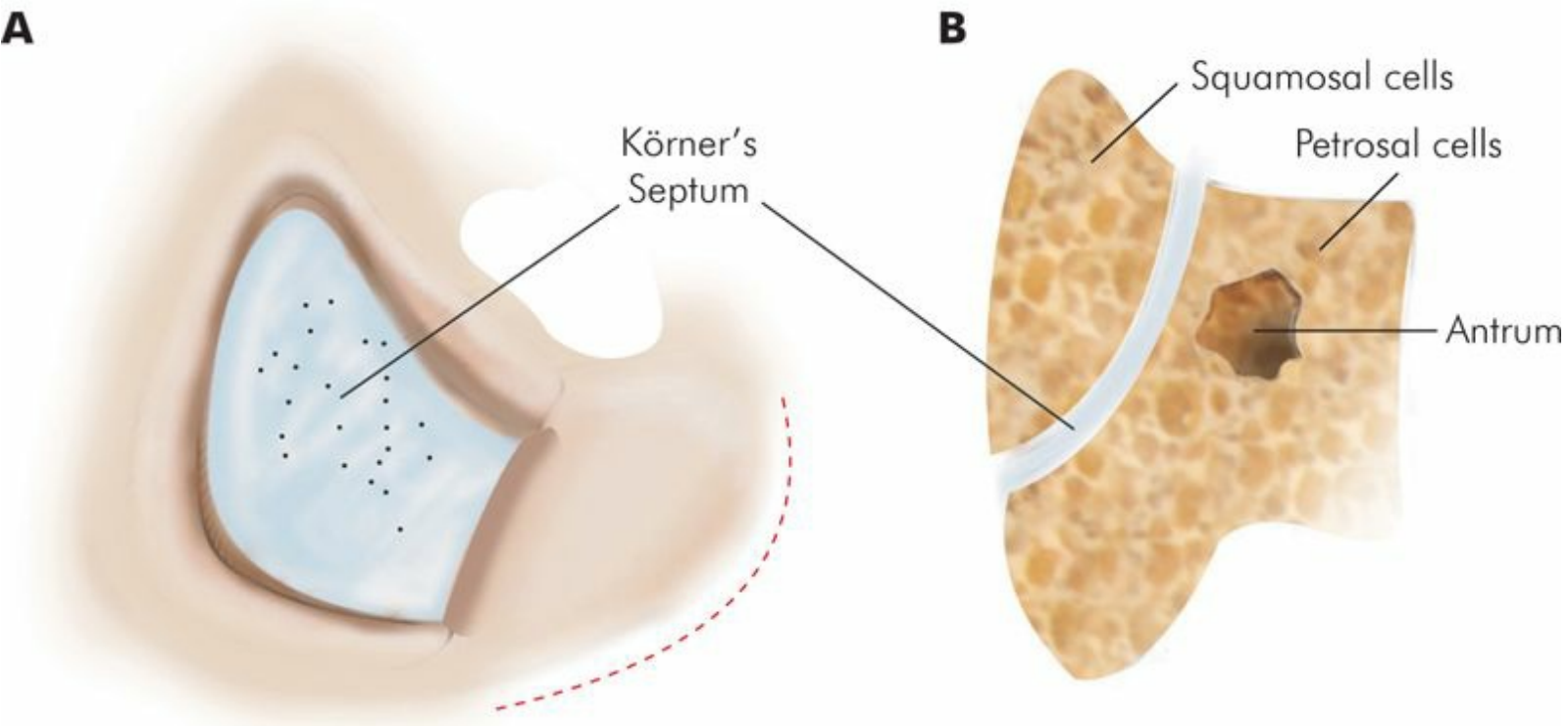
## Development of Mastoid



# Ossicles of the Middle Ear (Fig. 1.12)

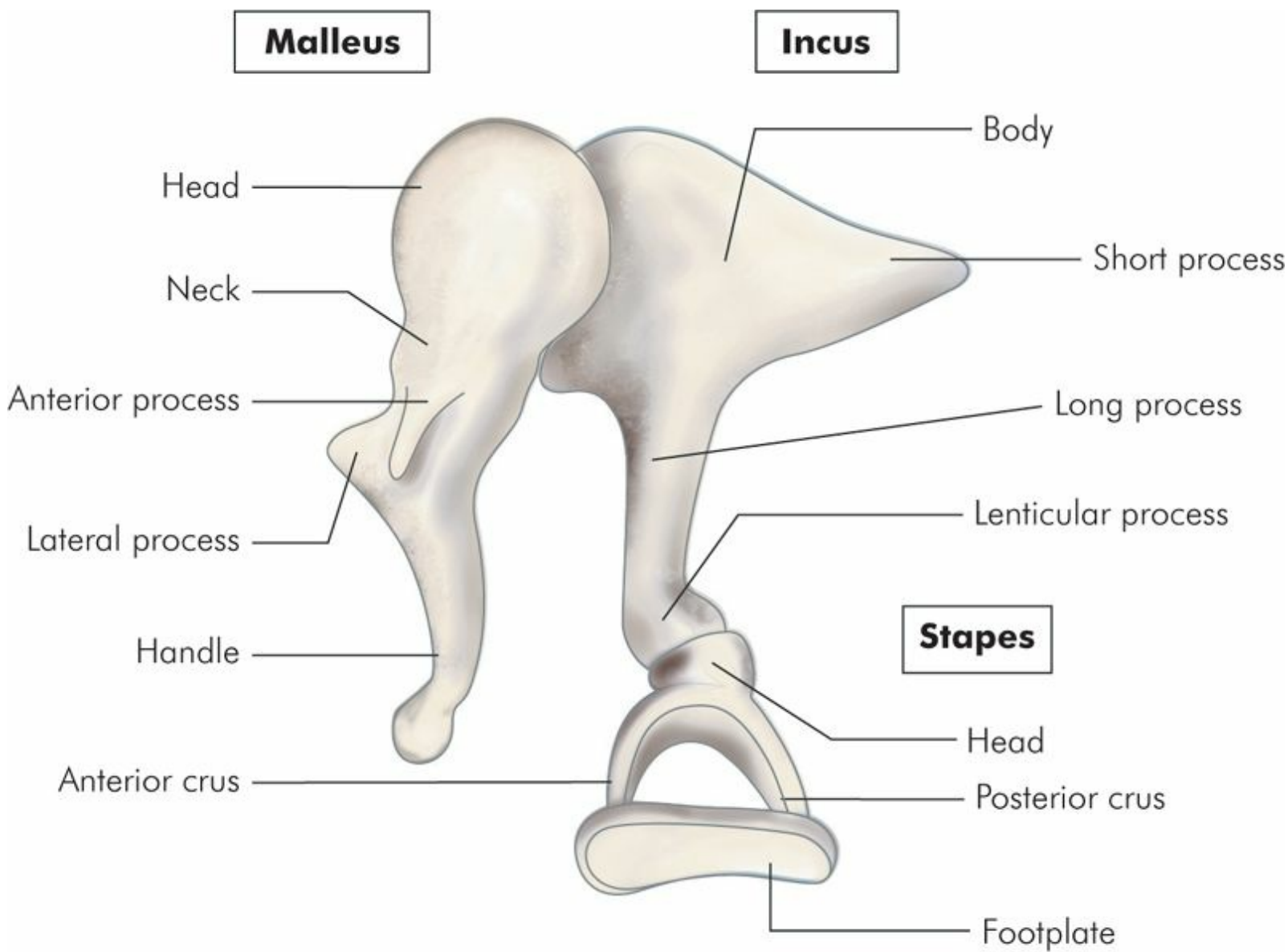
There are three ossicles in the middle ear-the malleus, incus and stapes.

## The malleus



Dhingra: Diseases of Ear Nose and Throat, 5th Edition  
Copyright © 2010 Elsevier. All rights reserved.

Figure 1.11 Korner's septum (A) as seen on mastoid exploration, (B) in coronal section of mastoid; in its presence there is difficulty in locating the antrum which lies deep to it.



Dhingra: Diseases of Ear Nose and Throat, 5th Edition  
 Copyright © 2010 Elsevier. All rights reserved.

Figure 1.12 Ear ossicles and their parts.

has head, neck, handle (manubrium), a lateral and an anterior process. Head and neck of malleus lie in the attic. Manubrium is embedded in the fibrous layer of the tympanic membrane. The lateral process forms a knob-like projection on the outer surface of the tympanic membrane and gives attachment to the anterior and posterior malleal (malleolar) folds.

***The incus***

has a body and a short process, both of which lie in the attic, and a long process which hangs vertically and attaches to the head of stapes.

***The stapes***

has a head, neck, anterior and posterior crura and a footplate. The footplate is held in the oval window by annular ligament.

The ossicles conduct sound energy from the tympanic membrane to the oval window and then to the inner ear fluid.

There are two muscles-*tensor tympani* and the *stapedius*; the former attaches to the neck of malleus and tenses the tympanic membrane while the latter attaches to the neck of stapes and helps to dampen very loud sounds thus preventing noise trauma to the inner ear. Stapedius is a 2nd arch muscle and is supplied by a branch of CN VII while tensor tympani develops from the 1st arch and is supplied by a branch of mandibular nerve (V<sub>3</sub>).

## Tympanic Plexus

It lies on the promontory and is formed by (i) tympanic branch of glossopharyngeal and (ii) sympathetic fibres from the plexus round the internal carotid artery. Tympanic plexus supplies innervation to the medial surface of the tympanic membrane, tympanic cavity, mastoid air cells and the bony eustachian tube. It also carries secretomotor fibres for the parotid gland. Section of tympanic branch of glossopharyngeal nerve can be carried out in the middle ear in cases of Frey's syndrome.

Course of secretomotor fibres to the parotid:

Inferior salivary nucleus → CN IX → Tympanic branch → Tympanic plexus → Lesser petrosal nerve → Otic ganglion → Auriculotemporal nerve → Parotid gland.

## Chorda Tympani Nerve

It is a branch of the facial nerve which enters the middle ear through posterior canaliculus, and runs on the medial surface of the tympanic membrane between the handle of malleus and long process of incus, above the attachment of tendon of tensor tympani. It carries taste from anterior two-thirds of tongue and supplies secretomotor fibres to the submaxillary and sublingual salivary glands.

## Lining of the Middle Ear Cleft

Mucous membrane of the nasopharynx is continuous with that of the middle ear, aditus, antrum and the mastoid air cells. It wraps the middle ear structures-the ossicles, muscles, ligaments, and nerves-like peritoneum wraps various viscera in the abdomen-raising several folds and dividing the middle ear into various compartments. Middle ear contains nothing but the air; all the structures lie outside the mucous membrane.

Histologically, the eustachian tube is lined by ciliated epithelium which is pseudostratified columnar in the cartilaginous part, columnar in the bony part with several mucous glands in the submucosa. Tympanic cavity is lined by ciliated columnar epithelium in its anterior and inferior part which changes to cuboidal type in the posterior part. Epitympanum and mastoid air cells are lined by flat, nonciliated epithelium.

## Blood Supply of Middle Ear

Middle ear is supplied by six arteries, out of which two are the main, i.e.

- **(i)** Anterior tympanic branch of maxillary artery which supplies tympanic membrane.
- **(ii)** Stylomastoid branch of posterior auricular artery which supplies middle ear and mastoid air cells.

Four minor vessels are:

- **(i)** Petrosal branch of middle meningeal artery (runs along greater petrosal nerve).
- **(ii)** Superior tympanic branch of middle meningeal artery traversing along the canal for tensor tympani muscle.
- **(iii)** Branch of artery of pterygoid canal (runs along eustachian tube).
- **(iv)** Tympanic branch of internal carotid.

Veins drain into pterygoid venous plexus and superior petrosal sinus.

## Lymphatic Drainage of Ear

Lymphatics from the middle ear drain into retropharyngeal and parotid nodes while those of the eustachian tube drain into retropharyngeal group (see Table 1.1).



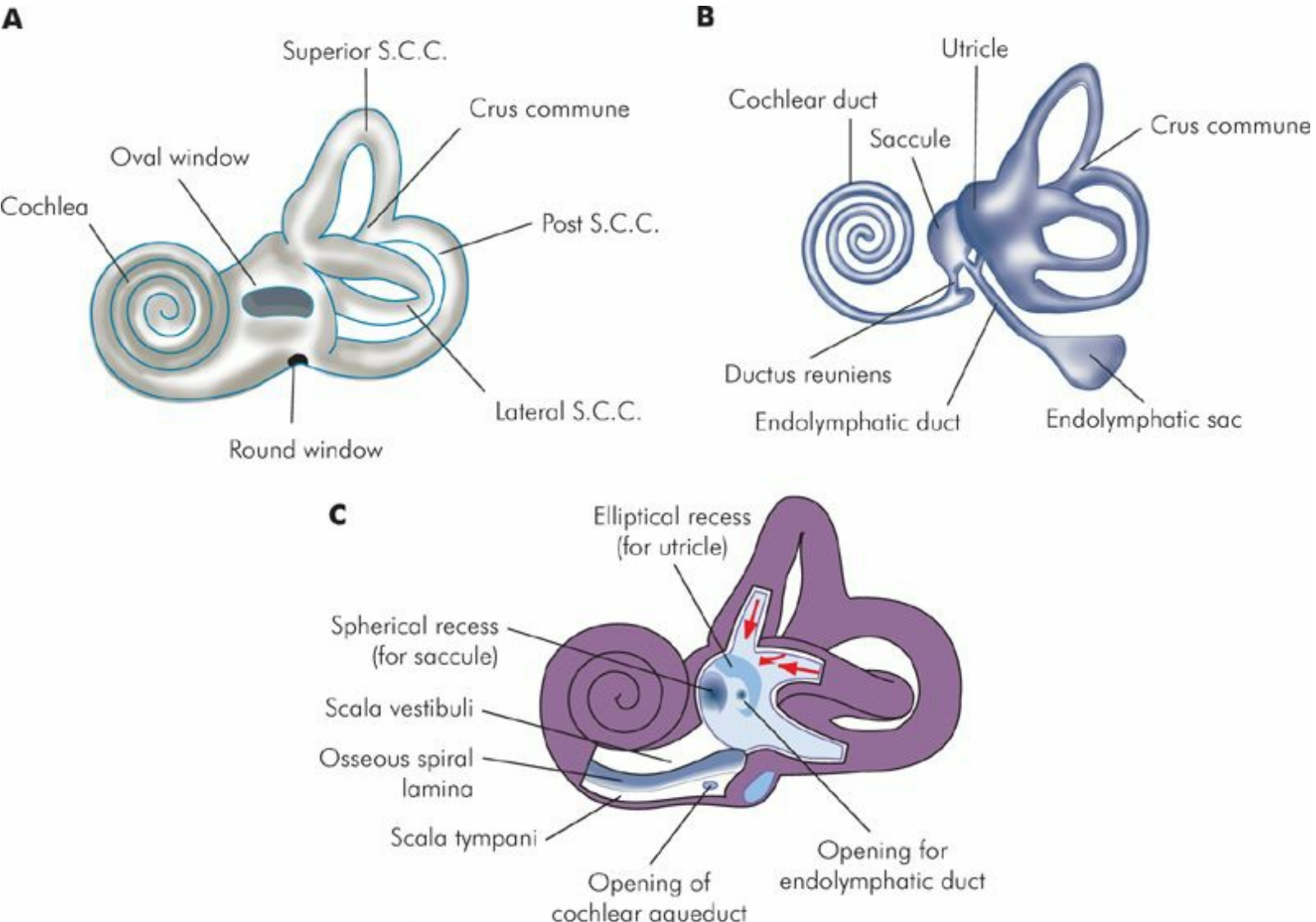
# THE INTERNAL EAR

The internal ear or the labyrinth is an important organ of hearing and balance. It consists of a bony and a membranous labyrinth. The membranous labyrinth is filled with a clear fluid called endolymph while the space between membranous and bony labyrinths is filled with perilymph.

Table 1-1. Lymphatic drainage of ear

Area	Nodes
Concha, tragus, fossa triangularis and external cartilaginous canal	Preauricular and parotid nodes
Lobule and antitragus	Infra-auricular nodes
Helix and antihelix	Post-auricular nodes, deep jugular and spinal accessory nodes
Middle ear and eustachian tube	Retropharyngeal nodes → upper jugular chain
Inner ear	No lymphatics

page 10  
page 11



Dhingra: Diseases of Ear Nose and Throat, 5th Edition  
Copyright © 2010 Elsevier. All rights reserved.

Figure 1.13 (A) Left bony labyrinth. (B) Left membranous labyrinth. (C) Cut section of bony labyrinth.

## Bony Labyrinth (Fig. 1.13A)

It consists of three parts: the vestibule, the semicircular canals and the cochlea.

### 1. Vestibule

is the central chamber of the labyrinth. In its lateral wall lies the oval window. The inside of its medial wall presents two recesses, a *spherical recess*, which lodges the saccule and an elliptical recess which lodges the utricle. Below the *elliptical recess* is the opening of aqueduct of vestibule through which passes the endolymphatic duct. In the posterosuperior part of vestibule are the five openings of semicircular canals (Fig. 1.13C).

### 2. Semicircular canals

They are three in number, the lateral, posterior and superior, and lie in planes at right angles to one another. Each canal has an ampullated end which opens independently into the vestibule and a nonampullated end. The non-ampullated ends of posterior and superior canals unite to form a common channel called the *crus commune*. Thus, the three canals open into the vestibule by five openings.

### 3. Cochlea

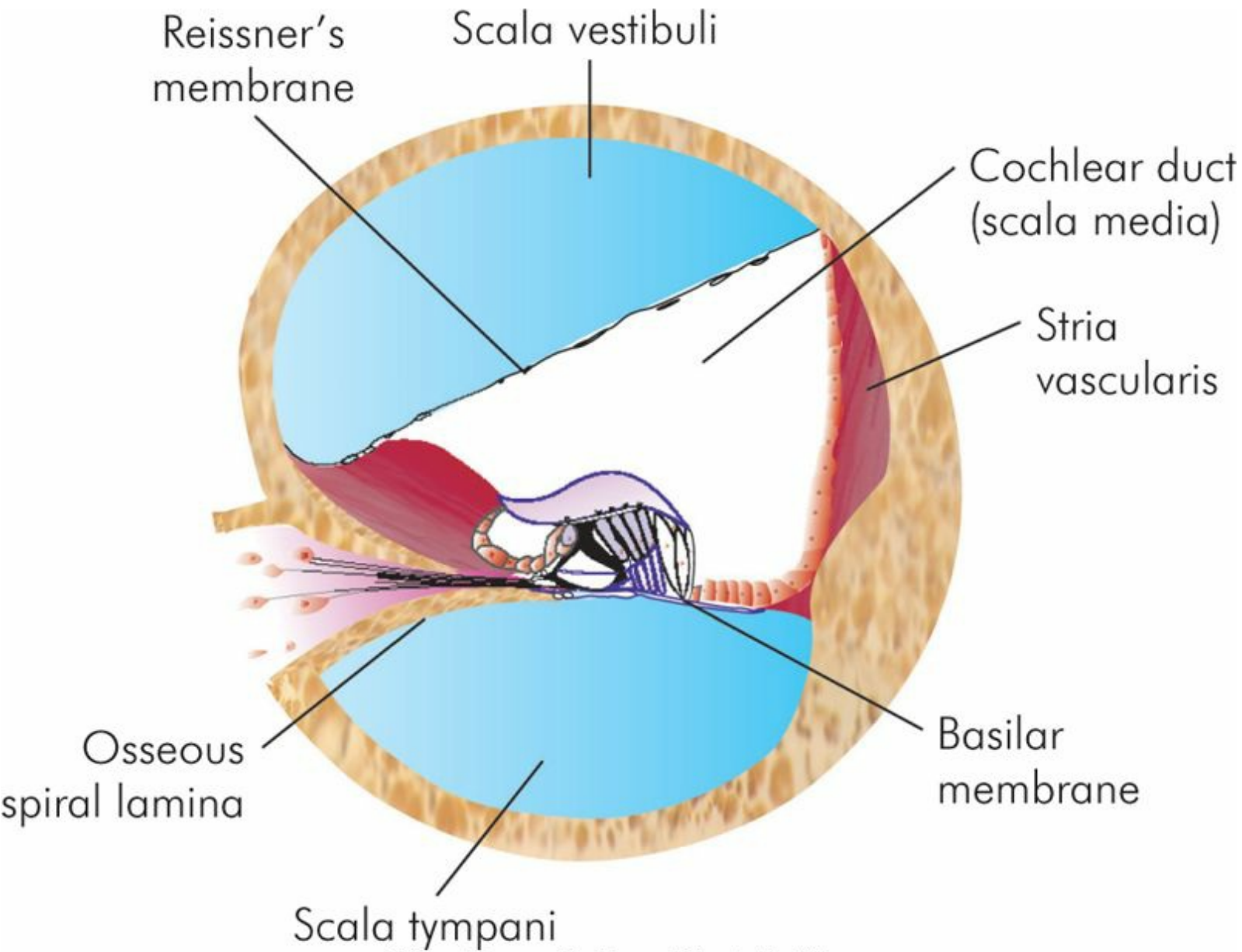
The bony cochlea is a coiled tube making 2.5 to 2.75 turns round a central pyramid of bone called the *modiolus*. The base of modiolus is directed towards internal acoustic meatus and transmits vessels and nerves to the cochlea. Around the modiolus and winding spirally like the thread of a screw, is a thin plate of bone called *osseous spiral lamina*. It divides the bony cochlea incompletely, and gives attachment to the basilar membrane. The bony bulge in the medial wall of middle ear-the promontory, is due to the basal coil of the cochlea. The bony cochlea contains three compartments:

- (a) scala vestibuli,
- (b) scala tympani,
- (c) scala media or the membranous cochlea (Fig. 1.14).

The scala vestibuli and scala tympani are filled with perilymph and communicate with each other at the apex of cochlea through an opening called *helicotrema*. Scala vestibuli is closed by the footplate of stapes which separates it from the air-filled middle ear. The scala tympani is closed by secondary tympanic membrane; it is also connected with the subarachnoid space through the *aqueduct of cochlea* (Fig. 1.15).

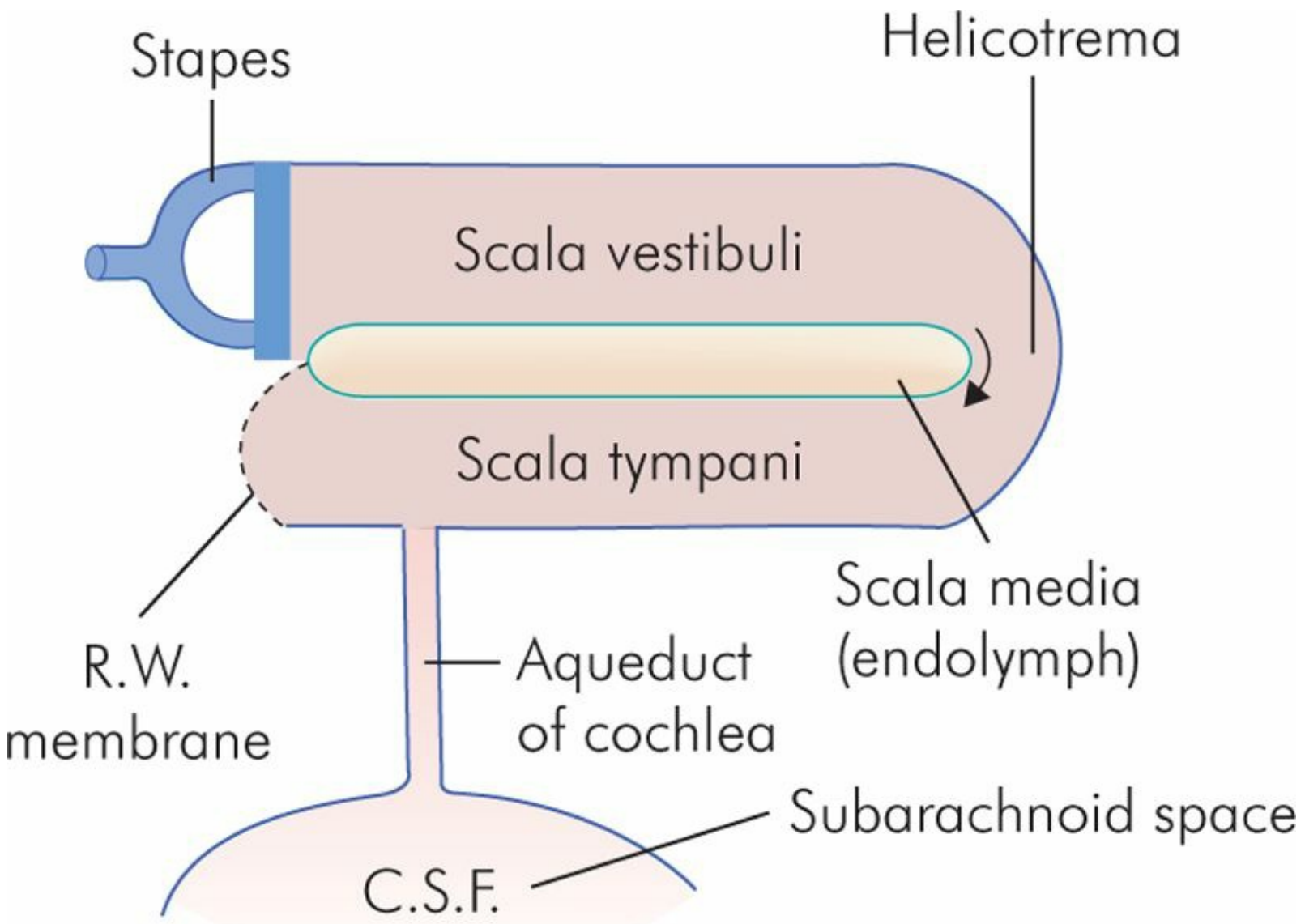
# Membranous Labyrinth (Fig. 1.13B)

It consists of the cochlear duct, the utricle and saccule, the three semicircular ducts, and the endolymphatic duct and sac.



Dhingra: Diseases of Ear Nose and Throat, 5th Edition  
Copyright © 2010 Elsevier. All rights reserved.

Figure 1.14 Section through cochlea to show scala media (cochlear duct), scala vestibuli and scala tympani.



Dhingra: Diseases of Ear Nose and Throat, 5th Edition  
 Copyright © 2010 Elsevier. All rights reserved.

Figure 1.15 Diagrammatic representation of perilymphatic system. CSF passes into scala tympani through aqueduct of cochlea.

### 1. Cochlear duct (Fig. 1.14)

Also called membranous cochlea or the scala media. It is a blind coiled tube. It appears triangular on cross-section and its three walls are formed by:

- (a) the basilar membrane, which supports the organ of corti,
- (b) the Reissner's membrane which separates it from the scala vestibuli,
- (c) the stria vascularis, which contains vascular epithelium and is concerned with secretion of endolymph.

Cochlear duct is connected to the saccule by *ductus reuniens* (Fig. 1.13B). The length of basilar membrane increases as we proceed from the basal coil to the apical coil. It is for this reason that higher frequencies of sound are heard at the basal coil while lower ones are heard at the apical coil.

### 2. Utricle and saccule

The utricle lies in the posterior part of bony vestibule. It receives the five openings of the three semicircular ducts. It is also connected to the saccule through utriculosaccular duct. The sensory epithelium of the utricle is called the macula and is concerned with linear acceleration and deceleration. The saccule also lies in the bony vestibule, anterior to the utricle and opposite the stapes footplate. Its sensory epithelium is also called the *macula*. Its exact function is not known. It probably also responds to linear acceleration and deceleration. In Meniere's disease, the distended saccule lies against the stapes footplate and can be surgically decompressed by perforating the footplate.

### 3. Semicircular ducts

They are three in number and correspond exactly to the three bony canals. They open in the utricle. The ampullated end of each duct contains a thickened ridge of neuroepithelium called *crista ampullaris*.

### 4. Endolymphatic duct and sac

Endolymphatic duct is formed by the union of two ducts, one each from the saccule and the utricle. It passes through the vestibular aqueduct. Its terminal part is dilated to form endolymphatic sac which lies between the two layers of dura on the posterior surface of the petrous bone.

Endolymphatic sac is surgically important. It is exposed for drainage or shunt operation in Meniere's disease.

# Inner Ear Fluids and their Circulation

There are two main fluids in the inner ear, perilymph and endolymph.

## ***Perilymph***

resembles extracellular fluid and is rich in Na ions. It fills the space between the bony and the membranous labyrinth. It communicates with CSF through the aqueduct of cochlea which opens into the scala tympani near the round window. In fact this duct is not a direct communication but contains connective tissue resembling arachnoid through which perilymph percolates. There are two views regarding the formation of perilymph: (i) It is a filtrate of blood serum and is formed by capillaries of the spiral ligament and (ii) it is a direct continuation of CSF and reaches the labyrinth via aqueduct of cochlea.

## ***Endolymph***

fills the entire membranous labyrinth and resembles intracellular fluid, being rich in K ions. It is secreted by the secretory cells of the stria vascularis of the cochlea and by the dark cells (present in the utricle and also near the ampullated ends of semicircular ducts). There are two views regarding its flow: (i) Longitudinal, i.e. endolymph from the cochlea reaches saccule, utricle and endolymphatic duct and gets absorbed through endolymphatic sac which lies in the subdural space and (ii) radial, i.e. endolymph is secreted by stria vascularis and also gets absorbed by the stria vascularis. This view presumes that endolymphatic sac is a vestigial structure in man and plays no part in endolymph absorption. Composition of endolymph, perilymph and CSF is given in Table 1.2.

# Blood Supply of Labyrinth

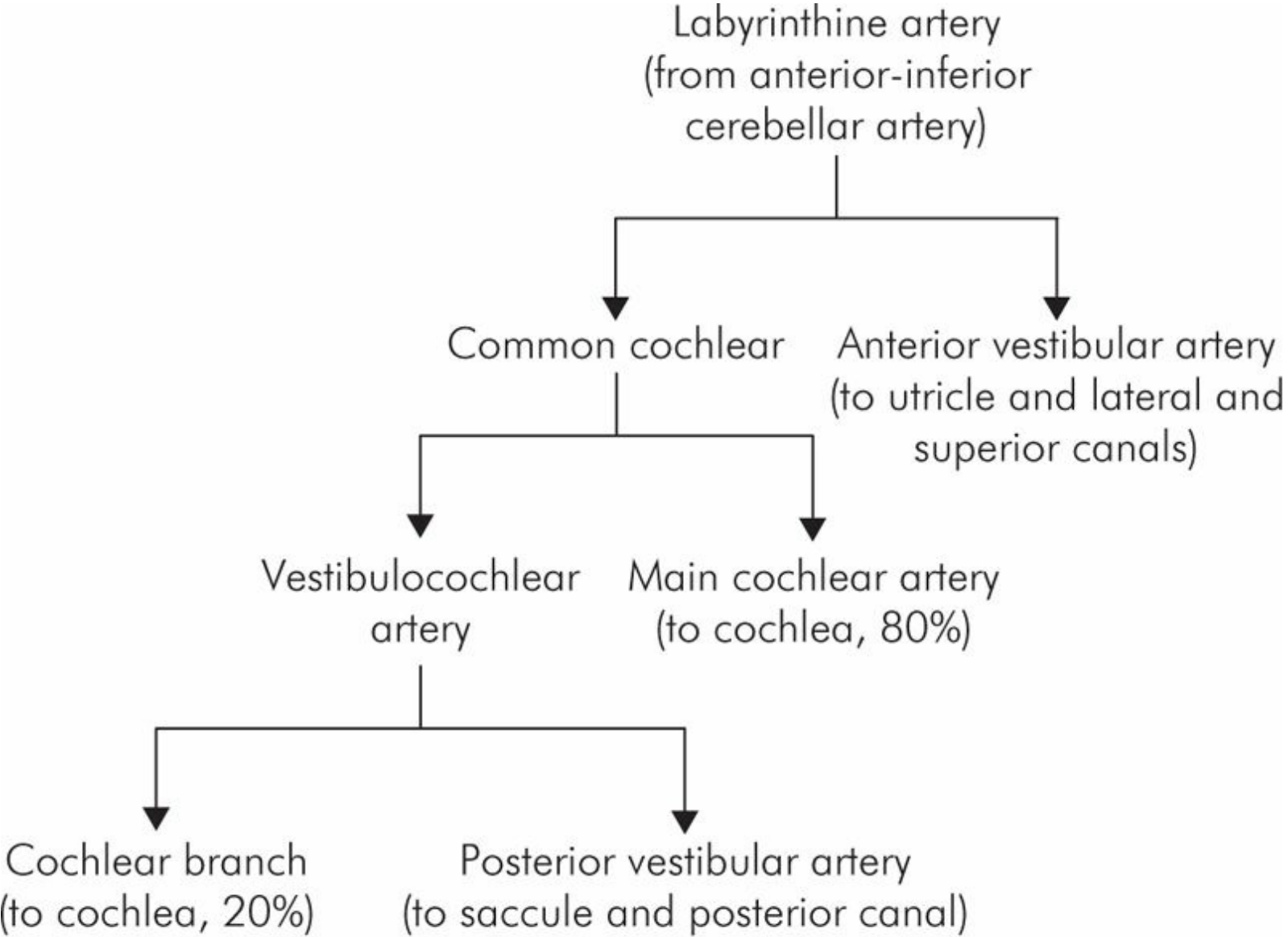
Table 1-2. Composition of inner ear fluids

	Endolymph	Perilymph	CSF
Na <sup>+</sup> (mEq/L)	5	140	152
K <sup>+</sup> (mEq/L)	144	10	4
Protein (mg/dL)	126	200-400	20-50
Glucose (mg/dL)	10-40	85	70

Values are average and may differ slightly according to the site of collection of endolymph (cochlea, utricle, sac) and perilymph (scala tympani or scala vestibuli).

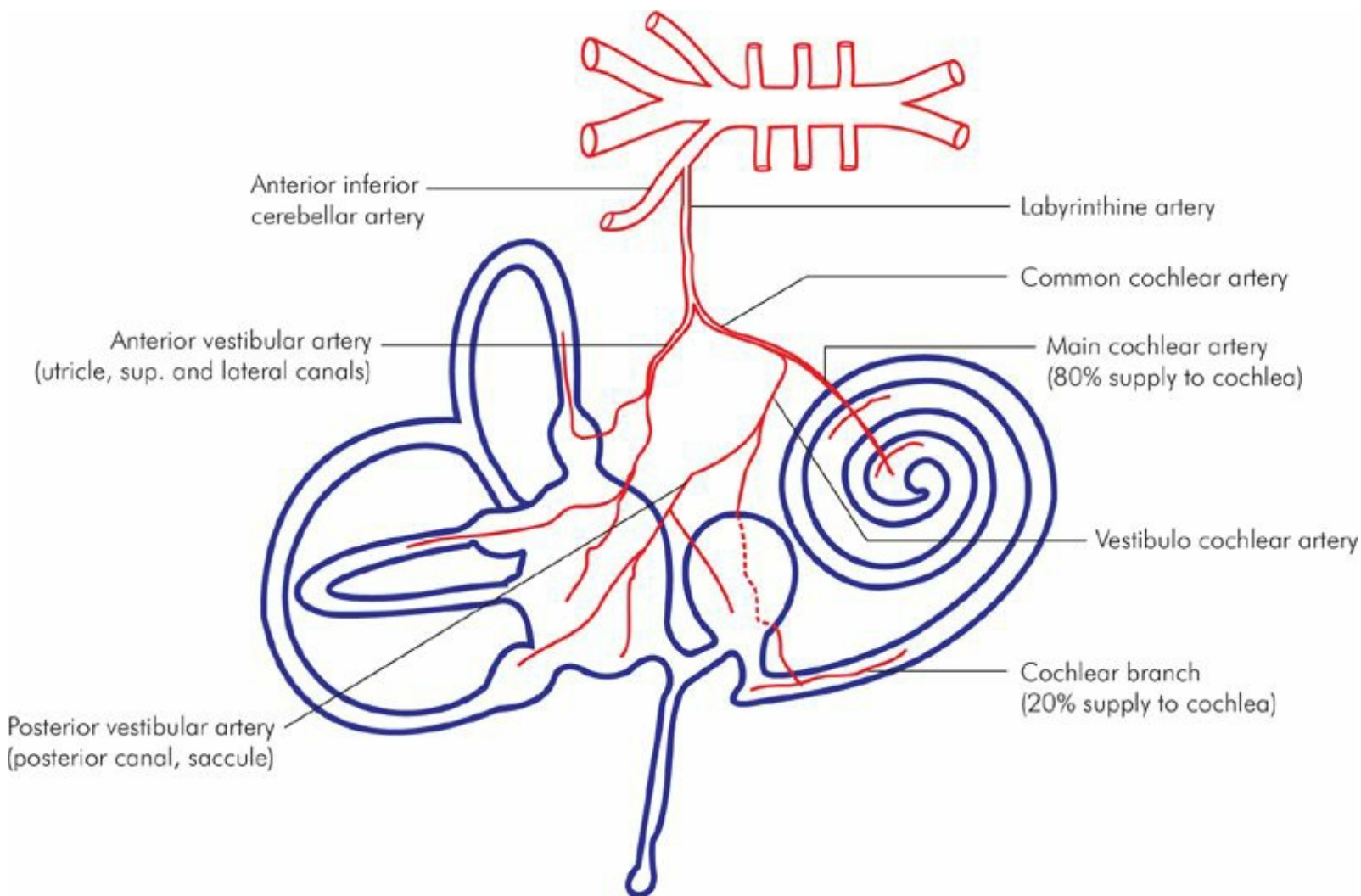
The entire labyrinth receives its arterial supply through labyrinthine artery which is a branch of anterior-inferior cerebellar artery but sometimes from the basilar. In the internal auditory canal it divides in the manner shown in Figs 1.16 and 1.17.

Venous drainage is through three veins, namely internal auditory vein, vein of cochlear aqueduct and vein of vestibular aqueduct which ultimately drain into inferior petrosal sinus and lateral venous sinus.



Dhingra: Diseases of Ear Nose and Throat, 5th Edition  
 Copyright © 2010 Elsevier. All rights reserved.

Figure 1.16 Divisions of the labyrinthine artery to supply various parts of labyrinth.



Dhingra: Diseases of Ear Nose and Throat, 5th Edition  
 Copyright © 2010 Elsevier. All rights reserved.

Figure 1.17 Blood supply of labyrinth.

It is to be noted that:

- **(a)** Blood supply to the inner ear is independent of blood supply to middle ear and bony otic capsule, and there is no cross circulation between the two.
- **(b)** Blood supply to cochlea and vestibular labyrinth is segmental, therefore, independent ischaemic damage can occur to these organs causing either cochlear or vestibular symptoms.

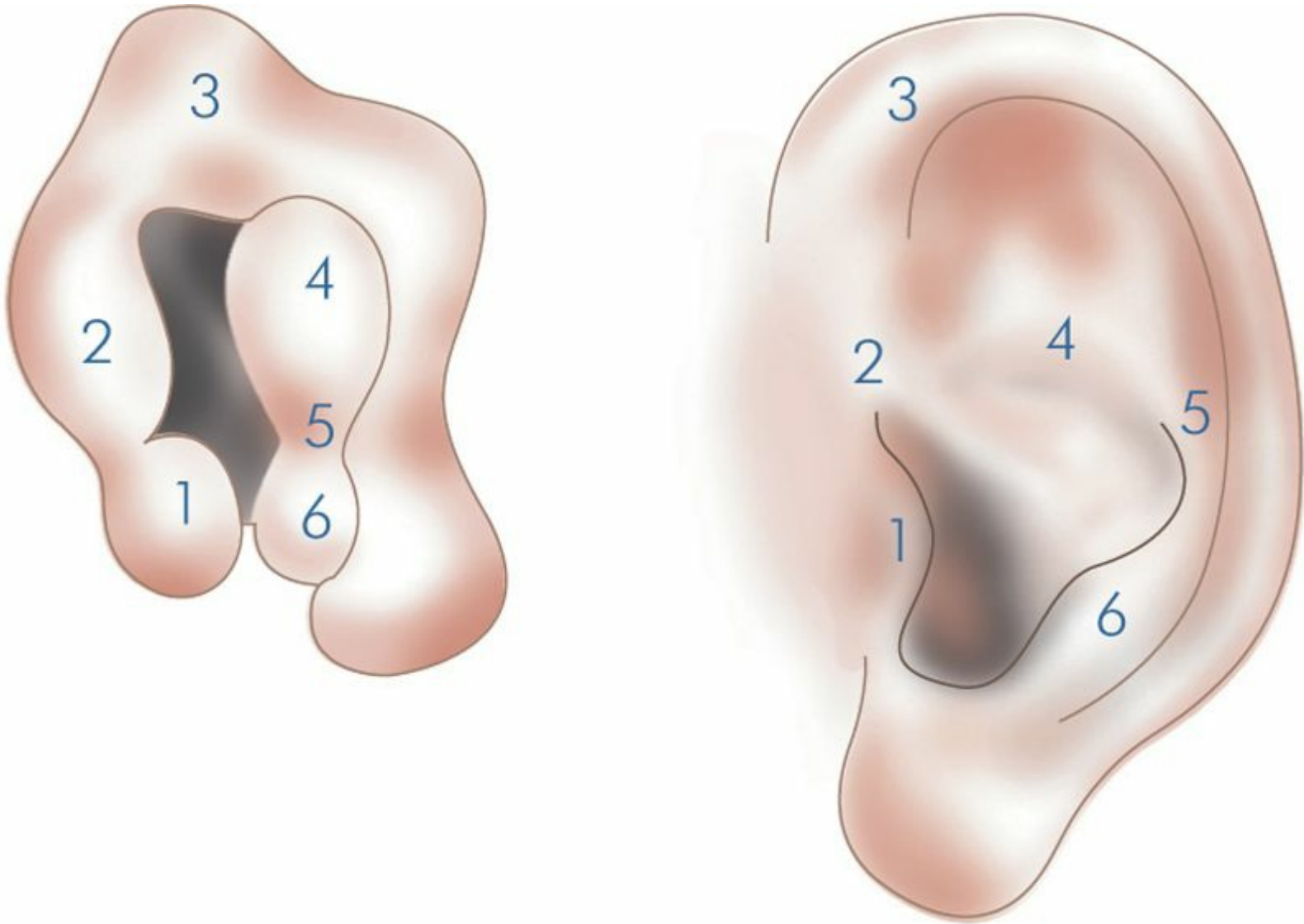


# DEVELOPMENT OF EAR

## *Auricle*

First branchial cleft is the precursor of external auditory canal. Around the sixth week of embryonic life, a series of six tubercles appear around the first branchial cleft. They progressively coalesce to form the auricle (Fig. 1.18). Tragus develops from the tubercle of the first arch while the rest of the pinna develops from the remaining five tubercles of the second arch. Faulty fusion between the first and the second arch tubercles causes preauricular sinus or cyst which is commonly seen between the tragus and crus of helix. By the 20th week, pinna achieves adult shape. Initially, the pinna is located low on the side of the neck and then moves on to a more lateral and cranial position.

## *External auditory meatus*



Dhingra: Diseases of Ear Nose and Throat, 5th Edition  
Copyright © 2010 Elsevier. All rights reserved.

Figure 1.18 Development of pinna. Six hillocks around first branchial cleft and the corresponding parts of pinna which develop from them.

develops from the first branchial cleft. By about the 16th embryonic week, cells proliferate from the bottom of ectodermal cleft and form a meatal plug. Recanalisation of this plug forms the epithelial lining of the bony meatus. Recanalisation begins from the deeper part near the tympanic membrane and progresses outwards, and that explains why deeper meatus is sometimes developed while there is atresia of canal in the outer part. External ear canal is fully formed by the 28th week of gestation.

## *Tympanic membrane*

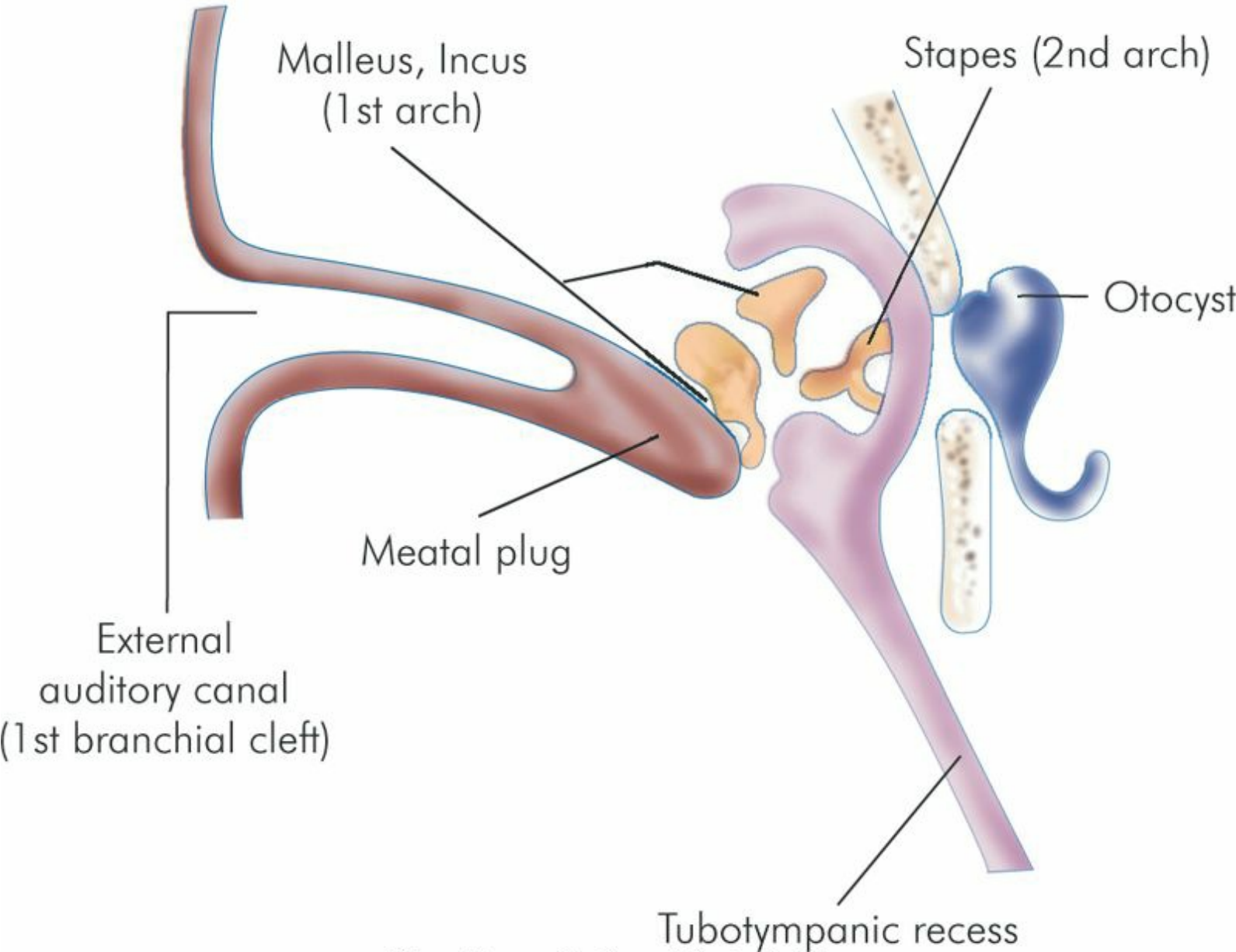
develops from all the three germinal layers. Outer epithelial layer is formed by the ectoderm, inner mucosal layer by the endoderm and the middle fibrous layer by the mesoderm.

## *Middle ear cleft*

The eustachian tube, tympanic cavity, attic, antrum and mastoid air cells develop from the endoderm of tubotympanic recess which arises from the first and partly from the second pharyngeal pouches (Fig. 1.19).

Malleus and incus are derived from mesoderm of the first arch while the stapes develop from the second arch except its footplate and annular ligament which are derived from the otic capsule.

**Membranous inner ear**



Dhingra: Diseases of Ear Nose and Throat, 5th Edition  
Copyright © 2010 Elsevier. All rights reserved.

Figure 1.19 Development of external auditory canal and middle ear.

**Table 1-3. Timing of development of the ear in the week of gestation\***

Development	Pinna	Meatus	Middle ear	Vestibular labyrinth	Cochlea
Begins	6th	8th	3rd	3rd	3rd
Completes	20th	28th	30th	20th	20th

\*Source: Gulya, A.J. Developmental Anatomy of the Ear. In Glasscock and Shambaugh ed. Surgery of the Ear. Philadelphia: W.B. Saunders Company, 1990.

Development of the inner ear starts in the third week of foetal life and is complete by the 16th week. Ectoderm in the region of hind brain thickens to form an *auditory placode* which is invaginated to form auditory vesicle or the otocyst. The latter then differentiates into the endolymphatic duct and sac; the utricle, the semicircular ducts; and saccule and the cochlea. Development of phylogenetically older part of labyrinth-*pars superior* (semicircular canals and utricle) takes place earlier than *pars inferior* (saccule and cochlea).

The embryologic source and the time of development of external and middle ears is quite independent of the development of the inner ear. It is

therefore not unusual to see malformed and non-functional inner ear in the presence of normal external and middle ears, and vice versa.

The cochlea is developed sufficiently by 20 weeks of gestation (Table 1.3) and the foetus can hear in the womb of the mother. This probably explains how Abhimanyu, while still unborn, could have heard the conversation between his mother and father (Arjuna) in the legend given in the Great Indian epic of Mahabharata written thousands of years ago.

### AUDITORY SYSTEM

#### Organ of Corti (Fig. 2.1)

Organ of Corti is the sense organ of hearing and is situated on the basilar membrane. Important components of the organ of Corti are:

##### 1. Tunnel of Corti

which is formed by the inner and outer rods. It contains a fluid called *cortilymph*. The exact function of the rods and cortilymph is not known.

##### 2. Hair cells

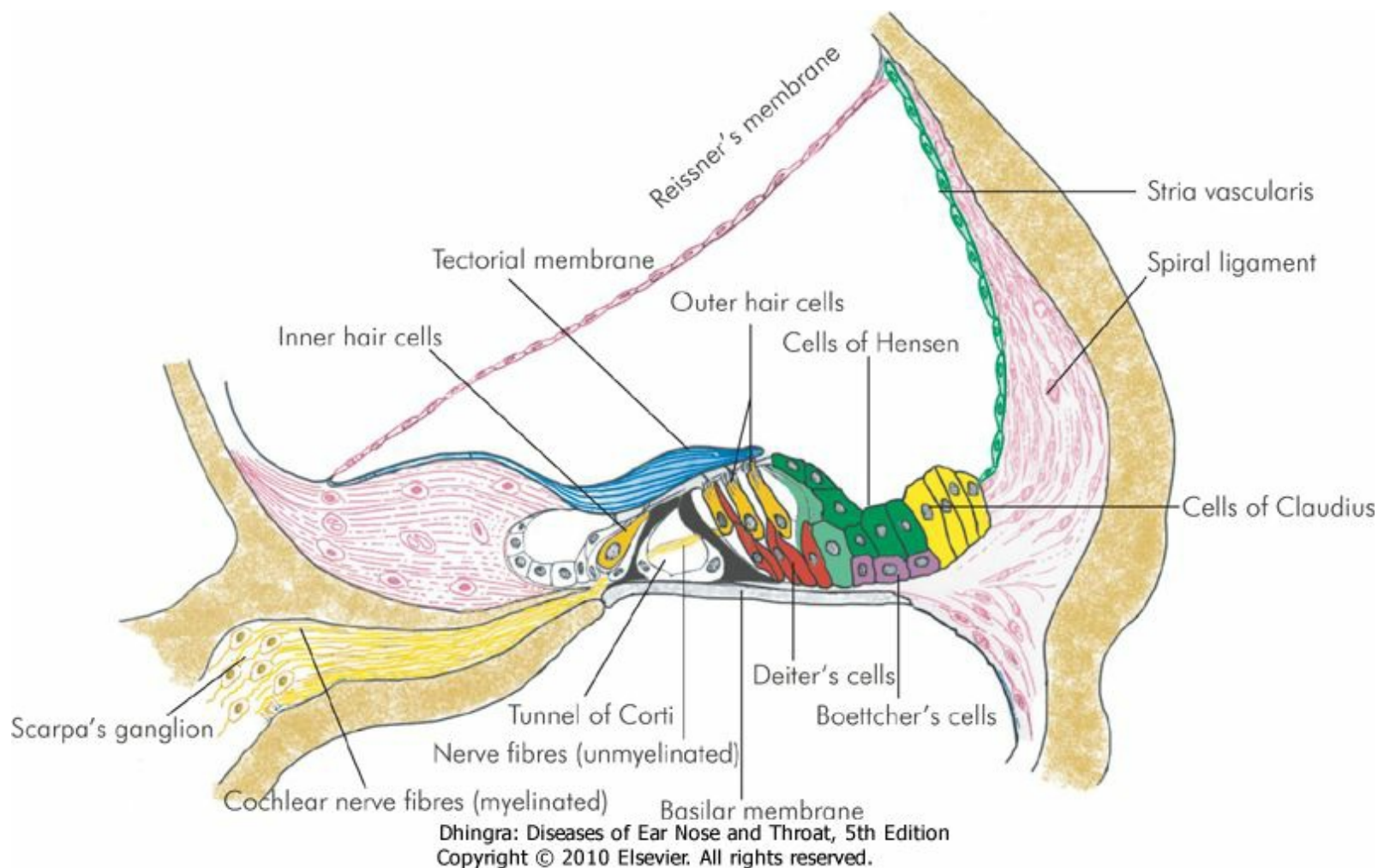


Figure 2.1 Structure of organ of Corti.

They are important receptor cells of hearing and transduce sound energy into electrical energy. Inner hair cells form a single row while outer hair cells are arranged in three or four rows. Inner hair cells are richly supplied by afferent cochlear fibres and are probably more important in the transmission of auditory impulses. Outer hair cells mainly receive efferent innervation from the olivary complex and are concerned with modulating the function of inner hair cells. Differences between inner and outer hair cells are given in Table 2.1.

##### 3. Supporting cell

Deiters' cells are situated between the outer hair cells and provide support to the latter. Cells of Hensen lie outside the Deiters' cells.

##### 4. Tectorial membrane

It consists of gelatinous matrix with delicate fibres. It overlies the organ of Corti. The shearing force between the hair cells and tectorial membrane produces the stimulus to hair cells.

**Table 2-1. Differences between inner and outer hair cells**

	<b>Inner hair cells</b>	<b>Outer hair cells</b>
Total no.	3500	12,000
Rows	One row	Three or four rows
Shape	Flask-shaped	Cylindrical
Nerve supply	Primarily afferent fibres and very few efferent	Mainly efferent fibres and very few afferent
Development	Develop earlier	Develop late
Function	Transmit auditory stimuli	Modulate function of inner hair cells
Vulnerability	More resistant	Easily damaged by ototoxic drugs and high intensity noise

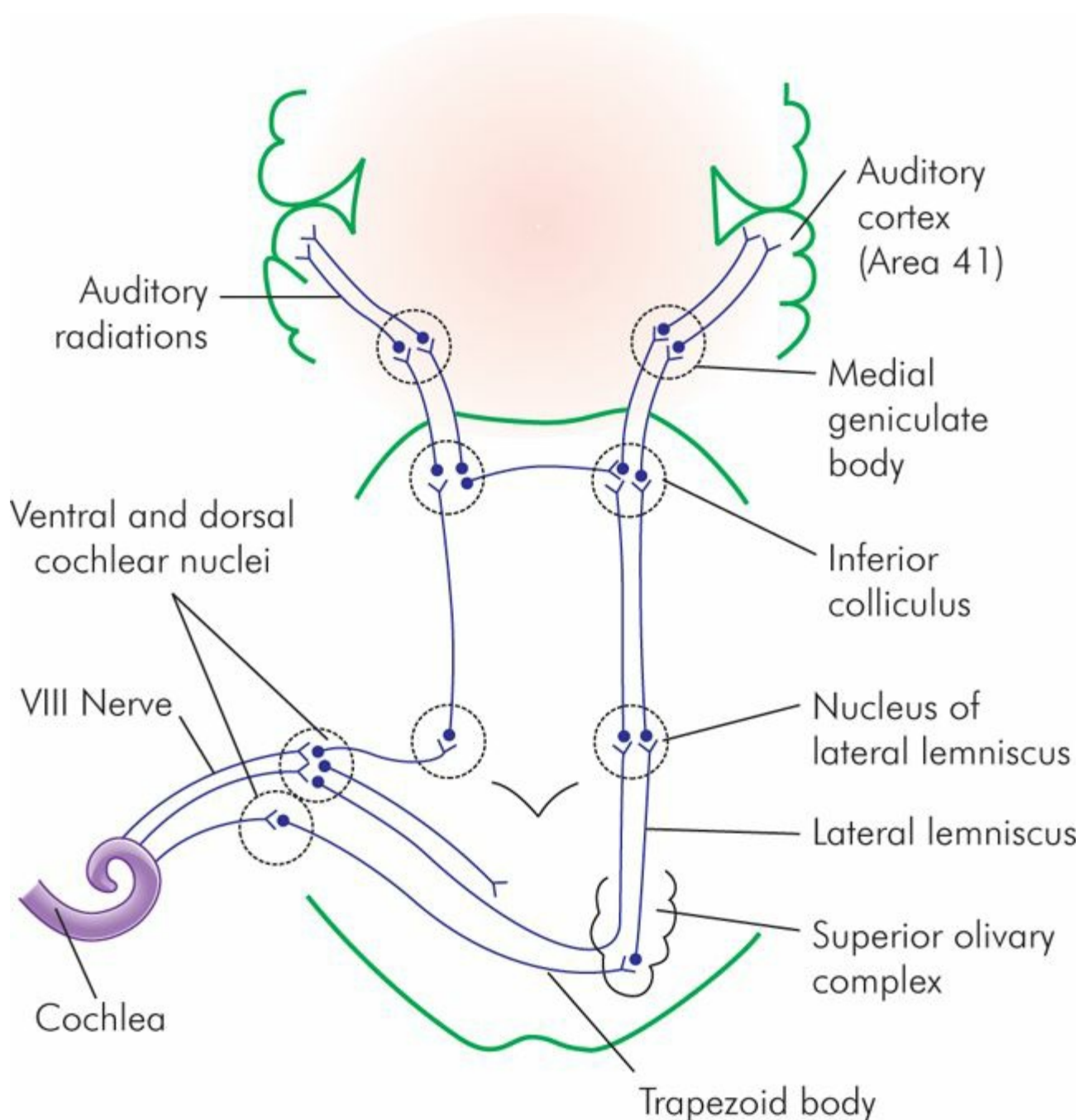
## Nerve Supply of Hair Cells

Ninety-five percent of afferent fibres of spiral ganglion supply the inner hair cells while only 5% supply the outer hair cells. Efferent fibres to the hair cells come from the olivocochlear bundle. Their cell bodies are situated in superior olivary complex. Each cochlea sends innervation to both sides of the brain.

## Auditory Neural Pathways and their Nuclei (Fig. 2.2)

Hair cells are innervated by dendrites of bipolar cells of spiral ganglion which is situated in Rosenthal's canal (canal running along the osseous spiral lamina). Axons of these bipolar cells form the cochlear division of CN VIII and end in the cochlear nuclei, the dorsal and ventral, on each side of the medulla. Further course of auditory pathways is complex. From cochlear nuclei, the main nuclei in the ascending auditory pathways, sequentially, from below upwards, are:

- (a) Superior olivary complex
- (b) Nucleus of lateral lemniscus
- (c) Inferior colliculus
- (d) Medial geniculate body
- (e) Auditory cortex.



Dhingra: Diseases of Ear Nose and Throat, 5th Edition  
Copyright © 2010 Elsevier. All rights reserved.

Figure 2.2 Auditory pathways from the right cochlea. Note bilateral route through brainstem and bilateral cortical representation.

The auditory fibres travel via the ipsilateral and contralateral routes and have multiple decussation points. Thus each ear is represented in both cerebral hemispheres. The area of cortex, concerned with hearing is situated in the superior temporal gyrus (Brodmann's area 41). For auditory pathways, remember the mnemonic E.COLI-MA: Eighth nerve, Cochlear nuclei, Olivary complex, Lateral lemniscus, Inferior colliculus, Medial geniculate body and Auditory cortex.

## **PHYSIOLOGY OF HEARING**

Any vibrating object causes waves of compression and rarefaction and is capable of producing sound. In the air, at 20°C and at sea level, sound travels at a speed of 344 metres (1 120 feet) per second. It travels faster in liquids and solids than in the air. Also, when sound energy has to pass from air to liquid medium, most of it is reflected because of the impedance offered by the liquid.



A sound signal in the environment is collected by the pinna, passes through external auditory canal and strikes the tympanic membrane. Vibrations of the tympanic membrane are transmitted to stapes footplate through a chain of ossicles coupled to the tympanic membrane. Movements of stapes footplate cause pressure changes in the labyrinthine fluids which move the basilar membrane. This stimulates the hair cells of the organ of Corti. It is these hair cells which act as transducers and convert the mechanical energy into electrical impulses which travel along the auditory nerve. Thus, the mechanism of hearing can be broadly divided into:

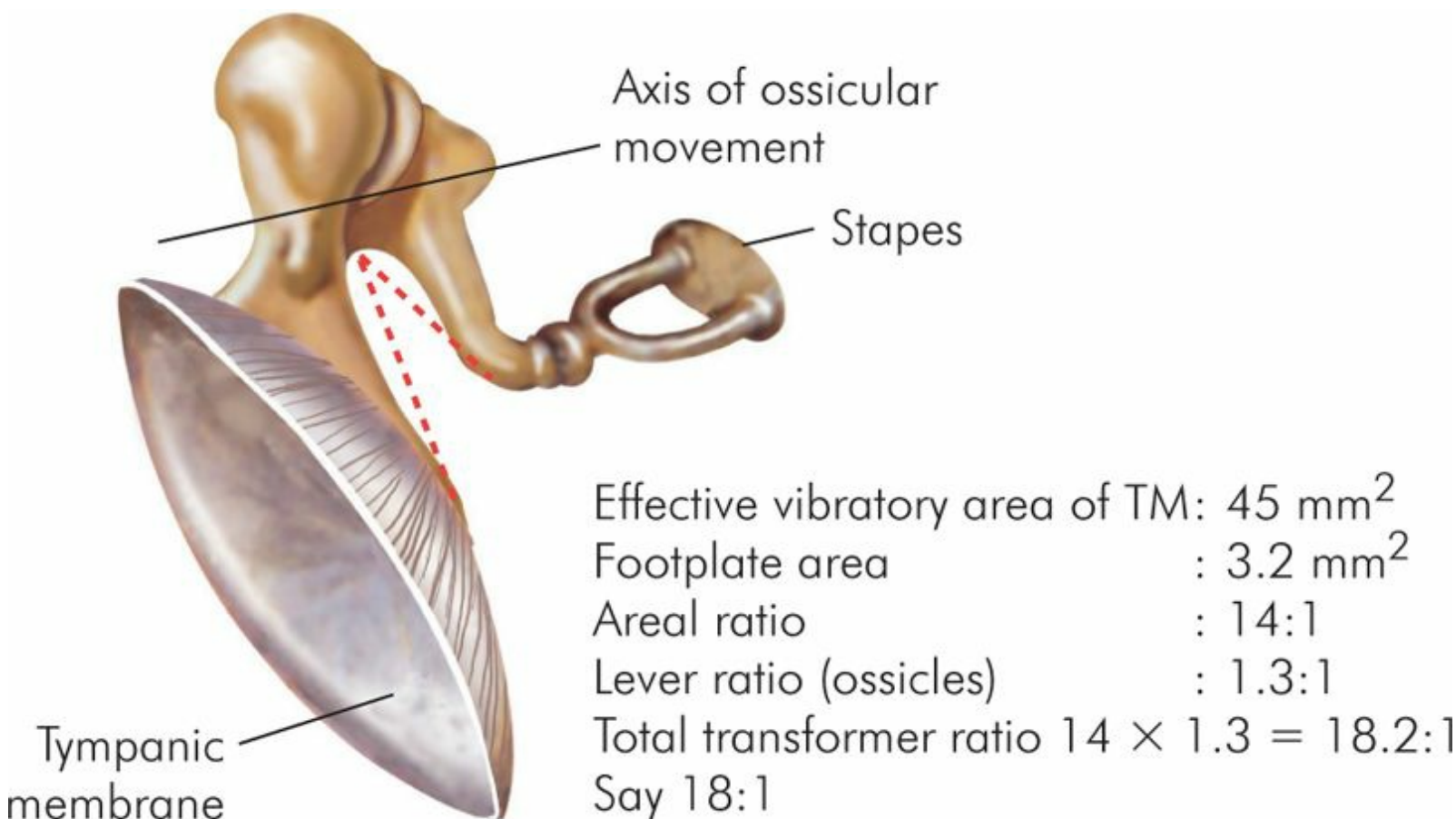
- 1. Mechanical conduction of sound (conductive apparatus).
- 2. Transduction of mechanical energy to electrical impulses (sensory system of cochlea).
- 3. Conduction of electrical impulses to the brain (neural pathways).

## 1. Conduction of Sound

A person under water cannot hear any sound made in the air because 99.9% of the sound energy is reflected away from the surface of water because of the impedance offered by it. A similar situation exists in the ear when air-conducted sound has to travel to cochlear fluids. Nature has compensated for this loss of sound energy by interposing the middle ear which converts sound of greater amplitude, but lesser force, to that of lesser amplitude but greater force. This function of the middle ear is called *impedance matching mechanism* or the *transformer action*.

It is accomplished by:

- (a) *Lever action of the ossicles*. Handle of malleus is 1.3 times longer than long process of the incus, providing a mechanical advantage of 1.3.
- (b) *Hydraulic action of tympanic membrane*. The area of tympanic membrane is much larger than the area of stapes footplate, the average ratio between the two being 21:1. As the effective vibratory area of tympanic membrane is only two-thirds, the effective areal ratio is reduced to 14:1, and this is the mechanical advantage provided by the tympanic membrane (Fig. 2.3).  
The product of areal ratio and lever action of ossicles is 18:1.  
According to some workers (Wever & Lawrence) out of a total of 90 mm<sup>2</sup> area of human tympanic membrane, only 55 mm<sup>2</sup> is functional and given the area of stapes footplate (3.2 mm<sup>2</sup>), the areal ratio is 17:1 and total transformer ratio (17 × 1.3) is 22.1.
- (c) *Curved membrane effect*. Movements of tympanic membrane are more at the periphery than at the centre where malleus handle is attached. This too provides some leverage.



**Phase differential between oval and round windows**

Sound waves striking the tympanic membrane do not reach the oval and round windows simultaneously. There is a preferential pathway to the oval window because of the ossicular chain. Thus, when oval window is receiving wave of compression, the round window is at the phase of rarefaction. If the sound waves were to strike both the windows simultaneously, they would cancel each other's effect with no movement of the perilymph and no hearing. This acoustic separation of windows is achieved by the presence of intact tympanic membrane and a cushion of air in the middle ear around the round window. Phase differential between the windows contributes 4 dB when tympanic membrane is intact.

**Natural resonance of external and middle ear**

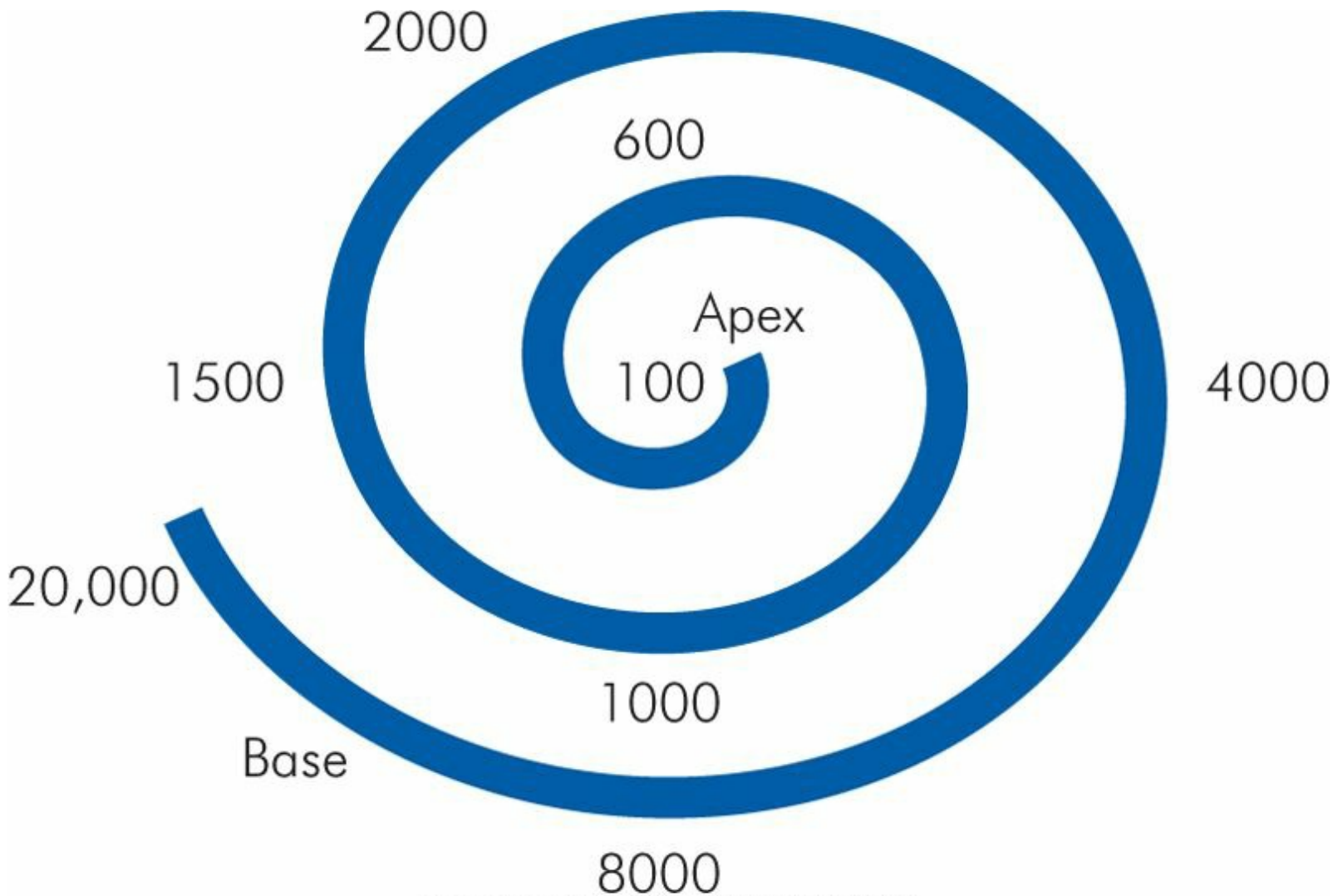
Inherent anatomic and physiologic properties of the external and middle ear allow certain frequencies of sound to pass more easily to the inner ear due to their natural resonances. Natural resonance of external ear canal is 3000 Hz and that of middle ear 800 Hz. Frequencies most efficiently transmitted by ossicular chain are between 500 and 2000 Hz while that by tympanic membrane is 800-1600 Hz. Thus greatest sensitivity of the sound transmission is between 500 and 3000 Hz and these are the frequencies most important to man in day to day conversation (Table 2.2).

**2. Transduction of Mechanical Energy to Electrical Impulses**

Movements of the stapes footplate, transmitted to the cochlear fluids, move the basilar membrane, setting up shearing force between the tectorial membrane and the hair cells. The distortion of hair cells gives rise to cochlear microphonics which trigger the nerve impulse.

**Table 2-2. Natural resonance and efficiency of auditory apparatus**

External auditory canal	3000 Hz
Tympanic membrane	800-1600 Hz
Middle ear	800 Hz
Ossicular chain	500-2000 Hz



Dhingra: Diseases of Ear Nose and Throat, 5th Edition  
 Copyright © 2010 Elsevier. All rights reserved.

Figure 2.4 Frequency localisation in the cochlea. Higher frequencies are localised in the basal turn and then progressively decrease towards the apex.

A sound wave, depending on its frequency, reaches maximum amplitude on a particular place on the basilar membrane and stimulates that segment (*travelling wave theory of von Békésy*). Higher frequencies are represented in the basal turn of the cochlea and the progressively lower ones towards the apex (Fig. 2.4).

### 3. Neural Pathways

Hair cells get innervation from the bipolar cells of spiral ganglion. Central axons of these cells collect to form cochlear nerve which goes to ventral and dorsal cochlear nuclei. From there, both crossed and uncrossed fibres travel to the superior olivary nucleus, lateral lemniscus, inferior colliculus, medial geniculate body and finally reach the auditory cortex of the temporal lobe.

# Electrical Potentials of Cochlea and CN VIII

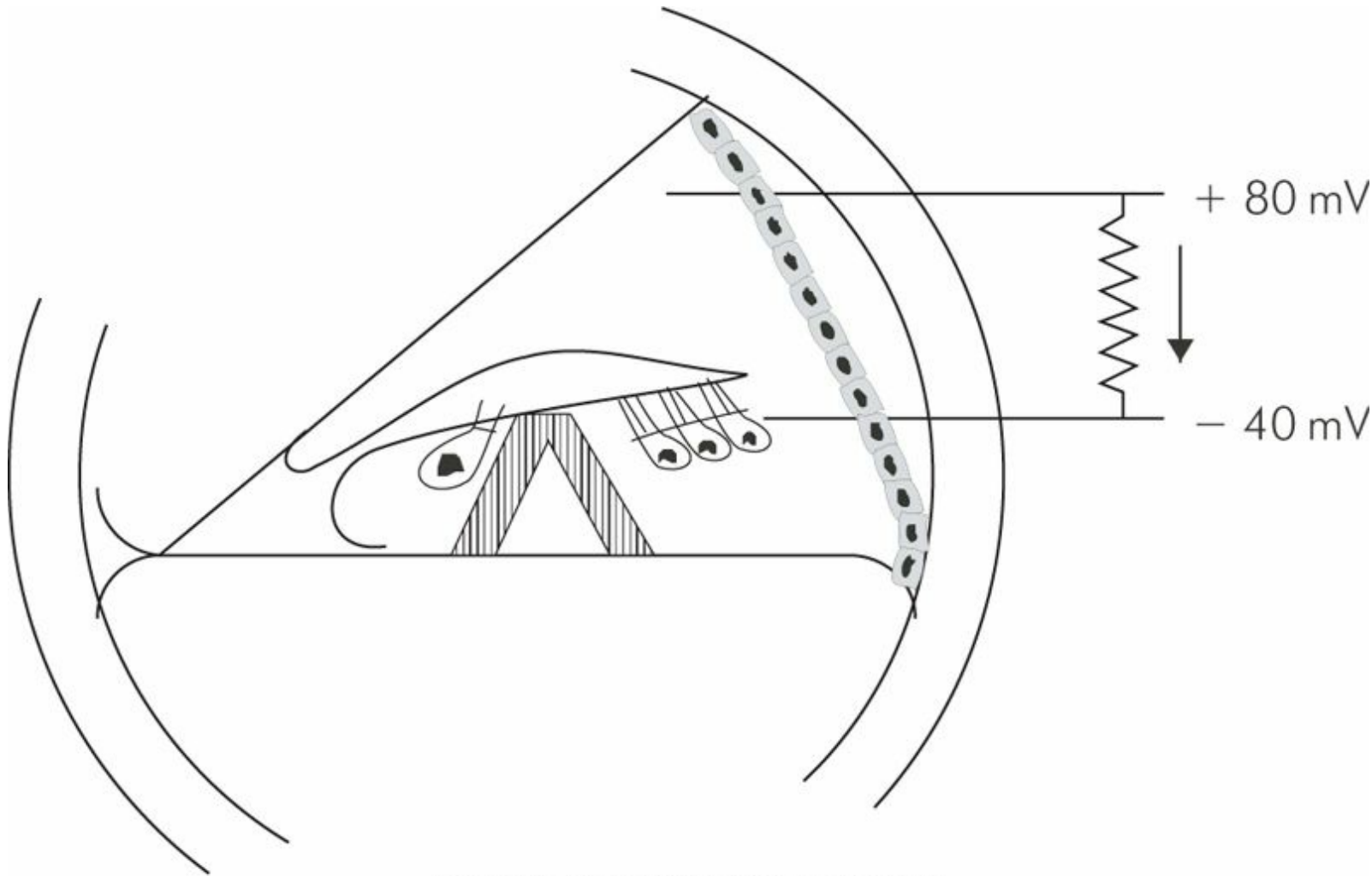
1. Endocochlear potential	
2. Cochlear microphonic	from cochlea
3. Summating potential	
4. Compound action potential	from nerve fibres

Four types of potentials have been recorded; three from the cochlea and one from CN VIII fibres. They are:

## 1. Endocochlear potential

It is a direct current (DC) potential recorded from scala media. It is +80 mV and is generated from the stria vascularis by  $\text{Na}^+/\text{K}^+$ -ATPase pump and provides source of energy for cochlear transduction (Fig. 2.5). It is present at rest and does not require sound stimulus. This potential provides a sort of "battery" to drive the current through hair cells when they move in response to a sound stimulus.

## 2. Cochlear microphonic (CM)



Dhingra: Diseases of Ear Nose and Throat, 5th Edition  
Copyright © 2010 Elsevier. All rights reserved.

Figure 2.5 Davis' battery model of cochlear transduction. Scala media has a DC potential of +80 mV. Stimulation of hair cells produces intracellular potential of -40 mV. This provides flow of current of 120 mV through the top of hair cells.

When basilar membrane moves in response to sound stimulus, electrical resistance at the tips of hair cells changes allowing flow of  $\text{K}^+$  through hair cells and produces voltage fluctuations called cochlear microphonic. It is an alternating current (AC) potential.

## 3. Summating potential (SP)

It is a DC potential and follows "envelope" of stimulating sound. It is produced by hair cells. It may be negative or positive. SP has been used in diagnosis of Mèniere's disease. It is superimposed on VIII nerve action potential.

Both CM and SP are receptor potentials as seen in other sensory end-organs. They differ from action potentials in that (a) they are graded rather than all or none phenomenon, (b) have no latency, (c) are not propagated and (d) have no post-response refractory period.

# VESTIBULAR SYSTEM

## Peripheral Receptors

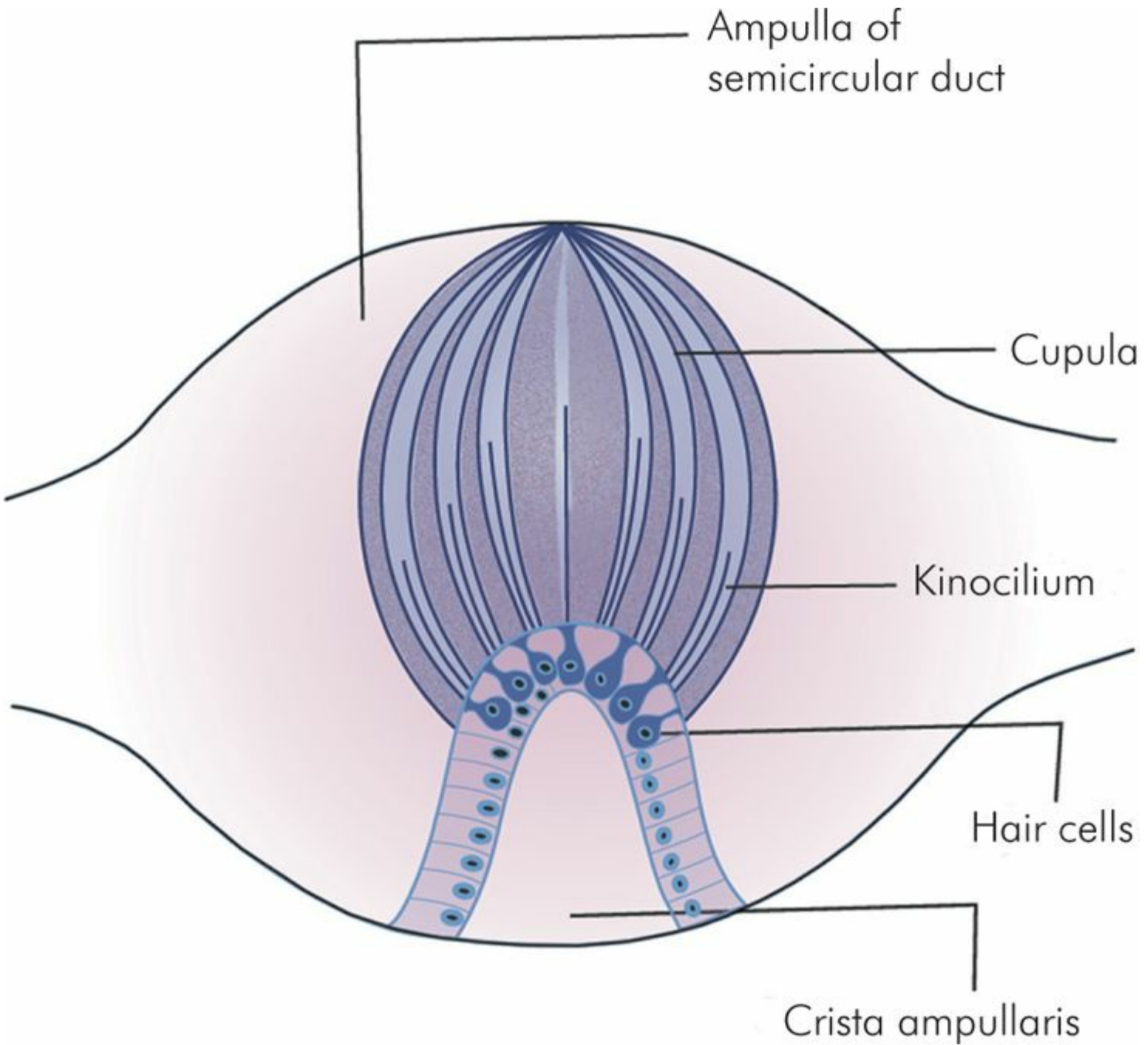
They are of two types:

### 1. Cristae

They are located in the ampullated ends of the three semicircular ducts. These receptors respond to angular acceleration.

### 2. Maculae

page 19  
page 20



Dhingra: Diseases of Ear Nose and Throat, 5th Edition  
Copyright © 2010 Elsevier. All rights reserved.

Figure 2.6 Structure of ampullary end of semicircular duct. Over the crista lie sensory hair cells interspersed with supporting cells. Hair from sensory cells project into the gelatinous substance of cupula.

They are located in otolith organs (i.e. utricle and saccule). Macula of the utricle lies in its floor in a horizontal plane. Macula of saccule lies in its medial wall in a vertical plane. They sense position of head in response to gravity and linear acceleration.

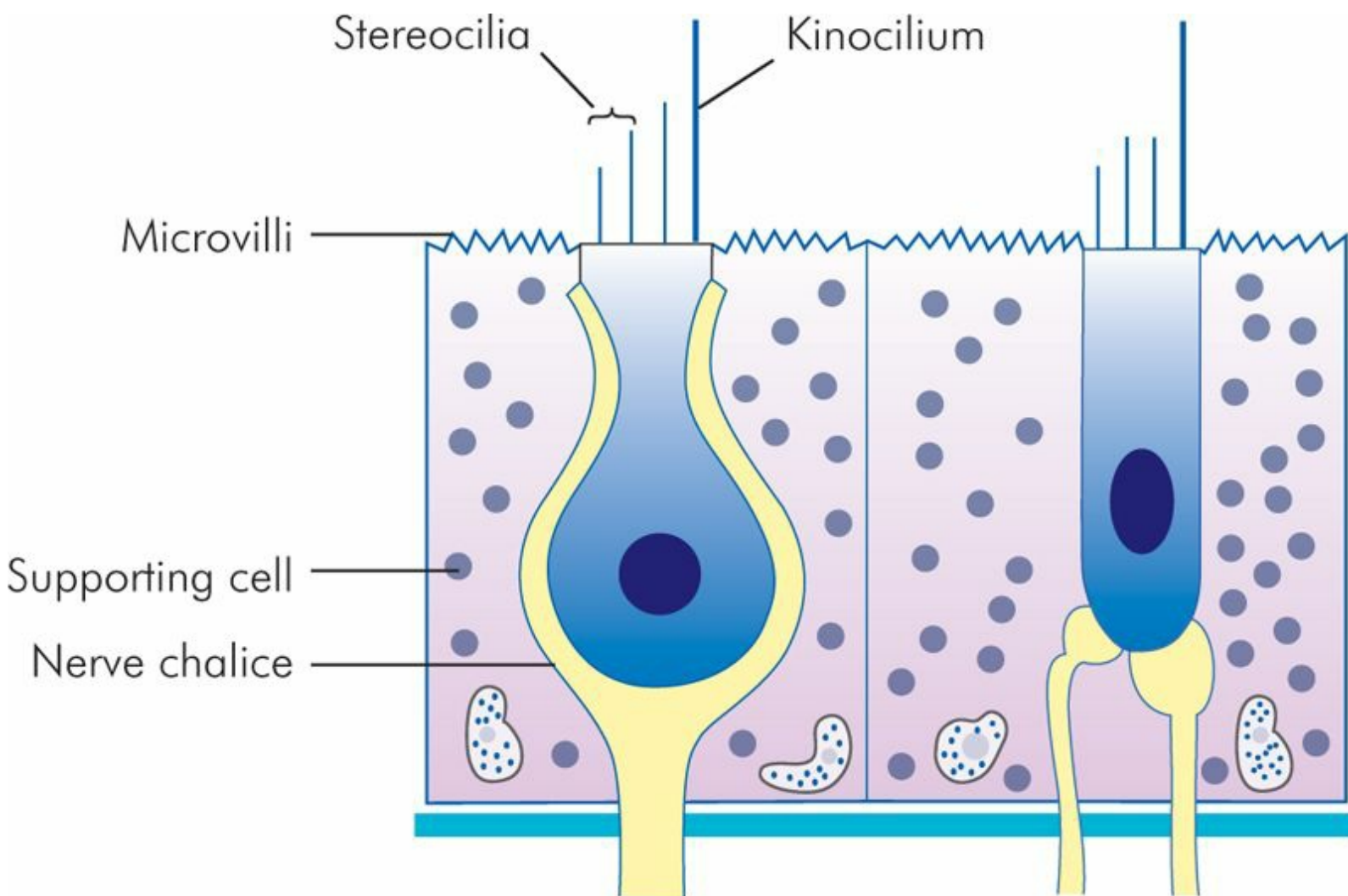
### Structure of a crista (Fig. 2.6)

It is a crest-like mound of connective tissues on which lie the sensory epithelial cells. The cilia of the sensory hair cells project into the cupula which is a gelatinous mass extending from the surface of crista to the ceiling of the ampulla and forms a water tight partition, only to be displaced to one or the other side like a swing door, with movements of endolymph. The gelatinous mass of cupula consists of polysaccharide and contains canals into which project the cilia of sensory cells.

Hair cells are of two types (Fig. 2.7). *Type I* cells are flask-shaped with a single large cup-like nerve terminal surrounding the base. *Type II* cells are cylindrical with multiple nerve terminals at the base. From the upper surface of each cell, project a single hair, the kinocilium and a number of other cilia, the stereocilia. The kinocilium is thicker and is located on the edge of the cell. Sensory cells are surrounded by supporting cells which show microvilli on their upper ends.

### Structure of macula

A macula consists mainly of two parts: (a) a sensory neuroepithelium, made up of type I and type II cells, similar to those in the crista; (b) an otolithic membrane, which is made up of a gelatinous mass and on the top, the crystals of calcium carbonate called *otoliths* or *otoconia* (Fig. 2.8). The cilia of hair cells project into the gelatinous layer. The linear, gravitational and head tilt movements cause displacement of otolithic membrane and thus stimulate the hair cells which lie in different planes.



Dhingra: Diseases of Ear Nose and Throat, 5th Edition  
Copyright © 2010 Elsevier. All rights reserved.

Figure 2.7 Sensory hair cells of the vestibular organs. Type I (left) and Type II (right).

## Vestibular Nerve

Vestibular or Scarpa's ganglion is situated in the lateral part of the internal acoustic meatus. It contains bipolar cells. The distal processes of bipolar cells innervate the sensory epithelium of the labyrinth while its central processes aggregate to form the vestibular nerve.

## Central Vestibular Connections

The fibres of vestibular nerve end in vestibular nuclei and some go to the cerebellum directly.

Vestibular nuclei are four in number, the superior, medial, lateral and descending. *Afferents* to these nuclei come from:

- (i) Peripheral vestibular receptors (semicircular canals, utricle and saccule)
- (ii) Cerebellum
- (iii) Reticular formation
- (iv) Spinal cord
- (v) Contralateral vestibular nuclei.

Thus, information received from the labyrinthine receptors is integrated with information from other somatosensory systems.

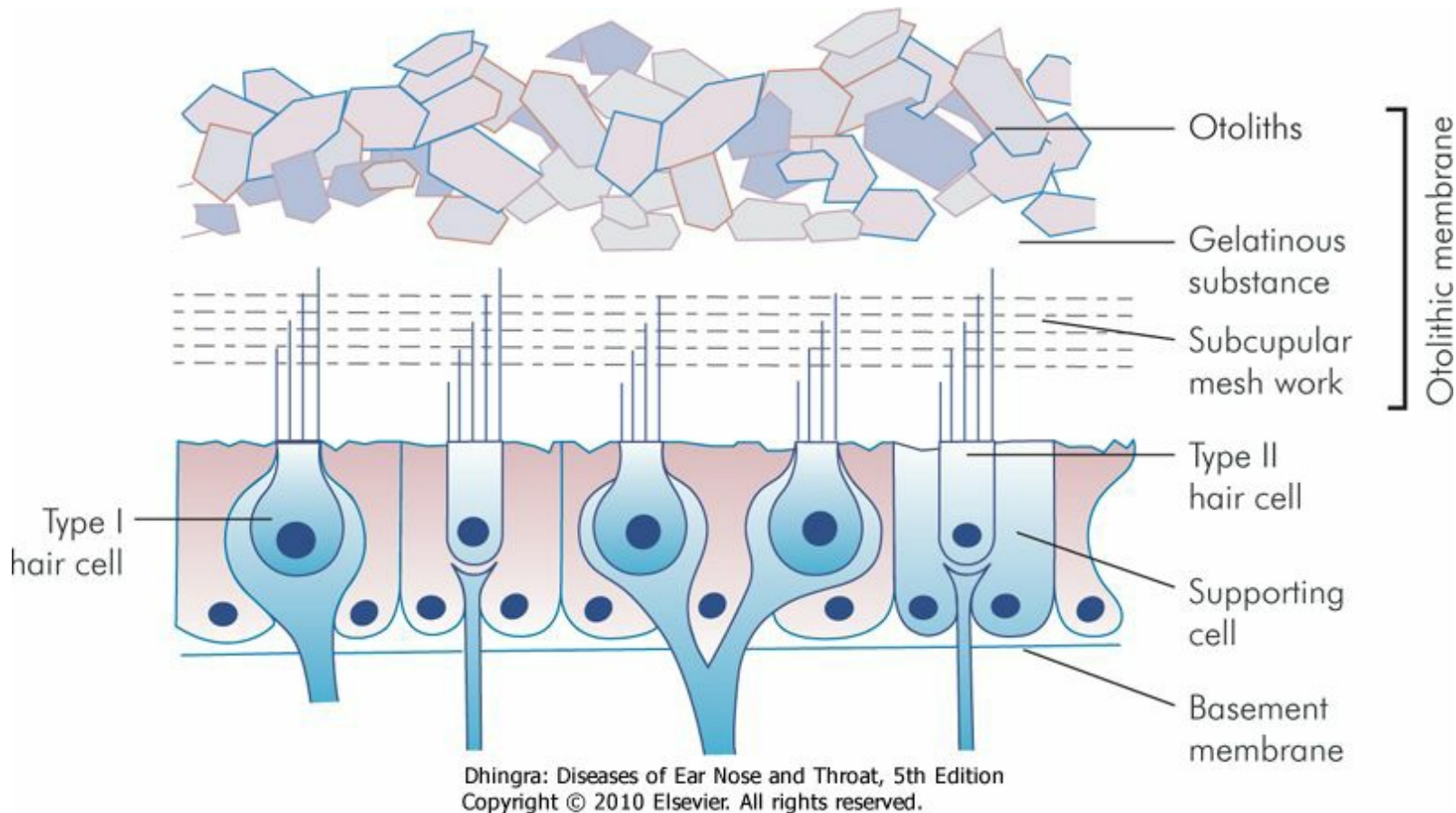


Figure 2.8 Structure of macula, the sensory end organ of the utricle and the saccule.

*Efferents* from vestibular nuclei go to:

- (i) Nuclei of CN III, IV, VI via medial longitudinal bundle. It is the pathway for vestibulo-ocular reflexes and this explains the genesis of nystagmus.
- (ii) Motor part of spinal cord (vestibulospinal fibres). This coordinates the movements of head, neck and body in the maintenance of balance.
- (iii) Cerebellum (vestibulocerebellar fibres). It helps to coordinate input information to maintain the body balance.
- (iv) Autonomic nervous system. This explains nausea, vomiting, palpitation, sweating and pallor seen in vestibular disorders (e.g. Meniere's disease).
- (v) Vestibular nuclei of the opposite side.
- (vi) Cerebral cortex (temporal lobe). This is responsible for subjective awareness of motion.



# PHYSIOLOGY OF VESTIBULAR SYSTEM

Vestibular system is conveniently divided into:

- **(a) *Peripheral***, which is made up of membranous labyrinth (semicircular ducts, utricle and saccule) and vestibular nerve.
- **(b) *Central***, which is made up of nuclei and fibre tracts in the central nervous system to integrate vestibular impulses with other systems to maintain body balance.

## Semicircular Canals

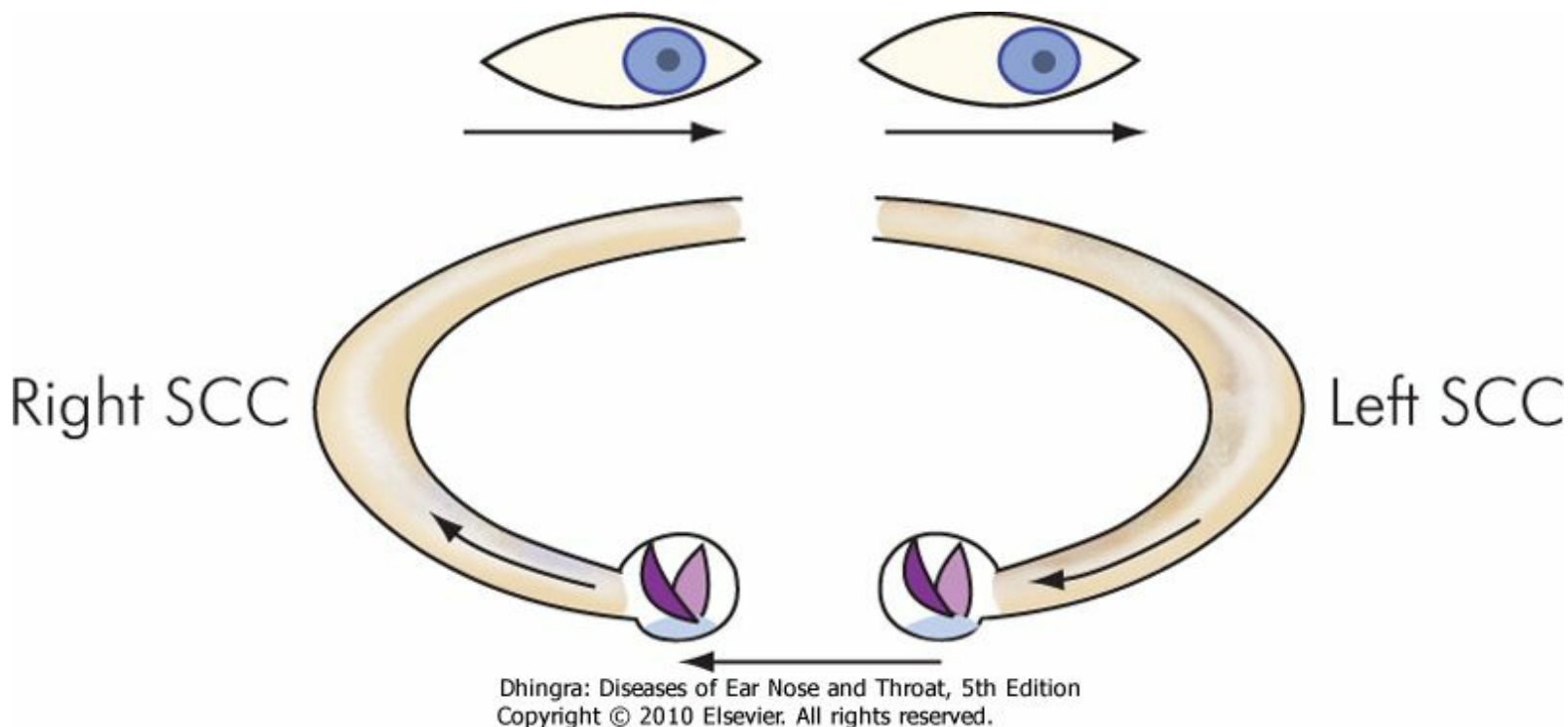


Figure 2.9 Rotation test. At the end of rotation to the right, semicircular canals stop but endolymph continues to move to the right, i.e. towards the left ampulla but away from the right, causing nystagmus to the left.

They respond to angular acceleration and deceleration. The three canals lie at right angles to each other but the one which lies at right angles to the axis of rotation is stimulated the most. Thus horizontal canal will respond maximum to rotation on the vertical axis and so on. Due to this arrangement of the three canals in three different planes, any change in position of head can be detected. Stimulation of semicircular canals produces nystagmus and the direction of nystagmus is determined by the plane of the canal being stimulated. Thus, nystagmus is horizontal from horizontal canal, rotatory from the superior canal, and vertical from the posterior canal.

The stimulus to semicircular canal is flow of endolymph which displaces the cupula. The flow may be towards the cupula (ampullopetal) or away from it (ampullofugal), better called utriculopetal and utriculofugal. Ampullopetal flow is more effective than ampullofugal for the horizontal canal. The quick component of nystagmus is always opposite to the direction of flow of endolymph. Thus, if a person is rotated to the right for sometime and then abruptly stopped, the endolymph continues to move to the right due to inertia (i.e. ampullopetal for left canal), the nystagmus will be horizontal and directed to the left (Fig. 2.9).

Utricle is stimulated by linear acceleration and deceleration or gravitational pull during the head tilts. The sensory hair cells of the macula lie in different planes and are stimulated by displacement of otolithic membrane during the head tilts.

The function of sacculle is similar to that of utricle as the structure of maculae in the two organs is similar but experimentally, the sacculle is also seen to respond to sound vibrations.

The vestibular system thus registers changes in the head position, linear or angular acceleration and deceleration and gravitational effects. This information is sent to the central nervous system where information from other systems-visual, auditory, somatosensory (muscles, joints, tendons, skin)-is also received. All this information is integrated and used in the regulation of equilibrium and body posture.

Cerebellum, which is also connected to vestibular end organs further coordinates muscle movements in their rate, range, force and duration and thus helps in the maintenance of balance.

## Maintenance of Body Equilibrium

A useful clinical approach to understand the physiology of equilibrium is to imagine that the balance system (vestibular, visual and somatosensory) is a two-sided push and pull system. In static neutral position, each side contributes equal sensory information, i.e. push and pull system of one side is equal to that of the other side. If one side pulls more than the other, balance of the body is disturbed. During movement, i.e. turning or tilt, there is a temporary change in the push and pull system which is corrected by appropriate reflexes and motor outputs to the eyes (vestibulo-ocular reflex), neck (vestibulocervical reflex), and trunk and limbs (vestibulospinal reflex) to maintain new position of head and body, but if any component of push and pull system of one side is disturbed for a longer time due to disease, vertigo and ataxia will develop.

## Vertigo and Dizziness

Disorientation in space causes vertigo or dizziness and can arise from disorders of any of the three systems, vestibular, visual or somatosensory. Normally, the impulses reaching the brain from the three systems are equal and opposite. If any component on one side is inhibited or stimulated, the information reaching the cortex is mismatched, resulting in disorientation and vertigo. The vestibular inhibition on one side (e.g. acute vestibular failure, labyrinthectomy, Meniere's disease, VIIIth nerve section) causes vertigo. Similarly, stimulation of labyrinth by thermal or rotational stimulus causes vertigo. Dizziness can similarly result from the ocular causes, e.g. high errors of refraction or acute extraocular muscle paralysis with diplopia.

Vertigo and its causes are discussed in detail in Chapter 7.

## Motion Sickness

It is characterised by nausea, vomiting, pallor and sweating during sea, air, bus or car travel in certain susceptible individuals. It can be induced by both real and apparent motion and is thought to arise from the mismatch of information reaching the vestibular nuclei and cerebellum from the visual, labyrinthine and somatosensory systems. It can be controlled by the usual labyrinthine sedatives.

This section aims to introduce certain terms which are frequently used in audiology and acoustics.

#### **Sound**

It is a form of energy produced by a vibrating object. A sound wave consists of compression and rarefaction of molecules of the medium (air, liquid or solid) in which it travels. Velocity of sound is different in different media. In the air, at 20°C, at sea level, sound travels 344 metres (1120 feet) per second, and is faster in liquid and still more fast in a solid medium.

#### **Frequency**

It is the number of cycles per second. The unit of frequency is Hertz (Hz) named after the German scientist Heinrich Rudolf Hertz. A sound of 1000 Hz means 1000 cycles per second.

#### **Pure tone**

A single frequency sound is called a pure tone, e.g. a sound of 250, 500 or 1000 Hz. In pure-tone audiometry, we measure the threshold of hearing in decibels for various pure tones from 125 to 8000 Hz.

#### **Complex sound**

Sound with more than one frequency is called a complex sound. Human voice is a complex sound.

#### **Pitch**

It is a subjective sensation produced by frequency of sound. Higher the frequency, greater is the pitch.

#### **Overtones**

A complex sound has a fundamental frequency, i.e. the lowest frequency at which a source vibrates. All frequencies above that tone are called the overtones. The latter determine the quality or the timbre of sound.

#### **Intensity**

Whisper	=	30 dB
Normal conversation	=	60 dB
Shout	=	90 dB
Discomfort of the ear	=	120 dB
Pain in the ear	=	130 dB

It is the strength of sound which determines its loudness. It is usually measured in decibels. At a distance of one metre, intensity of

#### **Loudness**

It is the subjective sensation produced by intensity. More the intensity of sound, greater the loudness.

#### **Decibel (dB)**

It is 1/10th of a bel and is named after Alexander Graham Bell, the inventor of telephone. It is not an absolute figure but represents a logarithmic ratio between two sounds, namely the sound being described and the reference sound. Sound can be measured as power, i.e. watts/cm<sup>2</sup> or as pressure, i.e. dynes/cm<sup>2</sup>. In audiology, sound is measured as sound pressure level (SPL). It is compared with the reference sound which has an SPL of 0.0002 dynes/cm<sup>2</sup> or 20 μPa (micropascals) which roughly corresponds to the threshold of hearing in normal subjects at 1000 Hz. Decibel notation was introduced in audiology to avoid dealing with large figures of sound pressure level (0.0002 dynes/cm<sup>2</sup> at normal threshold of hearing to 200 dynes/cm<sup>2</sup> which causes pain in the ear. The latter is 1,000,000 times the former).

$$\text{Sound in dB} = 10 \log \frac{\text{Power of } S_1}{\text{Power of } S_0}$$

$$\text{or } 10 \log \frac{(\text{SPL of } S_1)^2}{(\text{SPL of } S_0)^2}$$

$$\text{or } 20 \log \frac{\text{SPL of } S_1}{\text{SPL of } S_0}$$

Formula for decibel is:

- $S_1$  = sound being described
- $S_0$  = reference sound

(because power of sound is proportional to square of SPL)

If a sound has an SPL of 1000, i.e.  $(10^3)$  times the reference sound, it is expressed as  $20 \times 3 = 60$  dB. Similarly, a sound of 1,000,000, i.e.  $(10^6)$  times the reference sound SPL is expressed simply as 120 dB and so on.

## Noise

page 23

page 24

It is defined as an aperiodic complex sound. There are three types of noise:

- **(a) White noise.** It contains all frequencies in audible spectrum and is comparable to the white light which contains all the colours of the visible spectrum. It is a broad-band noise and is used for masking.
- **(b) Narrow band noise.** It is white noise with certain frequencies, above and below the given noise, filtered out. Thus, it has a frequency range smaller than the broad-band white noise. It is used to mask the test frequency in pure tone audiometry.
- **(c) Speech noise.** It is a noise having frequencies in the speech range (300-3000 Hz). All other frequencies are filtered out.

## Masking

It is a phenomenon to produce inaudibility of one sound by the presentation of another. In clinical audiometry, one ear is kept busy by a sound while the other is being tested. Masking of non-test ear is essential in all bone conduction tests, but for air conduction tests, it is required only when difference of hearing between two ears exceeds 40 dB.

## Sound pressure level (SPL)

The SPL of a sound in decibels is 20 times the logarithm to the base 10, of the pressure of a sound to the reference pressure. The reference pressure is taken as  $0.0002 \text{ dynes/cm}^2$  or  $20 \text{ } \mu\text{Pa}$  (micropascals) for a frequency of 1000 Hz and represents the threshold of hearing in normally hearing young adults.

## Frequency range in normal hearing

A normal person can hear frequencies of 20 to 20,000 Hz but in routine audiometric testing only 125 to 8000 Hz are evaluated.

## Speech frequencies

Frequencies of 500, 1000 and 2000 Hz are called *speech frequencies* as most of human voice falls within this range. PTA (pure tone average) is the average threshold of hearing in these three speech frequencies. It roughly corresponds to the speech reception threshold.

## Audiometric zero

Threshold of hearing, i.e. the faintest intensity which a normal healthy person can hear will vary from person to person. The International Standards Organisation (ISO) adopted a standard for this, which is represented as the zero level on the audiometer. *According to ISO, audiometric zero is the mean value of minimal audible intensity in a group of normally hearing healthy young adults.*

## Hearing level (HL)

It is the sound pressure level produced by an audiometer at a specific frequency. It is measured in decibels with reference to audiometric zero. If an audiometer delivers a sound at 70 dB, it is represented as 70 dB HL.

## Sensation level (SL)

It refers to the level of sound above the threshold of hearing for an individual. If someone is tested at 40 dB SL, it means he was tested at 40 dB above his threshold. For a normal person, this would be a sound of  $0 + 40$ , i.e. 40 dB HL, but for one with a hearing loss of say 30 dB, it would be  $30 + 40$ , i.e. 70 dB HL. In other words, *sensation level refers to the sound which will produce the same sensation, as in normally hearing person.* In speech audiometry, discrimination scores are tested at 30 to 40 dB SL. Stapedial reflex is elicited with a sound of 70-100 dB SL.

## Most comfortable level (MCL)

It is the intensity level of sound that is most comfortable for the person.

## Loudness discomfort level

It is the level of sound which produces discomfort in the ear. Usually, it is 90-105 dB SL. It is important to find the loudness discomfort level of a person when prescribing a hearing aid.



***Dynamic range***

It is the difference between the most comfortable level and the loudness discomfort level. The dynamic range is reduced in patients with positive recruitment phenomenon, as is the case in cochlear type of hearing loss.

***Sound level meter***

It is an instrument to measure level of noise and other sounds. Sound level meters have different weighting networks (e.g. A, B or C) for different sensitivities at different frequencies. When describing a sound measured by a sound level meter, the weighting network must be indicated.

Noise levels are often expressed as dB(A) which refers to sound pressure level measured with "A" network where the low and extremely high frequencies are given much less weightage compared to those in the middle range which are more important and are responsible for noise-induced hearing loss.

Hearing loss can be of three types:

### 1. *Conductive hearing loss*

It is caused by any disease process interfering with the conduction of sound from the external ear to the stapediovestibular joint. Thus the cause may lie in the external ear (obstructions), tympanic membrane (perforation), middle ear (fluid), ossicles (fixation or disruption) or the eustachian tube (obstruction).

### 2. *Sensorineural (SN) hearing loss*

It results from lesions of the cochlea (sensory type) or VIIIth nerve and its central connections (neural type). The term *retrocochlear* is used when hearing loss is due to lesions of VIIIth nerve, and *central deafness*, when it is due to lesions of central auditory connections.

### 3. *Mixed hearing loss*

In this type, elements of both conductive and sensorineural deafness are present in the same ear. There is air-bone gap indicating conductive element, and impairment of bone conduction indicating sensorineural loss. Mixed hearing loss is seen in some cases of otosclerosis and chronic suppurative otitis media.

While assessing the auditory function it is important to find out:

- **(a) Type of hearing loss** (conductive, sensorineural or mixed).
- **(b) Degree of hearing loss** (mild, moderate, moderately severe, severe, profound or total).
- **(c) Site of lesion.** If conductive, the lesion may be at external ear, tympanic membrane, middle ear, ossicles or eustachian tube. Clinical examination and tympanometry can be helpful to find the site of such lesions. If sensorineural, find out whether the lesion is cochlear, retrocochlear or central. Special tests of hearing will be required to differentiate these types.
- **(d) Cause of hearing loss.** The cause may be congenital, traumatic, infective, neoplastic, degenerative, metabolic, ototoxic, vascular or autoimmune process. Detailed history and laboratory investigations are required.

# ASSESSMENT OF HEARING

Hearing of an individual can be tested by clinical and audiometric tests.

## A. Clinical Tests of Hearing

- 1. Finger friction test
- 2. Watch test
- 3. Speech tests
- 4. Tuning fork tests.

### 1. Finger Friction Test

It is a rough but quick method of screening and consists of rubbing or snapping the thumb and a finger close to patient's ear.

### 2. Watch Test

A clicking watch is brought close to the ear and the distance at which it is heard, is measured. It had been popular as a screening test before the audiometric era but is practically obsolete now.

### 3. Speech (Voice) Tests

Normally, a person hears conversational voice at 12 metres (40 feet) and whisper (with residual air after normal expiration) at 6 metres (20 feet) but for purposes of test, 6 metres is taken as normal for both conversation and whisper.

The test is conducted in reasonably quiet surroundings. The patient stands with his test ear towards the examiner at a distance of 6 metres. His eyes are shielded to prevent lipreading and the non-test ear is blocked by intermittent pressure on the tragus by an assistant. The examiner uses spondee words (e.g. black-night, football, daydream) or numbers with letters (X3B, 2AZ, M6D) and gradually walks towards the patient.

page 25

page 26

The distance at which conversational voice and the whispered voice are heard is measured. The disadvantage of speech tests is lack of standardisation in intensity and pitch of voice used for testing and the ambient noise of the testing place.

### 4. Tuning Fork Tests

These tests are performed with tuning forks of different frequencies such as 128, 256, 512, 1024, 2048 and 4096 Hz, but for routine clinical practice, tuning fork of 512 Hz is ideal. Forks of lower frequencies produce sense of bone vibration while those of higher frequency have a shorter decay time and are thus not routinely preferred.

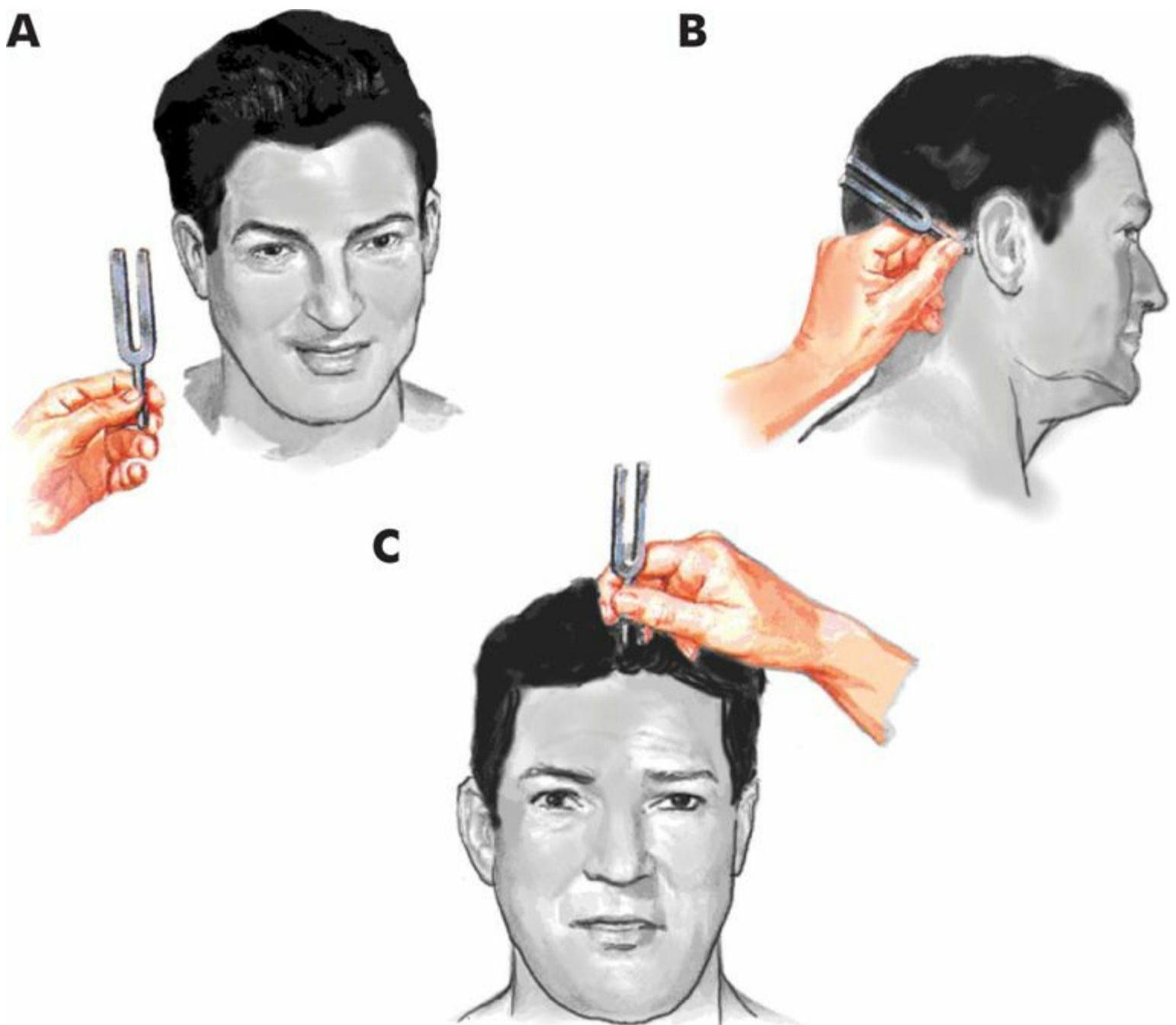
A tuning fork is activated by striking it gently against the examiner's elbow, heel of hand or the rubber heel of the shoe.

*To test air conduction (AC)* (Fig. 4.1), a vibrating fork is placed vertically, about 2 cm away from the opening of external auditory meatus. The sound waves are transmitted through the tympanic membrane, middle ear and ossicles to the inner ear. Thus, by the air conduction test, the function of both the conducting mechanism and the cochlea are tested. Normally, hearing through air conduction is louder and heard twice as long as through the bone conduction route.

*To test bone conduction (BC)*, the footplate of vibrating tuning fork is placed firmly on the mastoid bone. Cochlea is stimulated directly by vibrations conducted through the skull bones. Thus, BC is a measure of the cochlear function only.

The clinically useful tuning fork tests include:

#### (a) Rinne test



Dhingra: Diseases of Ear Nose and Throat, 5th Edition  
Copyright © 2010 Elsevier. All rights reserved.

Figure 4.1 Tuning fork tests. (A) Testing for air conduction. (B) Testing for bone conduction. (C) Weber test.

In this test air conduction of the ear is compared with its bone conduction. A vibrating tuning fork is placed on the patient's mastoid and when he stops hearing, it is brought beside the meatus. If he still hears, AC is more than BC. Alternatively, the patient is asked to compare the loudness of sound heard through air and bone conduction. Rinne test is called positive when AC is longer or louder than BC. It is seen in normal persons or those having sensorineural deafness. A negative Rinne (BC > AC) is seen in conductive deafness. A negative Rinne indicates a minimum air-bone gap of 15-20 dB.

A prediction of air-bone gap can be made if tuning forks of 256, 512 and 1024 Hz are used.

- A Rinne test equal or negative for 256 Hz but positive for 512 Hz indicates air-bone gap of 20-30 dB.
- A Rinne test negative for 256 and 512 Hz but positive for 1024 Hz indicates air-bone gap of 30-45 dB.
- A Rinne negative for all the three tuning forks of 256, 512 and 1024 Hz, indicates air-bone gap of 45-60 dB.

Remember that a negative Rinne for 256, 512 and 1024 Hz indicates a minimum AB gap of 15, 30, 45 dB respectively.

**False negative Rinne.** It is seen in severe unilateral sensorineural hearing loss. Patient does not perceive any sound of tuning fork by air conduction but responds to bone conduction testing. This response to bone conduction is, in reality, from the opposite ear because of transcranial transmission of sound. In such cases, correct diagnosis can be made by masking the non-test ear with Barany's noise box while testing for bone conduction. Weber test will further help as it gets lateralised to the better ear.

### (b) Weber test

In this test, a vibrating tuning fork is placed in the middle of the forehead or the vertex and the patient is asked in which ear the sound is heard. Normally, it is heard equally in both ears. It is lateralised to the worse ear in conductive deafness and to the better ear in sensorineural deafness. In weber test, sound travels directly to the cochlea via bone. Lateralisation of sound in weber test with a tuning fork of 512 Hz implies a conductive loss of 15-25 dB in ipsilateral ear or a sensorineural loss in the contralateral ear.

### (c) Absolute bone conduction (ABC) test

Bone conduction is a measure of cochlear function. In ABC test, patient's bone conduction is compared with that of the examiner (presuming that the examiner has normal hearing). External auditory meatus of both the patient and examiner should be *occluded* (by pressing the tragus inwards), to prevent ambient noise entering through AC route. In conductive deafness, the patient and the examiner hear the fork for the same duration of time. In sensorineural deafness, the patient hears the fork for a shorter duration.

### (d) Schwabach's test

page 26

page 27

Table 4-1. Tuning fork tests and their interpretation

Test	Normal	Conductive deafness	SN deafness
Rinne	AC > BC (Rinne positive)	BC > AC (Rinne negative)	AC > BC
Weber	Not lateralised	Lateralised to poorer ear	Lateralised to better ear
ABC	Same as examiner's	Same as examiner's	Reduced
Schwabach	Equal	Lengthened	Shortened

Here again BC of patient is compared with that of the normal hearing person (examiner) but meatus is *not occluded*. It has the same significance as absolute bone conduction test. Schwabach is reduced in sensorineural deafness and lengthened in conductive deafness.

Table 4.1 summarises the interpretation of tuning fork tests.

### (e) Bing test

It is a test of bone conduction and examines the effect of *occlusion of ear canal* on the hearing. A vibrating tuning fork is placed on the mastoid while the examiner alternately closes and opens the ear canal by pressing on the tragus inwards. A normal person or one with sensorineural hearing loss hears louder when ear canal is occluded and softer when the canal is open (Bing positive). A patient with conductive hearing loss will appreciate no change (Bing negative).

### (f) Gelle's test

It is also a test of bone conduction and examines the effect of *increased air pressure* in ear canal on the hearing. Normally, when air pressure is increased in the ear canal by Siegle's speculum, it pushes the tympanic membrane and ossicles inwards, raises the intralabyrinthine pressure and causes immobility of basilar membrane and decreased hearing, but no change in hearing is observed when ossicular chain is fixed or disconnected. Gelle's test is performed by placing a vibrating fork on the mastoid while changes in air pressure in the ear canal are brought about by Siegle's speculum. Gelle's test is positive in normal persons and in those with sensorineural hearing loss. It is negative when ossicular chain is fixed or disconnected. It was a popular test to find out stapes fixation in otosclerosis but has now been superceded by tympanometry.

## B. Audiometric Tests

### 1. Pure Tone Audiometry



Dhingra: Diseases of Ear Nose and Throat, 5th Edition  
Copyright © 2010 Elsevier. All rights reserved.

Figure 4.2 Two-room audiometry setup. Audiometrician watches responses of the patient sitting across a glass partition.

An audiometer is an electronic device which produces pure tones, the intensity of which can be increased or decreased in 5 dB steps (Fig. 4.2). Usually air conduction thresholds are measured for tones of 125, 250, 500, 1000, 2000 and 4000 and 8000 Hz and bone conduction thresholds for 250, 500, 1000 and 2000 and 4000 Hz. The amount of intensity that has to be raised above the normal level is a measure of the degree of hearing impairment at that frequency. It is charted in the form of a graph called *audiogram*. The threshold of bone conduction is a measure of cochlear function. The difference in the thresholds of air and bone conduction (A-B gap) is a measure of the degree of conductive deafness. It may be noted that audiometer is so calibrated that the hearing of a normal person, both for air and bone conduction, is at zero dB and there is no A-B gap, while tuning fork tests normally show  $AC > BC$ .

When difference between the two ears is 40 dB or above in air conduction thresholds, the better ear is masked to avoid getting a shadow curve from the non-test better ear. Similarly, masking is essential in all bone conduction studies. Masking is done by employing narrow-band noise to the non-test ear.

#### Uses of pure tone audiogram

- (i) It is a measure of threshold of hearing by air and bone conduction and thus the degree and type of hearing loss.
- (ii) A record can be kept for future reference.
- (iii) Audiogram is essential for prescription of hearing aid.
- (iv) Helps to find degree of handicap for medicolegal purposes.
- (v) Helps to predict speech reception threshold.

## 2. Speech Audiometry

In this test, the patient's ability to hear and understand speech is measured. Two parameters are studied: (i) speech reception threshold and (ii) discrimination score.

### **Speech reception threshold (SRT)**

It is the minimum intensity at which 50% of the words are repeated correctly by the patient. A set of spondee words (two syllable words with equal stress on each syllable, e.g. baseball, sunlight, daydream, etc.) is delivered to each ear through the headphone of an audiometer. The word lists are delivered in the form of recorded tapes or monitored voice and their intensity varied in 5 dB steps till half of them are correctly heard. Normally, SRT is within 10 dB of the average of pure tone threshold of three speech frequencies (500, 1000 and 2000 Hz). An SRT better than pure tone average by more than 10 dB suggests a functional hearing loss.

### **Speech discrimination score**

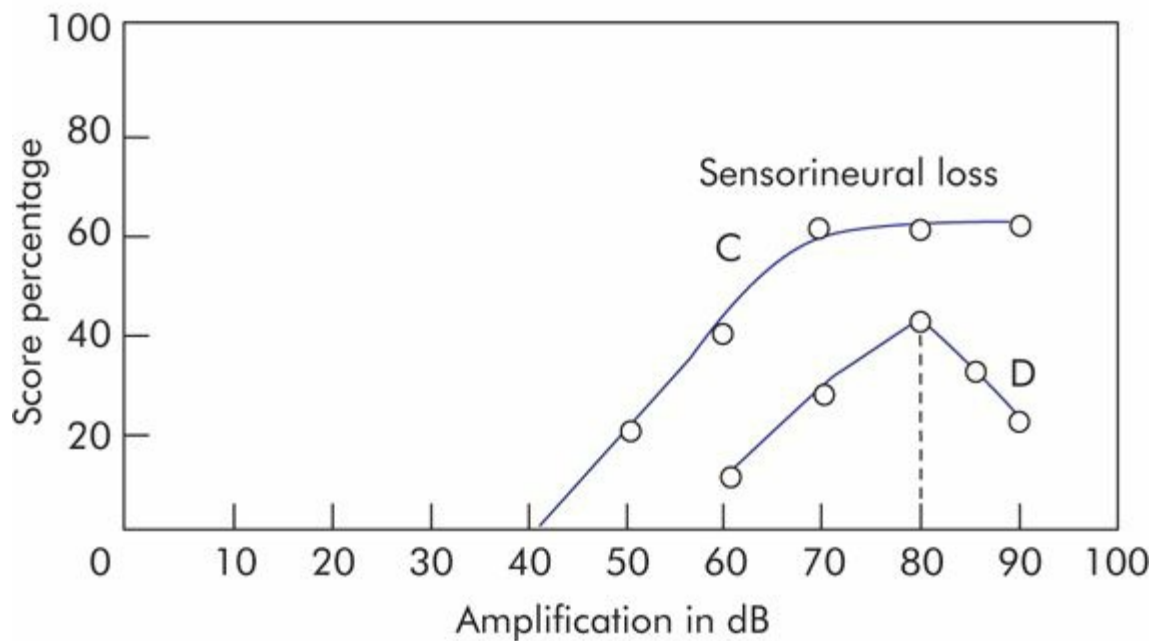
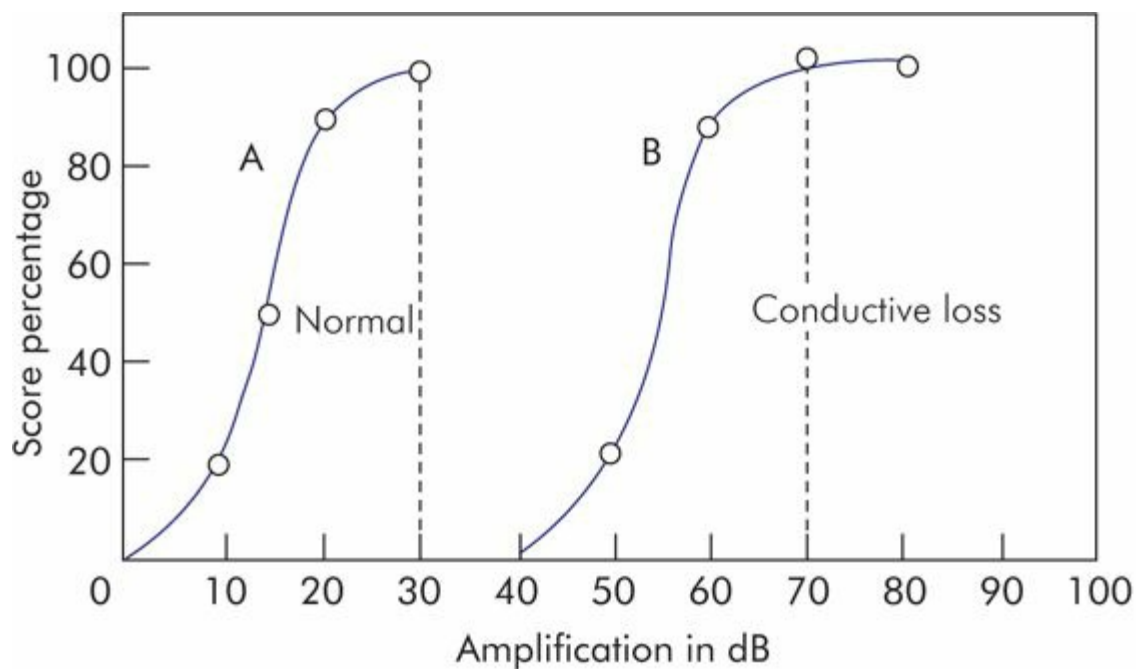
Also called *speech recognition* or *word recognition score*. It is a measure of patient's ability to understand speech. Here, a list of phonetically balanced (PB) words (single syllable words, e.g. pin, sin, day, bus, etc.) is delivered to the patient's each ear separately at 30-40 dB above his SRT and the percentage of words correctly heard by the patient is recorded. In normal persons and those with conductive hearing loss a high score of 90-100% can be obtained (Fig. 4.3A, B and Table 4.2).

### **Performance intensity function for PB words**

*PB max*. Instead of using a single suprathreshold intensity of 30-40 dB above SRT as described above, it is better to chart PB scores against several levels of speech intensity and find the maximum score (PB max) a person can attain. Also note the intensity of sound at which PB max is attained. It is a useful test clinically to set the volume of hearing aid (Fig. 4.3C). Maximum volume of hearing aid should not be set above PB max.

*Roll over phenomenon*. It is seen in retrocochlear hearing loss. With increase in speech intensity above a particular level, the PB word score falls rather than maintain a plateau as in cochlear type of sensorineural hearing loss (Fig. 4.3D).





Dhingra: Diseases of Ear Nose and Throat, 5th Edition  
 Copyright © 2010 Elsevier. All rights reserved.

Figure 4.3 Speech audiogram.

A-PB score in a normal person 100% at 30 dB.

B-PB score in conductive hearing loss 100% at 70 dB. This curve runs parallel to that of a normal person.

C-Cochlear SNHL. PB max is at 70 dB and then attains a plateau.

D-Roll over curve: PB max at 80 dB. PB scores decline as intensity increases further.

Table 4-2. Ability to understand speech and its relation to speech discrimination (SD) score

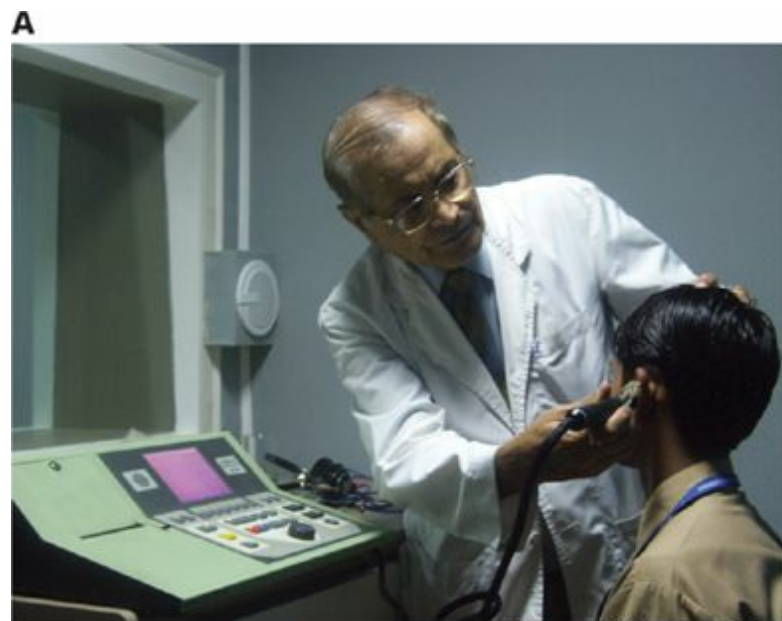A list of 50 PB words is presented and the number correctly heard is multiplied by 2.	
SD score	Ability to understand speech
90-100%	Normal
76-88%	Slight difficulty
60-74%	Moderate difficulty
40-58%	Poor
<40%	Very poor

Thus speech audiometry is useful in several ways:

- (i) To find speech reception threshold which correlates well with average of three speech frequencies of pure tone audiogram.

- (ii) To differentiate organic from non-organic (functional) hearing loss.
- (iii) To find the intensity at which discrimination score is best. This is helpful for fitting a hearing aid and setting its volume for maximum discrimination.
- (iv) To differentiate a cochlear from a retrocochlear sensorineural hearing loss.

### 3. Bekesy Audiometry



Dhingra: Diseases of Ear Nose and Throat, 5th Edition  
Copyright © 2010 Elsevier. All rights reserved.

Figure 4.4 (A) Impedance audiometry in progress. (B) Impedance audiometry.

It is a self-recording audiometry where various pure tone frequencies automatically move from low to high while the patient controls the intensity through a button. Two tracings, one with continuous and the other with pulsed tone are obtained. The tracings help to differentiate a cochlear from retrocochlear and an organic from a functional hearing loss.

Various types of tracings obtained are:

Type I	Continuous and pulsed tracings overlap. Seen in normal hearing or <i>conductive hearing loss</i> .
Type II	Continuous and pulsed tracings overlap up to 1000 Hz and then continuous tracing falls. <i>Seen in cochlear loss</i> .
Type III	Continuous tracing falls below pulsed tracing at 100 to 500 Hz even up to 40-50 dB. Seen in <i>retrocochlear/neural lesion</i> .
Type IV	Continuous tracing falls below pulsed lesion at frequencies up to 1000 Hz by more than 25 dB. Seen in <i>retrocochlear/neural lesion</i> .
Type V	Continuous tracing is above pulsed one. Seen in <i>non-organic hearing loss</i> .

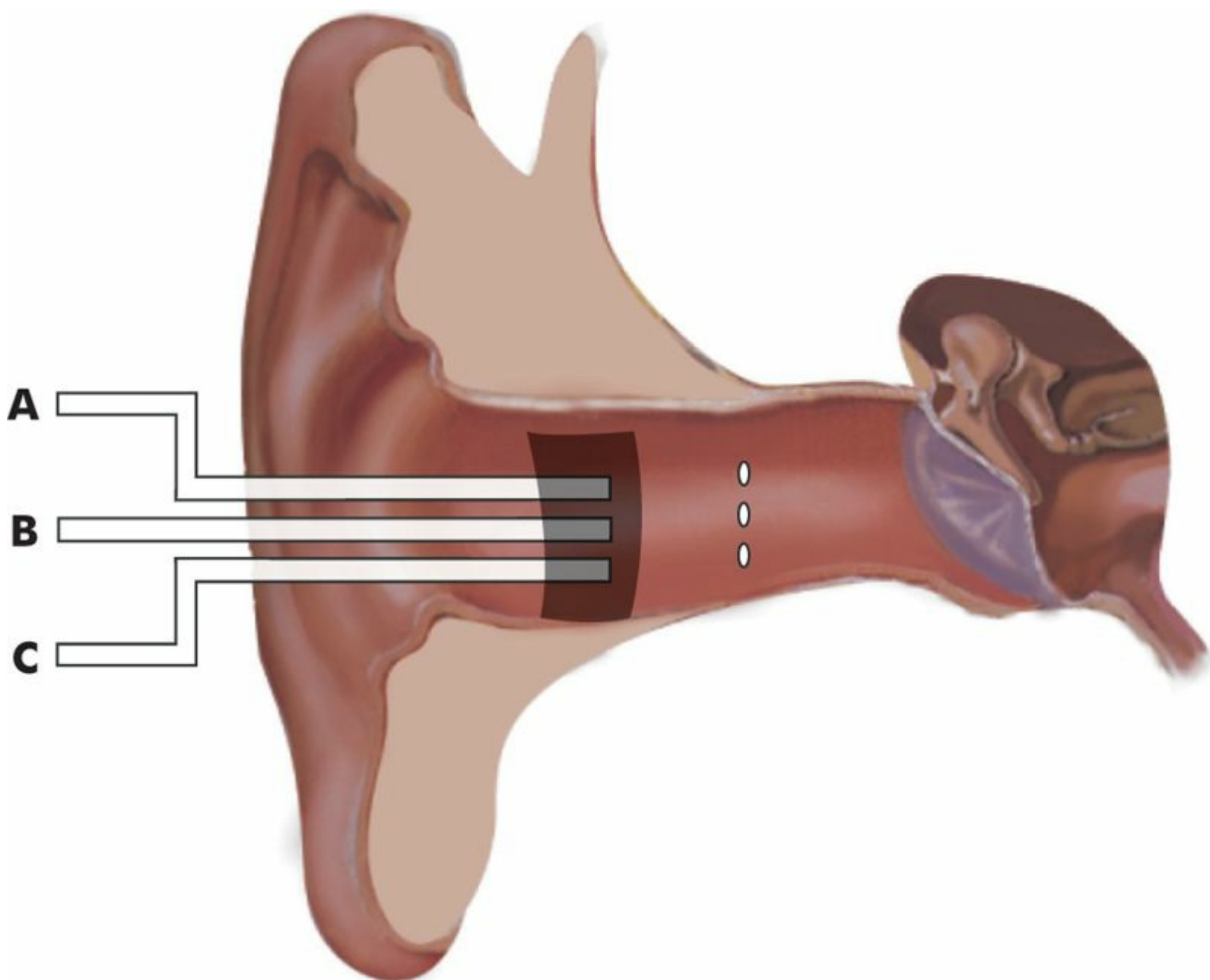
Bekesy audiometry is seldom performed these days.

### 4. Impedance Audiometry (Fig. 4.4)

It is an objective test, widely used in clinical practice and is particularly useful in children. It consists of:

- (a) Tympanometry
- (b) Acoustic reflex measurements

#### Tympanometry



Dhingra: Diseases of Ear Nose and Throat, 5th Edition  
 Copyright © 2010 Elsevier. All rights reserved.

Figure 4.5 Principle of impedance audiometry. (A) Oscillator to produce a tone of 220 Hz. (B) Air pump to increase or decrease air pressure in the air canal. (C) Microphone to pick up and measure sound pressure level reflected from the tympanic membrane.

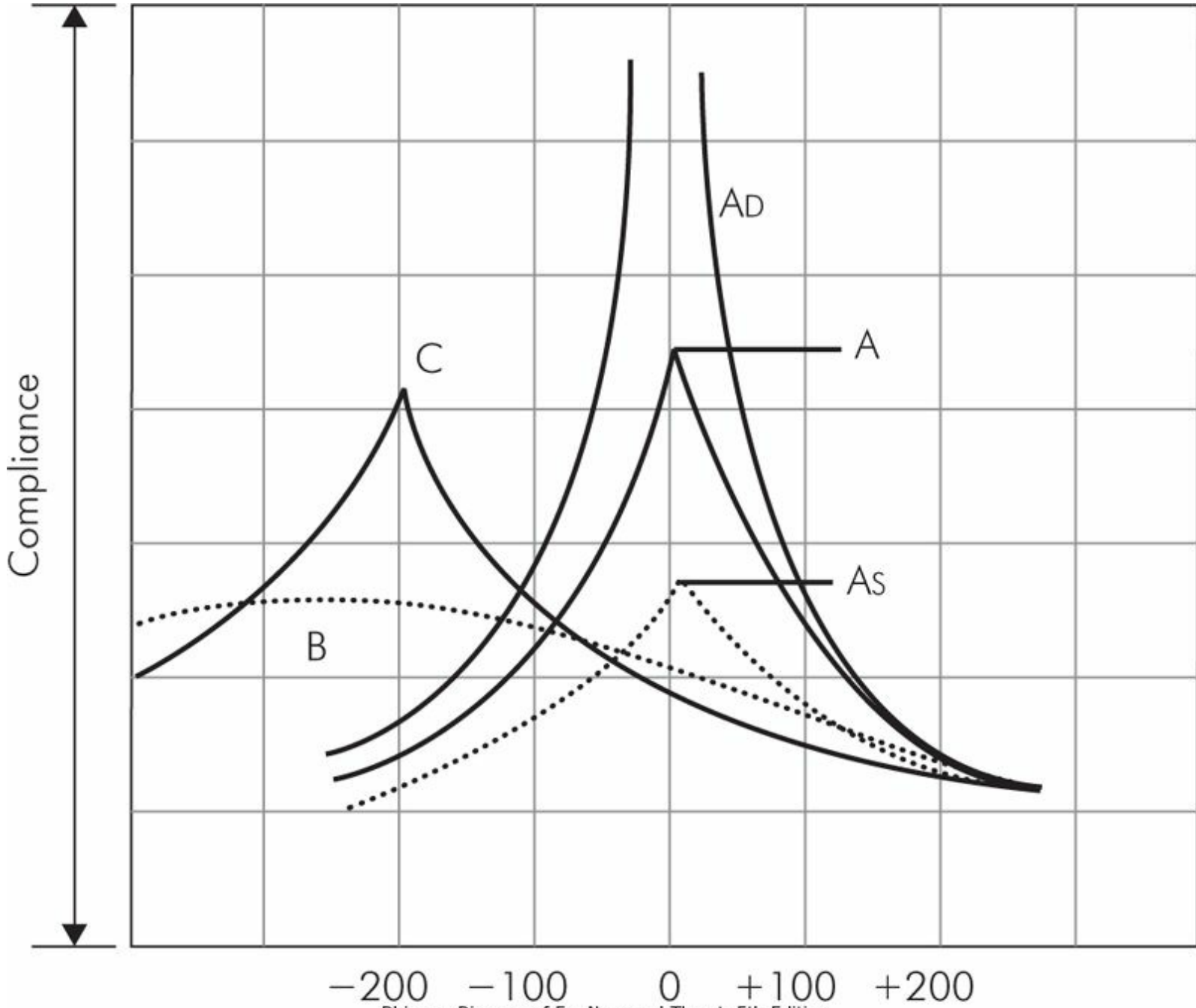
It is based on a simple principle, i.e. when a sound strikes tympanic membrane, some of the sound energy is absorbed while the rest is reflected. A stiffer tympanic membrane would reflect more of sound energy than a compliant one. By changing the pressures in a sealed external auditory canal and then measuring the reflected sound energy, it is possible to find the compliance or stiffness of the tympano-ossicular system and thus find the healthy or diseased status of the middle ear.

Essentially, the equipment consists of a probe which snugly fits into the external auditory canal and has three channels; (i) to deliver a tone of 220 Hz, (ii) to pick up the reflected sound through a microphone and (iii) to bring about changes in air pressure in the ear canal from positive to normal and then negative (Fig. 4.5). By charting the compliance of tympano-ossicular system against various pressure changes, different types of graphs called *tympanograms* are obtained which are diagnostic of certain middle ear pathologies.

**Types of tympanograms (Fig. 4.6)**

Type A	Normal tympanogram.
Type As	Compliance is lower at or near ambient air pressure. Seen in fixation of ossicles, e.g. otosclerosis or malleus fixation.
Type Ad	High compliance at or near ambient pressure. Seen in ossicular discontinuity or thin and lax tympanic membrane.

Type B	A flat or dome-shaped graph. No change in compliance with pressure changes. Seen in middle ear fluid or thick tympanic membrane.
Type C	Maximum compliance occurs with negative pressure in excess of 100 mm of H <sub>2</sub> O. Seen in retracted tympanic membrane and may show some fluid in middle ear.



Dhingra: Diseases of Ear Nose and Throat, 5th Edition  
Copyright © 2010 Elsevier. All rights reserved.

Figure 4.6 Types of tympanograms.

A-Normal.

As-Reduced compliance at ambient pressure (otosclerosis).

AD-Increased compliance at ambient pressure (ossicular discontinuity).

B-Flat or dome-shaped (fluid in middle ear).

C-Maximum compliance at pressures more than -100 mm H<sub>2</sub>O (negative pressure in middle ear), e.g. eustachian tube obstruction or early stage of otitis media with effusion.

**Testing function of eustachian tube.** Tympanometry has also been used to find function of eustachian tube in cases of intact or perforated tympanic membrane. A negative or a positive pressure (-200 or +200 mm of H<sub>2</sub>O) is created in the middle ear and the person is asked to swallow 5 times in 20 seconds. The ability to equilibrate the pressure indicates normal tubal function. The test can also be used to find the patency of the grommet placed in the tympanic membrane in cases of serous otitis media.

#### Acoustic reflex

It is based on the fact that a loud sound, 70-100 dB above the threshold of hearing of a particular ear, causes bilateral contraction of the stapedial muscles which can be detected by tympanometry. Tone can be delivered to one ear and the reflex picked from the same or the contralateral ear. The reflex arc involved is:

*Ipsilateral*: CN VIII → ventral cochlear nucleus → CN VII nucleus → ipsilateral stapedius muscle.

*Contralateral*: CN VIII → ventral cochlear nucleus → contralateral medial superior olivary nucleus → contralateral CN VII nucleus → contralateral stapedius muscle (Fig. 4.7).

This test is useful in several ways:

- (i) *To test the hearing in infants and young children.* It is an objective method.
- (ii) *To find malingerers.* A person who feigns total deafness and does not give any response on pure tone audiometry but shows a positive stapedial reflex is a malingerer.
- (iii) *To detect cochlear pathology.* Presence of stapedial reflex at lower intensities, e.g. 40 to 60 dB than the usual 70 dB indicates recruitment and thus a cochlear type of hearing loss.
- (iv) *To detect VIIIth nerve lesion.* If a sustained tone of 500 or 1000 Hz, delivered 10 dB above acoustic reflex threshold, for a period of 10 seconds, brings the reflex amplitude to 50%, it shows abnormal adaptation and is indicative of VIIIth nerve lesion (stapedial reflex decay).
- (v) *Lesions of facial nerve.* Absence of stapedial reflex when hearing is normal indicates lesion of the facial nerve, proximal to the nerve to stapedius. The reflex can also be used to find prognosis of facial paralysis as the appearance of reflex, after it was absent, indicates return of function and a favourable prognosis.
- (vi) *Lesion of brainstem.* If ipsilateral reflex is present but the contralateral reflex is absent, lesion is in the area of crossed pathways in the brainstem.

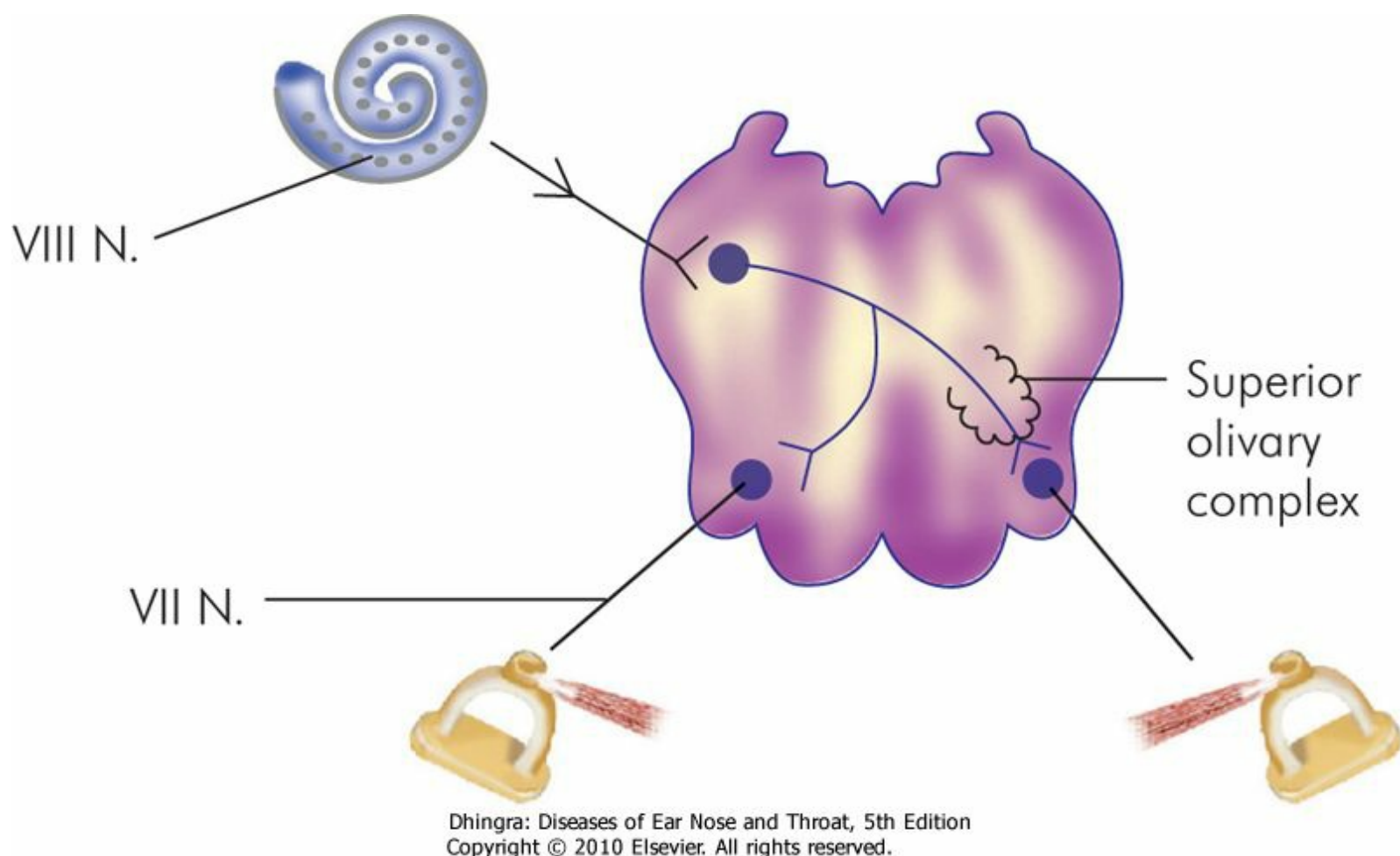


Figure 4.7 Acoustic reflex.

### **Physical volume of ear canal**

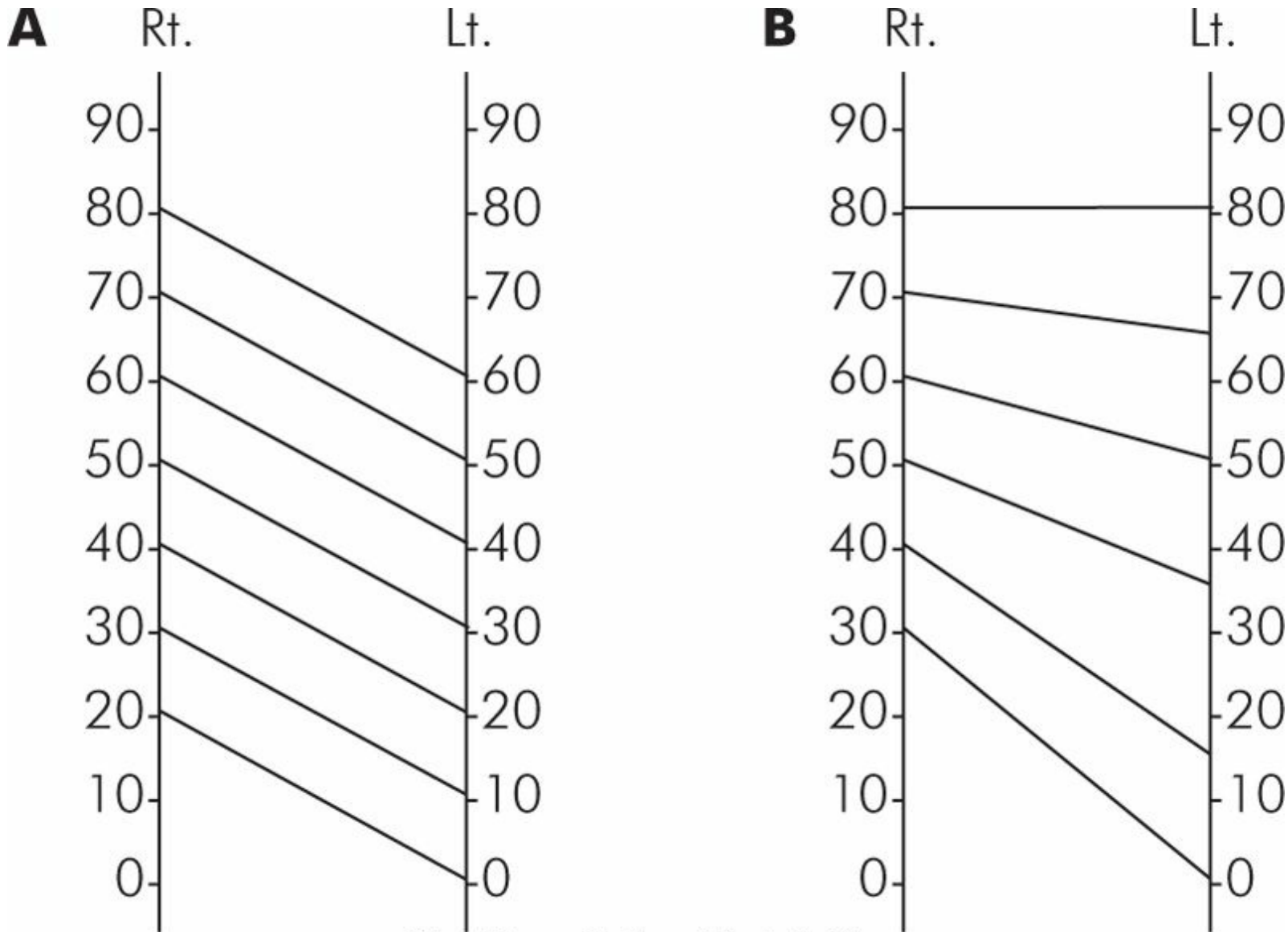
Acoustic immittance can also measure the physical volume of air between the probe tip and tympanic membrane. Normally it is up to 1.0 ml in children and 2 ml in adults. Any increase in volume, >2 ml in children and >2.5 ml in adults, indicates perforation of the tympanic membrane (because middle ear volume is added up to the volume of external ear canal). This has also been used to find patency of the ventilation tube.

## C. Special Tests of Hearing

### 1. Recruitment

It is a phenomenon of abnormal growth of loudness. The ear which does not hear low intensity sound begins to hear greater intensity sounds as loud or even louder than normal hearing ear. Thus, a loud sound which is tolerable in normal ear may grow to abnormal levels of loudness in the recruiting ear and thus becomes intolerable. The patients with recruitment are poor candidates for hearing aids. Recruitment is typically seen in lesions of the cochlea (e.g. Meniere's disease, presbycusis) and thus helps to differentiate a cochlear from a retrocochlear sensorineural hearing loss.

*Alternate binaural loudness balance test* is used to detect recruitment in unilateral cases. A tone, say of 1000 Hz, is played alternately to the normal and the affected ear and the intensity in the affected ear is adjusted to match the loudness in normal ear. The test is started at 20 dB above the threshold of deaf ear and then repeated at every 20 dB rise until the loudness is matched or the limits of audiometer reached. In conductive and neural deafness, the initial difference is maintained throughout while in cochlear lesions, partial, complete or over-recruitment may be seen (Fig. 4.8).



Dhingra: Diseases of Ear Nose and Throat, 5th Edition  
Copyright © 2010 Elsevier. All rights reserved.

Figure 4.8 Alternate binaural loudness balance test.

(A) Non-recruiting ear. The initial difference of 20 dB between the right and left ear is maintained at all intensity levels.

(B) Recruiting ear right side. At 80 dB loudness perceived by right ear is as good as left ear though there was difference of 30 dB initially.

### 2. Short Increment Sensitivity Index (SISI Test)

Patients with cochlear lesions distinguish smaller changes in intensity of pure tone better than normal persons and those with conductive or retrocochlear pathology. SISI test is thus used to differentiate a cochlear from a retrocochlear lesion.

In this test, a continuous tone is presented 20 dB above the threshold and sustained for about 2 minutes. Every 5 seconds, the tone is increased by 1 dB and 20 such blips are presented. Patient indicates the blips heard. In conductive deafness, SISI score is seldom more than 15%; it is 70-

100% in cochlear deafness; and 0-20% in nerve deafness.

### 3. Threshold Tone Decay Test

It is a measure of nerve fatigue and is used to detect retrocochlear lesions. Normally, a person can hear a tone continuously for 60 seconds. In nerve fatigue, he stops hearing earlier. The threshold tone decay test is simple and is performed in the following manner:

A tone of 4000 Hz is presented at 5 dB above the patient's threshold of hearing, continuously for a period of 60 seconds. If patient stops hearing earlier, intensity is increased by another 5 dB. The procedure is continued till patient can hear the tone continuously for 60 seconds, or no level exists above the threshold where tone is audible for full 60 seconds. The result is expressed as number of dB of decay. A decay more than 25 dB is diagnostic of a retrocochlear lesion.

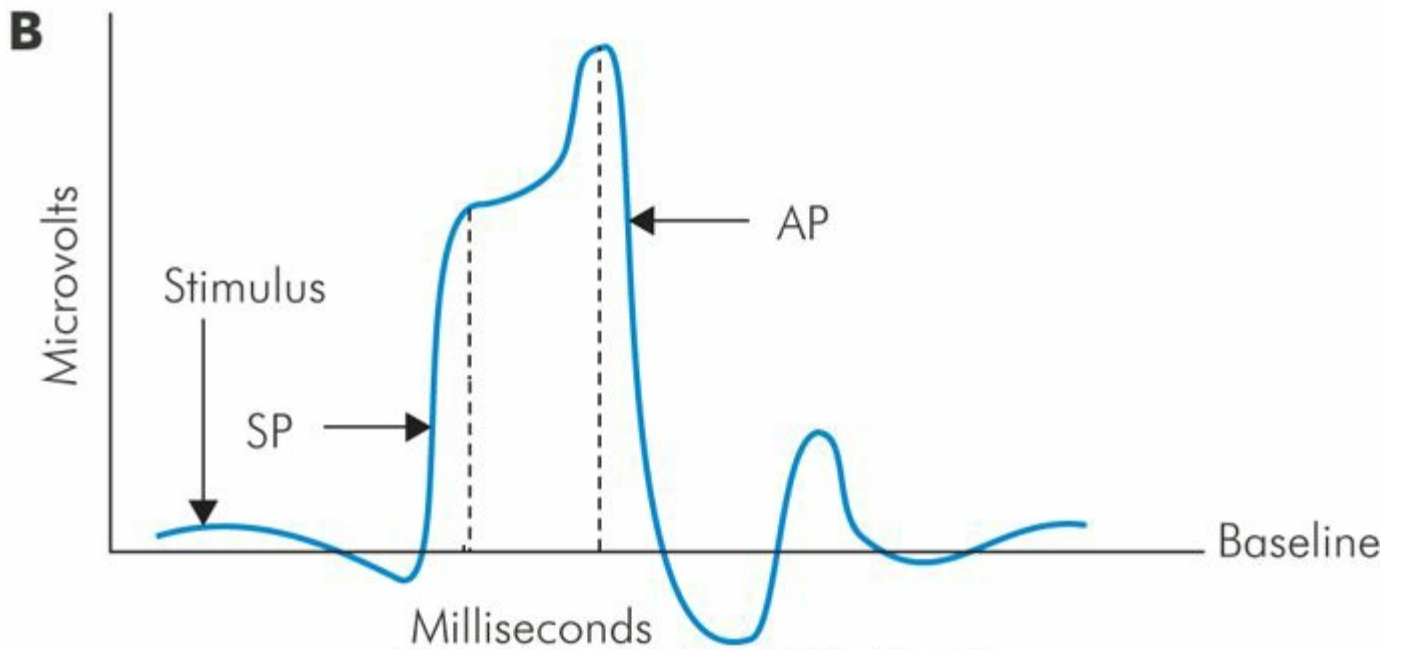
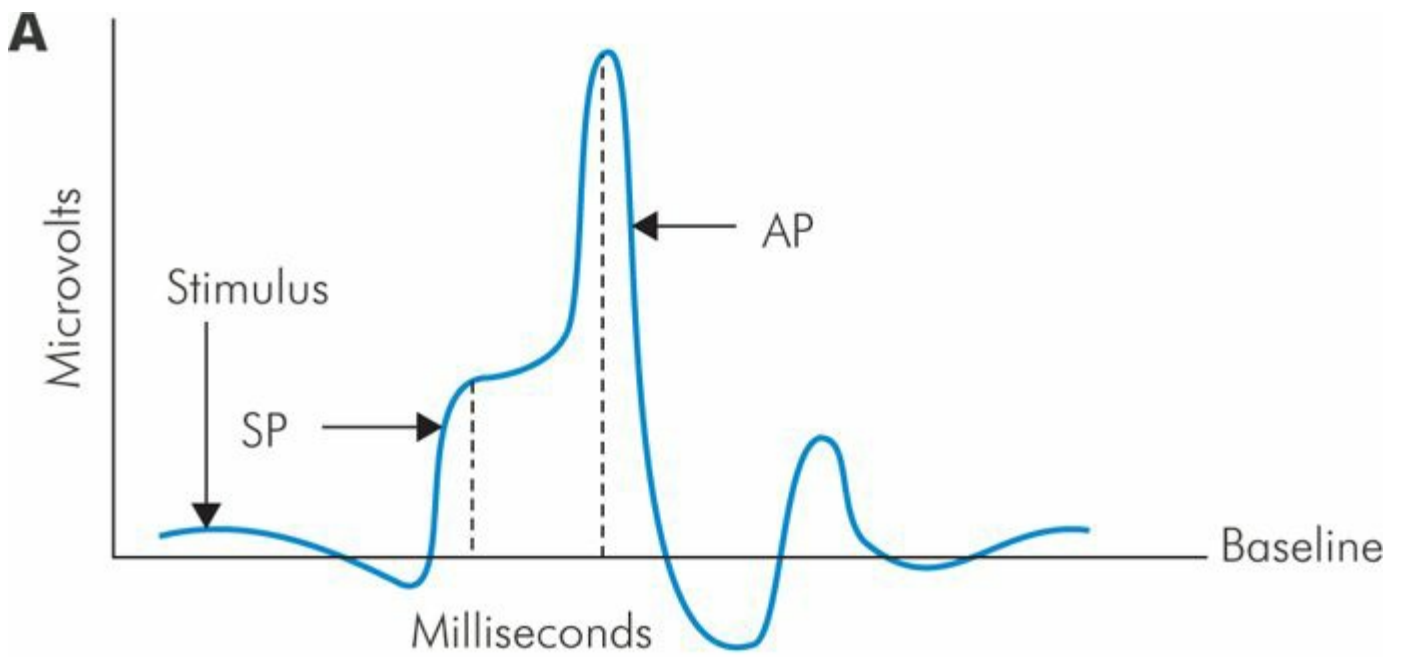
### 4. Evoked Response Audiometry

page 31

page 32

It is an objective test which measures electrical activity in the auditory pathways in response to auditory stimuli. It requires special equipment with an averaging computer. There are several components of evoked electric response but only two have gained clinical acceptance. They are:

- **(a) Electrocochleography (EcoG)** It measures electrical potentials arising in the cochlea and CN VIII in response to auditory stimuli within first 5 milliseconds. The response is in the form of three phenomena: cochlear microphonics, summing potentials and the action potential of VIIIth nerve. The recording electrode is usually a thin needle passed through the tympanic membrane onto the promontory. In adults, it can be done under local anaesthesia but in children or anxious persons sedation or general anaesthesia is required. Sedation does not interfere in these responses. EcoG is useful (i) to find threshold of hearing in young infants and children to within 5-10 dB, (ii) to differentiate lesions of cochlea from those of the VIIIth nerve. Normally the ratio between the amplitude of summing potential to the action potential is less than 30%. An increase in this ratio is indicative of Mèniere's disease (Fig. 4.9).
- **(b) Auditory brainstem response (ABR)** Also called BAER or BAEP (brainstem auditory evoked response or potential) or BERA (brainstem evoked response audiometry) is to elicit brainstem responses to auditory stimulation by clicks or tone bursts. It is a non-invasive technique to find the integrity of central auditory pathways through the VIIIth nerve, pons and midbrain. In this method, electrical potentials are generated in response to several click stimuli or tone-bursts and picked up from the vertex by surface electrodes. It measures hearing sensitivity in the range of 1000-4000 Hz. In a normal person, 7 waves are produced in the first 10 milliseconds. The first, third and fifth waves are most stable and are used in measurements. The waves are studied for absolute *latency*, *inter-wave latency* (usually between wave I and V) and *the amplitude* (Fig. 4.10).

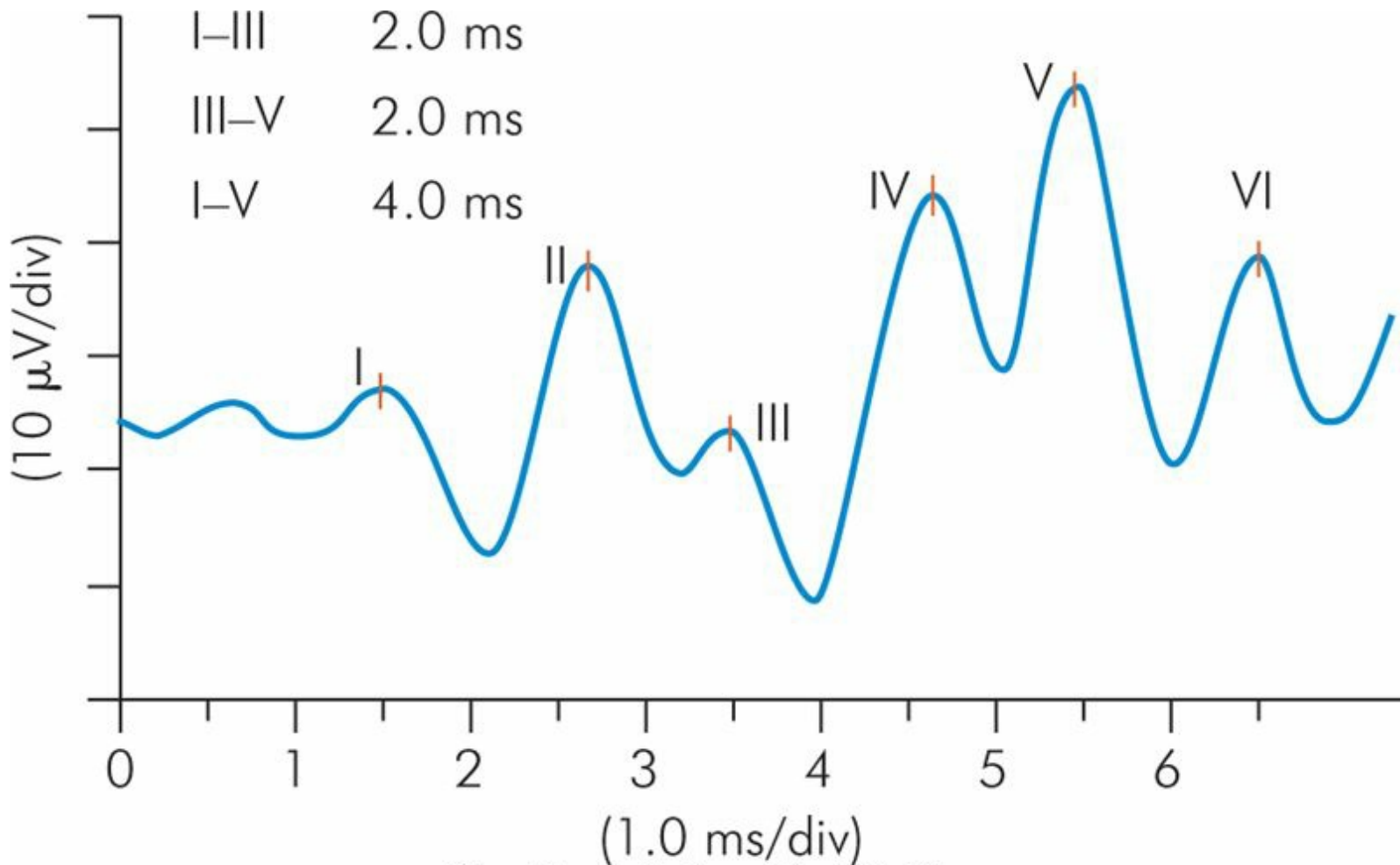


Dhingra: Diseases of Ear Nose and Throat, 5th Edition  
 Copyright © 2010 Elsevier. All rights reserved.

Figure 4.9 Electrocochleography . (A) Normal ear. (B) Ear with Meniere's disease. Voltage of summing potential (SP) is compared with that of action potential (AP). Normally SP is 30% of AP. This ratio is enhanced in Meniere's disease.

Wave I	Distal part of CN VIII
Wave II	Proximal part of CN VIII near the brainstem
Wave III	Cochlear nucleus
Wave IV	Superior olivary complex
Wave V	Lateral lemniscus
Waves VI and VII	Inferior colliculus





Dhingra: Diseases of Ear Nose and Throat, 5th Edition  
Copyright © 2010 Elsevier. All rights reserved.

Figure 4.10 Brainstem auditory evoked potentials.

(a) Amplitude of a wave is measured in microvolts ( $\mu\text{V}$ ) from peak of a wave to the peak of next trough.

(b) Absolute peak latency is the duration in milliseconds (ms) from the start of click to appearance of a wave.

(c) Interpeak latency or interval is the duration in milliseconds between peaks of two waves, e.g., waves I-III or I-V or III and V, and it is compared with normative data (I-III, 2.0 ms; III-V, 2.0 ms; I-V, 4.0 ms).

(d) Interaural peak latency is the difference in milliseconds of a particular wave between two ears. This is useful in unilateral ear disease, e.g., acoustic neuroma (interaural wave V latencies).

The exact anatomic site of neural generators for various waves is disputed but the latest studies indicate the following sites: As an aide memorie remember the mnemonic EE COLI (eight, eight, cochlear nucleus, olivary complex, lateral lemniscus, inferior colliculus) compare E COLI-MA in pathways of hearing.

ABR is used:

- (i) As a screening procedure for infants.
- (ii) To determine the threshold of hearing in infants; also in children and adults who do not cooperate and in malingerers.
- (iii) To diagnose retrocochlear pathology particularly acoustic neuroma.
- (iv) To diagnose brainstem pathology, e.g. multiple sclerosis or pontine tumours.
- (vi) To monitor CN VIII intraoperatively in surgery of acoustic neuromas to preserve the function of cochlear nerve.

## 5. Otoacoustic Emissions (OAEs)

page 32

page 33

They are low intensity sounds produced by outer hair cells of a normal cochlea and can be elicited by a very sensitive microphone placed in the external ear canal and analyzed by a computer. Sound produced by outer hair cells travels in a reverse direction: outer hair cells  $\rightarrow$  basilar membrane  $\rightarrow$  perilymph  $\rightarrow$  oval window  $\rightarrow$  ossicles  $\rightarrow$  tympanic membrane  $\rightarrow$  ear canal. OAEs are present when outer hair cells are healthy and are absent when they are damaged and thus help to test the function of cochlea. They do not disappear in eighth nerve pathology as cochlear hair cells are normal.

**Types of OAEs:** Broadly OAEs are of two types: spontaneous or evoked. The latter are elicited by a sound stimulus.

**Spontaneous OAEs:** They are present in healthy normal hearing persons where hearing loss does not exceed 30 dB. They may be absent in 50% of normal persons.

*Evoked OAEs*: They are further divided into two types depending on the sound stimulus used to elicit them.

- **(a)** Transient evoked OAEs (TEOAEs). Evoked by clicks. A series of click stimuli are presented at 80-85 dB SPL and response recorded.
- **(b)** Distortion product OAEs (DPOAEs). Two tones are simultaneously presented to the cochlea to produce distortion products. They have been used to test hearing in the range of 1000-8000 Hz.

### **Uses**

- **1.** OAEs are used as a screening test of hearing in neonates and to test hearing in uncooperative or mentally challenged individuals after sedation. Sedation does not interfere with OAEs.
- **2.** They help to distinguish cochlear from retrocochlear hearing loss. OAEs are absent in cochlear lesions, e.g. ototoxic sensorineural hearing loss. They detect ototoxic effects earlier than pure-tone audiometry.
- **3.** OAEs are also useful to diagnose retrocochlear pathology, especially auditory neuropathy. Auditory neuropathy is a neurologic disorder of CN VIII. Audiometric tests, e.g. SNHL for pure tones, impaired speech discrimination score, absent or abnormal auditory brainstem response, show a retrocochlear type of lesion but OAEs are normal.

OAEs are absent in 50% of normal individuals, lesions of cochlea, middle ear disorders (as sound travelling in reverse direction cannot be picked up) and when hearing loss exceeds 30 dB.

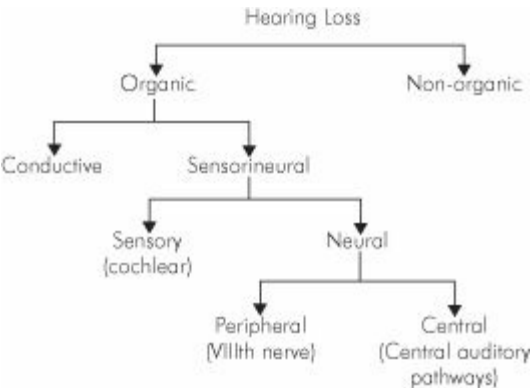
## **6. Central Auditory Tests**

These tests are designed to find defects in the central auditory pathways and the temporal cortex. Several tests with test signal delivered to one ear (monotic) or both ears (dichotic) have been used, but currently the "Staggered spondaic words" test is widely employed. Central auditory tests are not used routinely.

## **7. Hearing Assessment in Infants and Children (see page 131)**

# 5 Hearing Loss

## CLASSIFICATION



# CONDUCTIVE HEARING LOSS AND ITS MANAGEMENT

Any disease process which interferes with the conduction of sound to reach cochlea causes conductive hearing loss. The lesion may lie in the external ear and tympanic membrane, middle ear or ossicles up to stapediovestibular joint.

The characteristics of conductive hearing loss are:

- 1. Negative Rinne test, i.e. BC > AC.
- 2. Weber lateralised to poorer ear.
- 3. Normal absolute bone conduction.
- 4. Low frequencies affected more.
- 5. Audiometry shows bone conduction better than air conduction with air-bone gap. Greater the air-bone gap, more is the conductive loss (Fig. 5.1).
- 6. Loss is not more than 60 dB.
- 7. Speech discrimination is good.

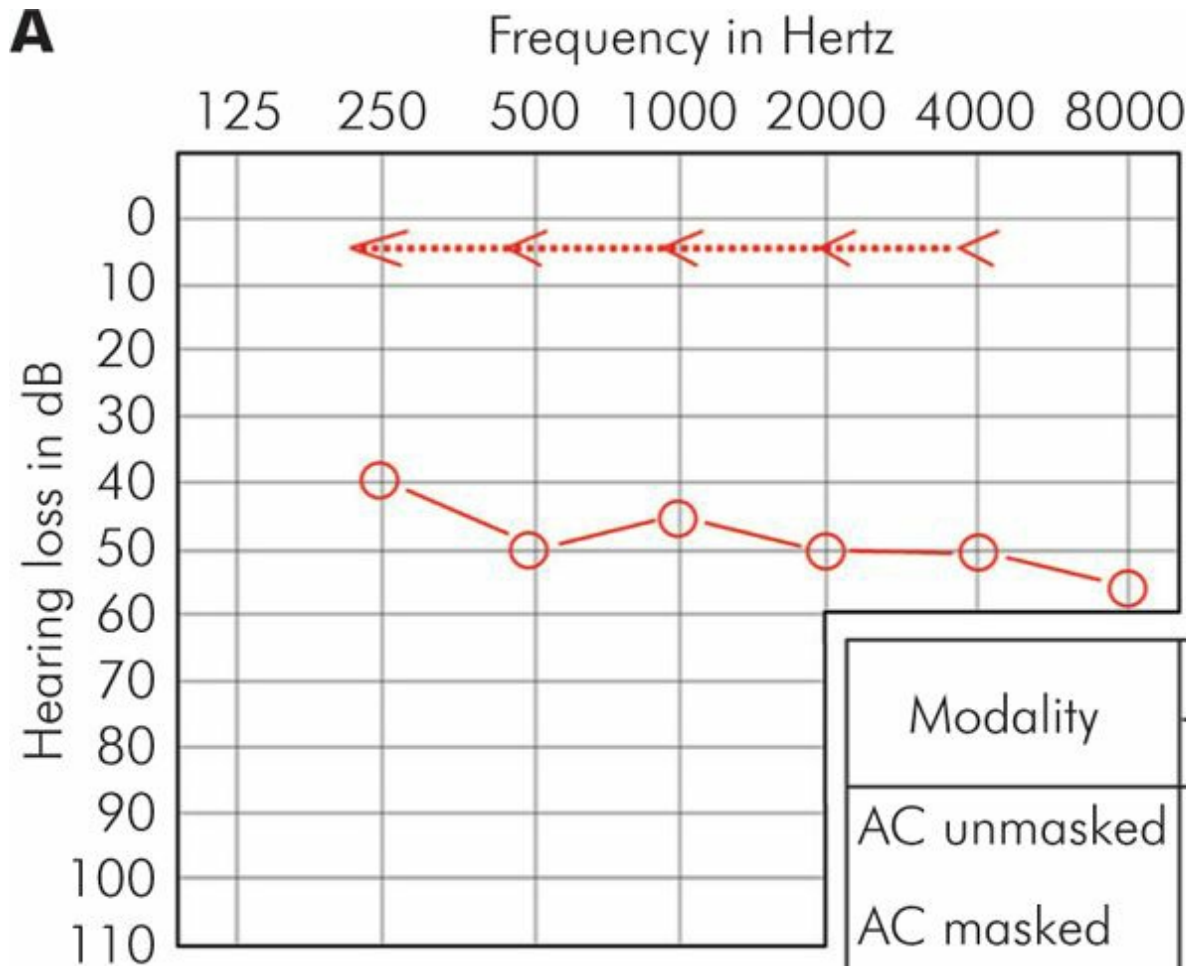
## Aetiology

The cause may be congenital (Table 5.1) or acquired (Table 5.2).

# Average Hearing Loss Seen in Different Lesions of Conductive Apparatus

1. Complete obstruction of ear canal:	30 dB
2. Perforation of tympanic membrane (It varies and is directly proportional to the size of perforation):	10-40 dB
3. Ossicular interruption with intact drum:	54 dB
4. Ossicular interruption with perforation:	38 dB
5. Malleus fixation:	10-25 dB
6. Closure of oval window:	60 dB

Note here that ossicular interruption with intact drum causes more loss than ossicular interruption with perforated drum.



**B**

Modality	Ear	
	Right	Left
AC unmasked	○	×
AC masked	△	□
BC unmasked	<	>
BC masked	┌	┐
No response	⊙	⊗

Dhingra: Diseases of Ear Nose and Throat, 5th Edition  
Copyright © 2010 Elsevier. All rights reserved.

Figure 5.1 (A) Audiogram of right ear showing conductive hearing loss with A-B gap. (B) Symbols used in audiogram charting.

Table 5-1. Congenital causes of conductive hearing loss

Meatal atresia
Fixation of stapes footplate

Fixation of malleus head

Ossicular discontinuity

Congenital cholesteatoma

**Table 5-2. Acquired causes of conductive hearing loss**

External ear	Any obstruction in the ear canal, e.g. wax, foreign body, furuncle, acute inflammatory swelling, benign or malignant tumour or atresia of canal.
Middle ear	<ul style="list-style-type: none"><li>• (a) Perforation of tympanic membrane, traumatic or infective</li><li>• (b) Fluid in the middle ear, e.g. acute otitis media, serous otitis media or haemotympanum</li><li>• (c) Mass in middle ear, e.g. benign or malignant tumour</li><li>• (d) Disruption of ossicles, e.g. trauma to ossicular chain, chronic suppurative otitis media, cholesteatoma</li><li>• (e) Fixation of ossicles, e.g. otosclerosis, tympanosclerosis, adhesive otitis media</li><li>• (f) Eustachian tube blockage, e.g. retracted tympanic membrane, serous otitis media.</li></ul>

# Management

Most cases of conductive hearing loss can be managed by medical or surgical means. Treatment of these conditions is discussed in respective sections. Briefly, it consists of:

- **1. Removal of canal obstructions**, e.g. impacted wax, foreign body, osteoma or exostosis, keratotic mass, benign or malignant tumours, meatal atresia.
- **2. Removal of fluid** Myringotomy with or without grommet insertion.
- **3. Removal of mass from middle ear** Tympanotomy and removal of small middle ear tumours or cholesteatoma behind intact tympanic membrane.
- **4. Stapedectomy**, as in otosclerotic fixation of stapes footplate.
- **5. Tympanoplasty** Repair of perforation, ossicular chain or both.
- **6. Hearing aid** In cases, where surgery is not possible, refused or has failed.

## Tympanoplasty

It is an operation to (i) eradicate disease in the middle ear and (ii) to reconstruct hearing mechanism. It may be combined with mastoidectomy if disease process so demands. Type of middle ear reconstruction depends on the damage present in the ear. The procedure may be limited only to repair of tympanic membrane (*myringoplasty*), or to reconstruction of ossicular chain (*ossiculoplasty*), or both (*tympanoplasty*). Reconstructive surgery of the ear has been greatly facilitated by development of operating microscope, microsurgical instruments and biocompatible implant materials.

From the physiology of hearing mechanism, the following principles can be deduced to restore hearing surgically:


- (i) *An intact tympanic membrane*, to provide large hydraulic ratio between the tympanic membrane and stapes footplate.
- (ii) *Ossicular chain*, to conduct sound from tympanic membrane to the oval window.
- (iii) *Two functioning windows*, one on the scala vestibuli (to receive sound vibrations) and the other on the scala tympani (to act as a relief window). If it is only one window, as in stapes fixation or closure of round window, there will be no movement of cochlear fluids resulting in conductive hearing loss.
- (iv) *Acoustic separation of two windows*, so that sound does not reach both the windows simultaneously. It can be achieved by providing an intact tympanic membrane, preferential pathway to one window (usually the oval) by providing ossicular chain and by the presence of air in the middle ear.
- (v) *Functioning eustachian tube*, to provide aeration to the middle ear.
- (vi) *A functioning sensorineural apparatus*, i.e. the cochlea and VIIIth nerve.

## Types of tympanoplasty

Wullstein classified tympanoplasty into five types (Fig. 5.2).

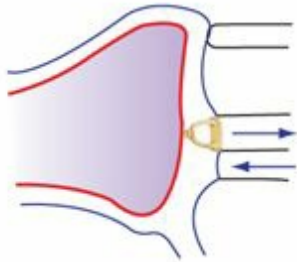
<b>Type I</b>	Defect is perforation of tympanic membrane which is repaired with a graft. It is also called myringoplasty.
<b>Type II</b>	Defect is perforation of tympanic membrane with erosion of malleus. Graft is placed on the incus or remnant of malleus.
<b>Type III</b>	Malleus and incus are absent. Graft is placed directly on the stapes head. It is also called <b>myringostapediopexy or columella tympanoplasty</b> .
<b>Type IV</b>	Only the footplate of stapes is present. It is exposed to the external ear, and graft is placed between the oval and round windows. A narrow middle ear (cavum minor) is thus created, to have an air pocket around the round window. A mucosa-lined space extends from the eustachian tube to the round window. Sound waves in this case act directly on the footplate while the round window has been shielded.
<b>Type V</b>	Stapes footplate is fixed but round window is functioning. In such cases, another window is created on horizontal semicircular canal and covered with a graft. Also called <b>fenestration operation</b> .



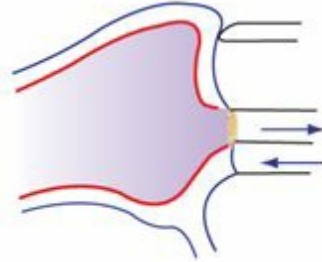


Type I (Myringoplasty)

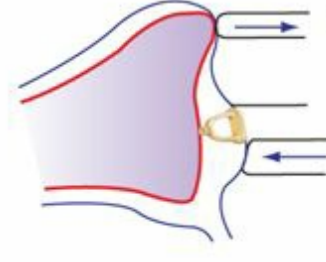
Type II



Type III (Myringostapediopexy)



Type IV



Type V (Fenestration)

Dhingra: Diseases of Ear Nose and Throat, 5th Edition  
Copyright © 2010 Elsevier. All rights reserved.

Figure 5.2 Types of tympanoplasty. The graft is progressively in contact with malleus (type I), incus (type II), stapes (type III), stapes footplate (type IV), or fenestra in horizontal semicircular canal (type V). In classical type IV, the graft was attached to promontory, this provides sound protection for round window while footplate was directly exposed.

Several modifications have appeared in the above classification and they mainly pertain to the types of ossicular reconstruction.

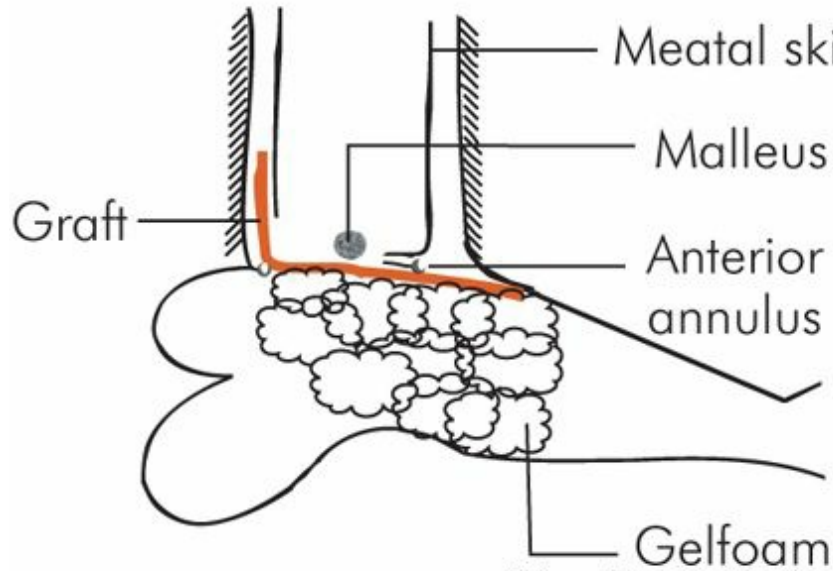
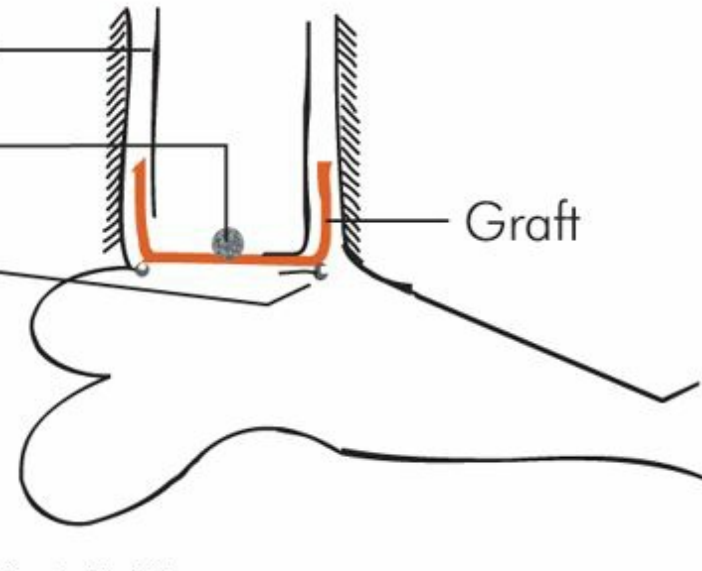
### **Myringoplasty**

It is repair of tympanic membrane. Graft materials of choice are temporalis fascia or the perichondrium taken from the patient. Sometimes, homografts such as dura, vein, fascia or cadaver tympanic membrane are also used. Repair can be done by two techniques—the underlay or the overlay. In the *underlay technique*, margins of perforation are freshened and the graft placed medial to perforation or tympanic annulus, if large, and is supported by gelfoam in the middle ear (Fig. 5.3A). In the *overlay technique*, the graft is placed lateral to fibrous layer of the tympanic membrane after carefully removing all squamous epithelium from the lateral surface of tympanic membrane remnant (Fig. 5.3B and Chapter 80).

### **Ossicular reconstruction**

It is required when there is destruction or fixation of ossicular chain. Most common defect is necrosis of the long process of incus, the malleus and the stapes being normal. In others, there is additional loss of stapes superstructure, leaving only a mobile footplate and malleus. Yet in others, only the footplate is left, all other ossicles, the malleus, incus and the stapes superstructure are destroyed.

### **Repair of ossicular chain**

**A****B**

Dhingra: Diseases of Ear Nose and Throat, 5th Edition  
 Copyright © 2010 Elsevier. All rights reserved.

Figure 5.3 Myringoplasty. (A) Underlay technique-fascia graft is under the anterior annulus. It is supported by gelfoam in the middle ear to prevent medial displacement. (B) Overlay technique-fascia graft lies lateral to anterior annulus onto the anterior bony canal wall. It is placed medial to malleus handle to prevent lateralization.

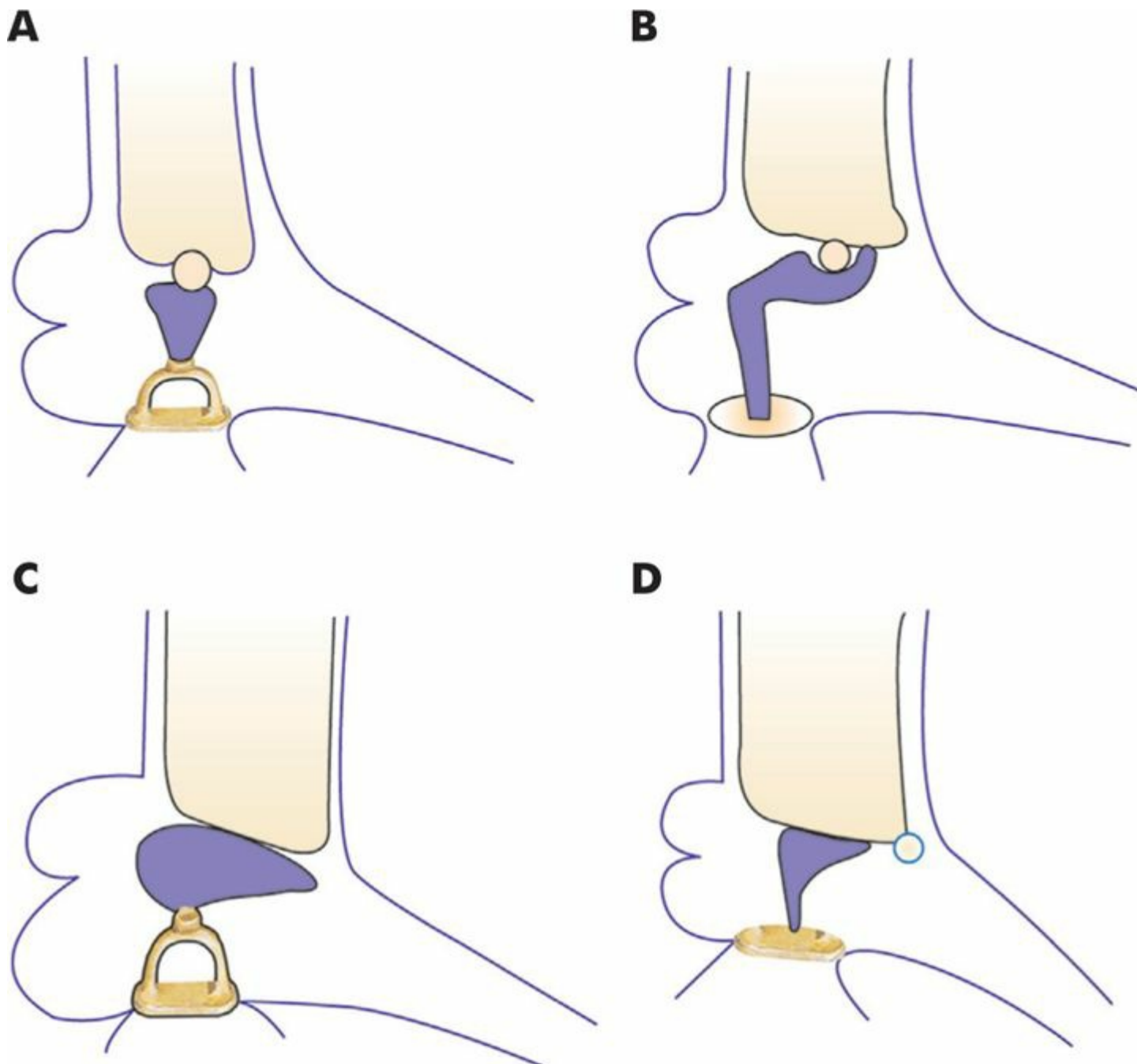
can be achieved by the use of autograft incus or cartilage, homograft ossicles, or the prosthetic implants made of ceramic (hydroxyapatite) or teflon. The techniques commonly employed in ossicular reconstruction in such cases are incus transposition or a sculptured ossicle (Fig. 5.4).

Most common ossicular fixations are the ankylosis of stapes footplate as in otosclerosis, and the congenital or acquired fixation of the head of malleus in the attic.

Ankylosis of stapes can be corrected by removal of the fixed stapes and its replacement by a prosthesis while the attic fixation of malleus head entails removal of the head of malleus and entire incus and then establishing contact between handle of malleus and the stapes.

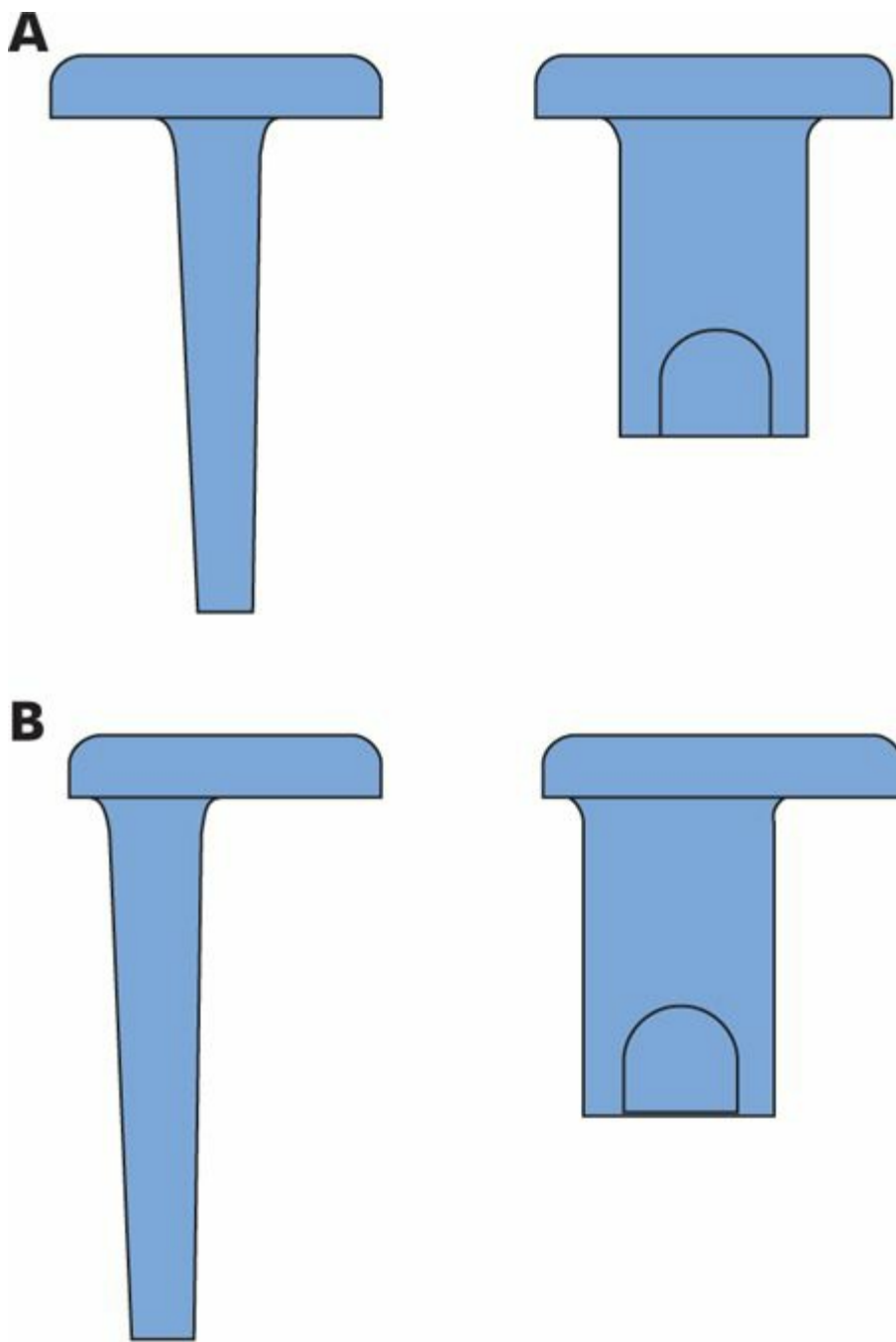
page 36  
 page 37

Prosthetic implants include a TORP or a PORP (total or partial ossicular replacement prosthesis). They are made of teflon or ceramic (Fig. 5.5). A TORP is used to bridge the gap between tympanic membrane and stapes footplate while a PORP is used to provide a direct contact between tympanic membrane and stapes head.



Dhingra: Diseases of Ear Nose and Throat, 5th Edition  
 Copyright © 2010 Elsevier. All rights reserved.

Figure 5.4 Ossicular reconstruction. Sculptured autograft or homograft ossicles have been used. (A) Malleus-Stapes assembly. Modified incus graft connecting malleus handle with stapes head. (B) Malleus-Footplate assembly. Modified malleus connecting malleus handle with stapes footplate. (C) Modified incus connecting TM to stapes head. Malleus is missing. (D) Modified incus connecting TM to stapes footplate.



Dhingra: Diseases of Ear Nose and Throat, 5th Edition  
Copyright © 2010 Elsevier. All rights reserved.

Figure 5.5 Hydroxyapatite TORP and PORP centered (A) and offset (B) types.

# SENSORINEURAL HEARING LOSS AND ITS MANAGEMENT

## *Sensorineural hearing loss (SNHL)*

results from lesions of the cochlea, VIIIth nerve or central auditory pathways. It may be present at birth (congenital) or start later in life (acquired).

The characteristics of sensorineural hearing loss are:

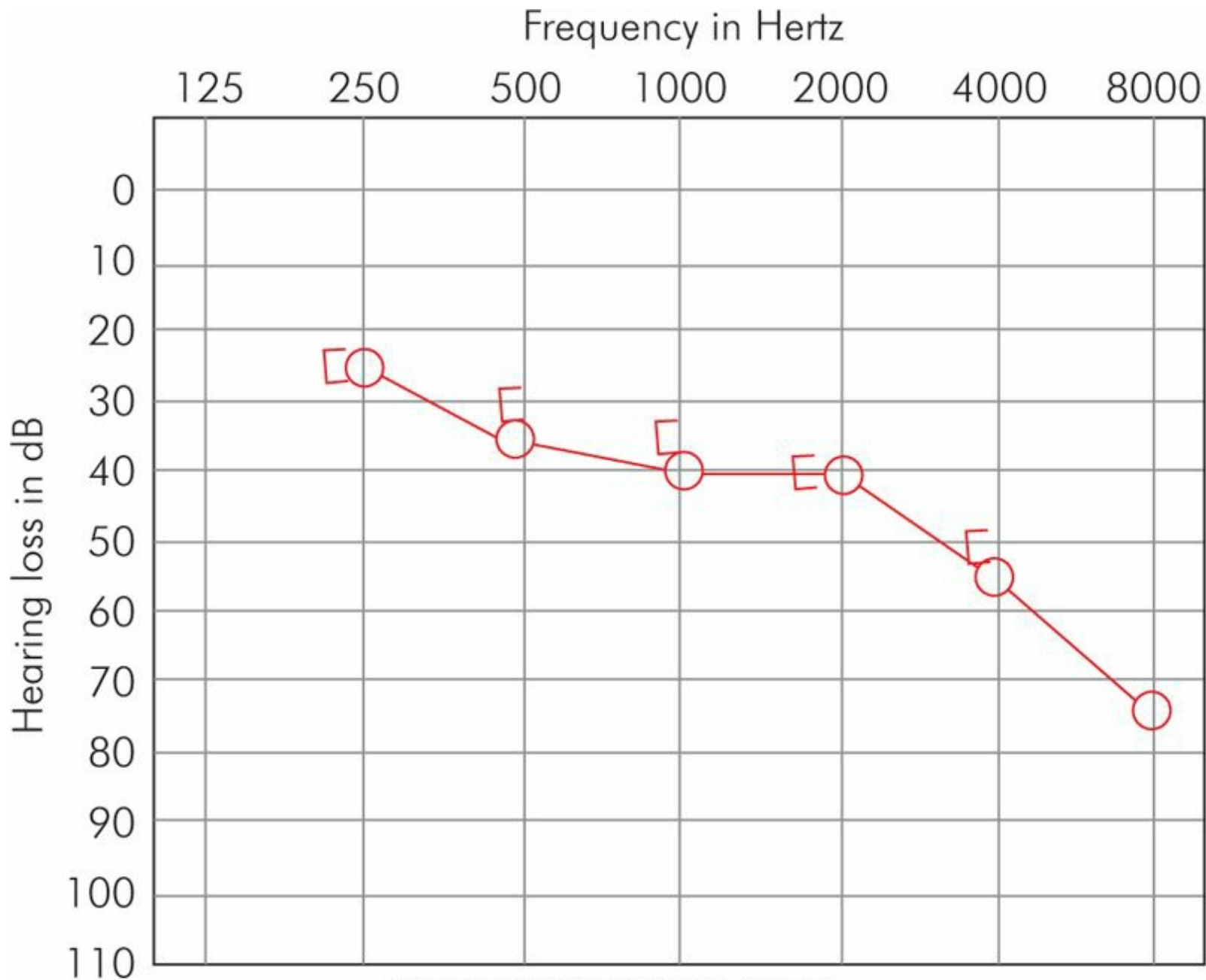- 1. A positive Rinne test, i.e. air AC > BC.
- 2. Weber lateralised to better ear.
- 3. Bone conduction reduced on Schwabach and absolute bone conduction tests.
- 4. More often involving high frequencies.
- 5. No gap between air and bone conduction curve on audiometry (Fig. 5.6).
- 6. Loss may exceed 60 dB.
- 7. Speech discrimination is poor.
- 8. There is difficulty in hearing in the presence of noise.

# Aetiology of SNHL

## Congenital

It is present at birth and is the result of anomalies of the inner ear or damage to the hearing apparatus by prenatal or perinatal factors (see page 127).

## Acquired



Dhingra: Diseases of Ear Nose and Throat, 5th Edition  
Copyright © 2010 Elsevier. All rights reserved.

Figure 5.6 Audiogram of right ear showing sensorineural loss with no A-B gap.

It appears later in life. The cause may be genetic or non-genetic. The genetic cause may manifest late (delayed onset) and affect only the hearing, or be a part of a larger syndrome affecting other systems of the body as well. Common causes of acquired SNHL include:

- 1. Infections of labyrinth-viral, bacterial or spirochaetal,
- 2. Trauma to labyrinth or VIIIth nerve, e.g. fractures of temporal bone or concussion of labyrinth or ear surgery,
- 3. Noise-induced hearing loss,
- 4. Ototoxic drugs,
- 5. Presbycusis,
- 6. Meniere's disease,

- **7.** Acoustic neuroma,
- **8.** Sudden hearing loss,
- **9.** Familial progressive SNHL,
- **10.** Systemic disorders, e.g. diabetes, hypothyroidism, kidney disease, autoimmune disorders, multiple sclerosis, blood dyscrasias.

# Diagnosis

## **1. History**

it is important to know whether disease is congenital or acquired, stationary or progressive, associated with other syndromes or not, involvement of other members of the family and possible aetiologic factors.

## **2. Severity of deafness**

(mild, moderate, moderately severe, severe, profound or total) This can be found out on audiometry.

## **3. Type of audiogram**

whether loss is high frequency, low frequency, mid-frequency or flat type.

## **4. Site of lesion**

i.e. cochlear, retrocochlear or central.

## **5. Laboratory tests**

They depend on the aetiology suspected, e.g. X-rays or CT scan of temporal bone for evidence of bone destruction (congenital cholesteatoma, glomus tumour, middle ear malignancy or acoustic neuroma), blood counts (leukaemia), blood sugar (diabetes), serology for syphilis, thyroid functions (hypothyroidism), kidney function tests, etc.



# Management

Early detection of SNHL is important as measures can be taken to stop its progress, reverse it or to start an early rehabilitation programme, so essential for communication.

*Syphilis* of the inner ear is treatable with high doses of penicillin and steroids with improvement in hearing. Hearing loss of *hypothyroidism* can be reversed with replacement therapy. *Serous labyrinthitis* can be reversed by attention to middle ear infection. Early management of *Meniere's disease* can prevent further episodes of vertigo and hearing loss. SNHL due to *perilymph fistula* can be corrected surgically by sealing the fistula in the oval or round window with fat.

*Ototoxic drugs* should be used with care and discontinued if causing hearing loss. In many such cases, it may be possible to regain hearing, total or partial, if the drug is stopped. *Noise induced hearing loss* can be prevented from further deterioration if the person is removed from the noisy surroundings.

Rehabilitation of hearing-impaired with hearing aids and other devices is discussed in Chapter 20.

# SPECIFIC FORMS OF HEARING LOSS

## A. Inflammations of Labyrinth

It may be viral, bacterial or syphilitic.

### 1. *Viral labyrinthitis*

Viruses usually reach the inner ear by blood stream affecting stria vascularis and then the endolymph and organ of Corti. Measles, mumps and cytomegaloviruses are well documented to cause labyrinthitis. Several other viruses, e.g. rubella, herpes zoster, herpes simplex, influenza and Epstein-Barr are clinically known to cause deafness but direct proof of their invasion of labyrinth is lacking.

### 2. *Bacterial*

Bacterial infections reach labyrinth through the middle ear (tympagogenic) or through CSF (meningogenic). Labyrinthitis as a complication of middle ear infection is discussed on page 52. Sensorineural deafness following meningitis is a well-known clinical entity. Bacteria can invade the labyrinth along nerves, vessels, cochlear aqueduct or the endolymphatic sac. Membranous labyrinth is totally destroyed.

### 3. *Syphilitic*

Sensorineural hearing loss is caused both by congenital and acquired syphilis. Congenital syphilis is of two types: the *early form*, manifesting at the age of 2 or the *late form*, manifesting at the age of 8-20 years. Syphilitic involvement of the inner ear can cause:

- **(i)** Sudden sensorineural hearing loss which may be unilateral or bilateral. The latter is usually symmetrical in high frequencies or is a flat type.
- **(ii)** Meniere's syndrome with episodic vertigo, fluctuating hearing loss, tinnitus and aural fullness—a picture simulating Meniere's disease.
- **(iii)** Hennebert's sign. A positive fistula sign in the absence of a fistula. This is due to fibrous adhesions between the stapes footplate and the membranous labyrinth.
- **(iv)** Tullio phenomenon in which loud sounds produce vertigo.

page 38

page 39

*Diagnosis* of otosyphilis can be made by other clinical evidence of late acquired or congenital syphilis (interstitial keratitis, Hutchinson's teeth, saddle nose, nasal septal perforation and frontal bossing) and the laboratory tests. FTA-ABS (fluorescent treponema-absorption test) and VDRL or RPR (rapid plasma reagin) tests from CSF are useful to establish the diagnosis.

*Treatment* of otosyphilis includes i.v. penicillin and steroids.

## B. Familial Progressive Sensorineural Hearing Loss

It is a genetic disorder in which there is progressive degeneration of the cochlea starting in late childhood or early adult life. Hearing loss is bilateral with flat or basin-shaped audiogram but an excellent speech discrimination.

## C. Ototoxicity

Various drugs and chemicals can damage the inner ear and cause sensorineural hearing loss and tinnitus (Table 5.3).

### 1. Aminoglycoside antibiotics

Streptomycin, gentamicin and tobramycin are primarily vestibulotoxic. They selectively destroy type I hair cells of the crista ampullaris but, administered in large doses, can also damage the cochlea.

Neomycin, kanamycin, amikacin, sisomycin and dihydrostreptomycin are cochleotoxic. They cause selective destruction of outer hair cells, starting at the basal coil and progressing onto the apex of cochlea.

Patients particularly at risk are those

- (i) having impaired renal function,
- (ii) elderly people above the age of 65,
- (iii) concomitantly receiving other ototoxic drugs,
- (iv) who have already received aminoglycoside antibiotics,
- (v) who have genetic susceptibility to aminoglycosides. Here the antibiotic binds to the ribosome and interferes with protein synthesis, thus causing death of the cochlear cells.

Symptoms of ototoxicity-hearing loss, tinnitus and/or giddiness-may manifest during treatment or after completion of the treatment (delayed toxicity).

### 2. Diuretics

Furosemide and ethacrynic acid are called *loop diuretics* as they block transport of sodium and chloride ions in the ascending loop of Henle. They are known to cause oedema and cystic changes in the stria vascularis of the cochlear duct. In most cases, the effect is *reversible* but permanent damage may occur.

### 3. Salicylates

Table 5-3. Ototoxic drugs

- **A. Aminoglycoside antibiotics**
  - Streptomycin
  - Gentamicin
  - Tobramycin
  - Neomycin
  - Kanamycin
  - Amikacin
  - Sisomycin
- **B. Diuretics**
  - Furosemid
  - Ethacrynic acid
- **C. Antimalarials**
  - Quinine
  - Chloroquin
- **D. Cytotoxic drugs**
  - Nitrogen mustard
  - Cisplatin
  - Carboplatin
- **E. Analgesics**
  - Salicylates
  - Indomethacin
  - Phenyl butazone
  - Ibuprofen
- **F. Chemicals**
  - Alcohol
  - Tobacco
  - Marijuana
  - Carbon monoxide poisoning
- **G. Miscellaneous**
  - Erythromycin
  - Ampicillin
  - Propranolol
  - Propyl thiouracil

Symptoms of salicylate ototoxicity are tinnitus and bilateral sensorineural hearing loss particularly affecting higher frequencies. Site of lesion testing indicates cochlear involvement, but light and electron microscopy have failed to show any morphologic changes in the hair cells. Possibly they interfere at enzymatic level. Hearing loss due to salicylates is *reversible* after the drug is discontinued.

#### **4. Quinine**

Ototoxic symptoms due to quinine are tinnitus and sensorineural hearing loss, both of which are *reversible*. The symptoms generally appear with prolonged medication but may occur with smaller doses in those who are susceptible. Congenital deafness and hypoplasia of cochlea have been reported in children whose mothers received this drug during the first trimester of pregnancy. Ototoxic effects of quinine are due to vasoconstriction in the small vessels of the cochlea and stria vascularis.

#### **5. Chloroquin**

Effect is similar to that of quinine and permanent deafness can result.

#### **6. Cytotoxic drugs**

Nitrogen mustard, cisplatin and carboplatin can cause cochlear damage. They affect the outer hair cells of cochlea.

#### **7. Deferoxamine (Desferrioxamine)**

It is an iron-chelating substance used in the treatment of thalassaemic patients who receive repeated blood transfusions and in turn have high iron-load. Like cisplatin and aminoglycosides, deferoxamine also causes high frequency sensorineural hearing loss. Onset of hearing loss is sudden or delayed. It is permanent but in some cases it may be reversible when the drug is discontinued.

#### **8. Miscellaneous**

Isolated cases of deafness have been reported with erythromycin, ampicillin and chloramphenicol, indomethacin, phenylbutazone, ibuprofen, tetanus antitoxin, propranolol and propylthiouracil.

Alcohol, tobacco and marijuana also cause damage to the inner ear.

#### **9. Topical ear drops**

Topical use of drugs in the middle ear can also cause damage to the cochlea by absorption through oval and round windows. Deafness has occurred with the use of chlorhexidine which was used in the preparation of ear canal before surgery or use of ear drops containing aminoglycoside antibiotics, e.g. neomycin, framycetin and gentamicin.

## D. Noise Trauma

Hearing loss associated with exposure to noise has been well-known in boiler makers, iron-and coppersmiths and artillery men. Lately, noise trauma has assumed greater significance because of its being an occupational hazard; the compensations asked for and the responsibilities thrust upon the employer and the employee to conserve hearing. Hearing loss caused by excessive noise can be divided into two groups:

### 1. Acoustic trauma

Permanent damage to hearing can be caused by a *single brief exposure* to very intense sound, e.g. an explosion, gunfire or a powerful cracker. Noise level in rifle or a gun fire may reach 140-170 dB SPL. Sudden loud sound may damage outer hair cells, disrupt the organ of Corti and rupture the Reissner's membrane. A severe blast may concomitantly rupture tympanic membrane and disrupt ossicular chain.

### 2. Noise-induced hearing loss (NIHL)

Hearing loss, in this case, follows *chronic exposure* to less intense sounds than seen in acoustic trauma and is mainly a hazard of noisy occupations.

- **(a) Temporary threshold shift** The hearing is impaired immediately after exposure to noise but recovers after an interval of a few minutes to a few hours.
- **(b) Permanent threshold shift** The hearing impairment is permanent and does not recover at all.

The damage caused by noise trauma depends on several factors:

- **1. Frequency of noise** A frequency of 2000 to 3000 Hz causes more damage than lower or higher frequencies;
- **2. Intensity and duration of noise** As the intensity increases, permissible time for exposure is reduced. Table 5.4 gives the permissible limits of time for various intensity levels for the safety of ear;
- **3. Continuous vs interrupted noise** Continuous noise is more harmful;
- **4. Susceptibility of the individual**
- **5. Pre-existing ear disease.**

Table 5-4. Permissible exposure in cases of continuous noise or a number of short term exposures. [Government of India, Ministry of Labour, Model Rules under Factories Act 1948 (corrected up to 31.3.87)]

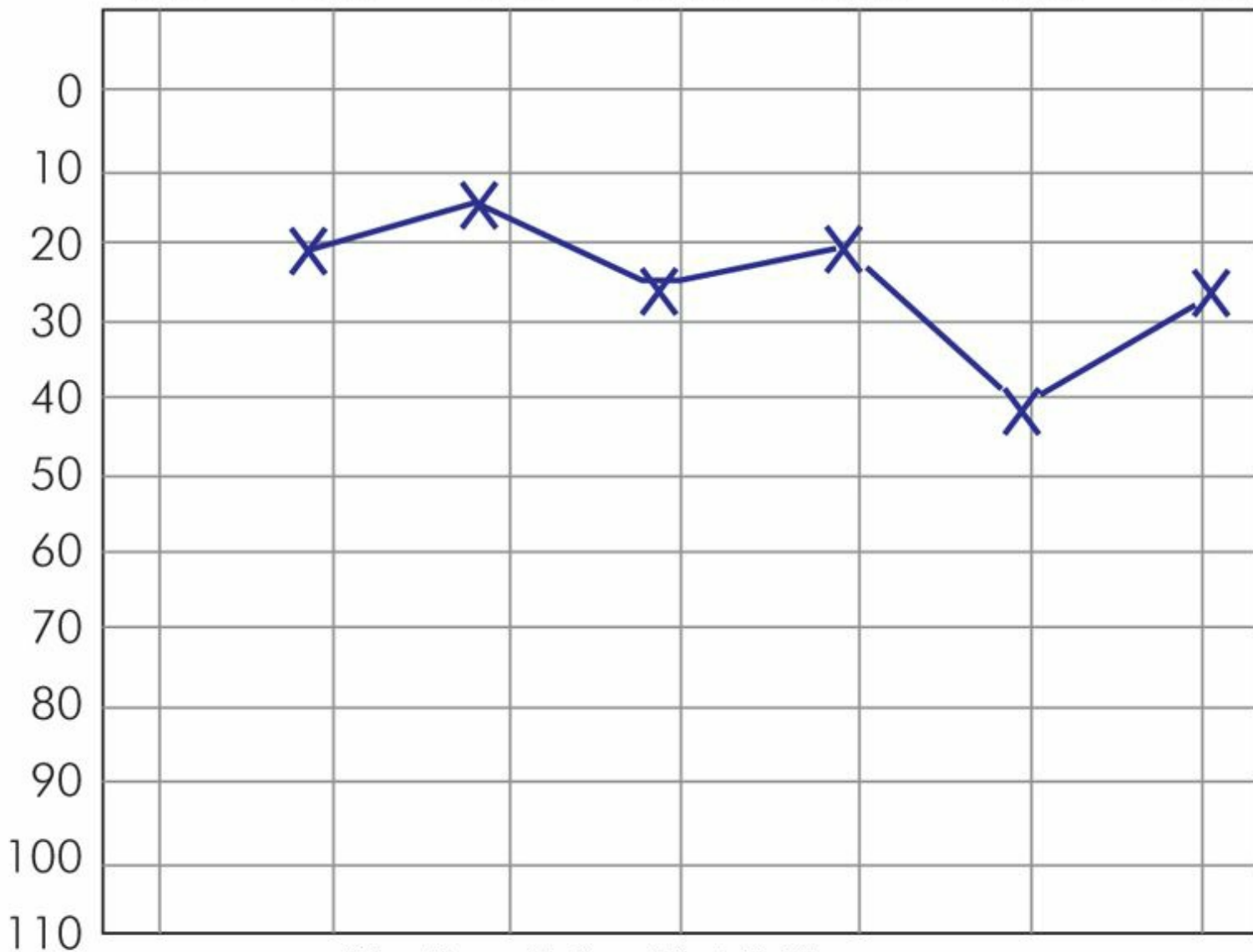
Noise level* (dBA)	Permitted daily exposure (hours)
90	8.0
92	6.0
95	4.0
97	3.0
100	2.0
102	1 1/2
105	1.0
110	1/2
115	1/4

\*5 dB rule of time-intensity states that "any rise of 5 dB noise level will reduce the permitted noise exposure time to half".

# Frequency in Hertz

125 250 500 1000 2000 4000 8000

Hearing loss in dB



Dhingra: Diseases of Ear Nose and Throat, 5th Edition  
Copyright © 2010 Elsevier. All rights reserved.

Figure 5.7 Early case of noise-induced hearing loss. Note dip at 4000 Hz.

A noise of 90 dB (A) SPL, 8 hours a day for 5 days per week is the maximum safe limit as recommended by Ministry of Labour, Govt. of India-Model Rules under Factories Act. (Table 5.4). No exposure in excess of 115 dB (A) is to be permitted. No impulse noise of intensity greater than 140 dB (A) is permitted.

page 40

page 41

The audiogram in NIHL shows a typical notch, at 4 kHz, both for air and bone conduction (Fig. 5.7). It is usually symmetrical on both sides. At this stage, patient complains of high pitched tinnitus and difficulty in hearing in noisy surroundings but no difficulty in day to day hearing. As the duration of noise exposure increases, the notch deepens and also widens to involve lower and higher frequencies. Hearing impairment becomes clinically apparent to the patient when the frequencies of 500, 1000 and 2000 Hz (the speech frequencies) are also affected.

NIHL causes damage to hair cells, starting in the basal turn of cochlea. Outer hair cells are affected before the inner hair cells.

Noise-induced hearing loss is preventable. Persons who have to work at places where noise is above 85 dB (A) should have pre-employment and then annual audiograms for early detection. Ear protectors (ear plugs or ear muffs) should be used where noise levels exceed 85 dB (A). They provide protection up to 35 dB. If hearing impairment has already occurred, rehabilitation is similar to that employed for other sensorineural hearing losses.

## E. Sudden Hearing Loss

It is defined as sensorineural hearing loss that has developed over a period of hours or a few days. Loss may be partial or complete. Mostly it is unilateral. It may be accompanied by tinnitus or temporary spell of vertigo.

### **Aetiology**

Most often the cause of sudden deafness remains obscure, in which case it is called the idiopathic variety. In such cases, three aetiological factors are considered - **viral**, **vascular** or the **rupture of cochlear membranes**. Spontaneous perilymph fistulae may form in the oval or round window. Other aetiological factors which cause sudden deafness and must be excluded are listed below. Remember the mnemonic "In The Very Ear Too No Major Pathology".

- **1. Infections** Mumps, herpes zoster, meningitis, encephalitis, syphilis, otitis media.
- **2. Trauma** Head injury, ear operations, noise trauma, barotrauma, spontaneous rupture of cochlear membranes.
- **3. Vascular** Haemorrhage (leukaemia), embolism or thrombosis of labyrinthine or cochlear artery or their vasospasm. They may be associated with diabetes, hypertension, polycythaemia, macroglobinaemia or sickle cell trait.
- **4. Ear (otologic)** Meniere's disease, Cogan's syndrome, large vestibular aqueduct.
- **5. Toxic** Ototoxic drugs, insecticides.
- **6. Neoplastic** Acoustic neuroma. Metastases in cerebellopontine angle, carcinomatous neuropathy.
- **7. Miscellaneous** Multiple sclerosis, hypothyroidism, sarcoidosis.
- **8. Psychogenic.**

### **Management**

As far as possible, the aetiology of sudden hearing loss should be discovered by detailed history, physical examination and laboratory investigations. The investigations may include audiometry, vestibular tests, imaging studies of temporal bones, sedimentation rate, tests for syphilis, diabetes, hypothyroidism, blood disorders and lipid profiles. Some cases may require exploratory tympanotomy where perilymph fistula is strongly suspected. Where the cause still remains obscure, treatment is empirical and consists of:

- **1. Bed rest.**
- **2. Steroid therapy** Prednisolone 40-60 mg in a single morning dose for one week and then tailed off in a period of 3 weeks. Steroids are anti-inflammatory and relieve oedema. They have been found useful in idiopathic sudden hearing loss of moderate degree.
- **3. Inhalation of carbogen** (5% CO<sub>2</sub> + 95% O<sub>2</sub>) It increases cochlear blood flow and improves oxygenation.
- **4. Vasodilator drugs.**
- **5. Low molecular weight dextran** It decreases blood viscosity. It is contraindicated in cardiac failure and bleeding disorders.
- **6. Hyperbaric oxygen therapy** Given in the first month of onset of hearing loss, some benefits have been claimed.

### **Prognosis**

Fortunately, about half the patients of idiopathic sensorineural hearing loss recover spontaneously within 15 days. Chances of recovery are poor after 1 month. Severe hearing loss and that associated with vertigo have poor prognosis. Younger patients below 40 and those with moderate losses have better prognosis.



## F. Presbycusis

Sensorineural hearing loss associated with physiological aging process in the ear is called presbycusis. It usually manifests at the age of 65 years but may do so early if there is hereditary predisposition, chronic noise exposure or generalised vascular disease.

Four pathological types of presbycusis have been identified.

### **1. Sensory**

This is characterised by degeneration of the organ of corti, starting at the basal coil and progressing gradually to the apex. Higher frequencies are affected but speech discrimination remains good.

### **2. Neural**

This is characterised by degeneration of the cells of spiral ganglion, starting at the basal coil and progressing to the apex. Neurons of higher auditory pathways may also be affected. This manifests with high tone loss but speech discrimination is poor and out of proportion to the pure tone loss.

### **3. Strial or metabolic**

This is characterised by atrophy of stria vascularis in all turns of cochlea. In this, the physical and chemical processes of energy production are affected. It runs in families. Audiogram is flat but speech discrimination is good.

### **4. Cochlear conductive**

This is due to stiffening of the basilar membrane thus affecting its movements. Audiogram is sloping type.

Patients of presbycusis have great difficulty in hearing in the presence of background noise though they may hear well in quiet surroundings. They may complain of speech being heard but not understood. Recruitment phenomenon is positive and all the sounds suddenly become intolerable when volume is raised. Tinnitus is another bothersome problem and in some it is the only complaint.

Patients of presbycusis can be helped by a hearing aid. They should also have lessons in speech reading through visual cues. Curtailment of smoking and stimulants like tea and coffee may help to decrease tinnitus.

# NON-ORGANIC HEARING LOSS (NOHL)

In this type of hearing loss, there is no organic lesion. It is either due to malingering or is psychogenic. In the former, usually there is a motive to claim some compensation for being exposed to industrial noises, head injury or ototoxic medication. Patient may present with any of the three clinical situations:

(a) Total hearing loss in both ears, (b) total loss in only one ear or (c) exaggerated loss in one or both ears. The responsibility of the physician is to find out: Is the patient malingering? If so, what is his actual threshold of hearing? This is accomplished by:

## **1. High index of suspicion**

Suspicion further rises when the patient makes exaggerated efforts to hear, frequently making requests to repeat the question or placing a cupped hand to the ear.

## **2. Inconsistent results on repeat pure tone and speech audiometry tests**

Normally, the result of repeat tests are within  $\pm 5$  dB. A variation greater than 15 dB is diagnostic of NOHL.

## **3. Absence of shadow curve**

Normally, a shadow curve can be obtained while testing bone conduction, if the healthy ear is not masked. This is due to transcranial transmission of sound to the healthy ear. Absence of this curve in a patient complaining of unilateral deafness is diagnostic of NOHL.

## **4. Inconsistency in PTA and SRT**

Normally, pure tone average (PTA) of three speech frequencies (500, 1000 and 2000 Hz) is within 10 dB of SRT. An SRT better than PTA by more than 10 dB points to NOHL.

## **5. Stenger test**

It can be done with a pair of identical tuning forks or a double-channel audiometer. Principle involved is that, if a tone of two intensities, one greater than the other, is delivered to two ears simultaneously, only the ear which receives tone of greater intensity will hear it. To do this test, take two tuning forks of equal frequency, strike and keep them say 25 cm from each ear. Patient will claim to hear it in the normal ear. Now bring the tuning fork on the side of feigned deafness to within 8 cm, keeping the tuning fork on the normal side at the same distance. The patient will deny hearing anything even though tuning fork on normal side is where it could be heard earlier. A person with true deafness should continue to hear on the normal side. Patient should be blind-folded during this test.

This same test can be performed with a two-channel audiometer using pure tone or speech signals.

## **6. Acoustic reflex threshold**

Normally, stapedial reflex is elicited at 70-100 dB SL. If patient claims total deafness but the reflex can be elicited, it indicates NOHL.

## **7. Electric response audiometry (ERA)**

It is very useful in NOHL and can establish hearing acuity of the person to within 5-10 dB of actual thresholds.

# SOCIAL AND LEGAL ASPECTS OF HEARING LOSS

## Hearing Loss and Deafness

### *Hearing loss*

is impairment of hearing and its severity may vary from mild to severe or profound, while the term **deafness** is used, when there is little or no hearing at all. In some countries, this rigid differentiation is not made. They use the term deafness to denote any degree of hearing loss irrespective of its severity. In 1980, WHO recommended that the term "deaf" should be applied only to those individuals whose hearing impairment is so severe that they are unable to benefit from any type of amplification. A similar definition is used in our country while extending benefits to the hearing handicapped.

## Definition of Deaf

(Ministry of Social Welfare, Government of India-Scheme of Assistance to Hearing Handicap).

"The deaf are those in whom the sense of hearing is non-functional for ordinary purposes of life". They do not hear/understand sounds at all even with amplified speech. The cases included in the category will be those having hearing loss more than 90 dB in the better ear (profound impairment) or total loss of hearing in both ears.

page 42

page 43

### ***The partially hearing***

are defined as those falling under any one of the following categories:

<b><i>Category</i></b>	<b><i>Hearing acuity</i></b>
Mild impairment	More than 30 but not more than 45 dB in better ear
Serious impairment	More than 45 but not more than 60 dB in better ear
Severe impairment	More than 60 but not more than 90 dB in better ear.

## Degree of Hearing Loss (WHO classification)

WHO (1980) recommended the following classification on the basis of pure tone audiogram taking the average of the thresholds of hearing for frequencies of 500, 1000 and 2000 Hz with reference to ISO: R. 389-1970 (international calibration of audiometers).

<b>Degree of hearing loss</b> (Fig. 5.8)	
<b>1. Mild</b>	26-40 dB
<b>2. Moderate</b>	41-55 dB
<b>3. Moderately severe</b>	56-70 dB
<b>4. Severe</b>	71-91 dB
<b>5. Profound</b>	More than 91 dB
<b>6. Total</b>	

From this it is implied that there is no *apparent* impairment of hearing from 0 to 25 dB.

The disability to understand speech with different degrees of hearing loss is given in Table 5.5.

# Impairment, Disability and Handicap

When a disease process strikes an organ or a system it causes an *impairment* either in structure or function, but this impairment may or may not become clinically manifested. When impairment affects the ability to perform certain functions in the range considered normal for that individual it is called *disability*. The disability further restricts the duties and roles expected from an individual by society and is called a *handicap*.

Table 5-5. Hearing loss and difficulty in hearing speech

Hearing threshold in better ear (average of 500, 1000, 2000 Hz)	Degree of impairment (WHO classification)	Ability to understand speech
0-25	Not significant	No significant difficulty with faint speech
26-40	Mild	Difficulty with faint speech.
41-55	Moderate	Frequent difficulty with normal speech.
56-70	Moderately severe	Frequent difficulty even with loud speech.
71-91	Severe	Can understand only shouted or amplified speech.
Above 91	Profound	Usually cannot understand even amplified speech.

Disease → Impairment → Disability → Handicap.

To exemplify, injury (disease) to the ear may result in hearing impairment which, depending on its severity, will affect the individual's ability to hear and perform certain activities (disability) and will be termed as handicap by the society.

# Degree of Handicap

Sometimes it is desired to express the impairment and handicap in terms of percentage for the purposes of compensation. Different countries and professional bodies have adopted their own system to calculate this percentage.

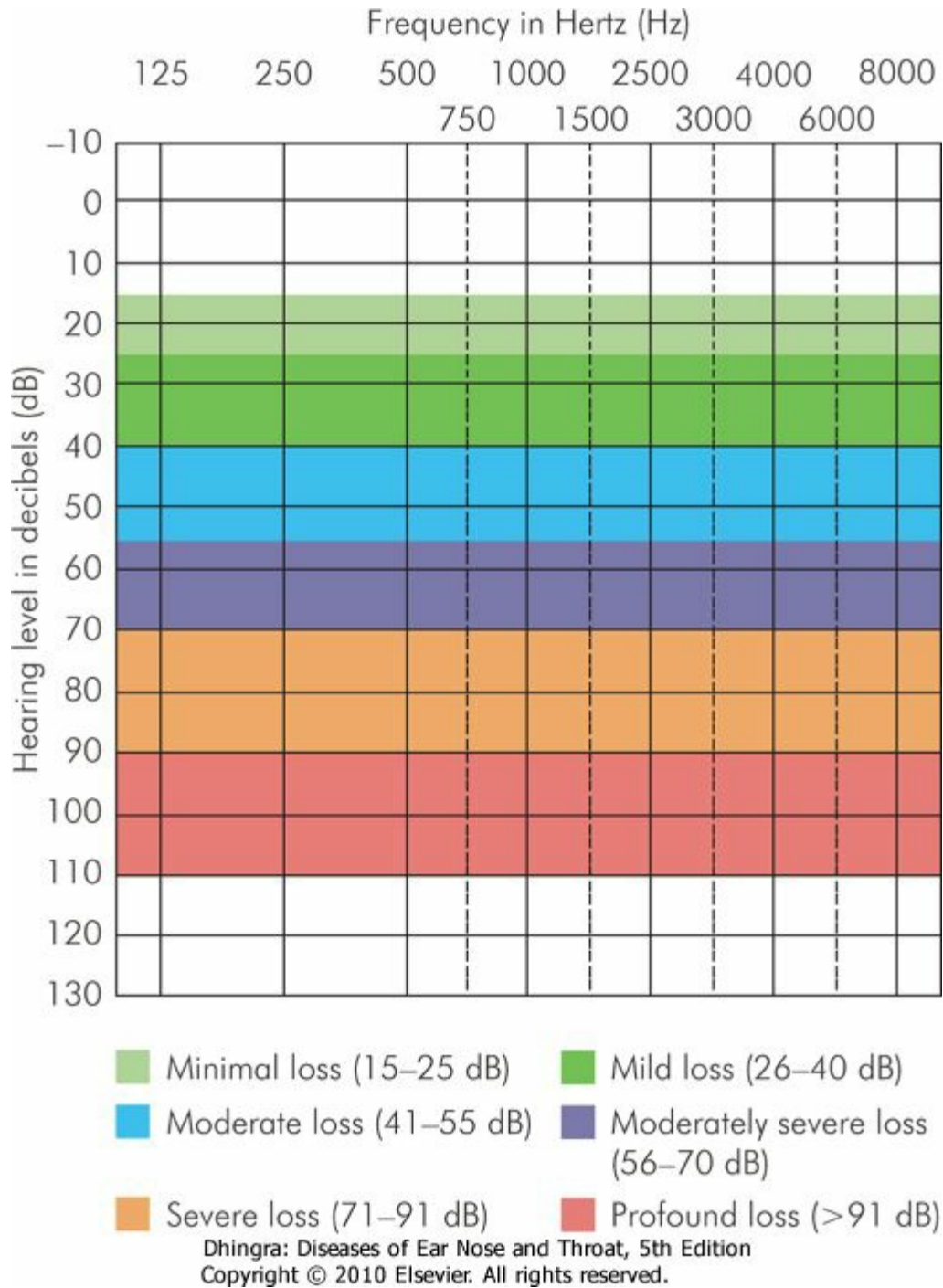


Figure 5.8 Classification of hearing loss. Ninety five percent of population has thresholds between -10 and +10 dB HL.

## Recommended categorisation and percentage of hearing impairment (Dept. of Personnel, Govt. of India)

Table 5-6. Recommendations about the categories and the tests required

I. Recommended classification					
S. no.	Category	Type of impairment	dB level and/or	Speech discrimination	Percentage of impairment
1.	I.	Mild hearing impairment	dB 26 to 40 dB in better ear	80 to 100% in better ear	Less than 40%
		Moderate hearing			

2.	II.	impairment	41 to 55 dB in better ear	50 to 80% in better ear	40 to 50%
3.	III.	Severe hearing impairment	56 to 70 dB hearing impairment in better ear	40 to 50%	50 to 75%
4.	IV.	(a) Total deafness	No hearing	No discrimination	100%
		(b) Near total deafness	91 dB and above in better ear	-do-	100%
		(c) Profound hearing Impairment	71 to 90 dB	Less than 40% in better ear	75 to 100%

(Pure tone average of hearing in 500, 1000 and 2000 Hz by air conduction should be taken as basis for consideration as per the test recommendations).

Further it should be noted that:

(a) When there is only an island of hearing present in one or two frequencies in better ear, it should be considered as total loss of hearing.

(b) Wherever there is no response (NR) at any of the 3 frequencies (500, 1000, 2000 Hz) it should be considered as equivalent to 130 dB loss for the purposes of classification of disability and in arriving at the average. This is based on the fact that maximum intensity limits in most of the audiometers is 110 dB and some audiometers have additional facilities for 20 dB for testing.

**II. Recommendations about the categories of disability (Hearing impairment-Physical aspect only-Test recommended).**

(a) Pure tone audiometry (ISO R 389-1970 at present, is being used as Audiometric Standard in most of the audiometers. Hence the audiometers used in testing should be accordingly calibrated). Three frequency average at 500, 1000 and 2000 Hz by Air Conduction (A.C.), will be used for categorisation.

(b) Wherever possible the pure tone audiometric results should be supplemented by the speech discrimination score-tested at sensation level (S.L.), i.e. the speech discriminations test is conducted at 30-40 dB\* the patient's hearing threshold. The stimuli used be either phonetically balance words (PB) of the particular language or its equivalent material. At present only a few Indian languages have standard speech material for testing. Hence wherever the standardised test material is not available, either standardised Indian English Test could be made use of with English knowing population or equivalent material to PB, be used.

(c) Wherever children are tested and pure tone audiometry is not possible, free field testing should be employed.

**Suggestions of the facilities to be offered to the disabled for rehabilitation.**

Category I	No special benefits.
Category II	Considered for Hearing Aids at free or concessional costs only.
Category III	Hearing aids, free of cost or at concessional rates. Job reservation-benefit of special Employment Exchange. Scholarships at School. Single language formula.
Category IV	Hearing Aids-facilities of reservation-special employment exchange. Special facilities in schools like scholarships. Hearing aids-exemption from 3 language formula (to study in recommended single language).

It is felt that for consideration of admission under special category for courses conducted by institutions like Indian Institute of Technology (IIT), Industrial Training Institute (ITI) and others, categories I and II only should be considered for reservation of seats, provided they fulfill the other educational stipulations for the course.

We have considered the different types of hearing affection, i.e. conductive versus sensorineural, and agree that the disability will be judged by the conditions prevalent in the patient at the time of referral and examination. In case of failure of surgery or other therapeutic interventions, the patient will be considered and categorised on the basis of the recommended tests.

\*Left blank is the original recommendations; has been added by the author.

**Total percentage handicap of an individual**

$$= \frac{(\text{better ear \%} \times 5) + \text{worse ear\%}}{6}$$

	500 Hz	1000 Hz	2000 Hz	Average
Right ear	60	75	90	75 dB
Left ear	30	45	60	45 dB
Impairment Rt. ear: 75 - 25 = 50; 50 × 1.5 = 75%				
Impairment Lt. ear: 45 - 25 = 20; 20 × 1.5 = 30%				

$$\begin{aligned} \text{Total handicap} &= \frac{(30 \times 5) + 75}{6} = \frac{225}{6} \\ &= 37.5\% \\ &= 38\% \text{ (rounded off)} \end{aligned}$$

One of the methods to find hearing handicap is given below:



- (i) Take an audiogram and calculate the average of thresholds of hearing for frequencies of 500, 1000 and 2000 Hz say = A.
- (ii) Deduct from it 25 dB (as there is no impairment up to 25 dB), i.e. A-25.
- (iii) Multiply it by 1.5, i.e.  $(A-25) \times 1.5$ .

This is the percentage of hearing impairment for that ear. Similarly calculate the percentage of hearing impairment for the other ear. *Example:*

In the above calculation only three speech frequencies (500, 1000 and 2000 Hz) are taken into account but it is felt that frequency of 3000 Hz is important for hearing in the presence of noise and should also be taken into account. American Academy of Ophthalmology and Otolaryngology recommends and takes into account the average of four frequencies 500, 1000, 2000 and 3000 Hz when calculating the handicap.

Government of India reserved certain percentage of vacancies in Group C and D in favour of the physically handicapped and has extended certain other benefits. It has also recommended the classification based on percentage of impairment and the test required to be performed (see Table 5.6). (Brochure on Reservations and concessions for physically handicapped in central Govt. Services published by Ministry of Personnel, Public grievances and pensions, Dept. of Personnel and Training).

## Unilateral Hearing Loss

Unilateral loss of hearing, even though total, does not produce a serious handicap or affect speech but it impairs localisation of the sound source, difficulty in discrimination of speech in the presence of background noise and some difficulty at a meeting or in classroom when the speaker is on the side of affected ear. It should also alert the individual that he does not have a "spare or reserve ear" and has to take all precautions for the safety of the only hearing ear; also the surgeon should be careful when he is called upon to operate on this only hearing ear. Bone-anchored hearing aids are the treatment of choice for management of single-sided deafness (see page 137).

Assessment of vestibular functions can be divided into two groups:

- **A.** Clinical tests
- **B.** Laboratory tests

# A. Clinical Tests

## 1. Spontaneous Nystagmus

Nystagmus is an important sign in the evaluation of vestibular system. It is defined as involuntary, rhythmical, oscillatory movement of eyes. It may be horizontal, vertical or rotatory. Vestibular nystagmus has a slow and a fast component, and by convention, the direction of nystagmus is indicated by the direction of the fast component. Intensity of nystagmus is indicated by its degree (Table 6.1).

To elicit nystagmus, patient is seated in front of the examiner or lies supine on the bed. The examiner keeps his finger about 30 cm from the patient's eye in the central position and moves it to the right or left, up or down, but not moving at any time, more than 30° from the central position to avoid gaze nystagmus. Presence of spontaneous nystagmus always indicates an organic lesion.

**Table 6-1. Degree of nystagmus\***

1st degree	It is weak nystagmus and is present when patient looks in the direction of fast component.
2nd degree	It is stronger than the 1st degree nystagmus and is present when patient looks straight ahead.
3rd degree	It is stronger than 2nd degree nystagmus and is present even when patient looks in the direction of the slow component.

\*These degrees are according to Alexander's law and may not hold true in case of nystagmus of central origin.

Vestibular nystagmus is called *peripheral*, when it is due to lesion of labyrinth or VIIIth nerve and *central*, when lesion is in the central neural pathways (vestibular nuclei, brainstem, cerebellum).

Irritative lesions of the labyrinth (serous labyrinthitis) cause nystagmus to the side of lesion. Paretic lesions (purulent labyrinthitis, trauma to labyrinth, section of VIIIth nerve) cause nystagmus to the healthy side. Nystagmus of peripheral origin can be suppressed by optic fixation by looking at a fixed point, and enhanced in darkness or by the use of Frenzel glasses (+20 dioptré glasses) both of which abolish optic fixation.

Nystagmus of central origin cannot be suppressed by optic fixation. Purely *torsional nystagmus* indicates lesion of the brain stem/vestibular nuclei and is seen in syringomyelia. *Vertical downbeat* nystagmus indicates lesion at craniocervical region such as Arnold-Chiari malformation or degenerative lesion of the cerebellum. *Vertical upbeat* nystagmus is seen in lesions at the junction of pons and medulla or pons and mid-brain. *Pendular nystagmus* is either congenital or acquired. The latter is seen in multiple sclerosis. Pendular nystagmus may also be disconjugate, i.e. vertical in one eye and horizontal in the other. Table 6.2 shows differences in the nystagmus of peripheral and central lesions.

**Table 6-2. Positional nystagmus in peripheral and central lesions of vestibular system. Positional nystagmus is elicited by Hallpike manoeuvre (vide infra)**

	Peripheral	Central
Latency	2-20 seconds	No latency
Duration	Less than 1 minute	More than 1 minute
Direction of nystagmus	Direction fixed, towards the undermost ear	Direction changing
Fatiguability	Fatiguable	Non-fatiguable
Accompanying symptoms	Severe vertigo	None or slight

page 46

page 47

## 2. Fistula Test

The basis of this test is to induce nystagmus by producing pressure changes in the external canal which are then transmitted to the labyrinth. Stimulation of labyrinth results in nystagmus and vertigo. The test is performed by applying intermittent pressure on the tragus or by using Siegle's speculum. Normally, the test is negative because the pressure changes in the external auditory canal cannot be transmitted to the labyrinth. It is positive when there is erosion of horizontal semicircular canal as in cholesteatoma or a surgically-created window in the horizontal canal (fenestration operation), abnormal opening in the oval window (post-stapedectomy fistula) or the round window (rupture of round window membrane). A positive fistula also implies that the labyrinth is still functioning; it is absent when labyrinth is dead. A *false negative fistula* test is also seen when cholesteatoma covers the site of fistula and does not allow pressure changes to be transmitted to the labyrinth.

A *false positive fistula test* (i.e. positive fistula test without the presence of a fistula) is seen in congenital syphilis and in about 25% cases of Meniere's disease (*Hennebert's sign*). In congenital syphilis, stapes footplate is hypermobile while in Meniere's disease it is due to the fibrous bands connecting utricular macula to the stapes footplate. In both these conditions, movements of stapes result in stimulation of the utricular macula.

## 3. Romberg Test

The patient is asked to stand with feet together, and arms by the side with eyes first open and then closed. With the eyes open, patient can still

compensate the imbalance but with eyes closed, vestibular system is at more disadvantage. In peripheral vestibular lesions, the patient sways to the side of lesion. In central vestibular disorder, patient shows instability. If patient can perform this test without sway, "sharpened Romberg test", is performed. In this the patient stands with one heel in front of toes and arms folded across the chest. Inability to perform the sharpened Romberg test indicates vestibular impairment.

#### **4. Gait**

The patient is asked to walk along a straight line to a fixed point, first with eyes open and then closed. In case of uncompensated lesion of peripheral vestibular system, with eyes closed, the patient deviates to the affected side.

#### **5. Past-pointing and Falling**

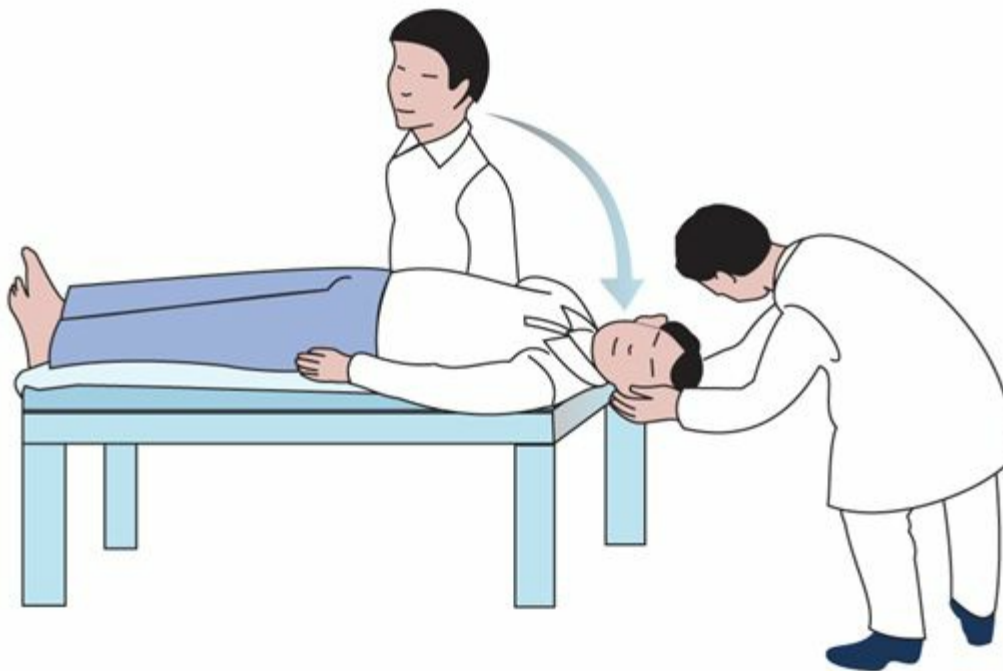
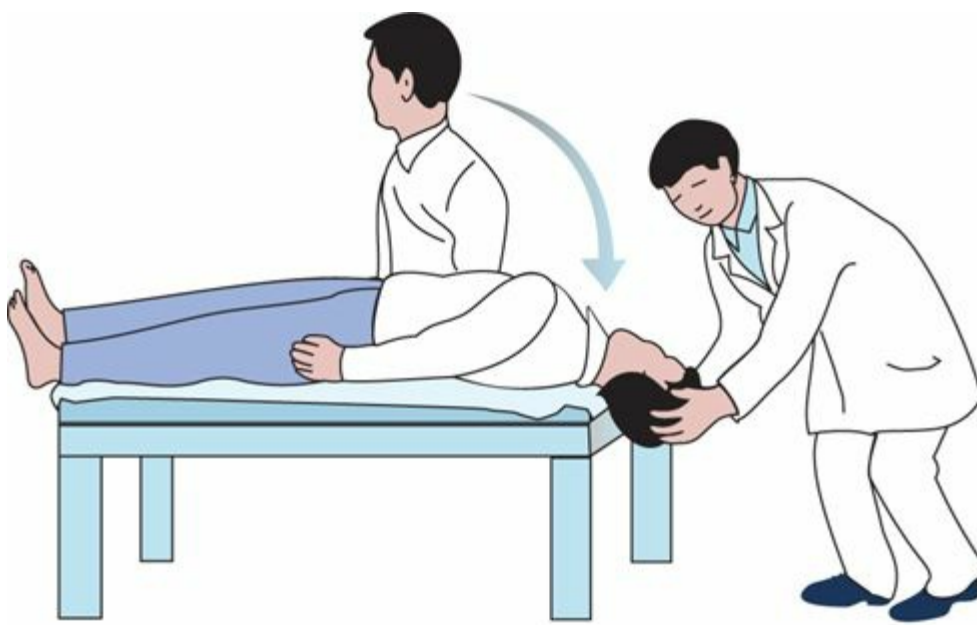The past-pointing, falling and slow component of nystagmus are all in the same direction. If there is acute vestibular failure, say on the right side, nystagmus is to the left but the past-pointing and falling will be towards the right, i.e. towards side of the slow component.

#### **6. Hallpike Manoeuvre (Positional Test)**

This test is particularly useful when patient complains of vertigo in certain head positions. It also helps to differentiate a peripheral from a central lesion.

##### ***Method***

Patient sits on a couch. Examiner holds the patient's head, turns it 45° to the right and then places the patient in a supine position so that his head hangs 30° below the horizontal (Fig. 6.1). Patient's eyes are observed for nystagmus. The test is repeated with head turned to left and then again in straight head-hanging position. Four parameters of nystagmus are observed: *latency*, *duration*, *direction* and *fatiguability* (see Table 6.2). In benign paroxysmal positional vertigo, nystagmus appears after a latent period of 2-20 seconds, lasts for less than a minute and is always in one direction, i.e. towards the ear that is undermost. On repetition of the test, nystagmus may still be elicited but lasts for a shorter period. On subsequent repetitions it disappears altogether, i.e. nystagmus is fatiguable. Patient also complains of vertigo when the head is in critical position.



Dhingra: Diseases of Ear Nose and Throat, 5th Edition  
Copyright © 2010 Elsevier. All rights reserved.

Figure 6.1 Hallpike manoeuvre.

In central lesions (tumours of IVth ventricle, cerebellum, temporal lobe, multiple sclerosis, vertebrobasilar insufficiency or raised intracranial tension) nystagmus is produced immediately, as soon as the head is in critical position without any latency and lasts as long as head is in that critical position. Direction of nystagmus also varies in different test positions (direction changing) and is non-fatiguable on repetition of test (Table 6.2).

### Test of Cerebellar Dysfunction

All cases of giddiness should be tested for cerebellar disorders. Disease of the cerebellar hemisphere causes:

- (i) Asynergia (abnormal finger-nose test)
- (ii) Dysmetria (inability to control range of motion)
- (iii) Adiadochokinesia (inability to perform rapid alternating movements)
- (iv) Rebound phenomenon (inability to control movement of extremity when opposing forceful restraint is suddenly released)

Midline disease of cerebellum causes:

- (i) Wide base gait

- **(ii)** Falling in any direction
- **(iii)** Inability to make sudden turns while walking
- **(iv)** Truncal ataxia

Nystagmus observed in midline or hemispherical disorders of cerebellum includes gaze evoked nystagmus, rebound nystagmus and abnormal optokinetic nystagmus.

## B. Laboratory Tests of Vestibular Function

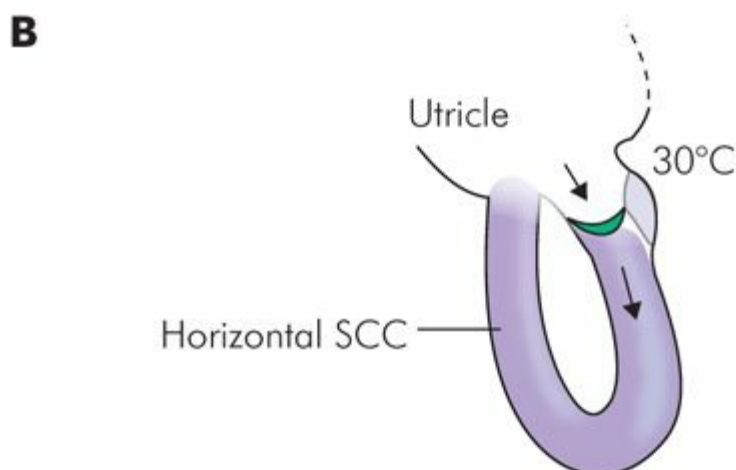
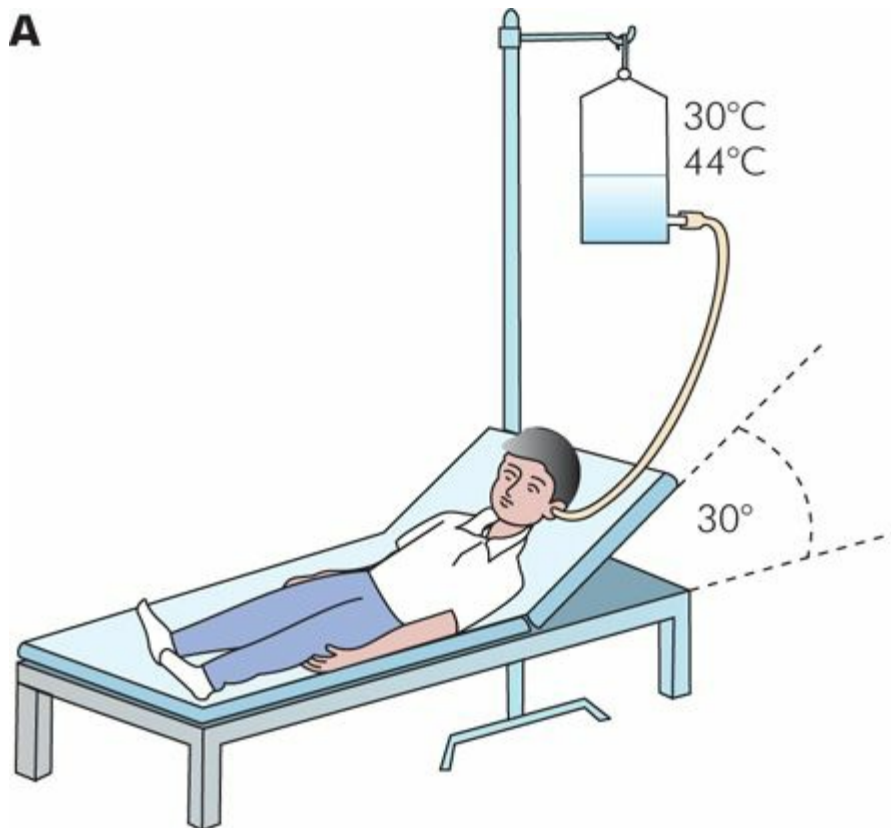
### 1. Caloric Test

The basis of this test is to induce nystagmus by thermal stimulation of the vestibular system. Advantage of the test is that each labyrinth can be tested separately. Patient is also asked whether vertigo induced by the caloric test is qualitatively similar to the type experienced by him during the episode of vertigo. If yes, it proves labyrinthine origin of vertigo.

#### (a) Modified Kobrak test

It is a quick office procedure. Patient is seated with head tilted 60° backwards to place horizontal canal in vertical position. Ear is irrigated with ice water for 60 seconds, first with 5 ml and if there is no response, 10 ml, 20 ml and 40 ml. Normally, nystagmus beating towards the opposite ear, will be seen with 5 ml of ice water. If response is seen with increased quantities of water between 5 and 40 ml, labyrinth is considered hypoactive. No response to 40 ml water indicates dead labyrinth.

#### (b) Fitzgerald-Hallpike test (bithermal caloric test)



Dhingra: Diseases of Ear Nose and Throat, 5th Edition  
Copyright © 2010 Elsevier. All rights reserved.

Figure 6.2 Fitzgerald-Hallpike test. (A) Patient is in supine position and head raised by 30° to make horizontal canal vertical. (B) Position of canal and the direction of flow of endolymph.

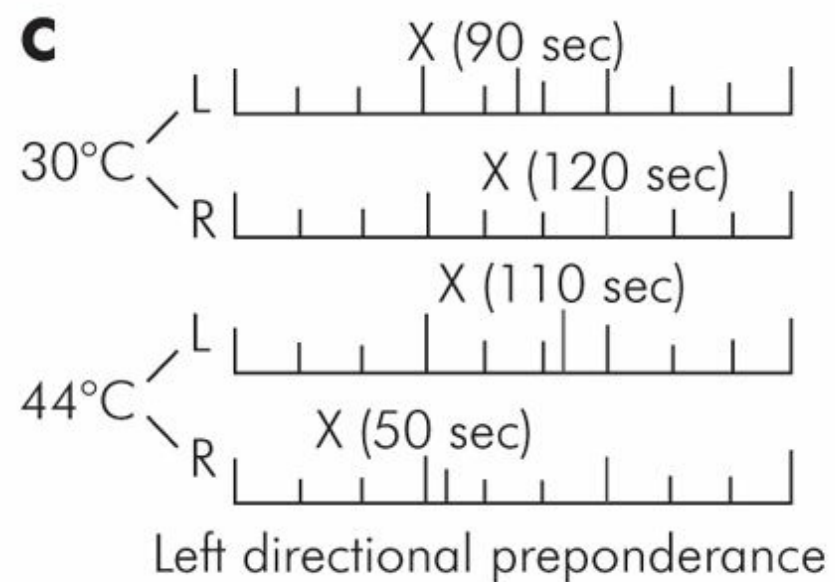
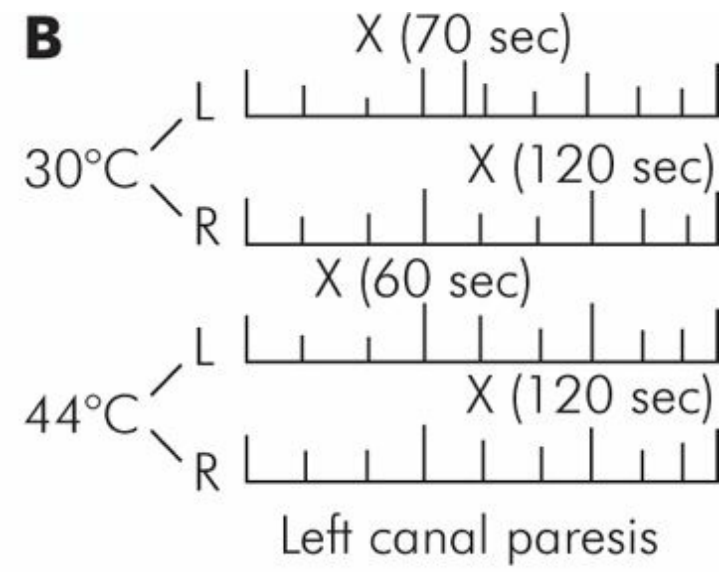
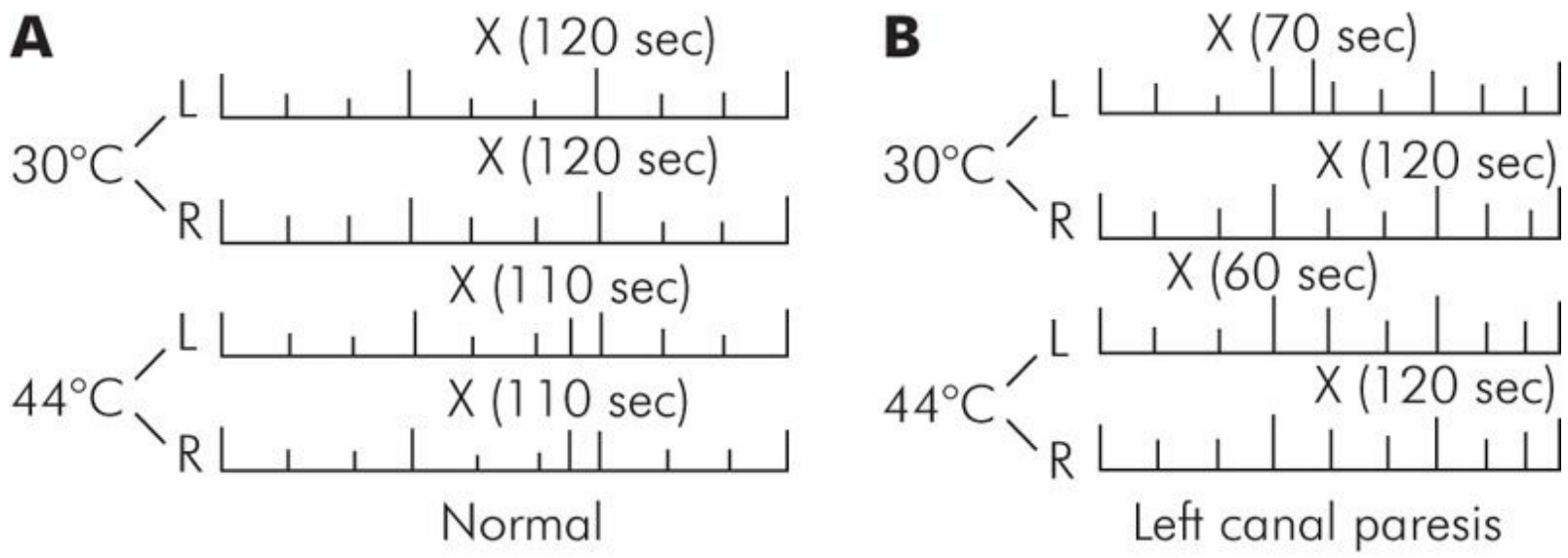
In this test, patient lies supine with head tilted 30° forward so that horizontal canal is vertical (Fig. 6.2). Ears are irrigated for 40 seconds alternately with water at 30°C and at 44°C (i.e. 7° below and above normal body temperature) and eyes observed for appearance of nystagmus till its end



point. Time taken from the start of irrigation to the end point of nystagmus is recorded and charted on a *calorigram* (Fig. 6.3). If no nystagmus is elicited from any ear, test is repeated with water at 20°C for 4 minutes before labelling the labyrinth dead. A gap of 5 minutes should be allowed between two ears. Cold water induces nystagmus to opposite side and warm water to the same side (remember mnemonic COWS: Cold-Opposite, Warm-Same). Depending on response to the caloric test, we can find canal paresis or dead labyrinth, directional preponderance, i.e. nystagmus is more in one particular direction than in the other, or both canal paresis and directional preponderance.

$$\text{Response from the left ear} = \frac{L_{30} + L_{44} \times 100}{L_{30} + L_{44} + R_{30} + R_{44}}$$

$$\text{Response from the right ear} = \frac{R_{30} + R_{44} \times 100}{L_{30} + L_{44} + R_{30} + R_{44}}$$



Dhingra: Diseases of Ear Nose and Throat, 5th Edition  
Copyright © 2010 Elsevier. All rights reserved.

Figure 6.3 Calorigram.

1. Normal: Responses from both labyrinths are almost same with both cold and warm water. Cold water is usually a stronger stimulus than the warm one.
2. Left canal paresis. Responses from left labyrinth both with cold and warm water are much less compared to those from right.

$$(L) \frac{70 + 60}{70 + 120 + 60 + 120} = \frac{130}{370} \quad \text{Left canal paresis}$$

$$(R) \frac{120 + 120}{70 + 120 + 60 + 120} = \frac{240}{370}$$

$$(L) \frac{120 + 110}{90 + 120 + 110 + 50} = \frac{230}{370} \quad \text{Left directional preponderance}$$

$$(R) \frac{90 + 50}{90 + 120 + 110 + 50} = \frac{140}{370}$$

**Canal paresis.** It indicates that response (measured as duration of nystagmus) elicited from a particular canal (labyrinth), right or left, after stimulation with cold and warm water is less than that from the opposite side. It can also be expressed as percentage of the total response from both ears. where  $L_{30}$  is the response from left side with water at 30°C and  $L_{44}$  is response from left ear after stimulation with warm water at 44°C. Less or no response from a particular side is indicative of depressed function of the ipsilateral labyrinth, vestibular nerve or vestibular nuclei and is seen in Meniere's disease, acoustic neuroma, post-labyrinthectomy or vestibular nerve section.

**Directional preponderance.** It takes into consideration the duration of *nystagmus to the right or left* irrespective of whether it is elicited from the right or left labyrinth. We know that:

$$\text{Right beating nystagmus} = \frac{L_{30} + R_{44}}{L_{30} + L_{44} + R_{30} + R_{44}} \times 100$$

$$\text{Left beating nystagmus} = \frac{R_{30} + L_{44}}{L_{30} + L_{44} + R_{30} + R_{44}} \times 100$$

Right beating nystagmus is caused by  $L_{30}$  and  $R_{44}$  and left beating nystagmus is caused by  $R_{30}$  and  $L_{44}$ . Therefore:

If the nystagmus is 25-30% or more on one side than the other, it is called directional preponderance to that side.

It is believed that directional preponderance occurs towards the side of a central lesion, away from the side in a peripheral lesion; however it does not help to localise the lesion in central vestibular pathways.

Canal paresis and directional preponderance can also be seen together.

Canal paresis on one side with directional preponderance to the opposite side is seen in unilateral Meniere's disease while canal paresis with directional preponderance to ipsilateral side is seen in acoustic neuroma.

### (c) Cold-air caloric test

This test is done when there is perforation of tympanic membrane because irrigation with water in such a case with perforation is contraindicated. The test employs Dundas Grant tube which is a coiled copper tube wrapped in cloth. The air in the tube is cooled by pouring ethyl chloride, and then blown into the ear. It is only a rough qualitative test.

## 2. Electronystagmography

It is a method of detecting and recording of nystagmus which is spontaneous or induced by caloric, positional, rotational or optokinetic stimulus. The test depends on the presence of corneoretinal potentials which are recorded by placing electrodes at suitable places round the eyes. The test is also useful to detect nystagmus which is not seen with the naked eye. It also permits to keep a permanent record of nystagmus.

## 3. Optokinetic Test

Patient is asked to follow a series of vertical stripes on a drum moving first from right to left and then from left to right. Normally it produces nystagmus with slow component in the direction of moving stripes and fast component in the opposite direction. Optokinetic abnormalities are seen in brainstem and cerebral hemisphere lesions. Thus this test is useful to diagnose a central lesion.

## 4. Rotation Test

Patient is seated in Barany's revolving chair with his head tilted 30° forward and then rotated 10 turns in 20 seconds. The chair is stopped abruptly and nystagmus observed. Normally there is nystagmus for 25-40 seconds. The test is useful as it can be performed in cases of congenital abnormalities where ear canal has failed to develop and it is not possible to perform the caloric test. Disadvantage of the test is that both the labyrinths are simultaneously stimulated during the rotation process and cannot be tested individually. The test has now been made more sophisticated by the use of torsion swings, electronystagmography and computer analysis of the results.

## 5. Galvanic Test

It is the only vestibular test which helps in differentiating an end organ lesion from that of vestibular nerve. Patient stands with his feet together, eyes closed and arms outstretched and then a current of 1 mA is passed to one ear. Normally, person sways towards the side of anodal current.

Body sway can be studied by a special platform.

## **6. Posturography**

It is a method to evaluate vestibular function by measuring postural stability and is based on the fact that maintenance of posture depends on three sensory inputs-visual, vestibular and somatosensory. It uses either a fixed or a moving platform. Visual cues can also be varied. The clinical application of posturography is still under investigation.

Disorders of vestibular system cause vertigo and are divided into:

### **A. Peripheral**

which involve vestibular end organs and their first order neurons (i.e. the vestibular nerve). The cause lies in the internal ear or the VIIIth nerve. They are responsible for 85% of all cases of vertigo.

### **B. Central**

which involve central nervous system after the entrance of vestibular nerve in the brainstem and involve vestibulo-ocular, vestibulo-spinal and other central nervous system pathways.

Table 7.1 lists the common causes of vertigo of peripheral and central origin.

# A. PERIPHERAL VESTIBULAR DISORDERS

## 1. Meniere's disease (endolymphatic hydrops)

It is characterised by vertigo, fluctuating hearing loss, tinnitus and sense of pressure in the involved ear. Vertigo is of sudden onset, lasts for a few minutes to 24 hours or so. (The disease has been discussed on page 111).

## 2. Benign paroxysmal positional vertigo (BPPV)

Table 7-1. Vestibular disorders

Peripheral (Lesions of end organs vestibular nerve)	Central (Lesions of brainstem and central connections)
<ul style="list-style-type: none"> <li>• Meniere's disease</li> <li>• Benign paroxysmal positional vertigo</li> <li>• Vestibular neuronitis</li> <li>• Labyrinthitis</li> <li>• Vestibulotoxic drugs</li> <li>• Head trauma</li> <li>• Perilymph fistula</li> <li>• Syphilis</li> <li>• Acoustic neuroma</li> </ul>	<ul style="list-style-type: none"> <li>• Vertebrobasilar insufficiency</li> <li>• Posterior inferior cerebellar artery syndrome</li> <li>• Basilar migraine</li> <li>• Cerebellar disease</li> <li>• Multiple sclerosis</li> <li>• Tumours of brainstem and fourth ventricle</li> <li>• Epilepsy</li> <li>• Cervical vertigo</li> </ul>

It is characterised by vertigo when the head is placed in a certain critical position. There is no hearing loss or other neurologic symptoms. Positional testing establishes the diagnosis and helps to differentiate it from positional vertigo of central origin (Table 7.1). Disease is caused by a disorder of posterior semicircular canal though many patients have history of head trauma and ear infection.

It has been demonstrated that otoconial debris, consisting of crystals of calcium carbonate, is released from the degenerating macula of the utricle and floats freely in the endolymph. When it settles on the cupula of posterior semicircular canal in a critical head position, it causes displacement of the cupula and vertigo. The vertigo is fatiguable on assuming the same position repeatedly due to dispersal of the otoconia but can be induced again after a period of rest. Thus, typical history and Hallpike manoeuvre establishes the diagnosis.

The condition can be treated by performing **Epley's manoeuvre**. The principle of this manoeuvre is to reposition the otoconial debris from the posterior semicircular canal back into the utricle. The doctor stands behind the patient and the assistant on the side. The patient is made to sit on the table so that when he is made to lie down, his head is beyond the edge of the table as is done in Dix-Hallpike manoeuvre. His face is turned 45° to the affected side.

Position 1.	With the head turned 45°, the patient is made to lie down in head-hanging position (Dix-Hallpike manoeuvre). It will cause vertigo and nystagmus. Wait till vertigo and nystagmus subside.
Position 2.	Head is now turned so that affected ear is up.
Position 3.	The whole body and head are now rotated away from the affected ear to a lateral recumbent position in a face-down position.
Position 4.	Patient is now brought to a sitting position with head still turned to the unaffected side by 45°.
Position 5.	The head is now turned forward and chin brought down 20°.

The manoeuvre consists of five positions.

There should be a pause at each position till there is no nystagmus or there is slowing of nystagmus, before changing to the next position. After manoeuvre is complete, patient should maintain an upright posture for 48 hours. Eighty percent of the patients will be cured by a single manoeuvre. If the patient remains symptomatic, the manoeuvre can be repeated. A bone vibrator placed on the mastoid bone helps to loosen the debris.

## 3. Vestibular neuronitis

It is characterised by severe vertigo of sudden onset with no cochlear symptoms. Attacks may last from a few days to 2 or 3 weeks. It is thought to occur due to a virus that attacks vestibular ganglion. Management of acute attack is similar to that in Meniere's disease. The disease is usually self-limiting.

## 4. Labyrinthitis

It has been discussed in detail on page 90.

*Circumscribed labyrinthitis* is seen in cases of unsafe type of CSOM, and fistula test is positive.

*Serous labyrinthitis* is caused by trauma or infection (viral or bacterial) adjacent to inner ear but without actual invasion. There is severe vertigo and sensorineural hearing loss. A partial or full recovery of inner ear functions is possible if treated early.

*Purulent labyrinthitis* is a complication of CSOM. There is actual bacterial invasion of inner ear with total loss of cochlear and vestibular functions. Vertigo in this condition is due to acute vestibular failure. There is severe nausea and vomiting. Nystagmus is seen to the opposite side due to destruction of the affected labyrinth.

### **5. Vestibulotoxic drugs**

Several drugs cause ototoxicity by damaging the hair cells of the inner ear. Some primarily affect the cochlear while others affect the vestibular labyrinth. Aminoglycoside antibiotics particularly streptomycin, gentamicin, kanamycin have been shown to affect hair cells of the crista ampullaris and to some extent those of the maculae. Certain other drugs which cause dizziness or unsteadiness are antihypertensives, labyrinthine sedatives, oestrogen preparations, diuretics, antimicrobials (nalidixic acid, metronidazole) and antimalarials. However, their mode of action may be different.

### **6. Head trauma**

Head injury may cause concussion of labyrinth, completely disrupt the bony labyrinth or VIIIth nerve, or cause a perilymph fistula. Severe acoustic trauma, such as that caused by an explosion can also disturb the vestibular end organ (otoliths) and result in vertigo.

### **7. Perilymph fistula**

In this condition, perilymph leaks into the middle ear through the oval or round window. It can follow as a complication of stapedectomy, or ear surgery when stapes is accidentally dislocated. It can also result from sudden pressure changes in the middle ear (e.g. barotrauma, diving, forceful Valsalva) or raised intracranial pressure (weightlifting or vigorous coughing). A perilymph fistula causes intermittent vertigo and fluctuating sensorineural hearing loss, sometimes with tinnitus and sense of fullness in the ear (*compare* Meniere's disease).

### **8. Syphilis**

Syphilis of inner ear, both acquired and congenital, causes dizziness in addition to sensorineural hearing loss. Late congenital syphilis usually manifesting between 8 and 20 years, mimics Meniere's disease with episodes of acute vertigo, sensorineural hearing loss and tinnitus. Hennebert's sign, i.e. a positive fistula test in the presence of an intact tympanic membrane, is present in congenital syphilis. Neurosyphilis (tertiary acquired) can cause central type of vestibular dysfunction.

### **9. Acoustic neuroma**

It has been classified in peripheral vestibular disorders as it arises from CN VIII within internal acoustic meatus. It causes only unsteadiness or vague sensation of motion. Severe episodic vertigo, as seen in the end organ disease, is usually missing. (For details refer Chapter 18).

Other tumours of temporal bone (e.g. glomus tumour, carcinoma of external or middle ear and secondaries), destroy the labyrinth directly and cause vertigo.

## **B. CENTRAL VESTIBULAR DISORDERS**

### **1. Vertebrobasilar insufficiency**

It is a common cause of central vertigo in patients over the age of 50 years. There is transient decrease in cerebral blood flow. Common cause is atherosclerosis. Ischaemia in these patients may also be precipitated by hypotension or neck movements when cervical osteophytes press on the vertebral arteries during rotation and extension of head.

Vertigo is abrupt in onset, lasts several minutes and is associated with nausea and vomiting. Other neurological symptoms like visual disturbances, drop attacks, diplopia, hemianopia, dysphagia, hemiparesis resulting from ischaemia to other areas of brain may also accompany vertigo.

Some patients only complain of intermittent attacks of dizziness or vertigo on lateral rotation and extension of head.

### **2. Posterior inferior cerebellar artery syndrome (Wallenberg's syndrome)**

Thrombosis of the posterior inferior cerebellar artery cuts off blood supply to lateral medullary area. There is violent vertigo along with diplopia, dysphagia, hoarseness of voice, Horner's syndrome, sensory loss on ipsilateral side of face and contralateral side of the body, and ataxia. There may be horizontal or rotatory nystagmus to the side of the lesion.

### **3. Basilar migraine**

page 52

page 53

Migraine is a vascular syndrome, producing recurrent headaches with symptom-free intervals. Headache is usually unilateral and of the throbbing type. Basilar artery migraine produces occipital headache, visual disturbances, diplopia and severe vertigo which is abrupt and may last for 5-60 minutes. Basilar migraine is common in adolescent girls with strong menstrual relationship and positive family history.

### **4. Cerebellar disease**

Cerebellum may be affected by haemorrhage (hypertension), infarction (occlusion of arterial supply), infection (otogenic cerebellar abscess) or tumours (glioma, teratoma or haemangioma). Acute cerebellar disease may cause severe vertigo, vomiting and ataxia simulating an acute peripheral labyrinthine disorder. Tumours are slow growing and produce classical features of cerebellar disease, i.e. incoordination, past-pointing, adiadokinesia, rebound phenomenon, wide-based gait.

### **5. Multiple sclerosis**

It is a demyelinating disease affecting young adults. Vertigo and dizziness are common complaints. There are other multiple neurological signs and symptoms, e.g. blurring or loss of vision, diplopia, dysarthria, paraesthesia and ataxia. Spontaneous nystagmus may be seen. Acquired pendular nystagmus, dissociated nystagmus and vertical upbeat nystagmus are important features in diagnosis.

### **6. Tumours of brainstem and floor of IVth ventricle**

Gliomas, astrocytomas may arise from pons and midbrain; medulloblastoma, epidymomas, epidermoid cysts or teratomas may arise from floor of IVth ventricle. These tumours cause other neurological signs and symptoms in addition to vertigo and dizziness. Positional vertigo and nystagmus may also be the presenting features. CT scan and magnetic resonance imaging are useful in their diagnosis.

### **7. Epilepsy**

Vertigo may occur as an aura in temporal lobe epilepsy. The history of seizure and/or unconsciousness following the aura may help in the diagnosis. Sometimes, vertigo is the only symptom of epilepsy and that may pose a difficult diagnostic problem. E.E.G. may show abnormalities during the attack.

### **8. Cervical vertigo**

Vertigo may follow injuries of neck 7-10 days after the accident. It is usually provoked with movements of neck to the side of injury. Examination shows tenderness of neck, spasms of cervical muscles and limitation of neck movements. X-rays show loss of cervical lordosis. Exact mechanism of cervical vertigo is not known. It may be due to disturbed vertebrobasilar circulation, involvement of sympathetic vertebral plexus or alteration of tonic neck reflexes.

## Other Causes of Vertigo

### ***Ocular vertigo***

Normally, balance is maintained by integrated information received from the eyes, labyrinths and somatosensory system. A mismatch of information from any of these organs causes vertigo and in this case from the eyes. Ocular vertigo may occur in case of acute extraocular muscle paresis or high errors of refraction.

### ***Psychogenic vertigo***

This diagnosis is suspected in patients suffering from emotional tension and anxiety. Often other symptoms of neurosis, e.g. palpitation, breathlessness, fatigue, insomnia, profuse sweating and tremors are also present. Symptom of vertigo is often vague in the form of floating or swimming sensation or light-headedness. There is no nystagmus or hearing loss. Caloric test shows an exaggerated response.



### I. DISEASES OF THE PINNA

The pinna may be afflicted by congenital, traumatic, inflammatory or neoplastic disorders.

## A. Congenital Disorders

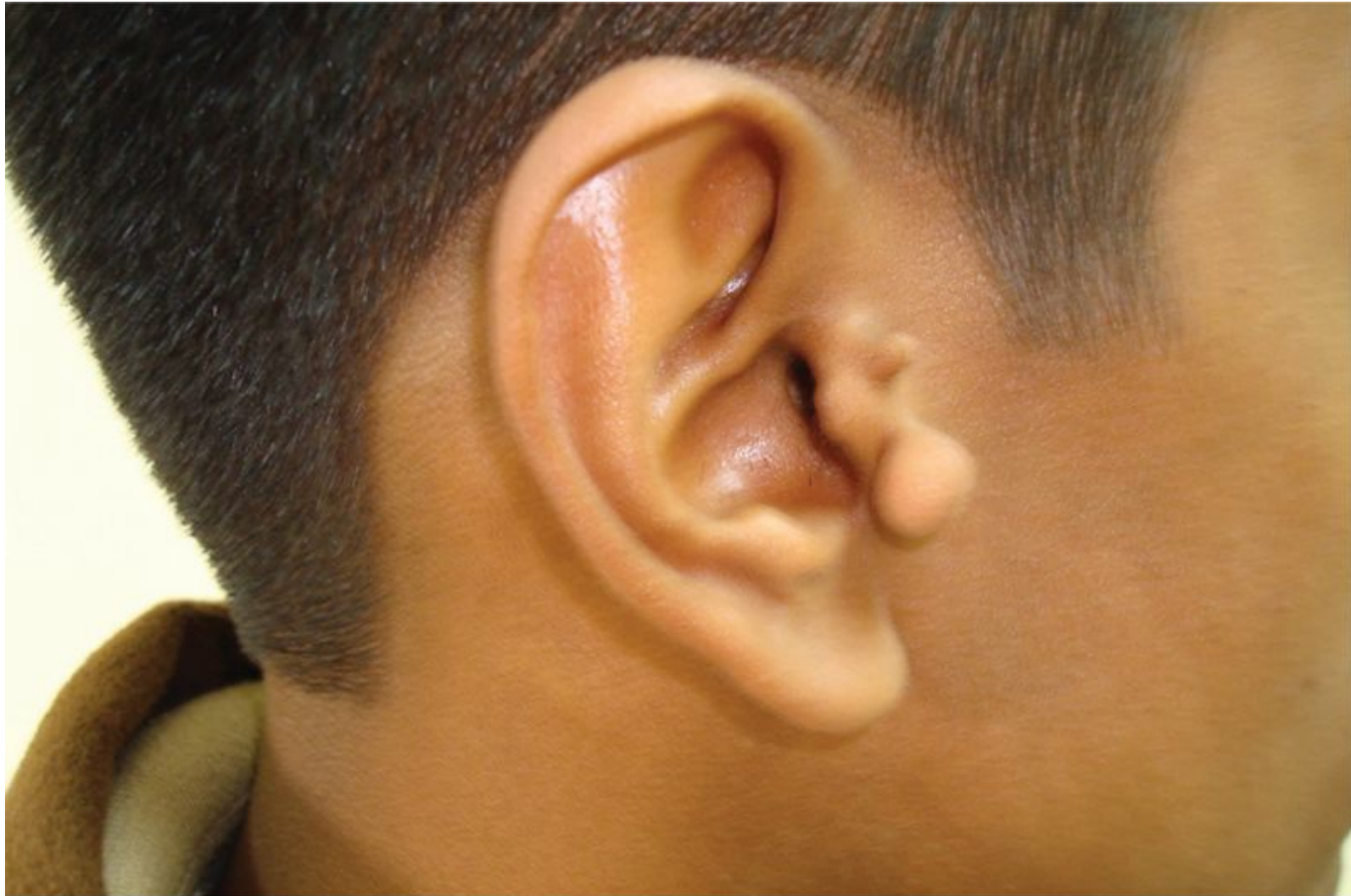The developmental abnormalities of the pinna may be just minor variations from the normal or major abnormalities.

### 1. *Bat ear (Lop ear)*

This is an abnormally protruding ear. The concha is large with poorly developed antihelix and scapha. The deformity can be corrected surgically any time after the age of 6 years, if cosmetic appearance so demands.

### 2. *Preauricular appendages*

They are skin-covered tags that appear on a line drawn from the tragus to the angle of mouth. They may contain small pieces of cartilage (Fig. 8.1).



Dhingra: Diseases of Ear Nose and Throat, 5th Edition  
Copyright © 2010 Elsevier. All rights reserved.

Figure 8.1 Preauricular appendages.

### 3. *Preauricular pit or sinus*

This is commonly seen at the root of helix and is due to incomplete fusion of tubercles. It may get repeatedly infected causing purulent discharge. Abscess may also form. Treatment is surgical excision of the track if the sinus gets repeatedly infected (Fig. 8.2).

### 4. *Anotia*

It is complete absence of pinna, and usually forms part of the first arch syndrome (Fig. 8.3).

### 5. *Macrotia*

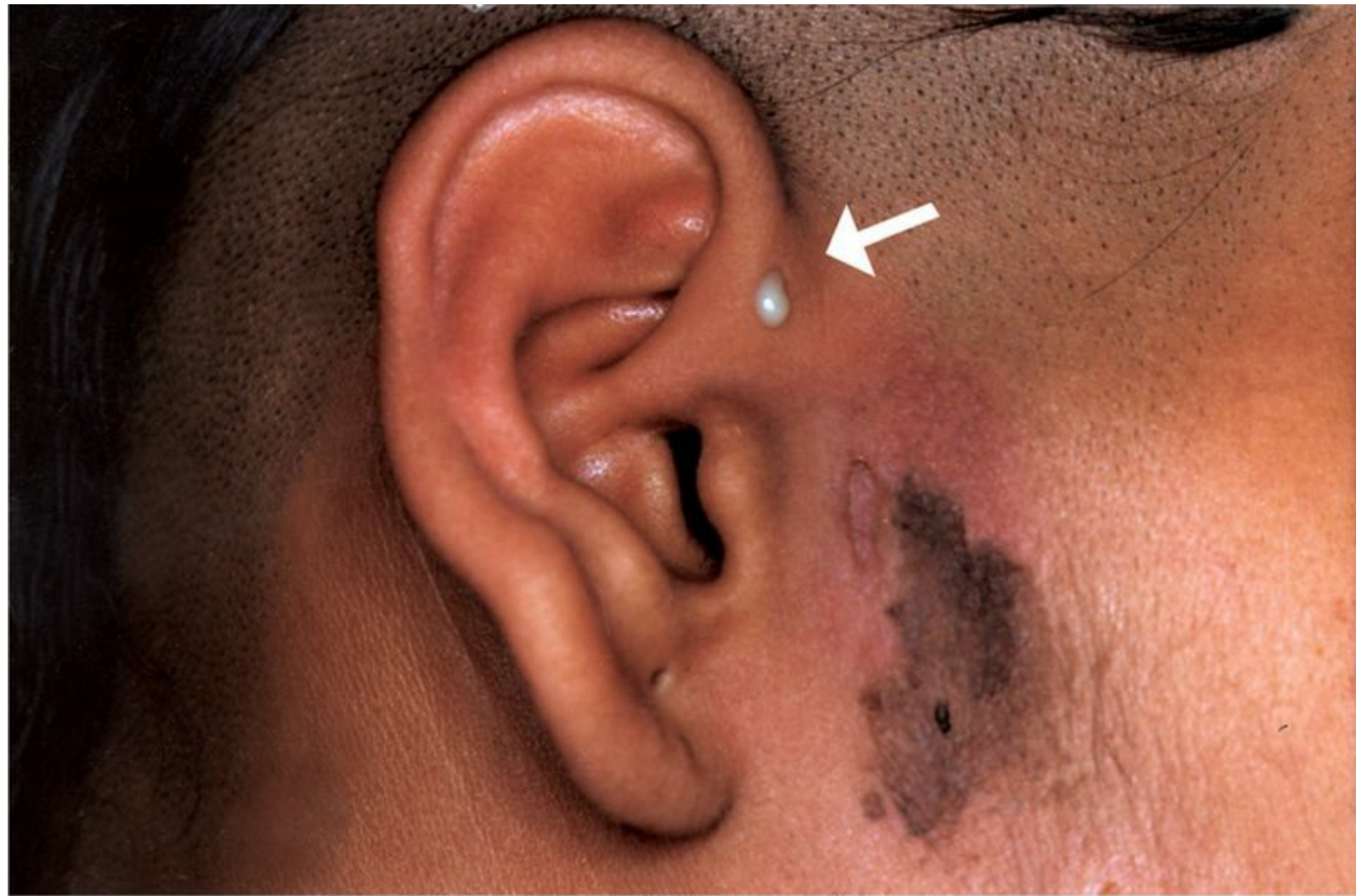It is excessively large pinna.

### 6. *Microtia (Fig. 8.4)*

It is a major developmental anomaly. Degree of microtia may vary. It is frequently associated with anomalies of external auditory canal, middle and

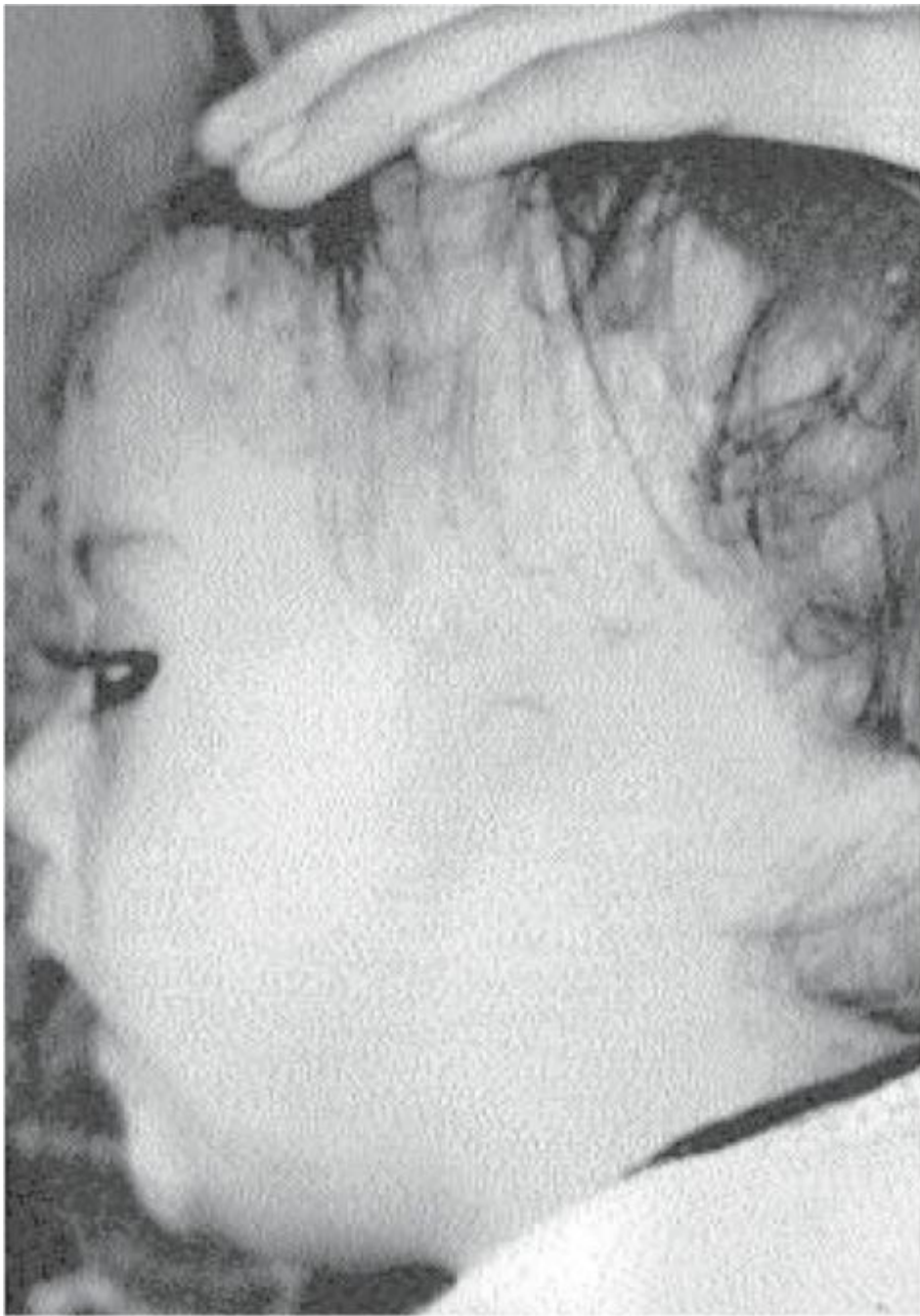## B. Trauma to the Auricle

### 1. Haematoma of the auricle



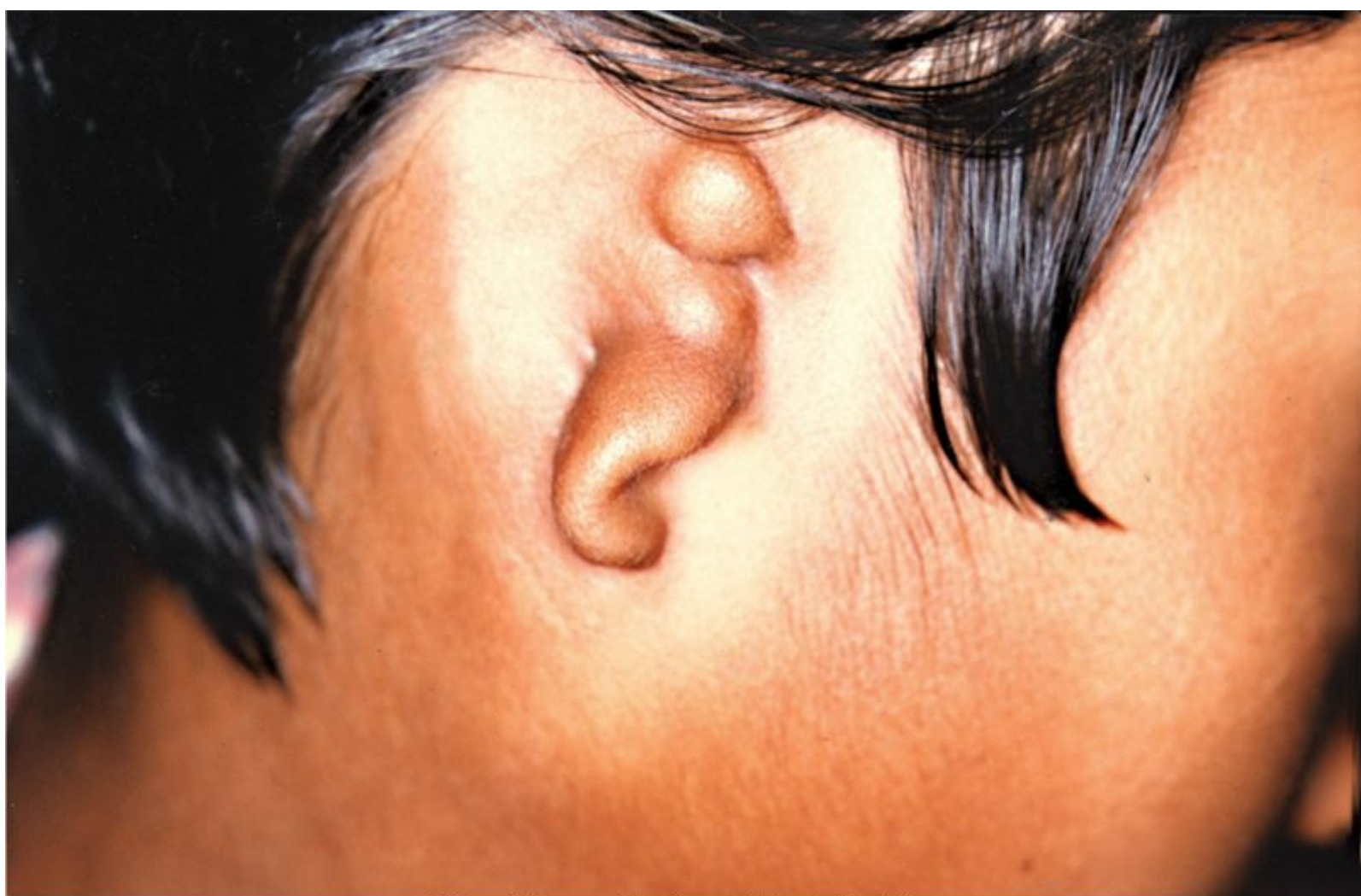Dhingra: Diseases of Ear Nose and Throat, 5th Edition  
Copyright © 2010 Elsevier. All rights reserved.

Figure 8.2 Infected preauricular sinus with pus exuding from the opening.



Dhingra: Diseases of Ear Nose and Throat, 5th Edition  
Copyright © 2010 Elsevier. All rights reserved.

Figure 8.3 Anotia. Note total absence of pinna and external auditory canal.



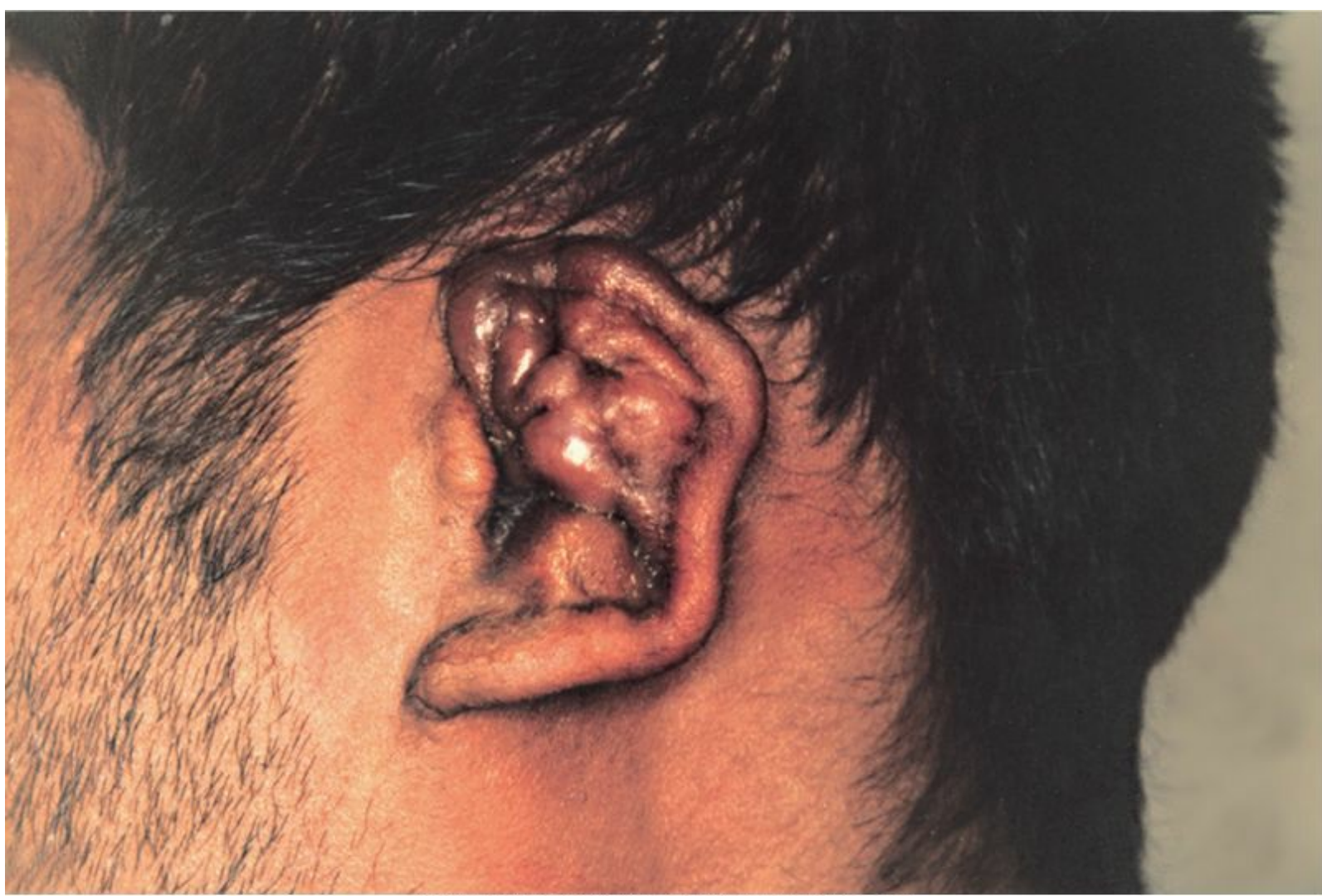Dhingra: Diseases of Ear Nose and Throat, 5th Edition  
Copyright © 2010 Elsevier. All rights reserved.

Figure 8.4 Microtia right ear.

It is collection of blood between the auricular cartilage and its perichondrium. Often it is the result of blunt trauma seen in boxers, wrestlers and rugby players. Extravasated blood may clot and then organise, resulting in a typical deformity called *Cauliflower ear* (Fig. 8.5). If haematoma gets infected, severe perichondritis may set in.

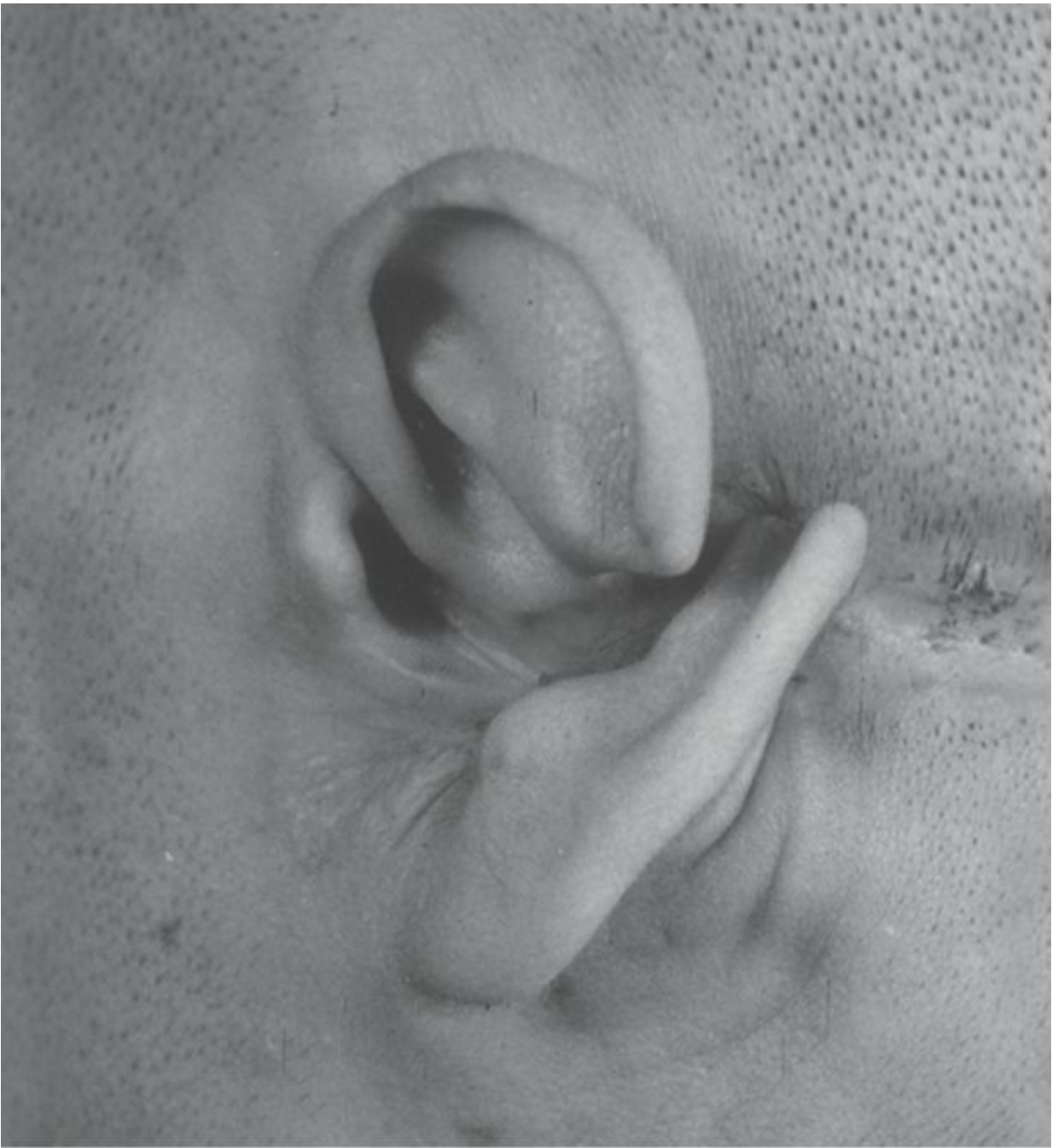Treatment is aspiration of the haematoma under strict aseptic precautions and a pressure dressing, carefully packing all concavities of the auricle to prevent reaccumulation. Aspiration may need to be repeated. When aspiration fails, incision and drainage should be done and pressure applied by dental rolls tied with through and through sutures. All cases should receive prophylactic antibiotics.

## **2. Lacerations (Fig. 8.6)**



Dhingra: Diseases of Ear Nose and Throat, 5th Edition  
Copyright © 2010 Elsevier. All rights reserved.

Figure 8.5 Cauliflower ear.



Dhingra: Diseases of Ear Nose and Throat, 5th Edition  
Copyright © 2010 Elsevier. All rights reserved.

Figure 8.6 Laceration left pinna.

They are repaired as early as possible. The perichondrium is stitched with absorbable sutures. Special care is taken to prevent stripping of perichondrium from cartilage for fear of avascular necrosis. Skin is closed with fine non-absorbable sutures. Broad spectrum antibiotics are given for one week.

### **3. Avulsion of pinna**

When pinna is still attached to the head by a small pedicle of skin, primary reattachment should be considered and it is usually successful. Completely avulsed pinna can be reimplanted in selected cases by the microvascular techniques; in others, the skin of the avulsed segment of pinna is removed and the cartilage implanted under the postauricular skin for later reconstruction.

### **4. Frostbite**

Injury due to frostbite varies between erythema and oedema, bullae formation, necrosis of skin and subcutaneous tissue, and complete necrosis with loss of the affected part.

Treatment of a frost-bitten ear consists of:

- **(a)** rewarming with moist cotton pledgets at a temperature of 38-42°C,

- **(b)** application of 0.5% silver nitrate soaks for superficial infection,
- **(c)** analgesics for pain; rapid rewarming of frost bitten ear causes considerable pain,
- **(d)** protection of bullae from rupture,
- **(e)** systemic antibiotics for deep infection,
- **(f)** surgical debridement should wait several months as the true demarcation between the dead and living tissues appears quite late.

### **5. Keloid of auricle**

It may follow trauma or piercing of the ear for ornaments. Usual sites are the lobule or helix (Fig. 8.7). Surgical excision of the keloid usually results in recurrence. Recurrence of keloid can be avoided by pre- and post-operative radiation with a total dose of 600-800 rads delivered in four divided doses. Some prefer local injection of steroid after excision.



## C. Inflammatory Disorders

### 1. *Perichondritis (Fig. 8.8)*

It results from infection secondary to lacerations, haematoma or surgical incisions. It can also result from extension of infection from diffuse otitis externa or a furuncle of the meatus. *Pseudomonas* and mixed flora are the common pathogens.

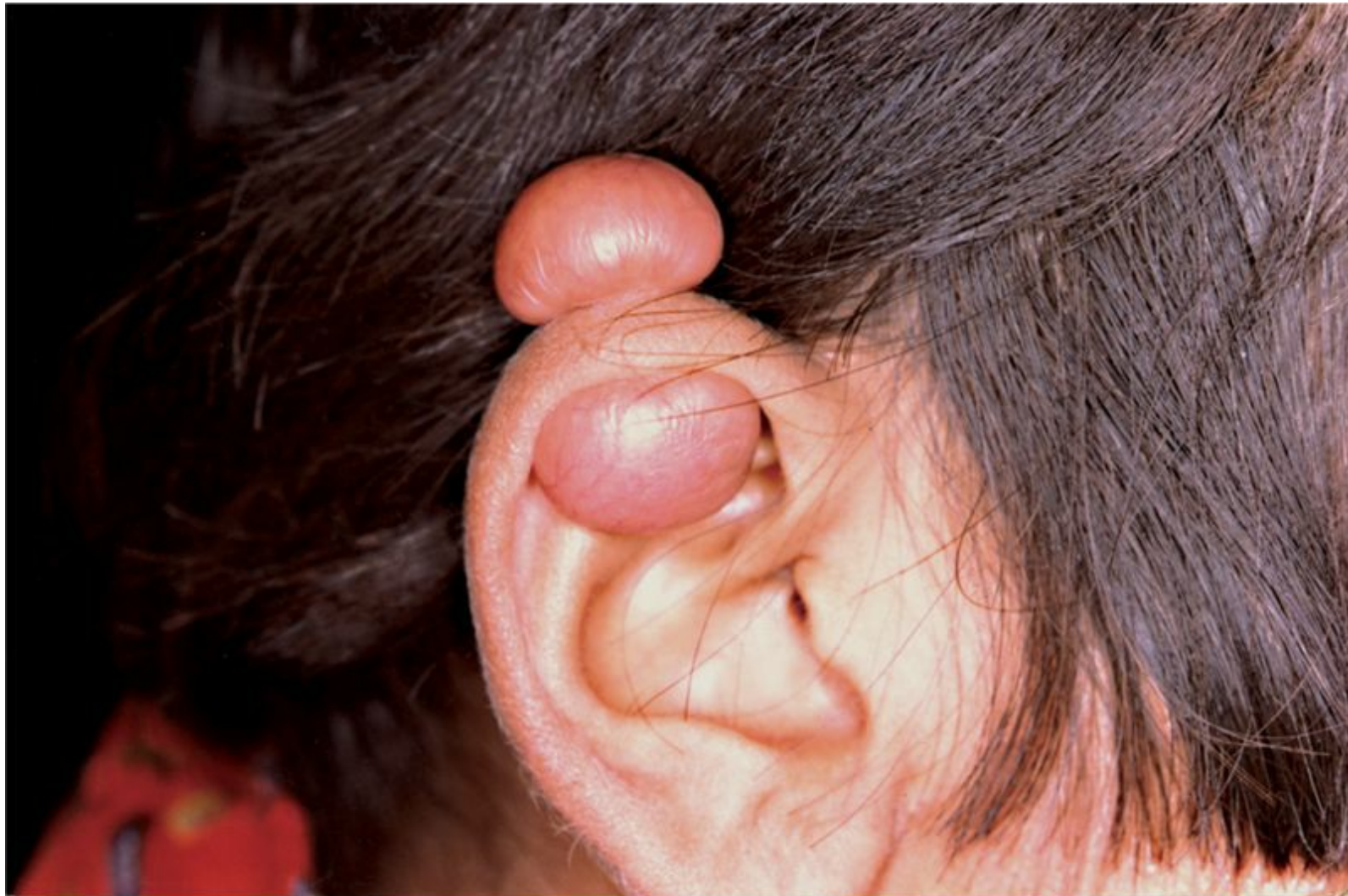Initial symptoms are red, hot and painful pinna which feels stiff. Later abscess may form between the cartilage and perichondrium with necrosis of cartilage as the cartilage survives only on the blood supply from its perichondrium. Treatment in early stages consists of systemic antibiotics and local application of 4% aluminium acetate compresses. When abscess has formed, it must be drained promptly and culture and sensitivity of the pus obtained. Incision is made in the natural fold and devitalised cartilage removed. Some prefer to place a catheter in the abscess and administer a continuous drip of antibiotics, selected by culture and sensitivity, for 7-10 days.

### 2. *Relapsing polychondritis*

It is a rare autoimmune disorder involving cartilage of the ear. Other cartilages, septal, laryngeal, tracheal, costal may also be involved. The entire auricle except its lobule becomes inflamed and tender. External ear canal becomes stenotic. Treatment consists of high doses of systemic steroids.

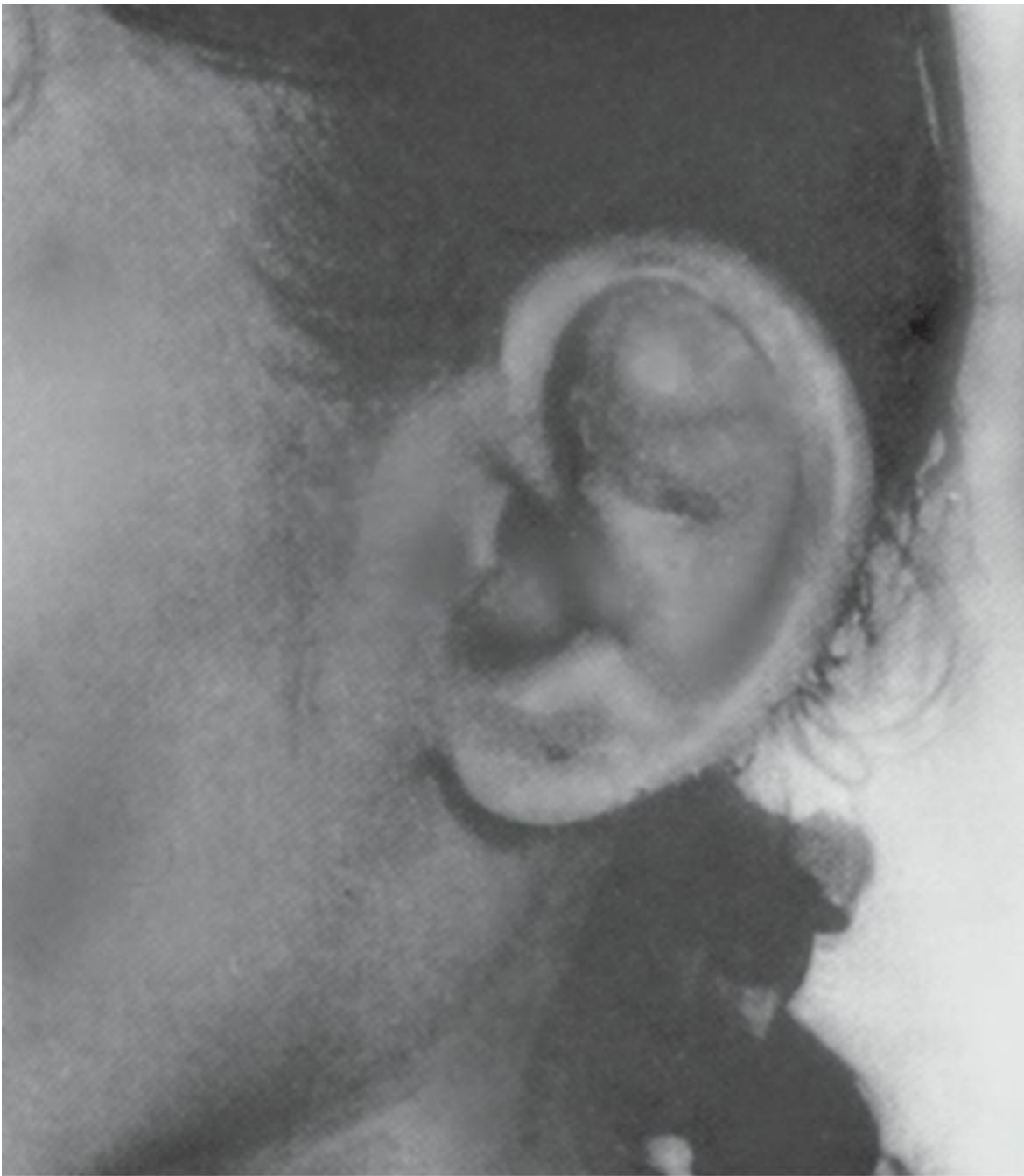### 3. *Chondrodermatitis nodularis chronica helicis*

Small painful nodules appear near the free border of helix in men about the age of 50 years. Nodules are tender and the patient is unable to sleep on the affected side. Treatment is excision of the nodule with its skin and cartilage.



Dhingra: Diseases of Ear Nose and Throat, 5th Edition  
Copyright © 2010 Elsevier. All rights reserved.

Figure 8.7 Keloid following piercing of pinna for ornaments.



Dhingra: Diseases of Ear Nose and Throat, 5th Edition  
Copyright © 2010 Elsevier. All rights reserved.

Figure 8.8 Perichondritis.

D. Tumours

See page 117.

## II. DISEASES OF EXTERNAL AUDITORY CANAL

The diseases of external auditory canal are grouped as:

- **A.** Congenital disorders
- **B.** Trauma
- **C.** Inflammation
- **D.** Tumours
- **E.** Miscellaneous conditions.

## A. Congenital Disorders

### **1. Atresia of external canal**

Congenital atresia of the meatus may occur alone or in association with microtia. When it occurs alone, it is due to failure of canalisation of the ectodermal core that fills the dorsal part of the first branchial cleft. The outer meatus, in these cases, is obliterated with fibrous tissue or bone while the deep meatus and the tympanic membrane are normal. Atresia with microtia is more common. It may be associated with abnormalities of the middle ear, internal ear and other structures.

### **2. Collaural fistula**

This is an abnormality of the first branchial cleft. The fistula has two openings; one, situated in the neck just below and behind the angle of mandible, and the other in the external canal or the middle ear. The track of the fistula traverses through the parotid in close relation to the facial nerve.

## B. Trauma to Ear Canal

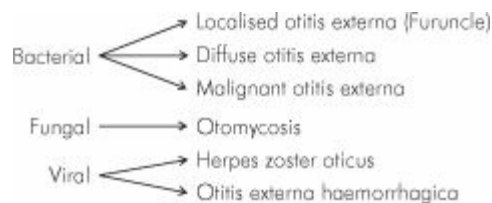*Minor lacerations* of canal skin result from Q-tip injury (scratching the ear with hair pins, needles or match stick) or unskilled instrumentation by the physician. They usually heal without sequelae.

*Major lacerations* result from gun shot wounds, automobile accidents or fights. The condyle of mandible may force through the anterior canal wall. These cases require careful treatment. Aim is to attain a skin-lined meatus of adequate diameter. Stenosis of the ear canal is a common complication.

## C. Inflammations of Ear Canal

Otitis externa may be divided, on aetiological basis, into:

### (i) Infective group



### (ii) Reactive group

- Eczematous otitis externa
- Seborrhoeic otitis externa
- Neurodermatitis

#### 1. Furuncle (localised acute otitis externa)

A furuncle is a staphylococcal infection of the hair follicle. As the hair are confined only to the cartilaginous part of the meatus, furuncle is seen only in this part of meatus. Usually single, the furuncles may be multiple.

Patient usually presents with severe pain and tenderness which are out of proportion to the size of the furuncle. Movements of the pinna are painful. Jaw movements, as in chewing, also cause pain in the ear. A furuncle of posterior meatal wall causes oedema over the mastoid with obliteration of the retroauricular groove. Periauricular lymph nodes (anterior, posterior and inferior) may also be enlarged and tender.

*Treatment* in early cases, without abscess formation, consists of systemic antibiotics, analgesics and local heat. An ear pack of 10% ichthammol glycerine provides splintage and reduces pain. Hygroscopic action of glycerine reduces oedema, while ichthammol is mildly antiseptic. If abscess has formed, incision and drainage should be done.

In case of *recurrent furunculosis*, diabetes should be excluded, and attention paid to the patient's nasal vestibules which may harbour staphylococci and the infection transferred by patient's fingers. Staphylococcal infections of the skin as a possible source should also be excluded and suitably treated.

#### 2. Diffuse otitis externa

It is diffuse inflammation of meatal skin which may spread to involve the pinna and epidermal layer of tympanic membrane.

#### Aetiology

Disease is commonly seen in hot and humid climate and in swimmers. Excessive sweating changes the pH of meatal skin from that of acid to alkaline which favours growth of pathogens. Two factors commonly responsible for this condition are:

- (a) trauma to the meatal skin, and
- (b) invasion by pathogenic organisms.

*Trauma* can result from scratching the ear canal with hair pins or match sticks, unskilled instrumentation to remove foreign bodies, vigorous cleaning of ear canal after a swim when meatal skin is already macerated. Break in continuity of meatal lining sets the ground for organisms to invade.

*Common organisms* responsible for otitis externa are *Staph. aureus*, *Pseud. pyocyaneus*, *B. proteus* and *Esch. coli* but more often the infection is mixed.

Some cases of otitis externa are secondary to infection of the middle ear, or allergic sensitisation to the topical ear drops used for chronic suppurative otitis media.

#### Clinical features

Diffuse otitis externa may be acute or chronic with varying degrees of severity.

*Acute phase* is characterised by hot burning sensation in the ear, followed by pain which is aggravated by movements of jaw. Ear starts oozing thin serous discharge which later becomes thick and purulent. Meatal lining becomes inflamed and swollen. Collection of debris and discharge

accompanied with meatal swelling gives rise to conductive hearing loss. In severe cases, regional lymph nodes become enlarged and tender with cellulitis of the surrounding tissues.

*Chronic phase* is characterised by irritation and strong desire to itch. This is responsible for acute exacerbations and reinfection. Discharge is scanty and may dry up to form crusts. Meatal skin which is thick and swollen may also show scaling and fissuring. Rarely, the skin becomes hypertrophic leading to meatal stenosis (*chronic stenotic otitis externa*).

**Treatment** *Acute phase* is treated as follows:

- **(a) Ear toilet:** It is the most important single factor in the treatment of diffuse otitis externa. All exudate and debris should be meticulously and gently removed. Special attention should be paid to antero-inferior meatal recess which forms a blind pocket where discharge is accumulated. Ear toilet can be done by dry mopping, suction clearance or irrigating the canal with warm, sterile normal saline.
- **(b) Medicated wicks:** After thorough toilet, a gauze wick soaked in antibiotic steroid preparation is inserted in the ear canal and patient advised to keep it moist by instilling the same drops twice or thrice a day. Wick is changed daily for 2-3 days when it can be substituted by ear drops. Local steroid drops help to relieve oedema and erythema, and prevent itching. Aluminium acetate (8%) or silver nitrate (3%) are mild astringents and can be used in the form of a wick to form a protective coagulum to dry-up an oozing meatus.
- **(c) Antibiotics:** Broad spectrum systemic antibiotics are used when there is cellulitis and acute tender lymphadenitis.
- **(d) Analgesics:** For relief of pain.

*Chronic phase.* Treatment aims at (a) reduction of meatal swelling so that ear toilet can be effectively done, and (b) alleviation of itching so that scratching is stopped and further recurrences controlled.

A gauze wick soaked in 10% ichthammol glycerine and inserted into the canal helps to reduce swelling. This is followed by ear toilet with particular attention to antero-inferior meatal recess. Itching can be controlled by topical application of antibiotic steroid cream.

When the meatal skin is thickened to the point of obstruction and resists all forms of medical treatment, i.e. chronic stenotic otitis externa, it is surgically excised, bony meatus is widened with a drill and lined by split-skin graft.

### **3. Otomycosis**

Otomycosis is a fungal infection of the ear canal that often occurs due to *Aspergillus niger*, *A. fumigatus* or *Candida albicans*. It is seen in hot and humid climate of tropical and subtropical countries. Secondary fungal growth is also seen in patients using topical antibiotics for treatment of otitis externa or middle ear suppuration.

The *clinical features* of otomycosis include: intense itching, discomfort or pain in the ear, watery discharge with a musty odour, and ear blockage. The fungal mass may appear white, brown or black and has been likened to a wet piece of filter paper.

Examined with an otoscope, *A. niger* appears as black-headed filamentous growth, *A. fumigatus*, pale blue or green; and *Candida* as white or creamy deposit. Meatal skin appears sodden, red and oedematous.

*Treatment* consists of thorough ear toilet to remove all discharge and epithelial debris which are conducive to the growth of fungus. It can be done by syringing, suction or mopping. Specific antifungal agents can be applied. Nystatin (100,000 units/ml of propylene glycol) is effective against *Candida*. Other broad spectrum antifungal agents include clotrimazole and povidone iodine. 2% salicylic acid in alcohol is also effective. It is a keratolytic agent which removes superficial layers of epidermis, and along with that, the fungal mycelia growing into them. Antifungal treatment should be continued for a week even after apparent cure to avoid recurrences. Ear must be kept dry. Bacterial infections are often associated with otomycosis, and treatment with an antibiotic/steroid preparation helps to reduce inflammation and oedema and thus permitting better penetration of antifungal agents.

### **4. Otitis externa haemorrhagica**

It is characterised by formation of haemorrhagic bullae on the tympanic membrane and deep meatus. It is probably viral in origin and may be seen in influenza epidemics. The condition causes severe pain in the ear and blood-stained discharge when the bullae rupture. Treatment with analgesics is directed to give relief from pain. Antibiotics are given for secondary infection of the ear canal, or middle ear if the bulla has ruptured into the middle ear.

### **5. Herpes zoster oticus**

It is characterised by formation of vesicles on the tympanic membrane, meatal skin, concha and postauricular groove. The seventh and eighth cranial nerves may be involved.

### **6. Malignant (necrotising) otitis externa**

It is an inflammatory condition caused by pseudomonas infection usually in the elderly diabetics, or in those on immunosuppressive drugs. Its early manifestations resemble diffuse otitis externa but there is excruciating pain and appearance of granulations in the meatus. Facial paralysis is common. Infection may spread to the skull base and jugular foramen causing multiple cranial nerve palsies. Anteriorly, infection spreads to temporomandibular fossa, posteriorly to the mastoid and medially into the middle ear and petrous bone. CT scan is useful, to know the extent of disease.



Treatment consists of high doses of i.v. antibiotics directed against pseudomonas (tobramycin, ticarcillin or third generation cephalosporins). Antibiotics are given for 6-8 weeks or longer. Diabetes should be controlled. Surgical debridement of devitalised tissue and bone should be done judiciously. Radical resections have been abandoned in favour of prolonged intensive medical therapy.

### **7. Eczematous otitis externa**

It is the result of hypersensitivity to infective organisms or topical ear drops such as chloromycetin or neomycin, etc. It is marked by intense irritation, vesicle formation, oozing and crusting in the canal. Treatment is withdrawal of topical antibiotic causing sensitivity, and application of steroid cream.

### **8. Seborrhoeic otitis externa**

It is associated with seborrhoeic dermatitis of the scalp. Itching is the main complaint. Greasy yellow scales are seen in the external canal, over the lobule and postauricular sulcus. Treatment consists of ear toilet, application of a cream containing salicylic acid and sulphur, and attention to the scalp for seborrhoea.

### **9. Neurodermatitis**

It is caused by compulsive scratching due to psychological factors. Patient's main complaint is intense itching. Otitis externa of bacterial type may follow infection of raw area left by scratching. Treatment is sympathetic psychotherapy and meant for any secondary infection. Ear pack and bandage to the ear are helpful to prevent compulsive scratching.

### **10. Primary cholesteatoma of external auditory canal**

In contrast to middle ear cholesteatoma, squamous epithelium of the external canal invades its bone. Usually there is some abnormality of bone of external canal which is conducive for epithelium to invade it. It may be post-traumatic or postsurgical. Clinical features include purulent otorrhoea and pain; tympanic membrane being normal. Granulations associated with sequestered bone need histological examination to differentiate it from carcinoma, necrotizing otitis externa and a benign sequestrum.

Treatment consists of removal of necrotic bone and cholesteatoma, and lining the defect with fascia.

D. Tumours

See page 118.

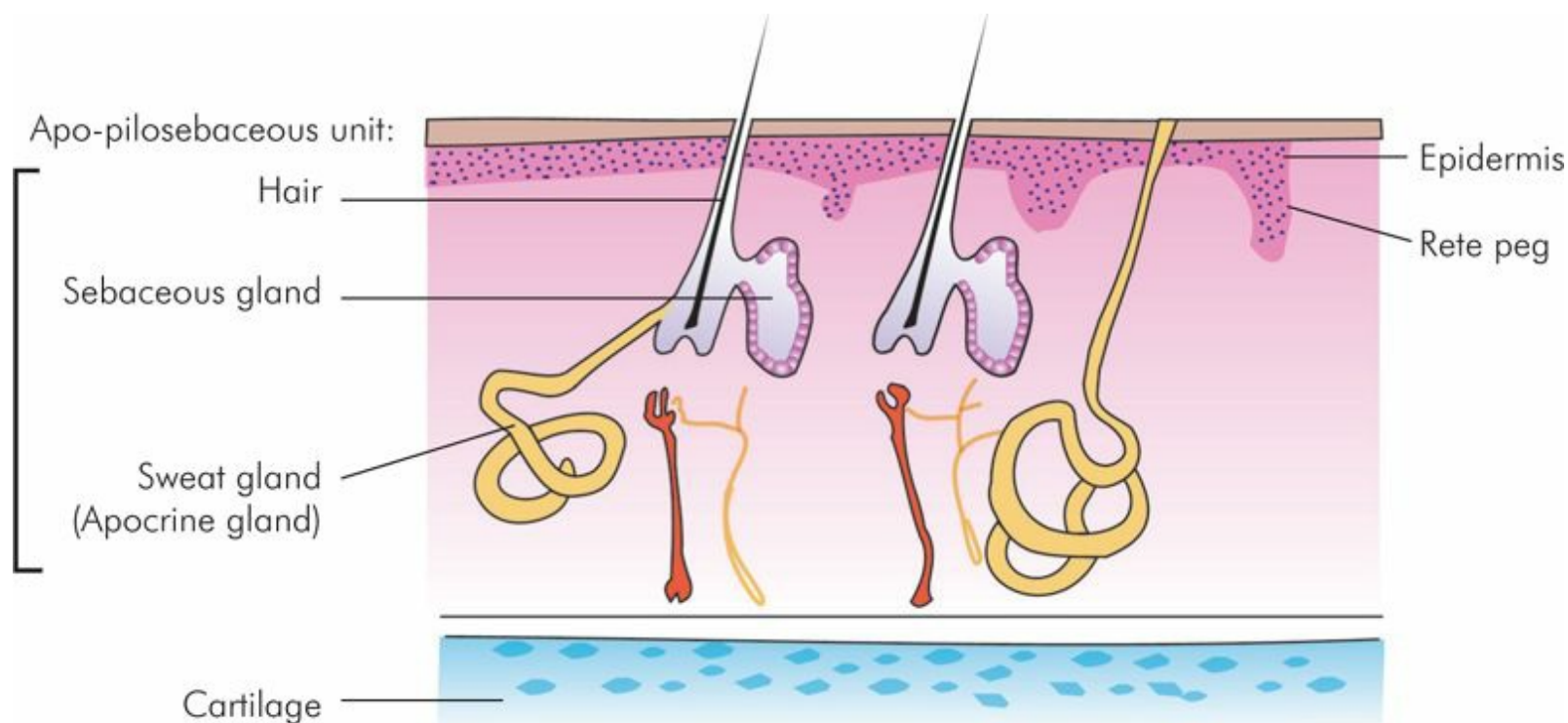
## E. Miscellaneous Conditions

### 1. Impacted wax or cerumen

Wax is composed of secretion of sebaceous glands, ceruminous glands, hair, desquamated epithelial debris, keratin and dirt.

Sebaceous and ceruminous (modified sweat glands) open into the space of the hair follicle (Fig. 8.9). Sebaceous glands provide fluid rich in fatty acids while secretion of ceruminous gland is rich in lipids and pigment granules. Secretion of both these glands mixes with the desquamated epithelial cells and keratin shed from the tympanic membrane and deep bony meatus to form wax.

Wax has a protective function as it lubricates the ear canal and entraps any foreign material that happens to enter the canal. Normally, only a small amount of wax is secreted, which dries up and is later expelled from the meatus by movements of the jaw. As some people sweat more than others, the activity of ceruminous glands also varies; excessive wax may be secreted and deposited as a plug in the meatus. Certain other factors like narrow and tortuous ear canal, stiff hair or obstructive lesion of the canal, e.g. exostosis, may favour retention of wax. It may dry up and form a hard impacted mass.



Dhingra: Diseases of Ear Nose and Throat, 5th Edition  
Copyright © 2010 Elsevier. All rights reserved.

Figure 8.9 Structure of skin of cartilaginous meatus.

page 59

page 60

Patient usually presents with impairment of hearing or sense of blocked ear. Tinnitus and giddiness may result from impaction of wax against the tympanic membrane. Reflex cough due to stimulation of auricular branch of vagus may sometimes occur. The onset of these symptoms may be sudden when water enters the ear canal during bathing or swimming and the wax swells up. Long standing impacted wax may ulcerate the meatal skin and result in granuloma formation (*wax granuloma*).

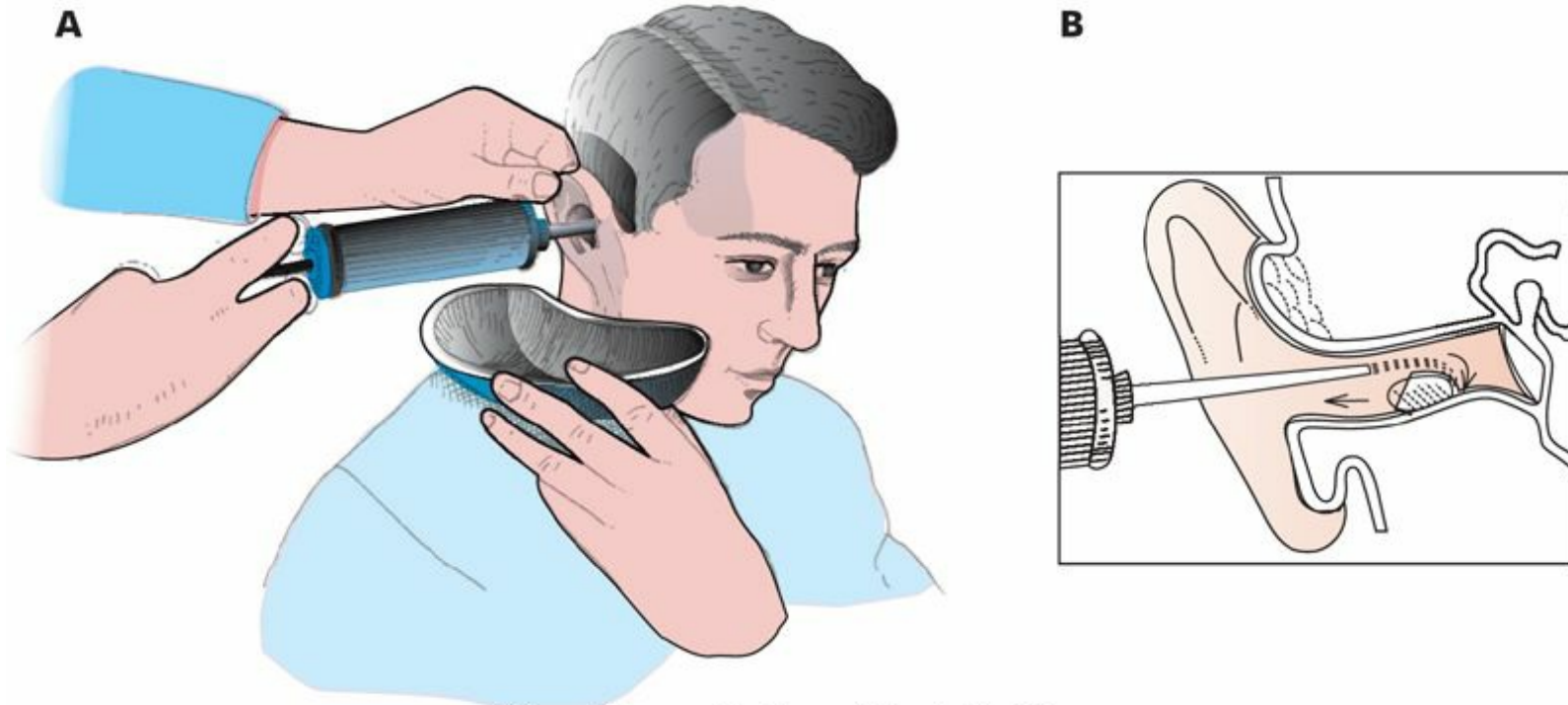
Treatment of wax consists in its removal by syringing or instrumental manipulation. Hard impacted mass may sometimes require prior softening with wax solvents.

**Technique of syringing the ear.** Patient is seated with ear to be syringed towards the examiner. A towel is placed round his neck. A kidney tray is placed over the shoulder and held snugly by the patient. Patient's head is slightly tilted over the tray to collect the return fluid.

Pinna is pulled upwards and backwards and a stream of water from the ear syringe is directed along the posterosuperior wall of the meatus. Pressure of water, built up deeper to the wax, expels the wax out (Fig. 8.10). If wax is tightly impacted, it is necessary to create a space between it and the meatal wall for the jet of water to pass, otherwise syringing will be ineffective or may even push the wax deeper. Ear canal should be inspected from time to time to see if all wax has been removed. Unnecessary syringing should be avoided.

At the end of the procedure, ear canal and tympanic membrane must be inspected and dried with a pledget of cotton. Any ulceration seen in meatal wall as a result of impacted wax is protected by application of suitable antibiotic ointment. Normally, boiled tap water cooled to body temperature is used. If it is too cold or too hot it would stimulate the labyrinth, as in caloric testing, and cause vertigo. Too much force used in syringing may rupture the tympanic membrane especially when it has already been weakened by previous disease. Patient complains of intense

pain and may become giddy and even faint. It is necessary before syringing to ask the patient for any past history of ear discharge or an existing perforation. A quiescent otitis media may be reactivated by syringing.



Dhingra: Diseases of Ear Nose and Throat, 5th Edition  
Copyright © 2010 Elsevier. All rights reserved.

Figure 8.10 (A) Syringing of ear. (B) Illustration to show how jet of water expels the wax or a foreign body.

**Instrumental manipulation.** It should always be done by skilled hands and under direct vision. Cerumen hook, scoop or Jobson-Horne probe are often used. First, a space is created between the wax and meatal wall, the instrument is passed beyond the wax, and whole plug then dragged out in a single piece. If it breaks, syringing may be used to remove the fragments.

Occasionally, if the wax is too hard and impacted, to be removed by syringing or instruments, it should be softened by drops of 5% soda bicarb in equal parts of glycerine and water instilled two or three times a day for a few days. Hydrogen peroxide, liquid paraffin or olive oil may also achieve the same result. Commercial drops containing cerumolytic agents like paradichlorobenzene 2% can also be used and above methods tried again.

## 2. Foreign bodies of ear

(a) **Non-living.** Children may insert a variety of foreign bodies in the ear; the common ones often seen are: a piece of paper or sponge, grain seeds (rice, wheat, maize), slate pencil, piece of chalk or metallic ball bearings. An adult may present with a broken end of match stick used for scratching the ear or an overlooked cotton swab. Vegetable foreign bodies tend to swell up with time and get tightly impacted in the ear canal or may even suppurate.

Methods of removing a foreign body include:

- (i) Forceps removal
- (ii) Syringing
- (iii) Suction
- (iv) Microscopic removal with special instruments
- (v) Postaural approach.

Soft and irregular foreign bodies like a piece of paper, swab or a piece of sponge can be removed with fine crocodile forceps.

page 60

page 61

Most of the seed grains and smooth objects can be removed with syringing. Smooth and hard objects like steel ball bearing should not be grasped with forceps as they tend to move inwards and may injure the tympanic membrane. *In all impacted foreign bodies or in those where earlier attempts at extraction have been made, it is preferable to use general anaesthetic and an operating microscope.* Occasionally, postaural approach is used to remove foreign bodies impacted in deep meatus, medial to the isthmus or those which have been pushed into the middle ear.

Unskilled attempts at removal of foreign bodies may lacerate the meatal lining, damage the tympanic membrane or the ear ossicles.

(b) *Living*. Flying or crawling insects like mosquitoes, beetles, cockroach or an ant may enter the ear canal and cause intense irritation and pain. No attempt should be made to catch them alive. First, the insect should be killed by instilling oil (a household remedy), spirit or chloroform water. Once killed, the insect can be removed by any of the methods described above.

*Maggots in the ear*. Flies may be attracted to the foul-smelling ear discharge and lay eggs which hatch out into larvae called maggots. They are commonly seen in the month of August, September, and October. There is severe pain with swelling round the ear and blood-stained watery discharge. Maggots may be seen filling the ear canal.

Treatment consists of instilling chloroform water to kill the maggots which can later be removed by forceps. Usually, such patients have discharging ears with perforation of the tympanic membrane, and syringing may not be advisable.

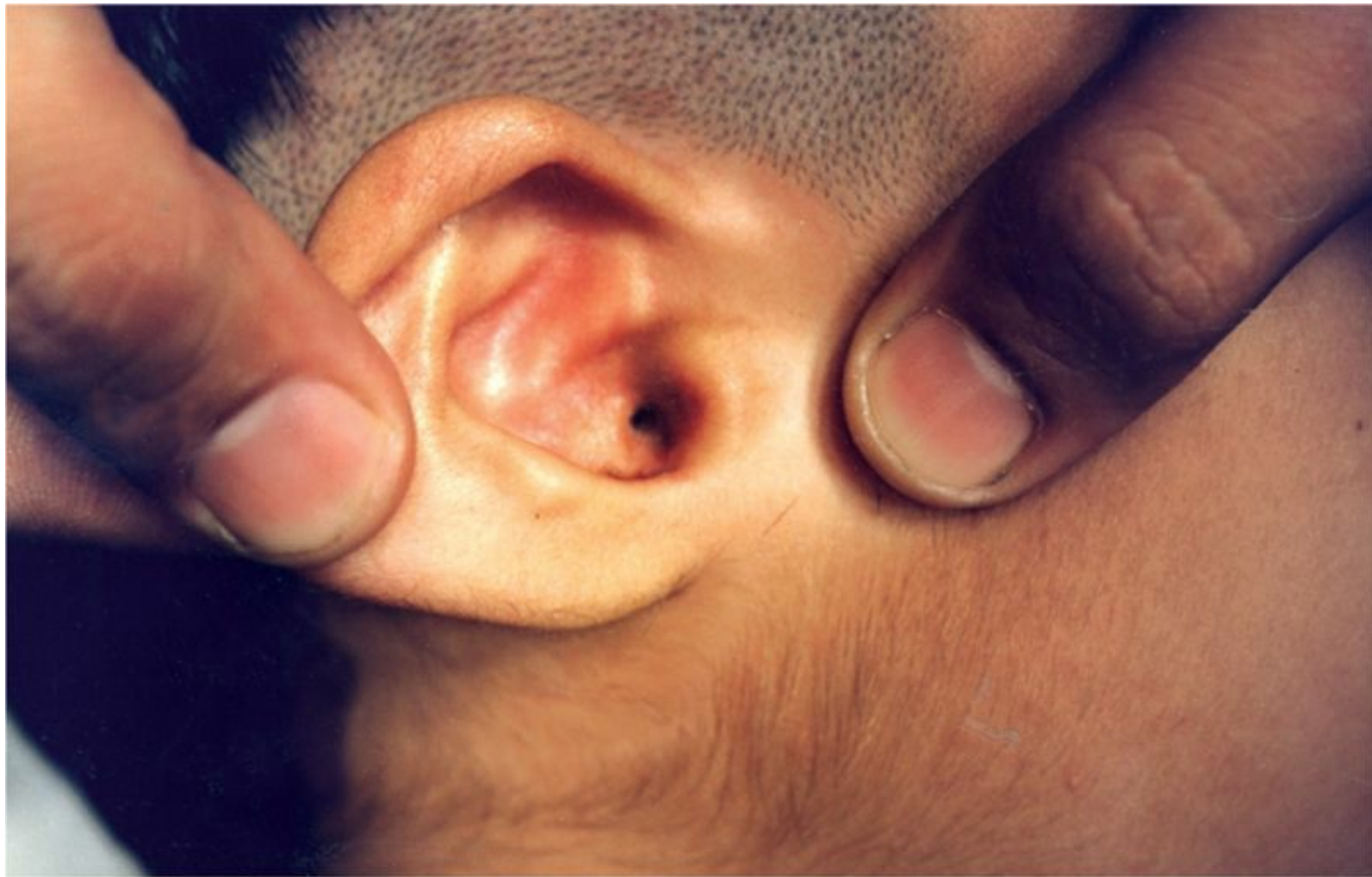### 3. *Keratosis obturans*

Collection of a pearly white mass of desquamated epithelial cells in the deep meatus is called keratosis obturans. This, by its pressure effect, causes absorption of bone leading to widening of the meatus so much so that facial nerve may be exposed and paralysed.

*Aetiology*. It is commonly seen between 5 and 20 years and may affect one or both ears. It may sometimes be associated with bronchiectasis and chronic sinusitis. Normally, epithelium from surface of tympanic membrane migrates onto the posterior meatal wall. Failure of this migration or obstruction to migration caused by wax may lead to accumulation of the epithelial plug in the deep meatus.

*Clinical features*. Presenting symptoms may be pain in the ear, hearing loss, tinnitus and sometimes ear discharge.

On examination, ear canal may be full of pearly white mass of keratin material disposed in several layers. Removal of this mass may show widening of bony meatus with ulceration and even granuloma formation.



Dhingra: Diseases of Ear Nose and Throat, 5th Edition  
Copyright © 2010 Elsevier. All rights reserved.

Figure 8.11 Meatal stenosis following chronic otitis externa.

*Treatment*. Keratotic mass is removed either by syringing or instrumentation, similar to the techniques employed for impacted wax. Secondary otitis externa may be present and should be treated. Patient should be periodically checked and any reaccumulations removed. Recurrence can be checked to some extent by the use of keratolytic agent such as 2% salicylic acid in alcohol.

### 4. *Acquired atresia and stenosis of meatus*

It can result from:

- **(a)** Infections, e.g. chronic otitis externa-an important cause (Fig. 8.11).
- **(b)** Trauma, e.g. lacerations, fracture of tympanic plate, surgery on ear canal or mastoid.
- **(c)** Burns-thermal or chemical.

Treatment is meatoplasty. Using a postaural incision, scar tissue and thickened meatal skin are excised, bony meatus is enlarged and the raw meatal bone is covered with pedicled flaps from meatus or split skin grafts.

### III. DISEASES OF TYMPANIC MEMBRANE

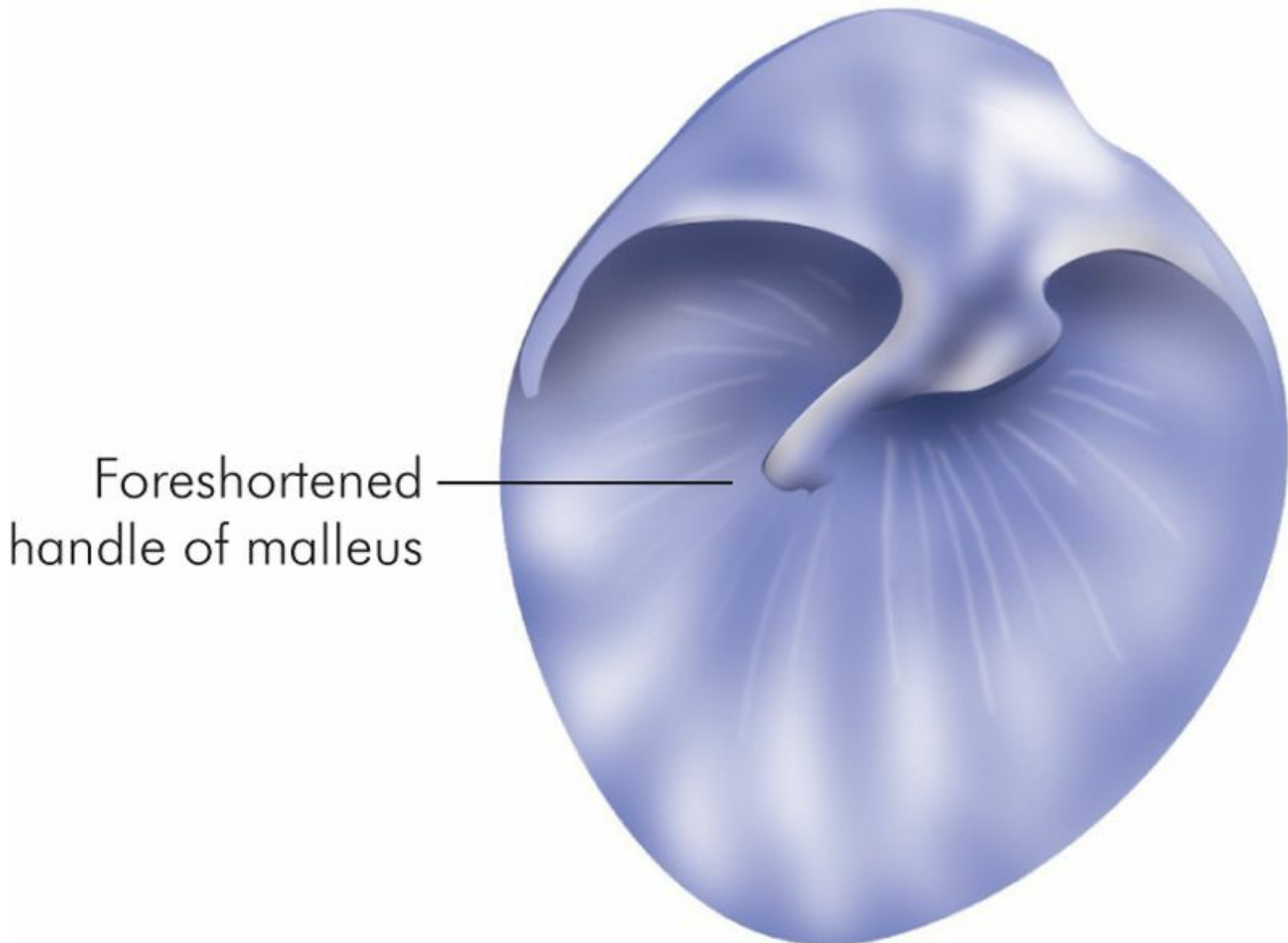
Diseases of tympanic membrane may be primary or secondary to conditions affecting external ear, middle ear or eustachian tube.

*Normal tympanic membrane.* It is shiny and pearly-grey in colour with a concavity on its lateral surface, more marked at the tip of malleus, the umbo. A bright cone of light can be seen in the antero-inferior quadrant. Attic area lies above the lateral process of malleus and is slightly pinkish. Transparency varies. Some middle ear structures can be seen through a transparent membrane. A normal tympanic membrane is mobile when tested with pneumatic otoscope or Siegle's speculum.

#### 1. Retracted tympanic membrane

page 61

page 62



Dhingra: Diseases of Ear Nose and Throat, 5th Edition  
Copyright © 2010 Elsevier. All rights reserved.

Figure 8.12 Retracted tympanic membrane.

It appears dull and lustreless. Cone of light is absent or interrupted. Handle of malleus appears foreshortened. Lateral process of malleus becomes more prominent. Anterior and posterior malleal folds become sickle-shaped (Fig. 8.12). A retracted tympanic membrane is the result of negative intratympanic pressure when the eustachian tube is blocked.

#### 2. Myringitis bullosa

It is a painful condition characterised by formation of haemorrhagic blebs on the tympanic membrane and deep meatus. It is probably caused by a virus or mycoplasma pneumoniae.

#### 3. Herpes zoster oticus

It is a viral infection involving geniculate ganglion of facial nerve. It is characterised by appearance of vesicles on the tympanic membrane, deep meatus, concha and retroauricular sulcus. It may involve seventh (more often) and the eighth cranial nerves.

#### **4. Myringitis granulosa**

Non-specific granulations form on the outer surface of tympanic membrane. It may be associated with impacted wax, long-standing foreign body or external ear infection.

#### **5. Traumatic rupture**

Tympanic membrane may be ruptured by:

- **(a)** Trauma due to a hair pin, match stick or unskilled attempts to remove a foreign body.
- **(b)** Sudden change in air pressure, e.g. a slap or a kiss on the ear or a sudden blast. Forceful Valsalva may rupture a thin atrophic membrane.
- **(c)** Pressure by a fluid column, e.g. diving, water sports or forceful syringing.
- **(d)** Fracture of temporal bone.

*Treatment.* In a majority of cases, edges of perforation get inverted towards the middle ear. In such cases, the ear should be examined under operating microscope and the edges of perforation repositioned and splinted (see page 417).

Injuries of tympanic membrane may be associated with facial paralysis or subluxation of stapes (vertigo and nystagmus) and sensorineural hearing loss. In such cases, urgent exploration may be required.

#### **6. Atrophic tympanic membrane**

A normal tympanic membrane consists of outer epithelial, middle fibrous and inner mucosal layer. In serous otitis media, the middle fibrous layer gets absorbed leaving a thin drumhead which easily gets collapsed with eustachian tube insufficiency. A perforation of tympanic membrane also heals only by epithelial and mucosal layers without the intervening fibrous layer.

#### **7. Retraction pockets and atelectasis**

When the tympanic membrane is thin and atrophic, a segment of it or the entire membrane may collapse inwards due to eustachian tube insufficiency. It may form a retraction pocket or get plastered onto promontory and also wrap round the ossicles. A deep retraction pocket may accumulate keratin debris and form a cholesteatoma.

#### **8. Tympanosclerosis**

It is hyalinisation and later calcification in the fibrous layer of tympanic membrane. It appears as chalky white plaque. Mostly, it remains asymptomatic. It is frequently seen in cases of serous otitis media as a complication of ventilation tube. Tympanosclerosis mostly affects tympanic membrane but may be seen involving ligaments, joints of ossicles, muscle tendons and submucosal layer of middle ear cleft, and interferes in the conduction of sound.

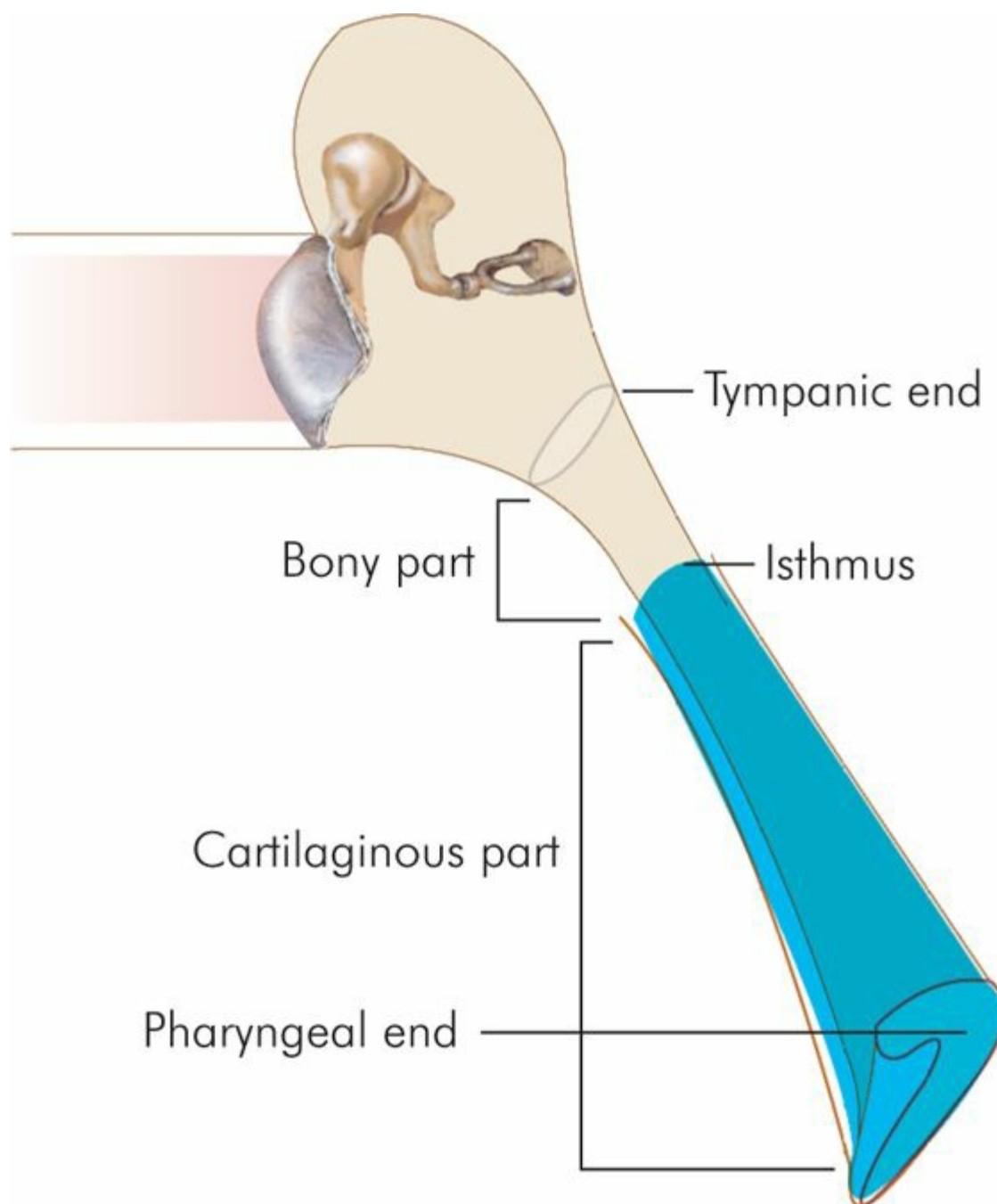
#### **9. Perforations**

They may be central, attic or marginal and are associated with chronic otitis media. (see page 89).



## Anatomy

Eustachian tube, also called the *auditory* or the *pharyngotympanic tube*, connects nasopharynx with the tympanic cavity. In an adult, it is about 36 mm long and runs downwards, forwards and medially from its tympanic end, forming an angle of  $45^\circ$  with the horizontal. It is divided into two parts: The *bony*, which is posterolateral, forms one third (12 mm) of the total length and *fibrocartilaginous*, which is anteromedial, forms two-thirds (24 mm). The two parts meet at isthmus which is the narrowest part of the tube (Fig. 9.1). The fibrocartilaginous part of the tube is made of a single piece of cartilage folded upon itself in such a way that it forms the whole of medial lamina, roof and a part of the lateral lamina; the rest of its lateral lamina is made of fibrous membrane.



Dhingra: Diseases of Ear Nose and Throat, 5th Edition  
Copyright © 2010 Elsevier. All rights reserved.

Figure 9.1 Horizontal section through the eustachian tube showing bony and cartilaginous parts, isthmus, tympanic and pharyngeal ends.

The *tympanic end* of the tube is bony, measures  $5 \times 2$  mm and is situated in the anterior wall of middle ear, a little above the level of floor. The *pharyngeal end* of the tube is slit-like, vertically. The cartilage at this end raises an elevation called torus tubarius which is situated in the lateral wall of the nasopharynx, 1-1.25 cm behind the posterior end of inferior turbinate.

# Structure

## Muscles Related to Eustachian Tube (Fig. 9.2)

Three muscles are related to the tube: Tensor veli palatini, Levator veli palatini and the Salpingopharyngeus. The medial fibres of the tensor veli palatini are attached to the lateral lamina of the tube, and when they contract help to open the tubal lumen. These fibres have also been called the *dilator tubae* muscle. The exact role of the levator veli palatini and the Salpingopharyngeus muscles to open the tube is uncertain. It is believed that levator veli palatini muscle which runs inferior and parallel to the cartilaginous part of the tube forms a bulk under the medial lamina, and during contraction pushes it upward and medially thus assisting in opening the tube.

*The elastin hinge.* The cartilage, at the junction of medial, and lateral lamina at the roof, is rich in elastin fibres which form a hinge. By its recoil it helps to keep the tube closed when no longer acted upon by dilator tubae muscle.

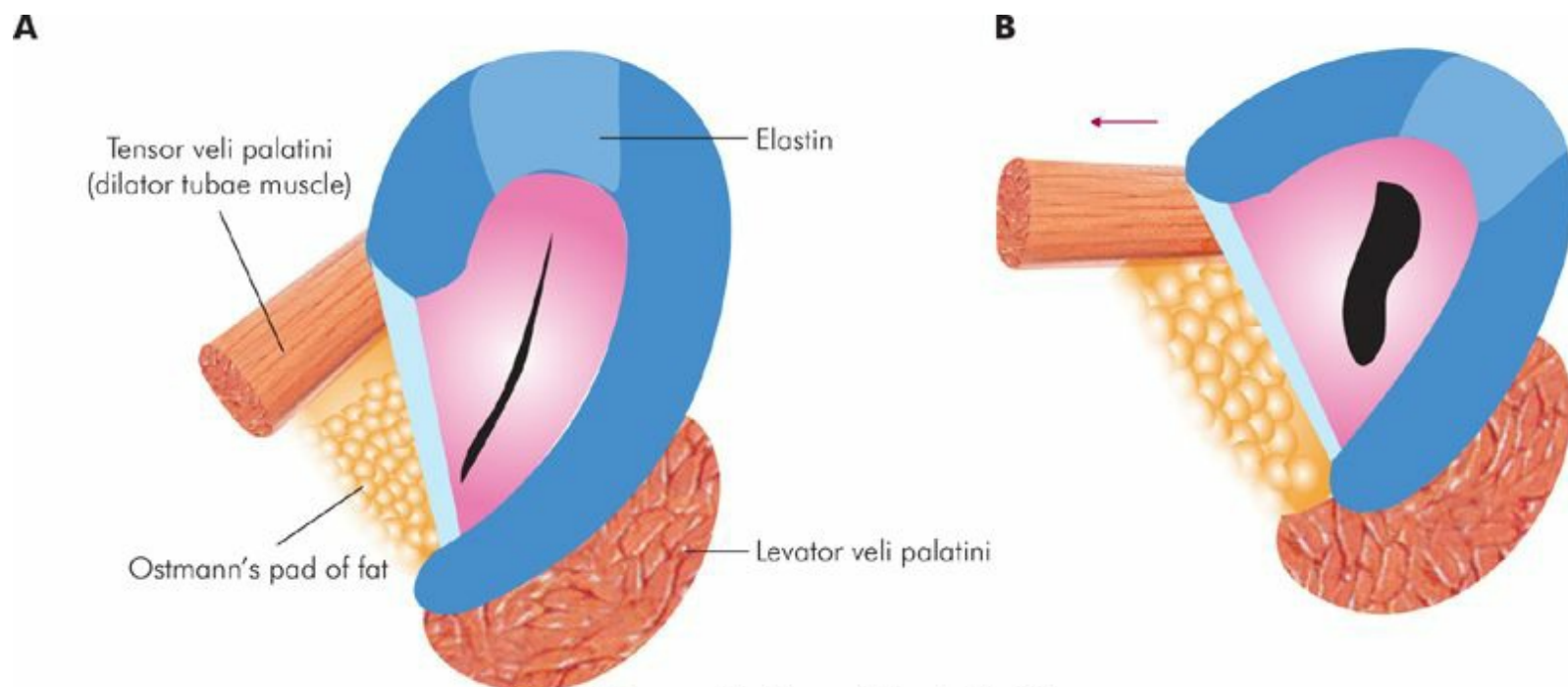
*Ostmann's pad of fat.* It is a mass of fatty tissues related laterally to the membranous part of the cartilaginous tube. It also helps to keep the tube closed and thus protect it from the reflux of nasopharyngeal secretions.

## Lining of the Eustachian Tube

Histologically, the mucosa shows pseudostratified ciliated columnar epithelium interspersed with mucous secreting goblet cells. Submucosa, particularly in the cartilaginous part of the tube, is rich in seromucinous glands. The cilia beat in the direction of nasopharynx and thus helps to drain secretions and fluid from the middle ear into the nasopharynx.

page 63

page 64



Dhingra: Diseases of Ear Nose and Throat, 5th Edition  
Copyright © 2010 Elsevier. All rights reserved.

Figure 9.2 Vertical section through eustachian tube. Note: Cartilage of the tube forms medial wall, roof and part of lateral wall. Elastin is situated in the roof at the junction of medial and lateral laminae and helps the medial laminae to regain its original position of closure. (A) Eustachian tube is closed in resting position. (B) Tube is open when tensor veli palatini (dilator tubae) muscle contracts.

## Nerve Supply

Tympanic branch of CN IX supplies sensory as well as parasympathetic secretomotor fibres to the tubal mucosa. Tensor veli palatini is supplied by mandibular branch of trigeminal ( $V_3$ ) nerve. Levator veli palatini and salpingopharyngeus receive motor nerve supply through pharyngeal plexus (Cranial part of CN XI through vagus).

## Differences Between the Infant and Adult Eustachian Tube

The eustachian tube of infants is wider, shorter and more horizontal; thus infections from the nasopharynx can easily reach the middle ear. Even the milk may regurgitate into the middle ear if the infants are not fed in head-up position (see Table 9.1).

# Functions

Physiologically, eustachian tube performs three main functions:

- 1. Ventilation and thus regulation of middle ear pressure.
- 2. Protection against (a) Nasopharyngeal sound pressure and (b) Reflux of nasopharyngeal secretions.
- 3. Middle ear clearance of secretions.

## 1. Ventilation and regulation of middle ear pressure

For normal hearing, it is essential that pressure on two sides of the tympanic membrane should be equal. Negative or positive pressure in the middle ear affects hearing. Thus, eustachian tube should open periodically to equilibrate the air pressure in the middle ear with the ambient pressure. Normally, the eustachian tube remains closed and opens intermittently during swallowing, yawning and sneezing. Posture also affects the function; tubal opening is less efficient in recumbent position and during sleep due to venous engorgement. Tubal function is also poor in infants and young children and thus responsible for more ear problems in that age group. It usually normalizes by the age of 7-10 years.

## 2. Protective functions

Abnormally, high sound pressures from the nasopharynx can be transmitted to the middle ear if the tube is open thus interfering with normal hearing. Normally, the eustachian tube remains closed and protects the middle ear against these sounds.

A normal eustachian tube also protects the middle ear from reflux of nasopharyngeal secretions into the middle ear. This reflux occurs more readily if the tube is wide in diameter (patulous tube), short in length, (as in babies), or the tympanic membrane is perforated (cause for persistence of middle ear infections in cases of tympanic membrane perforations).

High pressures in the nasopharynx can also force nasopharyngeal secretions into the middle ear, e.g. forceful nose blowing, closed-nose swallowing as in the presence of adenoids or bilateral nasal obstruction.

## 3. Clearance of middle ear secretions

Mucous membrane of the eustachian tube and anterior part of the middle ear is lined by ciliated columnar cells. The cilia beat in the direction of nasopharynx. This helps to clear the secretions and debris in the middle ear towards the nasopharynx. The clearance function is further augmented by active opening and closing of the tube.

page 64

page 65

**Table 9-1. Differences between infant and adult eustachian tube**

	<b>Infant</b>	<b>Adult</b>
Length	13-18 mm at birth (about half as long as in adult)	36 mm (31-38 mm)
Direction	More horizontal. At birth it forms an angle of 10° with the horizontal At age 7 and later it is 45°	Forms an angle of 45° with the horizontal
Angulation at isthmus	No angulation	Angulation present
Bony versus cartilaginous part	Bony part is slightly longer than 1/3 of the total length of the tube and is relatively wider	Bony part 1/3; cartilaginous part 2/3
Tubal cartilage	Flaccid. Retrograde reflux of nasopharyngeal secretions can occur	Comparatively rigid. Remains closed and protects the middle ear from the reflux
Density of elastin at the hinge	Less dense; tube does not efficiently close by recoil	Density of elastin more and helps to keep the tube closed by recoil of cartilage
Ostmann's pad of fat	Less in volume	Large and helps to keep the tube closed

# Eustachian Tube Function Tests

## 1. Valsalva test

The principle of this test, as also of politzerisation, is to build positive pressure in the nasopharynx so that air enters the eustachian tube. To do this test, patient pinches his nose between the thumb and index finger, takes a deep breath, closes his mouth and tries to blow air into the ears. If air enters the middle ear, the tympanic membrane will move outwards which can be verified by otoscope or the microscope. In the presence of a tympanic membrane perforation, a hissing sound is produced or if discharge is also present in the middle ear, cracking sound will be heard. Failure of this test does not prove blockage of the tube because only about 65% of persons can successfully perform this test. This test should be avoided (i) in the presence of atrophic scar of tympanic membrane which can rupture, and (ii) in the presence of infection of nose and nasopharynx where infected secretions are likely to be pushed into the middle ear causing otitis media.

## 2. Politzer test

This test is done in children who are unable to perform Valsalva test. In this test, olive-shaped tip of the Politzer's bag is introduced into the patient's nostril on the side of which the tubal function is desired to be tested. Other nostril is closed, and the bag compressed while at the same time the patient swallows (he can be given sips of water) or says "ik, ik, ik". By means of an auscultation tube, connecting the patient's ear under test to that of the examiner, a hissing sound is heard if tube is patent. Compressed air can also be used instead of Politzer's bag. The test is also used therapeutically to ventilate the middle ear.

## 3. Catheterisation

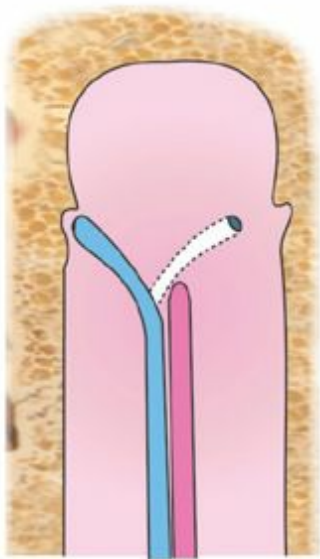
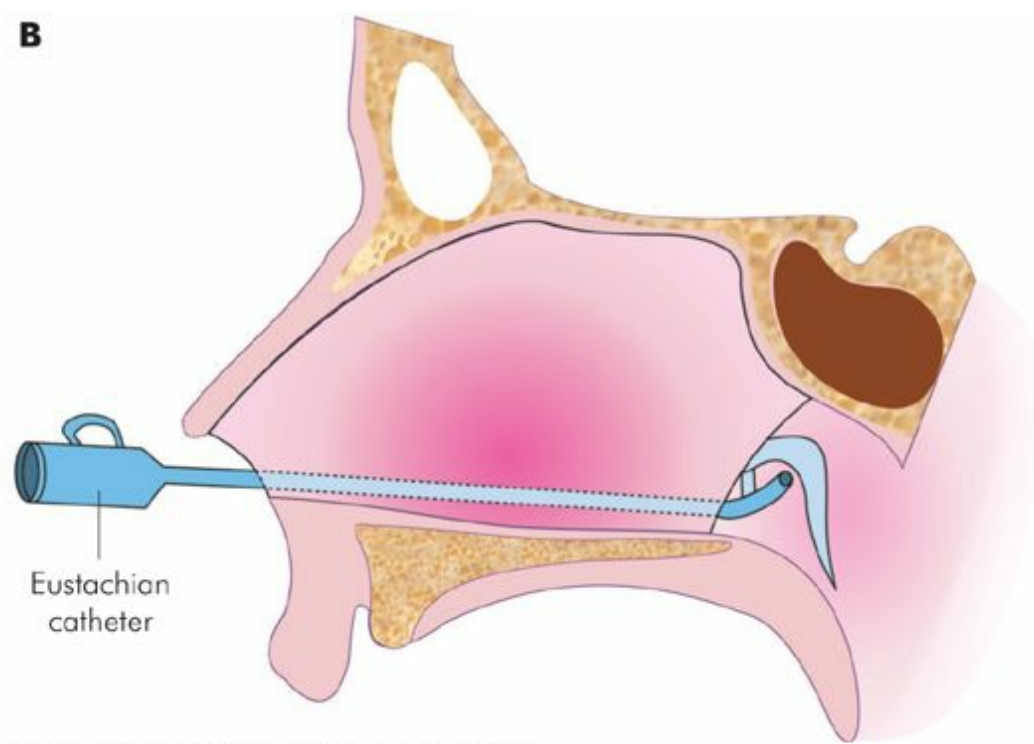
In this test, nose is first anaesthetised by topical spray of lignocaine and then a eustachian tube catheter, the tip of which is bent, is passed along the floor of nose till it reaches the nasopharynx. Here it is rotated 90° medially and gradually pulled back till it engages on the posterior border of nasal septum (Fig. 9.3A). It is then rotated 180° laterally so that the tip lies against the tubal opening (Fig. 9.3B). A Politzer's bag is now connected to the catheter and air insufflated. Entry of air into the middle ear is verified by an auscultation tube. The procedure of catheterization should be gentle as it is known to cause complications such as:

- (a) Injury to eustachian tube opening which causes scarring later.
- (b) Bleeding from the nose.
- (c) Transmission of nasal and nasopharyngeal infection into the middle ear causing otitis media.
- (d) Rupture of atrophic area of tympanic membrane if too much pressure is used.

## 4. Toynbee's test

While the above three tests use a positive pressure, Toynbee's manoeuvre causes negative pressure. It is a more physiological test. It is performed by asking the patient to swallow while nose has been pinched. This draws air from the middle ear into the nasopharynx and causes inward movement of tympanic membrane which is verified by the examiner otoscopically or with a microscope.

## 5. Tympanometry

**A****B**

Dhingra: Diseases of Ear Nose and Throat, 5th Edition  
Copyright © 2010 Elsevier. All rights reserved.

Figure 9.3 Catheterisation of eustachian tube (see text).

(Also called inflation-deflation test) In this test, positive and negative pressures are created in the external ear canal and the patient swallows repeatedly. The ability of the tube to equilibrate positive and negative pressures to the ambient pressure indicates normal tubal function. The test can be done both in patients with perforated or intact tympanic membranes (see page 29).

#### **6. Radiological test**

A radio-opaque dye, e.g. hypaque or lipoidal instilled into the middle ear through a pre-existing perforation, and X-rays taken should delineate the tube and any obstruction. The time taken by the dye to reach the nasopharynx also indicates its clearance function. This test is no longer popular now.

#### **7. Saccharine or methylene blue test**

Saccharine solution is placed into the middle ear through a pre-existing perforation. The time taken by it to reach the pharynx and impart a sweet taste is also a measure of clearance function.

Similarly, methylene blue dye can be instilled into the middle ear and the time taken by it to stain the pharyngeal secretions can be noted.

Indirect evidence of drainage/clearance function is established when ear drops instilled into the ear with tympanic membrane perforation cause bad taste in throat.

#### **8. Sonotubometry**

A tone is presented to the nose and its recording taken from the external canal. The tone is heard louder when the tube is patent (compare patulous eustachian tube). It also tells the duration for which the tube remains open. It is a non-invasive technique and provides information on active tubal opening. Accessory sounds produced in the nasopharynx, during swallowing, may interfere with the test results. The test is under development.

# Disorders of Eustachian Tube (ET)

## Tubal blockage

Normally, ET is closed. It opens intermittently during swallowing, yawning and sneezing through the active contraction of Tensor veli palatini muscle. Air, composed of oxygen, carbon dioxide, nitrogen and water vapour, normally fills the middle ear and mastoid. When tube is blocked, first oxygen is absorbed, but later other gases, CO<sub>2</sub> and nitrogen also diffuse out into the blood. This results in negative pressure in the middle ear and retraction of tympanic membrane. If negative pressure is still further increased, it causes "locking" of the tube with collection of transudate and later exudate and even haemorrhage. Effects of acute and long-term tubal blockage are shown in Table 9.2.

Eustachian tube obstruction can be mechanical, functional or both. *Mechanical obstruction* can result from (a) intrinsic causes such as inflammation or allergy or (b) extrinsic causes such as tumour in the nasopharynx or adenoids. *Functional obstruction* is caused by collapse of the tube due to increased cartilage compliance which resists opening of the tube or failure of active tubal-opening mechanism due to poor function of tensor veli palatini. The common clinical conditions which can cause tubal obstruction are listed in Table 9.3.

Symptoms of tubal occlusion include otalgia, which may be mild to severe, hearing loss, popping sensation, tinnitus and disturbances of equilibrium or even vertigo.

Signs of tubal occlusion will vary and depend upon the acuteness of the condition and severity. They include, retracted tympanic membrane, congestion along the handle of malleus and the pars tensa, transudate behind the tympanic membrane, imparting it an amber colour and sometimes a fluid level with conductive hearing loss. In severe cases, as in barotrauma, tympanic membrane is markedly retracted with haemorrhages in subepithelial layer, haemotympanum or sometimes a perforation.

**Table 9-2. Effects of acute and prolonged tubal blockage**

Acute tubal blockage
↓
Absorption of ME gases
↓
Negative pressure in ME
↓
Retraction of TM
↓
Transudate in ME/haemorrhage (acute OME)
Prolonged tubal blockage/dysfunction
↓
OME (thin watery or mucoid discharge)
↓
Atelectatic ear/perforation
↓
Retraction pocket/cholesteatoma
↓
Erosion of incudostapedial joint

ME-middle ear, TM-tympanic membrane, OME-otitis media with effusion

**Table 9-3. Causes of eustachian tube obstruction**

- Upper respiratory infection (viral or bacterial)
- Allergy
- Sinusitis
- Nasal polypi
- DNS
- Hypertrophic adenoids
- Nasopharyngeal tumour/mass
- Cleft palate
- Submucous cleft palate
- Down's syndrome
- Functional

### ***Adenoids and eustachian tube function***

Adenoids cause tubal dysfunction by:

- i. Mechanical obstruction of the tubal opening.
- ii. Acting as reservoir for pathogenic organisms.
- iii. In cases of allergy, mast cells of the adenoid tissue release inflammatory mediators which cause tubal blockage.

Thus, adenoids can cause otitis media with effusion or recurrent acute otitis media. Adenoidectomy can help both these conditions.

### ***Cleft palate and tubal function***

Tubal function is disturbed in cleft palate patients due to:

- (i) Abnormalities of torus tubarius, which shows high elastin density making tube difficult to open.
- (ii) Tensor veli palatini muscle does not insert into the torus tubarius in 40% cases of cleft palate and where it does insert, its function is poor.

Otitis media with effusion is common in these patients. Even after repair of the cleft palate deformity, many of them require insertion of grommets to ventilate the middle ear.

### ***Down's syndrome and tubal function***

Function of eustachian tube is defective possibly due to poor tone of tensor veli palatini muscle and abnormal shape of nasopharynx. Children with this syndrome are prone to frequent otitis media or otitis media with effusion.

### ***Barotrauma***

See page 74.

## Retraction Pockets and Eustachian Tube

In ventilation of the middle ear cleft, air passes from eustachian tube to mesotympanum, from there to attic, aditus, antrum and mastoid air cell system. Mesotympanum communicates with the attic via anterior and posterior isthmi, situated in membranous diaphragm between the mesotympanum and the attic. *Anterior isthmus* is situated between tendon of tensor tympani and the stapes. *Posterior isthmus* is situated between tendon of stapedius muscle and pyramid, and the short process of incus. In some cases, middle ear can also communicate directly with the mastoid air cells through the retrofacial cells. Any obstruction in the pathways of ventilation can cause retraction pockets or atelectasis of tympanic membrane, e.g.

- **(i)** Obstruction of eustachian tube → Total atelectasis of tympanic membrane.
- **(ii)** Obstruction in middle ear → Retraction pocket in posterior part of middle ear while anterior part is ventilated.
- **(iii)** Obstruction of isthmi → Attic retraction pocket.
- **(iv)** Obstruction at aditus → Cholesterol granuloma and collection of mucoid discharge in mastoid air cells, while middle ear and attic appear normal.

Depending on the location of pathologic process, other changes such as thin atrophic tympanic membrane, partial or total, (due to absorption of middle fibrous layer), cholesteatoma, ossicular necrosis, and tympanosclerotic changes may also be found.

Principles of management of retraction pockets and atelectasis of middle ear would entail correction/repair of the irreversible pathologic processes and establishment of the ventilation.



## Patulous Eustachian Tube

In this condition, the eustachian tube is abnormally patent. Most of the time it is idiopathic but rapid weight loss, pregnancy especially third trimester, or multiple sclerosis can also cause it.

page 67

page 68

Patient's chief complaints are hearing his own voice (autophony), even his own breath sounds, which is very disturbing. Due to abnormal potency, pressure changes in the nasopharynx are easily transmitted to the middle ear so much so that the movements of tympanic can be seen with inspiration and expiration; these movements are further exaggerated if patient breathes after closing the opposite nostril.

Acute condition of patulous tube is self-limiting and does not require treatment. In others, weight gain, oral administration of potassium iodide is helpful but some long-standing cases may require cauterisation of the tubes or insertion of a grommet.

## Examination of Eustachian Tube

*Pharyngeal end* of the eustachian tube can be examined by posterior rhinoscopy, rigid nasal endoscope or flexible nasopharyngoscope. The extrinsic causes which obstruct this end can be excluded.

*Tympanic end* of the tube can be examined by microscope or endoscope, if there is a preexisting perforation. Eustachian tube endoscopy or middle ear endoscopy can be done with very fine flexible endoscopes. Simple examination of tympanic membrane with otoscope or microscope may reveal retraction pockets or fluid in the middle ear. Similarly, movements of tympanic membrane with respiration point to patulous eustachian tube.

Further assessment of function of the tube can be made by Valsalva, politzerisation, Toynbee and other tests already described.

*Aetiologic causes* of eustachian tube dysfunction can be assessed by thorough nasal examination including endoscopy, tests of allergy, CT scan of temporal bones and of paranasal sinuses. MRI may be required to exclude multiple sclerosis in patulous eustachian tube.

## **10 Disorders of Middle Ear**

### **ACUTE SUPPURATIVE OTITIS MEDIA**

It is an acute inflammation of middle ear by pyogenic organisms. Here, middle ear implies middle ear cleft, i.e. eustachian tube, middle ear, attic, aditus, antrum and mastoid air cells.

## Aetiology

It is more common especially in infants and children of lower socio-economic group. Typically, the disease follows viral infection of upper respiratory tract but soon the pyogenic organisms invade the middle ear.

# Routes of Infection

## **1. *Via eustachian tube***

It is the most common route. Infection travels via the lumen of the tube or along subepithelial peritubal lymphatics. Eustachian tube in infants and young children is shorter, wider and more horizontal and thus may account for higher incidence of infections in this age group. Breast or bottle feeding in a young infant in horizontal position may force fluids through the tube into the middle ear and hence the need to keep the infant propped up with head a little higher. Swimming and diving can also force water through the tube into the middle ear.

## **2. *Via external ear***

Traumatic perforations of tympanic membrane due to any cause open a route to middle ear infection.

## **3. *Blood-borne***

This is an uncommon route.

## Predisposing Factors

Anything that interferes with normal functioning of eustachian tube predisposes to middle ear infection. It could be:

- 1. Recurrent attacks of common cold, upper respiratory tract infections, and exanthematous fevers like measles, diphtheria, whooping cough.
- 2. Infections of tonsils and adenoids.
- 3. Chronic rhinitis and sinusitis.
- 4. Nasal allergy.
- 5. Tumours of nasopharynx, packing of nose or nasopharynx for epistaxis.
- 6. Cleft palate.

### **Bacteriology**

Most common organisms in infants and young children are *Streptococcus pneumoniae* (30%), *Haemophilus influenzae* (20%) and *Moraxella catarrhalis* (12%). Other organisms include *Streptococcus pyogenes*, *Staphylococcus aureus* and sometimes *Pseudomonas aeruginosa*. In about 18-20%, no growth is seen. Many of the strains of *H. influenzae* and *Moraxella catarrhalis* are  $\beta$ -lactamase producing.

# Pathology and Clinical Features

The disease runs through the following stages:

## **1. Stage of tubal occlusion**

Oedema and hyperaemia of nasopharyngeal end of eustachian tube blocks the tube, leading to absorption of air and negative intratympanic pressure. There is retraction of tympanic membrane with some degree of effusion in the middle ear but fluid may not be clinically appreciable.

*Symptoms.* Deafness and earache are the two symptoms but they are not marked. There is generally no fever.

*Signs.* Tympanic membrane is retracted with handle of malleus assuming a more horizontal position, prominence of lateral process of malleus and loss of light reflex. Tuning fork tests show conductive deafness.

## **2. Stage of pre-suppurative**

If tubal occlusion is prolonged, pyogenic organisms invade tympanic cavity causing hyperaemia of its lining. Inflammatory exudate appears in the middle ear. Tympanic membrane becomes congested.

*Symptoms.* There is marked earache which may disturb sleep and is of throbbing nature. Deafness and tinnitus are also present, but complained only by adults. Usually, child runs high degree of fever and is restless.

page 69

page 70

*Signs.* To begin with, there is congestion of pars tensa. Leash of blood vessels appear along the handle of malleus and at the periphery of tympanic membrane imparting it a cart-wheel appearance. Later, whole of tympanic membrane including pars flaccida becomes uniformly red.

Tuning fork tests will again show conductive type of hearing loss.

## **3. Stage of suppuration**

This is marked by formation of pus in the middle ear and to some extent in mastoid air cells. Tympanic membrane starts bulging to the point of rupture.

*Symptoms.* Earache becomes excruciating. Deafness increases, child may run fever of 102-103°F. This may be accompanied by vomiting and even convulsions.

*Signs.* Tympanic membrane appears red and bulging with loss of landmarks. Handle of malleus may be engulfed by the swollen and protruding tympanic membrane and may not be discernible. A yellow spot may be seen on the tympanic membrane where rupture is imminent. In pre-antibiotic era, one could see a nipple-like protrusion of tympanic membrane with a yellow spot on its summit. Tenderness may be elicited over the mastoid antrum.

X-rays of mastoid will show clouding of air cells because of exudate.

**4. Stage of resolution** The tympanic membrane ruptures with release of pus and subsidence of symptoms. Inflammatory process begins to resolve. If proper treatment is started early or if the infection was mild, resolution may start even without rupture of tympanic membrane.

*Symptoms.* With evacuation of pus, earache is relieved, fever comes down and child feels better.

*Signs.* External auditory canal may contain blood-tinged discharge which later becomes mucopurulent. Usually, a small perforation is seen in antero-inferior quadrant of pars tensa. Hyperaemia of tympanic membrane begins to subside with return to normal colour and landmarks.

## **5. Stage of complication**

If virulence of organism is high or resistance of patient poor, resolution may not take place and disease spreads beyond the confines of middle ear. It may lead to acute mastoiditis, subperiosteal abscess, facial paralysis, labyrinthitis, petrositis, extradural abscess, meningitis, brain abscess or lateral sinus thrombophlebitis.

# Treatment

## 1. Antibacterial therapy (Table 10.1)

It is indicated in all cases with fever and severe earache. As the most common organisms are *Strept. pneumoniae* and *H. influenzae*, the drugs which are effective in acute otitis media are ampicillin (50 mg/kg/day in 4 divided doses), amoxicillin (40 mg/kg/day in 3 divided doses). Those allergic to these penicillins can be given cefaclor, co-trimoxazole or erythromycin. In cases where  $\beta$ -lactamase-producing *H. influenzae* or *Moraxella catarrhalis* are isolated, antibiotics like amoxicillin-clavulanate, augmentin, cefuroxime axetil or cefixime may be used. Antibacterial therapy must be continued for a minimum of 10 days, till tympanic membrane regains normal appearance and hearing returns to normal. Early discontinuance of therapy with relief of earache and fever, or therapy given in inadequate doses may lead to secretory otitis media and residual hearing loss.

## 2. Decongestant nasal drops

Ephedrine nose drops (1% in adults and 0.5% in children) or oxymetazoline (Nasivion) or xylometazoline (Otrivin) should be used to relieve eustachian tube oedema and promote ventilation of middle ear.

Table 10-1. Antibacterial agents and their dosage in acute otitis media

Drug	Trade names	Total daily dose	Divided dose
Amoxicillin	Novamox, Biomox	40 mg/kg	3
Ampicillin	Biocillin	50-100 mg/kg	4
Co-amoxiclav	Augmentin, Enhancin	40 mg/kg	2-3
Erythromycin	Emycin, Althrocin	30-50 mg/kg	4
Cefaclor (II generation)	Keflor, Distaclor	20 mg/kg	2-3
Cefixime (III generation)	Taxim-0, Biotax-0	8 mg/kg	1 or 2
Cefpodoxime proxetil	Cepodem, Cefoprox	10 mg/kg (max. 400 mg/day)	2
Ceftibuten (III generation)	Procadax	9 mg/kg	1
Co-trimoxazol (Trimethoprim + Sulphamethoxazole)	Ciplin, Septran	8 mg (TMP) + 40 mg (SMZ)/kg	2

\*Follow the dosage and instructions of the manufacturer.

page 70

page 71

## 3. Oral nasal decongestants

Pseudoephedrine (Sudafed) 30 mg twice daily or a combination of decongestant and antihistaminic (Triominic) may achieve the same result without resort to nasal drops which are difficult to administer in children.

## 4. Analgesics and antipyretics

Paracetamol helps to relieve pain and bring down temperature.

## 5. Ear toilet

If there is discharge in the ear, it is dry-mopped with sterile cotton buds and a wick moistened with antibiotic may be inserted.

## 6. Dry local heat

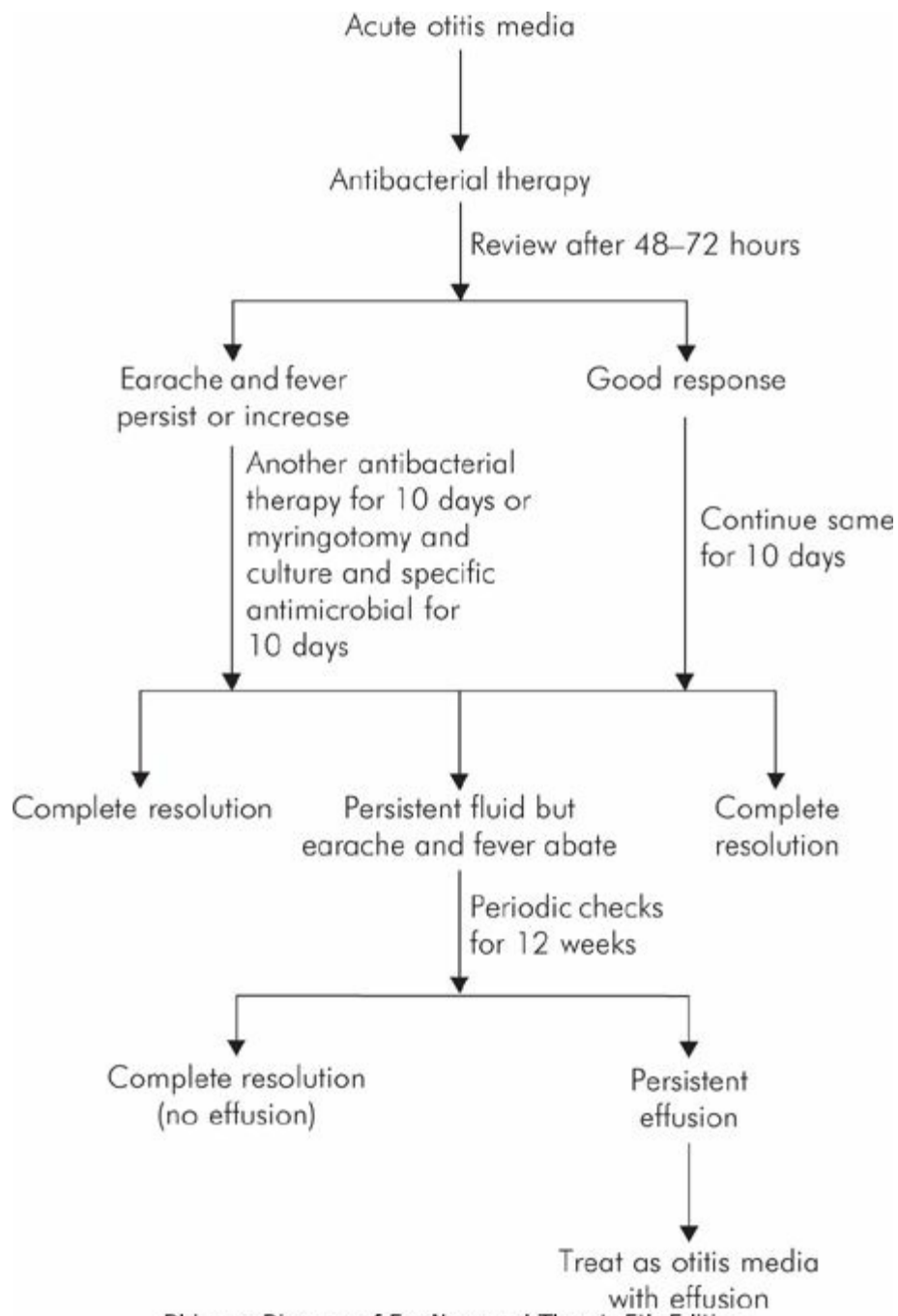
It helps to relieve pain.

## 7. Myringotomy

It is incising the drum to evacuate pus and is indicated when (a) drum is bulging and there is acute pain, (b) there is an incomplete resolution despite antibiotics when drum remains full with persistent conductive deafness, (c) there is persistent effusion beyond 12 weeks.

All cases of acute suppurative otitis media should be carefully followed till drum membrane returns to its normal appearance and conductive deafness disappears (Fig. 10.1).





Dhingra: Diseases of Ear Nose and Throat, 5th Edition  
 Copyright © 2010 Elsevier. All rights reserved.

Figure 10.1 Treatment of acute otitis media.

## **ACUTE NECROTISING OTITIS MEDIA**

It is a variety of acute suppurative otitis media, often seen in children suffering from measles, scarlet fever or influenza. Causative organism is  $\beta$ -haemolytic streptococcus. There is rapid destruction of whole of tympanic membrane with its annulus, mucosa of promontory, ossicular chain and even mastoid air cells. There is profuse otorrhoea. In these cases, healing is followed by fibrosis or ingrowth of squamous epithelium from the meatus (*secondary acquired cholesteatoma*).

Treatment is early institution of antibacterial therapy. It is continued for at least 7-10 days, even if response is seen early. Cortical mastoidectomy may be indicated if medical treatment fails to control or the condition gets complicated by acute mastoiditis.

## **OTITIS MEDIA WITH EFFUSION**

Syn. Serous Otitis Media, Secretory Otitis Media, Mucoid Otitis Media, "Glue Ear"

This is an insidious condition characterised by accumulation of non-purulent effusion in the middle ear cleft. Often the effusion is thick and viscid but sometimes it may be thin and serous. The fluid is nearly sterile. The condition is commonly seen in school-going children.

# Pathogenesis

Two main mechanisms are thought to be responsible:

## **1. Malfunctioning of eustachian tube**

Eustachian tube fails to aerate the middle ear and is also unable to drain the fluid.

## **2. Increased secretory activity of middle ear mucosa**

Biopsies of middle ear mucosa in these cases have confirmed increase in number of mucus or serous-secreting cells.

# Aetiology

## **1. Malfunctioning of eustachian tube**

page 71

page 72

The causes are:

- **(i)** Adenoid hyperplasia.
- **(ii)** Chronic rhinitis and sinusitis.
- **(iii)** Chronic tonsillitis. Enlarged tonsils mechanically obstruct the movements of soft palate and interfere with the physiological opening of eustachian tube.
- **(iv)** Benign and malignant tumours of nasopharynx. This cause should always be excluded in unilateral serous otitis media in an adult.
- **(v)** Palatal defects, e.g. cleft palate, palatal paralysis.

## **2. Allergy**

Seasonal or perennial allergy to inhalants or foodstuff is common in children. This not only obstructs eustachian tube by oedema but may also lead to increased secretory activity as middle ear mucosa acts as a shock organ in such cases.

## **3. Unresolved otitis media**

Inadequate antibiotic therapy in acute suppurative otitis media may inactivate infection but fail to resolve it completely. Low grade infection lingers on. This acts as stimulus for mucosa to secrete more fluid. The number of goblet cells and mucous glands also increase. Recent increase in the incidence of this disease seems to be due to this factor.

## **4. Viral infections**

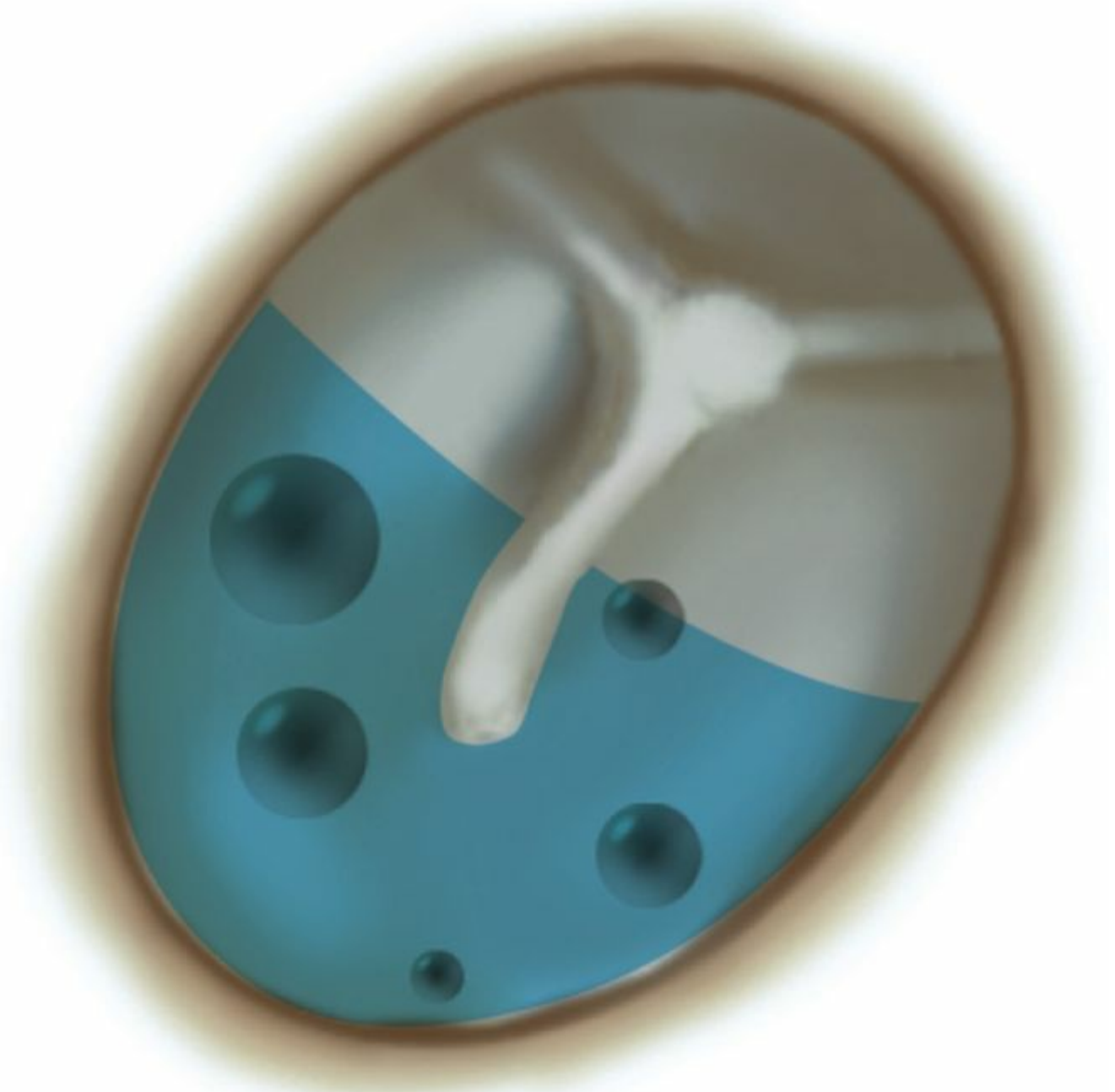
Various adeno- and rhino-viruses of upper respiratory tract may invade middle ear mucosa and stimulate it to increased secretory activity.

## Clinical Features

### Symptoms

The disease affects children of 5-8 years of age. The symptoms include:

- **(i) Hearing loss.** This is the presenting and sometimes the only symptom. It is insidious in onset and rarely exceeds 40 dB. Deafness may pass unnoticed by the parents and may be accidentally discovered during audiometric screening tests.
- **(ii) Delayed and defective speech.** Because of hearing loss, development of speech is delayed or defective.
- **(iii) Mild earaches.** There may be history of upper respiratory tract infections with mild earaches.



Dhingra: Diseases of Ear Nose and Throat, 5th Edition  
Copyright © 2010 Elsevier. All rights reserved.

Figure 10.2 Otitis media with effusion. Note appearance of bubbles on Valsalva.

### Otoscopic findings

Tympanic membrane is often dull and opaque with loss of light reflex. It may appear yellow, grey or bluish in colour.

Thin leash of blood vessels may be seen along the handle of malleus or at the periphery of tympanic membrane and differs from marked congestion of acute suppurative otitis media.

Tympanic membrane may show varying degree of retraction. Sometimes, it may appear full or slightly bulging in its posterior part due to effusion.

Fluid level and air bubbles may be seen when fluid is thin and tympanic membrane transparent (Fig. 10.2).

Mobility of the tympanic membrane is restricted.

## Hearing Tests

- (i) *Tuning fork tests* show conductive hearing loss.
- (ii) *Audiometry*. There is conductive hearing loss of 20-40 dB. Sometimes, there is associated sensorineural hearing loss due to fluid pressing on the round window membrane. This disappears with evacuation of fluid.
- (iii) *Impedance audiometry*. It is an objective test useful in infants and children. Presence of fluid is indicated by reduced compliance and flat curve with a shift to negative side.
- (iv) *X-ray mastoids*. There is clouding of air cells due to fluid.



# Treatment

The aim of treatment is removal of fluid and prevention of its recurrence.

## **A. Medical**

### **1. Decongestants**

Topical decongestants in the form of nasal drops, sprays or systemic decongestants help to relieve oedema of eustachian tube.

### **2. Antiallergic measures**

Antihistaminics or sometimes steroids may be used in cases of allergy. If possible, allergen should be found and desensitisation done.

### **3. Antibiotics**

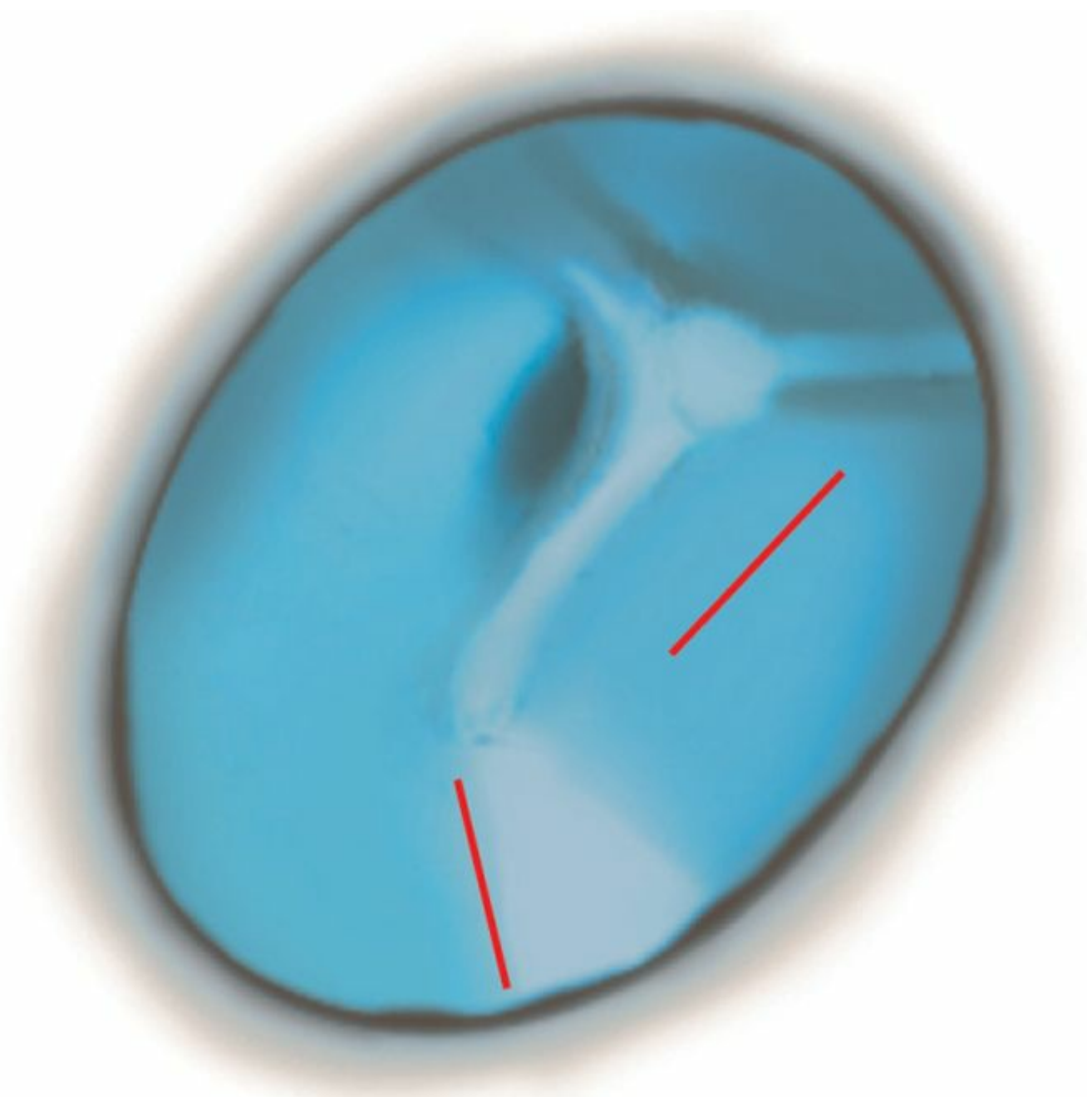
They are useful in cases of upper respiratory tract infections or unresolved acute suppurative otitis media.

### **4. Middle ear aeration**

Patient should repeatedly perform Valsalva manoeuvre. Sometimes, politzerisation or eustachian tube catheterisation has to be done. This helps to ventilate middle ear and promote drainage of fluid. Children can be given chewing gum to encourage repeated swallowing which opens the tube.

## **B. Surgical**

When fluid is thick and medical treatment alone does not help, fluid must be surgically removed.



Dhingra: Diseases of Ear Nose and Throat, 5th Edition  
 Copyright © 2010 Elsevier. All rights reserved.

Figure 10.3 To aspirate thick mucus, two incisions may be required in the tympanic membrane.

### **1. Myringotomy and aspiration of fluid**

An incision is made in tympanic membrane and fluid aspirated with suction. Thick mucus may require installation of saline or a mucolytic agent like chymotrypsin solution to liquefy mucus before it can be aspirated. Sometimes, two incisions are made in the tympanic membrane, one in the antero-inferior and the other in antero-superior quadrant, to aspirate thick, glue-like secretions (Fig. 10.3) on "beer-can" principle.

### **2. Grommet insertion**

If myringotomy and aspiration combined with medical measures has not helped and fluid recurs, a grommet is inserted to provide continued aeration of middle ear (Fig. 10.4). It is left in place for weeks or months or till it is spontaneously extruded.

### **3. Tympanotomy or cortical mastoidectomy**

It is sometimes required for removal of loculated thick fluid or other associated pathology such as cholesterol granuloma.

### **4. Surgical treatment of causative factor**

Adenoidectomy, tonsillectomy and/or wash-out of maxillary antra, may be required. This is usually done at the time of myringotomy.

## **Sequelae of Chronic Secretory Otitis Media**

### 1. Atrophic tympanic membrane and atelectasis of the middle ear

In prolonged effusions, there is dissolution of fibrous layer of tympanic membrane. It becomes thin and atrophic and retracts into the middle ear.

### 2. Ossicular necrosis

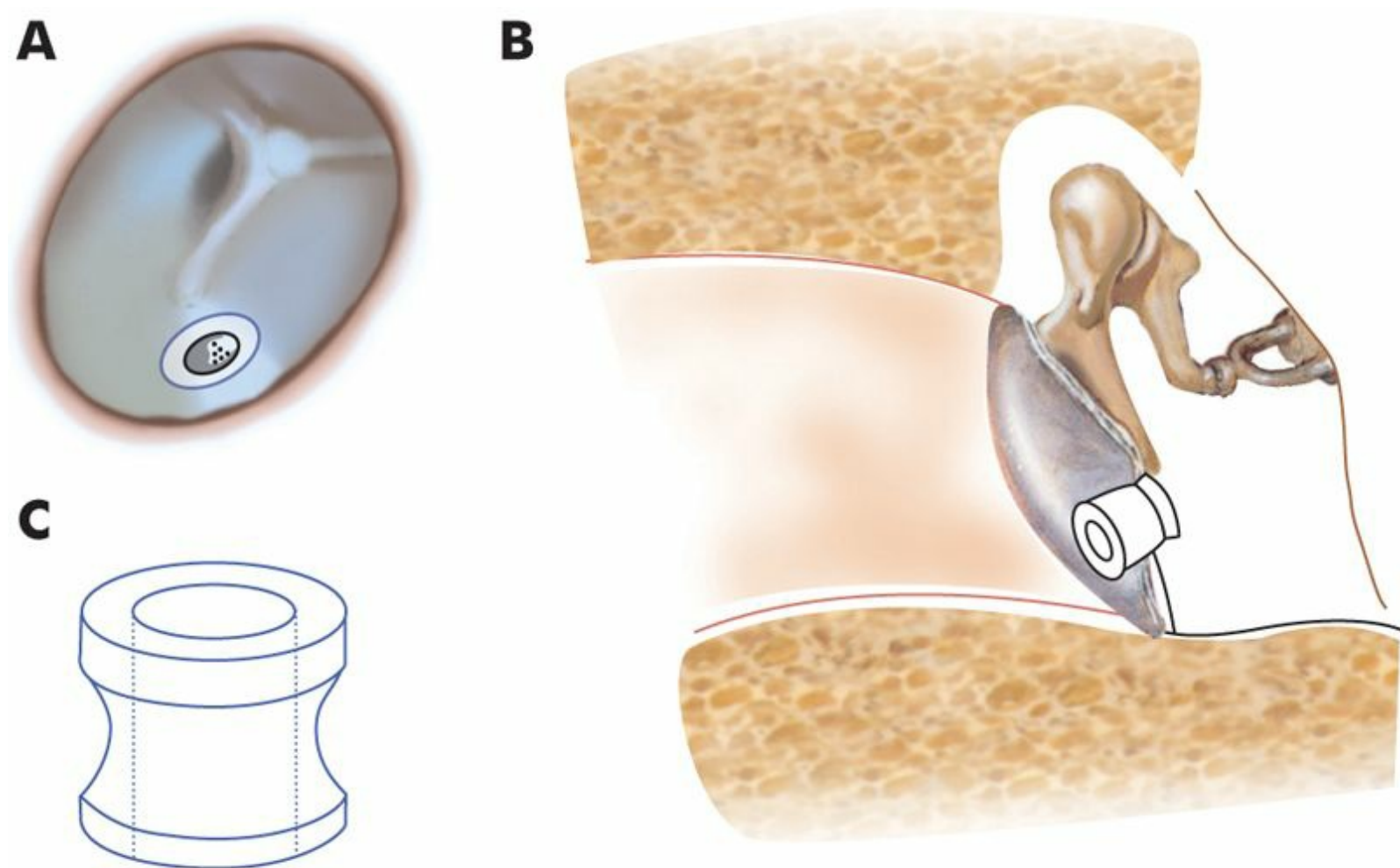
Most commonly, long process of incus gets necrosed. Sometimes, stapes superstructure also gets necrosed. This increases the conductive hearing loss to more than 50 dB.

### 3. Tympanosclerosis

Hyalinised collagen with chalky deposits may be seen in tympanic membrane, around the ossicles or their joints, leading to their fixation.

### 4. Retraction pockets and cholesteatoma

Thin atrophic part of pars tensa may get invaginated to form retraction pockets or cholesteatoma. Similar pockets may be seen in the attic region.



Dhingra: Diseases of Ear Nose and Throat, 5th Edition  
Copyright © 2010 Elsevier. All rights reserved.

Figure 10.4 Grommet in the tympanic membrane (A & B), the grommet (C).

### 5. Cholesterol granuloma

This is due to stasis of secretions in middle ear and mastoid.

## Recurrent Acute Otitis Media

Infants and children between the age of 6 months and 6 years may get recurrent episodes of acute otitis media. Such episodes may occur 4-5 times in a year. Usually, they occur after acute upper respiratory infection, the child being free of symptoms between the episodes; Recurrent middle infections may sometimes be superimposed upon an existing middle ear effusion. Sometimes, the underlying cause is recurrent sinusitis, velopharyngeal insufficiency, hypertrophy of adenoids, infected tonsils, allergy and immune deficiency. Feeding the babies in supine position without propping up the head may also cause the milk to enter the middle ear directly that can lead to middle ear infection.

Management of such children involves:

- **1.** Finding the cause and eliminating it, if possible.
- **2.** *Antimicrobial prophylaxis.* Amoxicillin (20 mg/kg for 3 to 6 months) or sulphasoxazole have been used but they prevent only 1-2 bouts of otitis media in a year and have the disadvantage of creating antimicrobial resistance or hypersensitivity reaction and thus not preferred by many in favour of early insertion of tympanostomy tubes.
- **3.** *Myringotomy and insertion of tympanostomy tube.* If the child has 4 bouts of acute otitis media in 6 months or 6 bouts in 1 year, insertion of a tympanostomy tube is recommended.
- **4.** Adenoidectomy with or without tonsillectomy.
- **5.** Management of inhalant or food allergy.

## **AERO-OTITIS MEDIA (OTITIC BAROTRAUMA)**

It is a non-suppurative condition resulting from failure of eustachian tube to maintain middle ear pressure at ambient atmospheric level. The usual cause is rapid descent during air flight, underwater diving or compression in pressure chamber.

## Mechanism

Eustachian tube allows easy and passive egress of air from middle ear to the pharynx if middle ear pressure is high. In the reverse situation, where nasopharyngeal air pressure is high, air cannot enter the middle ear unless tube is actively opened by the contraction of muscles as in swallowing, yawning or Valsalva manoeuvre. When atmospheric pressure is higher than that of middle ear by critical level of 90 mm of Hg, eustachian tube gets "locked", i.e. soft tissues of pharyngeal end of the tube are forced into its lumen. In the presence of eustachian tube oedema, even smaller pressure differentials cause "locking" of the tube. Sudden negative pressure in the middle ear causes retraction of tympanic membrane, hyperaemia and engorgement of vessels, transudation and haemorrhages.

Sometimes, though rarely, there is rupture of labyrinthine membranes with vertigo and sensorineural hearing loss.

## Clinical Features

Severe earache, hearing loss and tinnitus are common complaints. Vertigo is uncommon. Tympanic membrane appears retracted and congested. It may get ruptured.

Middle ear may show air bubbles or haemorrhagic effusion. Hearing loss is usually conductive but sensorineural type of loss may also be seen.

## Treatment

The aim is to restore middle ear aeration. This is done by catheterisation or politzerisation. In mild cases, decongestant nasal drops or oral nasal decongestant with antihistaminics are helpful. In the presence of fluid or failure of the above methods, myringotomy may be performed to "unlock" the tube and aspirate the fluid.



# Prevention

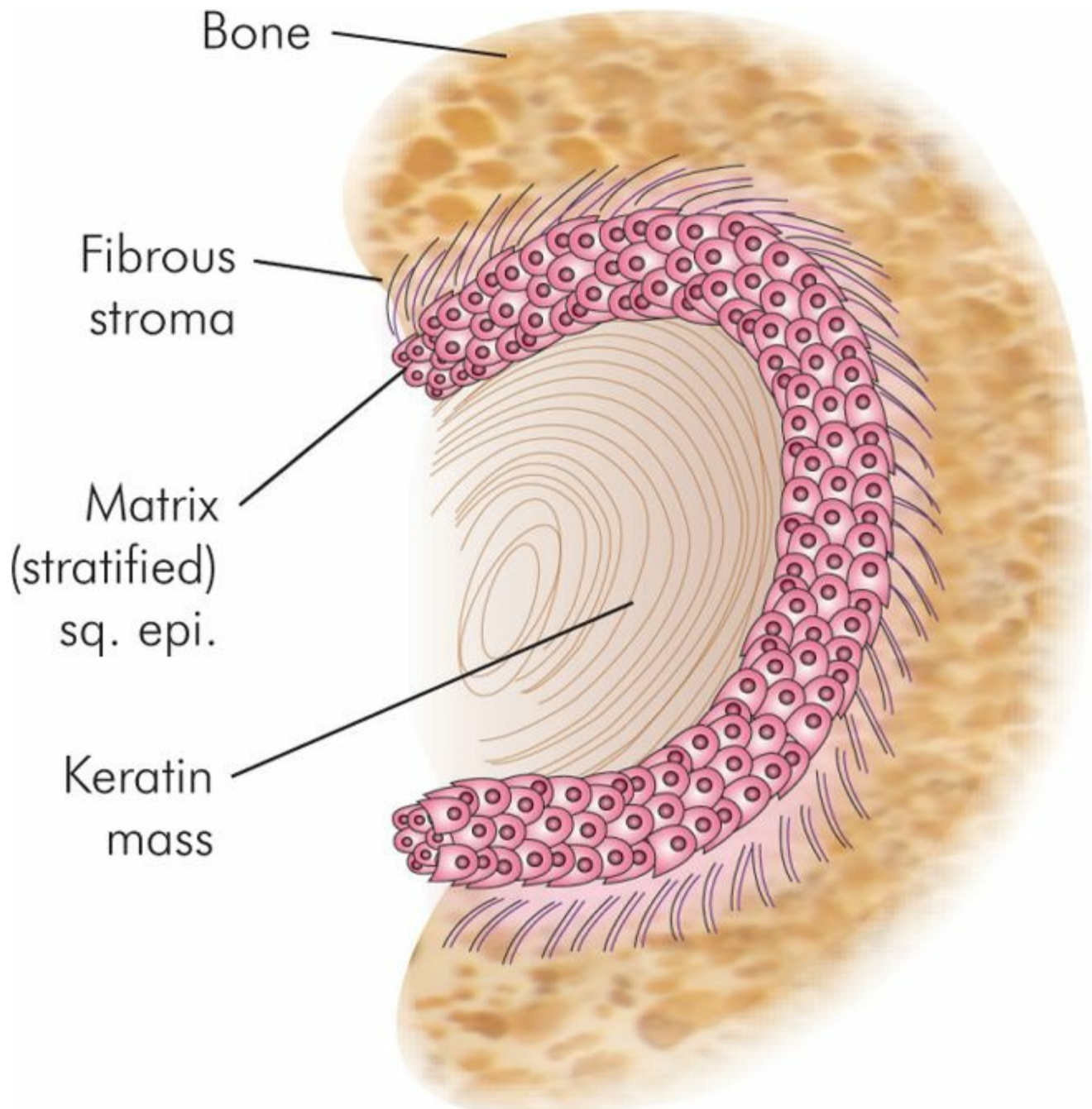
Aero-otitis can be prevented by the following measures:

- **1.** Avoid air travel in the presence of upper respiratory infection or allergy.
- **2.** Swallow repeatedly during descent. Sucking sweets or chewing gum is useful.
- **3.** Do not permit sleep during descent as number of swallows normally decrease during sleep.
- **4.** Autoinflation of the tube by Valsalva should be performed intermittently during descent.
- **5.** Use vasoconstrictor nasal spray and a tablet of antihistaminic and systemic decongestant, half an hour before descent in persons with previous history of this episode.
- **6.** In recurrent barotrauma, attention should be paid to nasal polyps, septal deviation, nasal allergy and chronic sinus infections.

## CHOLESTEATOMA

Normally, middle ear cleft is lined by different types of epithelium in different regions: ciliated columnar in the anterior and inferior part, cuboidal in the middle part and pavement-like in the attic. The middle ear is no where lined by keratinising squamous epithelium. It is the presence of latter type of epithelium in the middle ear or mastoid that constitutes a cholesteatoma. In other words, cholesteatoma is a "skin in the wrong place". The term cholesteatoma is a misnomer, because it neither contains cholesterol crystals nor is it a tumour to merit the suffix "oma". However, the term has been retained because of its wider usage.

Essentially, cholesteatoma consists of two parts, (i) the *matrix*, which is made up of keratinising squamous epithelium resting on a thin stroma of fibrous tissues and (ii) a central white mass, consisting of *keratin debris* produced by the matrix (Fig. 11.1). For this reason, it has also been named *epidermosis* or *keratoma*.



Dhingra: Diseases of Ear Nose and Throat, 5th Edition  
Copyright © 2010 Elsevier. All rights reserved.

Figure 11.1 Schematic structure of cholesteatoma.

# Origin of Cholesteatoma

Genesis of cholesteatoma is a matter of debate. Any theory of its genesis must explain how squamous epithelium appeared in the middle ear cleft. The various views expressed are:

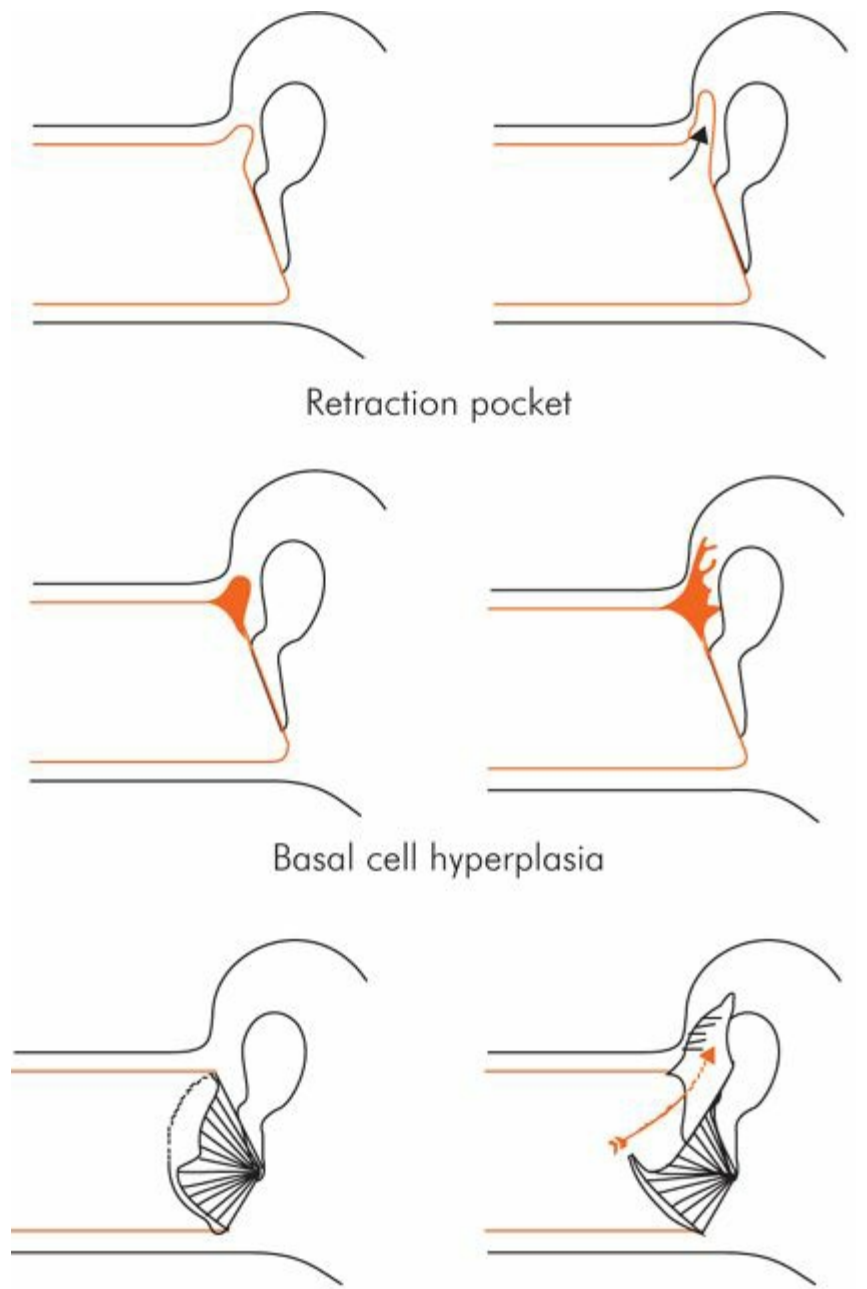
- **1.** Presence of congenital cell rests.
- **2.** Invagination of tympanic membrane from the attic or posterosuperior part of pars tensa in the form of retraction pockets (Fig. 11.2) (*Wittmaack's theory*). The outer surface of tympanic membrane is lined by stratified squamous epithelium which after invagination forms the matrix of cholesteatoma and lays down keratin in the pocket.
- **3.** Basal cell hyperplasia (*Ruedi's theory*). The basal cells of germinal layer of skin proliferate under the influence of infection, and lay down keratinising squamous epithelium.
- **4.** Epithelial invasion (*Habermann's theory*). The epithelium from the meatus or outer drum surface grows into the middle ear through a pre-existing perforation especially of the marginal type where part of annulus tympanicus has already been destroyed.
- **5.** Metaplasia (*Sade's theory*). Middle ear mucosa, like respiratory mucosa elsewhere, undergoes metaplasia due to repeated infections and transforms into squamous epithelium.

# Classification of Cholesteatoma (Fig. 11.3)

The cholesteatoma is classified into:

- 1. Congenital
- 2. Acquired, primary
- 3. Acquired, secondary

## 1. Congenital cholesteatoma



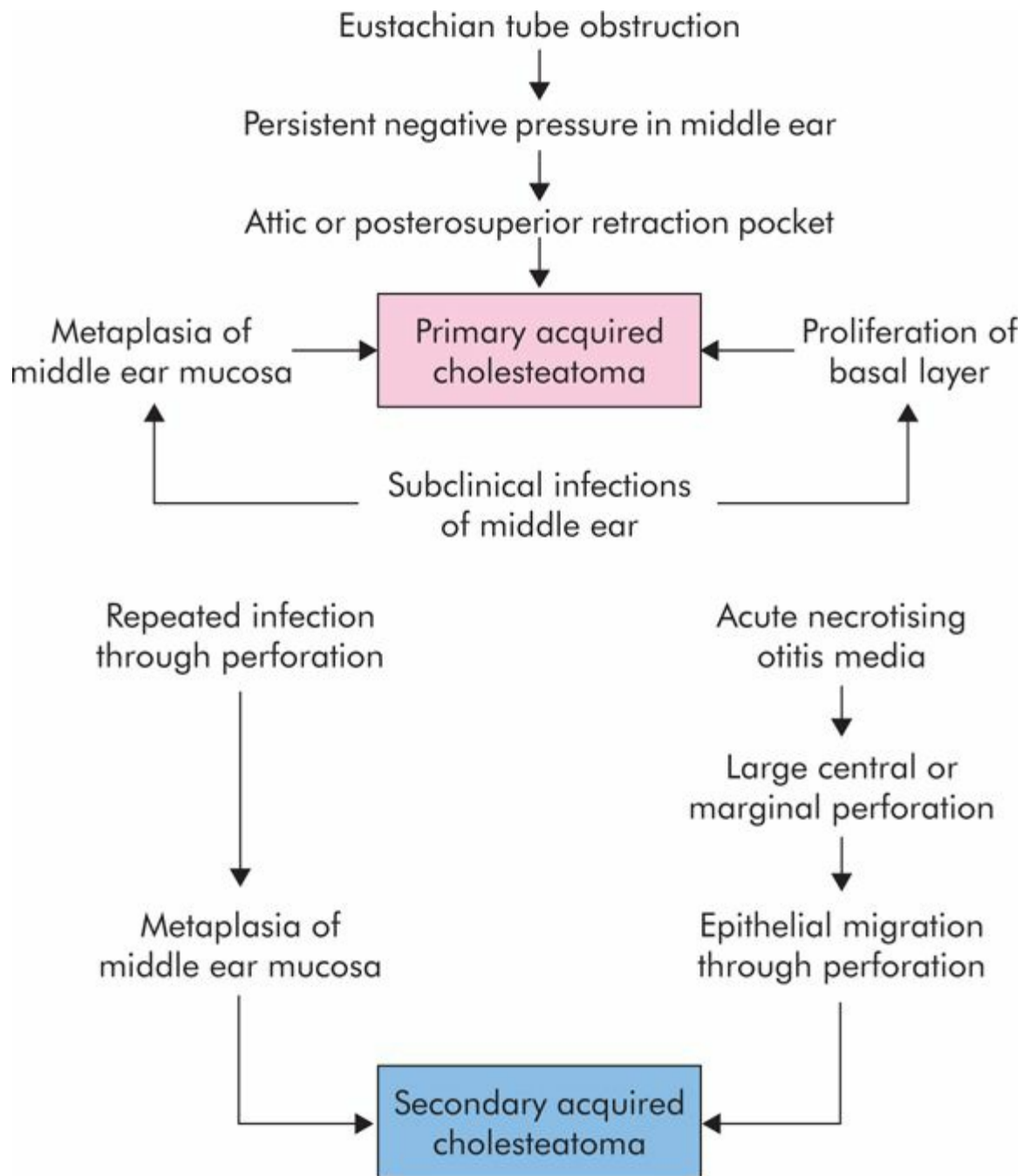
Retraction pocket

Basal cell hyperplasia

Epithelial invasion through posterosuperior perforation

Dhingra: Diseases of Ear Nose and Throat, 5th Edition  
Copyright © 2010 Elsevier. All rights reserved.

Figure 11.2 Genesis of cholesteatoma.



Dhingra: Diseases of Ear Nose and Throat, 5th Edition  
Copyright © 2010 Elsevier. All rights reserved.

Figure 11.3 Genesis of primary and secondary cholesteatoma.

It arises from the embryonic epidermal cell rests in the middle ear cleft or temporal bone. Congenital cholesteatoma occurs at three important sites: middle ear, petrous apex and the cerebellopontine angle, and produces symptomatology depending on its location.

A middle ear congenital cholesteatoma presents as a white mass behind an intact tympanic membrane and causes conductive hearing loss. It may sometimes be discovered on routine examination of children or at the time of myringotomy.

It may also spontaneously rupture through the tympanic membrane and present with a discharging ear indistinguishable from a case of chronic suppurative otitis media (CSOM).

## 2. Primary acquired cholesteatoma

It is called primary as there is no history of previous otitis media or a pre-existing perforation. Theories on its genesis are:

- **(a) Invagination of pars flaccida.** Persistent negative pressure in the attic causes a retraction pocket which accumulates keratin debris. When infected, the keratin mass expands towards the middle ear. Thus, attic perforation is in fact the proximal end of an expanding invaginated sac.
- **(b) Basal cell hyperplasia.** There is proliferation of the basal layer of pars flaccida induced by subclinical childhood infections. Expanding cholesteatoma then breaks through pars flaccida forming an attic perforation.
- **(c) Squamous metaplasia.** Normal pavement epithelium of attic undergoes metaplasia, keratinising squamous epithelium due to subclinical infections. Such a change has also been demonstrated in cases of otitis media with effusion.

### 3. Secondary acquired cholesteatoma

In these cases, there is already a pre-existing perforation in pars tensa. This is often associated with posterosuperior marginal perforation or sometimes large central perforation. Theories on its genesis include:

- **(a) Migration of squamous epithelium.** Keratinising squamous epithelium of external auditory canal or outer surface of tympanic membrane migrates through the perforation into the middle ear. Perforations, involving tympanic annulus as in acute necrotising otitis media, are more likely to allow in-growth of squamous epithelium.
- **(b) Metaplasia.** Middle ear mucosa undergoes metaplasia due to repeated infections of middle ear through the pre-existing perforation.

## Expansion of Cholesteatoma and Destruction of Bone

Once cholesteatoma enters the middle ear cleft, it invades the surrounding structures, first by following the path of least resistance, and then by enzymatic bone destruction.

page 76

page 77

An attic cholesteatoma may extend backwards into the aditus, antrum and mastoid; downwards into the mesotympanum; medially, it may surround the incus and/or head of malleus.

Cholesteatoma has the property to destroy bone. It may cause destruction of ear ossicles, erosion of bony labyrinth, canal of facial nerve, sinus plate or tegmen tympani and thus cause several complications. Bone destruction by cholesteatoma has been attributed to various enzymes such as collagenase, acid phosphatase and proteolytic enzymes, liberated by osteoclasts and mononuclear inflammatory cells, seen in association with cholesteatoma. The earlier theory that cholesteatoma causes destruction of bone by pressure necrosis is not accepted these days.

## **CHRONIC SUPPURATIVE OTITIS MEDIA**

Chronic suppurative otitis media (CSOM) is a long-standing infection of a part or whole of the middle ear cleft characterised by ear discharge and a permanent perforation. A perforation becomes permanent when its edges are covered by squamous epithelium and it does not heal spontaneously. A permanent perforation can be likened to an epithelium-lined fistulous track.



## Epidemiology

Incidence of CSOM is higher in developing countries because of poor socio-economic standards, poor nutrition and lack of health education. It affects both sexes and all age groups. In India, the overall prevalence rate is 46 and 16 persons per thousand in rural and urban population respectively. It is also the single most important cause of hearing impairment in rural population.

# Types of CSOM

Clinically, it is divided into two types:

## 1. *Tubotympanic*

Also called the *safe* or *benign type*; it involves anteroinferior part of middle ear cleft, i.e. eustachian tube and mesotympanum and is associated with a central perforation. There is no risk of serious complications.

## 2. *Atticoantral*

Also called *unsafe* or *dangerous type*; it involves posterosuperior part of the cleft (i.e. attic, antrum and mastoid) and is associated with an attic or a marginal perforation. The disease is often associated with a bone-eroding process such as cholesteatoma, granulations or osteitis. Risk of complications is high in this variety.

Table 11.1 shows differences between the two types of CSOM.

**Table 11-1. Differences between atticoantral and tubotympanic type of CSOM**

	<b>Tubotympanic or safe type</b>	<b>Atticoantral or unsafe type</b>
Discharge	Profuse, mucoid, odourless	Scanty, purulent, foul-smelling
Perforation	Central	Attic or marginal
Granulations	Uncommon	Common
Polyp	Pale	Red and fleshy
Cholesteatoma	Absent	Present
Complications	Rare	Common
Audiogram	Mild to moderate conductive deafness	Conductive or mixed deafness

# A. Tubotympanic Type

## Aetiology

The disease starts in childhood and is therefore common in that age group.

- 1. It is the sequela of *acute otitis media* usually following exanthematous fever and leaving behind a large central perforation. The perforation becomes permanent and permits repeated infection from the external ear. Also the middle ear mucosa is exposed to the environment and gets sensitised to dust, pollen and other aeroallergens causing persistent otorrhoea.
- 2. Ascending infections via the eustachian tube. Infection from tonsils, adenoids and infected sinuses may be responsible for persistent or recurring otorrhoea. Ascending infection to middle ear occur more easily in the presence of infection.
- 3. Persistent mucoid otorrhoea is sometimes the result of allergy to ingestants such as milk, eggs, fish, etc.

## Pathology

The tubotympanic disease remain localised to the mucosa and, that too, mostly to anteroinferior part of the middle ear cleft. Like any other chronic infection, the processes of healing and destruction go hand in hand and either of them may take advantage over the other, depending on the virulence of organism and resistance of the patient. Thus, acute exacerbations are not uncommon. The pathological changes seen in this type of CSOM are:

### 1. Perforation of *pars tensa*

It is a central perforation and its size and position varies.

### 2. Middle ear mucosa

It may be normal when disease is quiescent or inactive. It is oedematous and velvety when disease is active.

page 77

page 78

### 3. Polyp

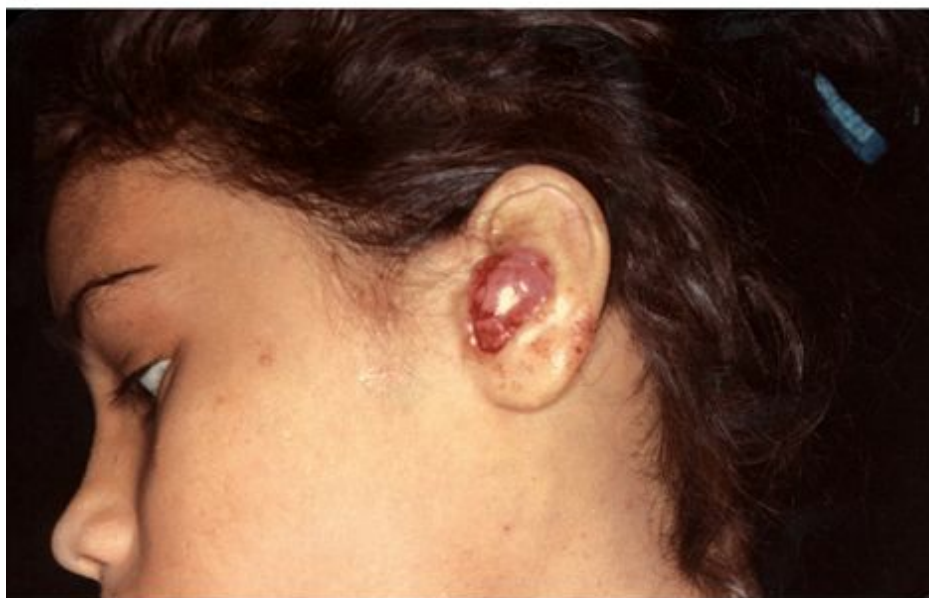A polyp is a smooth mass of oedematous and inflamed mucosa which has protruded through a perforation and presents in the external canal. It is usually pale in contrast to pink, fleshy polyp seen in atticoantral disease (Fig. 11.4).

### 4. Ossicular chain

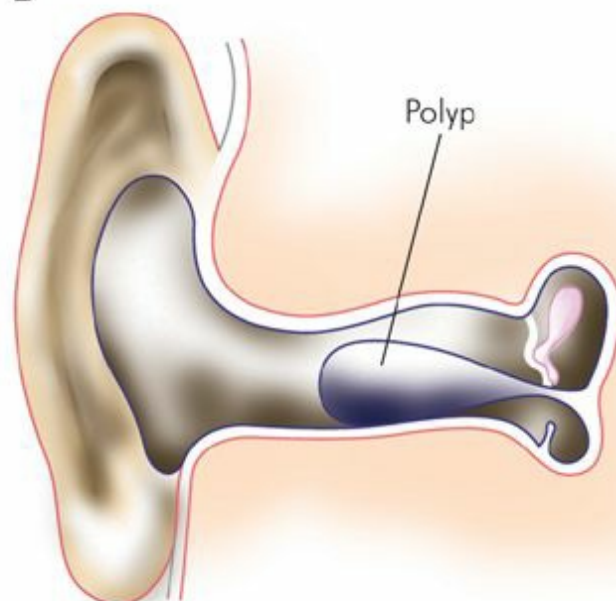
It is usually intact and mobile but may show some degree of necrosis, particularly of the long process of incus.

### 5. Tympanosclerosis

**A**



**B**



Dhingra: Diseases of Ear Nose and Throat, 5th Edition  
Copyright © 2010 Elsevier. All rights reserved.

Figure 11.4 (A) Polyp in the ear canal. (B) Schematic illustration of a polyp arising from the promontory passing through the perforation and presenting in the ear canal.

It is hyalinisation and subsequent calcification of subepithelial connective tissue. It is seen in remnants of tympanic membrane or under the mucosa of middle ear. It is seen as white chalky deposit on the promontory, ossicles, joints, tendons and oval and round windows.

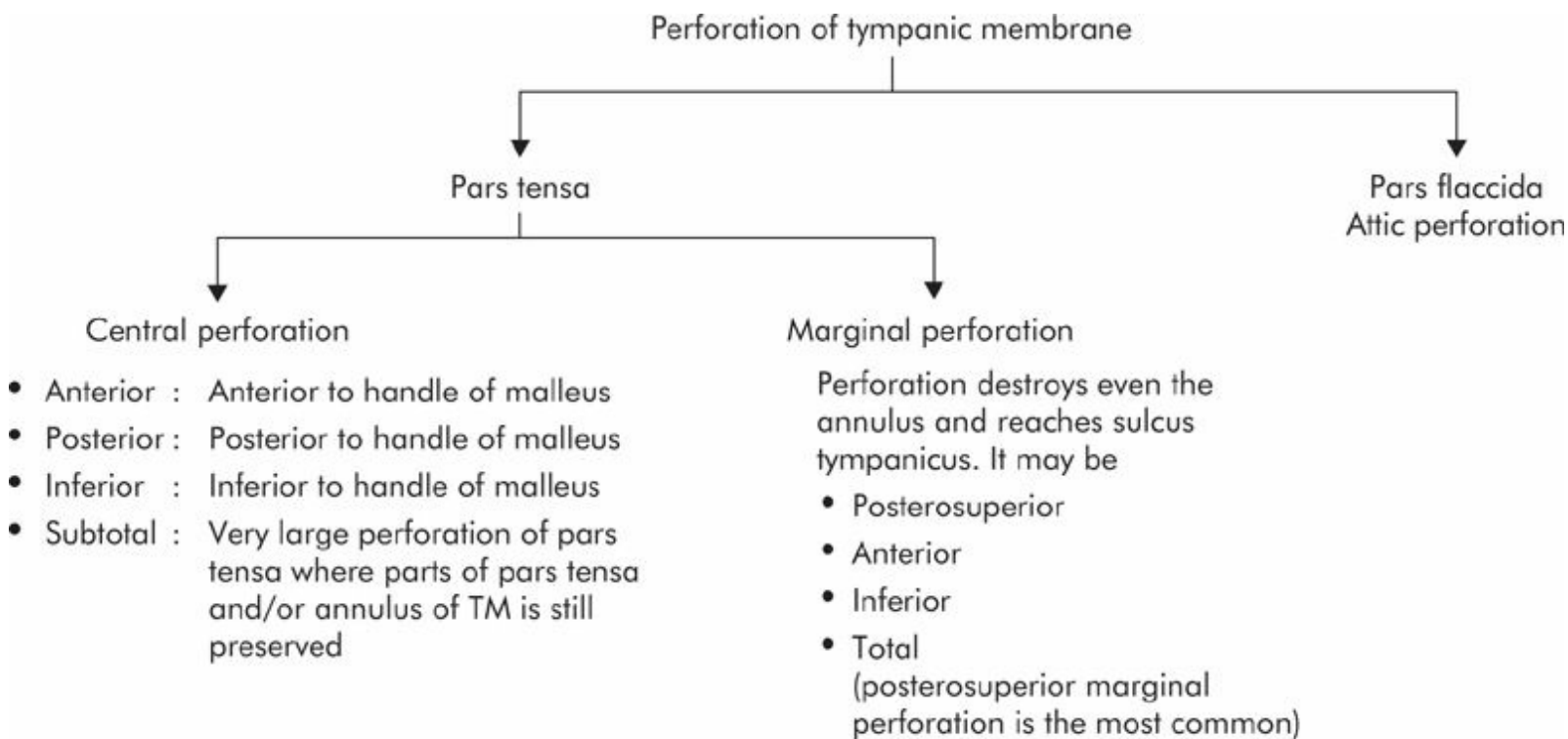
Tympanosclerotic masses may interfere with the mobility of these structures and cause conductive deafness.

## 6. Fibrosis and adhesions

They are the result of healing process and may further impair mobility of ossicular chain or block the eustachian tube.

**Note:** Attic and posterosuperior marginal perforation are seen in dangerous type of CSOM and are often associated with cholesteatoma. Stratified squamous epithelium from the external auditory canal can grow into the middle ear in any type of marginal perforation by immigration and form a cholesteatoma. Therefore, all marginal perforations are considered dangerous. Central perforations are considered safe as cholesteatoma is usually not associated with them.

## Bacteriology



Dhingra: Diseases of Ear Nose and Throat, 5th Edition  
Copyright © 2010 Elsevier. All rights reserved.

Figure 11.5 Perforation of tympanic membrane.

page 78

page 79

Pus culture in both types of aerobic and anaerobic CSOM may show multiple organisms. Common aerobic organisms are *Ps aeruginosa*, *Proteus*, *Esch. coli* and *Staph. aureus*, while anaerobes include *Bacteroides fragilis* and anaerobic *Streptococci*.

## Alternative Classification of Chronic Otitis Media

Tubotympanic disease of middle ear is a mucosal disease with no evidence of invasion of squamous epithelium. It is called "active" when there is a perforation of pars tensa with inflammation of mucosa and mucopurulent discharge. It is called "inactive" when there is a permanent perforation of pars tensa but middle ear mucosa is not inflamed and there is no discharge. *Permanent perforation* implies that squamous epithelium on the external surface of pars tensa and mucosa lining its inner surface have fused across its edge. *Healed chronic otitis media* is the condition when tympanic membrane has healed (usually by two layers), is atrophic and easily retracted if there is negative pressure in the middle ear. Healed otitis media may also have patches of tympanosclerosis in tympanic membrane, or in middle ear involving promontory, ossicles, tendons of stapedius and tensor tympanic. Fibrotic tissue may appear in middle ear. It is always associated with some degree of conductive hearing loss.

Atticoantral disease has been called squamosal disease of middle ear. It may be "inactive" when there are retraction pockets in pars tensa (usually the posterosuperior region) or pars flaccida. There is no discharge but there is a possibility of squamous debris in retraction pockets to become infected and start discharging. Some retraction pockets are shallow and self cleansing. "Active" squamosal disease of middle ear implies presence of cholesteatoma of posterosuperior region of pars tensa or in the pars flaccida. It erodes bone, forms granulation tissue and has purulent offensive discharge (Fig. 11.6).

## Clinical Features

### 1. Ear discharge

It is non-offensive, mucoïd or mucopurulent, constant or intermittent. The discharge appears mostly at time of upper respiratory tract infection or on accidental entry of water into the ear.

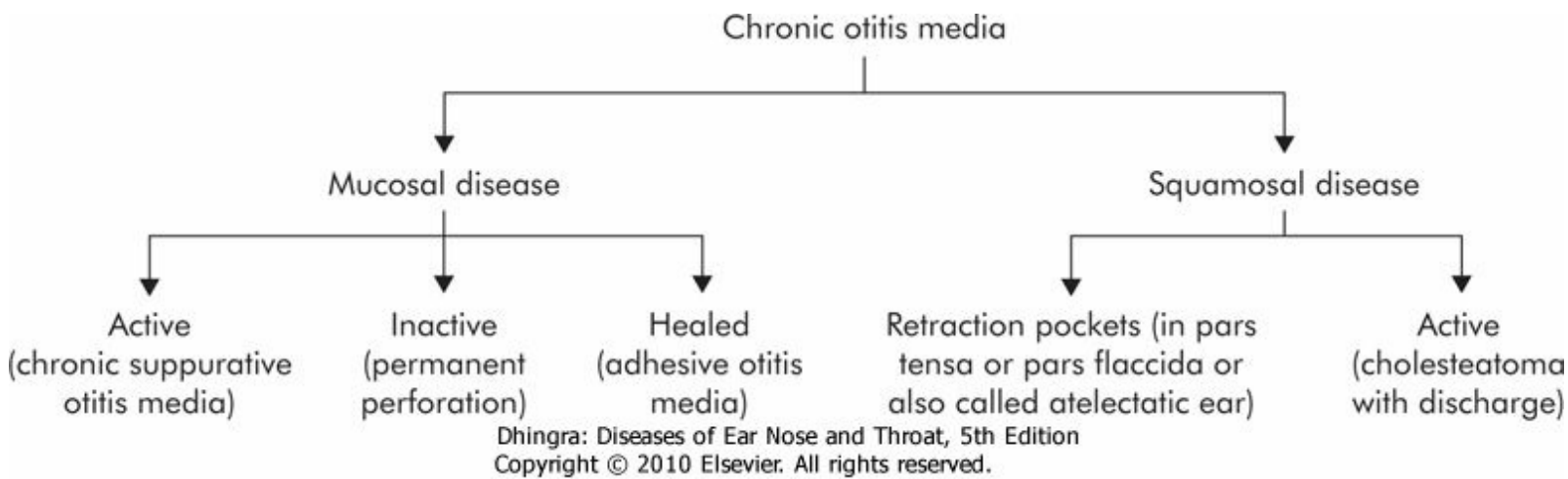


Figure 11.6 Classification of chronic otitis media.

## 2. Hearing loss

It is conductive type; severity varies but rarely exceeds 50 dB. Sometimes, the patient reports of a paradoxical effect, i.e. hears better in the presence of discharge than when the ear is dry. This is due to "*round window shielding effect*" produced by discharge which helps to maintain phase differential. In the dry ear with perforation, sound waves strike both the oval and round windows simultaneously, thus cancelling each other's effect (see Physiology of hearing).

In long standing cases, cochlea may suffer damage due to absorption of toxins from the oval and round windows and hearing loss becomes mixed type.

## 3. Perforation

Always central, it may lie anterior, posterior or inferior to the handle of malleus. It may be small, medium or large or extending up to the annulus, i.e. subtotal (Fig. 11.7).

## 4. Middle ear mucosa

It is seen when the perforation is large. Normally, it is pale pink and moist; when inflamed it looks red, oedematous and swollen. Occasionally, a polyp may be seen.

## Investigations

### 1. Examination under microscope

is essential in every case and provides useful information regarding presence of granulations, in-growth of squamous epithelium from the edges of perforation, status of ossicular chain, tympanosclerosis and adhesions. An ear which appears dry may show hidden discharge under the microscope. Rarely, cholesteatoma may co-exist with a central perforation and can be seen under a microscope.

### 2. Audiogram

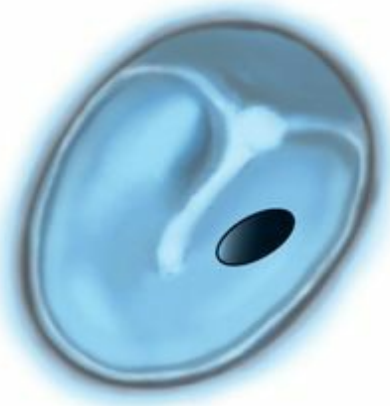It gives an assessment of degree of hearing loss and its type. Usually, the loss is conductive but a sensorineural element may be present.

### 3. Culture and sensitivity of ear discharge

It helps to select proper antibiotic ear drops.

### 4. Mastoid X-rays/CT scan temporal bone

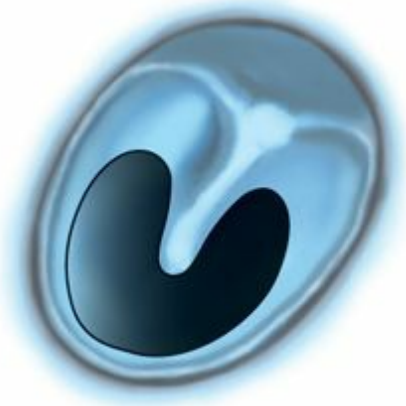Mastoid is usually sclerotic but may be pneumatized with clouding of air cells. There is no evidence of bone destruction. Presence of bone destruction is a feature of atticointral disease.



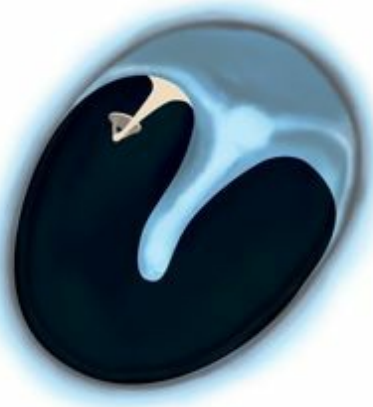Central perforation  
(anterior)



Central perforation  
(medium sized)



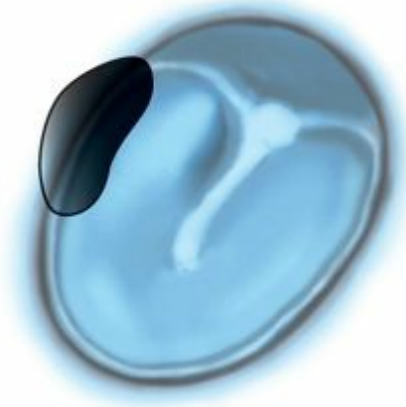Subtotal perforation



Total perforation with  
destruction of even  
the fibrous annulus



Attic perforation



Posterosuperior marginal  
perforation

Dhingra: Diseases of Ear Nose and Throat, 5th Edition  
Copyright © 2010 Elsevier. All rights reserved.

Figure 11.7 Types of perforations in the tympanic membrane seen in CSOM.

## Treatment

The aim is to control infection and eliminate ear discharge and at a later stage, to correct the hearing loss by surgical means.

### 1. Aural toilet

Remove all discharge and debris from the ear. It can be done by dry mopping with absorbent cotton buds, suction clearance under microscope or irrigation (not forceful syringing) with sterile normal saline. Ear must be dried after irrigation.

### 2. Ear drops

Antibiotic ear drops containing neomycin, polymyxin, chloromycetin or gentamicin are used. They are combined with steroids which have local anti-inflammatory effect. To use ear drops, patient lies down with the diseased ear up, antibiotic drops are instilled and then intermittent pressure applied on the tragus for antibiotic solution to reach the middle ear. This should be done three or four times a day. Acid pH helps to eliminate pseudomonas infection, and irrigations with 1.5% acetic acid are useful.

Care should be taken as ear drops are likely to cause maceration of canal skin, local allergy, growth of fungus or resistance of organisms. Some ear drops are potentially ototoxic.

### 3. Systemic antibiotics

They are useful in acute exacerbation of chronically infected ear, otherwise, role of systemic antibiotics in the treatment of CSOM is limited.

### 4. Precautions

Patients are instructed to keep water out of the ear during bathing, swimming and hair wash. Rubber inserts can be used. Hard nose-blowing can also push the infection from nasopharynx to middle ear and should be avoided.

### **5. Treatment of contributory causes**

Attention should be paid to treat concomitantly infected tonsils, adenoids, maxillary antra, and nasal allergy.

### **6. Surgical treatment**

Aural polyp or granulations, if present, should be removed before local treatment with antibiotics. It will facilitate ear toilet and permit ear drops to be used effectively. *An aural polyp should never be avulsed* as it may be arising from the stapes, facial nerve or horizontal canal and thus lead to facial paralysis or labyrinthitis.

### **7. Reconstructive surgery**

Once ear is dry, myringoplasty with or without ossicular reconstruction can be done to restore hearing. Closure of perforation will also check repeated infection from the external canal.

## B. Atticoantral Type

It involves posterosuperior part of middle ear cleft (attic, antrum and posterior tympanum and mastoid) and is associated with cholesteatoma, which, because of its bone eroding properties, causes risk of serious complications. For this reason, the disease is also called *unsafe* or *dangerous* type.

page 80

page 81

### Aetiology

Aetiology of atticoantral disease is same as of cholesteatoma and has been discussed earlier. It is seen in sclerotic mastoid, and whether the latter is the cause or effect of disease is not yet clear.

### Pathology

Atticoantral diseases is associated with the following pathological processes:

#### 1. Cholesteatoma

#### 2. Osteitis and granulation tissue

Osteitis involves outer attic wall and posterosuperior margin of the tympanic ring. A mass of granulation tissue surrounds the area of osteitis and may even fill the attic, antrum, posterior tympanum and mastoid. A fleshy red polypus may be seen filling the meatus.

#### 3. Ossicular necrosis

It is common in atticoantral disease. Destruction may be limited to the long process of incus or may also involve stapes superstructure, handle of malleus or the entire ossicular chain. Therefore, hearing loss is always greater than in disease of tubotympanic type. Occasionally, the cholesteatoma bridges the gap caused by the destroyed ossicles, and hearing loss is not apparent (cholesteatoma hearer).

#### 4. Cholesterol granuloma

It is a mass of granulation tissue with foreign body giant cells surrounding the cholesterol crystals. It is a reaction to long-standing retention of secretions or haemorrhage, and may or may not co-exist with cholesteatoma. When present in the mesotympanum, behind an intact drum, the latter appears blue.

### Bacteriology

Same as in tubotympanic type.

### Symptoms

#### 1. Ear discharge

Usually scanty, but always foul-smelling due to bone destruction. Discharge may be so scanty that the patient may not even be aware of it. Total cessation of discharge from an ear which has been active till recently should be viewed seriously, as perforation in these cases might be sealed by crusted discharge, inflammatory mucosa or a polyp, obstructing the free flow of discharge. Pus, in these cases, may find its way internally and cause complications.

#### 2. Hearing loss

Hearing is normal when ossicular chain is intact or when cholesteatoma, having destroyed the ossicles, bridges the gap caused by destroyed ossicles (*cholesteatoma hearer*). Hearing loss is mostly conductive but sensorineural element may be added.

#### 3. Bleeding

It may occur from granulations or the polyp when cleaning the ear.

### Signs

#### 1. Perforation

It is either attic or posterosuperior marginal type. A small attic perforation may be missed due to presence of a small amount of crusted discharge. Sometimes, the area of perforation is masked by a small granuloma.

#### 2. Retraction pocket

An invagination of tympanic membrane is seen in the attic or posterosuperior area of pars tensa. Degree of retraction and invagination varies. In early stages, pocket is shallow and self-cleansing but later when pocket is deep, it accumulates keratin mass and gets infected.

#### 3. Cholesteatoma



Pearly-white flakes of cholesteatoma can be sucked from the retraction pockets. Suction clearance and examination under operating microscope forms an important part of the clinical examination and assessment of any type of CSOM.

## Investigations

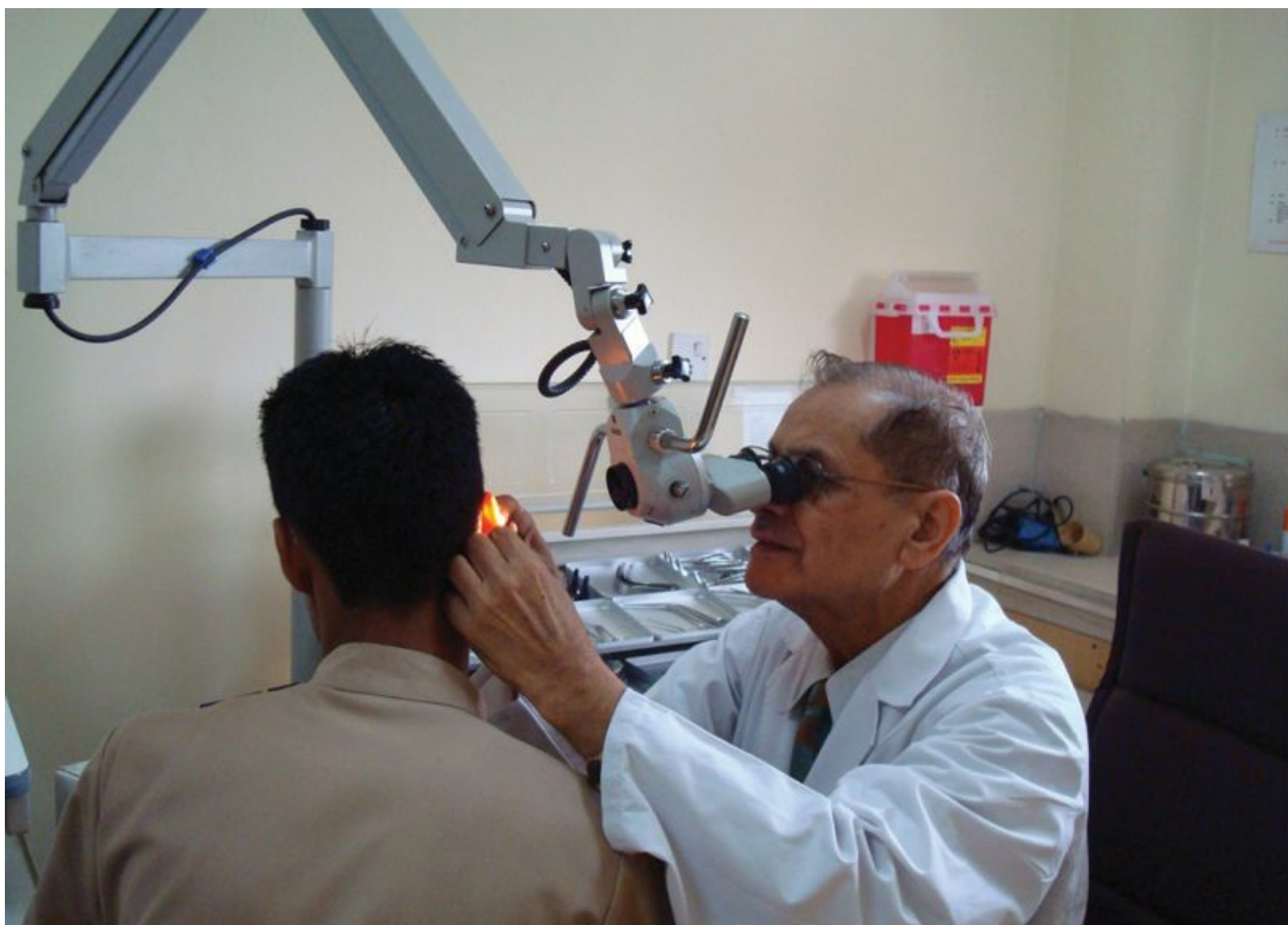### 1. Examination under microscope

All patients of chronic middle early disease should be examined under microscope (Fig. 11.8). It may reveal presence of cholesteatoma, its site and extent, evidence of bone destruction, granuloma, condition of ossicles and pockets of discharge.

### 2. Tuning fork tests and audiogram

They are essential for pre-operative assessment and to confirm the degree and type of hearing loss.

### 3. X-ray mastoids/CT scan temporal bone



Dhingra: Diseases of Ear Nose and Throat, 5th Edition  
Copyright © 2010 Elsevier. All rights reserved.

Figure 11.8 Examination of the ear under microscope (EUM).

They indicate extent of bone destruction and degree of mastoid pneumatisation. They are useful to indicate a low-lying dura or an anteposed sigmoid sinus when operation is being contemplated on a sclerotic mastoid. Cholesteatoma causes destruction in the area of attic and antrum (key area), better seen in lateral view. CT scan of temporal bone gives more information and is preferred to X-ray mastoids.

### 4. Culture and sensitivity of ear discharge

It helps to select proper antibiotic for local or systemic use.

## Features Indicating Complications in CSOM

### 1. Pain

Pain is uncommon in uncomplicated CSOM. Its presence is considered serious as it may indicate extradural, perisinus or brain abscess. Sometimes, it is due to otitis externa associated with a discharging ear.

### 2. Vertigo

It indicates erosion of lateral semicircular canal which may progress to labyrinthitis or meningitis. Fistula test should be performed in all cases.

### 3. Persistent headache

It is suggestive of an intracranial complication.

### 4. Facial weakness

indicates erosion of facial canal.

### 5. A listless child refusing to take feeds

and easily going to sleep (extradural abscess).

### 6. Fever, nausea and vomiting

(intracranial infection).

### 7. Irritability and neck rigidity

(meningitis).

### 8. Diplopia

(Gradenigo's syndrome).

### 9. Ataxia

(labyrinthitis or cerebellar abscess).

### 10. Abscess round the ear

(mastoiditis).

It is not uncommon for a patient of CSOM, residing in a far-flung village, where medical facilities are poor, to go to a doctor for the first time, presenting with complications. It then demands urgent attention and emergency medical or surgical treatment.

## Treatment

### 1. Surgical

It is the mainstay of treatment. Primary aim in surgical treatment is to remove the disease and render the ear safe, and second in priority is to preserve or reconstruct the hearing but never at the cost of the primary aim. Two types of surgical procedures are done to deal with cholesteatoma:

- **(a) Canal wall down procedures.** They leave the mastoid cavity open into the external auditory canal so that the diseased area is fully exteriorised. The commonly performed operations for atticofacial disease are atticotomy, modified radical mastoidectomy and rarely, the radical mastoidectomy (see operative surgery).
- **(b) Canal wall up procedures.** Here disease is removed by combined approach through the meatus and mastoid but retaining the posterior bony meatal wall intact, thereby avoiding an open mastoid cavity. It gives dry ear and permits easy reconstruction of hearing mechanism. However, there is danger of leaving some cholesteatoma behind. Incidence of residual or recurrent cholesteatoma in these cases is very high and therefore long-term follow-up is essential. Some surgeon's even advise routine re-exploration in all cases after 6 months or so. Canal wall up procedures are advised only in selected cases. In combined-approach or intact canal wall mastoidectomy, disease is removed both permeatally, and through cortical mastoidectomy and posterior tympanotomy approach, in which a window is created between the mastoid and middle ear, through the facial recess, to reach sinus tympani (see page 6).

See Table 11.2 for the comparison of canal wall up and canal wall down procedures.

### 2. Reconstructive surgery

Hearing can be restored by myringoplasty or tympanoplasty. It can be done at the time of primary surgery or as a second stage procedure.

**Table 11-2. Comparison of canal wall up and canal wall down procedures**

	<b>Canal wall up procedure</b>	<b>Canal wall down procedure</b>
Meatus	Normal appearance	Widely open meatus communicating with mastoid
Dependence	Does not require routine cleaning	Dependence on doctor for cleaning mastoid cavity once or twice a year
Recurrence or residual disease	High rate of recurrent or residual cholesteatoma	Low rate of recurrence or residual disease and thus a safe procedure
Second look surgery	Requires second look surgery after 6 months or so to rule out cholesteatoma	Not required
Patients limitations	No limitation. Patient allowed swimming	Swimming can lead to infection of mastoid cavity and it is thus curtailed
Auditory rehabilitation	Easy to wear a hearing aid if needed	Problems in fitting a hearing aid due to large meatus and mastoid cavity which sometimes gets infected

page 82

page 83

It has a limited role in the management of cholesteatoma but can be tried in selected cases, when cholesteatoma is small and easily accessible to suction clearance under operating microscope. Repeated suction clearance and periodic check ups are essential. It can also be tried out in elderly patients above 65 and those who are unfit for general anaesthesia or those refusing surgery. Polyps and granulations can also be surgically removed by cup forceps or cauterised by chemical agents like silver nitrate or trichloroacetic acid. Other measures like aural toilet and dry ear precautions are also essential.

# TUBERCULAR OTITIS MEDIA

## Aetiology

In most of the cases, infection is secondary to pulmonary tuberculosis; infection reaches the middle ear through eustachian tube. Sometimes, it is blood-borne from tubercular focus in the lungs, tonsils, cervical or mesenteric lymph nodes. Disease is mostly seen in *children* and *young adults*.

## Pathology

The process is slow and insidious. Tubercles appear in the submucosal layers of middle ear cleft and caseate. There is painless necrosis of tympanic membrane.

Multiple perforations may form which coalesce to form a single large perforation. Middle ear and mastoid get filled with pale granulations. Caries of bone and ossicles may occur leading to complications. Mastoiditis, facial paralysis, postauricular fistula, osteomyelitis with formation of bony sequestra and profound hearing loss are often seen in these cases.

# Clinical Features

## **1. Painless ear discharge**

Earache is characteristically absent in cases of tubercular otitis media. Discharge is often foul-smelling because of the underlying bone destruction.

## **2. Perforation**

Multiple perforations, 2 or 3 in number, are seen in pars tensa and form a classical sign of disease. These may coalesce into a single large perforation then it becomes indistinguishable from non-specific CSOM.

## **3. Hearing loss**

There is severe hearing loss, out of proportion to symptoms. Mostly conductive, it may have sensorineural component due to involvement of labyrinth.

## **4. Facial paralysis**

It is a common complication and may come unexpectedly. This may be the presenting feature in a child.

## Diagnosis

In the presence of secondary pyogenic infection, tubercular otitis media may be indistinguishable from chronic suppurative otitis media. Culture of ear discharge for tubercle bacilli, histopathological examination of granulations and X-ray chest, and other evidence of tuberculosis in the body help to confirm the diagnosis.

# Treatment

## **1. Systemic antitubercular therapy**

as being carried for primary disease.

## **2. Local treatment**

in the form of aural toilet, and control of secondary pyogenic infection.

## **3. Mastoid surgery**

indicated for complications. Healing is delayed in tuberculous cases. Wound break-down and fistula formation are common. Reconstructive surgery of middle ear is delayed till antitubercular therapy has been completed.



## **SYPHILITIC OTITIS MEDIA**

It is a rare condition. Spirochaetes reach middle ear through eustachian tube when syphilitic lesions are present in the nose or nasopharynx. Infection may also be blood-borne. Sensory end organs of the inner ear and their nerve is soon invaded by spirochaetes leading to profound sensorineural hearing loss, tinnitus and vertigo. Bone necrosis and sequestrum formation are common, leading to foetid ear discharge. Secondary pyogenic infection may occur, giving a clinical picture very much like chronic suppurative otitis media.

Definite diagnosis of syphilitic otitis media can only be made by specific treponemal antigen tests such as treponemal pallidum immobilisation (TPI) test and fluorescent treponemal antibody absorption test (FTA-ABS). VDRL and Wasserman tests are nonspecific and may give false positive results.

Treatment consists of antisyphilitic therapy with attention to aural toilet and control of secondary infection. Surgery may be required for removal of sequestra.

## **12 Complications of Suppurative Otitis Media**

Though there is a general decline in the incidence of complications, they are still frequently seen in our country. The causes are poor socio-economic conditions, lack of education and awareness about health care (middle ear discharge is still being considered merely a nuisance rather than a potentially dangerous condition), and lack of availability of trained specialists in the far-flung rural areas where transportation facilities are still inadequate.

# Factors Influencing Development of Complications

## **1. Age**

Most of the complications occur in the first decade of life or in the elderly when the patient's resistance is low.

## **2. Poor socio-economic group**

Several factors such as overcrowding, poor health education and personal hygiene, and limited access to health care play an important part.

## **3. Virulence of organisms**

Many organisms are developing resistance to antibiotics and acute infections are either not controlled or progress to subacute or chronic otitis media. Insufficient dose, less effective drug or insufficient period of administration of antibiotic can cause complications. *Streptococcus pneumoniae* type III (earlier called pneumococcus type III) is very virulent due to production of autolysin and pneumolysin. *H. influenzae* is developing resistance to  $\beta$ -lactam antibiotics and chloramphenicol. Other resistant strains are *Ps. aeruginosa* and methicillin resistant *Staph. aureus*.

## **4. Immune-compromised host**

Patients suffering from AIDS, uncontrolled diabetes, transplant patients receiving immunosuppressive drugs, cancer patients receiving chemotherapy are more prone to develop complications.

## **5. Preformed pathways**

*Infection* can easily travel beyond the middle ear cleft if preformed pathways exist, e.g. dehiscence of bony facial canal, previous ear surgery, fracture of temporal bone, stapedectomy, perilymph fistula or congenitally enlarged aqueduct of vestibule (as in Mondini's abnormality of inner ear) or dehiscence in the floor of middle ear.

## **6. Cholesteatoma**

Osteitis or granulation tissue in chronic otitis media destroy the bone and help infection to penetrate deeper.

In acute and chronic middle ear infection, disease process is limited only to the mucoperiosteal lining of the cleft but if it spreads into the bony walls of the cleft or beyond it, various complications can arise.

# Pathways of Spread of Infection

## **1. Direct bone erosion**

In acute infections, it is the process of hyperaemic decalcification. In chronic infection, it may be osteitis, erosion by cholesteatoma or granulation tissue.

## **2. Venous thrombophlebitis**

Veins of Haversian canals are connected with dural veins which in turn connect with dural venous sinuses and superficial veins of brain. Thus, infection from the mastoid bone can cause thrombophlebitis of venous sinuses and even cortical vein thrombosis. This mode of spread is common in acute infections.

## **3. Preformed pathways**

- **(i)** Congenital dehiscences, e.g. in bony facial canal, floor of middle ear over the jugular bulb.
- **(ii)** Patent sutures, e.g. petrosquamous suture.
- **(iii)** Previous skull fractures. The fracture sites heal only by fibrous scar which permits infection.
- **(iv)** Surgical defects, e.g. stapedectomy, fenestration and mastoidectomy with exposure of dura.
- **(v)** Oval and round windows.
- **(vi)** Infection from labyrinth can travel along internal acoustic meatus, aqueducts of the vestibule and that of the cochlea to the meninges.

# Classification

Complications of otitis media are classified into two main groups (Fig. 12.1):

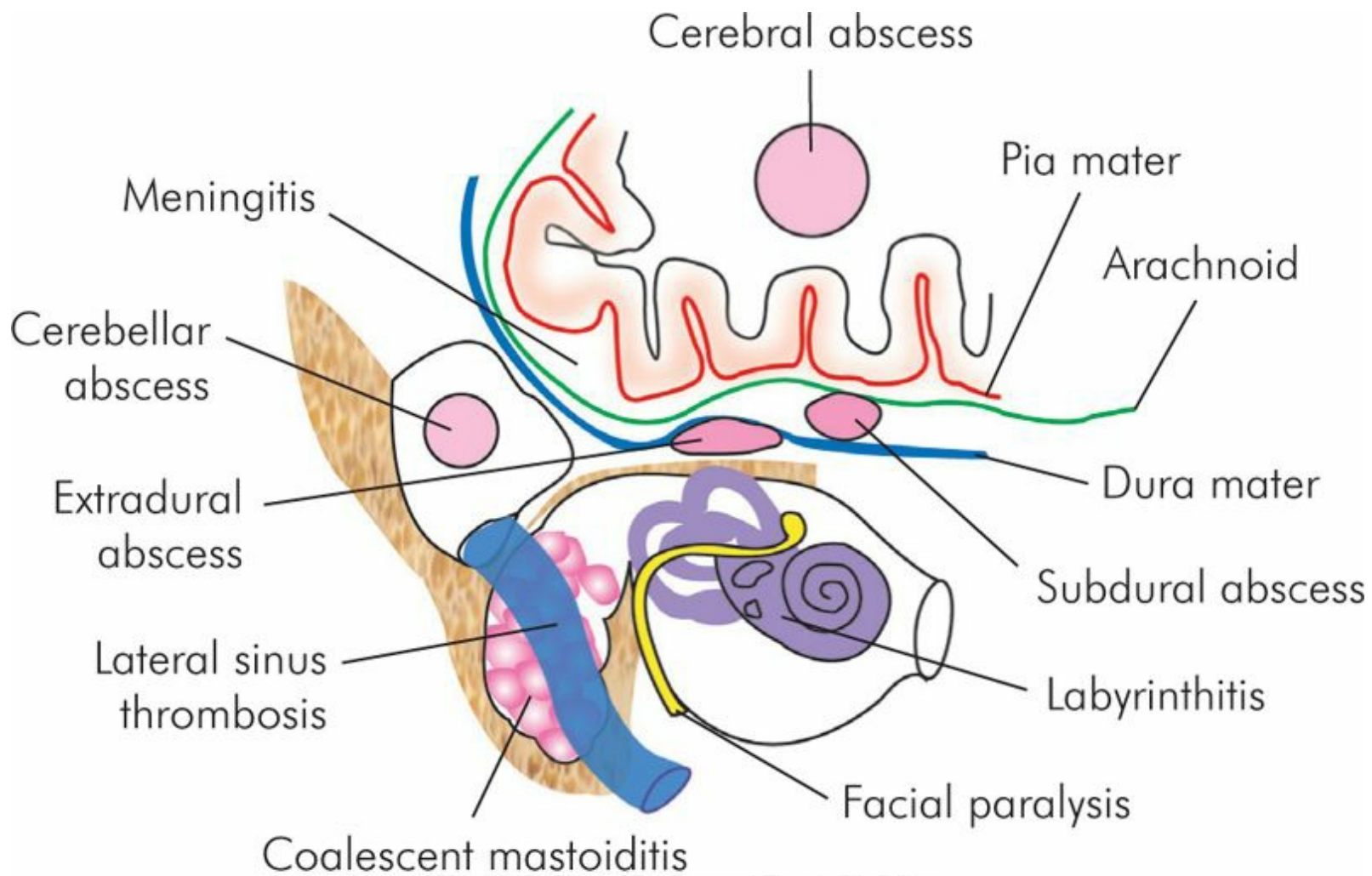
## A. Intratemporal (Within the Confines of Temporal Bone)

- 1. Mastoiditis
- 2. Petrositis
- 3. Facial paralysis
- 4. Labyrinthitis.

## B. Intracranial

- 1. Extradural abscess
- 2. Subdural abscess
- 3. Meningitis
- 4. Brain abscess
- 5. Lateral sinus thrombophlebitis
- 6. Otitic hydrocephalus.

## Sequelae of Otitis Media



Dhingra: Diseases of Ear Nose and Throat, 5th Edition  
Copyright © 2010 Elsevier. All rights reserved.

Figure 12.1 Complications of otitis media.

They are the direct result of middle ear infection and should be differentiated from complications. They include:

- 1. Perforation of tympanic membrane
- 2. Ossicular erosion
- 3. Atelectasis and adhesive otitis media
- 4. Tympanosclerosis
- 5. Cholesteatoma formation
- 6. Conductive hearing loss due to ossicular erosion or fixation
- 7. Sensorineural hearing loss
- 8. Speech impairment
- 9. Learning disabilities

The last two are secondary to loss of hearing in the developmental phase of the infant or child.

## A. INTRATEMPORAL COMPLICATIONS OF OTITIS MEDIA

### 1. (a) Acute Mastoiditis

Inflammation of mucosal lining of antrum and mastoid air cell system is an invariable accompaniment of acute otitis media and forms a part of it. The term "mastoiditis" is used when infection spreads from the mucosa, lining the mastoid air cells, to involve bony walls of the mastoid air cell system.

#### Aetiology

Acute mastoiditis usually accompanies or follows acute suppurative otitis media, the determining factors being high virulence of organisms or lowered resistance of the patient due to measles, exanthematous fevers, poor nutrition or associated systemic disease such as diabetes.

Acute mastoiditis is often seen in mastoids with well-developed air cell system. Children are affected more. Beta-haemolytic streptococcus is the most common causative organism though other organisms responsible for acute otitis media may also be seen. Very often, anaerobic organisms are also associated with mastoiditis and need antibacterial therapy against them.

#### Pathology

Two main pathological processes are responsible:

- 1. Production of pus under tension.
- 2. Hyperaemic decalcification and osteoclastic resorption of bony walls.

Extension of inflammatory process to mucoperiosteal lining of air cell system increases the amount of pus produced due to large surface area involved. Drainage of this pus, through a small perforation of tympanic membrane and/or eustachian tube, cannot keep pace with the amount being produced. Swollen mucosa of the antrum and attic also impede the drainage system resulting in accumulation of pus under tension.

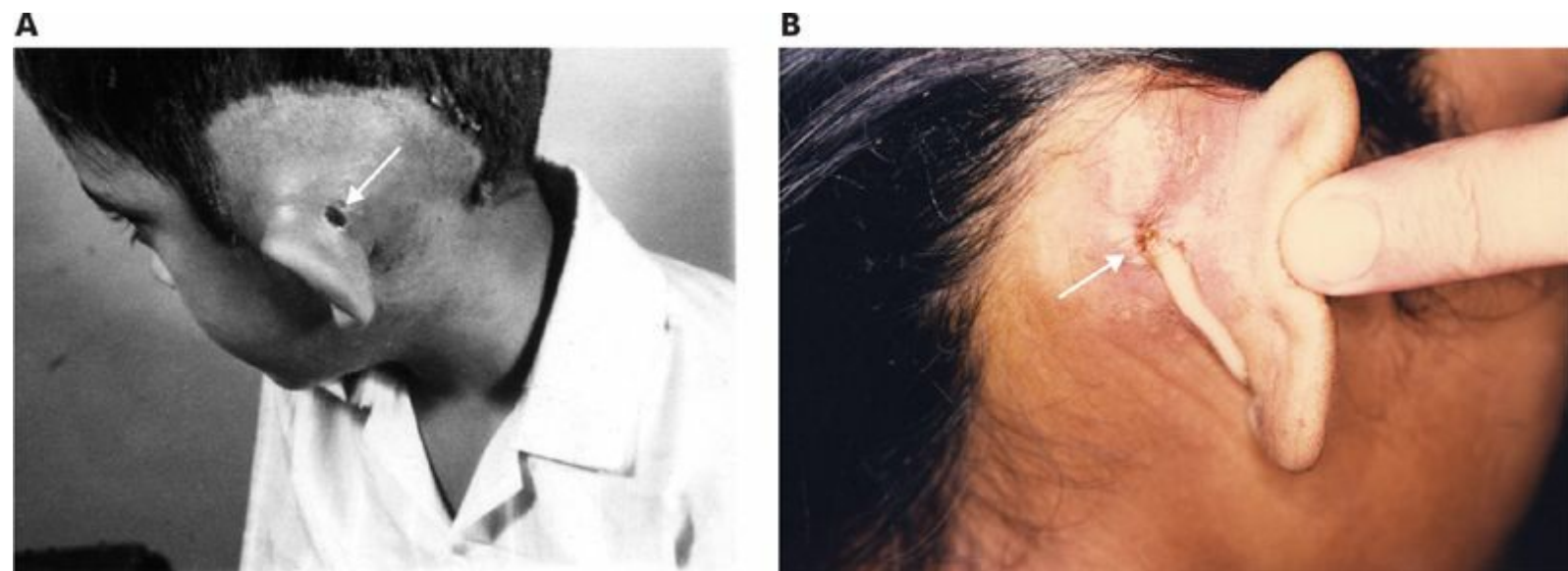
Hyperaemia and engorgement of mucosa causes dissolution of calcium from the bony walls of the mastoid air cells (hyperaemic decalcification).

Both these processes combine to cause destruction and coalescence of mastoid air cells, converting them into a single irregular cavity filled with pus (*Empyema of mastoid*).

Pus may break through mastoid cortex leading to sub-periosteal abscess which may even burst on surface leading to a discharging fistula (Fig. 12.2A,B).

page 85

page 86



Dhingra: Diseases of Ear Nose and Throat, 5th Edition  
Copyright © 2010 Elsevier. All rights reserved.

Figure 12.2 (A), (B) Mastoid fistula.

#### Clinical Features

##### Symptoms

They are similar to that of acute suppurative otitis media. In a case of acute middle ear infection, it is the change in the character of these

symptoms which is significant and a pointer to the development of acute mastoiditis.

- **(i) Pain behind the ear.** Pain is seen in acute otitis media but it subsides with establishment of perforation or treatment with antibiotics. It is the persistence of pain, increase in its intensity or recurrence of pain, once it had subsided. These are significant pointers of pain.
- **(ii) Fever.** It is the persistence or recurrence of fever in a case of acute otitis media, in spite of adequate antibiotic treatment that points to the development of mastoiditis.
- **(iii) Ear discharge.** In mastoiditis, discharge becomes profuse and increases in purulence. In some cases, discharge may cease due to obstruction to its drainage but other symptoms would worsen. Any persistence of discharge beyond three weeks, in a case of acute otitis media, points to mastoiditis.

## Signs

- **(i) Mastoid tenderness.** This is an important sign. Tenderness is elicited by pressure over the middle of mastoid process, at its tip, posterior border or the root of zygoma. Tenderness elicited over the suprameatal triangle may not be diagnostic of acute mastoiditis as it is seen even in cases of the acute otitis media due to inflammation of mastoid antrum (antritis). Tenderness should always be compared with that of the healthy side.
- **(ii) Ear discharge.** Mucopurulent or purulent discharge, often pulsatile (*light-house effect*), may be seen coming through a central perforation of pars tensa.
- **(iii) Sagging of posterosuperior meatal wall.** It is due to periosteitis of bony party wall between the antrum and deeper posterosuperior part of bony canal.
- **(iv) Perforation of tympanic membrane.** Usually, a small perforation is seen in pars tensa with congestion of the rest of tympanic membrane. Perforation may sometimes appear as a nipple-like protrusion. Sometimes, tympanic membrane is intact but dull and opaque especially in those who have received inadequate antibiotics.
- **(v) Swelling over the mastoid.** Initially, there is oedema of periosteum, imparting a smooth "ironed out" feel over the mastoid. Later retroauricular sulcus becomes obliterated and pinna is pushed forward and downwards. When pus bursts through bony cortex, a subperiosteal fluctuant abscess is formed (Fig. 12.3).
- **(vi) Hearing loss.** Conductive type of hearing loss is always present.
- **(vii) General findings.** Patient appears ill and toxic with low-grade fever. In children, fever is high with a rise in pulse rate.

## Investigations

### (a) Blood counts

show polymorphonuclear leucocytosis.

### (b) ESR

is usually raised.

### (c) X-ray mastoid

There is clouding of air cells due to collection of exudate in them. Bony partitions between air cells become indistinct, but the sinus plate is seen as a distinct outline. In later stages, a cavity may be seen in the mastoid.

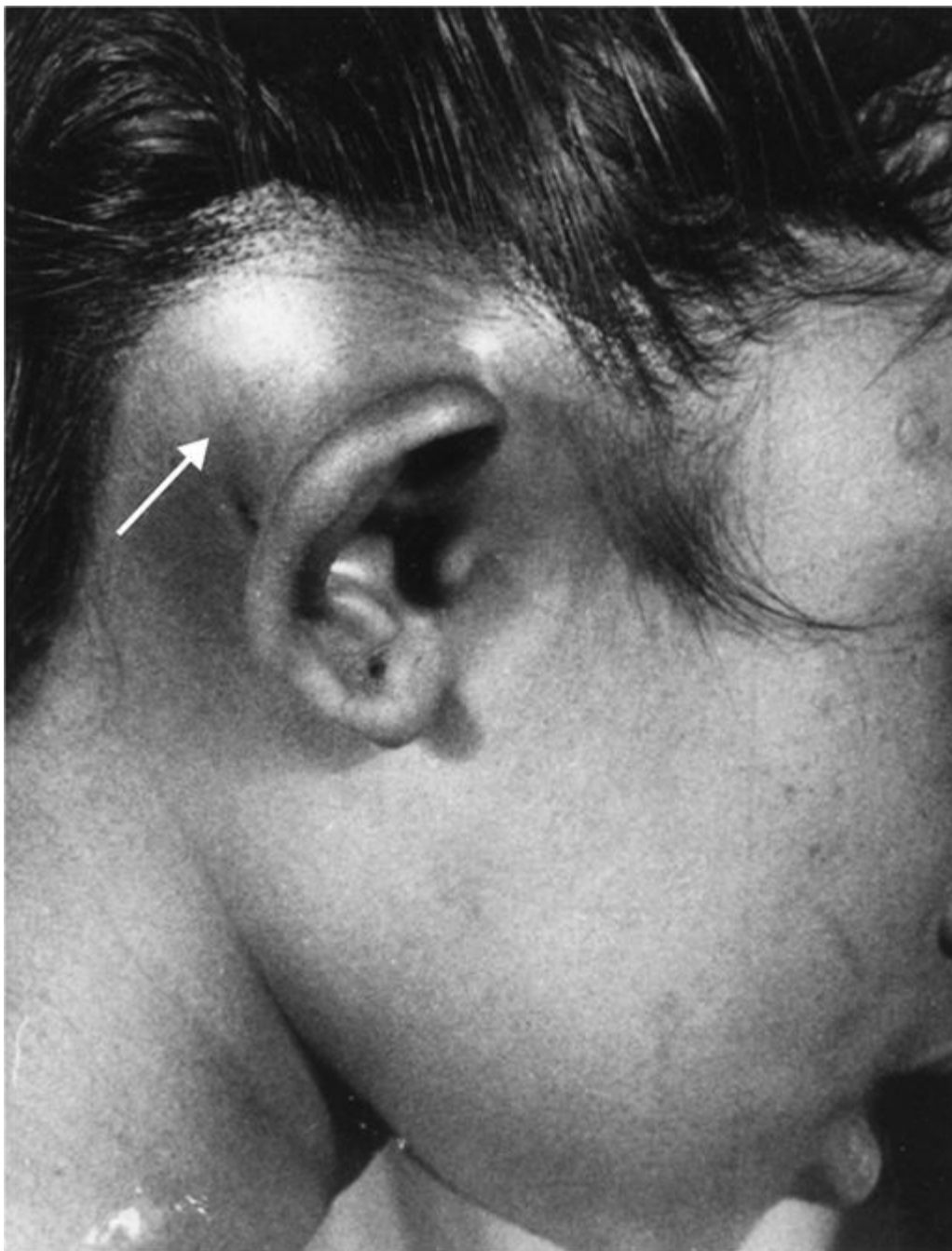### (d) Ear swab

for culture and sensitivity.

## Differential Diagnosis

### (a) Suppuration of mastoid lymph nodes





Dhingra: Diseases of Ear Nose and Throat, 5th Edition  
Copyright © 2010 Elsevier. All rights reserved.

Figure 12.3 Mastoid abscess. Note that pinna is pushed downwards and forwards.

Scalp infection may cause mastoid lymph node enlargement and then suppuration leading to abscess formation, but in such cases there is no history of preceding otitis media, ear discharge or deafness. Abscess is usually superficial.

**(b) Furunculosis of meatus**

It is differentiated from acute mastoiditis by:

- (i) Absence of preceding acute otitis media.
- (ii) Painful movements of pinna; pressure over the tragus or below the cartilaginous part of meatus causes excruciating pain.
- (iii) Swelling of meatus is confined to the cartilaginous part only.
- (iv) Discharge is never mucoid or mucopurulent. Mucoid element in discharge can only come from the middle ear and not from the external ear which is devoid of mucus-secreting glands.
- (v) Enlargement of pre- or postauricular lymph nodes.
- (vi) Conductive hearing loss is usually mild and is due to the occlusion of meatus.
- (vii) An absolutely normal looking tympanic membrane excludes possibility of acute mastoiditis.
- (viii) X-ray mastoid with clear air-cell system excludes acute mastoiditis. Sometimes, difficulty arises when air-cell system appears hazy due to superimposed soft tissue swelling in cases of furunculosis.

**(c) Infected sebaceous cyst**

## Treatment

### **(a) Hospitalisation of the patient**

Patient is hospitalised if not already done.

### **(b) Antibiotics**

In the absence of culture and sensitivity, start with amoxicillin or ampicillin. Specific antimicrobial is started on the receipt of sensitivity report. Since anaerobic organisms are often present, chloramphenicol or metronidazole is added.

### **(c) Myringotomy**

When pus is under tension it is relieved by wide myringotomy (see operative surgery). Early cases of acute mastoiditis respond to conservative treatment with antibiotics alone or combined with myringotomy.

### **(d) Cortical mastoidectomy**

It is indicated when there is:

- **(i)** Subperiosteal abscess.
- **(ii)** Sagging of posterosuperior meatal wall.
- **(iii)** Positive reservoir sign, i.e. meatus immediately fills with pus after it has been mopped out.
- **(iv)** No change in condition of patient or it worsens in spite of adequate medical treatment for 48 hours.
- **(v)** Mastoiditis, leading to complications, e.g. facial paralysis, labyrinthitis, intracranial complications, etc.

Aim of cortical mastoidectomy is to exenterate all the mastoid air cells and remove any pockets of pus. Adequate antibiotic treatment must be continued at least for 5 days following mastoidectomy.

## Complications of Acute Mastoiditis

- 1. Subperiosteal abscess
- 2. Labyrinthitis
- 3. Facial paralysis
- 4. Petrositis
- 5. Extradural abscess
- 6. Subdural abscess
- 7. Meningitis
- 8. Brain abscess
- 9. Lateral sinus thrombophlebitis
- 10. Otitic hydrocephalous.

## Abscesses in Relation to Mastoid Infection

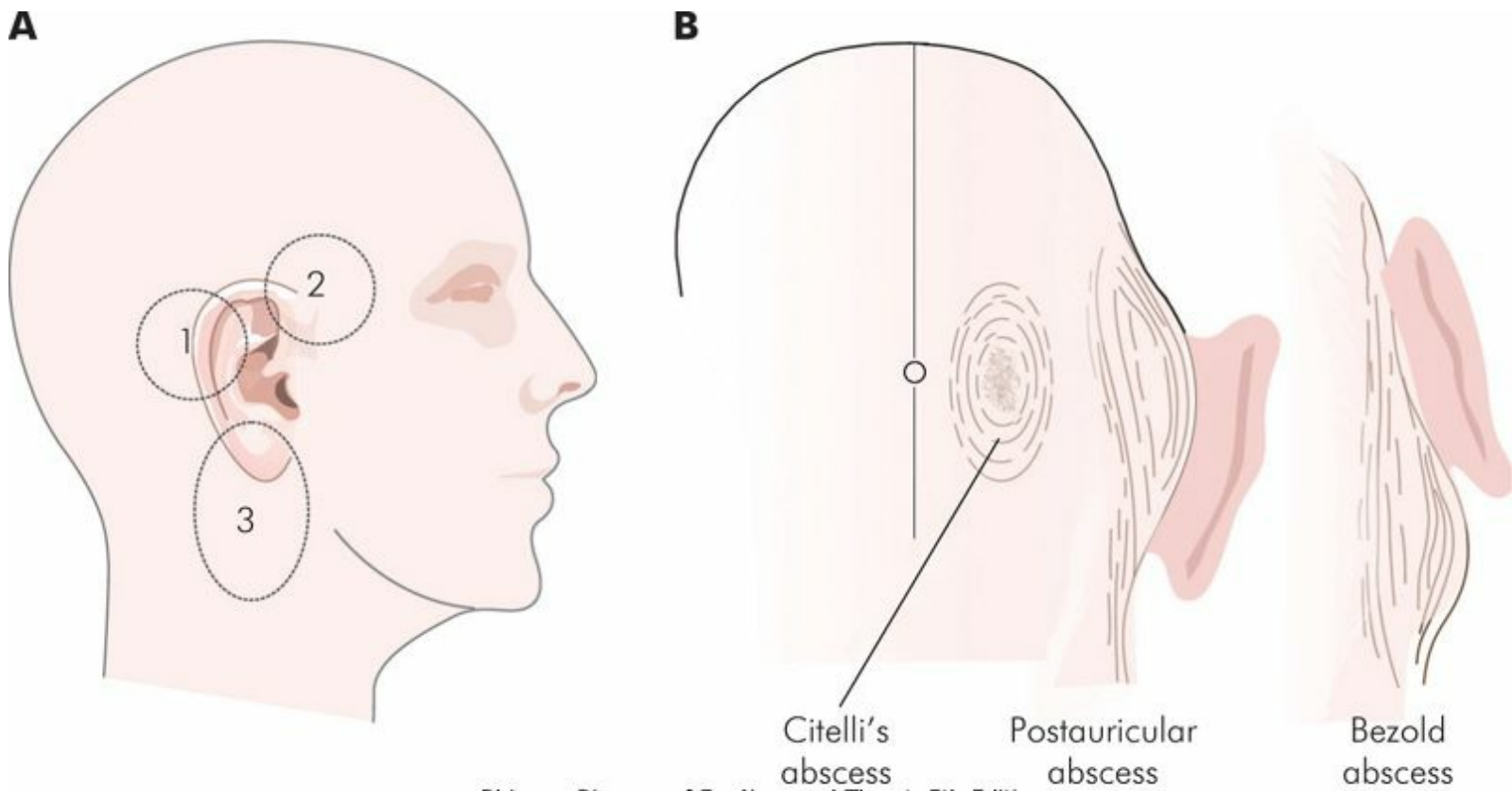
### **(a) Postauricular abscess**

This is the commonest abscess that forms over the mastoid. Pinna is displaced forwards, outwards and downwards. In infants and children, abscess forms over the MacEwen's triangle; pus in these cases travels along the vascular channels of lamina cribrosa.

### **(b) Zygomatic abscess**

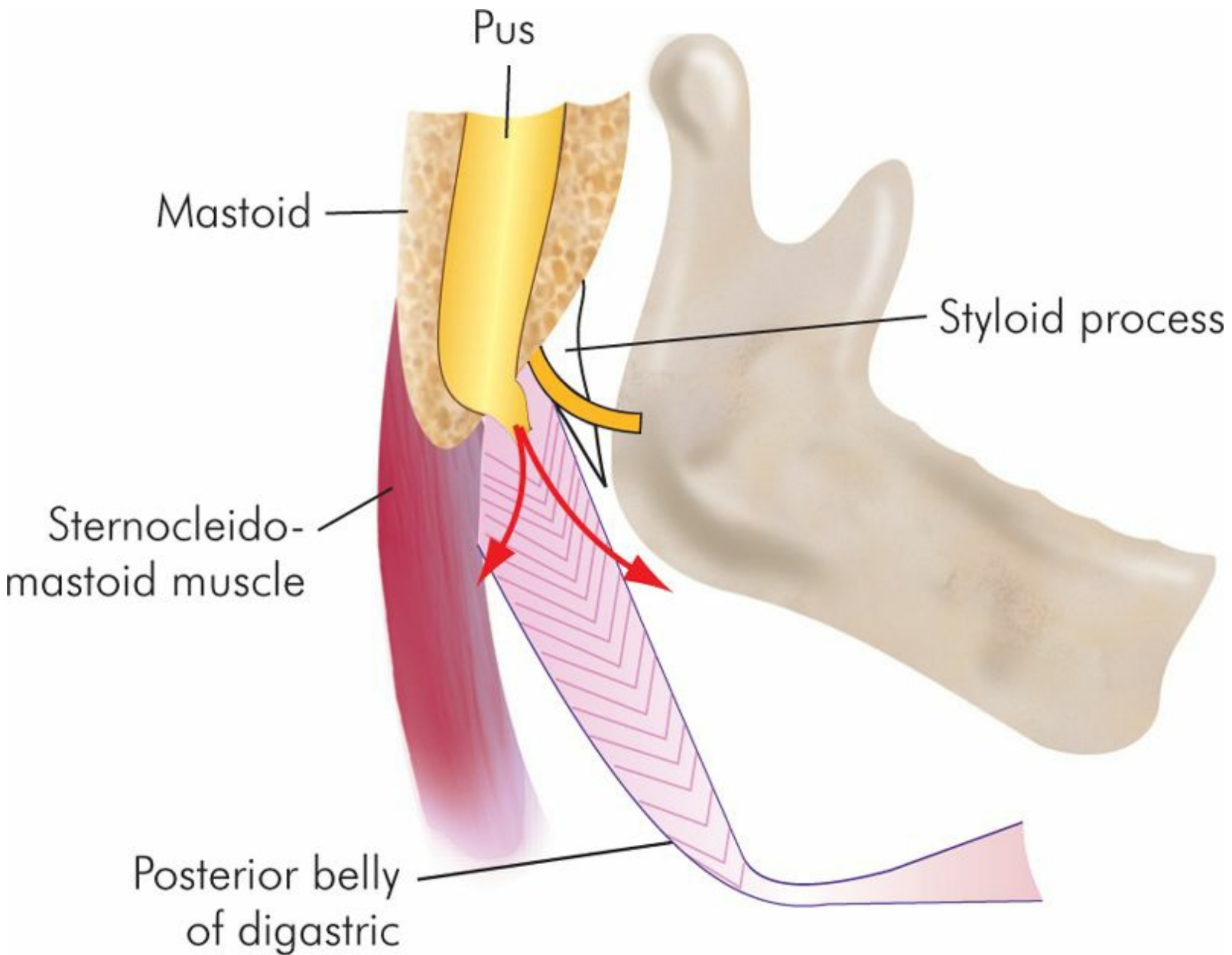
It occurs due to infection of zygomatic air cells situated at the posterior root of zygoma. Swelling appears in front of and above the pinna (Fig. 12.4A,B). There is associated oedema of the upper eyelid. In these cases, pus collects either superficial or deep to the temporalis muscle.

### **(c) Bezold abscess**



Dhingra: Diseases of Ear Nose and Throat, 5th Edition  
 Copyright © 2010 Elsevier. All rights reserved.

Figure 12.4 (A) Abscesses in relation to mastoid. 1. Postauricular, 2. Zygomatic, 3. Bezold abscess. (B) Citelli's, postauricular and Bezold abscesses seen from behind.



Dhingra: Diseases of Ear Nose and Throat, 5th Edition  
Copyright © 2010 Elsevier. All rights reserved.

Figure 12.5 Bezold abscess. Pus bursting through the medial side of the tip of mastoid and collecting under the sternomastoid or digastric triangle.

It can occur following acute coalescent mastoiditis when pus breaks through the thin medial side of the tip of the mastoid and presents as a swelling in the upper part of neck. The abscess may (i) lie deep to sternocleidomastoid, pushing the muscle outwards (ii) follow the posterior belly of digastric and present as a swelling between the tip of mastoid and angle of jaw, (iii) be present in upper part of posterior triangle, (iv) reach the parapharyngeal space or (v) track down along the carotid vessels (Fig. 12.5).

#### **Clinical features**

Onset is sudden. There is pain, fever, a tender swelling in the neck and torticollis. Patient gives history of purulent otorrhoea.

A Bezold abscess should be differentiated from:

- (i) acute upper jugular lymphadenitis.
- (ii) abscess or a mass in the lower part of the parotid gland.
- (iii) an infected branchial cyst.
- (iv) parapharyngeal abscess.
- (v) jugular vein thrombosis.

ACT scan of the mastoid and swelling of the neck may establish the diagnosis.

#### **Treatment**

- (i) Cortical mastoidectomy for coalescent mastoiditis with careful exploration of the tip for a fistulous opening into the soft tissues of the

neck.

- (ii) Drainage of the neck abscess through a separate incision and putting a drain in the dependent part.
- (iii) Administration of intravenous antibiotics guided by the culture and sensitivity report of the pus taken at the time of surgery.

**(d) Meatal abscess (Luc's abscess)**

In this case, pus breaks through the bony wall between the antrum and external osseous meatus. Swelling is seen in deep part of bony meatus. Abscess may burst into the meatus.

**(e) Behind the mastoid (Citelli's abscess)**

Abscess is formed behind the mastoid more towards the occipital bone (compare postauricular mastoid abscess which forms over the mastoid). Some authors consider abscess of the digastric triangle, which is formed by tracking of pus from the mastoid tip, as the Citelli's abscess.

**(f) Parapharyngeal or retropharyngeal abscess**

This results from infection of the peritubal cells due to acute coalescent mastoiditis.

It is a condition of slow destruction of mastoid air cells but without the acute signs and symptoms often seen in acute mastoiditis. There is no pain, no discharge, no fever and no mastoid swelling but mastoidectomy may show extensive destruction of the air cells with granulation tissue and dark gelatinous material filling the mastoid. It is not surprising to find erosion of the tegmen tympani and sinus plate with an extradural or perisinus abscess.

### **Aetiology**

The condition often results from inadequate antibiotic therapy in terms of dose, frequency and duration of administration. Most often it results from use of oral penicillin given in cases of acute otitis media when acute symptoms subside but smouldering infection continues in the mastoid.

### **Clinical Features**

Patient is often a child, not entirely feeling well, with mild pain behind the ear but with persistent hearing loss.

Tympanic membrane appears thick with loss of translucency. Slight tenderness may be elicited over the mastoid. Audiometry shows conductive hearing loss of variable degree. X-ray of mastoid will reveal clouding of air cells with loss of cell outline.

### **Treatment**

Cortical mastoidectomy with full doses of antibiotics is the treatment of choice. This may cause tympanic membrane to return to normal with improvement in hearing.

## 2. Petrositis

Spread of infection from middle ear and mastoid to the petrous part of temporal bone is called petrositis. It may be associated with acute coalescent mastoiditis, latent mastoiditis or chronic middle ear infections.

### Pathology

Like mastoid, petrous bone may be of three types: *pneumatised* with air cells extending to the petrous apex, *diploic* containing only marrow space and *sclerotic*. Pneumatisation of petrous apex occurs in only 30% of cases with cells extending from the middle ear or mastoid to the petrous apex. Usually two cell tracts are recognised:

- **(a)** Posterosuperior tract which starts in the mastoid and runs behind or above the bony labyrinth to the petrous apex; some cells even pass through the arch of superior semicircular canal to reach the apex.
- **(b)** Anteroinferior tract which starts at the hypotympanum near the eustachian tube runs around the cochlea to reach the petrous apex.

Infective process runs along these cell tracts and reaches the petrous apex. Pathological process is similar to that of coalescent mastoiditis forming epidural abscess at the petrous apex involving CN VI and trigeminal ganglion.

### Clinical Features

*Gradenigo's syndrome* is the classical presentation, and consists of a triad of (a) external rectus palsy (VIth nerve palsy), (b) deep-seated ear or retro-orbital pain (Vth nerve involvement) and (c) persistent ear discharge. It is uncommon to see the full triad these days.

Persistent ear discharge with or without deep-seated pain in spite of an adequate cortical or modified radical mastoidectomy also points to petrositis.

Fever, headache, vomiting and sometimes neck rigidity may also be associated. Some patients may get facial paralysis and recurrent vertigo due to involvement of facial and statoacoustic nerves.

Diagnosis of petrous apicitis requires both CT scan and MRI. CT scan of temporal bone will show bony details of the petrous apex and the air cells while MRI helps to differentiate diploic marrow containing apex from fluid or pus.

### Treatment

Cortical, modified radical or radical mastoidectomy is often required if not already done. The fistulous tract should be found out, which is then curetted and enlarged to provide free drainage. Tract of posterosuperior cells starts in the Trautmann's triangle or the attic. Tract of anterior cells is situated near the tympanic opening of eustachian tube and passes above the carotid artery, anterior to the cochlea. In the latter case, radical mastoidectomy is required.

Suitable intravenous antibacterial therapy should precede and follow surgical intervention. Most cases of acute petrositis can now be cured with antibacterial therapy alone. It should be given in initial high doses and continued for 4-5 days, even after complete disappearance of symptoms.

### 3. Facial Paralysis

It can occur as a complication of both acute and chronic otitis media.

#### Acute Otitis Media

page 89

page 90

Facial nerve is normally well protected in its bony canal. Sometimes, the bony canal is dehiscant, and the nerve lies just under the middle ear mucosa. It is in these cases that inflammation of middle ear spreads to epi- and perineurium, causing facial paralysis. Facial nerve function fully recovers if acute otitis media is controlled with systemic antibiotics. Myringotomy or cortical mastoidectomy may sometimes be required.

#### Chronic Otitis Media

Facial paralysis in chronic otitis media either results from cholesteatoma or from penetrating granulation tissue. Cholesteatoma destroys bony canal and then causes pressure on the nerve, further aided by oedema of associated inflammatory process. Facial paralysis is insidious but slowly progressive. Treatment is urgent exploration of the middle ear and mastoid. Facial canal is inspected from the geniculate ganglion to the stylomastoid foramen. If granulation tissue or cholesteatoma has entered the bony canal, the latter is uncapped in the area of involvement. Granulation tissue surrounding the nerve is removed but if it actually invades the nerve sheath, it is left in place. If a segment of the nerve has been destroyed by the granulation tissue, resection of nerve and grafting are better left to a second stage when infection has been controlled and fibrosis has matured.



## 4. Labyrinthitis

There are three types of labyrinthitis:

- (a) Circumscribed labyrinthitis
- (b) Diffuse serous labyrinthitis
- (c) Diffuse suppurative labyrinthitis

### Circumscribed Labyrinthitis (Fistula of Labyrinth)

There is thinning or erosion of bony capsule of labyrinth, usually of the horizontal semicircular canal.

#### **Aetiology**

The causes are:

- (a) Chronic suppurative otitis media with cholesteatoma is the most common cause.
- (b) Neoplasms of middle ear, e.g. carcinoma or glomus tumour.
- (c) Surgical or accidental trauma to labyrinth.

#### **Clinical features**

A part of membranous labyrinth is exposed and becomes sensitive to pressure changes. Patient complains of transient vertigo often induced by pressure on tragus, cleaning the ear or while performing Valsalva manoeuvre.

It is diagnosed by "fistula test" which can be performed in two ways.

- (a) *Pressure on tragus*. Sudden inward pressure is applied on the tragus. This increases air pressure in the ear canal and stimulates the labyrinth. Patient will complain of vertigo. Nystagmus may also be induced with quick component towards the ear under test.
- (b) *Siegle's speculum*. When positive pressure is applied to ear canal, patient complains of vertigo usually with nystagmus. The quick component of nystagmus would be towards the affected ear (ampullopetal displacement of cupula).

Ampullopetal flow of endolymph (as also ampullopetal displacement of cupula) whether in rotation, caloric or fistula test causes nystagmus to same side.

If negative pressure is applied, again it would induce vertigo and nystagmus but this time the quick component of nystagmus would be directed to the (opposite) healthy side due to ampullofugal displacement of cupula.

#### **Treatment**

In chronic suppurative otitis media or cholesteatoma, mastoid exploration is often required to eliminate the cause. Systemic antibiotic therapy should be instituted before and after operation to prevent spread of infection into the labyrinth.

### Diffuse Serous Labyrinthitis

It is diffuse intralabyrinthine inflammation without pus formation and is a reversible condition if treated early.

#### **Aetiology**

- (a) Most often it arises from pre-existing circumscribed labyrinthitis associated with chronic middle ear suppuration or cholesteatoma.
- (b) In acute infections of middle ear, cleft inflammation spreads through annular ligament or the round window.
- (c) It can follow stapedectomy or fenestration operation.

#### **Clinical features**

Mild cases complain of vertigo and nausea but in severe cases, vertigo is worse with marked nausea, vomiting and even spontaneous nystagmus. Quick component of nystagmus is towards the affected ear.

As the inflammation is diffuse, cochlea is also affected with some degree of sensorineural hearing loss.

Serous labyrinthitis, if not checked, may pass onto suppurative labyrinthitis with total loss of vestibular and cochlear function.

#### **Treatment**

*Medical.*

- **(a)** Patient is put to bed, his head immobilised with affected ear above.
- **(b)** Antibacterial therapy is given in full doses to control infection.
- **(c)** Labyrinthine sedatives, e.g. prochlorperazine (Stemetil) or dimenhydrinate (Dramamine), are given for symptomatic relief of vertigo.
- **(d)** Myringotomy is done if labyrinthitis has followed acute otitis media and the drum is bulging. Pus is cultured for specific antibacterial therapy.

*Surgical.* Cortical mastoidectomy (in acute mastoiditis) or modified radical mastoidectomy (in chronic middle ear infection or cholesteatoma) will often be required to treat the source of infection. Medical treatment should always precede surgical intervention.

## **Diffuse Suppurative Labyrinthitis**

This is diffuse pyogenic infection of the labyrinth with permanent loss of vestibular and cochlear functions.

### ***Aetiology***

It usually follows serous labyrinthitis, pyogenic organisms entering through a pathological or surgical fistula.

### ***Clinical features***

There is severe vertigo with nausea and vomiting due to acute vestibular failure. Spontaneous nystagmus will be observed with its quick component towards the healthy side. Patient is markedly toxic. There is total loss of hearing. Relief from vertigo is seen after 3-6 weeks due to adaptation.

### ***Treatment***

It is same as for serous labyrinthitis. Rarely, drainage of the labyrinth is required, if intralabyrinthine suppuration is acting as a source of intracranial complications, e.g. meningitis or brain abscess.

## **B. INTRACRANIAL COMPLICATIONS OF OTITIS MEDIA**

### **1. Extradural Abscess**

It is collection of pus between the bone and dura. It may occur both in acute and chronic infections of middle ear.

#### **Pathology**

In acute otitis media, bone over the dura is destroyed by hyperaemic decalcification, while in chronic otitis media it is destroyed by cholesteatoma and in such a case the pus comes to lie directly in contact with dura. Spread of infection can also occur by venous thrombophlebitis; in this case, bone over the dura remains intact. An extradural abscess may lie in relation to dura of middle or posterior cranial fossa or outside the dura of lateral venous sinus (perisinus abscess). The affected dura may be covered with granulations or appear unhealthy and discoloured.

#### **Clinical Features**

Most of the time, extradural or perisinus abscesses are asymptomatic and silent, and are discovered accidentally during cortical or modified radical mastoidectomy.

However, their presence is suspected when there is:

- **(i)** Persistent headache on the side of otitis media.
- **(ii)** Severe pain in the ear.
- **(iii)** General malaise with low-grade fever.
- **(iv)** Pulsatile purulent ear discharge.
- **(v)** Disappearance of headache with free flow of pus from the ear (spontaneous abscess drainage).

Diagnosis is made on contrast-enhanced CT or MRI.

#### **Treatment**

##### ***(a) Cortical or modified radical or radical mastoidectomy***

It is often required to deal with the causative disease process. Extradural abscess is evacuated by removing overlying bone till the limits of healthy dura are reached. Cases where bony plate of tegmen tympani or sinus plate is intact but there is suspicion of an abscess, the intact bony plate is deliberately removed to evacuate any collection of pus.

##### ***(b) An antibiotic cover***

should be provided for a minimum of 5 days and patient closely observed for any further complications, such as sinus thrombosis, meningitis or brain abscess.

## 2. Subdural Abscess

This is collection of pus between dura and arachnoid.

### Pathology

Infection spreads from the ear by erosion of bone and dura or by thrombophlebitic process in which case intervening bone remains intact. Pus rapidly spreads in subdural space and comes to lie against the convex surface of cerebral hemisphere causing pressure symptoms. With time, the pus may get loculated at various places in subdural space.

### Clinical Features

Signs and symptoms of subdural abscess are due to (a) meningeal irritation, (b) thrombophlebitis of cortical veins of cerebrum, (c) raised intracranial tension.

#### **(a) Meningeal irritation**

There is headache, fever (102°F or more), malaise, increasing drowsiness, neck rigidity and positive Kernig's sign.

#### **(b) Cortical venous thrombophlebitis**

Veins over the cerebral hemisphere undergo thrombophlebitis leading to aphasia, hemiplegia, hemianopia. There may be Jacksonian type of epileptic fits which may increase to give a picture of status epilepticus.

#### **(c) Raised intracranial tension**

There is papilloedema, ptosis and dilated pupil (IIIrd nerve involvement), and involvement of other cranial nerves. CT scan or MRI are required for diagnosis.

### Treatment

Lumbar puncture should not be done as it can cause herniation of the cerebellar tonsils. It is a neurological emergency. A series of burr holes or a craniotomy is done to drain subdural empyema. Intravenous antibiotics are administered to control infection. Once infection is under control, attention is paid to causative ear disease which may require mastoidectomy.

### 3. Meningitis

It is inflammation of leptomeninges (pia and arachnoid) usually with bacterial invasion of CSF in subarachnoid space. It is the most common intracranial complication of otitis media. It can occur in both acute and chronic otitis media. In infants and children, otogenic meningitis usually follows acute otitis media while in adults it is due to chronic middle ear infection.

#### Mode of infection

Blood-borne infection is common in infants and children; in adults, it follows chronic ear disease, which spreads by bone erosion or retrograde thrombophlebitis. In the latter case it may be associated with an extradural abscess or granulation tissue.

In one-third of the patients with meningitis, another intracranial complication may coexist.

#### Clinical Features

Symptoms and signs of meningitis are due to (a) presence of infection, (b) raised intracranial tension and (c) meningeal and cerebral irritation. Their severity will vary with the extent of disease.

- (i) There is rise in temperature (102-104°F) often with chills and rigors.
- (ii) Headache.
- (iii) Neck rigidity.
- (iv) Photophobia and mental irritability.
- (v) Nausea and vomiting (sometimes projectile).
- (vi) Drowsiness which may progress to delirium or coma.
- (vii) Cranial nerve palsies and hemiplegia.

Examination will show: (i) neck rigidity, (ii) positive Kernig's sign (extension of leg with thigh flexed on abdomen causing pain), (iii) positive Brudzinski's sign (flexion of neck causes flexion of hip and knee), (iv) tendon reflexes are exaggerated initially but later become sluggish or absent, (v) papilloedema (usually seen in late stages).

#### Diagnosis

CT or MRI with contrast will help to make the diagnosis. It may also reveal another associated intracranial lesion.

Lumbar puncture and CSF examination establish the diagnosis. CSF is turbid, cell count is raised and may even reach 1000/ml with predominance of polymorphs; protein level is raised, sugar is reduced and chlorides are diminished.

CSF is always cultured to find the causative organisms and their antibiotic sensitivity.

#### Treatment

##### *Medical*

Medical treatment takes precedence over surgery.

Antimicrobial therapy directed against aerobic and anaerobic organisms should be instituted. Culture and sensitivity of CSF will further aid in the choice of antibiotics.

Corticosteroids combined with antibiotic therapy further helps to reduce neurological or audiological complications.

##### *Surgical*

Meningitis following acute otitis media may require myringotomy or cortical mastoidectomy. Meningitis following chronic otitis media with cholesteatoma will require radical or modified radical mastoidectomy.

Surgery is undertaken as soon as general condition of patient permits. It may be done urgently, if there has been no satisfactory response to medical treatment.

## 4. Otogenic Brain Abscess

Fifty percent of brain abscesses in adults and 25% in children are otogenic in origin. In adults, abscess usually follows chronic suppurative otitis media with cholesteatoma, while in children, it is usually the result of acute otitis media. Cerebral abscess is seen twice as frequently as cerebellar abscess.

### Route of Infection

Cerebral abscess develops as a result of direct extension of middle ear infection through the tegmen or by retrograde thrombophlebitis, in which case the tegmen will be intact. Often it is associated with extradural abscess.

Cerebellar abscess also develops as a direct extension through the Trautmann's triangle or by retrograde thrombophlebitis. This is often associated with extradural abscess, perisinus abscess, sigmoid sinus thrombophlebitis or labyrinthitis.

### Bacteriology

Both aerobic and anaerobic organisms are seen. Aerobic ones include pyogenic staphylococci, *Strep. pneumoniae*, *Strep. haemolyticus*, *Proteus mirabilis*, *Esch. coli* and *Ps. aeruginosa*. Common among the anaerobic ones are the *Peptostreptococcus* and *Bacteroides fragilis*. *H. influenzae* is rarely seen.

### Pathology

Brain abscess develops through four stages.

page 92

page 93

#### (a) Stage of invasion (initial encephalitis)

It often passes unnoticed as symptoms are slight. Patient may have headache, low-grade fever, malaise and drowsiness.

#### (b) Stage of localisation (latent abscess)

There are no symptoms during this stage. Nature tries to localise the pus by formation of a capsule. The stage may last for several weeks.

#### (c) Stage of enlargement (manifest abscess)

Abscess begins to enlarge. A zone of oedema appears round the abscess and is responsible for aggravation of symptoms. Clinical features at this stage are due to:

- (i) Raised intracranial tension.
- (ii) Disturbance of function in the cerebrum or cerebellum, causing focal symptoms and signs.

#### (d) Stage of termination (rupture of abscess)

An expanding abscess in the white matter of brain ruptures into the ventricle or subarachnoid space resulting in fatal meningitis.

### Clinical Features

Brain abscess is often associated with other complications, such as extradural abscess, perisinus abscess, meningitis, sinus thrombosis and labyrinthitis, and thus the clinical picture may be overlapping.

Clinical features can be divided into:

- (i) those due to raised intracranial tension,
- (ii) those due to area of brain affected. They are the localising features.

#### (a) Symptoms and signs of raised intracranial tension

- (i) *Headache*. Often severe and generalised, worse in the morning.
- (ii) *Nausea and vomiting*. The latter is usually projectile. Seen more often in cerebellar lesions.
- (iii) *Level of consciousness*. Lethargy, which progresses to drowsiness, confusion, stupor and finally coma.
- (iv) *Papilloedema* is absent in early cases. Appears late when raised intracranial tension has persisted for 2-3 weeks. Appears early in cerebellar abscess.
- (v) *Slow pulse and subnormal temperature*.

#### (b) Localising features

## Temporal lobe abscess

- (i) *Nominal aphasia*. If abscess involves dominant hemisphere, i.e. left hemisphere in right-handed persons, patient fails to tell the names of common objects such as key, pen, etc. but can demonstrate their use.
- (ii) *Homonymous hemianopia*. This is due to pressure on the optic radiations. Visual field, opposite to the side of lesion, is lost. It can be elicited by confrontation test, by standing in front of the patient and comparing his visual field with that of the examiner, or by perimetry. The defect is usually in the upper, but sometimes in the lower quadrants.
- (iii) *Contralateral motor paralysis*. In the usual upward spread of abscess, face is involved first followed by the arm and leg. Inward spread, towards internal capsule, involves the leg first followed by the arm and the face.
- (iv) *Epileptic fits*. Involvement of uncinate gyrus causes hallucinations of taste, and small and involuntary smacking movements of lips and tongue. Generalised fits may occur.
- (v) *Pupillary changes and oculomotor palsy*. It indicates transtentorial herniation.

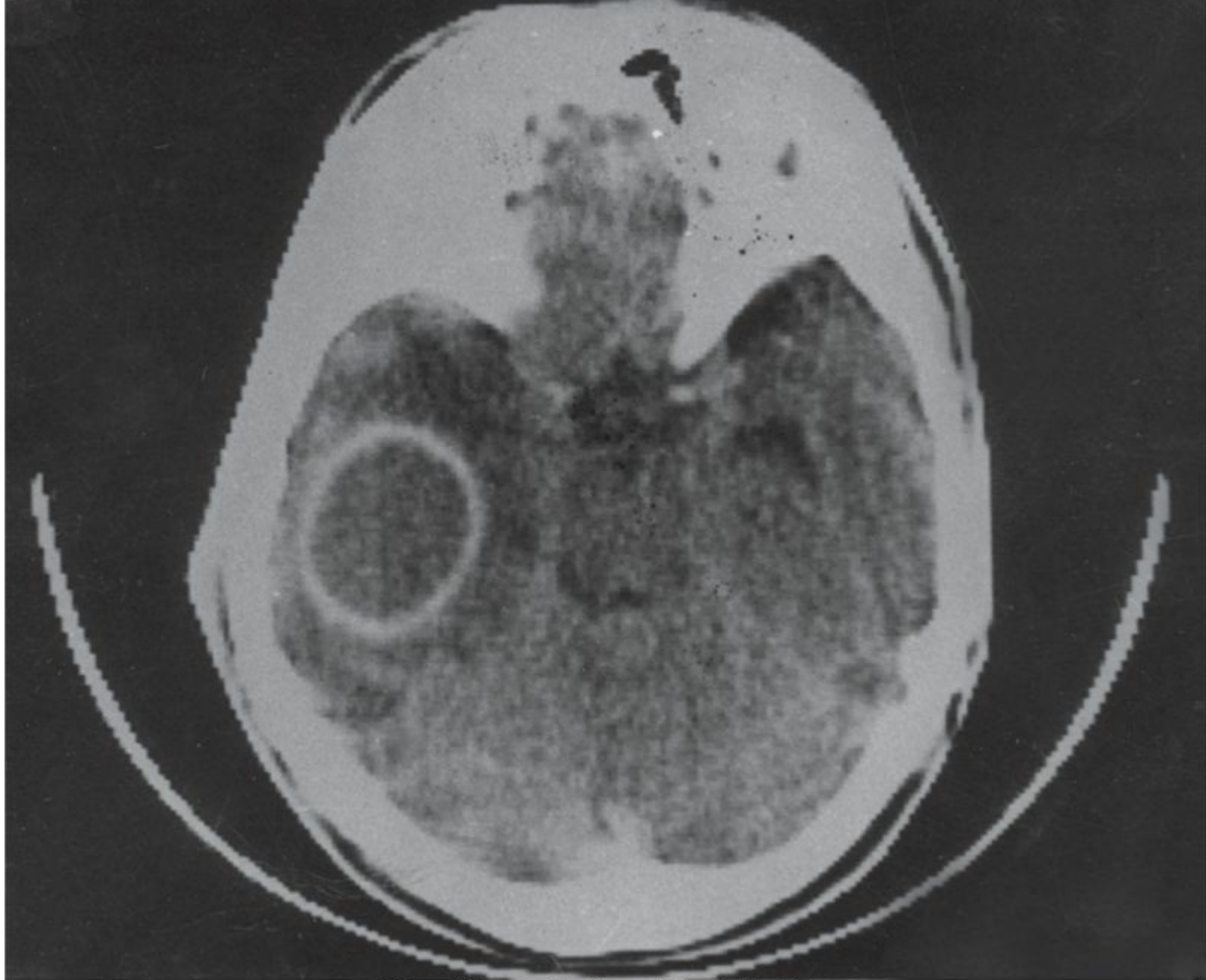## Cerebellar abscess (Fig. 12.6)

- (i) *Headache* involves suboccipital region and may be associated with neck rigidity.
- (ii) *Spontaneous nystagmus* is common and irregular and generally to the side of lesion.
- (iii) *Ipsilateral hypotonia and weakness*.
- (iv) *Ipsilateral ataxia*. Patient staggers to the side of lesion.
- (v) *Past-pointing and intention tremor* can be elicited by finger nose test.
- (vi) *Dysidiadokokinesia*. Rapid pronation and supination of the forearm shows slow and irregular movements on the affected side.

## Investigations

### (a) Skull X-rays

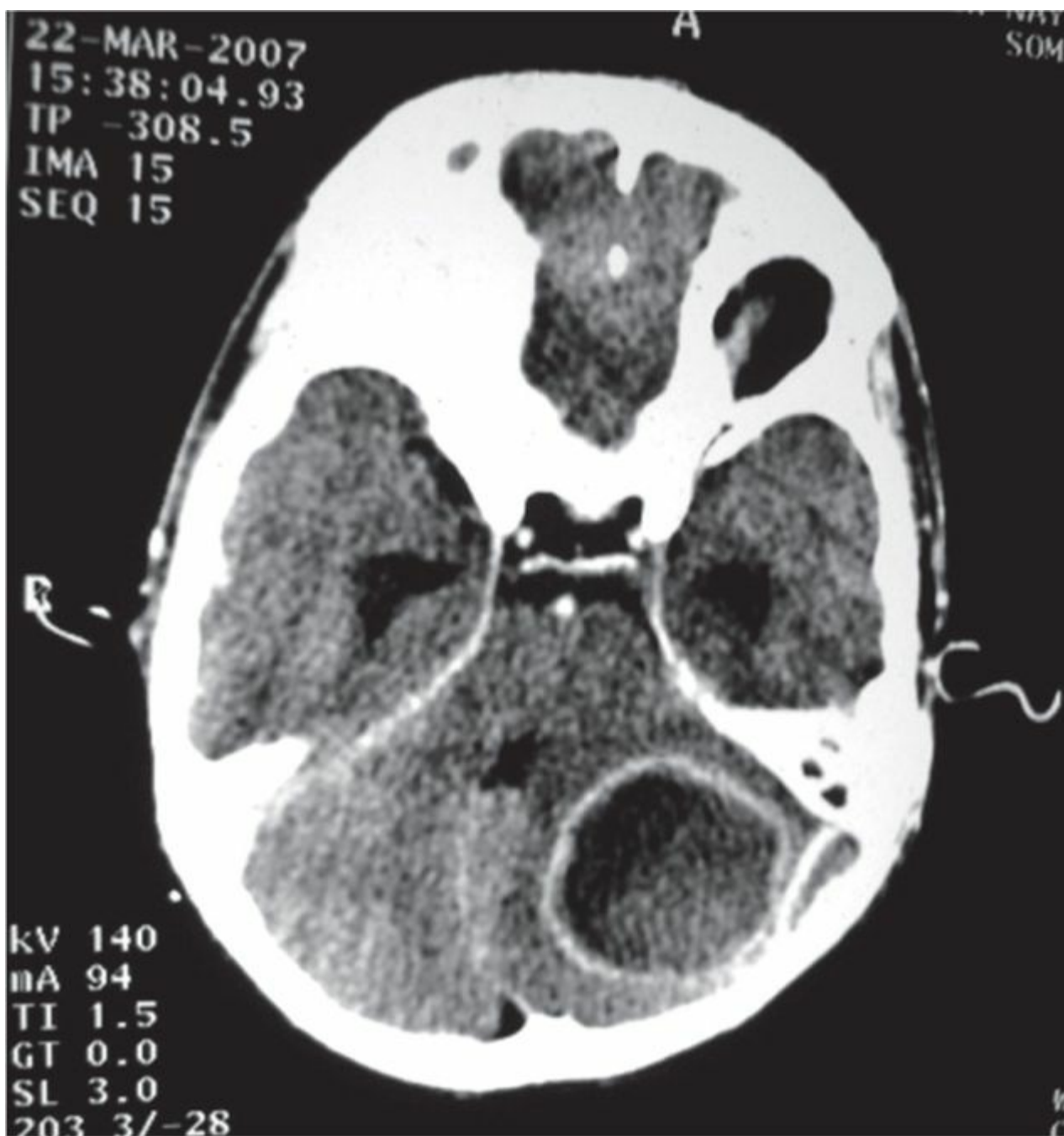are useful to see midline shift, if pineal gland is calcified, and also reveals gas in the abscess cavity.



Dhingra: Diseases of Ear Nose and Throat, 5th Edition  
Copyright © 2010 Elsevier. All rights reserved.

Figure 12.6 CT scan of right-sided otogenic cerebral abscess.





Dhingra: Diseases of Ear Nose and Throat, 5th Edition  
Copyright © 2010 Elsevier. All rights reserved.

Figure 12.7 CT scan showing left-sided cerebellar abscess.

**(b) CT scan**

is the single most important means of investigation and helps to find the site and size of an abscess (Fig. 12.7). It also reveals associated complications such as extradural abscess, sigmoid sinus thrombosis, etc. MRI has further improved the diagnosis.

**(c) X-ray mastoids or CT scan**

of the temporal bone for evaluation of associated ear disease.

**(d) Lumbar puncture**

Great care should be exercised while doing lumbar puncture because of the risk of coning. CSF will show some rise in pressure, increase in protein content but normal glucose level. White cell count of CSF is raised but is much less than seen in cases of meningitis. CSF contains polymorphs or lymphocytes depending on the acuteness of lesion.

**Treatment**

**Medical**

High doses of antibiotics are given parenterally. As the infection is often mixed, antibiotics may be combined. Chloramphenicol and third generation cephalosporins are usually effective. *Bacteroides fragilis*, an obligate anaerobe, often seen in brain abscess, responds to

metronidazole. Aminoglycoside antibiotics, e.g. gentamicin, may be required if infection suspected is pseudomonas or proteus. Culture of discharge from the ear may be helpful in the choice of antibiotic.

Raised intracranial tension can be lowered by dexamethasone, 4 mg i.v. 6 hourly or mannitol 20% in doses of 0.5 g/kg body weight.

Discharge from the ear should be treated by suction clearance and use of topical ear drops.

### ***Neurosurgical***

Abscess is approached through a sterile field. Options include: (i) repeated aspiration through a burr hole, (ii) excision of abscess, (iii) open incision of the abscess and evacuation of pus. The choice of surgical procedure is left to the judgement of the neurosurgeon. If abscess is treated by aspiration, it should be followed by repeat CT or MRI scans to see if it diminishes in size. An expanding abscess, or one that does not decrease in size, may require excision. Pus recovered from the abscess should be cultured and its sensitivity discovered. Penicillin can be instilled into the abscess after aspiration.

### ***Otologic***

Associated ear disease which caused the brain abscess needs attention. Acute otitis media might have resolved with the antibiotics given for the abscess. Chronic otitis media would require radical mastoidectomy to remove the irreversible disease and to exteriorise the infected area. Surgery of the ear is undertaken only after the abscess has been controlled by antibiotics and neurosurgical treatment.

## 5. Lateral Sinus Thrombophlebitis (Syn. Sigmoid Sinus Thrombosis)

It is an inflammation of inner wall of lateral venous sinus with formation of a thrombus.

### Aetiology

It occurs as a complication of acute coalescent mastoiditis, masked mastoiditis or chronic suppuration of middle ear and cholesteatoma.

### Pathology

The pathological process can be divided into the following stages:

#### (a) Formation of perisinus abscess

Abscess forms in relation to outer dural wall of the sinus. Overlying bony dural plate may have been destroyed by coalescent bone erosion or cholesteatoma. Sometimes, it remains intact when route of infection was by thrombophlebitic process.

#### (b) Endophlebitis and mural thrombus formation

Inflammation spreads to inner wall of the venous sinus with deposition of fibrin, platelets, and blood cells leading to thrombus formation within the lumen of sinus.

#### (c) Obliteration of sinus lumen and intrasinus abscess

Mural thrombus enlarges to occlude the sinus lumen completely. Organisms may invade the thrombus causing intrasinus abscess which may release infected emboli into the blood stream causing septicaemia.

#### (d) Extension of thrombus

Though central part of thrombus breaks down due to intrasinus abscess, thrombotic process continues both proximally and distally. Proximally, it may spread to confluence of sinuses and to superior sagittal sinus or cavernous sinus, and distally, into mastoid emissary vein, to jugular bulb or jugular vein.

page 94

page 95

### Bacteriology

In acute infections, haemolytic *streptococcus*, *pneumococcus* or *staphylococcus* are common. These days, majority of cases of thrombophlebitis are seen in chronic infection with cholesteatomas, and the organisms found are *B. proteus*, *Ps. pyocyaneus*, *Esch. coli* and *staphylococci*.

### Clinical Features

#### (a) Hectic Picket-fence type of fever with rigors

This is due to septicaemia, often coinciding with release of septic emboli into blood stream. Fever is irregular having one or more peaks a day. It is usually accompanied by chills and rigors. Profuse sweating follows fall of temperature. Clinical picture resembles malaria but lacks regularity.

In between the bouts of fever, patient is alert with a sense of well-being. Patients receiving antibiotics may not show this picture.

#### (b) Headache

In early stage, it may be due to perisinus abscess and is mild. Later, it may be severe when intracranial pressure rises due to venous obstruction.

#### (c) Progressive anaemia and emaciation

#### (d) Griesinger's sign

This is due to thrombosis of mastoid emissary vein. Oedema appears over the posterior part of mastoid.

#### (e) Papilloedema

Its presence depends on obstruction to venous return. It is often seen when right sinus (which is larger than left) is thrombosed or when clot extends to superior sagittal sinus. Fundus may show blurring of disc margins, retinal haemorrhages or dilated veins. Fundus changes may be absent when collateral circulation is good.

#### (f) Tobey-Ayer test

This is to record CSF pressure by manometer and to see the effect of manual compression of one or both jugular veins.

Compression of vein on the thrombosed side produces no effect while compression of vein on healthy side produces rapid rise in CSF pressure

which will be equal to bilateral compression of jugular veins.

#### **(g) Crowe-Beck test**

Pressure on jugular vein of healthy side produces engorgement of retinal veins (seen by ophthalmoscopy) and supraorbital veins. Engorgement of veins subside on release of pressure.

#### **(h) Tenderness along jugular vein**

This is seen when thrombophlebitis extends along the jugular vein. There may be associated enlargement and inflammation of jugular chain of lymph nodes and torticollis.

### **Investigations**

#### **(a) Blood smear**

is done to rule out malaria.

#### **(b) Blood culture**

is done to find causative organisms. Culture should be taken at the time of chill when organisms enter the blood stream. Repeated cultures may be required to identify the organisms.

#### **(c) CSF examination-CSF**

is normal except for rise in pressure. It also helps to exclude meningitis.

#### **(d) X-ray mastoids**

may show clouding of air cells (acute mastoiditis) or destruction of bone (cholesteatoma).

#### **(e) Imaging studies**

Contrast-enhanced CT scan can show sinus thrombosis by typical *delta sign*. It is a triangular area with rim enhancement, and central low density area is seen in posterior cranial fossa on axial cuts. MR imaging better delineates thrombus. "Delta sign" may also be seen on contrast-enhanced MRI. MR venography is useful to assess progression or resolution of thrombus.

#### **(f) Culture and sensitivity**

of ear swab.

### **Complications**

- 1. Septicaemia and pyaemic abscesses in lung, bone, joints or subcutaneous tissue.
- 2. Meningitis and subdural abscess.
- 3. Cerebellar abscess.
- 4. Thrombosis of jugular bulb and jugular vein with involvement of IXth, Xth and XIth cranial nerves.
- 5. Cavernous sinus thrombosis. There would be chemosis, proptosis, fixation of eyeball and papilloedema.
- 6. Otitic hydrocephalus, when thrombus extends to sagittal sinus via confluens of sinuses.

### **Treatment**

#### **(a) Intravenous antibacterial therapy**

Choice of antibiotic will depend on sensitivity of organism and tolerance of the patient. Antibiotic can be changed after culture and sensitivity report is available. Antibiotics should be continued at least for a week after the operation, which is invariably required.

#### **(b) Mastoidectomy and exposure of sinus**

A complete cortical or modified radical mastoidectomy is performed, depending on whether sinus thrombosis has complicated acute or chronic middle ear disease. Sinus bony plate is removed to expose the dura and drain the perisinus abscess.

An infected clot or intrasinus abscess may be present and must be drained. In such cases, sinus dura is already destroyed or may appear unhealthy and discoloured with granulations on its surface. Dura is incised and the infected clot and abscess drained. Before incision in the dura, sinus is packed, above and below, by inserting a pack between the bone and dura of sinus to control bleeding.

Healthy red clot beyond the abscess at either end of sinus should not be disturbed. Pack is removed 5-6 days post-operatively and wound secondarily closed.

***(c) Ligation of internal jugular vein***

It is rarely required these days. It is indicated when antibiotic and surgical treatment have failed to control embolic phenomenon and rigors, or tenderness and swelling along jugular vein is spreading.

***(d) Anticoagulant therapy***

It is rarely required and used when thrombosis is extending to cavernous sinus.

***(e) Supportive treatment***

Repeated blood transfusions may be required to combat anaemia and improve patient's resistance.

## 6. Otitic Hydrocephalus

It is characterised by raised intracranial pressure with normal CSF findings. It is seen in children and adolescents with acute or chronic middle ear infections.

### Mechanism

Lateral sinus thrombosis accompanying middle ear infection causes obstruction to venous return. If thrombosis extends to superior sagittal sinus, it will also impede the function of arachnoid villi to absorb CSF. Both these factors result in raised intracranial tension.

### Clinical Features

#### *Symptoms*

- (a) Severe headache, sometimes intermittent, is the presenting feature. It may be accompanied by nausea and vomiting.
- (b) Diplopia due to paralysis of VIth cranial nerve.
- (c) Blurring of vision due to papilloedema or optic atrophy.

#### *Signs*

- (a) Papilloedema may be 5-6 diopters, sometimes with patches of exudates and haemorrhages.
- (b) Nystagmus due to raised intracranial tension.
- (c) Lumbar puncture. CSF pressure exceeds 300 mm of water (normal 70-120 mm H<sub>2</sub>O). It is otherwise normal in cell, protein and sugar content and is bacteriologically sterile.

### Treatment

The aim is to reduce CSF pressure to prevent optic atrophy and blindness. This is achieved medically by acetazolamide and corticosteroids and repeated lumbar puncture or placement of a lumbar drain. Sometimes, draining CSF into the peritoneal cavity (lumboperitoneal shunt) is necessary.

Middle ear infection may require antibiotic therapy and mastoid exploration to deal with sinus thrombosis.

## 13 Otosclerosis (Syn. Otospongiosis)

### Anatomy

It may be pertinent to review the anatomy of the labyrinth and introduce the terminology often used to describe it:

- **(i) Otic labyrinth** Also called membranous labyrinth or endolymphatic labyrinth. It consists of utricle, saccule, cochlea, semicircular ducts, endolymphatic duct and sac. It is filled with endolymph.
- **(ii) Periotic labyrinth or perilymphatic labyrinth (or space)** It surrounds the otic labyrinth and is filled with perilymph. It includes vestibule, scala tympani, scala vestibuli, perilymphatic space of semicircular canals and the periotic duct, which surrounds the endolymphatic duct of otic labyrinth.
- **(iii) Otic capsule** It is the bony labyrinth. It has three layers.

*Endosteal.* The innermost layer. It lines the bony labyrinth.

*Enchondral.* Develops from the cartilage and later ossifies into bone. It is in this layer that some islands of cartilage are left unossified that later give rise to otosclerosis.

*Periosteal.* Covers the bony labyrinth.

Otic capsule or the bony labyrinth ossifies from 14 centres, the first one appears in the region of cochlea at 16 weeks and the last one appears in the posterolateral part of posterior semicircular canal at 20th week.

Otosclerosis, more aptly called *otospongiosis*, is a primary disease of the bony labyrinth. In this, one or more foci of irregularly laid spongy bone replace part of normally dense enchondral layer of bony otic capsule. Most often, otosclerotic focus involves the stapes region leading to stapes fixation and conductive deafness. However, it may involve certain other areas of the bony labyrinth where it may cause neurosensory loss, or no symptoms at all.

## Aetiology

The exact cause of *otosclerosis* is not known; however the following facts have been documented.

**Anatomical basis.** Bony labyrinth is made of enchondral bone which is subject to little change in life. But sometimes, in this hard bone, there are areas of cartilage rests which due to certain non-specific factors, are activated to form a new spongy bone. One such area is the *fissula ante fenestram* lying in front of the oval window-the site of predilection for stapedial type of otospongiosis.

**Heredity.** About 50% of otosclerotics have positive family history; rest are sporadic. Genetic studies reveal that it is an autosomal dominant trait with incomplete penetrance and a variable expressivity.

**Race.** White races are affected more than Negros. It is common in Indians but rare among Chinese and Japanese.

**Sex.** Females are affected twice as often as males but in our country, otosclerosis seems to predominate in males.

**Age of onset.** Deafness usually starts between 20 and 30 years of age and is rare before 10 and after 40 years.

**Effect of other factors.** Deafness due to otosclerosis may be initiated or made worse by pregnancy. Similarly, deafness may increase during menopause, after an accident or a major operation.

The disease may be associated with *osteogenesis imperfecta* with history of multiple fractures. The triad of symptoms of osteogenesis imperfecta, otosclerosis and blue sclera, is called *van der Hoeve syndrome*. Lesions of otic capsule seen in osteogenesis imperfecta are histologically indistinguishable from those of otosclerosis and both are due to genes encoding type I collagen.

**Viral infection.** Electron microscopic and immunohistochemical studies have shown RNA related to measles virus. It is likely that otosclerosis is a viral disease as has been suggested for Paget's disease.



# Types of Otosclerosis

## 1. Stapedial otosclerosis

page 97

page 98

Stapedial otosclerosis causing stapes fixation and conductive deafness is the most common variety. Here lesion starts just in front of the oval window in an area called 'fissula ante fenestram'. This is the site of predilection (*anterior focus*). Lesion may start behind the oval window (*posterior focus*), around the margin of the stapes footplate (*circumferential*), in the footplate but annular ligament being free (*biscuit type*). Sometimes, it may completely obliterate the oval window niche (*obliterative type*) (Fig. 13.1).

## 2. Cochlear otosclerosis

Cochlear otosclerosis involves region of round window or other areas in the otic capsule, and may cause sensorineural hearing loss probably due to liberation of toxic materials into the inner ear fluid.

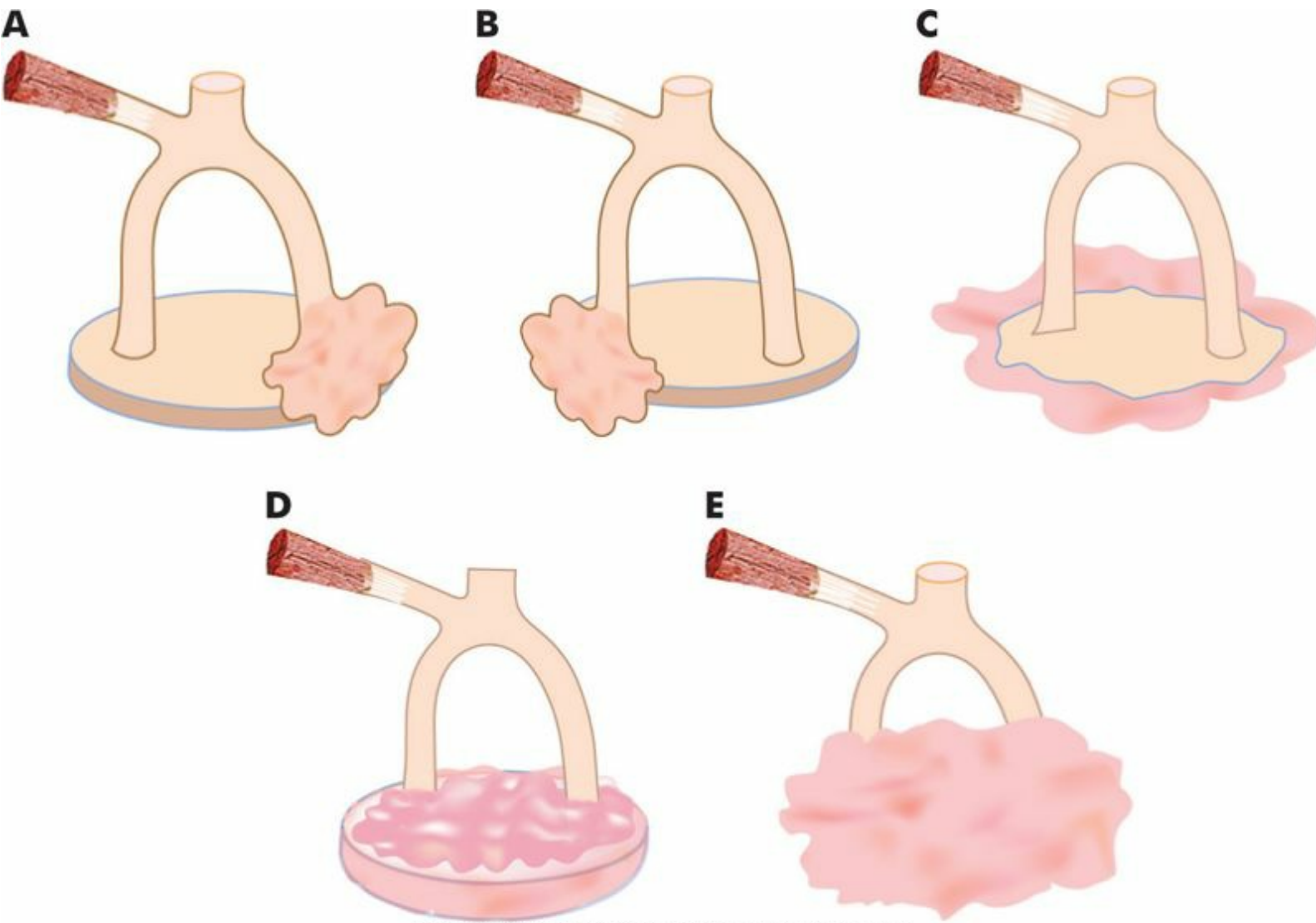
## 3. Histologic otosclerosis

This type of otosclerosis remains asymptomatic and causes neither conductive nor sensorineural hearing loss.

# Pathology

Grossly, otosclerotic lesion appears chalky white, greyish or yellow. Sometimes, it is red in colour due to increased vascularity, in which case, the otosclerotic focus is active and rapidly progressive.

Microscopically, spongy bone appears in the normally dense enchondral layer of otic capsule. In immature active lesions, there are numerous marrow and vascular spaces with plenty of osteoblasts and osteoclasts and a lot of cement substance which stains blue (blue mantles) with haematoxylin-eosin stain. Mature foci show less vascularity and laying of more bone and more of fibrillar substance than cementum, and is stained red.



Dhingra: Diseases of Ear Nose and Throat, 5th Edition  
Copyright © 2010 Elsevier. All rights reserved.

Figure 13.1 Types of stapedial otosclerosis. (A) Anterior focus. (B) Posterior focus. (C) Circumferential. (D) Biscuit type (thick plate). (E) Obliterative.

# Symptoms

## **1. Hearing loss**

This is the presenting symptom and usually starts in twenties. It is painless and progressive with insidious onset. Often it is bilateral conductive type.

## **2. Paracusis willisii**

An otosclerotic patient hears better in noisy than quiet surroundings. This is because a normal person will raise his voice in noisy surroundings.

## **3. Tinnitus**

It is more commonly seen in cochlear otosclerosis and in active lesions.

## **4. Vertigo**

It is an uncommon symptom.

## **5. Speech**

Patient has a monotonous, well modulated soft speech.

- **1.** Tympanic membrane is quite normal and mobile. Sometimes, a reddish hue may be seen on the promontory through the tympanic membrane (*Schwartz sign*). This is indicative of active focus with increased vascularity.
- **2.** Eustachian tube function is normal.
- **3.** Tuning fork tests show negative Rinne (i.e. BC > AC) first for 256 Hz and then 512 Hz and still later, when stapes fixation is complete, for 1026 Hz. Weber test will be lateralised to the ear with greater conductive loss. Absolute bone conduction may be normal. It is decreased in cochlear otosclerosis with sensorineural loss.

*Pure tone audiometry* shows loss of air conduction, more for lower frequencies.

Bone conduction is normal. In some cases, there is a dip in bone conduction curve. It is different at different frequencies but maximum at 2000 Hz and is called the *Carhart's notch*. (5 dB at 500 Hz, 10 dB at 1000 Hz, 15 dB at 2000 Hz and 5 dB at 4000 Hz) (Fig. 13.2). Carhart's notch disappears after successful stapedectomy.

Mixed hearing loss is not uncommon in otosclerosis. There is loss in bone conduction with air-bone gap.

Speech audiometry reveals normal discrimination score except in those with cochlear involvement.

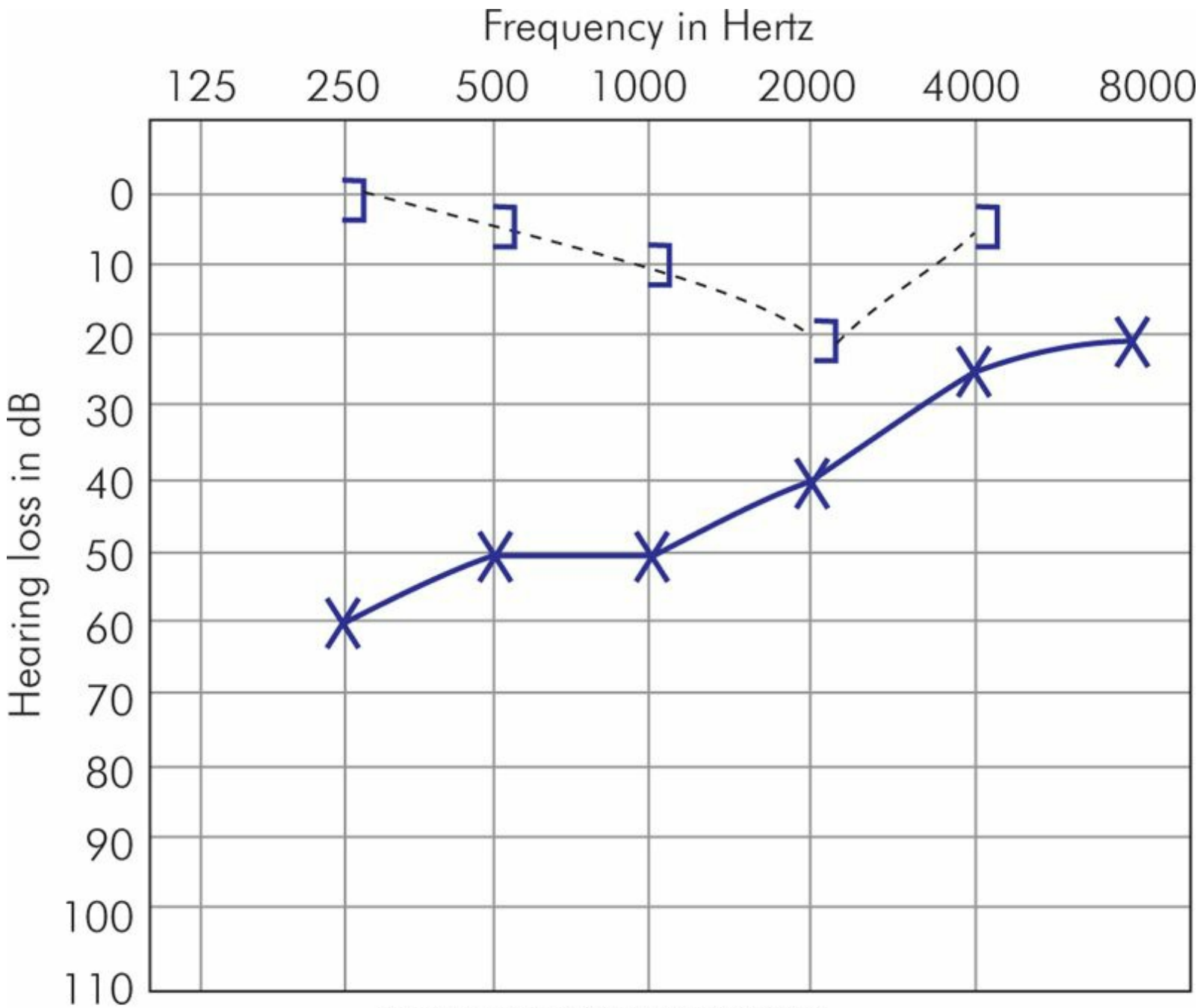
Tympanometry may be normal in early cases but later shows a curve of ossicular stiffness. Stapedial reflex becomes absent when stapes is fixed (see page 29).

## Differential Diagnosis

Otosclerosis should be differentiated from other causes of conductive deafness particularly serous otitis media, adhesive otitis media, tympanosclerosis, attic fixation of head of malleus, ossicular discontinuity or congenital stapes fixation.

# Treatment

## Medical



Dhingra: Diseases of Ear Nose and Throat, 5th Edition  
Copyright © 2010 Elsevier. All rights reserved.

Figure 13.2 Otosclerosis left ear. Note dip at 2000 Hz in bone conduction (Carhart's notch).

There is no medical treatment that cures otosclerosis. Sodium fluoride has been tried to hasten the maturity of active focus and arrest further cochlear loss, but controversies exist and this treatment is not recommended generally.

## Surgical

*Stapedectomy* with a placement of prosthesis is the treatment of choice. Here the fixed otosclerotic stapes is removed and a prosthesis inserted between the incus and oval window (Fig. 13.3). Prosthesis employed may be a teflon piston, stainless steel piston, platinum teflon or titanium teflon piston (Fig. 13.4). In 90% of patients, there is good improvement in hearing after stapedectomy.

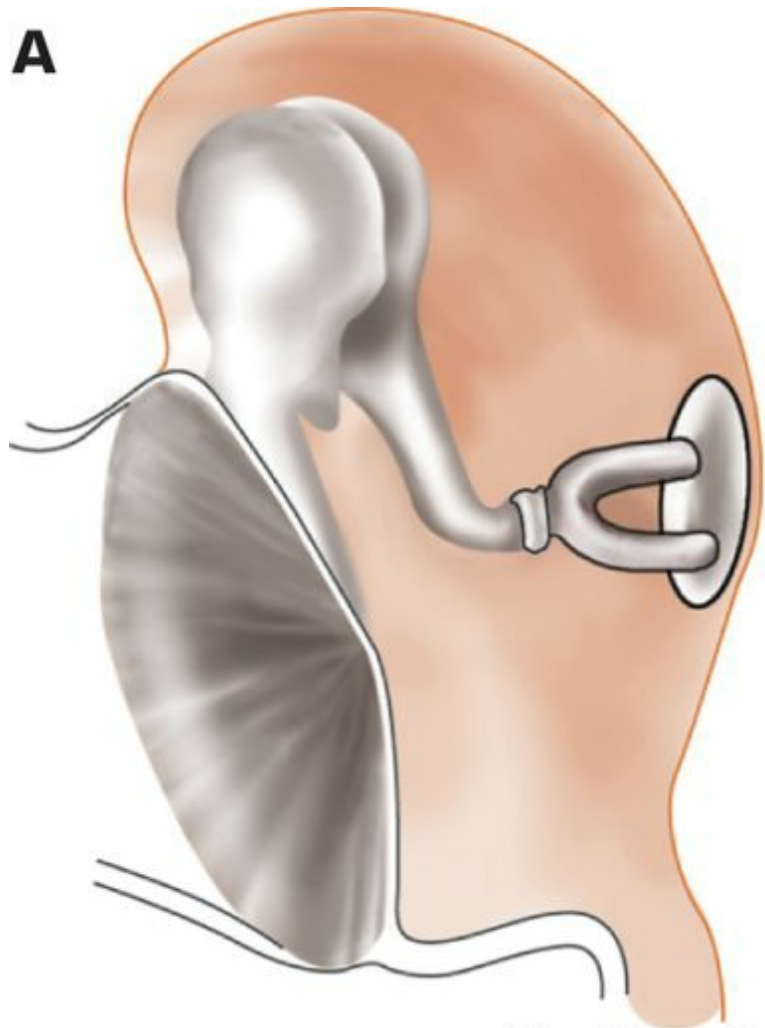
### Selection of patients for stapes surgery

Hearing threshold should be 30 dB or worse (It is this level when patient starts feeling socially handicapped).

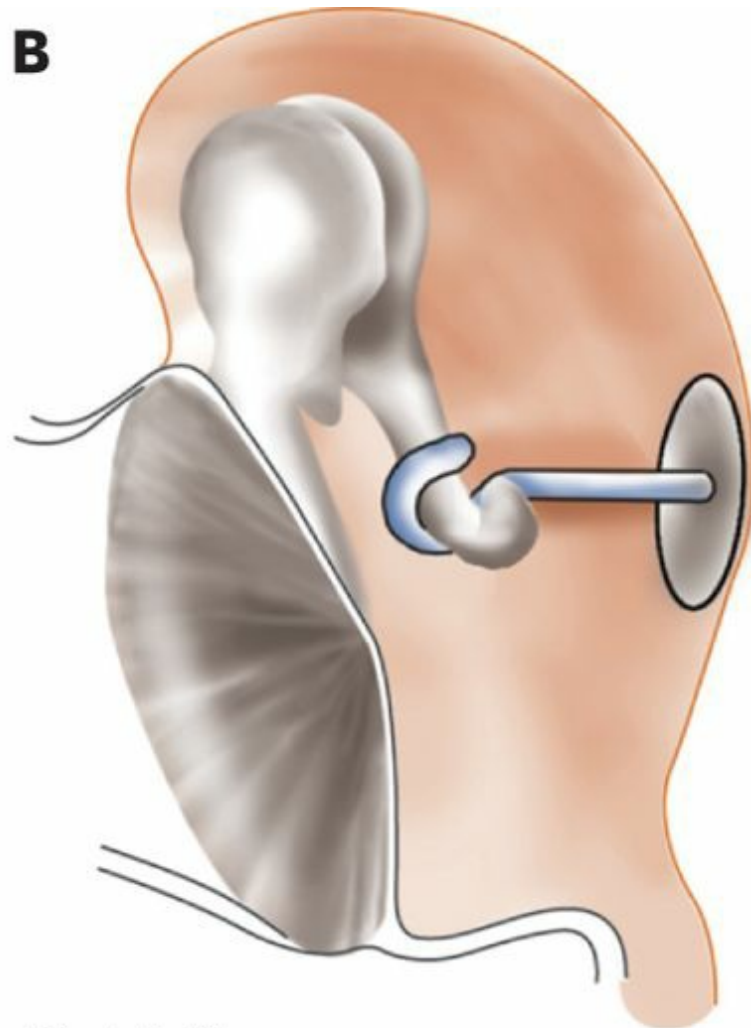
Average air-bone gap should be at least 15 dB with Rinne negative for 256 and 512 Hz.

Speech discrimination score should be 60% or more.

**A**

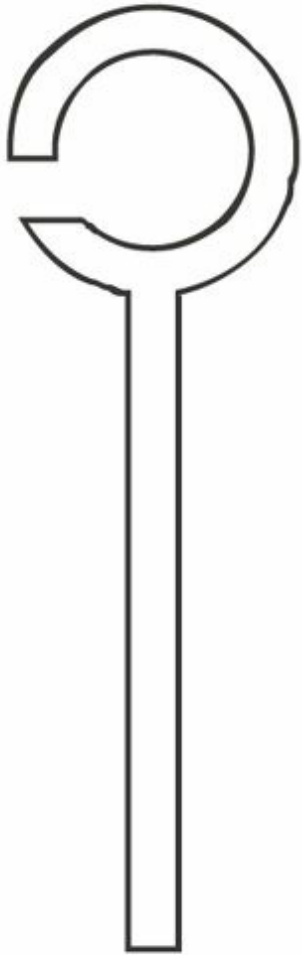


**B**



Dhingra: Diseases of Ear Nose and Throat, 5th Edition  
Copyright © 2010 Elsevier. All rights reserved.

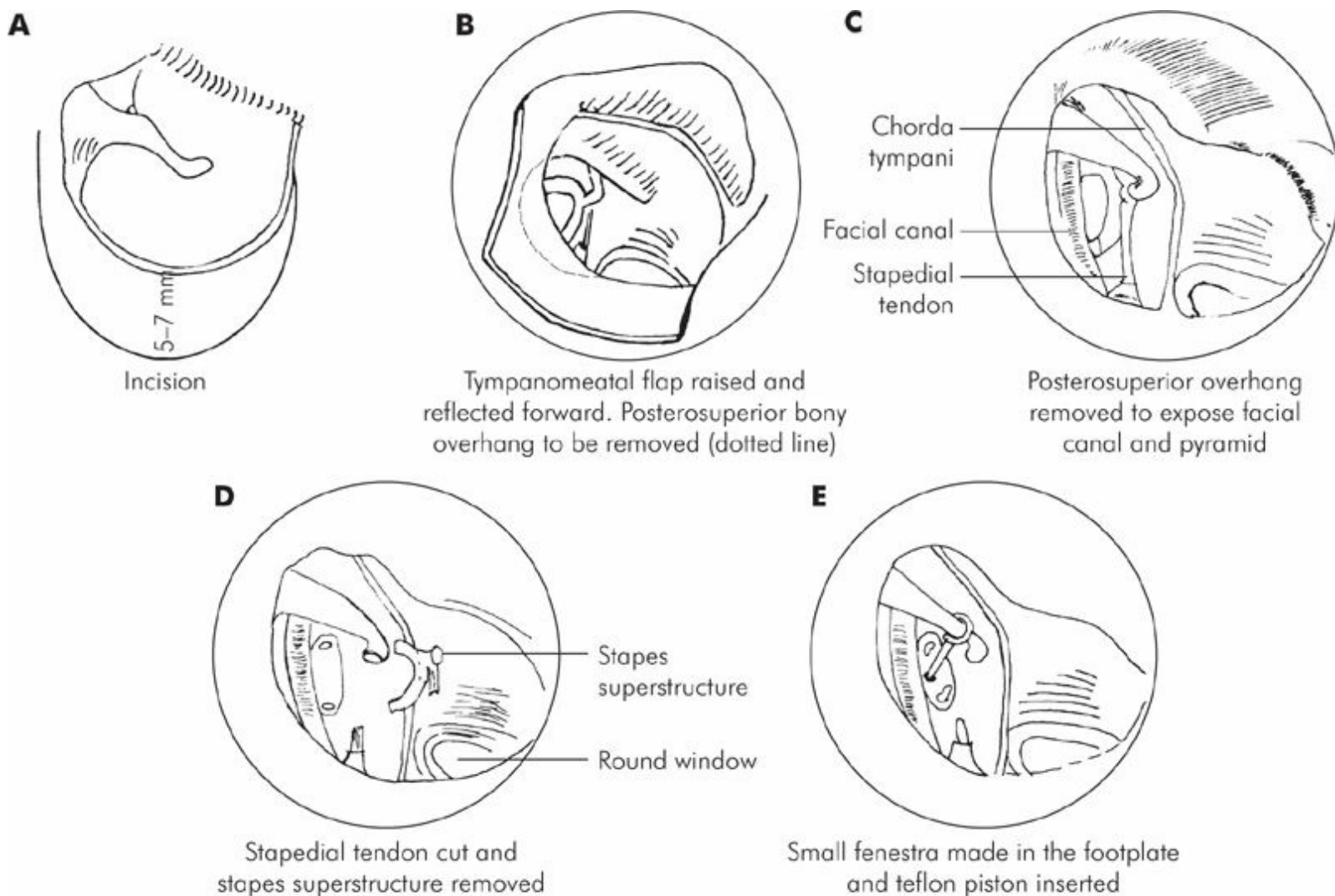
Figure 13.3 (A) Before removal of stapes. (B) Stapes removed and replaced by a teflon piston.

**A****B****C**

Dhingra: Diseases of Ear Nose and Throat, 5th Edition  
 Copyright © 2010 Elsevier. All rights reserved.

Figure 13.4 Stapes prostheses: (A) Teflon piston. (B) Platinum-teflon piston. (C) Titanium-teflon piston.





Dhingra: Diseases of Ear Nose and Throat, 5th Edition  
Copyright © 2010 Elsevier. All rights reserved.

Figure 13.5 Steps of stapedectomy (see text).

### Contraindications to stapes surgery

- (i) *The only hearing ear.*
- (ii) *Associated Meniere's disease.* When there is history of vertigo with clinical evidence of Meniere's disease in an otosclerotic patient, there are more chances of sensorineural hearing loss after stapedectomy.
- (iii) *Young children.* Recurrent eustachian tube dysfunction is common in children. It can displace the prosthesis or cause acute otitis media. Also the growth of otosclerotic focus is faster in children leading to reclosure of oval window.
- (iv) *Professional athletes, high construction workers, divers, and frequent air-travellers.* Stapes surgery has the risk to cause post-operative vertigo and/or dizziness and thus interfere with their profession; or frequent air pressure changes may damage the hearing or cause severe vertigo.
- (v) *Those who work in noisy surroundings.* After stapedectomy, they would be more vulnerable to get sensorineural hearing loss due to noise trauma.
- (vi) Otitis externa, tympanic membrane perforation and exostosis are relative contraindications. Stapedectomy can be done after they have been treated first for above conditions. Similarly, stapedectomy is avoided during pregnancy.

The operation is preferably done under local anaesthesia.

### Steps of stapedectomy

(Fig. 13.5) include:

1. Meatal incision and elevation of the tympanomeatal flap.
2. Exposure of stapes area. This may require removal of posterosuperior bony overhang of the canal.
3. Removal of stapes superstructure.
4. Creation of a hole in the stapes footplate (stapedotomy) or removal of a part of footplate (stapedectomy).
5. Placement of prosthesis.
6. Repositioning the tympanomeatal flap.

Two percent of patients undergoing this operation may suffer sensorineural loss. Slowly progressive high frequency loss is seen in long-term follow up. One in 200 patients may get a totally "dead" ear.

*Stapes mobilisation* is no longer done these days as it gives temporary results; re-fixation being quite common.

*Lempert's fenestration operation* is almost outdated now. Here an alternative window is created in the lateral semicircular canal to function for the obliterated oval window. It has the disadvantage of a post-operative mastoid cavity and an inherent hearing loss of 25 dB which cannot be corrected.

### **Hearing aid**

Patients who refuse surgery or are unfit for surgery can use hearing aid. It is an effective alternative.

## 14 Facial Nerve and Its Disorders

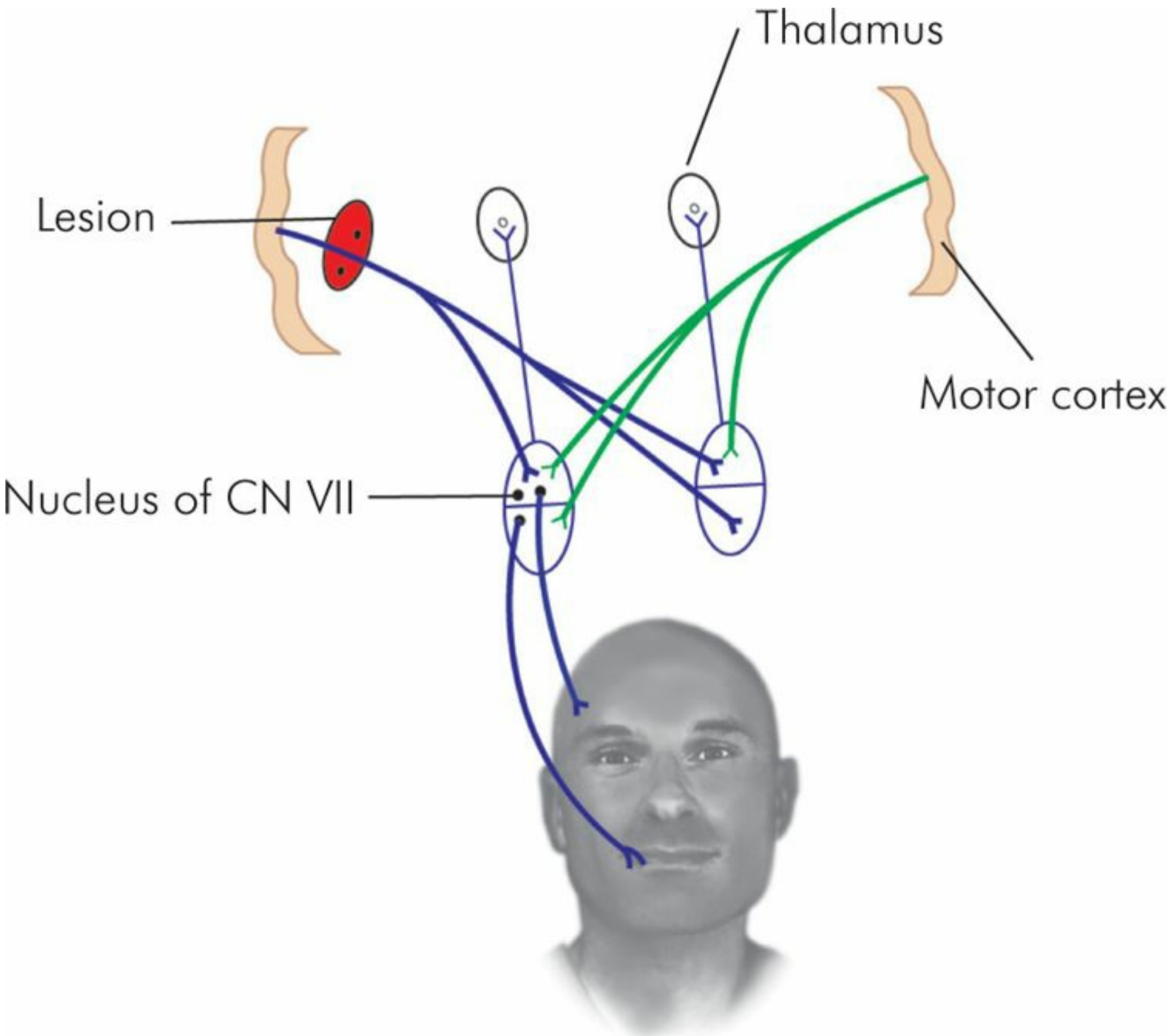
### ANATOMY AND FUNCTIONS OF FACIAL NERVE

Facial nerve is a mixed nerve having motor and a sensory root. The latter is also called the nerve of Wrisberg and carries secretomotor fibres to the lacrimal gland and salivary glands, and brings fibres of taste and general sensation. Thus there are two efferent and two afferent pathways. Components of the facial nerve include:

- **1. Special visceral efferent** forms the motor root and supplies all the muscles derived from the second branchial arch, i.e. all the muscles of facial expression, auricular muscles (now vestigial), stylohyoid, posterior belly of digastric and the stapedius.
- **2. General visceral efferent** supplies secretomotor fibres to lacrimal, submandibular and sublingual glands and the smaller secretory glands in the nasal mucosa and the palate.
- **3. Special visceral afferent** brings taste from the anterior two-thirds of tongue via chorda tympani and soft and hard palate via greater superficial petrosal nerve. Taste is carried to the nucleus of tractus solitarius.
- **4. General somatic afferent** brings general sensation from the concha, posterosuperior part of external canal and the tympanic membrane. These fibres account for vesicular eruption in herpes zoster infection of the geniculate ganglion. It also brings proprioceptive sensation from the facial muscles.

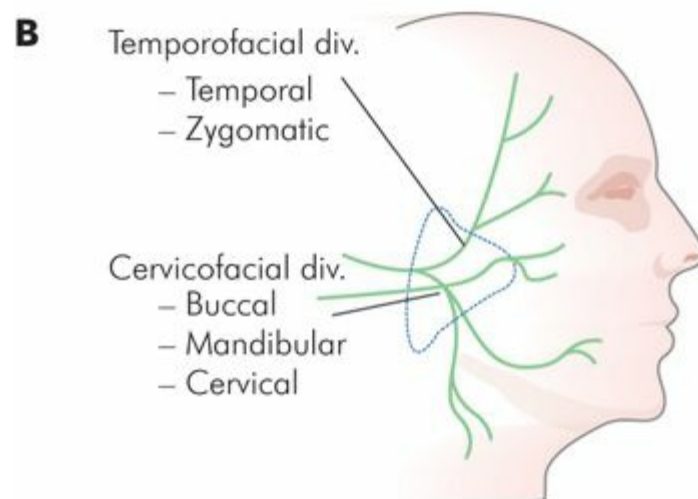
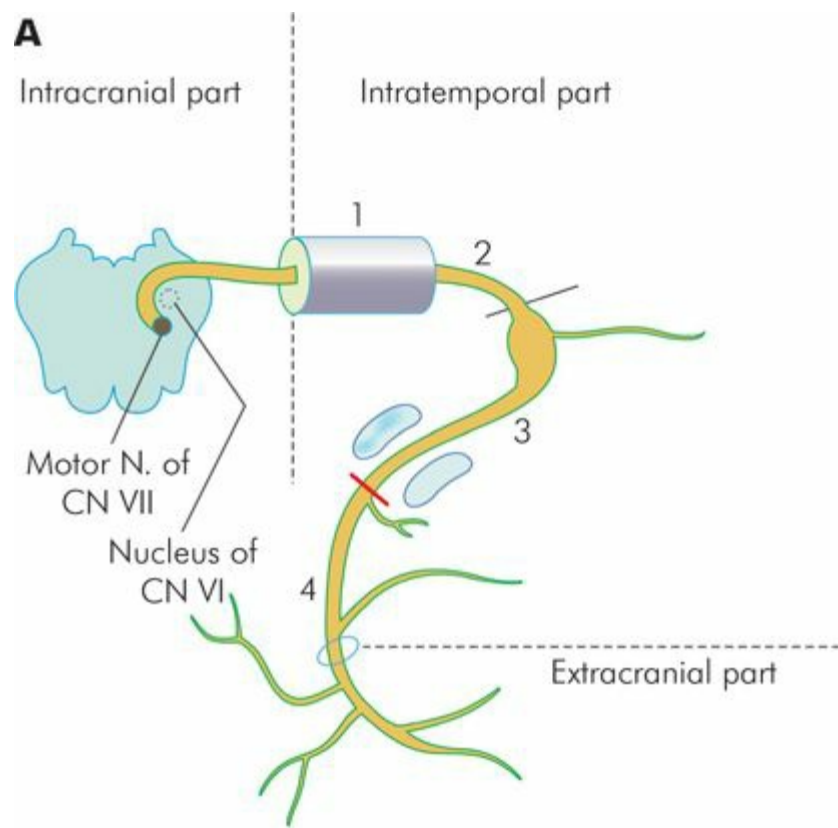
## Nucleus of Facial Nerve

Motor nucleus of the nerve is situated in the pons. It receives fibres from the precentral gyrus. Upper part of the nucleus which innervates forehead muscles receives fibres from both the cerebral hemispheres, while the lower part of nucleus which supplies lower face gets only crossed fibres from one hemisphere. The function of forehead is preserved in supranuclear lesions because of bilateral innervation. Facial nucleus also receives fibres from the thalamus by alternate routes and provides involuntary control to facial muscles. The emotional movements such as smiling and crying are thus preserved in supranuclear palsies because of these fibres from the thalamus (Fig. 14.1).



Dhingra: Diseases of Ear Nose and Throat, 5th Edition  
Copyright © 2010 Elsevier. All rights reserved.

Figure 14.1 Forehead receives bilateral innervation and is thus saved in supranuclear paralysis. Emotional movements controlled by thalamonuclear fibres are also preserved.



Dhingra: Diseases of Ear Nose and Throat, 5th Edition  
Copyright © 2010 Elsevier. All rights reserved.

Figure 14.2 (A) Course of facial nerve. Intratemporal part consists of four segments: Meatal (1), Labyrinthine (2), Tympanic (3), Mastoid (4). (B) Branches of facial nerve on face.

Motor fibres take origin from the nucleus of VIIth nerve, hook round the nucleus of VIth nerve and are joined by the sensory root (nerve of Wrisberg). Facial nerve leaves the brainstem at pontomedullary junction, travels through posterior cranial fossa and enters the internal acoustic meatus. At the fundus of the meatus (lateralmost part of meatus), the nerve enters the bony facial canal, traverses the temporal bone and comes out of the stylomastoid foramen. Here it crosses the styloid process and divides into terminal branches. The course of the nerve (Fig. 14.2) can thus be divided into:

### 1. Intracranial part

From pons to internal acoustic meatus (15-17 mm).

### 2. Intratemporal part

From internal acoustic meatus to stylomastoid foramen. It is further divided into:

- (a) *Meatal segment.* Within internal acoustic meatus (8-10 mm).
- (b) *Labyrinthine segment.* From fundus of meatus to the geniculate ganglion where nerve takes a turn posteriorly forming a "genu". The nerve in the labyrinthine segment has the narrowest diameter (0.61-0.68 mm) and the bony canal in this segment is also the narrowest. Thus oedema or inflammation can easily compress the nerve and cause paralysis. This is also the shortest segment of the nerve-only 4.0 mm.
- (c) *Tympanic or horizontal segment.* From geniculate ganglion to just above the pyramidal eminence. It lies above the oval window and

below the lateral semicircular canal (11.0 mm).

- **(d) Mastoid or vertical segment.** From the pyramid to stylomastoid foramen. Between the tympanic and mastoid segments is the second genu of the nerve (13.0 mm).

### **3. Extracranial part**

From stylomastoid foramen to the termination of its peripheral branches.

# Branches of Facial Nerve

## **1. Greater superficial petrosal nerve**

It arises from geniculate ganglion and carries secretomotor fibres to lacrimal gland and the glands of nasal mucosa.

## **2. Nerve to stapedius**

It arises at the level of second genu and supplies the stapedius muscle.

## **3. Chorda tympani**

It arises from the middle of vertical segment, passes between the incus and neck of malleus, and leaves the tympanic cavity through petrotympanic fissure. It carries secretomotor fibres to submandibular and sublingual glands and brings taste from anterior two-thirds of tongue.

## **4. Communicating branch**

It joins auricular branch of vagus and supplies the concha, retroauricular groove, posterior meatus and the outer surface of tympanic membrane.

## **5. Posterior auricular nerve**

It supplies muscles of pinna, occipital belly of occipitofrontalis and communicates with auricular branch of vagus.

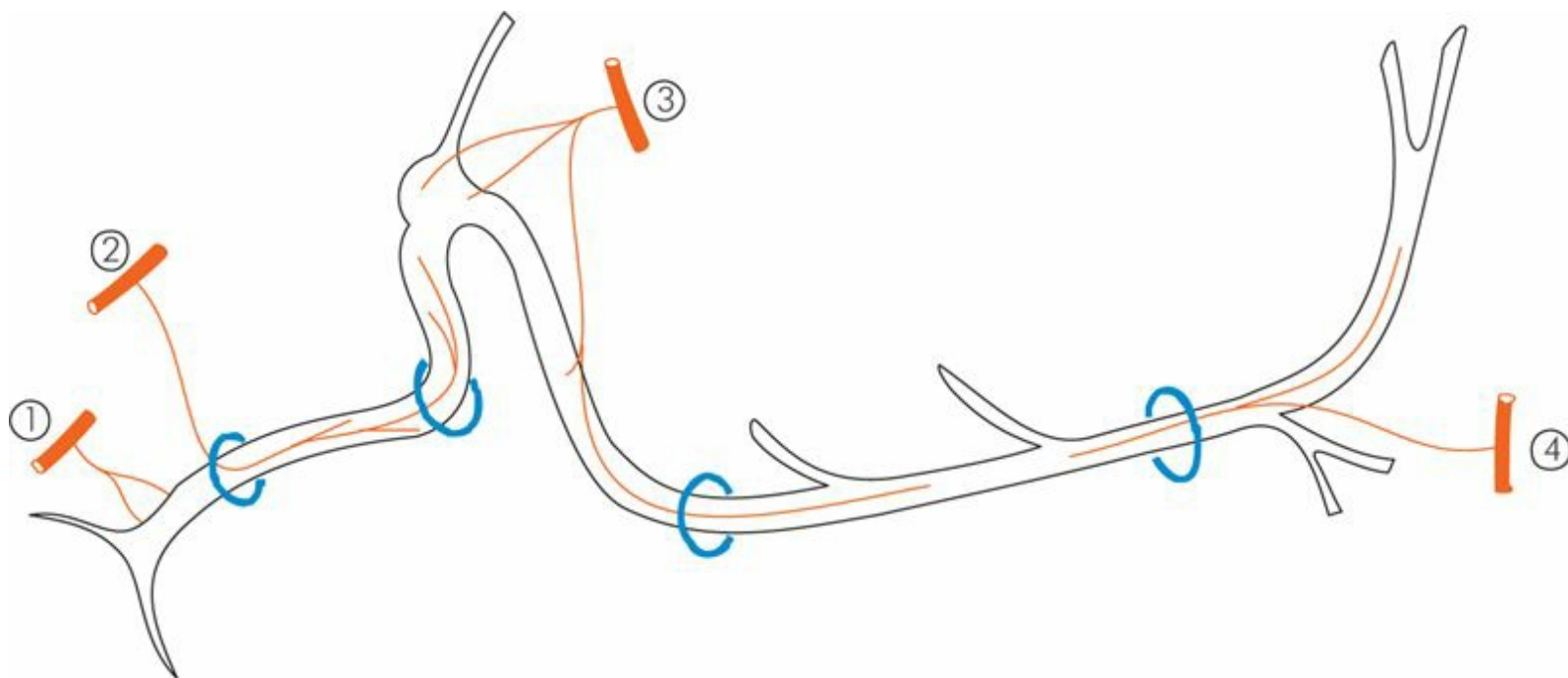
## **6. Muscular branches**

to stylohyoid and posterior belly of digastric.

## **7. Peripheral branches**

The nerve trunk, after crossing the styloid process, forms two divisions, an upper temporofacial and a lower cervicofacial, which further divide into smaller branches. These are the temporal, zygomatic, buccal, mandibular and cervical and together form *pes anserinus* (goose-foot). They supply all the muscles of facial expression.





Dhingra: Diseases of Ear Nose and Throat, 5th Edition  
 Copyright © 2010 Elsevier. All rights reserved.

Figure 14.3 Blood supply of facial nerve. (1) Cerebellopontine angle: Anterior-inferior cerebellar artery. (2) Internal auditory canal: Labyrinthine artery. (3) Geniculate ganglion and adjacent facial nerve: Superficial petrosal. (4) Mastoid segment: Stylomastoid artery.

It is derived from four blood vessels: (i) Anterior-inferior cerebellar artery supplies the nerve in CP angle; (ii) labyrinthine artery, branch of anterior inferior cerebellar artery, supplies the nerve in internal auditory canal; (iii) superficial petrosal artery, a branch of middle meningeal artery, which supplies geniculate ganglion and the adjacent region; and (iv) stylomastoid artery, branch of posterior auricular artery, which supplies the mastoid segment. All the arteries form an *external plexus* which lies in the epineurium and feeds a deeper intraneural *internal plexus* (Fig. 14.3).

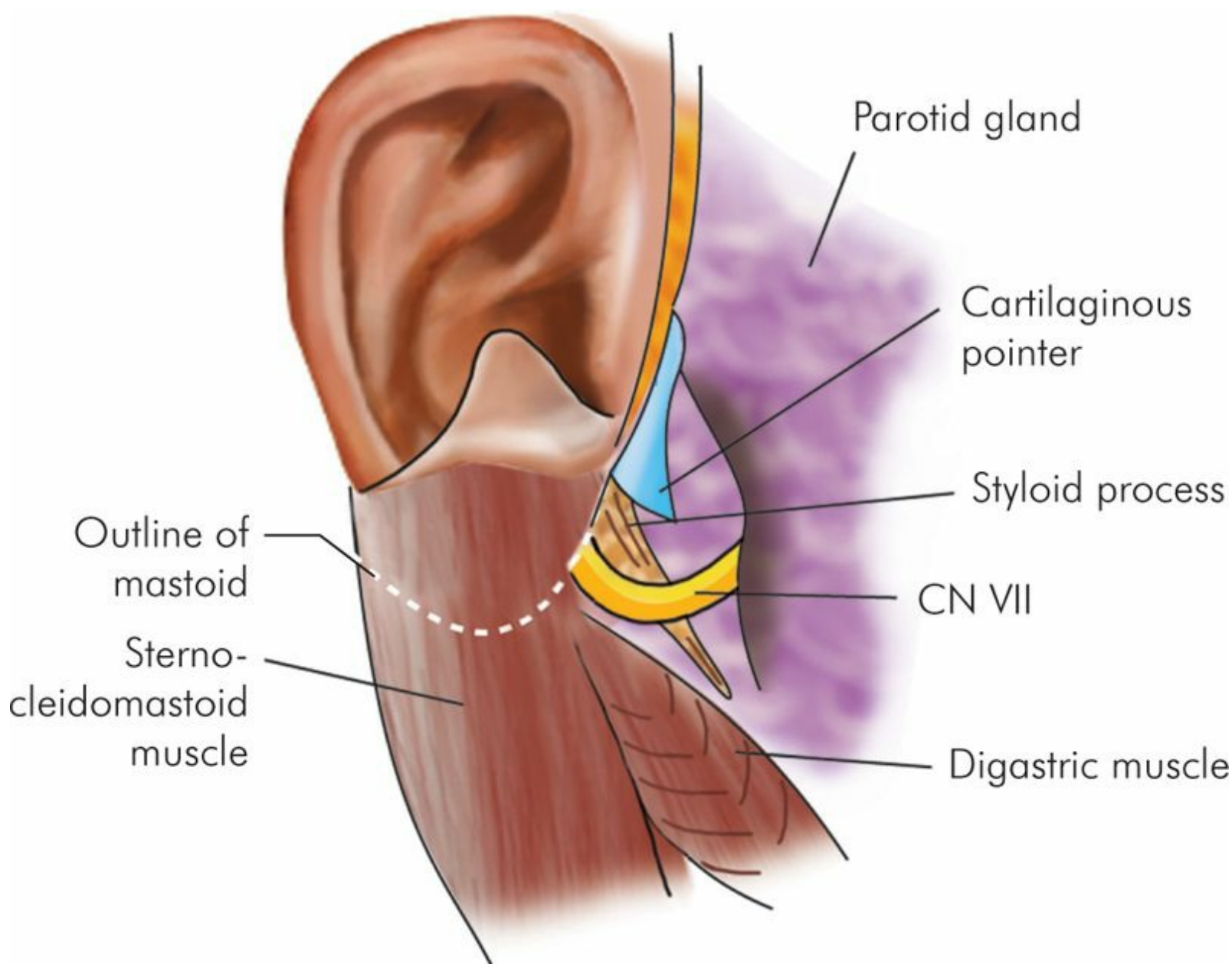
# Surgical Landmarks of Facial Nerve

For middle ear and mastoid surgery

- 1. *Processus cochleariformis*. It demarcates the geniculate ganglion which lies just anterior to it. Tympanic segment of the nerve starts at this level.
- 2. *Oval window and horizontal canal*. The facial nerve runs above the oval window (stapes) and below the horizontal canal.
- 3. *Short process of incus*. Facial nerve lies medial to the short process of incus at the level of aditus.
- 4. *Pyramid*. Nerve runs behind the pyramid and the posterior tympanic sulcus.
- 5. *Tympanomastoid suture*. In vertical or mastoid segment, nerve runs behind this suture.
- 6. *Digastric ridge*. The nerve leaves the mastoid at the anterior end of digastric ridge.

For parotid surgery (Fig. 14.4)

- 1. *Cartilaginous pointer*. The nerve lies 1 cm deep and slightly anterior and inferior to the pointer. Cartilaginous pointer is a sharp triangular piece of cartilage of the pinna and "points" to the nerve.
- 2. *Tympanomastoid suture*. Nerve lies 6-8 mm deep to this suture.
- 3. *Styloid process*. The nerve crosses lateral to styloid process.
- 4. *Posterior belly of digastric*. If posterior belly of digastric muscle is traced backwards along its upper border to its attachment to the digastric groove, nerve is found to lie between it and the styloid process.



Dhingra: Diseases of Ear Nose and Throat, 5th Edition  
Copyright © 2010 Elsevier. All rights reserved.

Figure 14.4 Surgical landmarks of the facial nerve in parotid surgery.

## Structure of Nerve

From inside out, a nerve fibre consists of axon, myelin sheath, neurilemma and *endoneurium*. A group of nerve fibres is enclosed in a sheath called *perineurium* to form a fascicle, and the fascicles are bound together by *epineurium* (Fig. 14.5).

Degree of nerve injury will determine the regeneration of nerve and its function. Earlier nerve injuries were divided into:

- (a) *Neurapraxia*, a conduction block, where flow of axoplasm through the axons was partially obstructed.
- (b) *Axonotmesis*-injury to axons.
- (c) *Neurotmesis*-injury to nerve.

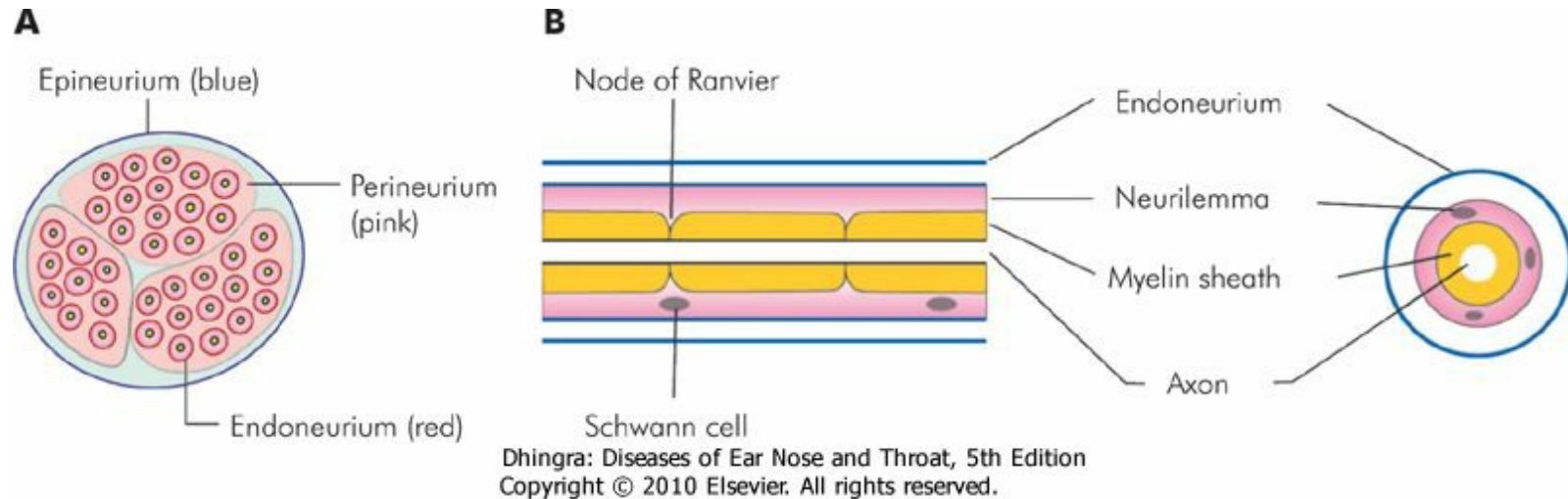


Figure 14.5 Structure of a nerve. (A) Cross section of nerve. (B) Structure of nerve fibre, longitudinal and cross-sectional views.

Sunderland classified nerve injuries into five degrees of severity based on anatomical structure of the nerve, and this classification is now widely accepted.

- 1° = Partial block to flow of axoplasm; no morphological changes are seen. Recovery of function is complete (neurapraxia).
- 2° = Loss of axons, but endoneurial tubes remain intact. During recovery, axons will grow into their respective tubes, and the result is good (axonotmesis).
- 3° = Injury to endoneurium. During recovery, axons of one tube can grow into another. Synkinesis can occur (neurotmesis).
- 4° = Injury to perineurium in addition to above. Scarring will impair regeneration of fibres (partial transection).
- 5° = Injury to epineurium in addition to above (complete nerve transection).

The first three degrees are seen in viral and inflammatory disorders while fourth and fifth are seen in surgical or accidental trauma to the nerve or in neoplasms.

# Electrodiagnostic Tests

These tests are useful to differentiate between neurapraxia and degeneration of the nerve. They also help to predict prognosis and indicate time for surgical decompression of the nerve.

## 1. Minimal nerve excitability test

The nerve is stimulated at steadily increasing intensity till facial twitch is just noticeable. This is compared with the normal side. There is no difference between the normal and paralysed side in conduction block. In other injuries, where degeneration sets in, nerve excitability is gradually lost. When the difference between two sides exceed 3.5 milliamperes, the test is positive for degeneration. Degeneration of fibres cannot be detected earlier than 48-72 hours of its commencement.

## 2. Maximal stimulation test (MST)

This test is similar to the minimal nerve excitability test but instead of measuring the threshold of stimulation, the current level which gives maximum facial movement is determined and compared with the normal side. Response is visually graded as equal, decreased or absent. Reduced or absent response with maximal stimulation indicates degeneration and is followed by incomplete recovery.

## 3. Electroneuronography (ENoG)

It is a sort of evoked electromyography. The facial nerve is stimulated at the stylomastoid foramen and the compound muscle action potentials are picked up by the surface electrodes. Supramaximal stimulation is used to obtain maximal action potentials. The response of action potentials of the paralysed side are compared with that of the normal side on similar stimulation and thus percentage of degenerating fibres is calculated. Studies reveal that degeneration of 90% occurring in the first 14 days indicates poor recovery of function. Faster rate of degeneration occurring in less than 14 days has a still poorer prognosis. ENoG is most useful between 4 and 21 days of the onset of complete paralysis.

## 4. Electromyography (EMG)

This tests the motor activity of facial muscles by direct insertion of needle electrodes usually in orbicular oculi and orbicularis oris muscles and the recordings are made during rest and voluntary contraction of muscle.

In a normal resting muscle, biphasic or triphasic potentials are seen every 30-50 milliseconds.

In a denervated muscle spontaneous involuntary action potentials called *fibrillation potentials* are seen. They appear 14-21 days after denervation. With regeneration of the nerve after injury, *polyphasic reinnervation* potentials replace fibrillation potentials. They appear 6-12 weeks prior to clinical evidence of facial function and thus provide the earliest evidence of recovery.

Voluntary contraction causes motor discharge. Diminished or no response to voluntary contraction is seen after nerve injury.

page 104

page 105

Electromyography is useful in planning reanimation procedures. Presence of normal or polyphasic potentials after 1 year of injury indicates that reinnervation is taking place and there is no need for reanimation procedure. If fibrillation potentials are seen, it indicates intact motor end plates but no evidence of reinnervation and need for nerve substitution. Electrical silence indicates atrophy of motor end plates and need for muscle transfer procedures rather than nerve substitution.

Thus ENoG and EMG are complimentary and help to prognosticate in cases of facial paralysis and in deciding the procedure for reanimation, i.e. nerve substitution versus muscle transposition or sling operation.

## CAUSES OF FACIAL PARALYSIS

The cause may be *central* or *peripheral*. The peripheral lesion may involve the nerve in its intracranial, intratemporal or extratemporal parts. Peripheral lesions are more common and about two-thirds of them are of the idiopathic variety (Table 14.1).

# A. IDIOPATHIC

## 1. Bell's Palsy

Sixty to seventy-five percent of facial paralysis is due to Bell's palsy. It is defined as *idiopathic, peripheral facial paralysis or paresis of acute onset*. Both sexes are affected with equal frequency. Any age group may be affected though incidence rises with increasing age. A positive family history is present in 6-8% of patients. Risk of Bell's palsy is more in diabetics (angiopathy) and pregnant women (retention of fluid).

### Aetiology

#### (a) Viral infection

Most of the evidence supports the viral aetiology due to herpes simplex, herpes zoster or the Epstein-Barr virus. Other cranial nerves may also be involved in Bell's palsy which is thus considered a part of the total picture of polyneuropathy.

#### (b) Vascular ischaemia

It may be primary or secondary. *Primary ischaemia* is induced by cold or emotional stress. *Secondary ischaemia* is the result of primary ischaemia which causes increased capillary permeability leading to exudation of fluid, oedema and compression of microcirculation of the nerve.

#### (c) Hereditary

Table 14-1. Causes of facial paralysis

1. *Central*
  - Brain abscess
  - Pontine gliomas
  - Poliomyelitis
  - Multiple sclerosis
2. *Intracranial part (cerebellopontine angle)*
  - Acoustic neuroma
  - Meningioma
  - Congenital cholesteatoma
  - Metastatic carcinoma
  - Meningitis
3. *Intratemporal part*
  - (a) Idiopathic
    - Bell's palsy
    - Melkersson's syndrome
  - (b) Infections
    - Acute suppurative otitis media
    - Chronic suppurative otitis media
    - Herpes zoster oticus
    - Malignant otitis externa
  - (c) Trauma
    - Surgical: Mastoidectomy Stapedectomy
    - Accidental: Fractures of temporal bone
  - (d) Neoplasms
    - Malignancies of external and middle ear
    - Glomus jugulare tumour
    - Facial nerve neuroma
    - Metastasis to temporal bone (from cancer of breast, bronchus, prostate)
4. *Extracranial part*
  - Malignancy of parotid
  - Surgery of parotid
  - Accidental injury in parotid region
  - Neonatal facial injury (obstetrical forceps)
5. *Systemic diseases*
  - Diabetes mellitus
  - Hypothyroidism
  - Uraemia
  - Polyarteritis nodosa
  - Wegener's granulomatosis
  - Sarcoidosis (Heerfordt's syndrome)
  - Leprosy
  - Leukaemia
  - Demyelinating disease

The fallopian canal is narrow because of hereditary predisposition and this makes the nerve susceptible to early compression with the slightest oedema. Ten percent of the cases of Bell's palsy have a positive family history.

#### **(d) Autoimmune disorder**

T-lymphocyte changes have been observed.

page 105

page 106

### **Clinical Features (Fig. 14.6)**

Onset is sudden. Patient is unable to close his eye. On attempting to close the eye, eyeball turns up and out (Bell's phenomenon). Saliva dribbles from the angle of mouth. Face becomes asymmetrical. Tears flow down from the eye (epiphora). Pain in the ear may precede or accompany the nerve paralysis. Some complain of noise intolerance (stapedial paralysis) or loss of taste (involvement of chorda tympani). Paralysis may be complete or incomplete. Bell's palsy is recurrent in 3-10% of patients.

### **Diagnosis**

Diagnosis is always by exclusion. All other known causes of peripheral facial paralysis should be excluded. This requires careful history, complete otological and head and neck examination, X-ray studies, blood tests such as total count, peripheral smear, sedimentation rate, blood sugar and serology.

Nerve excitability tests are done daily or on alternate days and compared with the normal side to monitor nerve degeneration.

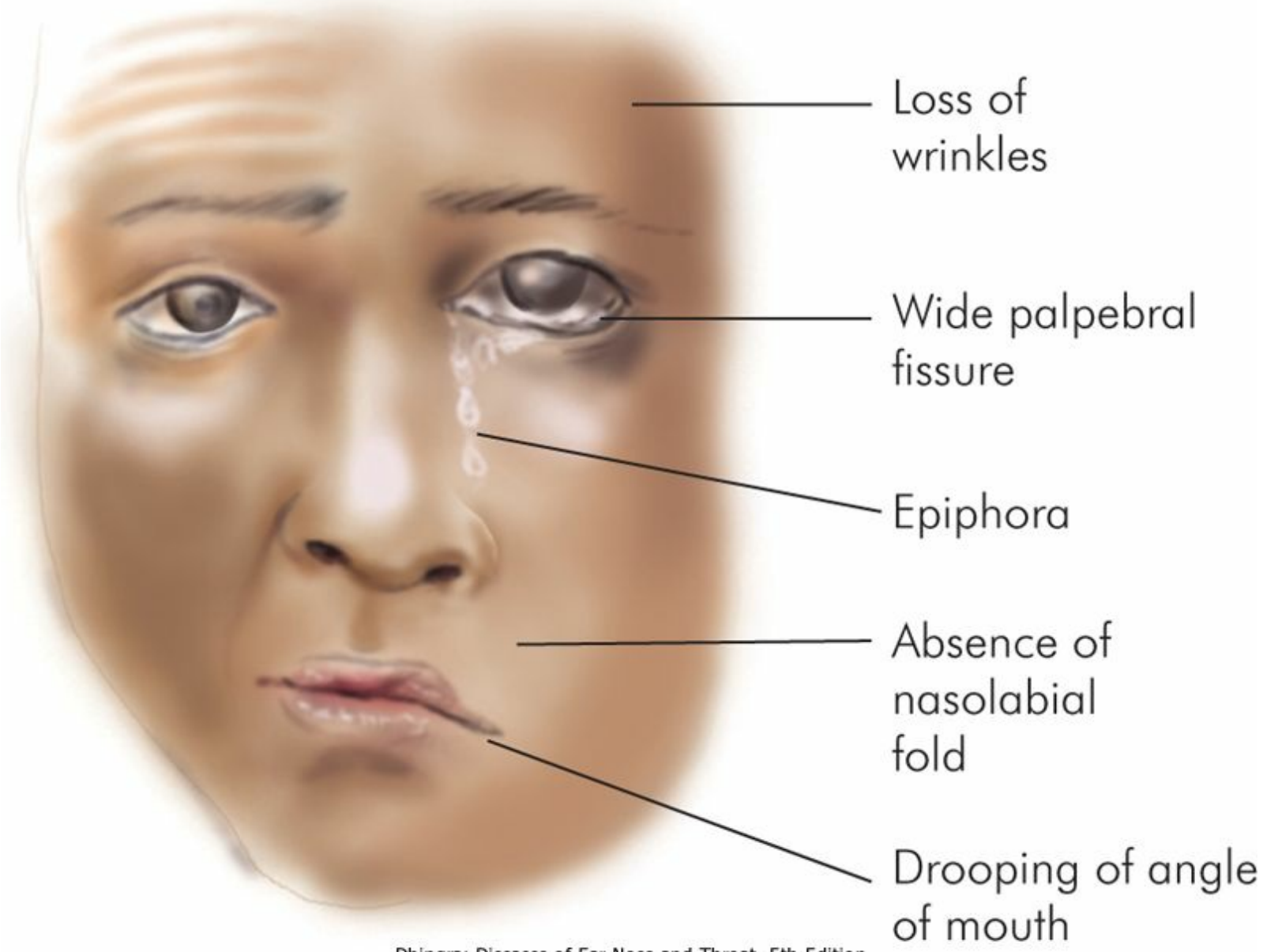
Localising the site of lesion (topodiagnosis) helps in establishing the aetiology and also the site of surgical decompression of nerve, if that becomes necessary.

### **Treatment**

#### **General**

- 1. Reassurance.
- 2. Relief of ear pain by analgesics.
- 3. Care of the eye as outlined on page 109. Eye must be protected against exposure keratitis.
- 4. Physiotherapy or massage of the facial muscles gives psychological support to the patient. It has not been shown to influence recovery. Active facial movements are encouraged when there is return of some movement to the facial muscles.





Dhingra: Diseases of Ear Nose and Throat, 5th Edition  
 Copyright © 2010 Elsevier. All rights reserved.

Figure 14.6 Facial paralysis left side. Compare with normal side.

**Medical management**

**Steroids**

Their utility has not been proved beyond doubt in carefully controlled studies. Prednisolone is the drug of choice. If patient reports within 1 week, the adult dose of prednisolone is 1 mg/kg/day divided into morning and evening doses for 5 days. Patient is seen on the 5th day. If paralysis is incomplete or is recovering, dose is tapered during the next 5 days. If paralysis remains complete, the same dose is continued for another 10 days and thereafter tapered in next 5 days. (total of 20 days). Contraindications to use of steroids include pregnancy, diabetes, hypertension, peptic ulcer, pulmonary tuberculosis and glaucoma. Steroids have been found useful to prevent incidence of synkinesis, crocodile tears and to shorten the recovery time of facial paralysis. Steroids can be combined with acyclovir for Herpes zoster oticus or Bell's palsy.

**Other drugs**

Vasodilators, vitamins, mast cell inhibitors, antihistaminics have not been found useful.

**Surgical treatment**

Nerve decompression relieves pressure on the nerve fibres and thus improves the microcirculation of the nerve. Vertical and tympanic segments of nerve are decompressed. Some workers have suggested total decompression including labyrinthine segment by postaural and middle fossa approach.

**Prognosis**

Eighty-five to ninety percent of the patients recover fully. 10-15% recover incompletely and may be left with some stigmata of regeneration. Recurrent facial palsy may not recover fully. Prognosis is good in incomplete Bell's palsy (95% complete recovery) and in those where clinical

recovery starts within 3 weeks of onset (75% complete recovery).

## 2. Melkersson's Syndrome

It is also an idiopathic disorder consisting of a triad of facial paralysis, swelling of lips and fissured tongue. Paralysis may be recurrent. Treatment is the same as for Bell's palsy.

### ***Recurrent facial palsy***

Recurrent facial palsy is seen in Bell's palsy (3-10% cases), Melkersson's syndrome, diabetes, sarcoidosis and tumours. Recurrent palsy on the same side may be caused by a tumour in 30% of cases.

### ***Bilateral facial paralysis***

Simultaneous bilateral facial paralysis may be seen in Guillain-Barré syndrome, sarcoidosis, sickle cell disease, acute leukaemia, bulbar palsy, leprosy and some other systemic disorders.

## **B. INFECTIONS**

### **Herpes Zoster Oticus (Ramsay-Hunt Syndrome)**

There is facial paralysis along with vesicular rash in the external auditory canal and pinna (Fig. 14.7). There may also be anaesthesia of face, giddiness and hearing impairment due to involvement of Vth and VIIIth nerves. Treatment is the same as for Bell's palsy.

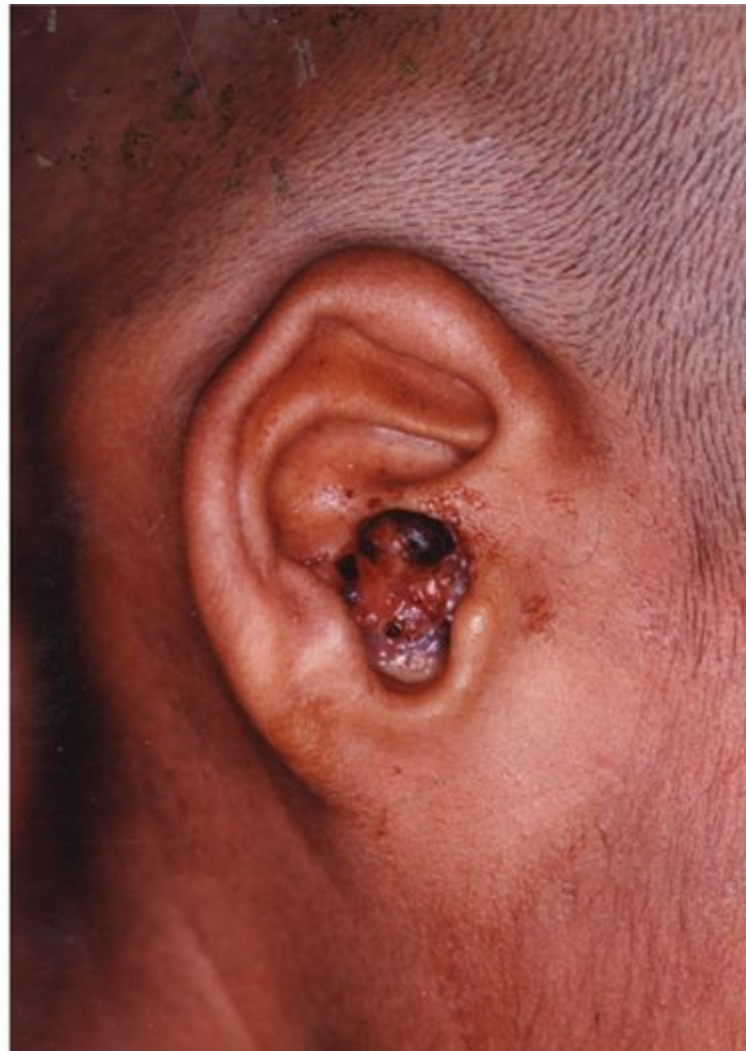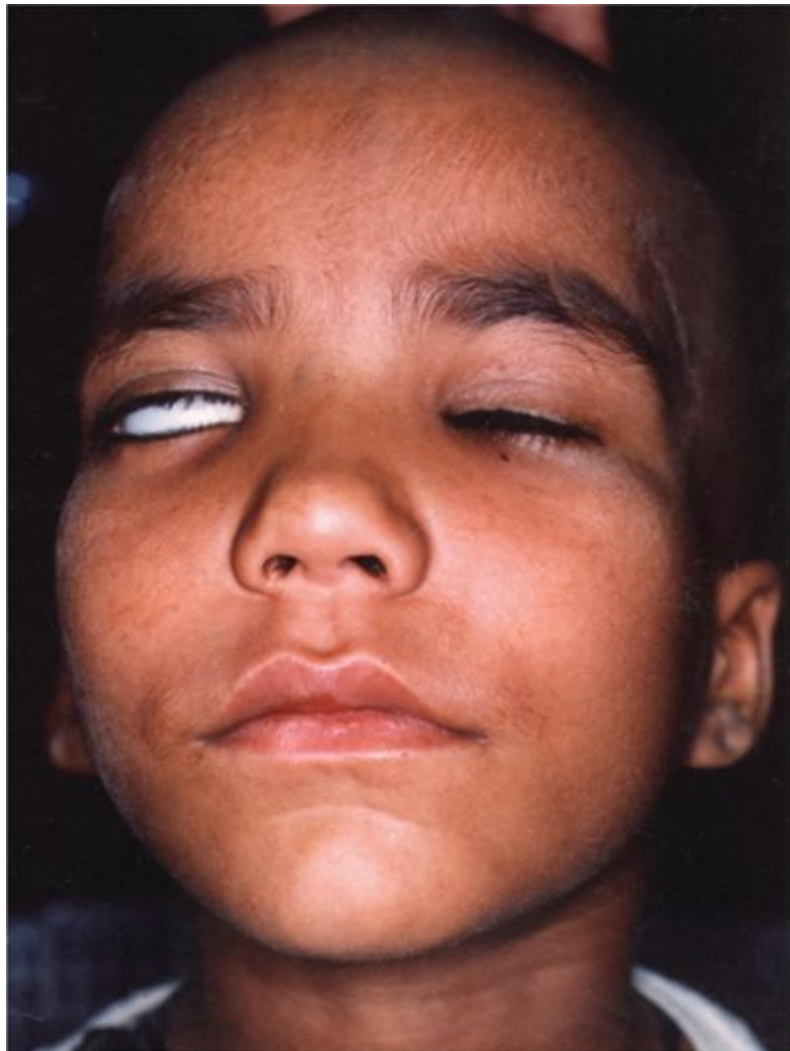*Infections of Middle Ear (see page 90)*

*Malignant Otitis Externa (see page 58)*

## C. TRAUMA

### 1. Fractures of Temporal Bone

Fractures of temporal bone may be *longitudinal*, *transverse* or *mixed* (Fig. 14.8). Facial palsy is seen more often in transverse fractures (50%). Paralysis is due to intraneural haematoma, compression by a bony spicule or transection of nerve. In these cases, it is important to know whether paralysis was of immediate or delayed onset. Delayed onset paralysis is treated conservatively like Bell's palsy while immediate onset paralysis may require surgery in the form of decompression, re-anastomosis of cut ends or cable nerve graft (Table 14.2).



Dhingra: Diseases of Ear Nose and Throat, 5th Edition  
Copyright © 2010 Elsevier. All rights reserved.

Figure 14.7 Ramsay-Hunt syndrome. Note facial palsy and small vesicles in the concha of the right side.

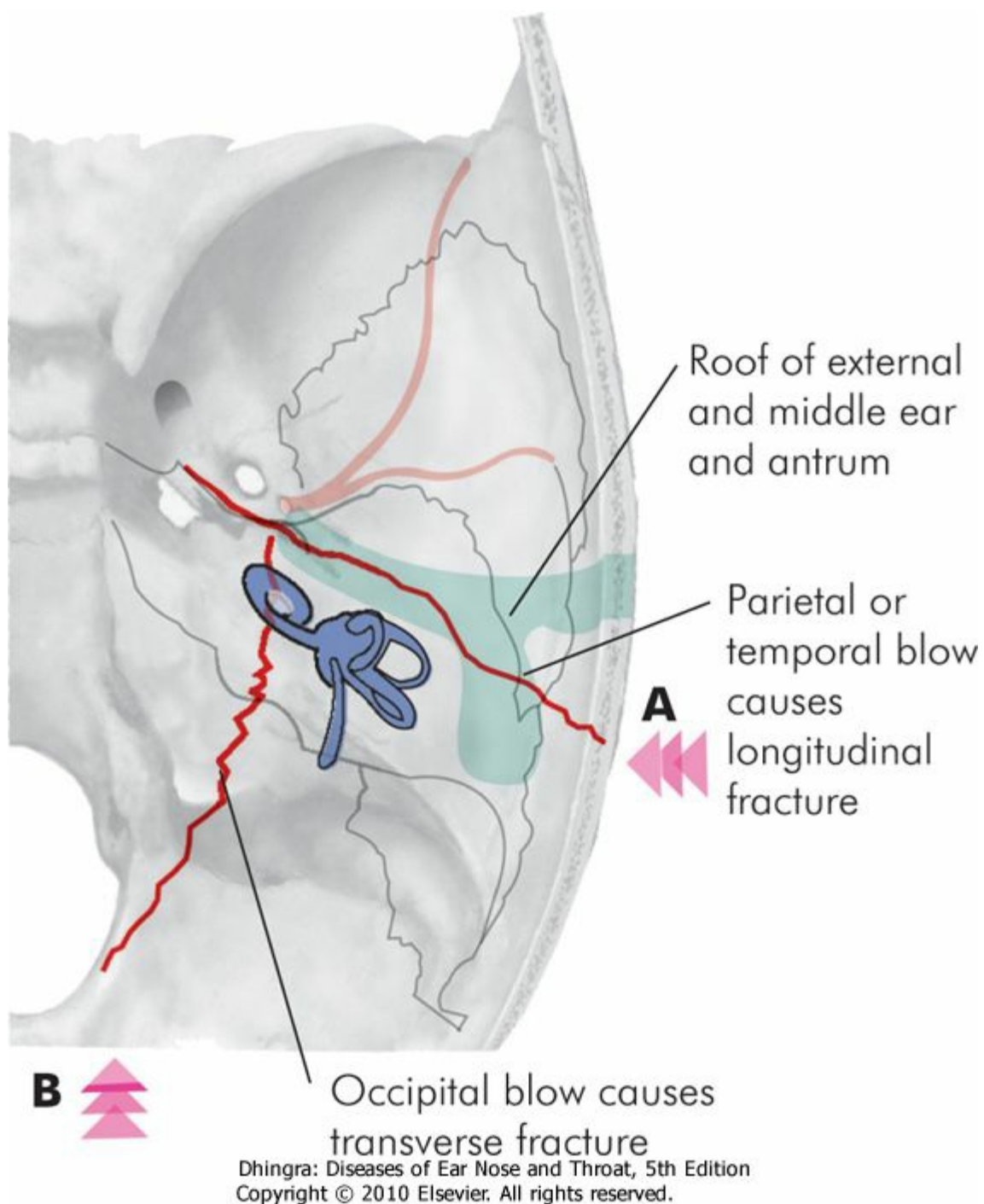


Figure 14.8 (A) Longitudinal fracture runs along the axis of petrous pyramid. Typically, it starts at squamous part of temporal bone, runs through roof of external ear canal and middle ear towards the petrous apex, and to foramen lacerum. (B) Transverse fracture. It runs across the axis of petrous. Typically, it begins at foramen magnum, passes through occipital bone, jugular fossa, petrous pyramid ending in middle cranial fossa. It may pass medial, lateral or through the labyrinth.

Table 14-2. Differences in longitudinal and transverse fractures of temporal bone

	Longitudinal	Transverse
• Frequency	More common (80%)	Less common (20%)
• Type of injury	Parietal blow	Occipital blow
• Fracture line	Runs parallel to long axis of petrous pyramid. Starts at squamous part of temporal bone to end at foramen lacerum	Runs across the petrous pyramid. Starts at foramen magnum or jugular foramen towards the foramen spinosum
• Bleeding from ear	Common, due to injury to tegmen and tympanic membrane	Absent because tympanic membrane is intact. Haemotympanum may be seen
• C.S.F.	Present, often mixed with blood	Absent or unmanifested

• Otorrhoea		
Structures injured	Tegmen, ossicles and tympanic membrane	Labyrinth or CN VIII
• Hearing loss	Conductive	Sensorineural
• Vertigo	Less often; due to concussion	Severe, due to injury to labyrinth or CN VIII
• Facial paralysis	Less (20%), delayed onset. Nerve is injured in tympanic segment, distal to geniculate ganglion	Most common (50%). Immediate onset. Injury to nerve in meatal or labyrinthine segment proximal to geniculate ganglion.

## 2. Ear or Mastoid Surgery

Facial nerve is injured during stapedectomy, tympanoplasty or mastoid surgery. Paralysis may be immediate or delayed and treatment is the same as in temporal bone trauma. Sometimes, nerve is paralysed due to pressure of packing on the exposed nerve and this should be relieved first.

Operative injuries to facial nerve can be avoided if attention is paid to the following:

- **(i)** Anatomical knowledge of the course of facial nerve, possible variations and anomalies and its surgical landmarks. Cadaver dissections should be an important part of the training in ear surgery.
- **(ii)** Always working along the course of nerve and never across it.
- **(iii)** Constant irrigation when drilling, to avoid thermal injury. Use diamond burr when working near the nerve.
- **(iv)** Gentle handling of the nerve when it is exposed, avoiding any pressure of instruments on the nerve.
- **(v)** Not to remove any granulations that penetrate the nerve.
- **(vi)** Using magnification; never to work on facial nerve without an operating microscope.



### 3. Parotid Surgery and Trauma to Face

Facial nerve may be injured in surgery of parotid tumours or deliberately excised in malignant tumours. Accidental injuries in the parotid region can also cause facial paralysis. Application of obstetrical forceps may also result in facial paralysis in the neonate due to pressure on the extratemporal part of nerve.

## **D. NEOPLASMS**

### **1. Intratemporal Neoplasms**

Carcinoma of external or middle ear, glomus tumour, rhabdomyosarcoma and metastatic tumours of temporal bone, all result in facial paralysis. Facial nerve neuroma occurs anywhere along the course of nerve and produces paralysis of gradual or sudden onset. It is treated by excision and nerve grafting. High resolution CT scan and gadolinium-enhanced MRI is very useful for facial nerve tumour.

## 2. Tumours of Parotid

Facial paralysis with tumour of the parotid almost always implies malignancy (see Tumours of salivary glands).

## **E. SYSTEMIC DISEASES AND FACIAL PARALYSIS**

Peripheral facial paralysis is mostly of idiopathic variety but always needs exclusion of diabetes, hypothyroidism, leukaemia, sarcoidosis, periarteritis nodosa, Wegener's granulomatosis, leprosy, syphilis and demyelinating disease.

# LOCALISATION OF FACIAL LESION

## 1. Central Facial Paralysis

It is caused by cerebrovascular accidents (haemorrhage, thrombosis or embolism), tumour or an abscess. It causes paralysis of only the lower half of face on the contralateral side. Forehead movements are retained due to bilateral innervation of frontalis muscle. Involuntary emotional movements and the tone of facial muscles are also retained.

## 2. Peripheral Facial Paralysis

All the muscles of the face on the involved side are paralysed. Patient is unable to frown, close the eye, purse the lips or whistle.

A lesion at *the level of nucleus* is identified by associated paralysis of VIth nerve.

A lesion at *cerebellopontine angle* is identified by the presence of vestibular and auditory defects and involvement of other cranial nerves such as Vth, IXth, Xth and XIth.

A lesion *in the bony canal*, from internal acoustic meatus to stylomastoid foramen, can be localised by topodiagnostic tests.

A lesion *outside the temporal bone*, in the parotid area, affects only the motor functions of nerve. It may sometimes be incomplete as some branches of the nerve may not be involved in tumour or trauma.

# Topodiagnostic Tests for Lesions in Intratemporal Part (Fig. 14.9)

The following tests are useful in finding the site of lesion in paralysis of lower motor neuron.

## 1. Schirmer's test

It compares lacrimation of the two sides. A strip of filter paper is hooked in the lower fornix of each eye and the amount of wetting of strip measured. Decreased lacrimation indicates lesion proximal to the geniculate ganglion as the secretomotor fibres to lacrimal gland leave at the geniculate ganglion via greater superficial petrosal nerve.

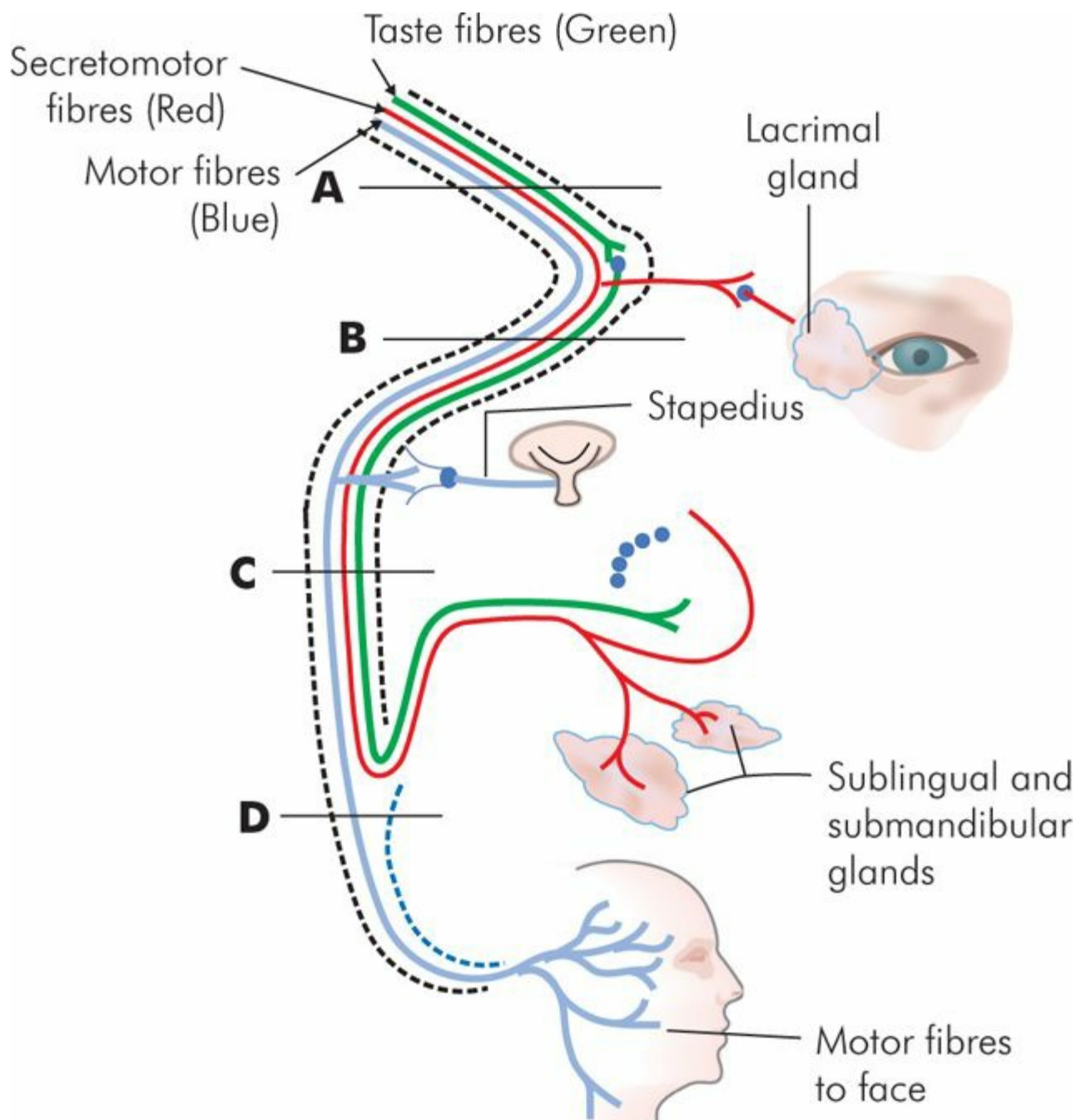
## 2. Stapedial reflex

Stapedial reflex is lost in lesions above the nerve to stapedius. It is tested by tympanometry.

## 3. Taste test

It can be measured by a drop of salt or sugar solution placed on one side of the protruded tongue, or by electrogustometry. Impairment of taste indicates lesion above the chorda tympani.

## 4. Submandibular salivary flow test



Dhingra: Diseases of Ear Nose and Throat, 5th Edition  
Copyright © 2010 Elsevier. All rights reserved.

Figure 14.9 Topographical localisation of VIIth nerve lesions. (A) Suprageniculate or transgeniculate lesion. Secretomotor fibres to the lacrimal gland leave at the geniculate ganglion and are

interrupted in lesions situated at/or proximal to geniculate ganglion. (B) Suprastapedial lesions cause loss of stapedial reflex and taste but preserve lacrimation. (C) Infrastapedial lesions cause loss of taste but preserve stapedial reflex and lacrimation. (D) Infrachordal lesions cause loss of facial motor function only.

It also measures function of chorda tympani. Polythene tubes are passed into both Wharton's ducts and drops of saliva counted during one minute period. Decreased salivation shows injury above the chorda.



# COMPLICATIONS FOLLOWING FACIAL PARALYSIS

Peripheral facial paralysis due to any cause may result in any of the following complications:

## **1. Incomplete recovery**

Facial asymmetry persists. Eye cannot be closed resulting in epiphora. A weak oral sphincter causes drooling and difficulty in taking food.

## **2. Exposure keratitis**

Eye cannot be closed, tear film from the cornea evaporates causing dryness, exposure keratitis and corneal ulcer. This is worse when tear production is also affected. It can be prevented by use of artificial tears (methylcellulose drops) every 1-2 hours, eye ointment and proper cover for the eye at night.

Temporary tarsorrhaphy may also be indicated. Eye closure can also be improved by using gold-weight implant sutured to the tarsal plate deep to levator palpebrae muscle.

## **3. Synkinesis (mass movement)**

page 109

page 10

When the patient wishes to close the eye, corner of mouth also twitches or vice versa. It is due to cross innervation of fibres; there is no treatment.

## **4. Tics and spasms**

They are the result of faulty regeneration of fibres. Involuntary movements are seen on the affected side of the face.

## **5. Contractures**

They result from fibrosis of atrophied muscles or fixed contraction of a group of muscles. They affect movements of face but facial symmetry at rest is good.

## **6. Crocodile tears (gustatory lacrimation)**

There is unilateral lacrimation with mastication. This is due to faulty regeneration of parasympathetic fibres which now supply lacrimal gland instead of the salivary glands. It can be treated by section of greater superficial petrosal nerve or *tympanic neurectomy*.

## **7. Frey's syndrome (gustatory sweating)**

There is sweating and flushing of skin over the parotid area during mastication. It results from parotid surgery.

## **8. Psychological and social problems**

Drooling during eating and drinking and impairment of speech cause social problems.

# HYPERKINETIC DISORDERS OF FACIAL NERVE

They are characterised by involuntary twitching of facial muscles on one or both sides.

## **1. Hemifacial spasm**

It is characterised by repeated, uncontrollable twitchings of facial muscles on one side (Fig. 14.10). It is of two types (a) essential or idiopathic, where cause is not known and (b) secondary, where cause is acoustic neuroma, congenital cholesteatoma or glomus tumour. Many cases of hemifacial spasm are due to irritation of the nerve because of a vascular loop at the cerebellopontine angle. Microvascular decompression through posterior fossa craniotomy has met with high success rate in these cases. Idiopathic type has been treated by selective section of the branches of facial nerve in the parotid or by puncturing the facial nerve with a needle in its tympanic segment.

Botulinum toxin has been used in the affected muscle. It blocks the neuromuscular junction by preventing release of acetylcholine.

## **2. Blepharospasm**

Twitchings and spasms are limited to orbicularis oculi muscles on both sides. The eyes are closed due to muscle spasms causing functional blindness. The cause is uncertain, but probably lies in the basal ganglia. It is treated by selective section of nerves supplying muscles around the eye on both sides.

Botulinum-A toxin injected into the periorbital muscles gives relief for 3-6 months. Injection can be repeated if necessary.

# **SURGERY OF FACIAL NERVE**

## ***1. Decompression***

The nerve may be compressed by oedema, haematoma or a fractured bone in its intratemporal part. The bony canal is exposed and uncapped. The sheath of nerve is also slit to relieve pressure due to oedema or intraneural haematoma.

## ***2. End to end anastomosis***

This is done when the gap between severed ends of the nerves is only a few millimetres. It is a suitable procedure for extratemporal part of the nerve. There should not be any tension in the approximated ends.

## ***3. Nerve graft (cable graft)***

When the gap between severed ends cannot be closed by end to end anastomosis, a nerve graft is more suitable than extensive re-routing or mobilisation of nerve. Nerve graft is taken from greater auricular, lateral cutaneous nerve of thigh or the sural nerve. In the bony canal, the graft may not require any suturing.

## ***4. Hypoglossal-facial anastomosis***

Hypoglossal nerve is anastomosed to the severed peripheral end of the facial nerve. It improves the muscle tone and permits some movements of facial muscles, but at the expense of atrophy of tongue on that side. However, disability of tongue due to atrophy is not so severe and patient adjusts to the difficulty in chewing and articulation after a few weeks.

## ***5. Plastic procedures***

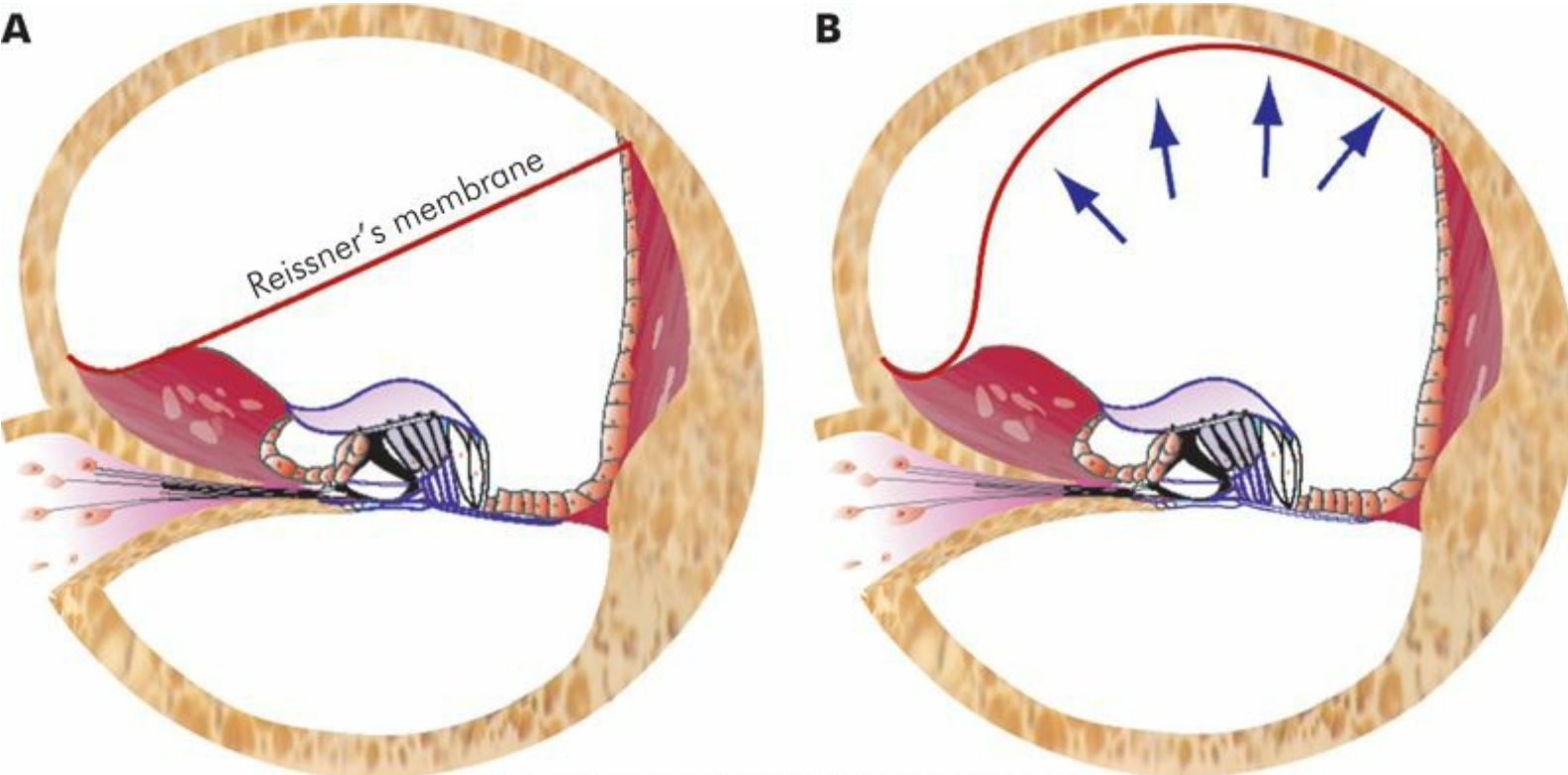
They are used to improve cosmetic appearance when nerve grafting is not feasible or has failed. The procedures include facial slings, face lift operation or slings of masseter and temporalis muscle. The latter also gives some movement to face in addition to symmetry.

## 15 Meniere's Disease

Meniere's Disease, also called *endolymphatic hydrops*, is a disorder of the inner ear where the endolymphatic system is distended with endolymph. It is characterised by (i) vertigo, (ii) sensorineural hearing loss and (iii) tinnitus and (iv) aural fullness.

# Pathology

The main pathology is distension of endolymphatic system, mainly affecting the cochlear duct (scala media) and the saccule, and to a lesser extent the utricle and semicircular canals. The dilatation of cochlear duct is such that, it may completely fill the scala vestibuli; there is marked bulging of Reissner's membrane which may even herniate through the helicotrema into the apical part of scala tympani (Fig. 15.1). The distended saccule may come to lie against the stapes footplate. The utricle and saccule may show out-pouchings into the semicircular canals.



Dhingra: Diseases of Ear Nose and Throat, 5th Edition  
Copyright © 2010 Elsevier. All rights reserved.

Figure 15.1 (A) Normal cochlear duct. (B) Cochlear duct is distended with endolymph pushing the Reissner's membrane into scala vestibuli.

# Aetiology

The main pathology in Meniere's disease is distension of endolymphatic system due to increased volume of endolymph. This can result either from increased production of endolymph or its faulty absorption or both. Normally, endolymph is secreted by stria vascularis, fills the membranous labyrinth and is absorbed through the endolymphatic sac (see page 12 for inner ear fluids).

The exact cause of Meniere's disease is not yet known. Various theories have been postulated (Fig. 15.2).

## 1. Defective absorption by endolymphatic sac

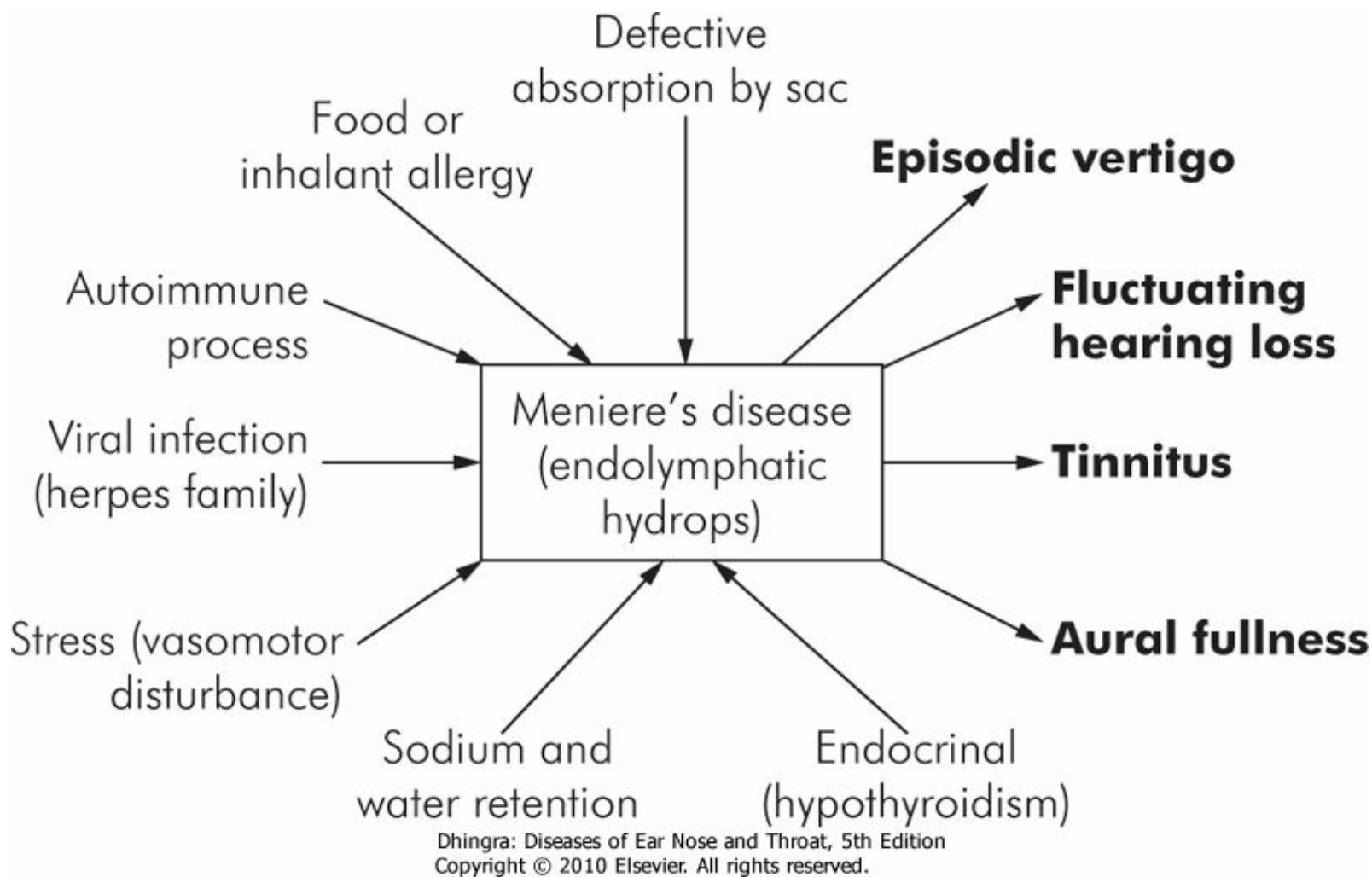


Figure 15.2 Aetiologic factors and symptomatology of Meniere's disease (endolymphatic hydrops).

Normally, endolymph is carried by the endolymphatic duct to the sac where it is absorbed. Defective absorption by the sac may be responsible for raised endolymph pressure. Experimental obstruction of endolymphatic sac and its duct also produces hydrops. Ischaemia of sac has been observed in cases of Meniere's disease undergoing sac surgery, indicating poor vascularity and thus poor absorption by the sac. Distension of membranous labyrinth leads to rupture of Reissner's membrane and thus mixing of perilymph with endolymph, which is thought to bring about an attack of vertigo.

## 2. Vasomotor disturbance

There is sympathetic over-activity resulting in spasm of internal auditory artery and/or its branches, thus interfering with the function of cochlear or vestibular sensory neuroepithelium. This is responsible for deafness and vertigo. Anoxia of capillaries of stria vascularis also causes increased permeability, with transudation of fluid and increased production of endolymph.

## 3. Allergy

The offending allergen may be a foodstuff or an inhalant. In these cases, inner ear acts as the "shock organ" producing excess of endolymph. Nearly 50% of patients with Meniere's disease have concomitant inhalant and/or food allergy.

It is possible that Meniere's disease is multifactorial, resulting in the common end point of endolymphatic hydrops with classical presentation.

#### **4. Sodium and water retention**

Excessive amounts of fluid are retained leading to endolymphatic hydrops.

#### **5. Hypothyroidism**

About 3% of cases of Meniere's disease are due to hypothyroidism. Such cases benefit from thyroid replacement therapy.

#### **6. Autoimmune and viral aetiologies**

have also been suggested on the basis of experimental, laboratory and clinical observations.

# Clinical Features

*Age and sex.* Disease is commonly seen in the age group of 35-60 years. Males are affected more than females. Usually, disease is unilateral but the other ear may be affected after a few years.

*Cardinal symptoms* of Meniere's disease are: (1) Episodic vertigo, (2) Fluctuating hearing loss, (3) Tinnitus and (4) Sense of fullness or pressure in the involved ear.

## **1. Vertigo**

It comes in attacks. The onset is sudden. Patient gets a feeling of rotation of himself or his environment. Sometimes, there is feeling of "to and fro" or "up and down" movement. Attacks come in clusters, with periods of spontaneous remission lasting for weeks, months or years. Usually, an attack is accompanied by nausea and vomiting with ataxia and nystagmus. Severe attacks may be accompanied by other symptoms of vagal disturbances such as abdominal cramps, diarrhoea, cold sweats, pallor and bradycardia. Usually, there is no warning symptom of an oncoming attack of vertigo but sometimes the patient may feel a sense of fullness in the ear, change in character of tinnitus or discomfort in the ear which herald an attack.

Some cases of Meniere's disease show *Tullio phenomenon*. It is a condition where loud sounds or noise produce vertigo and is due to the distended saccule lying against the stapes footplate. This phenomenon is also seen when there are three functioning windows in the ear, e.g. a fenestration of horizontal canal in the presence of a mobile stapes.

## **2. Hearing loss**

It usually accompanies vertigo or may precede it. Hearing improves after the attack and may be normal during the periods of remission. This fluctuating nature of hearing loss is quite characteristic of the disease. With recurrent attacks, improvement in hearing during remission may not be complete; some hearing loss being added in every attack leading to slow and progressive deterioration of hearing which is permanent.

*Distortion of sound.* Some patients complain of distorted hearing. A tone of a particular frequency may appear normal in one ear and of higher pitch in the other leading to *dipacusis*. Music appears discordant.

*Intolerance to loud sounds.* Patients of Meniere's disease cannot tolerate amplification of sound due to recruitment phenomenon. They are poor candidates for hearing aids.

## **3. Tinnitus**

It is low-pitched roaring type, and is aggravated during acute attacks. Sometimes, it has a hissing character. It may persist during periods of remission. Change in intensity and pitch of tinnitus may be the warning symptom of attack.

## **4. Sense of fullness or pressure**

Like other symptoms, it also fluctuates. It may accompany or precede an attack of vertigo.

## **5. Other features**

Patients of Meniere's disease often show signs of emotional upset due to apprehension of the repetition of attacks. Earlier, the emotional stress was considered to be the cause of Meniere's disease.



# Examination

## ***Otoscopy***

No abnormality is seen in the tympanic membrane.

## ***Nystagmus***

It is seen only during acute attack. The quick component of nystagmus is towards the unaffected ear.

## ***Tuning fork tests***

They indicate sensorineural hearing loss. Rinne test is positive, absolute bone conduction is reduced in the affected ear and Weber is lateralised to the better ear.

# Investigations

## 1. Pure tone audiometry

There is sensorineural hearing loss. In early stages, lower frequencies are affected and the curve is of rising type. When higher frequencies are involved curve becomes flat or a falling type (Fig. 15.3).

## 2. Speech audiometry

Discrimination score is usually 55-85% between the attacks but discrimination ability is much impaired during and immediately following an attack.

## 3. Special audiometry tests

They indicate the cochlear nature of disease and thus help to differentiate from retrocochlear lesions, e.g. acoustic neuroma (Table 15.1).

- (a) *Recruitment test* is positive.
- (b) *SISI (short increment sensitivity index) test*. SISI score is better than 70% in two-thirds of the patients (Normal 15%).
- (c) *Tone decay test*. Normally, there is decay of less than 20 dB.

## 4. Electrocochleography

It shows changes diagnostic of Meniere's disease. Normally, ratio of summing potential (SP) to action potential (AP) is 30%. In Meniere's disease, SP/AP ratio is greater than 30% (Fig. 15.4).

Table 15-1. Results of various tests to differentiate a cochlear from a retrocochlear lesion

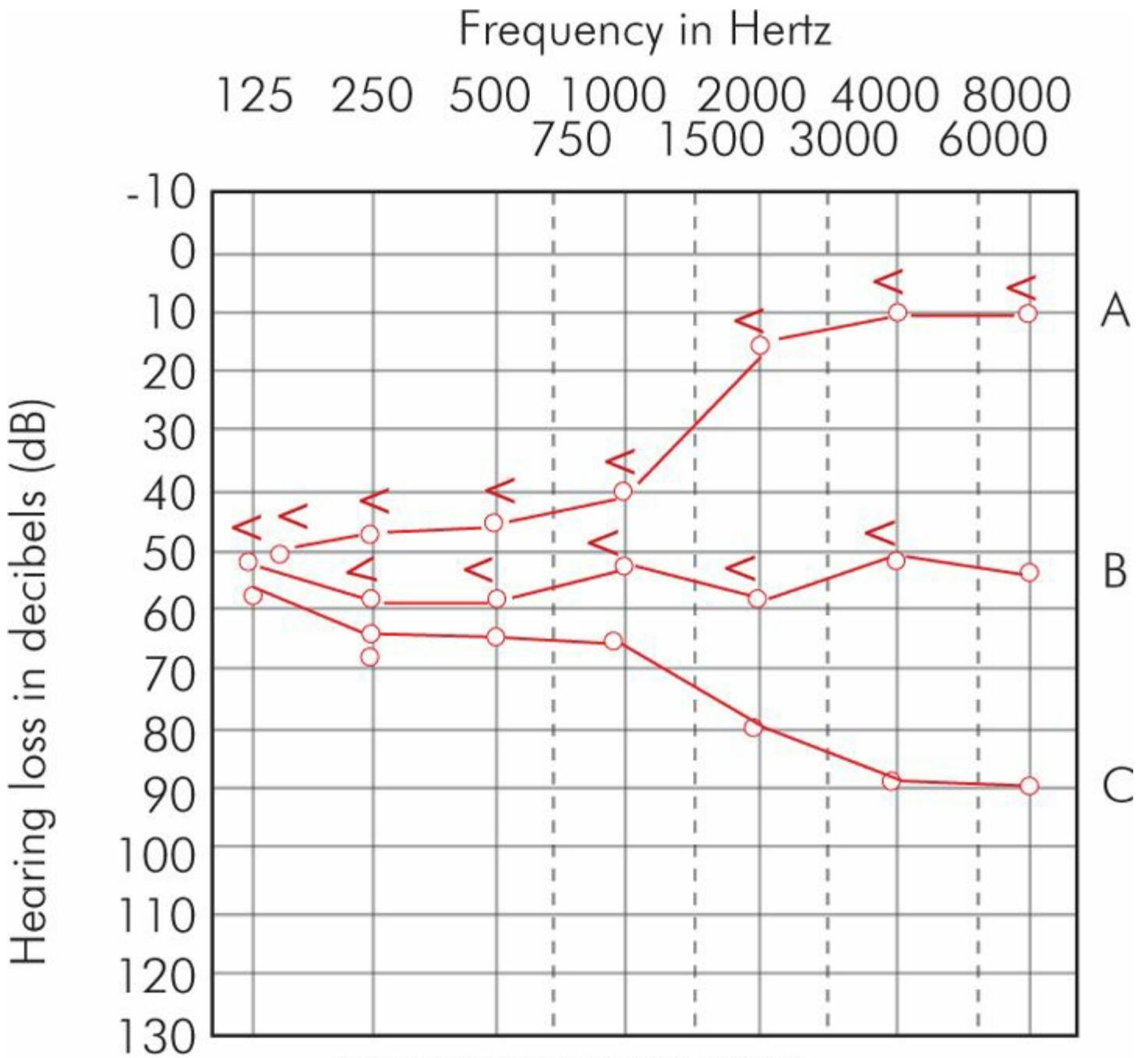
	Normal	Cochlear lesion	Retrocochlear lesion
• Pure tone audiogram	Normal	Sensorineural hearing loss	Sensorineural hearing loss
• Speech discrimination score	90-100%	Below 90%	Very poor
• Roll over phenomenon	Absent	Absent	Present
• Recruitment	Absent	Present	Absent
• SISI score	0-15%	Over 70%	0-20%
• Threshold tone decay test	0-15 dB	Less than 25 dB	Above 25 dB
• Stapedial reflex	Present	Present	Absent
• Stapedial reflex decay (page 109)	Normal	Normal	Abnormal
• E.R.A	Normal interval between wave I & V	Normal interval between wave I & V	Wave V delayed or absent

## 5. Caloric test

It shows reduced response on the affected side in 75% of cases. Often, it reveals a canal paresis on the affected side (most common) but sometimes there is directional preponderance to healthy side or a combination of both canal paresis on the affected side and directional preponderance on the opposite side.

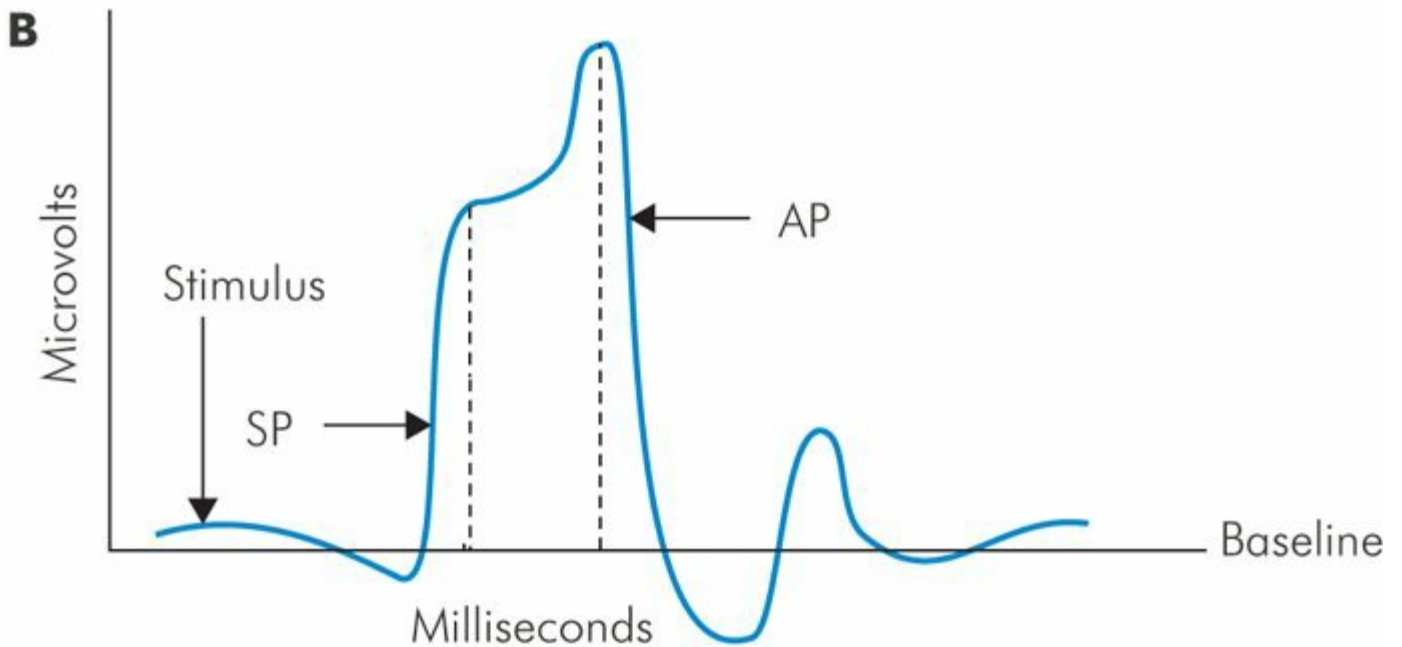
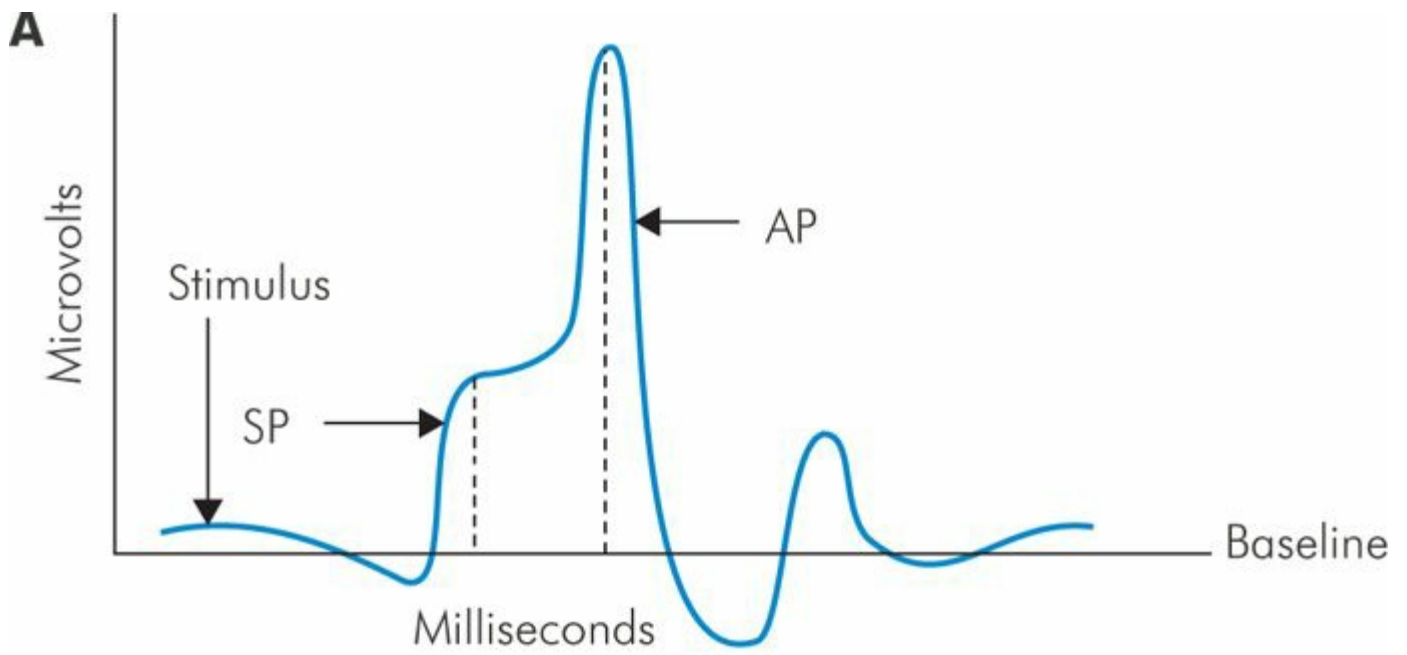
## 6. Glycerol test

Glycerol is a dehydrating agent. When given orally, it reduces endolymph pressure and thus causes an improvement in hearing.



Dhingra: Diseases of Ear Nose and Throat, 5th Edition  
 Copyright © 2010 Elsevier. All rights reserved.

Figure 15.3 (A) Audiogram in early Meniere's disease. Note: Hearing loss is sensorineural and more in lower frequencies-the rising curve. As the disease progresses, middle and higher frequencies get involved and audiogram becomes flat or falling type (B & C).



Dhingra: Diseases of Ear Nose and Throat, 5th Edition  
 Copyright © 2010 Elsevier. All rights reserved.

Figure 15.4 Electrocochleography . (A) Normal ear; (B) Ear with Meniere's disease. Voltage of summing potential (SP) is compared with that of action potential (AP). Normally SP is 30% of AP. This ratio is enhanced in Meniere's disease.

Patient is given glycerol (1.5 ml/kg) with an equal amount of water and a little flavouring agent or lemon juice. Audiogram and speech discrimination scores are recorded before and 1-2 hours after ingestion of glycerol. An improvement of 10 dB in two or more adjacent octaves or gain of 10% in discrimination score makes the test positive. There is also improvement in tinnitus and in the sense of fullness in the ear. The test has a diagnostic and prognostic value. These days, glycerol test is combined with electrocochleography.

## Variants of Meniere's Disease

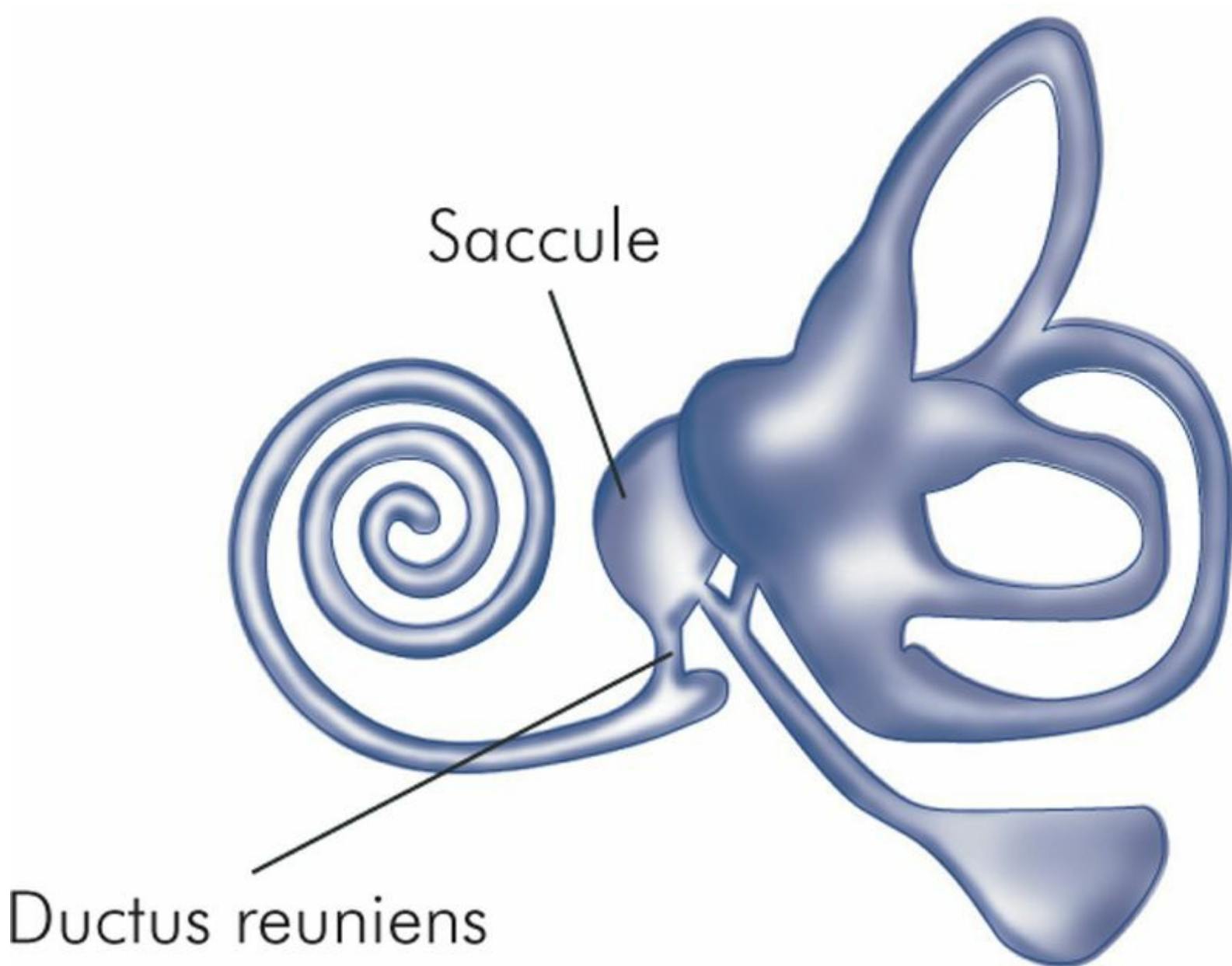
### ***Cochlear hydrops***

Here, only the cochlear symptoms and signs of Meniere's disease are present. Vertigo is absent. It is only after several years that vertigo will make its appearance. It is believed that in these cases, there is block at the level of ductus reuniens, thereby confining the increased endolymph pressure to the cochlea only (Fig. 15.5).

### ***Vestibular hydrops***

Patient gets typical attacks of episodic vertigo while cochlear functions remain normal. It is only with time that a typical picture of Meniere's disease will develop. Many of the cases of vestibular Meniere's disease are labelled "recurrent vestibulopathy" as endolymphatic hydrops could not be demonstrated in the study of temporal bones in such cases.

### ***Drop attacks (Tumarkin's otolithic crisis)***



Dhingra: Diseases of Ear Nose and Throat, 5th Edition  
Copyright © 2010 Elsevier. All rights reserved.

Figure 15.5 Left membranous labyrinth.

In this, there is a sudden drop attack without loss of consciousness. There is no vertigo or fluctuations in hearing loss. Patient gets a feeling of having been pushed to the ground or poleaxed. It is an uncommon manifestation of Meniere's disease and occurs either in the early or late course of disease. Possible mechanism is deformation of the otolithic membrane of the utricle or saccule due to changes in the endolymphatic pressure.

### ***Lermoyez syndrome***

## Meniere's Disease vs Meniere's Syndrome

Meniere's disease is an idiopathic condition while Meniere's syndrome, though resembling Meniere's disease clinically (episodic vertigo, fluctuating hearing loss, tinnitus and ear fullness), results from a variety of conditions such as trauma (head injury or ear surgery), viral infections (following measles or mumps), syphilis (congenital or late acquired), Cogan's syndrome, otosclerosis or autoimmune disorders. It is also called secondary Meniere's disease.

Committee on Hearing and Equilibrium of the American Academy of Otolaryngology-Head and Neck Surgery (AAOHNS) classified the diagnosis of Meniere's disease as follows:

- **1. Certain:** Definite Meniere's disease confirmed by histopathology.
- **2. Definite:** Two or more definitive spontaneous episodes of vertigo lasting 20 minutes or longer.
  - Audiometrically documented hearing loss on at least one occasion.
  - Tinnitus or aural fullness in the affected ear.
  - All other causes excluded.
- **3. Probable**
  - One definitive episode of vertigo.
  - Audiometrically documented hearing loss on at least one occasion.
  - Tinnitus or aural fullness in the treated ear.
  - Other causes excluded.
- **4. Possible**
  - Episodic vertigo of Meniere's type without documented hearing loss (vestibular variant) or
  - Sensorineural hearing loss, fluctuating or fixed, with disequilibrium but without definitive episodes (cochlear variant).
  - Other causes excluded.

**Table 15-2. Staging of Meniere's disease**

Stage	Pure tone average in dB in previous 6 months
1	≤ 25
2	26-40
3	41-70
4	> 70

## Staging of Meniere's Disease

This can be done in certain and definite cases of Meniere's disease. It is based on average of the pure tone thresholds at 0.5, 1, 2, 3 kHz (rounded to nearest whole) of the worst audiogram during interval of 6 months before treatment (see Table 15.2).



# Treatment

## A. General Measures

### 1. Reassurance

Patient's anxiety can be relieved by reassurance and by explaining the true nature of disease. This is particularly important in acute attack.

### 2. Cessation of smoking

Nicotine causes vasospasm. Smoking should be completely stopped. For some patients, this may be the only treatment necessary.

### 3. Low salt diet

Patient should take salt-free diet as far as possible. No extra salt should be permitted. Salt intake should not exceed 1.5-2.0 g/day.

### 4

Avoid excessive intake of water

### 5

Avoid over-indulgence in coffee, tea and alcohol

### 6

Avoid stress and bring a change in life-style Mental relaxation exercises and yoga are helpful to decrease stress.

### 7. Avoid activities requiring good body balance

As the attack of Meniere's disease is abrupt, sometimes with no warning symptom, professions such as flying, under-water diving or working at great heights should be avoided.

## B. Management of Acute Attack

During the acute attack, there is severe vertigo with nausea and vomiting. Patient is apprehensive. Head movements provoke giddiness. Therefore, treatment would consist of:

### 1. Reassurance

and psychological support to allay worry and anxiety.

### 2. Bed rest

with head supported on pillows to prevent excessive movements.

### 3. Vestibular sedatives

to relieve vertigo. They should be administered intramuscularly or intravenously if vomiting precludes oral administration. Drugs useful in acute attack are dimenhydrinate (Dramamine), promethazine theoclate (Avomine) or prochlorperazine (Stemetil).

Diazepam (Valium or Calmpose) 5-10 mg may be given intravenously. It has a tranquillizing effect and also suppresses the activity of medial vestibular nucleus.

In some patients, acute attack can be stopped by atropine, 0.4 mg, given subcutaneously.

### 4. Vasodilators

- (i) *Inhalation of carbogen* (5% CO<sub>2</sub> with 95% O<sub>2</sub>). It is a good cerebral vasodilator and improves labyrinthine circulation.
- (ii) *Histamine drip*. Histamine diphosphate, 2.75 mg dissolved in 500 ml of glucose, given as i.v. drip at a slow rate is also a good vasodilator and helps to control acute attacks. Adverse effects of histamine include tachycardia, disturbances of cardiac rhythm, hypotension, hyperthermia and bronchospasm. It should not be used on empty stomach and is contraindicated in asthmatics.

## C. Management of Chronic Phase

When patient presents after the acute attack, the treatment consists of:

### 1. Vestibular sedatives

Prochlorperazine (Stemetil) 10 mg, thrice a day, orally for two months and then reduced to 5 mg thrice a day for another month.

## 2. Vasodilators

Nicotinic acid, 50 mg, is taken about an hour before meals thrice a day. The dose can be increased slowly to achieve flushing of skin.

Betahistine (Vertin) 8-16 mg, thrice a day, given orally, also increases labyrinthine blood flow by releasing histamine in the body.

## 3. Diuretics

Sometimes, diuretic Furosemide, 40 mg tablet, taken on alternate days with potassium supplement helps to control recurrent attacks, if not controlled by vasodilators or vestibular sedatives.

## 4. Propantheline bromide

(Probanthine), 15 mg, thrice a day, can be given alone or in combination with vasodilator and is quite effective.

## 5. Elimination of allergen

Sometimes, a food or inhalant allergen is responsible for such attacks. It should be found and eliminated or desensitisation done.

## 6. Hormones

page 115

page 116

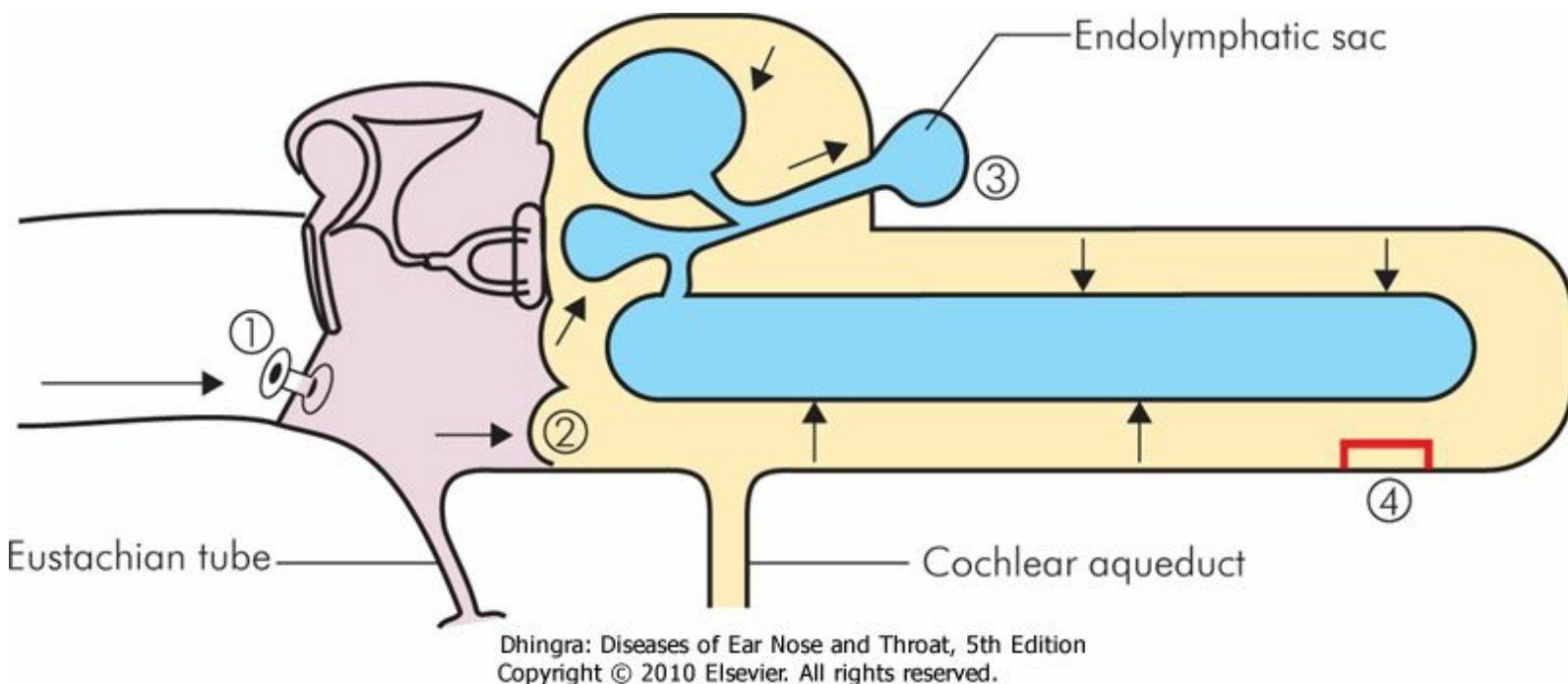


Figure 15.6 Mechanism of intermittent low pressure pulse therapy. Pressure waves pass through ventilation tube (1) to round window membrane (2) and transmitted to perilymph (yellow) and compress endolymphatic labyrinth (blue) to redistribute endolymph pressure to sac (3) and blood vessels (4).

Investigations should be directed to find any endocrinal disorder such as hypothyroidism, and appropriate replacement therapy given. Control of stress by change in life-style is important to prevent recurrent attacks. About 80% of the patients can be effectively managed by medical therapy alone.

### Intratympanic gentamicin therapy

(chemical labyrinthectomy). Gentamicin is mainly vestibulotoxic. It has been used in daily or biweekly injections into the middle ear. Drug is absorbed through the round window and causes destruction of the vestibular labyrinth. Total control of vertigo spells has been reported in 60-80% of patients with some relief from symptoms in others. Hearing loss, sometimes severe and profound, has been reported in 4-30% of patients treated with this mode of therapy.

## D. Surgical Treatment

It is used only when medical treatment fails.

### 1. Conservative procedures

They are used in cases where vertigo is disabling but hearing is still useful and needs to be preserved. They are:

- (i) *Decompression of endolymphatic sac.*

- **(ii) Endolymphatic shunt operation.** A tube is put, connecting endolymphatic sac with subarachnoid space, to drain excess endolymph.
- **(iii) Sacculotomy (Fick's operation).** It is puncturing the sacculle with a needle through stapes footplate. A distended sacculle lies close to stapes footplate and can be easily penetrated. Cody's tack procedure consists of placing a stainless steel tack through the stapes footplate. The tack would cause periodic decompression of the sacculle when it gets distended. Both these operations were claimed to have shown good results but they could not be reproduced by others and thus abandoned. Cochleosacculotomy is another similar procedure in which, instead of sacculle, cochlear duct is punctured and drained into the perilymph (otic-periotic shunt). The procedure is performed with a curved needle passed through the round window to puncture cochlear duct.
- **(iv) Section of vestibular nerve.** The nerve is exposed by retrosigmoid or middle cranial fossa approach and selectively sectioned. It controls vertigo but preserves hearing.
- **(v) Ultrasonic destruction of vestibular labyrinth.** Cochlear function is preserved.

## **2. Destructive procedures**

They totally destroy cochlear and vestibular function and are thus used only when cochlear function is not serviceable.

*Labyrinthectomy.* Membranous labyrinth is completely destroyed either by opening through the lateral semicircular canal by transmastoid route or through the oval window by a transcanal approach. This gives relief from the attacks of vertigo.

*Intermittent low pressure pulse therapy [Meniett device therapy (Fig. 15.6)].* It is observed that intermittent positive pressure delivered to inner ear fluids brings relief from the symptoms of Meniere's disease. Not only there is improvement in vertigo, tinnitus and ear fullness, but hearing may also improve. Intermittent positive pressure waves can be delivered through an instrument called Meniett device which has been approved by FDA. A prerequisite for such a therapy is to perform a myringotomy and insert a ventilation tube so that the device when coupled to the external ear canal can deliver pressure waves to the round window membrane via the ventilation tube. Pressure waves pass through the perilymph and cause reduction in endolymph pressure by redistributing it through various communication channels such as the endolymphatic sac or the blood vessels (Fig. 15.6). Some believe they regulate secretion of endolymph by the stria vascularis.

Patient can self-administer the treatment at home. It may require a few months before complete remission of disease is obtained. Meniett device therapy has been recommended for patients who have failed medical treatment and the surgical options are being considered.

## 16 Tumours of External Ear

Of all the cases of ear carcinoma, 85% occur on the pinna, 10% in the external canal and 5% in the middle ear.

Tumours of the external ear may arise from the pinna or external auditory canal (Table 16.1).

# TUMOURS OF AURICLE

## Benign Tumours

### 1. Preauricular sinus or cyst

This results from faulty union of hillocks of the 1st and 2nd branchial arches during the development of pinna. Preauricular sinus presents as a small opening in front of the crus of helix. It has a branching tract lined by squamous epithelium which when blocked results in a retention cyst. Patient usually presents with a cyst which is infected. Surgery is indicated if there is unsightly swelling or infection. Cyst or sinus tract must be excised completely to avoid recurrence.

Table 16-1. Tumours of external ear

Pinna	External ear canal
<p><i>Benign</i></p> <ul style="list-style-type: none"> <li>• Preauricular cyst or sinus</li> <li>• Sebaceous cyst</li> <li>• Dermoid cyst</li> <li>• Keloid</li> <li>• Haemangioma</li> <li>• Papilloma</li> <li>• Cutaneous horn</li> <li>• Keratoacanthoma</li> <li>• Neurofibroma</li> </ul> <p><i>Malignant</i></p> <ul style="list-style-type: none"> <li>• Squamous cell carcinoma</li> <li>• Basal cell carcinoma</li> <li>• Melanoma</li> </ul>	<p><i>Benign</i></p> <ul style="list-style-type: none"> <li>• Osteoma</li> <li>• Exostosis</li> <li>• Ceruminoma</li> <li>• Sebaceous adenoma</li> <li>• Papilloma</li> </ul> <p><i>Malignant</i></p> <ul style="list-style-type: none"> <li>• Squamous cell carcinoma</li> <li>• Basal cell carcinoma</li> <li>• Adenocarcinoma</li> <li>• Malignant ceruminoma</li> <li>• Melanoma</li> </ul>

### 2. Sebaceous cyst

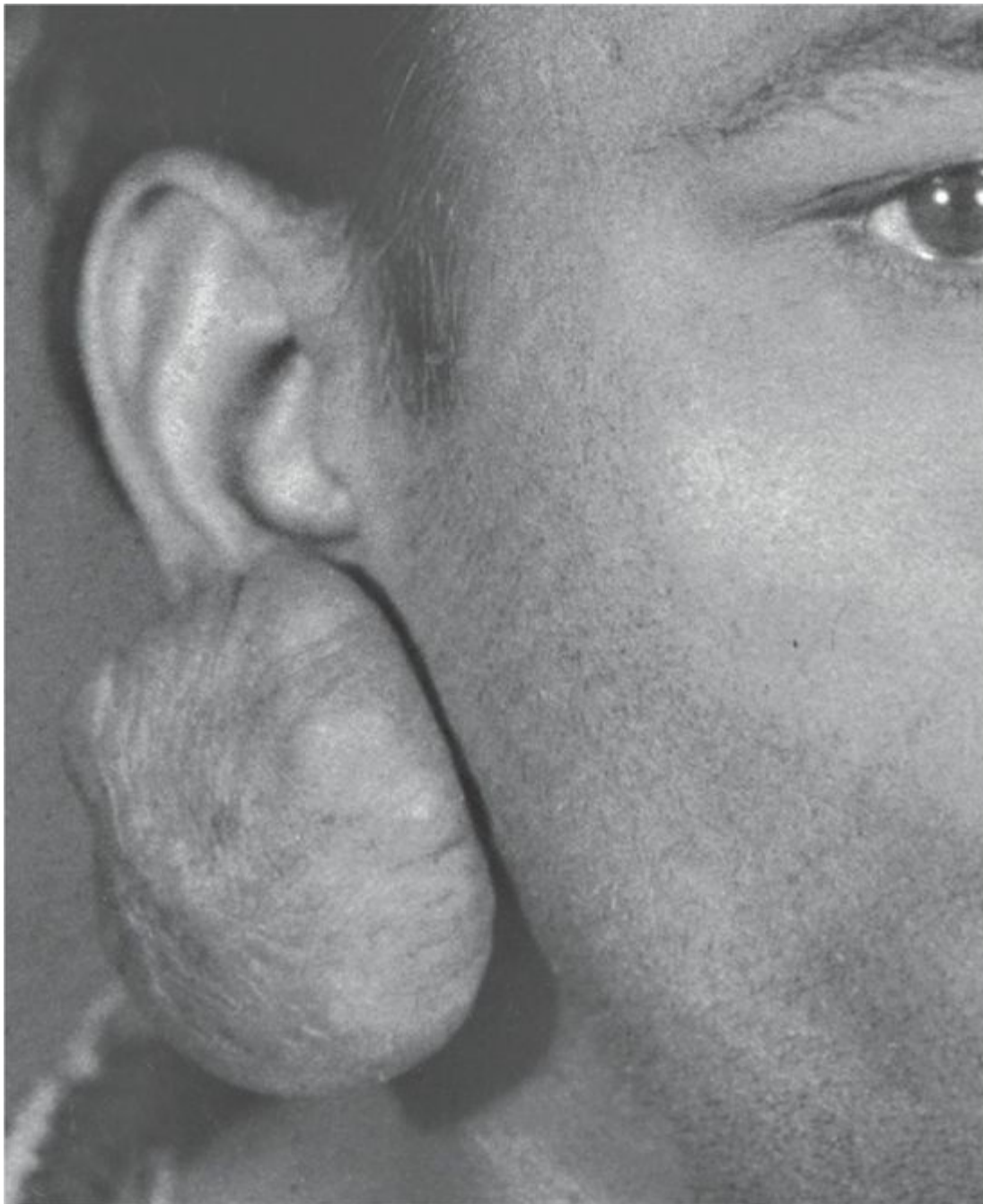Common site is postauricular sulcus or below and behind the ear lobule. Treatment is total surgical excision.

### 3. Dermoid cyst

Usually presents as a rounded mass over the upper part of mastoid behind the pinna.

### 4. Keloid

It often follows trauma such as piercing the ear lobule for ornaments or a surgical incision (Fig. 16.1). There is a genetic susceptibility. Black races are more often affected. Keloid presents as a pedunculated tumour. Treatment is surgical excision with injection of triamcinolone into the surgical site or immediate post-operative radiation of 300 rads.



Dhingra: Diseases of Ear Nose and Throat, 5th Edition  
Copyright © 2010 Elsevier. All rights reserved.

Figure 16.1 Keloid following piercing of ear lobule for an ear ring.

## 5. Haemangiomas

They are congenital tumours often seen in childhood. Other parts of face and neck may also be involved. They are of two types:

- **(a) Capillary haemangioma.** It is a mass of capillary-sized blood vessels and may present as a "port-wine stain". It does not regress spontaneously.
- **(b) Cavemous haemangioma** (also called strawberry tumour). It consists of endothelial-lined spaces filled with blood. It increases rapidly during the first year but regresses thereafter and may completely disappear by the fifth year.

## 6. Papilloma (wart)

It may present as a tufted growth or flat grey plaque and is rough to feel. It is viral in origin. Treatment is surgical excision or curettage with cauterisation of its base.

## 7. Cutaneous horn

It is a form of papilloma with heaping up of keratin and presents as horn-shaped tumour. It is often seen at the rim of helix in elderly people.

Treatment is surgical excision.

### **8. Keratoacanthoma**

It is a benign tumour clinically resembling a malignant one. It presents as a raised nodule with a central crater. Initially, it grows rapidly but slowly regresses leaving a scar. Treatment is excision biopsy.

### **9. Neurofibroma**

It presents as a non-tender, firm swelling and may be associated with von Recklinghausen's disease. Treatment is surgical excision, if tumour occludes ear canal or presents a cosmetic problem.

# Malignant Tumours

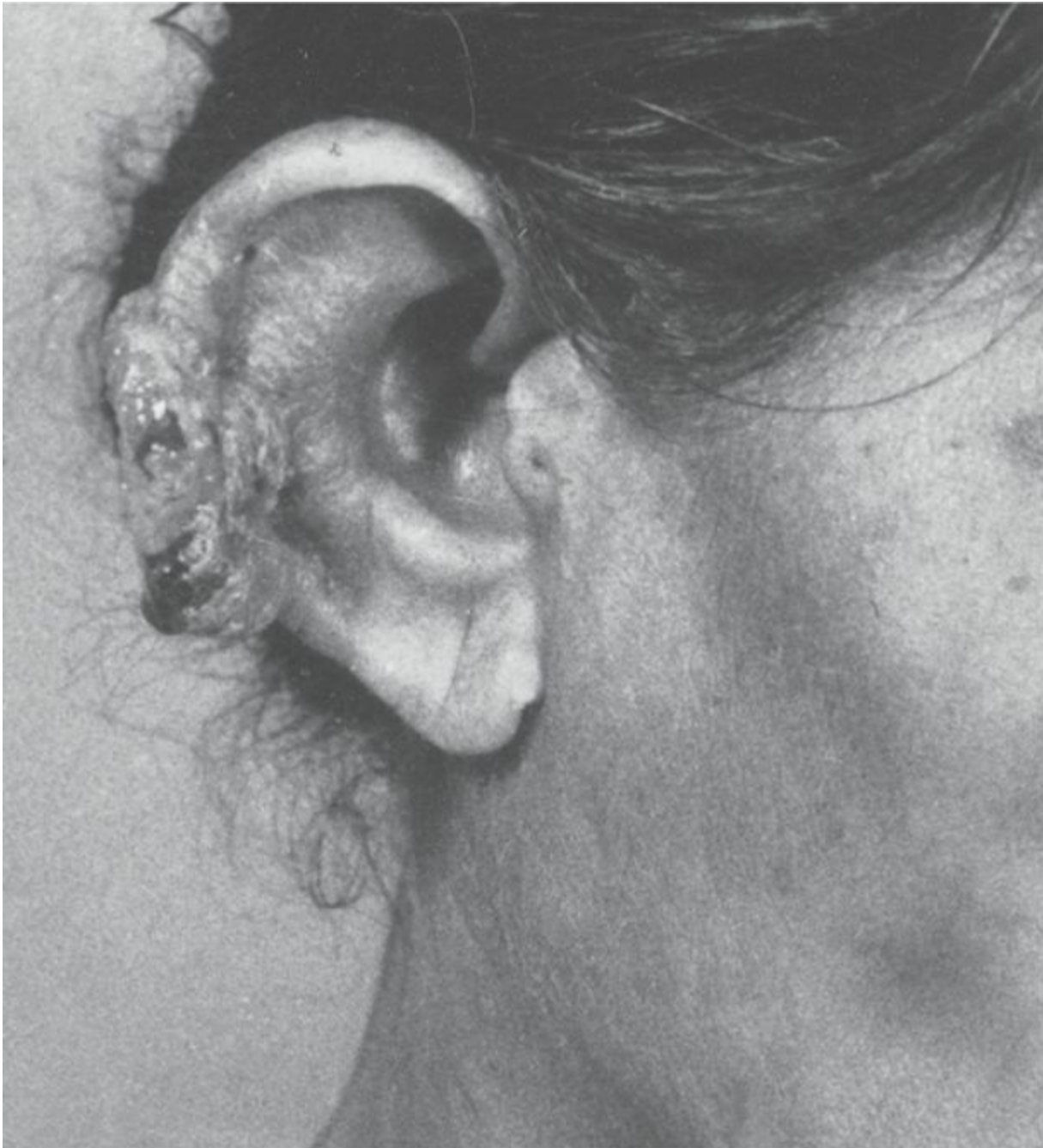## 1. Squamous cell carcinoma

The site of predilection is the helix (Fig. 16.2). It may present as a painless nodule or an ulcer with raised everted edges and indurated base. Metastases to regional lymph nodes occur very late. Disease is more common in males in their fifties who had prolonged exposure to direct sunlight. Fair-complexioned people are more prone.

*Treatment.* Small lesions with no nodal metastases are excised locally with 1 cm of healthy area around it. Larger lesions of the pinna or those coming within 1 cm of external auditory canal and lesions with nodal metastases, may require total amputation of the pinna, often with en bloc removal of parotid gland and cervical lymph nodes.

## 2. Basal cell carcinoma

The common sites are the helix and the tragus. It is more common in men beyond 50 years of age. It presents as a nodule with central crust, removal of which results in bleeding. Ulcer has a raised or beaded edge. Lesion often extends circumferentially into the skin but may penetrate deeper, involving cartilage or bone. Lymph node metastases usually do not occur.



Dhingra: Diseases of Ear Nose and Throat, 5th Edition  
Copyright © 2010 Elsevier. All rights reserved.

Figure 16.2 Squamous cell carcinoma of pinna.

*Treatment.* Superficial lesions, not involving cartilage, can be irradiated and cosmetic deformity avoided. Lesions involving cartilage may require



surgical excision as in cases of squamous cell carcinoma.

### **3. Melanoma**

It may occur anywhere over the auricle. It is more common in men of light complexion who are exposed to sun. Metastases are seen in 16-50% of the cases.

*Treatment.* Superficial melanoma, less than 1 cm in diameter, situated over the helix, is managed by wedge resection and primary closure.

Superficial melanoma, larger than 1 cm, infiltrative melanomas, melanoma of posterior auricular surface or concha and all recurrent melanomas are treated by resection of pinna, parotidectomy and radical neck dissection.

# TUMOURS OF EXTERNAL AUDITORY CANAL

## Benign Tumours

### 1. Osteoma

It arises from cancellous bone and presents as a single, smooth, bony, hard, pedunculated tumour, often arising from the posterior wall of the osseous meatus, near its outer end. Treatment is surgical removal by fracturing through its pedicle or removal with a drill.

### 2. Exostoses

page 118

page 119

They are multiple and bilateral, often presenting as smooth, sessile, bony swellings in the deeper part of the meatus near the tympanic membrane. They arise from compact bone. Exostosis is often seen in persons exposed to entry of cold water in the meatus as in divers and swimmers. Males are affected three times more than females.

*Treatment.* When small and asymptomatic, no treatment is necessary. Larger ones, which impair hearing or cause retention of wax and debris, may be removed with high speed drill to restore normal sized meatus. Exostoses may extend deeply and lie in close relation to the facial nerve. Therefore, use of gouge and hammer should be avoided.

### 3. Ceruminoma

It is a tumour of modified sweat glands which secrete cerumen. It presents as a smooth, firm, skin-covered polypoid swelling in outer part of the meatus, generally attached to the posterior or inferior wall. It obstructs the meatus leading to retention of wax and debris. Malignant type outnumbers the benign by 2:1 ratio.

*Treatment.* Tumour has a tendency to recur, therefore wide surgical excision should be done and patient regularly followed up. Some of the ceruminomas are malignant and if there is any suspicion of malignancy on histology, post-operative radiotherapy should be given.

### 4. Sebaceous adenoma

It arises from sebaceous glands of the meatus and presents as a smooth, skin-covered swelling in the outer meatus. Treatment is surgical excision.

### 5. Papilloma

Similar to the one seen on the pinna.

# Malignant Tumours

## **1. Squamous cell carcinoma**

Most often, it is seen in cases of long-standing ear discharge. It may arise primarily from the meatus or be a secondary extension from the middle ear carcinoma.

Presenting symptoms are: blood staining of hitherto mucopurulent or purulent discharge and severe earache.

Examination may show an ulcerated area in the meatus or a bleeding polypoid mass or granulations. Facial nerve may be paralysed because of local extension of disease through posterior meatal wall or its spread into the middle ear. Regional lymph nodes (preauricular, postauricular, infra-auricular and upper deep cervical) may be involved.

Treatment is en bloc wide surgical excision with post-operative radiation.

## **2. Basal cell and adenocarcinomas**

They can rarely arise from the meatus. Clinical picture is similar to that of squamous cell variety. Diagnosis is made only on biopsy. Treatment is wide surgical excision and post-operative radiation.

## **3. Malignant ceruminoma**

Malignant type is twice as common as benign.

## **4. Malignant melanoma**

Rare tumour.

# 17 Tumours of Middle Ear and Mastoid

## CLASSIFICATION

Tumours of middle ear and mastoid can be divided into:

### 1. Primary Tumours

- Benign: Glomus tumour
- Malignant: Carcinoma, sarcoma

### 2. Secondary Tumours

- **(a)** From adjacent areas, e.g. nasopharynx, external meatus and the parotid.
- **(b)** Metastatic, e.g. from carcinoma of bronchus, breast, kidney, thyroid, prostate and gastrointestinal tract.

## **GLOMUS TUMOUR**

It is the most common benign neoplasm of middle ear and is so-named because of its origin from the glomus bodies. The latter resemble carotid body in structure and are found in the dome of jugular bulb or on the promontory along the course of tympanic branch of IXth cranial nerve (Jacobson's nerve). The tumour consists of paraganglionic cells derived from the neural crest.

## Aetiology and Pathology

The tumour is often seen in the middle age (40-50 years). Females are affected five times more.

It is a benign, non-encapsulated but extremely vascular neoplasm. Its rate of growth is very slow and several years may pass before there is any change from the initial symptoms. Tumour is locally invasive.

Microscopically, it shows masses or sheets of epithelial cells which have large nuclei and a granular cytoplasm. There is abundance of thin-walled blood sinusoids with no contractile muscle coat, accounting for profuse bleeding from the tumours.

For purposes of diagnosis and treatment, two types are differentiated.

### **1. *Glomus jugulare***

They arise from the dome of jugular bulb, invade the hypotympanum and jugular foramen, causing neurological signs of IXth to XIIth cranial nerve involvement. They may compress jugular vein or invade its lumen.

### **2. *Glomus tympanicum***

They arise from the promontory of the middle ear and cause aural symptoms, sometimes with facial paralysis.

## Spread of Glomus Tumour

- 1. Tumour may initially fill the middle ear and later perforate through the tympanic membrane to present as a vascular polyp.
- 2. It may invade labyrinth, petrous pyramid and the mastoid.
- 3. It may invade jugular foramen and the base of skull, causing IXth to XIIth cranial nerve palsies.
- 4. By spread through eustachian tube, it may present in the nasopharynx.
- 5. It may spread intracranially to the posterior and middle cranial fossae.
- 6. Metastatic spread to lungs and bones is rare, but seen in 4% of cases. Metastatic lymph node enlargement can also occur.

## Clinical Features

In 90% of cases, symptoms pertain to the ear.

### **(a) When tumour is intratympanic**

Earliest symptoms are hearing loss and tinnitus. Hearing loss is conductive and slowly progressive. Tinnitus is pulsatile and of swishing character, synchronous with pulse, and can be temporarily stopped by carotid pressure.

page 120

page 121

Otoscopy shows a red reflex through intact tympanic membrane. "Rising sun" appearance is seen when tumour arises from the floor of middle ear. Sometimes, tympanic membrane appears bluish and may be bulging.

"Pulsation sign" (Brown's sign) is positive, i.e. when ear canal pressure is raised with Siegle's speculum, tumour pulsates vigorously and then blanches; reverse happens with release of pressure.

### **(b) When tumour presents as a polyp**

In addition to hearing loss and tinnitus, there is history of profuse bleeding from the ear either spontaneously or on attempts to clean it.

Dizziness or vertigo and facial paralysis may appear. Earache is less common than in carcinoma of the external and middle ear, and helps to differentiate it.

Otorrhoea may occur due to secondary infection and the condition may simulate chronic suppurative otitis media with polyp.

Examination reveals a red, vascular polyp filling the meatus. It bleeds readily and profusely on manipulation or at biopsy.

### **Cranial nerve palsies**

This is a late feature appearing several years after aural symptoms. IXth to XIIth cranial nerves may be paralysed. There is dysphagia and hoarseness with unilateral paralysis of the soft palate, pharynx and vocal cord with weakness of the trapezius and sternomastoid muscles.

Tumour may present as a mass over the mastoid or in the nasopharynx.

Signs of intracranial involvement may also occur.

### **Audible bruit**

At all stages, auscultation with stethoscope over the mastoid may reveal systolic bruit.

Some glomus tumours secrete catecholamines and produce symptoms like headache, sweating, palpitation, hypertension and anxiety, and require further investigations.

### **Rule of 10s**

Remember that 10% of the tumours are familial, 10% multicentric and up to 10% functional, i.e. they secrete catecholamines.

# Diagnosis

In addition to thorough history and physical examination, the patient is checked-up to find out the extent of tumour, other associated glomus tumours, and serum levels of catecholamines or their break-down products in urine (vanillylmandelic acid, metanephrine, etc.). Investigations include:

## ***CT scan-head***

Using bone window, 1 mm thin sections are cut. It helps to distinguish glomus tympanicum from the glomus jugulare tumour by identification of caroticojugular spine which is eroded in the latter. CT scan also helps to differentiate it from the aberrant carotid artery, high or dehiscent jugular bulb.

## ***MRI***

It gives soft tissue extent of tumour. Magnetic resonance angiography and venography further help to delineate invasion of jugular bulb and vein or compression of the carotid artery.

CT head and MRI combined together provide an excellent preoperative guidance in the differential diagnosis of petrous apex lesions.

## ***Four-vessel angiography***

It is necessary when CT head shows involvement of jugular bulb, carotid artery or intradural extension. It also helps to delineate any other glomus tumour (as they may be multiple), find the feeding vessels or embolization of tumour if required.

## ***Brain perfusion and flow studies***

They are necessary when tumour is pressing on internal carotid artery. If the case needs surgery, brain perfusion and adequacy of contralateral internal carotid artery and circle of Willis can be assessed. If needed, xenon blood flow and isotope studies are done for precise blood flow, and the risk of stroke and need for surgical replacement of internal carotid artery.

## ***Embolization***

In large tumours, embolization of feeding vessels 1-2 days before operation helps to reduce blood loss.

## ***Biopsy***

Preoperative biopsy of the tumour for diagnosis is ***never*** done. Clinical and radiologic features are very characteristic to make diagnosis. Tumour is very vascular and bleeds profusely. There is also likelihood of injuring the high jugular bulb or aberrant internal carotid artery if diagnosis is mistaken.



# Treatment

It consists of:

- 1. Surgical removal.
- 2. Radiation.
- 3. Embolisation.
- 4. Combination of the above techniques.

## Surgical approaches to glomus tumours

page 121

page 122

- **1. Transcanal approach** Suited for limited glomus tympanicum tumour where entire circumference of the tumour is visible, only tympanotomy will suffice.
- **2. Hypotympanic approach** Suited for tumours limited to promontory with extension to hypotympanum but not into the mastoid. A superiorly based tympanomeatal flap is raised by postauricular approach. Bony inferior tympanic ring is drilled away to see the lower limit of tumour.
- **3. Extended facial recess approach** Used for glomus tympanicum extending into mastoid but not into the jugular bulb. If extensive, modified radical operation is done.
- **4. Mastoid-neck approach** Used for glomus jugulare tumours not extending to internal carotid artery, posterior cranial fossa or neck.
- **5. Infratemporal fossa approach of Fisch** Used for large glomus jugulare tumours.
- **6. Transcondylar approach** Used for tumours extending towards foramen magnum. Usually they are recurrent glomus jugulare tumours. It gives approach to cranio-cervical junction with exposure of occipital condyle and jugular tubercle.

Radiation treatment does not cure the tumour but may reduce its vascularity and arrest its growth. Radiation is used for inoperable tumours, residual tumours, recurrences after surgery or for older individuals where extensive skull base surgery is not indicated.

Embolisation is used to reduce the vascularity of tumour before surgery, or is the sole treatment in inoperable patients who have received radiation.

## **CARCINOMA OF MIDDLE EAR AND MASTOID**

It is a rare condition, there being one case in 20,000 new patients examined, but it is the commonest primary middle ear malignancy.

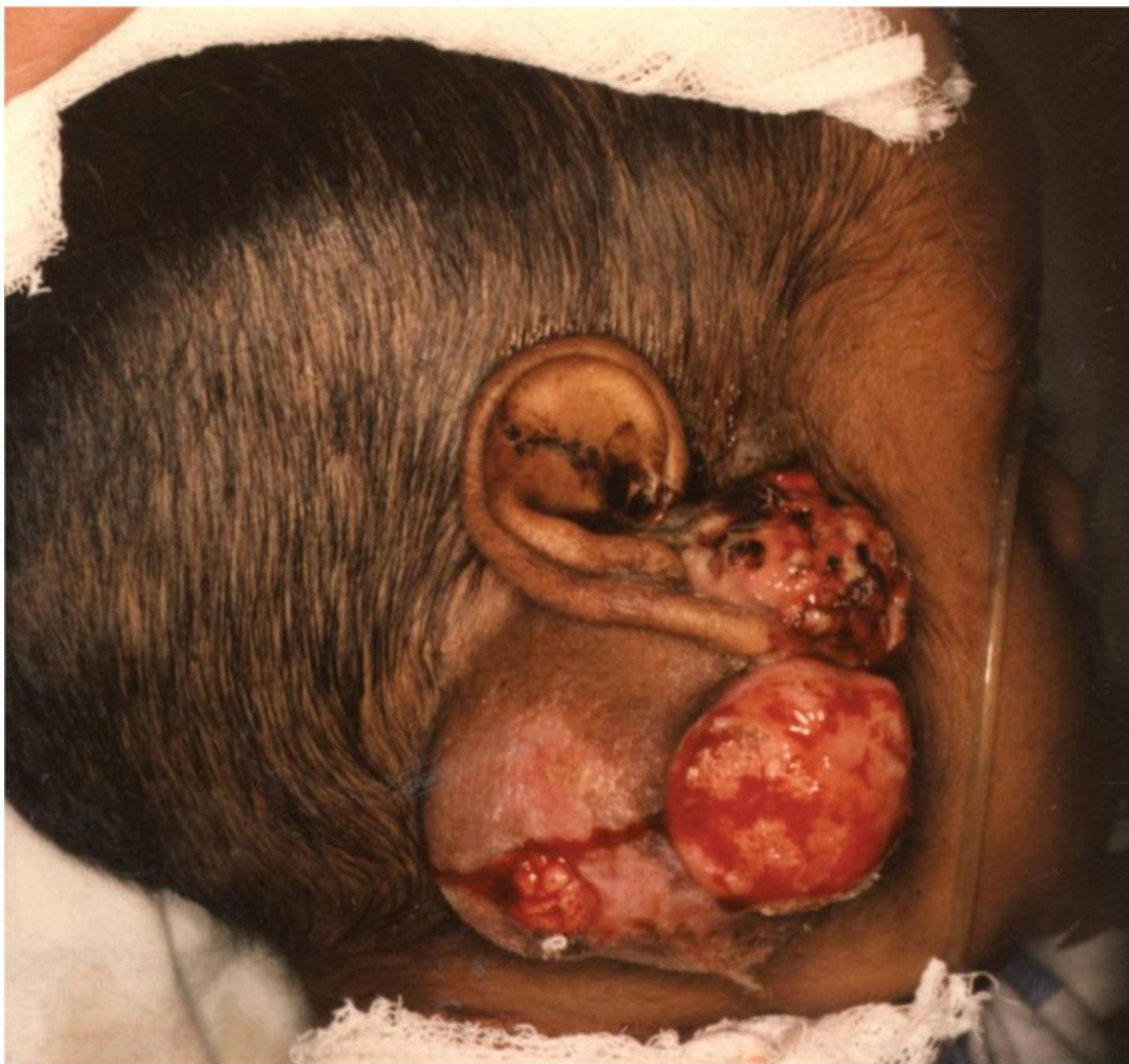## Aetiology

It affects age group of 40-60 and is slightly more common in females. Most cases (75%) have associated long-standing ear discharge. Chronic irritation may be the causative factor in such cases. Some cases are seen in radical mastoid cavities. Primary carcinoma of mastoid air cells is also seen in radium dial painters.

## Pathology

Tumour may arise primarily from middle ear or be an extension of carcinoma of the deep meatus. Squamous cell variety is by far the most common (Fig. 17.1). Adenocarcinoma may occasionally be seen; it arises from the glandular elements of middle ear.

### *Spread of tumour*



Dhingra: Diseases of Ear Nose and Throat, 5th Edition  
Copyright © 2010 Elsevier. All rights reserved.

Figure 17.1 Squamous cell carcinoma of middle ear and mastoid in a 3-year-old child. He also had facial paralysis.

To begin with, carcinoma destroys ossicles, facial canal, internal ear, jugular bulb, carotid canal or deep bony meatus and mastoid. It may spread in petrous pyramid towards its apex. Dura is usually resistant. It may spread to the parotid gland, temporomandibular joint, infratemporal fossa and down the eustachian tube to nasopharynx. Lymph node enlargement occurs late.

## Clinical Features

Patient often presents with clinical picture simulating chronic suppurative otitis media. However, the following features in age group of 40-60 years may arouse suspicion of malignancy:

- **(a)** Chronic foul-smelling discharge especially when blood-stained.
- **(b)** Pain which is usually severe and comes at night.
- **(c)** Facial palsy.
- **(d)** Friable, haemorrhagic granulations or polyp.
- **(e)** Appearance of or increase in hearing loss or vertigo.

## Diagnosis

Definitive diagnosis is made only on biopsy. Extent of disease is judged by clinical and radiological examination. CT scan and angiography are useful in the assessment of disease.

A combination of surgery and radiotherapy gives better results. Surgery consists of radical mastoidectomy, subtotal or total petrosectomy, depending on the extent of tumour.

Radiotherapy alone is given as a palliative measure when tumour involves cranial nerves (IXth to XIIth) or spreads into the cranial cavity or the nasopharynx.

# **SARCOMAS**

## ***Rhabdomyosarcoma***

It is a rare tumour, mostly affecting children. It arises from the embryonic muscles tissue or the pluripotential mesenchyme. In early stages, it mimics chronic suppurative otitis media with ear discharge, polyp or granulations. Facial palsy occurs early. Diagnosis is made only on biopsy. Prognosis is poor. A combination of radiation and chemotherapy is the treatment of choice. Surgery is done in selected localised lesions.

## ***Other sarcomas***

Osteosarcoma, lymphoma, fibrosarcoma and chondrosarcoma are rare. Distant metastases are seen in the lungs or bone. Prognosis is poor.



## **SECONDARY TUMOURS**

Tumours of external auditory meatus, parotid gland or nasopharynx may invade middle ear cleft either through the preformed pathways or bone erosion.

Sometimes, temporal bone is the site of distant metastases in advanced cases of carcinoma of the breast, bronchus, prostate, kidney or gastrointestinal tract.

Acoustic neuroma is also known as vestibular schwannoma, neurilemmoma or eighth nerve tumour.

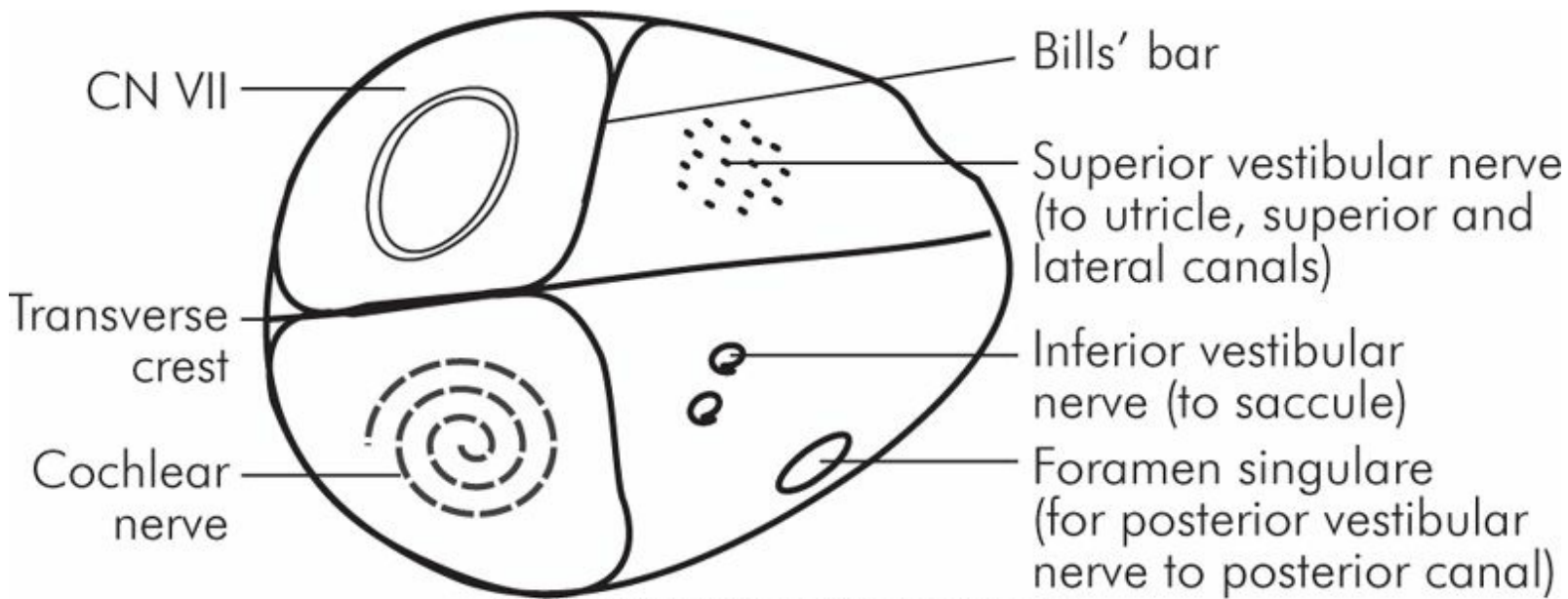
## Incidence

Acoustic neuroma constitutes 80% of all cerebellopontine angle tumours and 10% of all the brain tumours.

## Pathology

It is a benign, encapsulated, extremely slow-growing tumour of the 8th nerve. Microscopically, it consists of elongated spindle cells with rod-shaped nuclei lying in rows or palisades. Bilateral tumours are seen in patients with neurofibromatosis.

# Origin and Growth of Tumour



Dhingra: Diseases of Ear Nose and Throat, 5th Edition  
Copyright © 2010 Elsevier. All rights reserved.

Figure 18.1 Inner aspect of lateral end of internal auditory canal with structures passing through different areas.

The tumour almost always arises from the Schwann cells of the vestibular, but rarely from the cochlear division of VIIIth nerve within the internal auditory canal (Fig. 18.1). As it expands, it causes widening and erosion of the canal and then appears in the cerebellopontine angle. Here, it may grow anterosuperiorly to involve Vth nerve or inferiorly to involve the IXth, Xth and XIth cranial nerves. In later stages, it causes displacement of brainstem, pressure on cerebellum and raised intracranial tension (Fig. 18.2). The growth of the tumour is extremely slow and the history may extend over several years.

# Classification

Depending on the size, the tumour is classified as:

- **(a)** Intracanalicular (when it is confined to internal auditory canal)
- **(b)** Small size (up to 1.5 cm)
- **(c)** Medium size (1.5 to 4 cm)
- **(d)** Large size (over 4 cm)

# Clinical Features

## **1. Age and sex**

Tumour is mostly seen in age group of 40-60 years. Both sexes are equally affected.

## **2. Cochleovestibular symptoms**

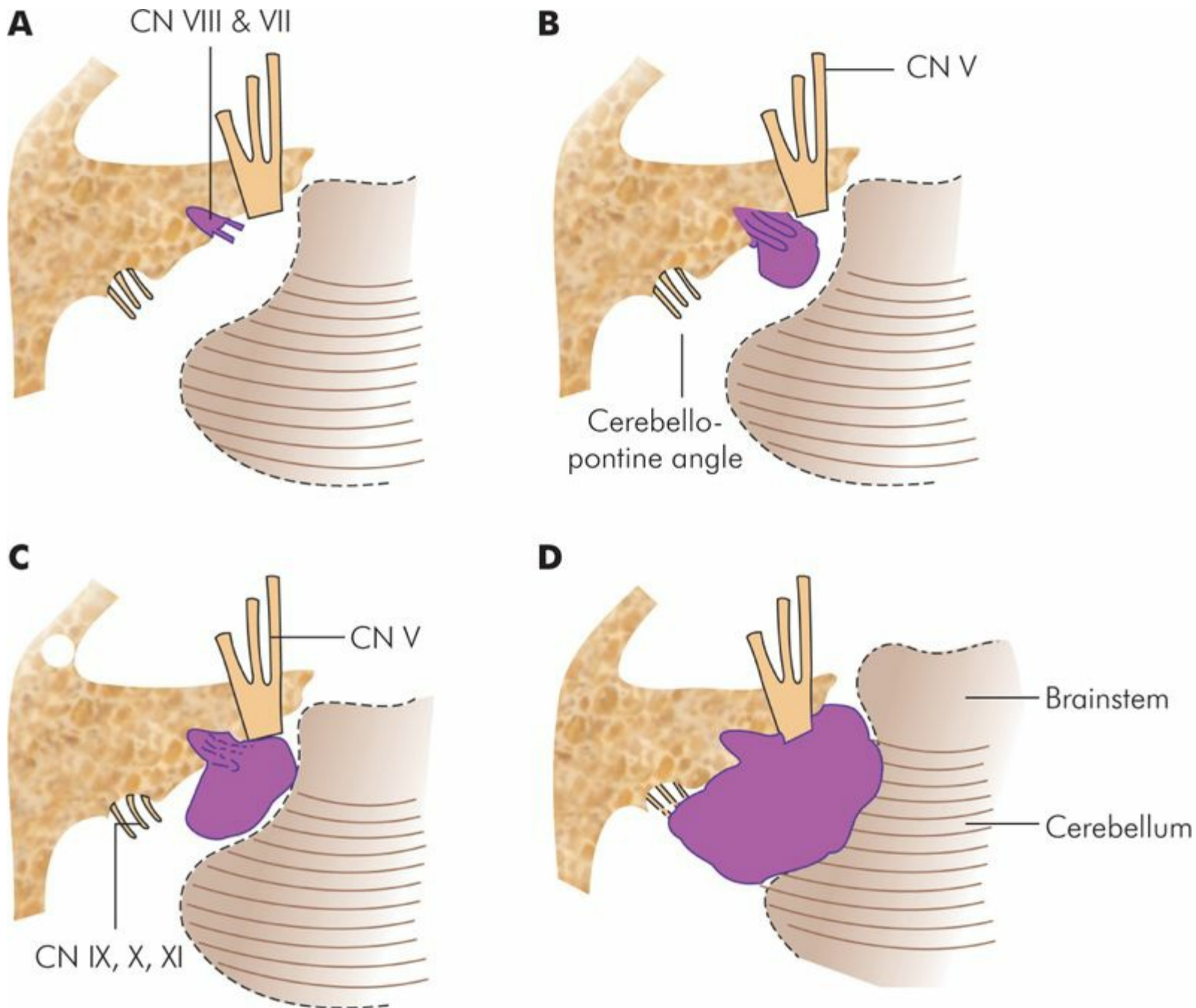
They are the earliest symptoms when tumour is still intracanalicular and are caused by pressure on cochlear or vestibular nerve fibres or on the internal auditory artery.

Progressive unilateral sensorineural hearing loss, often accompanied by tinnitus, is the presenting symptom in majority of cases. There is marked difficulty in understanding speech, out of proportion to the pure tone hearing loss. This feature is characteristic of acoustic neuroma. Some patients may get sudden hearing loss.

*Vestibular symptoms* are imbalance or unsteadiness. True vertigo is seldom seen.

## **3. Cranial nerve involvement**

*(Vth nerve)* This is the earliest nerve to be involved. There is reduced corneal sensitivity, numbness or paraesthesia of face. Involvement of this nerve indicates that the tumour is roughly 2.5 cm in diameter and occupies the cerebellopontine angle.



Dhingra: Diseases of Ear Nose and Throat, 5th Edition  
Copyright © 2010 Elsevier. All rights reserved.

Figure 18.2 Acoustic neuroma and its expansion: (A) Intracanalicular. (B) Tumour extending into cerebellopontine angle. (C) Tumour pressing on CN V. (D) Very large tumour pressing on CN V, IX, X, XI, and brainstem and cerebellum.

**VIIth nerve.** Sensory fibres are affected early. There is hypoaesthesia of posterior meatal wall (Hitzelberger's sign), loss of taste (as tested by electrogustometry) and reduced lacrimation on Schirmer's test. Motor fibres are more resistant and are affected late. Delayed blink reflex may be an early manifestation.

**IXth and Xth nerves.** There is dysphagia and hoarseness due to palatal, pharyngeal and laryngeal paralysis.

**Other cranial nerves.** XIth and XIIth, IIIrd, IVth and VIth are affected when tumour is very large.

#### 4. Brainstem involvement

There is ataxia, weakness and numbness of the arms and legs with exaggerated tendon reflexes. They are seen when long motor and sensory tracts are involved.

#### 5. Cerebellar involvement

Pressure symptoms on cerebellum are seen in large tumours. This is revealed by finger-nose test, knee-heel test, dysdiadochokinesia, ataxic gait, inability to walk along a straight line with tendency to fall to the affected side.

#### 6. Raised intracranial tension



This is also a late feature. There is headache, nausea, vomiting, diplopia due to VIth nerve involvement and papilloedema with blurring of vision.

# Investigations and Diagnosis

Attempts should be made to diagnose the tumour in its otological phase when it is still intracanalicular. This is possible when all cases of unilateral sensorineural hearing loss with tinnitus or imbalance are carefully evaluated.

## 1. Audiological tests

See Table 15.1 for difference between cochlear and retrocochlear lesions.

- (a) Pure tone audiometry will show sensorineural hearing loss, more marked in high frequencies.
- (b) Speech audiometry shows poor speech discrimination and this is disproportionate to pure tone hearing loss. Roll-over phenomenon, i.e. reduction of discrimination score when loudness is increased beyond a particular limit is most commonly observed.
- (c) Recruitment phenomenon is absent.
- (d) Short Increment Sensitivity Index (SISI) test will show a score of 0-20% in 70-90% of cases.
- (e) Threshold tone decay test shows retrocochlear type of lesion.

## 2. Stapedial reflex decay test

(see page 30).

## 3. Vestibular tests

Caloric test will show diminished or absent response in 96% of patients. When tumour is very small, caloric test may be normal.

## 4. Neurological tests

Complete examination of cranial nerves, cerebellar functions, brainstem signs of pyramidal and sensory tracts should be done. Fundus is examined for blurring of disc margins or papilloedema.

page 125

page 126

## 5. Radiological tests

- (a) *Plain X-rays* (transorbital, Stenver's, Towne's and submentovertical views) give positive findings in 80% of patients. However, small intracanalicular tumours are not detected.
- (b) *CT scan*. A tumour that projects even 0.5 cm into the posterior fossa can be detected by a CT scan. If combined with intrathecal air, even the intrameatal tumour can be detected. CT scan has replaced earlier methods of pneumoencephalography and myodil meatography.
- (c) *MRI with gadolinium contrast*. It is superior to CT scan and is the *gold standard* for diagnosis of acoustic neuroma. Intracanalicular tumour, of even a few millimetres, can be easily diagnosed by this method.
- (d) *Vertebral angiography*. This is helpful to differentiate acoustic neuroma from other tumours of cerebellopontine angle when doubt exists.

## 6. Evoked response audiometry (BERA)

It is very useful in the diagnosis of retrocochlear lesions. In the presence of VIIIth nerve tumour, a delay of >0.2 msec in wave V between two ears is significant (see page 31).

## 7. CSF examination

Protein level is raised. Lumbar puncture is usually avoided. Important tests for work-up of acoustic neuroma are given below:

## Important Tests for Work-up of Acoustic Neuroma

- Pure tone audiometry
- Speech discrimination score
- Roll-over curve
- Stapedial reflex decay
- Evoked response audiometry
- MRI with contrast

# Differential Diagnosis

Acoustic neuroma should be differentiated from the cochlear pathology (i.e. Meniere's disease) and other cerebellopontine angle tumours, e.g. meningioma, primary cholesteatoma and arachnoidal cyst (Table 18.1).

**Table 18-1. Tumours of cerebellopontine angle**

- Acoustic neuroma
- Meningioma
- Epidermoid (cholesteatoma)
- Arachnoid cyst
- Schwannoma of other cranial nerves (e.g. CN V > VII > IX, X, XI)
- Aneurysm
- Glomus tumour
- Metastasis

# Treatment

## Surgery

Surgical removal of the tumour is the treatment of choice. Surgical approach will depend upon the size of tumour.

The various approaches are:

- 1. Middle cranial fossa approach.
- 2. Translabyrinthine approach.
- 3. Suboccipital (retrosigmoid) approach.
- 4. Combined translabyrinthine-suboccipital approach.

## Radiotherapy

*Conventional radiotherapy* by external beam has no role in the treatment of acoustic neuromas due to low tolerance of the central nervous system to radiation.

*X-knife or Gamma knife surgery.* It is a form of stereo-tactic radiotherapy where radiation energy is converged on the tumour, thus minimising its effect on the surrounding normal tissue. This causes arrest of the growth of the tumour and also reduction in its size. It can be used in patients who refuse surgery or have contraindications to surgery or in those with a residual tumour.

X-knife surgery is done through linear accelerator and gamma knife through a Cobalt-60 source.

*Cyber knife:* It is an improvement over the above. It is totally frameless and more accurate. It uses real-time image guidance technology through computer controlled robotics.

Children with profound (>90 dB loss) or total deafness fail to develop speech and have often been termed as *deaf-mute* or *deaf and dumb*. However, these children have no defect in their speech producing apparatus. The main defect is deafness. They have never heard speech and therefore do not develop it. In lesser degrees of hearing loss, speech does develop but is defective. The period from birth to 5 years of life is critical for the development of speech and language, therefore, there is need for early identification and assessment of hearing loss and early rehabilitation in infants and children. It was observed that children whose hearing loss was observed and managed before 6 months of age had higher scores of vocabulary, better expressive and comprehensive language skills than those diagnosed and managed after 6 months of age emphasising the importance of early identification and treatment.

# Aetiology

Hearing loss in a child may develop from causes before birth (prenatal), during birth (perinatal) or thereafter (postnatal).

## A. Prenatal Causes

They may pertain to the infant or the mother.

### 1. Infant factors

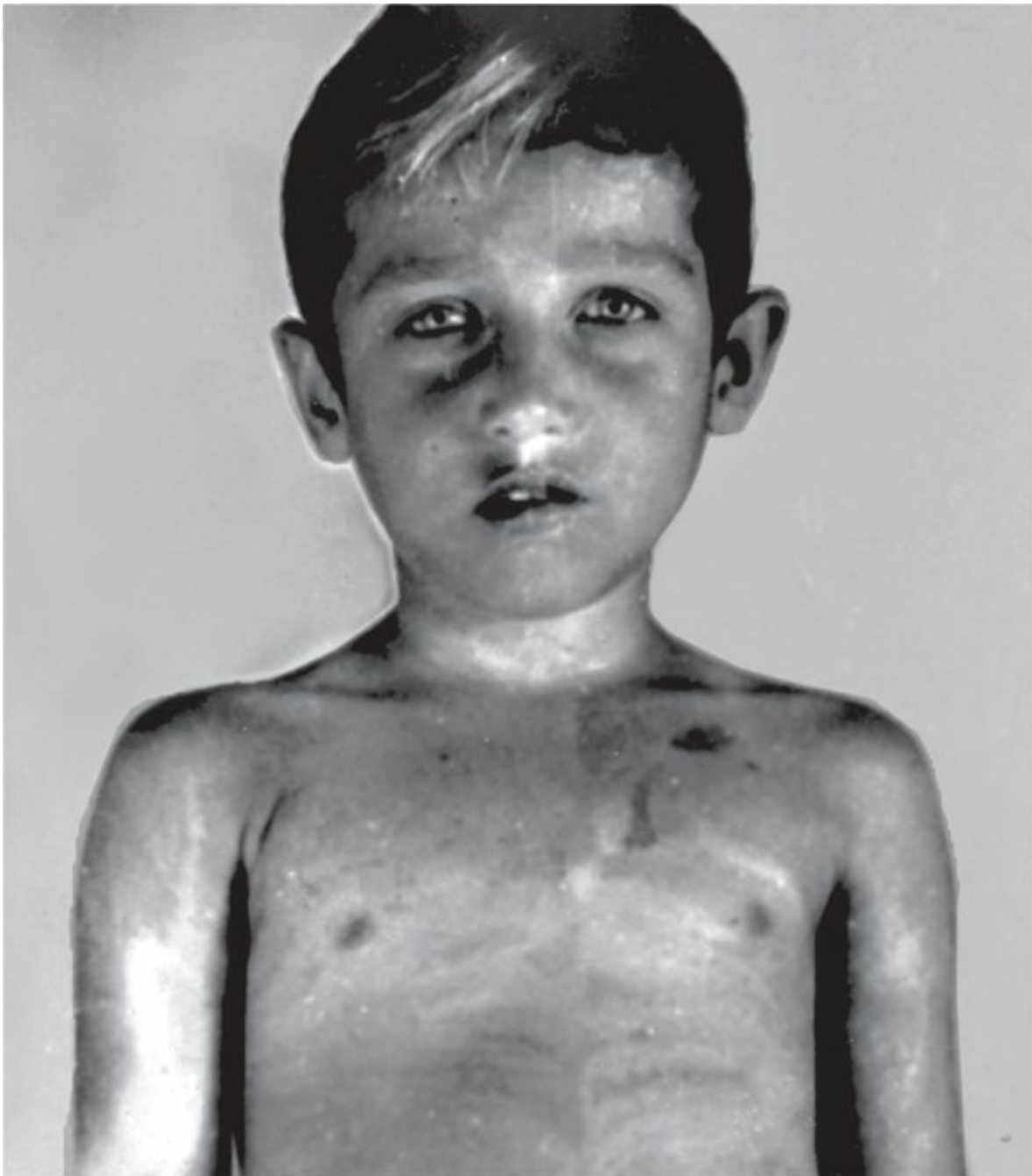An infant may be born with inner ear anomalies due to genetic or non-genetic causes. Anomalies may affect inner ear alone (non-syndromic) or may form part of a syndrome (syndromic).

Anomalies affecting the inner ear may involve only the membranous labyrinth or both the membranous and bony labyrinths. They include:

- **(i) Sheibe's dysplasia.** It is the most common inner ear anomaly. Bony labyrinth is normal. Superior part of membranous labyrinth (utricle and semicircular ducts) is also normal. Dysplasia is seen in the cochlea and saccule; hence also called *cochleosaccular dysplasia*. It is inherited as an autosomal recessive non-syndromic trait.
- **(ii) Alexander's dysplasia.** It affects only the basal turn of membranous cochlea. Thus only high frequencies are affected. Residual hearing is present in low frequencies and can be exploited by amplification with hearing aids.
- **(iii) Bing-Siebenmann dysplasia.** There is complete absence of membranous labyrinth.
- **(iv) Michel aplasia.** There is complete absence of bony and membranous labyrinth. Even the petrous apex is absent but external and middle ears may be completely unaffected. No hearing aids or cochlear implantation can be used.
- **(v) Mondini's dysplasia.** Only basal coil is present or cochlea is 1.5 turns. There is incomplete partition between the scalae due to absence of osseous spiral lamina. Condition is unilateral or bilateral. This deformity may be seen in Pendred, Waardenburg, Branchio-oto-renal, Treacher-Collins and Wildervanch syndromes.
- **(vi) Enlarged vestibular aqueduct.** Vestibular aqueduct is enlarged (>2 mm), endolymphatic sac is also enlarged and can be seen on T<sub>2</sub> MRI. It causes early onset sensorineural hearing loss which is progressive. Vertigo may be present. Perilymphatic fistula may occur.
- **(vii) Semicircular canal malformations.** Both superior and lateral or only lateral semicircular canal malformations may be seen. They can be identified on imaging techniques.

### 2. Maternal factors

- **(a) Infections**
- **(b) Drugs during pregnancy**
- **(c) Radiation to mother in the first trimester**
- **(d) Other factors**



Dhingra: Diseases of Ear Nose and Throat, 5th Edition  
Copyright © 2010 Elsevier. All rights reserved.

Figure 19.1 Waardenburg's syndrome. Note white forelock, heterochromia iridis and depigmentation of skin.

Syndromes commonly associated with hearing loss are given in Table 19.1.

- **(a) Infections.** Infections which affect the developing foetus are toxoplasmosis, rubella, cytomegaloviruses, herpes type 1 and 2 and syphilis. Remember mnemonic, TORCHES.
- **(b) Drugs during pregnancy.** Streptomycin, gentamicin, tobramycin, amikacin, quinine or chloroquine, when given to the pregnant mother, cross the placental barrier and damage the cochlea. Thalidomide not only affects ear but also causes abnormalities of limbs, heart, face, lip and palate.
- **(c) Radiation to mother in the first trimester.**
- **(d) Other factors.** Nutritional deficiency, diabetes, toxæmia and thyroid deficiency. Maternal alcoholism is also teratogenic to the developing auditory system.

## B. Perinatal Causes

They relate to causes during birth or in early neonatal period. They are:

### 1. Anoxia

It damages the cochlear nuclei and causes haemorrhage into the ear. Placenta praevia, prolonged labour, cord round the neck and prolapsed cord can all cause foetal anoxia.



## **2. Prematurity and low birth weight**

Born before term or with birth weight less than 1500 g.

## **3. Birth injuries**

e.g. forceps delivery. They may cause intracranial haemorrhage with extravasation of blood into the inner ear.

## **4. Neonatal jaundice**

Bilirubin level greater than 20 mg% damages the cochlear nuclei.

## **5. Neonatal meningitis**

## **6. Sepsis**

## **7. Time spent in neonatal ICU**

## **8. Ototoxic drugs**

used for neonatal meningitis or septicaemia.

## **C. Postnatal Causes**

### **1. Genetic**

Though deafness is genetic it manifests later in childhood or adult life. Deafness may occur alone as in *familial progressive sensorineural deafness* or in association with certain syndromes, e.g. Alport's, Klippel-Feil, Hurler, etc.

### **2. Non-genetic**

They are essentially same as in adults and include:

- (i) Viral infections (measles, mumps, varicella, influenza), meningitis and encephalitis.
- (ii) Secretory otitis media.
- (iii) Ototoxic drugs.
- (iv) Trauma, e.g. fractures of temporal bone, middle ear surgery or perilymph leak.
- (v) Noise-induced deafness.

# EVALUATION OF A DEAF CHILD

## Finding the Cause

This may require a detailed history of prenatal, perinatal or postnatal causes, family history, physical examination and certain investigations depending on the cause suspected.

### Suspicion of hearing loss

Hearing loss is suspected if (i) the child sleeps through loud noises unperturbed or fails to startle to loud sound, (ii) fails to develop speech at 1-2 years. A partially hearing child may have a defective speech and perform poorly in school and be labelled mentally retarded. It is essential that all children *at risk* for hearing loss should be screened and followed.

### Risk factors for hearing loss in children

page 128

page 129

page 129

page 130

page 130

page 131

\*Developed by Virginia Apgar, an anaesthesiologist. It takes note of five items: heart rate, respiratory effort, muscle tone, reflex irritability and colour; noted at 1 and 5 minutes after birth. Low score is 0 and highest 10, i.e. 2 marks for each item.

(Recommendations of Joint Committee on Infant Hearing—updated to 1994).

- (i) Family history of hearing loss.
- (ii) Prenatal infections (TORCHES).
- (iii) Craniofacial anomalies including those of pinna and ear canal.
- (iv) Birth weight less than 1500 g (3.3 lbs).
- (v) Hyperbilirubinaemia requiring exchange transfusion.
- (vi) Ototoxic medications included but not limited to aminoglycosides used in multiple courses or in combination with loop diuretics.
- (vii) Bacterial meningitis.
- (viii)\* Apgar score of 0-4 at 1 minute or 0-6 at 5 minutes.
- (ix) Mechanical ventilation for 5 days or longer.
- (x) Stigmata or other findings associated with a syndrome known to include sensorineural and/or conductive hearing loss.

**Table 19-1. Syndromes associated with hearing loss**

Syndrome	Features	Type of hearing loss	Onset (Congenital/Delayed)	Type of inheritance
1. Waardenburg's syndrome (Fig. 19.1)	<ul style="list-style-type: none"> <li>• White forelock</li> <li>• Heterochromia iridis</li> <li>• Vitiligo</li> <li>• Dystopia canthorum</li> </ul>	Unilateral or bilateral SNHL	Congenital	AD
2. Usher syndrome	<ul style="list-style-type: none"> <li>• Retinitis pigmentosa</li> <li>• Night-blindness</li> </ul>	SNHL	Delayed	AR
3. Jervell and Lange-Nielson's syndrome	<ul style="list-style-type: none"> <li>• Repeated syncopal attacks</li> <li>• Prolonged QT interval in ECG</li> </ul>	SNHL	Congenital	AR
4. Pendred syndrome	<ul style="list-style-type: none"> <li>• Goitre (non-toxic) usually evident before puberty</li> <li>• Perchlorate discharge test shows defect in organic binding of iodine</li> </ul>	SNHL	Congenital	AR

5. Alport syndrome	<ul style="list-style-type: none"> <li>• Hereditary progressive glomerulonephritis</li> <li>• Corneal dystrophy</li> </ul>	Progressive SNHL	Delayed	AD or X-linked
6. Treacher-Collins syndrome (mandibulofacial dysostosis)	<ul style="list-style-type: none"> <li>• Antimongoloid palpebral fissures</li> <li>• Coloboma of lower lid</li> <li>• Hypoplasia of mandible and malar bones</li> <li>• Malformed pinna and meatal atresia</li> <li>• Malformed malleus and incus (stapes normal)</li> </ul>	Conductive	Congenital	AD
7. Crouzon's syndrome (craniofacial dysostosis)	<ul style="list-style-type: none"> <li>• Frog eyes (exophthalmos with divergent squint)</li> <li>• Hypertelorism</li> <li>• Parrot-beak nose</li> <li>• Mandibular prognathism</li> <li>• Premature closure of cranial sutures with mental retardation</li> </ul>	Conductive or mixed	Congenital	AD
8. Apert's syndrome	<ul style="list-style-type: none"> <li>• Syndactyly</li> <li>• All other features of Crouzon's syndrome</li> </ul>	Conductive (Stapes fixation)		AD
9. Klippel-Feil syndrome	<ul style="list-style-type: none"> <li>• Short neck</li> <li>• Fused cervical vertebrae</li> <li>• Spina bifida</li> <li>• Atresia of ear canal</li> </ul>	SNHL or mixed	Congenital	AR
10. Wildervanch syndrome	<ul style="list-style-type: none"> <li>• Klippel-Feil syndrome</li> <li>• SNHL</li> <li>• CN VI Paralysis</li> </ul>	SNHL	Congenital	X-linked
11. Branchio-oto-renal syndrome	<ul style="list-style-type: none"> <li>• Branchial fistulas/cysts</li> <li>• Malformed pinnae with preauricular pits or sinuses</li> <li>• Renal abnormalities</li> </ul>	Conductive or mixed	Congenital	AD
12. Stickler's syndrome	<ul style="list-style-type: none"> <li>• Small jaw</li> <li>• Cleft palate (Pierre-Robin sequence)</li> <li>• Myopia <math>\geq</math> retinal detachment</li> <li>• Cataract</li> <li>• Juvenile onset arthritis</li> </ul>	Conductive or SNHL	Delayed	AD
	<ul style="list-style-type: none"> <li>• Osteogenesis imperfecta with history of fractures</li> </ul>	Conductive, SNHL or mixed		

13. Van der Hoeve's syndrome	<ul style="list-style-type: none"> <li>• Blue sclera</li> <li>• Hearing loss (delayed onset)</li> </ul>	(like otosclerosis)	Delayed	AD
14. Pierre-Robin sequence*	<ul style="list-style-type: none"> <li>• Micrognathia</li> <li>• Glossoptosis</li> <li>• Cleft palate</li> <li>• Often part of Stickler's syndrome</li> </ul>	SNHL Conductive loss		AD
15. Goldenhar's syndrome (Facio-auriculo-vertebral dysplasia) or (oculo-auriculo-vertebral [OAV] syndrome)	<ul style="list-style-type: none"> <li>• Facial asymmetry</li> <li>• Low set ears, atresia of ear canal</li> <li>• Cardiac abnormalities</li> <li>• Preauricular tags/pits</li> <li>• Hemivertebrae in cervical region</li> <li>• Epibulbar dermoid</li> <li>• Coloboma of upper lid</li> </ul>	Mixed or Conductive	Congenital	AD or sporadic Extra chromosome Multifactorial (genetic and environmental)
16. Down's syndrome (Trisomy 21)	<ul style="list-style-type: none"> <li>• Microcephaly</li> <li>• Mental retardation/delayed development</li> <li>• Short stature</li> <li>• Epicanthal folds</li> <li>• Stenosis of ear canal</li> <li>• High incidence of serous otitis media</li> <li>• Atlanto-axial instability</li> </ul>	Conductive	Congenital	Extra chromosome

\*It is called a sequence, not a syndrome, because multiple anomalies result in sequence from a single primary abnormality, i.e. micrognathia which leads to glossoptosis which in turn causes cleft palate.

SNHL = Sensorineural hearing loss; AD = Autosomal dominant; AR = Autosomal recessive.

# Assessment of Hearing in Infants and Children

Assessment of auditory function in neonates, infants and children demands special techniques. They are grouped under the following heads (Table 19.2):

## (a) Screening procedures

They are employed to test hearing in "high risk" infants and are based on infant's behavioural response to the sound signal.

**Arousal test.** A high frequency narrow band noise is presented for 2 seconds to the infant when he is in light sleep. A normal hearing infant can be aroused twice when three such stimuli are presented to him.

**Auditory response cradle** is a screening device for newborns, where baby is placed in a cradle and his behaviour (trunk and limb movement, head jerk and respiration) in response to auditory stimulation are monitored by transducers. It can screen babies with moderate, severe or profound hearing loss.

**Table 19-2. Methods of hearing assessment in infants and children**

1. Neonatal screening procedures
  - Arousal test
  - Auditory response cradle
  - ABR/OAE's
2. Behaviour observation audiometry
  - Moro's reflex
  - Cochleopalpebral reflex
  - Cessation reflex
3. Distraction techniques
4. Conditioning techniques
  - Visual reinforcement audiometry
  - Play audiometry
5. Objective tests
  - ABR
  - Otoacoustic emissions
  - Impedance audiometry

## (b) Behaviour observation audiometry

Auditory signal presented to an infant produces a change in behaviour, e.g. alerting, cessation of an activity, widening of eyes or facial grimacing. *Moro's reflex* is one of them and consists of sudden movement of limbs and extension of head in response to sound of 80-90 dB. In *cochleopalpebral reflex*, the child responds by a blink to a loud sound. In cessation reflex, an infant stops activity or starts crying in response to a sound of 90 dB.

## (c) Distraction techniques

are used in children 6-7 months old. The child at this age turns his head to locate the source of sound. In this test, the child is seated in his mother's lap, an assistant distracts the child's attention while the examiner produces a sound from behind or from one side to see if the child tries to locate it. Sounds used are high frequency rattle (8 kHz), low frequency hum, whispered sound as "S, S, S", xylophone, warbled tones or narrow band noise (500-4000 Hz).

## (d) Conditioning techniques

**Visual reinforcement audiometry (VRA).** It is a conditioning technique in which child is trained to look for an auditory stimulus by turning his head. This behaviour is reinforced by a flashing light or an animated toy. This test helps to determine the hearing threshold using standard audiometric techniques. The auditory stimulus is delivered by headphones or better still by insert earphones which are accepted better and are also light weight. Test is well suited between the developmental age of 5 months to 2 years.

**Play audiometry.** The child is conditioned to perform an act such as placing a marble in a box, putting a ring on a post or putting a plastic block in a bucket each time he hears a sound signal. Each correct performance of the act is reinforced with praise, encouragement or reward. Ear specific thresholds can be determined by standard audiometric techniques. This test can be used in children with developmental age of 2-4 or 5 years.

**Speech audiometry.** The child is asked to repeat the names of certain objects or to point them out on the pictures. The voice can be gradually lowered. In this way, hearing level and speech discrimination can be tested. The test can also be used to examine the child's expressive ability when he is asked to name the toys like horse, duck or objects like cup, plate, etc.

## (e) Objective tests

(i) *Evoked response audiometry.*

*Electrocochleography.* It can measure auditory sensitivity to within 20 dB. But it is an invasive procedure.

page 131

page 132

*Auditory brainstem response.* It is not a direct test of hearing but correlates highly with the pure-tone thresholds. Identifiable waveforms in ABR are generally present 10-20 dB above behavioural threshold. ABR provides an ear specific information as sound stimulus can be presented to each ear separately by headphones or ear inserts. It is an objective test and can be done under sedation as the latter has no effect on ABR. ABR is used both as a screening test and as a definitive hearing assessment test in children. In a screening test, a response to a click stimulus of 40 nHL or less is the criterion of passing the test. To find hearing threshold in an infant, ABR tracing is obtained first at higher sound stimulus and then gradually lowered till wave V is just identifiable but repeatable.

(ii) *Otoacoustic emissions* (see page 32). Transient evoked emissions (TEOAE's) are absent in ears where hearing loss exceeds 30 dB. Distortion product emissions (DPOAE's) are absent when hearing loss exceeds 50 dB.

(iii) *Impedance audiometry.* Normally, stapedius muscle contracts reflexly in response to a sound of 70-100 dB HL and this reflex can be recorded. Absence of acoustic reflex indicates middle ear disorder, retrocochlear hearing loss or severe to profound SNHL. Used with behaviour audiometry, acoustic reflexes are useful component to cross-check. Absence of acoustic reflex, but a normal tympanometry with parental concern for hearing loss suggests possibility of SNHL of severe to profound degree. Absence of acoustic reflex but an abnormal tympanogram generally indicates conductive loss. Since ABR and OAEs provide more information, use of acoustic reflexes in assessment of paediatric testing has declined.

OAEs and ABR have been used both in screening programmes and in hearing evaluation in infants and children.

# Management

It is essential to know the degree and type of hearing loss, and other associated handicaps such as blindness or mental retardation and whether hearing loss is pre-lingual (before development of speech) or post-lingual. Aetiology of hearing loss remains obscure in about half the cases.

Aims of habilitation of any hearing-impaired child are development of speech and language, adjustment in society and useful employment in a vocation.

## 1. Parental guidance

It is a great emotional shock for parents to learn that their child is deaf. They should be dealt with sympathetically, so as to accept the child. They should be told of child's disability and how to care for it. Habilitation of the deaf demands a lot from parents: care and periodic replacement of hearing aid, change of ear-moulds as child grows, follow up visits for reevaluation, education at home and the selection of vocation.

## 2. Hearing aids

Most deaf children have a small but useful portion of residual hearing which can be exploited by amplification of sound. Hearing aids should be prescribed as early as possible. If necessary, binaural aids, one for each ear, can be used. Hearing aids help to develop lip-reading also.

## 3. Development of speech and language

Communication is a two way process, depending on the receptive and expressive skills. Reception of information is through visual, auditory or tactile faculties while expression is through oral or written speech or the manual sign language. In the hearing-impaired, auditory faculty is poor or totally absent (Fig. 19.2). Thus, for proper communication, there is need either to improve hearing through amplification of the residual hearing or cochlear implants; and in the absence of the feasibility of developing the auditory faculty, one has to develop visual or tactile means of communication.

(a) *Auditory-oral communication.* This is the method used by a normal person and is the best way of communication. In the deaf, it can be used in those with moderate to severe hearing loss or those who are post-lingually deaf. Hearing aids are provided to augment auditory reception. At the same time, training is also imparted in speech reading, i.e. to read movements of lips, face, and natural gestures of hand and body. Expressive skill is encouraged through oral speech.

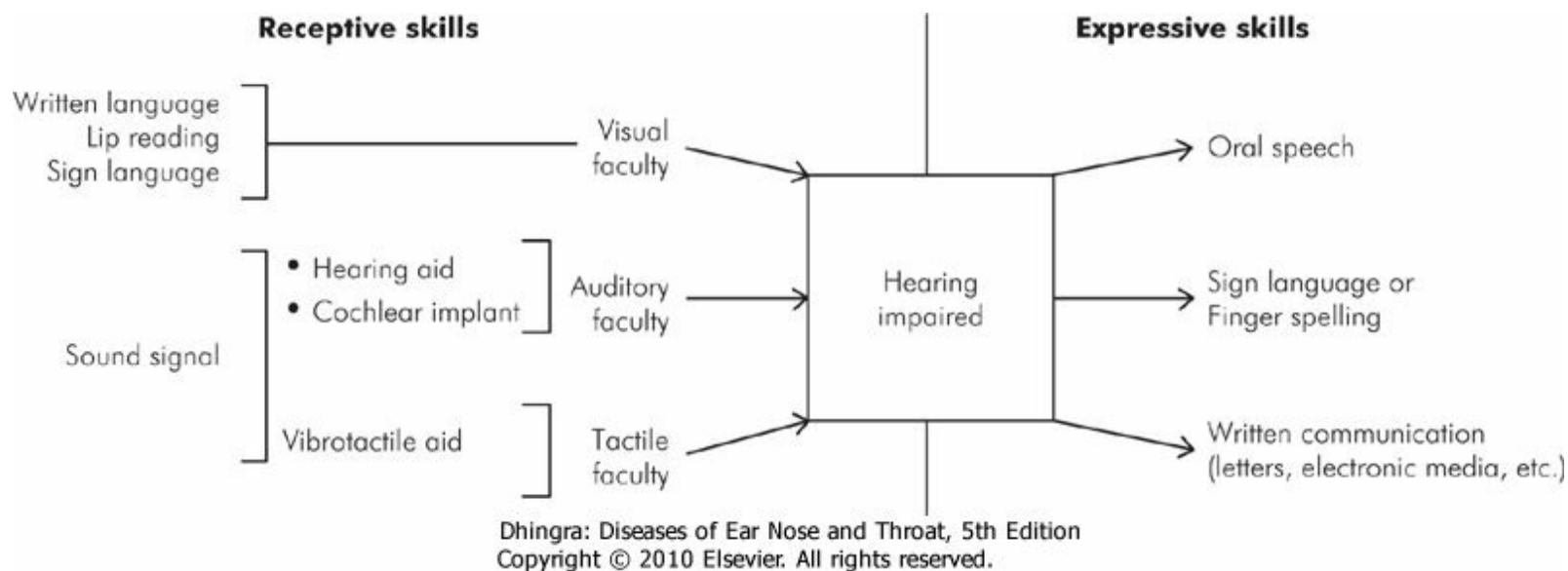


Figure 19.2 The faculties of a hearing-impaired person which can be utilised for receptive and expressive skills in communication.

(b) *Manual communication.* It makes use of the *sign language* or *finger-spelling method* but has the disadvantage that abstract ideas are difficult to express and general public does not understand it.

(c) *Total communication.* It uses all modalities of sensory input, i.e. auditory, visual, tactile and kinaesthetic. Such children are taught to develop oral speech, lip-reading and sign language. All children with pre-lingual severe to profound deafness, should undergo training in this form of communication. *Vibrotactile* aids are useful for those who are totally deaf and also blind. These aids are attached to the child's hand or sternum and the vibrations of speech are perceived through tactile sensation.

## 4. Education of the deaf

There are residential and day schools for the deaf. Some deaf children with moderate hearing loss can be integrated into schools for the normal children with preferential seating in the class.

Radio hearing aids have revolutionised education of the deaf. In this device, the microphone and transmitter are worn by the teacher and the receiver and amplifier by the child. With this system, the child can hear the teacher's voice better, without being disturbed by environmental noises.

### **5. Vocational guidance**

The deaf are sincere and good workers. Given the opportunity, commensurate with their ability, they can be usefully employed in several vocations.



## 20 Rehabilitation of the Hearing-Impaired

All hearing-impaired individuals need some sort of aural rehabilitation for communication. The various means available to them are:

1. Instrumental devices
  1. Hearing aids
    - (i) Conventional hearing aids
    - (ii) Bone anchored hearing aids (BAHA)
    - (iii) Implantable hearing aids (vibrant soundbridge)
  2. Implants
    - (i) Cochlear implants
    - (ii) Auditory brainstem implants
  3. Assistive devices for the deaf
2. Training
  1. Speech (lip) reading
  2. Auditory training
  3. Speech conservation

# I. INSTRUMENTAL DEVICES

## A. Hearing Aids

### Conventional Hearing Aids

A hearing aid is a device to amplify sounds reaching the ear. Essentially, it consists of three parts: (a) a *microphone*, which picks up sounds and converts them into electrical impulses, (b) an *amplifier*, which magnifies electrical impulses, and (c) a *receiver*, which converts electrical impulses back to sound. This amplified sound is then carried through the earmould to the tympanic membrane.

### Types of Hearing Aids

#### *Air conduction hearing aid*

In this, the amplified sound is transmitted via the ear canal to the tympanic membrane.

#### *Bone conduction hearing aid*

Instead of a receiver, it has a bone vibrator which snugly fits on the mastoid and directly stimulates the cochlea. This type of aid is specially useful in persons with actively draining ears, otitis externa or atresia of the ear canal when ear-inserts cannot be worn.

Most of the aids are air conduction type. They can be:

#### **1. Body-worn types**

Most common type (Fig. 20.1A); microphone and amplifier along with the battery are in one case worn at the chest level while receiver is situated at the ear level. This type of aid allows high degree of amplification with minimal feedback. It is useful in severely deaf persons or children with congenital deafness.

#### **2. Behind-the-ear (BTE) types**

Here microphone, amplifier, receiver and battery are all in one unit which is worn behind the ear. It is coupled to the ear canal with a tubing and an earmould. It is useful for slight to moderate cases of hearing loss particularly the high frequency ones.

#### **3. Spectacle types**

It is a modification of the "Behind-the-ear" type and the unit is housed in the auricular part of the spectacle frame. It is useful to persons who need both eye glasses for vision and a hearing aid. It is not very popular now.

#### **4. In-the-ear (ITE) types**

The entire hearing aid is housed in an earmould which can be worn in the ear. It is useful for mild to moderate hearing losses with flat configuration. They are very popular because of their cosmetic appeal.

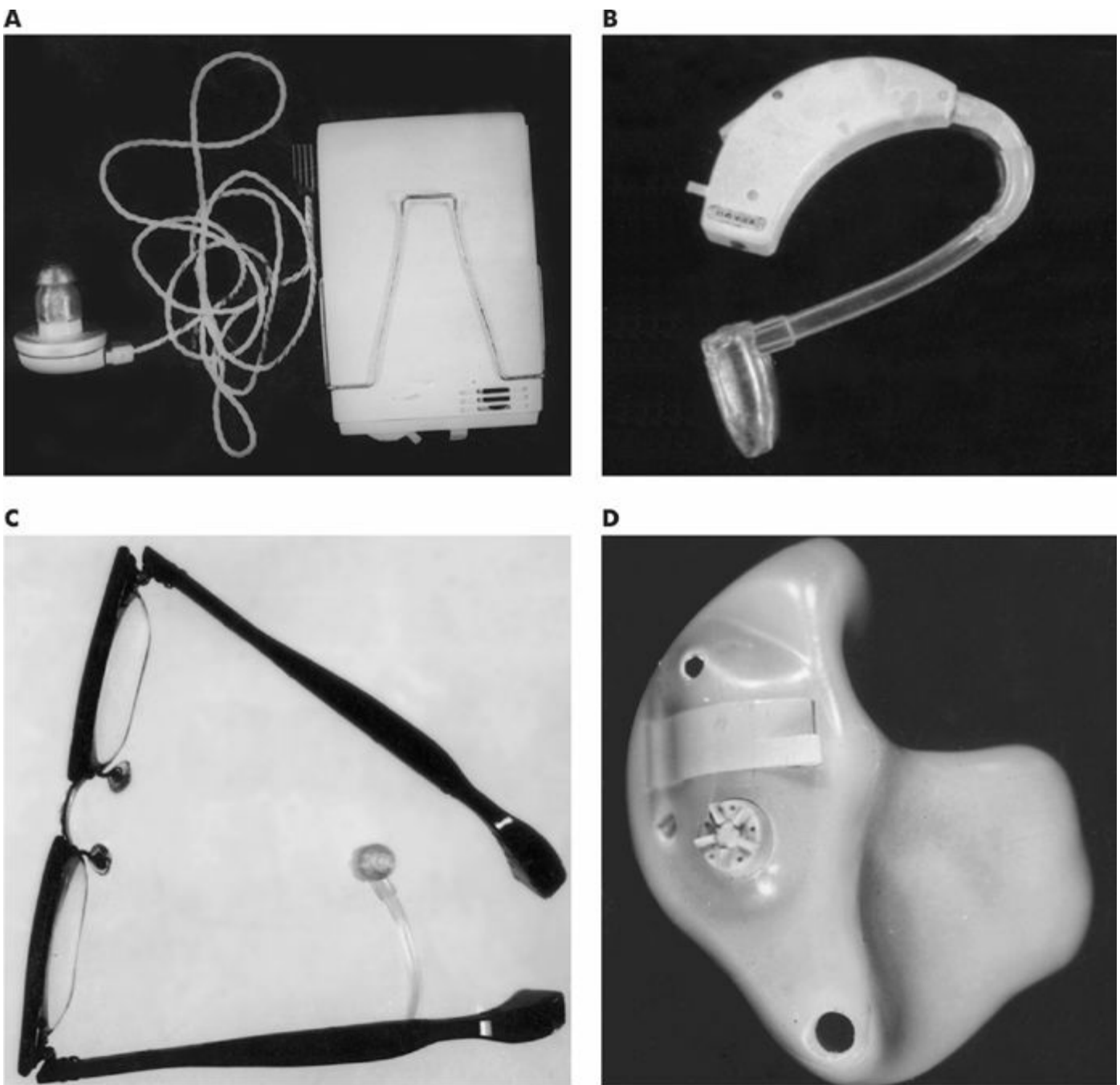
#### **5. Canal types (ITC & CIC)**

The hearing aid is so small that the entire aid can be worn in the ear canal without projecting into the concha. For using this aid, it is required that the ear canal should be large and wide, and patient should have the dexterity to manipulate the minute controls in the aid. It is useful for mild to moderate cases of hearing loss of high frequency (1 to 4 kHz).

Two types are available; in the canal (ITC) and another still smaller and invisible type, completely in the canal (CIC).

### Indications for Hearing Aid

Any individual who has a hearing problem that cannot be helped by medical or surgical means is a candidate for hearing aid.



Dhingra: Diseases of Ear Nose and Throat, 5th Edition  
 Copyright © 2010 Elsevier. All rights reserved.

Figure 20.1 Various types of hearing aids. (A) Body-worn. (B) Behind-the-ear type. (C) Spectacle type. (D) In-the-ear type.

### 1. Sensorineural hearing loss

which interferes with day to day activities of a person. Hearing aid may not suit all such persons because of the intolerable distortion of sound in some, particularly in those with recruitment.

### 2. Deaf children

should be fitted with hearing aid as early as possible for development of speech and learning. In severely deaf children, binaural aids (one for each ear and individually fitted) are more useful. Training in lip-reading is given simultaneously.

### 3. Conductive deafness

Most of such persons can be helped by surgery but hearing aid is prescribed when surgery is refused or not feasible or has failed.

### Fitting a Hearing Aid

While fitting a hearing aid, consideration is given to:

- (a) Degree of hearing loss,
- (b) Configuration of hearing loss (type of frequencies affected),

- (c) Type of hearing loss (conductive or sensorineural),
- (d) Presence of recruitment,
- (e) Uncomfortable loudness level,
- (f) Age and dexterity of patient,
- (g) Condition of the outer and middle ear,
- (h) Cosmetic acceptance of the aid,
- (i) Type of earmould,
- (j) The type of fitting, whether it is monoaural, (one aid only), binaural (one aid for each ear), binaural with y-connection (one aid but two receivers, one for each ear) or the CROS type.

### **CROS (contralateral routing of signals)**

In this type, microphone is fitted on the side of the deaf ear and the sound thus picked up is passed to the receiver placed in the better ear. This is useful for persons with one ear severely impaired and helps in sound localisation coming from the side of the deaf ear. Now bone-anchored hearing aids (BAHA) (see infra) are being preferred for single-sided deafness and have replaced the use of CROS aids.

### **Bone-anchored Hearing Aid (BAHA)**

Bone-anchored hearing aid is a type of hearing aid which is based on the principle of bone conduction. It is primarily suited to people who have conductive hearing loss, unilateral hearing loss and those with mixed hearing loss who cannot otherwise wear "in the ear" or "behind the ear" hearing aids.

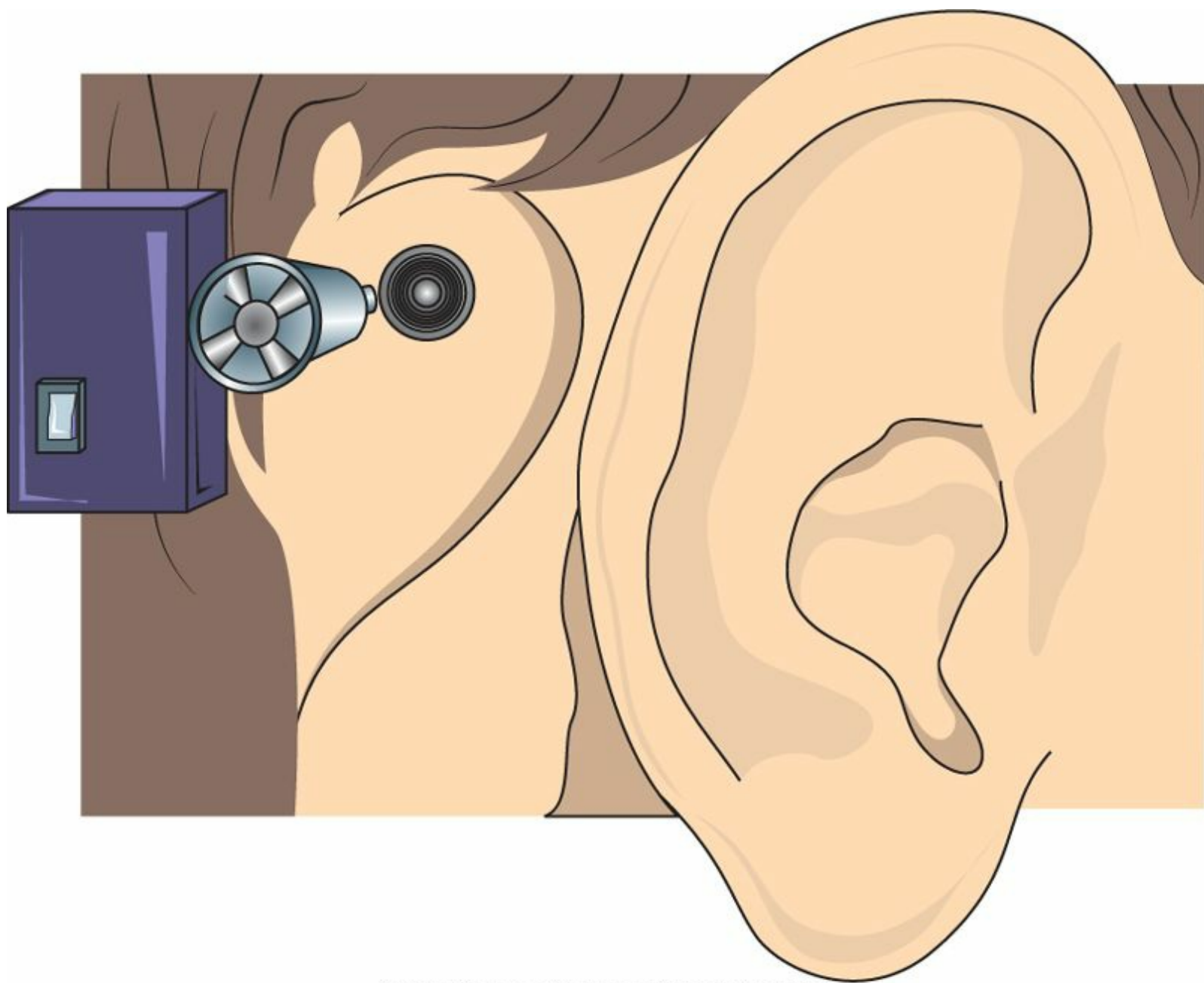
Bone-anchored hearing aids use a surgically implanted abutment to transmit sound by direct conduction through bone to the cochlea, bypassing the external auditory canal and middle ear (Fig. 20.2).

BAHA has three components: (a) titanium fixture (b) titanium abutment and (c) sound processor (Fig. 20.3). The titanium fixture is surgically embedded in the skull bone with abutment exposed outside the skin. The titanium fixture bonds with the surrounding tissue in a process called *osseointegration*. The sound processor is attached to the abutment once osseointegration is complete which usually takes 2 to 6 months after implantation. The BAHA device transmits vibrations to the external abutment which further vibrates the skull and cochleae.

#### **Candidacy profile**

Bone-anchored hearing aids can be used in:

- (i) People who have chronic inflammation or infection of the ear canal and cannot wear standard "in the ear" air-conduction hearing aids.
- (ii) Children with malformed or absent outer ear and ear canals as in microtia or canal atresia.
- (iii) Single-sided deafness (see Table 20.1)



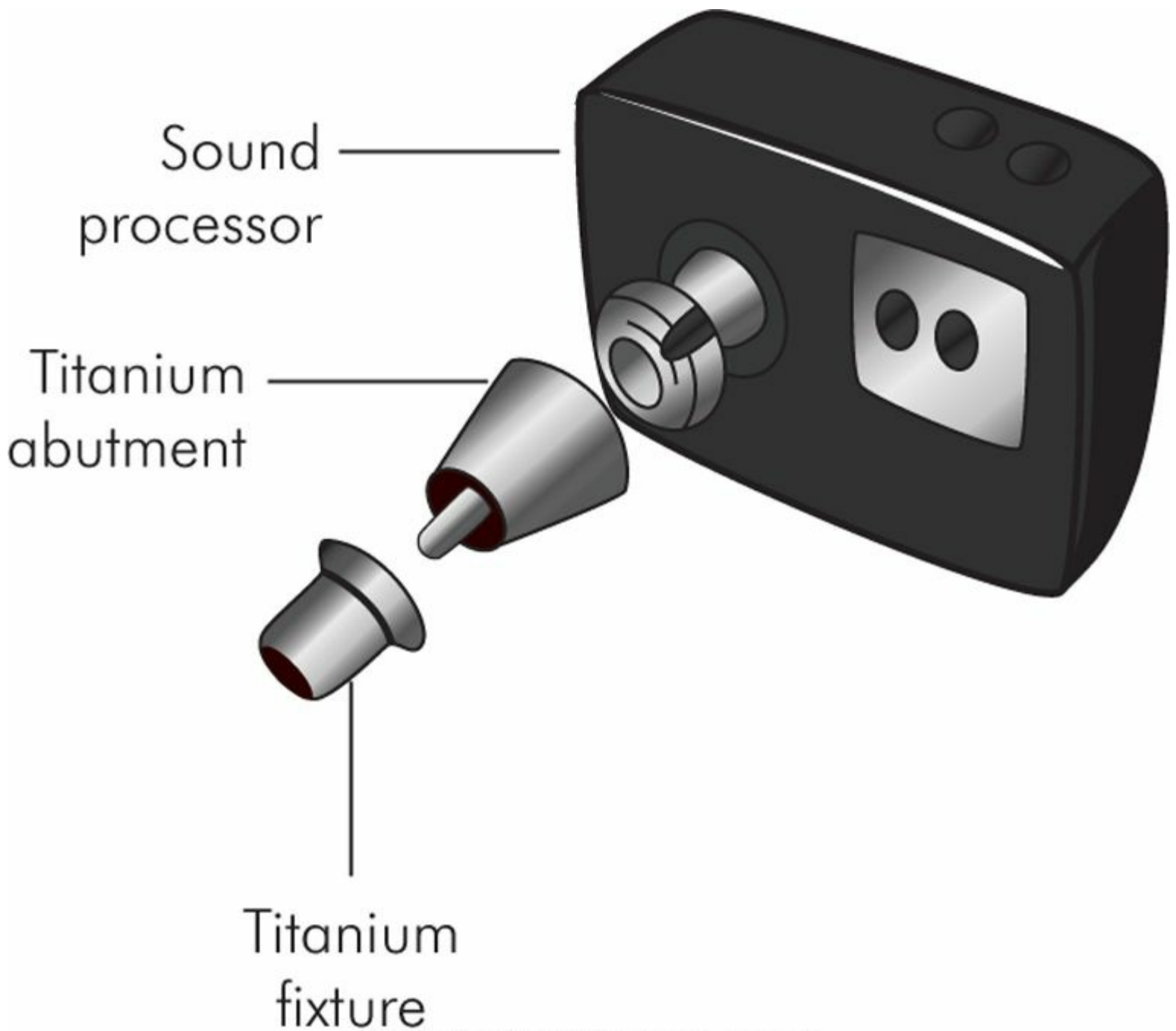
Dhingra: Diseases of Ear Nose and Throat, 5th Edition  
Copyright © 2010 Elsevier. All rights reserved.

Figure 20.2 Appearances when sound processor is attached to abutment.

In the past, the contralateral routing of signal (CROS) hearing aid was the only option available for rehabilitation of patients with single-sided deafness. Poor performance and aesthetic considerations limited the use of CROS aids. The BAHA device can now be implanted on the side of the deaf ear, and it transmits the sound by means of bone conduction to the contralateral cochlea. The BAHA is fixed on the deaf side and collects sound waves to transmit to healthy cochlea of the other side. This process eliminates the head-shadow effect and allows for hearing from both sides of the head. The BAHA substantially improves speech recognition in quiet and in noise compared with the CROS aids.

### **Surgery**

The surgery is typically performed in a single stage in adults. About 3 months are allowed for osseointegration before the sound processor can be attached. A two-stage procedure is recommended in children in whom the fixture is placed into the bone in the first stage. After about 6 months to allow for osseointegration, a second-stage operation is done to connect the abutment through the skin to the fixture.



Dhingra: Diseases of Ear Nose and Throat, 5th Edition  
 Copyright © 2010 Elsevier. All rights reserved.

Figure 20.3 Bone-anchored hearing aid (BAHA).

**Table 20-1. Indications for BAHA**

1. When air-conduction (AC) hearing aid cannot be used:
  - Canal atresia, congenital or acquired, not amenable to treatment.
  - Chronic ear discharge, not amenable to treatment.
  - Excessive feedback and discomfort from air-conduction hearing aid.
2. Conductive or mixed hearing loss, e.g. otosclerosis and tympanosclerosis where surgery is contraindicated.
3. Single-sided hearing loss.

Complications of BAHA are few and may include occasional failure to osseointegrate the implant and local infections and inflammation at the implant site.

### Implantable Hearing Aids

Implantable middle ear hearing aids represent a new category of hearing devices that work on a direct drive principle. Rather than delivering

acoustic energy into the external auditory canal (as with traditional hearing aid systems), direct drive middle ear implant systems use mechanical vibrations delivered directly to the ossicular chain, while leaving the ear canal completely open.

Implantable middle ear devices are generally available in two types:

- **1. Piezoelectric devices** Piezoelectric devices operate by passing an electric current into a piezoceramic crystal, which changes its volume and thereby produce a vibratory signal. This piezoelectric transducer in turn is coupled to the ossicles and drives the ossicular chain by vibration.  
Examples of such devices are: Envoy, MET (middle-ear transducer (or also called Otologics device), Rion and TICA (totally integrated cochlear amplifier).
- **2. Electromagnetic hearing devices** Electromagnetic hearing devices function by passing an electric current into a coil, which creates a magnetic flux that drives an adjacent magnet. The small magnet is attached to one of the ossicles of the middle ear to convey vibrations to the cochlea.  
An example of such a device is the vibrant soundbridge device (previously known as the Symphonix device; now being manufactured by MED-EL).

### ***Vibrant soundbridge device***

The vibrant soundbridge is a semi-implantable device made of two components: an internal and an external. The *internal component* is called VORP (vibrating ossicular prosthesis) and is made up of three parts the receiver, FMT (floating mass transducer) and a conductor link between the two. FMT is connected to the incus (Figs 20.4 and 20.5).

The external component is called the audio processor which is worn behind the ear. The audio processor contains a microphone that picks up sound from the environment and transmits it across the skin by radiofrequency waves to the internal receiver.

### ***Candidacy profile***

Appropriate candidates for direct drive middle ear hearing devices include adults aged 18 years and older with moderate-to-severe sensorineural hearing loss. Candidates should have experience of using traditional hearing aids and should have a desire for an alternative hearing system.

EXTERNAL PART

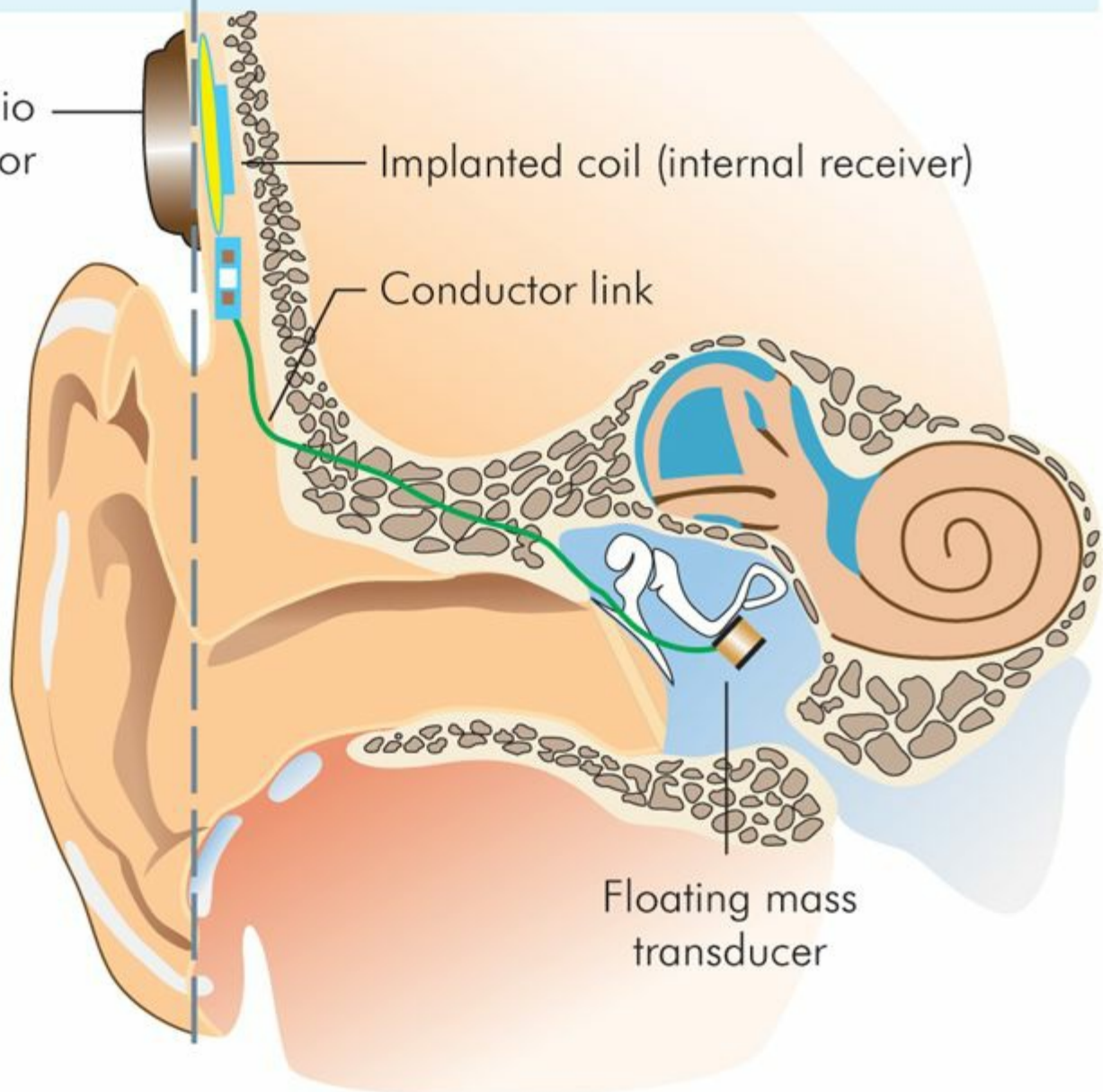
IMPLANTED PART

Audio processor

Implanted coil (internal receiver)

Conductor link

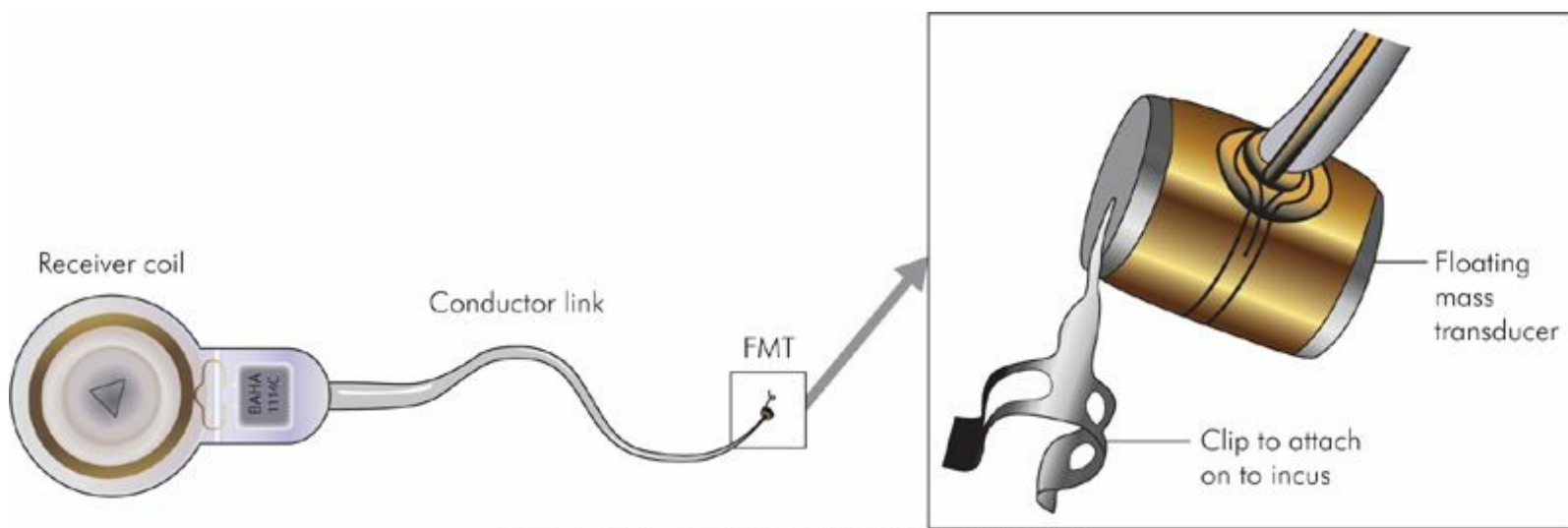
Floating mass transducer



Dhingra: Diseases of Ear Nose and Throat, 5th Edition  
Copyright © 2010 Elsevier. All rights reserved.

Figure 20.4 Vibrant soundbridge middle ear implant.





Dhingra: Diseases of Ear Nose and Throat, 5th Edition  
Copyright © 2010 Elsevier. All rights reserved.

Figure 20.5 Components of the vibrating ossicular prosthesis (VORP).

**Table 20-2. Disadvantages of conventional hearing aids**

- Cosmetically unacceptable due to visibility
- Acoustic feedback
- Spectral distortion
- Occlusion of external auditory canal
- Collection of wax in the canal and blockage of insert
- Sensitivity of canal skin to earmoulds
- Problem to use in discharging ears

Often, patients who are interested in seeking direct drive middle ear hearing devices have experienced dissatisfaction regarding the sound quality of their current hearing aids. Other problems these patients feel with these aids are: discomfort due to the occlusion effect of the canal, wax occluding hearing aid mould and wax impaction of the external auditory canal, inability to wear traditional hearing aids due to sensitive ear canal skin, and the inability to overcome acoustic feedback issues. (see Table 20.2 for disadvantages of conventional hearing aids).

### **Procedure**

The internal device is surgically implanted. The procedure is conducted under general anaesthesia. The receiver of the implant is positioned under the skin over the mastoid bone via a standard cortical mastoidectomy and posterior tympanotomy approach; the ossicular chain is visualised and the FMT is attached to the long process of the incus. The middle ear structures are not modified. Therefore, there is no significant impact on the residual hearing of the patient.

Six to eight weeks after the procedure, the patient is fitted with the external audio processor that attaches magnetically to the back of the ear. The processor is then programmed.

### **Advantages**

A direct drive system provides mechanical energy directly to the ossicles, bypassing the ear canal and the tympanic membrane. This eliminates many of the inherent issues of conventional hearing aids such as occlusion, feedback, discomfort and wax related problems. One major advantage of direct drive devices is the ability to provide improved sound quality to the hearing-impaired subjects particularly in noisy environments.

## B. Implants

### Cochlear Implants

A cochlear implant is an electronic device that can provide useful hearing and improved communication abilities for persons who have severe to profound sensorineural hearing loss and who cannot benefit from hearing aids.

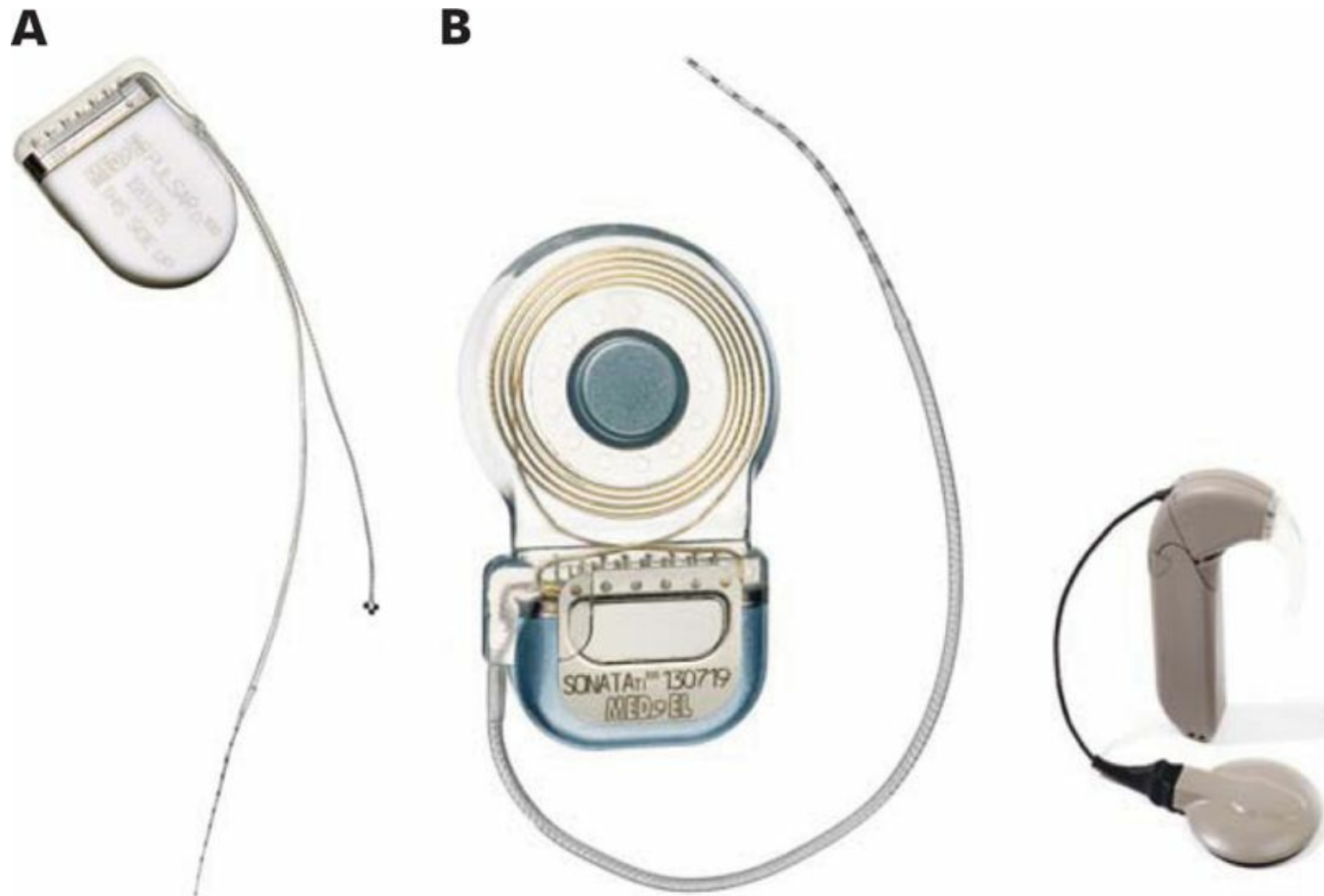
A cochlear implant works by producing meaningful electrical stimulation of the auditory nerve where degeneration of the hair cells in the cochlea has progressed to a point such that amplification provided by hearing aids is no longer effective. Various cochlear implants are shown in Figs 20.6 to 20.8.

#### Components and Functioning of a Cochlear Implant (Fig. 20.9)

A cochlear implant has an external and internal component.

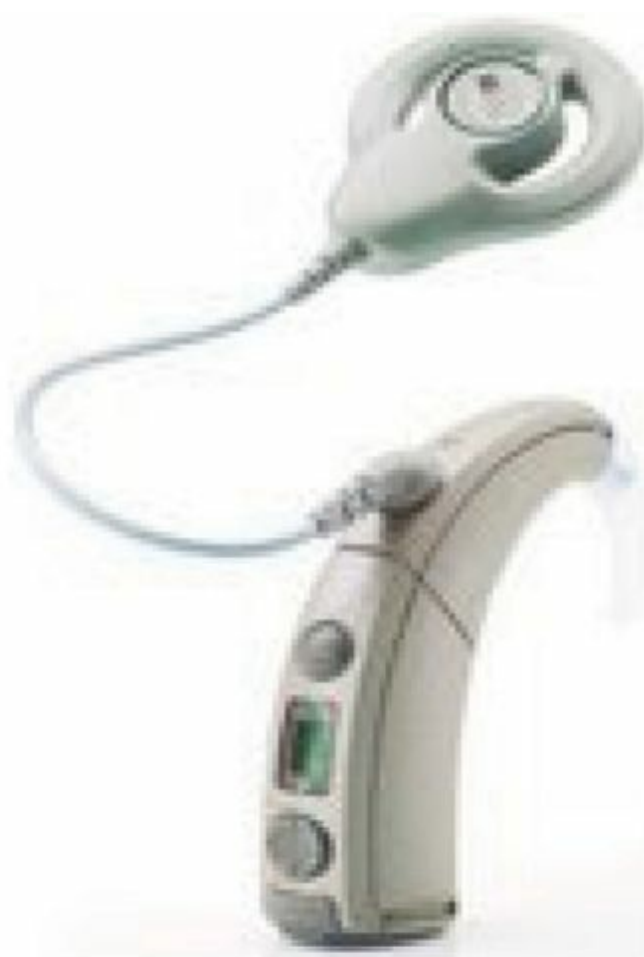- **1. External component** It consists of an external speech processor and a transmitter. The speech processor may be body worn or behind the ear type; the latter being preferred.
- **2. Internal component** It is surgically implanted and comprises the *receiver/stimulator* package with an *electrode array*.

Sound is picked up by the microphone in the speech processor. The speech processor analyses and codes sounds into electrical pulses. The processor uses a variety of coding strategies to deliver meaningful speech parameters from the acoustic stimulus to the nerve. Examples of such strategies are SAS (simultaneous analogue strategy), CIS (continuous interleaved sampling), SPEAK (spectral peak) and ACE (advanced combination encoder).



Dhingra: Diseases of Ear Nose and Throat, 5th Edition  
Copyright © 2010 Elsevier. All rights reserved.

Figure 20.6 MED-EL cochlear implants: (A) MED-EL C-40+. (B) Sonata model with ear level speech processor.

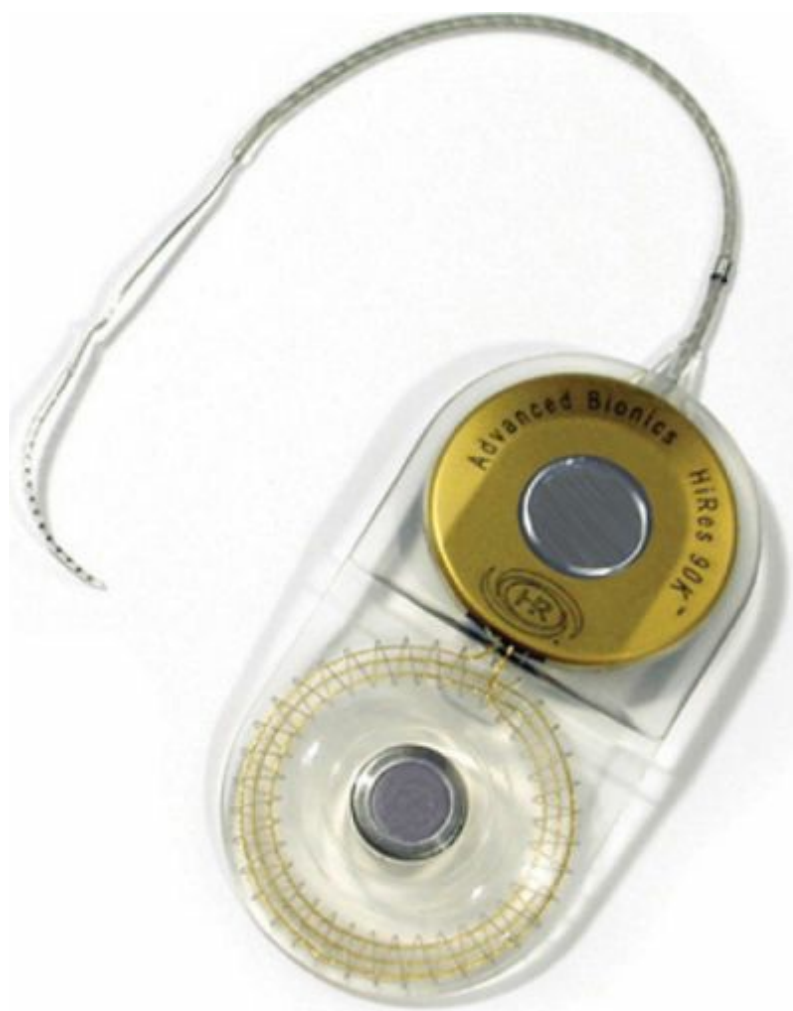

Dhingra: Diseases of Ear Nose and Throat, 5th Edition  
Copyright © 2010 Elsevier. All rights reserved.

Figure 20.7 Nucleus cochlear implant (Cochlear Corporation) with ear level speech processor.

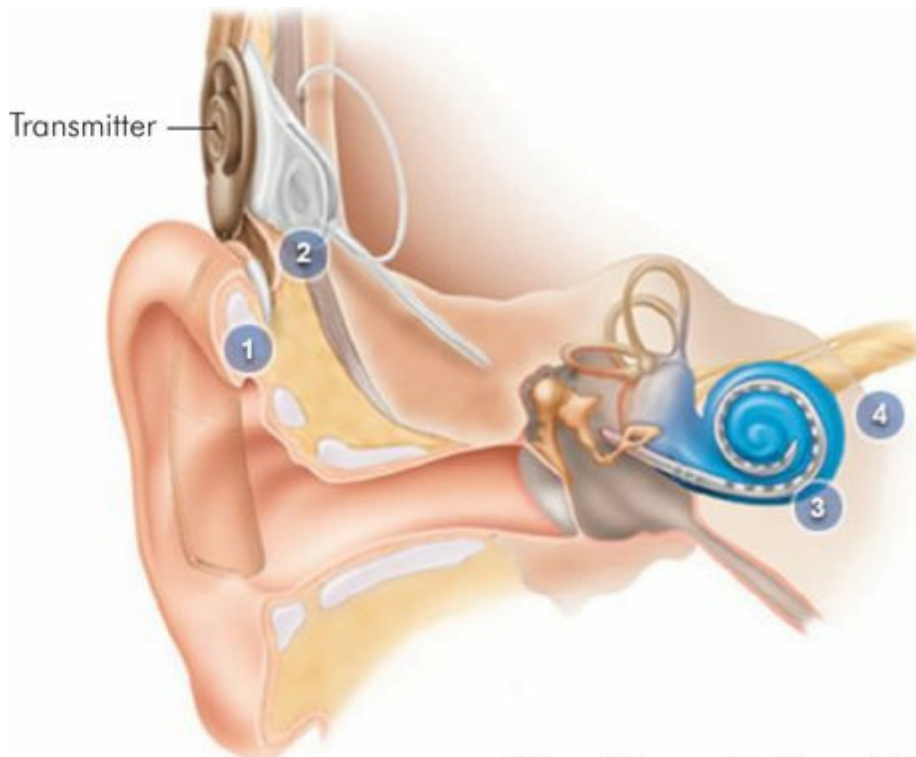
The electrical impulses are sent from the processor to the transmitting coil which in turn sends the signal to the surgically implanted receiver/stimulator via radiofrequency. The receiver/stimulator decodes the signal and transmits it to the electrode array. Current day implants are multichannel processors with the electrode having a linear array of electrode contacts used to deliver multiple channels of current to different places along the basilar membrane. The electrode array which has been placed in the scala tympani of the cochlea stimulates the spiral ganglion cells. The auditory nerve is thus stimulated and sends these electrical pulses to the brain which are finally interpreted as sound.

### ***Candidacy profile***



Dhingra: Diseases of Ear Nose and Throat, 5th Edition  
Copyright © 2010 Elsevier. All rights reserved.

Figure 20.8 Advanced bionics cochlear implant system.



1. External speech processor captures sound and converts it to digital signals
2. Processor sends digital signals to internal implant
3. Internal implant turns signals into electrical energy, sending it to an array inside the cochlea
4. Electrodes stimulate hearing nerve, bypassing damaged hair cells, and the brain perceives signals; you hear sound

Dhingra: Diseases of Ear Nose and Throat, 5th Edition  
Copyright © 2010 Elsevier. All rights reserved.

Figure 20.9 Principle of cochlear implant.

Cochlear implants may be used both in children and adults. The following criteria help define candidacy for cochlear implantation:

- Bilateral severe to profound sensorineural hearing loss.
- Little or no benefit from hearing aids.
- No medical contraindication for surgery.
- Realistic expectation.
- Good family and social support toward habilitation.
- Adequate cognitive function to be able to use the device.

Candidates with such hearing impairment may be defined as pre-lingual or post-lingual depending on whether they were deafened before or after the acquisition of speech and language.

In children who have hearing impairment at birth or early in childhood, early intervention with hearing aids or a cochlear implant is vital for auditory stimulus. Auditory deprivation, i.e. lack of auditory stimulus in the early developmental period causes degeneration in the central auditory pathways. This will limit the benefit in terms of speech and language acquisition following cochlear implantation.

## Outcomes of Cochlear Implantation

Factors that predict a successful clinical outcome are:

- Previous auditory experience (post-lingual patients or prior use of hearing aids).
- Younger age at implantation (especially for pre-lingual children).
- Shorter duration of deafness.
- Neural plasticity within the auditory system.

Multichannel implants are the standard today and perform much better than single-channel devices. Post-lingual children or adults achieve very good benefit. They develop the ability to recognize speech with no or minimal lip reading or visual cues. They eventually can also use the telephone.

Pre-lingually deafened children also develop good speech understanding and language acquisition over a period of time. This can take a couple of years and requires constant auditory-verbal training. Early age at implantation ensures better results and children can be implanted at 12 months of age.

page 139

page 140

Pre-lingually deafened adults with no or little prior auditory experience obtain very limited benefit from cochlear implantation. They will however obtain sound awareness.

## Evaluation

Thorough evaluation of the patient is very critical in the selection of candidates for a cochlear implant. The main purpose is to determine if the patient is medically and audiotologically suitable for an implant. It also helps the clinicians to predict and counsel the family regarding the expected outcomes following the procedure.

Medical evaluation through detailed history and physical examination is necessary to confirm fitness for a general anaesthetic. The necessary preanaesthetic tests will be required to be carried out. All candidates must be fully vaccinated against meningitis (particularly *Haemophilus Influenzae* type B, *Pneumococcus* and in some areas *Meningococcus*).

Imaging of the temporal bone, cochlea, auditory nerve and brain is carried out using CT and MRI. This is required to provide an image of the structure of the cochlea and help identify any anomalies or pathology that may complicate the implantation process.

Audiological evaluation may include some or all of the following depending on the age of the patient:

- Pure tone audiogram
- Speech discrimination tests
- Tympanometry
- Otoacoustic emissions (OAE)
- Auditory brainstem responses (ABR) and
- Auditory steady state responses (ASSR).

A hearing aid trial and evaluation is mandatory in determining the candidacy for cochlear implantation. This may include aided free-field sound detection thresholds, as well as aided speech perception and discrimination scores.

Speech and language evaluation is required to assess the child's communicative status and to determine any developmental language or articulation disorders. This will also form a baseline for further evaluations post-implantation to help assess progress and identify areas of deficit in speech perception. This in turn would aid in the programming of the patient's device.

Psychological evaluation is performed where there may be concerns regarding the cognitive status or mental function of the patient. This is also important to identify children who may have disabilities other than hearing loss. This may provide information that is important when counselling parents about expectations following cochlear implantation.

## Surgery

The principle of cochlear implant surgery is to place the electrode array within the scala tympani of the cochlea. This allows the electrodes to be in close proximity to the spiral ganglion cells and their dendrites (that lie in the modiolus and osseous spiral lamina of the cochlea, respectively).

Surgery is carried out under general anaesthesia and is similar to mastoid surgery. Once the patient is positioned, prepped and draped, the position of the device is marked and the incision planned. Flaps are elevated carefully so as not to disrupt the blood supply. Usually, a two-layered approach is chosen utilising a flap of skin and subcutaneous tissue, followed by a second layer of musculo-periosteal flap. A pocket is created under the second flap and a well or recess is drilled in the bone to house the receiver/stimulator.

There are broadly two surgical techniques to approach the cochlea for implantation. (i) The facial recess approach where a simple cortical mastoidectomy is done first and the short process of the incus and the lateral semicircular canal are identified. The facial recess is opened by performing a posterior tympanotomy. The stapes, promontory and round window niche are identified. Cochleostomy is then performed antero-inferior to the round window membrane to a diameter of 1.0 to 1.6 mm depending on the electrode to be used. (ii) The pericanal techniques where a tympanomeatal flap is elevated to perform a cochleostomy either by endaural or postaural approach. In the pericanal techniques a bony tunnel is drilled along the external canal towards the middle ear. The examples of pericanal techniques include the *Veria and suprameatal recess approach*.

The device is placed in the "well" created and is secured with ties. The electrode array is gently and gradually inserted through the cochleostomy till complete insertion has been achieved. Electrophysiological testing is carried out to check that the electrode impedances and telemetry responses are satisfactory.

The wound is closed in layers and a mastoid bandage applied.

## Postoperative Mapping (Programming) of Device and Habilitation

Activation of the implant is done 3 to 4 weeks after implantation. Following this the implant is "programmed" or "mapped". Mapping is done on a regular basis during postoperative rehabilitation to fine tune the processor and get the best performance as the patient gets used to hearing with the implant.

(Re) Habilitation is an essential part for those who have undergone cochlear implantation. All patients need auditory-verbal therapy. In auditory-verbal therapy, the emphasis is laid on making the child listen and speak like a normal person rather than use lip reading and visual cues. Learning to listen takes time and requires concerted efforts from the patient, the family and the person providing habilitation services.

page 140

page 141

**Table 20-3. Complications of cochlear implant surgery**

Early complications	Late complications
<ul style="list-style-type: none"> <li>● Facial paralysis</li> <li>● Wound infection</li> <li>● Wound dehiscence</li> <li>● Flap necrosis</li> <li>● Electrode migration</li> <li>● Device failure</li> <li>● CSF leak</li> <li>● Meningitis</li> <li>● Post-operative dizziness/vertigo</li> </ul>	<ul style="list-style-type: none"> <li>● Exposure of device and extrusion</li> <li>● Pain at the site of implant</li> <li>● Migration/displacement of device</li> <li>● Late device failure</li> <li>● Otitis media</li> </ul>

Table 20.3 summarises the complications of cochlear implant surgery.

## Auditory Brainstem Implant (ABI)

This implant is designed to stimulate the cochlear nuclear complex in the brainstem directly by placing the implant in the lateral recess of the fourth ventricle. Such an implant is needed when CN VIII has been severed in surgery of vestibular schwannoma. In these cases, *cochlear* implants are obviously of no use. In unilateral acoustic neuroma, ABI is not necessary as hearing is possible from the contralateral side but in bilateral acoustic neuromas as NF<sub>2</sub>, rehabilitation is required by ABI.

Brainstem implant is similar to "Nucleus" multichannel cochlear implant except that the multielectrode array is attached to a decron mesh which is placed on the brainstem. Receiver/stimulator has a removable magnet so that MRI can be safely performed in such cases if need arises.

ABIs help in communication, awareness and recognition of environmental sounds; however they are not as efficient as multichannel cochlear implants. Only limited number of such implants have been performed in the world and are under constant technological developments.

## C. Assistive Devices

Hearing-impaired persons should enjoy life as normally hearing persons do. For this, devices are needed to help him to listen in special difficult situations, warn him of danger signals and help him to telecommunicate with his family and friends who are far away from him. These devices can thus be divided into three groups:

### 1. Assistive Listening Devices and Systems

They are not hearing aids but devices which help the hearing impaired to listen efficiently in the presence of background noise, over the telephone, in auditoriums or theatres. They may be used by the person individually or are meant for a group.

According to the technology used, they are grouped as hard-wired system, induction loops, AM (amplitude modulation), FM (frequency modulation) or infra-red signals.

### 2. Alerting Devices

A hearing-impaired person may not hear a telephone or a doorbell, a baby crying in another room, an alarm clock or the noise of a smoke detector. Alerting devices are useful in such situations. They produce an extra loud sound signal or relay the signal to an area close to the individual. A "hearing dog" is one such simple device. The dog is trained to bark loudly at the sound of a doorbell, cry of a baby, etc.

For people with severe to profound or total deafness, even these devices which produce extra-loud sound may not be useful. They need assistive signalling devices where the sound (as of doorbell, telephone, alarm clock, baby crying) is changed into a light signal or vibrations. Alarm clock with flashing lights or those devices which produce strong vibrations to awaken the individual or even shake his bed are also available.

### 3. Telecommunication Devices

A telephone amplifier can be attached to the hand set of a telephone, residential or public, to amplify the sound. A telephone coupler is a device that can be connected to the telephone and the signal produced is picked up by the hearing aid.

For the profoundly or totally deaf individuals, Telecommunication Devices for the Deaf (TDDs) can be used. They convert typed message into sounds that can be transmitted over the standard telephone lines, and at the other end another TDD converts these sound signals back into typewritten messages.

Closed-caption television decoder can be attached to television sets to provide them cues to enjoy news, movies and other programmes.

## **II. TRAINING**

### **A. Speech Reading**

Earlier called lip-reading, it is an integrated process to understand speech by studying movements of lips, facial expression, gestures and the probable context of conversation. The skill of speech reading is not only useful for the totally deaf but also useful for those hearing-impaired individuals who have high frequency loss and difficulty in hearing in noisy surroundings.



## B. Auditory Training

It enhances listening skill and is used with speech reading. The patient is exposed to various listening situations with different degrees of difficulty and taught selectively to concentrate on speech sounds.

Auditory training is useful for those using hearing aids and cochlear implants.

## C. Speech Conservation

In sudden, severe or profound hearing loss, the person loses the ability to monitor his own speech production. As a result, defects arise in articulation, resonance, pitch and the volume of voice. Speech conservation aims to educate such a person to use his tactile and proprioceptive feedback systems to monitor his speech production.

## **21 Otagia (Earache)**

Pain in the ear can be due to causes occurring locally in the ear or referred to it from remote areas.

## A. Local Causes

### **1. External ear**

Furuncle, impacted wax, otitis externa, otomycosis, myringitis bullosa, herpes zoster, and malignant neoplasms.

### **2. Middle ear**

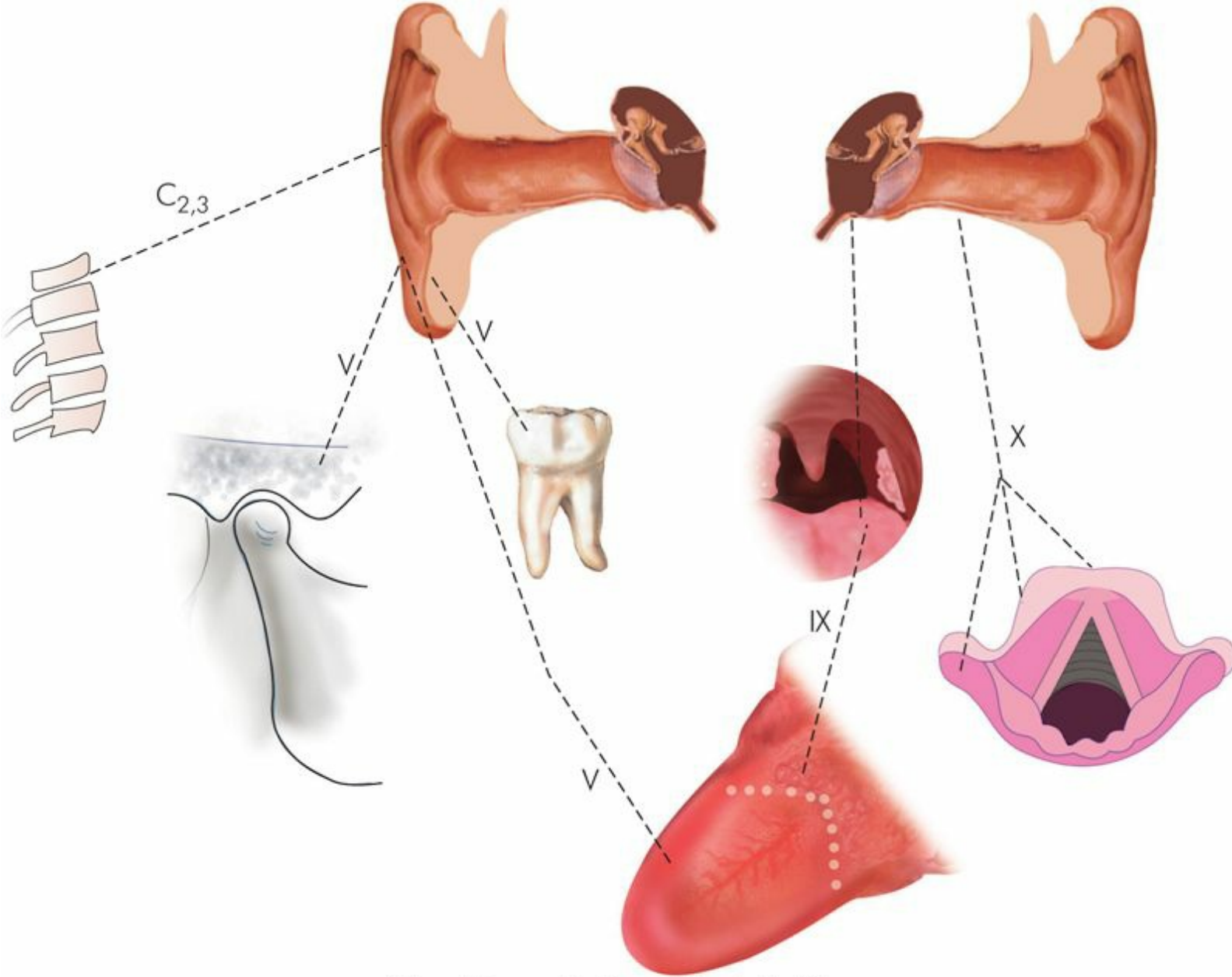
Acute otitis media, eustachian tube obstruction, mastoiditis, extradural abscess, aero-otitis media, and carcinoma middle ear.

## B. Referred Causes

As ear receives nerve supply from Vth (auriculotemporal br.), IXth (tympanic br.) and Xth (auricular br.) cranial nerves; and from C<sub>2</sub> (lesser occipital) and C<sub>2</sub> and C<sub>3</sub> (greater auricular), pain may be referred from these remote areas (Fig. 21.1).

### 1. Via Vth cranial nerve

- (a) *Dental*. Caries tooth, apical abscess, impacted molar, malocclusion.
- (b) *Oral cavity*. Benign or malignant ulcerative lesions of oral cavity or tongue.



Dhingra: Diseases of Ear Nose and Throat, 5th Edition  
Copyright © 2010 Elsevier. All rights reserved.

Figure 21.1 Referred causes of otalgia. Pain is referred via CN V (teeth, oral cavity, TM joint, anterior two thirds of tongue), C<sub>2,3</sub> (cervical spine), CN IX (tonsil, base of tongue, elongated styloid process) and CN X (vallecula, pyriform fossa or larynx).

- (c) *Temporomandibular joint disorders*. Bruxism, osteoarthritis, recurrent dislocation, ill-fitting denture.

- (d) *Sphenopalatine neuralgia*.

### 2. Via IXth cranial nerve

- (a) *Oropharynx*. Acute tonsillitis, peritonsillar abscess, tonsillectomy. Benign or malignant ulcers of soft palate, tonsil and its pillars.

(b) *Base of tongue*. Tuberculosis or malignancy.

(c) *Elongated styloid process*.

**3. Via Xth cranial nerve**

Malignancy or ulcerative lesion of: vallecula, epiglottis, larynx or laryngopharynx, oesophagus.

**4. Via C<sub>2</sub> and C<sub>3</sub> spinal nerves**

Cervical spondylosis, injuries of cervical spine, caries spine.

## C. Psychogenic Causes

When no cause has been discovered, pain may be functional in origin but the patient should be kept under observation with periodic re-evaluation.

Otalgia is a *symptom*. It is essential to find its cause before specific treatment can be instituted.

## 22 Tinnitus

Tinnitus is ringing sound or noise in the ear. The characteristic feature is that the origin of this sound is *within* the patient. Usually, it is unilateral but may also affect both ears. It may vary in pitch and loudness and has been variously described by the patient as roaring, hissing, swishing, rustling or clicking type of noise. Tinnitus is more annoying in quiet surroundings, particularly at night, when the masking effect of ambient noise from the environment is lost.



## Types of Tinnitus

Two types of tinnitus are described:

- **(a)** Subjective, which can only be heard by the patient.
- **(b)** Objective, which can *even* be heard by the examiner with the use of a stethoscope.

## Causes of Tinnitus (Table 22.1)

*Subjective tinnitus* may have its origin in the external ear, middle ear, inner ear, VIIIth nerve or the central nervous system. Systemic disorders like anaemia, arteriosclerosis, hypertension and certain drugs may act through the inner ear or central auditory pathways. In the presence of conductive deafness, the patient may hear abnormal noises in the head during eating, speaking or even respiration.

*Objective tinnitus* is seen less frequent. Vascular lesions, e.g. glomus tumour or carotid artery aneurysm cause swishing tinnitus synchronous with pulse. It can be temporarily abolished by pressure on the common carotid artery. Venous hum can sometimes be stopped by pressure on the neck veins.

Tinnitus synchronous with respiration may occur due to abnormally patent eustachian tube. Palatal myoclonus produces clicking sound due to clonic contraction of the muscles of soft palate and can be easily diagnosed. Clonic contraction of muscles of middle ear (stapedius and tensor tympani) may cause tinnitus which is often difficult to diagnose.

Sometimes, tinnitus is psychogenic and no cause can be found in the ear or central nervous system.

Tinnitus should be differentiated from auditory hallucinations in which a person hears voices or other organised sounds like that of music. It is seen in psychiatric disorders.

Table 22-1. Causes of tinnitus

A. Subjective	
I. Otologic <ul style="list-style-type: none"> <li>• Impacted wax</li> <li>• Fluid in the middle ear</li> <li>• Acute and chronic otitis media</li> <li>• Abnormally patent eustachian tube</li> <li>• Meniere's disease</li> <li>• Otosclerosis</li> <li>• Presbycusis</li> <li>• Noise trauma</li> <li>• Ototoxic drugs</li> <li>• Tumours of VIIIth nerve</li> </ul>	II. Non-otologic <ul style="list-style-type: none"> <li>• Diseases of CNS</li> <li>• Anaemia</li> <li>• Arteriosclerosis</li> <li>• Hypertension</li> <li>• Hypotension</li> <li>• Hypoglycaemia</li> <li>• Epilepsy</li> <li>• Migraine</li> <li>• Drugs</li> </ul>
B. Objective	
<ul style="list-style-type: none"> <li>• Vascular tumours of middle ear (glomus tumour)</li> <li>• Aneurysm of carotid artery</li> <li>• Palatal myoclonus</li> </ul>	
C. Psychogenic	

page 145

page 146

Tinnitus is a symptom and not a disease. Where possible, its cause should be discovered and treated. Sometimes, even the treatment of cause may not alleviate tinnitus. When no cause is found, management of tinnitus includes:

- **1. Reassurance and psychotherapy.** Many times the patient has to learn to live with tinnitus.
- **2. Techniques of relaxation and biofeedback.**
- **3. Sedation and tranquillizers.** They may be needed in initial stages till patient has adjusted to the symptom.
- **4. Masking of tinnitus.** Tinnitus is more annoying at bed time when the surroundings are quite. Use of a fan, loudly clicking clock or a similar device may mask the tinnitus and help the patient to go to sleep. Use of a hearing aid, in persons with hearing loss, not only improves hearing but also provides a masking effect.

Tinnitus maskers can be used in patients who have no hearing loss. They are worn like a hearing aid. Use of tinnitus masker for a short time may provide, in some individuals, a symptom-free period for several hours due to the phenomenon of *residual inhibition*.

page 146

page 147

## SECTION II Diseases of Nose and Paranasal Sinuses

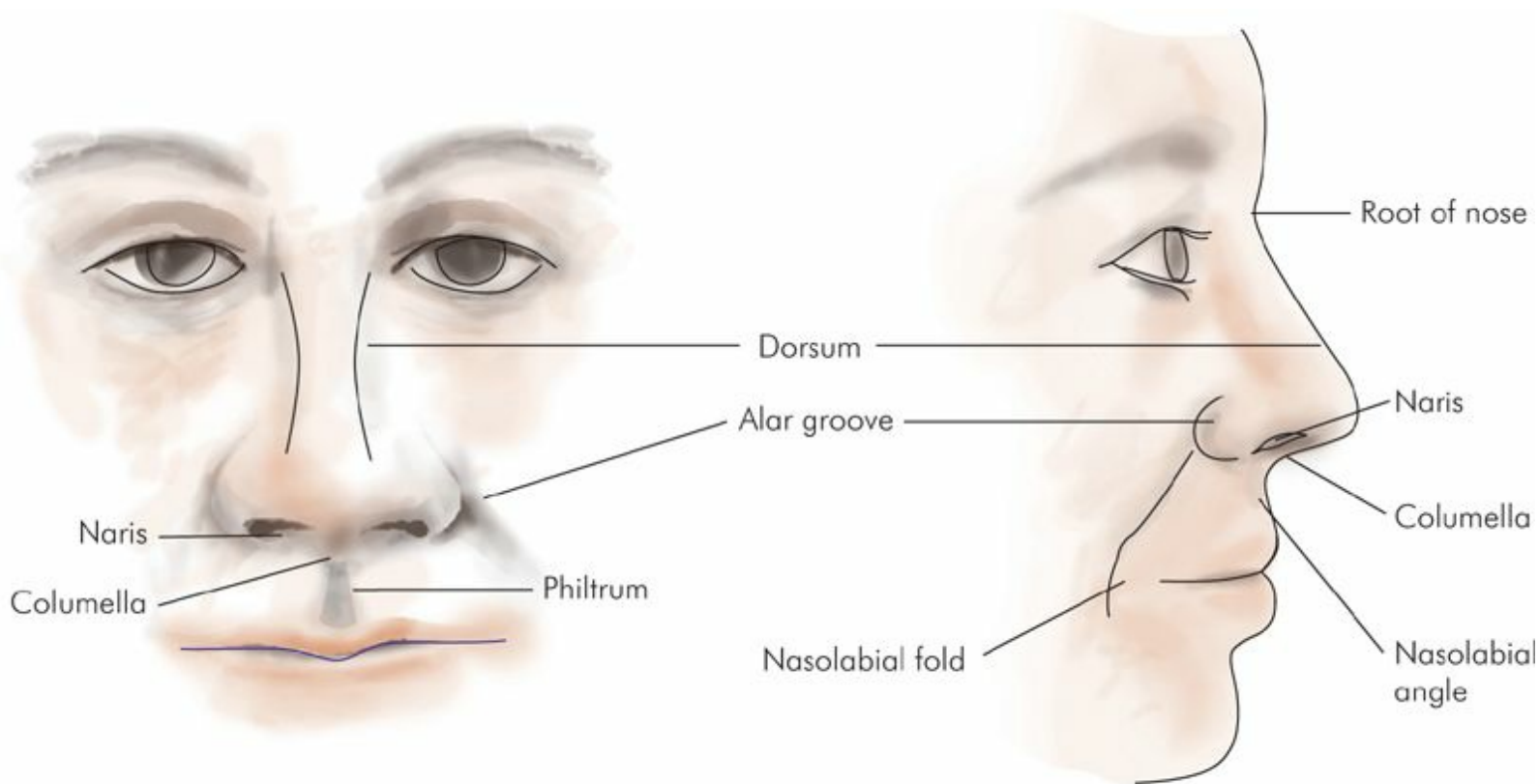
### EXTERNAL NOSE

It is pyramidal in shape with its root up and the base directed downwards. Various terms used in its description are shown in Fig. 23.1. Nasal pyramid consists of osteocartilaginous framework covered by muscles and skin.

# Osteocartilaginous Framework

## Bony Part

Upper one-third of the external nose is bony while lower two-thirds are cartilaginous. The bony part consists of two nasal bones which meet in the midline and rest on the upper part of the nasal process of the frontal bones and are themselves held between the frontal processes of the maxillae (Fig. 23.2).



Dhingra: Diseases of Ear Nose and Throat, 5th Edition  
Copyright © 2010 Elsevier. All rights reserved.

Figure 23.1 Various parts of nose and related facial structures.

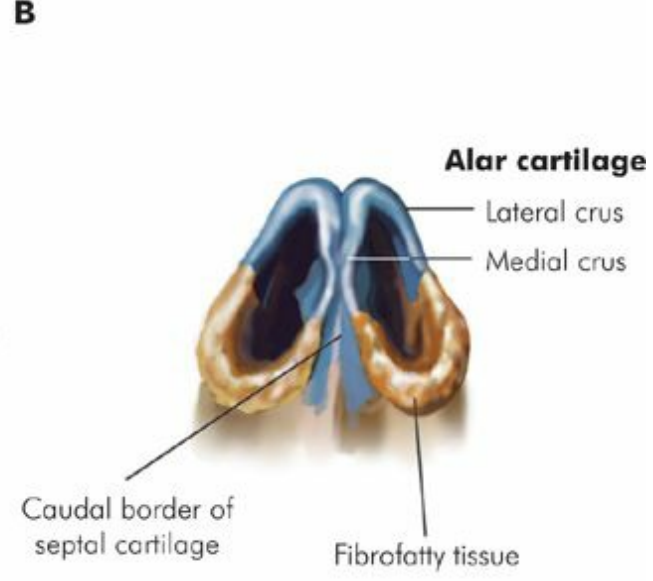
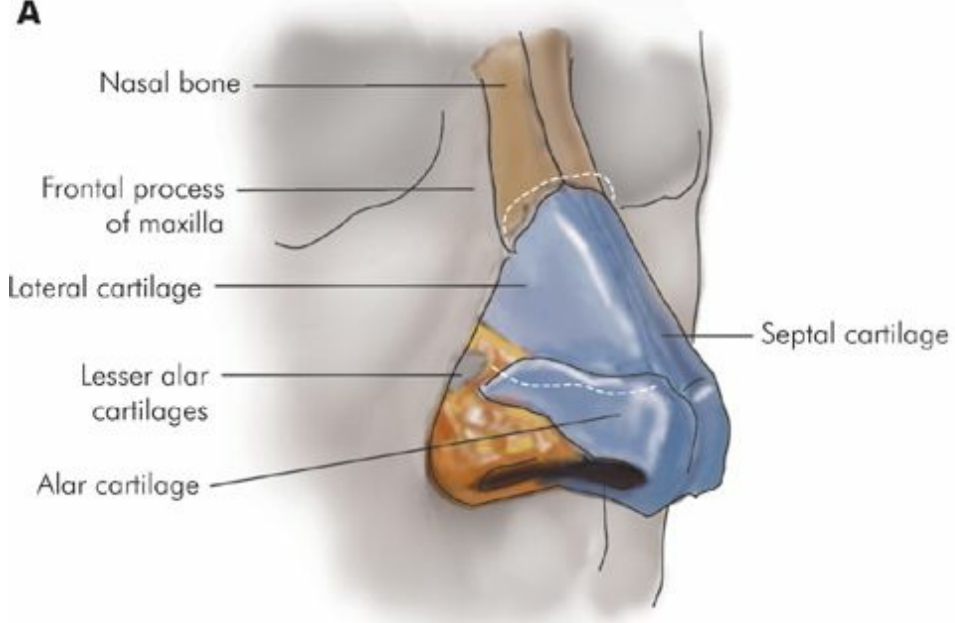
## Cartilaginous Part

page 149

page 150

It consists of:

- **(a) Upper lateral cartilages.** They extend from the undersurface of the nasal bones above, to the alar cartilages below. They fuse with each other and with the upper border of the septal cartilage in the midline anteriorly. The lower free edge of upper lateral cartilage is seen intranasally as *limen vestibuli* or *nasal valve* on each side.
- **(b) Lower lateral cartilages (alar cartilages).** Each alar cartilage is U-shaped. It has a lateral crus which forms the ala and a medial crus which runs in the columella. Lateral crus overlaps lower edge of upper lateral cartilage on each side.
- **(c) Lesser alar (or sesamoid) cartilages.** Two or more in number. They lie above and lateral to alar cartilages. The various cartilages are connected with one another and with the adjoining bones by perichondrium and periosteum. Most of the free margin of nostril is formed of fibrofatty tissue and not the alar cartilage.
- **(d) Septal cartilage.** Its anterosuperior border runs from under the nasal bones to the nasal tip. It supports the dorsum of the cartilaginous part of the nose. In septal abscess or after excessive removal of septal cartilage as in SMR (submucosal resection) operation, support of nasal dorsum is lost and a supratip depression results.



Dhingra: Diseases of Ear Nose and Throat, 5th Edition  
 Copyright © 2010 Elsevier. All rights reserved.

Figure 23.2 Osteocartilaginous framework of nose. (A) Lateral view. (B) Basal view.

## Nasal Musculature

Osteocartilaginous framework of nose is covered by muscles which bring about movements of the nasal tip, ala and the overlying skin. They are the procerus, nasalis (transverse and alar parts), levator labii superioris alaeque nasi, anterior and posterior dilator nares and depressor septi.

## Nasal Skin

The skin over the nasal bones and upper lateral cartilages is thin and freely mobile while that covering the alar cartilages is thick and adherent, and contains many sebaceous glands. It is the hypertrophy of these sebaceous glands which gives rise to a lobulated tumour called rhinophyma (see page 160).



## INTERNAL NOSE

It is divided into right and left nasal cavities by nasal septum. Each nasal cavity communicates with the exterior through *naris* or nostril and with the nasopharynx through posterior nasal aperture or the *choana*. Each nasal cavity consists of a skin-lined portion-the vestibule, and a mucosa-lined portion, the nasal cavity proper.

## Vestibule of Nose

Anterior and inferior part of nasal cavity is called the vestibule. It is lined by skin and contains sebaceous glands, hair follicles and the hair called *vibrissae*. Its upper limit on the lateral wall is marked by limen nasi (nasal valve) which is formed by the caudal margin of upper lateral cartilage. Its medial wall is formed by the columella and lower part of the nasal septum up to its mucocutaneous junction.

# Nasal Cavity Proper

Each nasal cavity has a lateral wall, a medial wall, a roof and a floor.

## Lateral nasal wall

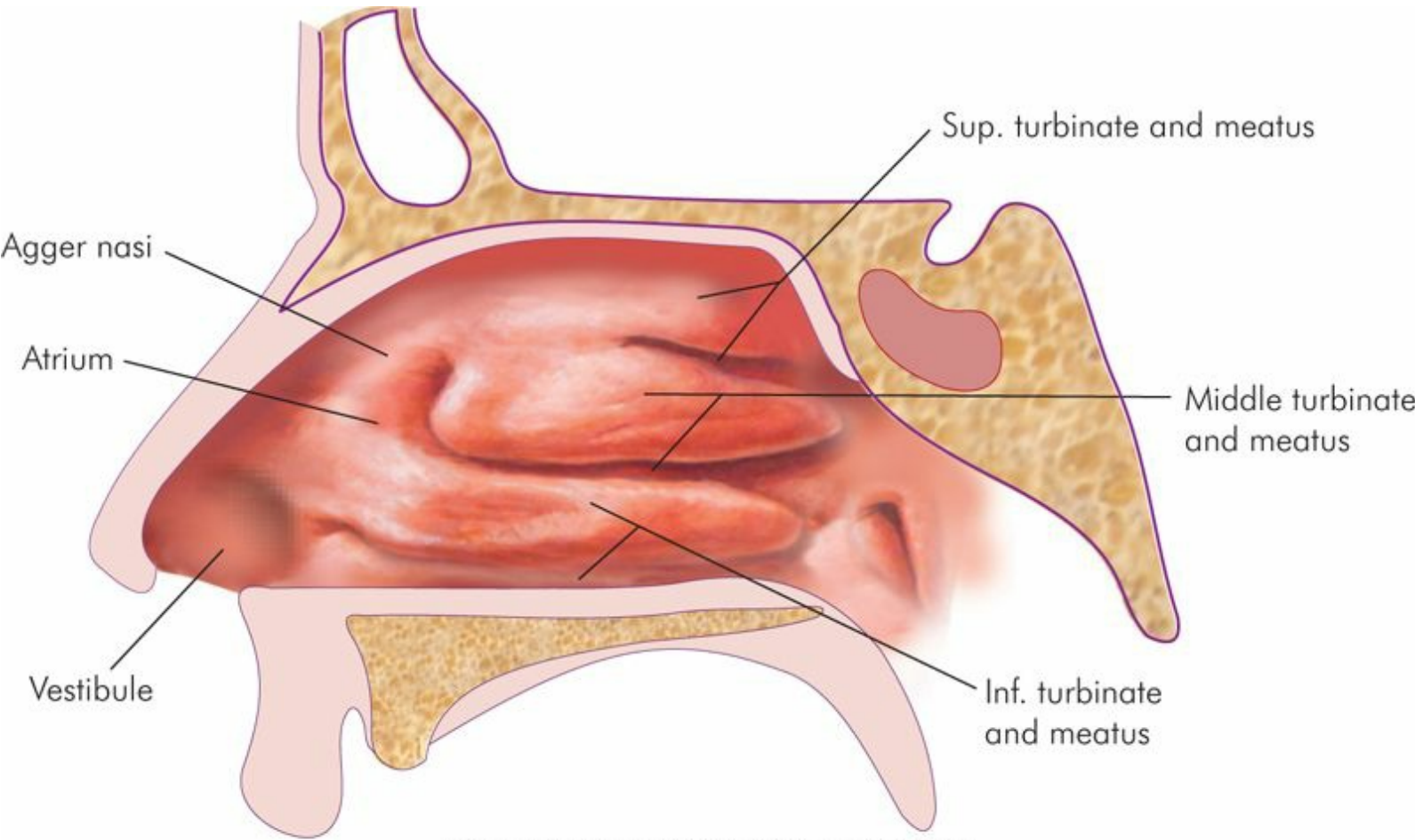
Three and occasionally four turbinates or conchae mark the lateral wall of nose. Conchae or turbinates are scroll-like bony projections covered by mucous membrane. The spaces below the turbinates are called meatuses (Figs 23.3 and 23.4).

## Inferior turbinate

is a separate bone and below it, into the inferior meatus, opens the nasolacrimal duct guarded at its terminal end by a mucosal valve called Hasner's valve.

## Middle turbinate

page 150  
page 151



Dhingra: Diseases of Ear Nose and Throat, 5th Edition  
Copyright © 2010 Elsevier. All rights reserved.

Figure 23.3 Structures on lateral wall of nose.

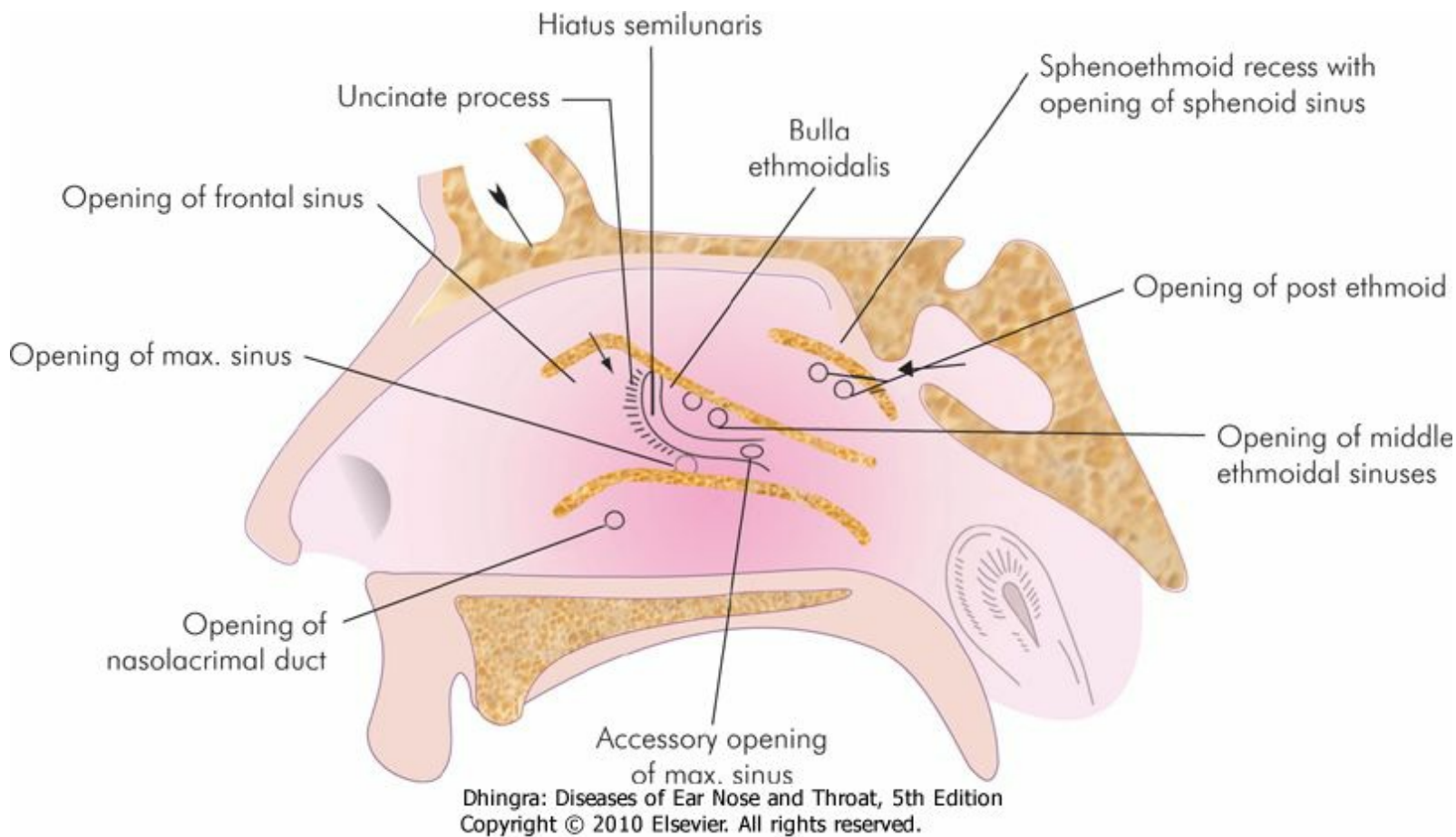


Figure 23.4 Lateral wall of nose with turbinates removed showing openings of various sinuses.

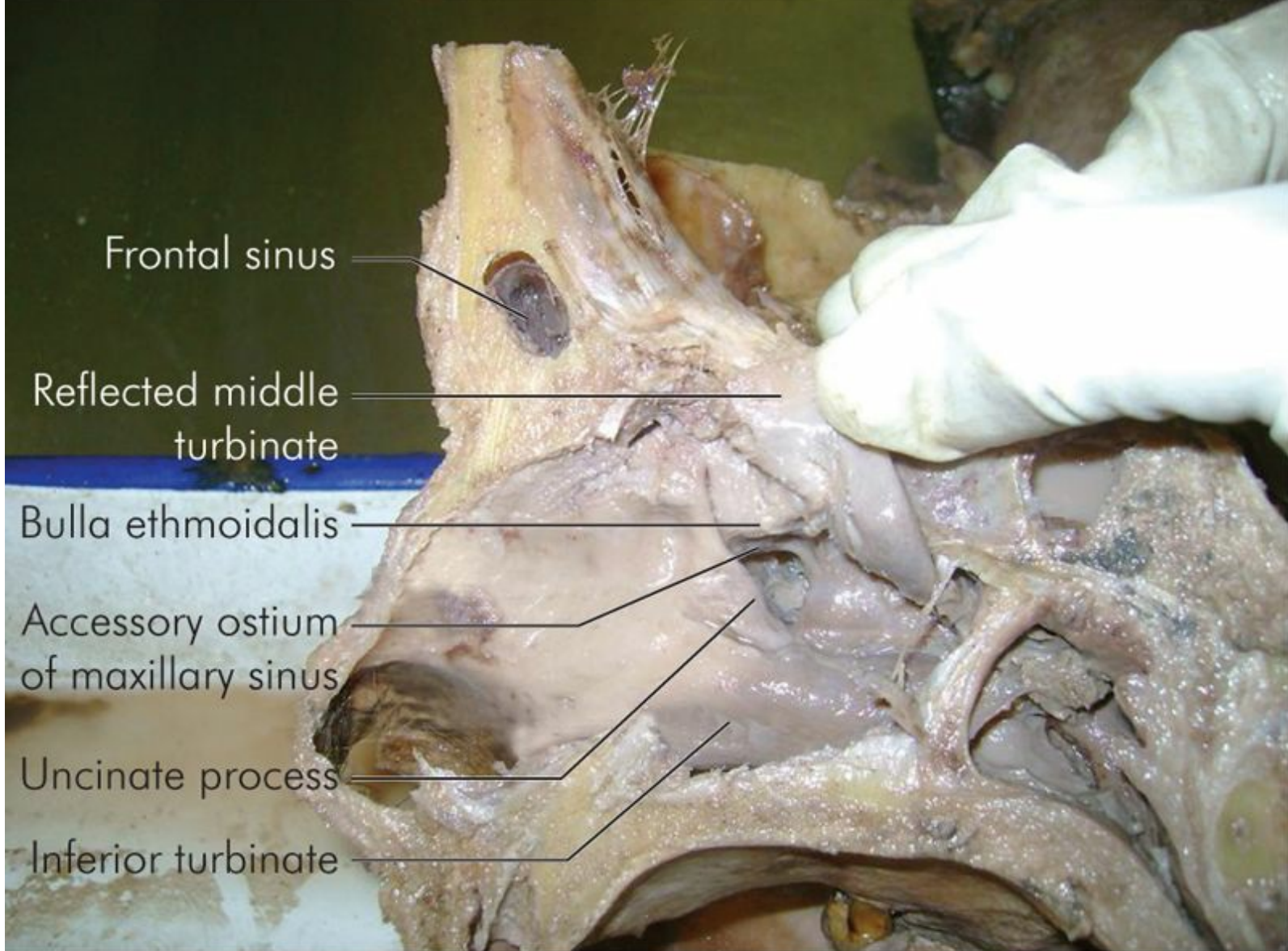
is an ethmoturbinal—a part of ethmoid bone. It is attached to the lateral wall by a bony lamella called *ground or basal lamella*. Its attachment is not straight but in an S-shaped manner. In the anterior third, it lies in sagittal plane and is attached to lateral edge of cribriform plate. In the middle third, it lies in frontal plane and is attached to lamina papyracea while in its posterior third, it runs horizontally and forms roof of the middle meatus and is attached to lamina papyracea and medial wall of maxillary sinus.

The ostia of various sinuses draining anterior to basal lamella form *anterior group of paranasal sinuses* while those which open posterior and superior to it form the *posterior group*.

#### *Middle meatus*

shows several important structures which are important in endoscopic surgery of the sinuses (Fig. 23.5).

*Uncinate process* is a hook-like structure running in from anterosuperior to posteroinferior direction. Its posterosuperior border is sharp and runs parallel to anterior border of bulla ethmoidalis; the gap between the two is called *hiatus semilunaris* (inferior). It is a two-dimensional space of 1-2 mm width.



Dhingra: Diseases of Ear Nose and Throat, 5th Edition  
 Copyright © 2010 Elsevier. All rights reserved.

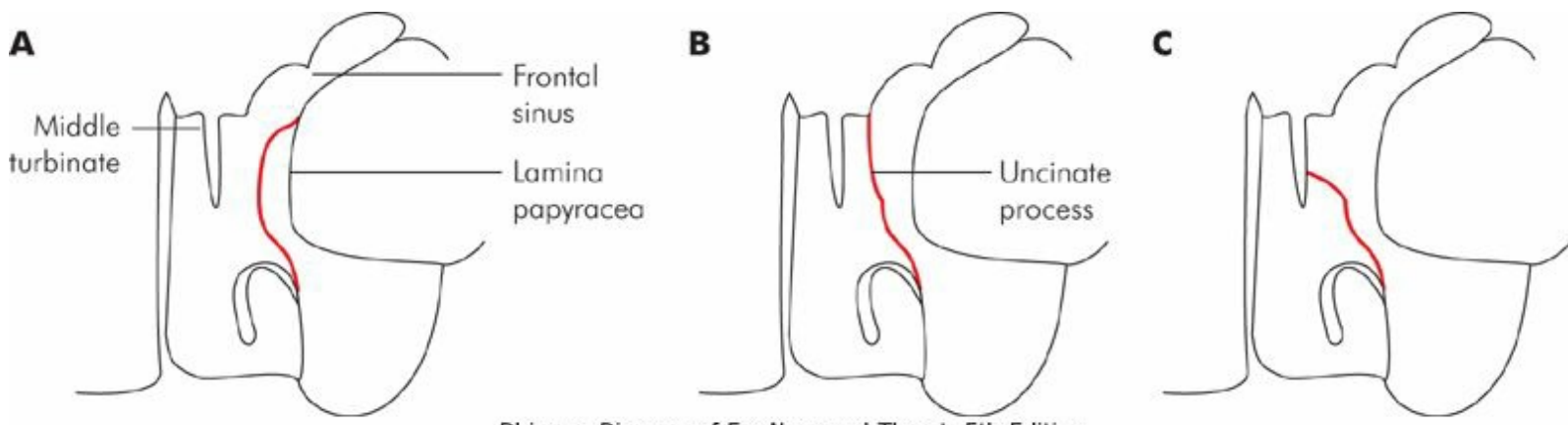
Figure 23.5 Lateral wall of nose. Middle turbinate is reflected upwards to show structures of the middle meatus.

The anteroinferior border of uncinat process is attached to the lateral wall. Posteroinferior end of uncinat process is attached to inferior turbinate dividing the membranous part of lower middle meatus into anterior and posterior fontanelle. The fontanel area is devoid of bone and consists of membrane only and leads into maxillary sinus when perforated. Upper attachment of uncinat process shows great variation and may be inserted into the lateral nasal wall, upwards into the base of skull or medially into the middle turbinate (Fig. 23.6). This also accounts for variations in drainage of frontal sinus.

The space limited medially by the uncinat process and frontal process of maxilla and sometimes lacrimal bone, and laterally by the lamina papyracea is called *infundibulum*.

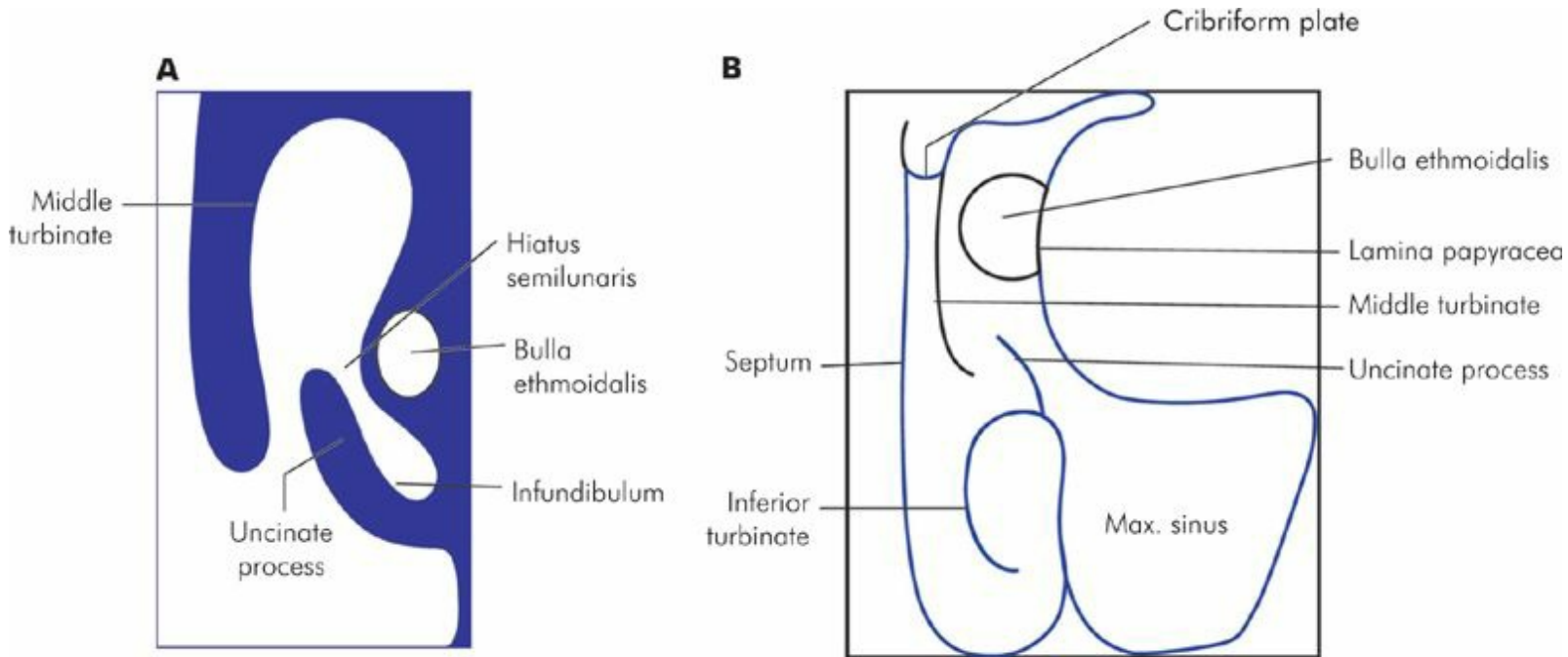
Natural ostium of the maxillary sinus is situated in the lower part of infundibulum. Accessory ostium or ostia of maxillary sinus are sometimes seen in the anterior or posterior fontanel (Fig. 23.7).

***Bulla ethmoidalis***



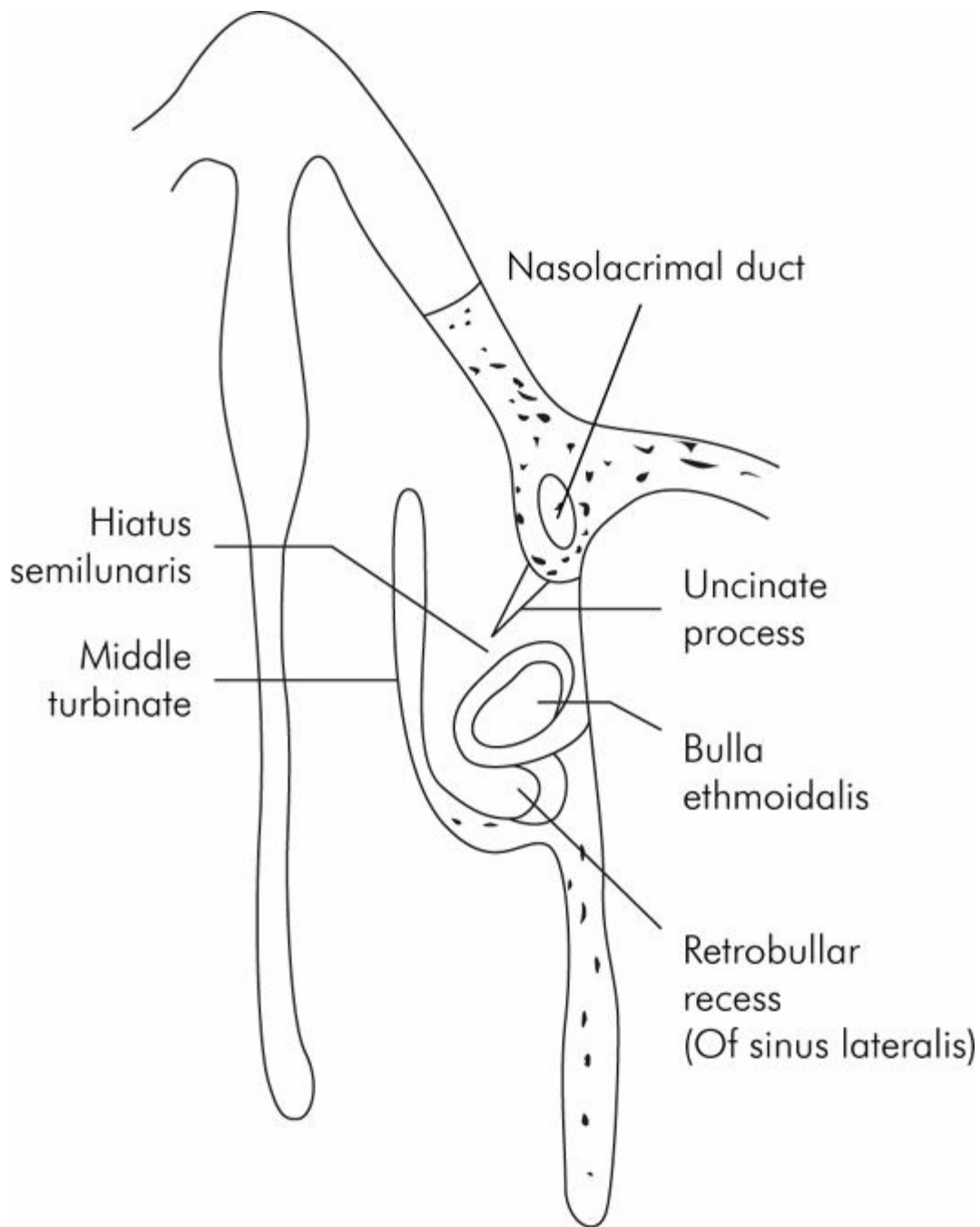
Dhingra: Diseases of Ear Nose and Throat, 5th Edition  
 Copyright © 2010 Elsevier. All rights reserved.

Figure 23.6 Upper attachment of uncinata process: (A) into lamina papyracea, (B) into skull base, (C) into middle turbinate thus affecting drainage of frontal sinus.



Dhingra: Diseases of Ear Nose and Throat, 5th Edition  
 Copyright © 2010 Elsevier. All rights reserved.

Figure 23.7 (A) Coronal section through middle meatus. Uncinate process forms the medial wall and floor of the infundibulum. (B) Coronal section showing relationships of uncinata process, bulla ethmoidalis, middle turbinate, maxillary sinus, orbit and cribriform plate.



Dhingra: Diseases of Ear Nose and Throat, 5th Edition  
Copyright © 2010 Elsevier. All rights reserved.

Figure 23.8 Axial view showing middle meatus and its structure. Note also the retrobullar recess.

It is an ethmoidal cell situated behind the uncinate process. Anterior surface of the bulla forms the posterior boundary of hiatus semilunaris. Depending on pneumatization bulla may be a pneumatized cell or a solid bony prominence. It may extend superiorly to the skull base and posteriorly to fuse with ground lamella. When there is a space about or behind the bulla, it is called suprabullar or retrobullar recesses, respectively (Fig. 23.8). The suprabullar and retrobullar recesses together form the *lateral sinus* (sinus lateralis of Grunwald). The lateral sinus is thus bounded superiorly by the skull base, laterally by lamina papyracea, medially by middle turbinate and inferiorly by the bulla ethmoidalis. Posteriorly the sinus lateralis may extend up to basal lamella of middle turbinate. The cleft-like communication between the bulla and skull base and opening into middle meatus is also called *hiatus semilunaris superior* in contrast to hiatus semilunaris inferior referred to before.

#### Atrium

of the middle meatus is a shallow depression lying in front of middle turbinate and above the nasal vestibule.

#### Agger nasi

is an elevation just anterior to the attachment of middle turbinate. When pneumatized it contains air cells, the agger nasi cells, which communicate with the frontal recess. An enlarged agger nasi cell may encroach on frontal recess area, constricting it and causing mechanical obstruction to frontal sinus drainage.

Pneumatization of middle turbinate leads to an enlarged ballooned out middle turbinate called *concha bullosa*. It drains into frontal recess directly or through agger nasi cells. *Haller cells* are air cells situated in the roof of maxillary sinus. They are pneumatized from anterior or posterior

ethmoid cells. Enlargement of Haller cells encroaches on ethmoid infundibulum, impeding draining of maxillary sinus.

### *Superior turbinate*

is also an ethmoturbinal and is situated posterior and superior to middle turbinate. It may also get pneumatized by one or more cells.

### *Superior meatus*

is a space below the superior turbinate. Posterior ethmoid cells open into it. Number of posterior ethmoid cells varies from 1 to 5. Onodi cell is a posterior ethmoidal cell which may grow posteriorly by the side of sphenoid sinus or superior to it for as much a distance as 1.5 cm from the anterior surface of sphenoid. Onodi cell is surgically important as the optic nerve may be related to its lateral wall.

### *Sphenoethmoidal recess*

is situated above the superior turbinate. Sphenoid sinus opens into it.

### *Supreme turbinate*

is sometimes present above the superior turbinate and has a narrow meatus beneath it.

The ostium of sphenoid sinus is situated in the sphenoethmoidal recess medial to the superior or supreme turbinate. It can be located endoscopically about 1 cm above the upper margin of posterior choana close to the posterior border of the septum.

### *Medial wall*

Nasal septum forms the medial wall and is described on page 162.

### **Roof**

Anterior sloping part of the roof is formed by nasal bones; posterior sloping part is formed by the body of sphenoid bone; and the middle horizontal part is formed by the cribriform plate of ethmoid through which the olfactory nerves enter the nasal cavity.

### **Floor**

It is formed by palatine process of the maxilla in its anterior three-fourths and horizontal part of the palatine bone in its posterior one-fourth.



# Lining Membrane of Internal Nose

## Vestibule

It is lined by skin containing hair, hair follicles and sebaceous glands.

## Olfactory region

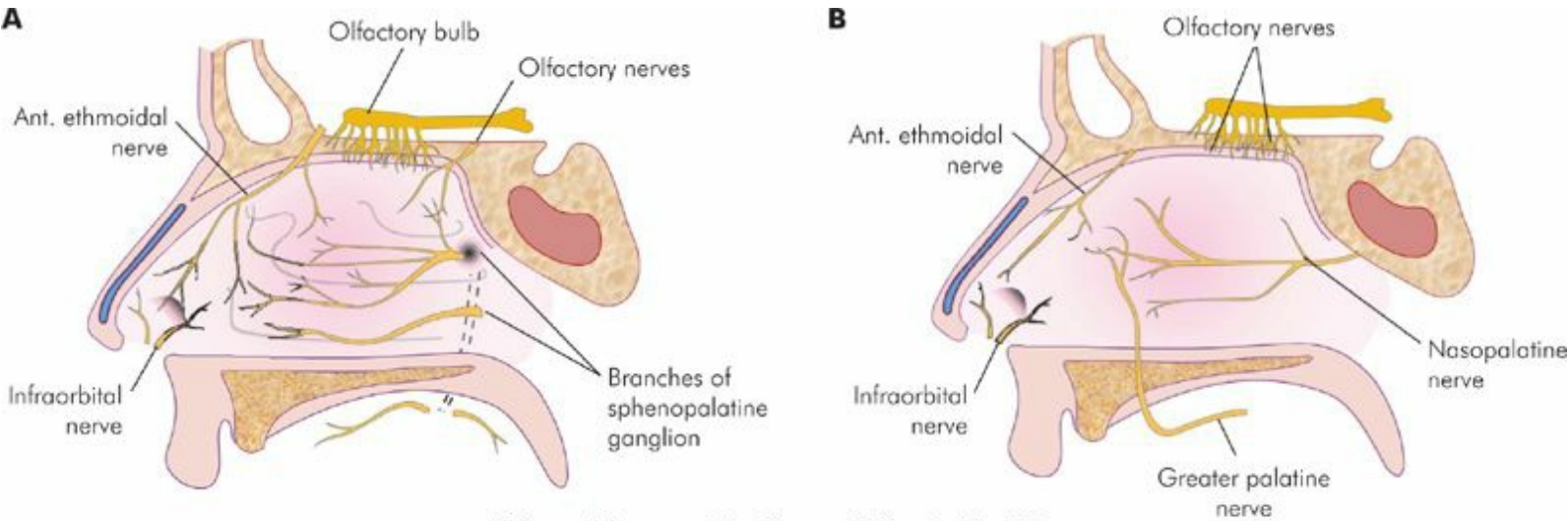
Upper one-third of lateral wall (up to superior concha), corresponding part of the nasal septum and the roof of nasal cavity form the olfactory region. Here, mucous membrane is paler in colour.

## Respiratory region

Lower two-thirds of the nasal cavity form the respiratory region. Here mucous membrane shows variable thickness being thickest over nasal conchae especially at their ends, quite thick over the nasal septum but very thin in the meatuses and floor of the nose. It is highly vascular and also contains erectile tissue. Its surface is lined by pseudostratified ciliated columnar epithelium which contains plenty of goblet cells. In the submucous layer of mucous membrane, are situated serous, mucous, both serous and mucous secreting glands, the ducts of which open on the surface of mucosa.

page 153

page 154



Dhingra: Diseases of Ear Nose and Throat, 5th Edition  
Copyright © 2010 Elsevier. All rights reserved.

Figure 23.9 Nerve supply of nose. (A) Lateral wall. Sphenopalatine ganglion situated at the posterior end of middle turbinate supplies most of posterior two-thirds of nose. (B) Nerves on the medial wall.

# Nerve Supply

## **(a) Olfactory nerves**

They carry sense of smell and supply olfactory region of nose. They are the central filaments of the olfactory cells and are arranged into 12-20 nerves which pass through the cribriform plate and end in the olfactory bulb. These nerves can carry sheaths of dura, arachnoid and pia with them into the nose. Injury to these nerves can open CSF space leading to CSF rhinorrhoea or meningitis (Fig. 23.9).

## **(b) Nerves of common sensation**

They are:

- **(i)** Anterior ethmoidal nerve.
- **(ii)** Branches of sphenopalatine ganglion.
- **(iii)** Branches of infra-orbital nerve. They supply vestibule of nose both on its medial and lateral side.

Most of the posterior two-thirds of nasal cavity (both septum and lateral wall) is supplied by branches of sphenopalatine ganglion which can be blocked by placing a pledget of cotton soaked in anaesthetic solution near the sphenopalatine foramen situated at the posterior extremity of middle turbinate. Anterior ethmoidal nerve which supplies anterior and superior part of the nasal cavity (lateral wall and septum) can be blocked by placing the pledget high up on the inside of nasal bones where the nerve enters.

## **(c) Autonomic nerves**

Parasympathetic nerve fibres supply the nasal glands and control nasal secretion. They come from greater superficial petrosal nerve, travel in the nerve of pterygoid canal (*vidian nerve*) and reach the sphenopalatine ganglion where they relay before reaching the nasal cavity. They also supply the blood vessels of nose and cause vasodilation.

Sympathetic nerve fibres come from upper two thoracic segments of spinal cord, pass through superior cervical ganglion, travel in deep petrosal nerve and join the parasympathetic fibres of greater petrosal nerve to form the nerve of pterygoid canal (*vidian nerve*). They reach the nasal cavity without relay in the sphenopalatine ganglion. Their stimulation causes vasoconstriction. Excessive rhinorrhoea in cases of vasomotor and allergic rhinitis can be controlled by section of the vidian nerve.

## Blood Supply

Both the internal and external carotid systems supply the nose. Details of blood supply are given on page 189.

## Lymphatic Drainage

Lymphatics from the external nose and anterior part of nasal cavity drain into submandibular lymph nodes while those from the rest of nasal cavity drain into upper jugular nodes either directly or through the retropharyngeal nodes. Lymphatics of the upper part of nasal cavity communicate with subarachnoid space along the olfactory nerves.

## 24 Physiology of Nose

**Functions** of the nose are classified as:

- 1. Respiration.
- 2. Air conditioning of inspired air.
- 3. Protection of lower airway.
- 4. Vocal resonance.
- 5. Nasal reflex functions.
- 6. Olfaction.

# Respiration

Nose is the natural pathway for breathing. Mouth breathing is an acquired act through learning. So natural is the instinct to breath through the nose that a newborn infant with choanal atresia may asphyxiate to death if urgent measures are not taken to relieve it. The nose also permits breathing and eating to go on simultaneously.

## ***During quiet respiration***

inspiratory air current passes through middle part of nose between the turbinates and nasal septum. Very little air passes through inferior meatus or olfactory region of nose (Fig. 24.1). Therefore, weak odorous substances have to be sniffed before they can reach the olfactory area.

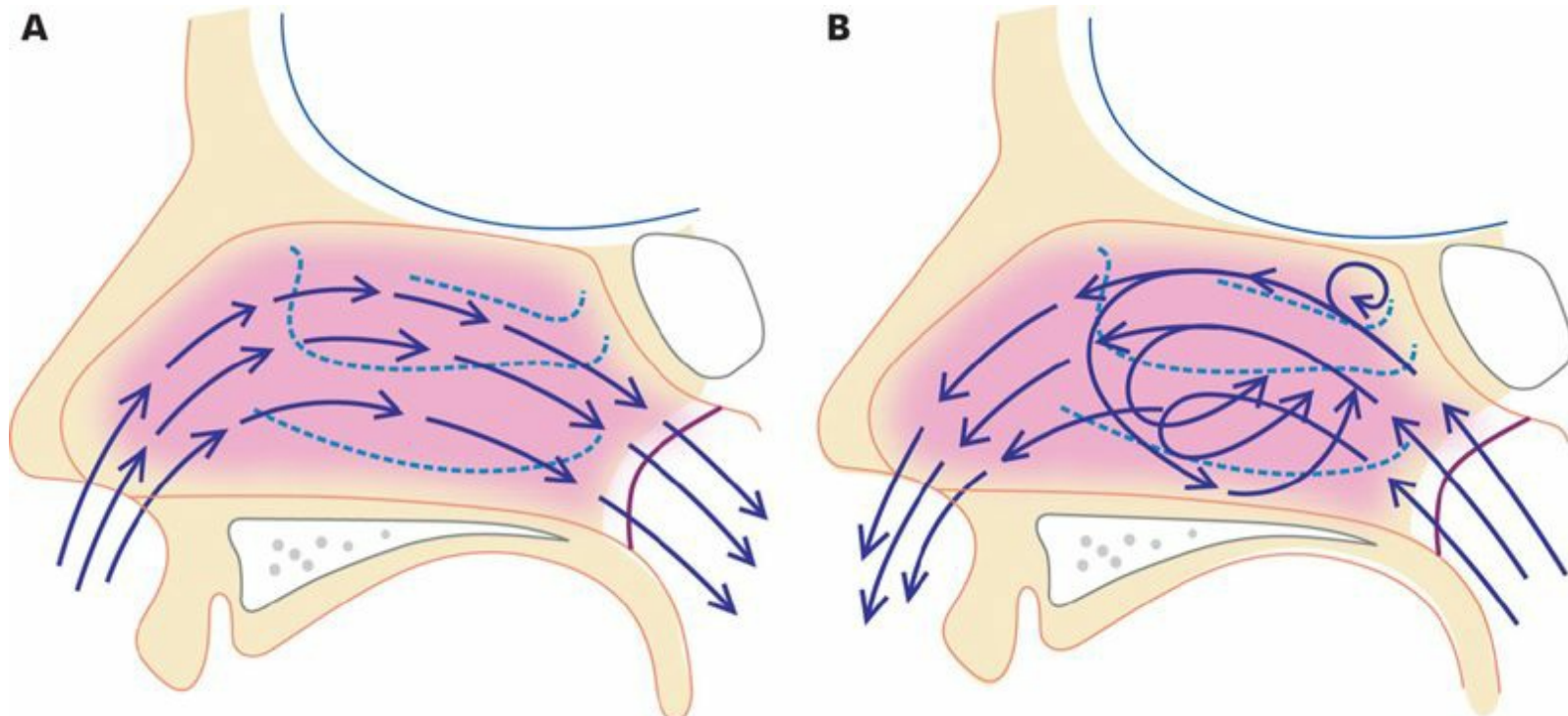
## ***During expiration***

air current follows the same course as during inspiration, but the entire air current is not expelled directly through the nares. Friction offered at limen nasi converts it into eddies under cover of inferior and middle turbinates and this ventilates the sinuses through the ostia.

Anterior end of inferior turbinate undergoes swelling and shrinkage thus regulating inflow of air.

## ***Nasal cycle***

Nasal mucosa undergoes rhythmic cyclical congestion and decongestion, thus controlling the air flow through nasal chambers. When one nasal chamber is working, total nasal respiration, equal to that of both nasal chambers, is carried out by it. Nasal cycle varies every 2½-4 hours and may be characteristic of an individual.



Dhingra: Diseases of Ear Nose and Throat, 5th Edition  
Copyright © 2010 Elsevier. All rights reserved.

Figure 24.1 Physiology of nasal airflow: (A) Inspiration. (B) Expiration.

## Air-conditioning of Inspired Air

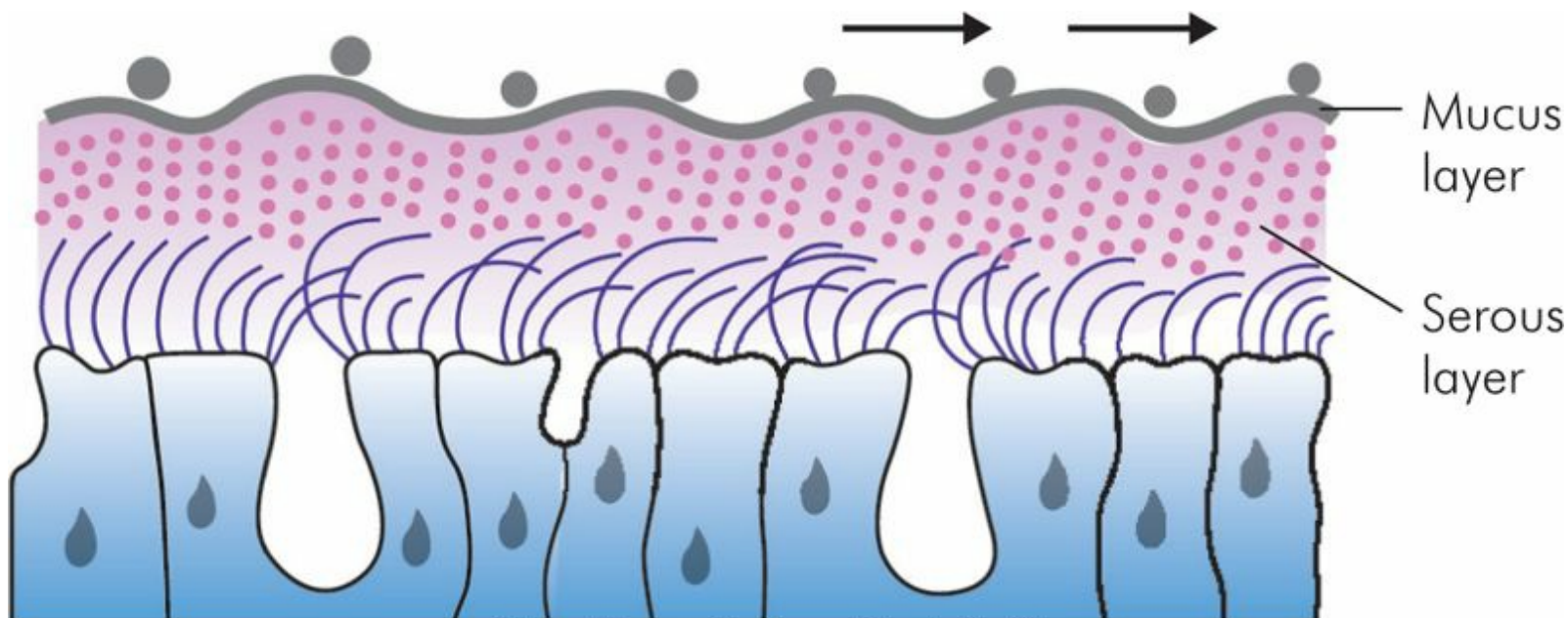
Nose is aptly called the "air-conditioner" for lungs. It filters and purifies the inspired air and adjusts its temperature and humidity before the air passes to the lungs.

- **(a) Filtration and purification.** Nasal vibrissae at the entrance of nose act as filters to sift larger particles like fluffs of cotton. Finer particles like dust, pollen and bacteria adhere to the mucus which is spread like a sheet all over the surface of the mucous membrane. The front of the nose can filter particles up to  $3\ \mu\text{m}$ , while nasal mucus traps particles as fine as  $0.5\text{-}3.0\ \mu\text{m}$ . Particles smaller than  $0.5\ \mu\text{m}$  seem to pass through the nose into lower airways without difficulty.
- **(b) Temperature control** of the inspired air is regulated by large surface of nasal mucosa which is structurally adapted to perform this function. This mucous membrane, particularly in the region of middle and inferior turbinates and adjacent parts of the septum is highly vascular with cavernous venous spaces or sinusoids which control the blood flow, and this increases or decreases the size of turbinates. This also makes an efficient "radiator" mechanism to warm up the cold air. Inspired air which may be at  $20^\circ\text{C}$  or  $0^\circ\text{C}$  or even at subzero temperature is heated to near body temperature ( $37^\circ\text{C}$ ) in one-fourth of second that the air takes to pass from the nostril to the nasopharynx. Similarly, hot air is cooled to the level of body temperature.
- **(c) Humidification.** This function goes on simultaneously with the temperature control of inspired air. Relative humidity of atmospheric air varies depending on climatic conditions. Air is dry in winter and saturated with moisture in summer months. Nasal mucous membrane adjusts the relative humidity of the inspired air to 75% or more. Water, to saturate the inspired air, is provided by the nasal mucous membrane which is rich in mucous and serous secreting glands. About 1000 ml of water is evaporated from the surface of nasal mucosa in 24 hours.

Moisture is essential for integrity and function of the ciliary epithelium. At 50% relative humidity, ciliary function stops in 8-10 minutes. Thus, dry air predisposes to infections of the respiratory tract. Humidification also has a significant effect on gas exchange in the lower airways. In nasal obstruction, gaseous exchange is affected in the lungs, leading to rise in  $\text{pCO}_2$ , causing apnoeic spells during sleep; it also decreases  $\text{pO}_2$ .

## Protection of Lower Airway

- **(a) Mucociliary mechanism.** Nasal mucosa is rich in goblet cells, secretory glands both mucous and serous. Their secretion forms a continuous sheet called *mucous blanket* spread over the normal mucosa. Mucous blanket consists of a superficial mucus layer and a deeper serous layer, floating on the top of cilia which are constantly beating to carry it like a "conveyer belt" towards the nasopharynx (Fig. 24.2). It moves at a speed of 5-10 mm per minute and the complete sheet of mucus is cleared into the pharynx every 10 to 20 minutes. The inspired bacteria, viruses and dust particles are entrapped on the viscous mucous blanket and then carried to the nasopharynx to be swallowed. Presence of turbinates almost doubles the surface area to perform this function. About 600-700 ml of nasal secretions are produced in 24 hours.  
In mammals, cilia beat 10-20 times per second at room temperature. They have a rapid "effective stroke" and a slow "recovery stroke". In the former, the extended cilia reach mucus layer while in the recovery stroke, they bend and travel slowly in the reverse direction in the thin serous layer, thus moving the mucous blanket in only one direction. In immotile cilia syndrome, cilia are defective and cannot beat effectively, leading to stagnation of mucus in the nose and sinuses and bronchi causing chronic rhinosinusitis and bronchiectasis. Movements of cilia are affected by drying, drugs (adrenaline), excessive heat or cold, smoking, infections and noxious fumes like sulphur dioxide and carbon dioxide.
- **(b) Enzymes and immunoglobulins.** Nasal secretions also contain an enzyme called muramidase (lysozyme) which kills bacteria and viruses. Immunoglobulins IgA and IgE, and interferon are also present in nasal secretions and provide immunity against upper respiratory tract infections.
- **(c) Sneezing.** It is a protective reflex. Foreign particles which irritate nasal mucosa are expelled by sneezing. Copious flow of nasal secretions that follows irritation by noxious substance helps to wash them out.



Dhingra: Diseases of Ear Nose and Throat, 5th Edition  
Copyright © 2010 Elsevier. All rights reserved.

Figure 24.2 "Conveyer belt" mechanism of mucus blanket to entrap and carry organisms and dust particles.

The pH of nasal secretion is nearly constant at 7. The cilia and the lysozyme act best at this pH. Alteration in nasal pH, due to infections or nasal drops, seriously impair the functions of cilia and lysozyme.

So efficient are the functions of nose that 500 cubic feet of air, that we breathe every 24 hours, is filtered, humidified, adjusted to proper temperature and cleared of all the dust, bacteria and viruses before reaching the lungs.



## Vocal Resonance

Nose forms a resonating chamber for certain consonants in speech. In phonating nasal consonants (M/N/NG), sound passes through the nasopharyngeal isthmus and is emitted through the nose. When nose (or nasopharynx) is blocked, speech becomes denasal, i.e. M/N/NG are uttered as B/D/G respectively. It is to be remembered that in Hindi alphabets, last letter of a "varga" (

कवर्ग : क, ख, ग, घ, ङ; तवर्ग : त, थ, द, ध, न; पवर्ग : प, फ, ब, भ, म) is substituted by its third letter. Thus, an affected person utters

दादा for

नाना and

बाबा for

मामा. Reverse is true in velopharyngeal insufficiency where

नाना is substituted for

दादा.

## Nasal Reflexes

Several reflexes are initiated in the nasal mucosa. Smell of a palatable food cause reflex secretion of saliva and gastric juice. Irritation of nasal mucosa causes sneezing. Nasal function is closely related to pulmonary functions through nasobronchial and nasopulmonary reflexes. It has been observed that nasal obstruction leads to increased pulmonary resistance and is reversed when nasal obstruction is surgically treated. Nasal packing in cases of epistaxis or after nasal surgery leads to lowering of  $pO_2$  which returns to normal after removal of the pack. Pulmonary hypertension or cor pulmonale can develop in children with longstanding nasal obstruction due to tonsil and adenoid hypertrophy and can be reversed after removal of the tonsils and adenoids.

# Olfaction

Sense of smell is well developed in lower animals to give warning of the environmental dangers but it is comparatively less important in man. Still it is important for pleasure and for enjoying the taste of food. When nose is blocked, food tastes bland and unpalatable. Vapours of ammonia are never used to test the sense of smell as they stimulate fibres of the trigeminal nerve and cause irritation in the nose rather than stimulate the olfactory receptors.

## **Olfactory pathways**

Smell is perceived in the olfactory region of nose which is situated high up in the nasal cavity. This area contains millions of olfactory, receptor cells. Peripheral process of each olfactory cell reaches the mucosal surface and is expanded into a ventricle with several cilia on it. This acts as a sensory receptor to receive odorous substances. Central processes of the olfactory cells are grouped into olfactory nerves which pass through the cribriform plate of ethmoid and end in the mitral cells of the olfactory bulb. Axons of mitral cells form olfactory tract and carry smell to the prepiriform cortex and the amygdaloid nucleus where it reaches consciousness. Olfactory system is also associated with autonomic system at the hypothalamic level.

## **Disorders of smell**

It is essential for the perception of smell that the odorous substance be volatile and that it should reach the olfactory area unimpeded. Also necessary are the healthy state of olfactory mucosa and the integrity of neural pathways, i.e. olfactory nerves, olfactory bulb and tract and the cortical centre of olfaction.

*Anosmia* is total loss of sense of smell while *hyposmia* is partial loss. They can result from nasal obstruction due to nasal polypi, enlarged turbinates or oedema of mucous membrane as in common cold, allergic or vasomotor rhinitis. Anosmia is also seen in atrophic rhinitis, a degenerative disorder of nasal mucosa; peripheral neuritis (toxic or influenzal); injury to olfactory nerves or olfactory bulb in fractures of anterior cranial fossa; and intracranial lesions like abscess, tumour or meningitis which cause pressure on olfactory tracts.

*Parosmia* is perversion of smell; the person interprets the odours incorrectly. Often these persons complain of disgusting odours. It is seen in the recovery phase of postinfluenzal anosmia and the probable explanation is misdirected regeneration of nerve fibres. Intracranial tumour should be excluded in all cases of parosmia.

Sense of smell can be tested by asking the patient to smell common odours such as lemon, peppermint, rose, garlic or cloves from each side of the nose separately, with eyes closed. Quantitative estimation (quantitative olfactometry) requires special equipment.

## **25 Diseases of External Nose and Nasal Vestibule**

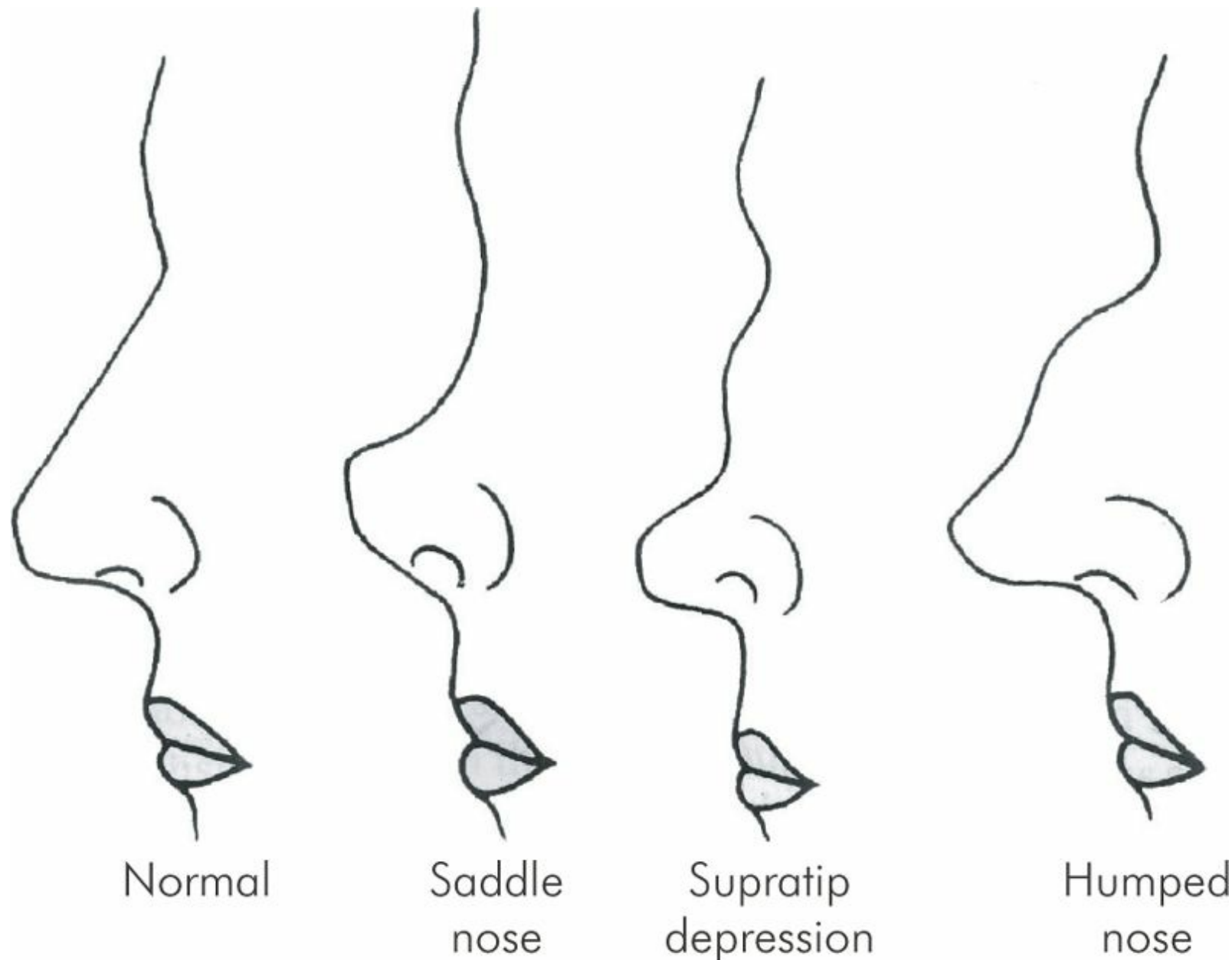
### **DISEASES OF EXTERNAL NOSE**

#### **Cellulitis**

The nasal skin may be invaded by streptococci or staphylococci leading to a red, swollen and tender nose. Sometimes, it is an extension of infection from the nasal vestibule. Treatment is systemic antibacterials, hot fomentation and analgesics.

# Nasal Deformities

## Saddle Nose



Dhingra: Diseases of Ear Nose and Throat, 5th Edition  
Copyright © 2010 Elsevier. All rights reserved.

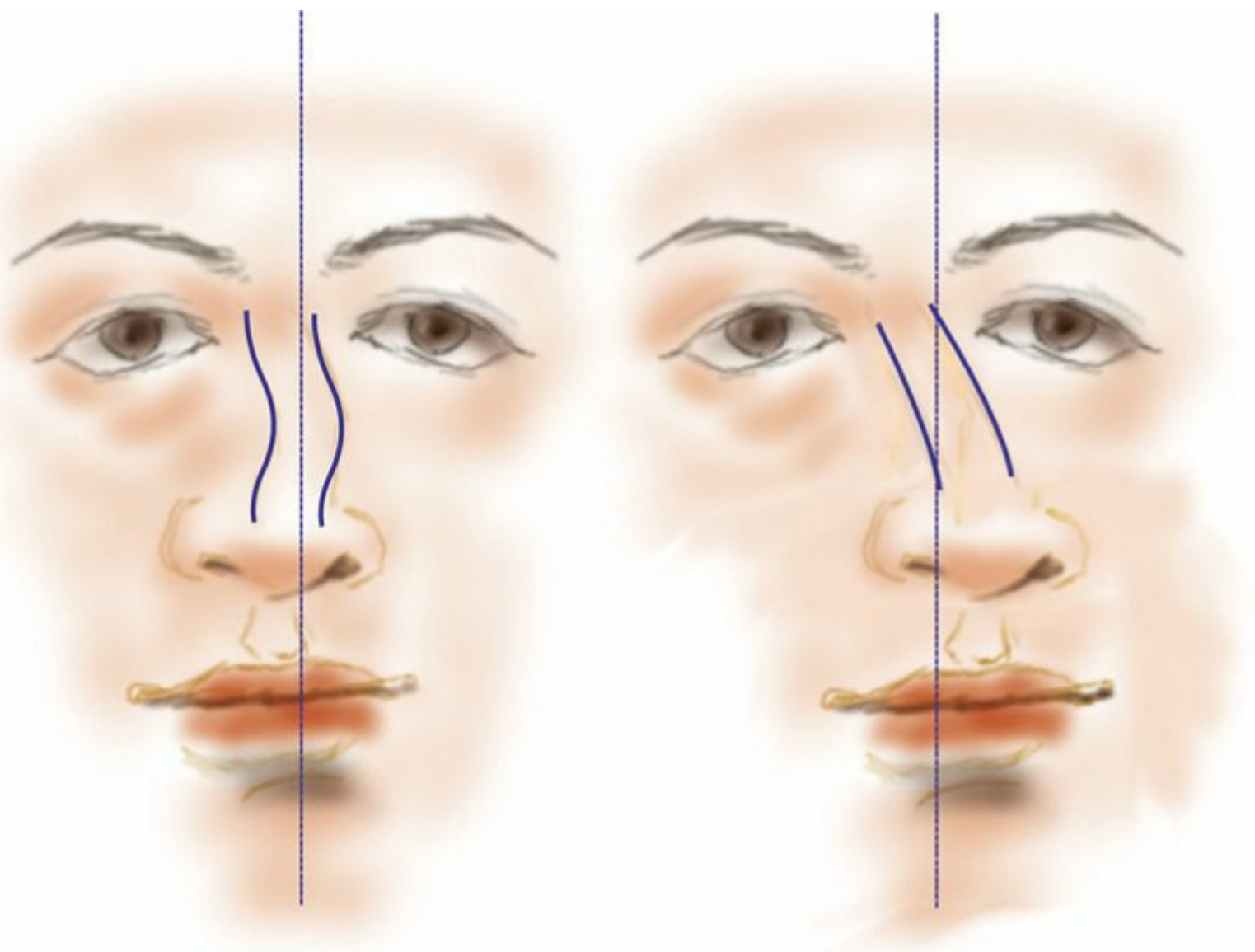
Figure 25.1 Deformities of nose.

Depressed nasal dorsum may involve bony, cartilaginous or both bony and cartilaginous components of nasal dorsum (Fig. 25.1). Nasal trauma causing depressed fractures is the most common aetiology. It can also result from excessive removal of septum in submucous resection, destruction of septal cartilage by haematoma or abscess, sometimes by leprosy, tuberculosis or syphilis. The deformity can be corrected by augmentation rhinoplasty by filling the dorsum with cartilage, bone or a synthetic implant. If depression is only cartilaginous, cartilage is taken from the nasal septum or auricle and laid in a single or multiple layers. If deformity involves both cartilage and bone, cancellous bone from the iliac crest is the best. Autografts (taken from the same individual) are preferred to allografts (taken from other individuals or cadavers). Saddle deformity can also be corrected by synthetic implants of silicone or teflon but they are likely to be extruded.

## Hump Nose

This may also involve the bone or cartilage or both bone and cartilage. It can be corrected by reduction rhinoplasty which consists of exposure of nasal framework by careful raising of the nasal skin by a vestibular incision, removal of hump and narrowing of the lateral walls by osteotomies to reduce the widening left by hump removal.

## Crooked or a Deviated Nose



## Crooked nose

## Deviated nose

Dhingra: Diseases of Ear Nose and Throat, 5th Edition  
Copyright © 2010 Elsevier. All rights reserved.

Figure 25.2 Nasal bridge is S-shaped in crooked nose. It is straight but deviated to one side in deviated nose.

In crooked nose, the midline of dorsum from frontonasal angle to the tip, is curved in a C or S shaped manner. In a deviated nose, the midline is straight but deviated to one side (Fig. 25.2).

Usually, these deformities are traumatic in origin. Injuries sustained during birth, neonatal period or childhood, but not immediately recognised, will also develop into these deformities with the growth of nose. The deviated or crooked nose can be corrected by rhinoplasty or septorhinoplasty. Aim of these operations is to correct not only the outer appearance of nose but also its function.

# Tumours

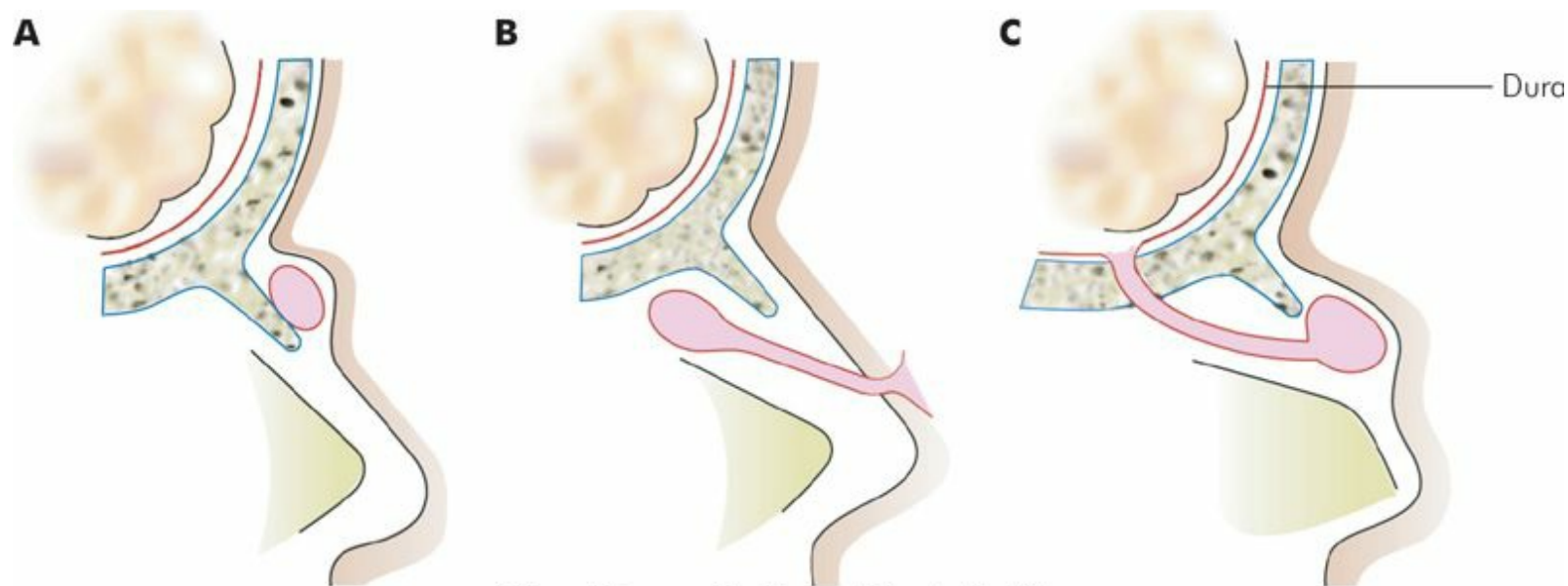
They may be congenital, benign or malignant.

## 1. Congenital Tumours

### ***Dermoid cyst (Fig. 25.3)***

It is of two types:

- (a) *Simple dermoid*. It occurs as a midline swelling under the skin but in front of the nasal bones. It does not have any external opening.
- (b) *That associated with a sinus*. It is seen in infants and children and is represented by a pit or a sinus in the midline of the dorsum of nose. Hair may be seen protruding through the sinus opening. In these cases, the sinus tract may lead to a dermoid cyst under the nasal bone in front of upper part of nasal septum or may have an intracranial dural connection. In those with intracranial extension, sinus tract passes through the cribriform plate or foramen caecum and is attached to dura or has other intracranial connection. Meningitis occurs if infection travels along this path. Treatment of such cysts may necessitate splitting of the nasal bones to remove any extension in the upper part of the nasal septum. A combined neurosurgical otolaryngologic approach is required in those extending intracranially so as to close simultaneously any bony defect through which the fistulous tract passes (Fig. 25.4).



Dhingra: Diseases of Ear Nose and Throat, 5th Edition  
Copyright © 2010 Elsevier. All rights reserved.

Figure 25.3 Types of dermoids. (A) Simple dermoid beneath the skin. (B) Dermoid with an external pit or sinus but in front of septum. Its tract extends under the nasal bones but in front of septum. (C) Dermoid with an intracranial connection to dura.

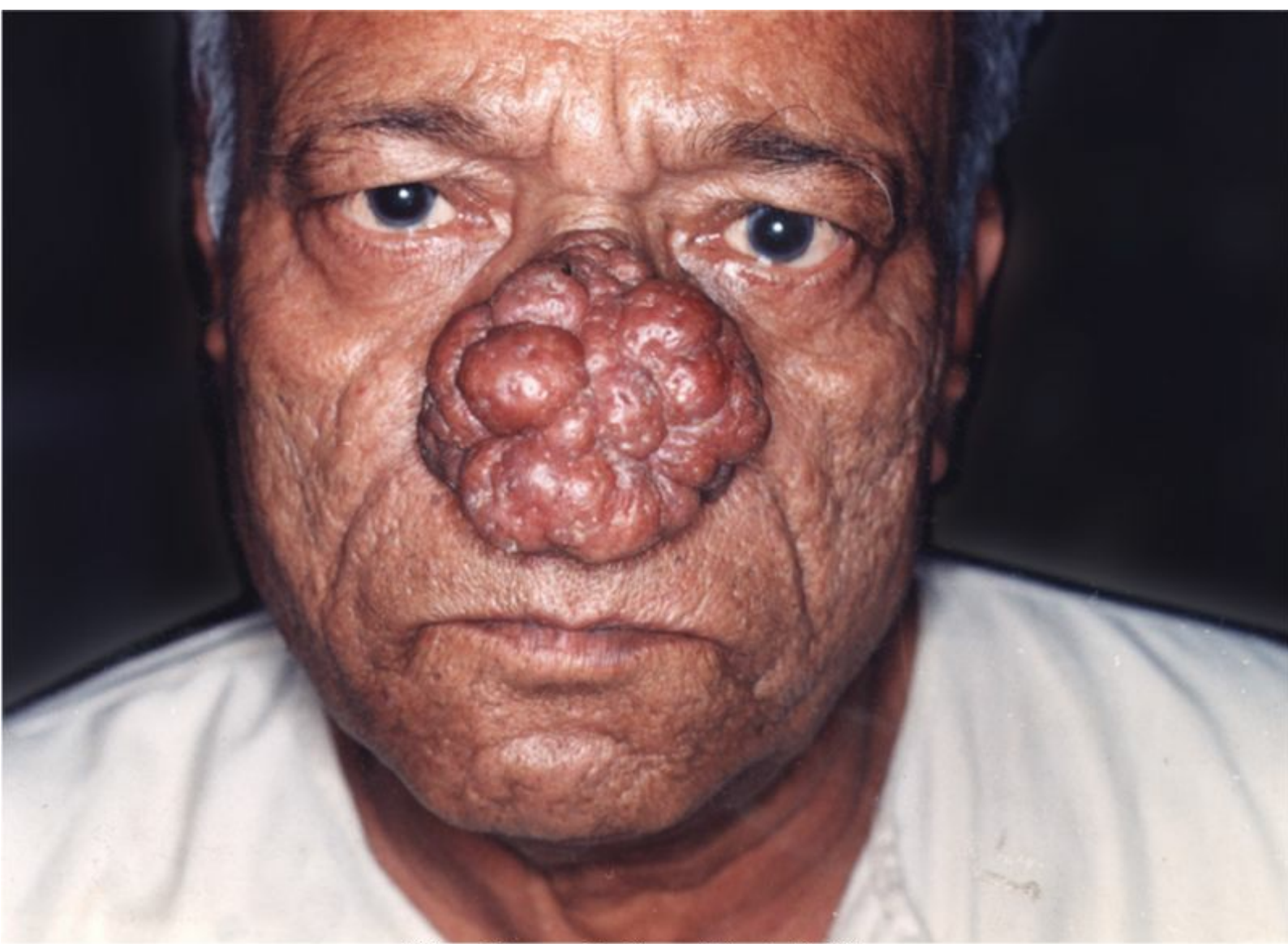### ***Encephalocele or meningoencephalocele***

It is a herniation of brain tissue with meninges through a congenital bony defect. An extranasal meningoencephalocele presents as a subcutaneous pulsatile swelling in the midline at the root of nose (*nasofrontal variety*), side of nose (*nasoethmoid variety*) or on the anteromedial aspect of the orbit (*naso-orbital variety*).

Swellings show cough impulse and may be reducible. Treatment is neurosurgical; severing the tumour stalk from the brain and repairing the bony defect through which herniation has taken place.

### ***Glioma***

It is a nipped off portion of encephalocele during embryonic development. Most of them (60%) are extranasal and present as firm subcutaneous swellings on the bridge, side of nose or near the inner canthus. Some of them are purely intranasal (30%) while 10% are both intra and extranasal. Extranasal gliomas are encapsulated and can be easily removed by external nasal approach.



Dhingra: Diseases of Ear Nose and Throat, 5th Edition  
Copyright © 2010 Elsevier. All rights reserved.

Figure 25.4 Rhinophyma.

page 159

page 160

## 2. Benign Tumours

They arise from the nasal skin and include *papilloma* (skin wart), *haemangioma*, *pigmented naevus*, *seborrhoeic keratosis*, *neurofibroma* or *tumour of sweat glands*.

**Rhinophyma** or potato tumour is a slow-growing benign tumour due to hypertrophy of the sebaceous glands of the tip of nose often seen in cases of long-standing acne rosacea. It presents as a pink, lobulated mass over the nose with superficial vascular dilation; mostly affects men past middle age (Fig. 25.4). Patient seeks advice because of the unsightly appearance of the tumour, or obstruction in breathing and vision due to the large size of the tumour. Treatment consists of paring down the bulk of tumour with sharp knife or carbon dioxide laser and the area allowed to re-epithelialise. Sometimes, tumour is completely excised and the raw area skin-grafted.

## 3. Malignant Tumours

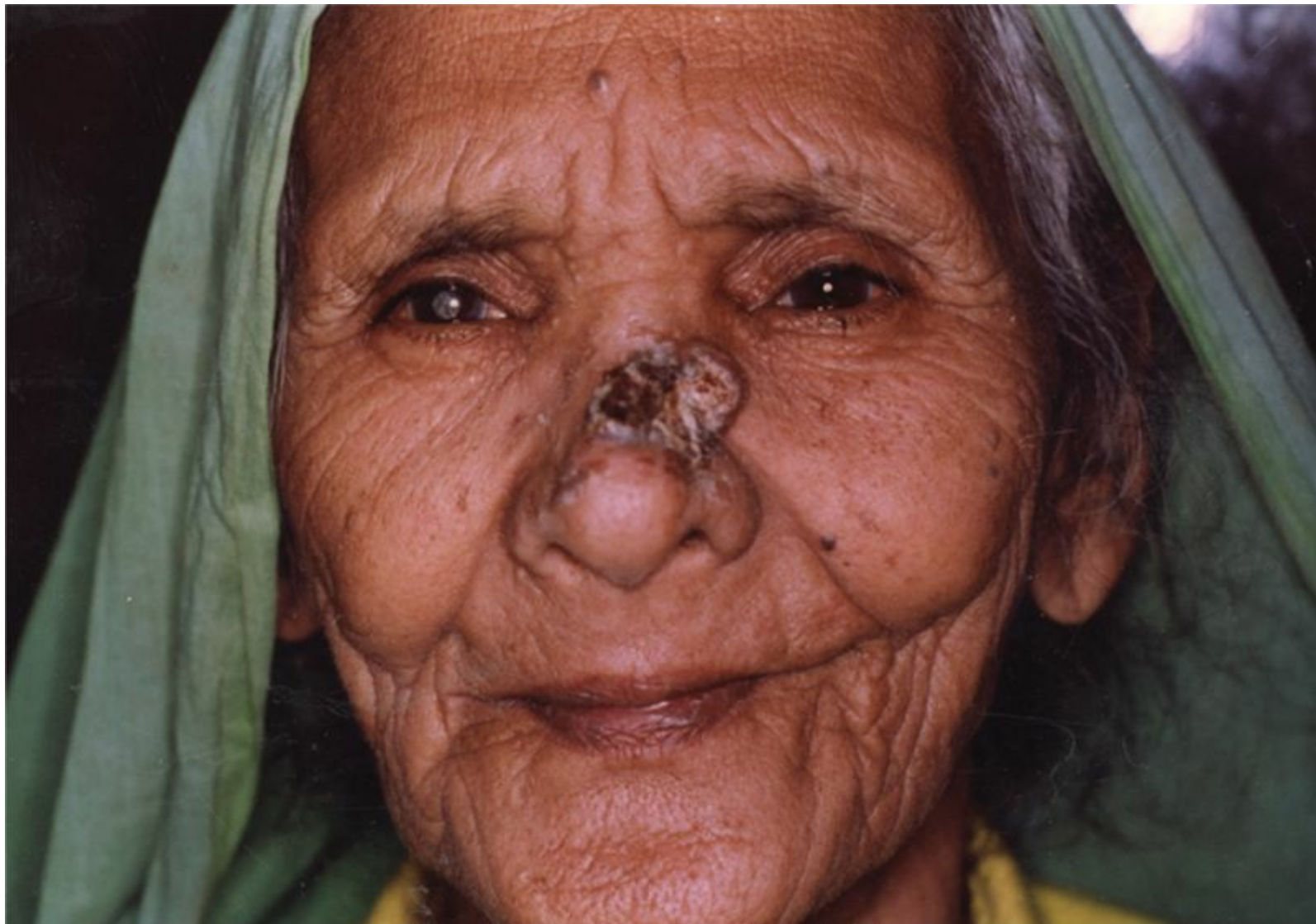### (a) *Basal cell carcinoma (rodent ulcer)* (Fig. 25.5)

This is the most common malignant tumour involving skin of nose (87%), equally affecting males and females in the age group of 40-60. Common sites on the nose are the tip and the ala. It may present as a *cyst* or *papulo-pearly nodule* or an *ulcer with rolled edges*. It is very slow-growing and remains confined to the skin for a long time. Underlying cartilage or bone may get invaded. Nodal metastases are extremely rare. Treatment depends on the size, location and depth of the tumour. Early lesion can be cured by cryosurgery, irradiation or surgical excision with 3-5 mm of skin around the palpable borders of the tumour.

Lesions which are recurrent, extensive or with involvement of cartilage or bone are excised and the surgical defect closed by local or distant flaps or a prosthesis.

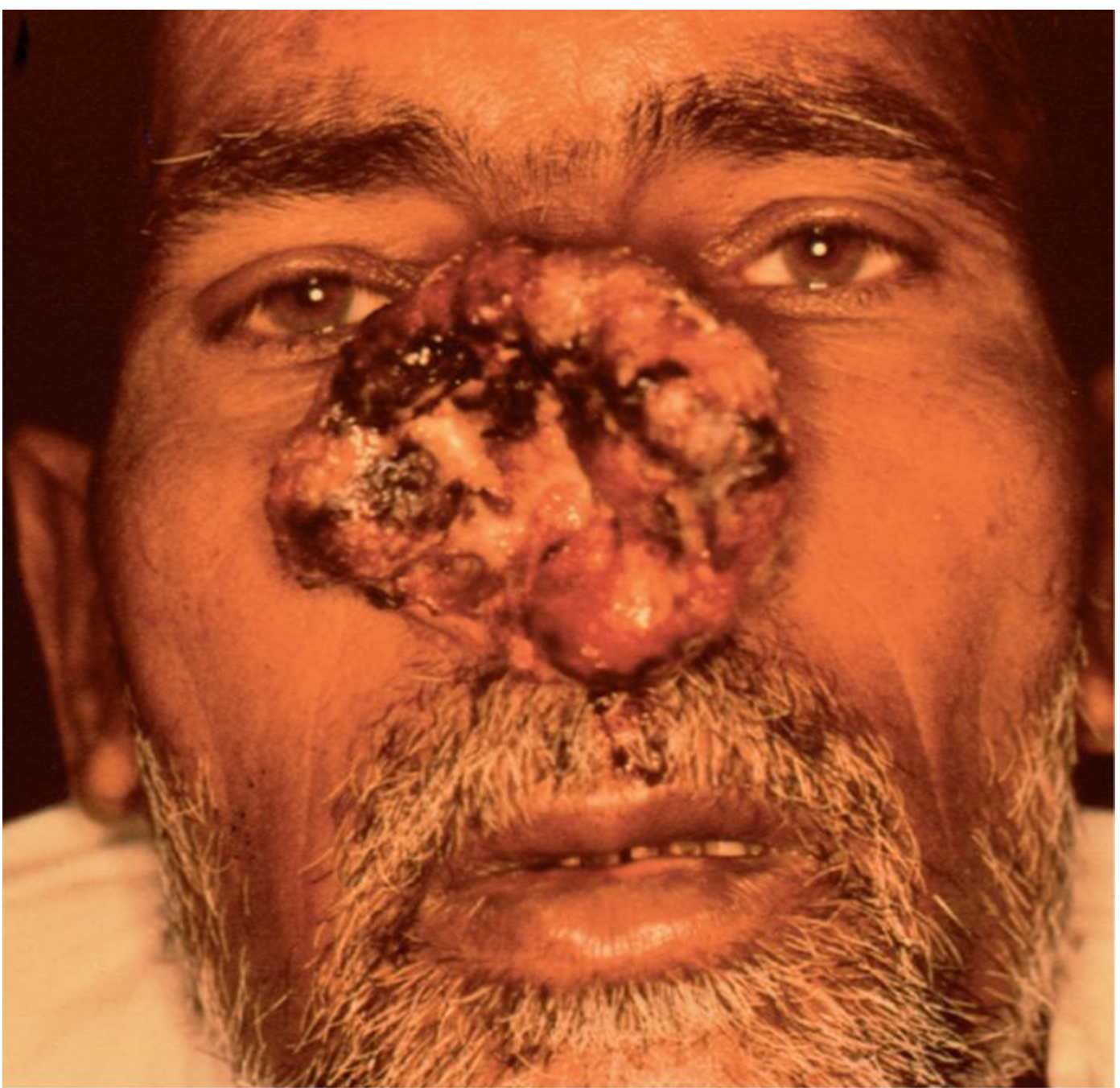

*(b) Squamous cell carcinoma (epithelioma)*



Dhingra: Diseases of Ear Nose and Throat, 5th Edition  
Copyright © 2010 Elsevier. All rights reserved.

Figure 25.5 Basal cell carcinoma of the nose.



Dhingra: Diseases of Ear Nose and Throat, 5th Edition  
Copyright © 2010 Elsevier. All rights reserved.

Figure 25.6 Carcinoma nose.

This is the second most common malignant tumour (11%), equally affecting both sexes in 40-60 age group. It occurs as an infiltrating nodule or an ulcer with rolled out edges affecting side of nose or columella (Fig. 25.6). Nodal metastases are seen in 20% of cases.

Early lesions respond to radiotherapy; more advanced lesions or those with exposure of bone or cartilage require wide surgical excision and plastic repair of the defect. Enlarged regional lymph nodes will require block dissection.

### **(c) Melanoma**

This is the least common variety. Clinically, it is superficially-spreading type (slow-growing) or nodular invasive type. Treatment is surgical excision.

## DISEASES OF NASAL VESTIBULE

### Furuncle or Boil (Fig. 25.7)

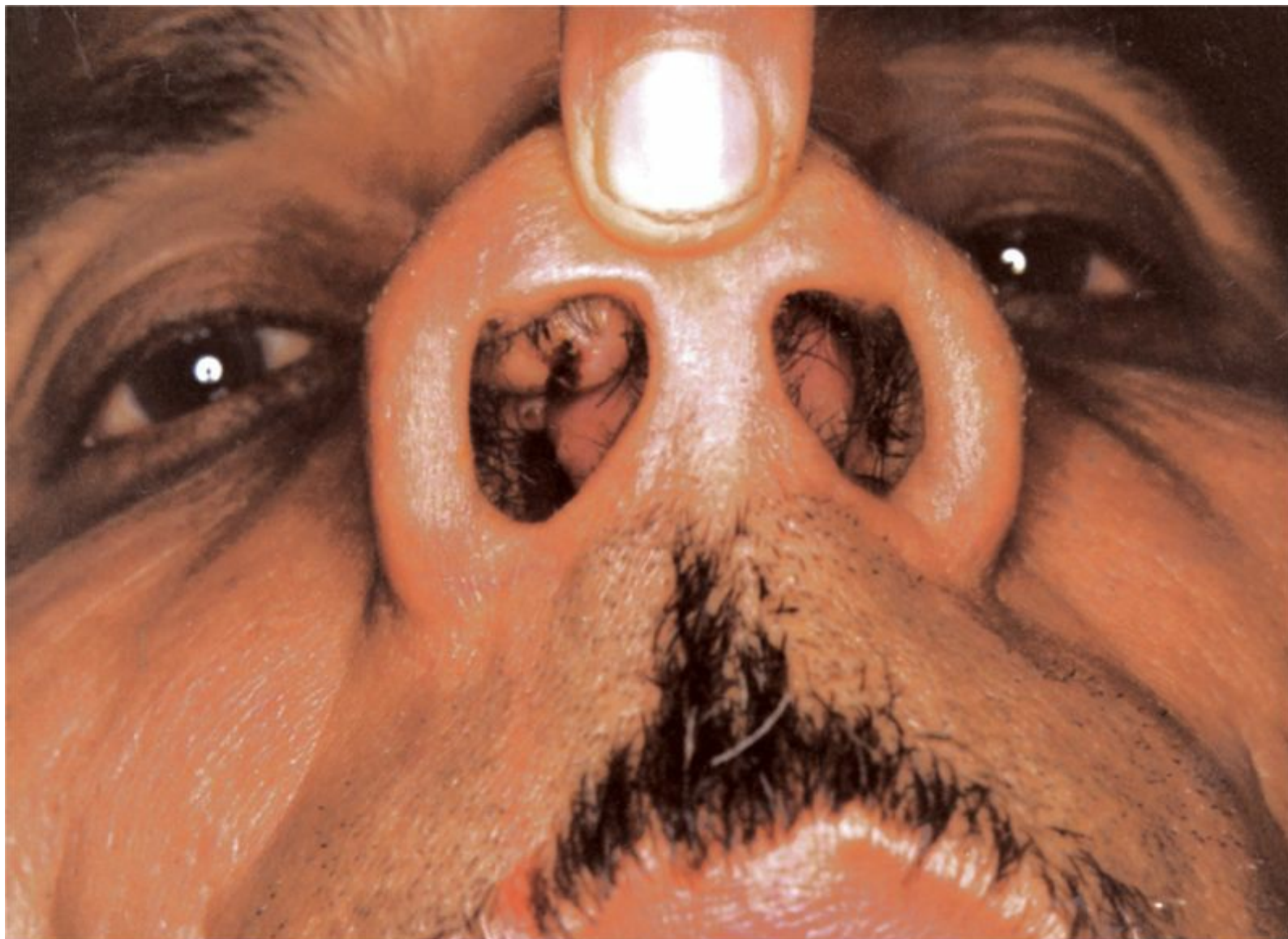It is an acute infection of the hair follicle by *Staphylococcus aureus*. Trauma from picking of the nose or plucking the nasal vibrissae, is the usual predisposing factor.

The lesion is small but exquisitely painful and tender. Inflammation may spread to the skin of nasal tip and dorsum which become red and swollen. The furuncle may rupture spontaneously in the nasal vestibule.

Treatment of furuncle consists of warm compresses, analgesics to relieve pain, and topical and systemic antibiotics directed against staphylococcus. If a fluctuant area appears, incision and drainage can be done. In no case should the furuncle be squeezed or prematurely incised because of the danger of spread of infection to cavernous sinus through venous thrombophlebitis.

page 160

page 161



Dhingra: Diseases of Ear Nose and Throat, 5th Edition  
Copyright © 2010 Elsevier. All rights reserved.

Figure 25.7 Furuncle right nasal vestibule.

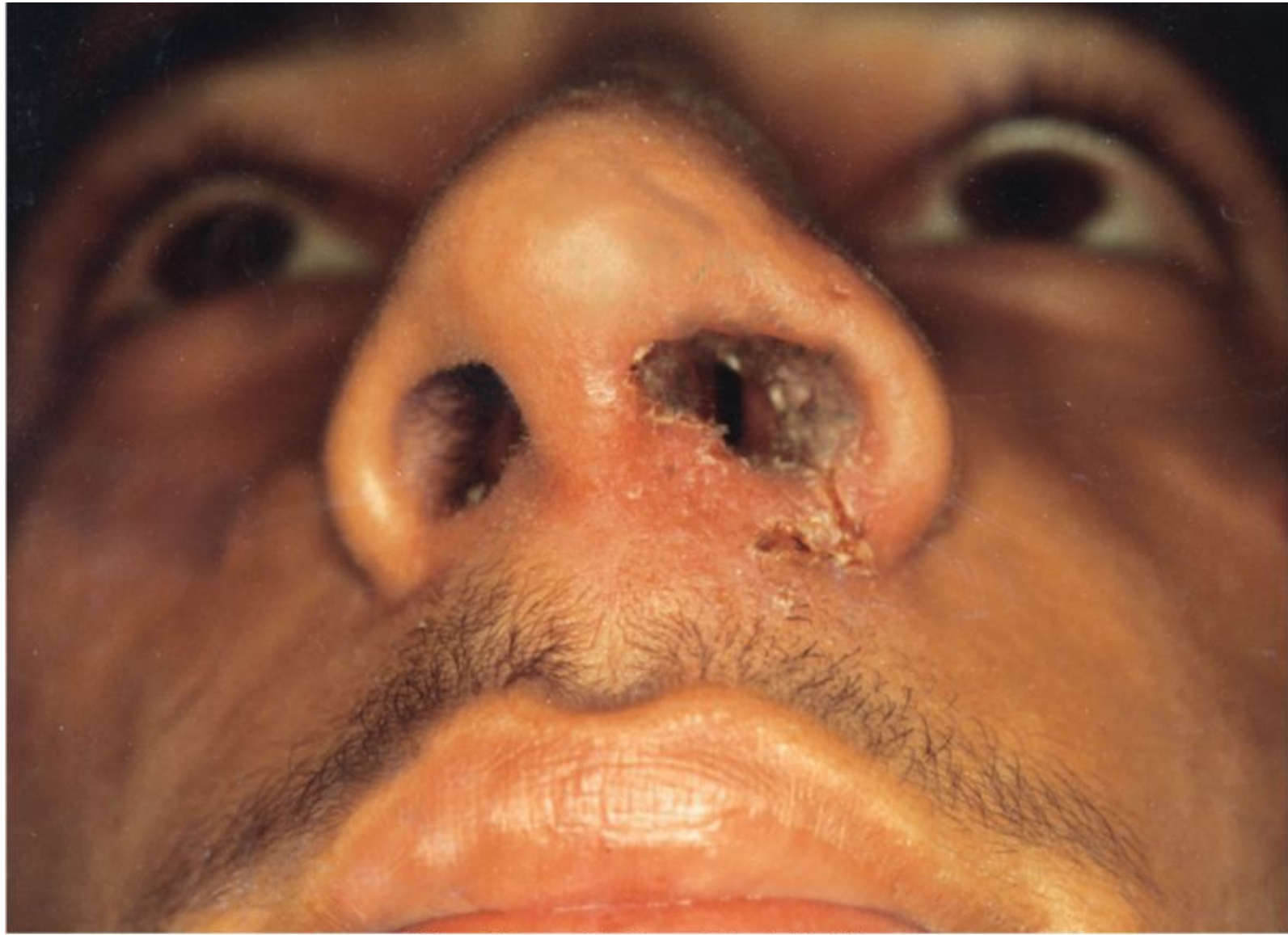A furuncle of nose may complicate into cellulitis of the upper lip or septal abscess.

## Vestibulitis

It is diffuse dermatitis of nasal vestibule. Nasal discharge, due to any cause such as rhinitis, sinusitis or nasal allergy, coupled with trauma of handkerchief, is the usual predisposing factor. The causative organism is *Staph. aureus*. Vestibulitis may be acute or chronic.

In *acute form*, vestibular skin is red, swollen and tender; crusts and scales cover an area of skin erosion or excoriation. The upper lip may also be involved (Fig. 25.8).

In *chronic form*, there is induration of vestibular skin with painful fissures and crusting.



Dhingra: Diseases of Ear Nose and Throat, 5th Edition  
Copyright © 2010 Elsevier. All rights reserved.

Figure 25.8 Acute vestibulitis (left side).

Treatment consists of cleaning the nasal vestibule of all crusts and scales with cotton applicator soaked in hydrogen peroxide and application of antibiotic-steroid ointment. The latter should always be continued for a few more days, even after the apparent cure, as the condition is likely to relapse. A chronic fissure can be cauterised with silver nitrate. Attention should be paid to the cause of nasal discharge.

## Stenosis and Atresia of the Nares

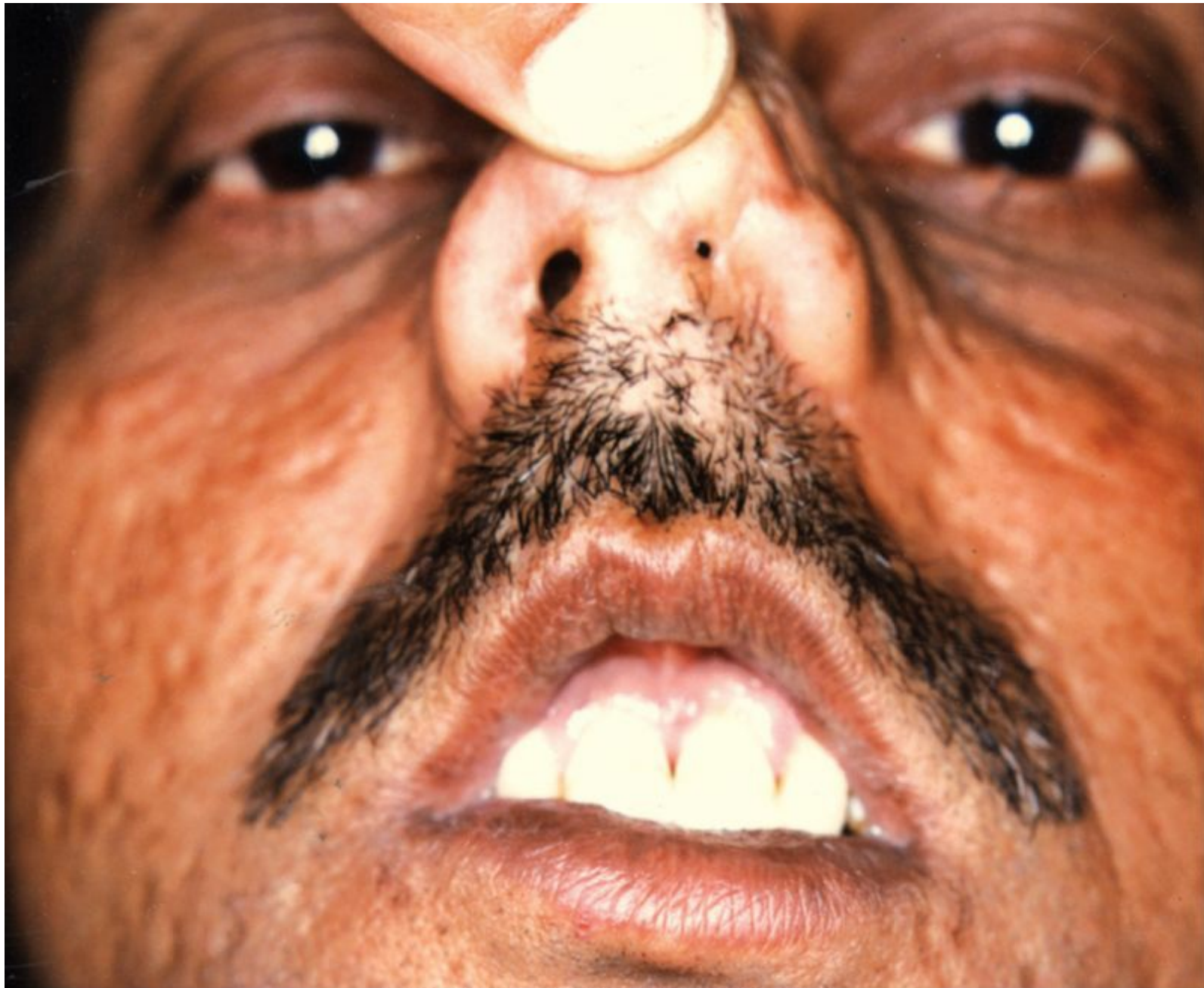Accidental or surgical trauma to the nasal tip or vestibule can lead to web formation and stenosis of anterior nares. In Young's operation, vestibular skin flaps are raised to create deliberate closure of nares in the treatment of atrophic rhinitis (see page 170). Destructive inflammatory lesions of nose also cause stenosis. Earlier, several cases of vestibular stenosis resulted from smallpox (Fig. 25.9).

*Congenital atresia* of anterior nares due to noncanalisation of epithelial plug is a rare condition.

Stenosis of nares can be corrected by reconstructive plastic procedures.

## Tumours

- 1. *Nasoalveolar cyst* presents a smooth bulge in the lateral wall and floor of nasal vestibule. The cyst can be excised by sublabial approach preserving the integrity of vestibular skin.
- 2. *Papilloma or wart* may be single or multiple, pedunculated or sessile. Treatment is surgical excision under local anaesthesia.
- 3. *Squamous cell carcinoma* arises from the lateral wall of the vestibule and may extend into nasal floor, columella and upper lip. It can metastasise to the parotid and submandibular nodes. Treatment is surgical excision or irradiation.



Dhingra: Diseases of Ear Nose and Throat, 5th Edition  
Copyright © 2010 Elsevier. All rights reserved.

Figure 25.9 Stenosis left naris following smallpox.

## 26 Nasal Septum and Its Diseases

### Anatomy

Nasal septum consists of three parts:

#### 1. Columellar septum

It is formed of columella containing the medial crura of alar cartilages united together by fibrous tissue and covered on either side by skin.

#### 2. Membranous septum

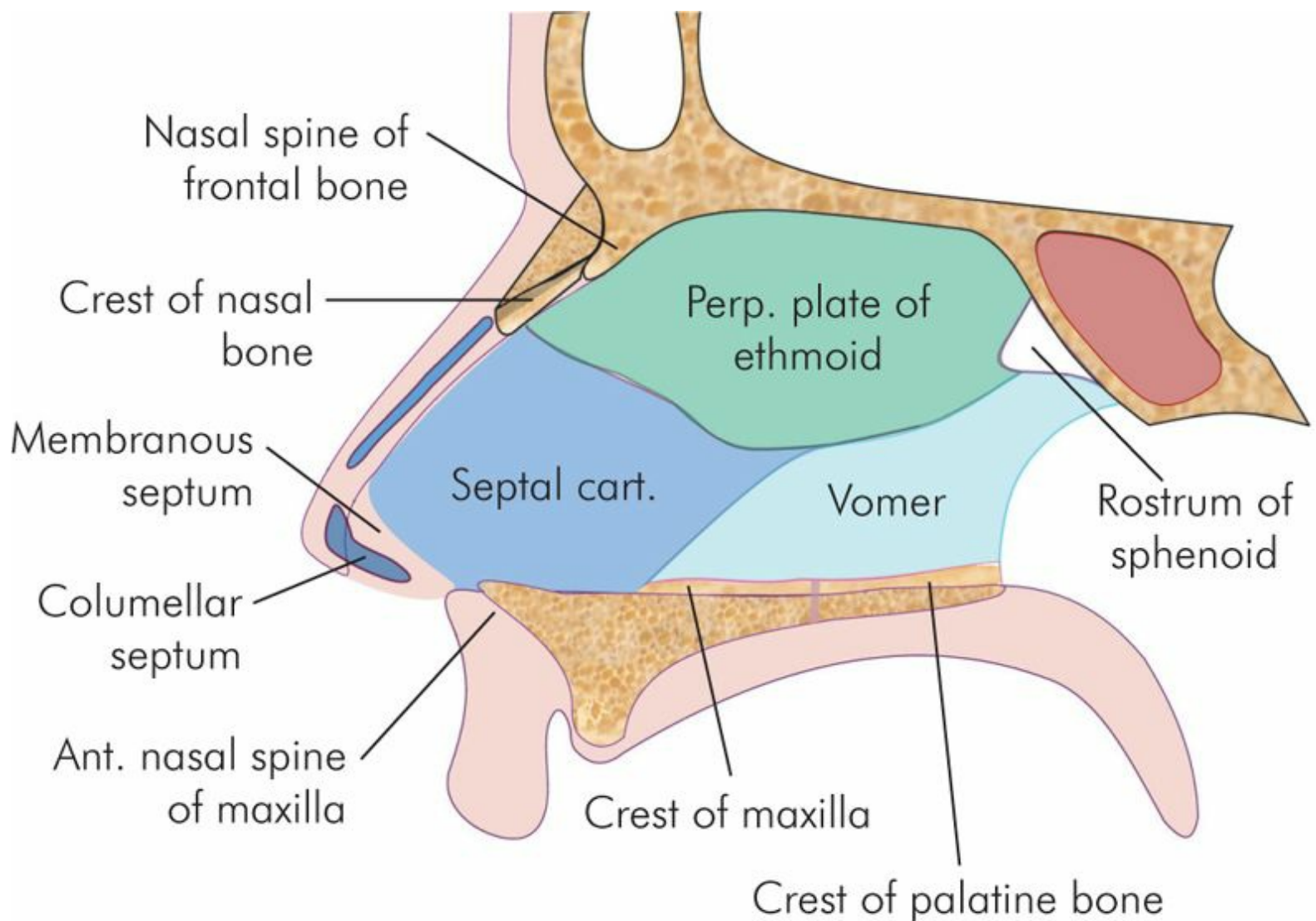
It consists of double layer of skin with no bony or cartilaginous support. It lies between the columella and the caudal border of septal cartilage. Both columellar and membranous parts are freely movable from side to side.

#### 3. Septum proper

It consists of osteocartilaginous framework, covered with nasal mucous membrane.

Its principal constituents are (Fig. 26.1):

- (i) the perpendicular plate of ethmoid
- (ii) the vomer, and
- (iii) a large septal (quadrilateral) cartilage wedged between the above two bones anteriorly. Other bones which make minor contributions at the periphery are: crest of nasal bones, nasal spine of frontal bone, rostrum of sphenoid, crest of palatine bones and the crest maxilla, and the anterior nasal spine of maxilla.



Dhingra: Diseases of Ear Nose and Throat, 5th Edition  
Copyright © 2010 Elsevier. All rights reserved.

Figure 26.1 Anatomy of nasal septum.

Septal cartilage not only forms a partition between the right and left nasal cavities but also provides support to the tip and dorsum of cartilaginous part of nose. Its destruction, e.g. in septal abscess, injuries, tuberculosis or excessive removal during septal surgery, leads to depression of lower part of nose and drooping of the nasal tip.

Septal cartilage lies in a groove in the anterior edge of vomer and rests anteriorly on anterior nasal spine. During trauma, it may get dislocated from anterior nasal spine or vomerine groove causing caudal septal deviation or septal spur respectively. This compromises the nasal airway. Septal cartilage is also intimately related to the upper lateral cartilages of nose and is in fact fused with them in the upper third. For this reason septal deviation may be associated with deviation of cartilaginous part of external nose.

*Blood Vessels of Nasal Septum (see Chapter 33).*

*Nerve Supply of Nasal Septum (see Chapter 23).*

### ***Little's area or Kiesselbach's plexus***

This is the vascular area in the antero-inferior part of nasal septum just above the vestibule. Anterior ethmoidal, sphenopalatine, greater palatine and septal branch of superior labial arteries and their corresponding veins form an anastomosis here. This is the commonest site for epistaxis. This is also the site for origin of the "bleeding polypus" (haemangioma) of nasal septum.



# Fractures of Nasal Septum

## Aetiopathogenesis

page 162

page 163

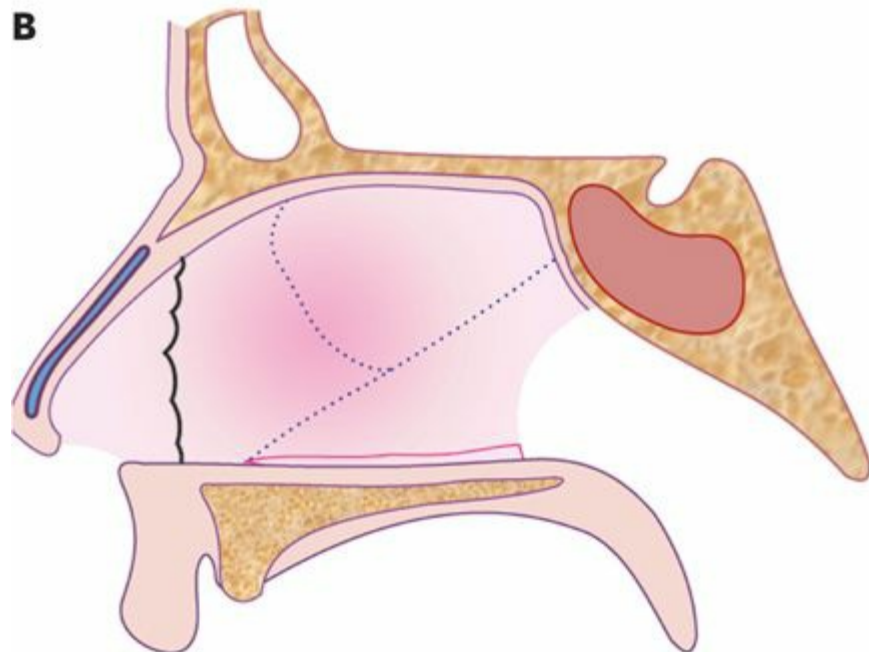
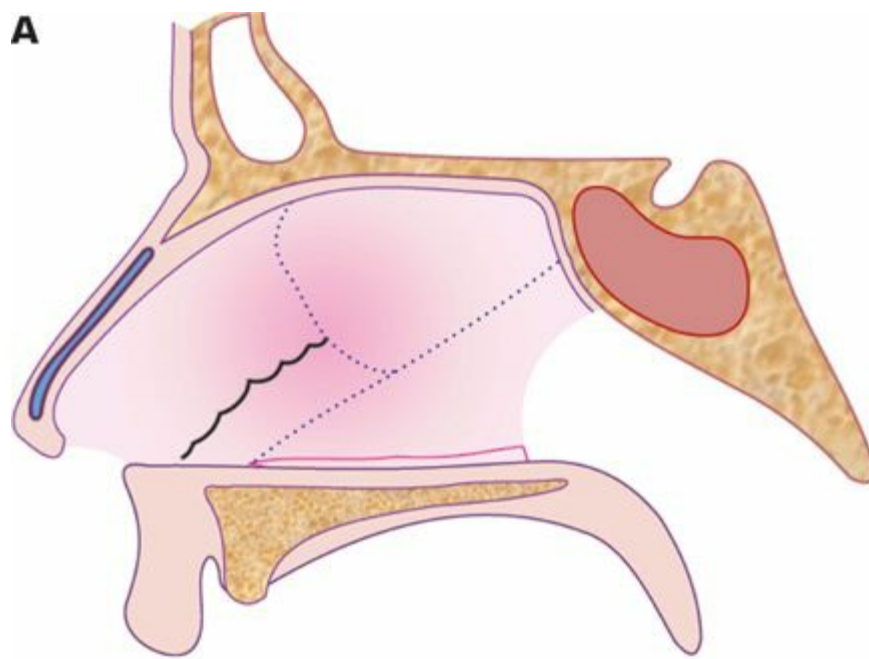
Trauma inflicted on the nose from the front, side or below can result in injuries to the nasal septum. The septum may buckle on itself, fracture vertically, horizontally or be crushed to pieces as in a smashed nose. The fractured pieces of septum may overlap each other or project into the nasal cavity through mucosal tears. Fracture of the septal cartilage or its dislocation from the vomerine groove, can result from trauma to the lower nose without associated fractures of nasal bones. Septal injuries with mucosal tears cause profuse epistaxis while those with intact mucosa result in septal haematoma which, if not drained early, will cause absorption of the septal cartilage and saddle nose deformity.

"Jarjaway" fracture of nasal septum results from blows from the front; it starts just above the anterior nasal spine and runs horizontally backwards just above the junction of septal cartilage with the vomer (Fig. 26.2A).

"Chevallet" fracture of septal cartilage results from blows from below; it runs vertically from the anterior nasal spine upwards to the junction of bony and cartilaginous dorsum of nose (Fig. 26.2B).

## Treatment

Early recognition and treatment of septal injuries is essential. Haematomas should be drained. Dislocated or fractured septal fragments should be repositioned and supported between mucoperichondrial flaps with mattress sutures and nasal packing. Fractures of nasal pyramid are often complicated with fractures of the septum and both should be treated concomitantly.



Dhingra: Diseases of Ear Nose and Throat, 5th Edition  
 Copyright © 2010 Elsevier. All rights reserved.

Figure 26.2 Septal fracture showing: (A) Jarjaway type. (B) Chevillet type.

## Complications

Septum is important in supporting the lower part of the external nose. If its injuries are ignored, they would result in deviation of the cartilaginous nose, or asymmetry of nasal tip, columella or the nostril.

# DEVIATED NASAL SEPTUM (DNS)

This is an important cause of nasal obstruction.

## Aetiology

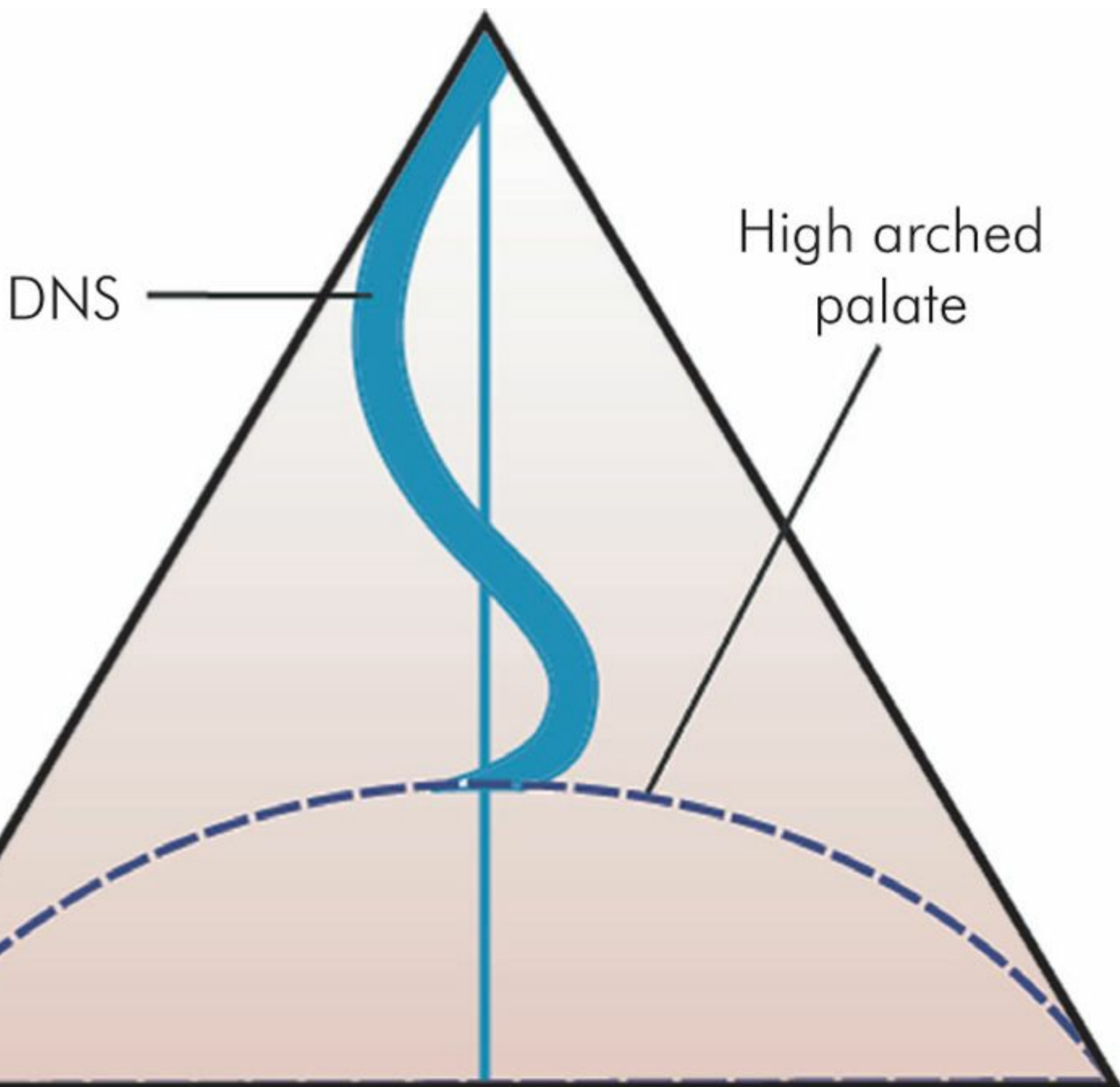
Trauma and errors of development form the two important factors in the causation of deviated septum.

### 1. Trauma

A lateral blow on the nose may cause displacement of septal cartilage from the vomerine groove and maxillary crest, while a crushing blow from the front may cause buckling, twisting, fractures and duplication of nasal septum with telescoping of its fragments. Injuries to the nose commonly occur in childhood but are often overlooked. Even the history may not be forthcoming. Trauma may also be inflicted at birth during difficult labour when nose is pressed during its passage through the birth canal. Birth injuries should be immediately attended to as they result in septal deviation later in life.

### 2. Developmental error

Nasal septum is formed by the tectoseptal process which descends to meet the two halves of the developing palate in the midline. During the primary and secondary dentition, further development takes place in the palate, which descends and widens to accommodate the teeth.



Unequal growth between the palate and the base of skull may cause buckling of the nasal septum. In mouth breathers, as in adenoid hypertrophy, the palate is often highly arched and the septum is deviated (Fig. 26.3). Similarly, DNS may be seen in cases of cleft lip and palate and in those with dental abnormalities.

### 3. Racial factors

Caucasians are affected more than Negroes.

### 4. Hereditary factors

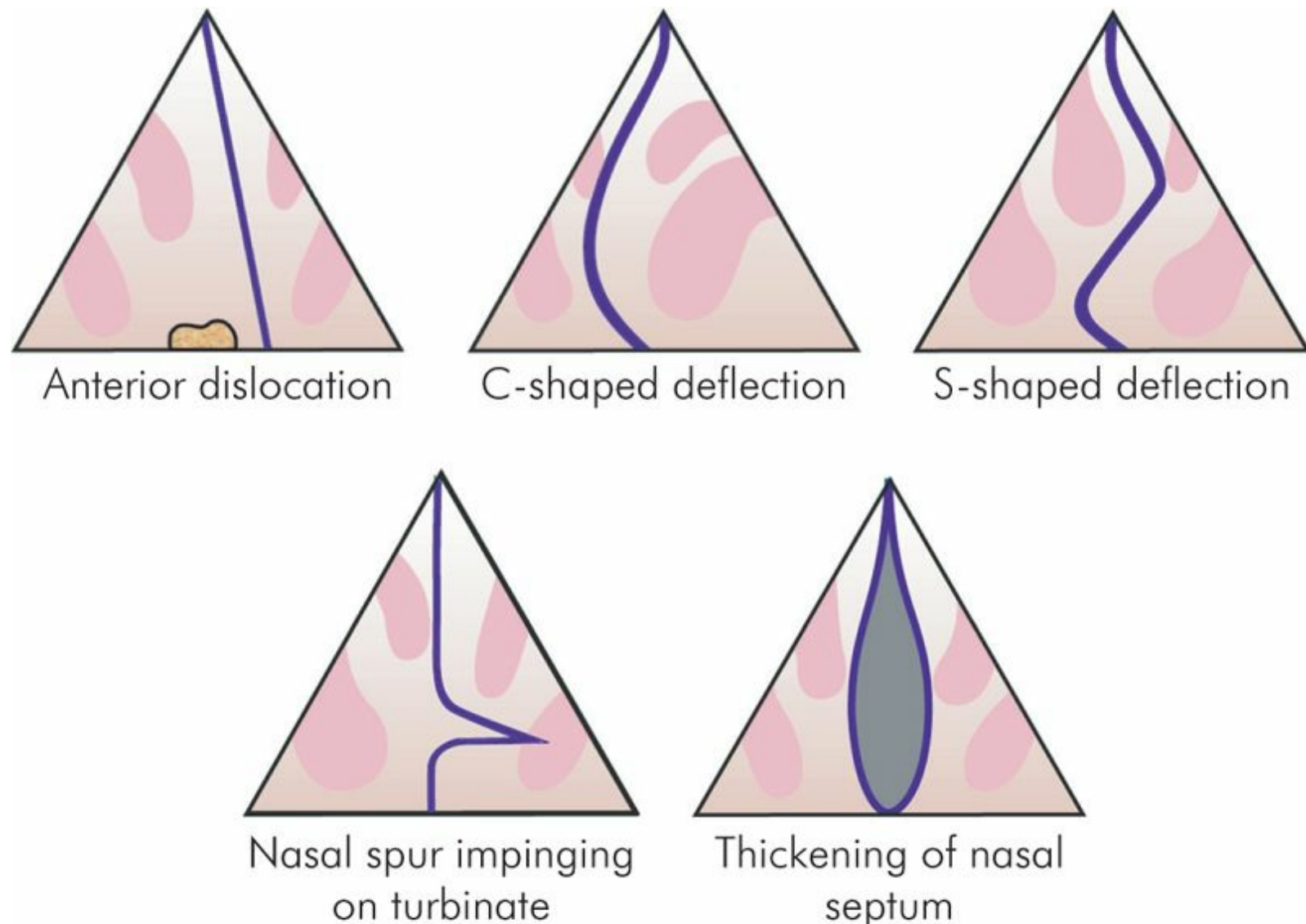
Several members of the same family may have deviated nasal septum.

## Types of DNS (Fig. 26.4)

Deviation may involve only the cartilage, bone or both the cartilage and bone.

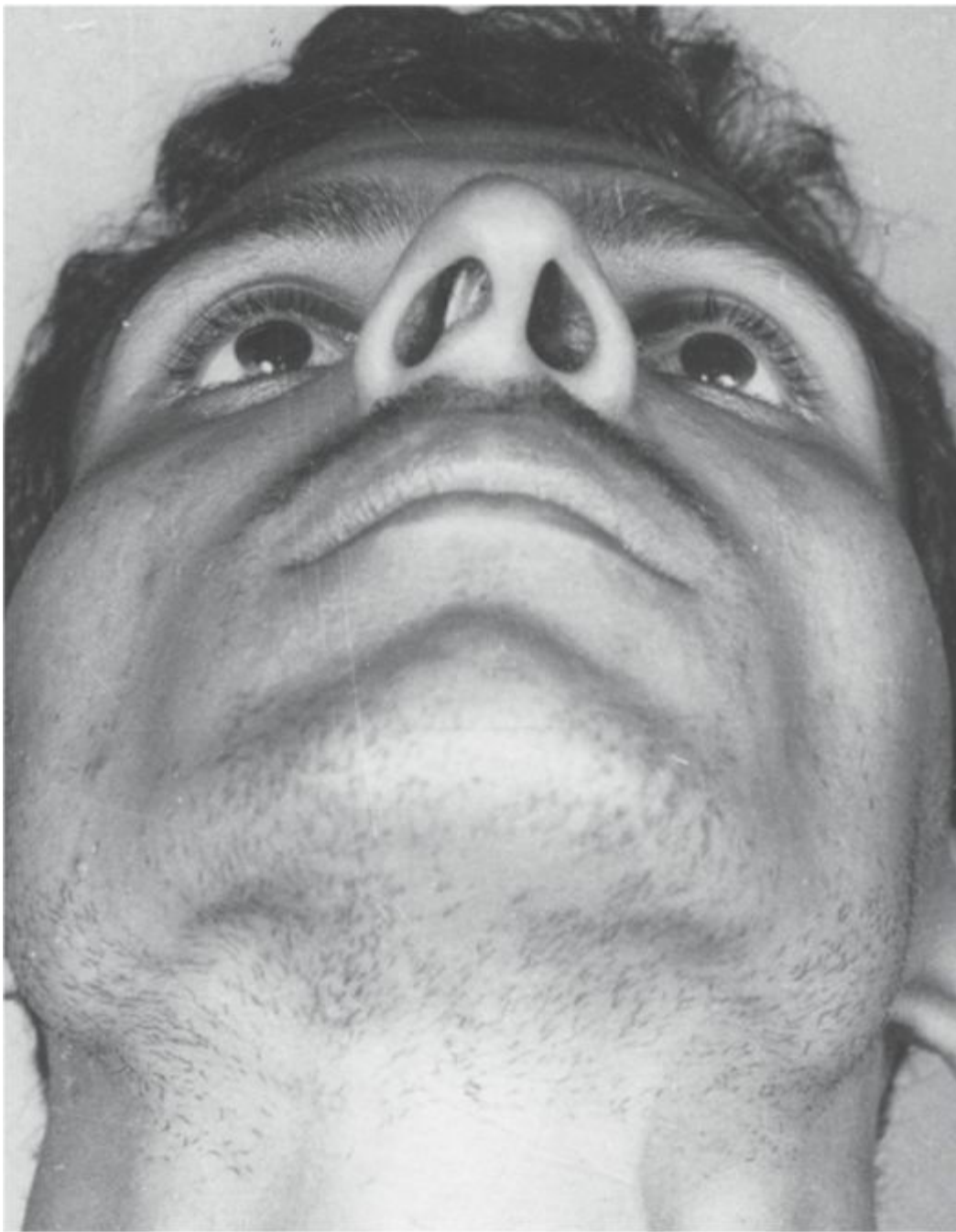
### 1. Anterior dislocation

Septal cartilage may be dislocated into one of the nasal chambers. This is better appreciated by looking at the base of nose when patient's head is tilted backwards (Fig. 26.5).



Dhingra: Diseases of Ear Nose and Throat, 5th Edition  
Copyright © 2010 Elsevier. All rights reserved.

Figure 26.4 Types of deviated nasal septum.



Dhingra: Diseases of Ear Nose and Throat, 5th Edition  
Copyright © 2010 Elsevier. All rights reserved.

Figure 26.5 Anterior dislocation. Caudal border of septal cartilage projects into right naris.

## **2. C-shaped deformity**

Septum is deviated in a simple curve to one side. Nasal chamber on the concave side of the nasal septum will be wider and may show compensatory hypertrophy of turbinates.

## **3. S-shaped deformity**

Septum may show a S-shaped curve either in vertical or anteroposterior plane. Such a deformity may cause bilateral nasal obstruction.

## **4. Spurs**

A spur is a shelf-like projection often found at the junction of bone and cartilage. A spur may press on the lateral wall and gives rise to headache. It may also predispose to repeated epistaxis from the vessels stretched on its convex surface.

## **5. Thickening**

It may be due to organised haematoma or over-riding of dislocated septal fragments.

## **Clinical Features**

DNS can involve any age and sex. Males are affected more than females.

### **1. Nasal obstruction**

Depending on the type of septal deformity, obstruction may be unilateral or bilateral. Respiratory currents pass through upper part of nasal cavity, therefore, high septal deviation cause nasal obstruction more than lower ones.

When examining a case of nasal obstruction, one should ascertain the site of obstruction in the nose. It could be (1) *vestibular* (caudal septal dislocation, synechiae or stenosis), (2) at the *nasal valve* (synechiae, usually post-rhinoplasty), (3) *attic* (along the upper part of nasal septum due to high septal deviation; (4) *turbinal* (hypertrophic turbinates or concha bullosa); and (5) *choanal* (choanal atresia or a choanal polyp.) unilateral choanal atresia may be missed in infancy and childhood. Choanal polyp may be missed on the anterior rhinoscopy unless posterior rhinoscopy or nasal endoscopy is done.

*Cottle test.* It is used in nasal obstruction due to abnormality of the nasal valve. In this test, cheek is drawn laterally while the patient breathes quietly. If the nasal airway improves on the test side, the test is positive, and indicates abnormality of the vestibular component of nasal valve (Fig. 26.6).

### **2. Headache**

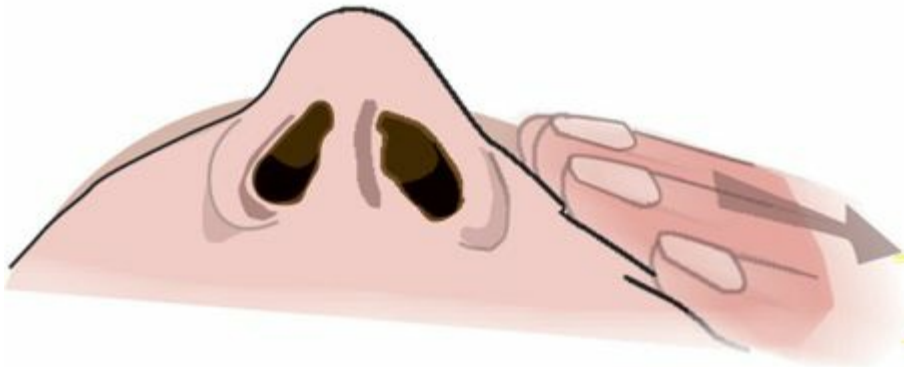

Deviated septum, especially a spur, may press on the lateral wall of nose giving rise to pressure headache.

### **3. Sinusitis**

Deviated septum may obstruct sinus ostia resulting in poor ventilation of the sinuses. Therefore, it forms an important cause to predispose or perpetuate sinus infections.

### **4. Epistaxis**

Mucosa over the deviated part of septum is exposed to the drying effects of air currents leading to formation of crusts which when removed, cause bleeding. Bleeding may also occur from vessels over a septal spur.



Dhingra: Diseases of Ear Nose and Throat, 5th Edition  
Copyright © 2010 Elsevier. All rights reserved.

Figure 26.6 Cottle test: On pulling the cheek away from the midline, the nasal valve opens, increasing the airflow from that side of the nasal cavity.

### **5. Anosmia**

Failure of the inspired air to reach the olfactory region may result in total or partial loss of sense of smell.

### **6. External deformity**

Septal deformities may be associated with deviation of the cartilaginous or both the bony and cartilaginous dorsum of nose, deformities of the nasal tip or columella.

### **7. Middle ear infection**

DNS also predisposes to middle ear infection.

## **Treatment**

Minor degrees of septal deviation with no symptoms are commonly seen in patients and require no treatment. It is only when deviated septum produces mechanical nasal obstruction or the symptoms given above, that an operation is indicated.

### **Submucous resection (SMR) operation**

It is generally done in adults under local anaesthesia. It consists of elevating the mucoperichondrial and mucoperiosteal flaps on either side of the septal framework by a single incision made on one side of the septum, removing the deflected parts of the bony and cartilaginous septum, and then repositioning the flaps (see section on Operative Surgery for details).

### ***Septoplasty***

It is a conservative approach to septal surgery. In this operation, much of the septal framework is retained. Only the most deviated parts are removed. Rest of the septal framework is corrected and repositioned by plastic means. Mucoperichondrial/periosteal flap is generally raised only on one side of the septum, retaining the attachment and blood supply on the other. Septoplasty has now almost replaced SMR operation (see Chapter 85).

Septal surgery is usually done after the age of 17 so as not to interfere with the growth of nasal skeleton. However, if a child has severe septal deviation causing marked nasal obstruction, conservative septal surgery (septoplasty) can be performed to provide a good airway.



# SEPTAL HAEMATOMA

## Aetiology

It is collection of blood under the perichondrium or periosteum of the nasal septum (Fig. 26.7). It often results from nasal trauma or septal surgery. In bleeding disorders, it may occur spontaneously.

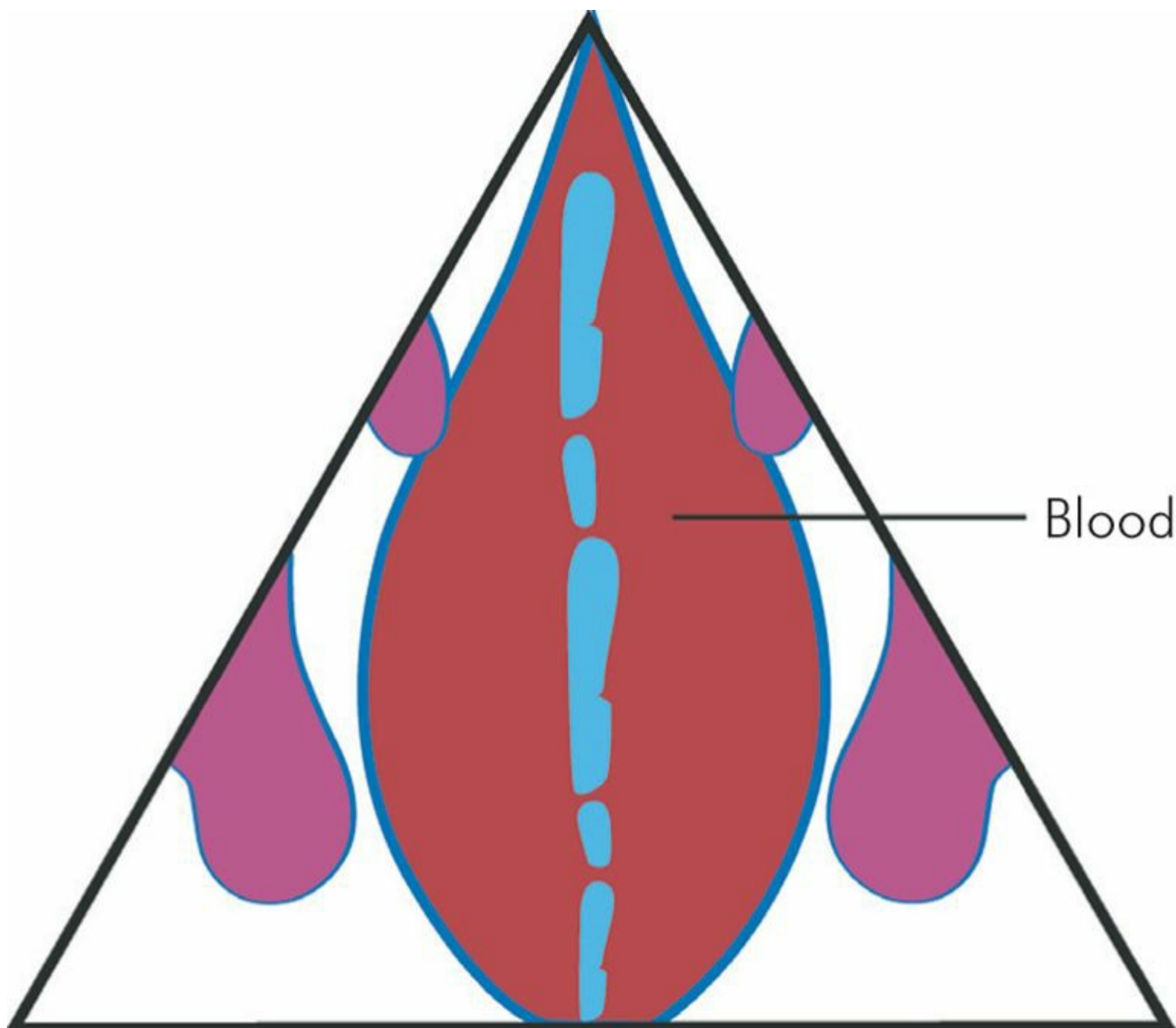
## Clinical Features

Bilateral nasal obstruction is the commonest presenting symptom. This may be associated with frontal headache and a sense of pressure over the nasal bridge.

Examination reveals smooth rounded swelling of the septum in both the nasal fossae. Palpation may show the mass to be soft and fluctuant.

## Treatment

Small haematomas can be aspirated with a wide bore sterile needle. Larger haematomas are incised and drained by a small antero-posterior incision parallel to the nasal floor. Excision of a small piece of mucosa from the edge of incision gives better drainage. Following drainage, nose is packed on both sides to prevent reaccumulation. Systemic antibiotics should be given, to prevent septal abscess.



Dhingra: Diseases of Ear Nose and Throat, 5th Edition  
Copyright © 2010 Elsevier. All rights reserved.

Figure 26.7 Septal haematoma.

## Complications

Septal haematoma, if not drained, may organise into fibrous tissue leading to a permanently thickened septum. If secondary infection supervenes, it results in septal abscess with necrosis of cartilage and depression of nasal dorsum.

# SEPTAL ABSCESS

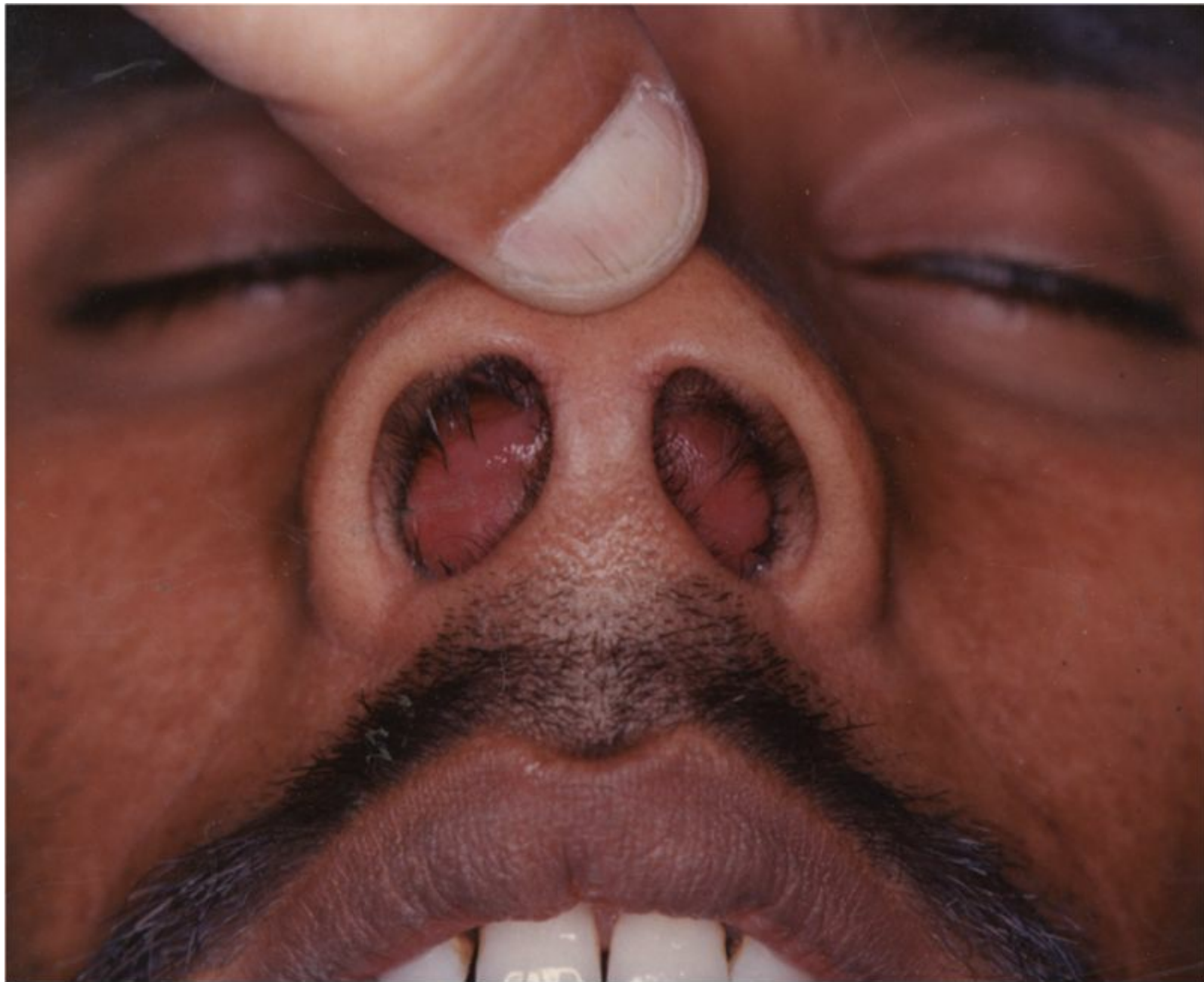
## Aetiology

Mostly, it results from secondary infection of septal haematoma. Occasionally, it follows furuncle of the nose or upper lip. It may also follow acute infection such as typhoid or measles.

## Clinical Features

There is severe bilateral nasal obstruction with pain and tenderness over the bridge of nose. Patient may also complain of fever with chills and frontal headache. Skin over the nose may be red and swollen. Internal examination of nose reveals smooth bilateral swelling of the nasal septum (Fig. 26.8). Fluctuation can be elicited in this swelling. Septal mucosa is often congested. Submandibular lymph nodes may also be enlarged and tender.

## Treatment



Dhingra: Diseases of Ear Nose and Throat, 5th Edition  
Copyright © 2010 Elsevier. All rights reserved.

Figure 26.8 Septal abscess.

Abscess should be drained as early as possible. Incision is made in the most dependent part of the abscess and a piece of septal mucosa excised. Pus and necrosed pieces of cartilage are removed by suction. Incision may require to be reopened daily for 2-3 days to drain any pus or to remove any necrosed pieces of cartilage. Systemic antibiotics are started as soon as diagnosis has been made and continued at least for a period of 10 days.

## **Complications**

Necrosis of septal cartilage often results in depression of the cartilaginous dorsum in the supratip area and may require augmentation rhinoplasty, 2 to 3 months later. Necrosis of septal flaps may lead to septal perforation. Meningitis and cavernous sinus thrombosis following septal abscess, though rare these days, can be a serious complication.

## PERFORATION OF NASAL SEPTUM (Fig. 26.9)

### Aetiology

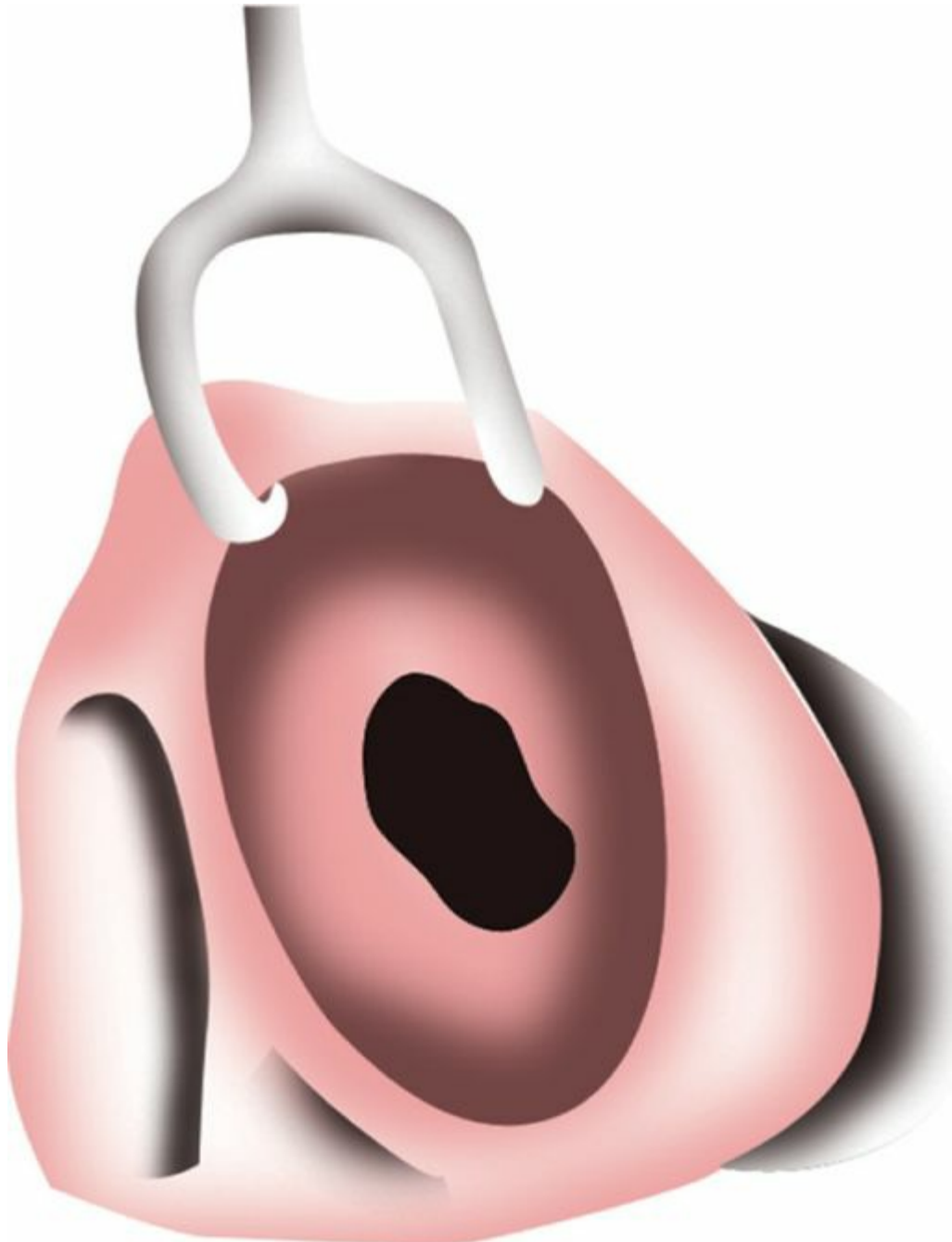
#### 1. Traumatic perforations

Trauma is the most common cause. Injury to mucosal flaps during SMR, cauterization of septum with chemicals or galvanocautery for epistaxis and habitual nose-picking are the common forms of trauma. Occasionally, septum is deliberately perforated to put ornaments.

#### 2. Pathological perforations

They can be caused by:

- (a) Septal abscess.
- (b) Nasal myiasis.
- (c) Rhinolith or neglected foreign body causing pressure necrosis.
- (d) Chronic granulomatous conditions like lupus, tuberculosis and leprosy cause perforation in the cartilaginous part while syphilis involves the bony part. In these cases, evidence of the causative disease, may also be seen in other systems of the body.
- (e) Wegener's granuloma is a midline destructive lesion which may cause total septal destruction.



### 3. *Drugs and chemicals*

- (a) Prolonged use of steroid sprays in nasal allergy.
- (b) Cocaine addicts.
- (c) Workers in certain occupations e.g. chromium plating, dichromate or soda ash (sodium carbonate) manufacture or those exposed to arsenic or its compounds.


### 4. *Idiopathic*

In many cases, there is no history of trauma or previous disease and the patient may even be unaware of the existence of a perforation.

### Clinical Features

Small anterior perforations cause whistling sound during inspiration or expiration. Larger perforations develop crusts which obstruct the nose or cause severe epistaxis when removed.

### Treatment



Dhingra: Diseases of Ear Nose and Throat, 5th Edition  
Copyright © 2010 Elsevier. All rights reserved.

Figure 26.10 Septal button for closure of perforation.

An attempt should always be made to find out the cause before treatment of perforation. This may require biopsy from the granulation or the edge

of the perforation. Inactive small perforations can be surgically closed by plastic flaps. Larger perforations are difficult to close. Their treatment is aimed to keep the nose crust-free by alkaline nasal douches and application of a bland ointment. Sometimes, a thin silastic button can be worn to get relief from the symptoms (Fig. 26.10.)

## 27 Acute and Chronic Rhinitis

### Acute Rhinitis

Acute rhinitis can be *viral*, *bacterial* or *irritative* type.



# VIRAL RHINITIS

## 1. Common cold (coryza)

**Aetiology.** It is caused by a virus. The infection is usually contracted through airborne droplets. Several viruses (adeno virus, picorna virus and its sub-groups such as rhinovirus, coxsackie, and ECHO) are responsible. Incubation period is 1-4 days and illness lasts for 2-3 weeks.

**Clinical features.** To begin with, there is burning sensation at the back of nose soon followed by nasal stuffiness, rhinorrhoea and sneezing. Patient feels chilly and there is low grade fever. Initially, nasal discharge is watery and profuse but may become mucopurulent due to secondary bacterial invasion. Secondary invaders include *Strept. haemolyticus*, *pneumococcus*, *staphylococcus*, *H. influenzae*, *Kleb. pneumoniae* and *M. catarrhalis*.

**Treatment.** Bed rest is essential to cut down the course of illness. Plenty of fluids are encouraged. Symptoms can be easily controlled with antihistaminics and nasal decongestants. Analgesics are useful to relieve headache, fever and myalgia. Non-aspirin containing analgesics are preferable as aspirin causes increased shedding of virus. Antibiotics are required when secondary infection supervenes.

**Complications.** The disease is usually self-limiting and resolves spontaneously after 2 to 3 weeks, but occasionally, complications such as sinusitis, pharyngitis, tonsillitis, bronchitis, pneumonia and otitis media may result.

## 2. Influenzal rhinitis

Influenza viruses A, B or C are responsible. Symptoms and signs are similar to those of common cold. Complications due to bacterial invasion are common.

## 3. Rhinitis associated with exanthemas

Measles, rubella, chickenpox are often associated with rhinitis which precedes exanthemas by 2-3 days. Secondary infection and complications are more frequent and severe.

# BACTERIAL RHINITIS

## ***Non-specific infections***

It may be primary or secondary. Primary bacterial rhinitis is seen in children and is usually the result of infection with *pneumococcus*, *streptococcus* or *staphylococcus*. A greyish white tenacious membrane may form in the nose, which with attempted removal, causes bleeding.

Secondary bacterial rhinitis is the result of bacterial infection supervening acute viral rhinitis.

## ***Diphtheritic rhinitis***

Diphtheria of nose is rare these days. It may be primary, or secondary to faucial diphtheria and may occur in acute or chronic form. A greyish membrane is seen covering the inferior turbinate and the floor of nose; membrane is tenacious and its removal causes bleeding. Excoriation of anterior nares and upper lip may be seen. Treatment is isolation of the patient, systemic penicillin and diphtheria antitoxin.

## **IRRITATIVE RHINITIS**

This form of acute rhinitis is caused by exposure to dust, smoke or irritating gases such as ammonia, formaline, acid fumes, etc. or it may result from trauma inflicted on the nasal mucosa during intranasal manipulation, e.g. removal of a foreign body. There is an immediate catarrhal reaction with sneezing, rhinorrhoea and nasal congestion. The symptoms may pass off rapidly with removal of the offending agent or may persist for some days if nasal epithelium has been damaged. Recovery will depend on the amount of epithelial damage and the infection that supervenes.

# Chronic Rhinitis

Chronic non-specific inflammations of nose include:

- 1. Chronic simple rhinitis.
- 2. Hypertrophic rhinitis.
- 3. Atrophic rhinitis.
- 4. Rhinitis sicca.
- 5. Rhinitis caseosa.

# CHRONIC SIMPLE RHINITIS

## Aetiology

Recurrent attacks of acute rhinitis in the presence of predisposing factors leads to chronicity. The predisposing factors are:

- (a) Persistence of nasal infection due to sinusitis, tonsillitis, and adenoids.
- (b) Chronic irritation from dust, smoke, cigarette smoking, snuff, etc.
- (c) Nasal obstruction due to DNS, synechia leading to persistence of discharge in the nose.
- (d) Vasomotor rhinitis.
- (e) Endocrinal or metabolic factors, e.g. hypothyroidism, excessive intake of carbohydrates, lack of exercise.

## Pathology

Simple chronic rhinitis is an early stage of hypertrophic rhinitis. There is hyperaemia and oedema of mucous membrane with hypertrophy of seromucinous glands and increase in goblet cells. Blood sinusoids particularly those over the turbinates are distended.

## Clinical Features

- (a) *Nasal obstruction*. Usually worse on lying and affects the dependent side of nose.
- (b) *Nasal discharge*. It may be mucoid or mucopurulent, thick and viscid and often trickles into the throat as post-nasal drip. Patient has a constant desire to blow the nose or clear the throat.
- (c) *Headache*. It is due to swollen turbinates impinging on the nasal septum.
- (d) *Swollen turbinates*. Nasal mucosa is dull red in colour. Turbinates are swollen; they pit on pressure and shrink with application of vasoconstrictor drops (this differentiates the condition from hypertrophic rhinitis). Middle turbinate may also be swollen and impinge on the septum.
- (e) *Post-nasal discharge*. Mucoid or mucopurulent discharge is seen on the posterior pharyngeal wall.

## Treatment

- (a) Treat the cause with particular attention to sinuses, tonsils, adenoids, allergy, personal habits (smoking or alcohol indulgence), environment or work situation (smoky or dusty surroundings).
- (b) Nasal irrigations with alkaline solution help to keep the nose free from viscid secretions and also remove superficial infection.
- (c) Nasal decongestants help to relieve nasal obstruction and improve sinus ventilation. Excessive use of nasal drops and sprays should be avoided because it may lead to rhinitis medicamentosa. A short course of systemic steroids helps to wean the patients already addicted to excessive use of decongestant drops or sprays.
- (d) Antibiotics help to clear nasal infection and concomitant sinusitis.

# HYPERTROPHIC RHINITIS

It is characterised by thickening of mucosa, submucosa, seromucinous glands, periosteum and bone. Changes are more marked on the turbinates.

## Aetiology

Common causes are recurrent nasal infections, chronic sinusitis, chronic irritation of nasal mucosa due to smoking, industrial irritants, prolonged use of nasal drops and vasomotor and allergic rhinitis.

## Symptoms

Nasal obstruction is the predominant symptom. Nasal discharge is thick and sticky. Some complain of headache, heaviness of head or transient anosmia.

## Signs

Examination shows hypertrophy of turbinates. Turbinal mucosa is thick and does not pit on pressure. It shows little shrinkage with vasoconstrictor drugs due to presence of underlying fibrosis.

Maximum changes are seen in the inferior turbinate. It may be hypertrophied in its entirety or only at the anterior end, posterior end or along the inferior border giving it a mulberry appearance.

## Treatment

page 169

page 170

Attempt should be made to discover the cause and remove it. Nasal obstruction can be relieved by reduction in size of turbinates. The various methods are:

- **(a)** Linear cauterisation.
- **(b)** Submucosal diathermy.
- **(c)** Cryosurgery of turbinates.
- **(d)** Partial or total turbinectomy. Hypertrophied inferior turbinate can be partially removed at its anterior end, inferior border or posterior end. Middle turbinate, if hypertrophied, can also be removed partially or totally. Excessive removal of turbinates should be avoided as it leads to persistent crusting.
- **(e)** Submucous resection of turbinate bone. This removes bony obstruction but preserves turbinal mucosa for its function.
- **(f)** Lasers have also been used to reduce the size of turbinates.

## Compensatory Hypertrophic Rhinitis

This is seen in cases of marked deviation of septum to one side. The roomier side of the nose shows hypertrophy of inferior and middle turbinates. This is an attempt on the part of nature to reduce the wide space to overcome the ill-effects of drying and crusting that always attend wider nasal space. Hypertrophic changes in these cases are not reversible with the correction of nasal septum and often require reduction of turbinates at the time of septal surgery.

## **ATROPHIC RHINITIS (OZAENA)**

It is a chronic inflammation of nose characterised by atrophy of nasal mucosa and turbinate bones. The nasal cavities are roomy and full of foul-smelling crusts. Atrophic rhinitis is of two types: primary and secondary.



# Primary Atrophic Rhinitis

## Aetiology (Remember Mnemonic HERNIA)

The exact cause is not known. Various theories advanced regarding its causation are:

- **(a) Hereditary factors.** Disease is known to involve more than one member in the same family.
- **(b) Endocrinal disturbance.** Disease usually starts at puberty, involves females more than males, the crusting and foetor associated with disease tends to cease after menopause; these factors have raised the possibility of disease being an endocrinal disorder.
- **(c) Racial factors.** White and yellow races are more susceptible than natives of equatorial Africa.
- **(d) Nutritional deficiency.** Disease may be due to deficiency of vitamin A, D or iron or some other dietary factors. The fact that incidence of disease is decreasing in western countries and is rarely seen in well-to-do families raises the possibility of some nutritional deficiency.
- **(e) Infective.** Various organisms have been cultured from cases of atrophic rhinitis such as *Klebsiella ozaenae*, (Perez bacillus), *diphtheroids*, *P. vulgaris*, *Esch. coli*, *Staphylococci* and *Streptococci* but they are all considered to be secondary invaders responsible for foul smell rather than the primary causative organisms of the disease.
- **(f) Autoimmune process.** The body reacts by a destructive process to the antigens released from the nasal mucosa. Viral infection or some other unspecified agents may trigger antigenicity of nasal mucosa.

## Pathology

Ciliated columnar epithelium is lost and is replaced by stratified squamous type. There is atrophy of seromucinous glands, venous blood sinusoids and nerve elements. Arteries in the mucosa, periosteum and bone show obliterative endarteritis. The bone of turbinates undergoes resorption causing widening of nasal chambers. Paranasal sinuses are small due to their arrested development.

## Clinical Features

Disease is commonly seen in females and starts around puberty. There is foul smell from the nose making the patient a social outcast though patient himself is unaware of the smell due to marked anosmia (*merciful anosmia*) which accompanies these degenerative changes. Patient may complain of nasal obstruction in spite of unduly wide nasal chambers. This is due to large crusts filling the nose. Epistaxis may occur when the crusts are removed.

Examination shows nasal cavity to be full of greenish or greyish black dry crusts covering the turbinates and septum. Attempts to remove them may cause bleeding. When the crusts have been removed, nasal cavities appear roomy with atrophy of turbinates so much so that the posterior wall of nasopharynx can be easily seen. Nasal turbinates may be reduced to mere ridges. Nasal mucosa appears pale. Septal perforation and dermatitis of nasal vestibule may be present. Nose may show a saddle deformity.

Atrophic changes may also be seen in the pharyngeal mucosa which may appear dry and glazed with crusts (atrophic pharyngitis, page 270).

Similar changes may occur in the larynx with cough and hoarseness of voice (atrophic laryngitis).

Hearing-impairment may be noticed because of obstruction to eustachian tube and middle ear effusion.

Paranasal sinuses are usually small and underdeveloped with thick walls. They appear opaque on X-ray. Antral wash is difficult to perform due to thick walls of the sinuses.

## Prognosis

The disease persists for years but there is a tendency to recover spontaneously in middle age.

page 170

page 171

## Treatment

It may be medical or surgical.

### 1. Medical

Complete cure of the disease is not yet possible. Treatment aims at maintaining nasal hygiene by removal of crusts and the associated putrefying smell, and to further check crust formation.

- **(a) Nasal irrigation and removal of crusts.** Warm normal saline or an alkaline solution made by dissolving a teaspoonful of powder containing soda bicarbonate 1 part, Sodium baborate 1 part, Sodium chloride 2 parts in 280 ml of water, is used to irrigate the nasal cavities. The solution is run through one nostril and comes out from the other. It loosens the crusts and removes thick tenacious discharge. Care should be taken to avoid pushing the fluid into the sinuses and eustachian tube. Initially, irrigations are done 2 or 3 times a day but later once every 2 or 3 days is sufficient. Hard crusts may be difficult to remove by irrigation. They are first loosened and then mechanically removed with forceps or suction.
- **(b) 25% glucose in glycerine.** After crusts are removed, nose is painted with 25% glucose in glycerine. This inhibits the growth of proteolytic organisms which are responsible for foul smell.
- **(c) Local antibiotics.** Spraying or painting the nose with appropriate antibiotics help to eliminate secondary infection. Kemicetine™

antiozaena solution contains chloromycetin, oestradiol and vitamin D<sub>2</sub> and may be found useful.

- **(d) Oestradiol spray.** Helps to increase vascularity of nasal mucosa and regeneration of seromucinous glands.
- **(e) Placental extract** injected submucosally in the nose may provide some relief.
- **(f) Systemic use of streptomycin.** 1 g/day for 10 days has given good results in reducing crusting and odour. It is effective against *Klebsiella* organisms.
- **(g) Potassium iodide** given by the mouth promotes and liquefies nasal secretion.

## 2. Surgical

It includes:

- **(a) Young's operation.** Both the nostrils are closed completely just within the nasal vestibule by raising flaps. They are opened after 6 months or later. In these cases, mucosa may revert to normal and crusting reduced.  
*Modified Young's operation.* To avoid the discomfort of bilateral nasal obstruction, modified Young's operation aims to partially close the nostrils. It is also claimed to give the same benefit as Young's.
- **(b) Narrowing the nasal cavities.** Nasal chambers are very wide in atrophic rhinitis and air currents dry up secretions leading to crusting. Narrowing the size of the nasal airway helps to relieve the symptoms. Among the techniques followed, some are:
  - (i) Submucosal injection of teflon paste.
  - (ii) Insertion of fat, cartilage, bone or teflon strips under the mucoperiosteum of the floor and lateral wall of nose and the mucoperichondrium of the septum.
  - (iii) Section and medial displacement of lateral wall of nose.

## Secondary Atrophic Rhinitis

Specific infections like syphilis, lupus, leprosy and rhinoscleroma may cause destruction of the nasal structures leading to atrophic changes. Atrophic rhinitis can also result from long-standing purulent sinusitis, radiotherapy to nose or excessive surgical removal of turbinates.

### ***Unilateral atrophic rhinitis***

Extreme deviation of nasal septum may be accompanied by atrophic rhinitis on the wider side.

## **RHINITIS SICCA**

It is also a crust-forming disease seen in patients who work in hot, dry and dusty surroundings, e.g. bakers, iron- and goldsmiths. Condition is confined to the anterior third of nose particularly of the nasal septum. Here, the ciliated columnar epithelium undergoes squamous metaplasia with atrophy of seromucinous glands. Crusts form on the anterior part of septum and their removal causes ulceration and epistaxis, and may lead to septal perforation.

Treatment consists of correction of the occupational surroundings and application of bland ointment or one with an antibiotic and steroid, to the affected part. Nose pricking and forcible removal of crusts should be avoided. Nasal douche, like the one used in cases of atrophic rhinitis, is useful.

## **RHINITIS CASEOSA**

It is an uncommon condition, usually unilateral and mostly affecting males.

Nose is filled with offensive purulent discharge and cheesy material. The disease possibly arises from chronic sinusitis with collection of inspissated cheesy material. Sinus mucosa becomes granulomatous. Bony walls of sinus may be destroyed, requiring differentiation from malignancy. Treatment is removal of debris and granulation tissue and free drainage of the affected sinus. Prognosis is good.

## **28 Granulomatous Diseases of Nose**

Various granulomatous lesions involving the nose are listed in Table 28.1. They are the result of bacterial or fungal infections or due to causes not yet clear. Many of these lesions may be manifestations of systemic diseases, which should always be looked for while making the diagnosis. Biopsy of the lesion is also essential, not only to establish the correct diagnosis of granulomatous disease but also to exclude a neoplasm, which many of these diseases may clinically simulate.

# BACTERIAL INFECTIONS

## Rhinoscleroma

It is a chronic granulomatous disease caused by Gram-negative bacillus called *Klebsiella rhinoscleromatis* or Frisch bacillus. The disease is endemic in several parts of the world. In India, it is seen more often in the northern than in the southern parts.

### Pathology

The disease starts in the nose and extends to nasopharynx, oropharynx, larynx (mostly subglottic region), trachea and bronchi. Mode of infection is unknown. Both sexes of any age may be affected.

### Clinical features

The disease runs through the following stages:

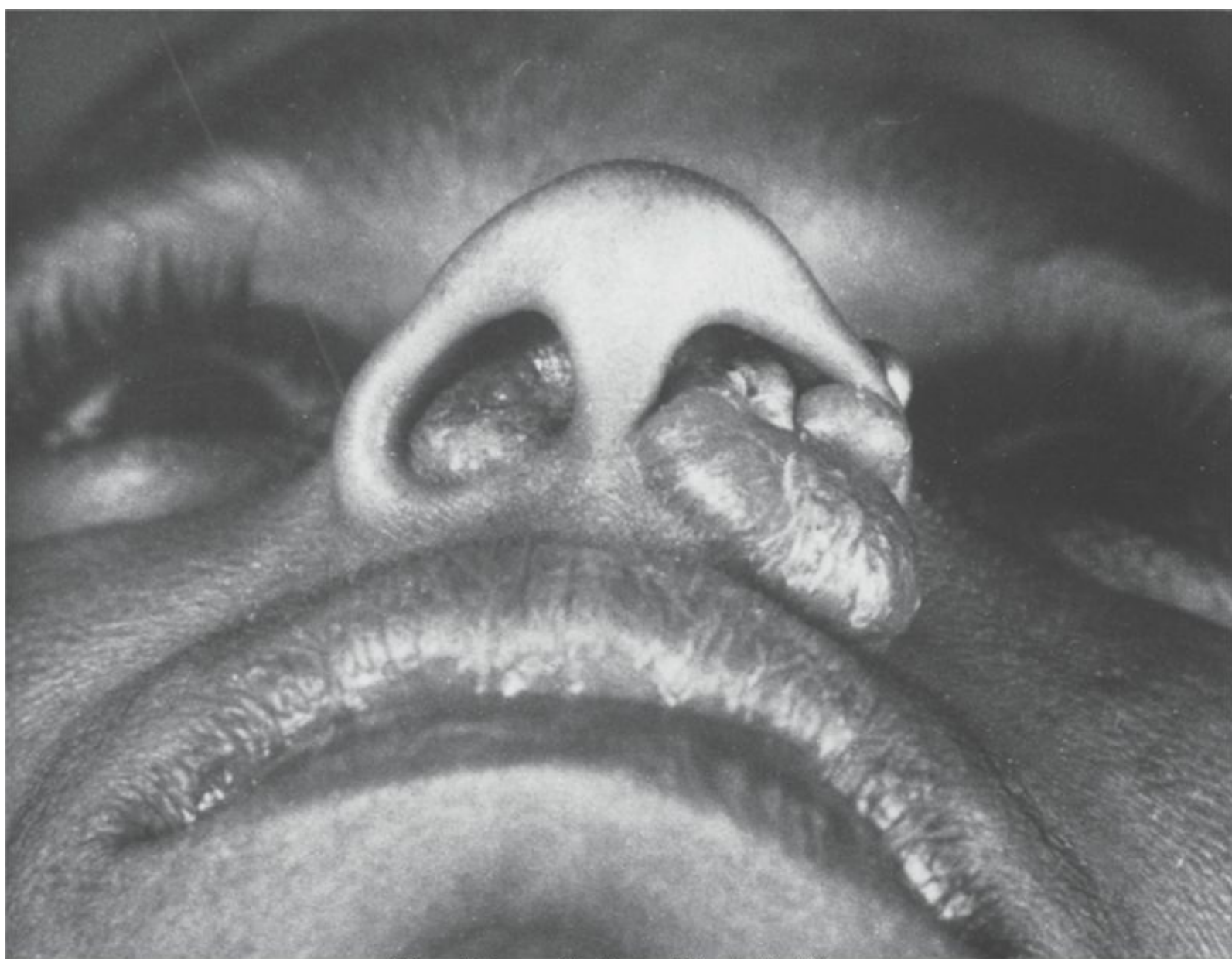
- **(a) Atrophic stage.** It resembles atrophic rhinitis and is characterised by foul smelling purulent nasal discharge and crusting.
- **(b) Granulomatous stage.** Granulomatous nodules form in nasal mucosa. There is also subdermal infiltration of lower part of external nose and upper lip giving a 'woody' feel (Fig. 28.1). Nodules are painless and non-ulcerative.
- **(c) Cicatricial stage.** This causes stenosis of nares, distortion of upper lip, adhesions in the nose, nasopharynx and oropharynx. There may be subglottic stenosis with respiratory distress.

Table 28-1. Granulomatous disease of nose

Bacterial	Fungal	Unspecified cause
Rhinoscleroma	Rhinosporidiosis	Wegener's granulomatosis
Syphilis	Aspergillosis	Non-healing midline
Tuberculosis	Mucormycosis	Granuloma
Lupus	Candidiasis	Sarcoidosis
Leprosy	Histoplasmosis	Rare
	Blastomycosis	

### Diagnosis

Biopsy shows infiltration of submucosa with plasma cells, lymphocytes, eosinophils, Mikulicz cells and Russell bodies. The latter two are diagnostic features of the disease. Mikulicz cells are large foam cells with a central nucleus and vacuolated cytoplasm containing causative bacilli. Russell bodies are homogenous eosinophilic inclusion bodies found in the plasma cells. They occur due to accumulation of immunoglobulins secreted by the plasma cells. The causative organisms can be cultured from the biopsy material.



Dhingra: Diseases of Ear Nose and Throat, 5th Edition  
Copyright © 2010 Elsevier. All rights reserved.

Figure 28.1 Rhinoscleroma nose.

page 172

page 173

### ***Treatment***

Both streptomycin (1 g/day) and tetracycline (2 g/day) are given together for a minimum period of 4-6 weeks and repeated, if necessary, after 1 month. Treatment is stopped only when two consecutive cultures from the biopsy material are negative. Steroids can be combined to reduce fibrosis.

Surgical treatment may be required to establish the airway and correct nasal deformity.



# Syphilis

Nasal syphilis is of two types: acquired and congenital.

## 1. Acquired

It occurs as:

- **(a) Primary.** It manifests as primary chancre of the vestibule of nose. It is rare.
- **(b) Secondary.** Rarely recognised. It manifests as simple rhinitis with crusting and fissuring in the nasal vestibule. Diagnosis is suggested by the presence of mucous patches in the pharynx, skin rash, fever and generalised lymphadenitis.
- **(c) Tertiary.** This is the stage in which nose is commonly involved. Typical manifestation is the formation of a gumma on the nasal septum. Later, the septum is destroyed both in its bony and cartilaginous parts. Perforation may also appear in the hard palate. There is offensive nasal discharge with crusts. Bony or cartilaginous sequestra may be seen. Bridge of the nose collapses causing a saddle nose deformity.

## 2. Congenital

It occurs in two forms: early and late.

*Early form.* It is seen in the first 3 months of life and manifests as "snuffles". Soon the nasal discharge becomes purulent. This is associated with fissuring and excoriation of the nasal vestibule and of the upper lip.

*Late form.* Usually manifests around puberty. Clinical picture is similar to that seen in tertiary stage of acquired syphilis. Gummatous lesions destroy the nasal structures. Other stigmata of syphilis such as corneal opacities, deafness and Hutchinson's teeth are also present.

## Diagnosis

It is made on serological tests (VDRL) and biopsy of the tissue with special stains to demonstrate *Trep. pallidum*.

## Treatment

Penicillin is the drug of choice: benzathine penicillin 2.4 million units i.m. every week for 3 weeks with a total dose of 7.2 million units. Nasal crusts are removed by irrigation with alkaline solution. Bony and cartilaginous sequestra should also be removed. Cosmetic deformity is corrected after disease becomes inactive.

## Complications

Syphilis can lead to vestibular stenosis, perforations of nasal septum and hard palate, secondary atrophic rhinitis and saddle nose deformity.

# Tuberculosis

Primary tuberculosis of nose is rare. More often it is secondary to lung tuberculosis. Anterior part of nasal septum and anterior end of inferior turbinate are the sites commonly involved. First, there is nodular infiltration followed later by ulceration and perforation of nasal septum in its cartilaginous part.

Diagnosis can be made on biopsy and special staining of sections for acid fast bacilli, culture of organisms and animal inoculation.

Treatment is antitubercular drugs.

## Lupus Vulgaris

It is a low-grade tuberculous infection commonly affecting nasal vestibule or the skin of nose and face. The skin lesions manifest characteristically as brown, gelatinous nodules called "apple-jelly" nodules. In the vestibule, it presents as chronic vestibulitis. Perforation may occur in the cartilaginous part of nasal septum.

It is difficult to isolate tubercle bacilli by culture or animal inoculation, however, biopsy of the lesion is useful to make the diagnosis.

Treatment is the same as for tuberculosis of nose.

## Leprosy

Leprosy is very common in the tropics and is widely prevalent in our country. It is caused by *Mycobacterium leprae*. The nose is involved as a part of systemic disease, more often in the lepromatous than tuberculoid or dimorphous forms of disease.

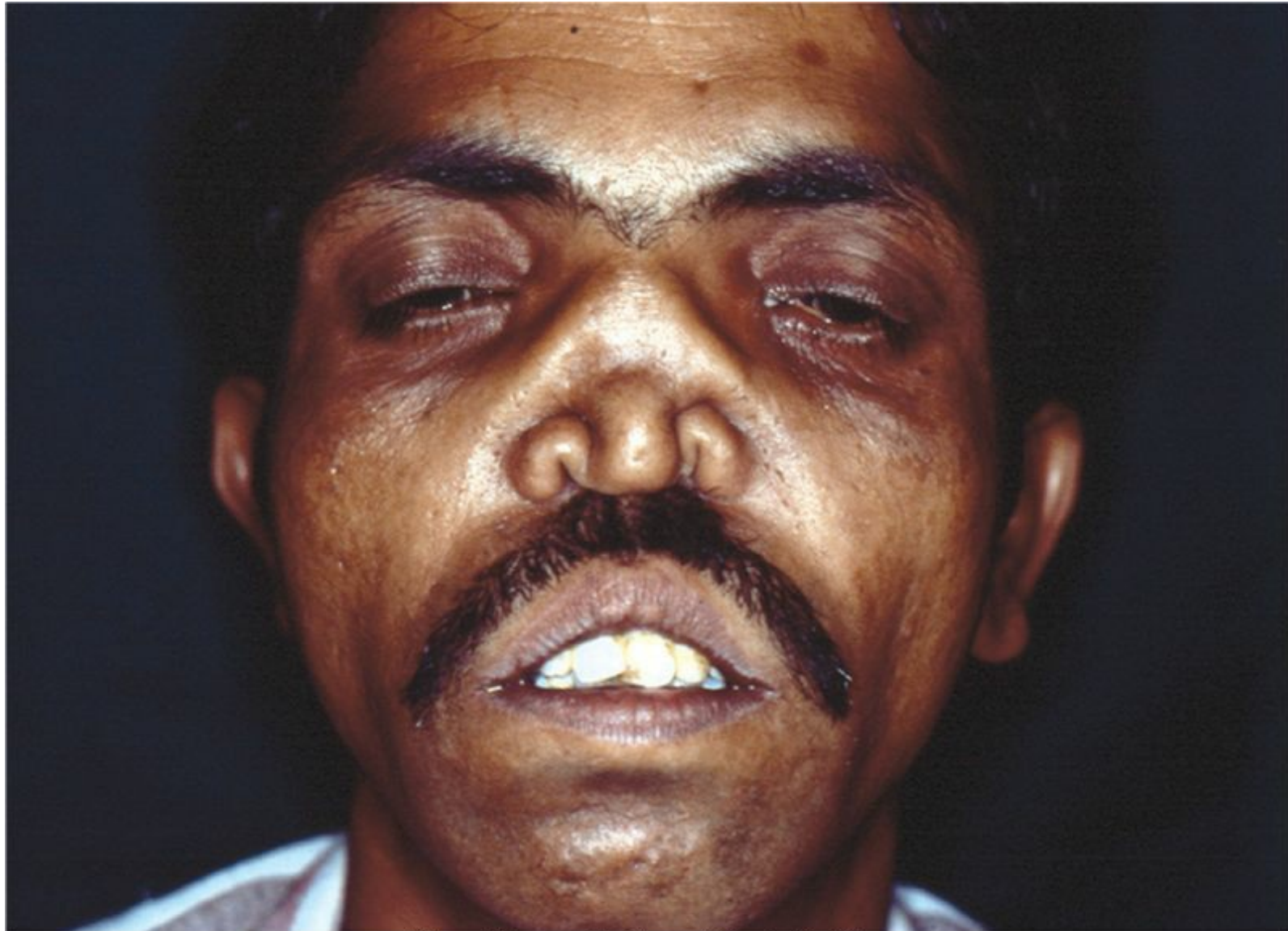Infection starts in the anterior part of nasal septum and anterior end of inferior turbinate. Initially, there is excessive nasal discharge with red and swollen mucosa. Later, crusting and bleeding supervene. Nodular lesions on the septum may ulcerate and cause perforation. Late sequelae of disease are atrophic rhinitis, depression of bridge of nose, destruction of anterior nasal spine with retrusion of the columella (Fig. 28.2).

Diagnosis can be made from the scrapings of nasal mucosa and biopsy. Acid-fast lepra bacilli can be seen in the foamy appearing histiocytes called lepra cells.

Treatment is with dapson, rifampin and isoniazid. Reconstruction procedures are required when disease is inactive.

page 173

page 174



Dhingra: Diseases of Ear Nose and Throat, 5th Edition  
Copyright © 2010 Elsevier. All rights reserved.

Figure 28.2 Leprosy nose.

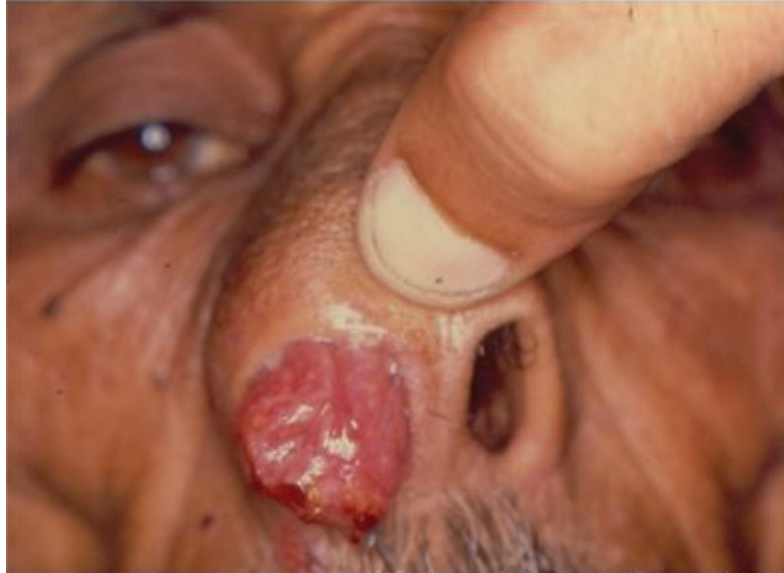## FUNGAL INFECTIONS

### Rhinosporidiosis (Fig. 28.3)

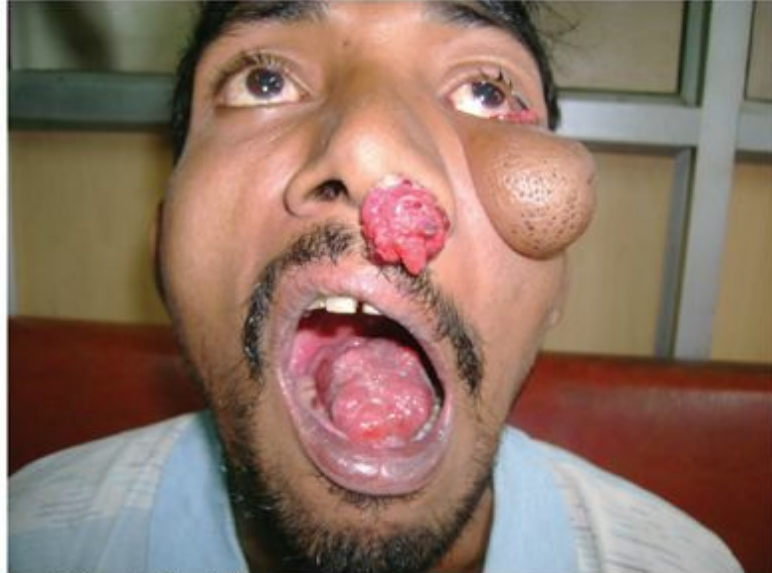It is a fungal granuloma caused by *Rhinosporidium seeberi*. It is seen in India, Pakistan and Sri Lanka. In India, most of the cases are seen in southern states though several cases have also been reported from other parts of the country.

*Clinical features.* The disease mostly affects nose and nasopharynx; other sites such as lip, palate, conjunctiva, epiglottis, larynx, trachea, bronchi, skin, vulva, vagina may also be affected.

**A**



**B**



Dhingra: Diseases of Ear Nose and Throat, 5th Edition  
Copyright © 2010 Elsevier. All rights reserved.

Figure 28.3 Rhinosporidiosis presenting as (A) a polypoidal mass protruding through the naris, (B) multiple sites of involvement, viz. nose, conjunctiva and tongue.

The disease is acquired through contaminated water of ponds also frequented by animals. In the nose, the disease presents as a leafy, polypoidal mass, pink to purple in colour and attached to nasal septum or lateral wall. Sometimes, it extends into the nasopharynx and may hang behind the soft palate. The mass is very vascular and bleeds easily on touch. Its surface is studded with white dots representing the sporangia of fungus.

In early stages, the patient may complain of nasal discharge which is often blood-tinged, or nasal stuffiness. Sometimes, frank epistaxis is the only presenting complaint.

*Diagnosis* is made on biopsy. It shows several sporangia, oval or round in shape and filled with spores which may be seen bursting through its chitinous wall. It has not been possible to culture the organism or transfer the disease to experimental animals.

*Treatment* is complete excision of the mass with diathermy knife and cauterisation of its base. Recurrence may occur after surgical excision. Not many drugs are effective against the disease. Dapsone has been tried with some success.

# Aspergillosis

The usual causative organisms are *Aspergillus niger*, *A. fumigatus* or *A. flavus*. They invade nasal tissues when host's defence mechanisms are compromised due to immunosuppressive drugs.

*Clinical features* are those of acute or subacute rhinitis or sinusitis. A black or greyish membrane is seen in the nasal mucosa. Exploration of maxillary sinus reveals a fungus ball containing semisolid cheesy-white or blackish material. The organisms can be seen on special staining.

*Treatment* is surgical debridement of the involved tissues and antifungal drugs, e.g. Amphotericin-B. Repeated irrigation of the involved area with application of 1% solution of gentian violet is also useful.

# Mucormycosis

It is fungal infection of nose and paranasal sinuses which may prove rapidly fatal. It is seen in uncontrolled diabetics or in those taking immunosuppressive drugs. From the nose and sinuses, infection can spread to orbit, cribriform plate, meninges and brain. The rapid destruction associated with the disease is due to affinity of the fungus to invade the arteries and cause endothelial damage and thrombosis. Typical finding is the presence of a black necrotic mass filling the nasal cavity and eroding the septum and hard palate. Special stains help to identify the fungus in tissue sections.

Treatment is by amphotericin-B and surgical debridement of the affected tissues and control of underlying predisposing cause.

## Other Fungal Infections

Other fungal infections of nose such as *candidiasis*, *histoplasmosis*, *blastomycosis*, etc. are rare.



# GRANULOMAS OF UNSPECIFIED AETIOLOGY

## Wegener's Granulomatosis

### Aetiology

It is a systemic disorder of unknown aetiology involving mainly the upper airways, lungs, kidneys and the skin. It should be differentiated from non-healing midline granuloma because the treatment of the two is quite different.

### Clinical Features

Early symptoms of Wegener's granulomatosis include clear or blood-stained nasal discharge which later becomes purulent. The patient often complains of "persistent cold" or "sinus". Nasal findings include crusting, granulations, septal perforation and a saddle nose. Destruction may also involve eyes, orbit, palate, oral cavity or oropharynx. Middle ear can also be involved.

General systemic symptoms include anaemia, fatigue, night sweats and migratory arthralgias.

Involvement of lung is manifested by cough and sometimes haemoptysis. X-ray chest may show a single or multiple cavity lesions.

Sooner or later, kidneys are also involved. Urine examination will show red cells, casts and albumin. Serum creatinine level is raised. Renal failure is the usual cause of death in these patients.

### Diagnosis

Biopsy from the nose is diagnostic. It shows necrosis and ulceration of mucosa, epithelioid granuloma and necrotising vasculitis involving small arteries or veins. ESR is raised.

### Treatment

It consists of systemic steroids and cytotoxic drugs. Cyclophosphamide and azathioprine, both are found effective.

## T-cell Lymphoma

Earlier terms used to describe this lesion were midline malignant lesion and polymorphic reticulosis.

It is a destructive lesion usually starting on one side of nose involving the upper lip, oral cavity maxilla and sometimes even extending to orbit. Histologically polymorphic lymphoid tissue with angiocentric and angioinvasive features is seen. There is no vasculitis-a feature typical of Wegener's granulomatosis. Unlike Wegener's granulomatosis, it is rapidly destructive and usually devoid of systemic involvement; there is absence of involvement of lung and kidneys. Immunohistochemical studies of biopsy material are necessary to establish diagnosis of T-cell lymphoma. Localised T-cell lymphoma is treated by radiation while a disseminated disease requires chemotherapy.

# Sarcoidosis

It is granulomatous disease of unknown aetiology resembling tuberculosis on history but with the absence of caseation. It is a systemic disorder and the symptoms may refer to involvement of lungs, lymph nodes, eyes or skin.

In the nose, it presents with submucosal nodules involving septum or the inferior turbinate with nasal obstruction, nasal pain and sometimes epistaxis. Nodules may also form in the nasal vestibule or skin of face.

X-ray chest shows diffuse pulmonary infiltrate with hilar adenopathy. Serum and urinary calcium levels are raised. Biopsy of the lesions helps to establish the diagnosis.

Treatment is with systemic steroids. For nasal symptoms, steroids can be used locally as nasal spray.

## 29 Miscellaneous Disorders of Nasal Cavity

### FOREIGN BODIES

#### ***Aetiology***

They are mostly seen in children and may be organic or inorganic. Pieces of paper, chalk, button, pebbles and seeds are the common objects. Pledgets of cotton or swabs may be accidentally left in the nose.

#### ***Clinical features***

Patient may present immediately if the history of foreign body is known. If overlooked, the child presents with unilateral nasal discharge which is often foul-smelling and occasionally blood-stained. It is a dictum that "*If a child presents with unilateral, foul-smelling nasal discharge, foreign body must be excluded.*" Occasionally, a radiograph of the nose is useful to confirm and localise a foreign body if it is radio-opaque. In addition to overlooked foreign body in the nose, other important causes for unilateral blood stained discharge in a child are rhinolith, nasal diphtheria, nasal myiasis and acute or chronic unilateral sinusitis.

#### ***Treatment***

Pieces of paper or cotton swabs can be easily removed with a pair of forceps. Rounded foreign bodies can be removed by passing a blunt hook (a eustachian catheter is a good instrument) past the foreign body and gently dragging it forward along the floor. In babies and uncooperative children, general anaesthesia with cuffed endotracheal tube is used. Patient is placed in Rose's position, a pack is inserted into the nasopharynx and the foreign body retrieved with a forceps or a hook. Foreign bodies lodged far behind in the nose may need to be pushed into the nasopharynx before removal.

#### ***Complications***

A foreign body left in the nose may result in:

- (i) nasal infection and sinusitis.
- (ii) rhinolith formation.
- (iii) inhalation into the tracheobronchial tree.

# RHINOLITH

## ***Aetiology***

It is stone formation in the nasal cavity. A rhinolith usually forms around the nucleus of a small exogenous foreign body, blood clot or inspissated secretion by slow deposition of calcium and magnesium salts. Over a period of time, it grows into a large, irregular mass which fills the nasal cavity and then may cause pressure necrosis of the septum and/or lateral wall of nose.

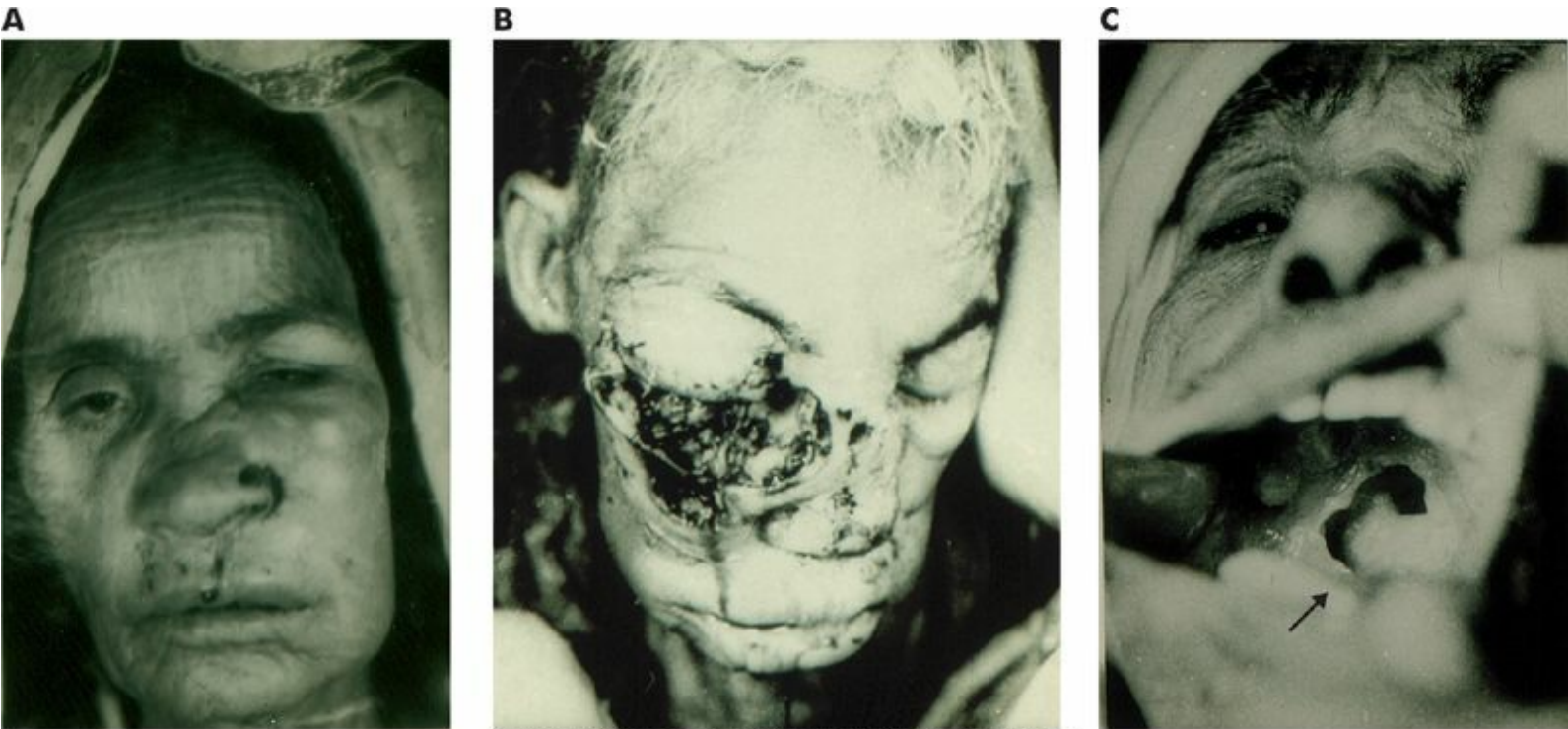
## ***Clinical features***

Rhinoliths are more common in adults. Its common presentation is unilateral nasal obstruction and foul-smelling discharge which is very often blood-stained. Frank epistaxis and neuralgic pain may result from ulceration of the surrounding mucosa.

On examination, a grey brown or greenish-black mass with irregular surface and stony hard feel is seen in the nasal cavity between the septum and turbinates. It is often brittle and a portion of it may break off while manipulating. Sometimes it is surrounded by granulations.

## ***Treatment***

They are removed under general anaesthesia. Most of them can be removed through anterior nares. Large ones need to be broken into pieces before removal. Some particularly hard and irregular ones, require lateral rhinotomy.



Dhingra: Diseases of Ear Nose and Throat, 5th Edition  
Copyright © 2010 Elsevier. All rights reserved.

Figure 29.1 Maggots nose. (A) Swelling of nose and puffy eyelids with serosanguinous nasal discharge. (B) Maggots have practically destroyed the cheek and eye in this old and neglected lady. (C) Perforation of palate (arrow).

**A****B**

Dhingra: Diseases of Ear Nose and Throat, 5th Edition  
Copyright © 2010 Elsevier. All rights reserved.

Figure 29.2 (A) The maggot. (B) The fly responsible for maggots.

Maggots are larval forms of flies. They are seen to infest nose, nasopharynx and paranasal sinuses causing extensive destruction (Figs 29.1 A,B,C and 29.2). Flies, particularly of the genus *Chrysomyia*, are attracted by the foul smelling discharge emanating from cases of atrophic rhinitis, syphilis, leprosy or infected wounds and lay eggs, about 200 at a time, which within 24 hours hatch into larvae. In our country, they are mostly seen from the month of August to October.

### **Clinical features**

In the first 3 or 4 days maggots produce intense irritation, sneezing, lacrimation and headache. Thin blood-stained discharge oozes from the nostrils. The eyelids and lips become puffy. Till this time patient is not aware of maggots. He may present simply as a case of epistaxis. It is only on the 3rd or 4th day that the maggots may crawl out of the nose. Patient has foul smell surrounding him. Maggots cause extensive destruction to nose, sinuses, soft tissue of face, palate and the eyeball. Fistulae may form in the palate or around the nose. Death may occur from meningitis.

### **Treatment**

All visible maggots should be picked up with forceps. Many of them try to retreat into darker cavities when light falls on them. Instillation of chloroform water and oil kills them. Nasal douche with warm saline is used to remove slough, crusts and dead maggots. A patient with maggots should be isolated with a mosquito net to avoid contact with flies which can perpetuate this cycle. All patients should receive instruction for nasal hygiene before leaving the hospital.

## **NASAL SYNECHIA**

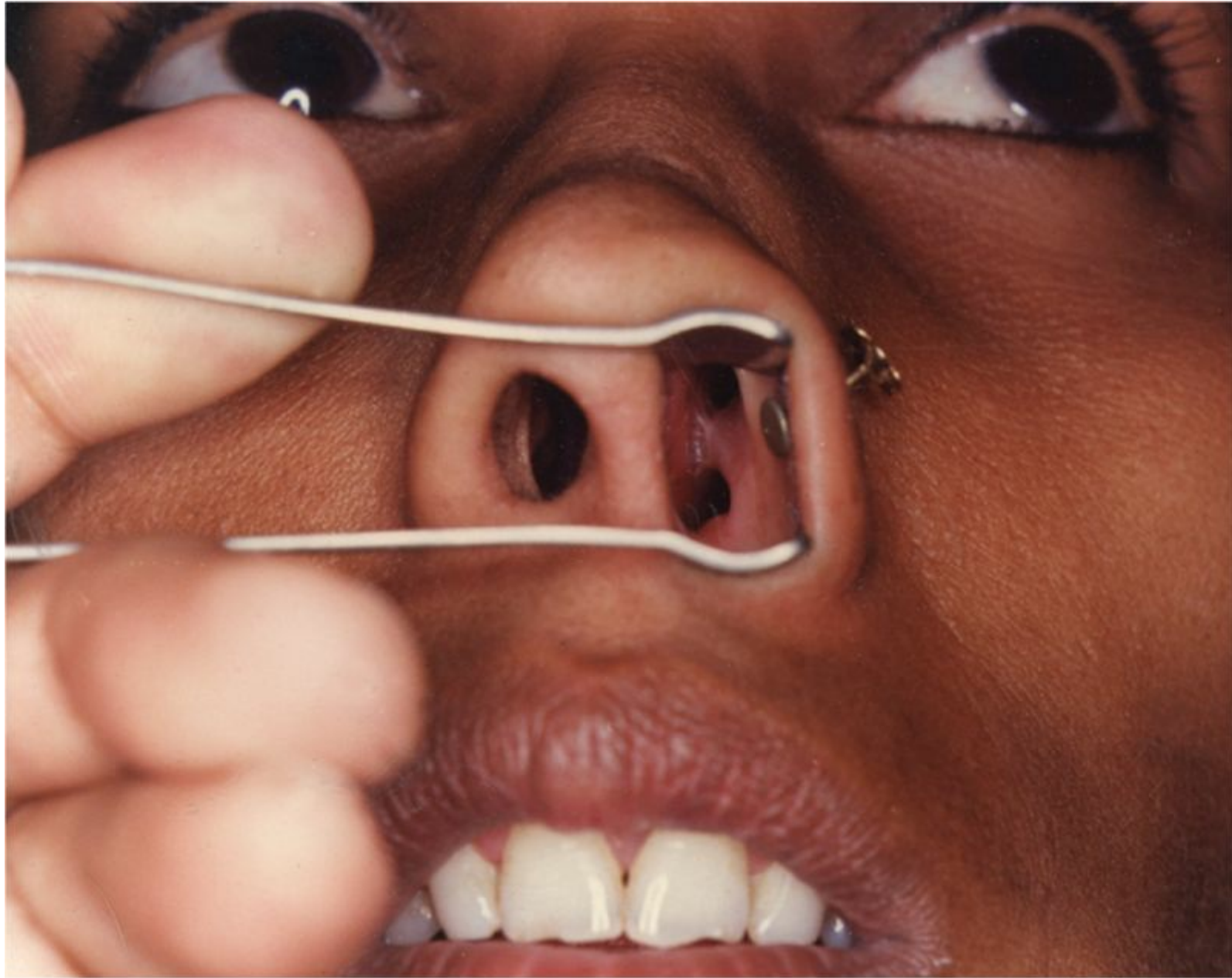
Adhesion formation between the nasal septum and turbinates by scar tissue is often the result of injury to opposing surfaces of nasal mucosa. It can result from intranasal operations such as septal surgery, polypectomy, removal of foreign bodies, reduction of nasal fractures or even intranasal packing. Severe infections which cause ulcerative lesions in the nose can also lead to synechia formation.

Nasal synechia (Fig. 29.3) often cause nasal obstruction or may impede drainage from the sinuses resulting in sinusitis, headache and nasal discharge.

Treatment is removal of synechia and prevention of the opposing raw surfaces to come into contact with each other by placing a thin silastic or a cellophane sheet between them. This is changed every two or three days till healing is complete.



## CHOANAL ATRESIA



Dhingra: Diseases of Ear Nose and Throat, 5th Edition  
Copyright © 2010 Elsevier. All rights reserved.

Figure 29.3 Nasal synechia left.

It is due to persistence of bucconasal membrane, and may be unilateral or bilateral, complete or incomplete, bony (90%) or membranous (10%). Unilateral atresia is more common and may remain undiagnosed until adult life. Bilateral atresia presents with respiratory obstruction as the newborn, being a natural nose-breather, does not breathe from mouth. Diagnosis of choanal atresia can be made by (i) presence of mucoid discharge in the nose, (ii) absence of air bubbles in the nasal discharge, (iii) failure to pass a catheter from nose to pharynx, (iv) putting a few drops of a dye (methylene-blue) into the nose and seeing its passage into the pharynx, or (v) installing radio-opaque dye into the nose and taking a lateral film.

Emergency management may be required in bilateral choanal atresia to provide an airway. A feeding nipple with a large hole provides a good oral airway (McGovern's technique) and obviates the need for tracheostomy. Definitive treatment consists of correction of atresia by transnasal or transpalatal approach. The latter is usually done at one and a half years. Choanal atresia can be corrected by using nasal endoscopes and drill.

# CSF RHINORRHOEA

CSF rhinorrhoea presents as flow of clear fluid from the nose.

## Aetiology

- **(i) Traumatic:** Head injuries, surgery of frontal, ethmoid or sphenoid sinus or hypophysectomy. It may follow as a complication of endoscopic sinus surgery. It may be immediate or delayed in onset.
- **(ii) Tumours:** Large osteomas of frontoethmoid region, tumours of the pituitary or the olfactory bulb.
- **(iii) Congenital defects** in skull associated with encephalocele.
- **(iv) Spontaneous type.**

## Sites of leakage

CSF from anterior cranial fossa reaches the nose by way of cribriform plate, ethmoid air cells or frontal sinus. CSF from middle cranial fossa reaches the nose via sphenoid sinus. Sometimes, injuries of temporal bone result in leakage of CSF into the middle ear and thence via the eustachian tube into the nose (otorhinorrhoea).

## Diagnosis

page 178

page 179

**Table 29-1. Differences between CSF and nasal secretions**

Features	CSF fluid	Nasal secretion
History	Nasal or sinus surgery, head injury or intracranial tumour	Sneezing, nasal stuffiness, itching in the nose or lacrimation
Flow of discharge	A few drops or a stream of fluid gushes down when bending forward or straining; cannot be sniffed back	Continuous, No effect of bending forward or straining. Can be sniffed back
Character of discharge	Thin, watery and clear	Slimy (mucus) or clear (tears)
Taste	Sweet	Salty
Sugar content	More than 30 mg/dl (Compare with sugar in CSF after lumbar puncture as sugar is less in CSF in meningitis)	Less than 10 mg/dl
Presence of $\beta_2$ transferrin	Always present. It is specific for CSF	Always absent

There is history of dribbling of clear fluid from the nose on bending or straining. CSF rhinorrhoea should be differentiated from nasal discharge of allergic or vasomotor rhinitis. Discharge in CSF rhinorrhoea is clear and watery, appears suddenly in a gush of drops when bending forward or straining, is uncontrollable and cannot be sniffed back. There is no associated sneezing, nasal congestion or lacrimation. When collected into a test-tube and allowed to stand, it remains clear in contradistinction to nasal discharge that leaves a sediment because of mucus and other proteins. This is also the reason that a nasal discharge stiffens the handkerchief. CSF contains glucose which can be demonstrated by oxidase-peroxidase paper strip or biochemical tests.  $\beta_2$  transferrin is specific for CSF. It is absent in nasal secretions or tears. Its presence confirms the diagnosis of CSF leak. (see Table 29.1 for differences between CSF rhinorrhoea and nasal discharge).

## Localisation of CSF leak

It is done by intrathecal injection of a dye (fluorescein 5%, 1 ml) or a radioisotope and placing pledgets of cotton in the olfactory slit, middle meatus, sphenoidal recess and near the eustachian tube and examining the pledgets for dye or radioactivity.

Olfactory slit	→	Cribriform plate
Middle meatus	→	Frontal or ethmoid sinuses
Sphenoethmoidal recess	→	Sphenoid sinus
Inferior meatus near the eustachian tube	→	Temporal bone

Site of leak can be determined by high resolution, thin section coronal cuts with bone window. It can show the area of bony defect. However, if this fails to localise the defect, a CT cisternogram is advised. In this procedure, CT scan is combined with injection of a contrast material into intrathecal space via cisterna magna. These days, a noninvasive, non-ionising technique of MRI with  $T_2$ -weighted images or MRI cisternography is more useful.

In suspected cases of otorhinorrhoea, always examine the ear for the presence of fluid and conductive hearing loss.

In traumatic CSF leak, when CSF and blood are mixed, *double ring sign* (or target sign) is helpful. In this sign, discharge collected on a piece of

filter paper shows a central spot of blood while CSF spreads out like a halo around it.

### ***Treatment***

Early cases of post-traumatic CSF rhinorrhoea are managed conservatively by placing the patient in the semi-sitting position, avoiding blowing of nose, sneezing and straining. Prophylactic antibiotics are also administered to prevent meningitis.

Persistent cases of CSF rhinorrhoea are treated surgically by nasal endoscopic or intracranial approach. Nasal endoscopic approach is useful for leaks from the frontal sinus, cribriform plate, ethmoid or sphenoid sinuses.

## 30 Allergic Rhinitis

It is an IgE-mediated immunologic response of nasal mucosa to air-borne allergens and is characterised by watery nasal discharge, nasal obstruction, sneezing and itching in the nose. This may also be associated with symptoms of itching in the eyes, palate and pharynx. Two clinical types have been recognised:

- **1. Seasonal** Symptoms appear in or around a particular season when the pollens of particular plant, to which the patient is sensitive, are present in the air.
- **2. Perennial** Symptoms are present throughout the year.

## Aetiology

*Inhalant allergens* are often the cause. Pollen from the trees and grasses, mould spores, house dust, debris from insects or house mite are common offenders. Food allergy is rarely an important cause.

*Genetic predisposition* plays an important part. Chances of children developing allergy are 20% and 47% respectively, if one or both parents suffer from allergic diathesis.

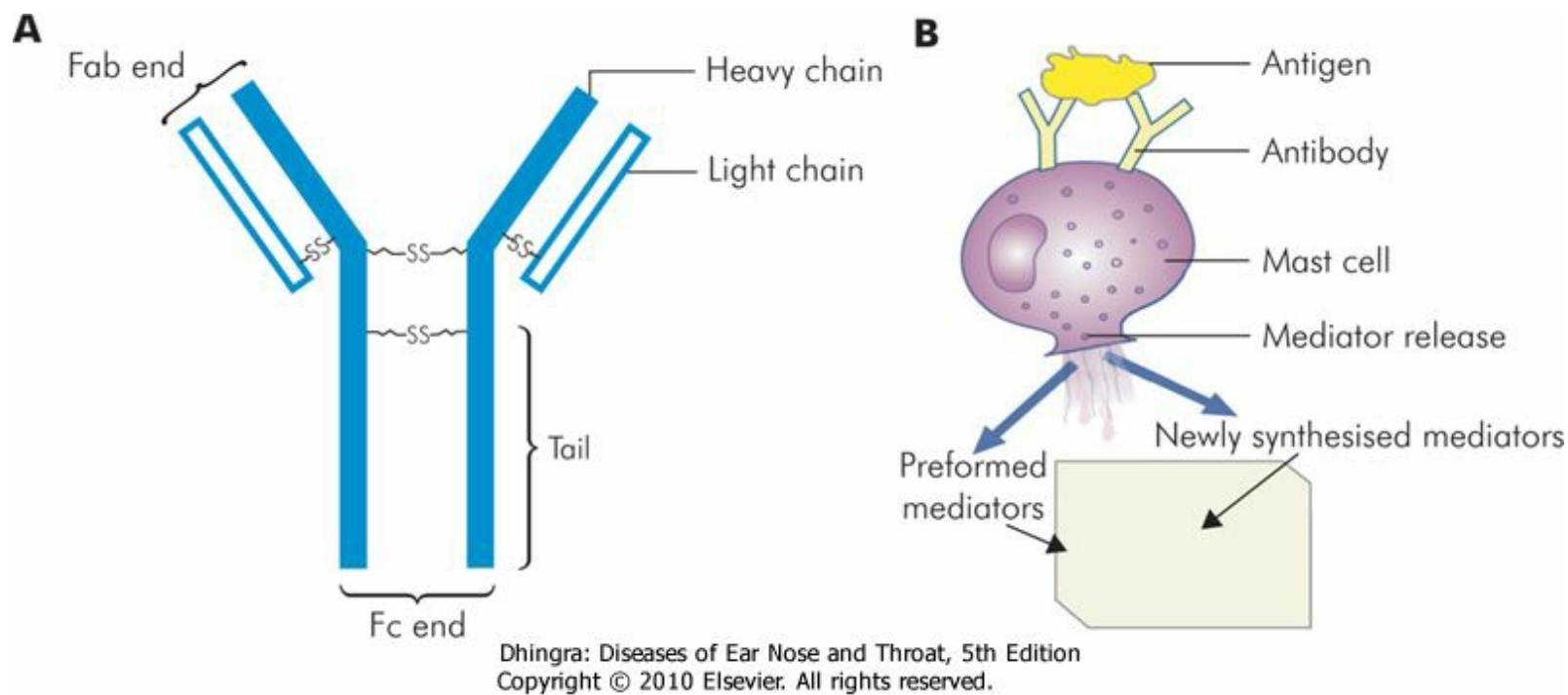


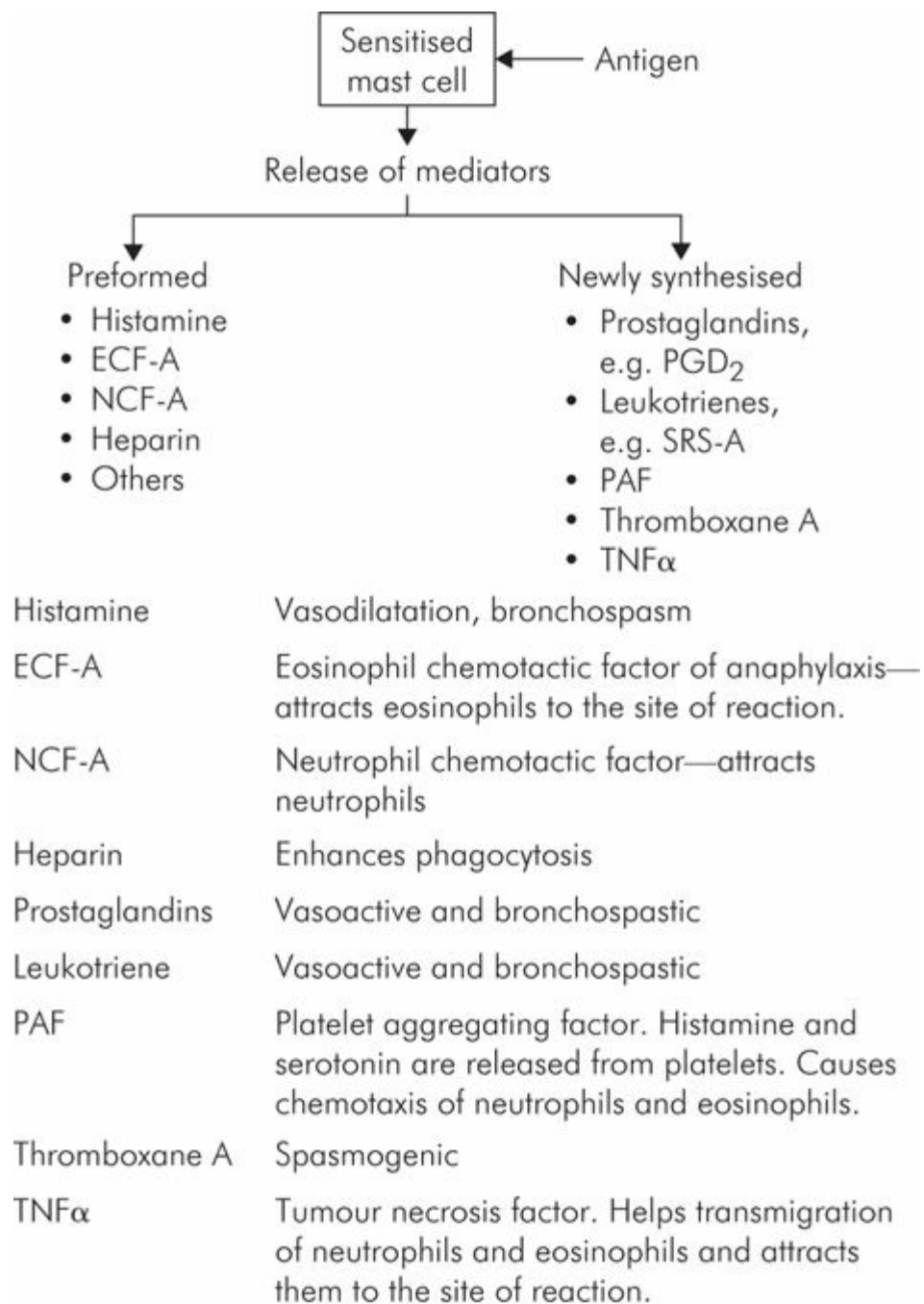
Figure 30.1 (A) Structure of IgE antibody . Fc end is attached to the mast cell or blood basophil while Fab end is the antigen binding site. (B) Release of mediator substances from mast cell producing symptoms of nasal allergy .

page 180

page 181

Inhaled allergens produce specific IgE antibody in the genetically predisposed individuals. This antibody becomes fixed to the blood basophils or tissue mast cells by its Fc end (Fig. 30.1). On subsequent exposure, antigen combines with IgE antibody at its Fab end. This reaction produces degranulation of the mast cells with release of several chemical mediators, some of which already exist in preformed state while others are synthesised afresh. These mediators (Fig. 30.2) are responsible for symptomatology of allergic disease. Depending on the tissues involved, there may be vasodilation, mucosal oedema, infiltration with eosinophils, excessive secretion from nasal glands or smooth muscle contraction. A "priming affect" has also been described, i.e. mucosa earlier sensitised to an allergen will react to smaller doses of subsequent specific allergen. It also gets "primed" to other non-specific antigens to which patient was not exposed (Fig. 30.3). Clinically, allergic response occurs in 2 phases:

- **(a) Acute or early phase** It occurs immediately within 5-30 min, after exposure to the specific allergen and consists of sneezing, rhinorrhoea nasal blockage and/or bronchospasm. It is due to release of vasoactive amines like histamine.
- **(b) Late or delayed phase** It occurs 2-8 hours after exposure to allergen without additional exposure. It is due to infiltration of inflammatory cells-eosinophils, neutrophils, basophil, monocytes and CD<sub>4</sub> + T cells at the site of antigen deposition causing swelling, congestion, thick secretion. In the event of repeated or continuous exposure to allergen, acute phase symptomatology overlaps the late phase.



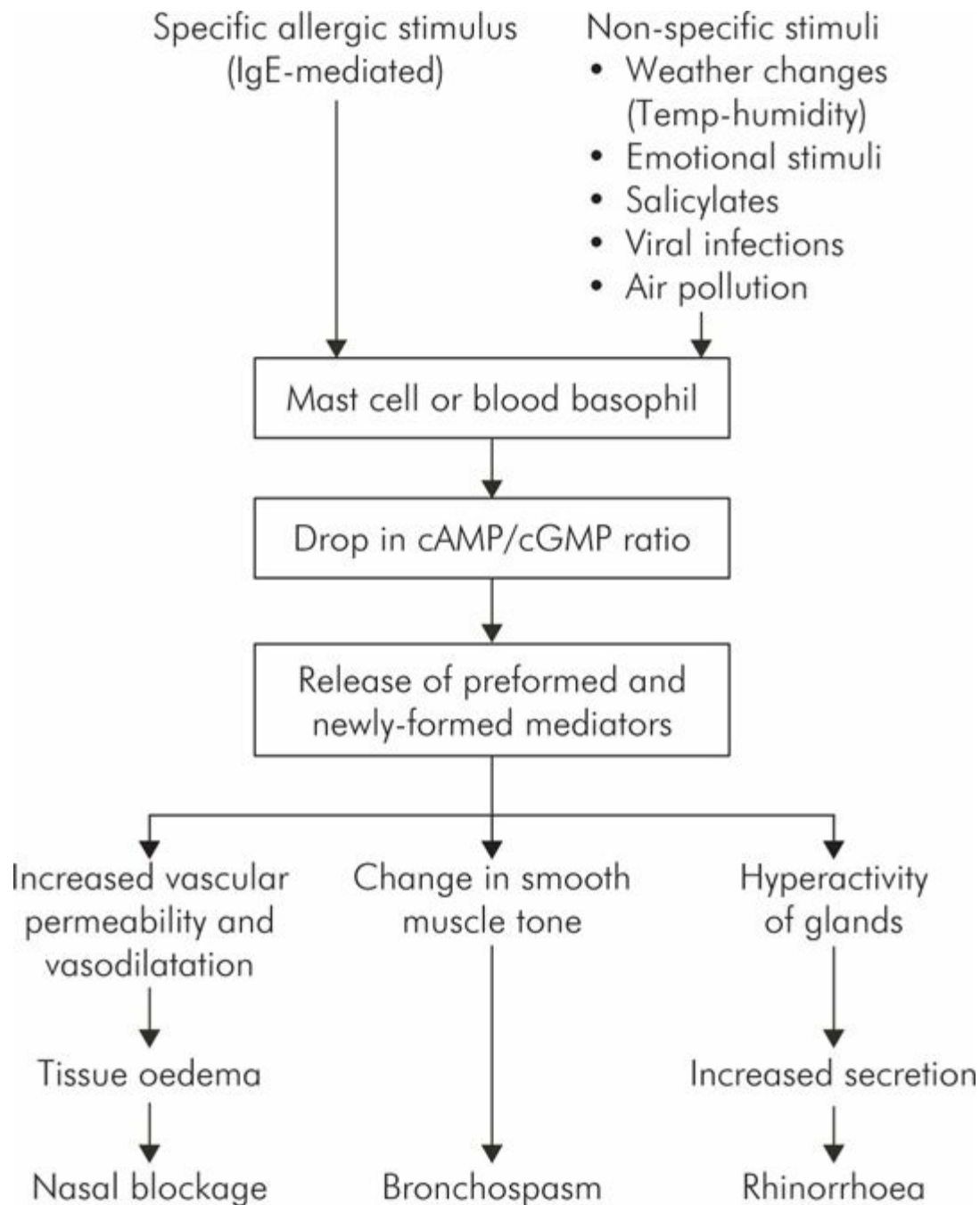
Dhingra: Diseases of Ear Nose and Throat, 5th Edition  
 Copyright © 2010 Elsevier. All rights reserved.

Figure 30.2 Release of mediators from mast cell when challenged by allergic or non-specific stimuli.

## Clinical Features

There is no age or sex predilection. It may start in infants as young as 6 months or older people. Usually the onset is at 12-16 years of age.

The cardinal *symptoms of seasonal nasal allergy* include paroxysmal sneezing, 10-20 sneezes at a time, nasal obstruction, watery nasal discharge and itching in the nose. Itching may also involve eyes, palate or pharynx. Some may get bronchospasm. The duration and severity of symptoms may vary with the season.



Dhingra: Diseases of Ear Nose and Throat, 5th Edition  
Copyright © 2010 Elsevier. All rights reserved.

Figure 30.3 Both allergic and non-specific stimuli act on mast cells or blood basophils releasing several mediator substances responsible for symptomatology of allergy.

*Symptoms of perennial allergy* are not so severe as that of the seasonal type. They include frequent colds, persistently stuffy nose, loss of sense of smell due to mucosal oedema, postnasal drip, chronic cough and hearing impairment due to eustachian tube blockage or fluid in the middle ear.

Signs of allergy may be seen in the nose, eyes, ears, pharynx or larynx.

*Nasal signs* include transverse nasal crease—a black line across the middle of dorsum of nose due to constant upward rubbing of nose simulating a salute (allergic salute), pale and oedematous nasal mucosa which may appear bluish. Turbinates are swollen. Thin, watery or mucoid discharge is usually present.



*Ocular signs* include oedema of lids, congestion and cobble-stone appearance of the conjunctiva, dark circles under the eyes (allergic shiners).

*Otologic signs* include retracted tympanic membrane or serous otitis media as a result of eustachian tube blockage.

*Pharyngeal signs* include granular pharyngitis due to hyperplasia of submucosal lymphoid tissue. A child with perennial allergic rhinitis may show all the features of prolonged mouth breathing as seen in adenoid hyperplasia.

*Laryngeal signs* include hoarseness of voice and oedema of the vocal cords.

## Diagnosis

A detailed history and physical examination is helpful, and also gives clues to the possible allergen. Other causes of nasal stuffiness should be excluded.

# Investigations

- **1. Total and differential count.** Peripheral eosinophilia may be seen but is an inconsistent finding.
- **2. Nasal smear** shows large number of eosinophils in allergic rhinitis. Nasal smear should be taken at the time of clinically active disease or after nasal challenge test. Nasal eosinophilia is also seen in certain non-allergic rhinitis, e.g. NARES (non-allergic rhinitis with eosinophilia syndrome).
- **3. Skin tests** help to identify specific allergen. They are prick, scratch and intradermal tests.
- **4. Radioallergosorbent test (RAST)** is an in vitro test and measures specific IgE antibody concentration in the patient's serum.
- **5. Nasal provocation test.** A crude method is to challenge the nasal mucosa with a small amount of allergen placed at the end of a toothpick and asking the patient to sniff into each nostril and to observe if allergic symptoms are reproduced. More sophisticated techniques are available now.

# Complications

Nasal allergy may cause:

- 1. Recurrent sinusitis because of obstruction to the sinus ostia.
- 2. Nasal polypi.
- 3. Serous otitis media.
- 4. Orthodontic problems and other ill-effects of prolonged mouth breathing especially in children.
- 5. Bronchial asthma. Patients of nasal allergy have four times more risk of developing bronchial asthma.

# Treatment

Treatment can be divided into:

- 1. Avoidance of allergen
- 2. Treatment with drugs
- 3. Immunotherapy

## **1. Avoidance of allergen**

This is most successful if the antigen involved is single. Removal of a pet from the house, encasing the pillow or mattress with plastic sheet, change of place of work or sometimes change of job may be required. A particular food article to which the patient is found allergic can be eliminated from the diet.

## **2. Treatment with drugs**

(a) *Antihistaminics*. They control rhinorrhoea, sneezing and pruritis. All antihistaminics have the side effect of drowsiness; some more than the other. The dose and type of the antihistaminic has to be individualised. If one antihistaminic is not effective, another may be tried from a different class.

(b) *Sympathomimetic drugs (oral or topical)*. Alpha-adrenergic drugs constrict blood vessels and reduce nasal congestion and oedema. They also cause CNS stimulation and are often given in combination with antihistaminics to counteract drowsiness. Pseudoephedrine and phenylpropanolamine are often combined with antihistaminics for oral administration.

Topical use of sympathomimetic drugs cause nasal decongestion. Phenylephrine, oxymetazoline and xylometazoline are often used to relieve nasal obstruction, but are notorious to cause severe rebound congestion. Patient resorts to using more and more of them to relieve nasal obstruction. This vicious cycle leads to rhinitis medicamentosa.

(c) *Corticosteroids*. Oral corticosteroids are very effective in controlling the symptoms of allergic rhinitis but their use should be limited to acute episodes which have not been controlled by other measures. They have several systemic side effects.

Topical steroids such as beclomethasone dipropionate, budesonide, flunisolide acetate, fluticasone and mometasone inhibit recruitment of inflammatory cells into the nasal mucosa and suppress late-phase allergic reaction, are used as aerosols and are very effective in the control of symptoms. They have also been used in rhinitis medicamentosa while withdrawing topical use of decongestant nasal drops. Topical steroids have fewer systemic side effects but their continuous use may cause mucosal atrophy and even septal perforation. It is wise to break their use for 1-2 weeks every 2-3 months. They may also promote growth of fungus.

(d) *Sodium cromoglycate*. It stabilises the mast cells and prevents them from degranulation despite the formation of IgE-antigen complex. It is used as 2% solution for nasal drops or spray or as an aerosol powder. It is useful both in seasonal and perennial allergic rhinitis.

## **3. Immunotherapy**

Immunotherapy or hyposensitisation is used when drug treatment fails to control symptoms or produces intolerable side effects. Allergen is given in gradually increasing doses till the maintenance dose is reached. Immunotherapy suppresses the formation of IgE. It also raises the titre of specific IgG antibody. Immunotherapy has to be given for a year or so before significant improvement of symptoms can be noticed. It is discontinued if uninterrupted treatment for 3 years shows no clinical improvement.

## 31 Vasomotor and Other Forms of Non-allergic Rhinitis

### Vasomotor Rhinitis (VMR)

It is non-allergic rhinitis but clinically simulating nasal allergy with symptoms of nasal obstruction, rhinorrhoea and sneezing. One or the other of these symptoms may predominate. The condition usually persists throughout the year and all the tests of nasal allergy are negative.

#### Pathogenesis

Nasal mucosa has rich blood supply. Its vasculature is similar to the erectile tissue in having venous sinusoids or "lakes" which are surrounded by fibres of smooth muscle which act as sphincters and control the filling or emptying of these sinusoids. Sympathetic stimulation causes vasoconstriction and shrinkage of mucosa, while parasympathetic stimulation causes vasodilation and engorgement. Overactivity of parasympathetic system also causes excessive secretion from the nasal glands.

Autonomic nervous system is under the control of hypothalamus and therefore emotions play a great role in vasomotor rhinitis. Autonomic system is unstable in cases of vasomotor rhinitis. Nasal mucosa is also hyperreactive and responds to several non-specific stimuli, e.g. change in temperature, humidity, blasts of air, small amounts of dust or smoke.

#### Symptoms

- **1. Paroxysmal sneezing** Bouts of sneezing start just after getting out of the bed in the morning.
- **2. Excessive rhinorrhoea** This accompanies sneezing or this may be the only predominant symptom. It is profuse and watery and may even wet several handkerchiefs. The nose may drip when the patient leans forward, and this may need to be differentiated from CSF rhinorrhoea (see page 178).
- **3. Nasal obstruction** This alternates from side to side. Usually more marked at night. It is the dependent side of nose which is often blocked when lying on one side.
- **4.** Postnasal drip.

#### Signs

Nasal mucosa over the turbinates is generally congested and hypertrophic. In some, it may be normal.

#### Complications

Long-standing cases of VMR develop nasal polypi, hypertrophic rhinitis and sinusitis.

#### Treatment

##### Medical

- **1.** Avoidance of physical factors which provoke symptoms, e.g. sudden change in temperature, humidity, blasts of air or dust.
- **2.** Antihistaminics and oral nasal decongestants are helpful in relieving nasal obstruction, sneezing and rhinorrhoea.
- **3.** Topical steroids (e.g. beclomethasone dipropionate, budesonide or fluticasone), used as spray or aerosol, are useful to control symptoms.
- **4.** Systemic steroids can be given for a short time in very severe cases.
- **5.** Psychological factors should be removed. Tranquillizers may be needed in some patients.

##### Surgical

- **1.** Nasal obstruction can be relieved by measures which reduce the size of nasal turbinates (see hypertrophic rhinitis). Other associated causes of nasal obstruction, e.g. polyp, deviated nasal septum, should also be corrected.
- **2.** Excessive rhinorrhoea, not corrected by medical therapy and bothersome to the patient, can be relieved by sectioning the parasympathetic secretomotor fibres to nose (vidian neurectomy).

# Vasomotor Rhinitis (VMR)

It is non-allergic rhinitis but clinically simulating nasal allergy with symptoms of nasal obstruction, rhinorrhoea and sneezing. One or the other of these symptoms may predominate. The condition usually persists throughout the year and all the tests of nasal allergy are negative.

## Pathogenesis

Nasal mucosa has rich blood supply. Its vasculature is similar to the erectile tissue in having venous sinusoids or "lakes" which are surrounded by fibres of smooth muscle which act as sphincters and control the filling or emptying of these sinusoids. Sympathetic stimulation causes vasoconstriction and shrinkage of mucosa, while parasympathetic stimulation causes vasodilation and engorgement. Overactivity of parasympathetic system also causes excessive secretion from the nasal glands.

Autonomic nervous system is under the control of hypothalamus and therefore emotions play a great role in vasomotor rhinitis. Autonomic system is unstable in cases of vasomotor rhinitis. Nasal mucosa is also hyperreactive and responds to several non-specific stimuli, e.g. change in temperature, humidity, blasts of air, small amounts of dust or smoke.

## Symptoms

- **1. Paroxysmal sneezing** Bouts of sneezing start just after getting out of the bed in the morning.
- **2. Excessive rhinorrhoea** This accompanies sneezing or this may be the only predominant symptom. It is profuse and watery and may even wet several handkerchiefs. The nose may drip when the patient leans forward, and this may need to be differentiated from CSF rhinorrhoea (see page 178).
- **3. Nasal obstruction** This alternates from side to side. Usually more marked at night. It is the dependent side of nose which is often blocked when lying on one side.
- **4.** Postnasal drip.

## Signs

Nasal mucosa over the turbinates is generally congested and hypertrophic. In some, it may be normal.

## Complications

Long-standing cases of VMR develop nasal polypi, hypertrophic rhinitis and sinusitis.

## Treatment

### Medical

- **1.** Avoidance of physical factors which provoke symptoms, e.g. sudden change in temperature, humidity, blasts of air or dust.
- **2.** Antihistaminics and oral nasal decongestants are helpful in relieving nasal obstruction, sneezing and rhinorrhoea.
- **3.** Topical steroids (e.g. beclomethasone dipropionate, budesonide or fluticasone), used as spray or aerosol, are useful to control symptoms.
- **4.** Systemic steroids can be given for a short time in very severe cases.
- **5.** Psychological factors should be removed. Tranquillizers may be needed in some patients.

### Surgical

- **1.** Nasal obstruction can be relieved by measures which reduce the size of nasal turbinates (see hypertrophic rhinitis). Other associated causes of nasal obstruction, e.g. polyp, deviated nasal septum, should also be corrected.
- **2.** Excessive rhinorrhoea, not corrected by medical therapy and bothersome to the patient, can be relieved by sectioning the parasympathetic secretomotor fibres to nose (vidian neurectomy).

# Other Forms of Non-allergic Rhinitis

Nasal mucosa responds to several different stimuli producing symptoms of rhinitis. Some of these conditions have acquired specific eponyms. Some authorities categorise them under the catch-all term of vasomotor rhinitis.

page 183

page 184

## **1. Drug-induced rhinitis**

Several antihypertensive drugs such as reserpine, guanethidine, methyl dopa and propranolol are sympathetic blocking agents and cause nasal stuffiness. Some anticholinesterase drugs, e.g. neostigmine, used in the treatment of myasthenia gravis, have acetylcholine like action and cause nasal obstruction. Contraceptive pills also cause nasal obstruction because of oestrogens.

## **2. Rhinitis medicamentosa**

Topical decongestant nasal drops are notorious to cause rebound phenomenon. Their excessive use causes rhinitis. It is treated by withdrawal of nasal drops, short course of systemic steroid therapy and in some cases, surgical reduction of turbinates, if they have become hypertrophied.

## **3. Rhinitis of pregnancy**

Pregnant women may develop persistent rhinitis due to hormonal changes. Nasal mucosa becomes oedematous and blocks the airway. Some may develop secondary infection and even sinusitis. In such cases, care should be taken while prescribing drugs. Generally, local measures such as limited use of nasal drops, topical steroids and limited surgery (cryosurgery) to turbinates are sufficient to relieve the symptoms. Safety of the developing fetus is not established for newer antihistaminics and they should be avoided.

## **4. Honeymoon rhinitis**

This usually follows sexual excitement leading to nasal stuffiness.

## **5. Emotional rhinitis**

Nose may react to several emotional stimuli. Psychological states like anxiety, tension, hostility, humiliation, resentment and grief are all known to cause rhinitis. Treatment is proper counselling for psychological adjustment. Imipramine, which has both antidepressant and anticholinergic effects has been found useful.

## **6. Rhinitis due to hypothyroidism**

Hypothyroidism leads to hypoactivity of the sympathetic system with predominance of parasympathetic activity causing nasal stuffiness and 'colds'. Replacement of thyroid hormone relieves the condition.

## **7. Gustatory rhinitis**

Spicy and pungent food may in some people produce rhinorrhoea, nasal stuffiness, lacrimation, sweating and even flushing of face. This is a cholinergic response to stimulation of sensory receptors on the palate. Spicy food, particularly the red pepper, contains capsaicin which is known to stimulate sensory nerves. It can be relieved by ipratropium bromide nasal spray (an anticholinergic), a few minutes before meals.

## **8. Non air-flow rhinitis**

It is seen in patients of laryngectomy and tracheostomy. Nose is not used for air flow and the turbinates become swollen due to loss of vasomotor control. Similar changes are also seen in nasopharyngeal obstruction due to choanal atresia or adenoidal hyperplasia, the latter having the additional factor of infection due to stagnation of discharge in the nasal cavity which should otherwise drain freely into the nasopharynx.



## 32 Nasal Polypi

Nasal Polypi are non-neoplastic masses of oedematous nasal or sinus mucosa.

They are divided into two main varieties:

- **(a)** Bilateral ethmoidal polypi.
- **(b)** Antrochoanal polyp.

# Bilateral Ethmoidal Polypi

## Aetiology

Aetiology of nasal polypi is very complex and not well-understood. They may arise in inflammatory conditions of nasal mucosa (rhinosinusitis), disorders of ciliary motility or abnormal composition of nasal mucus (cystic fibrosis). Various diseases associated with the formation of nasal polypi are:

- **(i) Chronic rhinosinusitis.** Polypi are seen in chronic rhinosinusitis of both allergic and non-allergic origin. Non-allergic rhinitis with eosinophilia syndrome (NARES) is a form of chronic rhinitis associated with polypi.
- **(ii) Asthma.** 7% of the patients with asthma of atopic or non-atopic origin show nasal polypi.
- **(iii) Aspirin intolerance.** 36% of the patients with aspirin intolerance may show polypi. Sampter's triad consists of nasal polypi, asthma and aspirin intolerance.
- **(iv) Cystic fibrosis.** 20% of patients with cystic fibrosis form polypi. It is due to abnormal mucus.
- **(v) Allergic fungal sinusitis.** Almost all cases of fungal sinusitis form nasal polypi.
- **(vi) Kartagener's syndrome.** This consists of bronchiectasis sinusitis, situs inversus and ciliary dyskinesia.
- **(vii) Young's syndrome.** It consists of sinopulmonary disease and azoospermia.
- **(viii) Churg-Strauss syndrome.** Consists of asthma, fever, eosinophilia, vasculitis and granuloma.
- **(ix) Nasal mastocytosis.** It is a form of chronic rhinitis in which nasal mucosa is infiltrated with mast cells but few eosinophils. Skin tests for allergy and IgE levels are normal.

## Pathogenesis

Nasal mucosa, particularly in the region of middle meatus and turbinate becomes oedematous due to collection of extracellular fluid causing polypoidal change. Polypi which are sessile in the beginning become pedunculated due to gravity and the excessive sneezing.

## Pathology

In early stages, surface of nasal polypi is covered by ciliated columnar epithelium like that of normal nasal mucosa but later it undergoes a metaplastic change to transitional and squamous type on exposure to atmospheric irritation. Submucosa shows large intercellular spaces filled with serous fluid. There is also infiltration with eosinophils and round cells.

## Site of origin

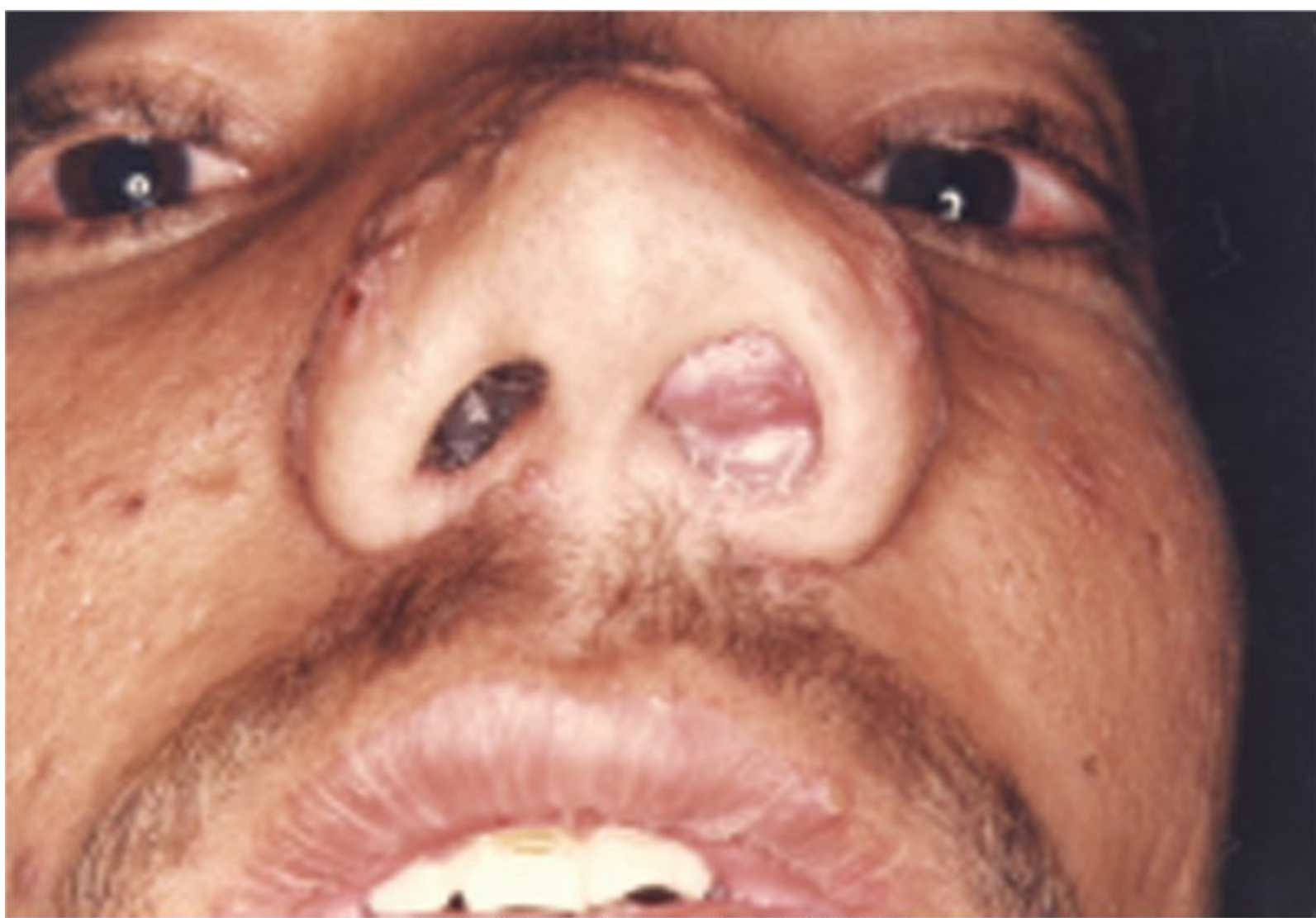Multiple nasal polypi always arise from the lateral wall of nose, usually from the middle meatus. Common sites are uncinata process, bulla ethmoidalis, ostia of sinuses, medial surface and edge of middle turbinate. Allergic nasal polypi almost never arise from the septum or the floor of nose.

## Symptoms

- 1. Multiple polypi can occur at any age but are mostly seen in adults.
- 2. Nasal stuffiness leading to total nasal obstruction may be the presenting symptom.
- 3. Partial or total loss of sense of smell.
- 4. Headache due to associated sinusitis.
- 5. Sneezing and watery nasal discharge due to associated allergy.
- 6. Mass protruding from the nostril.

## Signs

On anterior rhinoscopy, polypi appear as smooth, glistening, grape-like masses often pale in colour. They may be sessile or pedunculated, insensitive to probing and do not bleed on touch. Often they are multiple and bilateral. Long-standing cases present with broadening of nose and increased intercanthal distance. A polyp may protrude from the nostril and appear pink and vascular simulating neoplasm (Fig. 32.1). Nasal cavity may show purulent discharge due to associated sinusitis.



Dhingra: Diseases of Ear Nose and Throat, 5th Edition  
Copyright © 2010 Elsevier. All rights reserved.

Figure 32.1 A polyp protruding from the left nostril in a patient with bilateral ethmoidal polyp.

Probing of a solitary ethmoidal polyp may be necessary to differentiate it from hypertrophy of the turbinate or cystic middle turbinate.

### **Diagnosis**

Diagnosis can be easily made on clinical examination. CT scan of paranasal sinuses is essential to exclude the bony erosion and expansion suggestive of neoplasia. Simple nasal polypi may sometimes be associated with malignancy underneath, especially in people above 40 years and this must be excluded by histological examination of the suspected tissue. CT scan also helps to plan surgery.

### **Treatment**

#### *Conservative*

- 1. Early polypoidal changes with oedematous mucosa may revert to normal with antihistaminics and control of allergy.
- 2. A short course of steroids may prove useful in case of people who cannot tolerate antihistaminics and/or in those with asthma and polypoidal nasal mucosa. They may also be used to prevent recurrence after surgery. Contraindications to use of steroids, e.g. hypertension, peptic ulcer, diabetes, pregnancy and tuberculosis should be excluded.

#### *Surgical*

- 1. *Polypectomy*. One or two polyps which are pedunculated can be removed with snare. Multiple and sessile polypi require special forceps.
- 2. *Intranasal ethmoidectomy*. When polypi are multiple and sessile they require uncapping of the ethmoidal air cells by intranasal route, a procedure called intranasal ethmoidectomy.
- 3. *Extranasal ethmoidectomy*. This is indicated when polypi recur after intranasal procedures and surgical landmarks are ill-defined due to previous surgery. Approach is through the medial wall of the orbit by an external incision, medial to medial canthus.
- 4. *Transantral ethmoidectomy*. This is indicated when infection and polypoidal changes are also seen in the maxillary antrum. In this case,

antrum is opened by Caldwell-Luc approach and the ethmoid air cell approached through the medial wall of the antrum. This procedure is also superceded by endoscopic sinus surgery.

- **5. Endoscopic sinus surgery.** These days, ethmoidal polypi are removed by endoscopic sinus surgery more popularly called FESS (functional endoscopic sinus surgery). It is done with various endoscopes of 0°, 30° and 70° angulation. Polypi can be removed more accurately when ethmoid cells are removed, and drainage and ventilation provided to the other involved sinuses such as maxillary, sphenoidal or frontal.

# Antrochoanal Polyp

This polyp arises from the mucosa of maxillary antrum near its accessory ostium, comes out of it and grows in the choana and nasal cavity. Thus it has three parts.

- **(a) Antral:** which is a thin stalk.
- **(b) Choanal:** which is round and globular.
- **(c) Nasal:** which is flat from side to side.

## **Aetiology**

Exact cause is unknown. Nasal allergy coupled with sinus infection is incriminated. Antrochoanal polypi are seen in children and young adults. Usually they are single and unilateral.

## **Symptoms**

Unilateral nasal obstruction is the presenting symptom. Obstruction may become bilateral when polyp grows into the nasopharynx and starts obstructing the opposite choana (Tables 32.2 and 32.3). Voice may become thick and dull due to hyponasality. Nasal discharge, mostly mucoid, may be seen on one or both sides.

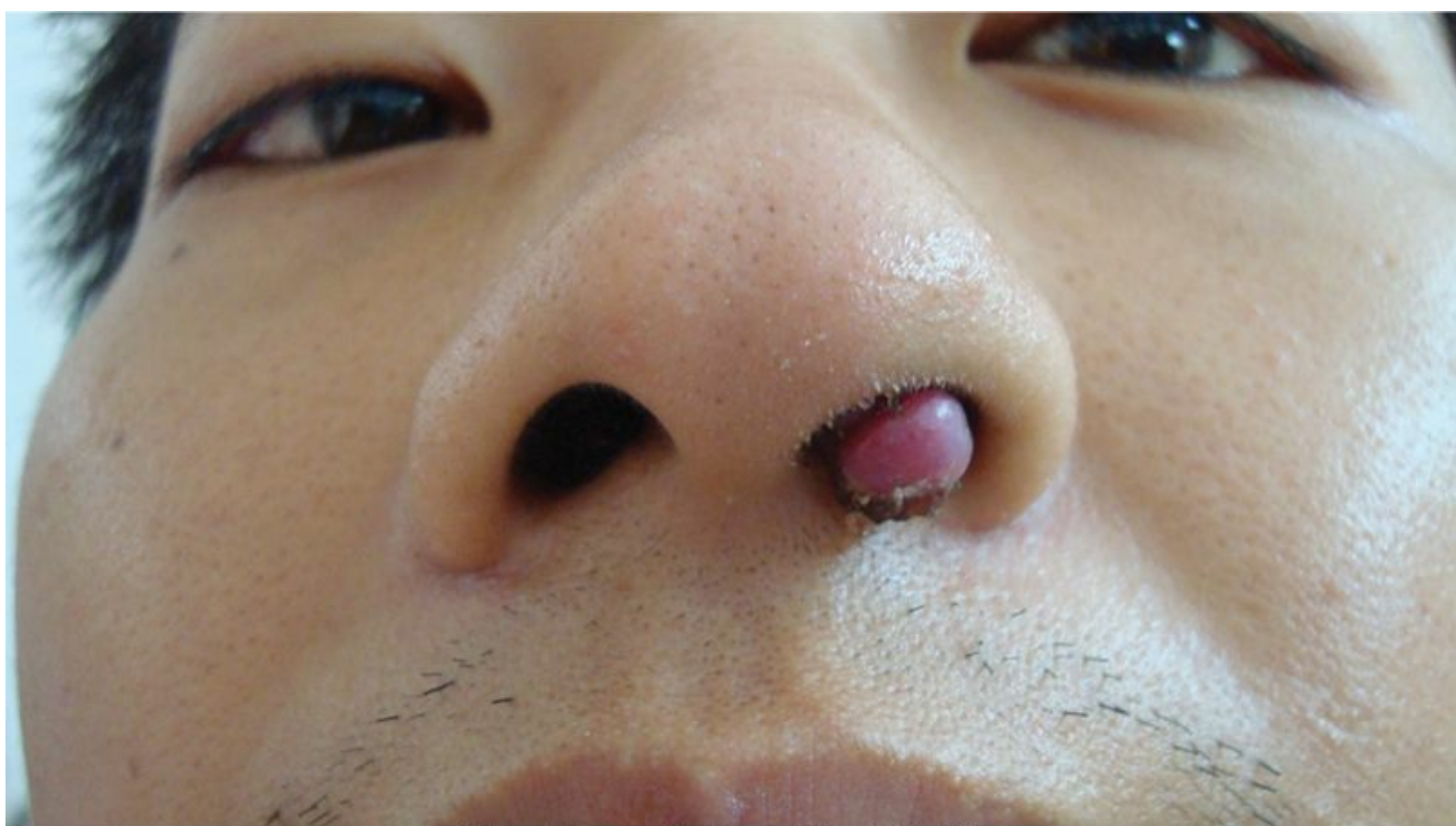## **Signs**

As the antrochoanal polyp grows posteriorly, it may be missed on anterior rhinoscopy. When large, a smooth greyish mass covered with nasal discharge may be seen. It is soft and can be moved up and down with a probe. A large polyp may protrude from the nostril and show a pink congested look on its exposed part (Fig. 32.2).

Posterior rhinoscopy may reveal a globular mass filling the choana or the nasopharynx. A large polyp may hang down behind the soft palate and present in the oropharynx (Fig. 32.3 A,B). (see Table 32.1 for differences between antrochoanal and ethmoidal polypi.)

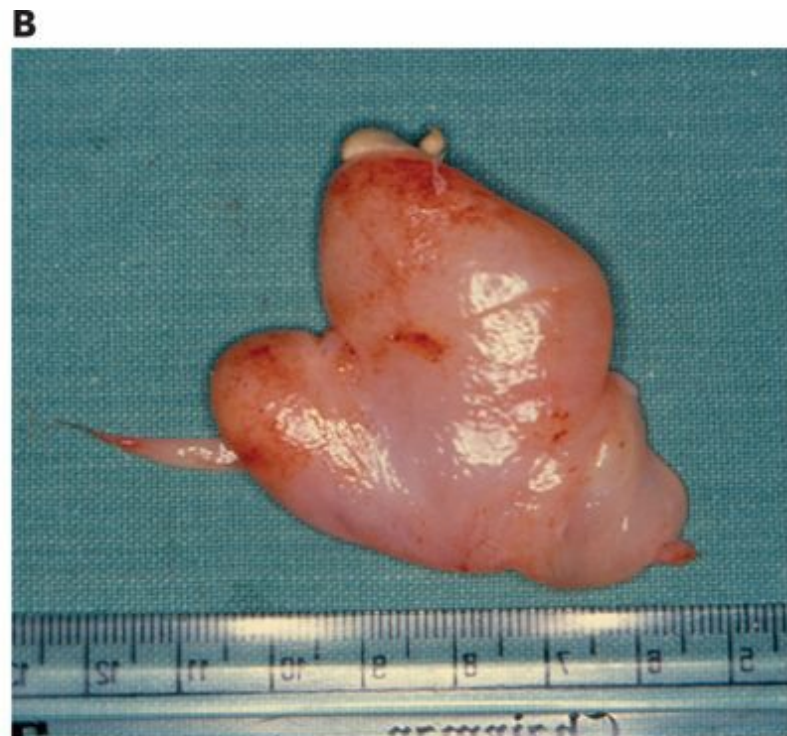
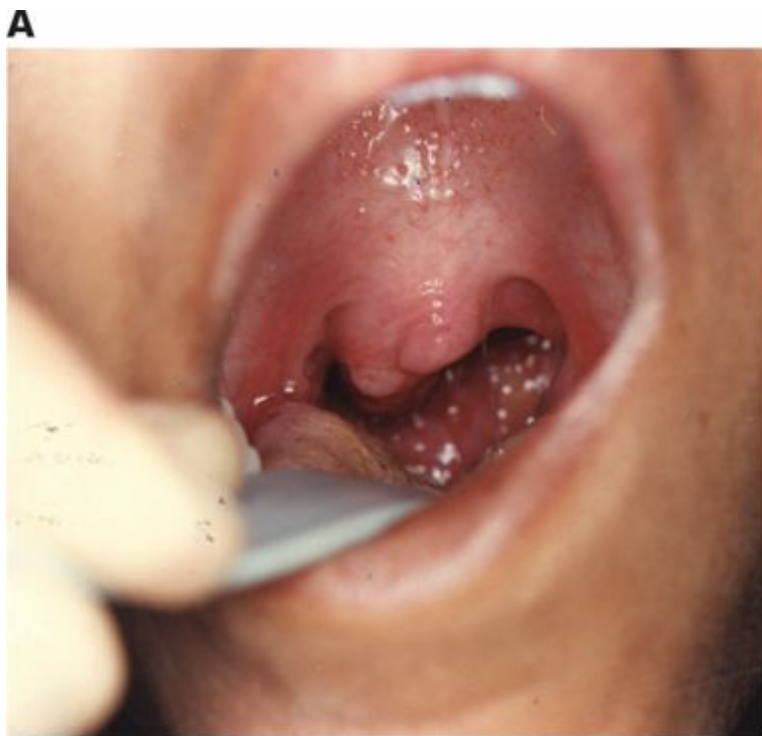## **Differential diagnosis**

- **1.** A blob of mucus often looks like a polyp but it would disappear on blowing the nose.
- **2.** Hypertrophied middle turbinate is differentiated by its pink appearance and hard feel of bone on probe testing.
- **3.** Angiofibroma has history of profuse recurrent epistaxis. It is firm in consistency and easily bleeds on probing.
- **4.** Other neoplasms may be differentiated by their fleshy pink appearance, friable nature and their tendency to bleed.



Dhingra: Diseases of Ear Nose and Throat, 5th Edition  
 Copyright © 2010 Elsevier. All rights reserved.

Figure 32.2 Antrochoanal polyp projecting through the left nostril in a 14-year-old patient.



Dhingra: Diseases of Ear Nose and Throat, 5th Edition  
 Copyright © 2010 Elsevier. All rights reserved.

Figure 32.3 (A) Antrochoanal polyp seen hanging in the oropharynx from behind the soft palate on the right side of uvula. (B) Polyp after removal.

**Table 32-1. Differences between antrochoanal and ethmoidal polypi**

	<b>Antrochoanal polypi</b>	<b>Ethmoidal polypi</b>
Age	Common in children	Common in adults

Aetiology	Infection	Allergy or multifactorial
Number	Solitary	Multiple
Laterality	Unilateral	Bilateral
Origin	Max. sinus near the ostium	Ethmoidal sinuses, uncinata process, middle turbinate and middle meatus
Growth	Grows backwards to the choana; may hang down behind the soft palate	Mostly grow anteriorly and may present at the nares
Size & shape	Trilobed with antral, nasal and choanal parts. Choanal part may protrude through the choana & fill the nasopharynx obstructing both sides	Usually small and grape-like masses
Recurrence	Uncommon, if removed completely	Common
Treatment	Polypectomy; endoscopic removal or Caldwell-Luc operation if recurrent	Polypectomy
		Endoscopic surgery or ethmoidectomy (which may be intranasal, extranasal or transantral)

X-rays of paranasal sinuses may show opacity of the involved antrum. X-ray, (lateral view) soft tissue nasopharynx, reveals a globular swelling in the postnasal space. It is differentiated from angiofibroma by the presence of a column of air behind the polyp.

page 187

page 188

**Table 32-2. Common causes of unilateral nasal obstruction**

<ul style="list-style-type: none"> <li>• <b>Vestibule</b> <ul style="list-style-type: none"> <li>◦ Furuncle</li> <li>◦ Vestibulitis</li> <li>◦ Stenosis of nares</li> <li>◦ Atresia</li> <li>◦ Nasoalveolar cyst</li> <li>◦ Papilloma</li> <li>◦ Squamous cell carcinoma</li> </ul> </li> <li>• <b>Nasal cavity</b> <ul style="list-style-type: none"> <li>◦ Foreign body</li> <li>◦ DNS</li> <li>◦ Hypertrophic turbinates</li> <li>◦ Concha bullosa</li> <li>◦ Antrochoanal polyp</li> <li>◦ Synechia</li> <li>◦ Rhinolith</li> <li>◦ Bleeding polypus of septum</li> <li>◦ Benign and malignant tumours of nose and paranasal sinuses</li> <li>◦ Sinusitis, unilateral</li> </ul> </li> <li>• <b>Nasopharynx</b> <ul style="list-style-type: none"> <li>◦ Unilateral choanal atresia</li> </ul> </li> </ul>
--

**Treatment**

An antrochoanal polyp is easily removed by avulsion either through the nasal or oral route. Recurrence is uncommon after complete removal. In cases which do recur, Caldwell-Luc operation may be required to remove the polyp completely from the site of its origin and to deal with co-existent maxillary sinusitis. These days, endoscopic sinus surgery has superseded other modes of polyp removal. Caldwell-Luc operation is avoided.

## Some Important Points to Remember in a Case of Nasal Polypi

- 1. If a polypus is red and fleshy, friable and has granular surface, especially in older patients, think of malignancy.
- 2. Simple nasal polyp may masquerade a malignancy underneath. Hence all polypi should be subjected to histology.
- 3. A simple polyp in a child may be a glioma, an encephalocele or a meningoencephalocele. It should always be aspirated and fluid examined for CSF. Careless removal of such polyp would result in CSF rhinorrhoea and meningitis.
- 4. Multiple nasal polypi in children may be associated with mucoviscidosis.
- 5. Epistaxis and orbital symptoms associated with a polyp should always arouse the suspicion of malignancy.

**Table 32-3. Common causes of bilateral nasal obstruction**

- **Vestibule**
  - Bilateral vestibulitis
  - Collapsing nasal alae
  - Stenosis of nares
  - Congenital atresia of nares
- **Nasal cavity**
  - Acute rhinitis (viral, bacterial)
  - Chronic rhinitis & sinusitis
  - Rhinitis medicamentosa
  - Allergic rhinitis
  - Hypertrophic turbinates
  - DNS
  - Nasal polypi
  - Atrophic rhinitis
  - Rhinitis sicca
  - Septal haematoma
  - Septal abscess
  - Bilateral choanal atresia
- **Nasopharynx**
  - Adenoid hyperplasia
  - Large choanal polyp
  - Thornwaldt's cyst
  - Adhesions between soft palate and posterior pharyngeal wall
  - Large benign and malignant tumours

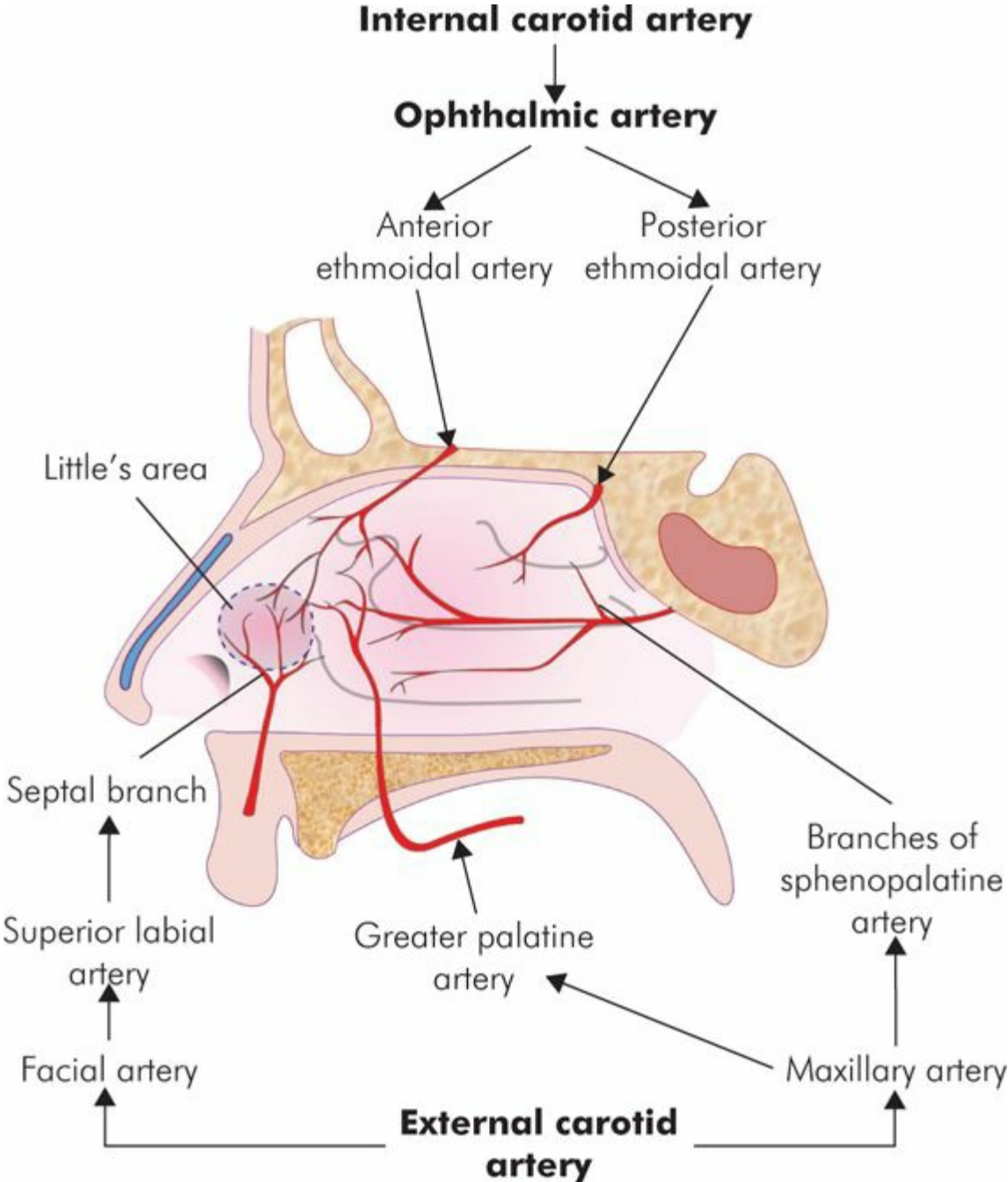


### 33 Epistaxis

Bleeding from *inside* the nose is called epistaxis. It is fairly common and is seen in all age groups-children, adults and older people. It often presents as an emergency. Epistaxis is a sign and not a disease per se and an attempt should always be made to find any local or constitutional cause.

# BLOOD SUPPLY OF NOSE (Figs 33.1 and 33.2)

Nose is richly supplied by both the external and internal carotid systems, both on the septum and the lateral walls.



Dhingra: Diseases of Ear Nose and Throat, 5th Edition  
Copyright © 2010 Elsevier. All rights reserved.

Figure 33.1 Blood supply of nasal septum.

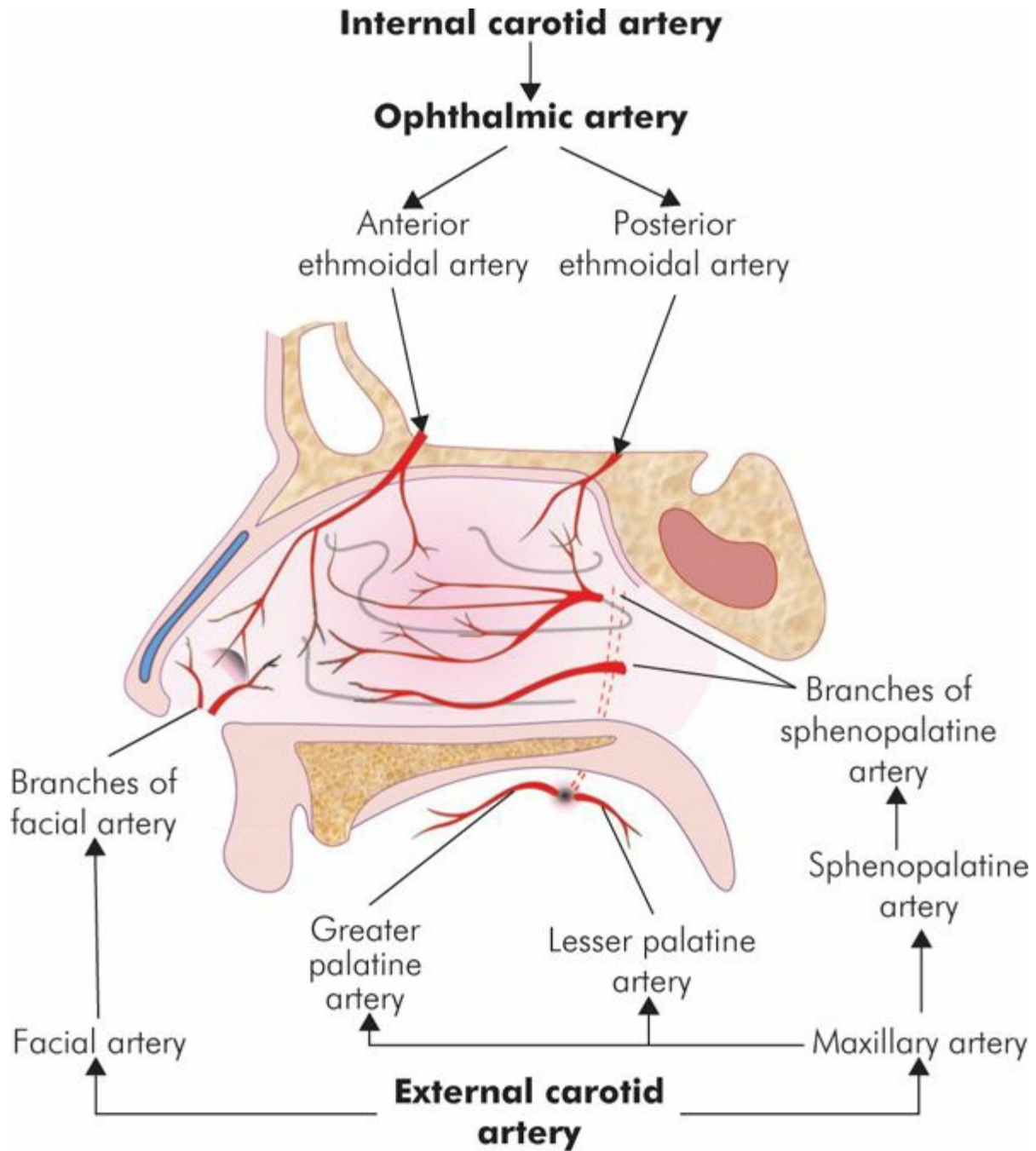
# Nasal Septum

## Internal Carotid System

(a) Anterior ethmoidal artery	Branches of ophthalmic artery
(b) Posterior ethmoidal artery	

## External Carotid System

- (a) Sphenopalatine artery (branch of maxillary artery) gives nasopalatine and posterior medial nasal branches.
- (b) Septal branch of greater palatine artery (Br. of maxillary artery).
- (c) Septal branch of superior labial artery (Br. of facial artery).



Dhingra: Diseases of Ear Nose and Throat, 5th Edition  
Copyright © 2010 Elsevier. All rights reserved.

Figure 33.2 Blood supply of lateral wall of nose.

## Lateral Wall

### Internal Carotid System

(a) Anterior ethmoidal	Branches of ophthalmic artery
(b) Posterior ethmoidal	

### External Carotid System

(a) Posterior lateral nasal branches	→	From sphenopalatine artery
(b) Greater palatine artery	→	From maxillary artery
(c) Nasal branch of anterior superior dental	→	From infraorbital branch of maxillary artery
(d) Branches of facial artery to nasal vestibule		

## Little's Area

It is situated in the anterior inferior part of nasal septum, just above the vestibule. Four arteries-anterior ethmoidal, septal branch of superior labial, septal branch of sphenopalatine and the greater palatine, anastomose here to form a vascular plexus called "*Kiesselbach's plexus*". This area is exposed to the drying effect of inspiratory current and to finger nail trauma, and is the usual site for epistaxis in children and young adults.

### ***Retrocolumellar vein***

This vein runs vertically downwards just behind the columella, crosses the floor of nose and joins venous plexus on the lateral nasal wall. This is a common site of venous bleeding in young people.

## Woodruff's Area

This vascular area is situated under the posterior end of inferior turbinate where sphenopalatine artery anastomoses with posterior pharyngeal artery. Posterior epistaxis may occur in this area.

## CAUSES OF EPISTAXIS

They may be divided into:

- **A.** Local, in the nose or nasopharynx.
- **B.** General.
- **C.** Idiopathic.

## A. Local Causes

### Nose

- **1. Trauma.** Finger nail trauma, injuries of nose, intranasal surgery, fractures of middle third of face and base of skull, hard-blowing of nose, violent sneeze.
- **2. Infections.**
  - Acute: Viral rhinitis, nasal diphtheria, acute sinusitis.
  - Chronic: All crust-forming diseases, e.g. atrophic rhinitis, rhinitis sicca, tuberculosis, syphilis septal perforation, granulomatous lesion of the nose, e.g. rhinosporidiosis.
- **3. Foreign bodies.**
  - Non-living: Any neglected foreign body, rhinolith.
  - Living: Maggots, leeches.
- **4. Neoplasms of nose and paranasal sinuses.**
  - Benign: Haemangioma, papilloma.
  - Malignant: Carcinoma or sarcoma.
- **5. Atmospheric changes.** High altitudes, sudden decompression (Caisson's disease).
- **6. Deviated nasal septum.**

### Nasopharynx

- **1.** Adenoiditis
- **2.** Juvenile angiofibroma
- **3.** Malignant tumours



## B. General Causes

- **1. Cardiovascular system.** Hypertension, arteriosclerosis, mitral stenosis, pregnancy (hypertension and hormonal).
- **2. Disorders of blood and blood vessels.** Aplastic anaemia, leukaemia, thrombocytopenic and vascular purpura, haemophilia, Christmas disease, scurvy, vitamin K deficiency, hereditary haemorrhagic telangiectasia.
- **3. Liver disease.** Hepatic cirrhosis (deficiency of factor II, VII, IX & X).
- **4. Kidney disease.** Chronic nephritis.
- **5. Drugs.** Excessive use of salicylates and other analgesics (as for joint pains or headaches), anticoagulant therapy (for heart disease).
- **6. Mediastinal compression.** Tumours of mediastinum (raised venous pressure in the nose).
- **7. Acute general infection.** Influenza, measles, chickenpox, whooping cough, rheumatic fever, infectious mononucleosis, typhoid, pneumonia, malaria, dengue fever.
- **8. Vicarious menstruation** (epistaxis occurring at the time of menstruation).

## C. Idiopathic

Many times the cause of epistaxis is not clear.

## SITES OF EPISTAXIS

- **1. Little's area.** In 90% cases of epistaxis, bleeding occurs from this site.
- **2. Above the level of middle turbinate.** Bleeding from above the middle turbinate and corresponding area on the septum is often from the anterior and posterior ethmoidal vessels (internal carotid system).
- **3. Below the level of middle turbinate.** Here bleeding is from the branches of sphenopalatine artery. It may be hidden, lying lateral to middle or inferior turbinate and may require infrastructure of these turbinates for localisation of the bleeding site and placement of packing to control it.
- **4. Posterior part of nasal cavity.** Here blood flows directly into the pharynx.
- **5. Diffuse.** Both from septum and lateral nasal wall. This is often seen in general systemic disorders and blood dyscrasias.
- **6. Nasopharynx.**

# **CLASSIFICATION OF EPISTAXIS**

## **Anterior Epistaxis**

When blood flows out from the front of nose with the patient in sitting position.

## **Posterior Epistaxis**

Mainly the blood flows back into the throat. Patient may swallow it and later have a "coffee-coloured" vomitus. This may erroneously be diagnosed as haematemesis.

The differences between the two types of epistaxis are tabulated herewith (Table 33.1).

# Management

In any case of epistaxis, it is important to know:

- 1. Mode of onset. Spontaneous or finger nail trauma.
- 2. Duration and frequency of bleeding.
- 3. Amount of blood loss.
- 4. Side of nose from where bleeding is occurring.
- 5. Whether bleeding is of anterior or posterior type.
- 6. Any known bleeding tendency in the patient or family.
- 7. History of known medical ailment (hypertension, leukaemias, mitral valve disease, cirrhosis, nephritis).
- 8. History of drug intake (analgesics, anticoagulants, etc.).

**Table 33-1. Differences between anterior and posterior epistaxis**

	<b>Anterior epistaxis</b>	<b>Posterior epistaxis</b>
Incidence	More common	Less common
Site	Mostly from Little's area or anterior part of lateral wall	Mostly from posterosuperior part of nasal cavity; often difficult to localise the bleeding point
Age	Mostly occurs in children or young adults	After 40 years of age
Cause	Mostly trauma	Spontaneous; often due to hypertension or arteriosclerosis
Bleeding	Usually mild, can be easily controlled by local pressure or anterior pack	Bleeding is severe, requires hospitalisation; postnasal pack often required

## First Aid

Most of the time, bleeding occurs from the Little's area and can be easily controlled by pinching the nose with thumb and index finger for about 5 minutes. This compresses the vessels of the Little's area. In Trotter's method patient is made to sit, leaning a little forward over a basin to spit any blood, and breathe quietly from the mouth. Cold compresses should be applied to the nose to cause reflex vasoconstriction.

## Cauterisation

This is useful in anterior epistaxis when bleeding point has been located. The area is first anaesthetised and the bleeding point cauterised with a bead of silver nitrate or coagulated with electrocautery.

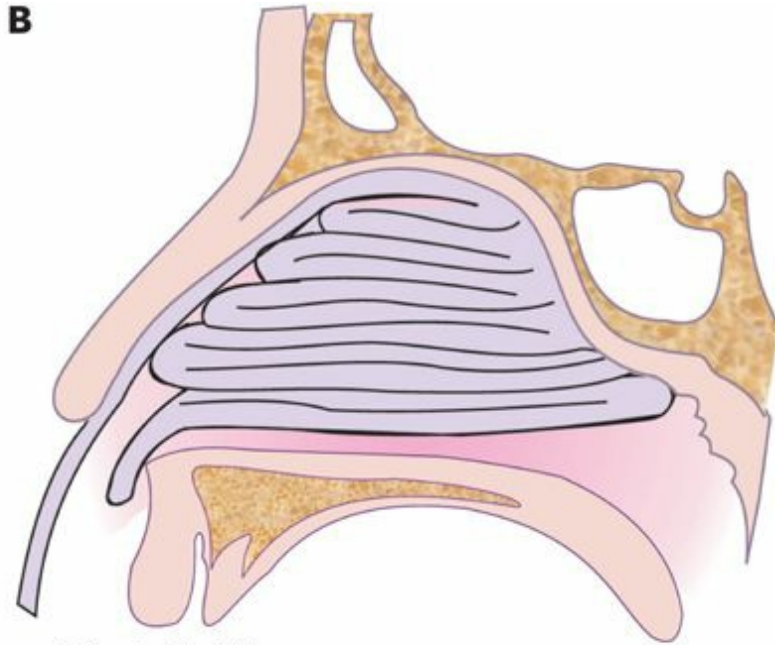
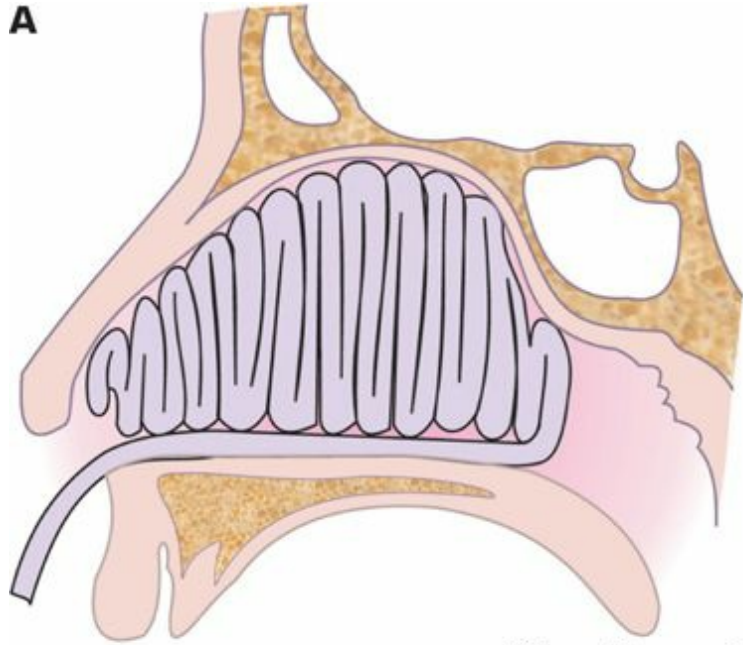
## Anterior Nasal Packing

page 191

page 192

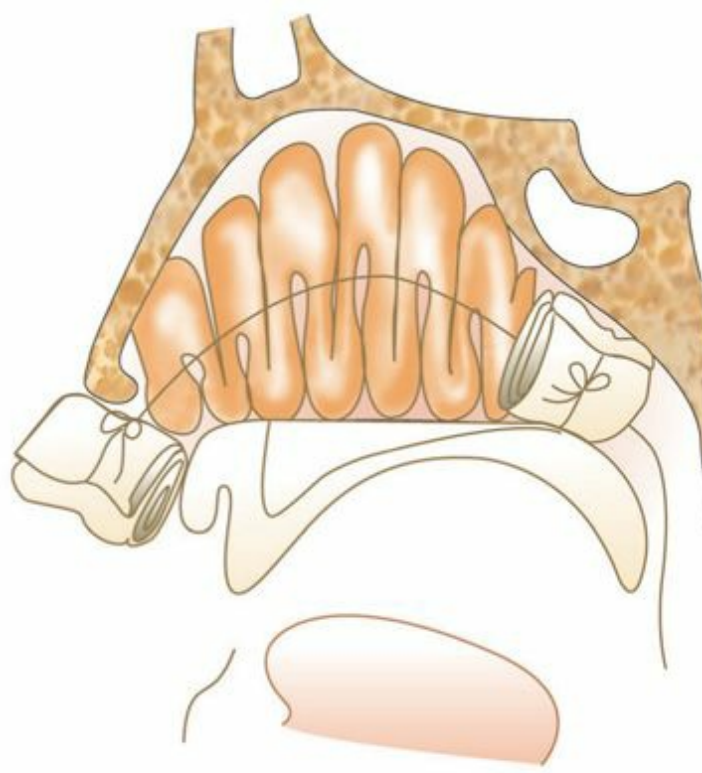
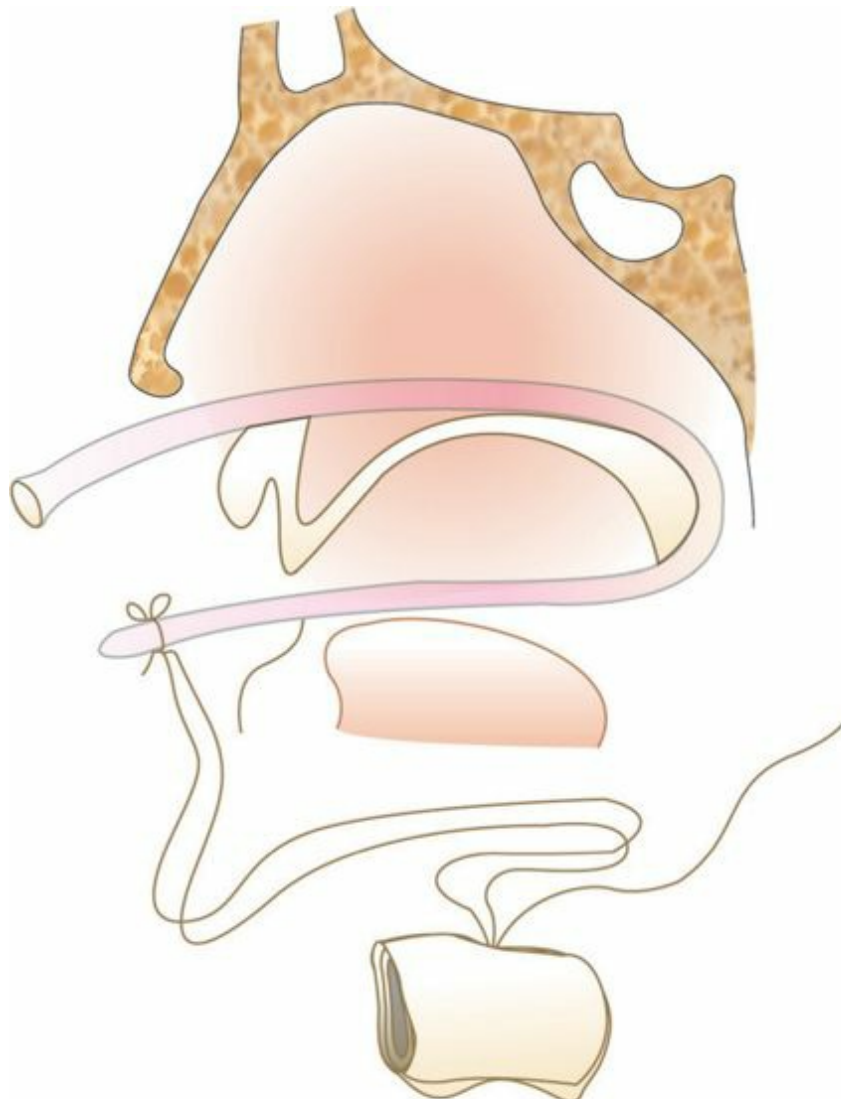
In cases of active anterior epistaxis, nose is cleared of blood clots by suction and attempt is made to localise the bleeding site. In minor bleeds, from the accessible sites, cauterisation of the bleeding area can be done. If bleeding is profuse and/or the site of bleeding is difficult to localise, anterior packing should be done. For this, use a ribbon gauze soaked with liquid paraffin. About 1 metre gauze (2.5 cm wide in adults and 12 mm in children) is required for each nasal cavity. First, few centimetres of gauze are folded upon itself and inserted along the floor, and then the whole nasal cavity is packed tightly by layering the gauze from floor to the roof and from before backwards. Packing can also be done in vertical layers from back to the front (Fig. 33.3). One or both cavities may need to be packed. Pack can be removed after 24 hours if bleeding has stopped. Sometimes, it has to be kept for 2 to 3 days; in that case, systemic antibiotics should be given to prevent sinus infection and toxic shock syndrome.

## Posterior Nasal Packing



Dhingra: Diseases of Ear Nose and Throat, 5th Edition  
 Copyright © 2010 Elsevier. All rights reserved.

Figure 33.3 Methods of anterior nasal packing. (A) Packing in vertical layers. (B) Packing in horizontal layers.



Dhingra: Diseases of Ear Nose and Throat, 5th Edition  
 Copyright © 2010 Elsevier. All rights reserved.

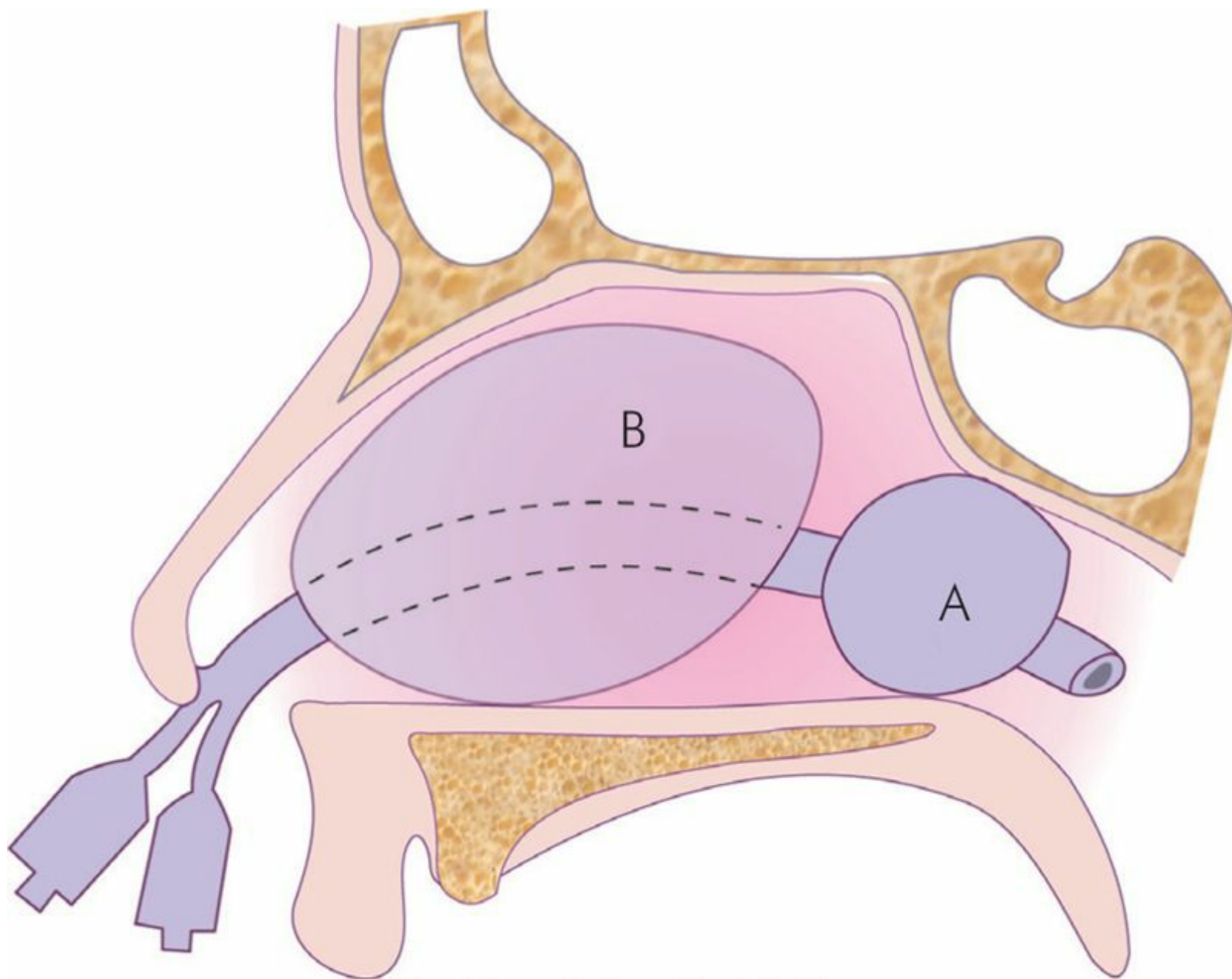
Figure 33.4 Technique of postnasal pack.

It is required for patients bleeding posteriorly into the throat. A postnasal pack is first prepared by tying three silk ties to a piece of gauze rolled into

the shape of a cone. A rubber catheter is passed through the nose and its end brought out from the mouth (Fig. 33.4). Ends of the silk threads are tied to it and catheter withdrawn from nose. Pack, which follows the silk thread, is now guided into the nasopharynx with the index finger. Anterior nasal cavity is now packed and silk threads tied over a dental roll. The third silk thread is cut short and allowed to hang in the oropharynx. It helps in easy removal of the pack later. Patients requiring postnasal pack should always be hospitalised. Instead of postnasal pack, a Foley's catheter size 12-14 F can also be used. After insertion balloon is inflated with 5-10 ml of saline. The bulb is inflated with saline and pulled forward so that choana is blocked and then an anterior nasal pack is kept in the usual manner. These days nasal balloons are also available (Fig. 33.5). A nasal balloon has two bulbs, one for the postnasal space and the other for nasal cavity.

page 192

page 193



Dhingra: Diseases of Ear Nose and Throat, 5th Edition  
Copyright © 2010 Elsevier. All rights reserved.

Figure 33.5 Epistaxis balloon for posterior epistaxis. Posterior balloon (A) is inflated with 10 ml and anterior balloon (B) with 30 ml. Catheter provides nasal airway.

## Endoscopic Cautery

Posterior bleeding point can sometimes be better located with an endoscope. It can be coagulated with suction cautery. Local anaesthesia with sedation may be required.

## Elevation of Mucoperichondrial Flap and SMR Operation

In case of persistent or recurrent bleeds from the septum, just elevation of mucoperichondrial flap and then repositioning it back helps to cause fibrosis and constrict blood vessels. SMR operation can be done to achieve the same result or remove any septal spur which is sometimes the cause of epistaxis.

## Ligation of Vessels

- **(a) External carotid.** When bleeding is from the external carotid system and the conservative measures have failed, ligation of external carotid artery above the origin of superior thyroid artery should be done. It is avoided these days in favour of embolisation or ligation of more peripheral branches.
- **(b) Maxillary artery.** Ligation of this artery is done in uncontrollable posterior epistaxis. Approach is via Caldwell-Luc operation. Posterior wall of maxillary sinus is removed and the maxillary artery or its branches are blocked by applying clips. Endoscopic ligation of the maxillary artery can also be done through nose.
- **(c) Ethmoidal arteries.** In anterosuperior bleeding above the middle turbinate, not controlled by packing, anterior and posterior ethmoidal arteries which supply this area, can be ligated. The vessels are exposed in the medial wall of the orbit by an external ethmoid incision.



## General Measures in Epistaxis

- 1. Make the patient sit up with a back rest and record any blood loss taking place through spitting or vomiting.
- 2. Reassure the patient. Mild sedation should be given.
- 3. Keep check on pulse, BP and respiration.
- 4. Maintain haemodynamics. Blood transfusion may be required.
- 5. Antibiotics may be given to prevent sinusitis, if pack is to be kept beyond 24 hours.
- 6. Intermittent oxygen may be required in patients with bilateral packs because of increased pulmonary resistance from nasopulmonary reflex.
- 7. Investigate and treat the patient for any underlying local or general cause.

### ***Hereditary haemorrhagic telangiectasia***

It occurs on the anterior part of nasal septum and is the cause of recurrent bleeding. It can be treated by using Argon, KTP or Nd: YAG laser. The procedure may require to be repeated several times in a year as telangiectasia recurs in the surrounding mucosa. Some cases require septodermoplasty where anterior part of septal mucosa is excised and replaced by a split skin graft.

## 34 Trauma to the Face

Injuries of face may involve soft tissues, bones or both. The majority of facial injuries are caused by automobile accidents. Others result from sports, personal accidents, assaults and fights. The management of facial trauma can be divided into:

- **(a)** General management.
- **(b)** Soft tissue injuries and their management.
- **(c)** Bone injuries and their management.

## GENERAL MANAGEMENT

- **1. Airway** Maintenance of airway should receive the highest priority. Airway is obstructed by loss of skeletal support, aspiration of foreign bodies, blood or gastric contents or swelling of tissues. Airway is secured by intubation or the tracheostomy.
- **2. Haemorrhage** Injuries of face may bleed profusely. Bleeding should be stopped by pressure or ligation of vessels.
- **3. Associated injuries** Facial injuries may be associated with injuries of head, chest, abdomen, neck, larynx, cervical spine or limbs and should be attended to.

# **SOFT TISSUE INJURIES AND THEIR MANAGEMENT**

## **Facial Lacerations**

Wound is thoroughly cleaned of any dirt, grease or foreign matter. The lacerations are closed by accurate approximation of each layer.

## Parotid Gland and Duct

Parotid tissue, if exposed, is repaired by suturing. Injuries of parotid duct are more serious. Both ends of the duct are identified and sutured over a polyethylene tube, with fine suture. The tube is left for 3 days to 2 weeks.

## Facial Nerve

If severed, the facial nerve is exposed by superficial parotidectomy and cut ends are approximated with 8-0 or 10-0 silk under magnification.

# BONE INJURIES AND THEIR MANAGEMENT

The face can be divided into three regions:

- **(a)** Upper third: Above the level of supraorbital ridge.
- **(b)** Middle third: Between the supraorbital ridge and the upper teeth.
- **(c)** Lower third: Mandible and the lower teeth.

The various fractures encountered in these regions are listed in Table 34.1.

# A. FRACTURES OF UPPER THIRD OF FACE

## 1. Frontal Sinus

Frontal sinus fractures may involve anterior wall, posterior wall or the nasofrontal duct.

- **(a) Anterior wall fractures** may be depressed or comminuted. Defect is mainly cosmetic. Sinus is approached through a wound in the skin if that is present, or through a brow incision. The bone fragments are elevated, taking care not to strip them from the periosteum. The interior of the sinus is always inspected to rule out fracture of the posterior wall.
- **(b) Posterior wall fractures** may be accompanied by dural tears, brain injury and CSF rhinorrhoea. They may require neurosurgical consultation. Dural tears can be covered by temporalis fascia. Small sinuses can be obliterated with fat.
- **(c) Injury to nasofrontal duct** cause obstruction to sinus drainage and may later be complicated by a mucocele. In such cases, make a large communication between the sinus and the nose. Small sinuses can be obliterated with fat after removing the sinus mucosa completely.

Table 34-1. Fractures of the face

Upper third	Middle third	Lower third
Frontal sinuses	Nasal bones and septum	Alveolar process
Supraorbital ridge	Naso-orbital area	Symphysis
Frontal bone	Zygoma	Body
	Zygomatic arch	Angle
	Orbital floor	Ascending ramus
	Maxilla	Condyle
	- Le Fort I (transverse)	Temporomandibular joint
	- Le Fort II (pyramidal)	
	- Le Fort III (craniofacial dysjunction)	



## 2. Supraorbital Ridge

Ridge fractures often cause periorbital ecchymosis, flattening of the eyebrow, proptosis or downward displacement of eye. Fragment of bone may also be pushed into the orbit and get impacted. Ridge fractures require open reduction through an incision in the brow or transverse skin line of the forehead.

### 3. Fractures of Frontal Bone

They may be depressed or linear, with or without separation. They often extend into the orbit. Brain injury and cerebral oedema are commonly associated with each other and require neurosurgical consultation.

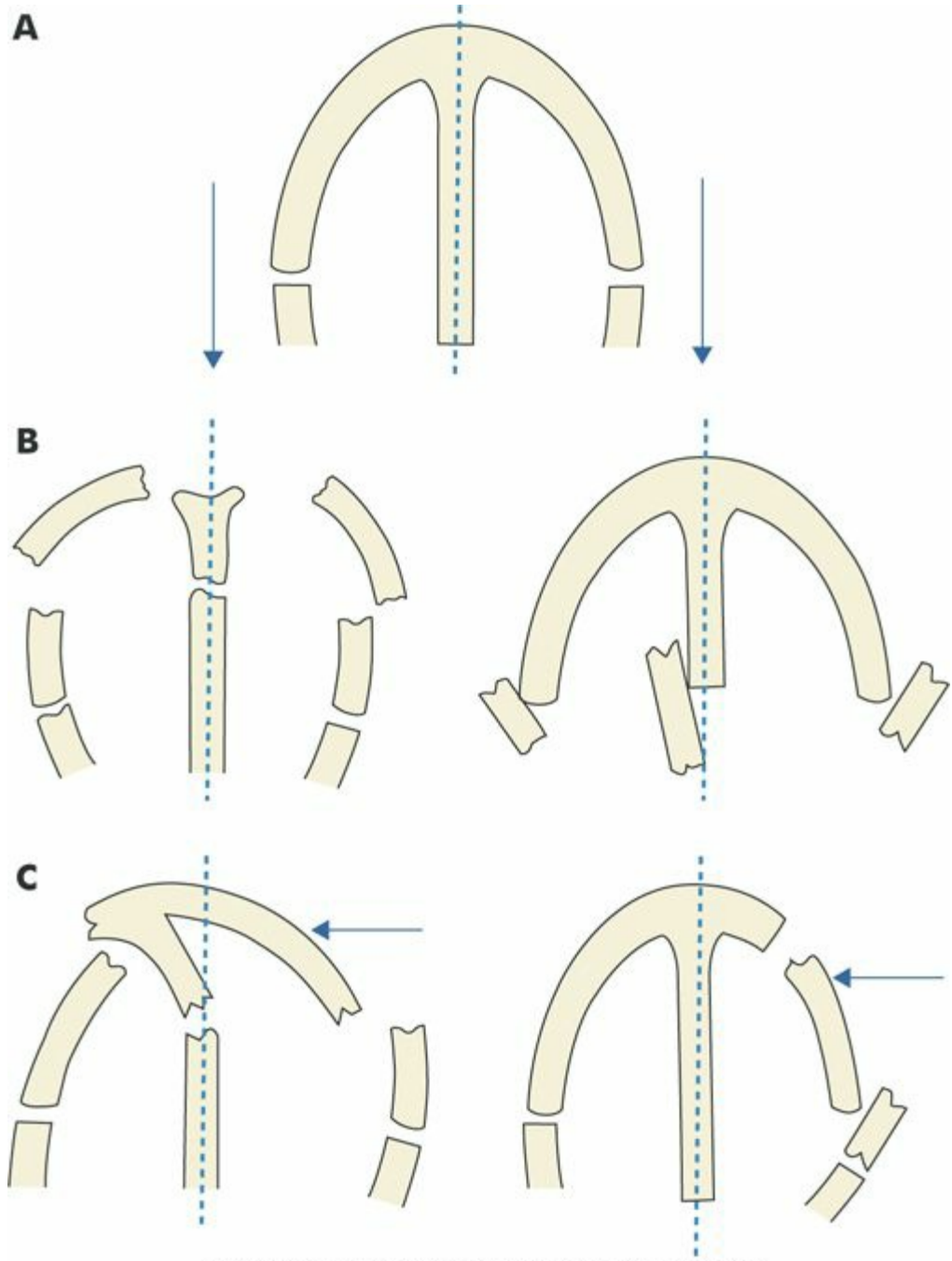
# B. FRACTURES OF MIDDLE THIRD OF FACE

## 1. Nasal Bones and Septum

Fractures of nasal bones are the most common because of the projection of nose on the face. Traumatic forces may act from the front or side. Magnitude of force will determine the depth of injury.

### Types of Nasal Fractures (Fig. 34.1)

#### Depressed



Dhingra: Diseases of Ear Nose and Throat, 5th Edition  
Copyright © 2010 Elsevier. All rights reserved.

Figure 34.1 Types of fractures. (A) Normal, (B) Frontal blow causing depressed fracture or open-book fracture and (C) Lateral blow causing deviation of nasal bridge or depression of one nasal bone.

They are due to frontal blow. Lower part of nasal bones which is thinner, easily gives way. A severe frontal blow will cause "open-book fracture" in which nasal septum is collapsed and nasal bones splayed out. Still, greater forces will cause comminution of nasal bones and even the frontal processes of maxillae with flattening and widening of nasal dorsum.

## **Angulated**

A lateral blow may cause unilateral depression of nasal bone on the same side or may fracture both the nasal bones and the septum with deviation of nasal bridge.

Nasal fractures are often accompanied by injuries of nasal septum which may be simply buckled, dislocated or fractured into several pieces. Septal haematoma may form.

## **Clinical Features**

- 1. Swelling of nose. Appears within few hours and may obscure details of examination.
- 2. Periorbital ecchymosis.
- 3. Tenderness.
- 4. Nasal deformity. Nose may be depressed from the front or side, or the whole of the nasal pyramid deviated to one side.
- 5. Crepitus and mobility of fractured fragments.
- 6. Epistaxis.
- 7. Nasal obstruction due to septal injury or haematoma.
- 8. Lacerations of the nasal skin with exposure of nasal bones and cartilage may be seen in compound fractures.

## **Diagnosis**

Diagnosis is best made on physical examination. X-rays may or may not show fracture (Fig. 34.2). Patient should not be dismissed as having no fracture because X-rays did not reveal it.

X-rays should include Waters' view, right and left lateral views and occlusal view.

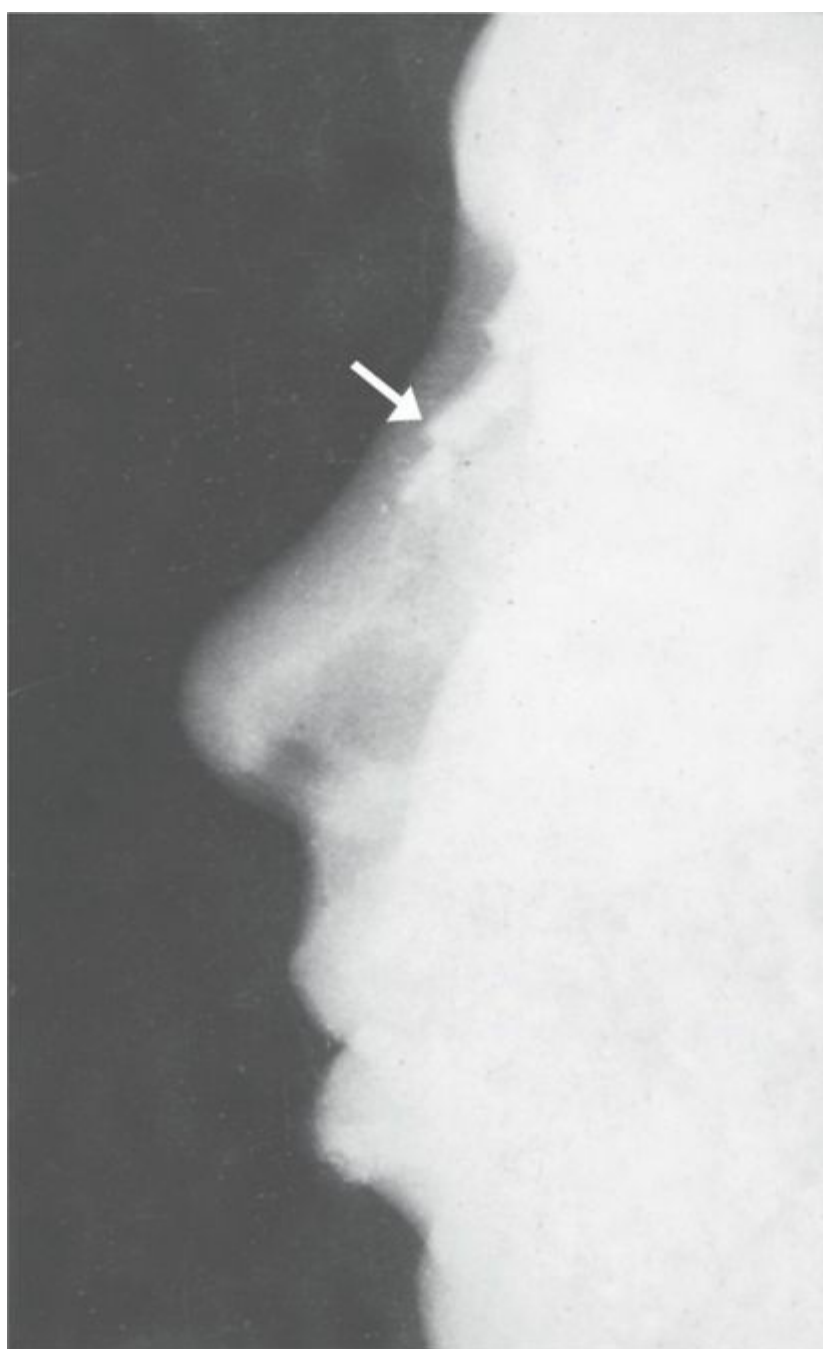
## **Treatment**

Simple fractures without displacement need no treatment; others may require closed or open reduction. Presence of oedema interferes with accurate reduction by closed methods. Therefore, the best time to reduce a fracture is before the appearance of oedema, or after it has subsided, which is usually in 5-7 days. It is difficult to reduce a nasal fracture after 2 weeks because it heals by that time. Healing is faster in children and therefore earlier reduction is imperative.

### ***Closed reduction***

Depressed fractures of nasal bones sustained by either frontal or lateral blow, can be reduced by a straight blunt elevator guided by digital manipulation from outside.

Laterally, displaced nasal bridge can be reduced by firm digital pressure in the opposite direction. Impacted fragments sometimes require disimpaction with Walsham or Asche's forceps before realignment. Septal fractures are also reduced by Asche's forceps. Septal haematoma, if present, must be drained.



Dhingra: Diseases of Ear Nose and Throat, 5th Edition  
Copyright © 2010 Elsevier. All rights reserved.

Figure 34.2 Fractured nasal bone (arrow) as seen in radiograph.

Simple fractures may not require intranasal packing. Unstable fractures require intranasal packing and external splintage.

### ***Open reduction***

Early open reduction in nasal fractures is rarely required. This is indicated when closed methods fail. Certain septal injuries can be better reduced by open methods.

Healed nasal deformities resulting from nasal trauma can be corrected by rhinoplasty or septorhinoplasty.

## 2. Naso-orbital Fractures

Direct force over the nasion fractures nasal bones and displaces them posteriorly. Perpendicular plate of ethmoid, ethmoidal air cells and medial orbital wall are fractured and driven posteriorly. Injury may involve cribriform plate, frontal sinus, frontonasal duct, extraocular muscles, eyeball and the lacrimal apparatus. Medial canthal ligament may be avulsed.

### Clinical Features

page 196

page 197

- 1. Telecanthus, due to lateral displacement of medial orbital wall.
- 2. Pug nose. Bridge of nose is depressed and tip turned up.
- 3. Periorbital ecchymosis.
- 4. Orbital haematoma due to bleeding from anterior and posterior ethmoidal arteries.
- 5. CSF leakage due to fracture of cribriform plate and dura.
- 6. Displacement of eyeball.

### Diagnosis

Various facial films will be required to assess the extent of fracture and injury to other facial bones. CT scans are more useful.

### Treatment

#### *Closed reduction*

In uncomplicated cases, fracture is reduced with Asche's forceps and stabilised by a wire passed through fractured bony fragments and septum and then tied over the lead plates. Intranasal packing is given. Splinting is kept for 10 days or so.

#### *Open reduction*

This is required in cases with extensive comminution of nasal and orbital bones, and those complicated by other injuries to lacrimal apparatus, medial canthal ligaments, frontal sinus, etc.

An H-type incision gives adequate exposure of the fractured area. This can be extended to the eyebrows if access to frontal sinuses is also required.

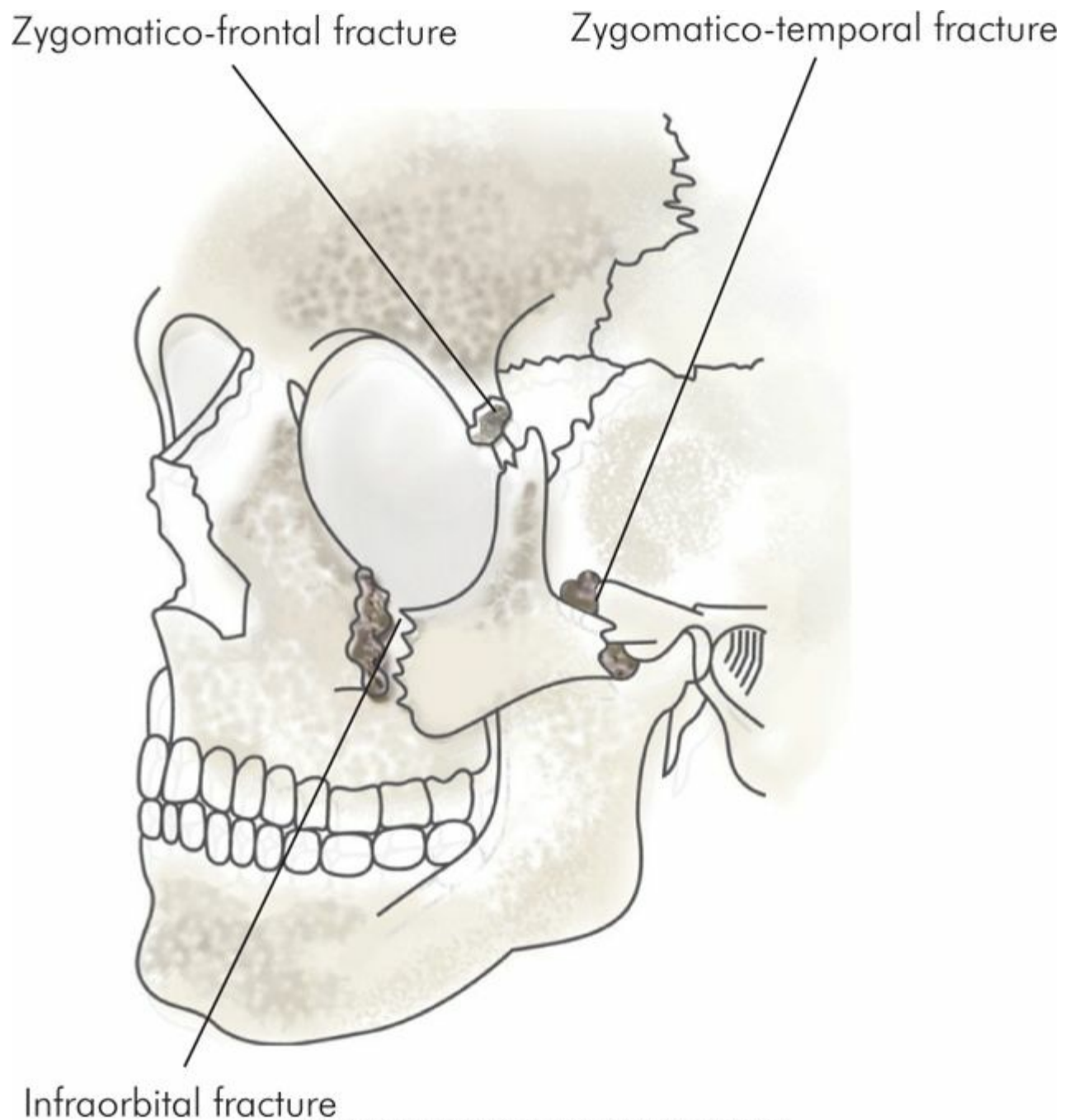
Nasal bones are reduced under vision and bridge height is achieved. Medial orbital walls can be reduced. Medial canthal ligaments, if avulsed, are restored with a through and through wire. Intranasal packing may be required to restore the contour. When bone comminution is severe, restoration of medial canthal ligaments and lacrimal apparatus should receive preference over reconstruction of nasal contour.

### 3. Fractures of Zygoma (Tripod Fracture)

After nasal bones, zygoma is the second most frequently fractured bone. Usually, the cause is direct trauma. Lower segment of zygoma is pushed medially and posteriorly resulting in flattening of the malar prominence and a step-deformity at the infraorbital margin. Zygoma is separated at its three processes (Fig. 34.3). Fracture line passes through zygomaticofrontal suture, orbital floor, infraorbital margin and foramen, anterior wall of maxillary sinus and the zygomaticotemporal suture. Orbital contents may herniate into the maxillary sinus.

#### Clinical Features

- 1. Flattening of malar prominence.
- 2. Step-deformity of infraorbital margin.
- 3. Anaesthesia in the distribution of infraorbital nerve.
- 4. Trismus, due to depression of zygoma on the underlying coronoid process.
- 5. Oblique palpebral fissure, due to the displacement of lateral palpebral ligament.
- 6. Restricted ocular movements, due to entrapment of inferior rectus muscle. It may cause diplopia.
- 7. Periorbital emphysema, due to escape of air from the maxillary sinus on nose-blowing.



Dhingra: Diseases of Ear Nose and Throat, 5th Edition  
Copyright © 2010 Elsevier. All rights reserved.

Figure 34.3 Fracture zygoma left.

## **Diagnosis**

Waters' or exaggerated Waters' view shows the fracture and displacement the best. Maxillary sinus may show clouding due to the presence of blood. Comminution with depression of orbital floor and herniation of orbital contents cannot be seen on plain X-rays. CT scan of the orbital will be more useful.

## **Treatment**

Only displaced fractures require treatment. Open reduction and internal wire fixation gives best results. Fracture is exposed at the frontozygomatic suture through lateral brow incision and reduced by passing an elevator behind the zygoma. Wire fixation is done at frontozygomatic suture and infraorbital margin. The latter is exposed by a separate incision in the lower lid. Fracture of orbital floor can also be repaired through this incision.

Transantral approach is less favourable. Antrum is exposed as in Caldwell-Luc operation, blood is aspirated, fracture reduced and then stabilised by a pack in the antrum. Fractures of orbital floor can also be reduced. Antral pack is removed in about 10 days through the buccal incision, which is left open at the end of operation, or through the intranasal antrostomy route.



## 4. Fractures of Zygomatic Arch

Zygomatic arch generally breaks into two fragments which get depressed. There are three fracture lines, one at each end and third in the centre of the arch.

### **Clinical Features**

Characteristic features are depression in the area of zygomatic arch, local pain aggravated by talking and chewing, trismus or limitation of the movements of mandible due to impingement of fragments on the condyle or coronoid process.

### **Diagnosis**

Arch fractures are best seen on submentovertical view of the skull. Waters' view is also taken.

### **Treatment**

A vertical incision is made in the hair-bearing area above or in front of the ear, cutting through temporal fascia. An elevator is passed deep to temporal fascia and carried under the depressed bony fragments which are then reduced. Fixation is usually not required as the fragments remain stable.

## 5. Fractures of Orbital Floor

Zygomatic and Le Fort II maxillary fractures are always accompanied by fractures of orbital floor. Isolated fractures of orbital floor, when a large blunt object strikes the globes, are called "*blow out fractures*" Orbital contents may herniate into the antrum (Fig. 34.4).

### Clinical Features

- 1. Ecchymosis of lid, conjunctiva and sclera.
- 2. Enophthalmos with inferior displacement of the eyeball. This becomes apparent when oedema subsides.
- 3. Diplopia, which may be due to displacement of the eyeball or entrapment of inferior rectus and inferior oblique muscles.
- 4. Hypoaesthesia or anaesthesia of cheek and upper lip, if infraorbital nerve is involved.



Dhingra: Diseases of Ear Nose and Throat, 5th Edition  
Copyright © 2010 Elsevier. All rights reserved.

Figure 34.4 Blow out fracture with herniation of orbital contents into the maxillary sinus.

### Diagnosis

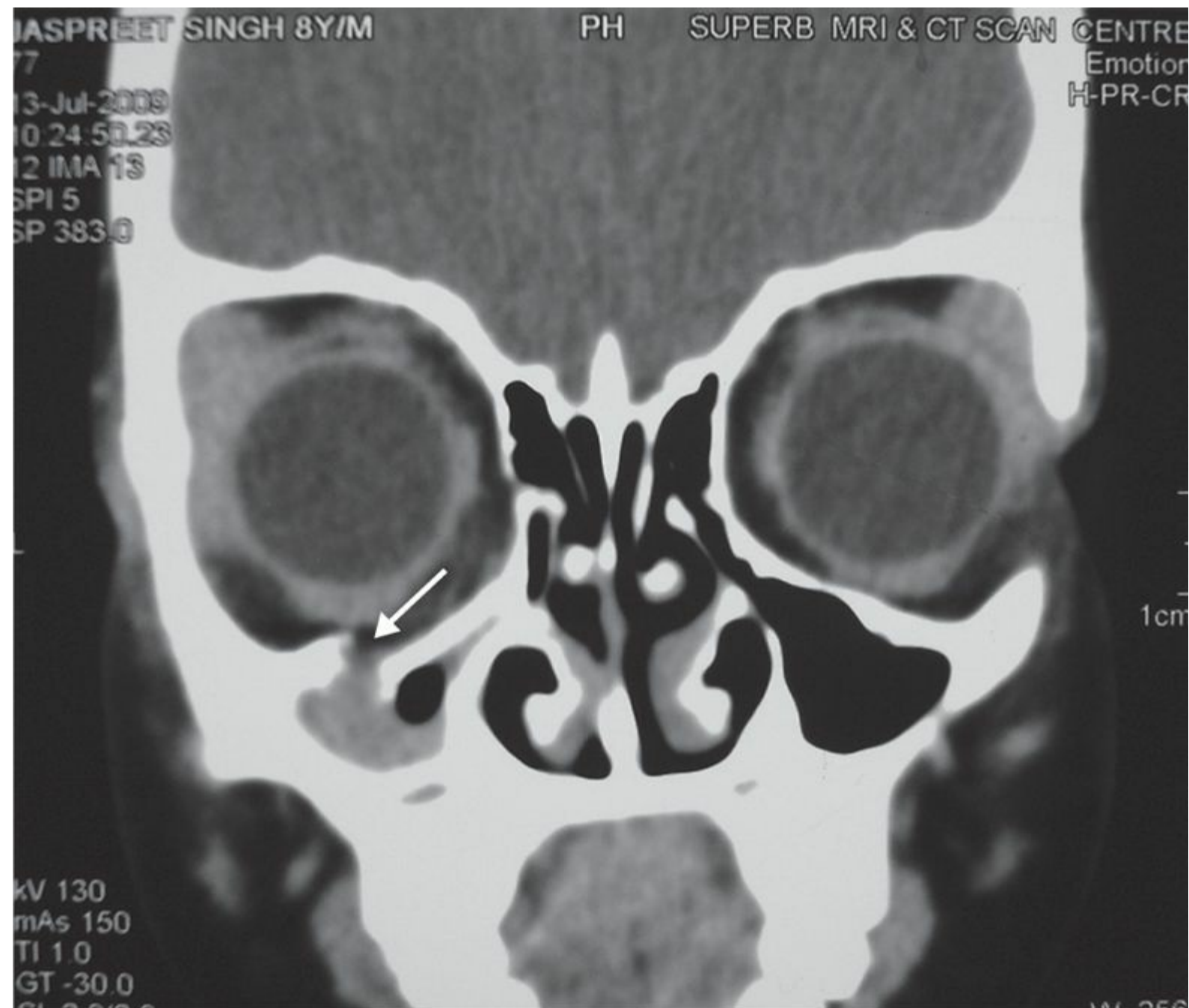
Waters' view shows a convex opacity bulging into the antrum from above (tear-drop opacity). CT scans may confirm the diagnosis (Fig. 34.5). Entrapment of inferior rectus and inferior oblique muscles is diagnosed by asking the patient to look up and down, or by the traction test. The latter is performed by grasping the globe and passively rotating it to check for restriction of its movements.

### Treatment

Indications for surgery include enophthalmos and persistent diplopia due to entrapment of muscle. Orbital floor fractures can be satisfactorily reduced by a finger passed into the antrum through a transantral approach. A pack can be kept in the antrum to support the fragments. Infraorbital approach, through a skin crease of the lower lid, can also be used either alone or in combination with transantral approach. Badly comminuted fractures of orbital floor can be repaired by a bone graft from the iliac crest, nasal septum or the anterior wall of the antrum. Silicon or teflon sheets have also been used to reconstruct the orbital floor but autogenous grafts are preferable.

They are classified into 3 types.

- (a) *Le Fort I (transverse)* fracture runs above and parallel to the palate. It crosses lower part of nasal septum, maxillary antra and the pterygoid plates.
- (b) *Le Fort II (pyramidal)* fracture passes through the root of nose, lacrimal bone, floor of orbit, upper part of maxillary sinus and pterygoid plates. This fracture has some features common with the zygomatic fractures.
- (c) *Le Fort III (craniofacial dysjunction)*. There is complete separation of facial bones from the cranial bones. The fracture line passes through root of nose, ethmoidal junction, superior orbital fissure, lateral wall of orbit, frontozygomatic and temporozygomatic sutures and the upper part of pterygoid plates.



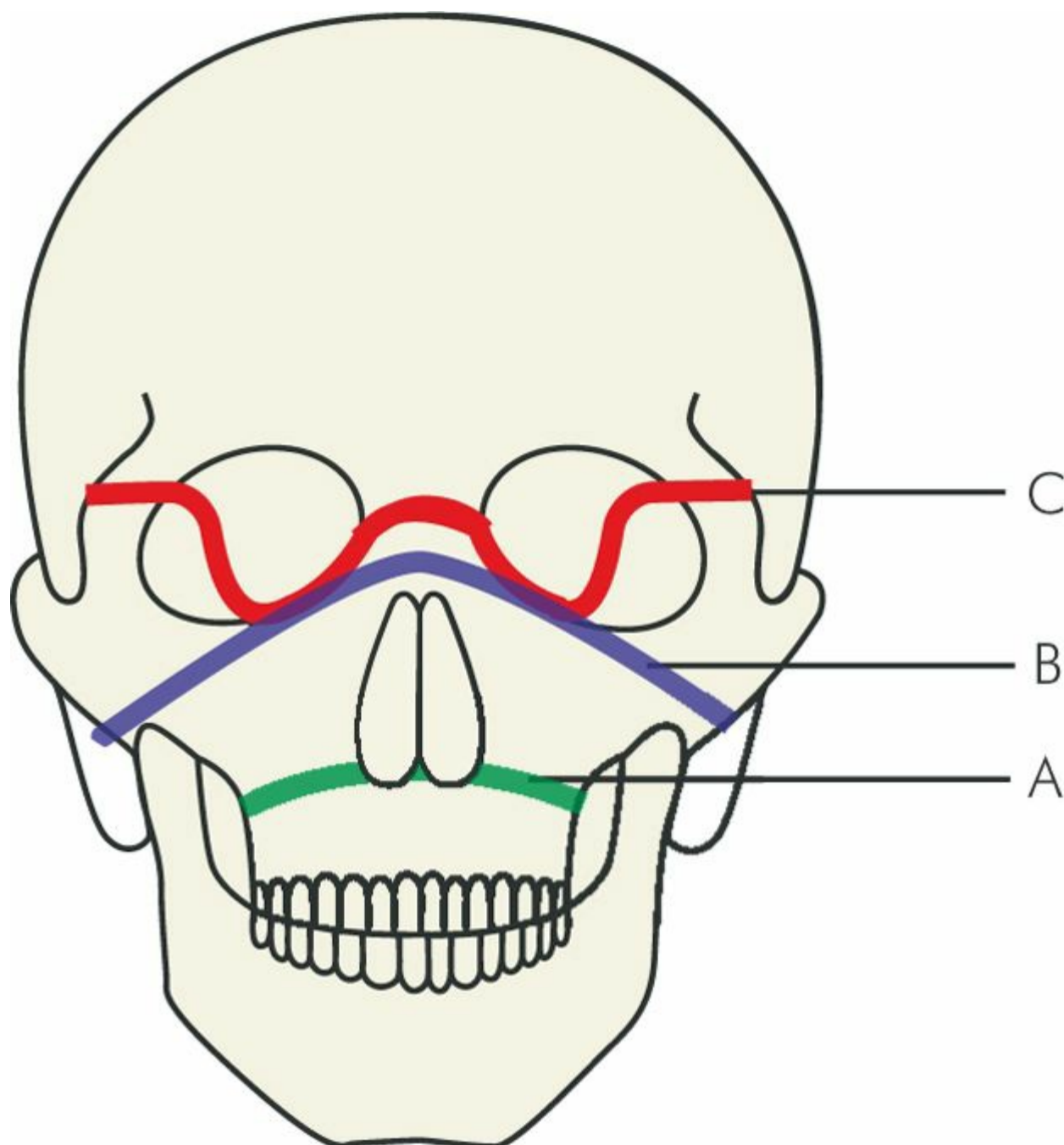
Dhingra: Diseases of Ear Nose and Throat, 5th Edition  
Copyright © 2010 Elsevier. All rights reserved.

Figure 34.5 CT scan showing blow out fracture of right orbital floor.

### Clinical Features

- (a) Malocclusion of teeth with anterior open bite.

- (b) Elongation of midface.
- (c) Mobility in the maxilla.
- (d) CSF rhinorrhoea. Cribriform plate is injured in Le Fort II and Le Fort III fractures.



Dhingra: Diseases of Ear Nose and Throat, 5th Edition  
 Copyright © 2010 Elsevier. All rights reserved.

Figure 34.6 Fractures of maxilla: (A) Le Fort I, (B) Le Fort II, (C) Le Fort III.

## Diagnosis

X-rays, helpful in diagnosis of maxillary fractures are Waters' view, posteroanterior view, lateral view and the CT scans. They help to delineate fracture lines and the displacement of fragments.

## Treatment

Treatment of maxillary fractures is complex. Immediate attention is paid to restore the airway and stop severe haemorrhage from maxillary artery or its branches. For good cosmetic and functional results, fractures should be treated as early as the patient's condition permits. Associated intracranial and cervical spine injuries may delay specific treatment.

Fixation of maxillary fractures can be achieved by:

- (a) Interdental wiring.
- (b) Intermaxillary wiring using arch bars.

- **(c)** Open reduction and interosseous wiring as in zygomatic fractures.
- **(d)** Wire slings from frontal bone, zygoma or infraorbital rim to the teeth or arch bars.

## C. FRACTURES OF LOWER THIRD

### Fractures of Mandible

Fractures of mandible have been classified according to their location (Fig. 34.7). Condylar fractures are the most common. They are followed, in frequency, by fractures of the angle, body and symphysis (mnemonic CABS). Fractures of the ramus, coronoid and alveolar processes are uncommon.

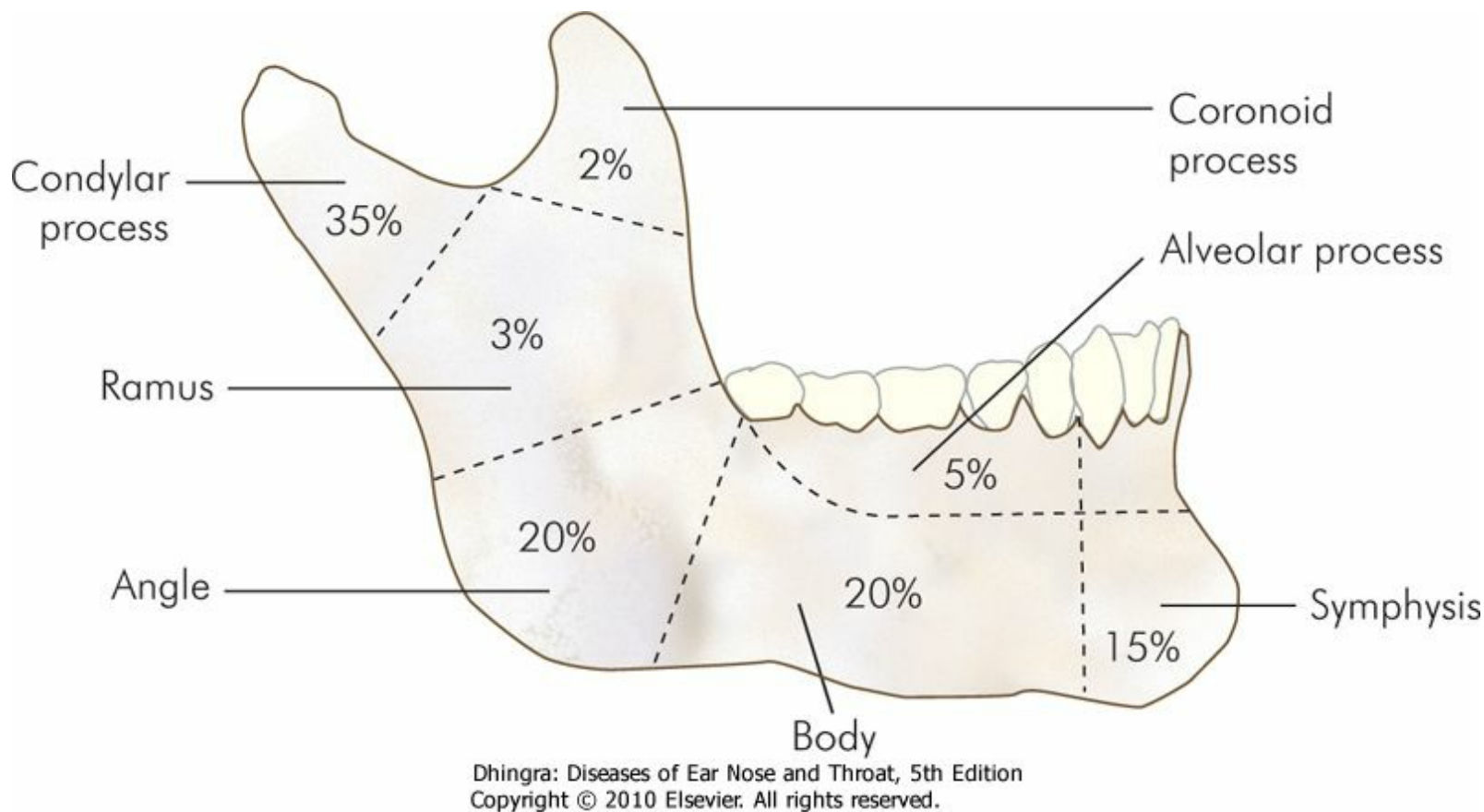


Figure 34.7 Fractures of mandible (Dingman's classification). Condylar fractures are the most common, followed by those of the angle, body and symphysis of mandible. Remember CABS.

page 199

page 200

Multiple fractures are seen as frequently as single ones. Most of the mandibular fractures are the result of direct trauma; however, condylar fractures are caused by indirect trauma to the chin or opposite side of the body of mandible. Displacement of mandibular fractures is determined by (i) the pull of muscles attached to the fragments, (ii) direction of fracture line and (iii) bevel of the fracture.

### Clinical Features

In fractures of condyle, if fragments are not displaced, pain and trismus are the main features and tenderness is elicited at the site of fracture. If fragments are displaced, there is in addition, malocclusion of teeth and deviation of jaw to the opposite side on opening the mouth.

Most of the fractures of angle, body and symphysis, can be diagnosed by intraoral and extraoral palpation. Step-deformity, malocclusion of teeth, ecchymosis of oral mucosa, tenderness at the site of fracture and crepitus may be seen.

### Diagnosis

X-rays useful in mandibular fractures are PA view of the skull (for condyle), right and left oblique views of mandible and the panorex view.

### Treatment

Both closed and open methods are used for reduction and fixation of the mandibular fractures.

In closed methods, interdental wiring and intermaxillary fixation are useful. External pin fixation can also be used.

In the open methods, fracture site is exposed and fragments fixed by direct interosseous wiring. This is further strengthened by a wire tied in a figure of eight manner. These days, compression plates are available to fix the fragments. With their use, prolonged immobilisation and intermaxillary fixation can be avoided.

Condylar fractures are also treated by intermaxillary fixation with arch bars and rubber bands. Sometimes, open reduction and interosseous wiring may be required in adult edentulous patients with bilateral condylar fractures or in fractures of children.

Immobilisation of mandible beyond three weeks, in condylar fractures, can cause ankylosis of temporomandibular joints. Therefore, intermaxillary wires are removed and jaw exercises started. If occlusion is still disturbed, intermaxillary wires are reapplied for another week and the process repeated till the bite and jaw movements are normal.

# OROANTRAL FISTULA

It is a communication between the antrum and oral cavity. The fistulous opening may be situated on the alveolus or gingivolabial sulcus.

## Aetiology

- **1. Dental extraction.** This is the most important cause. Roots of second premolar and upper molars (first and sometimes 2nd and 3rd) are closely related to the antral cavity and their extraction may lead to fistula formation. Presence of apical tooth abscess predisposes to it.
- **2. Failure of sublabial incision to heal after Caldwell-Luc operation.**
- **3. Erosion of antrum by carcinoma.**
- **4. Fractures or penetrating injuries of maxilla.**
- **5. Osteitis of maxilla, syphilis or malignant granuloma.**

## Clinical Features

- **1. Regurgitation of food.** Food or fluids pass from oral cavity into the antrum and thence into the nose.
- **2. Discharge.** Antrum is always infected. Foul-smelling discharge is seen, filling the nose or exuding from the fistulous opening into the mouth.
- **3. Inability to build positive or negative pressure in the mouth.** Patient will have difficulty to blow the wind instruments or drink through a straw. To drink through a straw, negative pressure has to be created in the oral cavity. This cannot be done in the presence of an oroantral fistula as air gets drawn from nose to antrum to oral cavity. Reverse is true when blowing wind instruments; instead of building a positive pressure in the oral cavity, air is blown out from the oral cavity to antrum and out through the nose.

## Diagnosis

A probe can be passed from the fistulous opening in the oral cavity into the antrum.

## Treatment

*Recent fistula.* When fistula is discovered immediately after tooth extraction, and there is no infection or a retained tooth in the antrum, conservative treatment with suturing of gum margins and a course of antibiotics is effective.

*Chronic fistula or a large fistula.* It requires surgical repair by a palatal or a buccal flap. Maxillary sinusitis is first treated by repeated irrigations and antibiotics. Squamous-lined fistulous track is excised, bony edges of the fistula are smoothed and prepared for the flaps to sit properly. Caldwell-Luc operation may be required to remove a retained tooth root or a foreign body, clear the antrum of diseased mucosa and to provide a nasoantral window for free drainage. Some fistulas are better closed by a dental obturator. The latter also permits observation of antral cavity particularly in those treated for cancer.



## 35 Anatomy and Physiology of Paranasal Sinuses

### ANATOMY OF PARANASAL SINUSES

Paranasal sinuses are air-containing cavities in certain bones of skull. They are four on each side.

Clinically, paranasal sinuses have been divided into two groups:

*Anterior group.* This includes maxillary, frontal and anterior ethmoidal. They all open in the middle meatus and their ostia lie anterior to basal lamella of middle turbinate.

*Posterior groups.* This includes posterior ethmoidal sinuses which open in the superior meatus, and the sphenoid sinus which open in sphenoidal recess.

## Maxillary Sinus (Antrum of Highmore)

It is the largest of paranasal sinuses and occupies the body of maxilla. It is pyramidal in shape with base towards lateral wall of nose and apex directed laterally into the zygomatic process of maxilla and sometimes in the zygomatic bone itself (Fig. 35.1). On an average, maxillary sinus has a capacity of 15 ml in an adult.

# Relations

*Anterior wall* is formed by facial surface of maxilla and is related to the soft tissues of cheek.

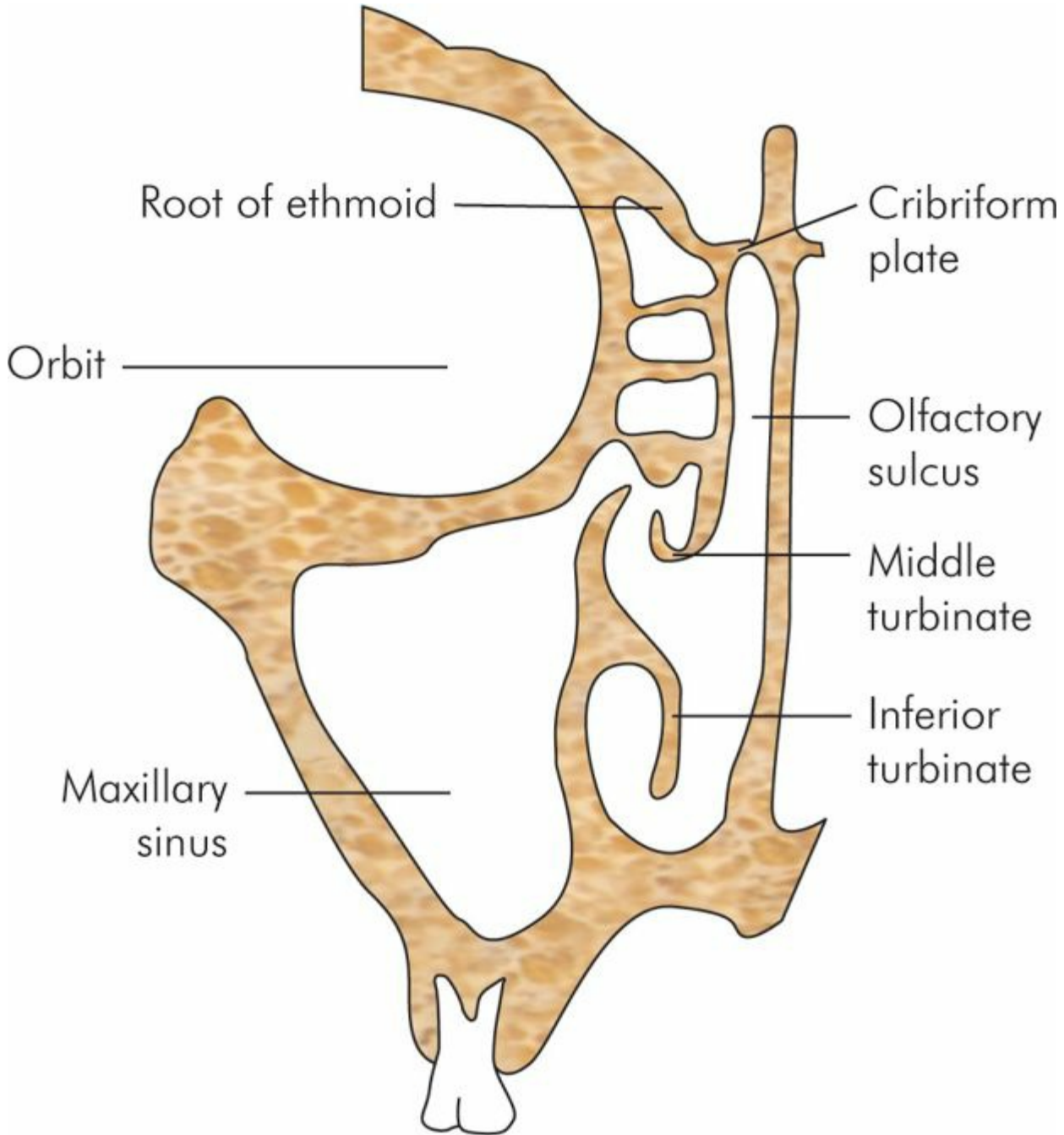
*Posterior wall* is related to infratemporal and pterygopalatine fossae.

*Medial wall* is related to the middle and inferior meatuses. At places, this wall is thin and membranous. It is related to uncinete process, anterior and posterior fontanelle, and inferior turbinate and meatus.

*Floor* is formed by alveolar and palatine processes of the maxilla and is situated about 1 cm below the level of floor of nose (Fig. 35.1). Depending on the age and pneumatization of the sinus, the roots of all the molars, sometimes the premolars and canine, are in close relation to the floor of maxillary sinus separated from it by a thin lamina of bone or even no bone at all. Oroantral fistulae can result from extraction of any of these teeth. Dental infection is also an important cause of maxillary sinusitis.

Ostium of the maxillary sinus is situated high up in medial wall and opens in the posterior part of ethmoidal infundibulum into the middle meatus. It is unfavourably situated for natural drainage. An accessory ostium is also present behind the main ostium in 30% of cases.

*Roof* of the maxillary sinus is formed by the floor of the orbit. It is traversed by infraorbital nerve and vessels.



Dhingra: Diseases of Ear Nose and Throat, 5th Edition  
Copyright © 2010 Elsevier. All rights reserved.

Figure 35.1 Coronal section showing relationship of maxillary and ethmoidal sinuses to orbit and the nasal cavity.

## Frontal Sinus

Each frontal sinus is situated between the inner and outer tables of frontal bone, above and deep to the supraorbital margin. It varies in shape and size and is often loculated. The two frontal sinuses are often asymmetric and the intervening bony septum is thin and often obliquely placed or may even be deficient. Frontal sinus may be absent on one or both sides or it may be very large extending into orbital plate in the roof of the orbit.

*Anterior wall* of the sinus is related to the skin over the forehead; *inferior wall*, to the orbit and its contents; and *posterior wall* to the meninges and frontal lobe of the brain. Opening of frontal sinus is situated in its floor and leads into the middle meatus directly or through a canal called frontonasal duct. In the middle meatus, frontal sinus drains into frontal recess (55%), above but not into the infundibulum (30%), into the infundibulum (15%) and above the bulla ethmoidalis (1%).

## Ethmoidal Sinuses (Ethmoid Air Cells)

Ethmoidal sinuses are thin-walled air cavities in the lateral masses of ethmoid bone. Their number varies from 3 to 18. They occupy the space between upper third of lateral nasal wall and the medial wall of orbit. Clinically, ethmoidal cells are divided into *anterior ethmoid group* which opens into the middle meatus, and *posterior ethmoid group* which opens into the superior meatus and sphenoidal recess.

Each ethmoid labyrinth has important relations. Roof is formed by anterior cranial fossa, lateral to the cribriform plate. Meninges of brain form important relations here. Lateral wall is related to the orbit. The thin paper-like lamina of bone (*lamina papyracea*) separating air cells from the orbit can be easily destroyed leading to spread of ethmoidal infections into the orbit. Optic nerve forms close relationship with the posterior ethmoidal cells and is at risk during ethmoid surgery.

## Sphenoid Sinus

It occupies the body of sphenoid. The two, right and left sinuses, are rarely symmetrical and are separated by a thin bony septum which is often obliquely placed and may even be deficient (compare frontal sinus). Ostium of the sphenoid sinus is situated in the upper part of its anterior wall and drains into sphenoidal recess.

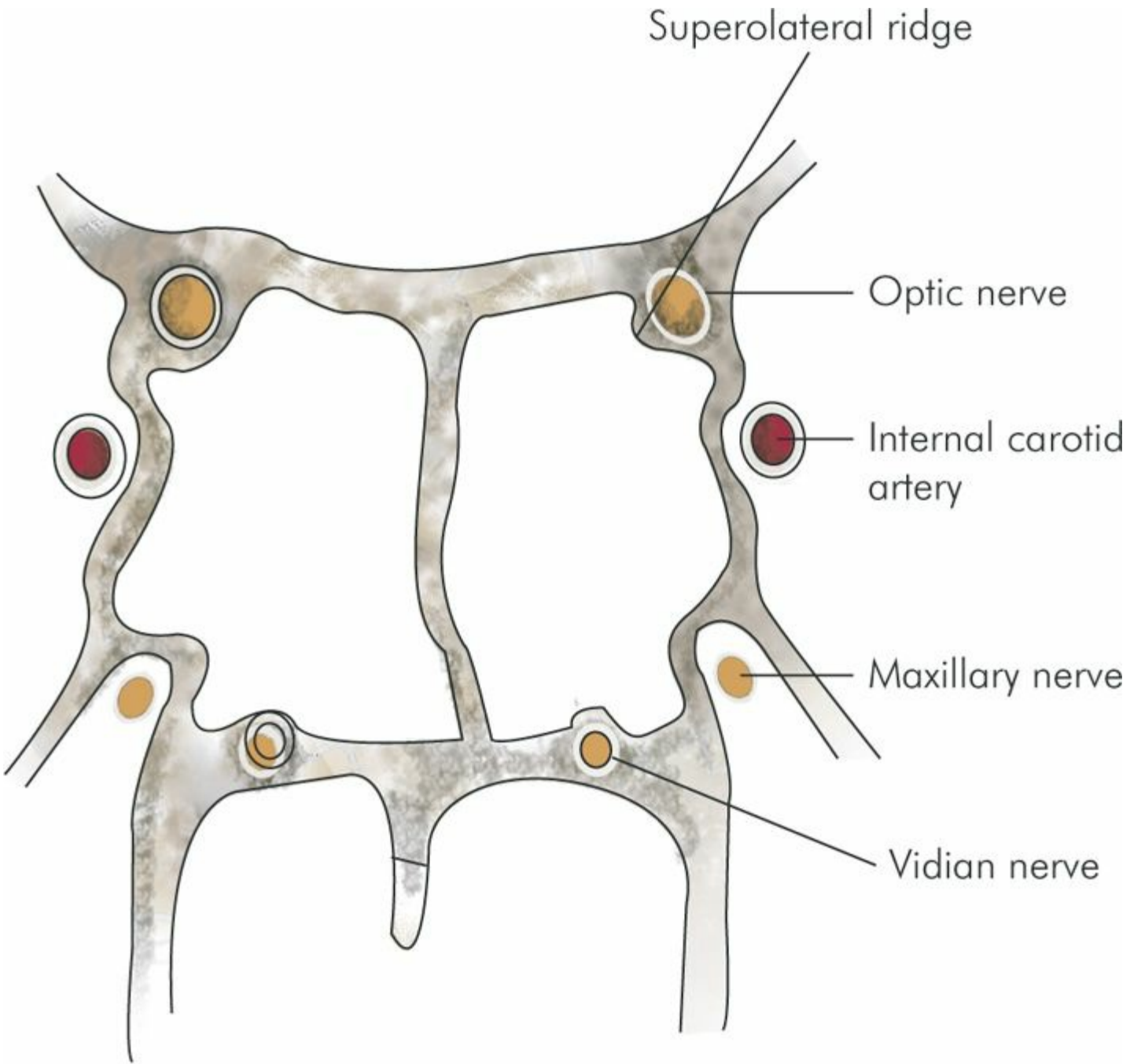
Relations of the sphenoid sinus are important to the surgeon while doing trans-sphenoidal hypophysectomy. They are depicted in Fig. 35.2. The relations of the sinus differ in the anterior and posterior parts.

In the *anterior part*, roof is related to the olfactory tract, optic chiasma and frontal lobe while the lateral wall is related to the optic nerve, internal carotid artery and maxillary nerve and these structures may stand in relief in the sinus cavity.

In the *posterior part*, roof is related to pituitary gland in the sella turcica while each lateral wall is related to cavernous sinus, internal carotid artery and CN III, IV, VI and all the divisions of V (Fig. 35.3).

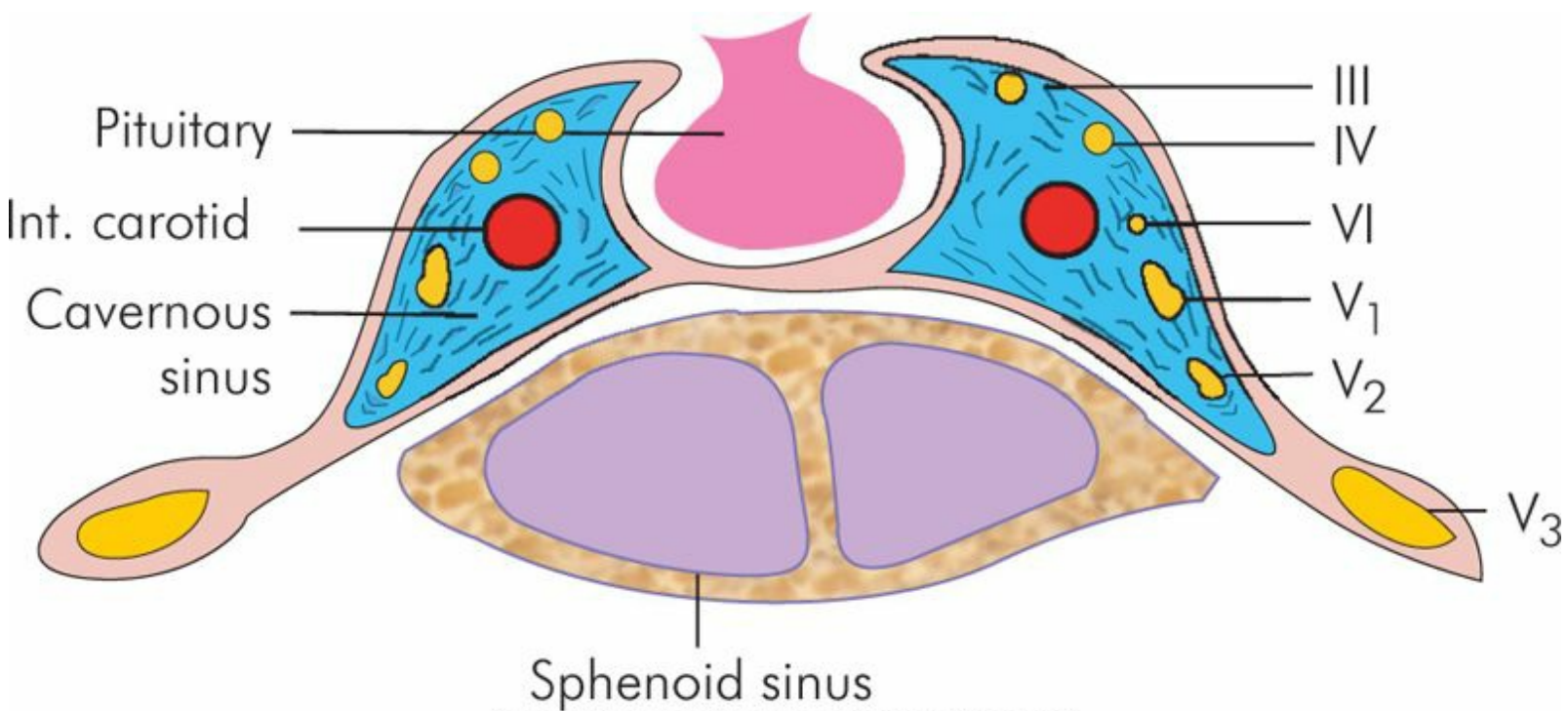
Degree of pneumatization of sphenoid sinus varies and so do the extent of sinus and the structures related to it. Sinus cavity may be large and extend into the wings of sphenoid and even pterygoid plates.

Mucous Membrane of Paranasal Sinuses



Dhingra: Diseases of Ear Nose and Throat, 5th Edition  
Copyright © 2010 Elsevier. All rights reserved.

Figure 35.2 Coronal section of sphenoid sinuses. Note the reliefs made by various structures in the cavity of sphenoid sinus. Optic nerve forms the superolateral ridge.



Dhingra: Diseases of Ear Nose and Throat, 5th Edition  
 Copyright © 2010 Elsevier. All rights reserved.

Figure 35.3 Relations of sphenoid sinus.

Paranasal sinuses are lined by mucous membrane which is continuous with that of the nasal cavity through the ostia of sinuses. It is thinner and less vascular compared to that of the nasal cavity. Histologically, it is ciliated columnar epithelium with goblet cells which secrete mucus. Cilia are more marked near the ostia of sinuses and help in drainage of mucus into the nasal cavity.



## Development of Paranasal Sinuses

Paranasal sinuses develop as outpouchings from the mucous membrane of lateral wall of nose. At birth, only the maxillary and ethmoidal sinuses are present and are large enough to be clinically significant.

Growth of sinuses continues during childhood and early adult life. Radiologically, maxillary sinuses can be identified at 4-5 months, ethmoids at 1 year, frontals at 6 years and sphenoids at 4 (Table 35.1).

## Lymphatic Drainage

The lymphatics of maxillary, ethmoid, frontal and sphenoid sinuses form a capillary network in their lining mucosa and collect with lymphatics of nasal cavity. Then they drain into lateral retropharyngeal and/or jugulodigastric nodes.

# PHYSIOLOGY OF PARANASAL SINUSES

## Ventilation of Sinuses

Ventilation of paranasal sinuses takes place through their ostia. During inspiration, air current causes negative pressure in the nose. This varies from -6 mm to -200 mm of H<sub>2</sub>O, depending on the force of inspiration. During expiration, positive pressure is created in the nose and this sets up eddies which ventilate the sinuses. Thus, ventilation of sinuses is paradoxical; they are emptied of air during inspiration and filled with air during expiration. This is just the reverse of what takes place in lungs which fill during inspiration and empty during expiration.

## Mucus Drainage of Sinuses

Mucus secreted in the paranasal sinuses travels to the ostium in a spiral manner. Here the cilia are very active and propel mucus into the meatuses from where it is carried to the pharynx. The mucus from anterior groups of sinuses travels along the respective lateral pharyngeal gutter situated behind the posterior pillar, and that from posterior group is spread over the posterior pharyngeal wall to be finally swallowed. In infections of the anterior group of sinuses, lateral lymphoid bands, situated behind the posterior pillars, get hypertrophied.

# Functions of Paranasal Sinuses

It is not clear why nature provided paranasal sinuses. Probable functions are:

- 1. Air-conditioning of the inspired air by providing large surface area over which the air is humidified and warmed.
- 2. To provide resonance to voice.
- 3. To act as thermal insulators to protect the delicate structures in the orbit and the cranium from variations of intranasal temperature.
- 4. To lighten the skull bones.

**Table 35-1. Development and growth of paranasal sinuses**

	Status at birth	Growth	First radiologic evidence
Maxillary	Present at birth	Rapid growth from birth to 3 years and from 7-12 years. Adult size - 15 years	4-5 months after birth
Ethmoid	Present at birth	Reach adult size by 12 years	1 year
	Anterior group: 5 × 2 × 2 mm.		
	Posterior group: 5 × 4 × 2 mm.		
Frontal	Not present	Invades frontal bone at the age of 4 years. Size increases until teens	6 years
Sphenoid	Not present	Reaches sella turcica by the age of 7 years, dorsum sellae by late teens and basisphenoid by adult age. Reaches full size between 15 years to adult age	4 years

## 36 Acute Sinusitis

Acute inflammation of sinus mucosa is called *acute sinusitis*. The sinus most commonly involved is the maxillary followed in turn by ethmoid, frontal and sphenoid. Very often, more than one sinus is infected (*multisinusitis*). Sometimes, all the sinuses of one or both sides are involved simultaneously (*pansinusitis* unilateral or bilateral).

Sinusitis may be 'open' or 'closed' type depending on whether the inflammatory products of sinus cavity can drain freely into the nasal cavity through the natural ostia or not. A 'closed' sinusitis causes more severe symptoms and is also likely to cause complications.

# AETIOLOGY OF SINUSITIS IN GENERAL

## A. Exciting Causes

- **1. *Nasal infections.*** Sinus mucosa is a continuation of nasal mucosa and infections from nose can travel directly by continuity or by way of submucosal lymphatics. Most common cause of acute sinusitis is viral rhinitis followed by bacterial invasion.
- **2. *Swimming and diving.*** Infected water can enter the sinuses through their ostia. High content of chlorine gas in swimming pools can also set up chemical inflammation.
- **3. *Trauma.*** Compound fractures or penetrating injuries of sinuses-frontal, maxillary and ethmoid-may permit direct infection of sinus mucosa. Similarly, barotrauma may be followed by infection.
- **4. *Dental infections.*** This applies to maxillary sinus. Infection from the molar or premolar teeth or their extraction may be followed by acute sinusitis.

## B. Predisposing Causes

### Local

- **1. Obstruction to sinus ventilation and drainage.** Normally, sinuses are well-ventilated. They also secrete small amount of mucus, which by ciliary movement, is directed towards the sinus ostia from where it drains into the nasal cavity. Any factor(s) which interfere with this function can cause sinusitis due to stasis of secretions in the sinus. They are:
  - (a) Nasal packing
  - (b) Deviated septum
  - (c) Hypertrophic turbinates
  - (d) Oedema of sinus ostia due to allergy or vasomotor rhinitis
  - (e) Nasal polypi
  - (f) Structural abnormality of ethmoidal air cells
  - (g) Benign or malignant neoplasm.
- **2. Stasis of secretions in the nasal cavity.** Normal secretions of nose may not drain into the nasopharynx because of their viscosity (cystic fibrosis) or obstruction (enlarged adenoids, choanal atresia), and get infected.
- **3. Previous attacks of sinusitis.** Local defences of sinus mucosa are already damaged.

### General

*Environment.* Sinusitis is common in cold and wet climate. Atmospheric pollution, smoke, dust and overcrowding also predispose to sinus infection.

*Poor general health.* Recent attack of exanthematous fever (measles, chickenpox, whooping cough), nutritional deficiencies, systemic disorders (diabetes, immune deficiency syndromes).



## Bacteriology

Most cases of acute sinusitis start as viral infections followed soon by bacterial invasion. The bacteria most often responsible for acute suppurative sinusitis are *Strept. pneumoniae*, *H. influenzae*, *Moraxella catarrhalis*, *Strept. pyogenes*, *Staph. aureus* and *Kleb. pneumoniae*. Anaerobic organisms and mixed infections are seen in sinusitis of dental origin.

## **PATHOLOGY OF SINUSITIS**

Acute inflammation of sinus mucosa causes hyperaemia, exudation of fluid, outpouring of polymorphonuclear cells and increased activity of serous and mucous glands. Depending on the virulence of organisms, defences of the host and capability of the sinus ostium to drain the exudates, the disease may be mild (non-suppurative) or severe (suppurative). Initially, the exudate is serous; later it may become mucopurulent or purulent. Severe infections cause destruction of mucosal lining. Failure of ostium to drain results in empyema of the sinus and destruction of its bony walls leading to complications. Dental infections are very fulminating and soon result in suppurative sinusitis.

Infections of individual sinuses are dealt with in this chapter.

# ACUTE MAXILLARY SINUSITIS

## Aetiology

- 1. Most commonly, it is viral rhinitis which spreads to involve the sinus mucosa. This is followed by bacterial invasion.
- 2. Diving and swimming in contaminated water.
- 3. Dental infections are important source of maxillary sinusitis. Roots of premolar and molar teeth are related to the floor of sinus and may be separated only by a thin layer of mucosal covering. Periapical dental abscess may burst into the sinus; or the root of a tooth, during extraction, may be pushed into the sinus. In case of oroantral fistula, following tooth extraction, bacteria from oral cavity enter the maxillary sinus.
- 4. Trauma to the sinus such as compound fractures, penetrating injuries or gun shot wounds may be followed by sinusitis.

## Predisposing factors

One or more of the predisposing factors enumerated for sinusitis in general may be responsible for acute or recurrent infection.

## Clinical Features

Clinical features depend on (a) severity of inflammatory process and (b) efficiency of ostium to drain the exudates. Closed ostium sinusitis is of greater severity and leads more often to complications.

- 1. *Constitutional symptoms* consist of fever, general malaise and body ache. They are the result of toxæmia.
- 2. *Headache*. Usually, this is confined to forehead and may thus be confused with frontal sinusitis.
- 3. *Pain*. Typically, it is situated over the upper jaw, but may be referred to the gums or teeth. For this reason patient may primarily consult a dentist. Pain is aggravated by stooping, coughing or chewing. Occasionally, pain is referred to the ipsilateral supraorbital region and thus may simulate frontal sinus infection.
- 4. *Tenderness*. Pressure or tapping over the anterior wall of antrum produces pain.
- 5. *Redness and oedema of cheek*. Commonly seen in children. The lower eyelid may become puffy.
- 6. *Nasal discharge*. Anterior rhinoscopy shows pus or mucopus in the middle meatus. Mucosa of the middle meatus and turbinate may appear red and swollen.  
*Postural test*. If no pus seen in the middle meatus, it is decongested with a pledget of cotton soaked with a vasoconstrictor and the patient is made to sit with the affected sinus turned up. Examination after 10-15 minutes may show discharge in the middle meatus.
- 7. *Post nasal discharge*. Pus may be seen on the upper soft palate on posterior rhinoscopy.

## Diagnosis

*Transillumination test*. Affected sinus will be found opaque.

*X-rays*. Waters' view will show either an opacity or a fluid level in the involved sinus. CT scan is the preferred imaging modality to investigate the sinuses.

## Treatment

### Medical

- 1. *Antimicrobial drugs*. Ampicillin and amoxicillin are quite effective and cover a wide range of organisms. Erythromycin or doxycycline or cotrimoxazole are equally effective and can be given to those who are sensitive to penicillin.  $\beta$ -lactamase-producing strains of *H. influenzae* and *M. catarrhalis* may necessitate the use of amoxicillin/clavulanic acid or cefuroxime axetil. Sparfloxacin is also effective, and has the advantage of single daily dose.
- 2. *Nasal decongestant drops*. 1% ephedrine or 0.1% xylo- or oxymetazoline are used as nasal drops or sprays to decongest sinus ostium and encourage drainage.
- 3. *Steam inhalation*. Steam alone or medicated with menthol or Tr. Benzoin Co. provides symptomatic relief and encourages sinus drainage. Inhalation should be given 15 to 20 minutes after nasal decongestion for better penetration.
- 4. *Analgesics*. Paracetamol or any other suitable analgesic should be given for relief of pain and headache.
- 5. *Hot fomentation*. Local heat to the affected sinus is often soothing and helps in the resolution of inflammation.

### Surgical

#### Antral lavage

Most cases of acute maxillary sinusitis respond to medical treatment. Lavage is rarely necessary. It is done only when medical treatment has failed and that too only under cover of antibiotics.

## Complications

- 1. Acute maxillary sinusitis may change to *subacute or chronic sinusitis*.
- 2. *Frontal sinusitis*. Frontonasal duct which opens in middle meatus is obstructed due to inflammatory oedema.
- 3. *Osteitis or osteomyelitis* of the maxilla.
- 4. *Orbital cellulitis or abscess*. Infection spreads to the orbit either directly, from the roof of maxillary sinus or indirectly, after involvement of ethmoid sinuses.

# ACUTE FRONTAL SINUSITIS

## Aetiology

- 1. Usually follows viral infections of upper respiratory tract followed later by bacterial invasion.
- 2. Entry of water into the sinus during diving or swimming.
- 3. External trauma to the sinus, e.g. fractures or penetrating injuries.
- 4. Oedema of middle meatus, secondary to associated ipsilateral maxillary or ethmoid sinus infection.

Predisposing factors, pathology and bacteriology are the same as in acute sinusitis in general.

## Clinical Features

- 1. *Frontal headache*. Usually severe and localised over the affected sinus. It shows characteristic periodicity, i.e. comes up on waking, gradually increases and reaches its peak by about mid day and then starts subsiding. It is also called "office headache" because of its presence only during the office hours.
- 2. *Tenderness*. Pressure upwards on the floor of frontal sinus, just above the medial canthus, causes exquisite pain. It can also be elicited by tapping over the anterior wall of frontal sinus in the medial part of supraorbital region.
- 3. *Oedema of upper eyelid* with suffused conjunctiva and photophobia.
- 4. *Nasal discharge*. A vertical streak of mucopus is seen high up in the anterior part of the middle meatus. This may be absent if the ostium is closed with no drainage. Nasal mucosa is inflamed in the middle meatus.

*X-rays*. Opacity of the affected sinus or fluid level can be seen. Both Waters' and lateral views should be taken. CT scan is the preferred modality.

## Treatment

### Medical

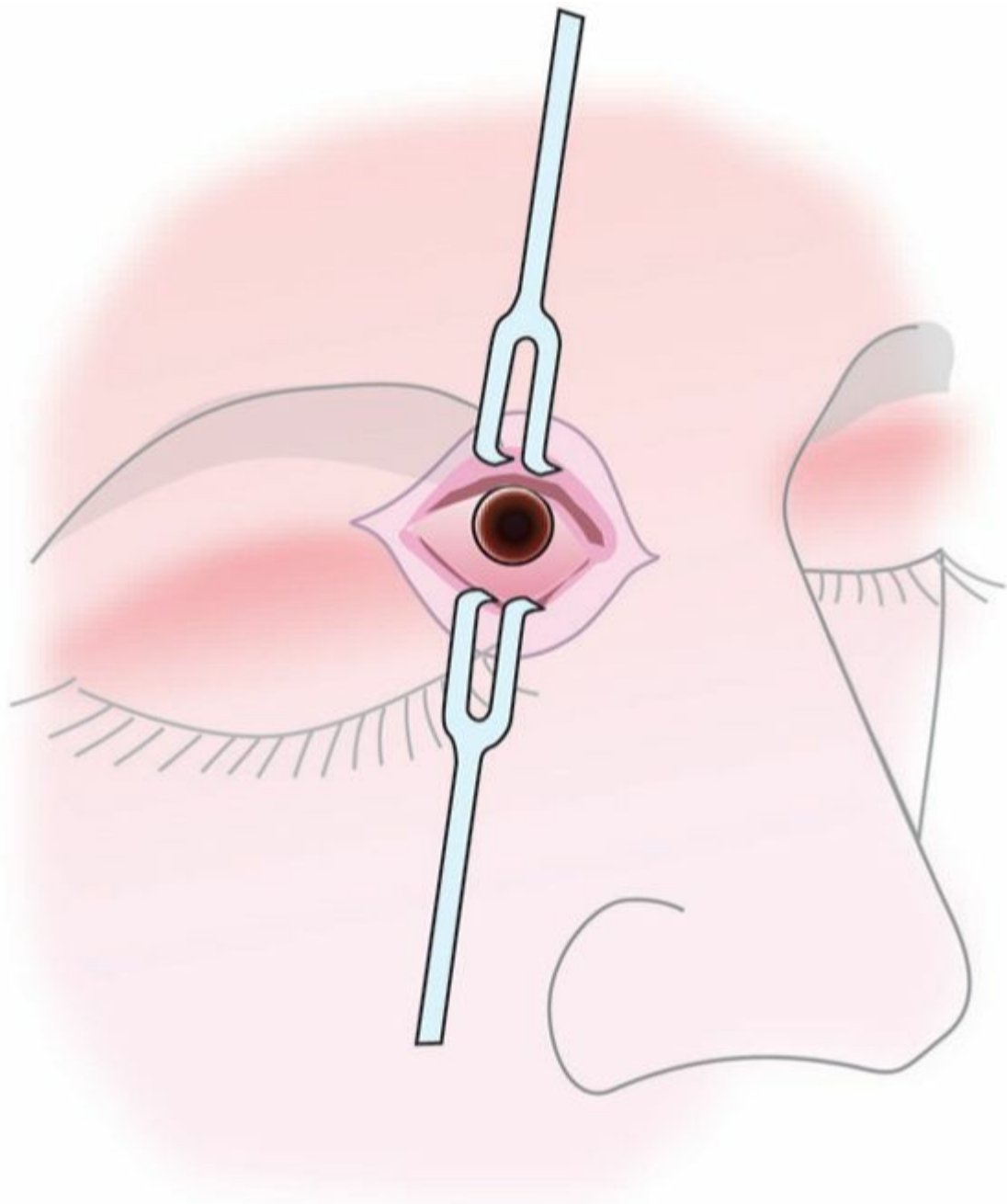
This is same as for acute maxillary sinusitis, i.e. antimicrobials, decongestion of the sinus ostium for drainage and analgesics. A combination of antihistaminic with an oral nasal decongestant (pseudoephedrine or phenylephrine hydrochloride) are useful. Placing a pledget of cotton soaked in a vasoconstrictor in the middle meatus, once or twice daily, helps to relieve ostial oedema and promotes sinus drainage and ventilation. If patient shows response to medical treatment and pain is relieved, treatment is continued for full 10 days to 2 weeks.

### Surgical

- 1. *Trephination of frontal sinus*. If there is persistence or exacerbation of pain or pyrexia in spite of medical treatment for 48 hours, or if the lid swelling is increasing and threatening orbital cellulitis, frontal sinus is drained externally. A 2 cm long horizontal incision is made in the superomedial aspect of the orbit below the eyebrow (Fig. 36.1). Floor of frontal sinus is exposed and a hole drilled with a burr. Pus is taken for culture and sensitivity, and a plastic tube inserted and fixed. Sinus can now be irrigated with normal saline two or three times daily until frontonasal duct becomes patent. This can be determined by adding a few drops of methylene blue to the irrigating fluid and its exit seen through the nose. Drainage tube is removed when frontonasal duct becomes patent.
- 2. *Antral lavage*. Co-existent maxillary sinusitis may require antral lavage. This will encourage frontal sinus drainage by relieving oedema of the middle meatus.

## Complications

- 1. Orbital cellulitis.
- 2. Osteomyelitis of frontal bone and fistula formation.
- 3. Meningitis, extradural abscess or frontal lobe abscess, if infection breaks through the posterior wall of the sinus.
- 4. Chronic frontal sinusitis, if the acute infection is neglected or improperly treated.



Dhingra: Diseases of Ear Nose and Throat, 5th Edition  
Copyright © 2010 Elsevier. All rights reserved.

Figure 36.1 Trephination of right frontal sinus.

# ACUTE ETHMOID SINUSITIS

## Aetiology

Acute ethmoiditis is often associated with infection of other sinuses. Ethmoid sinuses are more often involved in infants and young children.

## Clinical Features

- **1. Pain.** It is localised over the bridge of the nose, medial and deep to the eye. It is aggravated by movements of the eye ball.
- **2. Oedema of lids.** Both eyelids become puffy and swollen. There is increased lacrimation. Orbital cellulitis is an early complication in such cases.
- **3. Nasal discharge.** On anterior rhinoscopy, pus may be seen in middle or superior meatus depending on the involvement of anterior or posterior group of ethmoid sinuses.
- **4. Swelling of the middle turbinate.**

## Treatment

Medical treatment is the same as for acute maxillary sinusitis.

Visual deterioration and exophthalmos indicate abscess in the posterior orbit and may require drainage of the ethmoid sinuses into the nose through an external ethmoidectomy incision.

## Complications

- **1.** Orbital cellulitis and abscess.
- **2.** Visual deterioration and blindness due to involvement of optic nerve.
- **3.** Cavernous sinus thrombosis.
- **4.** Extradural abscess, meningitis or brain abscess.

# ACUTE SPHENOID SINUSITIS

## Aetiology

Isolated involvement of sphenoid sinus is rare. It is often a part of pansinusitis or is associated with infection of posterior ethmoid sinuses.

## Clinical Features

- **1. Headache.** Usually localised to the occiput or vertex. Pain may also be referred to the mastoid region.
- **2. Postnasal discharge.** It can only be seen on posterior rhinoscopy. A streak of pus may be seen on the roof and posterior wall of nasopharynx or above the posterior end of middle turbinate.

*X-rays.* Opacity or fluid level may be seen in the sphenoid sinus. Lateral view of the sphenoid sinus is taken in supine or prone position and is helpful to demonstrate the fluid level.

## Differential Diagnosis

Mucocele of the sphenoid sinus or its neoplasms may clinically simulate features of acute infection of sphenoid sinus and should always be excluded in any case of isolated sphenoid sinus involvement.

*Treatment* is the same as for acute infection of other sinuses.



## 37 Chronic Sinusitis

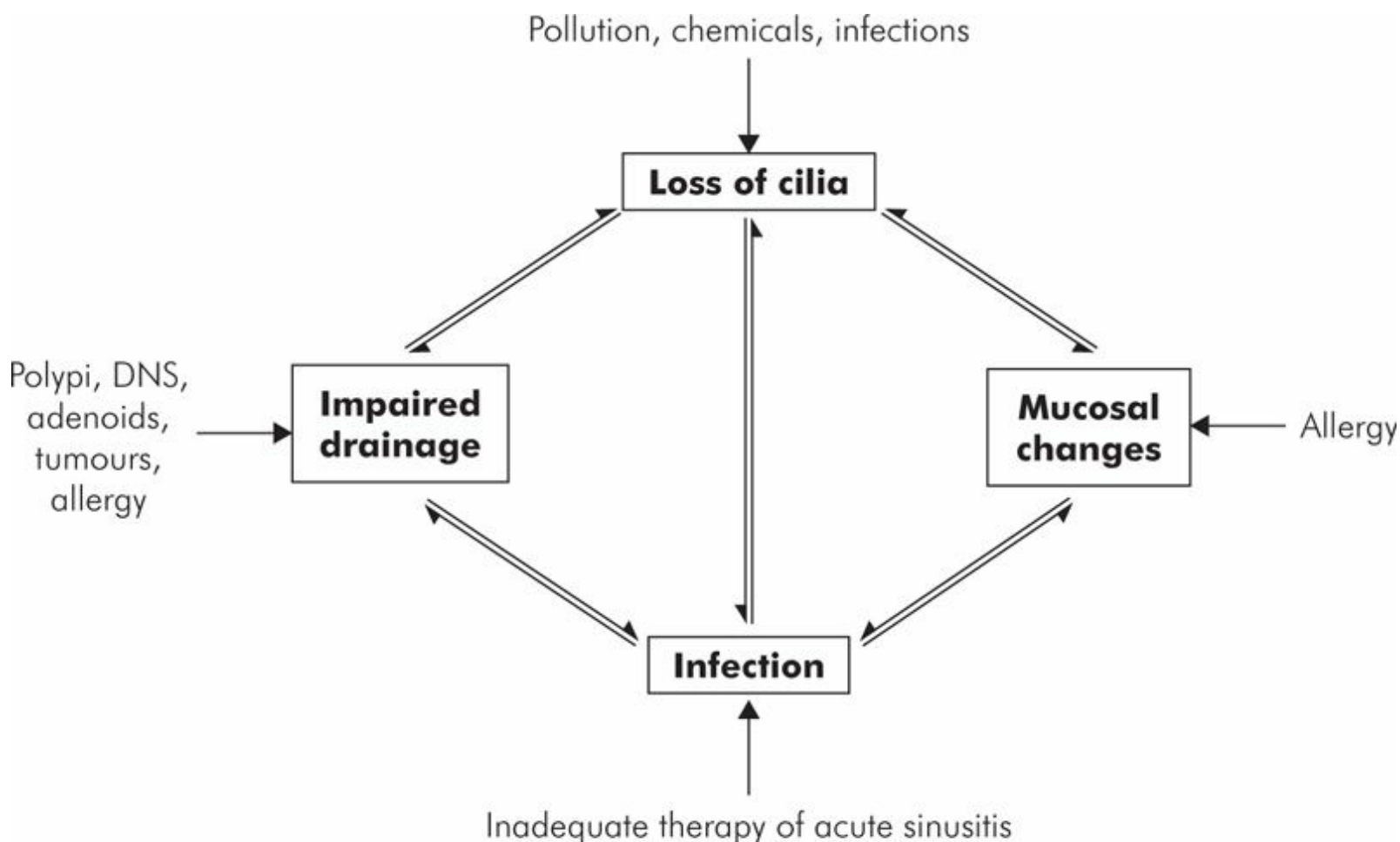
### CHRONIC SINUSITIS IN GENERAL

Sinus infection lasting for months or years is called chronic sinusitis. Most important cause of chronic sinusitis is failure of acute infection to resolve.

#### Pathophysiology

Acute infection destroys normal ciliated epithelium impairing drainage from the sinus. Pooling and stagnation of secretions in the sinus invites infection. Persistence of infection causes mucosal changes, such as loss of cilia, oedema and polyp formation, thus continuing the vicious cycle (Fig. 37.1).

#### Pathology



Dhingra: Diseases of Ear Nose and Throat, 5th Edition  
Copyright © 2010 Elsevier. All rights reserved.

Figure 37.1 Causative factors and pathophysiology of chronic sinusitis.

In chronic infections, process of destruction and attempts at healing proceed simultaneously. Sinus mucosa becomes thick and polypoidal (hypertrophic sinusitis) or undergoes atrophy (atrophic sinusitis). Surface epithelium may show desquamation, regeneration or metaplasia. Submucosa is infiltrated with lymphocytes and plasma cells and may show microabscesses, granulations, fibrosis or polyp formation.

#### Bacteriology

Mixed aerobic and anaerobic organisms are often present.

#### Clinical Features

Clinical features are often vague and similar to those of acute sinusitis but of lesser severity. Purulent nasal discharge is the commonest complaint. Foul-smelling discharge suggests anaerobic infection. Local pain and headache are often not marked except in acute exacerbations. Some patients complain of nasal stuffiness and anosmia.

## Diagnosis

- 1. X-ray of the involved sinus may show mucosal thickening or opacity.
- 2. X-rays after injection of contrast material may show soft tissue changes in the sinus mucosa.
- 3. CT scan is particularly useful in ethmoid and sphenoid sinus infections and has replaced studies with contrast materials.
- 4. Aspiration and irrigation: Finding of pus in the sinus is confirmatory.

## Treatment

It is essential to search for underlying aetiological factors which obstruct sinus drainage and ventilation. A work-up for nasal allergy may be required. Culture and sensitivity of sinus discharge helps in the proper selection of an antibiotic.

Initial treatment of chronic sinusitis is conservative, including antibiotics, decongestants, antihistaminics and sinus irrigations. More often, some form of surgery is required either to provide free drainage and ventilation or radical surgery to remove all irreversible diseases so as to provide wide drainage or to obliterate the sinus.

Recently, endoscopic sinus surgery is replacing radical operations on the sinuses and provides good drainage and ventilation. It also avoids external incisions.

# SURGERY FOR CHRONIC SINUSITIS

## Chronic Maxillary Sinusitis

- **1. *Antral puncture and irrigation.*** Sinus cavity is irrigated with a cannula passed through the inferior meatus. Removal of pus and exudates helps the sinus mucosa to revert to normal.
- **2. *Intranasal antrostomy.*** It is indicated if sinus irrigations fail to resolve infection. A window is created in the inferior meatus to provide aeration to the sinus and its free drainage.
- **3. *Caldwell-Luc operation.*** In this operation, antrum is entered through its anterior wall by a sublabial incision. All irreversible diseases are removed and a window is created between the antrum and inferior meatus.

Details of the above operations are described in the section on operative surgery.

## Chronic Frontal Sinusitis

- **1. Intranasal drainage operations.** Correction of deviated septum, removal of a polyp or anterior portion of middle turbinate, or intranasal ethmoidectomy, provide drainage through the frontonasal duct. Treatment of associated maxillary sinusitis also helps to resolve chronic frontal sinusitis.
- **2. Trephination of frontal sinus** (see page 206).
- **3. External frontoethmoidectomy (Howarth's or Lynch operation).** The frontal sinus is entered through its floor by a curvilinear incision round the inner margin of the orbit. Diseased mucosa is removed, ethmoid cells exenterated and a new frontonasal duct created.
- **4. Osteoplastic flap operation.** It may be unilateral or bilateral. A coronal or a brow incision is used. The anterior wall of frontal sinus is reflected as an osteoplastic flap, based inferiorly. The diseased tissues are removed and the sinus drained through a new frontonasal duct. If it is desired to obliterate the sinus, all diseased as well as healthy mucosa are stripped off and the sinus obliterated with fat.

## Chronic Ethmoid Sinusitis

- **1. Intranasal ethmoidectomy.** This operation is done for chronic ethmoiditis with polyp formation. The ethmoid air cells and the diseased tissue is removed between the middle turbinate and the medial wall of orbit by the intranasal route. The frontal and sphenoid sinuses can also be drained by this operation.
- **2. External ethmoidectomy.** In this operation, ethmoid sinuses are approached through medial orbital incision. Access can also be obtained to sphenoid and frontal sinuses and the operation is called frontospheno-ethmoidectomy.

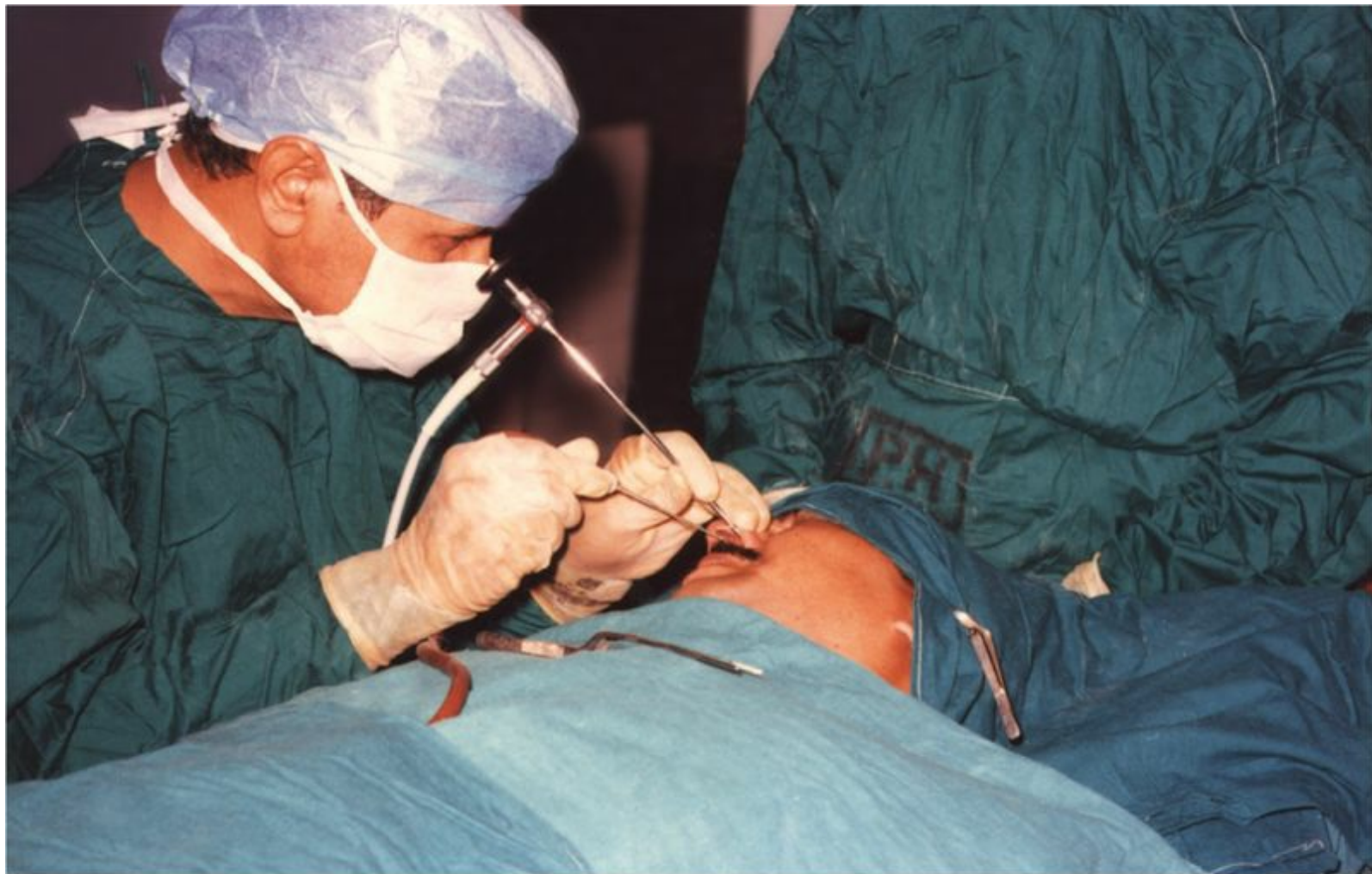## Chronic Sphenoiditis

*Sphenoidotomy.* Access to the sphenoid sinus can be obtained by removal of its anterior wall. This is accomplished by external ethmoidectomy or transseptal approach, usually the former, because of the co-existence of ethmoid disease with chronic sphenoiditis.

Many different species of fungi are found to involve the paranasal sinuses; the more common being the *Aspergillus*, *Alternaria*, *Mucor* or *Rhizopus*. They may involve single or multiple sinuses. Four different varieties of fungal infection of sinuses are seen:

- **1. Fungal ball.** It is due to implantation of fungus into an otherwise healthy sinus which on CT shows a hyperdense area with no evidence of bone erosion or expansion. Maxillary sinus is the most commonly involved followed by sphenoid, ethmoid and the frontal in that order. Treatment is surgical removal of the fungal ball and adequate drainage of the sinus. No antifungal therapy is required.
- **2. Allergic fungal sinusitis.** It is an allergic reaction to the causative fungus and presents with sinu-nasal polyposis and mucin. The latter contains eosinophils, Charcot-Leyden crystals and fungal hyphae. There is no invasion of the sinus mucosa with fungus. Usually more than one sinus are involved on one or both sides. CT scan shows mucosal thickening with hyperdense areas. There may be expansion of the sinus or bone erosion due to pressure, but no fungal invasion. Treatment is endoscopic surgical clearance of the sinuses with provision of drainage and ventilation. This is combined with pre- and post-operative systemic steroids.
- **3. Chronic invasive sinusitis.** Here the fungus invades into the sinus mucosa. There is bone erosion by fungus. Patient presents with chronic rhinosinusitis. CT scan shows thickened mucosa with opacification of sinus and bone erosion. Patient may have intracranial or intraorbital invasion. Histopathology shows fungal invasion of submucosa and granulomatous reaction with multinucleated giant cells. Treatment consists of surgical removal of the involved mucosa, bone and soft tissues followed by antifungal therapy with i.v. amphotericin B. Up to 2-3 g of the drug is given. This is followed by itraconazole therapy for 12 months or more monitored by serial CT or MRI scans.
- **4. Fulminant fungal sinusitis.** It is an acute presentation and is mostly seen in immunocompromised or diabetic individuals. Common fungal species are *Mucor* or *Aspergillus*.

*Mucor* causes rhinocerebral disease. Due to invasion of the blood vessels, mucor fungus causes ischaemic necrosis presenting as a black eschar, involving inferior turbinate, palate or the sinus. It spreads to the face, eye, skull base and the brain. Treatment is surgical debridement of necrotic tissue and i.v. amphotericin B.



Dhingra: Diseases of Ear Nose and Throat, 5th Edition  
Copyright © 2010 Elsevier. All rights reserved.

Figure 37.2 Functional endoscopic surgery of paranasal sinuses.

*Aspergillus* infection can also cause acute fulminant sinusitis with tissue invasion. Such patients present with acute sinusitis and develop sepsis

and other sinus complications. Unlike Mucor infection, there is no black eschar. Treatment is antifungal therapy and surgery.



## Functional Endoscopic Surgery of Sinuses (Fig. 37.2)

Better understanding of the pathophysiology of recurrent and chronic sinusitis and the fact that most of the changes are reversible, if proper drainage and ventilation is provided to the sinuses has, in more recent years, led to the development of endoscopic surgery of sinuses. This has further been made possible by advances in technology, such as development of:

- **(a)** Rigid endoscopes, which provide better illumination and magnification and permit visualisation of structures situated at different angles.
- **(b)** Microsurgical instruments, which permit precise and limited surgery, directed at specific sites, to remove obstruction to the sinus ostia.

Endoscopes can also be passed through a cannula into the maxillary sinus to visualise its interior and take accurate biopsies or deal with certain pathological conditions such as small cysts and polyps.

With endoscopic surgery, it is now possible to cure selected cases of chronic and recurrent infections of the frontal, maxillary, ethmoid and sphenoid sinuses without resort to external operations (see section on Operative Surgery).

## **38 Complications of Sinusitis**

As long as infection is confined only to the sinus mucosa, it is called sinusitis. Complications are said to arise when infection spreads into or beyond the bony wall of the sinus (see Table 38.1 and Fig. 38.1).

## A. LOCAL COMPLICATIONS

### i. Mucocele of Paranasal Sinuses and Mucous Retention Cysts

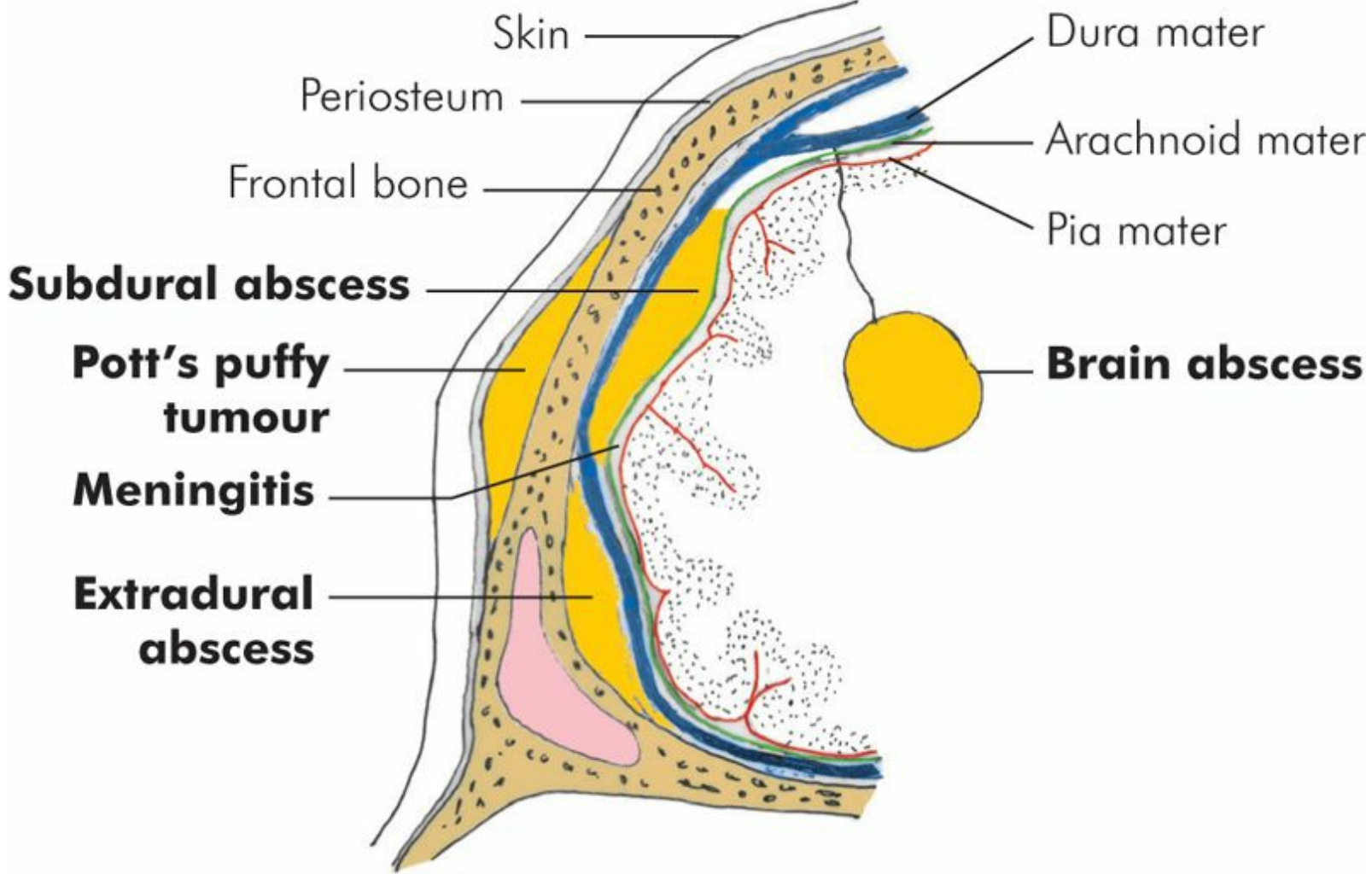
Table 38-1. Complications of paranasal sinus infection

A. Local	<ul style="list-style-type: none"><li>• (i) Mucocele/Mucopyocele</li><li>• (ii) Mucous retention cyst</li><li>• (iii) Osteomyelitis<ul style="list-style-type: none"><li>◦ Frontal bone (more common)</li><li>◦ Maxilla</li></ul></li></ul>
B. Orbital	<ul style="list-style-type: none"><li>• (i) Preseptal inflammatory oedema of lids</li><li>• (ii) Subperiosteal abscess</li><li>• (iii) Orbital cellulitis</li><li>• (iv) Orbital abscess</li><li>• (v) Superior orbital fissure syndrome</li><li>• (vi) Orbital apex syndrome</li></ul>
C. Intracranial	<ul style="list-style-type: none"><li>• (i) Meningitis</li><li>• (ii) Extradural abscess</li><li>• (iii) Subdural abscess</li><li>• (iv) Brain abscess</li><li>• (v) Cavernous sinus thrombosis</li></ul>
D. Descending infections	
E. Focal infections	

The sinuses commonly affected by mucocele in the order of frequency, are the frontal, ethmoidal, maxillary and sphenoidal. There are two views in the genesis of a mucocele:

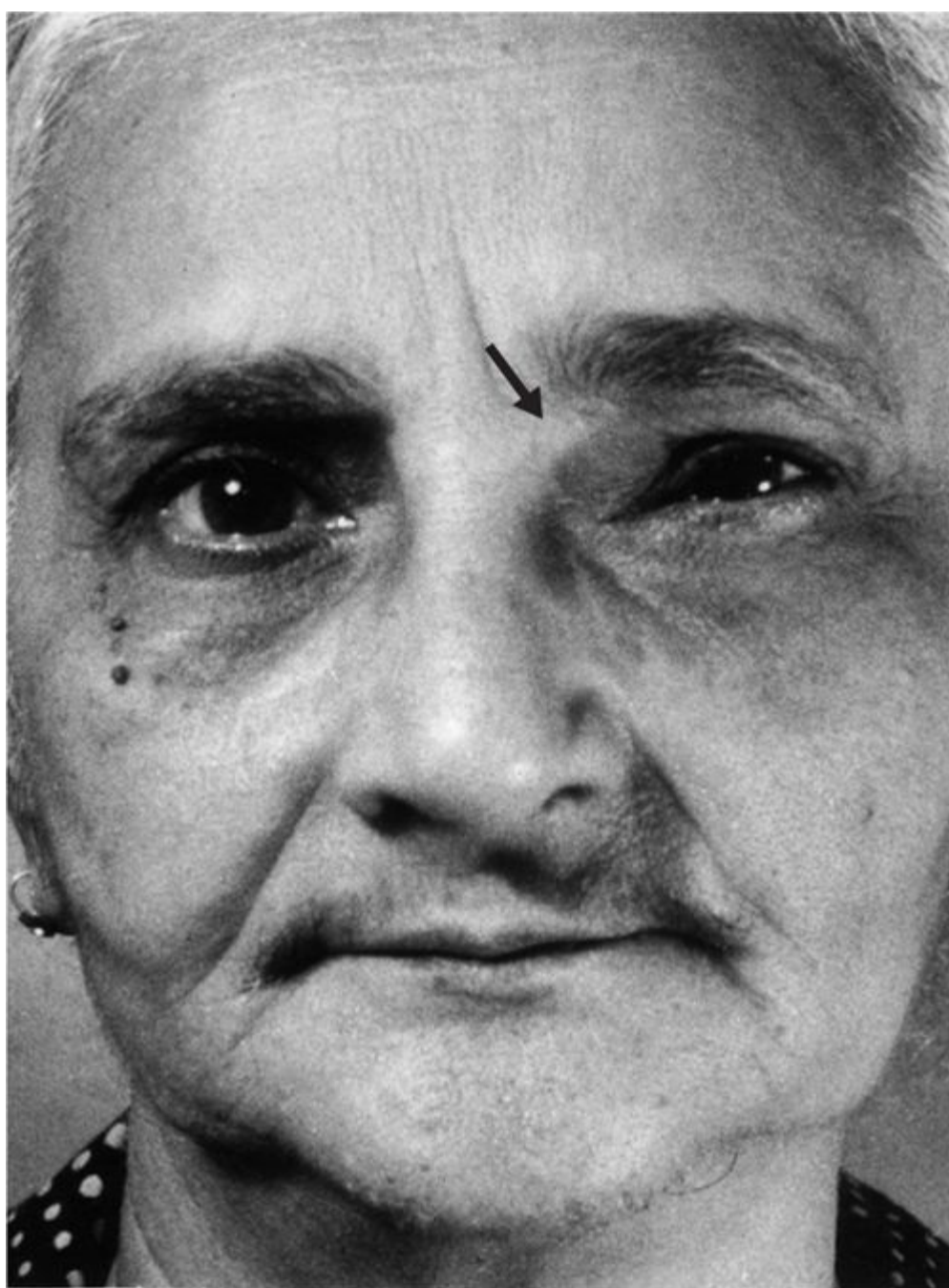
- (i) Chronic obstruction to sinus ostium resulting in accumulation of secretions which slowly expand the sinus and destroy its bony walls.
- (ii) Cystic dilatation of mucous gland of the sinus mucosa due to obstruction of its duct. In this case, wall of mucocele is surrounded by normal sinus mucosa. The contents of mucocele are sterile.

*Mucocele of the frontal sinus* (Fig. 38.2). It usually presents in the superomedial quadrant of the orbit (90%) and displaces the eyeball forward, downward and laterally. The swelling is cystic and non-tender; egg-shell crackling may be elicited. Sometimes, it presents as a cystic swelling in the forehead (10%). Patient's complaints are usually mild and may include headache, diplopia and proptosis. Radiographs of the frontal sinus usually reveal clouding of the sinus with loss of scalloped outline which is so typical of the normal frontal sinus. Treatment is frontoethmoidectomy with free drainage of frontal sinus into the middle meatus.



Dhingra: Diseases of Ear Nose and Throat, 5th Edition  
 Copyright © 2010 Elsevier. All rights reserved.

Figure 38.1 Complications of sinusitis.



Dhingra: Diseases of Ear Nose and Throat, 5th Edition  
Copyright © 2010 Elsevier. All rights reserved.

Figure 38.2 Mucocele of frontal sinus. Note swelling above the medial canthus of left eye (arrow).

*Mucocele of ethmoid sinuses* causes expansion of the medial wall of the orbit, displacing the eyeball forward and laterally. In addition, it may cause a bulge in the middle meatus of nose. A mucocele of the ethmoid can be drained by an intranasal operation, uncapping the ethmoidal bulge and establishing free drainage. Sometimes, it may require external ethmoid operation.

*Mucous retention cyst of the maxillary sinus* presents as a retention cyst due to obstruction of the duct of seromucinous gland and usually does not cause bone erosion. It is asymptomatic and is observed as an incidental finding on radiographs. No treatment is generally required for asymptomatic retention cysts as most of them regress spontaneously over a period of time.

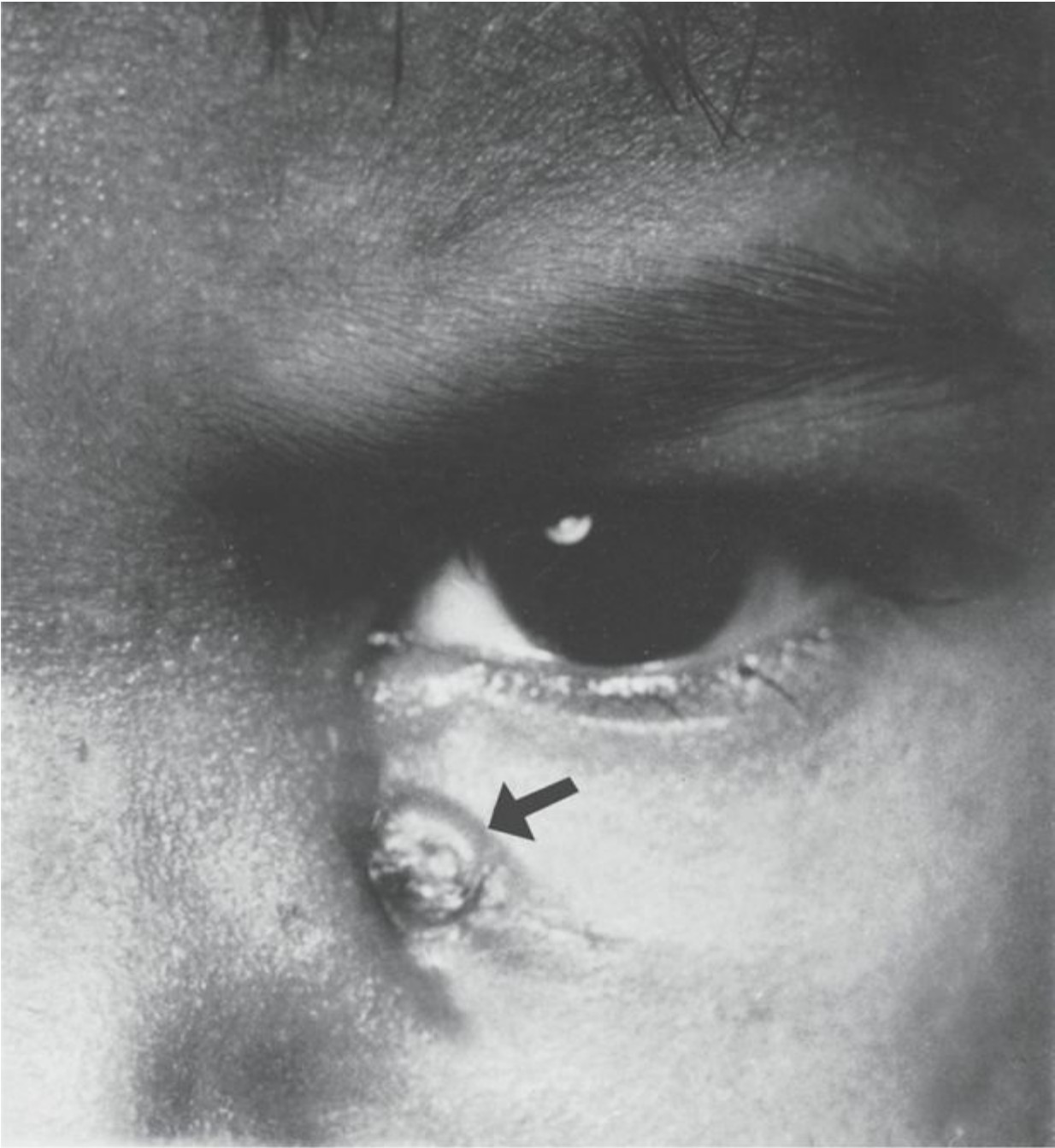
*Mucocele of the maxillary sinus* can occur as a complication of chronic sinus inflammation when its ostium is blocked. The sinus fills with mucus and its bony walls get expanded due to expansile process. CT scan and MRI can help in the diagnosis. A polyp, tumour or trauma in the middle meatus may also obstruct the sinus ostium to cause a mucocele.

*Mucocele of sphenoid sinus* or *sphenoethmoidal mucocele* arises from slow expansion and destruction of sphenoid and posterior ethmoid sinuses. Clinical features are those of superior orbital fissure syndrome (involvement of CN III, IV, VI and ophthalmic division of V) or orbital apex syndrome which is superior orbital fissure syndrome with additional involvement of optic and maxillary division of trigeminal nerve. Exophthalmos is always present and the pain is localised to the orbit or forehead. Some may complain of headache in the occiput or vertex. Treatment is external ethmoidectomy with sphenoidotomy. Anterior wall of the sphenoid sinus is removed, cyst wall uncapped and its fluid contents evacuated.

*Pyocele* or *muco-pyocele* is similar to mucocele but its contents are purulent. It can result from infection of a mucocele of any of the sinuses.

Endoscopic surgery has replaced external operation of the sinuses for treatment of all mucocele or mucopyoceles of various sinuses.

## ii. Osteomyelitis



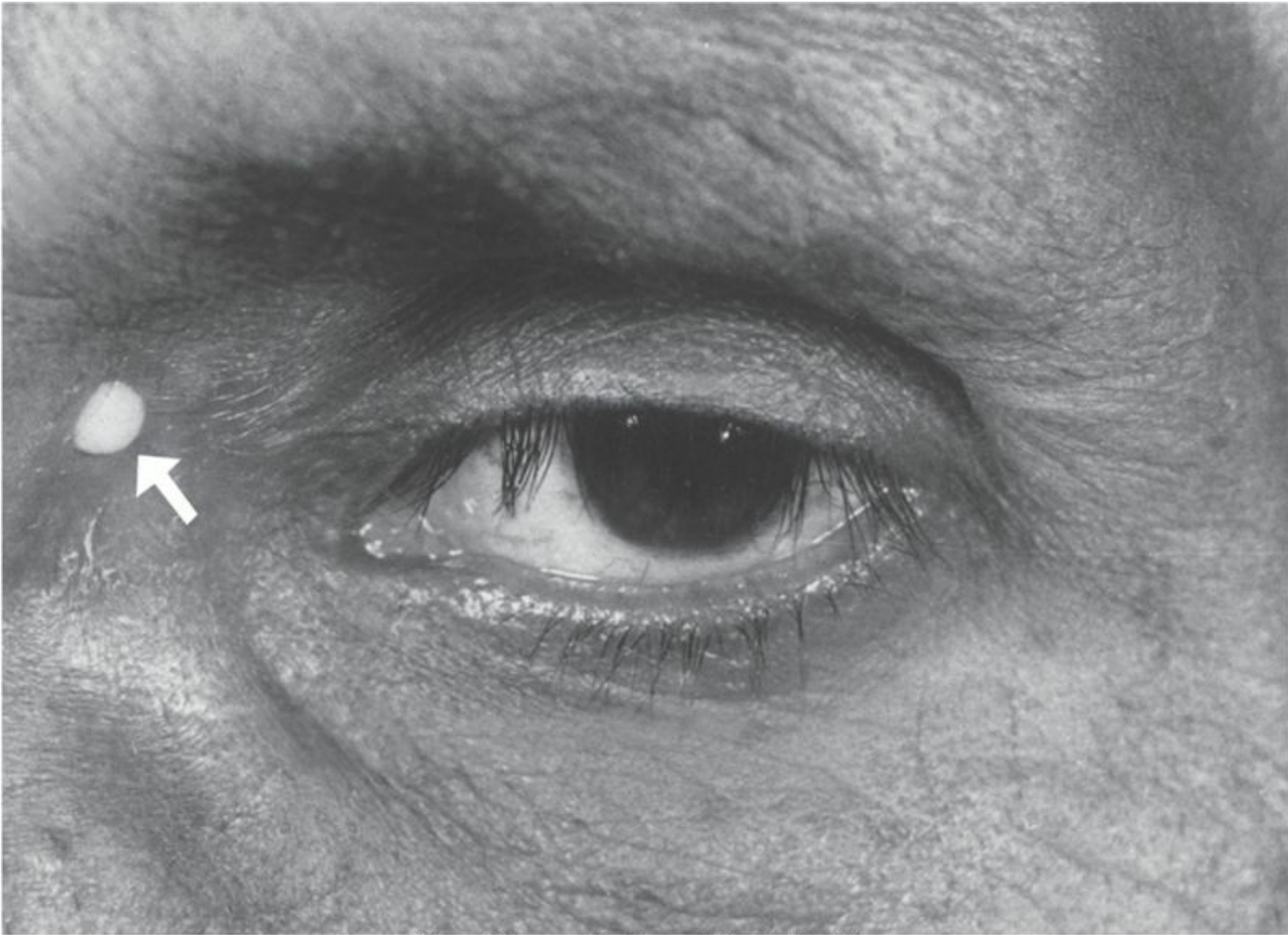Dhingra: Diseases of Ear Nose and Throat, 5th Edition  
Copyright © 2010 Elsevier. All rights reserved.

Figure 38.3 Osteomyelitis of maxilla with fistula formation in infraorbital region (arrow).

Osteomyelitis is infection of *bone marrow* and should be differentiated from osteitis which is infection of the *compact bone*. Osteomyelitis, following sinus infection, involves either the maxilla or the frontal bone.

- **(a) Osteomyelitis of the maxilla.** It is more often seen in infants and children than adults because of the presence of spongy bone in the anterior wall of the maxilla. Infection may start in the dental sac and then spread to the maxilla, but less often, it is primary infection of the maxillary sinus. Clinical features are erythema, swelling of cheek, oedema of lower lid, purulent nasal discharge and fever. Subperiosteal abscess followed by fistulae may form in infraorbital region (Fig. 38.3), alveolus or palate, or in zygoma. Sequestration of bone may occur. Treatment consists of large doses of antibiotics, drainage of any abscess and removal of the sequestra. Osteomyelitis of maxilla may cause damage to temporary or permanent tooth-buds, maldevelopment of maxilla, oroantral fistula, persistently draining sinus or epiphora.
- **(b) Osteomyelitis of frontal bone** (Fig. 38.4). It is more often seen in adults as frontal sinus is not developed in infants and children. Osteomyelitis of frontal bone results from acute infection of frontal sinus either directly or through the venous spread. It can also follow trauma or surgery of frontal sinus in the presence of acute infection. Pus may form externally under the periosteum as soft doughy swelling (Pott's puffy tumour), or internally as an extradural abscess. Treatment consists of large doses of antibiotics, drainage of abscess and

trephining of frontal sinus through its floor. Sometimes, it requires removal of sequestra and necrotic bone by raising a scalp flap through a coronal incision (Fig. 38.4).



Dhingra: Diseases of Ear Nose and Throat, 5th Edition  
Copyright © 2010 Elsevier. All rights reserved.

Figure 38.4 Case of chronic frontal sinusitis presenting with a fistula in the floor of the sinus.



## B. ORBITAL COMPLICATIONS

Orbit and its contents are closely related to the ethmoid, frontal, and maxillary sinuses, but most of the complications, however, follow infection of ethmoids as they are separated from the orbit only by a thin lamina of bone-lamina papyracea. Infection travels from these sinuses either by osteitis or as thrombophlebitic process of ethmoidal veins.

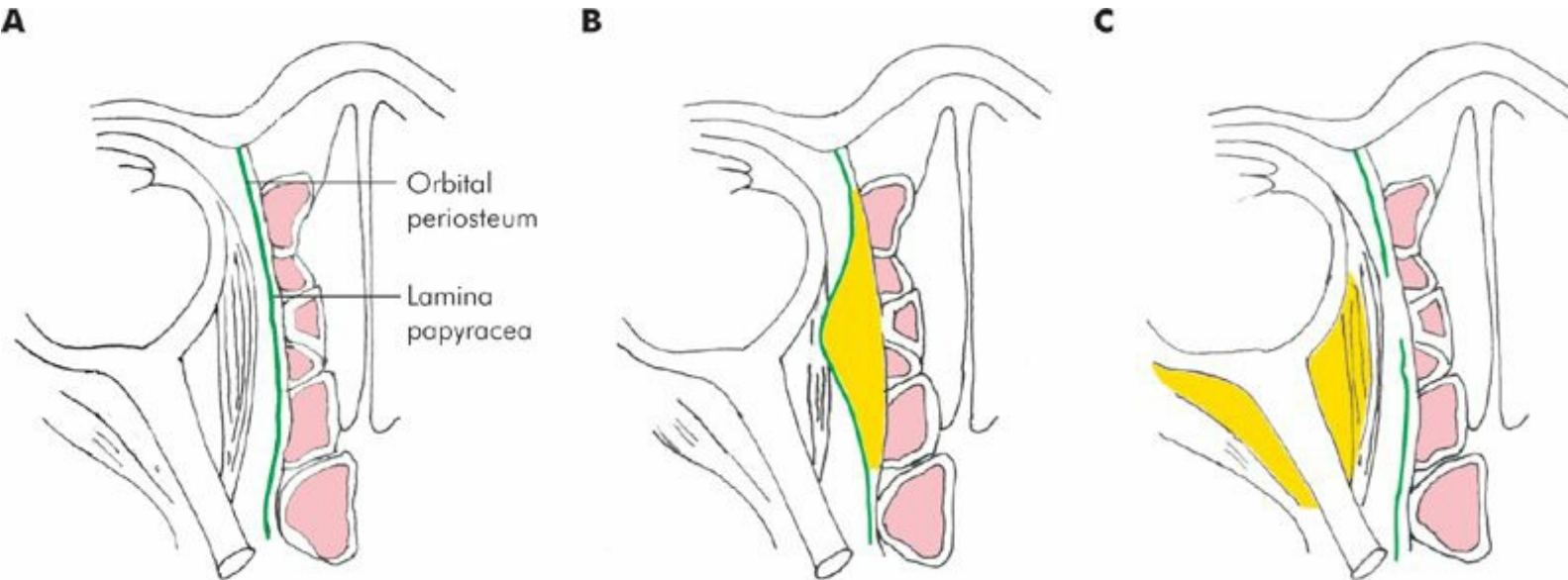
Orbital complications include:

- **(a) Inflammatory oedema of lids.** This is only reactionary. There is no erythema or tenderness of the lids which characterises lid abscess. It involves only preseptal space, i.e. lies in front of orbital septum. Eyeball movements and vision are normal. Generally, upper lid is swollen in frontal, lower lid in maxillary, and both upper and lower lids in ethmoid sinusitis.
- **(b) Subperiosteal abscess.** Pus collects outside the bone under the periosteum. A subperiosteal abscess from ethmoids forms on the medial wall of orbit and displaces the eyeball forward, downward and laterally; from the frontal sinus, abscess is situated just above and behind the medial canthus and displaces the eyeball downwards and laterally; from the maxillary sinus, abscess forms in the floor of the orbit and displaces the eyeball upwards and forwards.
- **(c) Orbital cellulitis.** When pus breaks through the periosteum and finds its way into the orbit, it spreads between the orbital fat, extraocular muscles, vessels and nerves. Clinical features will include oedema of lids, exophthalmos, chemosis of conjunctiva and restricted movements of the eye ball. Vision is affected causing partial or total loss which is sometimes permanent. Patient may run high fever. Orbital cellulitis is potentially dangerous because of the risk of meningitis and cavernous sinus thrombosis.
- **(d) Orbital abscess.** Intraorbital abscess usually forms along lamina papyracea or the floor of frontal sinus. Clinical picture is similar to that of orbital cellulitis. Diagnosis can be easily made by CT scan or ultrasound of the orbit. Treatment is i.v. antibiotics and drainage of the abscess and that of the sinus (ethmoidectomy or trephination of frontal sinus).
- **(e) Superior orbital fissure syndrome.** Infection of sphenoid sinus can rarely affect structures of superior orbital fissure. Symptoms consist of deep orbital pain, frontal headache and progressive paralysis of CN VI, III and IV, in that order.
- **(f) Orbital apex syndrome.** It is superior orbital fissure syndrome with additional involvement of the optic nerve and maxillary division of the trigeminal ( $V_2$ ) (Fig. 38.5).

# C. INTRACRANIAL COMPLICATIONS

Frontal, ethmoid and sphenoid sinuses are closely related to anterior cranial fossa and infection from these can cause:

- (a) Meningitis and encephalitis
- (b) Extradural abscess
- (c) Subdural abscess
- (d) Brain abscess
- (e) Cavernous sinus thrombosis.



Dhingra: Diseases of Ear Nose and Throat, 5th Edition  
Copyright © 2010 Elsevier. All rights reserved.

Figure 38.5 Orbital complications of sinusitis: (A) Normal. (B) Subperiosteal abscess. (C) Orbital abscess.

Table 38-2. Source and route of infection in cavernous sinus thrombosis

Source	Disease	Route
Nose and danger area of face	Furuncle and septal abscess	Pharyngeal plexus
Ethmoid sinuses	Orbital cellulites or abscess	Ophthalmic veins
Sphenoid sinus	Sinusitis	Direct
Frontal sinus	Sinusitis and osteomyelitis of frontal bone	Supraorbital and ophthalmic veins
Orbit	Cellulitis and abscess	Ophthalmic veins
Upper lid	Abscess	Angular vein and ophthalmic veins
Pharynx	Acute tonsillitis or peritonsillar abscess	Pharyngeal plexus
Ear	Petrositis	Petrosal venous sinuses

## Cavernous Sinus Thrombosis

*Aetiology.* Infection of paranasal sinuses, particularly those of ethmoid and sphenoid and less commonly the frontal, and orbital complications from these sinus infections can cause thrombophlebitis of the cavernous sinus(es). Other sources of infection are listed in Table 38.2. The valveless nature of the veins connecting the cavernous sinus causes easy spread of infection.

**Table 38-3. Differences between orbital cellulitis and cavernous sinus thrombosis**

	<b>Orbital cellulitis</b>	<b>Cavernous sinus thrombosis</b>
Source	Commonly ethmoid sinuses	Nose, sinuses, orbit, ear or pharynx
Onset	Slow; starts with oedema of eyelids the inner canthus → chemosis → proptosis	Abrupt with high fever and chills with near signs of toxemia Oedema of eyelids, chemosis and proptosis
Cranial nerve involvement	Involved concurrently with complete ophthalmoplegia	Involved individually and sequentially
Laterality	Often involves one eye	Involves both eyes

*Clinical features.* Onset of cavernous sinus thrombophlebitis is abrupt with chills and rigors. Patient is acutely ill. Eyelids get swollen with chemosis and proptosis of eyeball. Cranial nerves III, IV, VI which are related to the sinus get involved individually and sequentially causing total ophthalmoplegia. Pupil becomes dilated and fixed, optic disc shows congestion and oedema with diminution of vision. Sensation in the distribution of V<sub>1</sub> (ophthalmic division of CNV) is diminished. CSF is usually normal. Condition needs to be differentiated from orbital cellulitis (Table 38.3). CT scan is useful for this.

*Treatment* consists of i.v. antibiotics and attention to the focus of infection, drainage of infected ethmoid or sphenoid sinus. Blood culture should be taken before starting antibiotic therapy. Role of anticoagulants is not clear.

## D. DESCENDING INFECTIONS

In suppurative sinusitis, discharge constantly flows into the pharynx and can cause or aggravate:

- **(a) *Otitis media*** (acute or chronic).
- **(b) *Pharyngitis and tonsillitis***. Hypertrophy of lateral lymphoid bands behind the posterior pillars (lateral pharyngitis) is indicative of chronic sinusitis. It may be unilateral and affect the side of the involved sinus. Chronic sinusitis may also cause recurrent tonsillitis or granular pharyngitis.
- **(c) *Persistent laryngitis and tracheobronchitis***. Sinusitis may be associated with recurrent laryngitis, bronchiectasis and asthma but the latter are not necessarily caused by sinusitis.

## **E. FOCAL INFECTIONS**

The role of sinus infection to act as focus of infection is doubtful. A few conditions such as polyarthritis, tenosynovitis, fibrositis and certain skin diseases may respond to elimination of infection in the sinuses. However, sinus infection, if present in these cases, is treated on its own merit.

## 39 Neoplasms of Nasal Cavity

Both benign and malignant tumours of the nasal cavity (Table 39.1) per se are uncommon. Very often their separation from tumours of paranasal sinuses is difficult except in early stages. In addition to primary tumours, nasal cavity can be invaded by growths from paranasal sinuses, nasopharynx, cranial or buccal cavity.

Benign lesions are usually smooth, localised and covered with mucous membrane. Malignant ones are usually friable, have a granular surface and tend to bleed easily.

Table 39-1. Tumours of nasal cavity

Benign	Malignant
<ul style="list-style-type: none"><li>• Squamous papilloma</li><li>• Inverted papilloma</li><li>• Pleomorphic adenoma</li><li>• Schwannoma</li><li>• Meningioma</li><li>• Haemangioma</li><li>• Chondroma</li><li>• Angiofibroma</li><li>• Encephalocele</li><li>• Glioma</li><li>• Dermoid</li></ul>	<ul style="list-style-type: none"><li>• Carcinoma<ul style="list-style-type: none"><li>• - Squamous cell carcinoma</li><li>• - Adenocarcinoma</li></ul></li><li>• Malignant melanoma</li><li>• Olfactory neuroblastoma</li><li>• Haemangiopericytoma</li><li>• Lymphoma</li><li>• Solitary plasmacytoma</li><li>• Various types of sarcoma</li></ul>

# BENIGN NEOPLASMS

## 1. Squamous papilloma

Verrucous lesions similar to skin warts can arise from the nasal vestibule or lower part of nasal septum. They may be single or multiple, pedunculated or sessile (Fig. 39.1). Treatment is local excision with cauterisation of the base to prevent recurrence. They can also be treated by cryosurgery or laser.

## 2. Inverted papilloma (Transitional cell papilloma or Ringertz tumour)

It is so-named because microscopically neoplastic epithelium is seen to grow towards underlying stroma rather than on the surface. Mostly seen between 40-70 years with male preponderance (5:1). It arises from the lateral wall of nose and is always unilateral. It presents as red or grey masses which may be translucent and oedematous, simulating simple nasal polypi. Inverted papilloma has a marked tendency to recur after surgical removal and may be associated with squamous cell carcinoma in 10-15% of patients. Treatment is wide surgical excision by lateral rhinotomy or medial maxillectomy and en bloc ethmoidectomy.

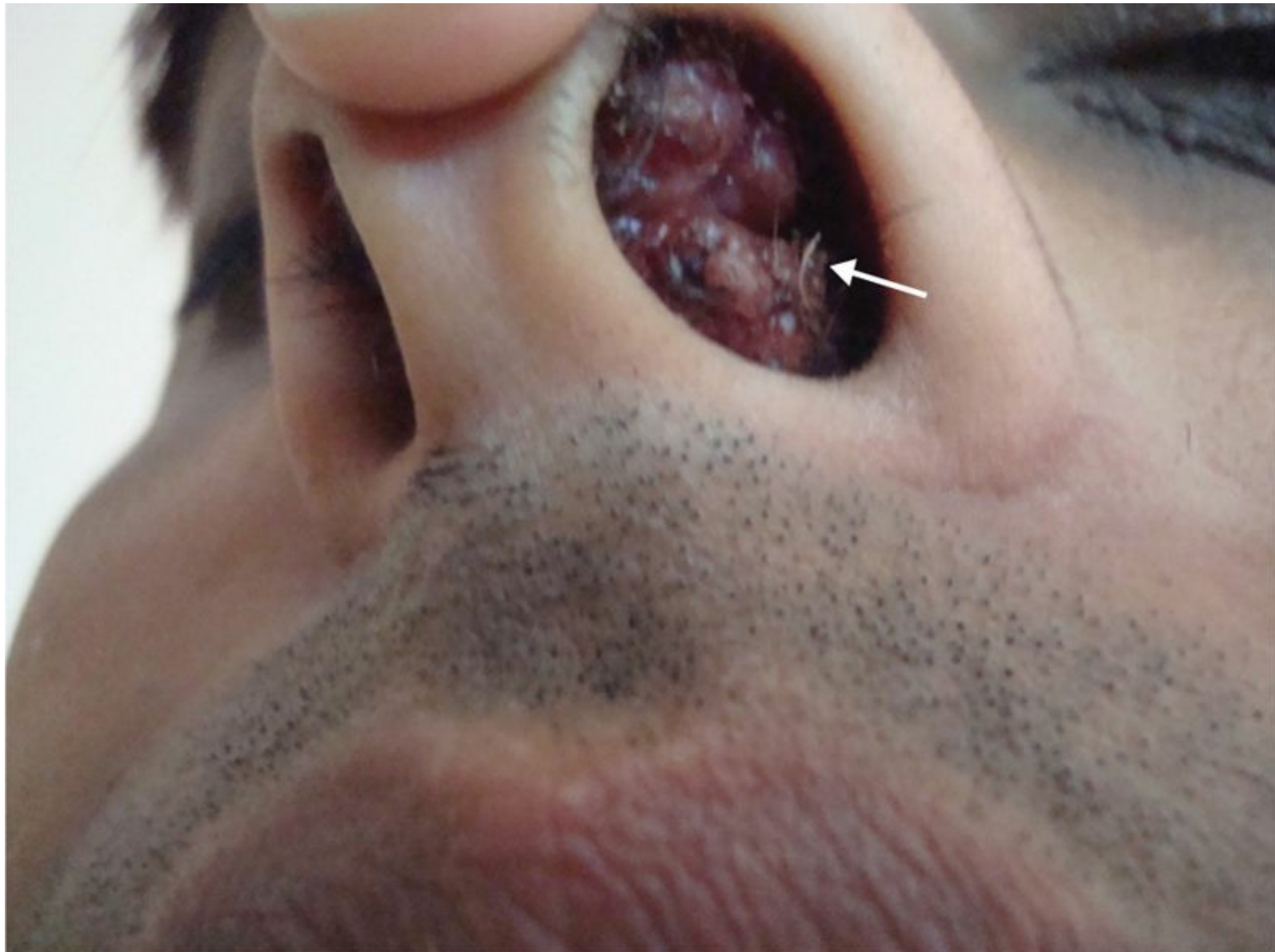## 3. Pleomorphic adenoma

Rare tumour, usually arises from the nasal septum. Treatment is wide surgical excision.

## 4. Schwannoma and meningioma

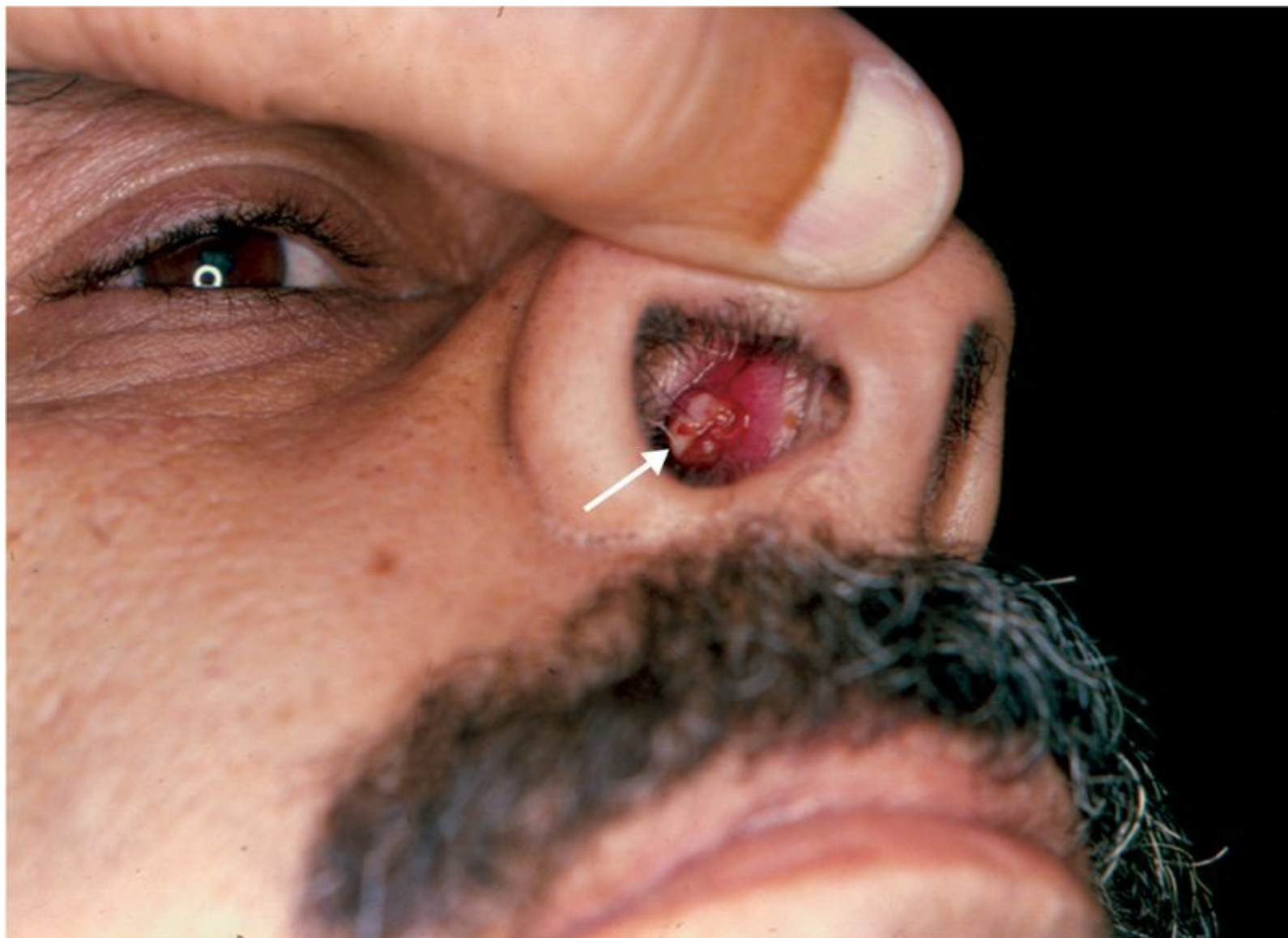They are uncommon tumours which are found intranasally. Treatment is surgical excision by lateral rhinotomy.

## 5. Haemangioma



It may be:

- **(a) Capillary haemangioma (Bleeding polypus of the septum).** It is a soft, dark red, pedunculated or sessile tumour arising from anterior part of nasal septum (Fig. 39.2). Usually it is smooth but may become ulcerated and present with recurrent epistaxis and nasal obstruction. Treatment is local excision with a cuff of surrounding mucoperichondrium.
- **(b) Cavernous haemangioma.** It arises from the turbinates on the lateral wall of nose. It is treated by surgical excision with preliminary cryotherapy. Extensive lesions may require radiotherapy and surgical excision.



Dhingra: Diseases of Ear Nose and Throat, 5th Edition  
Copyright © 2010 Elsevier. All rights reserved.

Figure 39.2 Bleeding polypus arising from right side of nasal septum.

## 6. Chondroma

It can arise from the ethmoid, nasal cavity or nasal septum. Pure chondromas are smooth, firm and lobulated. Others may be mixed type fibro-, osteo-, or angiochondromas. Treatment is surgical excision. For recurrent or large tumours, wide excision should be done because of their tendency to malignant transformation after repeated interference.

## 7. Angiofibroma

It is included in nasal tumours because its primary site of origin is supposed to be posterior part of nasal cavity near the sphenopalatine foramen (see page 261).

## 8. Intranasal meningoencephalocele



It is herniation of brain tissues and meninges through foramen caecum or cribriform plate. It presents as a smooth polyp in the upper part of nose between the septum and middle turbinate, usually in infants and young children. The mass increases in size on crying or straining. Unless care is taken, it may be misdiagnosed as a simple polyp and mistakenly avulsed, resulting in CSF rhinorrhoea or meningitis. For the same reason biopsy should not be taken. CT scan is essential to demonstrate a defect in the base of skull. Treatment is frontal craniotomy, severing the stalk from the brain, and repair of dural and bony defect. Intranasal mass is removed as secondary procedure after cranial defect has sealed.

### **9. Gliomas**

Of all the gliomas, 30% are intranasal and 10% both intra and extranasal. They are seen in infants and children. An intranasal glioma presents as a firm polyp sometimes protruding at the anterior nares.

### **10. Nasal dermoid**

It presents as widening of upper part of nasal septum with splaying of nasal bones and hypertelorism. A pit or a sinus may be seen in the midline of nasal dorsum with hair protruding from the opening.

# MALIGNANT NEOPLASMS

## 1. Carcinoma of nasal cavity

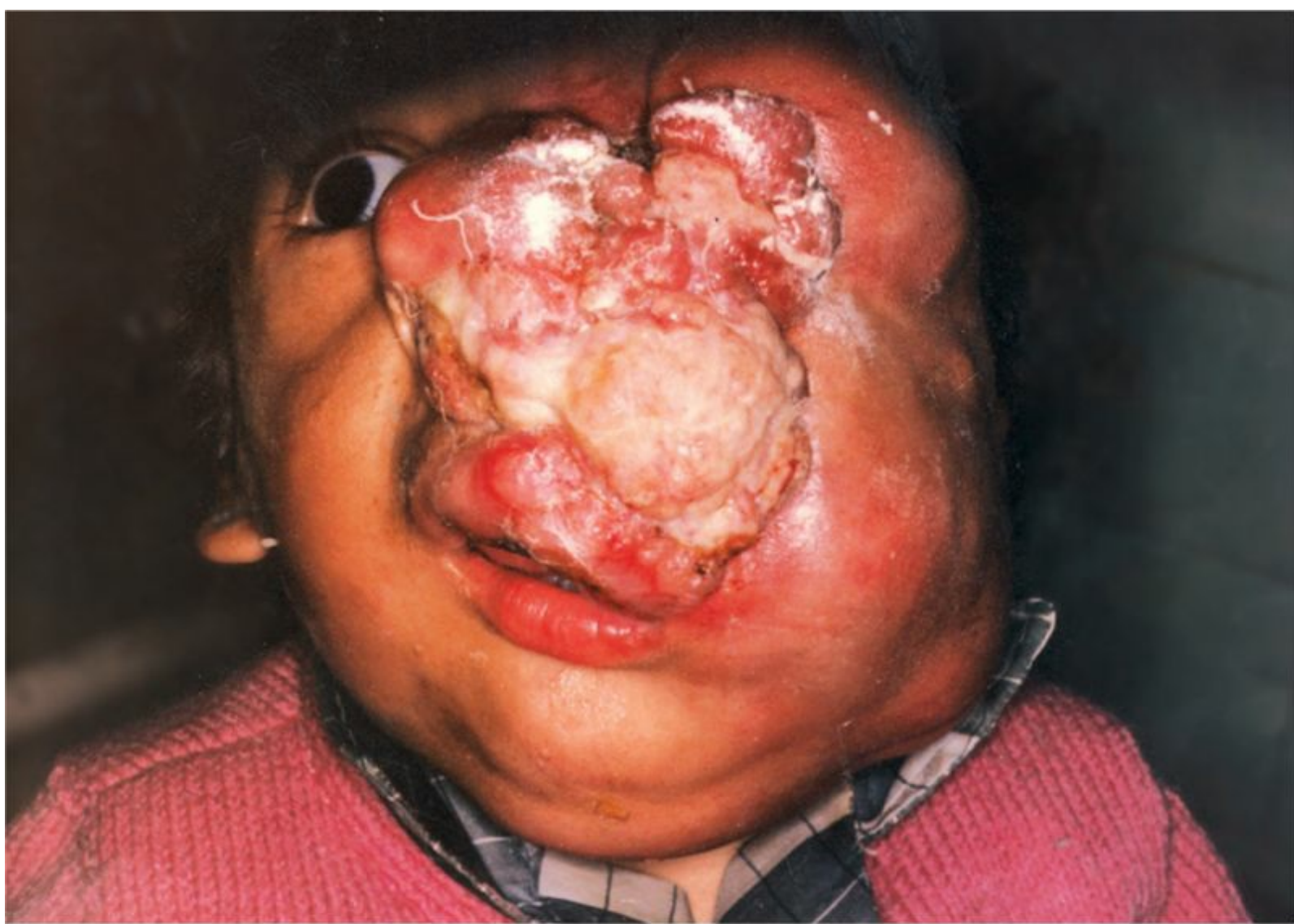Primary carcinoma per se is rare. It may be an extension of maxillary or ethmoid carcinoma. Squamous cell variety is the most common, seen in about 80% of cases. Rest may be adenoid cystic carcinoma or an adenocarcinoma.

- **(a) Squamous cell carcinoma.** It may arise from the vestibule, anterior part of nasal septum or the lateral wall of nasal cavity. Most of them are seen in men past 50 years of age.
  - (i) Vestibular: It arises from the lateral wall of nasal vestibule and may extend into the columella, nasal floor and upper lip with metastases to parotid nodes.
  - (ii) Septal: Mostly arises from mucocutaneous junction and causes burning and soreness in the nose. It has often been termed as "nose-picker's cancer". Usually, it is of low grade malignancy.
  - (iii) Lateral wall: This is the site most commonly involved. Easily extends into ethmoid or maxillary sinuses. Grossly, it presents as a polypoid mass in the lateral wall of nose. Metastases are rare. Treatment is combination of radiotherapy and surgery.
- **(b) Adenocarcinoma and adenoid cystic carcinoma.** They arise from the glands of mucous membrane or minor salivary glands and mostly involve upper part of the lateral wall of nasal cavity.

## 2. Malignant melanoma

Usually seen in persons about 50 years of age. Both sexes are equally affected. Grossly, it presents as a slaty-grey or bluish-black polypoid mass. Within the nasal cavity, most frequent site is anterior part of nasal septum followed by middle and inferior turbinate. Amelanotic varieties are nonpigmented. Tumour spreads by lymphatics and blood stream. Cervical nodal metastases may be present at the time of initial examination. Treatment is wide surgical excision. Immunological defences of the patient play a great role in the control of this disease. Radiotherapy and chemotherapy suppress the immune processes and are avoided. A five-year survival rate of 30% can be expected after surgical excision.

## 3. Olfactory neuroblastoma



Dhingra: Diseases of Ear Nose and Throat, 5th Edition  
Copyright © 2010 Elsevier. All rights reserved.

Figure 39.3 Rhabdomyosarcoma of the nose in a 2½-years old male child.

It is a tumour of olfactory placode seen in persons of either sex at any age group. It presents as a cherry red, polypoidal mass in the upper third of the nasal cavity. It is a vascular tumour and bleeds profusely on biopsy. Lymph node or systemic metastases can occur. The tumour is moderately radiosensitive and has been cured by radiation alone. Presently, favoured treatment is surgical excision followed by radiation. Craniofacial resection may be required for tumours of the cribriform plate.

#### **4. Haemangiopericytoma**

It is a rare tumour of vascular origin. It arises from the pericyte—a cell surrounding the capillaries. It is usually seen in the age group of 60-70 and presents with epistaxis. Brisk bleeding may occur on biopsy. The tumour may be benign or malignant but it cannot be distinguished histologically. Treatment is wide surgical excision. Radiotherapy is used for inoperable or recurrent lesions.

#### **5. Lymphoma**

Rarely a non-Hodgkin lymphoma presents on the septum.

#### **6. Plasmacytoma**

Solitary plasmacytoma without generalised osseous disease may be seen in the nasal cavity. It predominantly affects males over 40 years. Treatment is by radiotherapy followed three months later by surgery if total regression does not occur. Long-term follow up is essential to exclude development of multiple myeloma.

#### **7. Sarcomas**

Osteogenic sarcoma, chondrosarcoma, rhabdomyosarcoma (Fig. 39.3), angiosarcoma, malignant histiocytoma are other rare tumours affecting the nose.

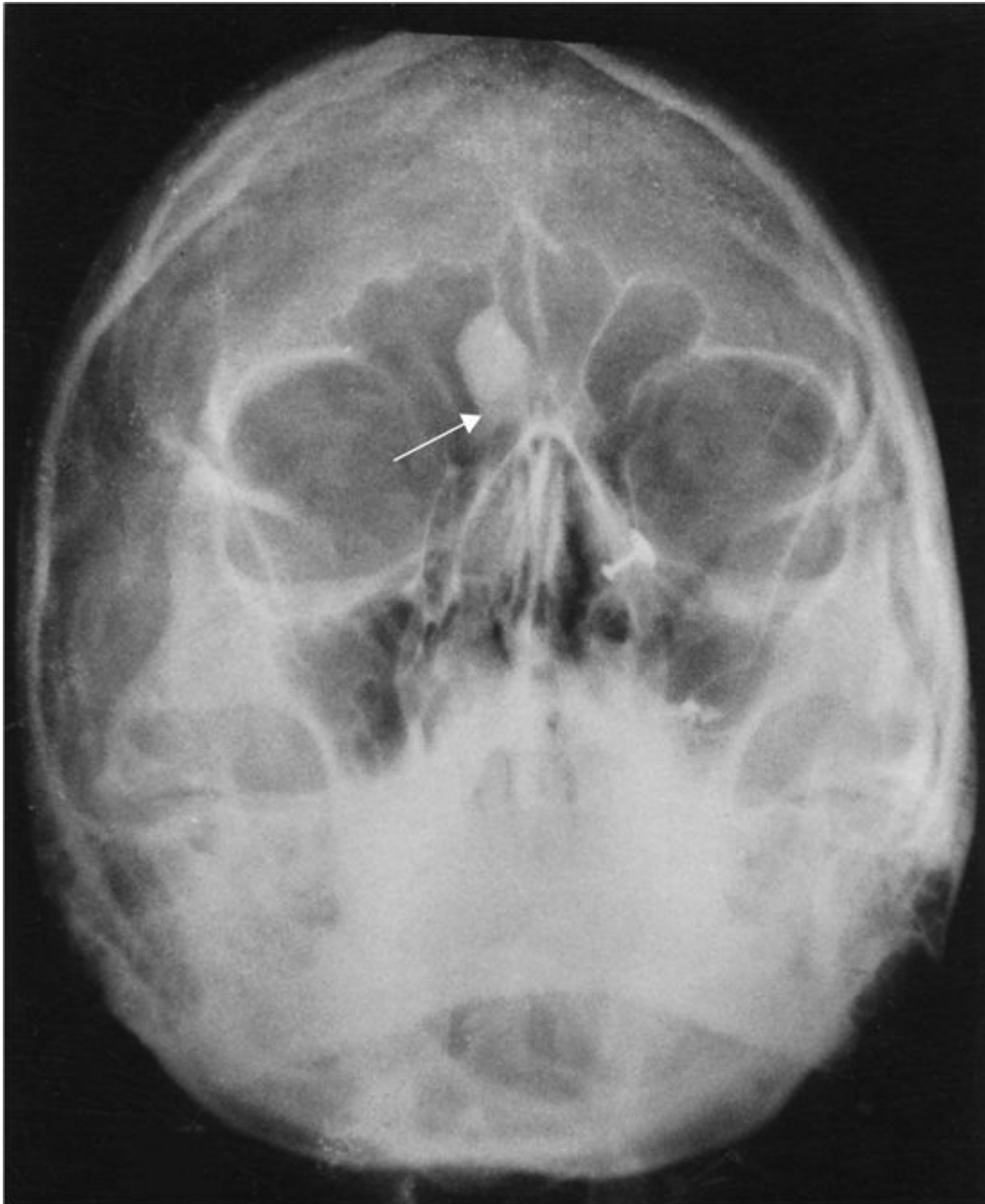## **40 Neoplasms of Paranasal Sinuses**

Paranasal sinuses may be affected by both benign and malignant neoplasms but the latter are much more common.

# BENIGN NEOPLASMS

## *Osteomas*

They are most commonly seen in the frontal sinus followed in turn by those of ethmoid and maxillary. They may remain asymptomatic, being discovered incidentally on X-rays (Fig. 40.1). Treatment is indicated when they become symptomatic, causing obstruction to the sinus ostium, formation of mucocele, pressure symptoms due to their growth in the orbit, nose or cranium.



Dhingra: Diseases of Ear Nose and Throat, 5th Edition  
Copyright © 2010 Elsevier. All rights reserved.

Figure 40.1 Osteoma right frontal sinus (arrow).

## *Fibrous dysplasia*

In this condition, bone is replaced by fibrous tissue; mostly involves maxillary but sometimes the ethmoid and frontal sinuses. Patient seeks advice for disfigurement of the face, nasal obstruction and displacement of the eye. Treatment is surgical resculpturing of the involved bone to achieve a good cosmetic and functional result (Fig. 40.2).

## *Ossifying fibroma*

Seen in young adults. The tumour can be shelled out easily.

# **MALIGNANT NEOPLASMS**

## ***Incidence***

Cancer of nose and paranasal sinuses constitutes 0.44% of all body cancers in India (0.57% in males and 0.44% in females). Its incidence during the same period (year 2000) was 0.3 per 100,000 persons.\* Most frequently involved are the maxillary sinuses followed in turn by ethmoids, frontal and sphenoid.

## ***Aetiology***

Cause of sinus malignancy is largely unknown. People working in hardwood furniture industry, nickel refining, leather work and manufacture of mustard gas have shown higher incidence of sinusal cancer. Cancer of the maxillary sinus is common in Bantus of South Africa where locally made snuff is used, which is found rich in nickel and chromium.

Workers of furniture industry develop adenocarcinoma of the ethmoids and upper nasal cavity, while those engaged in nickel refining get squamous cell and anaplastic carcinoma.

## ***Histology***

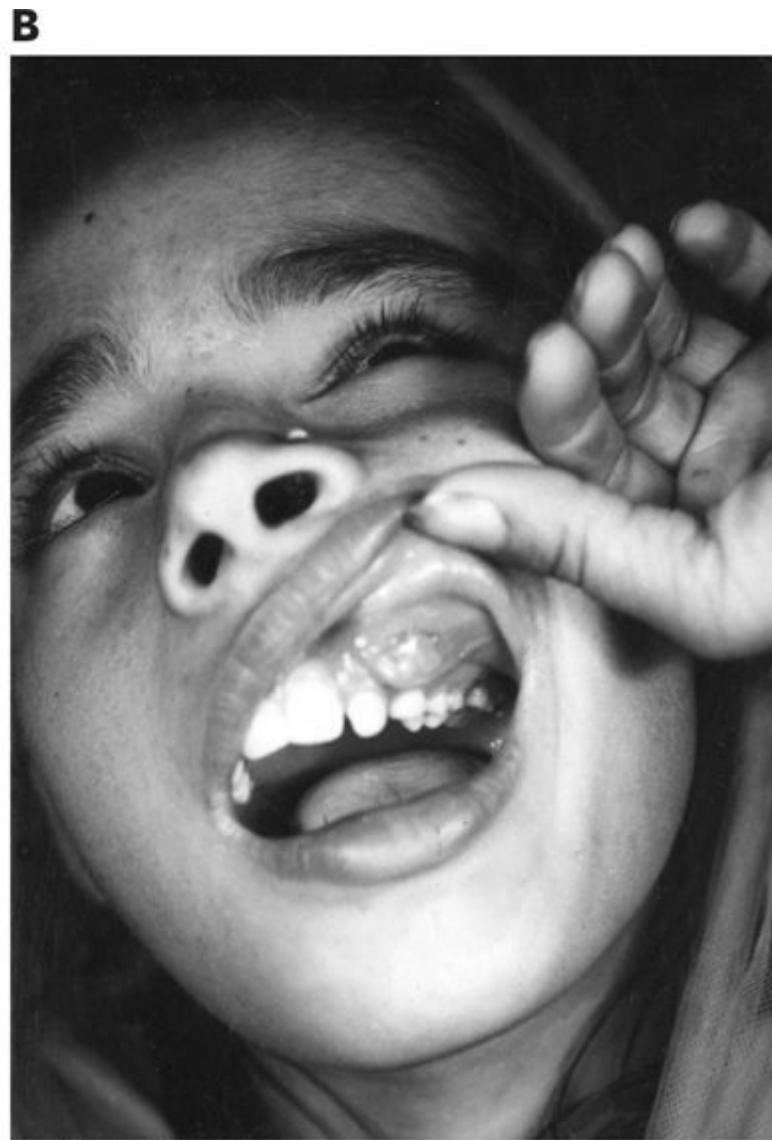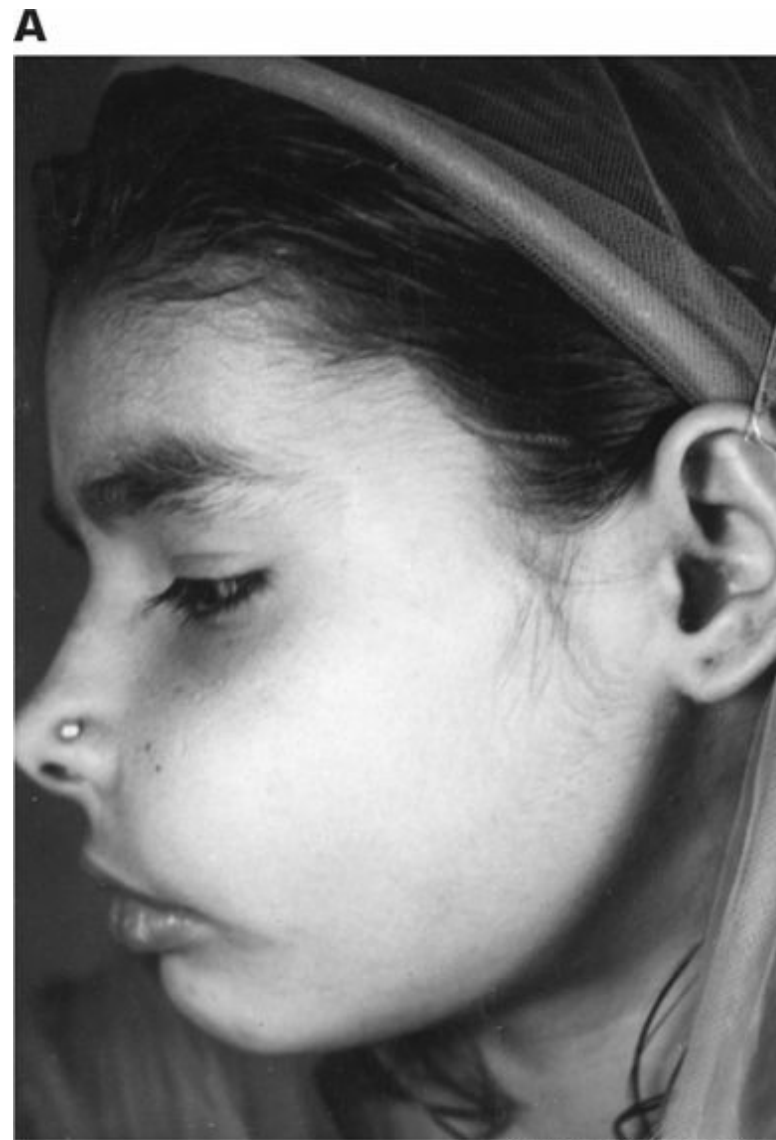More than 80% of the malignant tumours are of squamous cell variety. Rest are adenocarcinoma, adenoid cystic carcinoma, melanoma and various types of sarcomas.

## Carcinoma of Maxillary Sinus

It arises from the sinus lining and may remain silent for a long time giving only vague symptoms of "sinusitis". It then spreads to destroy the bony confines of the maxillary sinus and invades the surrounding structures.

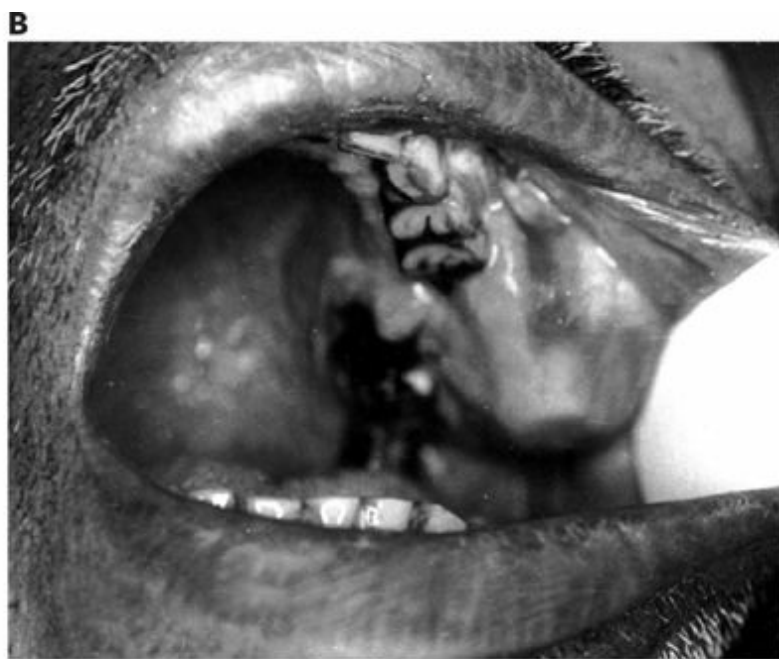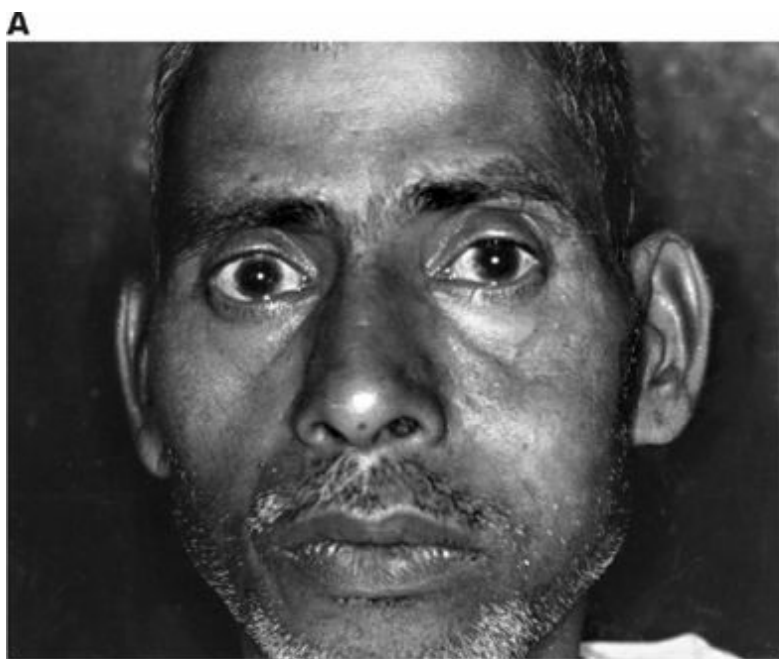
### Clinical Features (Fig. 40.3)

Disease is common in 40-60 age group with preponderance in males.



Dhingra: Diseases of Ear Nose and Throat, 5th Edition  
Copyright © 2010 Elsevier. All rights reserved.

Figure 40.2 Fibrous dysplasia of maxilla in a 13-years-old girl. (A) As seen externally . (B) After retraction of the lip.



Dhingra: Diseases of Ear Nose and Throat, 5th Edition  
Copyright © 2010 Elsevier. All rights reserved.

Figure 40.3 Antroethmoidal carcinoma left side. Note (A) Swelling of left cheek, (B) Expansion of alveolus and palate.

*Early features* of maxillary sinus malignancy are nasal stuffiness, blood-stained nasal discharge, facial paraesthesias or pain and epiphora. These symptoms may be missed or simply treated as sinusitis.

Late features will depend on the direction of spread and extent of growth.

*Medial spread* to nasal cavity gives rise to nasal obstruction, discharge and epistaxis. It may also spread into anterior and posterior ethmoid sinuses and that is why most antral malignancies are antroethmoidal in nature.

page 220

page 221

*Anterior spread* causes swelling of the cheek and later invasion of the facial skin.

*Inferior spread* causes expansion of alveolus with dental pain, loosening of teeth, poor fitting of dentures, ulceration of gingiva and swelling in the hard palate.

*Superior spread* invades the orbit causing proptosis, diplopia, ocular pain and epiphora.

*Posterior spread* is into pterygomaxillary fossa, pterygoid plates and the muscles causing trismus. Growth may also spread to the nasopharynx, sphenoid sinus and base of skull.

*Intracranial spread* can occur through ethmoids, cribriform plate or foramen lacerum.

*Lymphatic spread.* Nodal metastases are uncommon and occur only in the late stages of disease. Submandibular and upper jugular nodes are enlarged. Maxillary and ethmoid sinuses drain primarily into retropharyngeal nodes, but these nodes are inaccessible to palpation.

*Systemic metastases* are rare. May be seen in the lungs (most commonly) and occasionally in bone.

## Diagnosis

*Radiograph of sinuses.* Opacity of the involved sinus with expansion and destruction of the bony walls.

*CT scan.* If available, this is the best non-invasive method to find the extent of disease. CT scan should be done both in axial and coronal planes. It also helps in the staging of disease.

*Biopsy.* If growth presents in the nose or mouth, biopsy can be easily taken. In early cases, with suspicion of malignancy, sinus should be explored by Caldwell-Luc operation. Direct visualisation of the site of tumour in the sinus also helps in staging of the tumour.

Endoscopy of the nose and maxillary sinus will provide detailed examination. An accurate biopsy can also be taken.

## Classification

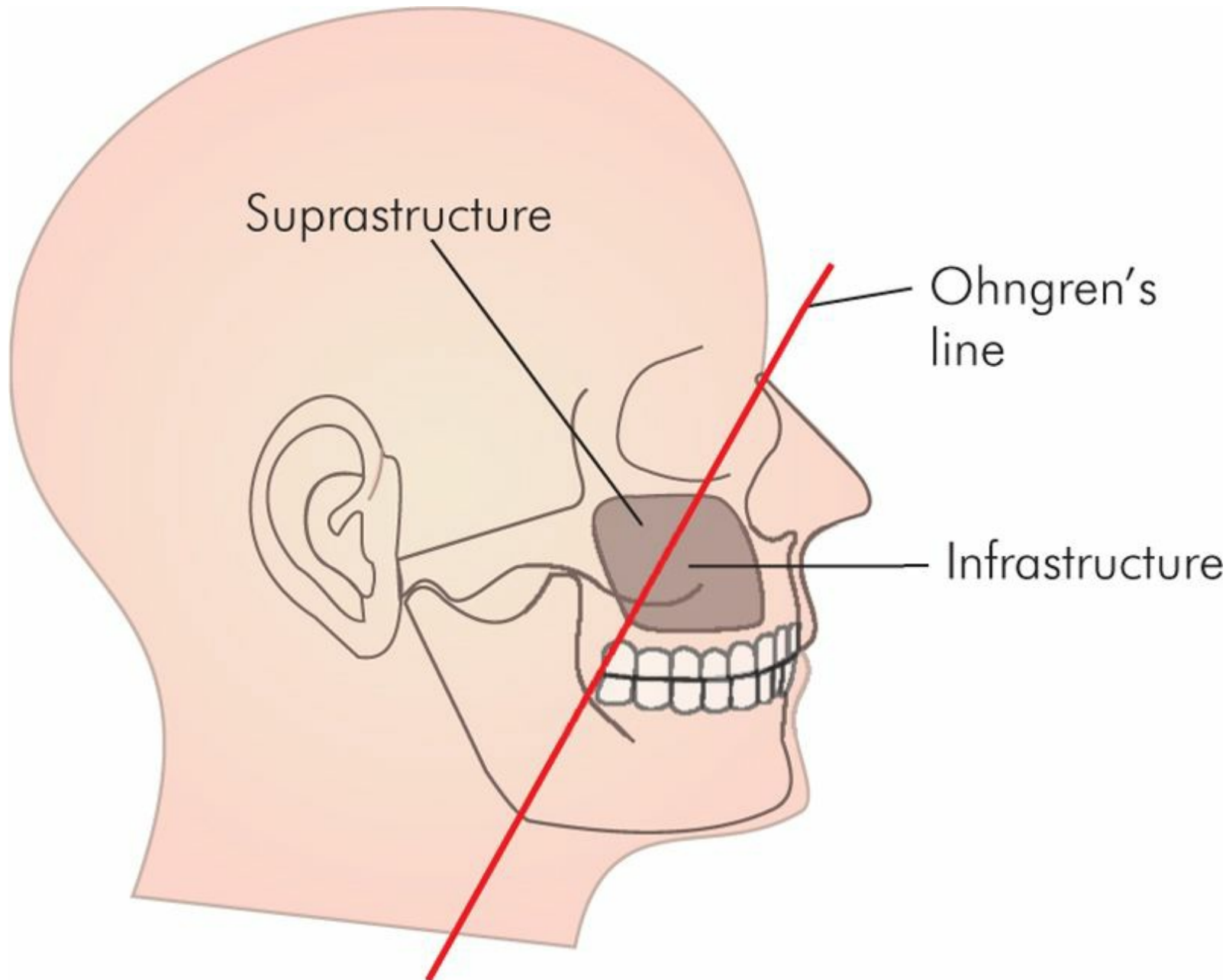


- (b) Moderately differentiated and
- (c) Poorly differentiated

In histopathology, note should also be made of vascular or perineural invasion.

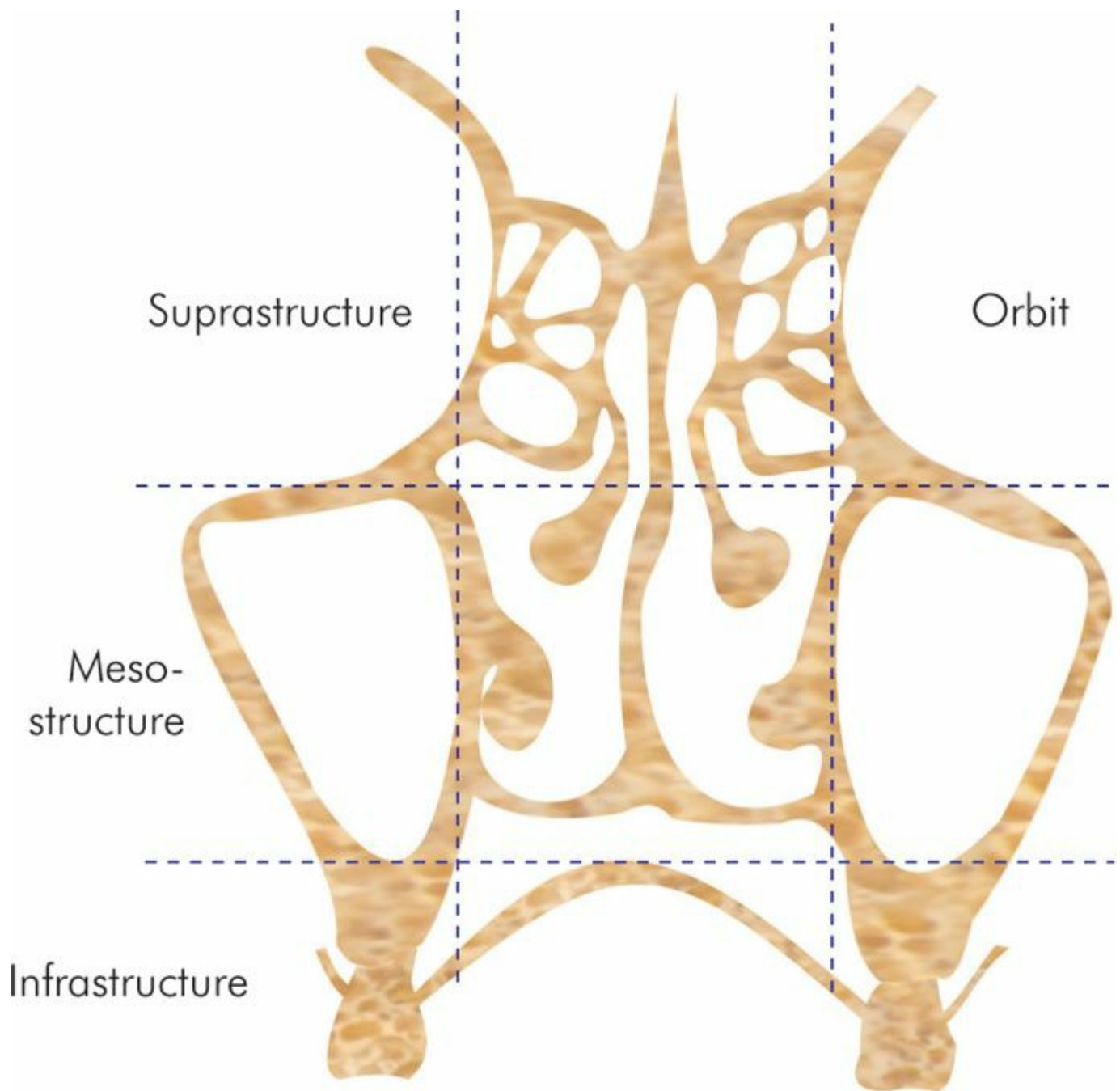
There is no universally accepted classification for maxillary carcinoma.

- **1. Ohngren's classification.** An imaginary plane is drawn, extending between medial canthus of eye and the angle of mandible (Fig. 40.4). Growths situated above this plane (suprastructural) have a poorer prognosis than those below it (infrastructural).
- **2. AJCC (American Joint Committee on Cancer) classification.** (Tables 40.1 to 40.3). AJCC classification is only for squamous cell carcinoma and does not include non-epithelial tumours of lymphoid tissue, soft tissue, cartilage and bone. Histopathologically, squamous cell carcinoma is further graded into:
- **3. Lederman's classification** (Fig. 40.5). It uses two horizontal lines of Seibileau; one passing through the floors of orbits and the other through floors of antra, thus dividing the area into:
  - (a) **Suprastructure:** Ethmoid, sphenoid and frontal sinuses and the olfactory area of nose.
  - (b) **Mesostructure:** Maxillary sinus and the respiratory part of nose.
  - (c) **Infrastructure:** Containing alveolar process. This classification further uses vertical lines, extending down the medial walls of orbit to separate ethmoid sinuses and nasal fossa from the maxillary sinuses.



Dhingra: Diseases of Ear Nose and Throat, 5th Edition  
Copyright © 2010 Elsevier. All rights reserved.

Figure 40.4 Ohngren's line extends from medial canthus of eye to the angle of mandible. Growths anteroinferior to this plane (infrastructural) have a better prognosis than those posterosuperior to it (suprastructural).



Dhingra: Diseases of Ear Nose and Throat, 5th Edition  
 Copyright © 2010 Elsevier. All rights reserved.

Figure 40.5 Lederman's classification.

Table 40-1. TNM classification and staging system of cancer of maxillary sinus

<b>Maxillary sinus</b>	
T <sub>1</sub>	Tumour limited to maxillary sinus mucosa with no erosion or destruction of bone
T <sub>2</sub>	Tumour causing bone erosion or destruction including extension into the hard palate and/or middle nasal meatus, except extension to posterior wall of maxillary sinus and pterygoid plates
T <sub>3</sub>	Tumour invades any of the following: bone of the posterior wall of maxillary sinus, subcutaneous tissues, floor or medial wall of orbit, pterygoid fossa and ethmoid sinuses
T <sub>4a</sub>	Tumour invades anterior orbital contents, skin of cheek, pterygoid plates, infratemporal fossa, cribriform plate, sphenoid or frontal sinuses
T <sub>4b</sub>	Tumour invades any of the following: orbital apex, dura, brain, middle cranial fossa, cranial nerves other than maxillary division of trigeminal nerve (V <sub>2</sub> ), nasopharynx or clivus
<b>Regional lymph nodes (N)</b>	
N <sub>x</sub>	Regional lymph nodes cannot be assessed

N <sub>0</sub>	No regional lymph node metastasis
N <sub>1</sub>	Metastasis in a single ipsilateral lymph node, 3 cm or less in greatest dimension
N <sub>2</sub>	Metastasis in a single ipsilateral lymph node, more than 3 cm but not more than 6 cm in greatest dimension; or in multiple ipsilateral lymph nodes, none more than 6 cm in greatest dimension; or in bilateral or contralateral lymph nodes, none more than 6 cm in greatest dimension
N <sub>2a</sub>	Metastasis in a single ipsilateral lymph node, more than 3 cm but not more than 6 cm in greatest dimension
N <sub>2b</sub>	Metastasis in multiple ipsilateral lymph nodes, none more than 6 cm in greatest dimension
N <sub>2c</sub>	Metastasis in bilateral or contralateral lymph nodes, none more than 6 cm in greatest dimension
N <sub>3</sub>	Metastasis in a lymph node, more than 6 cm in greatest dimension
<b>Distant metastasis (M)</b>	
M <sub>x</sub>	Distant metastasis cannot be assessed
M <sub>0</sub>	No distant metastasis
M <sub>1</sub>	Distant metastasis

\*Source: AJCC, Cancer Staging Manual, fifth ed. Chicago, 2002.

**Table 40-2. Stage grouping of cancer of maxillary and ethmoid sinuses**

Stage I	T <sub>1</sub> N <sub>0</sub> M <sub>0</sub>
Stage II	T <sub>2</sub> N <sub>0</sub> M <sub>0</sub>
Stage III	T <sub>3</sub> N <sub>0</sub> M <sub>0</sub>
	T <sub>1</sub> or T <sub>2</sub> or T <sub>3</sub> with N <sub>1</sub> M <sub>0</sub>
Stage IV A	T <sub>4</sub> N <sub>0</sub> M <sub>0</sub>
	T <sub>4</sub> N <sub>1</sub> M <sub>0</sub>
Stage IV B	Any T N <sub>2</sub> M <sub>0</sub>
	Any T N <sub>3</sub> M <sub>0</sub>
Stage IV C	Any T Any N M <sub>1</sub>

Regional lymph nodes and distant metastasis. They are divided in the usual manner into N<sub>0</sub>, N<sub>1</sub>, N<sub>2</sub> & N<sub>3</sub> (see page 241) and M<sub>0</sub>, M<sub>1</sub>.

The student may note here that suprastructure and infrastructure of Lederman's classification is not the same as in Ohngren's classification.

## Treatment

Histologically, nature of malignancy is important in deciding the line of treatment as is the location and extent of disease.

**Table 40-3. Classification of cancer of nasal cavity and ethmoid sinuses (AJCC, 2002)**

T <sub>1</sub>	Tumour restricted to any one subsite, with or without bony invasion
T <sub>2</sub>	Tumour invading two subsites in a single region or extending to involve an adjacent region within the nasoethmoidal complex, with or without bony invasion
T <sub>3</sub>	Tumour extends to invade the medial wall or floor of the orbit, maxillary sinus, palate or cribriform plate
T <sub>4a</sub>	Tumour invades any of the following: anterior orbital contents, skin of nose or cheek, minimal extension to anterior cranial fossa, pterygoid plates, sphenoid or frontal sinuses
T <sub>4b</sub>	Tumour invades any of the following: orbital apex, dura, brain, middle cranial nerves other than (V <sub>2</sub> ), nasopharynx or clivus

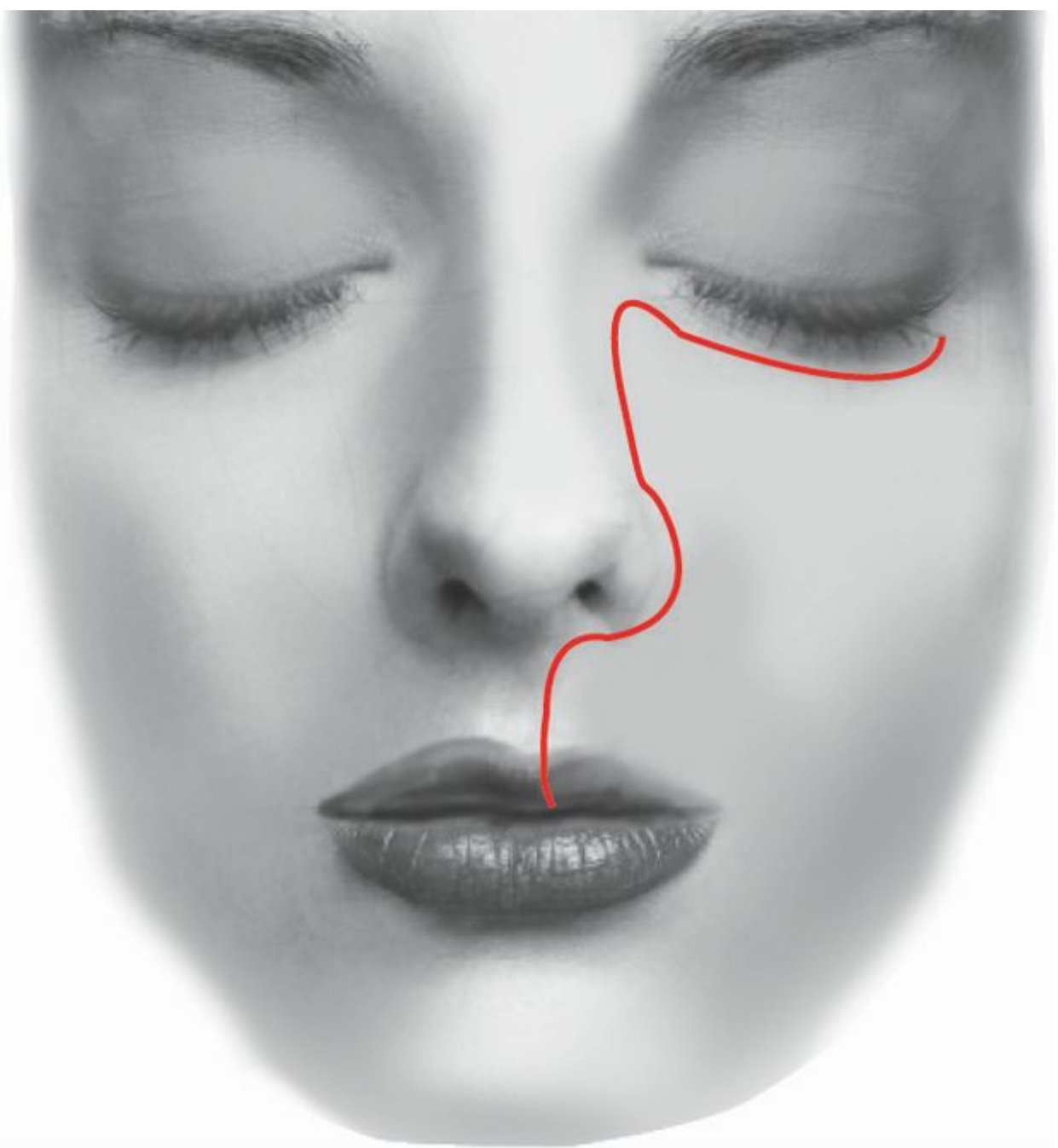
page 222

page 223

For squamous cell carcinoma, a combination of radiotherapy and surgery gives better results than either alone. Radiotherapy can be given before or after surgery. Very often, a full course of pre-operative telecobalt therapy is given, followed 4-6 weeks later by surgical excision of the growth by total or extended maxillectomy (Figs 40.6 and 40.7A,B).

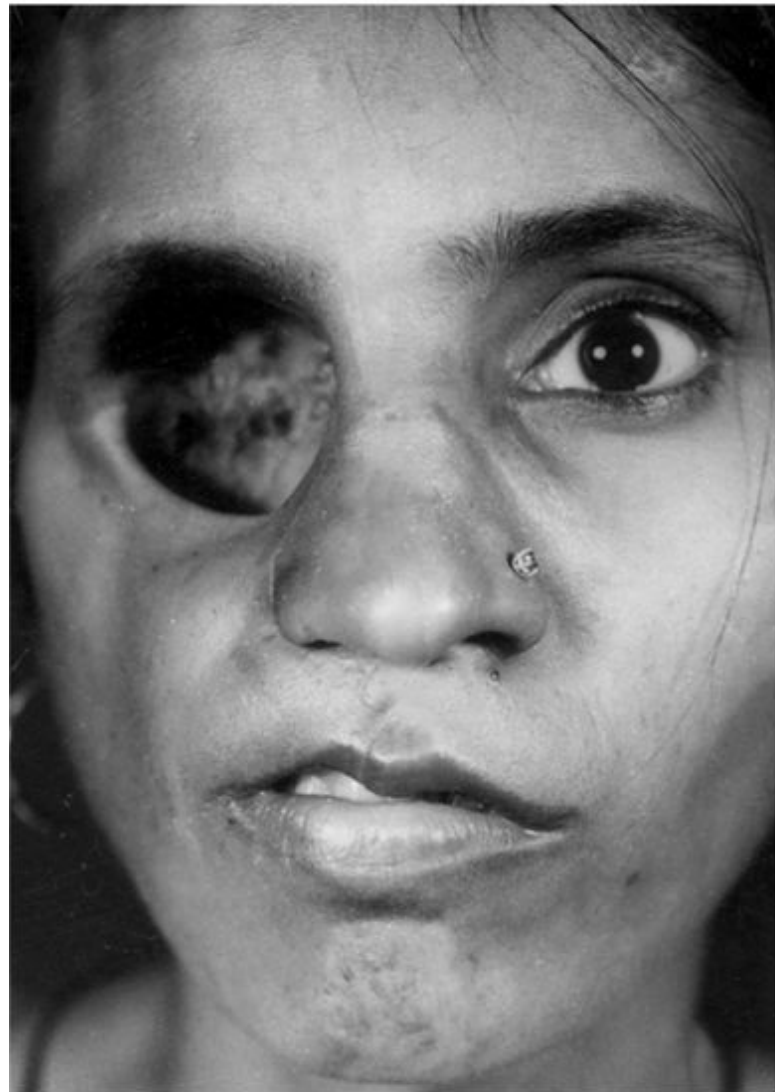## Prognosis

Overall, 5-years cure rate of 30% can be expected. However, the present concept of multimodal treatment, i.e. combining chemotherapy, radiation and surgery will further improve the results.



Dhingra: Diseases of Ear Nose and Throat, 5th Edition  
Copyright © 2010 Elsevier. All rights reserved.

Figure 40.6 Weber-Fergusson's incision used in maxillectomy .

**A****B**

Dhingra: Diseases of Ear Nose and Throat, 5th Edition  
Copyright © 2010 Elsevier. All rights reserved.

Figure 40.7 (A) Maxillectomy with orbital exenteration on the right side. (B) Same patient after rehabilitation with a maxillary prosthesis and an artificial eye.

# Ethmoid Sinus Malignancy

Ethmoid sinuses are often involved from extension of the primary growths of the maxillary sinus. Primary growth of ethmoid sinuses per se are not common.

## Clinical Features

Early features include nasal obstruction, blood-stained nasal discharge and retro-orbital pain.

Late features are: broadening of the nasal root, lateral displacement of eyeball and diplopia (Fig. 40.8). Extension through cribriform plate may cause meningitis.

Nodal involvement is not common. Upper nodes may be involved.

## Treatment

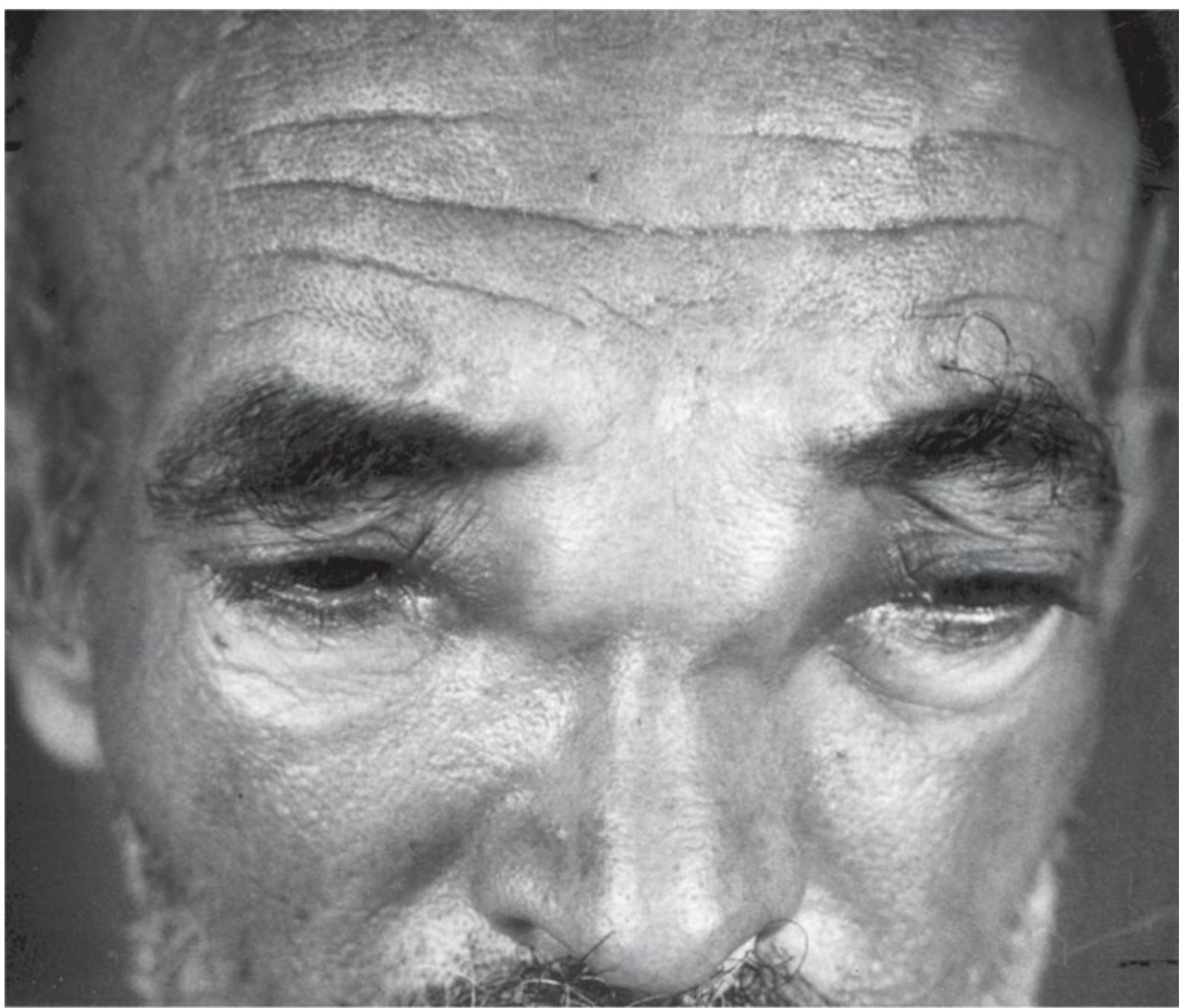
CT scan is essential to know the extent of disease and intracranial spread.

In early cases, treatment is pre-operative radiation, followed by lateral rhinotomy and total ethmoidectomy.

If cribriform plate is involved, anterior cranial fossa is exposed by a neurosurgeon and total exenteration of the growth in one piece is accomplished by what is called craniofacial resection.

## Prognosis

Five-years-cure rate of about 30% can be expected.



Dhingra: Diseases of Ear Nose and Throat, 5th Edition  
Copyright © 2010 Elsevier. All rights reserved.

Figure 40.8 Carcinoma ethmoid.

# Frontal Sinus Malignancy

Frontal sinus malignancies are uncommon and are seen in the age group of 40-50 years with male predominance (5:1).

## **Clinical Features**

Pain and swelling of the frontal region are the presenting features. Growths may erode through the floor of frontal sinus and present as a swelling above the medial canthus. Growths of frontal sinus may extend through the ethmoids into the orbit. Dura of anterior cranial fossa may be involved if growth penetrates the posterior wall of the sinus.

## **Treatment**

Frontal sinus malignancy is treated by pre-operative radiation followed by surgery. Surgery includes frontal sinusectomy with ethmoid and orbital exenteration. Neurosurgical approach may be required to resect the dura of anterior cranial fossa, if involved.



# Sphenoid Sinus Malignancy

Primary malignancy of the sinus is rare. It has to be differentiated from the inflammatory lesions in this area. Plain X-rays, CT scan and biopsy through sphenoidotomy are essential to know the nature and extent of disease. Radiotherapy is the mainstay of treatment.

page 224

page 225

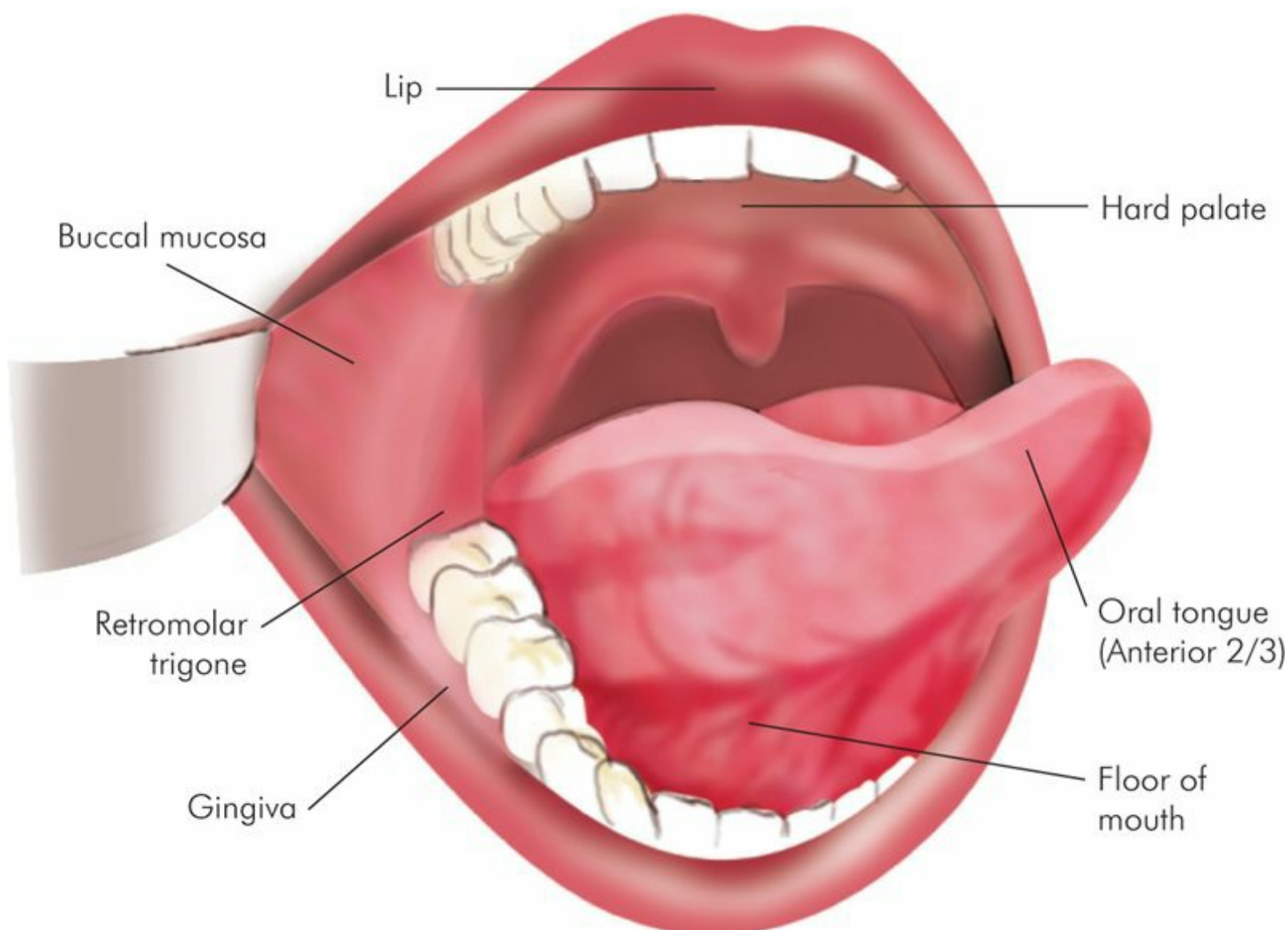
## **SECTION III Diseases of Oral Cavity and Salivary Glands**

page 225

page 226

# 41 Anatomy of Oral Cavity

## Applied Anatomy



Dhingra: Diseases of Ear Nose and Throat, 5th Edition  
Copyright © 2010 Elsevier. All rights reserved.

Figure 41.1 Various sites in oral cavity.

page 227

page 228

The oral cavity extends from the lips to the oropharyngeal isthmus, i.e. up to the level of anterior pillar of tonsils. It is divided into the following sites (Fig. 41.1):

- **1. Lips** They form anterior boundary of the oral vestibule.
- **2. Buccal or cheek mucosa** It lines the inner surface of cheeks and lips and extends up to pterygomandibular raphe. Anteriorly, it extends to the meeting line of lips.
- **3. Gums (gingivae)** They surround the teeth and cover the upper and lower alveolar ridges.
- **4. Retromolar trigone** It is a triangular area of mucosa covering anterior surface of the ascending ramus of mandible. Its base is posterior to the last molar while its apex is adjacent to the tuberosity of maxilla.
- **5. Hard palate** It forms roof of the oral cavity.
- **6. Oral tongue** Only anterior two-thirds of tongue are included in the oral cavity. Posterior one-third or base of tongue is situated behind the circumvallate papillae and forms part of the oropharynx. Oral tongue is divided into tip, lateral borders, dorsum and the undersurface.
- **7. Floor of mouth** It is a crescent-shaped area between the gingivae and undersurface of tongue. Anterior portion of the floor is best seen when patient raises the tip of tongue to touch the hard palate. Frenulum and sublingual papillae with openings of submandibular ducts can be easily seen. Lateral portion of floor of mouth is best seen by displacing the lateral surface of tongue in medial direction with the help of a tongue depressor.

## Lymphatic Drainage of Oral Cavity

- **1. Lips** *Lower:* Medial portion of lower lip drains into submental and lateral portion to submandibular nodes. *Upper:* Drain into preauricular, infraparotid and submandibular nodes.
- **2. Buccal mucosa** Submental and submandibular nodes.
- **3. Upper and lower alveolar ridges** Buccal aspect of mucosa drains into submental and submandibular nodes.  
Lingual aspect of upper alveolus drains into upper deep cervical and lateral retropharyngeal nodes.  
Lingual aspect of lower alveolus drains into submandibular nodes.
- **4. Hard palate** Upper deep cervical and lateral retropharyngeal nodes. Anterior part of palate drains into submandibular nodes.
- **5. Floor of mouth** Anterior portion of floor of mouth drains into submandibular nodes. Lymphatics from this area also cross the midline. Posterior portion drains into upper deep cervical nodes.
- **6. Tongue** Tip of tongue drains into submental and jugulo-omohyoid nodes; lateral portion drains into ipsilateral, submandibular and deep cervical nodes. Central portion and base drain into deep cervical nodes of both sides.

## **42 Common Disorders of Oral Cavity**

### **Ulcers of Oral Cavity**

Some of the common ulcers are described in this chapter. The causes of the ulcers of oral cavity are listed in Table 42.1.

# 1. Infection

## Viral

### *Herpangina*

It is a coxsackie viral infection mostly affecting children. To begin with, multiple small vesicles appear on the faucial pillars, tonsils, soft palate and uvula. They rupture to form ulcers which are usually 2-4 mm in size, have a yellow base and red areola around them. They seldom persist beyond one week.

**Table 42-1. Causes of ulcers of the oral cavity**

1. *Infections*
  - o (i) Viral: Herpangina; herpes simplex (primary and secondary); hand, foot and mouth disease
  - o (ii) Bacterial: Vincent's infection, TB, syphilis
  - o (iii) Fungal: Candidiasis
2. *Immune disorders*: Aphthous ulcer, Behcet's syndrome
3. *Trauma*
  - o (i) Physical: Cheek bite, jagged tooth, ill-fitting denture
  - o (ii) Chemical: Silver nitrate, phenol, aspirin burns
  - o (iii) Thermal: Hot food or fluid, reverse smoking
4. *Neoplasms*
5. *Skin disorders*: Erythema multiforme, lichen planus, BMMP, bullous pemphigoid, lupus erythematosus
6. *Blood disorders*: Leukaemia, agranulocytosis, pancytopenia, cyclic neutropenia, sickle cell anaemia
7. *Drug allergy*: Mouth washes, tooth paste, etc.  
Reactions to systemic drugs
8. *Vitamin deficiencies*
9. *Miscellaneous*: Radiation mucositis, cancer chemotherapy, diabetes mellitus, uraemia

### *Herpetic gingivostomatitis*

Also known as orolabial herpes. It is caused by herpes simplex virus and is of two types: primary and secondary.

The *primary infection* affects children and is characterised by clusters of multiple vesicles which soon rupture to form ulcers. Any part of the oral cavity may be affected. Constitutional symptoms like fever, malaise and headache may accompany sore throat and lymphadenopathy.

*Secondary or recurrent* herpes chiefly affects adults. It is milder in form as adults have some immunity to this virus. Most commonly, it involves the vermilion border of the lip (herpes labialis) but less often lesions appear intraorally on the hard palate and gingiva. In recurrent herpes, it is presumed that virus lies dormant in the trigeminal ganglion and, when reactivated, travels along peripheral sensory nerves to involve oropharyngeal mucosa. Precipitating factors include emotional stress, fatigue, fever, pregnancy or immune deficiency states. Treatment is mostly symptomatic. Acyclovir, 200 mg, five times a day for 5 days helps to cut down the course of recurrent herpes labialis.

### *Hand, foot and mouth disease*

It is also a viral infection affecting children. Oral lesions are seen on the palate, tongue and buccal mucosa. Vesicles also develop on the skin of hands, feet and sometimes buttocks.

## Bacterial

### *Vincent's infection (Acute necrotising ulcerative gingivitis)*

page 229

page 230

It is similar to Vincent's angina. Causative organisms are the same (a fusiform bacillus and a spirochaete-*Borrelia vincentii*). More often the disease affects young adults and middle-aged persons. It starts at the interdental papillae and then spreads to free margins of the gingivae which get covered with necrotic slough. Gingivae also become red and oedematous. Similar ulcer and necrotic membrane may also form over the tonsil (*Vincent's angina*). Diagnosis is made by smear from the affected area. Treatment is systemic antibiotics (penicillin or erythromycin and metronidazole), frequent mouth washes (with sodium bicarbonate solution) and attention to dental hygiene.

*Specific bacterial infections*. Tuberculosis, syphilis and actinomycosis may present as chronic ulcers.

## Fungal

### *Moniliasis (candidiasis)*

It is caused by *Candida albicans*, and occurs in two forms:

- **(a) Thrush.** It appears as white grey patches on the oral mucosa and tongue. When wiped off, they leave an erythematous mucosa. The condition is seen in infants and children. Adults are also affected when they are suffering from systemic malignancy and diabetes or taking broad spectrum antibiotics, cytotoxic drugs, steroids or radiation.
- **(b) Chronic hypertrophic candidiasis.** Also called *candidal leukoplakia*. The lesion appears as white patch which cannot be wiped off. Mostly affects anterior buccal mucosa just behind the angle of mouth.

Thrush can be treated by topical application of nystatin or clotrimazole. Hypertrophic form usually requires excisional surgery.

## 2. Immune Disorders

### ***Aphthous ulcers***

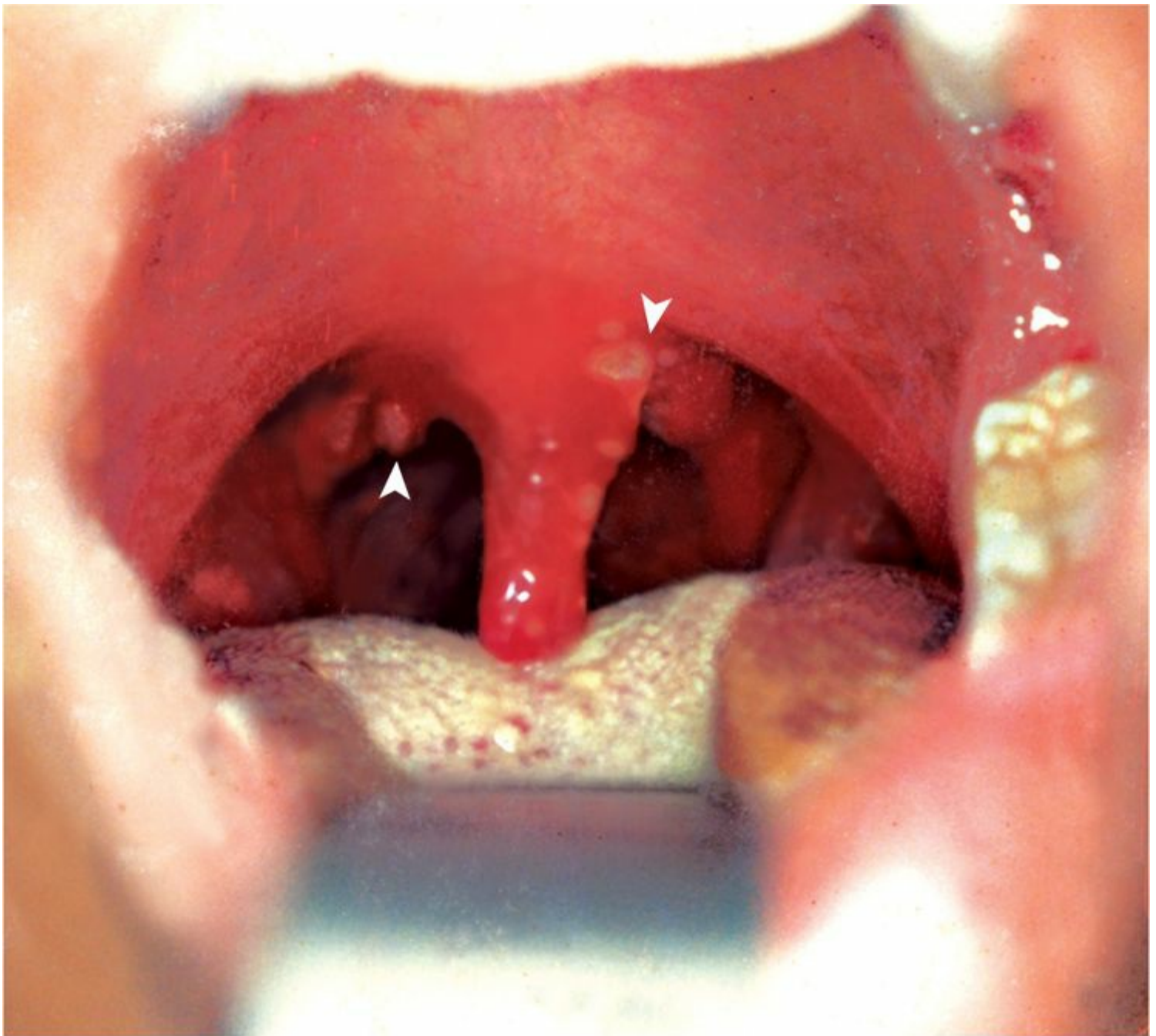
They are recurrent and superficial, usually involving movable mucosa, i.e. inner surfaces of lips, buccal mucosa, tongue, floor of mouth and soft palate, while sparing mucosa of the hard palate and gingivae. In the *minor form*, which is more common, ulcers are 2-10 mm in size and multiple with a central necrotic area and a red halo (Fig. 42.1). They heal in about 2 weeks without leaving a scar. In the *major form*, ulcer is very big, 2-4 cm in size, and heals with a scar but is soon followed by another ulcer.

Aetiology of aphthous ulcers is unknown. It may be an autoimmune process, nutritional deficiency (vitamin B<sub>12</sub>, folic acid and iron), viral or bacterial infection, food allergies or due to hormonal changes or stress.

Aphthous ulcers can be differentiated from viral ulcers by their frequent recurrence, involvement of movable mucosa as on the soft palate or cheek, and the absence of constitutional symptoms like fever, malaise and enlargement of cervical nodes.

Treatment consists of topical application of steroids and cauterisation with 10% silver nitrate. In severe cases, 250 mg of tetracycline dissolved in 50 ml of water is given as mouth rinse and then to be swallowed, four times a day. Local pain can be relieved with lignocaine viscous.

### ***Behcet's syndrome (Oculo-oro-genital syndrome)***



Dhingra: Diseases of Ear Nose and Throat, 5th Edition  
Copyright © 2010 Elsevier. All rights reserved.

Figure 42.1 Multiple aphthous ulcers on the uvula and faucial pillars (arrowheads).

### 3. Trauma

#### ***Traumatic ulcer***

A traumatic ulcer on the lateral border of tongue may be due to jagged tooth or ill-fitting denture; on the buccal mucosa due to cheek bite; and on the palate due to injury with a foreign object such as pencil or tooth brush (Fig. 42.2).

Similarly, acute ulcerative lesions of oral and oropharyngeal mucosa can result from accidental ingestion of acids or alkalies or hot fluids.

*Aspirin burn* is seen in the buccal sulcus when a tablet of aspirin is kept against a painful tooth to get relief from toothache.



## 4. Neoplasms

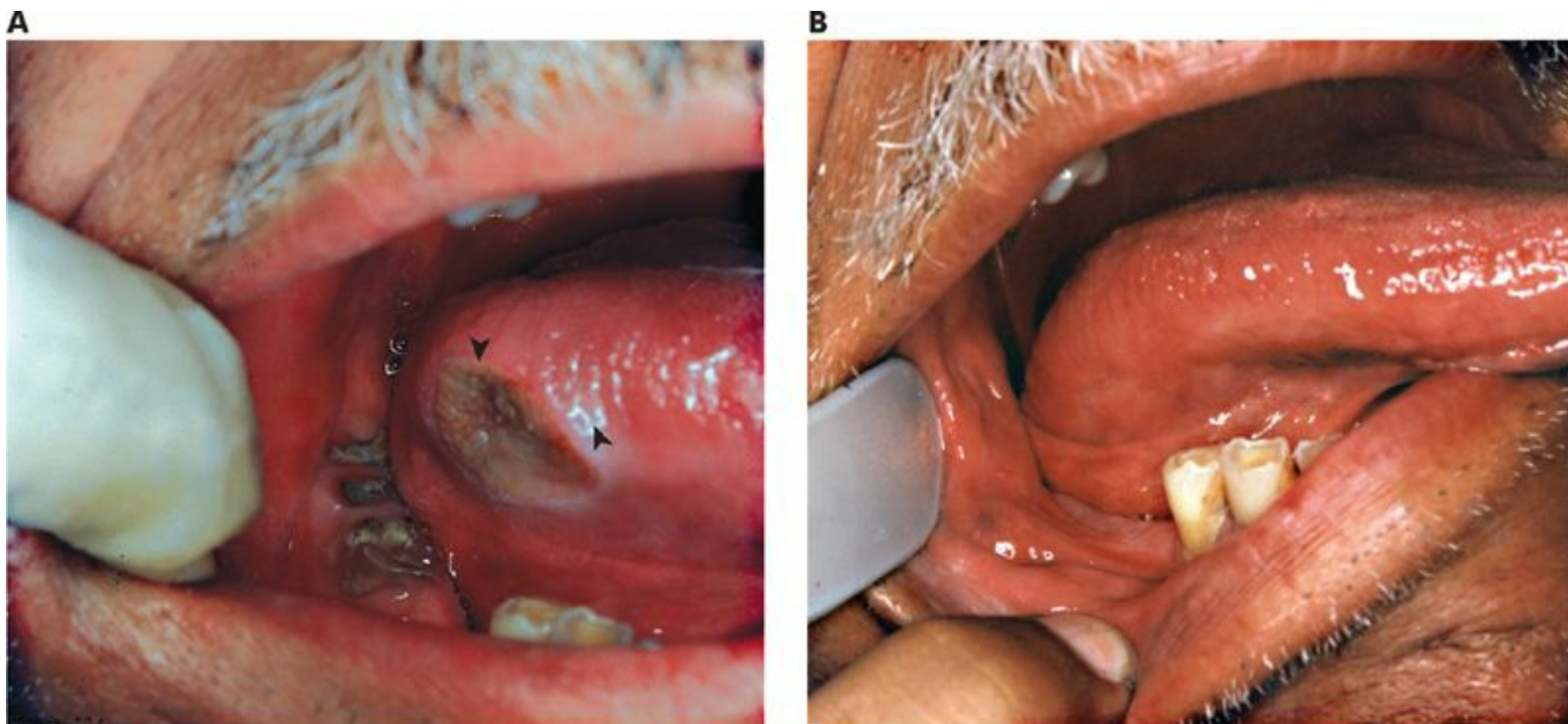
Malignancies of the oral cavity or oropharynx may present as chronic ulcers. Though most commonly it is squamous cell carcinoma, it could be carcinoma of minor salivary glands or non-Hodgkin's lymphoma.

## 5. Skin Disorders

### (i) *Erythema multiforme*

page 230

page 231



Dhingra: Diseases of Ear Nose and Throat, 5th Edition  
Copyright © 2010 Elsevier. All rights reserved.

Figure 42.2 Ulcer on lateral border of tongue simulating carcinoma (arrowheads). It was caused by a sharp jagged tooth (A) and healed completely following tooth extraction (B).

It is a disease of rapid onset involving the skin and mucous membranes, either of which may be involved alone. The aetiology is unknown but may be associated with drug allergy (sulphonamides) or recent herpes simplex infection. Oral mucosal lesions consist of vesicles or bullae which soon rupture to form ulcers covered with pseudomembrane. Any area of oral mucosa is involved but the common sites are lips, buccal mucosa and tongue. The lesions bleed easily. The distinctive feature is to form haemorrhagic crusts on the lips. Skin lesions consist of erythematous patches on the palms, soles and extensor surfaces of the extremities. Oral lesions may occur without skin involvement in 25% of patients. The disease is self-limiting and management is mainly supportive. Steroids are used to treat the severe form.

### (ii) *Pemphigus vulgaris*

It is an autoimmune disorder affecting older age group (50-70). Oral lesions are seen in 50% of the cases and may precede skin lesions.

Oral ulcerations are superficial and involve palate, buccal mucosa and tongue. Treatment consists of systemic steroids and cytotoxic drugs.

### (iii) *Benign mucous membrane pemphigoid (BMMP)*

It is also an autoimmune disorder. Mucosal lesions involve cheek, gingivae and palate. Conjunctiva is the next important site. Lesion starts as a bulla filled with clear or haemorrhagic fluid which ruptures to form superficial ulceration covered with shaggy collapsed mucosa. Skin lesions may be absent. Treatment consists of steroids.

### (iv) *Lichen planus*

Oral lesions are seen with or without skin lesions. Skin lesions are pruritic, purple, polygonal papules. They are seen on the forearms and medial side of thigh. Oral lesions occurs in two forms:

- (a) *Reticular*: White striae forming lace-like pattern are seen on the buccal mucosa on both sides. They are asymptomatic and require no treatment.
- (b) *Erosive*: It is characterised by painful ulceration on the buccal mucosa, gingiva or lateral tongue. Each ulcer is surrounded by a keratotic periphery. Treatment consists of topical steroids.

### (v) *Chronic discoid lupus erythematosus*

Oral lesions are almost always associated with skin lesions. Oral lesions are similar to those of erosive form of lichen planus.

## 6. Blood Disorders

Blood dyscrasias cause ulcerations in the oral cavity and pharynx. Due to lack of defence mechanism, e.g. granulocytes, infections quickly supervene causing ulcers. *Acute leukaemia* is mainly of 2 types-acute lymphoblastic type, which occurs in young children and acute myeloid type, occurring in the middle-aged or the elderly. Both cause hypertrophy of gums with ulceration and bleeding. *Agranulocytosis* is characterised by ulcerations in throat with severe neutropenia. *Cyclical neutropenia* is a condition with periodic falls in neutrophil count when the person becomes prone to infections and oral ulceration. In *pancytopenia*, there is a drop in RBC count, white cell count and platelets.

---

page 231

page 232

When suspected, blood dyscrasias are investigated by peripheral blood film, blood counts, and bone marrow aspiration.

## 7. Drug Allergy

Systemic administration of drugs like penicillin, tetracycline, sulpha drugs, barbiturates, phenytoin, etc. may cause erosive, vesicular or bullous lesions in the oral cavity. Contact stomatitis may occur due to local reaction to mouth washes, lozenges, chewing gum, tooth pastes or to prosthetic dental materials. Oral lesions may vary from erythema to vesicles and bullae formation.

## 8. Vitamin Deficiencies

## 9. Miscellaneous

*Radiation mucositis*. It follows radiation of oral cavity or oropharynx for cancer. At first, the mucosa becomes red and then forms spotty areas of mucositis which coalesce to form large ulcerated areas covered by slough.

Mucositis of cancer chemotherapy can be caused by drugs like methotrexate, 5-FU and bleomycin. It manifests as erythema, oedema and ulceration.

## 9. Miscellaneous

*Radiation mucositis.* It follows radiation of oral cavity or oropharynx for cancer. At first, the mucosa becomes red and then forms spotty areas of mucositis which coalesce to form large ulcerated areas covered by slough.

Mucositis of cancer chemotherapy can be caused by drugs like methotrexate, 5-FU and bleomycin. It manifests as erythema, oedema and ulceration.

# MISCELLANEOUS LESIONS OF TONGUE AND ORAL CAVITY

## ***Median rhomboid glossitis***

It is red rhomboid area, devoid of papillae, seen on the dorsum of tongue in front of foramen caecum. It is a developmental anomaly that occurs due to persistence of tuberculum impar, which fails to invaginate. Recent studies reveal this condition to be due to chronic candida infection. The condition is asymptomatic and no treatment is necessary.

## ***Geographical tongue***

It is characterised by erythematous areas, devoid of papillae, surrounded by an irregular keratotic white outline (Fig. 42.3). The lesions keep changing their shape and hence the condition is also called "migratory glossitis". The condition is asymptomatic and may not require any treatment.

## ***Hairy tongue***

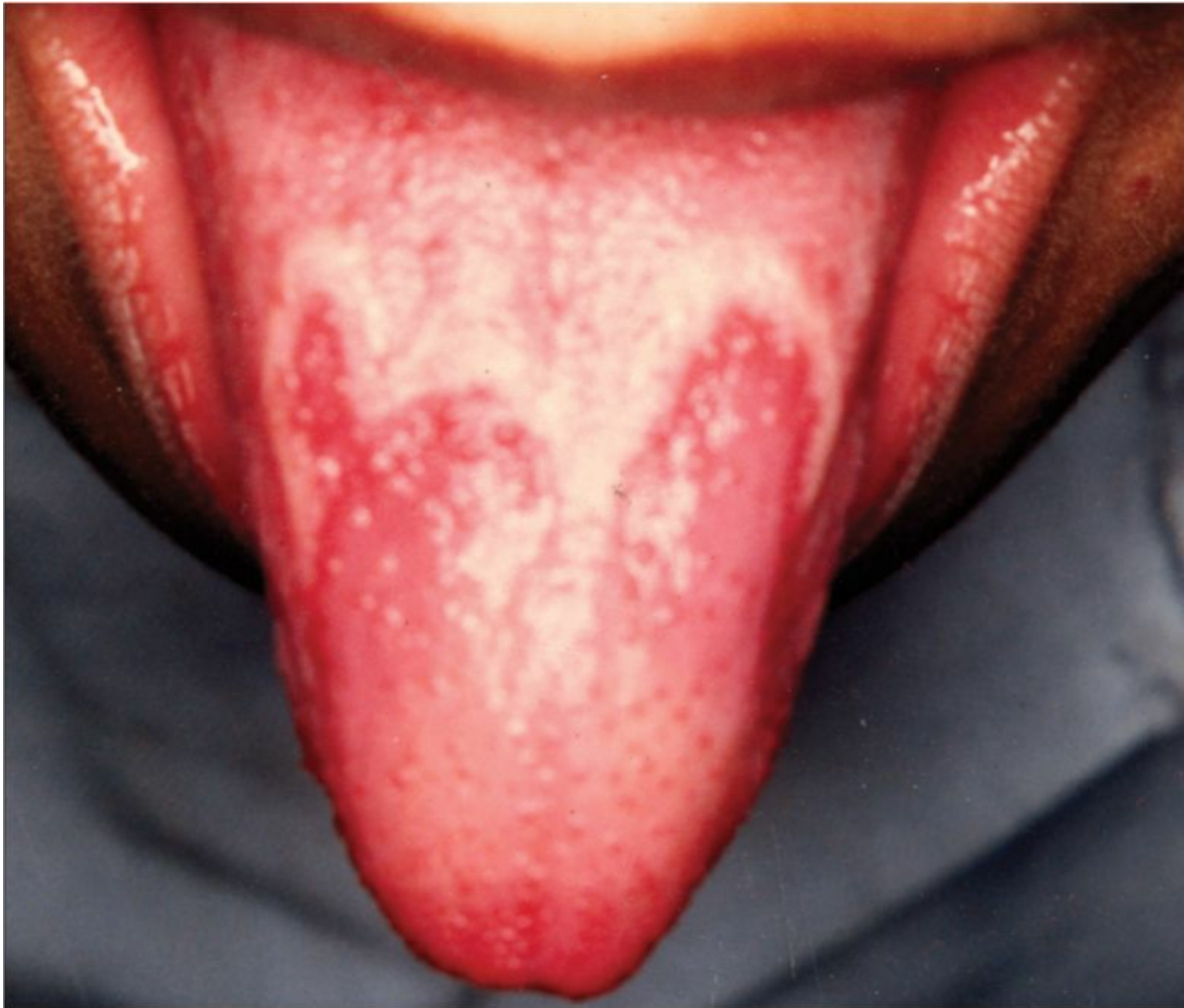Due to excessive formation of keratin, the filiform papillae on the dorsum of the tongue become elongated. They get coloured, brown or black, due to chromogenic bacteria and look like hair. Smoking seems to be one of the factors. Treatment consists of scraping the lesions with a tongue cleaner, application of half-strength hydrogen peroxide and improving the general nutritional status of the patient by vitamins. Causative factors, if known, should be removed.

## ***Fissured tongue***

It may be congenital or seen in cases of syphilis, deficiency of vitamin B complex or anaemia. Congenital fissuring associated facial palsy is seen in Melkersson-Rosenthal syndrome.

## ***Ankyloglossia (tongue tie) (Fig. 42.4)***

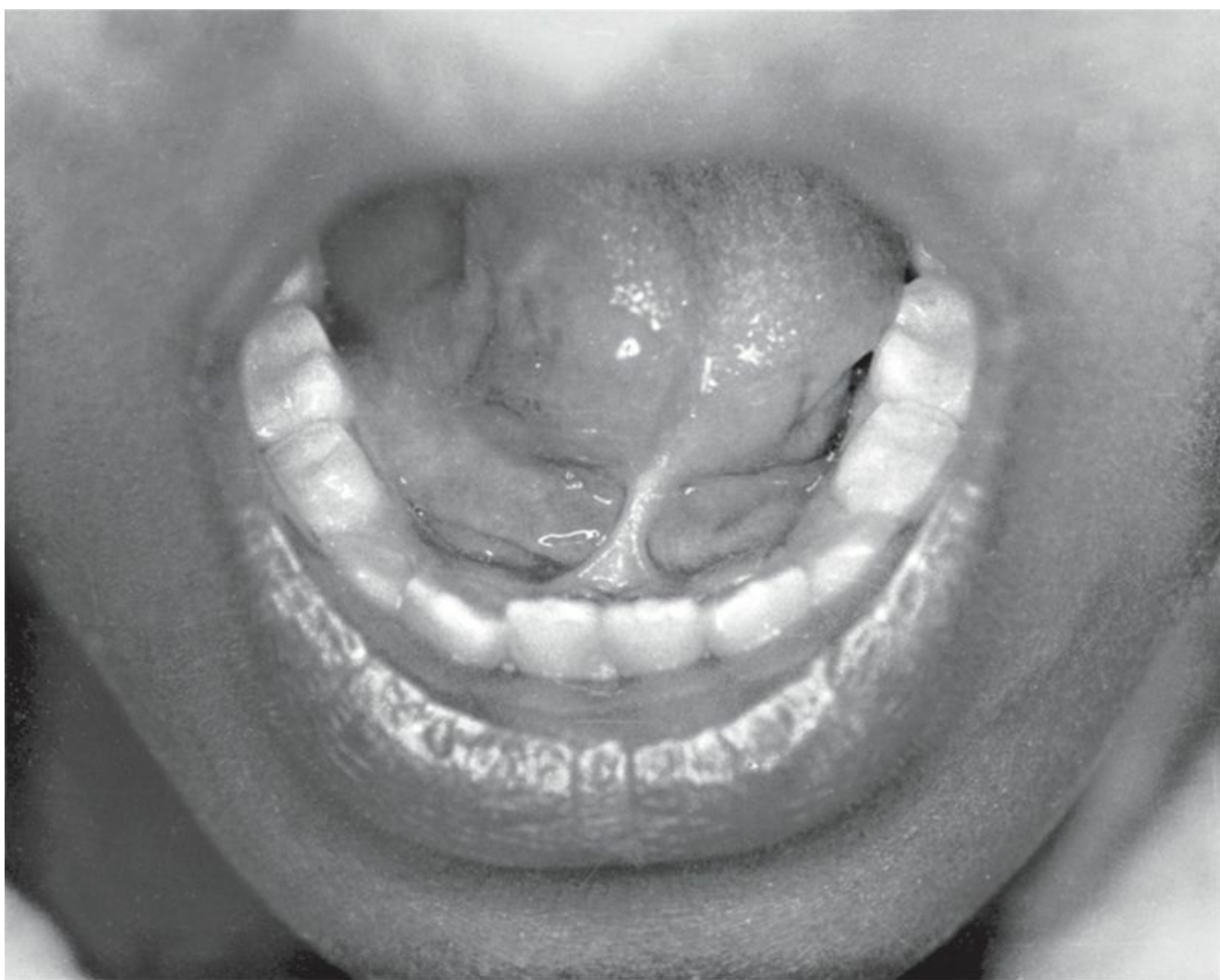True tongue tie which produces symptoms is uncommon. If tongue can be protruded beyond the lower incisors, it is unlikely to cause speech defects. A mobile tongue is important to maintain orodental hygiene-to clean the debris and prevent formation of dental plaques. Treatment of any significant tongue tie is transverse release and vertical closure. Thin mucosal folds can be simply incised.



Dhingra: Diseases of Ear Nose and Throat, 5th Edition  
Copyright © 2010 Elsevier. All rights reserved.

Figure 42.3 Geographical tongue.





Dhingra: Diseases of Ear Nose and Throat, 5th Edition  
Copyright © 2010 Elsevier. All rights reserved.

Figure 42.4 Tongue tie.

page 232

page 233

### ***Fordyce's spots***

They are aberrant sebaceous glands present under the buccal or labial mucosa and shine through it as yellowish or yellow-brown spots. They are seen with equal frequency in both males and females and are considered normal.

### ***Nicotine stomatitis***

This disorder is seen in smokers particularly those in the habit of reverse smoking. Palatal mucosa shows pin-point red spots in the centre of umbilicated papular lesions. They are due to inflammation of the minor salivary glands and their duct openings as a reaction to the heat of the smoke. The nicotine stomatitis is a misnomer as nicotine is not the cause. Management is elimination of smoking.

## **SUBMUCOUS FIBROSIS**

Oral submucous fibrosis (OSF) is a chronic insidious process characterised by juxta-epithelial deposition of fibrous tissue in the oral cavity and pharynx. The condition was first described in India by Joshi in 1953. The disease is widely seen in India, Pakistan, Taiwan, Sri Lanka, Nepal and Thailand due to habit of betel-nut chewing.

## Aetiology

- **1. Socio-economic status.** In India poor socio-economic status has been associated with higher risk of precancerous lesions like leukoplakia, erythroplakia and submucous fibrosis. This is related to education, diet, life-style and access to medical care.
- **2. Tobacco chewing.** It is a major risk factor in submucous fibrosis as it is in lesions of leukoplakia and erythroplakia.
- **3. Areca nuts.** Areca nuts are chewed alone, with tobacco or in the form of *pan* (containing lime, catechu and other ingredients on a betel leaf). Betel quid without tobacco also increases the risk of oral precancerous lesions, but causes higher risk for oral submucous fibrosis relative to leukoplakia, erythroplakia or multiple precancerous lesions. International agency for research on cancer has classified betel quid without tobacco also as a carcinogen for humans.
- **4. Alcohol.** It is observed that drinking increases the risk of leukoplakia by 1.5-fold, OSF by 2-fold and that of erythroplakia by 3-fold.
- **5. Nutritional.** Deficiency of vitamins and micronutrients has been suggested. Therapy of OSF with vitamin A, zinc and antioxidants has shown some beneficial effect. Lesser intake of fruits and vegetables has been associated with oral premalignant lesions.
- **6. Immune process.** OSF is considered a cell-mediated immune reaction to arecoline in areca nuts. It may also reflect a localized collagen disorder or an autoimmune process in the oral cavity.
- **7. Multifactorial.** Several factors may operate together in the causation of OSF. Habit of betel-nut chewing, drinking or smoking tobacco coupled with dietary deficiencies may have synergistic effect.

## Pathogenesis

Histopathology in early cases of OSF shows presence of polymorphonuclear leukocytes, eosinophils and a few lymphocytes while advanced cases show lymphocytes and plasma cells. Immunocytochemistry of inflammatory cells showed higher population of activated T-lymphocytes especially the T-helper/inducer lymphocytes but minor population of B-cells and macrophages. Later studies also showed significant increase in number of T-lymphocytes, macrophages and high CD4+ to CD8+ lymphocyte ratio in the subepithelial connective tissue suggesting that OSF is a cellular immune response. Small number of B-lymphocytes suggests minor role of humoral immunity in OSF. In advanced stages, there was severe fibrosis and loss of vascularity in the lamina propria and submucosa. The process may extend deeper into muscle layers also. Activated macrophages and T-lymphocytes produce fibrogenic cytokines which act on mesenchymal cells to produce fibrosis. Also certain cytokines liberated by T-lymphocytes upregulate synthesis of collagen but down-regulate collagenase production further promoting fibrosis. It is thus believed that OSF is due to increased production of collagen and its decreased degradation in subepithelial layers of the oral mucosa (Fig. 42.5).

## Pathology

The basic change is fibroelastotic transformation of connective tissues in lamina propria associated with epithelial atrophy, sometimes preceded by vesicle formation. In later stages, when fibrosis is marked, there is progressive trismus and difficulty to protrude the tongue.

Leukoplakia and squamous cell carcinoma may be associated with submucous fibrosis possibly because of common aetiological factors involved.

It is a premalignant condition and malignant transformation has been seen in 3-7.6% of cases.

# Clinical Features

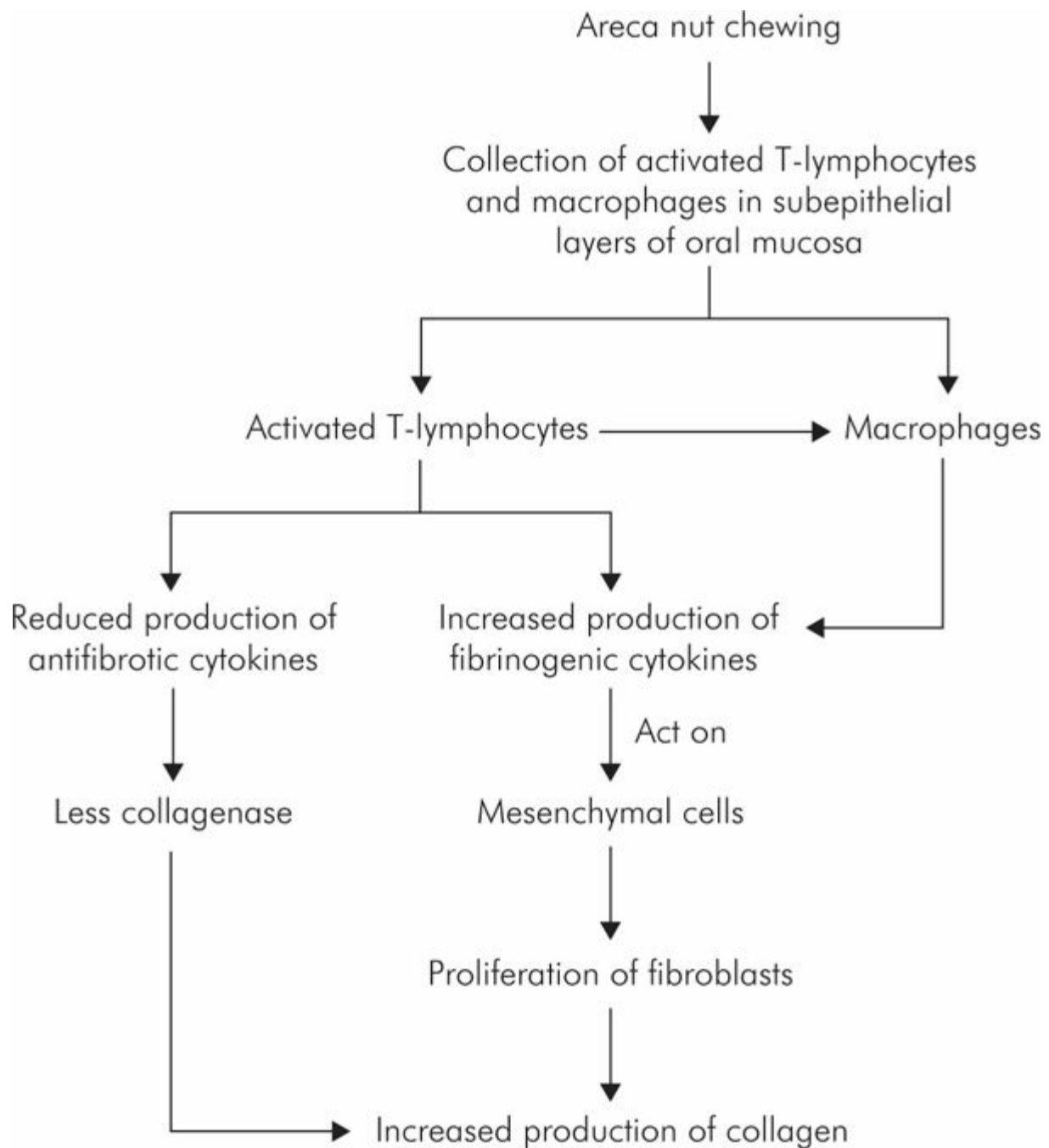
## Age and sex

No age or sex is immune but the disease mostly affects age group of 20-40.

page 233

page 234

## Symptoms



Dhingra: Diseases of Ear Nose and Throat, 5th Edition  
Copyright © 2010 Elsevier. All rights reserved.

Figure 42.5 Cellular immune response to areca nuts in oral submucous fibrosis and possible pathogenesis. (Based on CP Chiang et al. in Oral Oncology 2002;38:56-63.)

Patient often presents with:

- 1. Intolerance to chillies and spicy food.
- 2. Soreness of mouth with constant burning sensation; worsened during meals particularly of pungent spicy type.
- 3. Repeated vesicular eruption on the palate and pillars.
- 4. Difficulty to open the mouth fully.
- 5. Difficulty to protrude the tongue.

## **Findings**

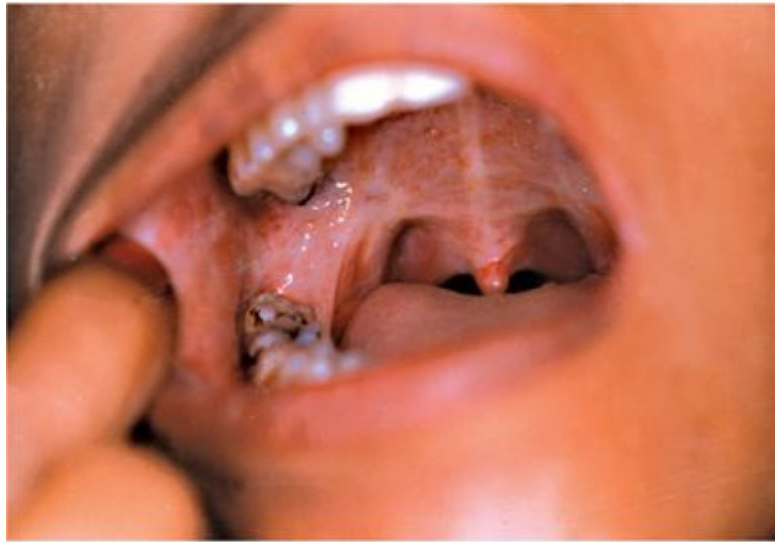Changes of submucous fibrosis are most marked over (i) soft palate, (ii) faucial pillars and (iii) buccal mucosa (Fig. 42.6). In initial stages, there is patchy redness of mucous membrane with formation of vesicles which rupture to form superficial ulcers.

In later stages, when fibrosis develops in the submucosal layers, there is blanching of mucosa with loss of suppleness. Fibrotic bands can be seen and felt in the affected areas. Fibrosis and scarring has also been demonstrated in the underlying muscle leading to further restrictive mobility of soft palate, tongue and jaw. Trismus is progressive, so much so that patient may not be able to put his finger in the mouth or brush his teeth. Oro-dental hygiene is affected badly and teeth become carious. Examination of oral cavity is difficult particularly to rule out other associated premalignant lesions or malignancy.

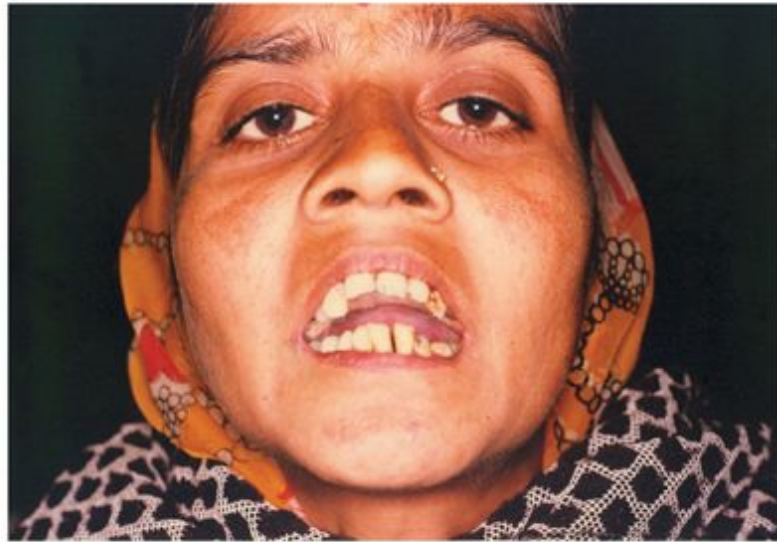## Treatment

### Medical

A



B



Dhingra: Diseases of Ear Nose and Throat, 5th Edition  
Copyright © 2010 Elsevier. All rights reserved.

Figure 42.6 Submucous fibrosis. (A) Note the blanched appearance of the soft palate and faucial pillars. (B) Marked trismus due to submucous fibrosis.

page 234

page 235

- 1. Steroids: Topical injection of steroids into the affected area is more effective than their systemic use as it also has the advantage of fewer side effects. It may be combined with hylase. Dexamethasone 4 mg (1 ml) combined with hylase, 1500 I.U. in one ml is injected into the affected area biweekly for 8-10 weeks. This brings marked improvement in symptoms and relieves trismus.
- 2. Avoid irritant factors, e.g. areca nuts, pan, tobacco, pungent foods, etc.
- 3. Treat existent anaemia or vitamin deficiencies.
- 4. Encourage jaw opening exercises.

### Surgical

It is indicated in advanced cases to relieve trismus. Various surgical techniques used are:

- 1. *Simple release of fibrosis and skin grafting.* There is high recurrence rate due to graft contracture.
- 2. *Bilateral tongue flaps.* Requires flap division at a second stage.
- 3. *Nasolabial flaps.* They are small to cover the defect completely, cause facial scar and require division of flaps at second stage.
- 4. *Island palatal mucoperiosteal flap.* It is based on greater palatine artery. Possible only in selected cases. Requires extraction of 2nd molar for the flap to sit without tension. Not suitable for bilateral cases.
- 5. *Bilateral radial forearm free flap.* It is bulky and hair-bearing. May require debulking procedure, 3rd molar may require extraction.
- 6. *Surgical excision and buccal fat pad graft.*
- 7. *Superficial temporal fascia flap and split skin graft.*
- 8. *Coronoidectomy and temporal muscle myotomy.*



## 43 Tumours of Oral Cavity

### Classification

The tumours of oral cavity can be classified as follows:

- **I. Benign tumours**
  - (a) Solid
  - (b) Cystic
- **II. Premalignant lesions**
- **III. Malignant lesions**
  - (a) Carcinoma
  - (b) Non-squamous malignant lesions

# I. BENIGN TUMOURS

## Solid Tumours

### 1. Papilloma

Papillomas are common in the oral cavity. Peak incidence is in the third to fifth decades. Most of them appear on the soft and hard palate, uvula, tongue and lips. Mostly they are less than 1 cm in size, pedunculated and white in colour. Their surface is irregular but sometimes smooth. Treatment is excisional biopsy. Recurrence is rare.

### 2. Fibroma (fibroepithelial polyp)

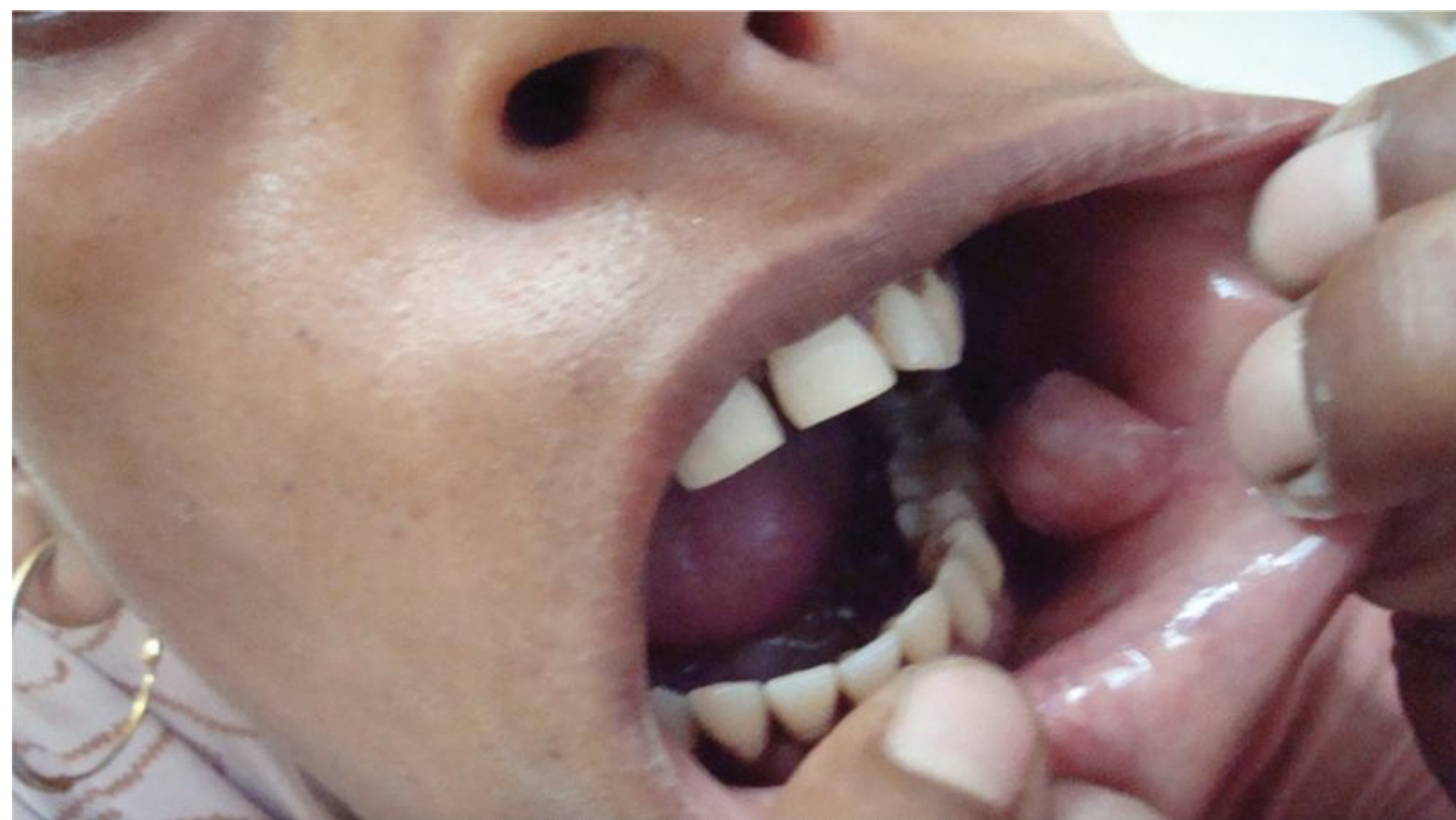It is a smooth, mucosa-covered pedunculated tumour, usually about 1 cm in size and soft to firm in consistency. It can occur anywhere in the oral or oropharyngeal mucosa (Fig. 43.1). The usual cause is chronic irritation. It is easily treated by conservative surgical excision.

### 3. Haemangioma

Mucosal haemangiomas can occur in the oral cavity or oropharynx (Fig. 43.2). They are mostly seen in children. Three types of haemangiomas are known: *capillary*, *cavernous* and *mixed*. When haemangiomas are present at birth or in young children, they should be observed for some period as spontaneous regression can occur.

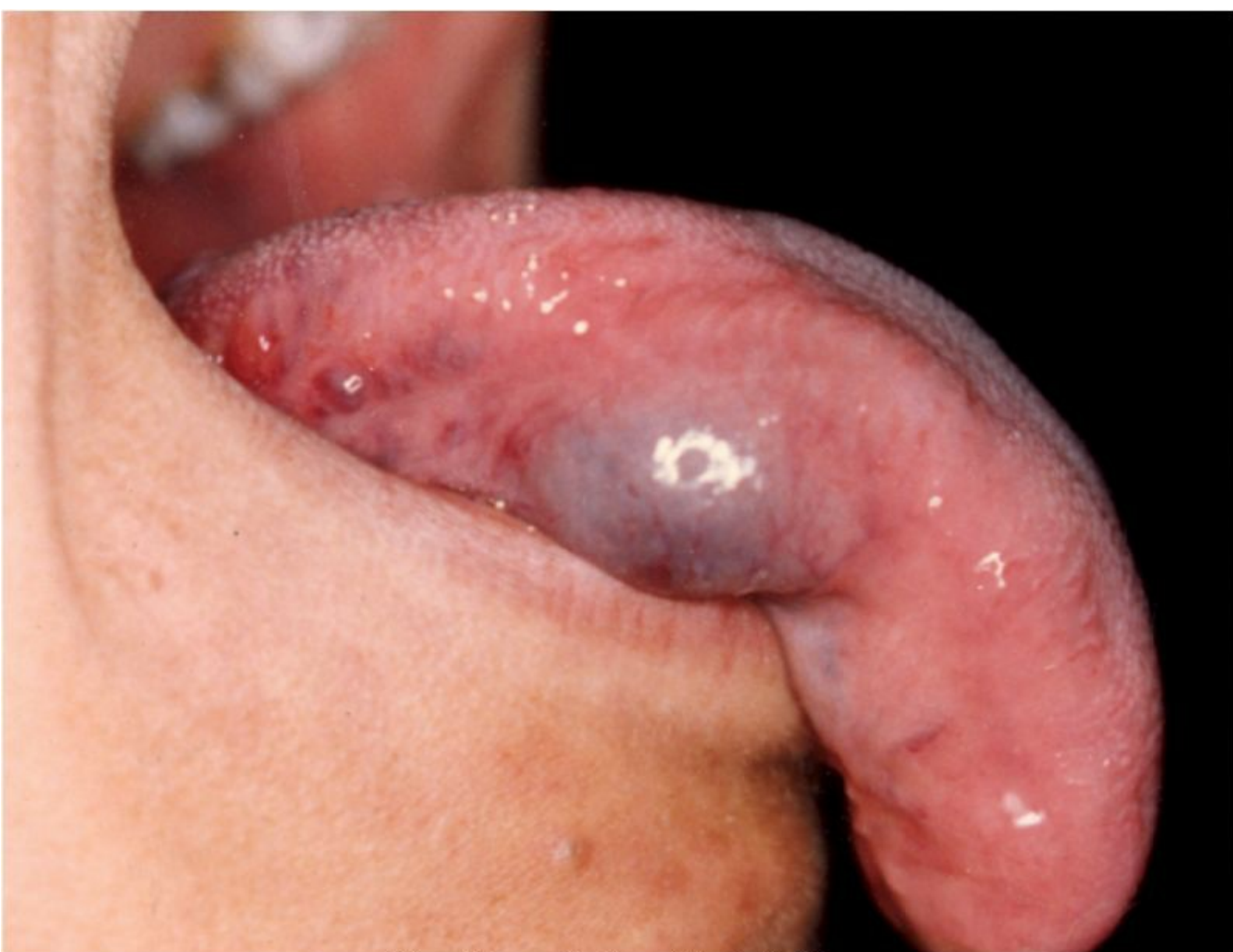In patients of 40-50 years, haemangioma-like dilated veins (phlebostasis) may occur on the oral or lingual mucosa.

An infected haemangioma may be difficult to differentiate from a pyogenic granuloma. Haemangiomas that are large and persistent or those which continue to grow are problematic. Use of cryosurgery or laser is not possible in large diffuse lesions. Sclerotherapy has also not been found effective. However, microembolisation alone or as a pre-operative adjunct to surgery has been found very useful.



Dhingra: Diseases of Ear Nose and Throat, 5th Edition  
Copyright © 2010 Elsevier. All rights reserved.

Figure 43.1 Fibroepithelial polyp left cheek.



Dhingra: Diseases of Ear Nose and Throat, 5th Edition  
Copyright © 2010 Elsevier. All rights reserved.

Figure 43.2 Haemangioma on the lateral border of tongue.

#### **4. Lymphangioma**

Lymphangiomas mostly involve anterior two-thirds of tongue. They may involve the tongue diffusely and cause macroglossia or may present as localised soft swelling which is compressible. They do not involute spontaneously. Small lesions can be excised surgically. Symptomatic large lesions can be partially excised to reduce the bulk. Total excision of these lesions is not possible.

#### **5. Torus**

It is a submucosal bony outgrowth. It may involve the hard palate or mandible. Palatine torus is more common and presents as a narrow ridge, solitary nodule or a lobulated mass in the midline of the hard palate.

Mandibular tori project from the lingual aspect of the gingiva, near the bicuspid area, and are bilateral. Tori are innocuous and resection is indicated only when they interfere with speech, mastication or the fitting of dentures.

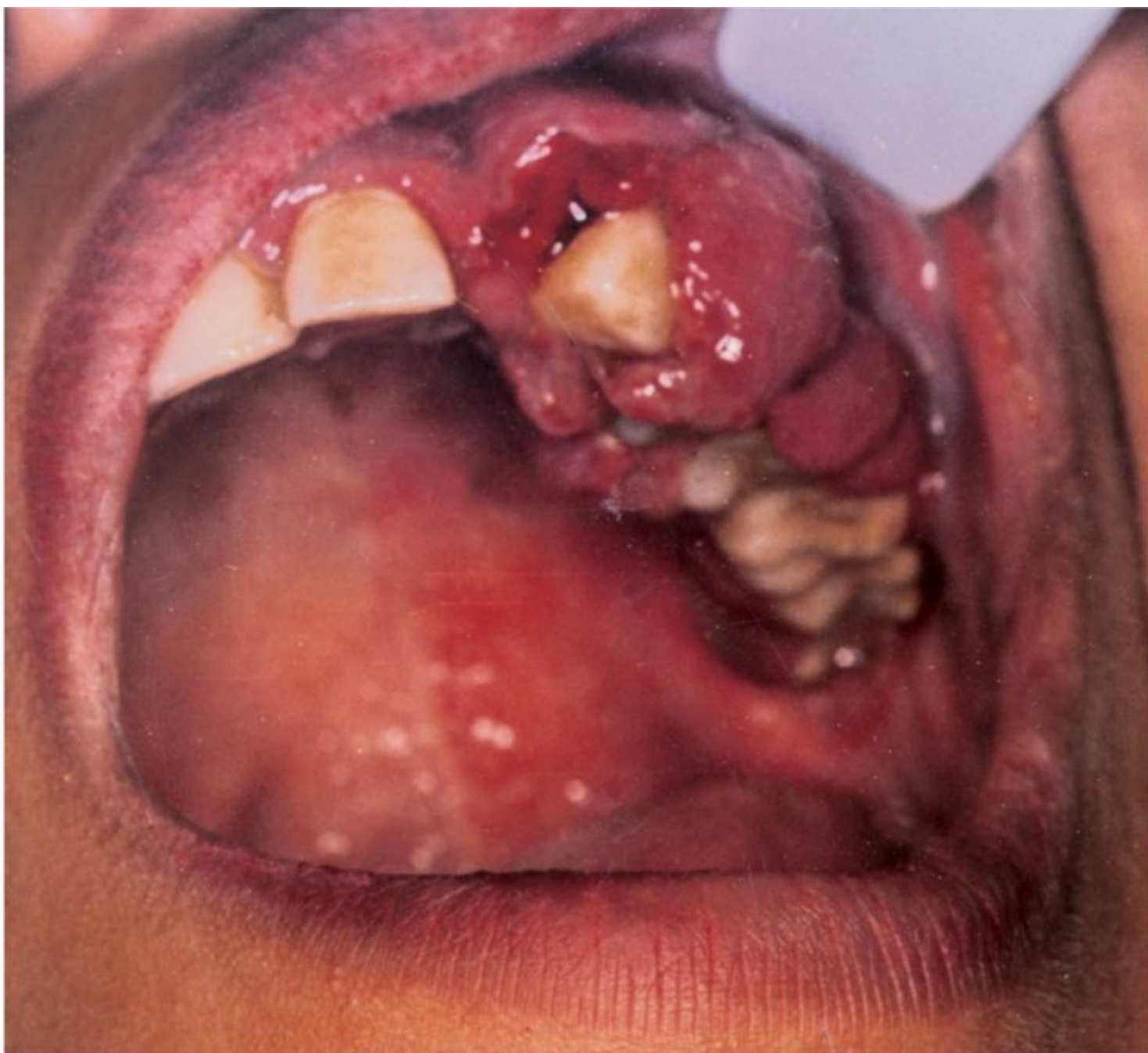#### **6. Pyogenic granuloma (Fig. 43.3)**

It is a reactive granuloma usually occurs in response to trauma or chronic irritation. It mostly involves anterior gingivae but sometimes the other sites such as tongue, buccal mucosa or lips. Usually it is soft, smooth, reddish to purple mass which bleeds on touch. Treatment is surgical excision. Recurrence is unlikely after complete excision.

#### **7. Pregnancy granuloma**

It is clinically and histologically similar to pyogenic granuloma. It usually starts in the first trimester of pregnancy and regresses once pregnancy has ended. It is excised only if it persists after pregnancy. It is likely to recur if operated during pregnancy.

#### **8. Granular cell myoblastoma or granular cell tumour**



Dhingra: Diseases of Ear Nose and Throat, 5th Edition  
Copyright © 2010 Elsevier. All rights reserved.

Figure 43.3 Pyogenic granuloma.

Most of these tumours occur in the oral cavity and the site of predilection is tongue. Earlier they were thought to arise from the muscle (hence called myoblastoma) but are now considered to be derived from Schwann cells. The tumour presents as a firm submucosal nodule; Treatment is conservative surgical excision. Recurrence is uncommon.

*Congenital epulis* is also a granular cell tumour involving the gums of future incisors in female infants.

#### **9. Minor salivary gland neoplasms**

Pleomorphic adenoma is the most common. Site of predilection is soft or hard palate but can occur anywhere in the oral cavity. It presents as a painless submucosal nodule. Treatment is wide surgical excision because of the high incidence of recurrence.

# Cystic Lesions

## 1. Mucocele

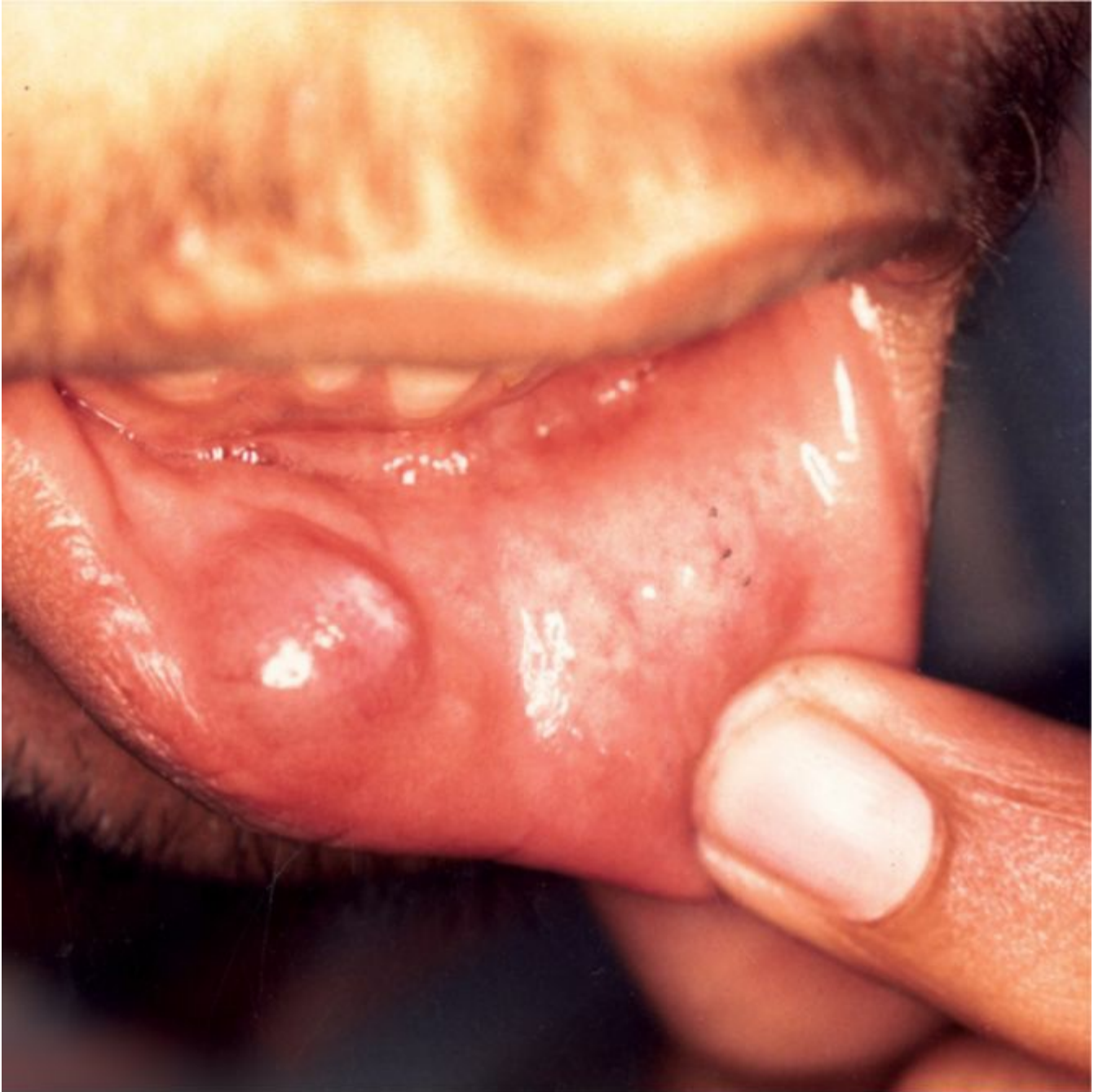Most common site is the lower lip (Fig. 43.4). It is a retention cyst of minor salivary glands of the lip. The lesion appears as a soft and cystic mass of bluish colour. Treatment is surgical excision.

## 2. Ranula (Fig. 43.5)

It is a cystic translucent lesion seen in the floor of mouth on one side of the frenulum and pushing the tongue up. It arises from the sublingual salivary gland due to obstruction of its ducts. Some ranulae extend into the neck (plunging type).

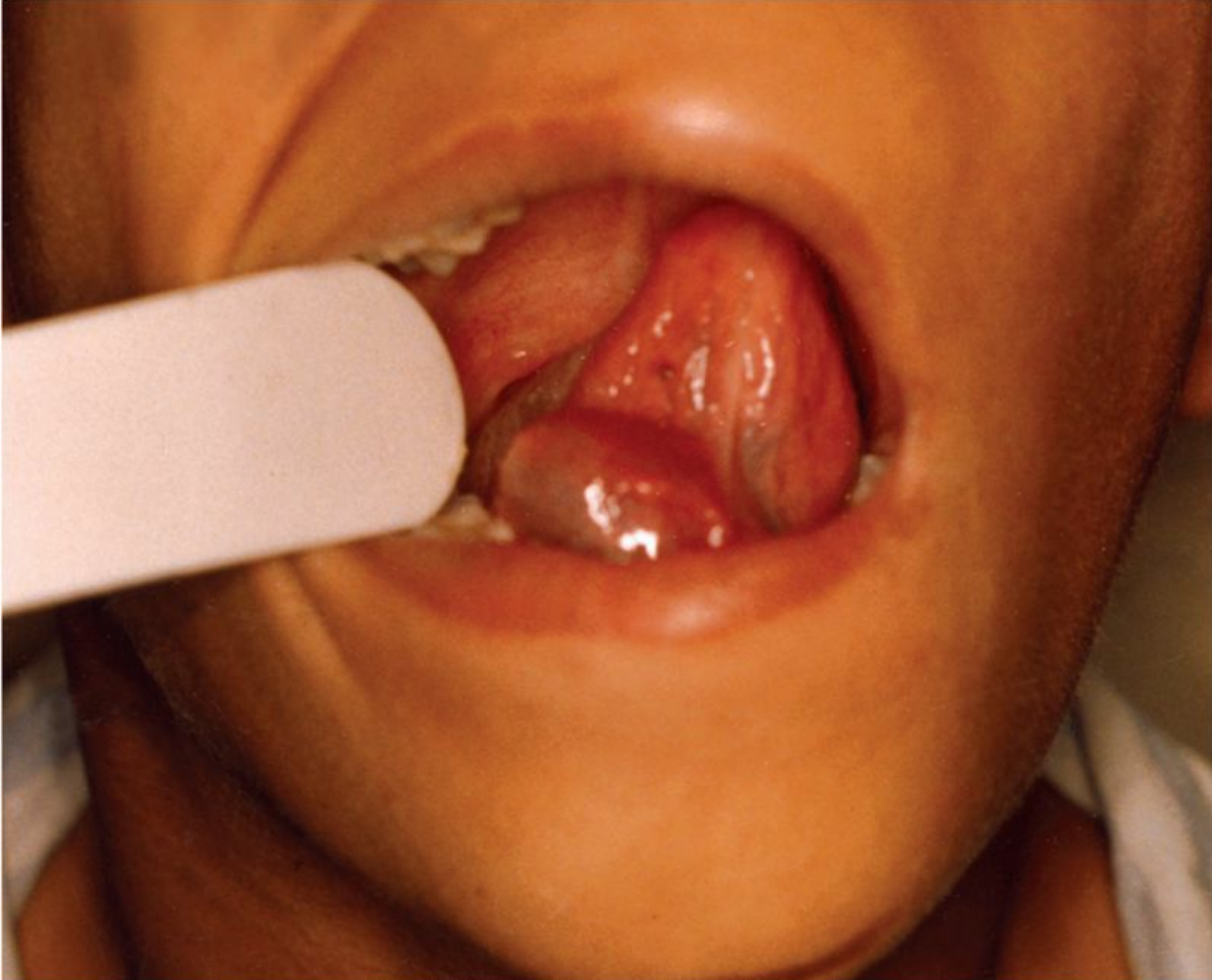
*Treatment* is complete surgical excision if small, or marsupialisation, if large. Often it is not possible to excise the ranula completely because of its thin wall or ramifications in various tissue planes.

## Dermoid



Dhingra: Diseases of Ear Nose and Throat, 5th Edition  
Copyright © 2010 Elsevier. All rights reserved.

Figure 43.4 Mucocele of the lower lip.



Dhingra: Diseases of Ear Nose and Throat, 5th Edition  
Copyright © 2010 Elsevier. All rights reserved.

Figure 43.5 Ranula. Note a translucent swelling under the tongue.

A sublingual dermoid is median or lateral, situated above the mylohyoid. It shines through the mucosa as a white mass in contrast to the translucent nature of the ranula. A submental dermoid develops below the mylohyoid and presents as a submental swelling behind the chin.

## II. PREMALIGNANT LESIONS

### **Leukoplakia**

WHO defined leukoplakia as a *clinical* white patch that cannot be characterised clinically or pathologically as any other disease. It is a clinical definition and does not take pathology into consideration. Other white lesions of oral mucosa, i.e. lichen planus, discoid lupus erythematosus, white spongy nevus and candidiasis are excluded.

*Aetiologic factors* include smoking, tobacco chewing, alcohol abuse particularly, if combined with smoking. Chronic trauma can also occur due to ill-fitting dentures or cheek bites. It may also be associated with submucous fibrosis, hyperplastic candidiasis or Plummer-Vinson syndrome.

*Sites involved.* Buccal mucosa and oral commissures are the most common sites. It may however involve floor of mouth, tongue, gingivobuccal sulcus and the mucosal surface of lip. Buccal mucosa is the most common site in India.

*Age and Sex.* Mostly, it is seen in the fourth decade, males are affected two to three times more often.

*Clinical types.* (a) *Homogenous* variety presents with a smooth or wrinkled white patch. It is less often associated with malignancy; (b) *Nodular (speckled)* variety presents as white patches or nodules on erythematous base; (c) *Erosive (erythroleukoplakia)* variety where leukoplakia is interspersed with erythroplakia and has erosions and fissures. The latter two varieties have higher incidence of malignant transformation.

*Histology.* About 25% of leukoplakias may show some form of epithelial dysplasia from mild to severe. Higher the grade of dysplasia more are the chances of its going into malignant change.

*Malignant potential.* The chances of leukoplakia becoming malignant are cited from 1 to 17.5%. On an average about 5% become malignant. Malignant potential varies according to the site and type of leukoplakia, and the duration of follow up.

### **Management**

- 1. Many of the lesions will disappear spontaneously if causative agent is removed.
- 2. In lesions with higher potential for malignant change, a biopsy is taken to rule out malignancy.
- 3. In suspicious small lesions, surgical excision or ablation with laser or cryotherapy can be done.

### **Erythroplakia**

Similar to leukoplakia, which is a white patch, erythroplakia is a red patch or plaque on the mucosal surface. Red colour is due to decreased keratinisation, and as a result the red vascular connective tissue of the submucosa shines through. There is no sex predilection. Most common sites are lower alveolar mucosa, gingivobuccal sulcus and the floor of the mouth. Most of lesions of erythroplakia show severe dysplasia, carcinoma in situ or a frank invasive carcinoma when first seen. Malignant potential is 17 times higher than in leukoplakia. Grossly, the lesion may be of three varieties-homogenous, speckled or granular, and erythroplakia, interspersed with areas of leukoplakia (often indistinguishable from erythroleukoplakia, type of leukoplakia). Treatment is excision biopsy and follow up.

### **Melanosis and mucosal hyperpigmentation**

Benign pigmented lesions of oral mucosa may transform into malignant melanomas; however, the incidence of this change is not known. About one-fourth of mucosal melanomas may resemble benign lesions and hence biopsy may become mandatory.

# MALIGNANT LESIONS

## Carcinoma Oral Cavity

### Aetiology

page 238

page 239

Compared to western countries, India has high incidence of oral cancers. Age adjusted incidence rate in India is 44.8 and 23.7 in males and females, respectively. Compared to 11.2 per 100,000 in USA. Several aetiological factors are responsible. (6-S aetiology, i.e. smoking, spirits, sharp jagged tooth, sepsis, syndrome of Plummer-Vinson and syphilitic glossitis).

- **(a) Smoking.** Incidence of oral cancer is six times more in smokers than in non-smokers. In certain parts of India, there is an unusual habit of reverse smoking where burning end of the "churat" (rolled tobacco leaf) is put in the mouth. This gives high incidence of cancer of the hard palate.
- **(b) Tobacco chewing.** Powdered tobacco, mixed with lime, is placed in some part of the vestibule of the mouth. Carcinoma develops at the site of the quid. Chewing "pan" and keeping the quid in the vestibule is largely responsible for oral cancer in our country.
- **(c) Alcohol.** Cancer of upper aerodigestive tract occurs six times more in heavy drinkers as compared to nondrinkers.
- **(d) Dietary deficiencies.** Their role in genesis of cancer has not been definitely established. Riboflavin deficiency may be responsible for cancer in alcoholics. Paterson-Brown-Kelly syndrome also called Plummer-Vinson syndrome (iron deficiency anaemia) is responsible for cancer of the oral cavity and hypopharynx.
- **(e) Dental sepsis, jagged sharp teeth and ill fitting dentures,** all cause chronic irritation and may lead to development of cancer.

#### Sites of cancer in the lip and oral cavity are (AJCC 2002):

- 1. Mucosal lip (from junction of skin-vermilion border to line of contact of upper and lower lip)
- 2. Buccal mucosa (includes mucosa of cheek and inner surface of lips up to line of contact of opposing lip)
- 3. Anterior two thirds of tongue (oral tongue)
- 4. Hard palate
- 5. Lower alveolar ridge
- 6. Upper alveolar ridge
- 7. Floor of mouth
- 8. Retromolar trigone.

Clinical presentation and treatment of cancer of the oral cavity at different sites are described below.

### 1. Carcinoma Lip (Fig. 43.6)

Mostly, it is squamous cell carcinoma, often seen in males in the age group of 40-70. Lower lip is more often involved. Site of predilection is between the midline and commissure of the lip. Lesion is of exophytic or ulcerative type. Lymph node metastases develop late. Submental and submandibular nodes are the first to be involved; other deep cervical nodes may also get involved later.

*Treatment* is surgical excision with adequate safety margin of healthy tissue and plastic repair of the defect. Lymph node metastases require block dissection.

Radiotherapy also gives good results in early cases.

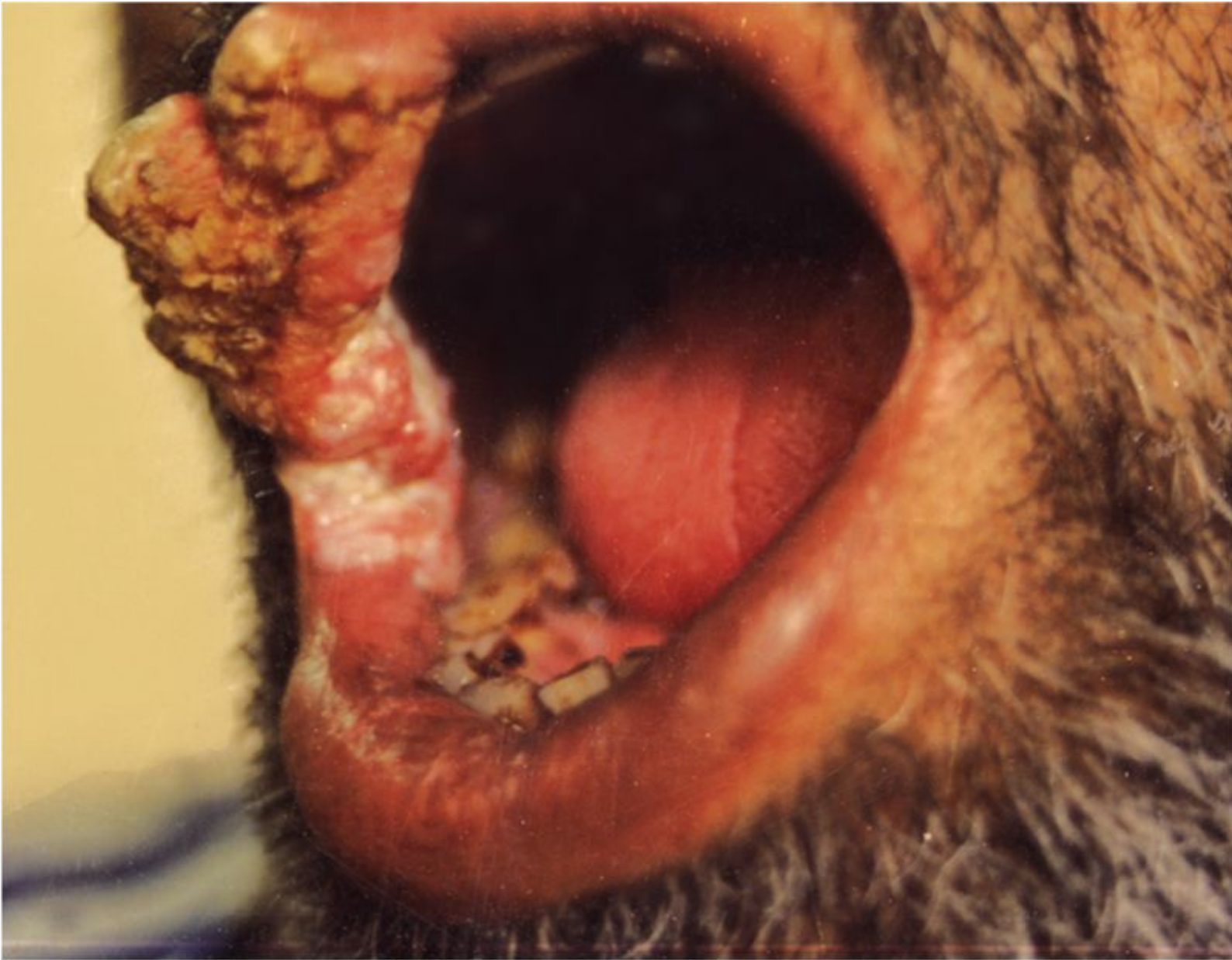### 2. Carcinoma Buccal Mucosa (Fig. 43.7)

Buccal mucosa covers a large area. It extends from the meeting point of lips in front to the pterygomandibular raphe behind and from upper gingivobuccal sulcus to the lower one.

Carcinoma of buccal mucosa is very common. Its incidence is next only to tongue cancer. Equally seen in both sexes.

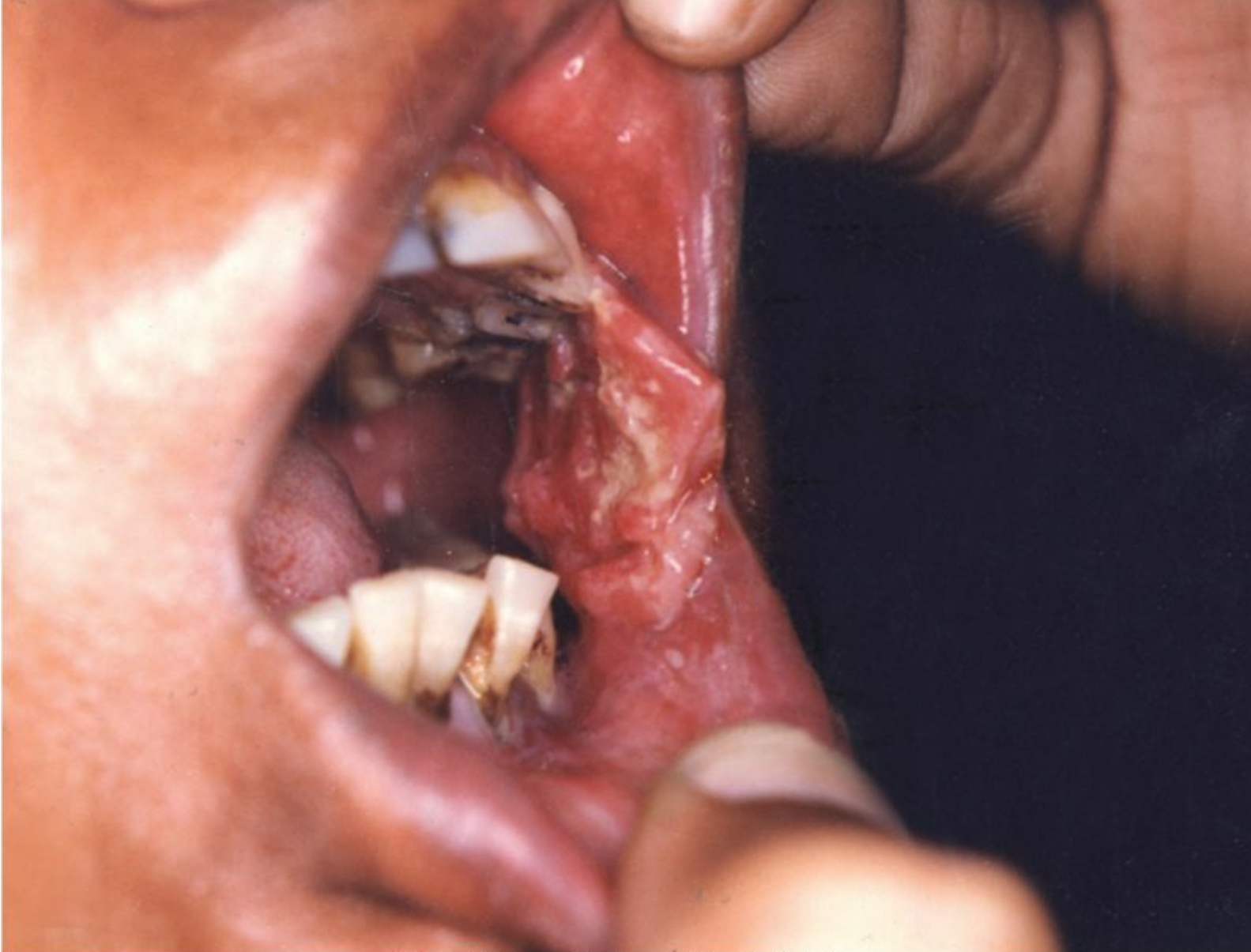*Site of origin:* Most common site is the angle of mouth or the line of occlusion of upper and lower teeth. It may also arise from the buccal sulcus where "pan" or tobacco quid is kept. As the whole of buccal mucosa is "condemned", carcinoma may be multicentric.





Dhingra: Diseases of Ear Nose and Throat, 5th Edition  
Copyright © 2010 Elsevier. All rights reserved.

Figure 43.6 Carcinoma upper lip and oral commissure. Note associated leukoplakia.



Dhingra: Diseases of Ear Nose and Throat, 5th Edition  
Copyright © 2010 Elsevier. All rights reserved.

Figure 43.7 Carcinoma buccal mucosa.

**Gross appearance.** Lesion may be exophytic or ulceroinfiltrative; the latter may infiltrate deeply. Exophytic type may be associated with erythroleukoplakia. Buccal mucosa is also the most common site for verrucous carcinoma which is a white papillary growth with considerable keratinisation.

**Local spread.** From its site of origin, the lesion may spread *deeply* involving submucosa → muscle → subcutaneous fat → skin. Involvement of buccinator muscle or anterior masseter causes trismus.

Tumour may spread radially from its site of origin and involve angle of the mouth and lip anteriorly, retromolar trigone and medial pterygoid posteriorly, upper gingivobuccal sulcus and maxilla superiorly, lower gingivobuccal sulcus and alveolar ridge and gums inferiorly.

**Lymphatic spread.** Nodal involvement occurs in about 50% of cases. Submandibular and later the upper jugular nodes may get involved. Upper jugular nodes may also be involved, directly skipping the submandibular group.

**Clinical features.** Early lesions are asymptomatic. Pain and bleeding are seen when lesions are ulcerative and invade deeply. Involvement of the buccinator, masseter or the pterygoid muscles causes trismus. Fungating mass over the cheek, or a foul-smelling bleeding mass in the oral cavity are late features.

**Histological type:** Squamous cell carcinoma is the most common. Tumours can also arise from minor salivary glands with histology as in salivary gland tumours.

**Investigations.** Biopsy of the lesion for histological type of the growth. CT scan for involvement of bone (mandible or maxilla) and extension into

infratemporal fossa.

### **Treatment**

Stage I (T<sub>1</sub> N<sub>0</sub>): Surgical excision.

Stage II (T<sub>2</sub> N<sub>0</sub>): (a) Radiotherapy to primary lesion and also nodes if bone is not involved.

(b) If bone (maxilla/mandible) is involved or growth infiltrates the muscle, surgery is the treatment of choice. It involves excision of the growth, marginal or segmental mandibulectomy (or partial maxillectomy) and reconstruction of the area with skin or mucosal flaps.

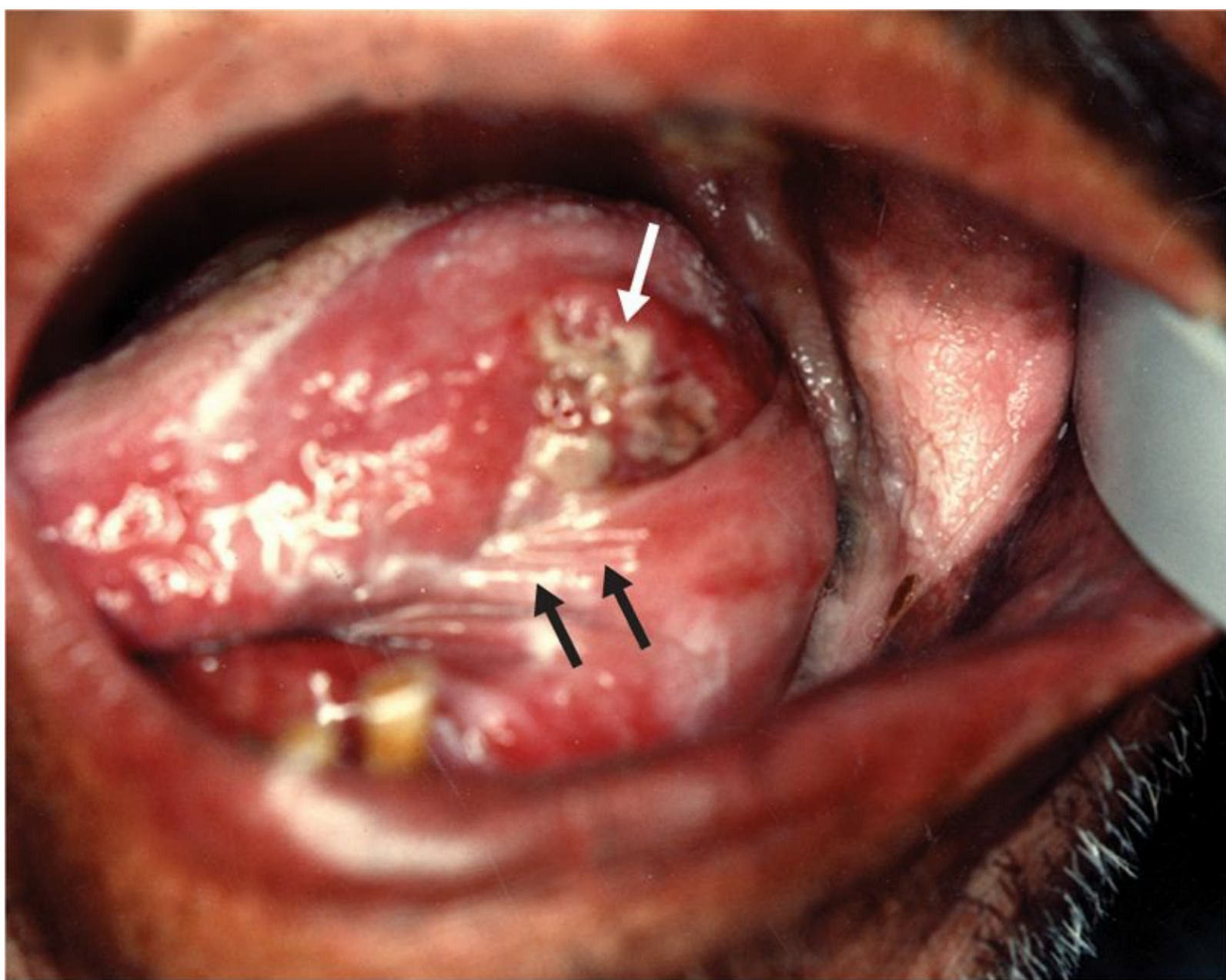Stage III and IV: Surgical resection, reconstruction with skin and/or myocutaneous flaps and post-operative radiotherapy to the site of lesion and nodes. Surgical resection is combined with neck dissection if nodes are clinically palpable.

## **3. Carcinoma Oral Tongue (Table. 43.1)**

**Table 43-1. Incidence of cancer per 100,00 population in India in year 2000\***

	<b>Males</b>	<b>Females</b>	<b>Average</b>	<b>Proportion relative to all body cancers</b>
Lip	0.25	0.12	0.18	0.32%
Mouth	3.42	2.97	3.19	4.46%
Tongue	3.23	1.15	2.19	3.13%

\*National Cancer Registry Programme (Indian Council of Medical Research), Bangalore, published, April 2005.



Dhingra: Diseases of Ear Nose and Throat, 5th Edition  
Copyright © 2010 Elsevier. All rights reserved.

Figure 43.8 Carcinoma lateral border of the tongue (arrow). Note associated leukoplakia of floor of mouth (Double arrows).

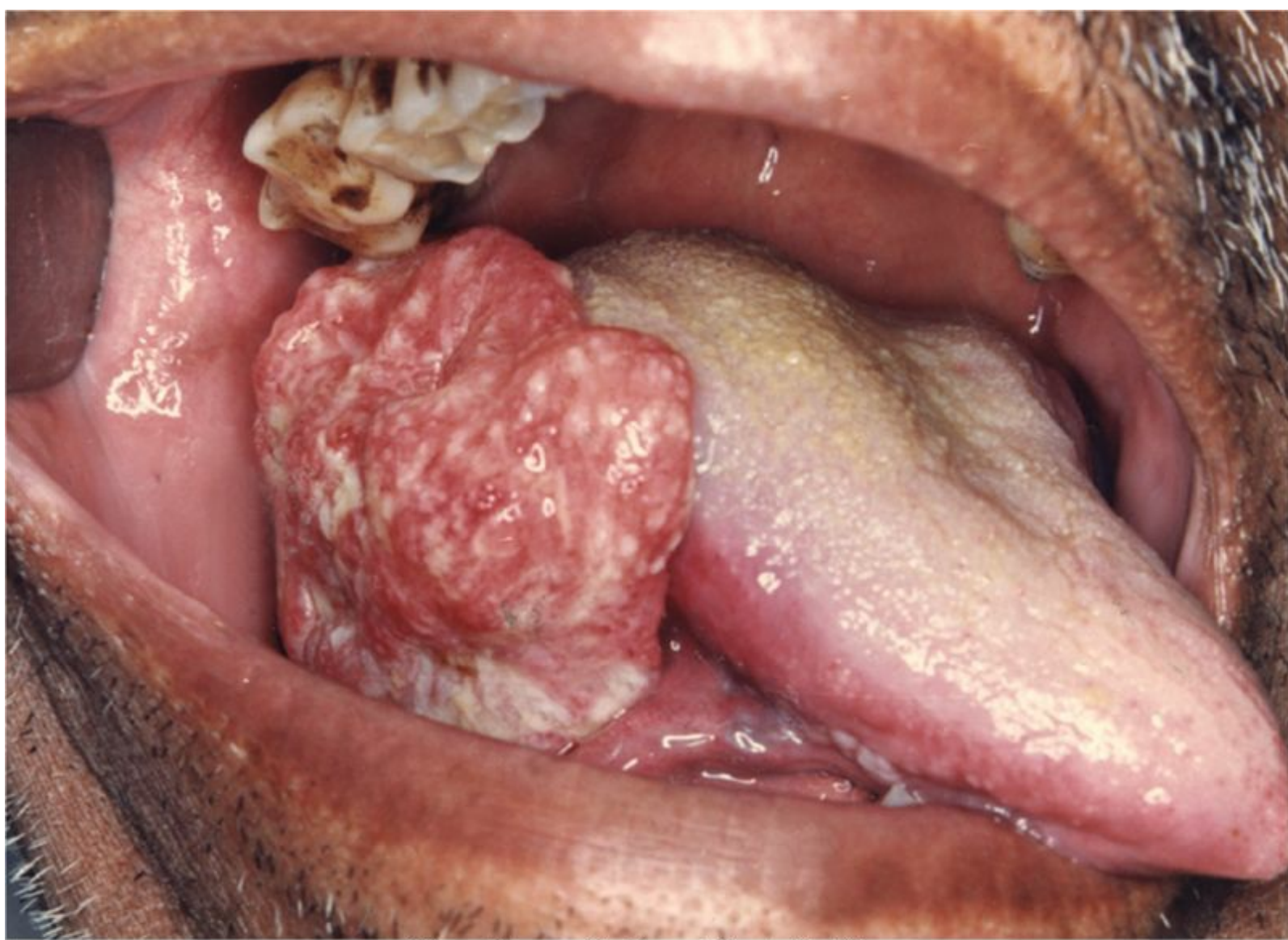Carcinoma involving anterior two thirds of tongue is commonly seen in men in the age group of 50-70 years. It may also occur in younger age group and in females. It may also develop on a pre-existing leukoplakia, longstanding dental ulcer or syphilitic glossitis (Fig. 43.8). Vast majority are squamous cell type.

*Site.* Most common site is middle of the lateral border or the ventral aspect of the tongue. Uncommonly, the tip or the dorsum may be involved.

*Spread.* Locally, it may infiltrate deeply into the lingual musculature causing ankyloglossia or may spread to the floor of mouth, alveolus and mandible. Lymph node metastases go to the submandibular and upper jugular nodes (from the lateral border of tongue) and to the submental and jugulo-omohyoid group (from the tip). Bilateral or contralateral nodal involvement can also occur.

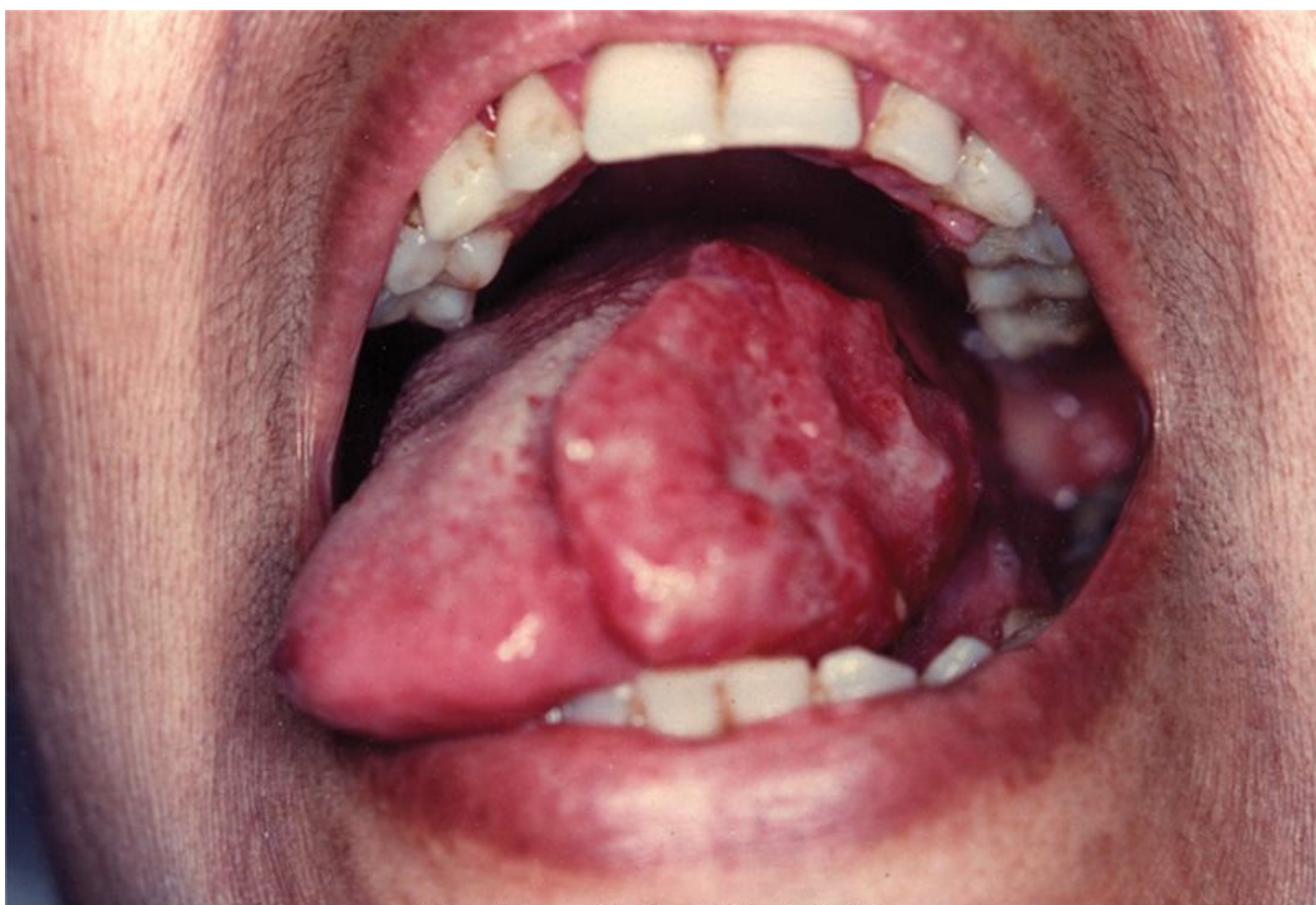Clinically, cancer of the oral tongue presents as:

- (i) An exophytic lesion like a papilloma (Fig. 43.9),
- (ii) A non-healing ulcer with rolled edges, greyish white shaggy base and induration (Fig. 43.10).
- (iii) A submucous nodule with induration of the surrounding tissue.



Dhingra: Diseases of Ear Nose and Throat, 5th Edition  
Copyright © 2010 Elsevier. All rights reserved.

Figure 43.9 Exophytic growth on the right lateral border of tongue in a 60-years-old male. It was squamous cell carcinoma.



Dhingra: Diseases of Ear Nose and Throat, 5th Edition  
Copyright © 2010 Elsevier. All rights reserved.

Figure 43.10 Ulcerative type of squamous cell carcinoma of tongue in a 40-years-old female.

### Symptomatology

- (i) Early lesions are painless and remain asymptomatic for a long time.
- (ii) Pain in the tongue locally at the site of ulcer.
- (iii) Pain in the ipsilateral ear; it is due to common nerve supply of the tongue (lingual nerve) and ear (auriculo temporal) from the mandibular division of the trigeminal nerve.
- (iv) A lump in the mouth.
- (v) Enlarged lymph node mass in the neck.
- (vi) Dysphagia, difficulty to protrude the tongue, slurred speech and bleeding from the mouth are late features.

For staging, see TNM classification (Tables 43.2 and 43.3).

*Treatment.* Aim of treatment is to treat primary tumour in the tongue, control neck disease (nodal metastasis) and preserve function of the tongue as much as possible.

Table 43-2. TNM classification (AJCC-2002) of cancers of lip and oral cavity and oral cavity

Primary tumour (T)	
T <sub>1</sub>	Tumour 2 cm or less in greatest dimension
T <sub>2</sub>	Tumour >2 cm but not more than 4 cm in greatest dimension
T <sub>3</sub>	Tumour >4 cm in greatest dimension
T <sub>4</sub>	(lip) Tumour invades adjacent structures (e.g. cortical bone, inferior alveolar nerve, floor of mouth, skin of face).
	(oral cavity) Tumour invades adjacent structures (e.g. cortical bone, deep (extrinsic) muscles of tongue, maxillary sinus, skin).

T <sub>4a</sub>	Superficial erosion alone of bone/tooth socket by gingival primary is not sufficient to classify as T <sub>4</sub> .
<b>Regional lymph nodes (N)</b>	
N <sub>1</sub>	Metastasis in a single ipsilateral lymph node 3 cm or less in greatest diameter.
N <sub>2</sub>	Metastasis in a single ipsilateral lymph node >3 cm but not more than 6 cm in greatest dimension (N <sub>2a</sub> ); or multiple ipsilateral lymph nodes none more than 6 cm in greatest dimension (N <sub>2b</sub> ) or bilateral or contralateral lymph nodes none more than 6 cm in greatest dimension (N <sub>2c</sub> ).
N <sub>3</sub>	Metastasis in lymph node more than 6 cm in greatest dimension.
<b>Distant metastasis (M)</b>	
M <sub>0</sub>	No distant metastasis
M <sub>1</sub>	Distant metastasis

Source: AJCC, Cancer Staging Manual, Chicago, 2002.

**Table 43-3. Staging of carcinoma lip and oral cavity**

Stage I	T <sub>1</sub>	N <sub>0</sub>	M <sub>0</sub>
Stage II	T <sub>2</sub>	N <sub>0</sub>	M <sub>0</sub>
Stage III	T <sub>3</sub>	N <sub>0</sub>	M <sub>0</sub>
	T <sub>1</sub>	N <sub>1</sub>	0
	T <sub>2</sub>		
	T <sub>3</sub>		
Stage IV A	T <sub>4</sub>	N <sub>0</sub>	M <sub>0</sub>
	T <sub>4</sub>	N <sub>1</sub>	M <sub>0</sub>
	Any T	N <sub>2</sub>	M <sub>0</sub>
Stage IV B	Any T	N <sub>3</sub>	M <sub>0</sub>
Stage IV C	Any T	Any N	M <sub>1</sub>

Small tumours (T<sub>1</sub>N<sub>0</sub>) give equal results if treated with radiotherapy or surgery.

T<sub>2</sub>N<sub>0</sub> tumours can also be treated by radiotherapy including the neck nodes, to eliminate micrometastases. They can also be treated by surgical excision with prophylactic neck dissection.

page 241

page 242

Stage III or IV tumours require combined treatment with surgery and post-operative radiotherapy. It gives better results than either modality alone. Block dissection neck is always done.

Depending on the size and extent of the primary lesion of the tongue, surgery may consist of hemiglossectomy including a portion of the floor of mouth, segmental or hemimandibulectomy and block dissection of neck nodes-the so-called "commando operation".

#### 4. Carcinoma Hard Palate

It is either squamous cell or glandular variety, the latter being more common. Glandular variety arises from minor salivary glands of the palate and may be adenoid cystic, mucoepidermoid or adenocarcinoma. It is common in our country especially in people who have the habit of reverse smoking, i.e. keeping the burning end of bidi or cigar in the mouth. Both men and women are affected.

Cancer starts as a superficial ulcer with rolled out edges and gives no symptoms except painless irregularity on the palate felt by the tongue. It may spread to the gingiva, lip, soft palate or invade the bone of hard palate, floor of the nasal cavity or the antrum. Lymphatic metastases may spread to the submandibular and upper jugular nodes. Cancer palate should be differentiated from cancer of maxillary antrum or nose which has spread to the palate.

*Treatment.* Small tumours are resected along with the underlying bone; larger ones require partial maxillectomy. If nodes are enlarged, block dissection is also combined. Surgical defect in the palate, left after excision of the growth, is closed by a suitable prosthesis.

#### 5. Carcinoma of Alveolar Ridges

It is also called gingival carcinoma; it is mostly seen in men. Usual site of involvement is lower jaw behind the first molar. Tumour may spread to the cheek, floor of mouth, retromolar trigone or the hard palate. Gingival cancer may invade the underlying bone and then spread rapidly along the neurovascular bundle. Nodal metastases go to submandibular and upper jugular nodes.

*Treatment.* Radiotherapy is avoided because of the risk of radio-osteo-necrosis. Surgery is the treatment of choice. Early mucosal lesion on the lower alveolus is treated by local excision with marginal resection of the mandible. Extensive lesions require wide excision which may necessitate segmental or hemimandibulectomy. Block dissection may be combined if nodes are also palpable. Upper alveolar lesions may require partial maxillectomy.

## **6. Cancer Floor of Mouth**

Squamous cell carcinoma is the most common. It affects males more than females in ratio of 4:1. Typically, lesions start anteriorly near the opening of submandibular duct which may get obstructed, leading to enlargement of submandibular gland (Fig. 43.11).

Usually, the lesion is ulcerative or infiltrative type and spreads locally into the adjoining areas such as ventral aspect of the tongue, lingual gingiva, mandibular periosteum or deeply into the floor of mouth and submental space. Lymphatic metastases go to submandibular nodes. Lesions of the floor of mouth remain asymptomatic for a long time or cause soreness or irregularity in the floor of the mouth. A swelling in the submandibular region may be either due to obstructive enlargement of submandibular salivary gland or lymph node metastases, and this may require differentiation.

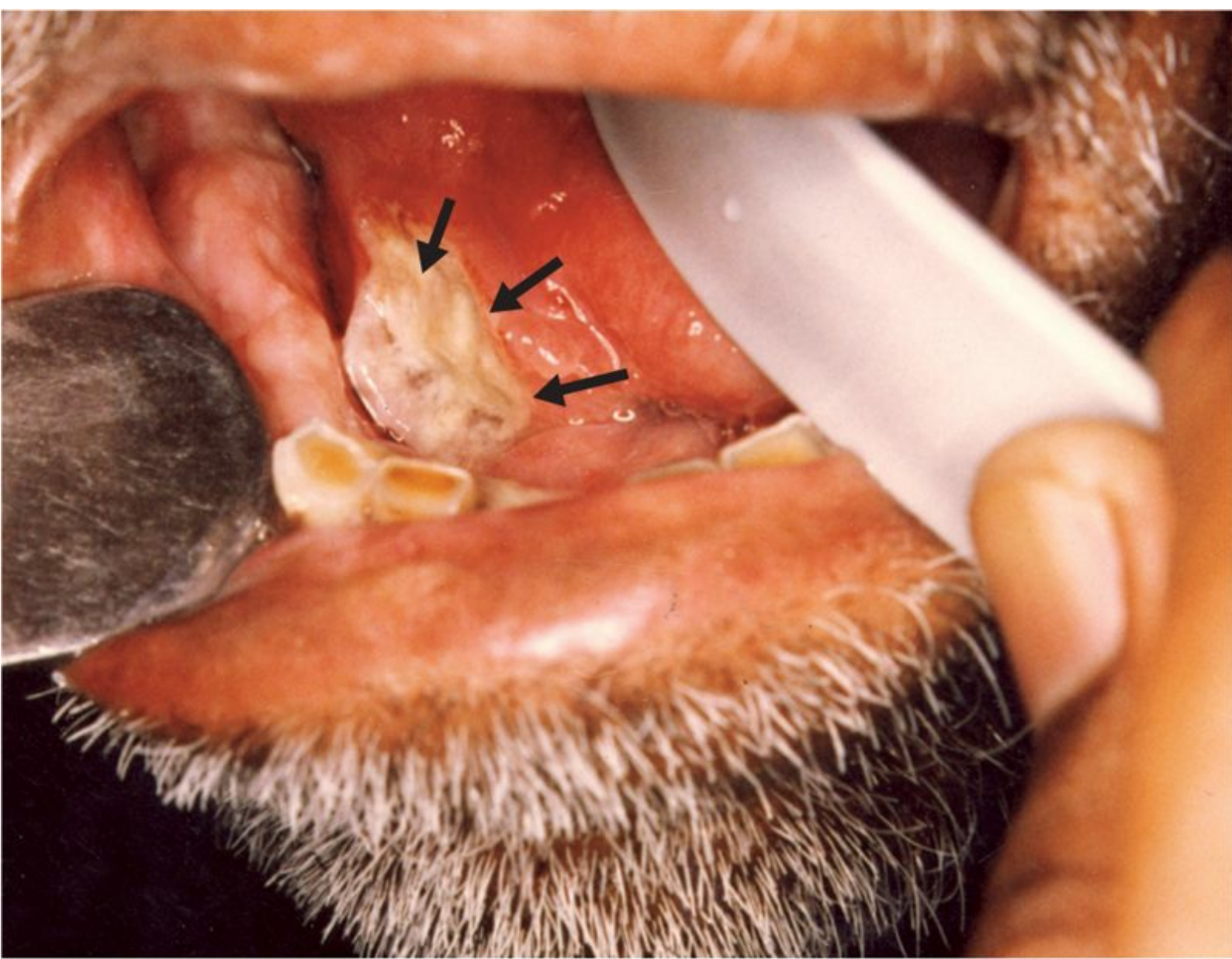*Treatment.* Small lesions without involvement of tongue, lingual gingiva or nodes can be treated by surgical excision or radiotherapy with equal results. Larger lesions with extension to the tongue, gingiva or mandible require wide excision including marginal or segmental mandibular resection. Block dissection is indicated when cervical nodes show clinical evidence of metastases. Prophylactic neck dissection or irradiation is advised for N<sub>0</sub> neck in stage II cancer because of high incidence of micrometastases (40%), stage III and IV cancers require surgery and radiotherapy.

## **7. Carcinoma Retromolar Trigone**

Involvement of retromolar trigone may be primary, or secondary to extension of growths from the gingiva, floor of mouth, buccal mucosa or the palatine arch.

*Treatment* depends on the extent of lesion. Wide surgical excision often combined with block dissection is required.





Dhingra: Diseases of Ear Nose and Throat, 5th Edition  
Copyright © 2010 Elsevier. All rights reserved.

Figure 43.11 Ulcerative squamous cell carcinoma in the floor of oral cavity (arrow) in a 55-years-old male.

## Multiple Primary Cancers

About 15% of patients with carcinoma of the oral cavity have multiple primary cancers affecting the upper aerodigestive tract. This is because of the common risk factors such as smoking and alcohol simultaneously operating at various sites.

# Non-squamous Malignant Lesions

In addition to carcinoma, other malignant lesions that involve the oral cavity are:

## **1. Minor salivary gland tumours**

In one series, 80-90% of all minor salivary gland tumours were malignant. Palate is the most common site but can involve tongue, cheek, lip, gums and floor of mouth (Fig. 43.12).

Adenoid cystic variety is the most common (40%). Next in frequency are the adenocarcinoma (30%) and mucoepidermoid carcinoma (20%). Treatment is wide surgical excision along with block dissection, if the neck nodes are positive.

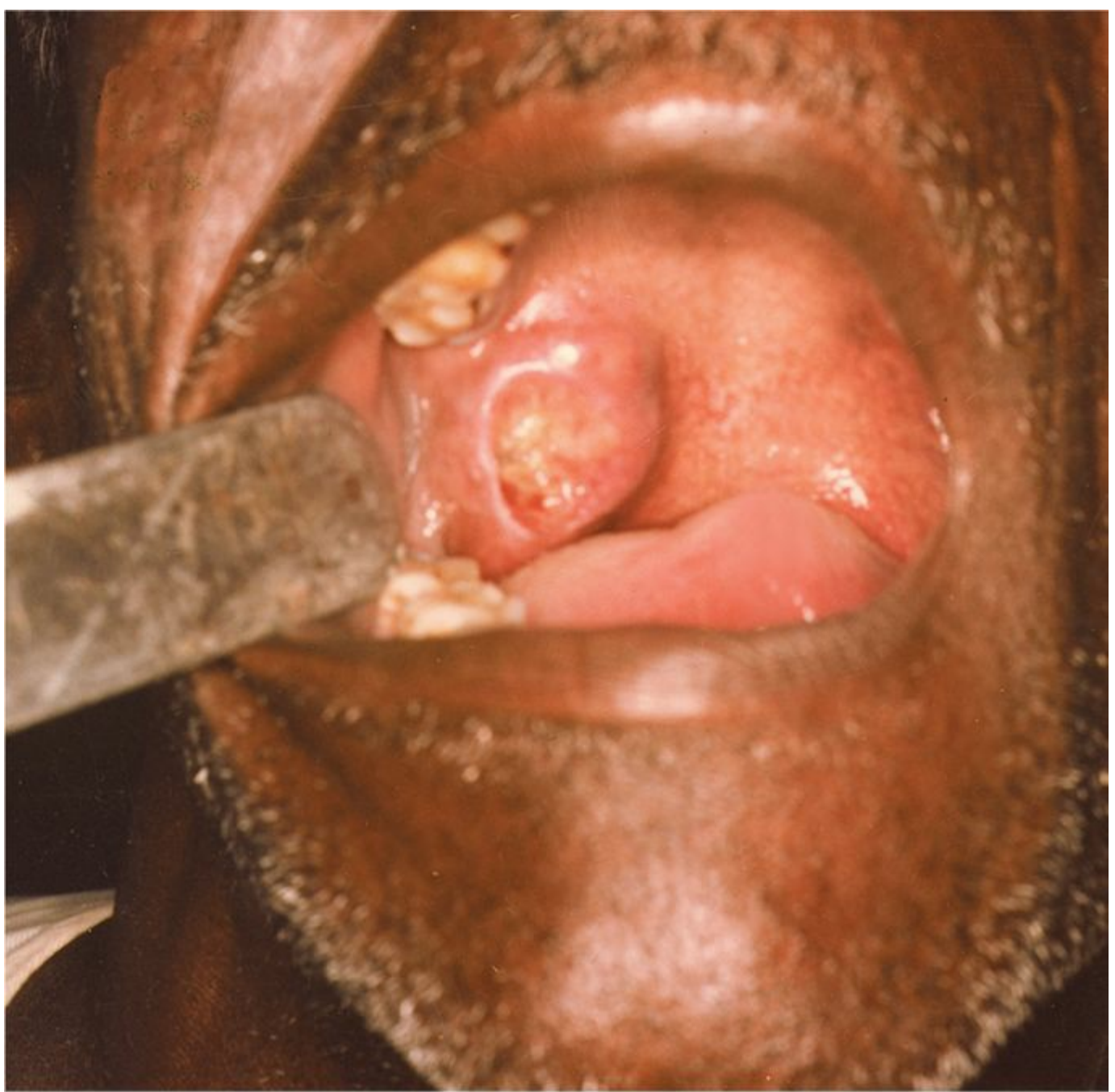## **2. Melanoma**

Mucosal melanomas of oral cavity and oropharynx are rare. Peak age incidence is the sixth decade; males are affected more (2:1). Palate and gingiva are the most common sites. They appear as areas of higher pigmentation and later may ulcerate and bleed. Amelanotic variety is also seen. Both cervical nodal and distant metastases are seen. Treatment of choice is wide surgical excision including underlying bone. Local recurrence is common. Prognosis is poor with 5-year cure rate of only 15%.

## **3. Lymphoma**

Lymphomas can involve oral cavity or oropharynx, majority of them occurring in the palatine tonsils. Males are affected more. Usual presentation is that of a smooth, submucosal bulky mass which is occasionally ulcerated. They are mostly of non-Hodgkin variety. Cervical nodes may be involved in 40-70% of the patients. Treatment is radiation, alone or in combination with chemotherapy.

## **4. Kaposi's sarcoma**



Dhingra: Diseases of Ear Nose and Throat, 5th Edition  
Copyright © 2010 Elsevier. All rights reserved.

Figure 43.12 Mixed salivary tumour palate.

It is a vascular tumour, multifocal in origin, primarily affecting skin but may occur in the oral cavity. Its incidence is high in AIDS (Acquired immune deficiency syndrome) patients. The lesion appears as a reddish purple nodule or a plaque mostly on the palate. Microscopically, it consists of spindle cells with haemorrhagic cleft-like spaces. Treatment is not satisfactory. Kaposi's sarcoma in non-AIDS patients may respond to chemotherapy but its response in patients suffering from AIDS is poor (see also page 375).

## Chemoprevention

It is the use of certain pharmacological agents to *halt, delay* or *reverse* the process of carcinogenesis. It has been used to prevent oral premalignant lesions to develop into cancer or to prevent the development of second primary cancers after the main primary cancer has been treated. Agents used have been vitamin A, beta carotene, alpha tocopherol (vitamin E), selenium and natural or synthetic retinoids such as 13-cis retinoic acid. Beta carotene and vitamin A induced remission of oral leukoplakia is seen in 25-50% of patients. Similarly, in a controlled trial, 13-cis retinoic acid reduced the incidence of second primary lesions in the aerodigestive tract. The beneficial effect of these agents may be limited to the duration of treatment only.

In addition to their use in head and neck, retinoids have shown significant chemopreventive activity in cancers of lung, skin, cervix, bladder and ovary. Trials are also being conducted in Cox-2 inhibitors (e.g. celecoxib) in the prevention of oral premalignant lesions.

## 44 Non-neoplastic Disorders of Salivary Glands

### Mumps (Viral Parotitis)

It is a viral infection caused by paramyxovirus. Disease is contracted by droplet infection and fomites. Children are most often affected but adults can also contract the disease. Incubation period is 2-3 weeks (7-23 days). Patient is infective even before the appearance of clinical manifestations and remains so 7-10 days after parotid swelling subsides. Virus is excreted through salivary, nasal and urinary excretions.

#### **Clinical features**

Initial period of viraemia causes fever (up to 103°F), malaise, anorexia and muscular pain. Parotid swelling may appear only on one side. Other parotid gland may be enlarged simultaneously or after some time. Submandibular and sublingual salivary glands may also be enlarged but isolated involvement of submandibular gland is rare. Swelling subsides in about a week.

#### **Complications**

*Orchitis* with painful and tender testis, on one but uncommonly both sides, may occur. Sterility following mumps is rare.

*Ophritis* causes lower abdominal pain. Female sterility is almost never seen.

*Pancreatitis* causes pain in abdomen.

*Aseptic meningitis* or meningoencephalitis may occur with or without the salivary gland involvement. Headaches, neck stiffness and drowsiness may occur.

*Unilateral sensorineural hearing loss* can occur due to involvement of the labyrinth. Sudden deafness has been noticed.

Other complications include thyroiditis, myocarditis, nephritis and arthritis.

#### **Diagnosis**

Usually clinical; difficulties arise when parotids are not enlarged.

- 1. Serum and urinary amylase are raised during the first week of parotitis.
- 2. *Serology*. Serum IgG and IgM are measured as early as possible and after 10-14 days of illness. Presence of IgG indicates past exposure and possible immunity. However rise in IgG titre  $\geq 4$  times from acute to convalescent serum indicates recent infection. Similarly presence of IgM also indicates recent infection. IgM is present in 100% patients by day 5.

#### **Treatment**

Parotitis is treated by proper hydration, rest, analgesics and cold or hot compresses over the parotid to relieve pain. Food which encourage salivary flow should be avoided as they cause pain. Parotid swelling persists for about 1 week.

Orchitis is treated by cold compresses and support to the scrotum, and administration of analgesics. Steroids have not been found useful.

#### **Prevention**

An infant has maternal immunity for 1 year. After that immunisation can be given by MMR (Mumps, Measles, Rubella) vaccine at the age of 15 months. Older children, adolescents and adults who were not protected by MMR and have not had mumps, and are in contact with children should receive monoclonal mumps or MMR vaccine.

Mumps immunoglobulin is of no value as a prophylaxis or in established disease.

# Acute Suppurative Parotitis

It is most commonly seen in the elderly, debilitated and dehydrated patients. Dry mouth due to any cause is a predisposing factor. *Staph. aureus* is the usual causative organism though other gram-positive and anaerobic organisms have also been observed. Usual route of infection is from the mouth through the Stensen's duct.

## **Clinical features**

The onset is sudden with severe pain and enlargement of gland. Movements of jaw aggravate the pain. Opening of the Stensen's duct is swollen and red and may be discharging pus or the latter can also be expressed by gentle pressure over the gland. Patient is usually febrile and toxaemic.

---

page 244

page 245

## **Investigations**

White cell count shows leukocytosis with increase in polymorphs. Causative organisms should be identified and their sensitivity established by culture of blood and the pus collected from the opening of the parotid duct.

## **Treatment**

It consists of appropriate antibiotics, preferably administered through i.v. route, adequate hydration, measures to promote salivary flow and attention to oral hygiene. If temperature does not subside and there is progressive induration of the gland, in spite of adequate medical management, surgical drainage should be done.

## Chronic Recurrent Sialadenitis

This usually involves parotid gland which shows recurrent bacterial infection. During acute exacerbation, parotid is enlarged and tender, and pus can be expressed from its duct. Between the acute episodes, gland is firm and slightly enlarged. Culture of pus from the duct reveals *staphylococci* or *streptococci*. Sialography shows normal duct system. Treatment of acute episode is similar to that of acute bacterial sialadenitis. Between the attacks, patient is instructed to keep good oral hygiene, avoid drugs which dry oral mucosa and use sialogogues to promote salivation.



## Sialectasis

As the name implies, there is dilatation of the ductal system, leading to stasis of secretions, which predisposes to infection. Clinically, sialectasis resembles chronic recurrent sialadenitis, but can be differentiated from it by sialography. Different degrees of dilatation of the ductal system-punctuate, globular or cavitory types-may be seen. Sialectasis may be congenital, associated with granulomatous disease or autoimmune disease such as Sjogren's syndrome.

## Granulomatous Diseases

Tuberculosis, sarcoidosis and actinomycosis may involve the salivary glands.

*Tubercular infection* may involve parenchyma or lymph nodes of the parotid and present as a non-tender mass. Sometimes, overlying skin undergoes necrosis leading to a fistula formation. Surgical excision of the involved tissue and antitubercular treatment usually control the disease.

Uveoparotid fever is due to *sarcoidosis* of the parotid. It is characterised by fever, enlargement of the parotid and lacrimal glands, chorioretinitis, and cranial nerve palsies.

*Actinomycosis* of parotid is uncommon. It may present as an acute abscess with sinus formation discharging sulphur-like granules, or as an indolent swelling in the parotid. Treatment is surgical drainage and large doses of penicillin or tetracycline.

## Salivary Calculi

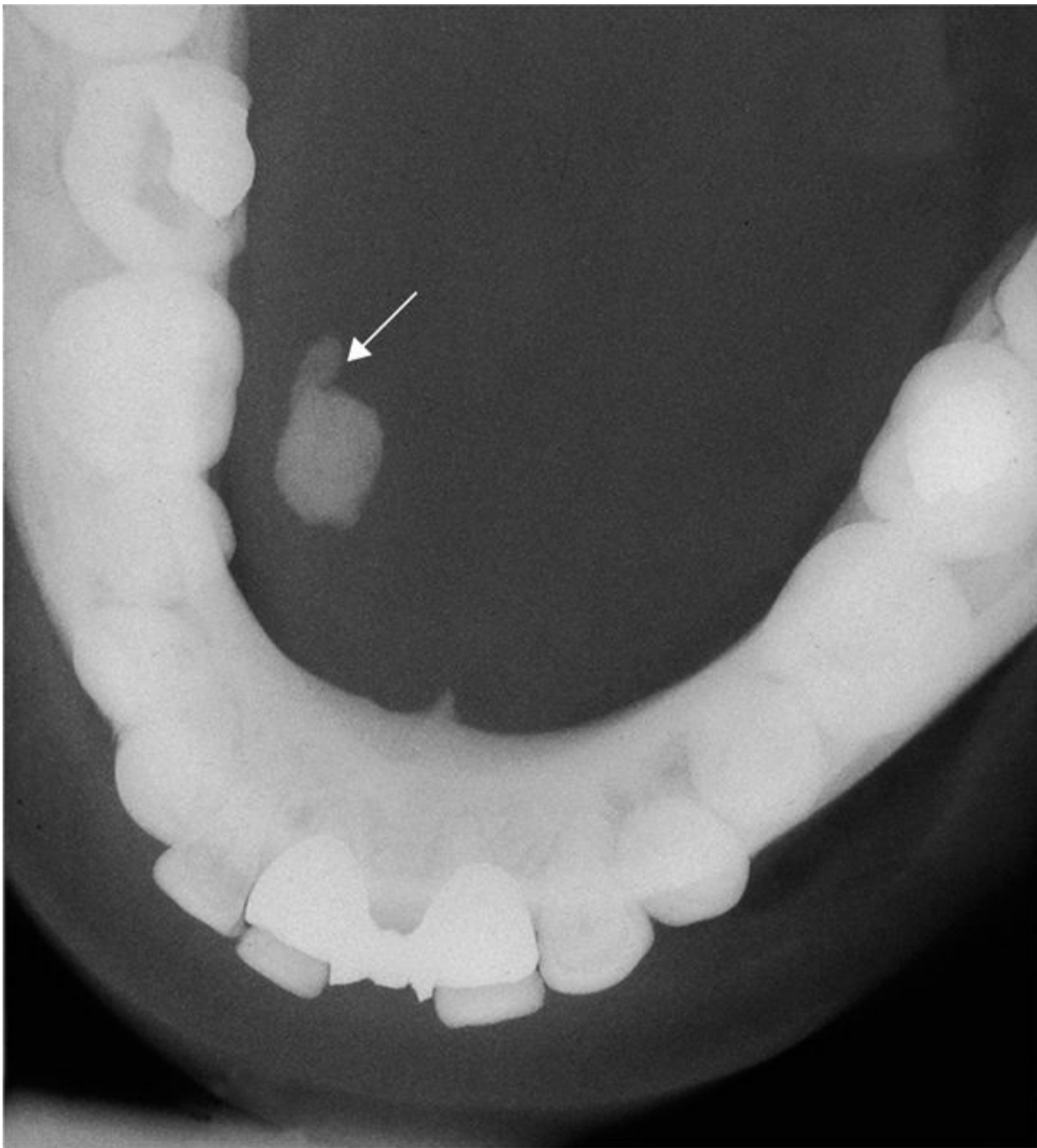
Calculi may form in the ducts of submandibular or parotid glands. They are formed by the deposition of calcium phosphate on the organic matrix of mucin or cellular debris. About 90% of the stones are seen in submandibular and 10% in the parotid. Stones may form in the duct or parenchyma of the gland.

The presenting feature is intermittent swelling of the involved gland, and pain due to obstruction to outflow of saliva. Sometimes, stone is visible at the duct opening or can be palpated. About 80% of the stones are radio-opaque and can be seen on appropriate X-rays (Fig. 44.1). Sialography may be required for radiolucent stones.

Stones in peripheral part of submandibular or parotid ducts can be removed intraorally, while those at the hilum or in the parenchyma require excision of the gland.

## Sjogren's Syndrome (Sicca Syndrome)

It is an autoimmune disorder involving exocrine glands of the body. It may be primary or secondary.



Dhingra: Diseases of Ear Nose and Throat, 5th Edition  
Copyright © 2010 Elsevier. All rights reserved.

Figure 44.1 A radio-opaque stone seen in the right submandibular duct (arrow).

*Primary Sjogren's syndrome* consists of xerostomia and xero-ophthalmia and is due to involvement of salivary and lacrimal glands. Parotid is most often involved. It has also been known as *benign lymphoepithelial lesion* of parotid or *Mikulicz's disease*. Both sexes are equally involved.

*Secondary Sjogren's syndrome* consists of three major components: (i) keratoconjunctivitis sicca (due to involvement of lacrimal gland); (ii) xerostomia (due to involvement of salivary glands and mucous glands of the oral cavity); (iii) autoimmune connective tissue disorder, usually the rheumatoid arthritis. Often there is bilateral swelling of the salivary glands. It is also more common in females (90%).

*Diagnosis* depends on raised ESR, positive rheumatoid factor, positive antinuclear antibodies and biopsy from the lower lip for evidence of involvement of minor salivary glands.

## 45 Neoplasms of Salivary Glands


The tumours of major or minor salivary glands are either from epithelial or mesenchymal tissues (Fig. 45.1). Larger the size of salivary gland, more are the chances of a tumour being benign. 80% of parotid, 50-60% of submandibular and only about 25% of other minor salivary gland tumours are benign. In other words, chances of malignant tumours in minor salivary glands are higher.

*Rapid growth, restricted mobility, fixity of overlying skin, pain and facial nerve involvement indicate the possibility of tumour being malignant.*

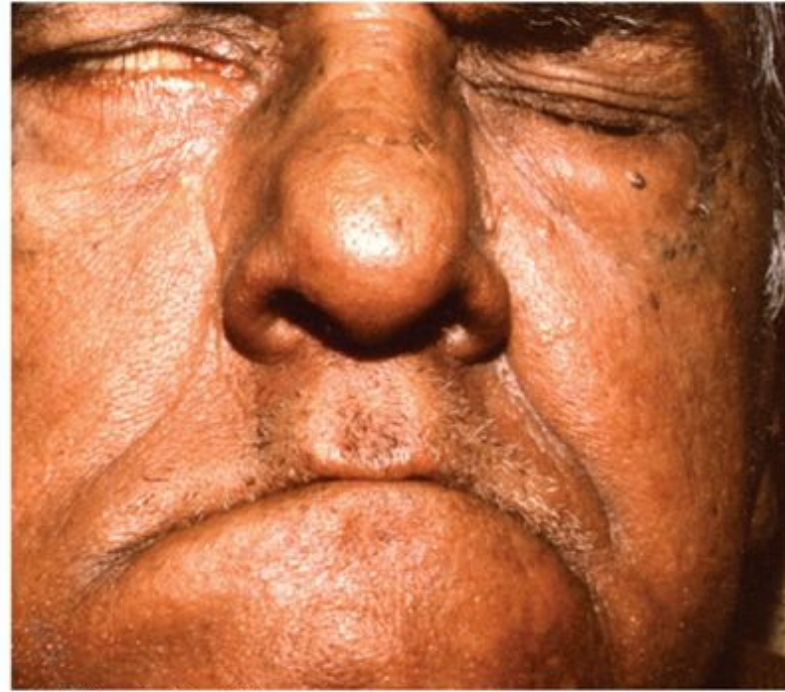
## BENIGN TUMOURS

### Pleomorphic Adenoma

**A**



**B**



Dhingra: Diseases of Ear Nose and Throat, 5th Edition  
Copyright © 2010 Elsevier. All rights reserved.

Figure 45.1 Squamous cell carcinoma of the right parotid. Patient presented with a parotid swelling (A) and facial palsy (B).

It is the most common benign tumour of salivary glands. It can arise from the parotid, submandibular or other minor salivary glands. In the parotid it usually arises from its tail. It can also arise from the deep lobe of the parotid and present as a parapharyngeal tumour in the oropharynx.

Pleomorphic adenomas are slow-growing tumours and may be quite large at initial presentation. They are usually seen in the third or fourth decade, with propensity for females. They are called "mixed tumours" because both epithelial and mesenchymal elements are seen in histology. The stroma of the tumour may be mucoid, fibroid, vascular, myxochondroid or chondroid and its proportion to the epithelial element may vary.

Though tumour is encapsulated, it sends pseudopods into the surrounding gland which are left behind if the tumour is simply shelled out. It is therefore essential that surgical excision of the tumour should include normal gland tissue around it. In the parotid, it amounts to superficial parotidectomy.

## Adenolymphoma (Papillary Cystadenoma Lymphomatosum, Warthin's Tumour)

They are commonly seen between fifth and seventh decade with preponderance in males (5:1). They mostly involve the tail of the parotid and are bilateral in 10% of the patients. They may be multiple. Adenolymphoma is a rounded, encapsulated tumour, at times cystic, with mucoid or brownish fluid. Histologically, epithelial and lymphoid elements are seen. Treatment is superficial parotidectomy though they can be enucleated without danger of recurrence.

## Oncocytoma (Oxyphil Adenoma)

They arise from acidophilic cells called *oncocytes* and comprise less than 1% of all salivary gland tumours. Mostly seen in the elderly, they usually do not grow larger than 5 cm and involve the superficial lobe of parotid. Benign oncocytomas are cystic rather than solid. Malignant oncocytomas are also seen. Oncocytomas show increased uptake of technetium-99.

Treatment for parotid oncocytomas is also superficial parotidectomy.



# Haemangiomas

Haemangiomas are the most common benign tumours of the parotid in children, predominantly affecting females. Most of them are discovered at birth, grow rapidly in the neonatal period and then involute spontaneously. Cutaneous haemangioma may co-exist in 50% of the patients. They are soft and painless and increase in size with crying or straining. Overlying skin may show bluish discoloration. Surgical excision is indicated if they do not regress spontaneously.

Table 45-1. Tumours of salivary glands

Benign	Malignant
<p data-bbox="180 432 289 457"><b>Epithelial</b></p> <ul data-bbox="151 464 578 575" style="list-style-type: none"><li data-bbox="151 464 435 489">● Pleomorphic adenoma</li><li data-bbox="151 495 578 520">● Adenolymphoma (Warthin's tumour)</li><li data-bbox="151 527 321 552">● Oncocytoma</li><li data-bbox="151 558 370 583">● Other adenomas</li></ul> <p data-bbox="180 604 342 630"><b>Mesenchymal</b></p> <ul data-bbox="151 636 354 747" style="list-style-type: none"><li data-bbox="151 636 354 661">● Haemangioma</li><li data-bbox="151 667 354 693">● Lymphangioma</li><li data-bbox="151 699 272 724">● Lipoma</li><li data-bbox="151 730 337 756">● Neurofibroma</li></ul>	<p data-bbox="870 390 979 415"><b>Epithelial</b></p> <ul data-bbox="841 422 1292 680" style="list-style-type: none"><li data-bbox="841 422 1179 447">● Mucoepidermoid carcinoma<ul data-bbox="919 453 1068 506" style="list-style-type: none"><li data-bbox="919 453 1068 478">○ Low grade</li><li data-bbox="919 485 1068 510">○ High grade</li></ul></li><li data-bbox="841 512 1292 537">● Adenoid cystic carcinoma (cylindroma)</li><li data-bbox="841 543 1101 569">● Acinic cell carcinoma</li><li data-bbox="841 575 1057 600">● Adenocarcinoma</li><li data-bbox="841 606 1133 632">● Malignant mixed tumour</li><li data-bbox="841 638 1159 663">● Squamous cell carcinoma</li><li data-bbox="841 669 1166 695">● Undifferentiated carcinoma</li></ul> <p data-bbox="870 716 1032 741"><b>Mesenchymal</b></p> <ul data-bbox="841 747 997 800" style="list-style-type: none"><li data-bbox="841 747 997 772">● Lymphoma</li><li data-bbox="841 779 971 804">● Sarcoma</li></ul>

## Lymphangiomas

They are less common and may involve parotid and submandibular glands. On palpation, they feel soft and cystic. They do not regress spontaneously and are surgically excised.

**Lipoma** and **neurofibroma** are rare.

# MALIGNANT TUMOURS

## Mucoepidermoid Carcinoma

Some pathologists do not consider it to be malignant and call it mucoepidermoid tumour and not cancer, but it is known to metastasise and kill. Generally, it is slow-growing but can invade the facial nerve. Histologically, there are areas of mucin-producing cells and the squamous cells, and hence the name. Greater the epidermoid element, more malignant is the behaviour of the tumour. The tumours have been further classified as *low grade* and *high grade*. Low grade tumours have good prognosis (90%, 5-years survival rate), high grade tumours are more aggressive and have poor prognosis (30%, 5-years survival rate). Low grade tumours are more common in children.

Behaviour of mucoepidermoid tumours of minor salivary glands is more aggressive and akin to adenoid cystic carcinoma, but in the major salivary glands they behave like pleomorphic adenoma.

Low grade tumours of the parotid are treated by superficial or total parotidectomy, depending on the location of the tumour. Facial nerve is preserved.

High grade tumours being more aggressive, are treated by total parotidectomy. Facial nerve may be sacrificed if invaded by tumour. Some surgeons also combine radical neck dissection because of high incidence of microscopic spread of the tumour.

## Adenoid Cystic Carcinoma (Cylindroma)

It is a slow-growing tumour but infiltrates widely into the tissue planes and muscles. It also invades perineural spaces and lymphatics and thus causes pain and VIIth nerve paralysis. It can metastasise to lymph nodes. Local recurrences after surgical excision are common and can occur as late as 10-20 years after surgery. Distant metastases go to the lung, brain and bone.

Treatment is radical parotidectomy with largest cuff of grossly normal tissue around the boundaries of the tumour. Radical neck is not done unless nodal metastases are present. Post-operative radiation is given if margins of the resected specimen are not free of tumour.

## Acinic Cell Carcinoma

It is a low grade tumour which appears similar to a benign mixed tumour. It presents as a small, firm, movable and encapsulated tumour, sometimes bilateral. Metastases are rare. A conservative approach of superficial or total parotidectomy is adopted.

# Adenocarcinoma

More often it arises in minor salivary glands. It is highly aggressive locally and sends distant metastasis.

## Malignant Mixed Tumour

There are two varieties of this tumour:

- **(a)** carcinoma developing in old benign mixed tumour, and
- **(b)** a 'de novo' tumour. The latter has much shorter history. Rapid growth and pain developing in a benign tumour should always arouse a suspicion of malignant change. Treatment of malignant tumour is radical parotidectomy. Facial nerve sacrificed during operation is grafted immediately.

## Squamous Cell Carcinoma (Fig. 45.1)

It is a rapidly growing tumour that infiltrates, causes pain, and ulcerates through the skin. It can metastasise to neck nodes. Treatment is radical parotidectomy which may include cuff of muscle or even a portion of mandible, temporal bone and the involved skin. Radical neck is combined if nodal metastases are present. Surgery is followed by post-operative radiation to primary site and the neck.



## Undifferentiated Carcinoma

It is a rare, but aggressive tumour. It has a tendency to spread rapidly, causes pain, becomes fixed to skin and ulcerates. It causes facial paralysis and cervical nodal metastasis. Treatment is wide excision, radical neck and post-operative radiation.

# Lymphoma

It is a rare tumour usually associated with systemic disease, but may occasionally be a primary tumour. Treatment is same as for other lymphomas.

## Sarcoma

Rarely other sarcomas, e.g. rhabdomyosarcoma may arise from the parotid.

## Frey's Syndrome (Gustatory Sweating)

Frey's syndrome arises as a complication of parotid surgery usually manifesting several months after the operation. It is characterised by sweating and flushing of the preauricular skin during mastication causing nuisance to the person or social embarrassment. It is the result of aberrant innervation of sweat glands by parasympathetic secretomotor fibres which were destined for the parotid. Now instead of causing salivary secretion from the parotid, they cause secretion from the sweat glands. The condition can be treated by tympanic neurectomy which intercepts these parasympathetic fibres at the level of middle ear. Some people like to place a sheet of fascia lata between the skin and the underlying fat to prevent secretomotor fibres reaching the sweat glands. Generally, no treatment other than reassurance is required in most of these patients.

---

page 249

page 250

page 250

page 251

## SECTION IV Diseases of Pharynx

---

page 251

page 252

## **46 Anatomy and Physiology of Pharynx**

### **PHARYNX IN GENERAL**

Pharynx is a conical fibromuscular tube forming upper part of the air and food passages. It is 12-14 cm long, extending from base of the skull (basiocciput and basisphenoid) to the lower border of cricoid cartilage where it becomes continuous with the oesophagus. The width of pharynx is 3.5 cm at its base and this narrows to 1.5 cm at pharyngo-oesophageal junction which is the narrowest part of digestive tract apart from the appendix.

## Structure of Pharyngeal Wall (Fig. 46.1)

From within outwards it consists of four layers:

- 1. Mucous membrane
- 2. Pharyngeal aponeurosis (pharyngobasilar fascia)
- 3. Muscular coat
- 4. Buccopharyngeal fascia

### **1. Mucous membrane**

It lines the pharyngeal cavity and is continuous with mucous membrane of eustachian tubes, nasal cavities, mouth, larynx and oesophagus. The epithelium is ciliated columnar in the nasopharynx and stratified squamous elsewhere. There are numerous mucous glands scattered in it.

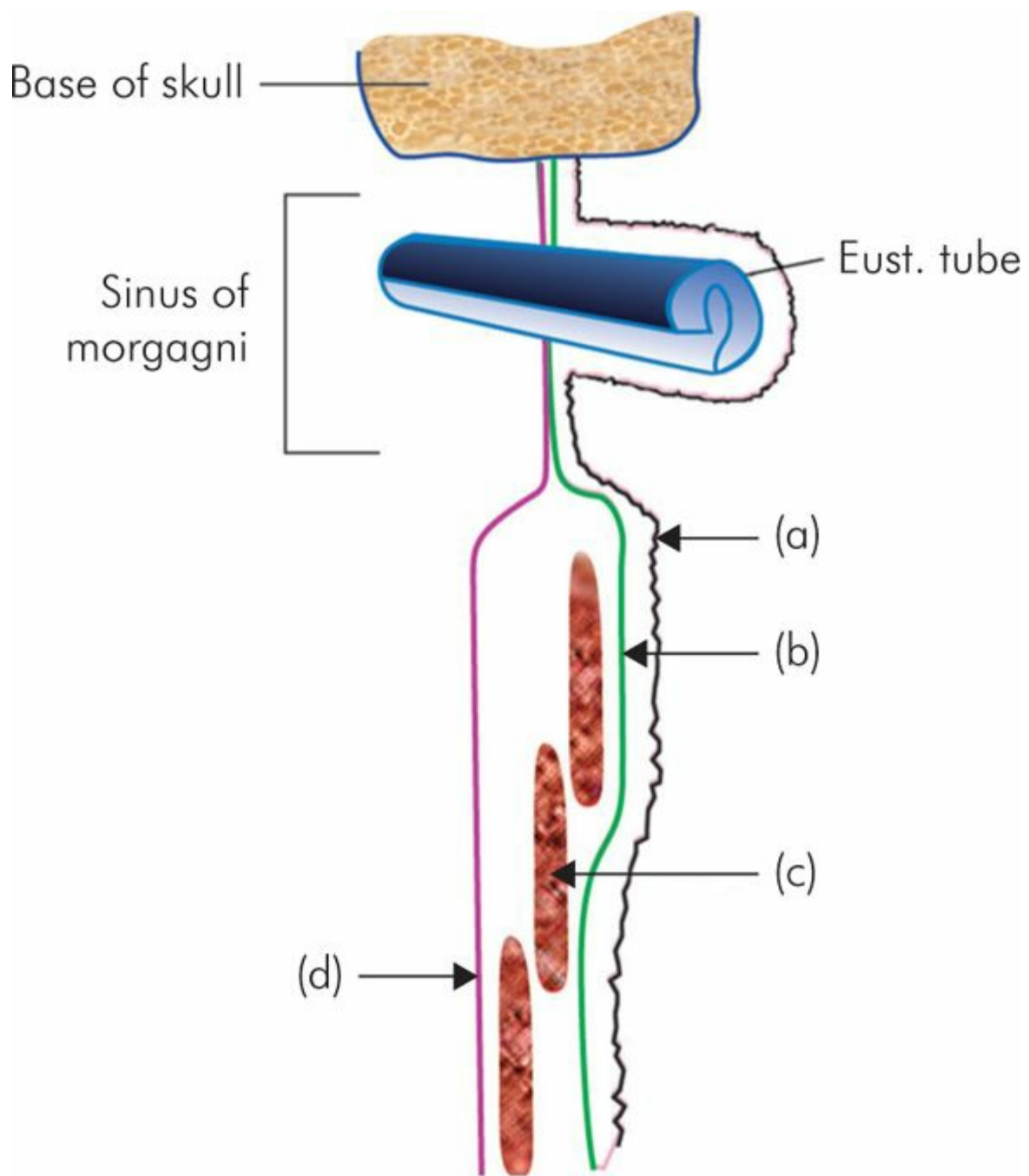
### **2. Pharyngeal aponeurosis (pharyngobasilar fascia)**

It is a fibrous layer which lines the muscular coat and is particularly thick near the base of skull but is thin and indistinct inferiorly. It fills up the gap left in the muscular coat near the base of skull.

### **3. Muscular coat**

It consists of two layers of muscles with three muscles in each layer.

- (a) External layer: contains superior, middle and inferior constrictor muscles.
- (b) Internal layer: contains stylopharyngeus, salpingopharyngeus and palatopharyngeus muscles.



Dhingra: Diseases of Ear Nose and Throat, 5th Edition  
 Copyright © 2010 Elsevier. All rights reserved.

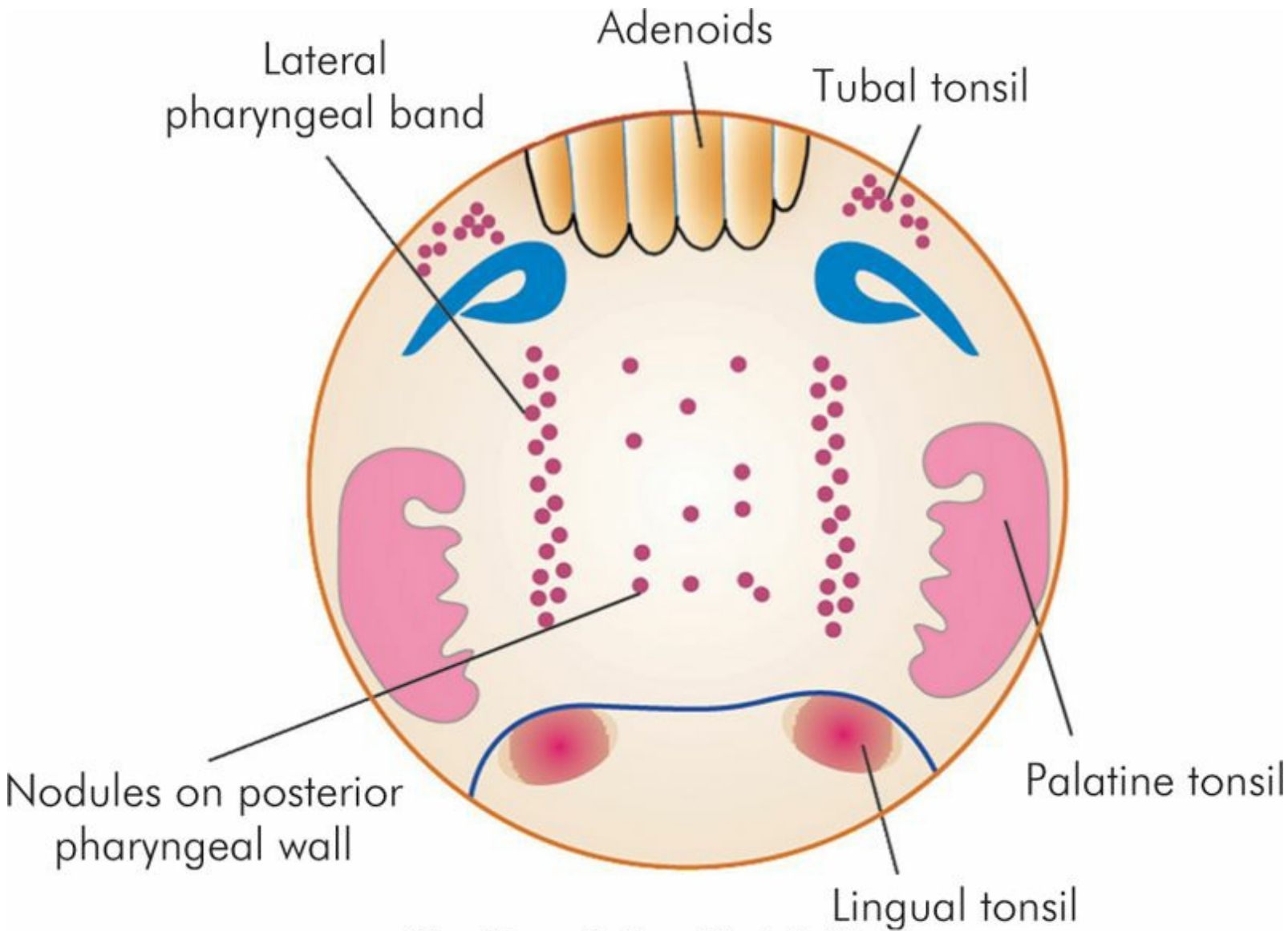
Figure 46.1 Structure of pharyngeal wall. From within outwards it consists of (a) Mucous membrane, (b) Pharyngobasilar fascia, (c) Muscular coat, and (d) Buccopharyngeal fascia.

#### 4. *Buccopharyngeal fascia*

It covers outer surface of the constrictor muscles, and in the upper part, it is also prolonged forwards to cover the buccinator muscles. Above the upper border of superior constrictor, it blends with pharyngeal aponeurosis.

# Killian's Dehiscence

Inferior constrictor muscle has two parts; thyropharyngeus with oblique fibres and cricopharyngeus with transverse fibres. Between these two parts exists a potential gap called *Killian's dehiscence*. It is also called the "gateway of tears" as perforation can occur at this site during oesophagoscopy. This is also the site for herniation of pharyngeal mucosa in cases of pharyngeal pouch.



Dhingra: Diseases of Ear Nose and Throat, 5th Edition  
Copyright © 2010 Elsevier. All rights reserved.

Figure 46.2 Waldeyer's ring.



## Waldeyer's Ring (Fig. 46.2)

Scattered throughout the pharynx in its subepithelial layer is the lymphoid tissue which is aggregated at places to form masses, collectively called Waldeyer's ring. The masses are:

- 1. Nasopharyngeal tonsil or the adenoids
- 2. Palatine tonsils or simply the tonsils
- 3. Lingual tonsil
- 4. Tubal tonsils (in fossa of Rosenmuller)
- 5. Lateral pharyngeal bands
- 6. Nodules (in posterior pharyngeal wall).

# Pharyngeal Spaces

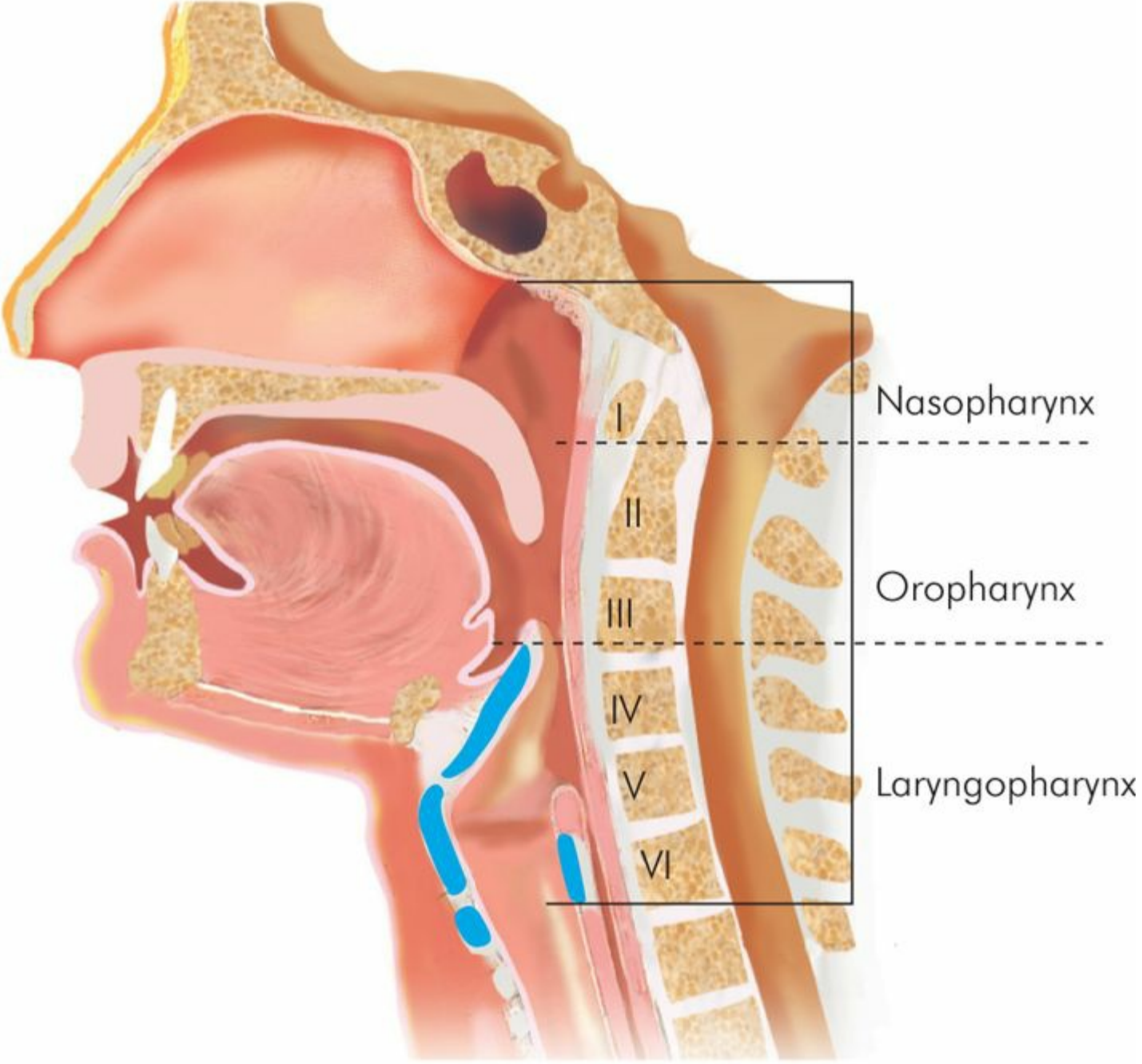
There are two potential spaces in relation to the pharynx where abscesses can form.

- **1.** Retropharyngeal space, situated behind the pharynx and extending from the base of skull to the bifurcation of trachea (see page 280).
- **2.** Parapharyngeal space, situated on the side of pharynx. It contains carotid vessels, jugular vein, last four cranial nerves and cervical sympathetic chain (see page 281).

# DIVISIONS OF PHARYNX

Anatomically, pharynx is divided into three parts (Fig. 46.3):

- 1. Nasopharynx
- 2. Oropharynx
- 3. Hypopharynx or Laryngopharynx.



Dhingra: Diseases of Ear Nose and Throat, 5th Edition  
Copyright © 2010 Elsevier. All rights reserved.

Figure 46.3 Divisions of pharynx and the vertebrae related to their posterior wall.

# Nasopharynx (Epipharynx)

## Applied Anatomy

Nasopharynx is the uppermost part of the pharynx and therefore, also called the epipharynx. It lies behind the nasal cavities and extends from the base of skull to the soft palate or the level of the horizontal plane passing through the hard palate (Fig. 46.4).

*Roof* of the nasopharynx is formed by basisphenoid and basiocciput.

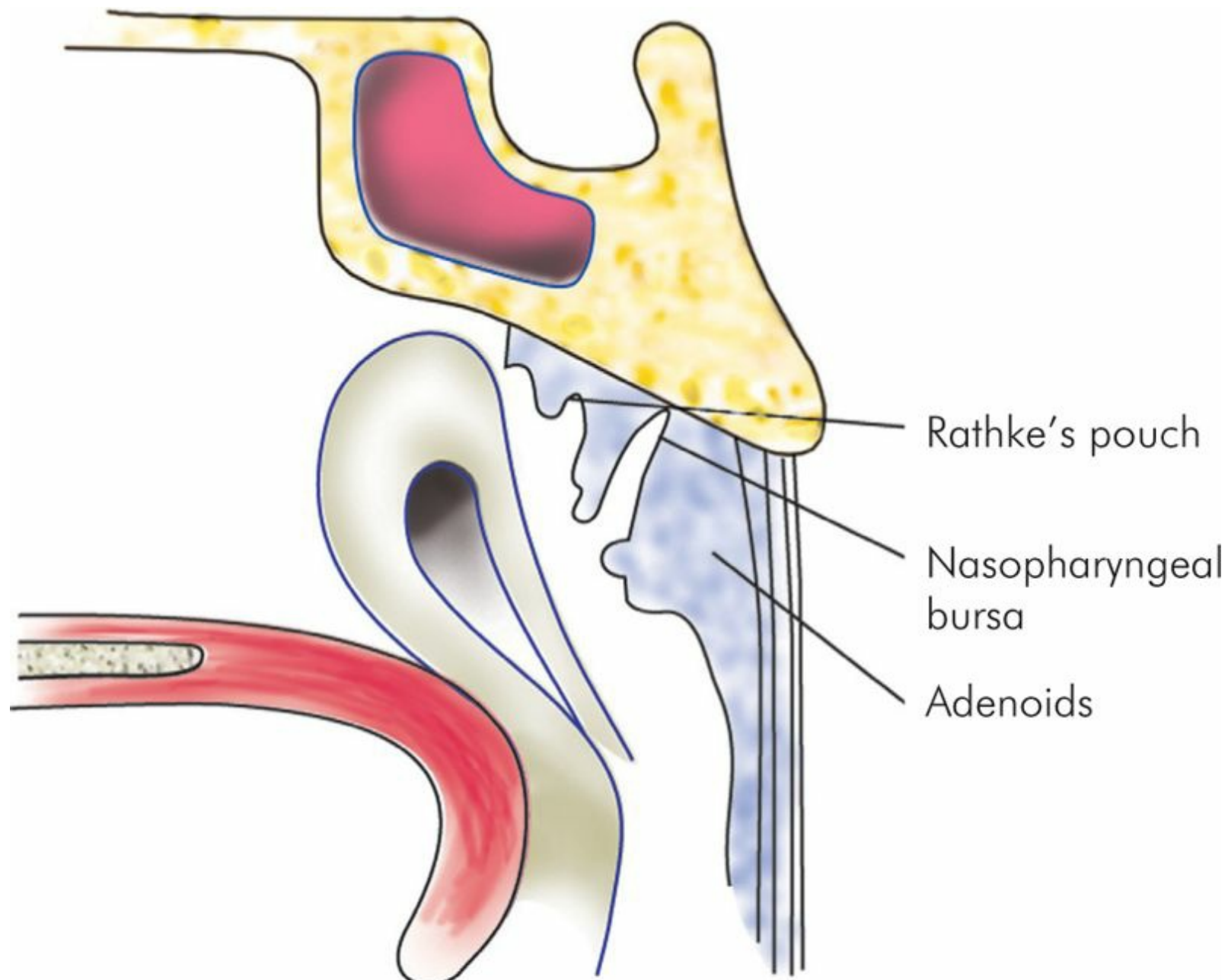
*Posterior wall* is formed by arch of the atlas vertebra covered by prevertebral muscles and fascia. Both the roof and the posterior wall imperceptibly merge with each other.

*Floor* is formed by the soft palate anteriorly but is deficient posteriorly. It is through this space-the *nasopharyngeal isthmus*, that the nasopharynx communicates with the oropharynx.

*Anterior wall* is formed by posterior nasal apertures or *choanae*, separated from each other by the posterior border of the nasal septum. Posterior ends of nasal turbinates and meatuses are seen in this wall.

page 254

page 255



Dhingra: Diseases of Ear Nose and Throat, 5th Edition  
Copyright © 2010 Elsevier. All rights reserved.

Figure 46.4 Rathke's pouch is represented by a dimple, high in nasopharynx. Inferior to this, within the adenoid mass, is the nasopharyngeal bursa.

**Lateral wall.** Each lateral wall presents the pharyngeal opening of eustachian tube situated 1.25 cm behind the posterior end of inferior turbinate. It is bounded above and behind by an elevation called *torus tubarius* raised by the cartilage of the tube. Above and behind the tubal elevation is a recess called *fossa of Rosenmuller* which is the commonest site for origin of carcinoma. A ridge extends from the lower end of torus tubarius to the lateral pharyngeal wall and is called the salpingopharyngeal fold. It is raised by the corresponding muscle.

### **Nasopharyngeal Tonsil (Adenoids)**

It is a subepithelial collection of lymphoid tissue at the junction of roof and posterior wall of nasopharynx and causes the overlying mucous membrane to be thrown into radiating folds. It increases in size up to the age of six years and then gradually atrophies.

### **Nasopharyngeal Bursa (Fig. 46.4)**

It is an epithelial-lined median recess found within the adenoid mass and extends from pharyngeal mucosa to the periosteum of the basiocciput. It represents the attachment of notochord to the pharyngeal entoderm during embryonic life. When infected, it may be the cause of persistent postnasal discharge or crusting. Sometimes an abscess can form in the bursa (Thornwaldt's disease).

### **Rathke's Pouch**

It is represented clinically by a dimple above the adenoids and is reminiscent of the buccal mucosal invagination, to form the anterior lobe of pituitary. A craniopharyngioma may arise from it.

### **Tubal Tonsil**

It is collection of subepithelial lymphoid tissue situated at the tubal elevation. It is continuous with adenoid tissue and forms a part of the Waldeyer's ring. When enlarged due to infection, it causes eustachian tube occlusion.

### **Sinus of Morgagni**

It is a space between the base of the skull and upper free border of superior constrictor muscle. Through it enters (i) the eustachian tube, (ii) the levator veli palatini, (iii) tensor veli palatini and (iv) ascending palatine artery-branch of the facial artery (Fig. 46.1).

### **Passavant's Ridge**

It is a mucosal ridge raised by fibres of palatopharyngeus. It encircles the posterior and lateral walls of nasopharyngeal isthmus. Soft palate, during its contraction, makes firm contact with this ridge to cut off nasopharynx from the oropharynx during the deglutition or speech.

### **Epithelial Lining of Nasopharynx**

Functionally, nasopharynx is the posterior extension of nasal cavity. It is lined by pseudostratified ciliated columnar epithelium.

### **Lymphatic Drainage**

Lymphatics of the nasopharynx, including those of the adenoids and pharyngeal end of eustachian tube, drain into upper deep cervical nodes either directly or indirectly through retropharyngeal and parapharyngeal lymph nodes. They also drain into spinal accessory chain of nodes in the posterior triangle of the neck. Lymphatics of the nasopharynx may also cross midline to drain into contralateral lymph nodes.

### **Functions of Nasopharynx**

- **1.** Acts as a conduit for air, which has been warmed and humidified in the nose, in its passage to the larynx and trachea.
- **2.** Through the eustachian tube, it ventilates the middle ear and equalises air pressure on both sides of tympanic membrane. This function is important for hearing.
- **3.** Elevation of the soft palate against posterior pharyngeal wall and the Passavant's ridge helps to cut off nasopharynx from oropharynx. This function is important during swallowing, vomiting, gagging and speech.
- **4.** Acts as a resonating chamber during voice production. Voice disorders are seen in nasopharyngeal obstruction and velopharyngeal incompetence (see Chapter 62).
- **5.** Acts as a drainage channel for the mucus secreted by nasal and nasopharyngeal glands.

Oropharynx extends from the plane of hard palate above to the plane of hyoid bone below. It lies opposite the oral cavity with which it communicates through *oropharyngeal isthmus*. The latter is bounded above, by the soft palate; below, by the upper surface of tongue, and on either side, by palatoglossal arch (anterior pillar).

### Boundaries of Oropharynx

#### **Posterior wall**

It is related to retropharyngeal space and lies opposite the second and upper part of the third cervical vertebrae.

#### **Anterior wall**

It is deficient above, where oropharynx communicates with the oral cavity, but below it presents:

- **(a) Base of tongue**, posterior to circumvallate papillae.
- **(b) Lingual tonsils**, one on either side, situated in the base of tongue. They may show compensatory enlargement following tonsillectomy or may be the seat of infection.
- **(c) Valleculae**. They are cup-shaped depressions lying between the base of tongue and anterior surface of epiglottis. Each is bounded medially by the median glossoepiglottic fold and laterally by pharyngoepiglottic fold (Fig. 46.5). They are the seat of retention cysts.

#### **Lateral wall**

It presents:

- **(a) Palatine (faucial) tonsil** (for details, see page 271).
- **(b) Anterior pillar** (palatoglossal arch) formed by the palatoglossus muscle.
- **(c) Posterior pillar** (palatopharyngeal arch) formed by the palatopharyngeus muscle.

Both anterior and posterior pillars diverge from the soft palate and enclose a triangular depression called *tonsillar fossa* in which is situated the palatine tonsil (Fig. 46.6).

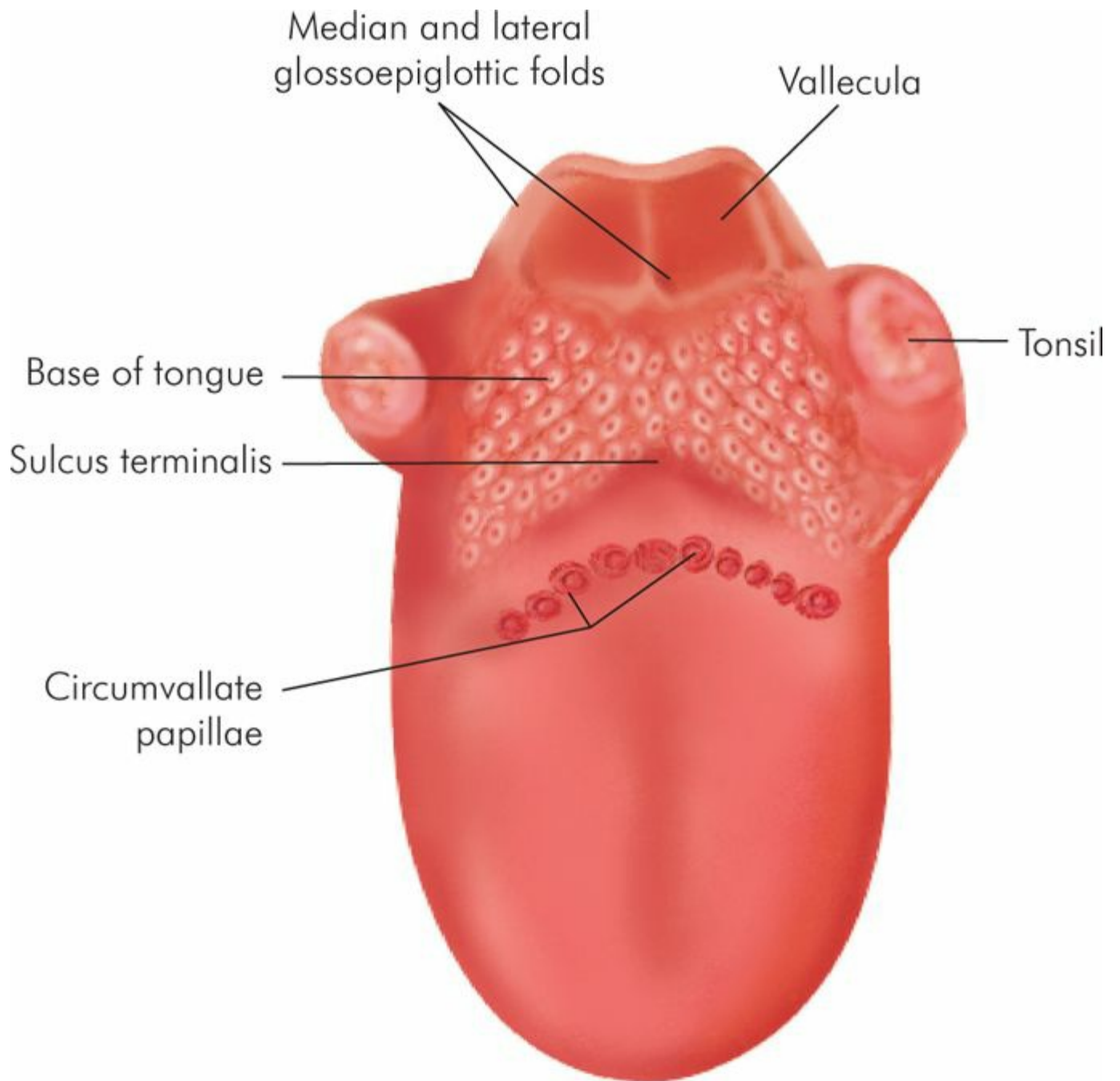
Boundary between oropharynx above and the hypopharynx below is formed by upper border of epiglottis and the pharyngoepiglottic folds.

### Lymphatic Drainage

Lymphatics from the oropharynx drain into upper jugular chain particularly the jugulodigastric (tonsillar) node. The soft palate, lateral and posterior pharyngeal walls and the base of tongue also drain into retropharyngeal and parapharyngeal nodes and from there to the jugulodigastric and posterior cervical group. The base of tongue may drain bilaterally.

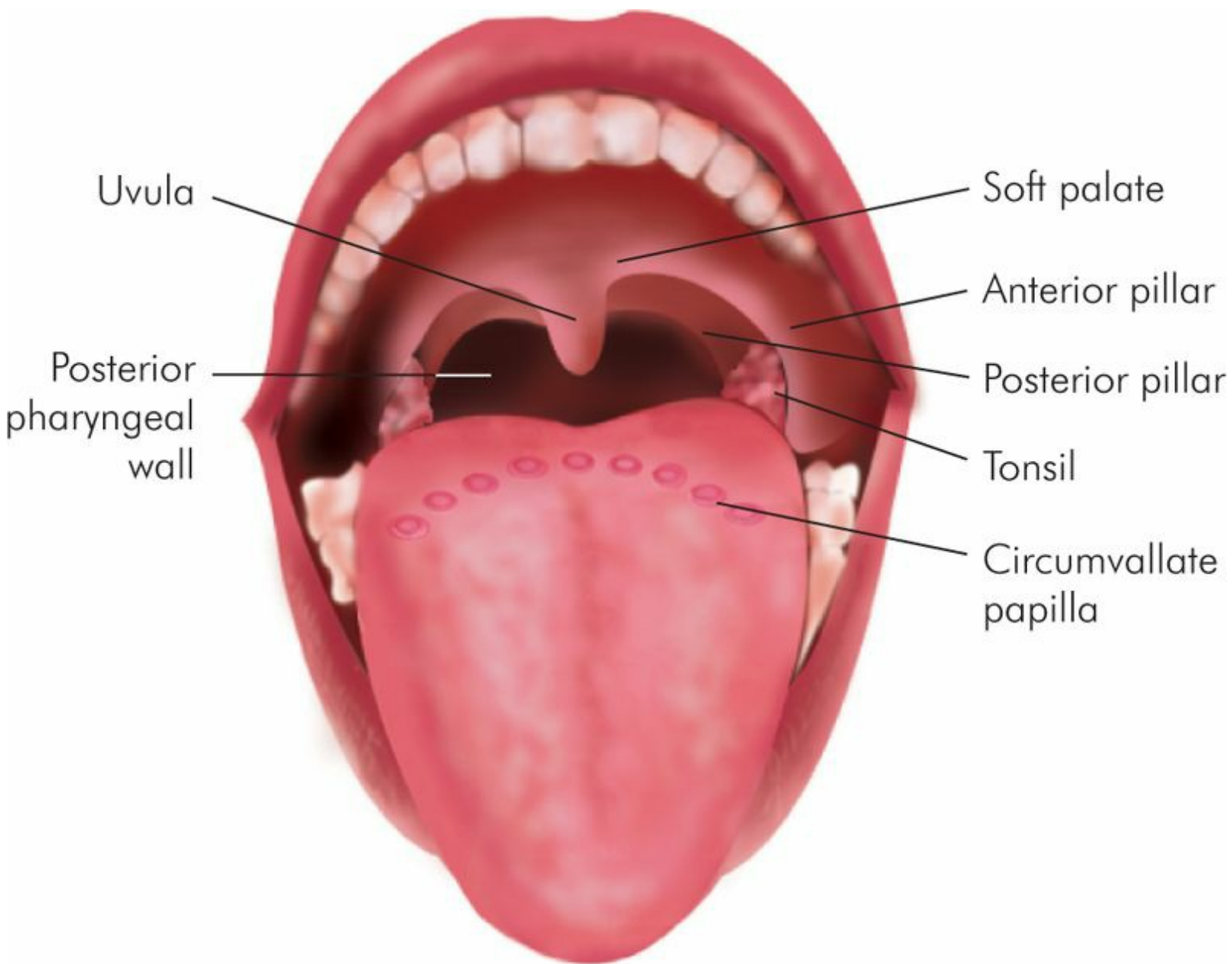
### Functions of Oropharynx

1. As a conduit for passage of air and food.
2. Helps in the pharyngeal phase of deglutition.
3. Forms part of vocal tract for certain speech sounds.
4. Helps in appreciation of the taste. Taste buds are present in the base of tongue, soft palate, anterior pillars and posterior pharyngeal wall.
5. Provides local defence and immunity against harmful intruders into the air and food passages. This function is subserved by subepithelial masses of lymphoid tissues scattered as Waldeyer's ring. They are strategically placed at the portals of air and food entry and act as protective sentinels. B-lymphocytes in the germinal centres of the follicles produce secretory antibodies of IgA class whereas T-lymphocytes in parafollicular region produce cell-mediated immunity against various viruses, bacteria and fungi. Pathogens which happen to enter into these lymphoid masses are dealt by IgM and IgG antibodies secreted by plasma cells.



Dhingra: Diseases of Ear Nose and Throat, 5th Edition  
Copyright © 2010 Elsevier. All rights reserved.

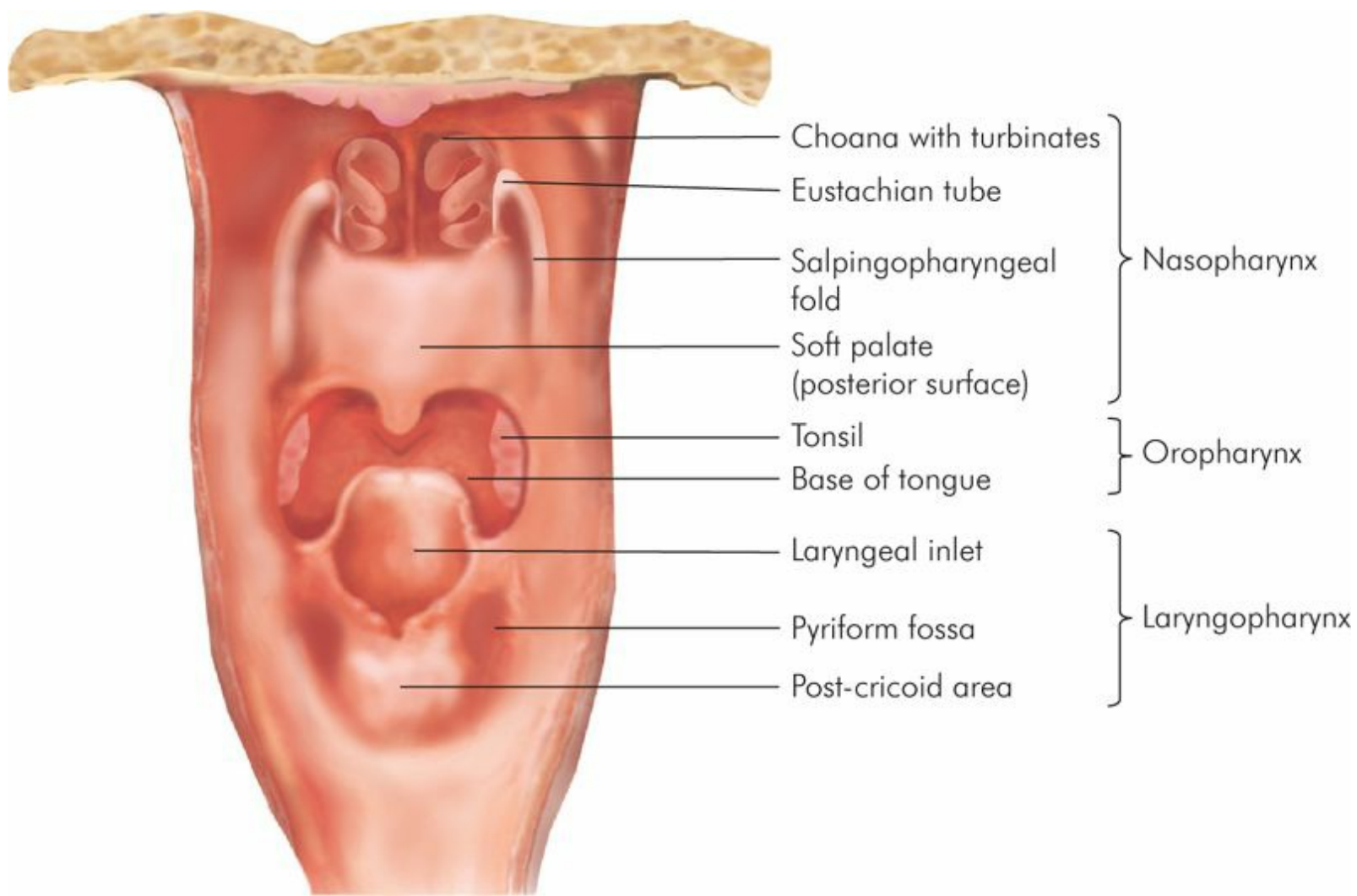
Figure 46.5 Base of tongue and valleculae.



Dhingra: Diseases of Ear Nose and Throat, 5th Edition  
Copyright © 2010 Elsevier. All rights reserved.

Figure 46.6 Various structures seen in the oropharynx.





Dhingra: Diseases of Ear Nose and Throat, 5th Edition  
 Copyright © 2010 Elsevier. All rights reserved.

Figure 46.7 Pharynx opened from behind showing structures related to nasopharynx, oropharynx and laryngopharynx.

# Hypopharynx (Laryngopharynx)

## Applied Anatomy

Hypopharynx is the lowest part of the pharynx and lies behind and partly on the sides of the larynx. Its superior limit is the plane passing from the body of hyoid bone to the posterior pharyngeal wall, while the inferior limit is lower border of cricoid cartilage where hypopharynx becomes continuous with oesophagus. Hypopharynx lies opposite the 3rd, 4th, 5th, 6th cervical vertebrae. Clinically, it is subdivided into three regions—the pyriform sinus, post-cricoid region and the posterior pharyngeal wall.

- **1. Pyriform sinus (fossa).** It lies on either side of the larynx and extends from pharyngoepiglottic fold to the upper end of oesophagus. It is bounded laterally by the thyrohyoid membrane and the thyroid cartilage and medially by the aryepiglottic fold, posterolateral surfaces of arytenoid and cricoid cartilages. It forms the lateral channel for food. Foreign bodies may lodge in the pyriform fossa. Internal laryngeal nerve runs submucosally in the lateral wall of the sinus and thus is easily accessible for local anaesthesia. It is also through this nerve that pain is referred to the ear in carcinoma of the pyriform sinus.
- **2. Post-cricoid region.** It is the part of the anterior wall of laryngopharynx between the upper and lower borders of cricoid lamina. It is a common site for carcinoma in females suffering from Plummer-Vinson syndrome (Fig. 46.7).
- **3. Posterior pharyngeal wall.** It extends from the level of hyoid bone to the level of cricoarytenoid joint.

## Lymphatic Drainage

Pyriform sinus is richly supplied by lymphatics which exit through the thyrohyoid membrane and drain into the upper jugular chain.

Lymphatics of the posterior wall terminate in the lateral pharyngeal or parapharyngeal nodes and thence to the deep cervical lymph nodes.

Lymphatics of post-cricoid region also drain into the parapharyngeal nodes but may also drain into nodes of supraclavicular and paratracheal chain.

Rich lymphatic network of pyriform fossae explains the high frequency with which nodal metastases are seen in carcinoma of this region.

## Functions of Hypopharynx

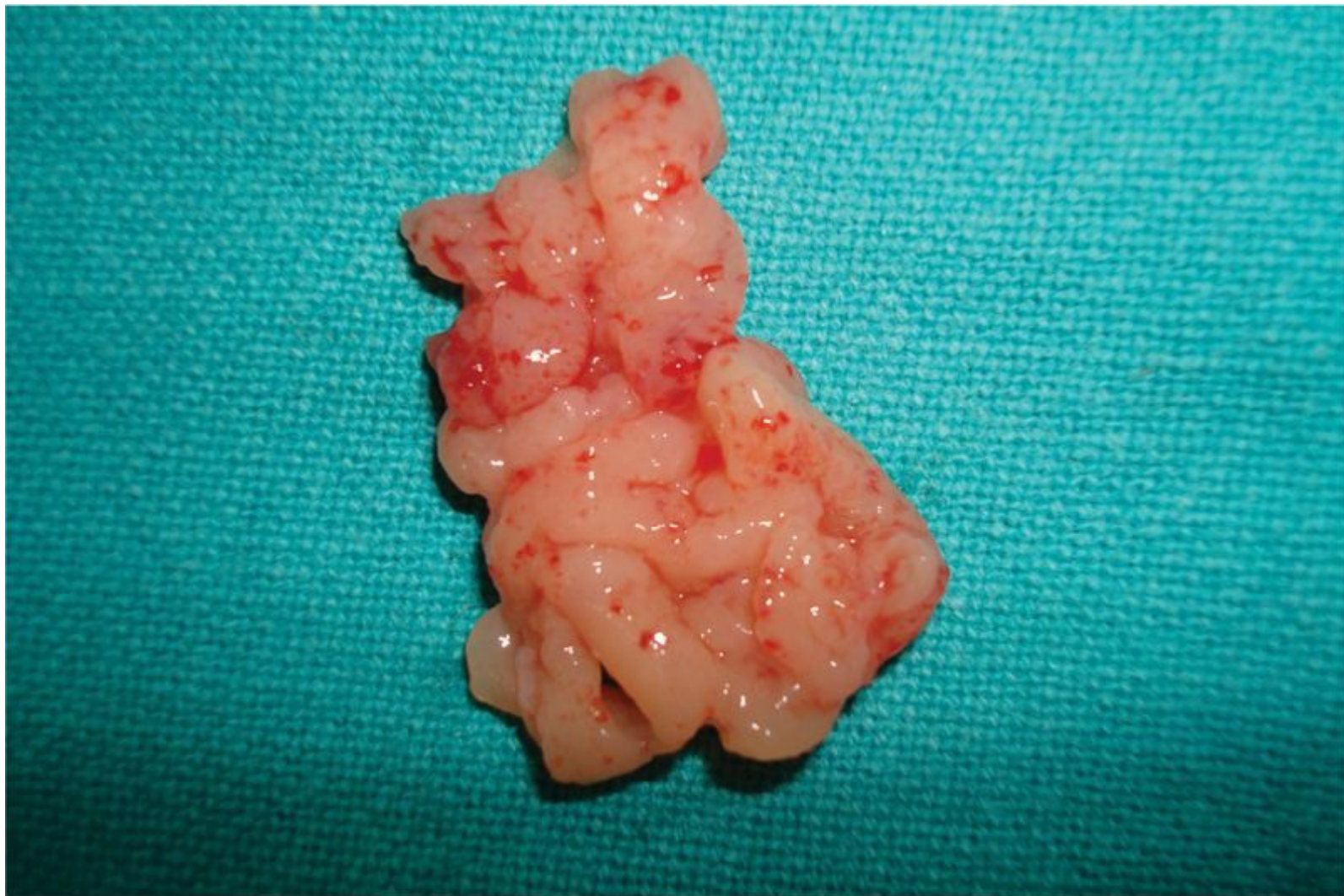Laryngopharynx, like oropharynx, is a common pathway for air and food, provides a vocal tract for resonance of certain speech sounds and helps in deglutition. There is a coordination between contraction of pharyngeal muscles and relaxation of cricopharyngeal sphincter at the upper end of oesophagus. Lack of this coordination, i.e. failure of cricopharyngeal sphincter to relax when pharyngeal muscles are contracting causes hypopharyngeal diverticulum.

## 47 Adenoids and Other Inflammations of Nasopharynx

### ADENOIDS

#### Anatomy and Physiology

The nasopharyngeal tonsil, commonly called "adenoids", is situated at the junction of the roof and posterior wall of the nasopharynx. It is composed of vertical ridges of lymphoid tissue separated by deep clefts and covered by ciliated columnar epithelium (Fig. 47.1). Unlike palatine tonsils, adenoids have no crypts and no capsule. Adenoid tissue is present at birth, shows physiological enlargement up to the age of six years, and then tends to atrophy at puberty and almost completely disappears by the age of 20.



Dhingra: Diseases of Ear Nose and Throat, 5th Edition  
Copyright © 2010 Elsevier. All rights reserved.

Figure 47.1 Adenoid mass after removal with curette. Note ridges of lymphoid tissue separated by deep clefts.

Adenoids receive their blood supply from:

- (i) Ascending palatine branch of facial.
- (ii) Ascending pharyngeal branch of external carotid.
- (iii) Pharyngeal branch of the third part of maxillary artery.
- (iv) Ascending cervical branch of inferior thyroid artery of thyrocervical trunk.

Lymphatics from the adenoid drain into upper jugular nodes directly or indirectly via retropharyngeal and parapharyngeal nodes.

## Aetiology

Adenoids are subject to physiological enlargement in childhood. Certain children have a tendency to generalised lymphoid hyperplasia in which adenoids also take part.

Recurrent attacks of rhinitis, sinusitis or chronic tonsillitis may cause chronic adenoid infection and hyperplasia.

Allergy of the upper respiratory tract may also contribute to the enlargement of adenoids.

# Clinical Features

Symptoms and signs depend not merely on the absolute size of the adenoid mass but are relative to the available space in the nasopharynx.

Enlarged and infected adenoids may cause nasal, aural or general symptoms.

## A. Nasal Symptoms

page 258

page 259

- **1. Nasal obstruction** is the commonest symptom. This leads to mouth breathing. Nasal obstruction also interferes with feeding or suckling in a child. As respiration and feeding cannot take place simultaneously, a child with adenoid enlargement fails to thrive.
- **2. Nasal discharge.** It is partly due to choanal obstruction, as the normal nasal secretions cannot drain into nasopharynx and partly due to associated chronic rhinitis. The child often has a wet bubbly nose.
- **3. Sinusitis.** Chronic maxillary sinusitis is commonly associated with adenoids. It is due to persistence of nasal discharge and infection. Reverse is also true that a primary maxillary sinusitis may lead to infected and enlarged adenoids.
- **4. Epistaxis.** When adenoids are acutely inflamed, epistaxis can occur with nose blowing.
- **5. Voice change.** Voice is toneless and loses nasal quality due to nasal obstruction.

## B. Aural Symptoms

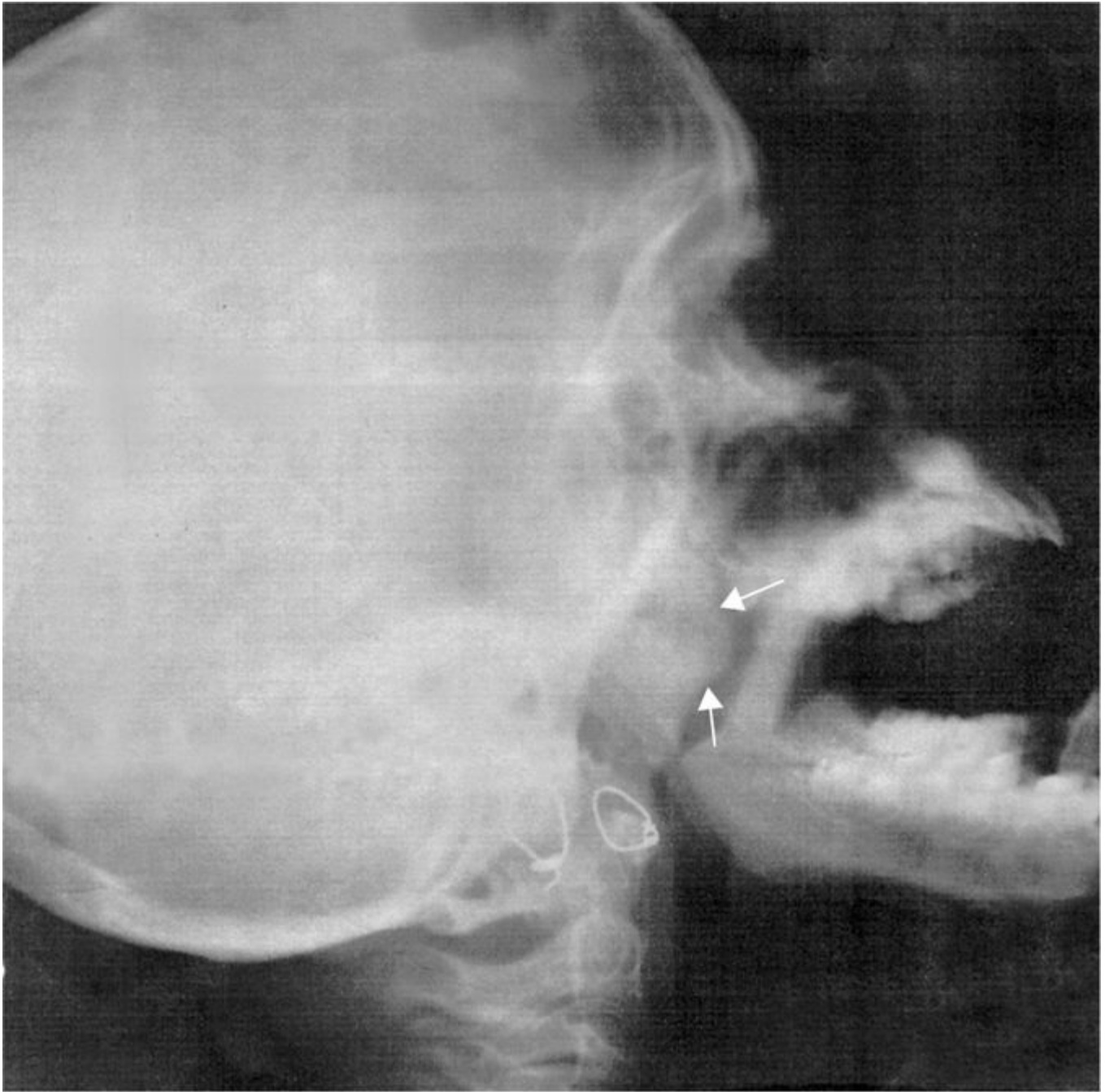
- **1. Tubal obstruction.** Adenoid mass blocks the eustachian tube leading to retracted tympanic membrane and conductive hearing loss.
- **2. Recurrent attacks of acute otitis media** may occur due to spread of infection via the eustachian tube.
- **3. Chronic suppurative otitis media** may fail to resolve in the presence of infected adenoids.
- **4. Serous otitis media.** Adenoids form an important cause of serous otitis media in children. The waxing and waning size of adenoids causes intermittent eustachian tube obstruction with fluctuating hearing loss.

## C. General Symptoms

- **1. Adenoid facies.** Chronic nasal obstruction and mouth breathing lead to characteristic facial appearance called *adenoid facies*. The child has an elongated face with dull expression, open mouth, prominent and crowded upper teeth, and hitched up upper lip. Nose gives a pinched-in appearance due to disuse atrophy of alae nasi. Hard palate in these cases is highly arched as the moulding action of the tongue on palate is lost.
- **2. Pulmonary hypertension.** Long-standing nasal obstruction due to adenoid hypertrophy can cause pulmonary hypertension and cor pulmonale.
- **3. Aproxia,** i.e. lack of concentration.

## Diagnosis

Examination of postnasal space is possible in some young children and an adenoid mass can be seen with a mirror. A rigid or a flexible nasopharyngoscope is also useful to see details of the nasopharynx. Soft tissue lateral radiograph of nasopharynx will reveal the size of adenoids and also the extent to which nasopharyngeal air space has been compromised (Fig. 47.2). Detailed nasal examination should always be conducted to exclude other causes of nasal obstruction.



Dhingra: Diseases of Ear Nose and Throat, 5th Edition  
Copyright © 2010 Elsevier. All rights reserved.

Figure 47.2 Enlarged adenoids (arrows) in a 7-year-old girl. There is very little breathing space in the nasopharynx.

When symptoms are not marked, breathing exercises, decongestant nasal drops and antihistaminics for any co-existent nasal allergy can cure the condition without resort to surgery.

When symptoms are marked, adenoidectomy is done. Indications and details of the operation are discussed in the section on operative surgery.

# ACUTE NASOPHARYNGITIS

## Aetiology

Acute infection of the nasopharynx may be an isolated infection confined to this part only or be a part of the generalised upper airway infection. It may be caused by viruses (common cold, influenza, para-influenza, rhino or adenovirus) or bacteria (especially *streptococcus*, *pneumococcus* or *Haemophilus influenzae*).



## Clinical Features

Dryness and burning of the throat above the soft palate is usually the first symptom as is commonly noted in common cold. This is followed by pain and discomfort localized to the back of nose with some difficulty on swallowing. In severe infections, there is pyrexia and enlarged cervical lymph nodes. Examination of nasopharynx reveals congested and swollen mucosa often covered with whitish exudate.

## Treatment

Mild cases clear up spontaneously. Some analgesic may be required for relief of pain and discomfort. In severe cases with general symptoms, systemic antibiotic or chemotherapy may be necessary. In children, there is associated adenoiditis which causes nasal obstruction, and requires nasal decongestant drops.

# **CHRONIC NASOPHARYNGITIS**

## **Aetiology**

It is often associated with chronic infections of nose, paranasal sinuses and pharynx. It is commonly seen in heavy smokers, drinkers and those exposed to dust and fumes.

## Clinical Features

Postnasal discharge and crusting with irritation at the back of nose is the most common complaint. Patient has a constant desire to clear the throat by hawking or inspiratory snorting (forcibly drawing nasal secretions back into the throat).

Examination of nasopharynx reveals congested mucosa and mucopus or dry crusts. In children, adenoids are often enlarged and infected (chronic adenoiditis).

## Treatment

Chronic infections of the nose, paranasal sinuses and oropharynx should be attended to. Excessive smoking and drinking should be corrected. Preventive measures should be taken to avoid dust and fumes. Alkaline nasal douche helps to remove crusts and mucopus. Steam inhalations are soothing.

## **THORNWALDT'S DISEASE (PHARYNGEAL BURSITIS)**

It is infection of the pharyngeal bursa which is a median recess representing attachment of notochord to endoderm of the primitive pharynx. Pharyngeal bursa is located in the midline of posterior wall of the nasopharynx in the adenoid mass.

## Clinical Features

- 1. Persistent postnasal discharge with crusting in the nasopharynx.
- 2. Nasal obstruction due to swelling in the nasopharynx.
- 3. Obstruction to eustachian tube and serous otitis media.
- 4. Dull type of occipital headache.
- 5. Recurrent sore throat.
- 6. Low grade fever.

Examination would reveal a cystic and fluctuant swelling in the posterior wall of nasopharynx. It may also show crusts in the nasopharynx due to dried up discharge.

## Treatment

Antibiotics are given to treat infection and marsupialisation of the cystic swelling and adequate removal of its lining membrane.



# 48 Tumours of Nasopharynx

## BENIGN TUMOURS

### Nasopharyngeal Fibroma (Juvenile Nasopharyngeal Angiofibroma)

It is a rare tumour, though it is the commonest of all benign tumours of nasopharynx.

#### Aetiology

The exact cause is unknown. As the tumour is predominantly seen in adolescent males in the second decade of life, it is thought to be testosterone dependent. Such patients have a hamartomatous nidus of vascular tissue in the nasopharynx and this is activated to form angiofibroma when male sex hormone appears.

#### Site of Origin and Growth

The site of origin of the tumour is still a matter of dispute. Earlier it was thought to arise from the roof of nasopharynx or the anterior wall of sphenoid bone but now it is believed to arise from the posterior part of nasal cavity close to the superior margin of sphenopalatine foramen. From here the tumour grows into the nasal cavity, nasopharynx and into the pterygopalatine fossa, running behind the posterior wall of maxillary sinus which is pushed forward as the tumour grows. Laterally, it extends into pterygomaxillary fossa and thence to infratemporal fossa and cheek.

#### Pathology

Angiofibroma, as the name implies, is made up of vascular and fibrous tissues: the ratio of the two components may vary. Mostly, the vessels are just endothelium-lined spaces with no muscle coat. This accounts for the severe bleeding as the vessels lose the ability to contract, and also the bleeding cannot be controlled by application of adrenaline.

#### Extensions of Nasopharyngeal Fibroma

Nasopharyngeal fibroma is a benign tumour but locally invasive and destroys the adjoining structures. It may extend into:

- (a) *Nasal cavity* causing nasal obstruction, epistaxis and nasal discharge.
- (b) *Paranasal sinuses*. Maxillary, sphenoid and ethmoid sinuses can all be invaded.
- (c) *Pterygomaxillary fossa, infratemporal fossa and cheek*.
- (d) *Orbits* giving rise to proptosis and "frog-face deformity". It enters through the inferior orbital fissure and also destroys apex of the orbit. It can also enter the orbit through superior orbital fissure.
- (e) *Cranial cavity*. Middle cranial fossa is the most common. There are two routes of entry:
  - (i) By erosion of floor of middle cranial fossa, anterior to foramen lacerum. The tumour lies lateral to carotid artery and cavernous sinus.
  - (ii) Through sphenoid sinus, into the sella. Tumour lies medial to carotid artery.

Anterior cranial fossa (through ethmoid roof or cribriform plate).


#### Clinical Features

page 261

page 262

- **1. Age and sex.** Tumour is seen almost exclusively in males in the age group of 10-20 years. Rarely, it may be seen in older people and females.
- **2. Profuse and recurrent epistaxis.** This is the most common presentation. Patient may be markedly anaemic due to repeated blood loss.
- **3. Progressive nasal obstruction and denasal speech** due to mass in the postnasal space.
- **4. Conductive hearing loss and serous otitis media** due to obstruction of eustachian tube.
- **5. Mass in the nasopharynx.** Tumour is sessile, lobulated or smooth and obstructs one or both choanae. It is pink or purplish in colour. Consistency is firm but digital palpation should never be done until at the time of operation.
- **6. Other clinical features** like broadening of nasal bridge, proptosis, swelling of cheek, infratemporal fossa or involvement of II<sup>nd</sup>, III<sup>rd</sup>, IV<sup>th</sup>, V<sup>th</sup> cranial nerves will depend on the extent of tumour (Fig. 48.1).

#### Investigations



Dhingra: Diseases of Ear Nose and Throat, 5th Edition  
Copyright © 2010 Elsevier. All rights reserved.

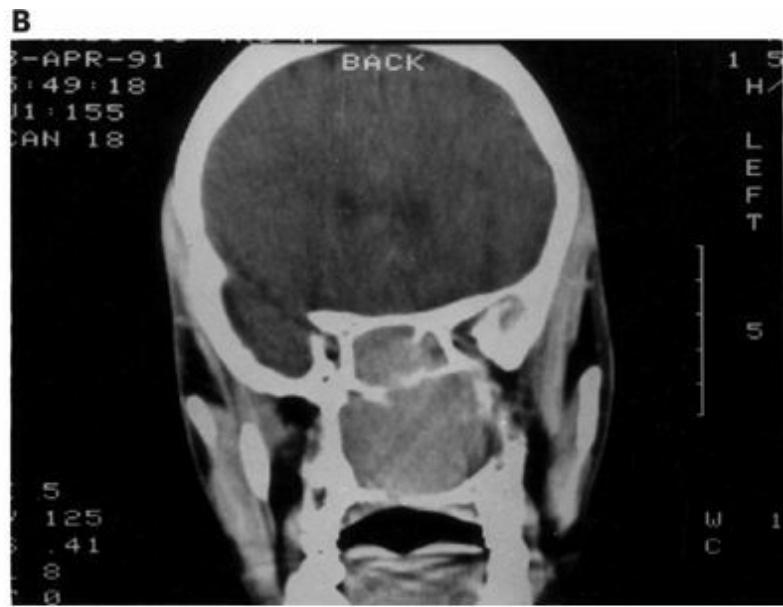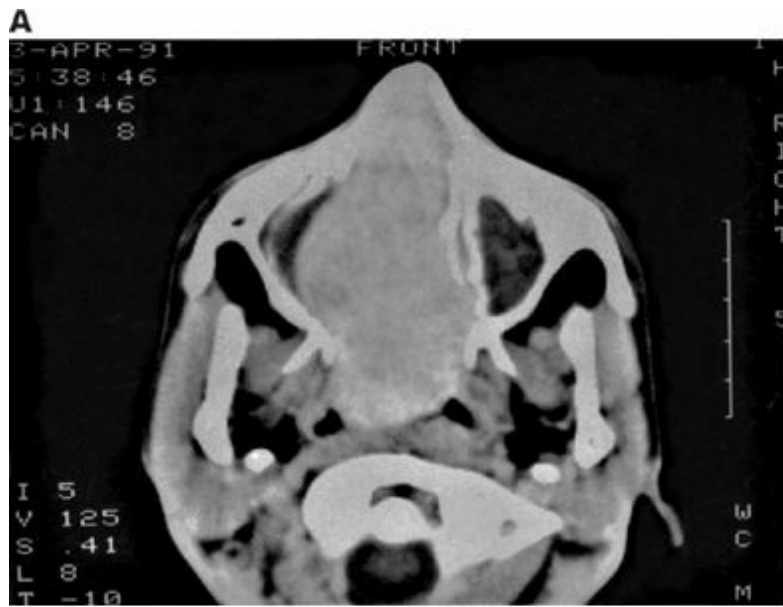Figure 48.1 Angiofibroma nasopharynx with extension into left cheek.

- 1. Soft tissue lateral film of nasopharynx shows soft tissue mass in the nasopharynx.
- 2. X-rays of paranasal sinuses and base of skull may show displacement of nasal septum, opacification of sinuses, anterior bowing of posterior wall of maxillary sinus, destruction of medial antral wall, erosion of greater wing of sphenoid or pterygoid plates, widening of lower lateral margin of superior orbital fissure.
- 3. CT scan of the head with contrast enhancement is now the investigation of choice (Fig. 48.2). It has replaced conventional radiographs. It shows the extent of tumour, bony destruction or displacements. Anterior bowing of the posterior wall of maxillary sinus (often called the **antral sign** or **Holman-Miller sign**) is pathognomic of angiofibroma.
- 4. Magnetic resonance imaging (MRI) is complementary to CT scans, when soft tissue extensions are present intracranially, in the infratemporal fossa or into the orbit.
- 5. Carotid angiography shows extension of tumour, its vascularity and feeding vessels. It is done when embolisation is planned before operation.

## Diagnosis

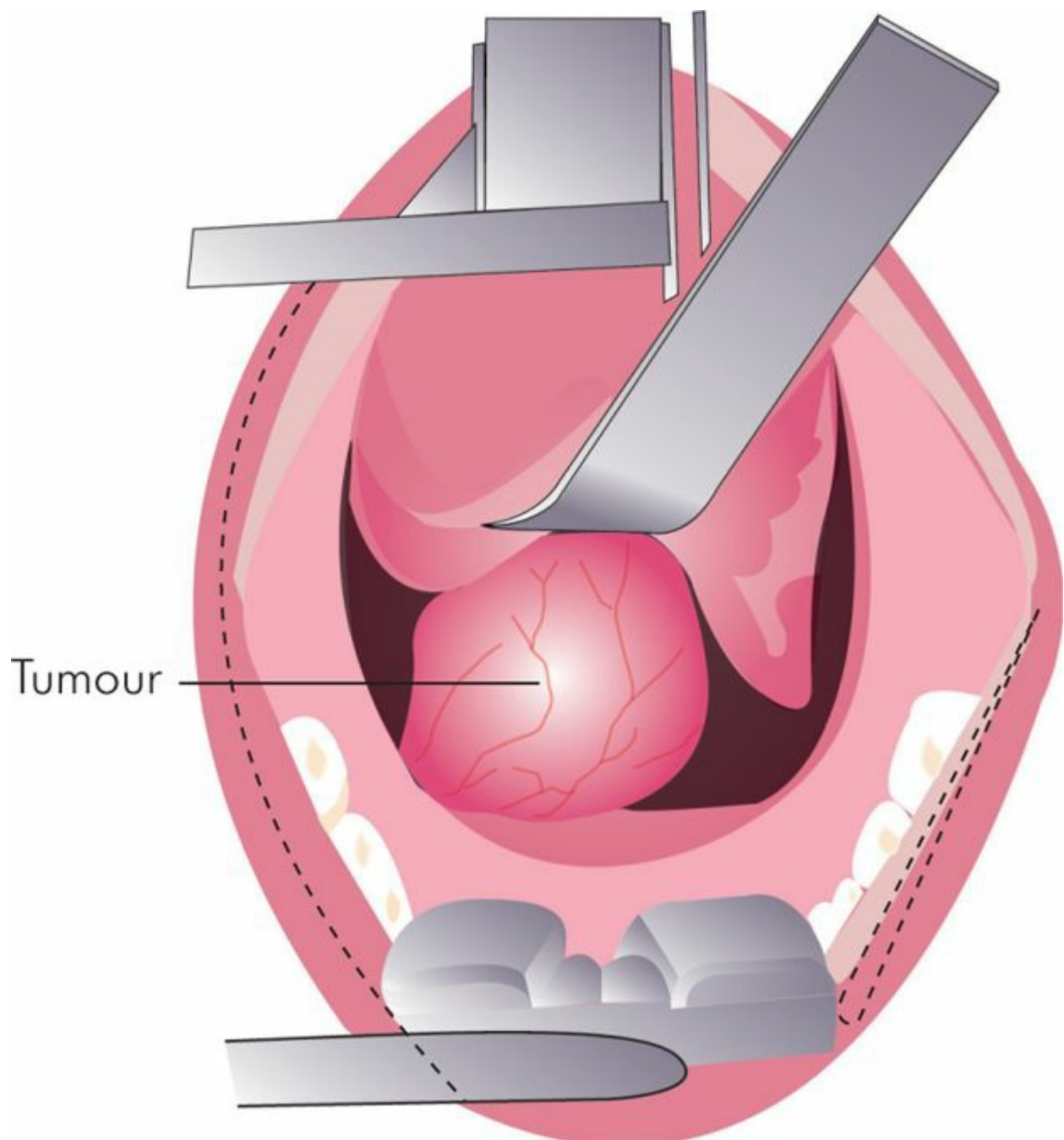
It is mostly based on clinical picture. Biopsy of the tumour is attended with profuse bleeding and is therefore, avoided. If it is essential to differentiate it from other tumours, biopsy can be done under general anaesthesia with all arrangements to control bleeding and transfuse blood.

## Treatment



Dhingra: Diseases of Ear Nose and Throat, 5th Edition  
Copyright © 2010 Elsevier. All rights reserved.

Figure 48.2 CT scan showing extent of angiofibroma: (A) Axial cut. (B) Coronal cut.



Dhingra: Diseases of Ear Nose and Throat, 5th Edition  
Copyright © 2010 Elsevier. All rights reserved.

Figure 48.3 Nasopharyngeal fibroma as seen after transpalatal exposure.

Earlier, nasopharyngeal angiofibromas were considered to undergo spontaneous regression with advancement of age but in practice it does not happen. Surgical excision is now the treatment of choice. Various surgical approaches to angiofibroma, depending on its origin and extensions, are listed below.

- 1. Transpalatine (Fig. 48.3)
- 2. Transpalatine + Sublabial (Sardana's approach)
- 3. Extended lateral rhinotomy
  - Via facial incision
  - Via degloving approach
- 4. Extended Denker's approach
- 5. Intracranial-extracranial
- 6. Infratemporal fossa
- 7. Endoscopic
- 8. Transmaxillary (Le Fort I approach)
- 9. Maxillary swing approach

Transpalatal approach is employed for tumours confined to nasopharynx. Lateral rhinotomy approach gives wide exposure and is generally preferred for the tumour and its extensions. There may be about 2 litres of blood loss during surgery. Therefore, attempts are made pre-operatively, to reduce the vascularity of tumour. A course of oestrogen therapy (stilboestrol 2.5 mg three times a day for 3 weeks) may reduce

vascularity of tumour. Pre-operative radiation also helps to reduce vascularity but is not generally favoured. Cryotherapy of the tumour or embolisation of the feeding vessels may also help to reduce blood loss at surgery.

Recurrence of tumour after surgical removal is not uncommon.

### ***Radiotherapy***

Radiotherapy has been used as a primary mode of treatment. A dose of 3000 to 3500 cGy in 15-18 fractions is delivered in 3-3.5 weeks. Response is not immediate. Tumour regresses slowly in about a year, sometimes even up to 3 years. Radiotherapy is also used for intracranial extension of disease when tumour derives its blood supply from the internal carotid system.

Recurrent angiofibromas have also been treated by intensity modulated radiotherapy-a newer mode of treatment.

### ***Hormonal***

Since the tumour occurs in young males at puberty, hormonal therapy as the primary or adjunctive treatment has been used. Diethylstilboestrol and flutamide have been used.

### ***Chemotherapy***

Recurrent and residual lesions have been treated by chemotherapy, doxorubicin, vincristine and dacarbazine in combination.

## OTHER BENIGN TUMOURS OF NASOPHARYNX

They are very rare and arise from the roof or lateral wall of nasopharynx. They include:

- **1. Teratomas.** Congenital tumours, seen at birth. Six times more common in females. Various types include, a *dermoid* with skin appendages, also called a hairy polyp, *true teratoma* having elements of all the three germ layers, and the *epignathi* with well-developed foetal parts.
- **2. Pleomorphic adenoma.**
- **3. Chordoma.** Derived from the notochord.
- **4. Hamartoma.** Malformed normal tissue, e.g. haemangioma.
- **5. Choristoma.** Mass of normal tissues at an abnormal site.
- **6. Paraganglioma.**

# MALIGNANT TUMOURS

## Nasopharyngeal Cancer

### Epidemiology and Geographic Distribution

Nasopharyngeal cancer is a multifactorial disease. Its incidence and geographic distribution depends on several factors such as genetic susceptibility, environment, diet and personal habits.

Nasopharyngeal cancer is most common in China particularly in southern states and Taiwan.

Its incidence in North American whites is 0.25% of all cancers, while it is 18% in American Chinese. Chinese born in America have lesser incidence than those born in China. Burning of incense or wood (polycyclic hydrocarbon), use of preserved salted fish (nitrosamines) along with vitamin C deficient diet (vitamin C blocks nitrosification of amines and is thus protective) may be other factors operative in China.

page 263

page 264

Nasopharyngeal cancer is uncommon in India and constitutes only 0.41% (0.66% in males and 0.17% in females) of all cancers except in the North East region where people are predominantly of Mongoloid origin. People in Southern China, Taiwan and Indonesia are more prone to this cancer.

### Aetiology

The exact aetiology is not known. The factors responsible are:

- **1. Genetic.** Chinese have a higher genetic susceptibility to nasopharyngeal cancer. Even after migration to other countries they continue to have higher incidence.
- **2. Viral.** Epstein-Barr virus is closely associated with nasopharyngeal cancer. Specific viral markers are being developed to screen people in high incidence areas.
- **3. Environmental.** Air pollution, smoking of tobacco and opium, nitrosamines from dry salted fish, smoke from burning of incense and wood have all been incriminated.

### Pathology

Squamous cell carcinoma in various grades of its differentiation or its variants as transitional cell carcinoma and lymphoepithelioma, is the most common (85%). Lymphomas constitute 10% and the rest 5% are rhabdomyosarcoma, malignant mixed salivary tumour or malignant chordoma.

On the basis of histology, as seen on light microscopy, WHO has lately reclassified epithelial growths into three types (see Table 48.1).

Grossly, the tumour presents in three forms:

#### 1. Proliferative

When a polypoid tumour fills the nasopharynx, it causes obstructive nasal symptoms.

#### 2. Ulcerative

Epistaxis is the common symptom.

#### 3. Infiltrative

Growths infiltrate submucosally.

Spread of nasopharyngeal carcinoma (see Fig. 48.4).

The commonest site of origin is fossa of Rosenmuller in the lateral wall of nasopharynx. It can spread into the cranium through foramen lacerum and cause involvement of various cranial nerves. Lymph node involvement is common because of rich lymphatic network in the nasopharynx.

Table 48-1. WHO classification based on histopathology

	Present WHO terminology	Former terminology
Type I (25%)	Squamous cell carcinoma	Squamous cell carcinoma
Type II (12%)	Non-keratinising carcinoma	Transitional cell carcinoma
	- Without lymphoid stroma	Intermediate cell carcinoma
	- With lymphoid stroma	Lymphoepithelial carcinoma (Regaud)
Type III (63%)	Undifferentiated carcinoma	Anaplastic carcinoma

	- Without lymphoid stroma	Clear cell carcinoma
	- With lymphoid stroma	Lymphoepithelial carcinoma (Schminke)
		Spindle cell carcinoma

## Clinical Features

**Age.** It is mostly seen in fifth to seventh decades but may involve younger age groups. It is not uncommon to see cancer of nasopharynx in twenties and thirties.

**Sex.** Males are three times more prone than females.

Symptomatology is divided into four main groups:

### 1. Nasal

Nasal obstruction, nasal discharge, denasal speech (rhinolalia clausa) and epistaxis.

### 2. Otologic

Due to obstruction of eustachian tube, there is conductive hearing loss, serous or suppurative otitis media. Tinnitus and dizziness may occur.

*Presence of unilateral serous otitis media in an adult should raise suspicion of nasopharyngeal growth.* Rarely, tumour grows up the tube into the middle ear.

### 3. Ophthalmoneurologic

This occurs due to extension of tumour to the surrounding regions. Nearly all the cranial nerves may be involved.

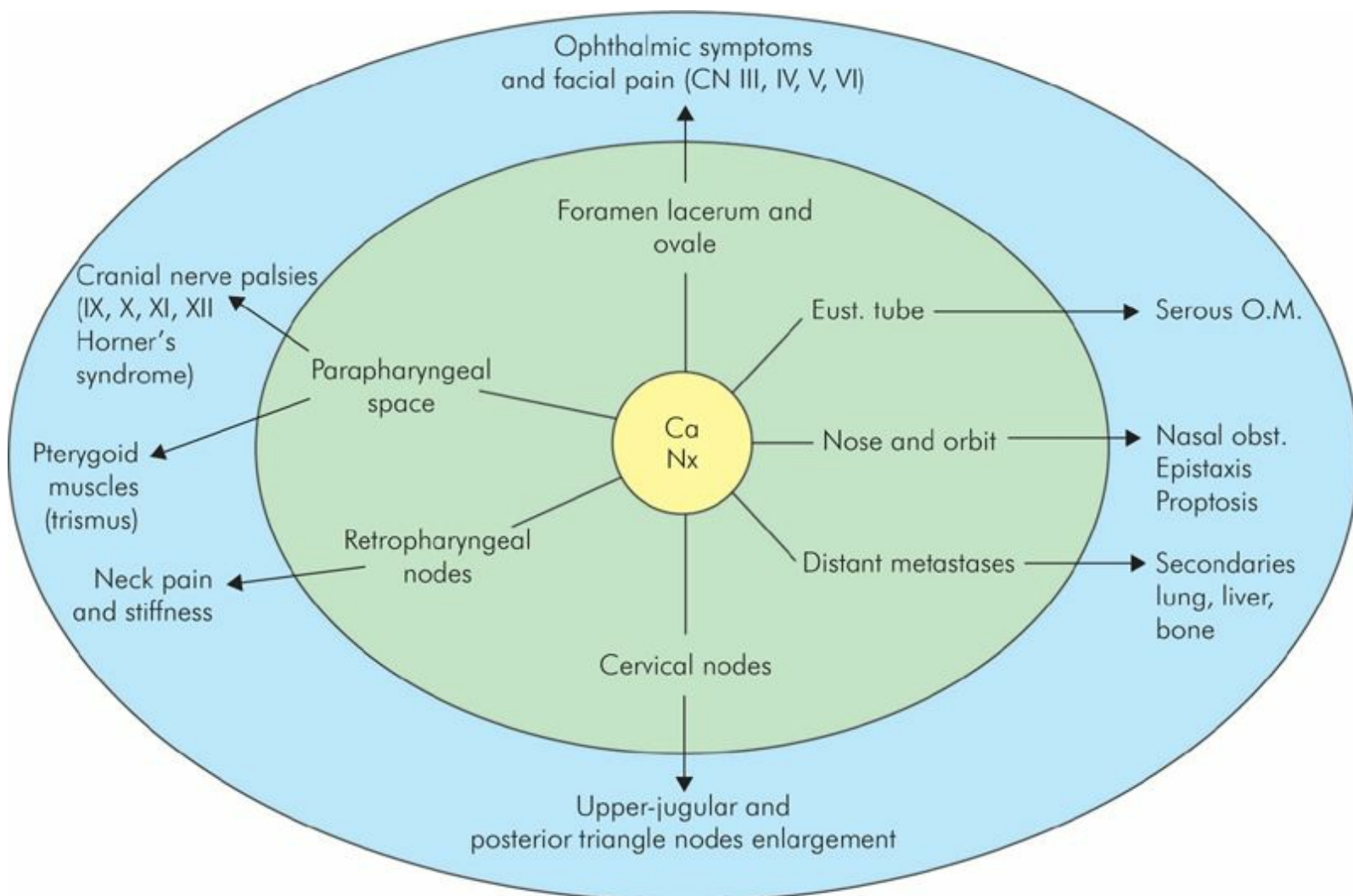
Squint and diplopia due to involvement of CN VI, ophthalmoplegia (CN III, IV and VI), facial pain and reduced corneal reflex may (invasion of CN V through foramen lacerum) occur. Tumours may directly invade the orbit leading to exophthalmos and blindness (CN II at the apex of the orbit). Involvement of IXth, Xth and XIth cranial nerves may occur, constituting *jugular foramen syndrome*. Usually, this is due to pressure of enlarged lateral retropharyngeal lymph nodes on these nerves in the neck. CN XII may be involved due to extension of growth to hypoglossal canal. Horner's syndrome may occur due to involvement of cervical sympathetic chain.

Nasopharyngeal cancer can cause conductive deafness (eustachian tube blockage), ipsilateral temporoparietal neuralgia (involvement of CN V) and palatal paralysis (CN X)-collectively called *Trotter's triad*.

### 4. Cervical nodal metastases

This may be the only manifestation of nasopharyngeal cancer. A lump of nodes is found between the angle of jaw and the mastoid and some nodes along the spinal accessory in the posterior triangle of neck. Nodal metastases are seen in 75% of the patients, when first seen, about half of them with bilateral nodes.





Dhingra: Diseases of Ear Nose and Throat, 5th Edition  
Copyright © 2010 Elsevier. All rights reserved.

Figure 48.4 Routes of spread (green area) and clinical features (blue area) of nasopharyngeal cancer.

### 5. Distant metastases

involve bone, lung, liver and other sites.

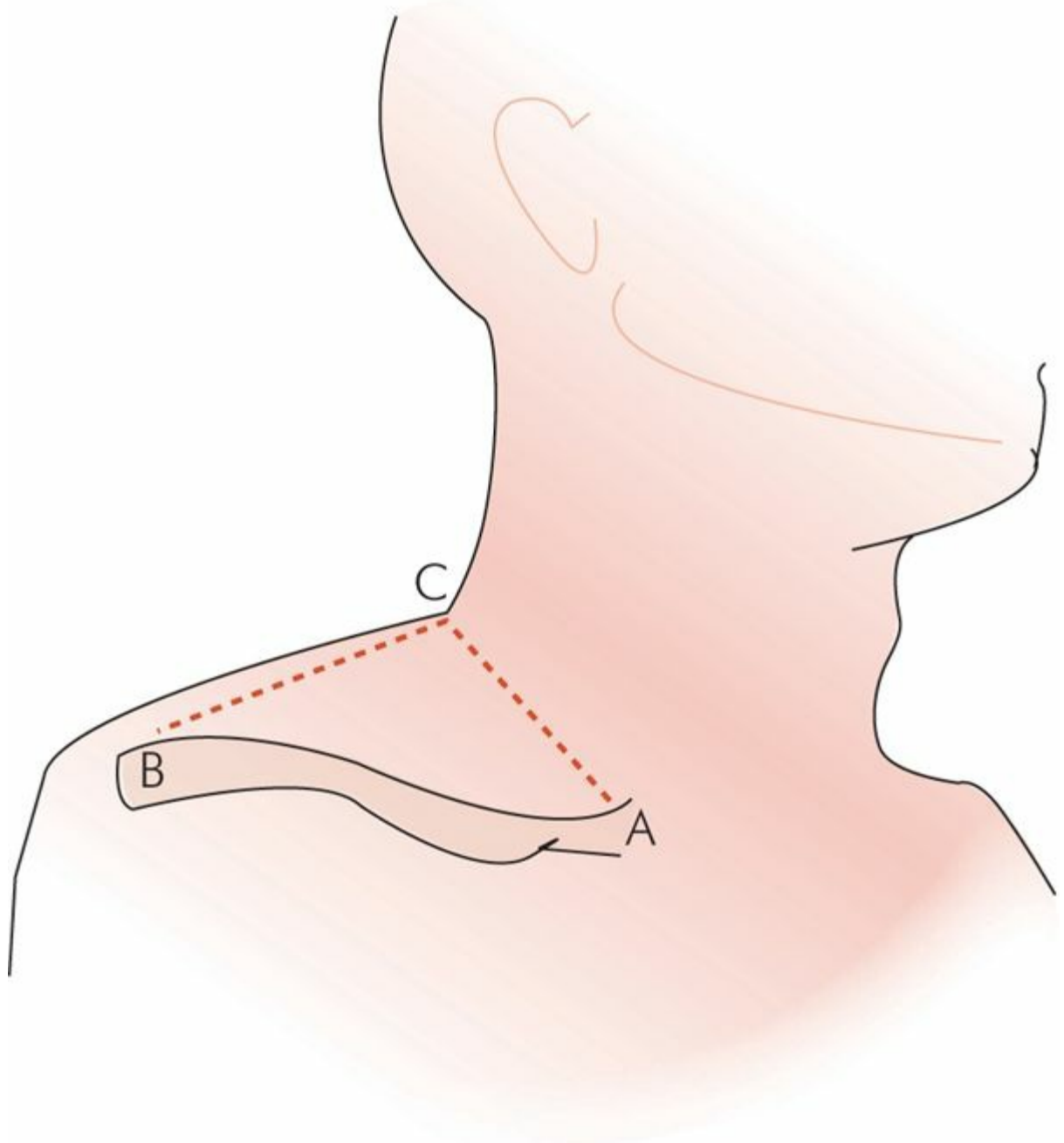
Presenting symptoms and signs of nasopharyngeal cancer in order of frequency are:

- Cervical lymphadenopathy (most common) (60-90%)
- Hearing loss
- Nasal obstruction
- Epistaxis
- Cranial nerve palsies. CN VI paralysis is the most common of these
- Headache
- Earache
- Neck pain
- Weight loss.

### Diagnosis

Examination of postnasal space by a nasopharyngeal mirror or nasopharyngoscope is the most important.

Skull X-rays, tomograms or preferably CT scans are done to demonstrate erosion of bone at the base of skull and the extent of tumour. MRI with gadolinium enhancement reveals the intracranial extension.



Dhingra: Diseases of Ear Nose and Throat, 5th Edition  
 Copyright © 2010 Elsevier. All rights reserved.

Figure 48.5 Supraclavicular fossa (or Ho's triangle) is bounded by medial (A) and lateral (B) ends of clavicle and the point (C) where neck meets the shoulder. It includes caudal portions of levels IV and V.

Biopsy is essential to show the exact histology of the malignancy. In the absence of a nasopharyngeal lesion but with strong suspicion of malignancy, nasopharynx is exposed by transpalatal approach and a strip of mucosa and submucosa from the region of fossa of Rosenmuller should be taken and subjected to histology. Submucosal spread, beneath a normal appearing surface mucosa, is quite common. Nasopharynx is also a common site for occult primaries.

## Classification (see Table 48.2)

WHO classified nasopharyngeal carcinoma on histopathological basis into three types (Table 48.1). Type III is the most common in North America. However, the frequency of different histopathological types may differ from country to country. These types have also been correlated to titres of Epstein-Barr (EB) virus and also in response to radiotherapy. It is observed that type II and type III are associated with higher titres of EB virus and have higher local control rates with radiotherapy.

## Treatment

Irradiation is the treatment of choice. Supervoltage therapy using large ports which include cervical nodes, delivering a tumour dose of 6000-7000 rads, is employed.

**Table 48-2. TNM classification of nasopharyngeal carcinoma (AJC 2002)**

<b>Primary tumour</b>			
T <sub>1</sub>	Tumour confined to the nasopharynx		
T <sub>2</sub>	Tumour extends to soft tissues of oropharynx and/or nasal fossa		
	T <sub>2a</sub>	without parapharyngeal extension	
	T <sub>2b</sub>	with parapharyngeal extension	
T <sub>3</sub>	Tumour invades bony structures and/or paranasal sinuses		
T <sub>4</sub>	Tumour with intracranial extension and/or involvement of cranial nerves, infratemporal fossa, hypopharynx or orbit or masticator space		
<b>Regional lymph nodes</b>			
The distribution and the prognostic impact of regional lymph node spread from nasopharynx cancer, particularly of the undifferentiated type, is different from that of other head and neck mucosal cancers and justifies use of a different N classification scheme			
N <sub>x</sub>	Regional lymph nodes cannot be assessed		
N <sub>0</sub>	No regional lymph node metastasis		
N <sub>1</sub>	Unilateral metastasis in lymph node(s), 6 cm or less in greatest dimension, above the supraclavicular fossa		
N <sub>2</sub>	Bilateral metastasis in lymph nodes, 6 cm or less in greatest dimension, above the supraclavicular fossa.		
N <sub>3</sub>	Metastasis in a lymph node(s)		
	N <sub>3a</sub>	Greater than 6 cm in dimension	
	N <sub>3b</sub>	In the supraclavicular fossa	
<b>Distant metastasis</b>			
M <sub>x</sub>	Distant metastasis cannot be assessed		
M <sub>0</sub>	No distant metastasis		
M <sub>1</sub>	Distant metastasis		
<b>Stage grouping</b>			
0	Tis	N <sub>0</sub>	M <sub>0</sub>
I	T <sub>1</sub>	N <sub>0</sub>	M <sub>0</sub>
IIA	T <sub>2a</sub>	N <sub>0</sub>	M <sub>0</sub>
IIB	T <sub>1</sub>	N <sub>1</sub>	M <sub>0</sub>
	T <sub>2</sub>	N <sub>1</sub>	M <sub>0</sub>
	T <sub>2a</sub>	N <sub>1</sub>	M <sub>0</sub>
	T <sub>2b</sub>	N <sub>0</sub> , N <sub>1</sub>	M <sub>0</sub>
	T <sub>1</sub>	N <sub>2</sub>	M <sub>0</sub>
	T <sub>2a</sub> , T <sub>2b</sub>	N <sub>2</sub>	M <sub>0</sub>
III	T <sub>3</sub>	N <sub>0</sub> , N <sub>1</sub> , N <sub>2</sub>	M <sub>0</sub>
	T <sub>4</sub>	N <sub>0</sub> , N <sub>1</sub> , N <sub>2</sub>	M <sub>0</sub>
	Any T	N <sub>3</sub>	M <sub>0</sub>
IVC	Any T	Any N	M <sub>1</sub>

Note: In nasopharyngeal carcinoma, N<sub>3</sub> classification is different from that of other mucosal cancers of the head and neck. Enlarged nodes in the lower neck (supraclavicular fossa) places them in N<sub>3</sub> category. Less weightage is given to nodes in upper neck. Nodes even up to 6 cm size are still categorised as N<sub>1</sub> as against N<sub>2</sub> at other sites.

Supraclavicular fossa or Ho's triangle is defined as area of neck lying between three points: (i) medial end of clavicle, (ii) lateral end of clavicle and (iii) the point where neck meets the shoulder (Fig. 48.5).

Enlarged node(s) in this triangle, irrespective of the size, are categorised as N<sub>3</sub>

Radical neck dissection is required for persistent nodes when primary has been controlled. Recurrent or residual tumour requires a second course of external radiation or intracavitary implants (brachytherapy). Recurrences have also been treated with cryosurgery through a palatal fenestration or in selected cases by skull base surgery.

### **Chemotherapy**

Some stages III and IV cancers of nasopharynx can be cured by radiotherapy alone but cure rate is doubled when chemotherapy is combined with radiotherapy. Chemotherapy can be given concomitantly or postradiotherapy. Cisplatin or cisplatin with 5-FU have been used. Chemotherapy has

also been found useful to control metastases from lymphoepithelioma and undifferentiated carcinoma of nasopharynx. Goal of chemoradiotherapy in nasopharyngeal carcinoma is to improve local control of tumour and treat distant metastases.

## OTHER MALIGNANT TUMOURS OF NASOPHARYNX

They are rare and include:

- 1. *Lymphomas*. Non-Hodgkin's type is more common than Hodgkin's. Almost all are B-cell type.
- 2. *Rhabdomyosarcoma*. Commonly seen in Children. Embryonal rhabdomyosarcoma presents as a polypoid mass in the nasopharynx.
- 3. *Plasmacytoma*. It may be solitary or part of generalised multiple myelomatosis.
- 4. *Chordoma* (from remnant of notochord).
- 5. *Adenoid cystic carcinoma* (from minor salivary glands).
- 6. *Melanoma* (rare).

## 49 Acute and Chronic Pharyngitis

### ACUTE PHARYNGITIS

#### Aetiology

Acute pharyngitis is very common and occurs due to varied aetiological factors like viral, bacterial, fungal or others (Table 49.1). Viral causes are more common. Acute streptococcal pharyngitis (due to Group A beta *haemolytic streptococci*) has received more importance because of its aetiology in rheumatic fever and post-streptococcal glomerulonephritis.

## Clinical Features

Pharyngitis may occur in different grades of severity. *Milder* infections present with discomfort in the throat, some malaise and low grade fever. Pharynx in these cases is congested but there is no lymphadenopathy. *Moderate* and *severe* infections present with pain in throat, dysphagia, headache, malaise and high fever. Pharynx in these cases shows erythema, exudate and enlargement of tonsils and lymphoid follicles on the posterior pharyngeal wall. *Very severe* cases show oedema of soft palate and uvula with enlargement of cervical nodes.

Table 49-1. Causes of acute pharyngitis

Viral	Bacterial	Fungal	Miscellaneous
<ul style="list-style-type: none"><li>• Rhinoviruses</li><li>• Influenza</li><li>• Parainfluenza</li><li>• Measles and chickenpox</li><li>• Coxsackie virus</li><li>• Herpes simplex</li><li>• Infectious mononucleosis</li><li>• Cytomegalovirus</li></ul>	<ul style="list-style-type: none"><li>• <i>Streptococcus</i> (Group A, beta-haemolyticus)</li><li>• <i>Diphtheria</i></li><li>• <i>Gonococcus</i></li></ul>	<ul style="list-style-type: none"><li>• <i>Candida albicans</i></li><li>• <i>Chlamydia trachomatis</i></li></ul>	<ul style="list-style-type: none"><li>• Toxoplasmosis (parasitic, rare)</li></ul>

It is not possible, on clinical examination, to differentiate viral from bacterial infections but, viral infections are generally mild and are accompanied by rhinorrhoea and hoarseness while the bacterial ones are severe. Gonococcal pharyngitis is mild and may even be asymptomatic.

## Diagnosis

Culture of throat swab is helpful in the diagnosis of bacterial pharyngitis. It can detect 90% of Group A *Streptococci*. *Diphtheria* is cultured on special media. Swab from a suspected case of gonococcal pharyngitis should be cultured immediately without delay. Failure to get any bacterial growth suggests a viral aetiology.



# Treatment

## **General measures**

Bed rest, plenty of fluids, warm saline gargles or pharyngeal irrigations and analgesics form the mainstay of treatment.

Local discomfort in the throat in severe cases can be relieved by lignocaine viscous before meals to facilitate swallowing.

## **Specific treatment**

page 268

page 269

Streptococcal pharyngitis (Group A, beta-haemolyticus) is treated with penicillin G, 200,000 to 250,000 units orally four times a day for 10 days or benzathine penicillin G, 600,000 units once i.m. for patient <60 lb in weight and 1.2 million units once i.m. for patient >60 lb. In penicillin-sensitive individuals, erythromycin, 20 to 40 mg/kg body weight daily, in divided oral doses for 10 days is equally effective.

Diphtheria is treated by diphtheria antitoxin and administration of penicillin or erythromycin (see page 274).

Gonococcal pharyngitis responds to conventional doses of penicillin or tetracycline.

## Viral Infections Causing Pharyngitis

*Herpangina*. It is caused by Group A coxsackie virus and mostly affects children. Characteristic features include fever, sore throat and vesicular eruption on the soft palate and pillars. Vesicles are small and surrounded by a zone of erythema.

*Infectious mononucleosis*. It is caused by Epstein-Barr virus. It affects older children and young adults, and is characterised by fever, sore throat, exudative pharyngitis, lymphadenopathy, splenomegaly and hepatitis.

*Cytomegalovirus*. It mostly affects immunosuppressed transplant patients. Clinically, it mimics infectious mononucleosis but heterophil antibody test is negative.

*Pharyngoconjunctival fever*. It is caused by an adenovirus, and is characterised by sore throat, fever and conjunctivitis. There may be pain in abdomen, mimicking appendicitis.

*Acute lymphonodular pharyngitis*. It is usually caused by a coxsackie virus and characterised by fever, malaise and sore throat. White-yellow, solid nodules appear on the posterior pharyngeal wall in this type of pharyngitis.

*Measles and chickenpox* also cause pharyngitis. Measles is characterised by the appearance of Koplik's spots (white spots surrounded by red areola) on the buccal mucosa opposite the molar teeth. The spots appear 3-4 days before the appearance of rash.

## Fungal Pharyngitis

*Candida* infection of the oropharynx can occur as an extension of oral thrush. It is seen in patients who are immunosuppressed, debilitated or taking high doses of antimicrobials. Often patient complains of pain in the throat with dysphagia. Nystatin is the drug of choice.

## Miscellaneous Causes of Pharyngitis

*Chlamydia trachomatis* infection causes acute pharyngitis and can be treated by erythromycin or sulphonamides. Toxoplasmosis is caused by *Toxoplasma gondii*, an obligate intracellular parasite. This infection is very rare.

# CHRONIC PHARYNGITIS

It is a chronic inflammatory condition of the pharynx. Pathologically, it is characterised by hypertrophy of mucosa, seromucinous glands, subepithelial lymphoid follicles and even the muscular coat of the pharynx.

Chronic pharyngitis is of two types:

- **1.** Chronic catarrhal pharyngitis
- **2.** Chronic hypertrophic (granular) pharyngitis.

# Aetiology

A large number of factors are responsible:

- **1. Persistent infection in the neighbourhood** In chronic rhinitis and sinusitis, purulent discharge constantly trickles down the pharynx and provides a constant source of infection. This causes hypertrophy of the lateral pharyngeal bands. Similarly, chronic tonsillitis and dental sepsis are also responsible for chronic pharyngitis and recurrent sore throats.
- **2. Mouth breathing** Breathing through the mouth exposes the pharynx to air which has not been filtered, humidified and adjusted to body temperature thus making it more susceptible to infections. Mouth breathing is due to:
  - (i) Obstruction in the nose, e.g. nasal polypi, allergic or vasomotor rhinitis, turbinal hypertrophy, deviated septum or tumours,
  - (ii) Obstruction in the nasopharynx, e.g. adenoids and tumours,
  - (iii) Protruding teeth which prevent apposition of lips,
  - (iv) Habitual, without any organic cause.
- **3. Chronic irritants** Excessive smoking, chewing of tobacco and pan, heavy drinking, highly spiced food can all lead to chronic pharyngitis.
- **4. Environmental pollution** Smoky or dusty environment or irritant industrial fumes may also be responsible for chronic pharyngitis.
- **5. Faulty voice production** Less often realised but an important cause of chronic pharyngitis in the faulty voice production. Excessive use of voice or faulty voice production seen in certain professionals or in "pharyngeal neurosis" where person resorts to constant throat clearing, hawking or snorting, and that may cause chronic pharyngitis, especially of hypertrophic variety.

Severity of symptoms in chronic pharyngitis varies from person to person.

- **1. Discomfort or pain in the throat** This is especially noticed in the mornings.
- **2. Foreign body sensation in throat** Patient has a constant desire to swallow or clear his throat to get rid of this "foreign body".
- **3. Tiredness of voice** Patient cannot speak for long and has to make undue effort to speak as throat starts aching. The voice may also lose its quality and may even crack.
- **4. Cough** Throat is irritable and there is tendency to cough. Mere opening of the mouth may induce retching or gagging.

# Signs

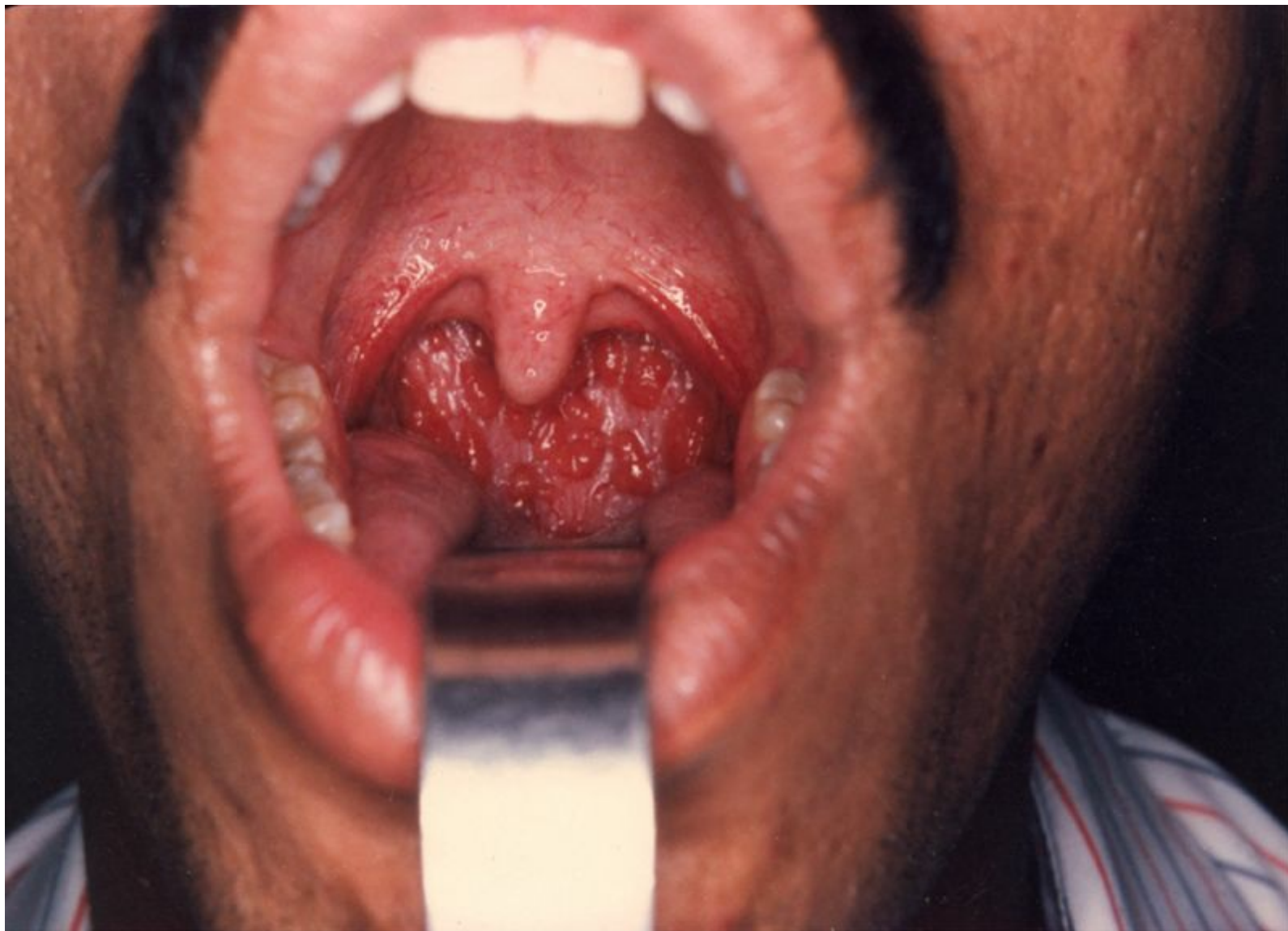## ***Chronic catarrhal pharyngitis***

In this, there is a congestion of posterior pharyngeal wall with engorgement of vessels; faucial pillars may be thickened. There is increased mucus secretion which may cover pharyngeal mucosa.

## ***Chronic hypertrophic (granular) pharyngitis***

- 1. Pharyngeal wall appears thick and oedematous with congested mucosa and dilated vessels.
- 2. Posterior pharyngeal wall may be studded with reddish nodules (hence the term granular pharyngitis). These nodules are due to hypertrophy of subepithelial lymphoid follicles normally seen in pharynx (Fig. 49.1).
- 3. Lateral pharyngeal bands become hypertrophied.
- 4. Uvula may be elongated and appear oedematous.





Dhingra: Diseases of Ear Nose and Throat, 5th Edition  
Copyright © 2010 Elsevier. All rights reserved.

Figure 49.1 Granular pharyngitis. Note: Reddish nodules on the posterior pharyngeal wall.

- 1. In every case of chronic pharyngitis, aetiological factor should be sought and eradicated.
- 2. Voice rest and speech therapy is essential for those with faulty voice production. Hawking, clearing the throat frequently or any other such habit should be stopped.
- 3. Warm saline gargles, especially in the morning, are soothing and relieve discomfort.
- 4. Mandl's paint may be applied to pharyngeal mucosa.
- 5. Cautery of lymphoid granules is suggested. Throat is sprayed with local anaesthetic and granules are touched with 10-25% silver nitrate. Electrocautery or diathermy of nodules may require general anaesthesia.

## **ATROPHIC PHARYNGITIS**

It is a form of chronic pharyngitis often seen in patients of atrophic rhinitis. Pharyngeal mucosa along with its mucous glands shows atrophy. Scanty mucus production by glands leads to formation of crusts which later get infected giving rise to foul smell.

## Clinical Features

Dryness and discomfort in throat are the main complaints. Hawking and dry cough may be present due to crust formation. Examination shows dry and glazed pharyngeal mucosa often covered with crusts.

## Treatment

This is the same as for co-existent atrophic rhinitis. Aim is to remove the crusts and promote secretion. The crusts can be removed by spraying the throat with alkaline solution, or pharyngeal irrigation. Mandl's paint applied locally has a soothing effect.

Potassium iodide, 325 mg, administered orally for a few days helps to promote secretion and prevents crusting.

## **KERATOSIS PHARYNGITIS**

It is a benign condition characterised by horny excrescences on the surface of tonsils, pharyngeal wall or lingual tonsils appearing as white or yellowish dots. These excrescences are the result of hypertrophy and keratinisation of epithelium. They are firmly adherent and cannot be wiped off. There is no accompanying inflammation nor any constitutional symptoms, thus it can be easily differentiated from acute follicular tonsillitis. The disease may show spontaneous regression and does not require any specific treatment except for reassurance to the patient.

## 50 Acute and Chronic Tonsillitis

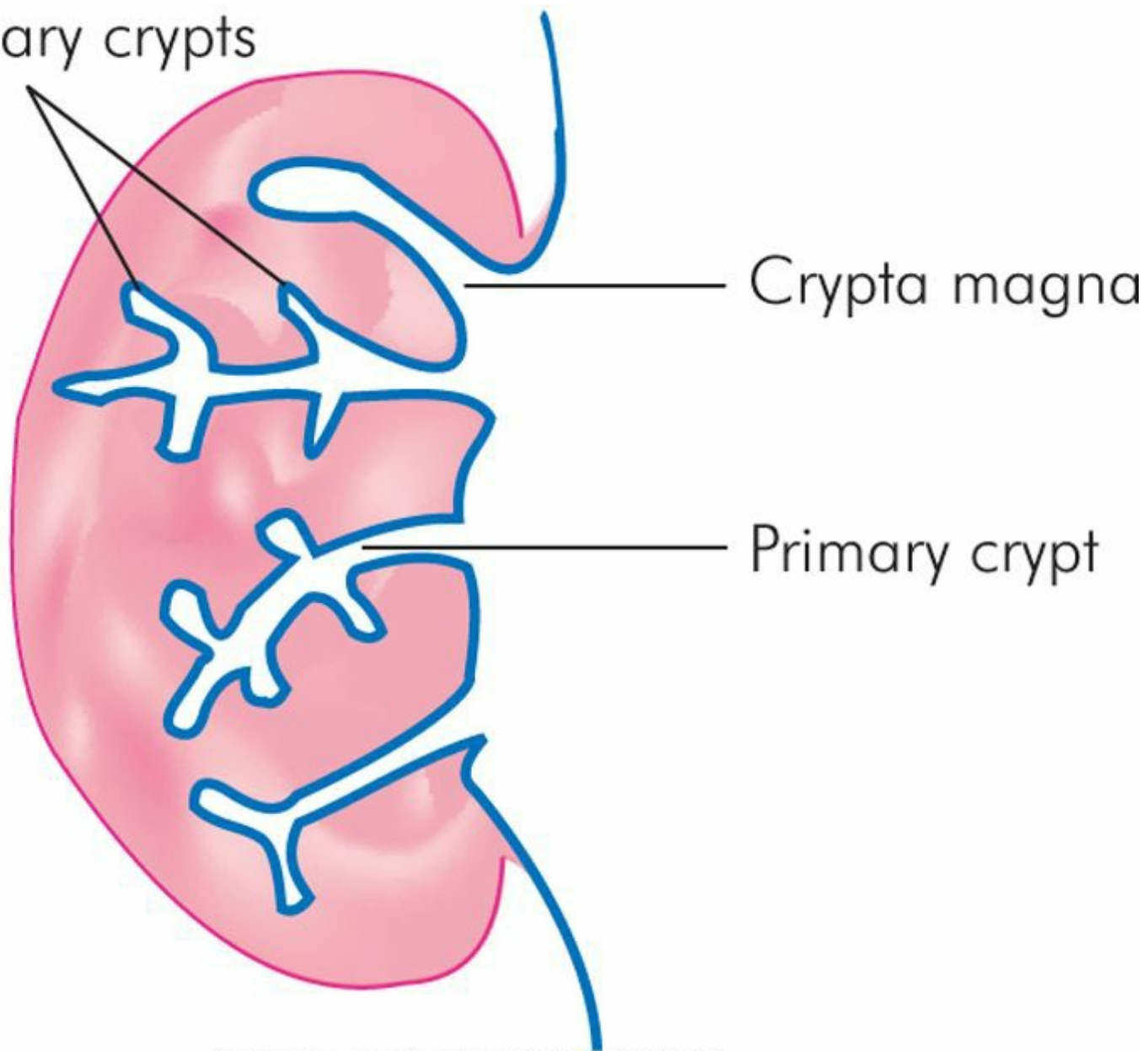
### APPLIED ANATOMY OF PALATINE (FAUCIAL) TONSILS

Palatine tonsils are two in number. Each tonsil is an ovoid mass of lymphoid tissue situated in the lateral wall of oropharynx between the anterior and posterior pillars. Actual size of the tonsil is bigger than the one that appears from its surface as parts of tonsil extend upwards into the soft palate, downwards into the base of tongue and anteriorly into palatoglossal arch. A tonsil presents two surfaces-a medial and a lateral, and two poles-an upper and a lower.

#### **Medial surface**

of the tonsil is covered by non-keratinising stratified squamous epithelium which dips into the substance of tonsil in the form of crypts. Openings of 12-15 crypts can be seen on the medial surface of the tonsil. One of the crypts, situated near the upper part of tonsil is very large and deep and is called *crypta magna* or *intratonsillar cleft* (Fig. 50.1). It represents the ventral part of second pharyngeal pouch. From the main crypts arise the secondary crypts, within the substance of tonsil. Crypts may be filled with cheesy material consisting of epithelial cells, bacteria and food debris which can be expressed by pressure over the anterior pillar.

### Secondary crypts



Dhingra: Diseases of Ear Nose and Throat, 5th Edition  
Copyright © 2010 Elsevier. All rights reserved.

Figure 50.1 Primary and secondary crypts of tonsils.

#### **Lateral surface**

of the tonsil presents a well-defined fibrous capsule. Between the capsule and the bed of tonsil is the loose areolar tissue which makes it easy to dissect the tonsil in the plane during tonsillectomy. It is also the site for collection of pus in peritonsillar abscess. Some fibres of palatoglossus and palatopharyngeus muscles are attached to the capsule of the tonsil.

### **Upper pole**

of the tonsil extends into soft palate. Its medial surface is covered by a *semilunar fold*, extending between anterior and posterior pillars and enclosing a potential space called *supratonsillar fossa*.

### **Lower pole**

of the tonsil is attached to the tongue. A *triangular fold* of mucous membrane extends from anterior pillar to the anteroinferior part of tonsil and encloses a space called *anterior tonsillar space*. The tonsil is separated from the tongue by a sulcus called tonsillolingual sulcus which may be the seat of carcinoma.

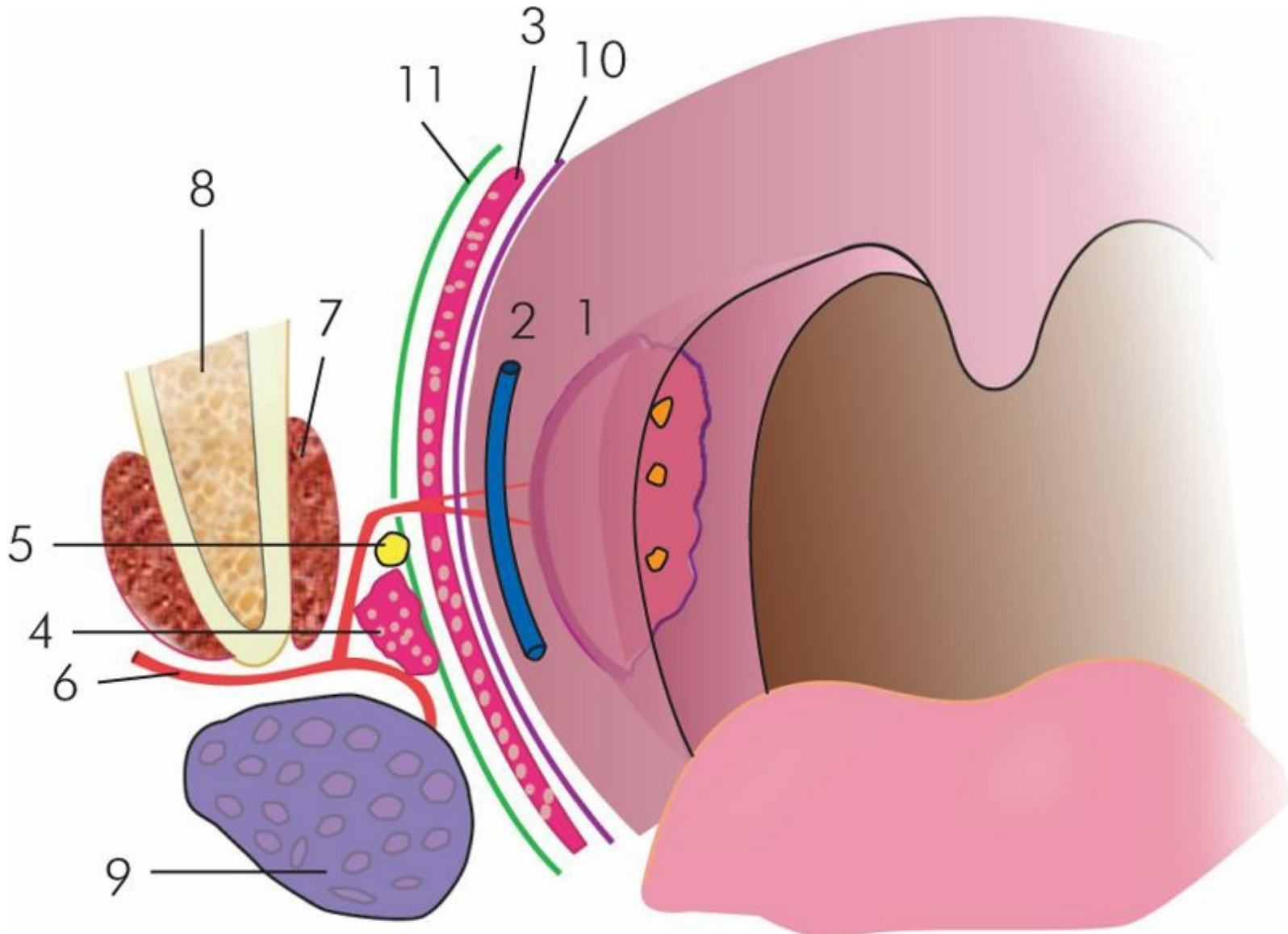
### **Bed of the tonsil**

It is formed by the superior constrictor and styloglossus muscles. The glossopharyngeal nerve and styloid process, if enlarged, may lie in relation to the lower part of tonsillar fossa. Both these structures can be surgically approached through the tonsil bed after tonsillectomy. Outside the superior constrictor, tonsil is related to the facial artery, submandibular salivary gland, posterior belly of digastric muscle, medial pterygoid muscle and the angle of mandible (Fig. 50.2).

# Blood Supply

The tonsil is supplied by five arteries (Fig. 50.3).

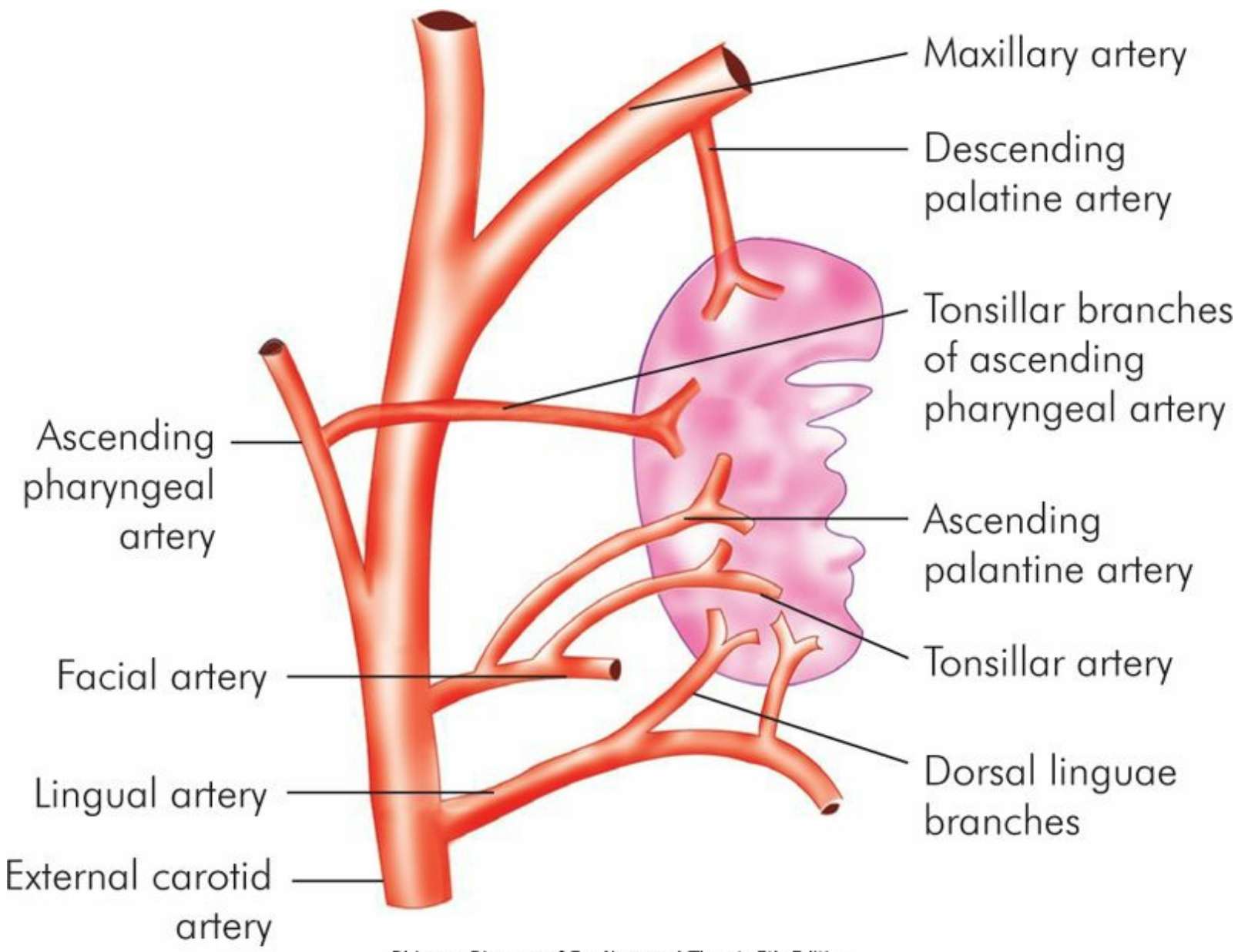
- 1. Tonsillar branch of facial artery. This is the main artery.
- 2. Ascending pharyngeal artery from external carotid.
- 3. Ascending palatine, a branch of facial artery.
- 4. Dorsal linguae branches of lingual artery.
- 5. Descending palatine branch of maxillary artery.



Dhingra: Diseases of Ear Nose and Throat, 5th Edition  
Copyright © 2010 Elsevier. All rights reserved.

Figure 50.2 Relations of tonsil. Tonsil is related laterally to its capsule (1), loose areolar tissue containing paratonsillar vein (2), superior constrictor muscle (3), styloglossus (4), glossopharyngeal nerve (5), facial artery (6), medial pterygoid muscle (7), angle of mandible (8) and submandibular salivary gland (9), pharyngobasilar fascia (10), buccopharyngeal fascia (11).





Dhingra: Diseases of Ear Nose and Throat, 5th Edition  
 Copyright © 2010 Elsevier. All rights reserved.

Figure 50.3 Arterial supply of tonsil.

## Venous Drainage

Veins from the tonsils drain into paratonsillar vein which joins the common facial vein and pharyngeal venous plexus.

## Lymphatic Drainage

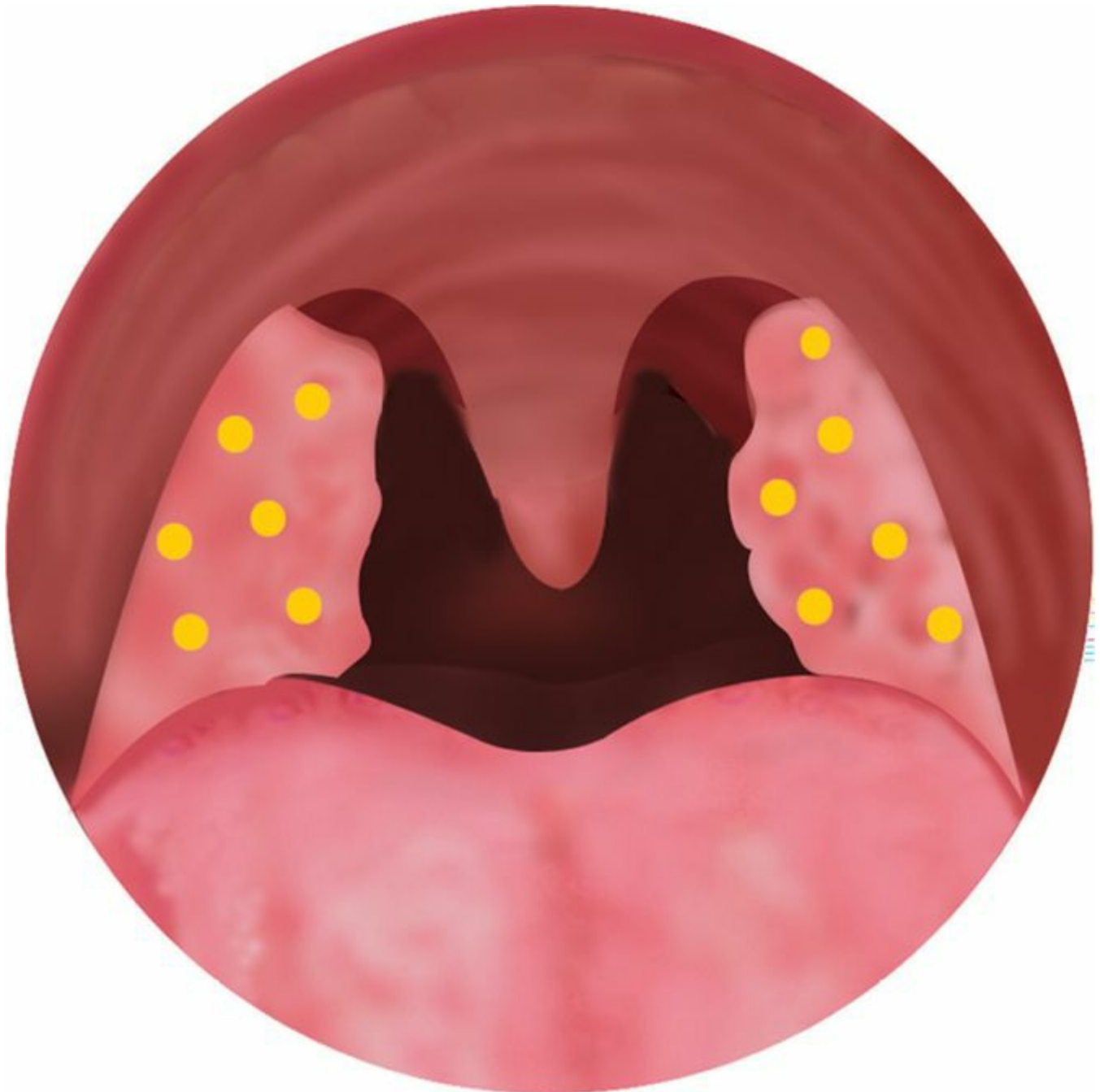
Lymphatics from the tonsil pierce the superior constrictor and drain into upper deep cervical nodes particularly the jugulodigastric (tonsillar) node situated below the angle of mandible.

## Nerve Supply

Lesser palatine branches of sphenopalatine ganglion (CN V) and glossopharyngeal nerve provide sensory nerve supply.

## Functions of Tonsils

Like other lymphoid masses of Waldeyer's ring, palatine tonsils have a protective role and act as sentinels at the portal of air and food passage. The crypts in tonsils increase the surface area for contact with foreign substances. Tonsils are larger in childhood and gradually diminish near puberty. They are removed when they themselves become the seat of disease.



Dhingra: Diseases of Ear Nose and Throat, 5th Edition  
Copyright © 2010 Elsevier. All rights reserved.

Figure 50.4 Acute follicular tonsillitis.

Primarily, the tonsil consists of (a) surface epithelium which is continuous with the oropharyngeal lining; (b) crypts which are tube-like invaginations from the surface epithelium; and (c) the lymphoid tissue. Acute infections of tonsil may involve these components and are thus classified as:

- 1. *Acute catarrhal or superficial tonsillitis*. Here tonsillitis is a part of generalised pharyngitis and is mostly seen in viral infections.
- 2. *Acute follicular tonsillitis*. Infection spreads into the crypts which become filled with purulent material, presenting at the openings of crypts as yellowish spots (Fig. 50.4).
- 3. *Acute parenchymatous tonsillitis*. Here tonsil substance is affected. Tonsil is uniformly enlarged and red.
- 4. *Acute membranous tonsillitis*. It is a stage ahead of acute follicular tonsillitis when exudation from the crypts coalesces to form a membrane on the surface of tonsil.

## Aetiology

Acute tonsillitis often affects school-going children, but also affects adults. It is rare in infants and in persons who are above 50 years of age.

*Haemolytic streptococcus* is the most commonly infecting organism. Other causes of infection may be *staphylococci*, *pneumococci* or *H. influenzae*. These bacteria may primarily infect the tonsil or may be secondary to a viral infection.

# Symptoms

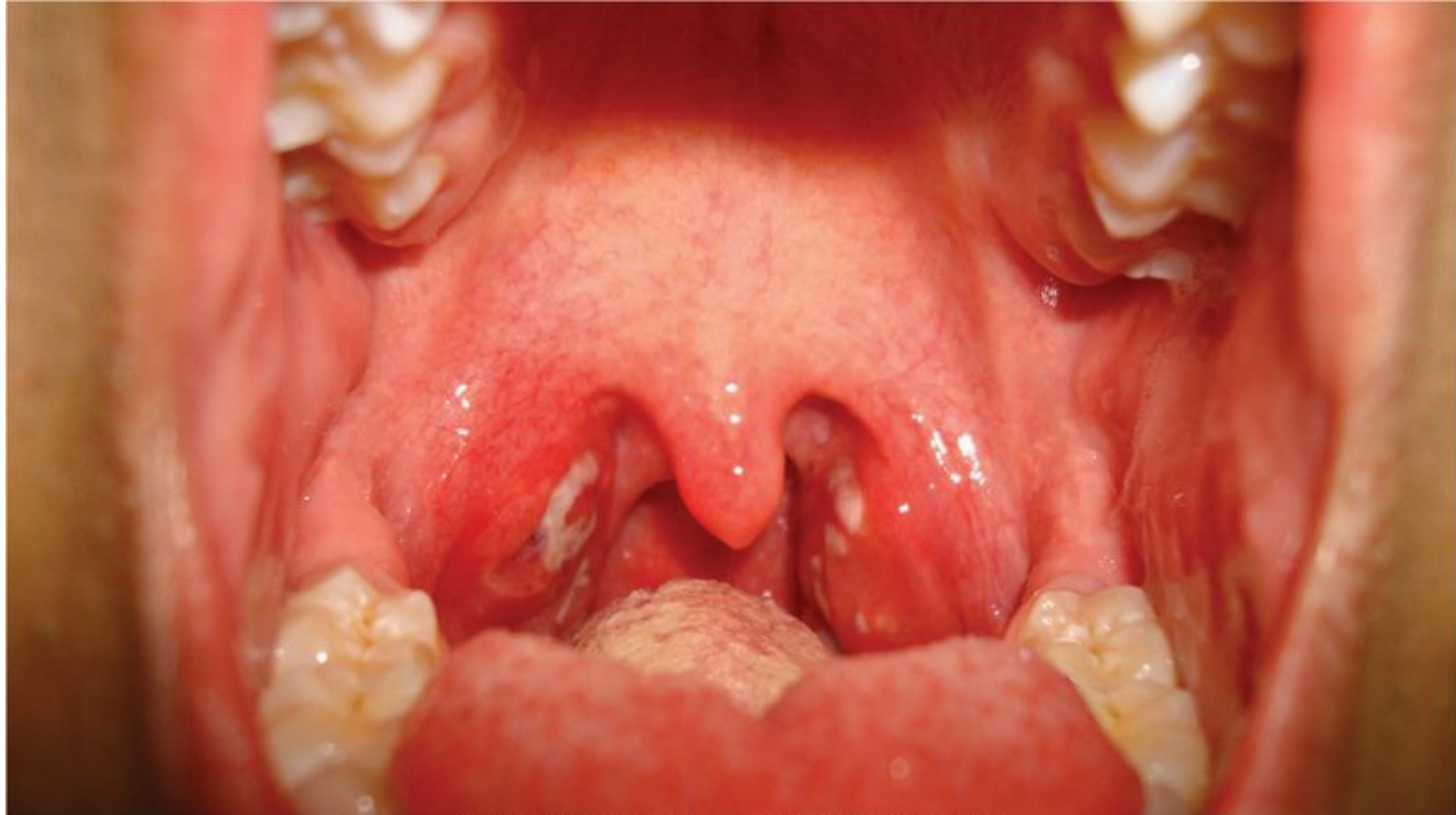
The symptoms vary with severity of infection. The predominant symptoms are:

- **1. Sore throat.**
- **2. Difficulty in swallowing.** The child may refuse to eat anything due to local pain.
- **3. Fever.** It may vary from 38 to 40°C and may be associated with chills and rigors. Sometimes, a child presents with an unexplained fever and it is only on examination that an acute tonsillitis is discovered.
- **4. Earache.** It is either referred pain from the tonsil or the result of acute otitis media which may occur as a complication.
- **5. Constitutional symptoms.** They are usually more marked than seen in simple pharyngitis and may include headache, general body aches, malaise and constipation. There may be abdominal pain due to mesenteric lymphadenitis simulating a clinical picture of acute appendicitis.



## Signs

- 1. Often the breath is foetid and tongue is coated.
- 2. There is hyperaemia of pillars, soft palate and uvula.
- 3. Tonsils are red and swollen with yellowish spots of purulent material presenting at the opening of crypts (*acute follicular tonsillitis*) or there may be a whitish membrane on the medial surface of tonsil which can be easily wiped away with a swab (*acute membranous tonsillitis*, Fig. 50.5). The tonsils may be enlarged and congested so much so that they almost meet in the midline along with some oedema of the uvula and soft palate (*acute parenchymatous tonsillitis*).
- 4. The jugulodigastric lymph nodes are enlarged and tender.



Dhingra: Diseases of Ear Nose and Throat, 5th Edition  
Copyright © 2010 Elsevier. All rights reserved.

Figure 50.5 Acute follicular tonsillitis. Note pus beads on the surface of left tonsil. On the right pus beads have coalesced together to form a membrane.

## Treatment

- **1.** *Patient is put to bed* and encouraged to take plenty of fluids.
- **2.** *Analgesics* (aspirin or paracetamol) are given according to the age of the patient to relieve local pain and bring down the fever.
- **3.** *Antimicrobial therapy.* Most of the infections are due to *streptococcus*, and penicillin is the drug of choice. Patients allergic to penicillin can be treated with erythromycin. Antibiotics should be continued for 7-10 days.

## Complications

- **1. Chronic tonsillitis** with recurrent acute attacks. This is due to incomplete resolution of acute infection. Chronic infection may persist in lymphoid follicles of the tonsil in the form of microabscesses.
- **2. Peritonsillar abscess.**
- **3. Parapharyngeal abscess.**
- **4. Cervical abscess** due to suppuration of jugulodigastric lymph nodes.
- **5. Acute otitis media.** Recurrent attacks of acute otitis media may coincide with recurrent tonsillitis.
- **6. Rheumatic fever.** Often seen in association with tonsillitis due to Group A beta-haemolytic *streptococci*.
- **7. Acute glomerulonephritis.** Rare these days.
- **8. Subacute bacterial endocarditis.** Acute tonsillitis in a patient with valvular heart disease may be complicated by endocarditis. It is usually due to *Streptococcus viridans* infection.

# Differential Diagnosis of Membrane Over the Tonsil

- **1. Membranous tonsillitis.** It occurs due to pyogenic organisms. An exudative membrane forms over the medial surface of the tonsils, along with the features of acute tonsillitis.
- **2. Diphtheria.** Unlike acute tonsillitis which is abrupt in onset, diphtheria is slower in onset with less local discomfort, the membrane in diphtheria extends beyond the tonsils, on to the soft palate and is dirty grey in colour. It is adherent and its removal leaves a bleeding surface. Urine may show albumin. Smear and culture of throat swab will reveal *Corynebacterium diphtheriae*.
- **3. Vincent's angina.** It is insidious in onset with less fever and less discomfort in throat. Membrane, which usually forms over one tonsil, can be easily removed revealing an irregular ulcer on the tonsil. Throat swab will show both the organisms typical of disease, namely fusiform bacilli and spirochaetes.
- **4. Infectious mononucleosis.** This often affects young adults. Both tonsils are very much enlarged, congested and covered with membrane. Local discomfort is marked. Lymph nodes are enlarged in the posterior triangle of neck along with splenomegaly. Attention to disease is attracted because of failure of the antibiotic treatment. Blood smear may show more than 50% lymphocytes, of which about 10% are atypical. White cell count may be normal in the first week but rises in the second week. Paul-Bunnell test (mono test) will show high titre of heterophil antibody.
- **5. Agranulocytosis.** It presents with ulcerative necrotic lesions not only on the tonsils but elsewhere in the oropharynx. Patient is severely ill. In acute fulminant form, total leucocytic count is decreased to < 2000/cu mm or even as low as 50/cu mm and polymorph neutrophils may be reduced to 5% or less. In chronic or recurrent form, total count is reduced to 2000/cu mm with less marked granulocytopenia.
- **6. Leukaemia.** In children, 75% of leukaemias are acute lymphoblastic and 25% acute myelogenous or chronic, while in adults 20% of acute leukaemias are lymphocytic and 80% non-lymphocytic. Peripheral blood shows TLC > 100,000/cu mm. It may be normal or less than normal. Anaemia is always present and may be progressive. Blasts cells are seen on examination of the bone marrow.
- **7. Aphthous ulcers.** They may involve any part of oral cavity or oropharynx. Sometimes, it is solitary and may involve the tonsil and pillars. It may be small or quite large and alarming. It is very painful.
- **8. Malignancy tonsil (see page 284).**
- **9. Traumatic ulcer.** Any injury to oropharynx heals by formation of a membrane. Trauma to the tonsil area may occur accidentally when hit with a tooth brush, a pencil held in mouth or fingering in the throat. Membrane appears within 24 hours.
- **10. Candidal infection of tonsil.**

Diagnosis of ulceromembranous lesion of throat thus requires:

- **1. History.**
- **2. Physical examination.**
- **3. Total and differential counts (for agranulocytosis, leukaemia, neutropenia, infectious mononucleosis).**
- **4. Blood smear (for atypical cells).**
- **5. Throat swab and culture (for pyogenic bacteria), Vincent's angina, diphtheria candidal infection.**
- **6. Bone marrow aspiration or needle biopsy.**
- **7. Other tests. Paul-Bunnell or mono spot test and biopsy of the lesion.**

# FAUCIAL DIPHTHERIA

## Aetiology

It is an acute specific infection caused by the Gram-positive bacillus, *Corynebacterium diphtheriae*. It spreads by droplet infection. Incubation period is 2-6 days. Some persons are "carriers" of this disease, i.e. they harbour organisms in their throat but have no symptoms.

## Clinical Features

Children are affected more often though no age group is immune. Oropharynx is commonly involved and the larynx and nasal cavity may also be affected.

In the oropharynx, a greyish white membrane forms over the tonsils and spreads to the soft palate and posterior pharyngeal wall. It is quite tenacious and causes bleeding when removed. Cervical lymph nodes, particularly the jugulodigastric, become enlarged and tender, sometimes presenting a "bull-neck" appearance. Patient is ill and toxæmic but fever seldom rises above 38°C.

## Complications

Exotoxin produced by *C. diphtheriae* is toxic to the heart and nerves. It causes *myocarditis*, *cardiac arrhythmias* and *acute circulatory failure*.

Neurological complications usually appear a few weeks after infection and include *paralysis of soft palate*, *diaphragm* and *ocular muscles*.

---

page 274

page 275

In the larynx, diphtheritic membrane may cause airway obstruction.

## Treatment

Treatment of diphtheria is started on clinical suspicion without waiting for the culture report. Aim is to neutralise the free exotoxin still circulating in the blood and to kill the organisms producing this exotoxin. Dose of antitoxin is based on the site involved and the duration and severity of disease. It is 20,000 to 40,000 units for diphtheria in less than 48 hours, or when the membrane is confined to the tonsils only; and 80,000 to 120,000 units, if disease has lasted longer than 48 hours, or the membrane is more extensive. Antitoxin is given by i.v. infusion in saline in about 60 minutes. Sensitivity to horse serum should be tested by conjunctival or intracutaneous test with diluted antitoxin, and adrenaline should be at hand for any immediate hypersensitivity. In the presence of hypersensitivity reaction, desensitization should be done.

Antibiotics used are benzyl penicillin 600 mg 6-hourly for 7 days. Erythromycin is used in penicillin-sensitive individuals (500 mg 6 hourly orally).



# CHRONIC TONSILLITIS

## Aetiology

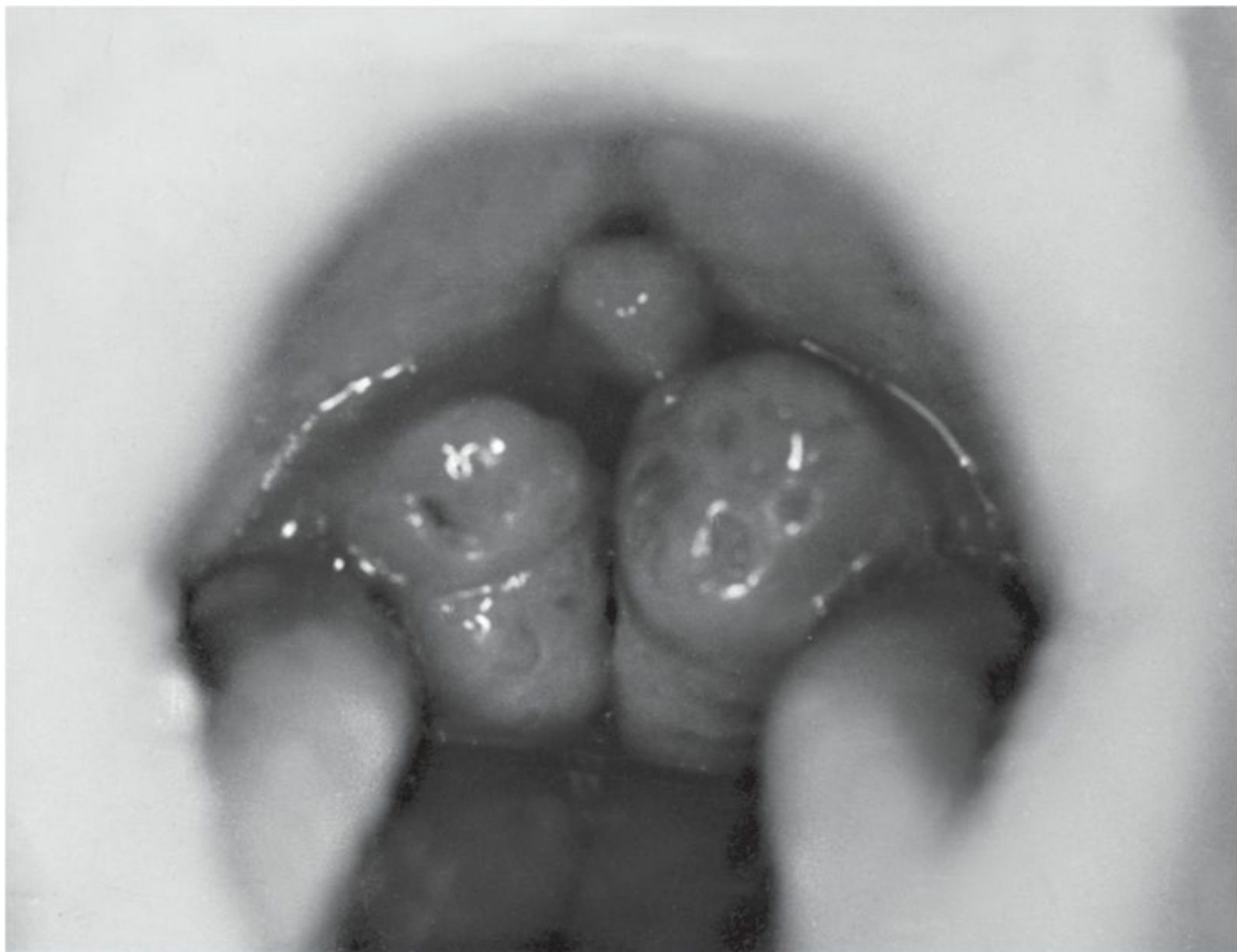
- **1.** It may be a complication of acute tonsillitis. Pathologically, microabscesses walled off by fibrous tissue have been seen in the lymphoid follicles of the tonsils.
- **2.** Subclinical infections of tonsils without an acute attack.
- **3.** Mostly affects children and young adults. Rarely occurs after 50 years.
- **4.** Chronic infection in sinuses or teeth may be a predisposing factor.

## Types

*Chronic follicular tonsillitis.* Here tonsillar crypts are full of infected cheesy material which shows on the surface as yellowish spots.

*Chronic parenchymatous tonsillitis.* There is hyperplasia of lymphoid tissue. Tonsils are very much enlarged and may interfere with speech, deglutition and respiration (Fig. 50.6). Attacks of sleep apnoea may occur. Long-standing cases develop features of cor pulmonale.

*Chronic fibroid tonsillitis.* Tonsils are small but infected, with history of repeated sore throats.



Dhingra: Diseases of Ear Nose and Throat, 5th Edition  
Copyright © 2010 Elsevier. All rights reserved.

Figure 50.6 Parenchymatous tonsillitis. The two tonsils are almost touching each other causing problems of deglutition, speech and respiration.

## Clinical Features

- 1. Recurrent attacks of sore throat or acute tonsillitis.
- 2. Chronic irritation in throat with cough.
- 3. Bad taste in mouth and foul breath (halitosis) due to pus in crypts.
- 4. Thick speech, difficulty in swallowing and choking spells at night (when tonsils are large and obstructive).

## Examination

- 1. Tonsils may show varying degree of enlargement. Sometimes they meet in the midline (chronic parenchymatous type).
- 2. There may be yellowish beads of pus on the medial surface of tonsil (chronic follicular type).
- 3. Tonsils are small but pressure on the anterior pillar expresses frank pus or cheesy material (chronic fibroid type).
- 4. Flushing of anterior pillars compared to the rest of the pharyngeal mucosa is an important sign of chronic tonsillar infection.
- 5. Enlargement of jugulodigastric lymph nodes is a reliable sign of chronic tonsillitis. During acute attacks, the nodes enlarge further and become tender.

- **1.** Conservative treatment consists of attention to general health, diet, treatment of co-existent infection of teeth, nose and sinuses.
- **2.** Tonsillectomy is indicated when tonsils interfere with speech, deglutition and respiration or cause recurrent attacks (see Chapter 91).

# Complications

- 1. Peritonsillar abscess.
- 2. Parapharyngeal abscess.
- 3. Intratonsillar abscess.
- 4. Tonsilloliths.
- 5. Tonsillar cyst.
- 6. Focus of infection in rheumatic fever, acute glomerulonephritis, eye and skin disorders.

*Tonsilloliths (calculus of the tonsil)*. It is seen in chronic tonsillitis when its crypt is blocked with retention of debris. Inorganic salts of calcium and magnesium are then deposited leading to formation of a stone. It may gradually enlarge and then ulcerate through the tonsil.

Tonsilloliths are more often seen in adults and give rise to local discomfort or foreign body sensation. They are easily diagnosed by palpation or gritty feeling on probing. Treatment is simple removal of the stone or tonsillectomy, if that be indicated for associated sepsis or for the deeply set stone which cannot be removed.

*Intratonsillar abscess*. It is accumulation of pus within the substance of tonsil. It usually follows blocking of the crypt opening in acute follicular tonsillitis. There is marked local pain and dysphagia. Tonsil appears swollen and red. Treatment is administration of antibiotics and drainage of the abscess if required; later tonsillectomy should be performed.

*Tonsillar cyst*. It is due to blockage of a tonsillar crypt and appears as a yellowish swelling over the tonsil. Very often it is symptomless. It can be easily drained.

## DISEASES OF LINGUAL TONSILS

- **1. Acute lingual tonsillitis** Acute infection of a lingual tonsil gives rise to unilateral dysphagia and feeling of lump in the throat. On examination with a laryngeal mirror, lingual tonsil may appear enlarged and congested, sometimes studded with follicles like the ones seen in acute follicular tonsillitis. Cervical lymph nodes may be enlarged. Treatment is by antibiotics.
- **2. Hypertrophy of lingual tonsils** Mostly, it is a compensatory hypertrophy of lymphoid tissue in response to repeated infections in tonsillectomised patients. Usual complaints are discomfort on swallowing, feeling of lump in the throat, dry cough and thick voice. Mirror examination of the base of tongue will show enlargement of lingual tonsils, sometimes associated with dilated veins over it. Treatment is conservative. Sometimes, diathermy coagulation or excision of lingual tonsils has to be done. These days they are excised by laser surgery.
- **3. Abscess of lingual tonsil** It is a rare condition but can follow acute lingual tonsillitis. Symptoms are severe unilateral dysphagia, pain in the tongue, excessive salivation and some degree of trismus. Protrusion of the tongue is painful. Jugulodigastric nodes will be enlarged and tender. It is a potentially dangerous condition as laryngeal oedema can easily follow. Diagnosis is made by mirror examination and palpation of the base of tongue. Treatment is by antibiotics, analgesics, proper hydration and incision and drainage of the abscess.

## 51 Head and Neck Space Infections

### PAROTID ABSCESS

It is suppurative of the parotid space. Deep cervical fascia splits into two layers, superficial and deep, to enclose the parotid gland and its associated structures. Parotid space lies deep to its superficial layer.

*Contents* of parotid space include parotid gland and its associated parotid lymph nodes, facial nerve, external carotid artery and retromandibular vein. Fascial layer is very thick superficially but very thin on the deep side of the parotid gland where parotid abscess can burst to form a parapharyngeal abscess and thence spread to the mediastinum.



## Aetiology

Dehydration, particularly in post-surgical cases and debilitated patients, with stasis of salivary flow is the predisposing cause. Infection from the oral cavity travels via the Stenson's duct to invade the parotid gland. Multiple small abscesses may form in the parenchyma. They may then coalesce to form a single abscess.

## Bacteriology

Most common organism is *Staph. aureus* but *Streptococci*, anaerobic organisms and rarely the gram negative organisms have been cultured.

## Clinical Features

Usually follows 5-7 days after operation. There is swelling, redness, indurations and tenderness in the parotid area and at the angle of mandible.

Parotid abscess is usually unilateral, but bilateral abscesses may occur. Fluctuation is difficult to elicit due to thick capsule. Opening of the Stenson's duct becomes congested and may exude pus on pressure over the parotid. Patient is toxic, running high fever and dehydrated.

## Diagnosis

Diagnosis of the abscess can be made by ultrasound or CT scan. More than one loculi of pus may be seen. Aspiration of abscess can be done for culture and sensitivity of the causative organisms.

## Treatment

Correct the dehydration, improve oral hygiene and promote salivary flow. Intravenous antibiotics are instituted.

Surgical drainage under local or general anaesthesia is carried out by a preauricular incision as employed for parotidectomy. Skin flap is raised to expose surface of the gland, and the abscess or abscesses are bluntly opened working parallel to the branches of the Vllth nerve. Skin incision is loosely approximated over a drain and allowed to heal by secondary intention.

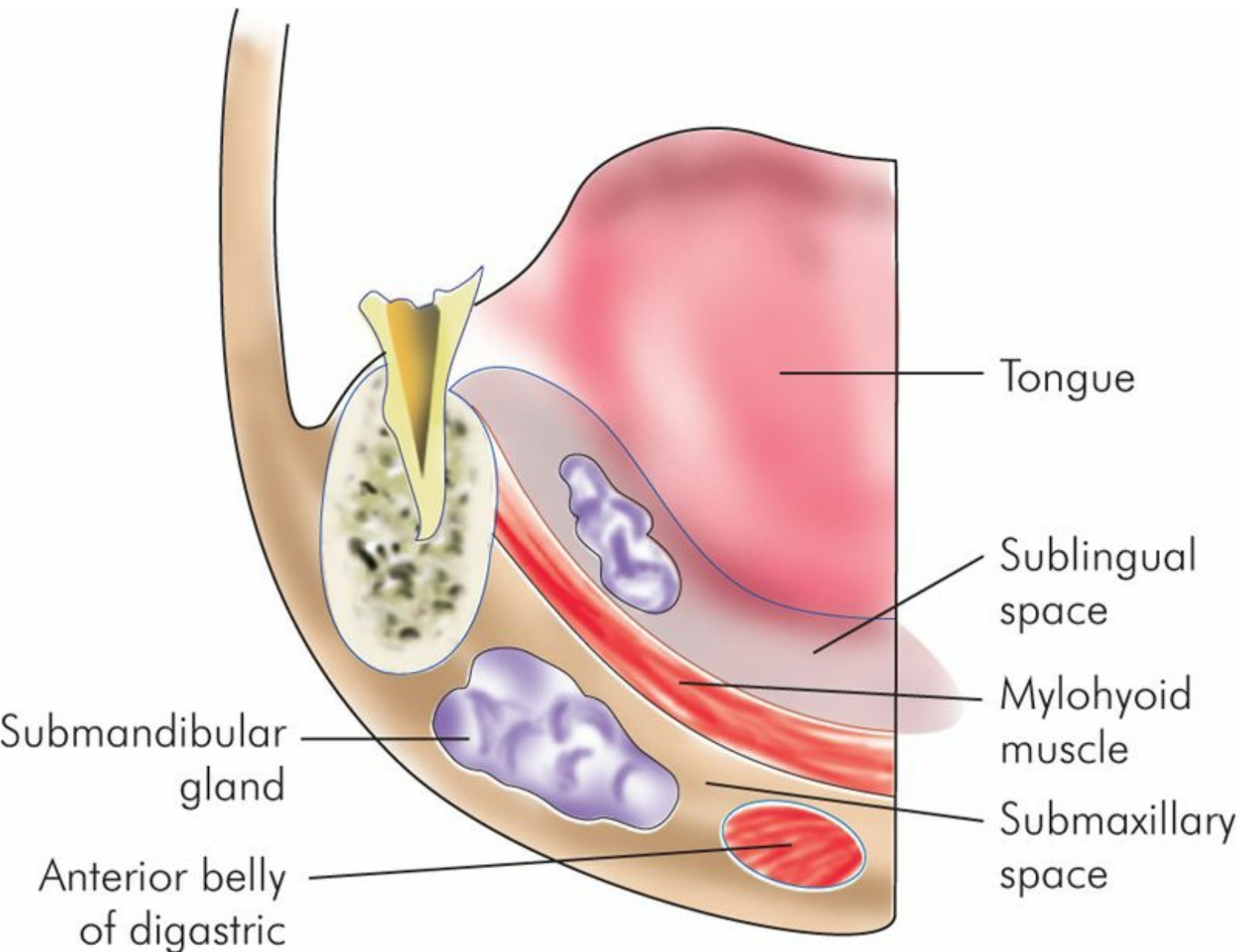
# LUDWIG'S ANGINA

## Applied Anatomy

Submandibular space lies between mucous membrane of the floor of mouth and tongue on one side and superficial layer of deep cervical fascia extending between the hyoid bone and mandible on the other (Fig. 51.1). It is divided into two compartments by the mylohyoid muscle:

- (a) *sublingual* compartment (above the mylohyoid)
- (b) *submaxillary* and submental compartment (below the mylohyoid).

page 277  
page 278



Dhingra: Diseases of Ear Nose and Throat, 5th Edition  
Copyright © 2010 Elsevier. All rights reserved.

Figure 51.1 Anatomy of submandibular space.

The two compartments are continuous around the posterior border of mylohyoid muscle.

Ludwig's angina is infection of submandibular space.

## Aetiology

- **1. Dental infections.** They account for 80% of the cases. Roots of premolars often lie above the attachment of mylohyoid and cause sublingual space infection while roots of the molar teeth extend up to or below the mylohyoid line and primarily cause submaxillary space infection (Fig. 51.2).
- **2. Submandibular sialadenitis, injuries of oral mucosa** and fractures of the mandible account for other cases.

## Bacteriology

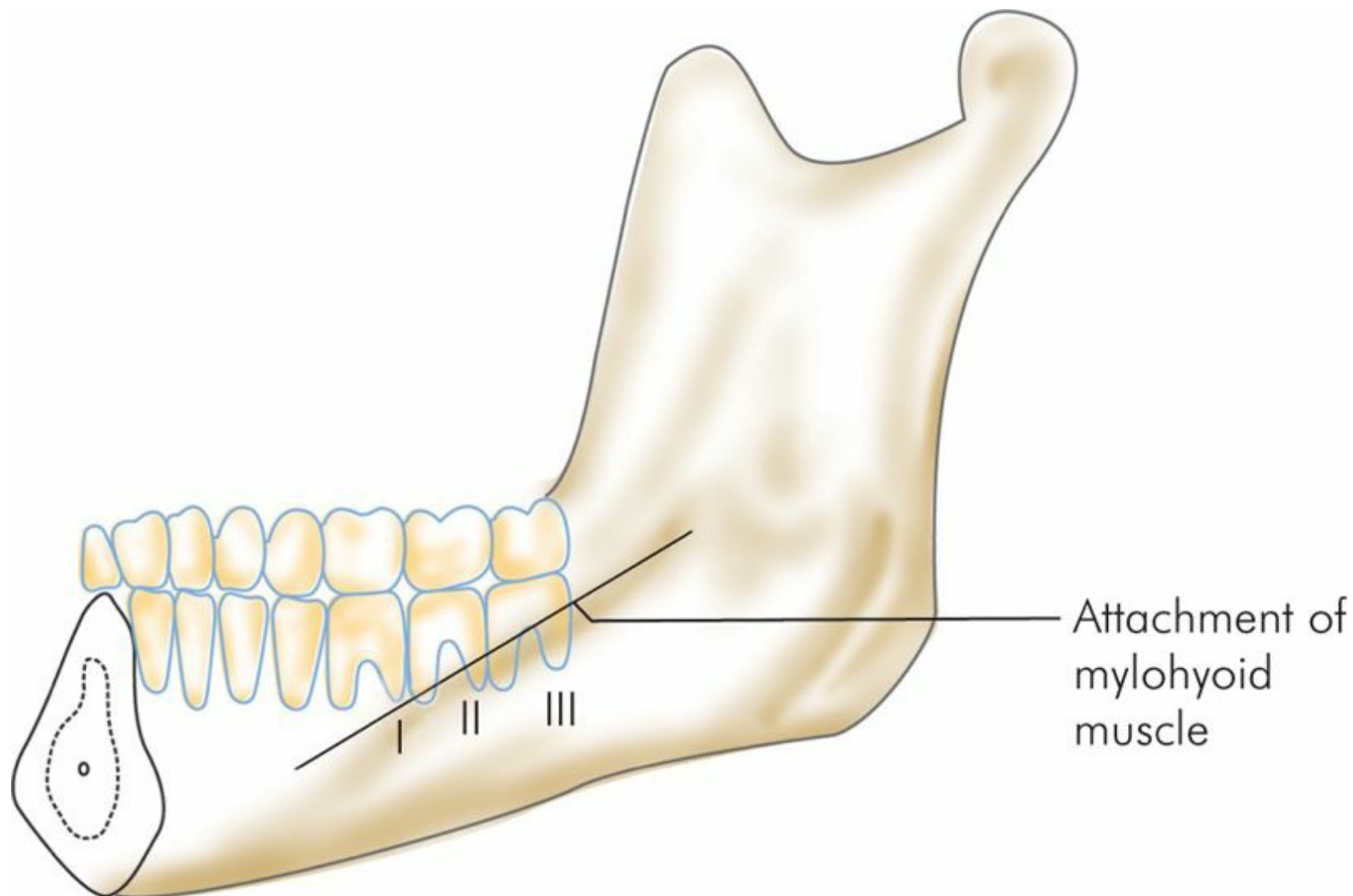
Mixed infections involving both aerobes and anaerobes are common. Alpha haemolytic *Streptococci*, *Staphylococci*, and bacteroides groups are common. Rarely *H. influenzae*, *Esch. coli* and *Pseudomonas* are seen.



## Clinical Features

There is marked difficulty in swallowing (odynophagia) with varying degrees of trismus.

When infection is localised to the sublingual space, structures in the floor of mouth are swollen and tongue seems to be pushed up and back.



Dhingra: Diseases of Ear Nose and Throat, 5th Edition  
Copyright © 2010 Elsevier. All rights reserved.

Figure 51.2 Roots of molar teeth project below, and those of premolars above the attachment of mylohyoid muscle.

When infection spreads to submaxillary space, submental and submandibular regions become swollen and tender, and impart woody-hard feel. Usually, there is cellulitis of the tissues rather than frank abscess. Tongue is progressively pushed upwards and backwards threatening the airway. Laryngeal oedema may appear.

## Treatment

- **1.** Systemic antibiotics.
- **2.** Incision and drainage of abscess.
  - (a) Intraoral-if infection is still localised to sublingual space.
  - (b) External-if infection involves submaxillary space. A transverse incision extending from one angle of mandible to the other is made with vertical opening of midline musculature of tongue with a blunt haemostat. Very often it is serous fluid rather than frank pus that is encountered.
- **3.** Tracheostomy, if airway is endangered.

## Complications

- 1. Spread of infection to parapharyngeal and retropharyngeal spaces and thence to the mediastinum.
- 2. Airway obstruction due to laryngeal oedema, or swelling and pushing back of the tongue.
- 3. Septicaemia.
- 4. Aspiration pneumonia.

## **PERITONSILLAR ABSCESS (QUINSY)**

It is a collection of pus in the peritonsillar space which lies between the capsule of tonsil and the superior constrictor muscle.

## Aetiology

Peritonsillar abscess usually follows acute tonsillitis though it may arise de novo without previous history of sore throats. First, one of the tonsillar crypts, usually the crypta magna, gets infected and sealed off. It forms an intratonsillar abscess which then bursts through the tonsillar capsule to set up *peritonsillitis* and then an abscess.

Culture of pus from the abscess may reveal pure growth of *Strept. pyogenes*, *Staph. aureus* or anaerobic organisms. More often the growth is mixed, with both aerobic and anaerobic organisms.

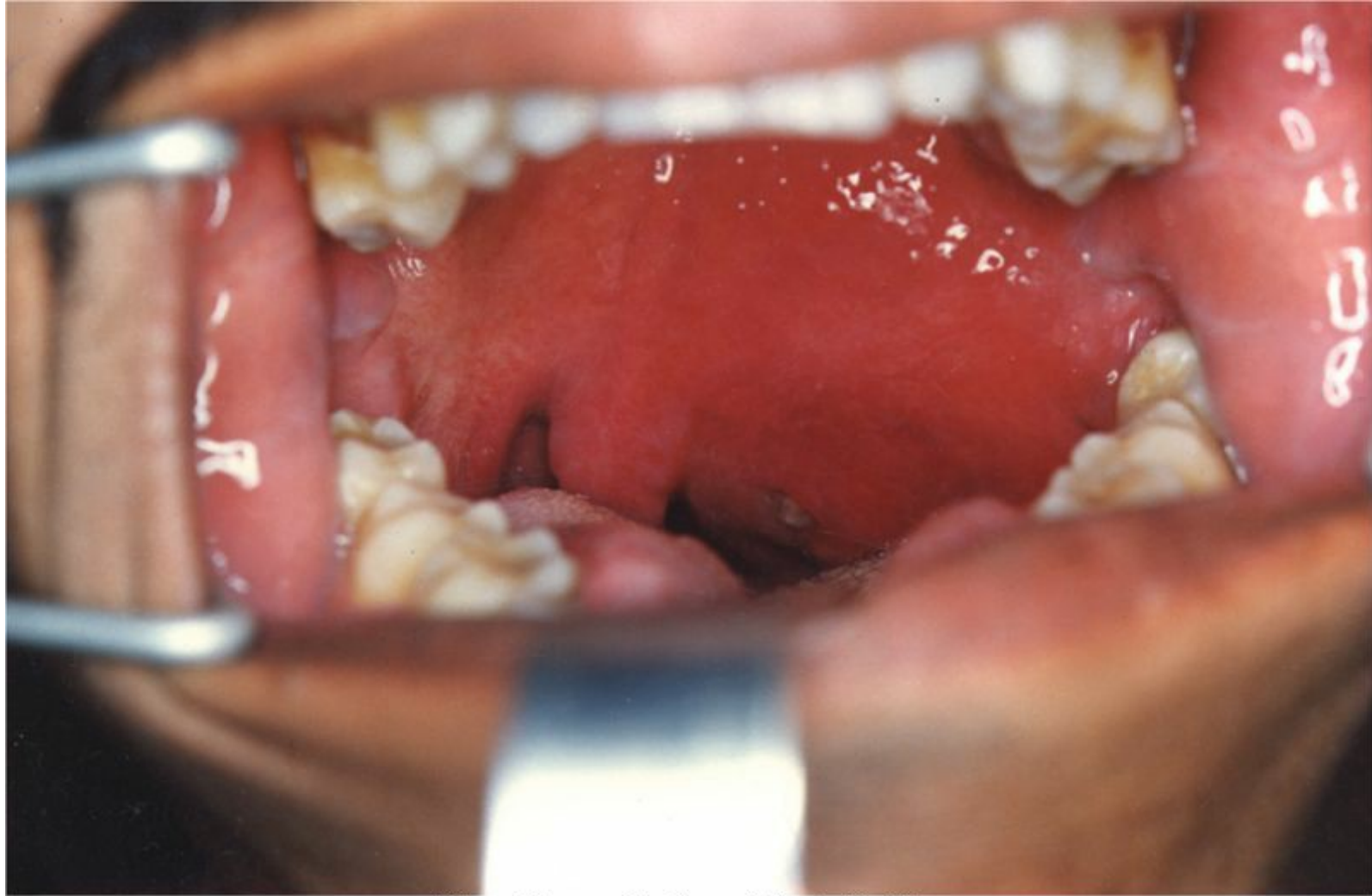# Clinical Features

Peritonsillar abscess mostly affects adults and rarely the children though acute tonsillitis is more common in children. Usually, it is unilateral though occasionally bilateral abscesses are recorded. Clinical features are divided into:

- **1. General.** They are due to septicaemia and resemble any acute infection. They include fever (up to 104°F), chills and rigors, general malaise, body aches, headache, nausea and constipation.
- **2. Local**
  - (i) Severe pain in throat. Usually unilateral.
  - (ii) Odynophagia. It is so marked that the patient cannot even swallow his own saliva which dribbles from the angle of his mouth. Patient is usually dehydrated.
  - (iii) Muffled and thick speech, often called "Hot potato voice".
  - (iv) Foul breath due to sepsis in the oral cavity and poor hygiene.
  - (v) Ipsilateral earache. This is referred pain via CN IX which supplies both the tonsil and the ear.
  - (vi) Trismus due to spasm of pterygoid muscles which are in close proximity to the superior constrictor.

## Examination

- 1. The tonsil, pillars and soft palate on the involved side are congested and swollen. Tonsil itself may not appear enlarged as it gets buried in the oedematous pillars (Fig. 51.3).
- 2. Uvula is swollen and oedematous and pushed to the opposite side.
- 3. Bulging of the soft palate and anterior pillar above the tonsil.
- 4. Mucopus may be seen covering the tonsillar region.
- 5. Cervical lymphadenopathy is commonly seen. This involves jugulodigastric lymph nodes.
- 6. Torticollis. Patient keeps the neck tilted to the side of abscess.



Dhingra: Diseases of Ear Nose and Throat, 5th Edition  
Copyright © 2010 Elsevier. All rights reserved.

Figure 51.3 Peritonsillar abscess left side.

## Treatment

- **1. Hospitalisation.**
- **2. Intravenous fluids** to combat dehydration.
- **3. Antibiotics.** Suitable antibiotics in large i.v. doses to cover both aerobic and anaerobic organisms.
- **4. Analgesics** like paracetamol is given for relief of pain and to lower the temperature. Sometimes, stronger analgesics like pethidine may be required. Aspirin is avoided because of the danger of bleeding.
- **5. Oral hygiene** should be maintained by hydrogen peroxide or saline mouth washes.

The above conservative measures may cure peritonsillitis. If a frank abscess has formed, incision and drainage will be required.

### ***Incision and drainage of abscess***

A peritonsillar abscess is opened at the point of maximum bulge above the upper pole of tonsil or just lateral to the point of junction of anterior pillar with a line drawn through the base of uvula (Fig. 51.4). With the help of a guarded knife, a small stab incision is made and then a sinus forceps inserted to open the abscess. Putting the sinus forceps the following day may also be necessary to drain any reaccumulation.

### ***Interval tonsillectomy***

Tonsils are removed four to six weeks following an attack of quinsy.

### ***Abscess or hot tonsillectomy***

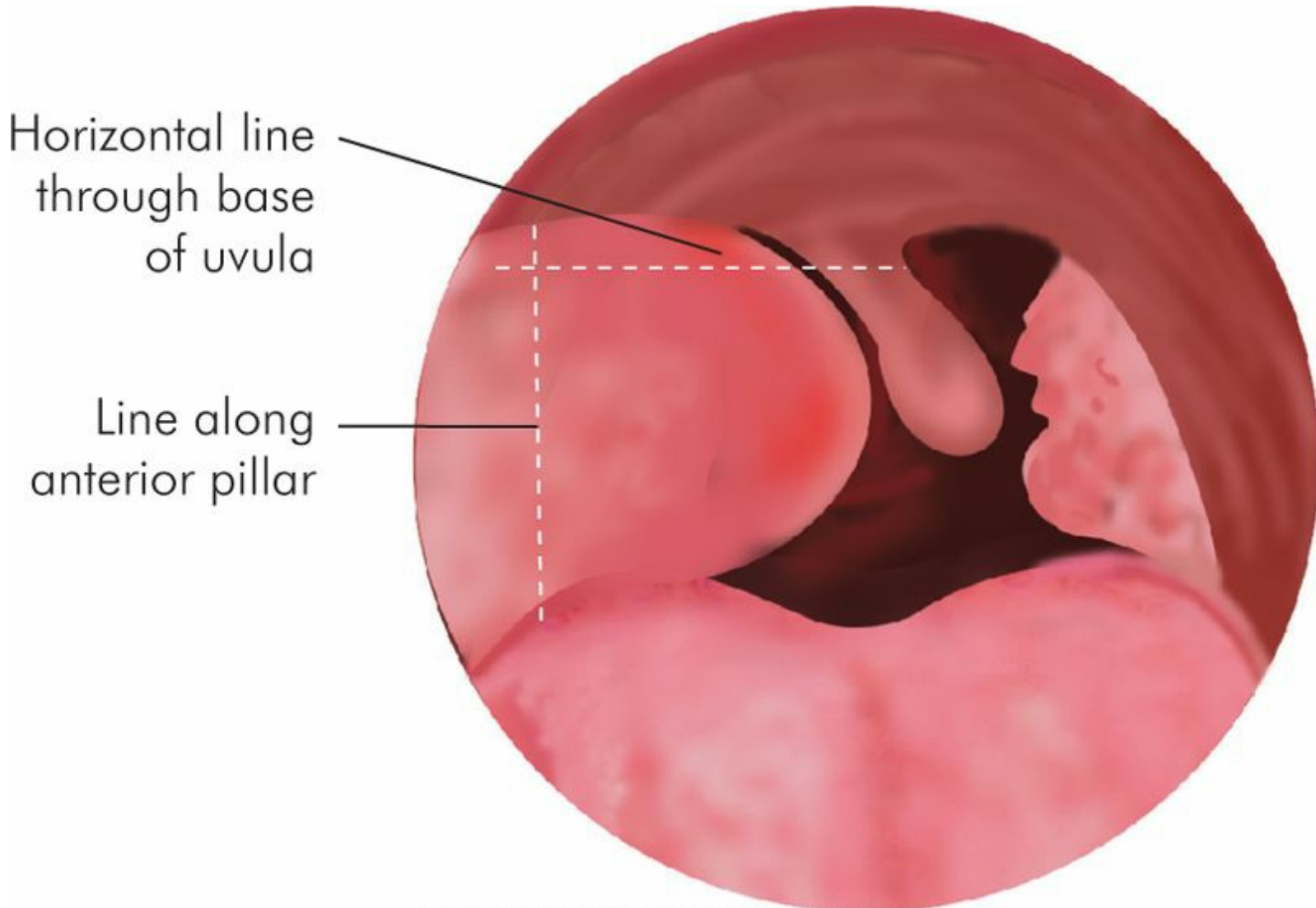
Some people prefer to do 'hot' tonsillectomy instead of incision and drainage. Abscess tonsillectomy has the risk of rupture of the abscess during anaesthesia, and excessive bleeding at the time of operation.



## Complications

Rare with modern therapy.

- 1. Parapharyngeal abscess (a peritonsillar abscess is a potential parapharyngeal abscess).
- 2. Oedema of larynx. Tracheostomy may be required.
- 3. Septicaemia. Other complications like endocarditis, nephritis, brain abscess may occur.
- 4. Pneumonitis or lung abscess. Due to aspiration of pus, if spontaneous rupture of abscess has taken place.
- 5. Jugular vein thrombosis.
- 6. Spontaneous haemorrhage from carotid artery or jugular vein.



Dhingra: Diseases of Ear Nose and Throat, 5th Edition  
Copyright © 2010 Elsevier. All rights reserved.

Figure 51.4 Peritonsillar abscess. Site of drainage is just lateral to the junction of vertical line through anterior pillar and horizontal line through base of uvula.

# RETROPHARYNGEAL ABSCESS

## Applied Anatomy

### ***Retropharyngeal space***

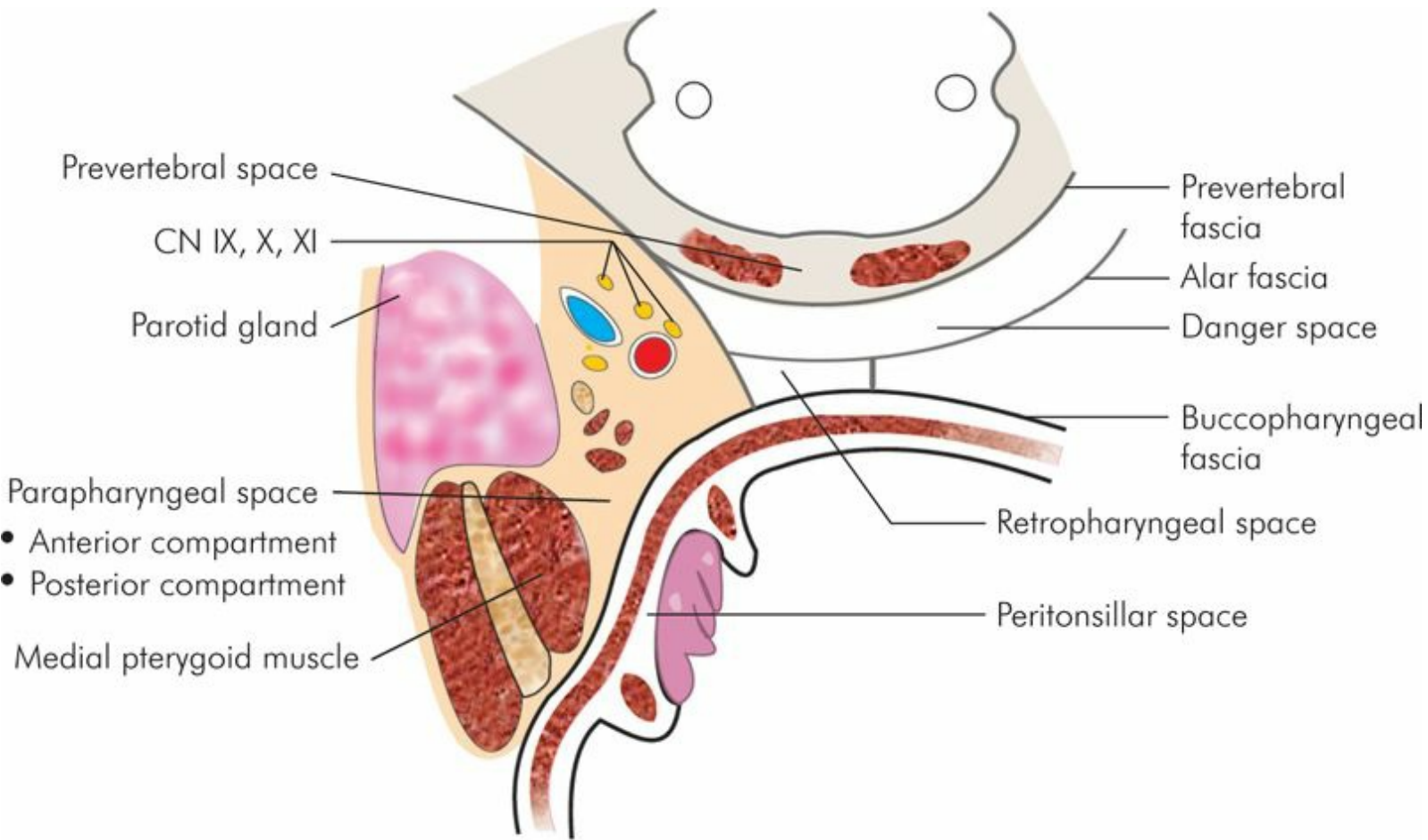
It lies behind the pharynx between the buccopharyngeal fascia covering pharyngeal constrictor muscles and the prevertebral fascia. It extends from the base of skull to the bifurcation of trachea. The space is divided into two lateral compartments (spaces of Gillette) by a fibrous raphe (Fig. 51.5). Each lateral space contains retropharyngeal nodes which usually disappear at 3-4 years of age. Parapharyngeal space communicates with the retropharyngeal space. Infection of retropharyngeal space can pass down behind the oesophagus into the mediastinum.

### ***Prevertebral space***

It lies between the vertebral bodies posteriorly and the prevertebral fascia anteriorly. It extends from the base to skull of coccyx. Infection of this space usually comes from the caries of spine. Abscess of this space produces a midline bulge in contrast to abscess of retropharyngeal space which causes unilateral bulge.

# ACUTE RETROPHARYNGEAL ABSCESS

## Aetiology



Dhingra: Diseases of Ear Nose and Throat, 5th Edition  
Copyright © 2010 Elsevier. All rights reserved.

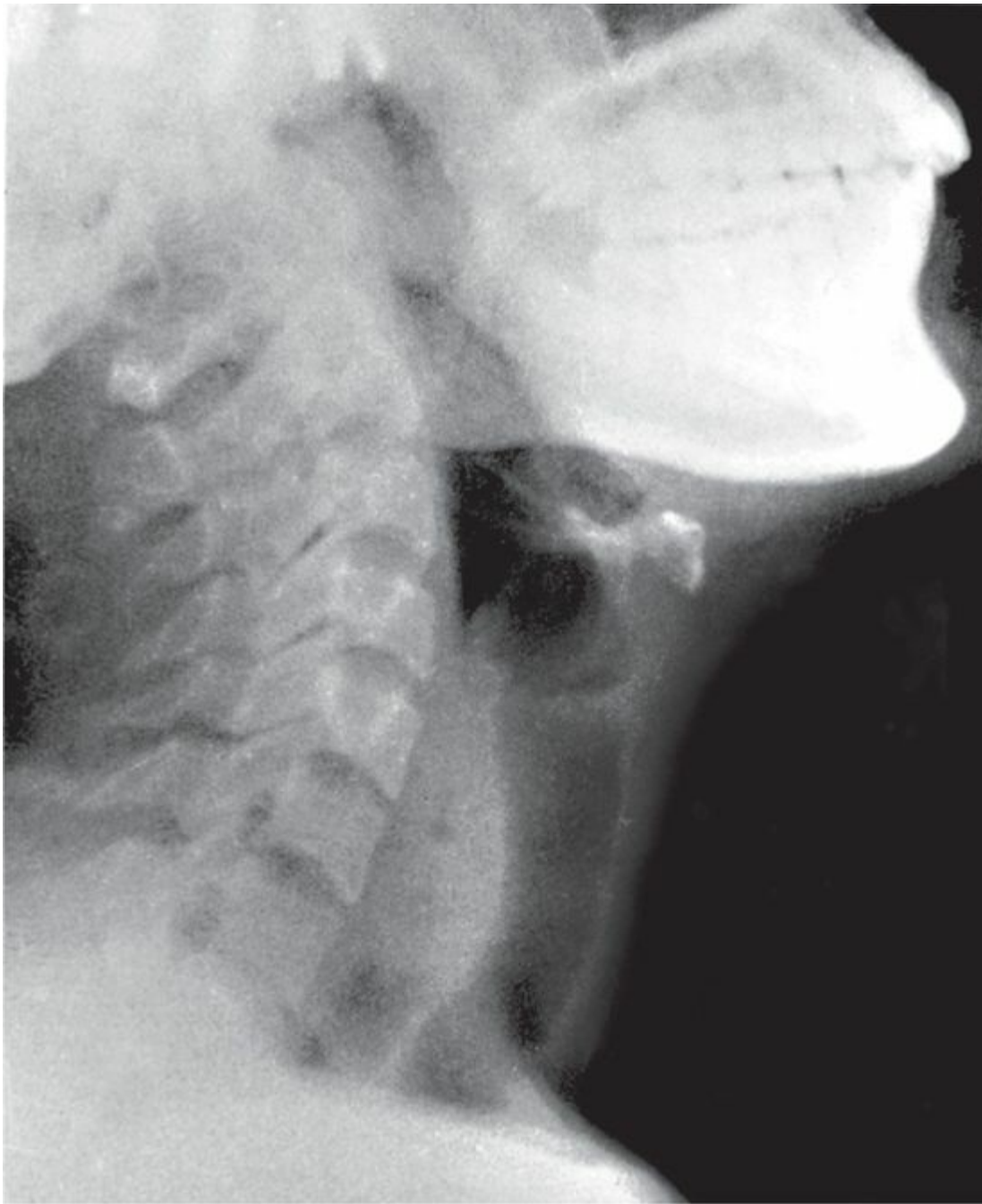
Figure 51.5 Spaces in relation to pharynx where abscesses can form.

It is commonly seen in children below 3 years. It is the result of suppuration of retropharyngeal lymph nodes secondary to infection in the adenoids, nasopharynx, posterior nasal sinuses or nasal cavity. In adults, it may result from penetrating injury of posterior pharyngeal wall or cervical oesophagus. Rarely, pus from acute mastoiditis tracks along the undersurface of petrous bone to present as retropharyngeal abscess.

## Clinical Features

- 1. *Dysphagia* and *difficulty in breathing* are prominent symptoms as the abscess obstructs the air and food passages.
- 2. *Stridor* and *croupy cough* may be present.
- 3. *Torticollis*. The neck becomes stiff and the head is kept extended.
- 4. *Bulge in posterior pharyngeal wall*. Usually seen on one side of the midline.

Radiograph of soft tissue lateral view of the neck shows widening of prevertebral shadow and possibly even the presence of gas (Fig. 51.6).



Dhingra: Diseases of Ear Nose and Throat, 5th Edition  
Copyright © 2010 Elsevier. All rights reserved.

Figure 51.6 Retropharyngeal abscess. Radiograph of soft tissue, lateral view neck showing widening of prevertebral space with gas formation.

- **1. Incision and drainage of abscess.** This is usually done without anaesthesia as there is risk of rupture of abscess during intubation. Child is kept supine with head low. Mouth is opened with a gag. A vertical incision is given in the most fluctuant area of the abscess. Suction should always be available to prevent aspiration of pus.
- **2. Systemic antibiotics.** Suitable antibiotics are given.
- **3. Tracheostomy.** A large abscess may cause mechanical obstruction to the airway or lead to laryngeal oedema. Tracheostomy becomes mandatory in these cases.

# **CHRONIC RETROPHARYNGEAL ABSCESS**

## **Aetiology**

It is tubercular in nature and is the result of (1) caries of cervical spine or (2) tuberculous infection of retropharyngeal lymph nodes secondary to tuberculosis of deep cervical nodes. The former presents centrally behind the prevertebral fascia while the latter is limited to one side of midline as in true retropharyngeal abscess behind the buccopharyngeal fascia.

## Clinical Features

Patient may complain of discomfort in throat. Dysphagia, though present, is not marked. Posterior pharyngeal wall shows a fluctuant swelling centrally or on one side of midline. Neck may show tuberculous lymph nodes. In cases with caries of cervical spine, X-rays are diagnostic.

## Treatment

- **1. *Incision and drainage of abscess.*** It can be done through a vertical incision along the anterior border of sternomastoid (for low abscess) or along its posterior border (for high abscess).
- **2.** Full course of *antitubercular therapy* should be given.



# PARAPHARYNGEAL ABSCESS

(syn. Abscess of pharyngomaxillary or lateral pharyngeal space).

## Applied Anatomy

Parapharyngeal space is pyramidal in shape with its base at the base of skull and its apex at the hyoid bone.

## Relations (Figs 51.5 to Fig. 51.7)

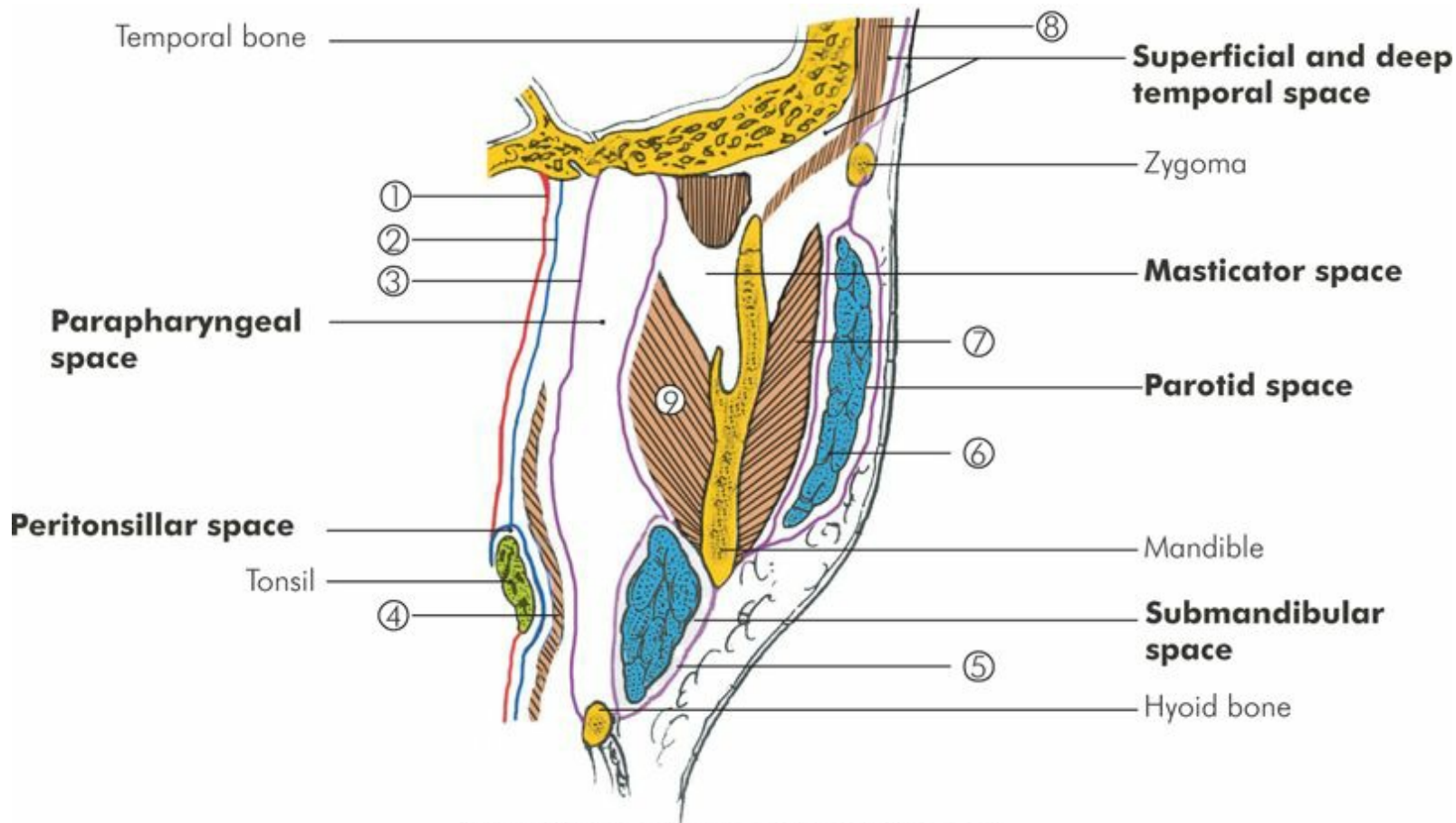
Medial:	Buccopharyngeal fascia covering the constrictor muscles.
Posterior:	Prevertebral fascia covering prevertebral muscles and transverse processes of cervical vertebrae.
Lateral:	Medial pterygoid muscle, mandible and deep surface of parotid gland.

Styloid process and the muscles attached to it divide the parapharyngeal space into anterior and posterior compartments. *Anterior compartment* is related to tonsillar fossa medially and medial pterygoid muscle laterally. *Posterior compartment* is related to posterior part of lateral pharyngeal wall medially and parotid gland laterally. Through the posterior compartment pass the carotid artery, jugular vein, IXth, Xth, XIth, XIIth cranial nerves and sympathetic trunk.

It also contains upper deep cervical nodes.

Parapharyngeal space communicates with other spaces, viz. retropharyngeal, submandibular, parotid, carotid and visceral (Table 51.1).

# Aetiology



Dhingra: Diseases of Ear Nose and Throat, 5th Edition  
Copyright © 2010 Elsevier. All rights reserved.

Figure 51.7 Spaces of head and neck seen in coronal section. Mucosa (1), pharyngobasilar fascia (2), buccopharyngeal fascia (3), superior constrictor muscle (4), superficial layer of deep cervical fascia enclosing submandibular gland (5), parotid gland (6), masseter muscle (7), temporalis muscle (8), medial pterygoid muscle (9).

Infection of parapharyngeal space can occur from:

- 1. *Pharynx*. Acute and chronic infections of tonsil and adenoid, bursting of peritonsillar abscess.
- 2. *Teeth*. Dental infection usually comes from the lower last molar tooth.
- 3. *Ear*. Bezold's abscess, petrositis.
- 4. *Other spaces*. Infections of parotid, retropharyngeal and submaxillary spaces.
- 5. *External trauma*. Penetrating injuries of neck, injection of local anaesthetic for tonsillectomy or mandibular nerve block.

## Clinical Features

Clinical features depend on the compartment involved.

*Anterior compartment* infections produce a triad of symptoms: (i) prolapse of tonsil and tonsillar fossa, (ii) trismus (due to spasm of medial pterygoid muscle) and (iii) external swelling behind the angle of jaw. There is marked odynophagia associated with it.

*Posterior compartment* involvement produces (i) bulge of pharynx behind the posterior pillar, (ii) paralysis of CN IX, X, XI, and XII and sympathetic chain, and (iii) swelling of parotid region. There is minimal trismus or tonsillar prolapse.

Fever, odynophagia, sore throat, torticollis (due to spasm of prevertebral muscles) and signs of toxæmia are common to both compartments.

- 1. Acute oedema of larynx with respiratory obstruction.
- 2. Thrombophlebitis of jugular vein with septicaemia.
- 3. Spread of infection to retropharyngeal space.
- 4. Spread of infection to mediastinum along the carotid space.
- 5. Mycotic aneurysm of carotid artery from weakening of its wall by purulent material. It may involve common carotid or internal carotid artery.
- 6. Carotid blow out with massive haemorrhage.

Table 51-1. Important spaces of the head and neck and their source of infection

Space	Extent	Location	Source of infection
Parotid space	Within two layers of superficial layer of deep cervical fascia	Parotid area	Infection of oral cavity via Stenson's duct
Submandibular space (submaxillary plus sublingual)	<i>Sublingual space</i> Oral mucosa to mylohyoid muscle	Below the tongue	<ul style="list-style-type: none"> <li>• Sublingual sialadenitis, tooth infection</li> <li>• Submandibular gland sialadenitis</li> <li>• Molar tooth infection</li> </ul>
	<i>Submandibular space</i> Mylohyoid muscle to superficial layer of deep cervical fascia extending from mandible to hyoid bone	Submental and submandibular triangles	
Peritonsillar space	Between superior constrictor and fibrous capsule on the lateral aspect of tonsil	Lateral to tonsil	Infection of tonsillar crypt
Retropharyngeal space	Base of skull to tracheal bifurcation (T4)	Between alar fascia and the buccopharyngeal fascia covering constrictor muscles	<ul style="list-style-type: none"> <li>• Extension of infection from parapharyngeal space, parotid or masticator space</li> <li>• Oesophageal perforation</li> <li>• Suppuration of retropharyngeal nodes</li> </ul>
Danger space	Base of skull to diaphragm	Between prevertebral fascia and alar fascia	<ul style="list-style-type: none"> <li>• Infected by rupture of retropharyngeal abscess</li> </ul>
Prevertebral space	Base of skull to coccyx	Between vertebrae on one side and prevertebral muscles and the prevertebral fascia on the other	<ul style="list-style-type: none"> <li>• Tuberculosis of spine</li> <li>• Penetrating trauma</li> </ul>
Parapharyngeal space ( <i>Lateral pharyngeal space or pharyngo-maxillary space</i> )	Base of skull to hyoid bone and submandibular gland	Buccopharyngeal fascia covering lateral aspect of pharynx medially, and fascia covering pterygoid muscles, mandible and parotid gland laterally	<ul style="list-style-type: none"> <li>• Peritonsillar abscess</li> <li>• Parotid abscess</li> <li>• Submandibular gland infection</li> <li>• Masticator space abscess</li> </ul>
		Between superficial layer of deep cervical fascia	

## Treatment

*Systemic antibiotics.* Intravenous antibiotics may become necessary to combat infection.

*Drainage of abscess.* This is usually done under general anaesthesia. If the trismus is marked, pre-operative tracheostomy becomes mandatory. Abscess is drained by a horizontal incision, made 2-3 cm below the angle of mandible. Blunt dissection along the inner surface of medial pterygoid muscle towards styloid process is carried out and abscess evacuated. A drain is inserted. Transoral drainage should never be done due to danger of injury to great vessels which pass through this space.

## **52 Tumours of Oropharynx**

### **BENIGN TUMOURS**

They are far less common compared to malignant tumours. The common ones are described here.



## Papilloma

It is usually pedunculated, arises from the tonsil, soft palate or faucial pillars. Often asymptomatic, it may be discovered accidentally by the patient or the physician. When large, it causes local irritation in the throat. Treatment is surgical excision.

## Haemangioma

It can occur on the palate, tonsil, posterior and lateral pharyngeal wall. It may be of capillary or cavernous type. Capillary haemangioma or asymptomatic cavernous haemangioma may be left alone. It is treated only if it is increasing in size or giving symptoms of bleeding and dysphagia. Treatment is diathermy coagulation or injection of sclerosing agents. Cryotherapy or laser coagulation is very effective.

## Pleomorphic Adenoma

It is mostly seen submucosally on the hard or soft palate. It is potentially malignant and should be excised totally.

## Mucous Cyst

It is usually seen in the vallecula. It is yellow in appearance and may be pedunculated or sessile. When large, it causes foreign body sensation in the throat. Treatment is surgical excision, if pedunculated; or incision and drainage with removal of its cyst wall.

**Lipoma**, **fibroma** and **neuroma** are other rare benign tumours.

# MALIGNANT TUMOURS

The common sites of malignancy in the oropharynx are: (Table 52.1)

- 1. Posterior one-third (or base) of tongue.
- 2. Tonsil and tonsillar fossa.
- 3. Faucial palatine arch, i.e. soft palate and anterior pillar.
- 4. Posterior and lateral pharyngeal wall.

Gross appearances of the tumour can be divided into 4 types:

- (a) Superficially spreading
- (b) Exophytic
- (c) Ulcerative
- (d) Infiltrative

The first two types are seen in the palatine arch; they are rarely associated with metastasis. Ulcerative and infiltrative types often involve the base of tongue and tonsil. They have poor prognosis and deeply invade the adjoining structures and have marked tendency for regional metastasis.

**Table 52-1. Subsites in the oropharynx**

- Base of tongue
- Tonsil, tonsillar fossa
- Faucial arch
- Pharyngeal wall

page 284

page 285

*Histologically*, the tumours may be:

- (a) *Squamous cell carcinoma*. Shows various grades of differentiation (well, moderately or poorly differentiated) and is the most common variety.
- (b) *Lymphoepithelioma*. A poorly differentiated variant of the above, with admixture of lymphocytes, which do not show any features of malignancy. This is often seen in tonsil, base of tongue and vallecula.
- (c) *Adenocarcinoma*. It arises from minor salivary glands. It is mostly seen on the palate and fauces.
- (d) *Lymphomas*. Both Hodgkin and non-Hodgkin lymphomas arise from the tonsil and base of tongue. They are seen in the young adults and sometimes in the children. Enlarged cervical nodes may co-exist.

## **TNM classification**

It is similar to the one used in cancer of the oral cavity. (see Table 52.2).

*Treatment*. Treatment of oropharyngeal cancer depends upon the site and extent of disease, patient's general condition, philosophy and experience of the treating surgeon and facilities available at a particular centre. The various options are:

- (i) Surgery alone
- (ii) Radiation alone
- (iii) Combination of surgery and radiotherapy
- (iv) Chemotherapy alone or as an adjunct to surgery or radiotherapy
- (v) Palliative therapy.

# 1. Carcinoma of Posterior One-third or Base of Tongue

This is commonly seen in our country (Fig. 52.1). The lesion remains asymptomatic for a long time and patient presents when metastases in cervical nodes make their appearance. Earlier symptoms of sore-throat, feeling of lump in the throat and slight discomfort on swallowing are often ignored or attributed to lingual tonsils. Late features are referred pain in the ear, dysphagia, bleeding from the mouth, and change in the quality of speech (hot potato voice).

## Spread

**Local.** Lesions are deeply infiltrative and spread to the rest of tongue musculature, epiglottis and pre-epiglottic space, tonsil and its pillars, and hypopharynx.

**Lymphatic.** 70% of the cases show cervical metastases either unilateral or bilateral at the time of initial consultation. Jugulodigastric nodes are the first to be involved.

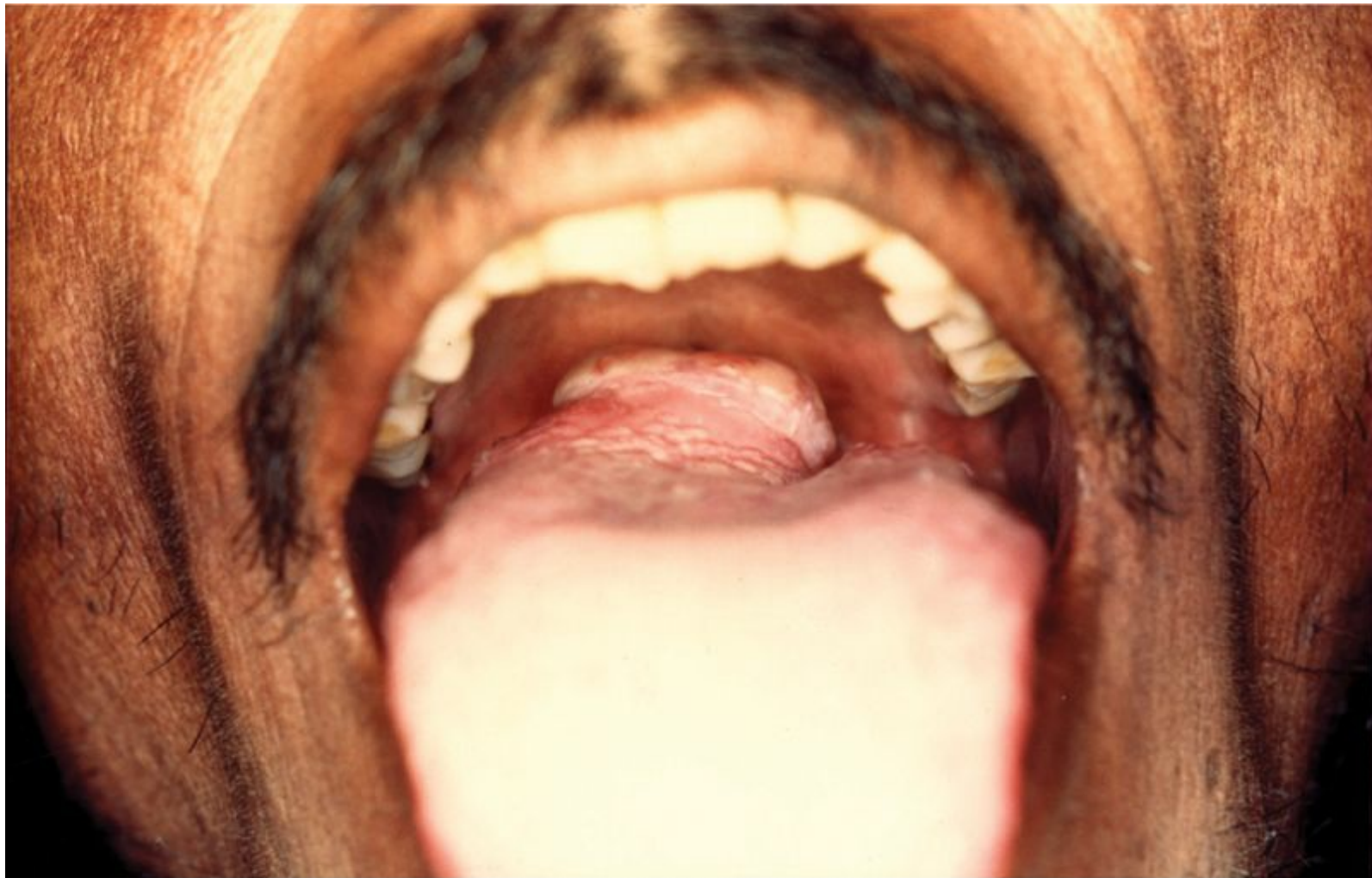**Distant metastases.** Bones, liver, lung may be involved.

## Diagnosis

**Table 52-2. TNM classification and staging of oropharyngeal cancer (AJCC, 2002)**

<b>Primary tumour (T)</b>			
T <sub>1</sub>	Tumour 2 cm or less in greatest dimension		
T <sub>2</sub>	Tumour more than 2 cm but not more than 4 cm in greatest dimension		
T <sub>3</sub>	Tumour more than 4 cm in greatest dimension		
T <sub>4a</sub>	Tumour invades the larynx, deep/extrinsic muscle of tongue, medial pterygoid, hard palate or mandible		
T <sub>4b</sub>	Tumour invades lateral pterygoid muscle, pterygoid plates, lateral nasopharynx, or base of skull or encases carotid artery		
<b>Regional lymph nodes (N)</b>			
N <sub>x</sub>	Regional lymph nodes cannot be assessed		
N <sub>0</sub>	No regional lymph node metastasis		
N <sub>1</sub>	Metastasis in a single ipsilateral lymph node, 3 cm or less in greatest dimension		
N <sub>2</sub>	Metastasis in a single ipsilateral lymph node, more than 3 cm but not more than 6 cm in greatest dimension, or in multiple ipsilateral lymph nodes, none more than 6 cm in greatest dimension, or in bilateral or contralateral lymph nodes, none more than 6 cm in greatest dimension		
N <sub>2a</sub>	Metastasis in a single ipsilateral lymph node more than 3 cm but not more than 6 cm in greatest dimension		
N <sub>2b</sub>	Metastasis in multiple ipsilateral lymph nodes, none more than 6 cm in greatest dimension		
N <sub>2c</sub>	Metastasis in bilateral or contralateral lymph nodes, none more than 6 cm in greatest dimension		
N <sub>3</sub>	Metastasis in a lymph node more than 6 cm in greatest dimension		
<b>Distant metastasis (M)</b>			
M <sub>x</sub>	Distant metastasis cannot be assessed		
M <sub>0</sub>	No distant metastasis		
M <sub>1</sub>	Distant metastasis		
<b>Stage grouping</b>			
0	Tis	N <sub>0</sub>	M <sub>0</sub>
I	T <sub>1</sub>	N <sub>0</sub>	M <sub>0</sub>
II	T <sub>2</sub>	N <sub>0</sub>	M <sub>0</sub>
III	T <sub>3</sub>	N <sub>0</sub>	M <sub>0</sub>
	T <sub>1</sub>	N <sub>1</sub>	M <sub>0</sub>
	T <sub>2</sub>	N <sub>1</sub>	M <sub>0</sub>
	T <sub>3</sub>	N <sub>1</sub>	M <sub>0</sub>
IVA	T <sub>4a</sub>	N <sub>0</sub>	M <sub>0</sub>
	T <sub>4a</sub>	N <sub>1</sub>	M <sub>0</sub>
	T <sub>1</sub>	N <sub>2</sub>	M <sub>0</sub>
	T <sub>2</sub>	N <sub>2</sub>	M <sub>0</sub>

	T <sub>3</sub>	N <sub>2</sub>	M <sub>0</sub>
	T <sub>4a</sub>	N <sub>2</sub>	M <sub>0</sub>
IVB	T <sub>4b</sub>	Any N	M <sub>0</sub>
	Any T	N <sub>3</sub>	M <sub>0</sub>
IVC	Any T	Any N	M <sub>1</sub>



Dhingra: Diseases of Ear Nose and Throat, 5th Edition  
Copyright © 2010 Elsevier. All rights reserved.

Figure 52.1 An exophytic growth at the base of tongue.

Lesions can be seen on indirect laryngoscopy but palpation of the tumour should *never* be omitted. Palpation under anaesthesia when tissues are relaxed gives better idea of the degree of infiltration of tissues. Lesion is usually far more extensive than it appears on mirror examination. CT scan is recommended for tumour and nodal staging. Biopsy is essential to know its histology.

## Treatment

Treatment may vary from centre to centre, some favouring radiotherapy, others surgery and still others radiotherapy followed by salvage surgery.

Tumours which are radiosensitive such as anaplastic carcinoma, lymphoepithelioma or lymphoma are treated by radiotherapy to the primary and neck nodes.

For T<sub>1</sub> and T<sub>2</sub> squamous cell carcinoma with N<sub>0</sub> or N<sub>1</sub> neck, surgical excision with block dissection is preferred and if neck dissection specimen reveals a stage more than N<sub>1</sub>, post-operative radiation is added.

T<sub>3</sub> and T<sub>4</sub> lesions require surgical excision with mandibular resection, neck dissection and post-operative radiation.

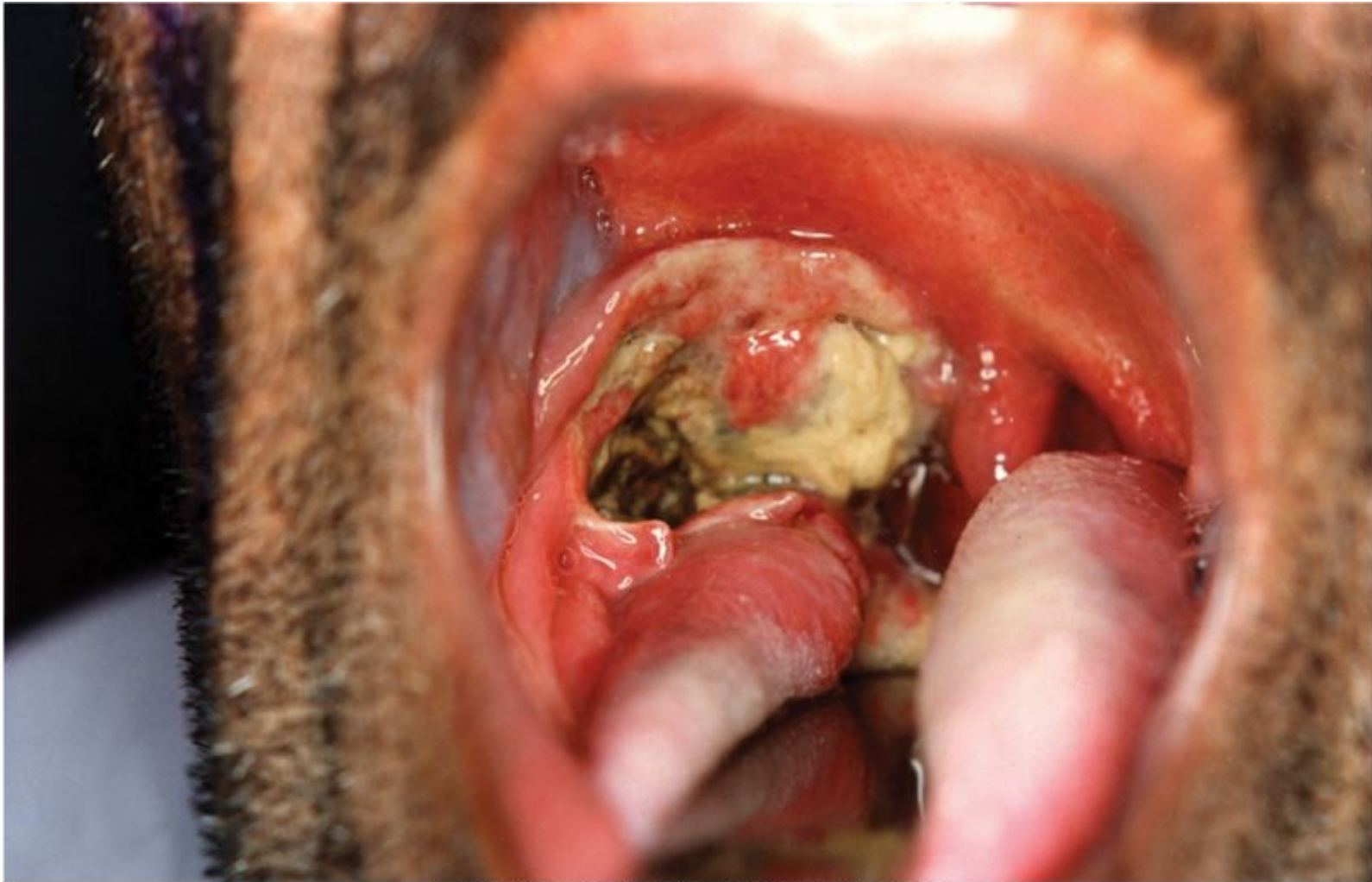T<sub>4</sub> lesions, which also extend into anterior 2/3 of tongue or vallecula, require extensive surgery with total glossectomy and laryngectomy in addition to the block dissection.

Chemotherapy may be combined with radiotherapy and surgery in such cases.

For advanced cancers, in patients with poor health, only palliation with radio- or chemotherapy may be required. They often end up into tracheostomy and gastrostomy in the terminal phase to restore their air and food passages and strong analgesics for relief of pain.

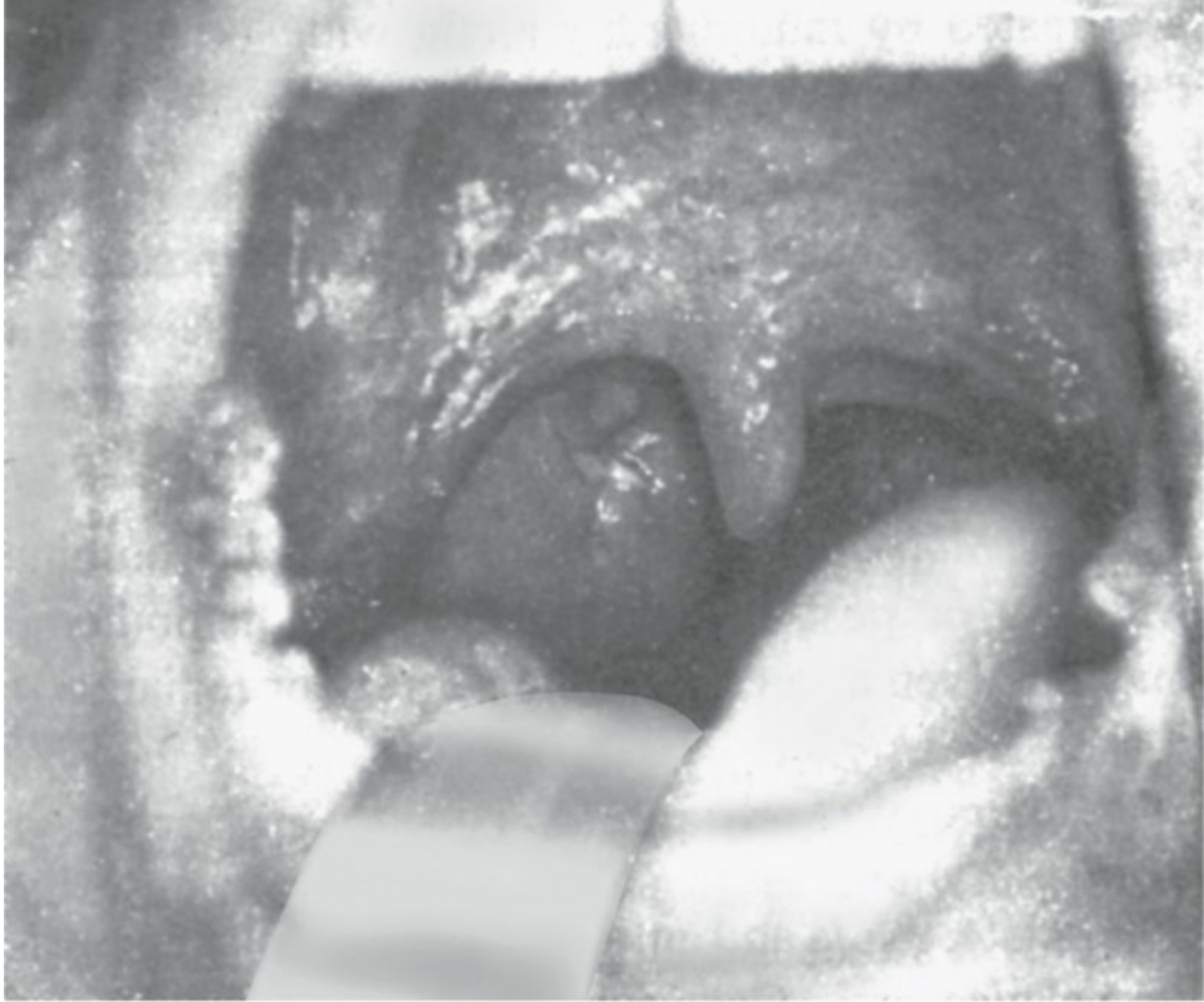


## 2. Carcinoma Tonsil and Tonsillar Fossa



Dhingra: Diseases of Ear Nose and Throat, 5th Edition  
Copyright © 2010 Elsevier. All rights reserved.

Figure 52.2 Squamous cell carcinoma involving tonsil, pillar and soft palate.



Dhingra: Diseases of Ear Nose and Throat, 5th Edition  
Copyright © 2010 Elsevier. All rights reserved.

Figure 52.3 Lymphoma tonsil presenting as unilateral tonsillar enlargement.

Squamous cell carcinoma is the most common and presents as an ulcerated lesion with necrotic base (Fig. 52.2). Lymphomas may present as unilateral tonsillar enlargement with or without ulceration and may simulate indolent peritonsillar abscess (Fig. 52.3).

### Spread

*Local.* Tumour may spread locally to soft palate and pillars, base of tongue, pharyngeal wall and hypopharynx. It may invade pterygoid muscles and mandible resulting in pain and trismus. Parapharyngeal space may also get invaded.

*Lymphatic.* Fifty percent of the patients have initial cervical node involvement at the time of presentation. Jugulodigastric nodes are the first to be involved.

*Distant metastases.* They are seen in late cases.

### Clinical Features

Persistent sore throat, difficulty in swallowing, pain in the ear or lump in the neck are the presenting symptoms. Later on, bleeding from the mouth, fetor oris and trismus may occur.

## **Diagnosis**

Palpation of tonsillar area should never be omitted to find the extent of tumour. Biopsy is essential for histological typing.

## **Treatment**

*Radiotherapy.* Early and radiosensitive tumours are treated by radiotherapy along with irradiation of cervical nodes.

*Surgery.* Excision of the tonsil can be done for early superficial lesions. Larger lesions and those which invade bone require wide surgical excision with hemimandibulectomy and neck dissection (commando operation).

*Combination therapy.* Surgery may be combined with pre- or post-operative radiation. Chemotherapy may be given as an adjunct to surgery or radiation.

### 3. Carcinoma of Faucial (Palatine) Arch

Soft palate, uvula and anterior tonsillar pillar comprise the faucial arch. Carcinoma in these sites is often of squamous cell variety. Lesions are superficially spreading and well-differentiated with late tendency for nodal metastases (Fig. 52.4). Thus they behave more like carcinomas of the oral cavity.

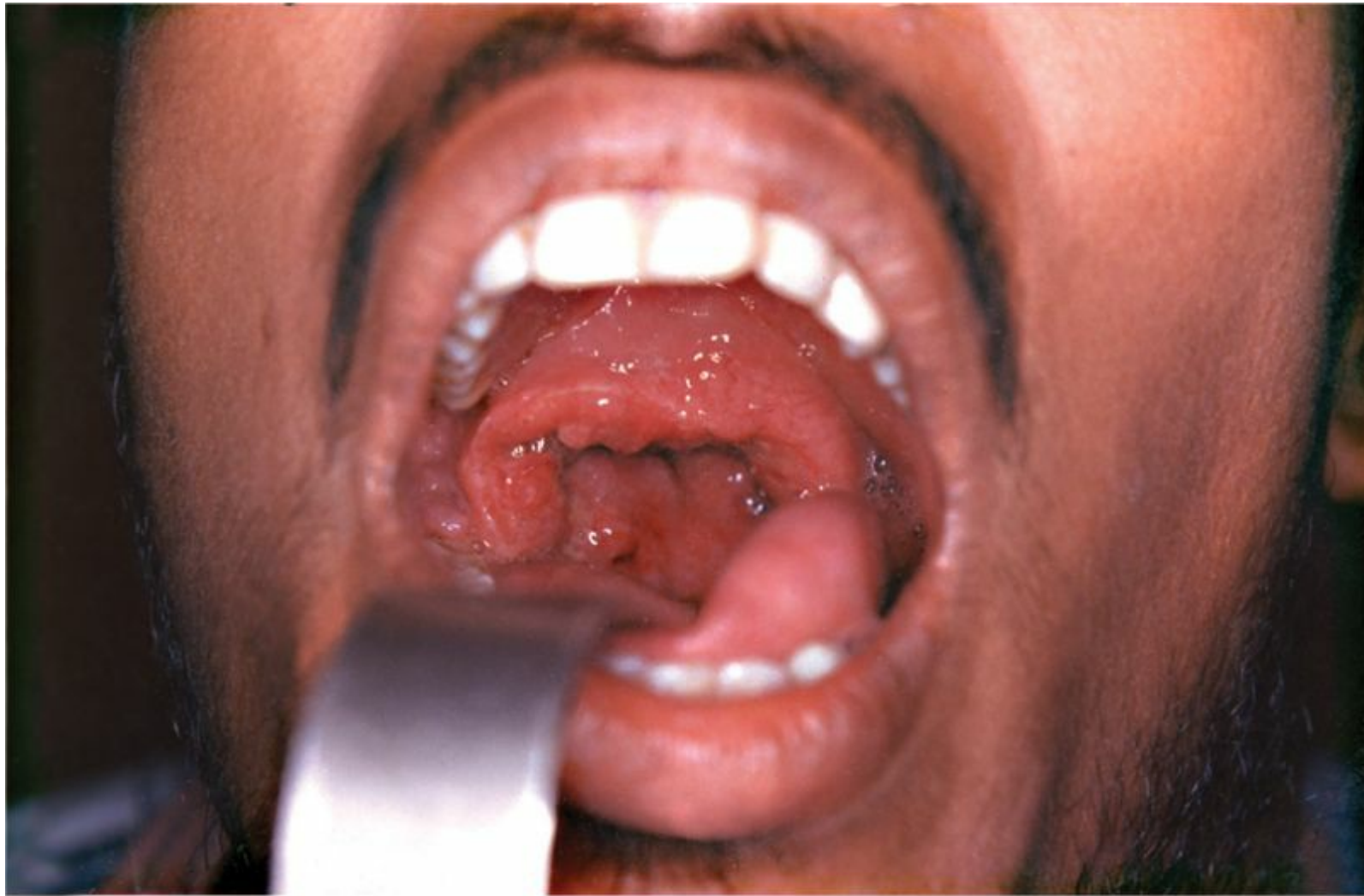Spread may occur locally to the contiguous structures or lymph nodes. Upper deep cervical and submandibular nodes may be involved.

Patients with palatine arch cancer usually present with persistent sore throat, local pain or earache. Growth may have been noticed by the patient while using the mirror, or by his physician while examining his throat or by the dentist.

Treatment is irradiation or surgical excision.

#### 4. Carcinoma of Posterior and Lateral Pharyngeal Wall

Lesions remain asymptomatic for a long time. They may spread submucosally to the adjoining areas such as tonsil, soft palate, tongue, nasopharynx or hypopharynx. They may also invade parapharyngeal space or anterior spinal ligaments. Sixty percent of patients may have lymph node metastases. Bilateral nodal involvement is common.



Dhingra: Diseases of Ear Nose and Throat, 5th Edition  
Copyright © 2010 Elsevier. All rights reserved.

Figure 52.4 An ulcerative lesion of palatine arch. It was well-differentiated squamous cell carcinoma.

Treatment is irradiation or surgical excision of growth with skin grafting. This is often combined with block dissection when nodes are palpable. Access to posterior pharyngeal wall is through lateral pharyngotomy with or without mandibular osteotomy.

## PARAPHARYNGEAL TUMOURS

Parapharyngeal space is described on page 281 (refer Fig. 51.6). It lies lateral to the pharynx. Both benign and malignant tumours are seen. They cause a bulge in lateral pharyngeal wall and distort the pillars and soft palate, and thus mimic neoplasms of the oropharynx. Commonly seen tumours are those from the deep lobe of parotid, neurogenic (e.g. neurilemmoma), chemodectoma (from carotid body), lipoma or aneurysm of internal carotid artery.

## **STYALGIA (EAGLE'S SYNDROME)**

It is due to elongated styloid process or calcification of stylohyoid ligament. Patient complains of pain in tonsillar fossa and upper neck which radiates to the ipsilateral ear. It gets aggravated on swallowing. Diagnosis can be made by transoral palpation of the styloid process in the tonsillar fossa and by a radiograph such as anteroposterior view with open mouth or lateral view of skull. Many persons may have elongated styloid process but remain asymptomatic and do not need treatment. Symptomatic styloid process can be excised by transoral or cervical approach.

## 53 Tumours of the Hypopharynx and Pharyngeal Pouch

### TUMOURS OF HYPOPHARYNX

#### ***Benign tumours***

They are exceptionally uncommon and include *papilloma*, *adenoma*, *lipoma*, *fibroma* and *leiomyoma*. They present as smooth well-defined masses which are sometimes pedunculated and mobile.

#### ***Malignant tumours***

Carcinoma of the hypopharynx is very common in our country. Practically, most of the tumours are squamous cell type with various grades of differentiation. The various sub-sites involved are: (1) pyriform sinus, (2) postcricoid region, and (3) posterior pharyngeal wall, in that order of frequency.



# 1. Carcinoma Pyriform Sinus

It constitutes 60% of all hypopharyngeal cancers, mostly affecting males above 40 years of age. Growth is either exophytic or ulcerative and deeply infiltrative. Because of the large size of the pyriform sinus, growths of this region remain asymptomatic for a long time. Metastatic neck nodes may be the first to attract attention.

## Spread

*Locally*, the growth may spread upwards to the vallecula and base of tongue; downwards to postcricoid region; medially to aryepiglottic folds and ventricles. It may infiltrate into the thyroid cartilage, thyroid gland or may present as a soft tissue mass in the neck.

*Lymphatic spread* occurs early. Pyriform fossa has a rich lymphatic network. Seventy five percent of the patients have cervical nodal metastases when first seen, with half of them having bilateral involvement. Upper and middle group of jugular cervical nodes are often involved. Sometimes, nodes make their appearance long after the primary has been eradicated.

*Distant metastases* often occur late and may be seen in lung, liver and bones.

## Clinical Features

Early symptoms are few. Something sticking in the throat and "pricking sensation" on swallowing may be the earliest symptoms. Referred otalgia, pain on swallowing and increasing dysphagia may follow. A mass of lymph nodes high up in the neck may be the first sign. Hoarseness and laryngeal obstruction indicate laryngeal oedema or spread of disease to the larynx.

## Diagnosis

Growth and its extent can often be seen on mirror examination. Sometimes, pooling of secretions obstructs the view. Barium swallow and CT scan are helpful to evaluate the extent of growth and status of lymph nodes.

Endoscopic examination is necessary for biopsy and accurate assessment of the extent of growth and also to find out any synchronous primary at any other site.

## Treatment

Early growth without nodes can be cured by radiotherapy with the advantage of preserving the laryngeal function.

If growth is limited to pyriform fossa and does not extend to postcricoid region, total laryngectomy and partial pharyngectomy is done. Remaining pharynx can be primarily closed. This is often combined with elective or prophylactic block dissection of lymph nodes.

If growth extends to postcricoid region, total laryngectomy and pharyngectomy is done along with block dissection. Pharyngo-oesophageal segment is reconstructed with myocutaneous flaps or stomach pull-up.

Planned post-operative radiotherapy can be given routinely to all cases. Patients with no palpable nodes (N<sub>0</sub> neck) can also be given radiotherapy avoiding block dissection.

## 2. Carcinoma Postcricoid Region

This constitutes 30% of laryngopharyngeal malignancies. Paterson-Brown-Kelly (Plummer-Vinson) syndrome characterised by hypochromic microcytic anaemia is an important aetiological factor as one-third of patients of postcricoid carcinoma may be suffering from it.

### Spread

Usually an ulcerative type of lesion arises from postcricoid region. Local spread often occurs in an annular fashion causing marked dysphagia. Growths may invade cervical oesophagus, arytenoids, or recurrent laryngeal nerve at cricoarytenoid joint.

Lymphatic spread involves paratracheal lymph nodes and may be bilateral due to the midline nature of lesions. They may not be clinically palpable.

### Clinical Features

Females are usually affected, sometimes in the early age group of twenties and thirties. Progressive dysphagia is the predominant presenting symptom. This may cause progressive malnutrition and weight loss. Sometimes, voice change and aphonia may be produced due to infiltration of recurrent laryngeal nerve or posterior cricoarytenoid muscles affecting vocal cord mobility.

### Diagnosis

Postcricoid growths may not be visible on indirect laryngoscopy. Oedema and erythema of the postcricoid region and pooling of secretions in the hypopharynx are suggestive of growth. Laryngeal crepitus, felt normally while moving larynx over the cervical spine, may be lost.

Lateral soft tissue radiograph of the neck may show an increased prevertebral shadow. Barium swallow is essential to find the lower extent of the disease. Endoscopy is always done to take biopsy and assess the extent of lesion.

### Treatment

Prognosis is poor both with irradiation and surgical treatment. Some prefer to give radiotherapy initially. It has the advantage of preserving laryngeal function. Failed cases are subjected to laryngo-pharyngo-oesophagectomy with stomach pull-up or colon transposition to reconstruct pharyngo-oesophageal segment. Many feel that initial surgery, if feasible, gives better results.

### 3. Carcinoma Posterior Pharyngeal Wall

This is the least common of laryngopharyngeal malignancy constituting only 10% of them. They are mostly seen in males above fifty years of age.

#### **Spread**

Growth is usually exophytic but may be ulcerative. It remains localized until late and then spreads to the prevertebral fascia, muscles and vertebrae.

Lymphatic spread is usually bilateral due to midline nature of the lesion. 50% of the patients with cancer of posterior pharyngeal wall have nodal metastasis on their initial examination. Retropharyngeal nodes, though not clinically palpable, may also be involved.

#### **Clinical Features**

Dysphagia or spitting of blood may be the presenting symptom. Some may present with a palpable mass of nodes in the neck without any symptoms pointing to the primary tumour.

#### **Diagnosis**

Indirect mirror examination often reveals the tumour. Lateral soft tissue radiography may show vertical extent and thickness of the tumour and any involvement of cervical vertebrae. Endoscopy is essential for biopsy and accurate assessment of the tumour and to find any synchronous primary at any other site.

#### **Treatment**

Early lesions, particularly exophytic, can be treated by radiotherapy with preservation of laryngeal function. Early small lesions can also be excised surgically via lateral pharyngotomy and primary repair with equally good results. Advanced lesions may require laryngopharyngectomy and block dissection of neck with repair of the food channel. Gross 5-year cure rate is only 19%.

# PHARYNGEAL POUCH

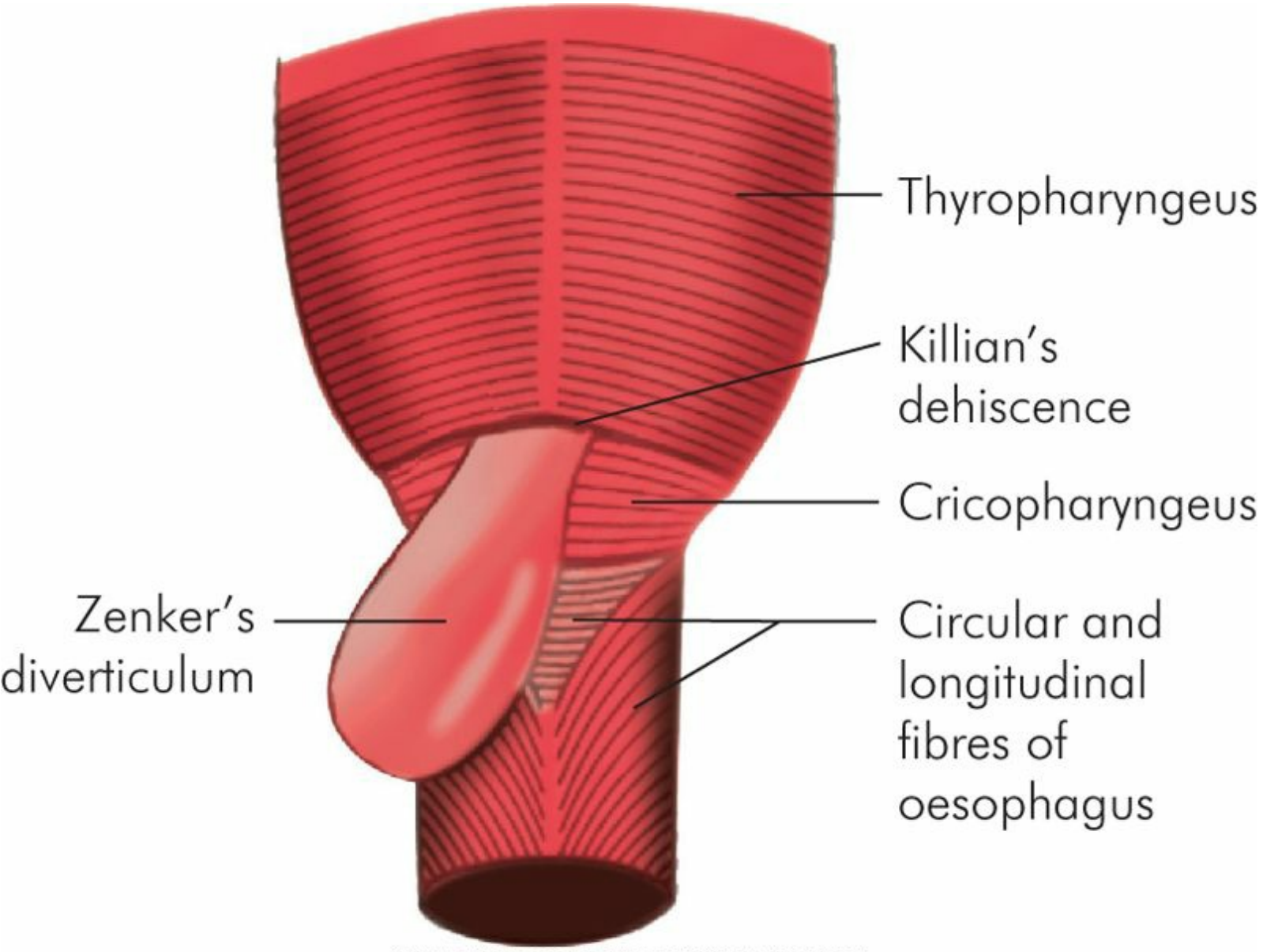
Also called **hypopharyngeal diverticulum** or **Zenker's diverticulum**, it is a pulsion diverticulum where pharyngeal mucosa herniates through the Killian's dehiscence—a weak area between two parts of the inferior constrictor (Figs 53.1 and 53.2).

## Aetiology

Exact cause is not known. It is probably due to spasm of cricopharyngeal sphincter or its incoordinated contractions during the act of deglutition. It is usually seen after 60 years of age.

## Pathology

page 289  
page 290



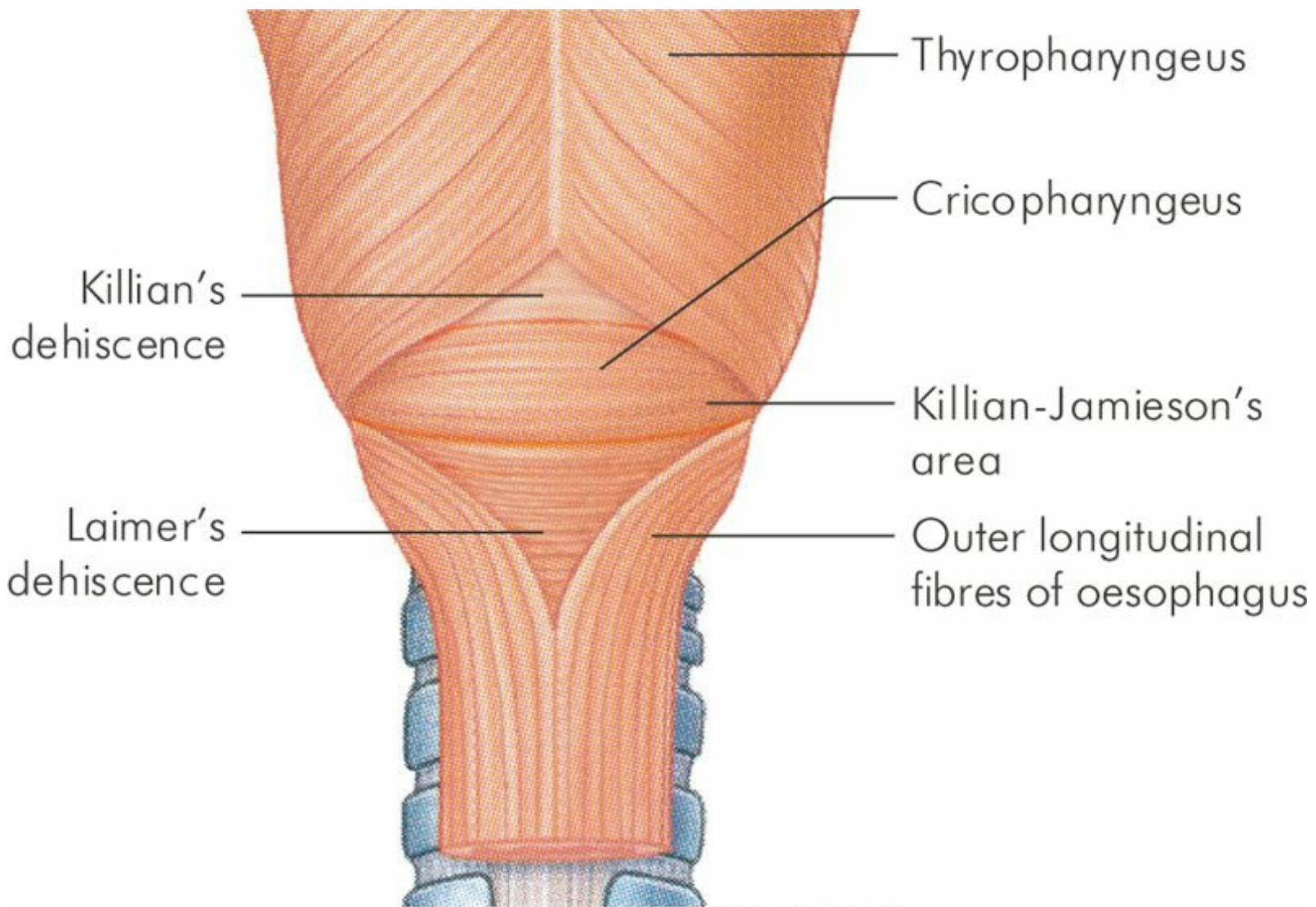
Dhingra: Diseases of Ear Nose and Throat, 5th Edition  
Copyright © 2010 Elsevier. All rights reserved.

Figure 53.1 Hypopharyngeal (Zenker's) diverticulum. Hypopharyngeal mucosa herniates through the Killian's dehiscence—a weak area between two parts of inferior constrictor muscle.

Herniation of pouch starts in the midline. It is at first behind the oesophagus and then comes to lie on its left. Mouth of the sac is wider than the opening of oesophagus and food preferentially enters the sac.

## Clinical Features

Dysphagia is the prominent feature. It appears after a few swallows when the pouch gets filled with food, and presses on the oesophagus. Gurgling sound is produced on swallowing. Undigested food may regurgitate at night, when patient is recumbent, causing cough and aspiration pneumonia. Patient is often malnourished due to dysphagia. Patients with pharyngeal pouch may have associated hiatus hernia. Rarely carcinoma can develop in long-standing cases of pharyngeal pouch.



Dhingra: Diseases of Ear Nose and Throat, 5th Edition  
Copyright © 2010 Elsevier. All rights reserved.

Figure 53.2 Potential sites for hypopharyngeal diverticulum.

## Diagnosis

Barium swallow will show the sac and its size.

## Treatment

- 1. Excision of pouch and cricopharyngeal myotomy. This is done through cervical approach.
- 2. Dohlman's procedure. The partition wall between the oesophagus and the pouch is divided by *diathermy* through an endoscope. This is done in poor risk debilitated patients.
- 3. Endoscopic laser treatment. It is similar to Dohlman's procedure. Partition between the pouch and oesophagus is divided by CO<sub>2</sub> laser using operating microscope.

## **54 Snoring and Sleep Apnoea**

### **SNORING**

It is an undesirable disturbing sound that occurs during sleep. It is estimated that 25% of adult males and 15% of adult females snore. Its prevalence increases with age.

## Definition of Terms

### ***Sleep apnoea***

It is cessation of breathing that last for 10 seconds or more during sleep. Less than five such episodes is normal.

### ***Apnoea index***

It is number of episodes of apnoea in 1 hour.

### ***Hypopnoea***

It is reduction of air flow. Some define it as drop of 50% of airflow from the base line associated with an EEG defined arousal or 4% drop in oxygen saturation.

### ***Respiratory disturbance index (RDI)***

Also called apnoea-hypopnoea index. It is the number of apnoea and hypopnoea events per hour. Normally RDI is less than 5. Based on RDI, severity apnoea has been classified as mild, 5-14; moderate, 15-30; and severe > 30.

### ***Arousal***

Transient awakening from sleep as a result of apnoea or respiratory efforts.

### ***Arousal index***

It is number of arousal events in 1 hour. Less than 4 is normal.

### ***Sleep efficiency***

Minutes of sleep divided by minutes in bed after lights are turned off.

### ***Multiple sleep latency test***

Patient undergoes four or five scheduled naps usually in the daytime. Latency period from wakefulness to the onset of sleep and REM sleep are measured. It is performed when narcolepsy is suspected or daytime sleepiness is evaluated objectively.

## Mechanism of Snoring

Muscles of pharynx are relaxed during sleep and cause partial obstruction. Breathing against obstruction causes vibrations of soft palate, tonsillar pillars and base of tongue producing sound. Sound as loud as 90 dB has been recorded during snoring.

Snoring may be primary, i.e. without association with obstructive sleep apnoea (OSA) or complicated, i.e. associated with OSA. Primary snoring is not associated with excessive daytime sleepiness and has apnoea-hypnoea index of less than 5.



## Aetiology

In children most common cause is adenotonsillar hypertrophy. In adults cause of snoring could be in the *nose or nasopharynx* such as septal deviation, turbinate hypertrophy, nasal valve collapse, nasal polypi or tumours; in *oral cavity* and *oropharynx* such as elongated soft palate and uvula, tonsillar enlargement, macroglossia, retrognathia, large base of tongue; or its tumour; in the *larynx and laryngopharynx* such as laryngeal stenosis or omega-shaped epiglottis.

Other causes include obesity and thick neck with collar size exceeding 42 cm. Use of alcohol, sedatives and hypnotics aggravates snoring due to muscle relaxation.

## Sites of Snoring

Site of snoring may be soft palate, tonsillar pillars or hypopharynx. It may vary from patient to patient and even in the same patient thus making surgical correction a difficult decision. Sometimes sites of snoring are multiple even in the same patient.

Excessive loud snoring is socially disruptive and forms snoring-spouse syndrome and is the cause of marital discord sometimes leading to divorce. In addition, a snorer with obstructive sleep apnoea may manifest with:

- Excessive daytime sleepiness
- Morning headaches
- General fatigue
- Memory loss
- Irritability and depression
- Decreased libido
- Increased risk of road accidents

Table 54.1 shows an Epworth sleepiness scale.

## Treatment

- 1. Avoidance of alcohol, sedatives and hypnotics.
- 2. Reduction of weight.
- 3. Sleeping on the side rather than on the back.
- 4. Removal of obstructing lesion in nose, nasopharynx, oral cavity, hypopharynx and larynx. Radiofrequency has been used for volumetric reduction of tissues of turbinates, soft palate and base of tongue.
- 5. Performing uvulopalatoplasty (UPP) surgically with cold knife or assisted with radiofrequency (RAUP) or laser (LAUP).

# SLEEP APNOEA

Apnoea means no breathing at all. There is no movement of air at the level of nose and mouth. It is of three types.

- **1. Obstructive:** There is collapse of the upper airway resulting in cessation of air flow. Other factors may be obstructive conditions of nose, nasopharynx, oral cavity and oropharynx, base of tongue or larynx.
- **2. Central:** Airways are patent but brain fails to signal the muscles to breath.
- **3. Mixed:** It is combination of both types.

Table 54-1. Epworth sleepiness scale

Situation	Score (0 to 3)
Sitting and reading	
Watching TV	
Sitting inactive in a public place (e.g. theatre or in a meeting)	
Being a passenger in a car for 1 hour without break	
Lying down to rest in the afternoon when circumstances permit	
Sitting and talking to someone	
Sitting quietly after a lunch without alcohol	
Sitting in a car while stopped in traffic for a few minutes	

0 = never dozing off; 1 = slight chance of dozing off; 2 = moderate chance of dozing off; 3 = high chance of dozing.

## Pathophysiology of OSA

Apnoea during sleep causes hypoxia and retention of carbon dioxide which leads to pulmonary constriction leading to congestive heart failure, bradycardia and cardiac hypoxia leading to left heart failure, and cardiac arrhythmias sometimes leading to sudden death. During sleep apnoea, there are frequent arousals which cause sleep fragmentation, daytime sleepiness and other manifestations. Table 54.2 lists the consequences of obstructive sleep apnoea.

# Physiology of Sleep

A normal healthy adult sleeps for 7-8 hours. Sleep occurs in two phases: non-REM (non-rolling eye movement) and REM (rolling eye movement). The two phases occur in semiregular cycles, each cycle lasting for 90-120 minutes. There are thus three or four cycles of sleep.

## Non-REM Sleep

Stage I	Transition from wakefulness to sleep. It constitutes 2-5% of sleep. EEG shows decrease of alpha and increase of theta waves. Muscle tone is less. Person can be easily aroused from this stage.
Stage II	Characterised by sleep spindles or 'K' complexes, and decrease in muscle tone. It constitutes 45-55% of sleep.
Stage III	Forms 3-8% of sleep, characterised by delta waves. It is deep sleep.
Stage IV	Forms 10-15% of sleep, characterised by delta waves. It is deep, most restful sleep.

It forms 75-80% of sleep and occurs in four stages:

## REM Sleep

Forms 20-25% of total sleep, characterised by rapid eye movements, increased autonomic activity with erratic cardiac and respiratory movements. Dreaming occurs in this stage but muscular activity is decreased so that dreams are not enacted.

See Table 54.3 for differences between non-REM and REM sleep.

**Table 54-2. Consequences of obstructive sleep apnoea**

<ul style="list-style-type: none"> <li>• Congestive heart failure/cor pulmonale</li> <li>• Polycythemia and hypertension</li> <li>• Atrial and ventricular arrhythmias and left heart failure</li> <li>• Attacks of angina</li> <li>• Snoring spouse syndrome</li> <li>• Loss of memory</li> <li>• Decreased libido</li> <li>• Traffic accidents</li> </ul>
---

**Table 54-3. Differences between non-REM and REM sleep**

	Non-REM	REM
Duration	75-80% of sleep	20-25% of sleep
Eye movements	No eye rolling	Rapid conjugate eye movements
Autonomic activity	Less autonomic activity gives slow heart rate, low BP, slow and steady respiration	Increased autonomic activity with fluctuations in BP, heart rate and respiration
Brain activity	Minimal	Brain is active (REM sleep is also called activated brain in a paralysed person)
Muscular activity	Functional but less	Decreased. Since muscles are relaxed, snoring and OSA occurs in this stage.
EEG	Passes from alpha to delta waves from stage I to IV	Mixed frequency, low voltage waves with occasional bursts of saw-tooth waves
Dreaming	No	Yes

# Clinical Evaluation of a Case of Sleep Apnoea

## History

Patient's bed partner gives more reliable information than the patient himself because latter does not know what happened during sleep. History should include snoring during sleep, restless disturbed sleep, gasping, choking or apnoeic events, and sweating. In the daytime, there is history of excessive daytime sleepiness (Epworth sleepiness scale is more often used, see Table 54.1) and fatigue, irritability, morning headaches, memory loss and impotence. Also one should elicit history of body position during sleep, use of alcohol, sedatives and caffeine intake, mouth breathing and history of menopause or having hormonal replacement therapy.

## Physical Examination

Risk factors include male gender, obesity and age above 40 years.

- **1. Body mass index** It is calculated by dividing body weight in kilograms by height in metres squared. Normal BMI (18.5-24.9); overweight 25-29%; obesity 30-34.9. Obese patients need to reduce weight.
- **2. Collar size** Neck circumference at the level of cricothyroid membrane is measured. Collar size should not exceed 42 cm in males and 37.5 cm in females.
- **3. Complete head and neck examination** Look for tonsillar hypertrophy, retrognathia, macroglossia, elongated soft palate and uvula, base of tongue tumours, septal deviation, nasal polyps, turbinate hypertrophy and nasal valve collapse. Also examine nasopharynx and larynx.
- **4. Muller's manoeuvre** A flexible endoscope is passed through the nose and the patient asked to inspire vigorously with nose and mouth completely closed. Look for collapse of the soft tissues at the level of base of tongue and just above the soft palate. Level of pharyngeal obstruction can be found.

## Systemic examination

is done to look for hypertension, congestive heart failure, pedal oedema, truncal obesity and any sign of hypothyroidism.

## Cephalometric radiographs

are taken for craniofacial anomalies and tongue base obstruction.

## Polysomnography

It is the "gold standard" for diagnosis of sleep apnoea and records various parameters which include:

- EEG (electroencephalography)-to look for non-REM or REM sleep and stages of non-REM sleep.
- ECG (electrocardiography)-for heart rate and rhythm.
- EOM (electroculogram)-for rolling eye movements.
- EMG (electromyography)-recorded from submental and tibialis anterior muscle.
- Pulse oximetry-to assess oxygen saturation of blood to know lowest SaO<sub>2</sub> during sleep.
- Nasal and oral airflow-for episodes of apnoea and hypopnoea.
- Sleep position-helps to know whether apnoea/hypopnoea episodes occur in supine or lateral recumbent position.
- Blood pressure.
- Oesophageal pressure. Not done in all laboratories. Negative oesophageal pressure helps to know degree of breathing efforts made by the patient.

## Split-night polysomnography

In this study, the first part of night is used in usual polysomnography while the second part of night is used in titration of pressures for continuous positive airway pressure (CPAP). It is not recommended because episodes of sleep apnoea occur more often in the second half of night and are thus missed. Titration of pressures for CPAP should ideally be done on a second night.

page 293

page 294

Polysomnography can differentiate between primary snoring, pure OSA and central sleep apnoea.

## Treatment (Non-surgical)

- **1. Change in lifestyle** Those with mild disease and minimal symptoms can be treated with weight loss and dietary changes but those with cor pulmonale as a result of severe OSA may require permanent tracheostomy.
  - Use of alcohol in the evening aggravates OSA. Sedatives/hypnotics taken at night also have the same effect.
  - Smoking should be avoided.
  - Reduction of weight is helpful.
- **2. Positional therapy** Patient should sleep on the side as supine position may cause obstructive apnoea. A rubber ball can be fixed to the back of shirt to prevent adopting supine position.



- **3. Intraoral devices** They alter the position of mandible or tongue to open the airway and relieve snoring and sleep apnoea. Mandible advancement device (MAD) keeps the mandible forward while tongue retaining device (TRD) keeps tongue in anterior position during sleep. They help improve or abolish snoring. MAD is also useful in retrognathic patients.
- **4. CPAP (continuous positive airway pressure)** It provides pneumatic splint to airway and increases its calibre. Optimum airway pressure for device to open the airway is determined during sleep study and is usually kept at 5-20 cm of H<sub>2</sub>O. About 40% of patients find the use of CPAP device cumbersome and difficult to carry with them when traveling and thus stop using it. When CPAP is not tolerated, a BiPAP (bilevel positive airway pressure) device is used. It delivers positive pressure at two fixed levels-a higher inspiratory and a lower expiratory pressure. Now an autotitrating PAP (APAP) is also available which continuously adjusts the pressure. Their disadvantages are same as those of CPAP.

## Surgery

It is indicated for failed or non-compliant medical therapy.

Permanent tracheostomy is the "gold standard" of treatment but it is not accepted socially and has complications of its own. It is usually not a preferred option by patients. Surgical procedures used in OSA include:

### **Tonsillectomy and/or adenoidectomy**

#### **Nasal surgery**

Nasal obstruction may be the primary or the aggravating factor for OSA. Septoplasty to correct deviated nasal septum, removal of nasal polyps and reduction of turbinate size help to relieve nasal obstruction. Sometimes nasal surgery is also indicated for efficient use of CPAP.

#### **Oropharyngeal surgery**

Uvulopalatoplasty (UPP) is the most common procedure performed for snoring and OSA. It is 80% effective in snoring but OSA is relieved only in 50%. Some patients of OSA are known to relapse in long-term studies because of another site becoming active in the cause of obstruction (e.g. base of tongue). UPP can be laser or radiofrequency assisted.

#### **Advancement genioplasty with hyoid suspension**

It is done in patients where base of tongue also contributes to OSA. Patients with retrognathia and micrognathia are also the candidates.

**Table 54-4. Summary of management of OSA**

Non-surgical	Surgical
<ul style="list-style-type: none"> <li>• Weight reduction</li> <li>• Avoidance of alcohol, sedatives and smoking</li> <li>• Positional therapy</li> <li>• Intraoral devices               <ul style="list-style-type: none"> <li>◦ Mandibular advancement device</li> <li>◦ Tongue retention device</li> </ul> </li> <li>• CPAP or BiPAP or APAP</li> </ul>	<ul style="list-style-type: none"> <li>• Tonsil and adenoid surgery (children)</li> <li>• Nasal surgery: septoplasty, turbinate reduction, polypectomy</li> <li>• Palate surgery               <ul style="list-style-type: none"> <li>◦ Uvulopalatoplasty (UPP)</li> <li>◦ Uvulopalatopharyngoplasty (UPPP)</li> </ul> </li> <li>• Advancement pharyngoplasty</li> <li>• Tongue base surgery: Lingual tonsillectomy, laser midline glossectomy</li> <li>• Tongue base radiofrequency reduction</li> <li>• Mandibular osteotomy with genioglossus advancement</li> <li>• Hyoid myotomy and suspension               <ul style="list-style-type: none"> <li>◦ Hyoid bone suspended to lower border of mandible</li> <li>◦ Hyoid bone suspended to upper border of thyroid cartilage</li> </ul> </li> <li>• Maxillomandibular osteotomy and advancement</li> <li>• Tracheostomy-the gold standard</li> </ul>

Procedure involves resection of a rectangular portion of the mandible including genial tubercles and the attached genioglossi muscles, its rotation by 90°, and fixation by plates. It helps to pull the base of tongue anteriorly. Along with this procedure, the hyoid bone is freed from its inferior musculature and suspended from lower border of mandible by wires. This also helps to pull the base of tongue anteriorly.

#### **Tongue base radiofrequency**

Radiofrequency (RF) is used in five to six sittings to reduce the size of tongue. RF needle is inserted submucosally. It coagulates tissue and causes scarring thus reducing the size of tissue.

#### **Maxillomandibular advancement osteotomy**

Osteotomies are performed on mandibular ramus and maxilla. Osteotomy of the maxilla is like a Le Fort I procedure. These osteotomies are

then fixed in anterior position with plates and screws. This surgical procedure is effective in selected cases but has the disadvantage of causing aesthetic facial changes.

See Table 54.4 for summary of management of OSA.

---

page 295

---

page 296

---

page 296

---

page 297

## **SECTION V Diseases of Larynx and Trachea**

---

page 297

---

page 298

## 55 Anatomy and Physiology of Larynx

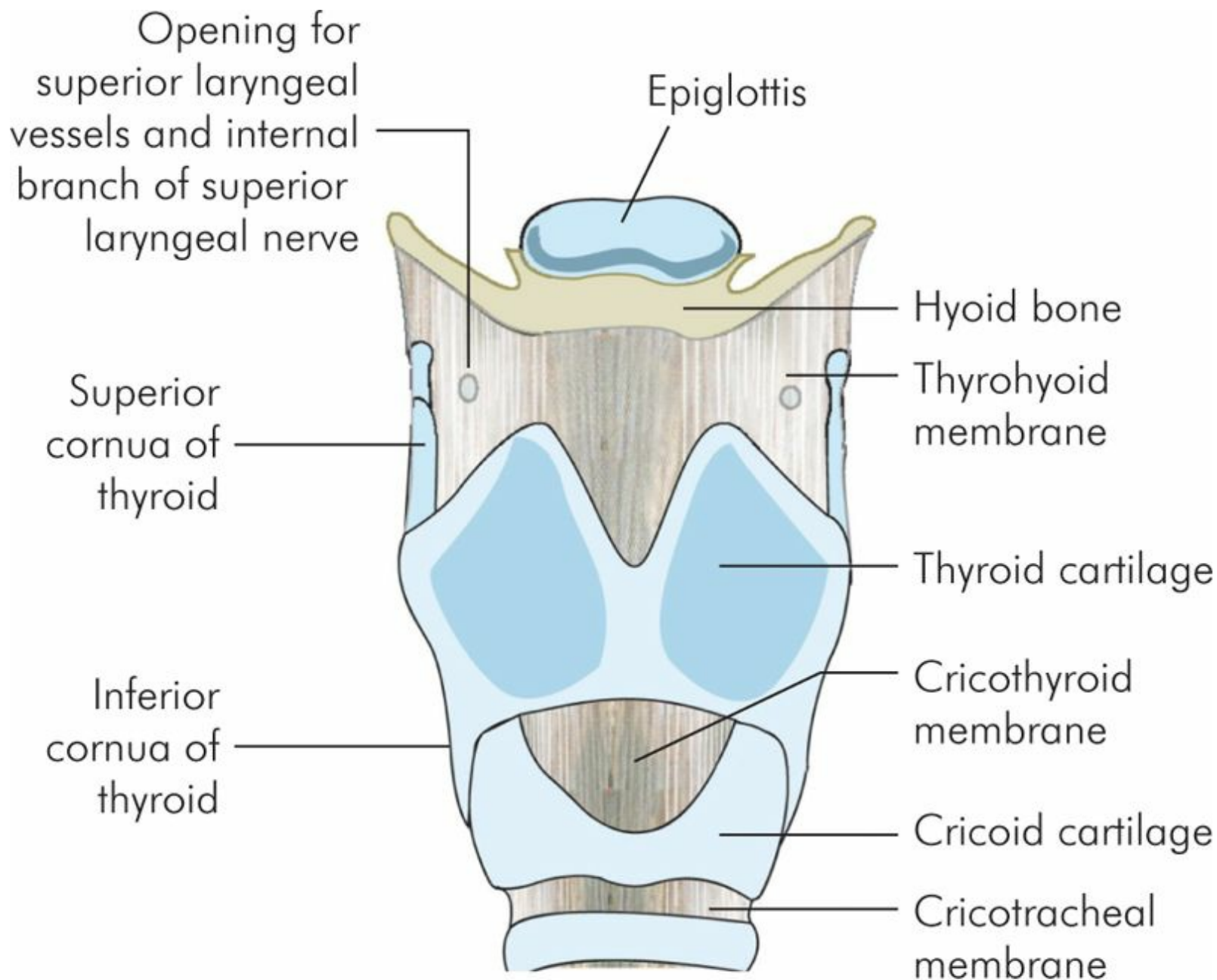
### ANATOMY OF LARYNX

The larynx lies in front of the hypopharynx opposite the third to sixth cervical vertebrae. It moves vertically and in anteroposterior direction during swallowing and phonation. It can also be passively moved from side to side producing a characteristic grating sensation called *laryngeal crepitus*. In an adult, the larynx ends at the lower border of C<sub>6</sub> vertebra.

# Laryngeal Cartilages

Larynx has 3 unpaired and 3 paired cartilages.

*Unpaired:* Thyroid, cricoid, epiglottis.



Dhingra: Diseases of Ear Nose and Throat, 5th Edition  
Copyright © 2010 Elsevier. All rights reserved.

Figure 55.1 Laryngeal framework.

*Paired:* Arytenoid, corniculate, cuneiform.

- **1. Thyroid** It is the largest of all (Fig. 55.1). Its two alae meet anteriorly forming an angle of  $90^\circ$  in males and  $120^\circ$  in females. Vocal cords are attached to the middle of thyroid angle. Most of laryngeal foreign bodies are arrested above the vocal cords, i.e. above the middle of thyroid cartilage and an effective airway can be provided by piercing the cricothyroid membrane—a procedure called *cricothyrotomy*.
- **2. Cricoid** It is the only cartilage forming a complete ring. Its posterior part is expanded to form a *lamina* while anteriorly it is narrow forming an *arch*.
- **3. Epiglottis** It is a leaf-like, yellow, elastic cartilage forming anterior wall of laryngeal inlet. It is attached to the body of hyoid bone by hyoepiglottic ligament which divides it into suprahyoid and infrahyoid epiglottis. A stalk-like process of epiglottis (petiole) attaches the epiglottis to the thyroid angle. Anterior surface of epiglottis is separated from thyrohyoid membrane and upper part of thyroid cartilage by a potential space filled with fat—the pre-epiglottic space. The space may be invaded in carcinoma of supraglottic larynx or the base of tongue.
- **4. Arytenoid cartilages** They are paired. Each arytenoid cartilage is pyramidal in shape. It has a *base* which articulates with cricoid cartilage; a *muscular process*, directed laterally to give attachment to intrinsic laryngeal muscles; a *vocal process* directed anteriorly, giving attachment to vocal cord; and an *apex* which supports the corniculate cartilage.

- **5. Corniculate cartilages (of Santorini)** They are paired. Each articulates with the apex of arytenoid cartilage.
- **6. Cuneiform cartilages (of Wrisberg)** They are rod shaped. Each is situated in aryepiglottic fold in front of corniculate cartilage and provides passive supports to the fold.

Thyroid, cricoid and most of the arytenoid cartilages are hyaline cartilages whereas epiglottis, corniculate, cuneiform and tip of arytenoid near the corniculate cartilage are fibroelastic in nature. Hyaline cartilages can undergo ossification; it begins at the age of 25 years in thyroid, a little later in cricoid and arytenoids, and is complete by 65 years of age.

# Laryngeal Joints

## ***Cricoarytenoid joint***

It is a synovial joint surrounded by capsular ligament. It is formed between the base of arytenoid and a facet, on the upper border of cricoid lamina. Two types of movements occur in this joint: (a) *rotatory*, in which arytenoid cartilage moves around a vertical axis, thus abducting or adducting the vocal cord; (b) *gliding movement*, in which one arytenoid glides towards the other cartilage or away from it, thus closing or opening the posterior part of glottis.

## ***Cricothyroid joint***

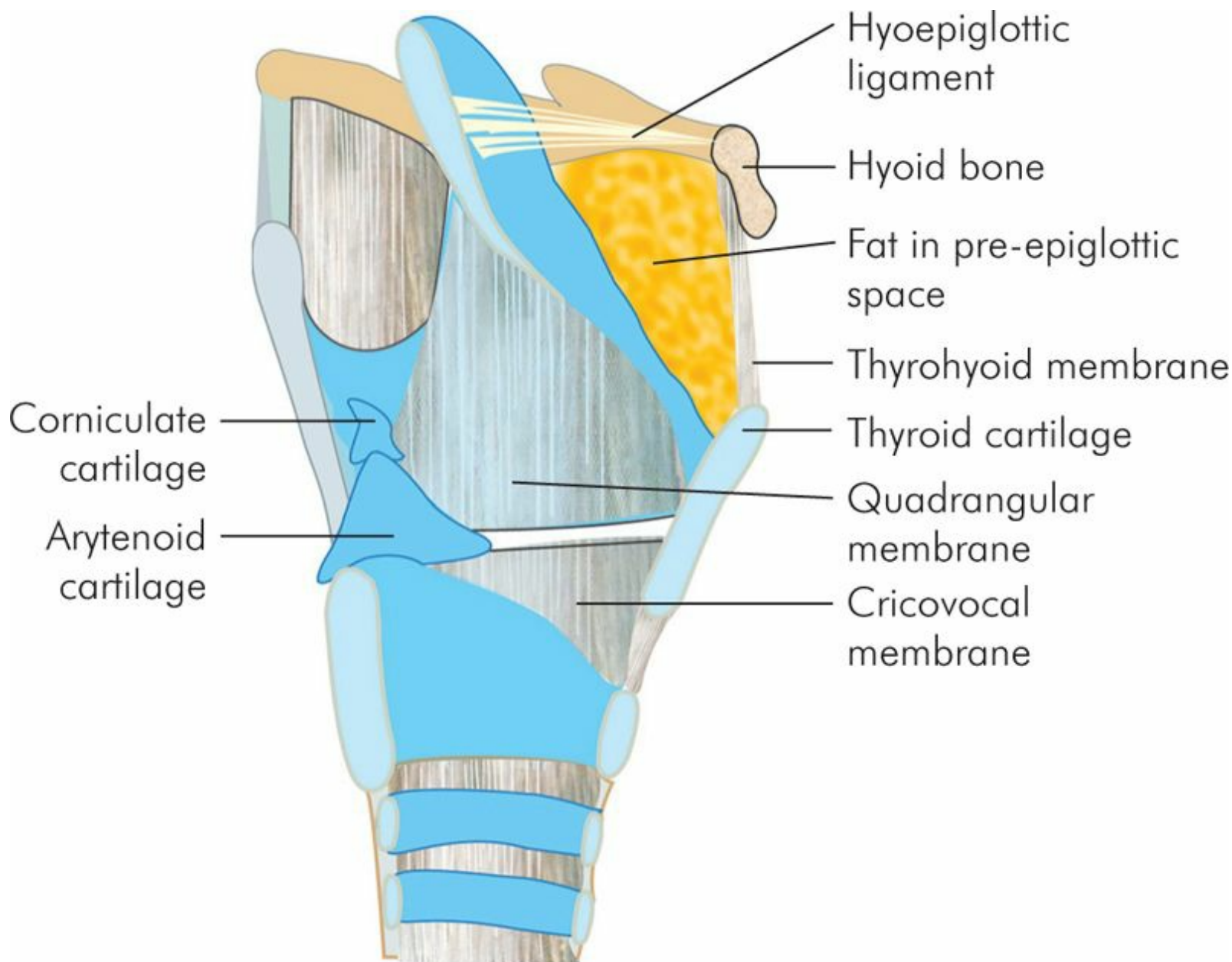
It is also a synovial joint. Each is formed by the inferior cornua of thyroid cartilage with a facet on the cricoid cartilage.

# Laryngeal Membranes

## 1. Extrinsic Membranes (Fig. 55.1)

- (a) **Thyrohyoid membrane** Connects thyroid cartilage to hyoid bone. It is pierced by superior laryngeal vessels and internal laryngeal nerve.
- (b) **Cricothyroid membrane** Connects thyroid cartilage to cricoid cartilage.
- (c) **Cricotracheal membrane** Connects cricoid cartilage to the first tracheal ring.

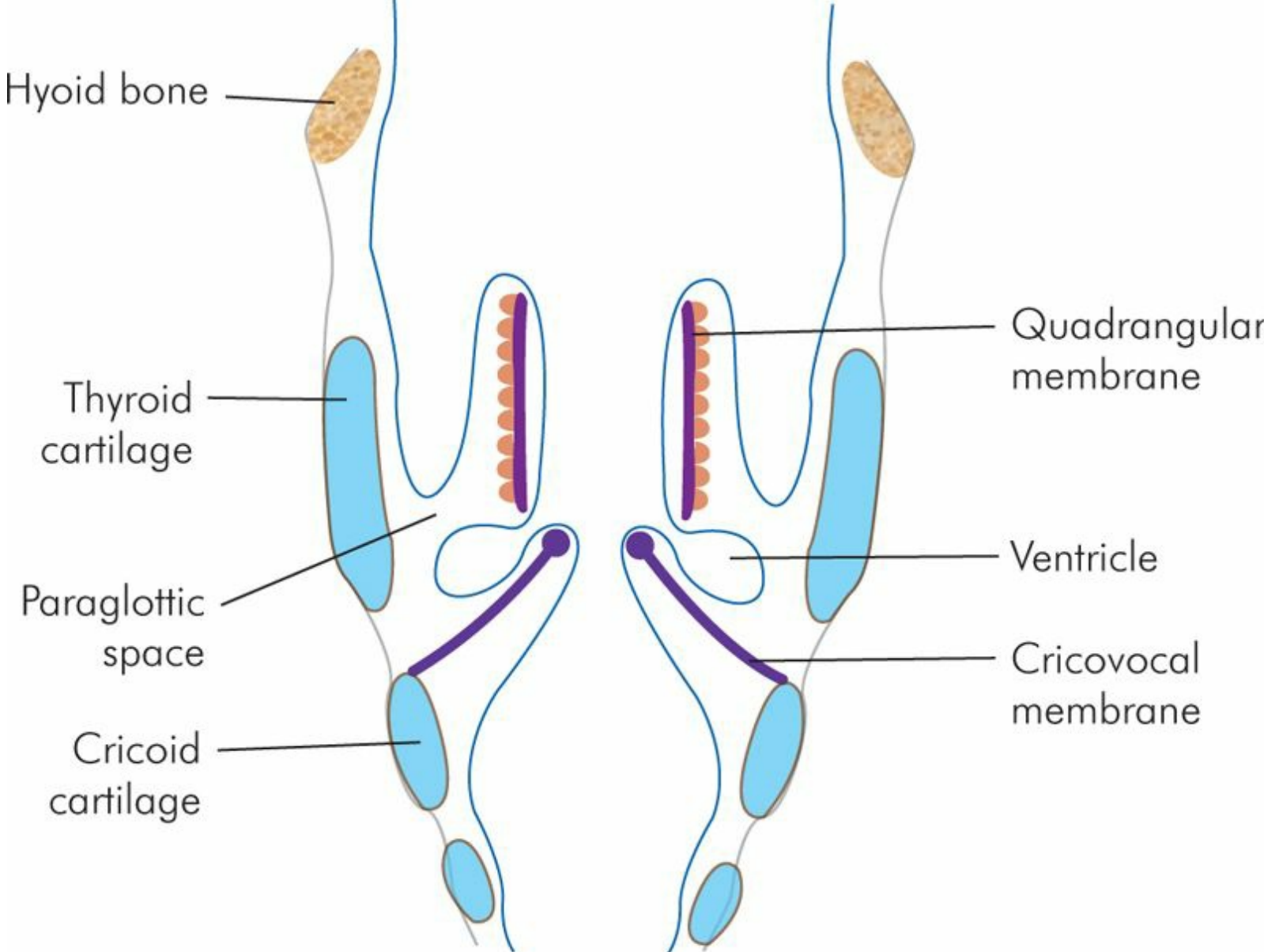
## 2. Intrinsic Membranes



Dhingra: Diseases of Ear Nose and Throat, 5th Edition  
Copyright © 2010 Elsevier. All rights reserved.

Figure 55.2 Sagittal section of larynx showing cricovocal and quadrangular membranes and boundaries of the pre-epiglottic space.

- (a) **Cricovocal membrane** It is a triangular fibroelastic membrane. Its upper border is free and stretches between middle of thyroid angle to the vocal process of arytenoid and forms the vocal ligament (Fig. 55.2). Its lower border attaches to the arch of cricoid cartilage. From its lower attachment the membrane proceeds upwards and medially and thus, with its fellow on the opposite side, forms conus elasticus (Fig. 55.3) where subglottic foreign bodies sometimes get impacted.
- (b) **Quadrangular membrane** It lies deep to mucosa of aryepiglottic folds and is not well defined. It stretches between the epiglottic and arytenoid cartilages. Its lower border forms the vestibular ligament which lies in the false cord.



Dhingra: Diseases of Ear Nose and Throat, 5th Edition  
 Copyright © 2010 Elsevier. All rights reserved.

Figure 55.3 Coronal section of larynx. Lower free edge of the quadrangular membrane lies in the false cord while upper free edge of the cricovocal membrane forms the vocal ligament. Note formation of conus elasticus by the cricovocal membranes of two sides.

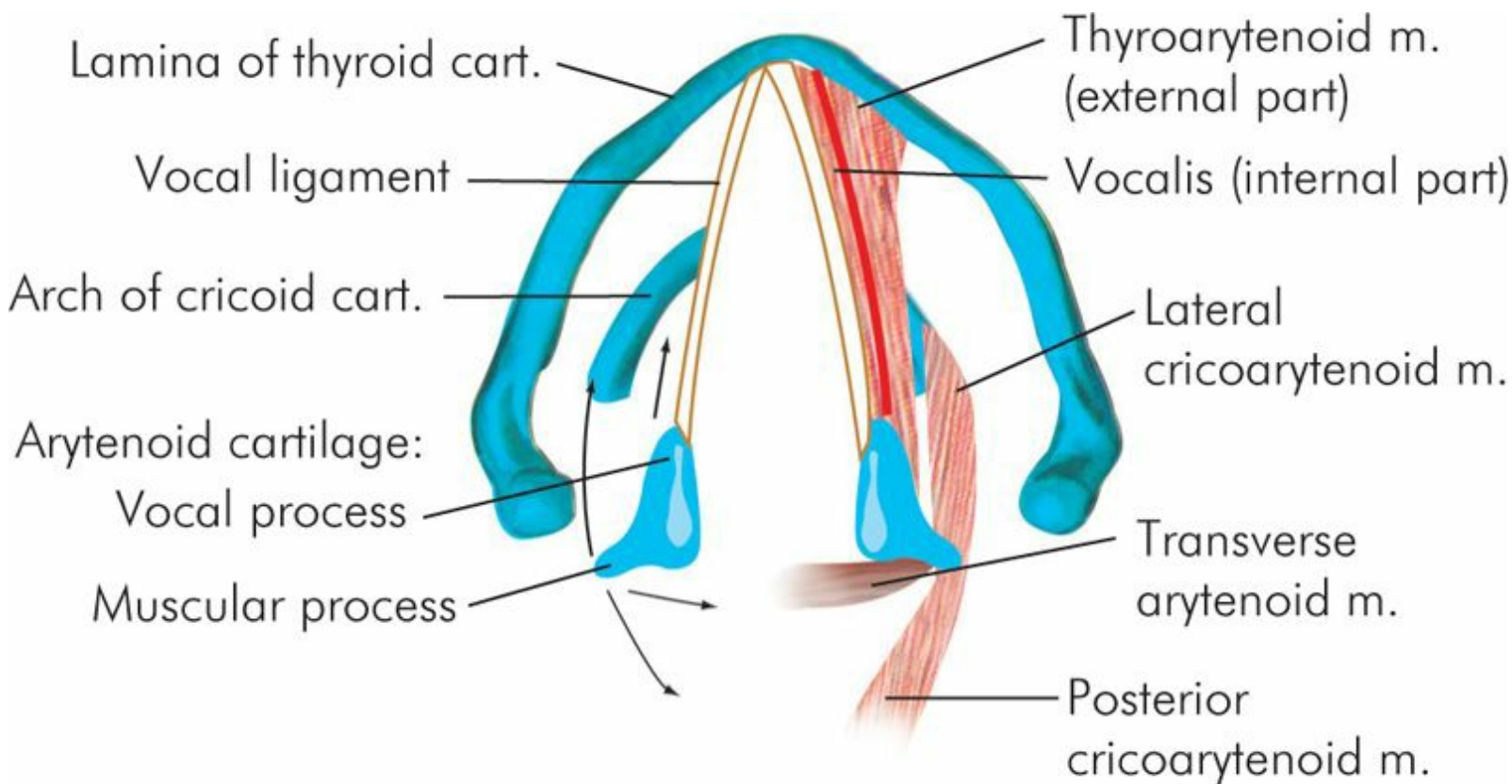


# Muscles of Larynx

<b>1. Intrinsic muscles</b> They may act on vocal cords or laryngeal inlet.	
<b>(a) Acting on vocal cords</b> (Figs 55.4 and 55.5)	
<i>Abductors:</i>	Posterior cricoarytenoid
<i>Adductors:</i>	Lateral cricoarytenoid
	Interarytenoid (transverse arytenoid)
	Thyroarytenoid (external part)
<i>Tensors:</i>	Cricothyroid
	Vocalis (internal part of thyroarytenoid)
<b>(b) Acting on laryngeal inlet</b> (Fig. 55.5)	
<i>Openers of laryngeal inlet:</i>	Thyroepiglottic (part of thyroarytenoid)
<i>Closers of laryngeal inlet:</i>	Interarytenoid (oblique part) Aryepiglottic (posterior oblique part of interarytenoids)

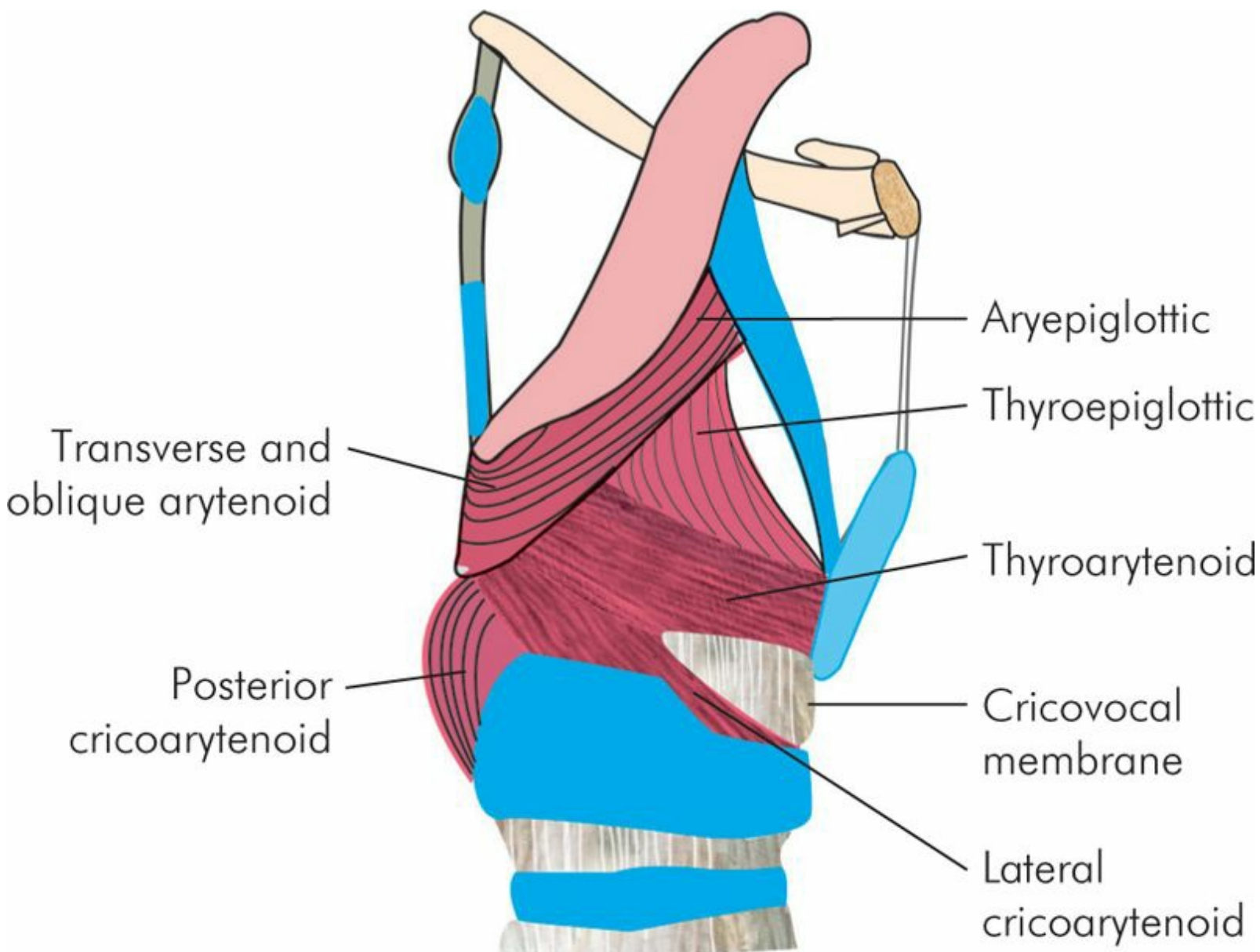
They are of two types, intrinsic, which attach laryngeal cartilages to each other, and extrinsic, which attach larynx to the surrounding structures.

- 2. Extrinsic muscles** They connect the larynx to the neighbouring structures and are divided into elevators or depressors of larynx.
  - (a) Elevators** *Primary elevators* act directly as they are attached to the thyroid cartilage and include stylopharyngeus, salpingopharyngeus, palatopharyngeus and thyrohyoid. *Secondary elevators* act indirectly as they are attached to the hyoid bone and include mylohyoid (main), digastric, stylohyoid, geniohyoid.
  - (b) Depressors** They include sternohyoid, sterno-thyroid and omohyoid.



Dhingra: Diseases of Ear Nose and Throat, 5th Edition  
Copyright © 2010 Elsevier. All rights reserved.

Figure 55.4 Laryngeal muscles and their action.



Dhingra: Diseases of Ear Nose and Throat, 5th Edition  
 Copyright © 2010 Elsevier. All rights reserved.

Figure 55.5 Intrinsic muscles of larynx as seen on lateral view.

# Cavity of the Larynx

Laryngeal cavity starts at the laryngeal inlet where it communicates with the pharynx and ends at the lower border of cricoid cartilage where it is continuous with the lumen of trachea. Two pairs of folds-vestibular and vocal, divide the cavity into three parts, namely the vestibule, the ventricle and the subglottic space.

## ***Inlet of larynx***

It is an oblique opening bounded anteriorly by free margin of epiglottis; on the sides, by aryepiglottic folds and posteriorly by interarytenoid fold (Fig. 55.6).

## ***Vestibule***

It extends from laryngeal inlet to vestibular folds. Its anterior wall is formed by posterior surface of epiglottis; sides by the aryepiglottic folds and posterior wall by mucous membrane over the anterior surface of arytenoids.

## ***Ventricle (sinus of larynx)***

is a deep elliptical space between vestibular and vocal folds, also extending a short distance above and lateral to vestibular fold. The saccule is a diverticulum of mucous membrane which starts from the anterior part of ventricular cavity and extends upwards between vestibular folds and lamina of thyroid cartilage. When abnormally enlarged and distended, it may form a *laryngocele*-an air containing sac which may present in the neck. There are many mucous glands in the saccule.

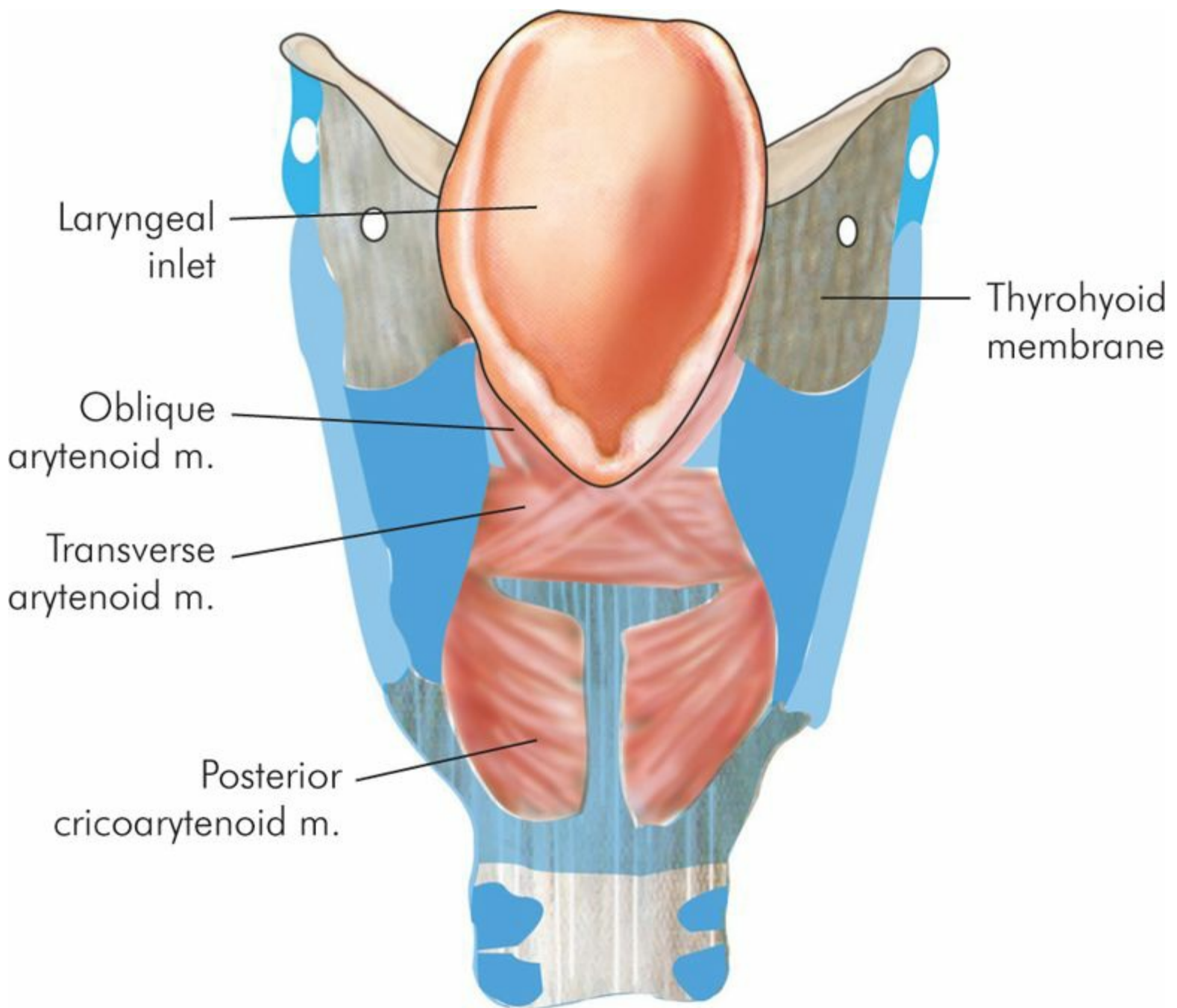
## ***Subglottic space (infraglottic larynx)***

It extends from vocal cords to lower border of cricoid cartilage.

## ***Vestibular folds (false vocal cords)***

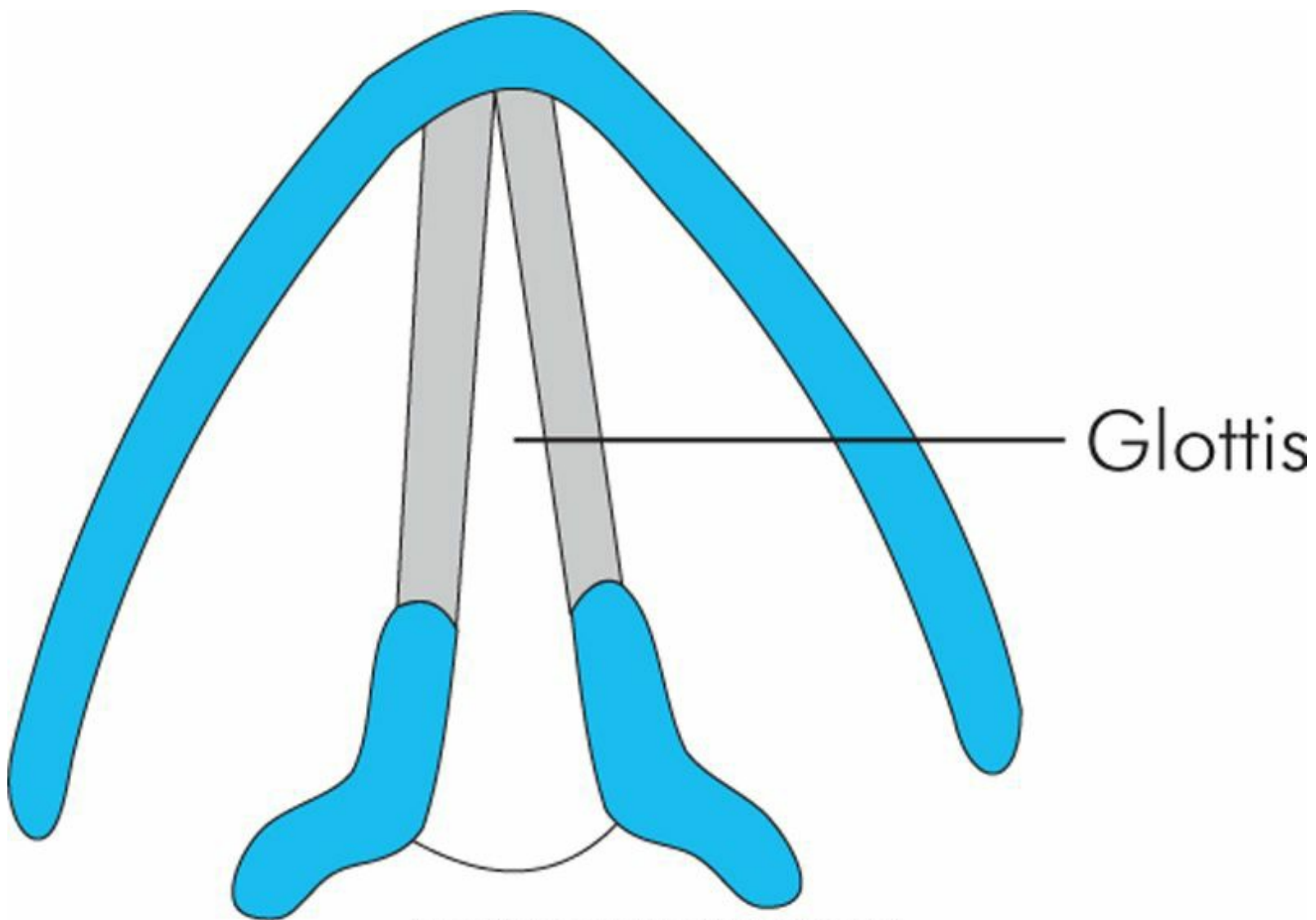
Two in number; each is a fold of mucous membrane extending anteroposteriorly across the laryngeal cavity. It contains vestibular ligament, a few fibres of thyroarytenoideus muscle and mucous glands.

## ***Vocal folds (true vocal cords)***



Dhingra: Diseases of Ear Nose and Throat, 5th Edition  
 Copyright © 2010 Elsevier. All rights reserved.

Figure 55.6 Laryngeal inlet and intrinsic muscles of larynx as seen from behind.



Dhingra: Diseases of Ear Nose and Throat, 5th Edition  
Copyright © 2010 Elsevier. All rights reserved.

Figure 55.7 Rima glottidis. Note anterior 2/3 of vocal cord is membranous and posterior 1/3 cartilaginous.

They are two pearly-white sharp bands extending from the middle of thyroid angle to the vocal processes of arytenoids. Each vocal cord consists of a vocal ligament which is the true upper edge of cricovocal membrane covered by closely bound mucous membrane with scanty subepithelial connective tissue.

**Glottis (rima glottidis)**

It is the elongated space between vocal cords anteriorly, and vocal processes and base of arytenoids posteriorly (Fig. 55.7).

Anteroposteriorly, glottis is about 24 mm in men and 16 mm in women. It is the narrowest part of laryngeal cavity. Anterior two-thirds of glottis are formed by membranous cords while posterior one-third by vocal processes of arytenoids. Size and shape of glottis varies with the movements of vocal cords.

## Mucous Membrane of the Larynx

It lines the larynx and is loosely attached except over the posterior surface of epiglottis, true vocal cords and corniculate and cuneiform cartilages.

*Epithelium* of the mucous membrane is ciliated columnar type except over the vocal cords and upper part of the vestibule where it is stratified squamous type.

*Mucous glands* are distributed all over the mucous lining and are particularly numerous on the posterior surface of epiglottis, posterior part of the aryepiglottic folds and in the saccules. There are no mucous glands in the vocal folds.

## Lymphatic Drainage

Supraglottic larynx *above the vocal cords* is drained by lymphatics which pierce the thyrohyoid membrane and go to upper deep cervical nodes.

Infraglottic larynx *below the vocal cords* is drained by lymphatics which pierce cricothyroid membrane and go to prelaryngeal and pretracheal nodes and thence to lower deep cervical and mediastinal nodes. Some vessels pierce through cricotracheal membrane and drain directly into lower deep cervical nodes.

There are practically no lymphatics in vocal cords, hence carcinoma of this site rarely shows lymphatic metastases.

Nerve Supply (see page 317)

## **Spaces of the Larynx**

### **1. Pre-epiglottic space of Boyer (Figs 55.2 and 55.8)**

It is bounded by upper part of thyroid cartilage and thyrohyoid membrane in front, hyoepiglottic ligament above and infrahyoid epiglottis and quadrangular membrane behind. Laterally, it is continuous with paraglottic space. It is filled with fat, areolar tissue and some lymphatics.

### **2. Paraglottic space**

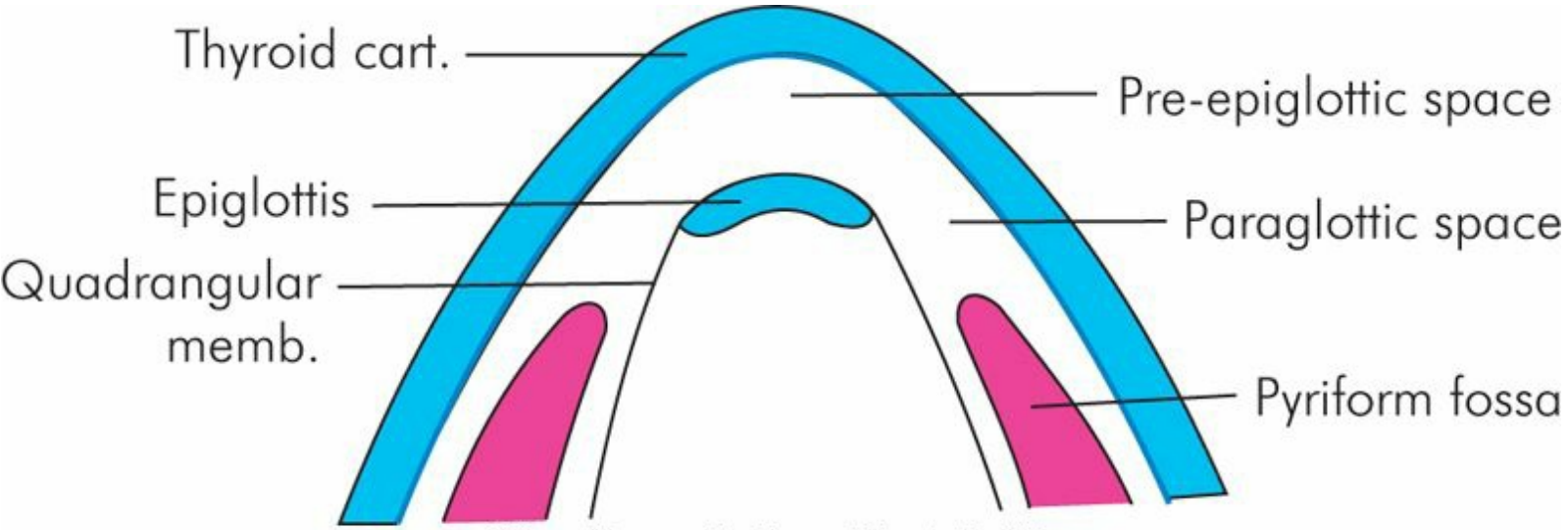
It is bounded by the thyroid cartilage laterally, conus elasticus inferomedially, the ventricle and quadrangular membrane medially, and mucosa of pyriform fossa posteriorly (Figs 55.3 and 55.8). It is continuous with pre-epiglottic space. Growths which invade this space can present in the neck through cricothyroid space.

### **3. Reinke's space**

Under the epithelium of vocal cords is a potential space with scanty subepithelial connective tissues. It is bounded above and below by the arcuate lines; in front, by anterior commissure, and behind by vocal process of arytenoid. Oedema of this space causes fusiform swelling of the membranous cords (Reinke's oedema).



# EMBRYOLOGICAL DEVELOPMENT



Dhingra: Diseases of Ear Nose and Throat, 5th Edition  
 Copyright © 2010 Elsevier. All rights reserved.

Figure 55.8 Paraglottic and pre-epiglottic spaces communicate with each other.

Epiglottis	Hypobranchial eminence
Upper part of thyroid cartilage	4th arch
Lower part of thyroid cartilage	6th arch
Cricoid cartilage	
Corniculate cartilage	
Cuneiform cartilage	
Intrinsic muscles of larynx	
Upper part of body of hyoid bone	2nd arch
Lesser cornua of hyoid bone	
Stylohyoid ligament	3rd arch
Lower part of body of hyoid bone and greater cornua	

Laryngeal mucosa develops from the endoderm of the cephalic part of foregut. Laryngeal cartilages and muscles develop from the mesenchyme. Development of other structures is as follow:

Superior laryngeal nerve, a branch of vagus, is 4th arch nerve and supplies cricothyroid and constrictors of pharynx.

Recurrent laryngeal nerve is 6th arch nerve and supplies all the intrinsic muscles of larynx.

# PAEDIATRIC LARYNX

The larynx of an infant differs considerably from that of an adult and has a great clinical significance.

- **1.** Infant's larynx is positioned high in the neck opposite C3 or C4 (level of vocal cords) at rest and reaches C1 or C2 during swallowing. This high position allows the epiglottis to meet soft palate and make a nasopharyngeal channel for nasal breathing during suckling. The milk feed passes separately over the dorsum of tongue and the side of epiglottis, thus allowing breathing and feeding to go on simultaneously.
- **2.** Laryngeal cartilages are soft and collapse easily. Epiglottis is omega-shaped and arytenoids relatively large covering significant portion of the posterior glottis.
- **3.** Thyroid cartilage in an infant is flat. It also overlaps the cricoid cartilage and is in turn overlapped by the hyoid bone. Thus cricothyroid and thyrohyoid spaces are narrow and not easily discernible as landmarks when performing tracheostomy.
- **4.** Infant's larynx is small and *conical*. The diameter of cricoid cartilage is smaller than the size of glottis, making subglottis the narrowest part. It has a bearing in the selection of paediatric endotracheal tube. In adults, subglottic-glottic dimensions are approximately same and larynx is *cylindrical*.
- **5.** Submucosal tissues of infant's larynx are comparatively loose and easily undergo oedematous change with trauma or inflammation leading to obstruction.

Infant's larynx shows two spurts in growth. In the first three years of life larynx grows in width and length, and thus obviates the need for any airway surgery in certain congenital anomalies. The second spurt in growth occurs during adolescence when the thyroid angle develops. The length of vocal cords then increases leading to voice changes associated with puberty (see puberphonia). With growth of the neck, larynx gradually descends to adult; the vocal cords lying opposite C<sub>5</sub>.

In childhood, vocal cord is 6 mm in females and 8 mm in males. It increases to 15-19 mm in adult female and 17-23 in adult male.

# PHYSIOLOGY OF LARYNX

The larynx performs the following important functions:

- 1. Protection of lower airways
- 2. Phonation
- 3. Respiration
- 4. Fixation of the chest.

# 1. Protection of Lower Airways

Phylogenetically, this is the earliest function to develop; voice production is secondary. The larynx protects the lower passages in three different ways:

- **(a)** Sphincteric closure of laryngeal opening.
- **(b)** Cessation of respiration.
- **(c)** Cough reflex.

When food is swallowed, its entry into air passage is prevented by closure of three successive sphincters consisting of (i) laryngeal inlet (aryepiglottic folds, tubercle of epiglottis and arytenoids, approximately closing the laryngeal inlet completely), (ii) false cords, (iii) true cords, which close the glottis. Thus, no foreign matter meant to be swallowed or accidentally vomited can enter the larynx.

Respiration temporarily ceases through a reflex generated by afferent fibres of ninth nerve, when food comes in contact with posterior pharyngeal wall or the base of tongue.

Cough is an important and powerful mechanism to dislodge and expel a foreign particle when it comes into contact with respiratory mucosa. Larynx is aptly called the *watch-dog of lungs* as it immediately 'barks' at the entry of any foreign intruder.

## 2. Phonation

Larynx is like a wind instrument. Voice is produced by the following mechanism (*Aerodynamic myoelastic theory of voice production*):

- **(a)** Vocal cords are kept adducted.
- **(b)** Infraglottic air pressure is generated by the exhaled air from the lungs due to contraction of thoracic and abdominal muscles.
- **(c)** The air force open the cords and is released as small puffs which vibrate the vocal cords and produce sound which is amplified by mouth, pharynx, nose and chest.

This sound is converted into speech by the modulatory action of lips, tongue, palate, pharynx, and teeth.

---

page 303

page 304

Intensity of sound depends on the air pressure produced by the lungs while pitch depends on the frequency with which the vocal cords vibrate.

### 3. Respiration

Larynx regulates flow of air into the lungs. Vocal cords abduct during inspiration and adduct during expiration.

#### 4. Fixation of the Chest

When larynx is closed, chest wall gets fixed and various thoracic and abdominal muscles can then act best. This function is important in digging, pulling and climbing. Coughing, vomiting, defaecation, micturition and childbirth also require a fixed thoracic cage against a closed glottis.

## 56 Laryngotracheal Trauma

### Aetiology

- 1. Most common cause is automobile accidents when neck strikes against the steering wheel or the instrument panel.
- 2. Blow or kick on the neck.
- 3. Neck striking against a stretched wire or cable.
- 4. Strangulation.
- 5. Penetrating injuries with sharp instruments or gun shot wounds.



# Pathology

The degree and severity of damage will vary from slight bruises externally or the tear and laceration of mucosa internally to a comminuted fracture of the laryngeal framework. The wound may be compounded externally, due to break in the skin, or internally by mucosal tears. Laryngeal fractures are common after 40 years of age because of calcification of the laryngeal framework. In children, cartilages are more resilient and escape injury.

Pathological changes that may be seen in laryngeal trauma are:

- 1. Haematoma and oedema of supraglottic or subglottic region.
- 2. Tears in laryngeal or pharyngeal mucosa leading to subcutaneous emphysema.
- 3. Dislocation of cricoarytenoid joints. The arytenoid cartilage may be displaced anteriorly, dislocated or avulsed.
- 4. Dislocation of cricothyroid joint. This may cause recurrent laryngeal nerve paralysis which traverses just behind this joint.
- 5. Fractures of the hyoid bone.
- 6. Fractures of thyroid cartilage. They may be vertical or transverse. Fracture of upper part of thyroid cartilage may result in avulsion of epiglottis and one or both false cords. Fractures of lower part of thyroid cartilage may displace or disrupt the true vocal cords.
- 7. Fractures of cricoid cartilage.
- 8. Fractures of upper tracheal rings.
- 9. Trachea may separate from the cricoid cartilage and retract into upper mediastinum. Injury to recurrent laryngeal nerve is often associated with laryngotracheal separation.

## Clinical Features

Symptoms of laryngotracheal injury would vary, greatly depending on the structures damaged and the severity of damage. They include:

- 1. Respiratory distress.
- 2. Hoarseness of voice or aphonia.
- 3. Painful and difficult swallowing. This is accompanied by aspiration of food.
- 4. Local pain in the larynx. More marked on speaking or swallowing.
- 5. Haemoptysis, usually the result of tears in laryngeal or tracheal mucosa.

*External signs* include:

- 1. Bruises or abrasions over the skin.
- 2. Palpation of the laryngeal area is painful.
- 3. Subcutaneous emphysema due to mucosal tears. It may increase on coughing.
- 4. Flattening of thyroid prominence and contour of anterior cervical region. Thyroid notch may not be palpable.
- 5. Fracture displacements of thyroid or cricoid cartilage or hyoid bone. Gap may be felt between the fractured fragments.
- 6. Bony crepitus between fragments of hyoid bone, thyroid or cricoid cartilages, may sometimes be elicited.
- 7. Separation of cricoid cartilage from larynx or trachea.

## Diagnostic Evaluation

- **1. Indirect laryngoscopy** If patient's condition permits, this is the most valuable examination. It may reveal location and degree of oedema, haematoma, mucosal lacerations, posterior displacement of epiglottis, exposed fragments of cartilage, asymmetry of glottis or laryngeal inlet.
- **2. Direct laryngoscopy** It is rarely informative in early period following injury. If performed, it may precipitate respiratory distress and necessitate immediate tracheostomy. Fibre optic laryngoscopy gives improved visualisation and has replaced direct laryngoscopy in recent years.
- **3. X-rays** Soft tissue lateral film of the neck is very useful and may reveal subcutaneous emphysema, swelling of laryngeal mucosa, displacement of epiglottis, fracture displacements of hyoid bone, thyroid and cricoid cartilages or change in the configuration of air column.
- **4. CT scan** It is very valuable in assessing moderately severe or severe injuries of larynx. Presently three dimensional CT is found more useful in laryngeal trauma.
- **5. Associated injuries** It is essential to examine for other injuries like injury to head, cervical spine, chest, abdomen and extremities. X-ray chest for pneumothorax and gastrograffin swallow for oesophageal tears may be required.

# Treatment

## Conservative

- 1. Patient should be hospitalised and observed for respiratory distress.
- 2. Voice rest is essential.
- 3. Humidification of inspired air is essential.
- 4. Steroid therapy should be started immediately and in full dose. It helps to resolve oedema and haematoma and prevent scarring and stenosis.
- 5. Antibiotics are given to prevent perichondritis and cartilage necrosis.

## Surgical

- 1. *Tracheostomy* Endotracheal intubation in cases of laryngeal trauma may be difficult and hazardous. Tracheostomy is preferred in these cases.
- 2. *Open reduction* Ideally, it is done 3-5 days after injury and if possible should not be delayed beyond 10 days.
  - (a) Fractures of hyoid bone, thyroid or cricoid cartilage can be wired and replaced in their anatomic positions. Miniplates made of titanium can be used for immobilisation of cartilaginous fragments.
  - (b) Mucosal lacerations are repaired with catgut and any loose fragments of cartilage removed.
  - (c) Epiglottis is anchored in its normal position and if already avulsed, may be excised.
  - (d) Arytenoid cartilages can be repositioned in their normal position or may be removed if completely avulsed.
  - (e) In laryngotracheal separation, end to end anastomosis can be done.
  - (f) Internal splintage of laryngeal structures may be required. It is done with a laryngeal stent, or silicone tube which may have to be left for 2 to 6 weeks on an average.
  - (g) Webbing of anterior commissure can be prevented by a silastic keel.

## Complications

- 1. Laryngeal stenosis, which may be supraglottic, glottic or subglottic.
- 2. Perichondritis and laryngeal abscess.
- 3. Vocal cord paralysis.

## **57 Acute and Chronic Inflammations of Larynx**

### **ACUTE LARYNGITIS**

Acute laryngitis may be infectious or non-infectious.

## Aetiology

The *infectious type* is more common and usually follows upper respiratory infection. To begin with, it is viral in origin but soon bacterial invasion takes place with *Strept. pneumoniae*, *H. influenzae* and haemolytic *streptococci* or *Staph. aureus*. Exanthematous fevers like measles, chickenpox and whooping cough are also associated with laryngitis.

The *non-infectious type* is due to vocal abuse, allergy, thermal or chemical burns to larynx due to inhalation or ingestion of various substances, or laryngeal trauma such as endotracheal intubation.

# Clinical Features

*Symptoms* are usually abrupt in onset and consist of:

- 1. Hoarseness which may lead to complete loss of voice.
- 2. Discomfort or pain in throat, particularly after talking.
- 3. Dry, irritating cough which is usually worse at night.
- 4. General symptoms of head, cold, rawness or dryness of throat, malaise and fever if laryngitis has followed viral infection of upper respiratory tract.

*Laryngeal appearances* vary with severity of disease. In early stages, there is erythema and oedema of epiglottis, aryepiglottic folds, arytenoids and ventricular bands, but the vocal cords appear white and near normal and stand out in contrast to surrounding mucosa, betraying the degree of hoarseness patient has. Later, hyperaemia and swelling increase. Vocal cords also become red and swollen. Subglottic region also gets involved. Sticky secretions are seen between the cords and interarytenoid region. In case of vocal abuse, submucosal haemorrhages may be seen in the vocal cords.



## Treatment

- **1. Vocal rest.** This is the most important single factor. Use of voice during acute laryngitis may lead to incomplete or delayed recovery.
- **2. Avoidance** of smoking and alcohol.
- **3. Steam inhalations** with Tr. Benzoin Co, oil of eucalyptus or pine are soothing and loosen viscid secretions.
- **4. Cough sedative.** To suppress troublesome irritating cough.
- **5. Antibiotics.** When there is secondary infection with fever and toxemia or purulent expectoration.
- **6. Analgesics.** To relieve local pain and discomfort.
- **7. Steroids.** Useful in laryngitis following thermal or chemical burns.

### ***Acute membranous laryngitis***

This condition is similar to acute membranous tonsillitis and is caused by pyogenic non-specific organisms. It may begin in the larynx or may be an extension from the pharynx. It should be differentiated from laryngeal diphtheria.

## **ACUTE EPIGLOTTITIS (Syn. Supraglottic Laryngitis)**

It is an acute inflammatory condition confined to supraglottic structures, i.e. epiglottis, aryepiglottic folds and arytenoids. There is marked oedema of these structures which may obstruct the airway.

## Aetiology

It is a serious condition and affects children of 2-7 years of age but can also affect adults. *H. influenzae* B is the most common organism responsible for this condition in children.

## Clinical Features

- 1. Onset of symptoms is abrupt with rapid progression.
- 2. Sore throat and dysphagia are the common presenting symptoms in adults.
- 3. Dyspnoea and stridor are the common presenting symptoms in children. They are rapidly progressive and may prove fatal unless relieved.
- 4. Fever may go up to 40°C. It is due to septicaemia. Patient's condition may rapidly deteriorate.

## Examination

- **1.** Depressing the tongue with a tongue depressor may show red and swollen epiglottis. Indirect laryngoscopy may show oedema and congestion of supraglottic structure. This examination is avoided for fear of precipitating complete obstruction. It is better done in operation theatre where facilities for intubation are available.
- **2.** Lateral soft tissue X-ray of neck may show swollen epiglottis (thumb sign).

## Treatment

- **1. Hospitalisation.** Essential because of the danger of respiratory obstruction.
- **2. Antibiotics.** Ampicillin or third generation cephalosporin are effective against *H. influenzae* and are given by parenteral route (i.m. or i.v.) without waiting for results of throat swab and blood culture.
- **3. Steroids.** Hydrocortisone or dexamethasone is given in appropriate doses i.m. or i.v. They relieve oedema and may obviate need for tracheostomy.
- **4. Adequate hydration.** Patient may require parenteral fluids.
- **5. Humidification and oxygen.** Patient may require mist tent or a croupette.
- **6. Intubation or tracheostomy** may be required for respiratory obstruction.

## **ACUTE LARYNGO-TRACHEO-BRONCHITIS**

It is an inflammatory condition of the larynx, trachea and bronchi; more common than acute epiglottitis.

## Aetiology

Mostly, it is viral infection (parainfluenza type I and II) affecting children between 6 months to 3 years of age.

Male children are more often affected. Secondary bacterial infection by Gram positive cocci soon supervenes.



## Pathology

The loose areolar tissue in the subglottic region swells up and causes respiratory obstruction and stridor. This, coupled with thick tenacious secretions and crusts, may completely occlude the airway.

## Symptomatology

Disease starts as upper respiratory infection with hoarseness and croupy cough. There is fever of 39-40°C. This may be followed by difficulty in breathing and inspiratory type of stridor. Respiratory difficulty may gradually increase with signs of upper airway obstruction, i.e. suprasternal and intercostal recession. Differences between acute epiglottitis and acute laryngo-tracheo-bronchitis are given in Table 57.1.

## Treatment

- 1. *Hospitalisation* is often essential because of the increasing difficulty in breathing.
- 2. *Antibiotics* like ampicillin 50 mg/kg/day in divided doses is effective against secondary infections due to gram-positive cocci and *H. influenzae*.
- 3. *Humidification* helps to soften crusts and tenacious secretions which block tracheobronchial tree.
- 4. *Parenteral fluids* are essential to combat dehydration.
- 5. *Steroids*, e.g. hydrocortisone 100 mg i.v. may be useful to relieve oedema.
- 6. *Adrenaline*, racemic adrenaline administered via a respirator is a bronchodilator and may relieve dyspnoea and avert tracheostomy.
- 7. *Intubation/tracheostomy* is done, should respiratory obstruction increase in spite of the above measures. Tracheostomy is done if intubation is required beyond 72 hours. Assisted ventilation may be required.

# LARYNGEAL DIPHTHERIA

## Aetiology

Mostly, it is secondary to faucial diphtheria affecting children below 10 years of age. Incidence of diphtheria in general is declining due to widespread use of immunisation.

page 308

page 309

**Table 57-1. Differences between acute epiglottitis and acute laryngo-tracheo-bronchitis in children**

Acute epiglottitis		Acute laryngo-tracheo-bronchitis (or group)
• Causative organism	<i>Haemophilus influenzae</i> type B	Parainfluenza virus type I and II
• Age	2-7 years	3 months to 3 years
• Pathology	Supraglottic larynx	Subglottic area
• Prodromal symptoms	Absent	Present
• Onset	Sudden	Slow
• Fever	High	Low grade or no fever
• Patient's look	Toxic	Non-toxic
• Cough	Usually absent	Present, (Barking seal-like)
• Stridor	Present and may be marked	Present
• Odynophagia	Present, with drooling of secretions	Usually absent
• Radiology	*Thumb sign on lateral view	Steeple sign on anteroposterior view of neck
• Treatment	Humidified oxygen, third generation cephalosporin (ceftriaxone) or amoxicillin	Humidified O <sub>2</sub> tent, steroids

\*Examination of larynx and radiographs are avoided lest complete obstruction is precipitated. Examination is done in the operation theatre where immediate intubation can be done.

# Pathology

Effects of laryngeal diphtheria are due to:

- 1. Formation of a tough pseudomembrane over the larynx and trachea which may completely obstruct the airway.
- 2. Exotoxin liberated by bacteria leading to myocarditis and various neurological complications.

## Clinical Features

*General symptoms.* Onset is insidious with low grade fever (100-101°F), sore throat and malaise but patient is very toxæmic with tachycardia and thready pulse.

*Laryngeal symptoms.* Hoarse voice, croupy cough, inspiratory stridor, increasing dyspnoea with marked upper airway obstruction.

*Membrane.* Greyish white membrane is seen on the tonsil, pharynx and soft palate. It is adherent and its removal leaves a bleeding surface. Similar membrane is seen over the larynx and trachea.

*Cervical lymphadenopathy.* Characteristic "bull-neck" may be seen.

## Diagnosis

Laryngeal diphtheria is mostly secondary to faucial diphtheria. Diagnosis is always clinical but confirmed by smear and culture of *Corynebacterium diphtheriae*. Treatment is started on clinical suspicion.

## Treatment

- **1. *Diphtheria antitoxin*.** Dose depends on clinical severity and duration of illness, and varies from 20,000 to 100,000 units i.v. route as saline infusion after a test dose. It neutralises free toxin circulating in the blood.
- **2. *Antibacterials*.** Benzylpenicillin, 500,000 units i.m. every 6 hours for 6 days, is effective against diphtheria bacilli. Erythromycin can be given to those who are allergic to penicillin.
- **3. *Maintenance of airway*.** Tracheostomy may become essential. Direct laryngoscopy, removal of diphtheritic membrane and intubation can be done. Intubation relieves respiratory obstruction and can make subsequent tracheostomy easy.
- **4. *Complete bed rest*.** Complete bed rest for 2-4 weeks is essential to guard against effects of myocarditis.



## Complications

- 1. Asphyxia and death due to airway obstruction.
- 2. Toxic myocarditis and circulatory failure.
- 3. Palatal paralysis with nasal regurgitation.
- 4. Laryngeal and pharyngeal paralysis.

# OEDEMA OF LARYNX

---

Often termed "*oedema glottidis*" in the past, it involves the supraglottic and subglottic region where laryngeal mucosa is loose. Oedema of the vocal cords occurs rarely because of the sparse subepithelial connective tissue.

# Aetiology

- **1. Infections**
  - (i) Acute epiglottitis, laryngo-tracheo-bronchitis, tuberculosis or syphilis of larynx.
  - (ii) Infection in neighbourhood, e.g. peritonsillar abscess, retropharyngeal abscess and Ludwig's angina.
- **2. Trauma** Surgery of tongue, floor of mouth, laryngeal trauma, foreign body, endoscopy especially in children, intubation, thermal or caustic burns or inhalation or irritant gases or fumes.
- **3. Neoplasms** Cancer of larynx or laryngopharynx often associated with deep ulceration.
- **4. Allergy** Angioneurotic oedema, anaphylaxis.
- **5. Radiation** For cancer of larynx or pharynx.
- **6. Systemic diseases** Nephritis, heart failure, or myxoedema.

## Symptoms and Signs

- **1. Airway obstruction** Degree of respiratory distress varies. Tracheostomy may become essential.
- **2. Inspiratory stridor.**
- **3. Indirect laryngoscopy** shows oedema of supraglottic or subglottic region. Children may require direct laryngoscopy.

## Treatment

If there is airway obstruction, intubation of larynx or tracheostomy will be immediately required. Less severe cases are treated conservatively and treatment will depend on the cause. An injection of adrenaline (1:1000) 0.3-0.5 ml i.m., repeated in 15 minutes if necessary, is useful in allergic or angioneurotic oedema. Steroids are useful in epiglottitis, laryngo-tracheo-bronchitis or oedema due to traumatic allergic or post-radiation causes.

# CHRONIC LARYNGITIS

## A. Chronic Laryngitis Without Hyperplasia (Chronic Hyperaemic Laryngitis)

It is a diffuse inflammatory condition symmetrically involving the whole larynx, i.e. true cords, ventricular bands, interarytenoid region and root of the epiglottis.

### Aetiology

- 1. It may follow incompletely resolved acute simple laryngitis or its recurrent attacks.
- 2. Presence of chronic infection in paranasal sinuses, teeth and tonsils and the chest are important contributory causes.
- 3. Occupational factors, e.g. exposure to dust and fumes such as in miners, stokers, gold or iron smiths and workers in chemical industries.
- 4. Smoking and alcohol.
- 5. Persistent trauma of cough as in chronic lung diseases.
- 6. Vocal abuse.

### Clinical Features

- 1. Hoarseness. This is the commonest complaint. Voice becomes easily tired and patient becomes aphonic by the end of the day.
- 2. Constant hawking. There is dryness and intermittent tickling in the throat and patient is compelled to clear the throat repeatedly.
- 3. Discomfort in the throat.
- 4. Cough. It is dry and irritating.

*Laryngeal examination* There is hyperaemia of laryngeal structures. Vocal cords appear dull red and rounded. Flecks of viscid mucus are seen on the vocal cords and interarytenoid region.

### Treatment

- 1. **Eliminate infection of upper or lower respiratory tract** Infection in the sinuses, tonsils, teeth or chronic chest infection (bronchitis, bronchiectasis, tuberculosis, etc.) should be treated.
- 2. **Avoidance of irritating factors**, e.g. smoking, alcohol or polluted environment, dust and fumes.
- 3. **Voice rest and speech therapy** Voice rest has to be prolonged for weeks or months. Patient should receive training in proper use of voice.
- 4. **Steam inhalations** They help to loosen secretions and give relief.
- 5. **Expectorants** They help to loosen viscid secretions and give relief from hawking.

## B. Chronic Hypertrophic Laryngitis (Syn. Chronic Hyperplastic Laryngitis)

It may be either a diffuse and symmetrical process or a localised one, the latter appearing like a tumour of the larynx. Localised variety presents as dysphonia plica ventricularis, vocal nodules, vocal polyp, Reinke's oedema and contact ulcer (They have been described in the relevant sections).

page 310

page 311

### Aetiology

Same as discussed under chronic laryngitis without hyperplasia.

### Pathology

Pathological changes start in the glottic region and later may extend to ventricular bands, base of epiglottis and even subglottis. Mucosa, submucosa, mucous glands and in later stages intrinsic laryngeal muscles and joints may be affected.

Initially, there is hyperaemia, oedema and cellular infiltration in the submucosa. The pseudostratified ciliated epithelium of respiratory mucosa changes to squamous type, and squamous epithelium of the vocal cords to hyperplasia and keratinisation. The mucous glands suffer hypertrophy at first but later undergo atrophy with diminished secretion and dryness of larynx.

### Clinical Features

This disease mostly affects males (8:1) in the age group of 30-50 years.

Hoarseness, constant desire to clear the throat, dry cough, tiredness of voice, and discomfort in throat when the voice has been used for an extended period of time, are the common presenting symptoms.

### Examination

On examination, changes are often diffuse and symmetrical.

- **1.** Laryngeal mucosa, in general, is dusky red and thickened.
- **2.** Vocal cords appear red and swollen. Their edges lose sharp demarcation and appear rounded. In late stages, cords become bulky and irregular giving nodular appearance.
- **3.** Ventricular bands appear red and swollen and may be mistaken for prolapse or eversion of the ventricle.
- **4.** Mobility of cords gets impaired due to oedema and infiltration, and later due to muscular atrophy or arthritis of the cricoarytenoid joint.

### Treatment

#### Conservative

Same as for chronic laryngitis without hyperplasia.

#### Surgical

Stripping of vocal cords, removing the hyperplastic and oedematous mucosa, may be done in selected cases. Damage to underlying vocal ligament should be carefully avoided. One cord is operated at a time.

## **POLYPOID DEGENERATION OF VOCAL CORDS (REINKE'S OEDEMA)**

It is bilateral symmetrical swelling of the whole of membranous part of the vocal cords, most often seen in middle-aged men and women. This is due to oedema of the subepithelial space (Reinke's space) of the vocal cords. Chronic irritation of vocal cords due to misuse of voice, heavy smoking, chronic sinusitis and laryngopharyngeal reflex are the probable aetiological factors. It can also occur in myxoedema.



## Clinical Features

Hoarseness is the common symptom. Patient uses false cords for voice production and this gives him a low-pitched and rough voice.

On indirect laryngoscopy, vocal cords appear as fusiform swellings with pale translucent look. Ventricular bands may appear hyperaemic and hypertrophic and may hide the view of the true cords.

## Treatment

- **1.** Decortication of the vocal cords, i.e. removal of strip of epithelium, is done first on one side and 3-4 weeks later on the other.
- **2.** Voice rest.
- **3.** Speech therapy for proper voice production.

## **PACHYDERMIA LARYNGIS**

It is a form of chronic hypertrophic laryngitis affecting posterior part of larynx in the region of interarytenoid and posterior part of the vocal cords.

Clinically, patient presents with hoarseness or husky voice and irritation in the throat. Indirect laryngoscopy reveals heaping up of red or grey granulation tissue in the interarytenoid region and posterior thirds of vocal cords; the latter sometimes showing ulceration due to constant hammering of vocal processes as in talking, forming what is called the 'contact ulcer'. The condition is bilateral and symmetrical. It does not undergo malignant change. However, biopsy of the lesion is essential to differentiate the lesion from carcinoma and tuberculosis. Aetiology is uncertain. It is mostly seen in men who indulge in excessive alcohol and smoking. Other factors are excessive forceful talking and gastro-oesophageal reflux disease where posterior part of larynx is being constantly bathed with acid juices from the stomach.

Treatment is removal of granulation tissue under operating microscope which may require repetition, control of acid reflux and speech therapy.

## **ATROPHIC LARYNGITIS (LARYNGITIS SICCA)**

It is characterised by atrophy of laryngeal mucosa and crust formation. Condition is often seen in women and is associated with atrophic rhinitis and pharyngitis.

Common symptoms include hoarseness of voice which temporarily improves on coughing and removal of crusts. Dry irritating cough and sometimes dyspnoea is due to obstructing crusts.

Examination shows atrophic mucosa covered with foul-smelling crusts. When crusts have been expelled, mucosa may show excoriation and bleeding. Crusting may also be seen in the trachea.

Treatment is elimination of the causative factor and humidification. Laryngeal sprays with glucose in glycerine or oil of pine are comforting and help to loosen the crusts. Associated nasal and pharyngeal conditions will require attention. Expectorants containing ammonium chloride or iodides also help to loosen the crusts.

# TUBERCULOSIS OF LARYNX

## Aetiology

It is almost always secondary to pulmonary tuberculosis, mostly affecting males in middle age group. Tubercle bacilli reach the larynx by bronchogenic or haematogenous routes.

## Pathology

Disease affects posterior part of larynx more than anterior. Parts affected are: (i) interarytenoid fold, (ii) ventricular bands, (iii) vocal cords and (iv) epiglottis, in that order.

Tubercle bacilli, carried by sputum from the bronchi, settle and penetrate the intact laryngeal mucosa particularly in the interarytenoid region (bronchogenic spread). This leads to formation of submucosal tubercles which may later caseate and ulcerate. Laryngeal mucosa appears red and swollen due to cellular infiltration (pseudooedema). Stages of perichondritis and cartilage necrosis are not commonly seen these days.

## Symptoms and Signs

They would greatly depend on the stage of tuberculosis. Weakness of voice is the earliest symptom followed by hoarseness. Ulceration in the larynx gives rise to severe pain which may radiate to the ears. Swallowing is painful with marked dysphagia in later stages.

## Laryngeal Examination

- 1. Hyperaemia of the vocal cord in its whole extent or confined to posterior part with impairment of adduction is the first sign.
- 2. Swelling in the interarytenoid region giving a mamillated appearance.
- 3. Ulceration of vocal cord giving mouse-nibbled appearance.
- 4. Superficial ragged ulceration on the arytenoids and interarytenoid region.
- 5. Granulation tissue in interarytenoid region or vocal process of arytenoid.
- 6. Pseudoedema of the epiglottis "turban epiglottis".
- 7. Swelling of ventricular bands and aryepiglottic folds.
- 8. Marked pallor of surrounding mucosa.



## Diagnosis

In addition to X-ray chest and sputum examination, biopsy of laryngeal lesion is essential to exclude carcinoma and differentiate it from other condition.

## Treatment

Treatment is the same as for pulmonary tuberculosis. Voice rest is important.

## **LUPUS OF THE LARYNX**

It is an indolent tubercular infection associated with lupus of nose and pharynx. Unlike tuberculosis of larynx which mostly affects posterior parts, lupus involves the anterior part of larynx. Epiglottis is involved first and may be completely destroyed by the disease. The lesion spreads to aryepiglottic folds and sometimes to ventricular bands. Lupus of larynx is a painless and often an asymptomatic condition and may be discovered on routine laryngeal examination in cases of lupus of nose. There is no pulmonary tuberculosis. Treatment is antitubercular drugs. Prognosis is good.

## **SYPHILIS OF THE LARYNX**

It is a rare condition now. Only gumma of tertiary stage is sometimes seen. It may occur in any part of the larynx and present as a smooth swelling which may later ulcerate. Diagnosis is only on biopsy and serological tests. Laryngeal stenosis is a frequent complication.

## **LEPROSY OF THE LARYNX**

It is a rare condition and is often associated with leprosy of the skin and nose. It presents as diffuse nodular infiltration of epiglottis, aryepiglottic folds and arytenoids. Lesions may ulcerate. It is associated with nasal leprosy. Diagnosis is made on biopsy from the lesion. Deformity of the laryngeal inlet and stenosis are the end results of this disease after healing.

## **SCLEROMA OF THE LARYNX**

It is a chronic inflammatory condition caused by *Klebsiella rhinoscleromatis*. Nasal involvement is very common in our country. Laryngeal involvement may be seen occasionally with or without a nasal lesion. Typically, it presents as a smooth red swelling in the subglottic region. Hoarseness of voice, wheezing and dyspnoea may be the presenting symptoms in addition to the nasal lesion. Diagnosis is made on biopsy. Treatment is by streptomycin or tetracycline, often combined with steroids to prevent fibrosis. Subglottic stenosis is a frequent complication requiring subsequent reconstructive surgery.

## **LARYNGEAL MYCOSIS**

Fungal infections such as candidiasis, histoplasmosis and blastomycosis may rarely affect the larynx. Diagnosis is usually made on biopsy and on finding a similar lesion in other parts of the body.

## 58 Congenital Lesions of Larynx and Stridor

### CONGENITAL LESIONS OF LARYNX

- Laryngomalacia (congenital laryngeal stridor)
- Congenital vocal cord paralysis
- Congenital subglottic stenosis
- Laryngeal web
- Subglottic haemangioma
- Laryngo-oesophageal cleft
- Laryngocele
- Laryngeal cyst

#### **1. Laryngomalacia (congenital laryngeal stridor)**

It is the most common congenital abnormality of the larynx. It is characterised by excessive flaccidity of supraglottic larynx which is sucked in during inspiration producing stridor and sometimes cyanosis. Stridor is increased on crying but subsides on placing the child in prone position; cry is normal. The condition manifests at birth or soon after, and usually disappears by 2 years of age. Direct laryngoscopy shows elongated epiglottis, curled upon itself (omega-shaped  $\Omega$ ), floppy aryepiglottic folds and prominent arytenoids. Flexible laryngoscope is very useful to make the diagnosis. Mostly, treatment is conservative. Tracheostomy may be required for some cases of severe respiratory obstruction (Fig. 58.1).

#### **2. Congenital vocal cord paralysis**

It results from birth trauma when recurrent laryngeal nerve is stretched during breech or forceps delivery or can result from anomalies of the central nervous system.

#### **3. Congenital subglottic stenosis**

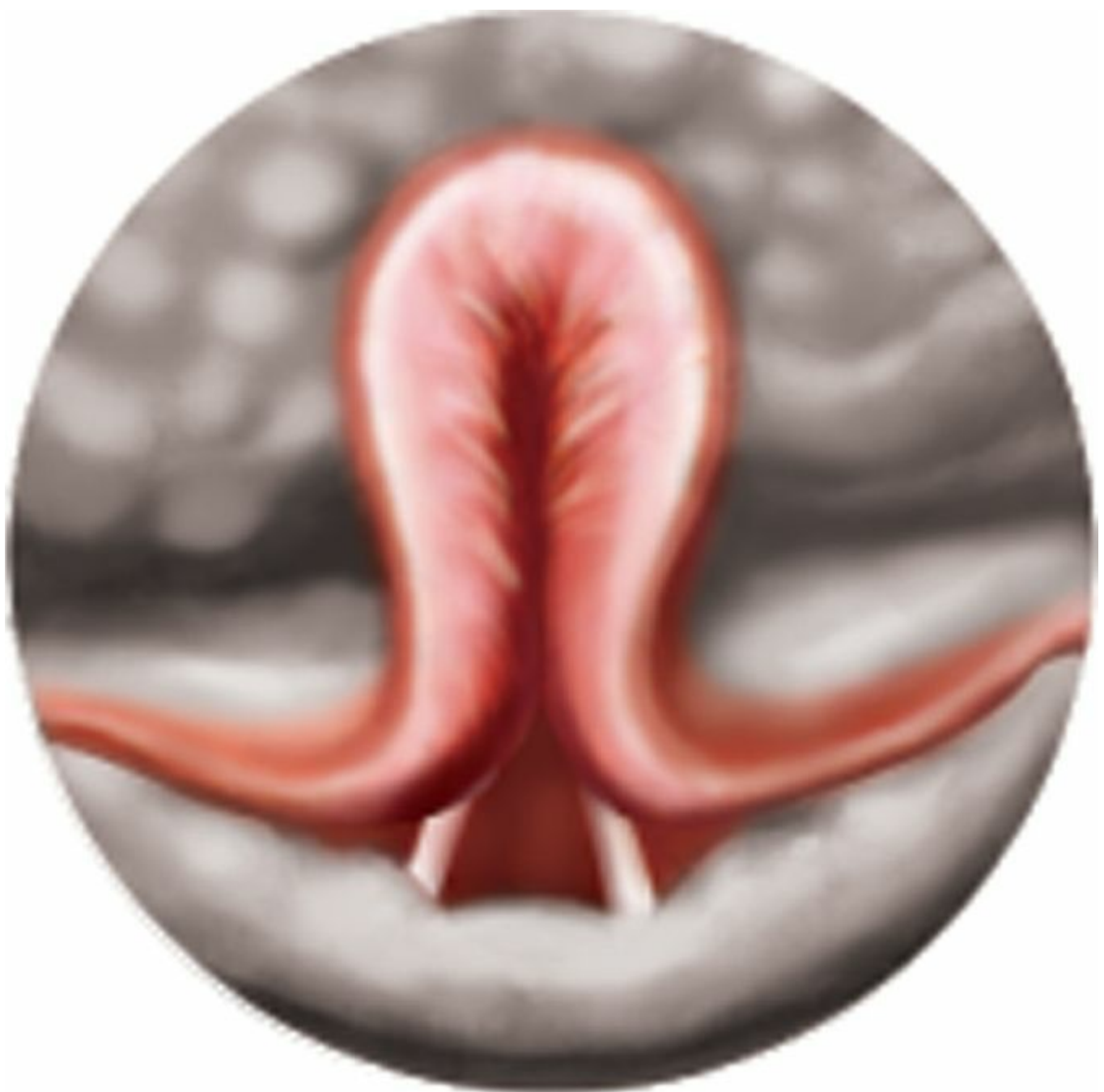It is due to abnormal thickening of cricoid cartilage or fibrous tissue seen below the vocal cords. Child may remain asymptomatic till upper respiratory infection causes dyspnoea and stridor. Cry is normal as in laryngomalacia. Diagnosis is made when subglottic diameter is less than 4 mm in full-term neonate (normal 4.5-5.5 mm) or 3 mm in premature neonate (normal 3.5 mm). Many cases of congenital stenosis improve as the larynx grows but some may require surgery.

#### **4. Laryngeal web (Fig. 58.2)**

It is due to incomplete recanalisation of larynx. Mostly, the web is seen between the vocal cords and has a concave posterior margin. Presenting features are airway obstruction, weak cry or aphonia dating from birth. Treatment depends on the thickness of the web. Thin webs can be cut with a knife or CO<sub>2</sub> laser. Thick ones may require excision via laryngofissure and placement of a silicon keel and subsequent dilatations.

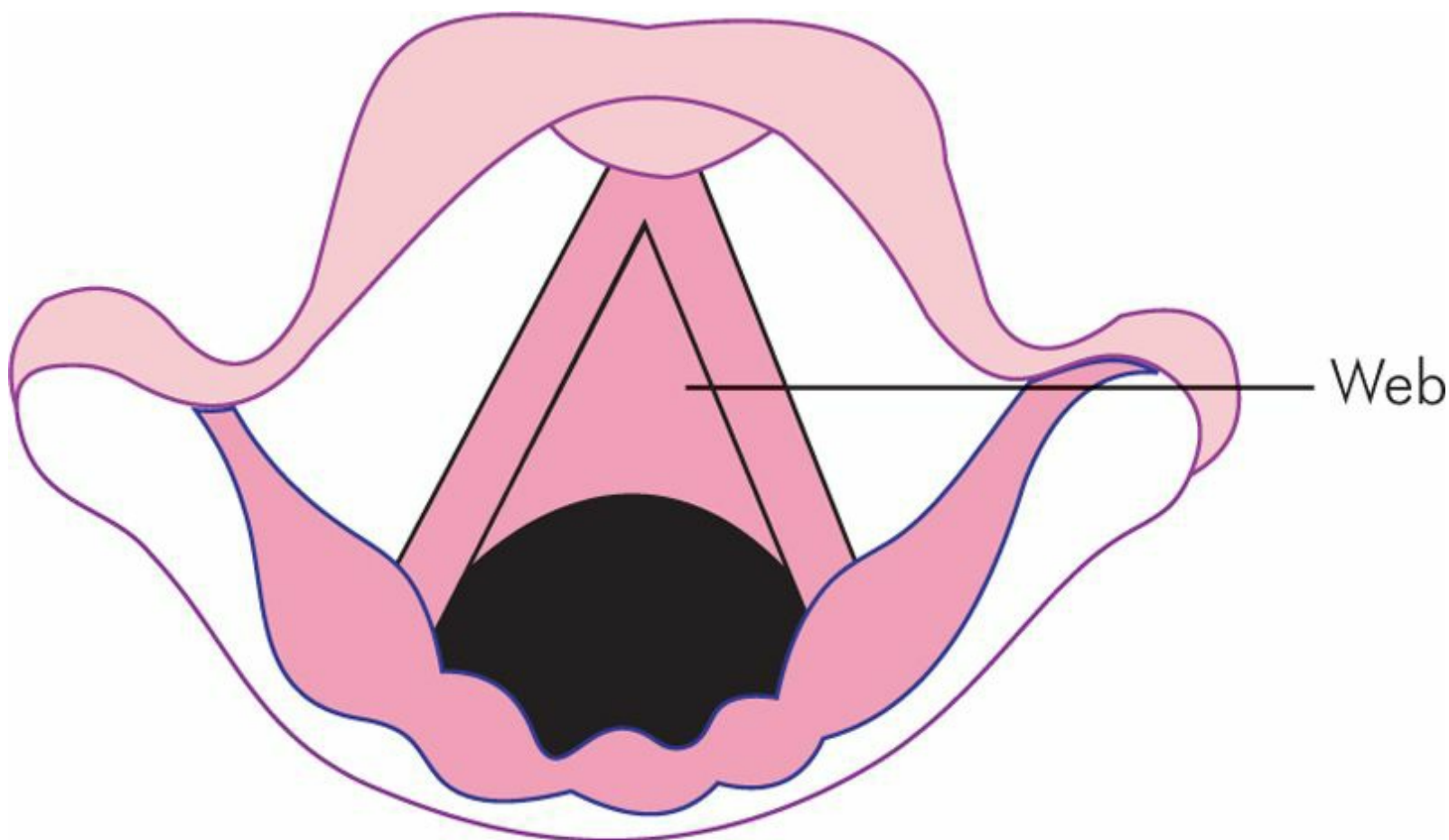
#### **5. Subglottic haemangioma**





Dhingra: Diseases of Ear Nose and Throat, 5th Edition  
Copyright © 2010 Elsevier. All rights reserved.

Figure 58.1 Laryngomalacia. Note: epiglottis is folded longitudinally forming an omega.



Dhingra: Diseases of Ear Nose and Throat, 5th Edition  
Copyright © 2010 Elsevier. All rights reserved.

Figure 58.2 Laryngeal web.

page 314

page 315

Though congenital, patient is asymptomatic till 3-6 months of age when haemangioma begins to increase in size. About 50% of the children have associated cutaneous haemangiomas. Patient may present with stridor but has a normal cry. Agitation of the patient or crying may increase airway obstruction due to venous filling. Direct laryngoscopy shows reddish-blue mass below the vocal cords. Biopsy is sometimes, not always, associated with haemorrhage. Some patients have associated mediastinal haemangioma.

Depending on individual case, the treatment is:

- **(a)** Tracheostomy and observation, as many haemangiomas involute spontaneously.
- **(b)** Steroid therapy. Dexamethasone 1 mg/kg/day for 1 week and then prednisolone 3 mg/kg in divided doses for one year.
- **(c)** CO<sub>2</sub> laser excision if lesion is small.

### 6. Laryngo-oesophageal cleft

It is due to failure of the fusion of cricoid lamina. Patient presents with repeated aspiration and pneumonitis. Coughing, choking and cyanosis are present at the time of feeding.

### 7. Laryngocele

It is dilatation of laryngeal saccule and extends between thyroid cartilage and the ventricle. It may be internal, external or combined. Treatment is endoscopic or external excision.

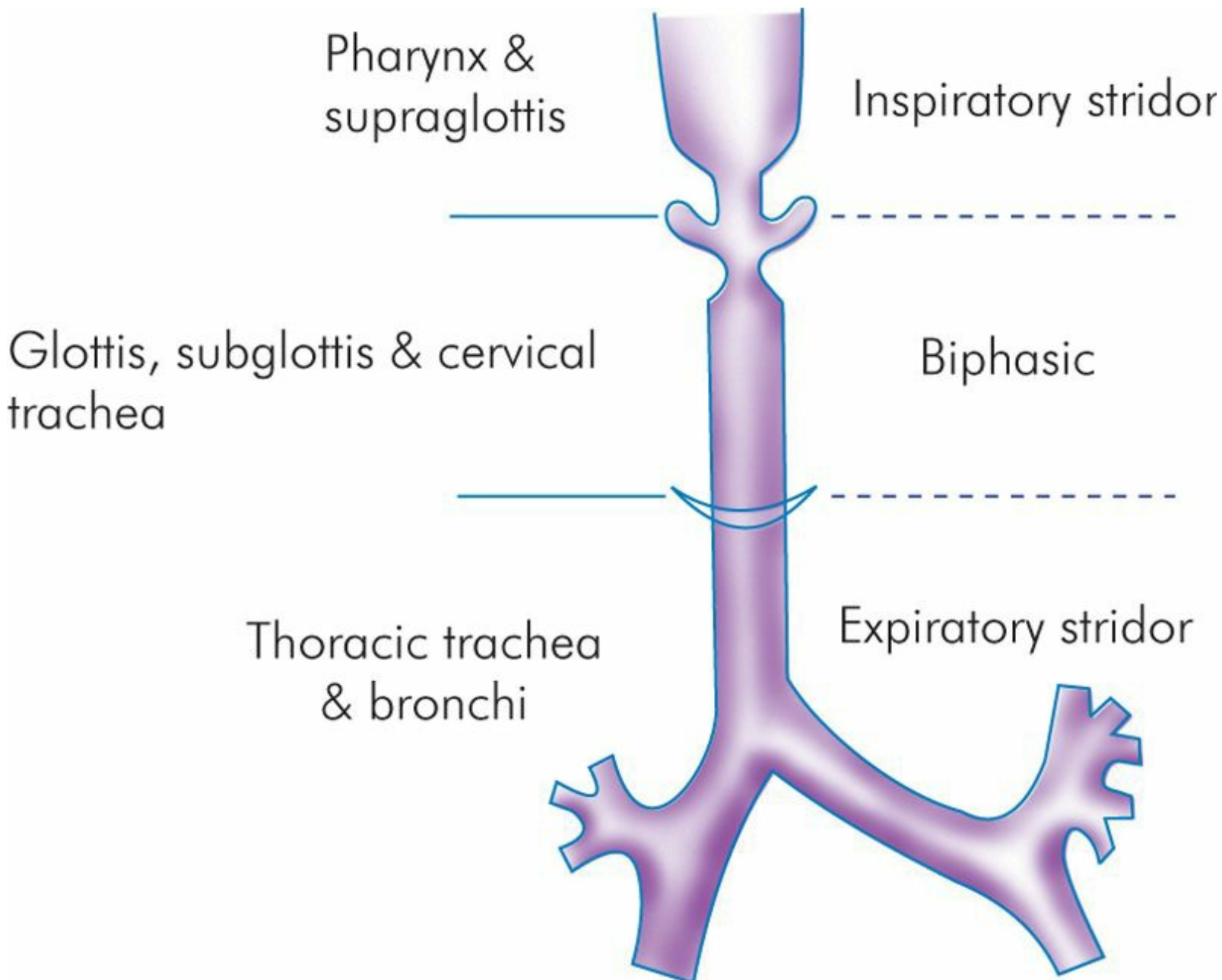
### 8. Laryngeal cyst

It arises in the aryepiglottic fold and appears as bluish, fluid-filled smooth swelling in the supraglottic larynx. Respiratory obstruction may necessitate tracheostomy. Needle aspiration or incision and drainage of cyst provides an emergency airway. Treatment is deroofting the cyst or excision with CO<sub>2</sub> laser.

# STRIDOR

Stridor is noisy respiration produced by turbulent air flow through the narrowed air passages. It may be heard during inspiration, expiration or both (Fig. 58.3).

- *Inspiratory stridor* is often produced in obstructive lesions of supraglottis or pharynx, e.g. laryngomalacia or retropharyngeal abscess.
- *Expiratory stridor* is produced in lesions of thoracic trachea, primary and secondary bronchi, e.g. bronchial foreign body, tracheal stenosis.
- *Biphasic stridor* is seen in lesions of glottis, subglottis and cervical trachea, e.g. laryngeal papillomas, vocal cord paralysis and subglottis stenosis.

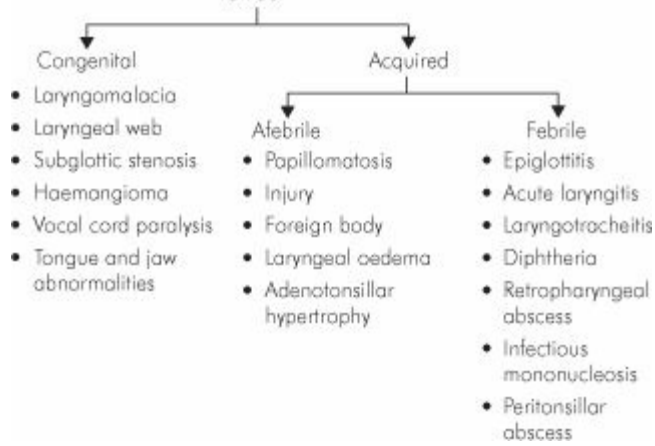


Dhingra: Diseases of Ear Nose and Throat, 5th Edition  
Copyright © 2010 Elsevier. All rights reserved.

Figure 58.3 Types of stridor and their site of origin.

Stridor may arise from lesions of nose, tongue, mandible, pharynx, larynx or trachea and bronchi. Common causes of stridor in infants and children are given below:

## Stridor



- **(a) Nose.** Choanal atresia in newborn.
- **(b) Tongue.** Macroglossia due to cretinism, haemangioma or lymphangioma, dermoid at base of tongue, lingual thyroid.
- **(c) Mandible.** Micrognathia, Pierre-Robin syndrome. In these cases, stridor is due to falling back of tongue.
- **(d) Pharynx.** Congenital dermoid, adenotonsillar hypertrophy, retropharyngeal abscess, tumours.
- **(e) Larynx.**
  - (i) Congenital: Laryngeal web, laryngomalacia, cysts, vocal cord paralysis, subglottic stenosis.
  - (ii) Inflammatory: Epiglottitis, laryngotracheitis, diphtheria, tuberculosis.
  - (iii) Neoplastic: Haemangioma and juvenile multiple papillomas, carcinoma in adults.
  - (iv) Traumatic: Injuries of larynx, foreign bodies, oedema following endoscopy, or prolonged intubation.
  - (v) Neurogenic: Laryngeal paralysis due to acquired lesions.
  - (vi) Miscellaneous: Tetanus, tetany, laryngismus stridulus.
- **(f) Trachea and bronchi**
  - (i) Congenital: Atresia, stenosis, tracheomalacia.
  - (ii) Inflammatory: Tracheobronchitis.
  - (iii) Neoplastic: Tumours of trachea.
  - (iv) Traumatic: Foreign body, stenosis trachea (e.g. following prolonged intubation or tracheostomy).
- **(g) Lesions outside respiratory tract**
  - (i) Congenital: Vascular rings (cause stridor and dysphagia), oesophageal atresia, tracheo-oesophageal fistula, congenital goitre, cystic hygroma.
  - (ii) Inflammatory: Retropharyngeal and retro-oesophageal abscess.
  - (iii) Traumatic: FB oesophagus (secondary tracheal compression).
  - (iv) Tumours: Masses in neck.

# Management

## History

Stridor is a physical sign and not a disease. Attempt should always be made to discover the cause. It is important to elicit:

- **(a) Time of onset** to find whether cause is congenital or acquired.
- **(b) Mode of onset.** Sudden onset (foreign body, oedema), gradual and progressive (laryngomalacia, subglottic haemangioma, juvenile papillomas).
- **(c) Duration.** Short (foreign body, oedema, infections), long (laryngomalacia, laryngeal stenosis, subglottic haemangioma, anomalies of tongue and jaw).
- **(d) Relation to feeding.** Aspiration in laryngeal paralysis, oesophageal atresia, laryngeal cleft, vascular ring, foreign body oesophagus.
- **(e) Cyanotic spells.** Indicate need for airway maintenance.
- **(f) Aspiration or ingestion of a foreign body.**
- **(g) Laryngeal trauma.** Blunt injuries to larynx, intubation, endoscopy.

## Physical Examination

- **(a)** Stridor is always associated with respiratory distress. There may be recession in suprasternal notch, sternum, intercostal spaces and epigastrium during inspiratory efforts.
- **(b)** Note whether stridor is inspiratory, expiratory or biphasic which indicates the probable site of obstruction.
- **(c)** Note associated characteristics of stridor.
  - (i) Snoring or snorting sound-nasal or nasopharyngeal cause.
  - (ii) Gurgling sound and muffled voice-pharyngeal cause.
  - (iii) Hoarse cry or voice-laryngeal cause at vocal cords. Cry is normal in laryngomalacia and subglottic stenosis.
  - (iv) Expiratory wheeze-bronchial obstruction.
- **(d)** Associated fever indicates infective condition, e.g. acute laryngitis, epiglottitis, laryngo-tracheo-bronchitis or diphtheria.
- **(e)** Stridor of laryngomalacia, micrognathia, macroglossia and innominate artery compression disappears when baby lies in prone position.
- **(f)** Sequential auscultation with unaided ear and with stethoscope over the nose, open mouth, neck and the chest helps to localise the probable site of origin of stridor.
- **(g)** Examination of nose, tongue, jaw and pharynx and larynx can exclude local pathology in these areas. In adults, indirect laryngoscopy can be done easily while infants and children require direct laryngoscopy.

## Radiography

- **(a)** X-ray of chest and soft tissue neck both in anteroposterior and lateral views.
- **(b)** Fluoroscopy to see chest movements both during inspiration and expiration.
- **(c)** Tomography of chest for mediastinal mass.
- **(d)** Oesophagogram with lipoidal for atresia of oesophagus, tracheobronchial fistula or aberrant vessels.
- **(e)** Angiography, if aberrant vessels are suspected.
- **(f)** Xeroradiography is useful to show soft tissue lesions in the neck; now obsolete.
- **(g)** CT scan/MRI.

## Direct Laryngoscopy Without Anaesthesia

A quick direct laryngoscopy can be done in infants and small children without anaesthesia. However, resuscitative measures and tracheostomy tray should be made available. Direct laryngoscopy also gives opportunity to see if intubation will be possible or tracheostomy will be required for further examination.

## General Anaesthesia Followed by Bronchoscopy, Laryngoscopy and Oesophagoscopy

After slow induction, bronchoscopy is done first. It is useful to find any obstruction in air passage from subglottis to bronchi, removal of the obstruction, obtain aspirate or biopsy. If 3.5 mm size bronchoscope can be passed, intubation of the child is possible. After bronchoscopy, child is intubated and detailed examination of the larynx and oesophagus can then be done. Larynx should again be examined when patient is coming out of anaesthesia and the tube has been removed to see active movements of vocal cords to exclude laryngeal paralysis.

## Treatment

Once the diagnosis has been made, treatment of exact cause can be planned.

## 59 Laryngeal Paralysis

### Nerve Supply of Larynx

#### **Motor**

All the muscles which move the vocal cord (abductors, adductors or tensors) are supplied by the recurrent laryngeal nerve except the cricothyroid muscle. The latter receives its innervation from the external laryngeal nerve-a branch of superior laryngeal nerve.

#### **Sensory**

Above the vocal cords, larynx is supplied by internal laryngeal nerve-a branch of superior laryngeal, and below the vocal cords by recurrent laryngeal nerve.

#### **Recurrent laryngeal nerve**

Right recurrent laryngeal nerve arises from the vagus at the level of subclavian artery, hooks around it and then ascends between the trachea and oesophagus. The left recurrent laryngeal nerve arises from the vagus in the mediastinum at the level of arch of aorta, loops around it and then ascends into the neck in the tracheo-oesophageal groove. Thus, left recurrent laryngeal nerve has a much longer course which makes it more prone to paralysis compared to the right one (Fig. 59.1).

#### **Superior laryngeal nerve**

It arises from inferior ganglion of the vagus, descends behind internal carotid artery and, at the level of greater cornua of hyoid bone, divides into external and internal branches. The external branch supplies cricothyroid muscle while the internal branch pierces the thyrohyoid membrane and supplies sensory innervation to the larynx and hypopharynx.

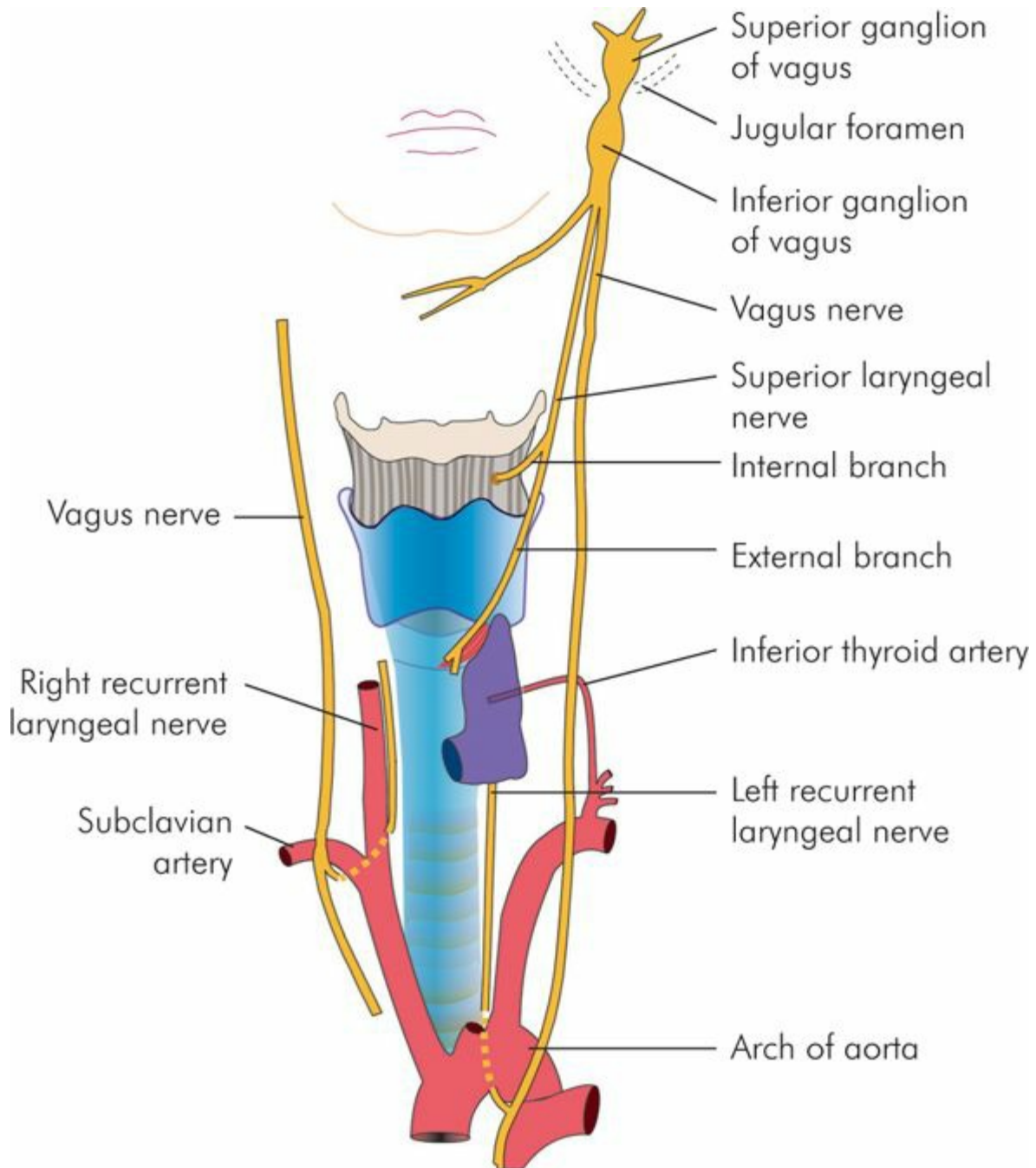


# Classification of Laryngeal Paralysis

Laryngeal paralysis may be unilateral or bilateral, and may involve:

- **1.** Recurrent laryngeal nerve.
- **2.** Superior laryngeal nerve.
- **3.** Both recurrent and superior laryngeal nerves (combined or complete paralysis).

# Causes of Laryngeal Paralysis



Dhingra: Diseases of Ear Nose and Throat, 5th Edition  
Copyright © 2010 Elsevier. All rights reserved.

Figure 59.1 Recurrent and superior laryngeal nerves.

In topographical manner, the causes are:

- **1. Supranuclear** Rare.
- **2. Nuclear** There is involvement of nucleus ambiguus in the medulla. The causes are vascular, neoplastic, motor neurone disease, polio, and syringobulbia. In nuclear lesions, there would be associated paralysis of other cranial nerves and neural pathways.
- **3. High vagal lesions** Vagus nerve may be involved in the skull, at the exit from jugular foramen or in parapharyngeal space (Table 59.1).
- **4. Low vagal or recurrent laryngeal nerve** (Table 59.2).
- **5. Systemic causes** Diabetes, syphilis, diphtheria, typhoid, streptococcal or viral infections, lead poisoning.
- **6. Idiopathic** In about 30% of cases, cause remains obscure.

Table 59-1. Causes of combined paralysis (high vagal lesions)

Intracranial	Tumours of posterior fossa
--------------	----------------------------

	Basal meningitis (tubercular)
<i>Skull base</i>	Fractures
	Nasopharyngeal cancer
	Glomus tumour
<i>Neck</i>	Penetrating injury
	Parapharyngeal tumours
	Metastatic nodes
	Lymphoma

# RECURRENT LARYNGEAL NERVE PARALYSIS

## A. Unilateral

Unilateral injury to recurrent laryngeal nerve results in ipsilateral paralysis of all the intrinsic muscles except the cricothyroid. The vocal cord thus assumes a median or paramedian position and does not move laterally on deep inspiration (Table 59.2). There are many theories to explain the median or paramedian position of the cord. One is *Semon's law* which states that, in all progressive organic lesions, abductor fibres of the nerve, which are phylogenetically newer, are more susceptible and thus the first to be paralysed compared to adductor fibres. The other explanation is *Wagner and Grossman hypothesis* which states that cricothyroid muscle which receives innervation from superior laryngeal nerve keeps the cord in paramedian position due to its adductor function.

Table 59-2. Position of the vocal cord in health and disease

Position of the cord	Location of the cord from midline	Situation in	
		Health	Disease
Median	Midline	• Phonation	• RLN paralysis
Paramedian	1.5 mm	• Strong whisper	• RLN paralysis
Intermediate (cadaveric)	3.5 mm. This is neutral position of cricoarytenoid joint. Abduction and adduction take place from this position	-	• Paralysis of both recurrent and superior laryngeal nerves
Gentle abduction	7 mm	• Quiet respiration	• Paralysis of adductors
Full abduction	9.5 mm	• Deep inspiration	-

The aetiology of recurrent laryngeal nerve paralysis is given in Table 59.3. Bronchogenic carcinoma is an important cause of left recurrent paralysis and should always be excluded by X-ray chest, bronchoscopy and biopsy unless the other cause is obvious.

### Clinical Features

Unilateral recurrent laryngeal paralysis may pass undetected as about one-third of the patients are asymptomatic. Others have some change in voice but no problems of aspiration or airways obstruction. The voice in unilateral paralysis gradually improves due to compensation by the healthy cord which crosses the midline to meet the paralysed one.

### Treatment

Generally no treatment is required.

## B. Bilateral (Bilateral Abductor Paralysis)

### Aetiology

Neuritis or surgical trauma (thyroidectomy) are the most important causes. The condition is often acute.

### Position of Cords

As all the intrinsic muscles of larynx are paralysed, the vocal cords lie in median or paramedian position due to unopposed action of cricothyroid muscles (Fig. 59.2).

### Clinical Features

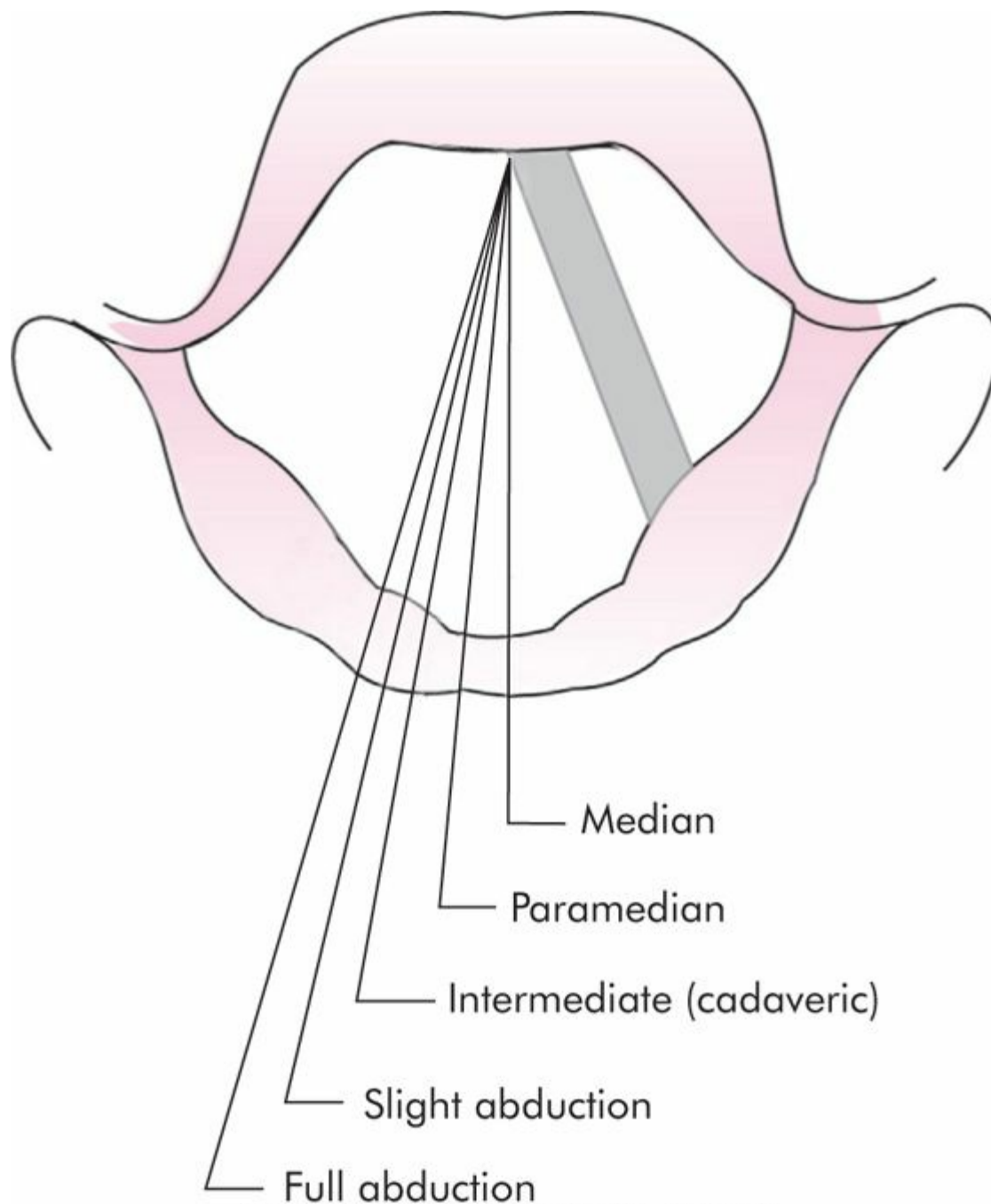
As both the cords lie in median or paramedian position, the airway is inadequate causing dyspnoea and stridor but the voice is good. Dyspnoea and stridor become worse on exertion or during an attack of acute laryngitis.

page 318

page 319

**Table 59-3. Causes of recurrent laryngeal nerve paralysis (low vagal trunk or recurrent laryngeal nerve)**

Right	Left	Both
• Neck trauma	I. <i>Neck</i>	
• Benign or malignant thyroid disease	• Accidental trauma	
• Thyroid surgery	• Thyroid disease (benign or malignant)	Thyroid surgery
• Carcinoma cervical oesophagus	• Thyroid surgery	Carcinoma thyroid
• Cervical lymphadenopathy	• Carcinoma cervical oesophagus	Cancer cervical oesophagus
	• Cervical lymphadenopathy	Cervical lymphadenopathy
	II. <i>Mediastinum</i>	
• Aneurysm of subclavian artery	• Bronchogenic cancer	
• Carcinoma apex right lung	• Carcinoma thoracic oesophagus	
• Tuberculosis of cervical pleura	• Aortic aneurysm	
• Idiopathic	• Mediastinal lymphadenopathy	
	• Enlarged left auricle	
	• Intrathoracic surgery	
	• Idiopathic	



Dhingra: Diseases of Ear Nose and Throat, 5th Edition  
 Copyright © 2010 Elsevier. All rights reserved.

Figure 59.2 Position of vocal cords.

## Treatment

### **Tracheostomy**

Many cases of bilateral abductor paralysis require tracheostomy as an emergency procedure or when they develop upper respiratory tract infection.

In long-standing cases, the choice is between a permanent tracheostomy with a speaking valve or a surgical procedure to lateralise the cord. The former relieves stridor, preserves good voice but has the disadvantage of a tracheostomy hole in the neck. The latter relieves airway obstruction but at the expense of a good voice; however there is no tracheostomy hole in the neck.

### **Lateralisation of the cord**

Aim is to move and fix the cord in a lateral position to improve the airway. The various procedures are:

- (a) *Arytenoidectomy*. Arytenoid cartilage is excised by an external neck approach and the cord fixed in a lateral position. Arytenoidectomy can also be done through an endoscope.
- (b) *Vocal cord lateralisation through endoscope*.
- (c) *Thyroplasty type II*. (See phonosurgery).
- (d) *Cordectomy*. This can be accomplished through neck incision. These days CO<sub>2</sub> laser has been used to excise the cord through the

endoscope.

- **(e) Nerve muscle implant.** Sternohyoid muscle with its nerve supply is transplanted into the paralysed posterior cricoarytenoid to bring some movement to the cord. This operation is not very successful.

# PARALYSIS OF SUPERIOR LARYNGEAL NERVE

## A. Unilateral

page 319

page 320

Isolated lesions of this nerve are rare; usually, it is a part of combined paralysis. Paralysis of superior laryngeal nerve causes paralysis of cricothyroid muscle and ipsilateral anaesthesia of the larynx above the vocal cord. Paralysis of cricothyroid can also occur when external laryngeal nerve is involved in thyroid surgery, tumours, neuritis or diphtheria.

### Clinical Features

Voice is weak and pitch cannot be raised. Anaesthesia of the larynx on one side may pass unnoticed or cause occasional aspiration. Laryngeal findings include:

- **1.** Askew position of glottis as anterior commissure is rotated to the healthy side.
- **2.** Shortening of cord with loss of tension. The paralysed cord appears wavy due to lack of tension.
- **3.** Flapping of the paralysed cord. As tension of the cord is lost, it sags down during inspiration and bulges up during expiration.



## **B. Bilateral**

This is an uncommon condition. Both the cricothyroid muscles are paralysed along with anaesthesia of upper larynx.

### **Aetiology**

Important causes include surgical or accidental trauma, neuritis (mostly diphtheritic), pressure by cervical nodes or involvement in a neoplastic process.

### **Clinical Features**

Presence of both paralysis and bilateral anaesthesia causes inhalation of food and pharyngeal secretions giving rise to cough and choking fits. Voice is weak and husky.

### **Treatment**

It depends on cause. Cases due to neuritis may recover spontaneously. Patients with repeated aspiration may require tracheostomy with a cuffed tube and an oesophageal feeding tube.

Epiglottopexy is an operation to close the laryngeal inlet to protect the lungs from repeated aspiration. It is a reversible procedure.

# COMBINED (COMPLETE) PARALYSIS (RECURRENT AND SUPERIOR LARYNGEAL NERVE PARALYSIS)

## A. Unilateral

This causes paralysis of all the muscles of larynx on one side except the interarytenoid which also receives innervation from the opposite side.

### Aetiology

Thyroid surgery is the most common cause when both recurrent and external laryngeal nerves of one side may be involved.

It may also occur in lesions of nucleus ambiguus or that of the vagus nerve proximal to the origin of superior laryngeal nerve. Thus, lesion may lie in the medulla, posterior cranial fossa, jugular foramen or parapharyngeal space.

### Clinical Features

As all the muscles of larynx on one side are paralysed, vocal cord will lie in the cadaveric position, i.e. 3.5 mm from the midline (Table 59.2). The healthy cord is unable to approximate the paralysed cord, thus causing glottic incompetence. This results in hoarseness of voice and aspiration of liquids through the glottis. Cough is ineffective due to air waste.

### Treatment

- **1. Speech therapy.** With proper speech therapy, the healthy cord may compensate the loss of function of paralysed vocal cord by moving across the midline.
- **2. Procedures to medialise the cord.** In uncompensated cases, aim is to bring the paralysed cord towards the midline so that healthy cord can meet it. This is achieved by:
  - (a) *Injection of teflon paste* lateral to the paralysed cord. This is done by direct laryngoscopy under local anaesthesia.
  - (b) *Thyroplasty type I.* (See phonosurgery vide infra).
  - (c) *Muscle or cartilage implant.* Laryngofissure is done and a bipedicled muscle graft or piece of cartilage is inserted between thyroid cartilage and its inner perichondrium lateral to vocal cord, thus pushing the cord medially.
  - (d) *Arthrodesis of cricoarytenoid joint.* Larynx is opened by laryngofissure, arytenoid cartilage rotated medially and fixed with a screw.

## B. Bilateral

Both recurrent and superior laryngeal nerves on both sides are paralysed. This is a rare condition. As all the laryngeal muscles are paralysed, both cords lie in cadaveric position. There is also total anaesthesia of the larynx.

### Clinical Features

page 320

page 321

- 1. *Aphonia*. As cords do not meet at all.
- 2. *Aspiration*. This is due to incompetent glottis and laryngeal anaesthesia.
- 3. *Inability to cough*. This is due to inability of the cords to meet. This results in retention of secretions in the chest.
- 4. *Bronchopneumonia*. This is due to repeated aspirations and retention of secretions.

### Treatment

- 1. *Tracheostomy*. Essential to remove pulmonary secretions and inhaled material.
- 2. *Epiglottopexy*. It is an operation in which epiglottis is folded backwards and fixed to the arytenoids so as to prevent aspiration into the lungs. It is a reversible procedure.
- 3. *Vocal cord plication*. Larynx is opened by laryngofissure. Mucosa of the true and false cords is removed and then they are approximated with sutures. This procedure helps to prevent aspiration and can be reversed when required.
- 4. *Total laryngectomy*. May be needed in those where cause is progressive and irreversible and speech is unserviceable.
- 5. *Diversion procedures*.

## **CONGENITAL VOCAL CORD PARALYSIS**

It may be unilateral or bilateral. Unilateral paralysis is more common. The cause may be birth trauma or congenital anomaly of a great vessel or heart. Bilateral paralysis may be due to hydrocephalus or Arnold-Chiari malformation, intracerebral haemorrhage during birth, meningocele, or cerebral or nucleus ambiguus agenesis. The patient of bilateral paralysis presents with features of bilateral abductor paralysis and respiratory obstruction necessitating tracheostomy.

# Phonosurgery

Several surgical procedures have been designed to improve the quality of voice. They include:

- 1. Excision of benign or malignant lesions by microlaryngeal surgery or laser.
- 2. Injection of vocal cord with teflon paste or gelfoam to augment and medialise the paralysed cord so that the opposite healthy cord can easily approximate.
- 3. Thyroplasty. Isshiki divided thyroplasty procedures into four categories to produce functional alteration of vocal cords.
  - (a) Type I. It is *medial displacement* of vocal cord as is achieved in teflon paste injection.
  - (b) Type II. It is *lateral displacement* of vocal cord and is used to improve the airway.
  - (c) Type III. It is used to *shorten (relax)* the vocal cord. Relaxation of vocal cord lowers the pitch. This procedure is done in mutational falsetto or in those who have undergone gender transformation from female to male.
  - (d) Type IV. This procedure is used to *lengthen (tighten)* the vocal cord and elevate the pitch. It converts male character of voice to female and has been used in gender transformation. It is also used when vocal cord is lax and bowing due to aging process or trauma.
- 4. Laryngeal reinnervation procedures. In this, a segment of anterior belly of omohyoid muscle, carrying its nerve (ansa hypoglossi) and vessels, is implanted into the thyroarytenoid muscle after making a window in thyroid cartilage. It is supposed to innervate the paralysed thyroarytenoid muscle.

# 60 Benign Tumours of Larynx

Benign tumours of the larynx are not as common as the malignant ones. They are divided into: (a) Non-neoplastic and (b) Neoplastic tumours (Table 60.1).

## **NON-NEOPLASTIC**

They are not true neoplasms but are tumour-like masses which form as a result of infection, trauma or degeneration. They are seen more frequently than true benign neoplasms.

## A. Solid Non-neoplastic Lesions

### 1. Vocal Nodules (Singer's or Screamer's Nodes)

Table 60-1. Benign tumours of larynx

Non-neoplastic	Neoplastic
<ul style="list-style-type: none"><li>• Solid<ul style="list-style-type: none"><li>◦ Vocal nodules</li><li>◦ Vocal polyp</li><li>◦ Reinke's oedema</li><li>◦ Contact ulcer</li><li>◦ Intubation granuloma</li><li>◦ Leukoplakia</li><li>◦ Amyloid tumours</li></ul></li><li>• Cystic<ul style="list-style-type: none"><li>◦ Ductal cysts</li><li>◦ Saccular cysts</li><li>◦ Laryngocele</li></ul></li></ul>	<ul style="list-style-type: none"><li>• Squamous papilloma<ul style="list-style-type: none"><li>◦ Juvenile type</li><li>◦ Adult-onset type</li></ul></li><li>• Chondroma</li><li>• Haemangioma</li><li>• Granular cell tumour</li><li>• Glandular tumours</li><li>• Rhabdomyoma</li><li>• Lipoma</li><li>• Fibroma</li></ul>

They appear symmetrically on the free edge of vocal cord, at the junction of anterior one-third, with the posterior two-thirds, as this is the area of maximum vibration of the cord and thus subject to maximum trauma (Figs 60.1 and 60.2). Their size varies from that of pin-head to half a pea. They are the result of vocal trauma when person speaks in unnatural low tones for prolonged periods or at high intensities. They mostly affect teachers, actors, vendors or pop singers. They are also seen in school going children who are too assertive and talkative.

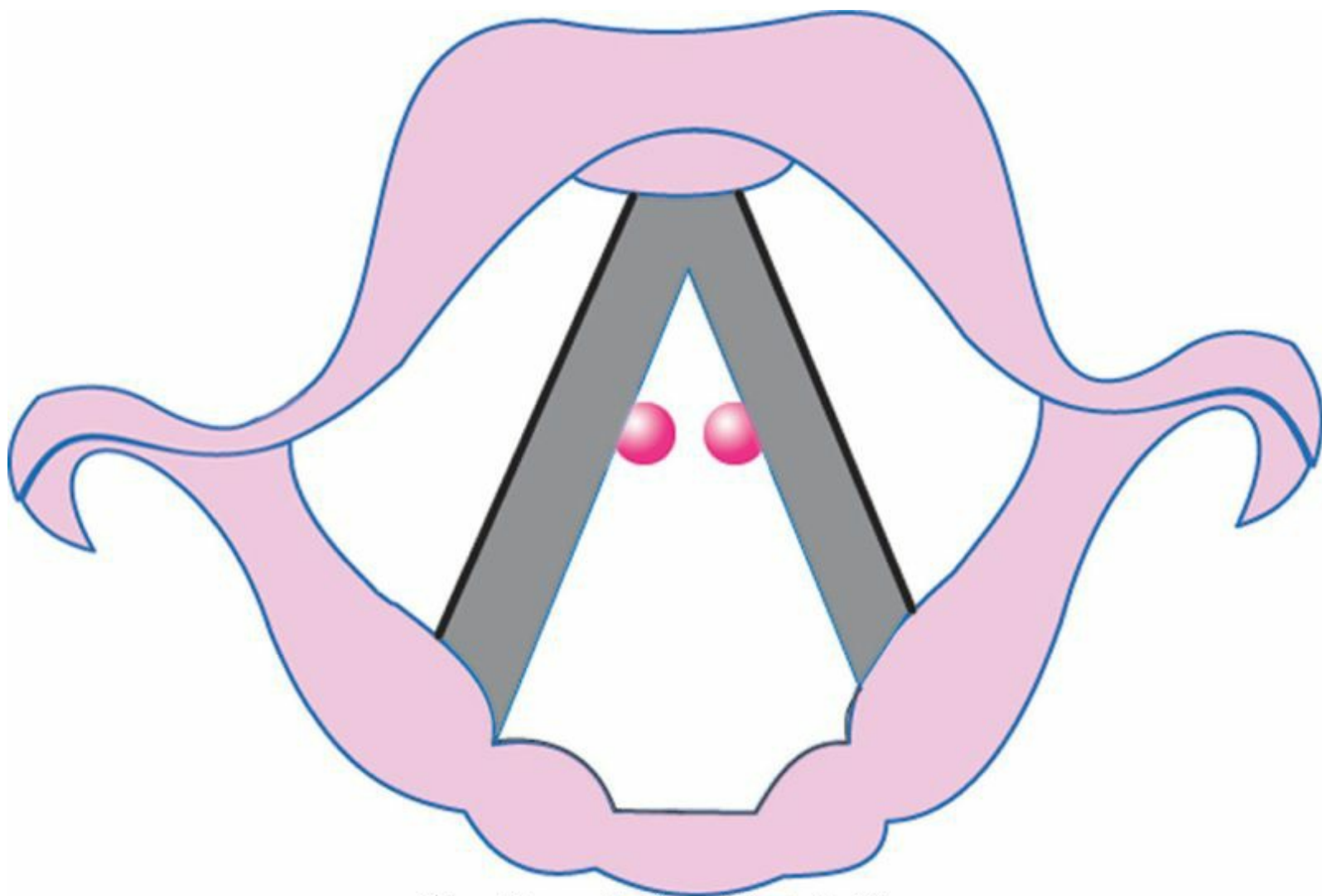
Pathologically, trauma to the vocal cord in the form of vocal abuse or misuse causes oedema and haemorrhage in the submucosal space. This undergoes hyalinisation and fibrosis. The overlying epithelium also undergoes hyperplasia forming a nodule. In early stages, the nodules appear soft, reddish and oedematous swellings but later become greyish or white in colour.

Patients with vocal nodules complain of hoarseness. Vocal fatigue and pain in the neck on prolonged phonation, are other common symptoms.

Early cases of vocal nodules can be treated conservatively by educating the patient in proper use of voice. With this treatment, many nodules in children disappear completely. Surgery is required for large nodules or nodules of long-standing in adults. They are excised with precision under operating microscope avoiding any trauma to the underlying vocal ligament.

Speech therapy and re-education in voice production are essential to prevent their recurrence.





Dhingra: Diseases of Ear Nose and Throat, 5th Edition  
 Copyright © 2010 Elsevier. All rights reserved.

Figure 60.1 Vocal nodules. Typically, they form at the junction of anterior one-third with posterior two-thirds of vocal cord.

## 2. Vocal Polyp

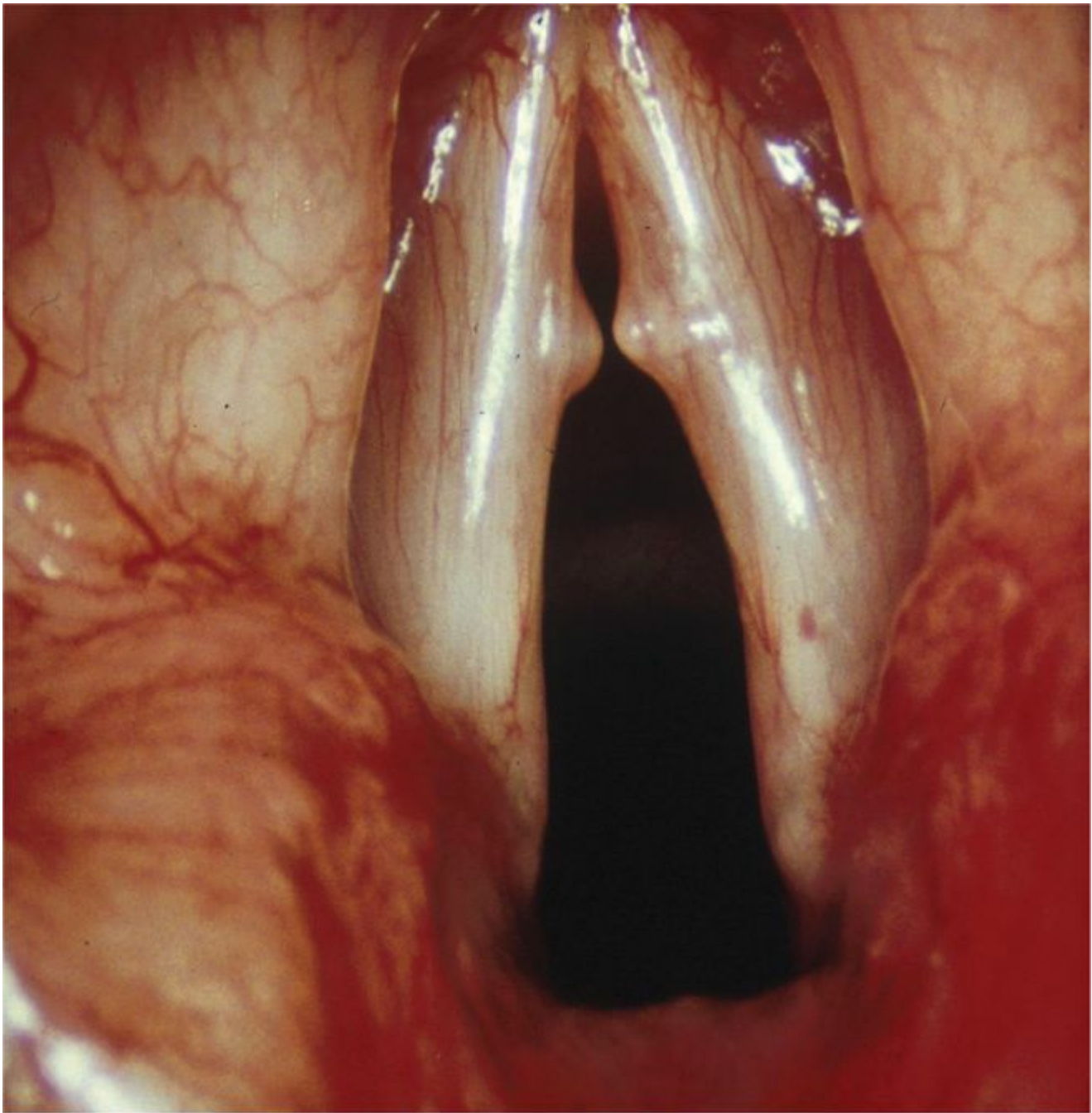
It is also the result of vocal abuse or misuse. Other contributing factors are allergy and smoking. Mostly, it affects men in the age group of 30-50. Typically, a vocal polyp is unilateral arising from the same position as vocal nodule. It is soft, smooth and often pedunculated. It may flop up and down the glottis during respiration or phonation. Hoarseness is a common symptom. Large polyp may cause dyspnoea, stridor or intermittent choking. Some patients complain of diplophonia (double voice) due to different vibratory frequencies of the two vocal cords.

Vocal polyp is caused by sudden shouting resulting in haemorrhage in the vocal cord and subsequent submucosal oedema. Treatment is surgical excision under operating microscope followed by speech therapy.

## 3. Reinke's Oedema (Bilateral Diffuse Polyposis)

This is due to collection of oedema fluid in the subepithelial space of Reinke. Usual cause is vocal abuse and smoking. Both vocal cords show diffuse symmetrical swellings. Treatment is vocal cord stripping, preserving enough mucosa for epithelialisation. Only one cord is operated at a time. Re-education in voice production and cessation of smoking are essential to prevent recurrence.

## 4. Contact Ulcer



Dhingra: Diseases of Ear Nose and Throat, 5th Edition  
Copyright © 2010 Elsevier. All rights reserved.

Figure 60.2 Vocal nodules.

This is again due to faulty voice production in which vocal processes of arytenoids hammer against each other resulting in ulceration and granuloma formation. Some cases are due to gastric reflux. Chief complaints are hoarse voice, a constant desire to clear the throat and pain in the throat which is worse on phonation. Examination reveals unilateral or bilateral ulcers with congestion of arytenoid cartilages. There may be granuloma formation.

### **5. Intubation Granuloma**

It results from injury to vocal processes of arytenoids due to rough intubation, use of large tube or prolonged presence of tube between the cords. Mucosal ulceration is followed by granuloma formation over the exposed cartilage. Usually, they are bilateral involving posterior thirds of true cords. They present with hoarseness and if large, dyspnoea. Treatment is voice rest and endoscopic removal of the granuloma.

### **6. Leukoplakia or Keratosis**

This is also a localised form of epithelial hyperplasia involving upper surface of one or both vocal cords. It appears as a white plaque or warty growth on the cord without affecting its mobility. It is regarded as a precancerous condition because "carcinoma in situ" frequently supervenes. Hoarseness is the common presenting symptom. Treatment is stripping of vocal cords and subjecting the tissues to histology for any malignant change. Chronic laryngeal irritants as the aetiological factors should be sought and eliminated.

### **7. Amyloid Tumour**

It mostly affects men in the age group of 50-70. The tumour presents as a smooth plaque or a pedunculated mass. Diagnosis is only on histology. Treatment is endoscopic surgical excision.

## B. Cystic Lesions

They are of three types:

### 1. *Ductal cysts*

Most often they are retention cysts due to blockage of ducts of seromucinous glands of laryngeal mucosa. They are seen in the vallecula, aryepiglottic fold, false cords, ventricles and pyriform fossa. They may remain asymptomatic if small, or cause hoarseness, cough, throat pain and dyspnoea, if large (Fig. 60.3).

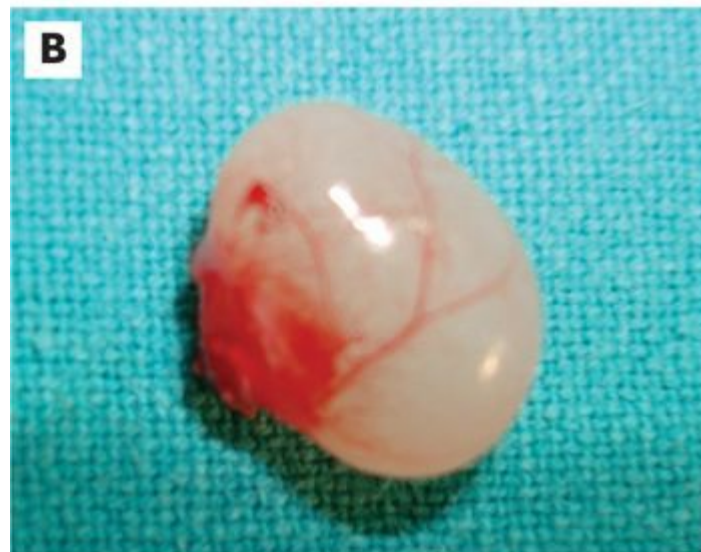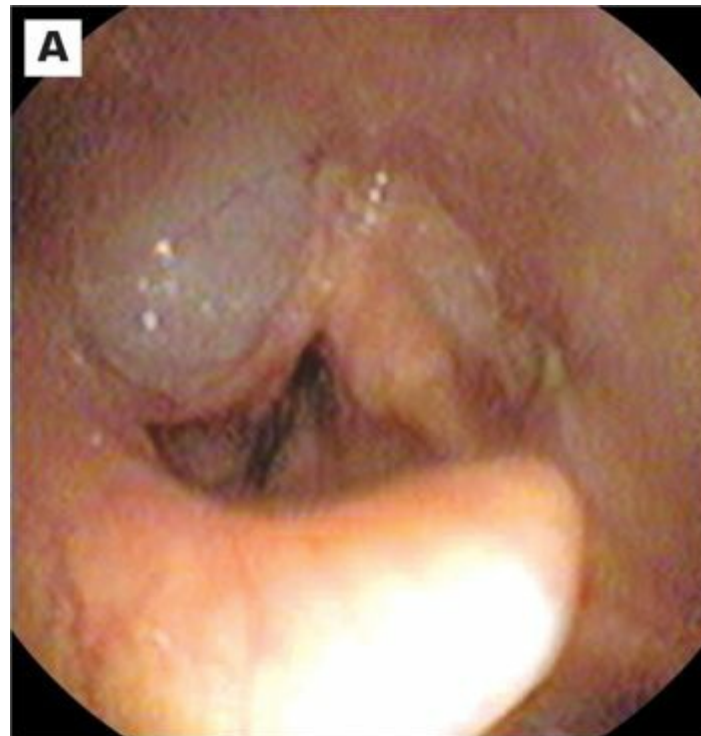
Sometimes, an intracordal cyst may occur on the true cord. It is similar to an epidermoid inclusion cyst.

### 2. *Saccular cysts*

Obstruction to the orifice of sacculae causes retention of secretion and distension of sacculae which presents as a cyst in laryngeal ventricle. *Anterior saccular cysts* present in the anterior part of ventricle and obscure part of vocal cord. *Lateral saccular cysts*, which are larger, extend into the false cord, aryepiglottic fold and may even appear in the neck through thyrohyoid membrane just as laryngoceles do.

page 323

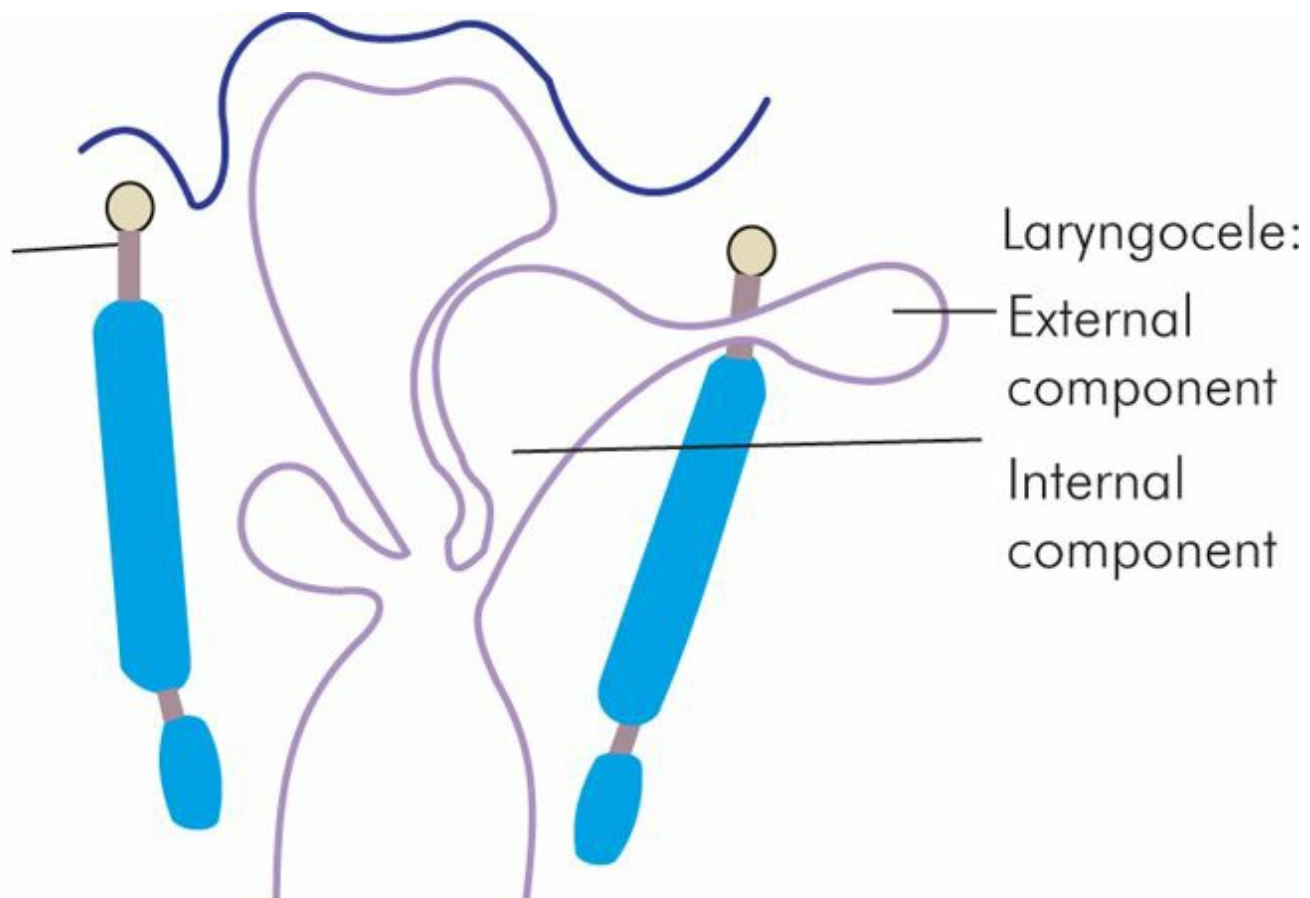
page 324



Dhingra: Diseases of Ear Nose and Throat, 5th Edition  
Copyright © 2010 Elsevier. All rights reserved.

Figure 60.3 (A) Aryepiglottic cyst. It caused intermittent laryngeal obstruction. (B) Cyst after removal.

Thyrohyoid  
membrane



Laryngocele:  
External  
component  
Internal  
component

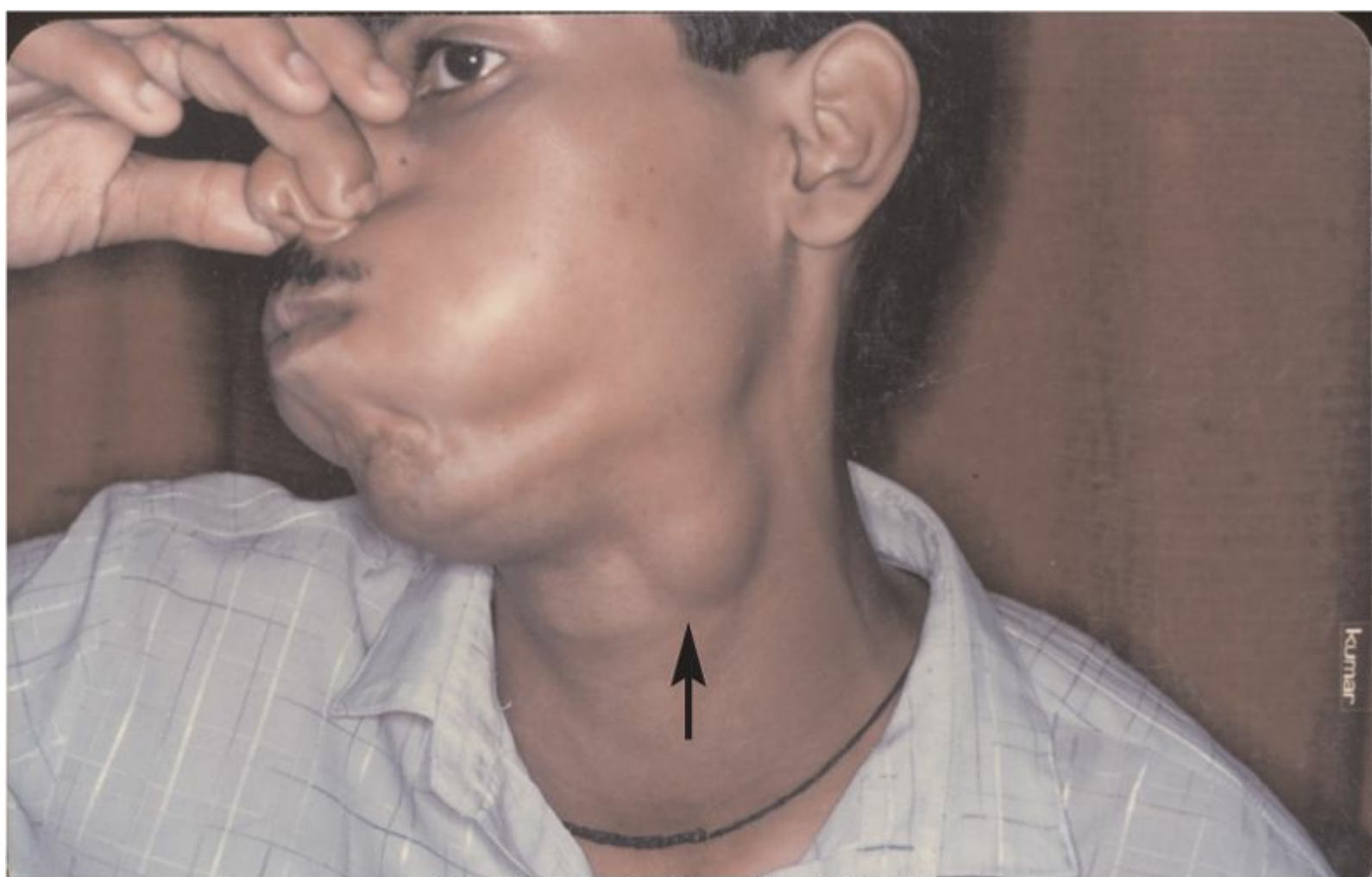Dhingra: Diseases of Ear Nose and Throat, 5th Edition  
Copyright © 2010 Elsevier. All rights reserved.

Figure 60.4 Laryngocele mixed type with internal and external components.

### 3. Laryngocele

It is an air-filled cystic swelling due to dilatation of the saccule (Fig. 60.4). A laryngocele may be:

- (i) *Internal* which is confined within the larynx and presents as distension of false cord and aryepiglottic fold.
- (ii) *External* in which distended saccule herniates through the thyrohyoid membrane and presents in neck; or
- (iii) *Combined or mixed* in which both internal and external components are seen.



Dhingra: Diseases of Ear Nose and Throat, 5th Edition  
Copyright © 2010 Elsevier. All rights reserved.

Figure 60.5 Laryngocele left side as seen on Valsalva (arrow).

A laryngocele is supposed to arise from raised transglottic air pressure as in trumpet players, glass-blowers or weight lifters.

A laryngocele presents with hoarseness, cough and if large, obstruction to the airway. An external laryngocele presents as a reducible swelling in the neck which increases in size on coughing or performing Valsalva (Fig. 60.5).

Diagnosis can be made by indirect laryngoscopy, and soft tissue A.P. and lateral views of neck with Valsalva. CT scan helps to find the extent of lesion.

Treatment is surgical excision through an external neck incision. Marsupialisation of an internal laryngocele can be done by laryngoscopy but there are chances of recurrence.

A laryngocele in an adult may be associated with carcinoma.

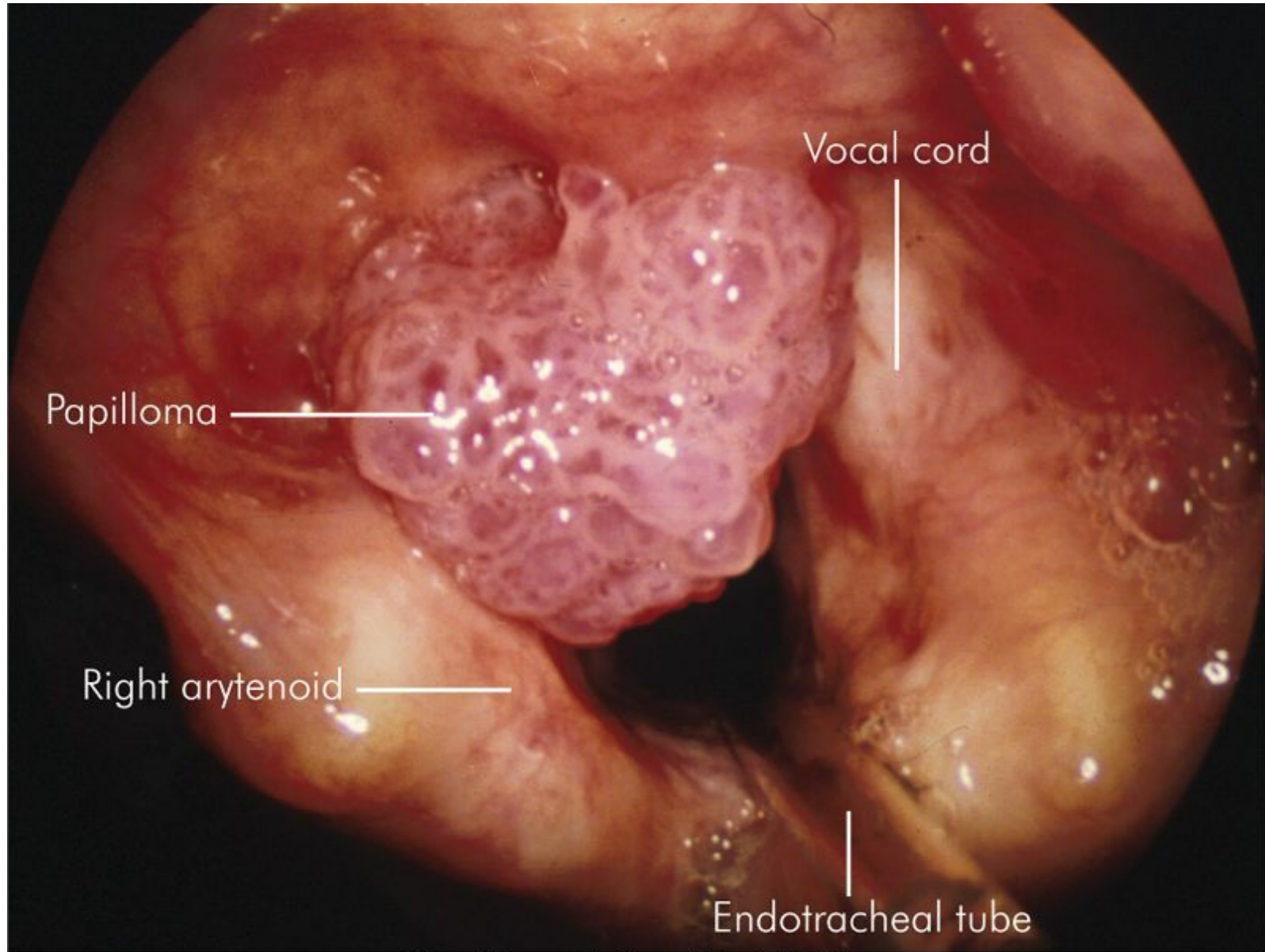
## NEOPLASTIC

Except for laryngeal papillomas which constitute about 80% of the total occurrence of neoplasms of the larynx, others are uncommon.

# 1. Squamous Papillomas

They can be divided into (a) juvenile and (b) adult-onset types.

## (a) Juvenile papillomas



Dhingra: Diseases of Ear Nose and Throat, 5th Edition  
Copyright © 2010 Elsevier. All rights reserved.

Figure 60.6 Supraglottic papillomatosis.

They are viral in origin and multiple, often involving infants and young children who present with hoarseness and stridor. They are mostly seen on the true and false cords and the epiglottis, but they may involve other sites in the larynx and trachea. Clinically, they appear as glistening white irregular growths, pedunculated or sessile, friable and bleeding easily (Fig. 60.6). They are known for recurrence after removal and therefore multiple laryngoscopies may be required. They tend to disappear spontaneously after puberty. They have been treated by endoscopic removal with cup forceps, cryotherapy and microelectrocautery. These days, CO<sub>2</sub> laser is preferred because of the precision in removal and less bleeding. Interferon therapy is being tried to prevent recurrence and has been found successful.

## (b) Adult-onset papilloma

Usually, it is single, smaller in size, less aggressive and does not recur after surgical removal. It is common in males (2:1) in the age group of 30-50 and usually arises from the anterior half of vocal cord or anterior commissure. Treatment is the same as for juvenile type.



## 2. Chondroma

Most of them arise from cricoid cartilage and may present in the subglottic area causing dyspnoea or may grow outward from the posterior plate of cricoid and cause sense of lump in throat and dysphagia. They mostly affect men in the age group of 40-60.

### 3. Haemangioma

Infantile haemangioma involves the subglottic area and presents with stridor in the first 6 months of life. About 50% of such children have haemangiomas elsewhere in the body particularly in the head and neck area. They tend to involute spontaneously but a tracheostomy may be needed to relieve respiratory obstruction if airway is compromised. Most of them are of capillary type and can be vaporised with CO<sub>2</sub> laser.

Adult haemangiomas involve vocal cord or supraglottic larynx. They are cavernous type and cannot be treated with laser. They are left alone if asymptomatic. For larger ones causing symptoms, steroid or radiation therapy may be employed.

#### 4. Granular Cell Tumour

It arises from Schwann cells and is often submucosal. Overlying epithelium shows pseudoepitheliomatous hyperplasia, which may on histology, resemble well differentiated carcinoma.

## 5. Glandular Tumour

Pleomorphic adenoma or oncocytoma are rare glandular tumours.

Other rare benign laryngeal tumours include **rhabdomyoma, neurofibroma, neurilemmoma, lipoma or fibroma.**

## 61 Cancer Larynx

### Epidemiology

Cancer larynx constitutes 2.63% of all body cancers in India. It is 10 times more common in males than in females (4.79% versus 0.47%). Its incidence is 3.29 new cases in males and 0.42 new cases in females per 100,000 population (National Cancer Registry, ICMR, April 2005 report). Recently, its incidence in females has increased in western countries due to more women taking to smoking. Disease is mostly seen in the age group of 40-70 years but younger people in 30s may occasionally be affected.

# Aetiology

**Table 61-1. Classification of sites and various subsites under each site in larynx (AJCC classification 2002)**

Site	Subsite
Supraglottis	<ul style="list-style-type: none"><li>• Suprahyoid epiglottis (both lingual and laryngeal surfaces)</li><li>• Infrahyoid epiglottis</li><li>• Aryepiglottic folds (laryngeal aspect only)</li><li>• Arytenoids</li><li>• Ventricular bands (or false cords)</li></ul>
Glottis	<ul style="list-style-type: none"><li>• True vocal cords including anterior and posterior commissure</li></ul>
Subglottis	<ul style="list-style-type: none"><li>• Subglottis up to lower border of cricoid cartilage</li></ul>

Both *tobacco* and *alcohol* are well established risk factors in laryngeal cancer. Cigarette smoke contains benzopyrene and other hydrocarbons which are carcinogenic in man. Combination of alcohol and smoking increases the risk 15-folds compared to each factor alone (2-3 folds). *Previous radiation* to neck for benign lesions or laryngeal papilloma may induce laryngeal carcinoma. Japanese and Russian workers have reported cases of familial laryngeal malignancy incriminating *genetic factors*. *Occupational exposure* to asbestos, mustard gas and other chemical or petroleum products has also been related to the genesis of laryngeal cancer but without conclusive evidence.

## TNM Classification and Staging

According to AJCC (2002), larynx has been divided into three sites (or regions) with several subsites under each site (see Table 61.1 and Fig. 61.1).

Tumours arising from these sites are further classified by TNM system where:

- T-indicates tumour and its extent, e.g. T<sub>1</sub>, T<sub>2</sub>, T<sub>3</sub>, etc.
- N-indicates regional lymph node enlargement and its size, e.g. N<sub>0</sub>, N<sub>1</sub>, N<sub>2</sub>, etc.
- M-indicates distant metastasis. Absence of metastasis is M<sub>0</sub> while presence of metastasis is M<sub>1</sub>. Depending on TNM, tumour is further grouped into various stages.

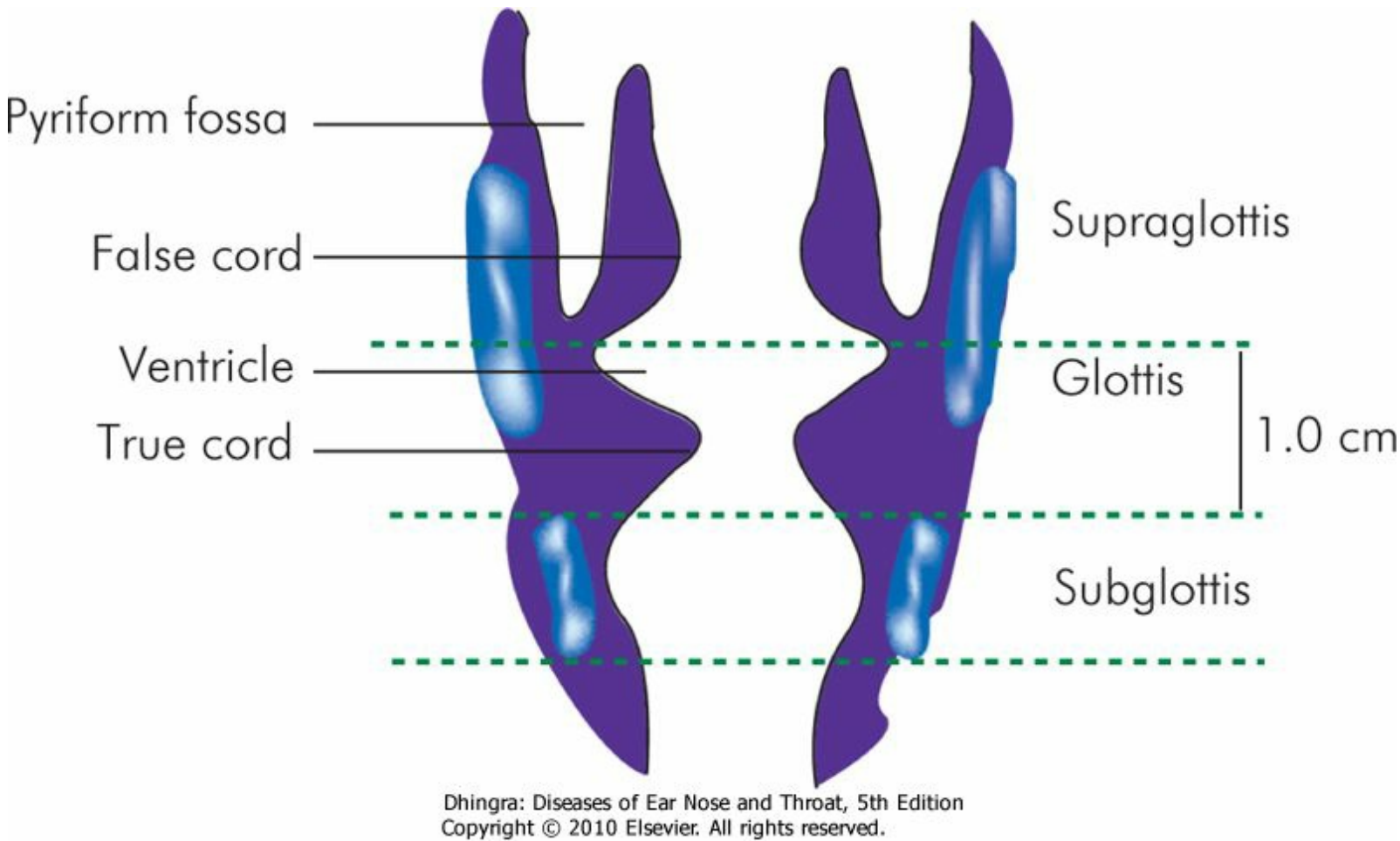


Figure 61.1 According to AJCC, glottis extends from the horizontal plane passing through lateral margin of ventricle at its junction with superior surface of the vocal cord to 1 cm below it. Subglottis extends from lower limit of glottis to lower border of cricoid cartilage.

Thus, each laryngeal cancer can be staged, depending upon the extent of disease, nodal or distant metastasis (Table 61.2). This international staging of disease helps to compare the results of different modalities of treatment by different workers and assists in the choice of treatment and prognosis of disease.

# Histopathology

About 90-95% of laryngeal malignancies are squamous cell carcinoma with various grades of differentiation. Cordal lesions are often well-differentiated while supraglottic ones are anaplastic.

The rest 5-10% of lesions include verrucous carcinoma, spindle cell carcinoma, malignant salivary gland tumours and sarcomas.

## 1. Supraglottic Cancer

Supraglottic cancer is less frequent than glottic cancer. Majority of lesions are seen on epiglottis, false cords followed by aryepiglottic folds, in that order.

### **Spread**

Cancer of supraglottic region may spread locally and invade the adjoining areas, i.e. vallecula, base of tongue and pyriform fossa. Cancer of infrahyoid epiglottis and anterior ventricular band may extend into pre-epiglottic space and penetrate the thyroid cartilage.

Nodal metastases occur early. Upper and middle jugular nodes are often involved. Bilateral metastases may be seen in cases of epiglottic cancer.

### **Symptoms**

Supraglottic growths are often silent. Hoarseness is a late symptom. Throat pain, dysphagia and referred pain in the ear or mass of lymph nodes in the neck may be the presenting features. Weight loss, respiratory obstruction, halitosis are late features.

## 2. Glottic Cancer

In vast majority of cases, laryngeal cancer originates in the glottic region. Free edge and upper surface of vocal cord in its anterior and middle third is the most frequent site (Fig. 61.2).

### **Spread**

Locally, the lesion may spread anteriorly to anterior commissure and then to the opposite cord; posteriorly to vocal process and arytenoid region; upward to ventricle and false cord; and downwards to subglottic region. Vocal cord mobility is unaffected in early stages.

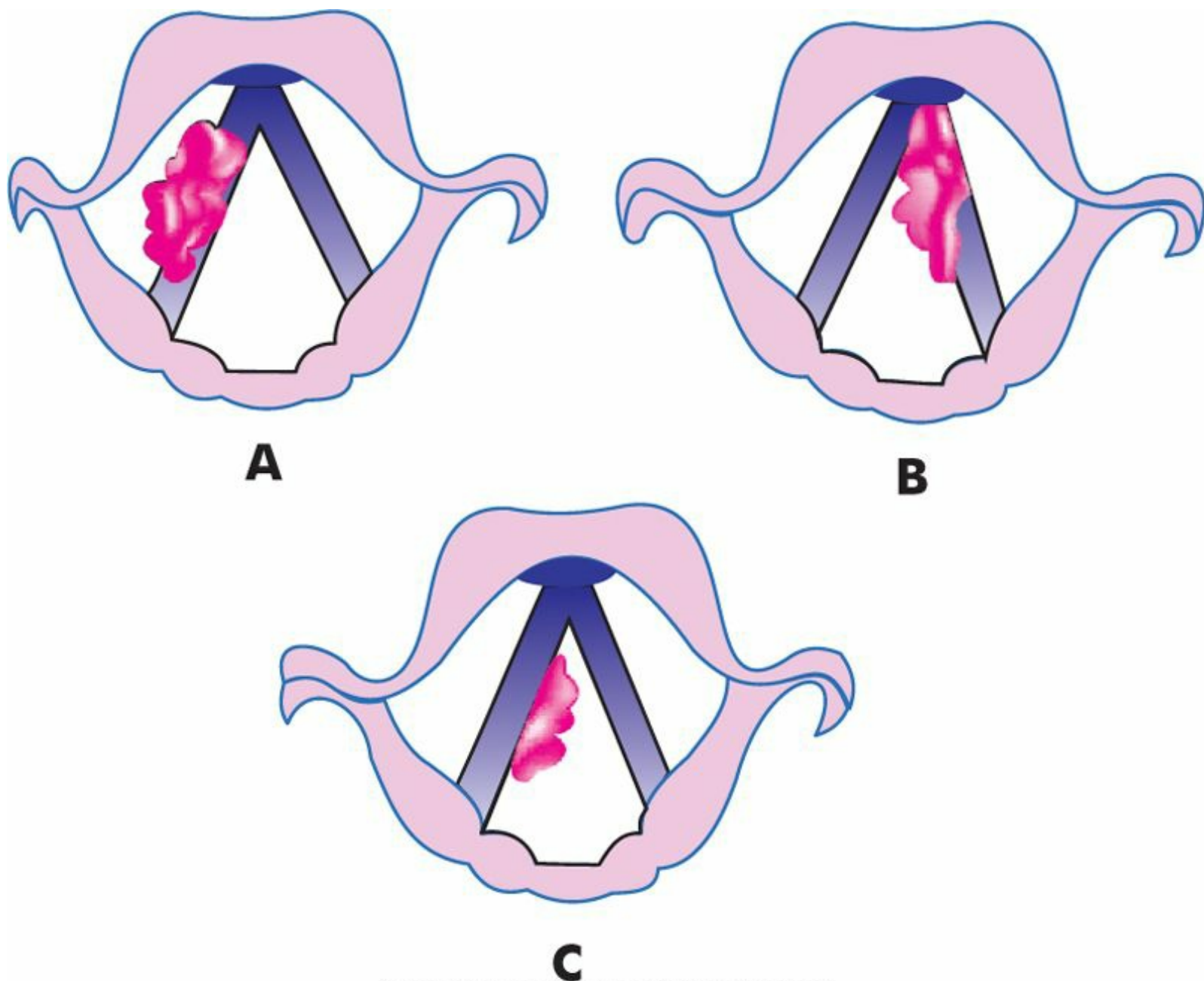
Fixation of vocal cord indicates spread of disease to thyroarytenoid muscle and is a bad prognostic sign.

There are few lymphatics in vocal cords and nodal metastasis are practically never seen in cordal lesions unless the disease spreads beyond the region of membranous cord.

### **Symptoms**

Hoarseness of voice is an early sign because lesions of cord affect its vibratory capacity. It is because of this that glottic cancer is detected early.





Dhingra: Diseases of Ear Nose and Throat, 5th Edition  
Copyright © 2010 Elsevier. All rights reserved.

Figure 61.2 Cancer larynx (A) Supraglottic, (B) Glottic, (C) Subglottic.

Increase in size of growths with accompanying oedema or cord fixation may cause stridor and laryngeal obstruction.

### 3. Subglottic Cancer (1-2%)

Subglottic region extends from glottic area to lower border of cricoid cartilage. Lesions of this region are rare.

#### **Spread**

Growth starts on one side of subglottis and may spread around the anterior wall to the opposite side or downwards to the trachea. Upward spread to the vocal cords is late and that is why hoarseness is not an early symptom. Subglottic growths can invade cricothyroid membrane, thyroid gland and ribbon muscles of neck.

Lymphatic metastases go to prelaryngeal, pretracheal, paratracheal and lower jugular nodes.

#### **Symptoms**

The earliest presentation of subglottic cancer may be stridor or laryngeal obstruction but this is often late and by this time disease has already spread sufficiently to encroach the airway.

Hoarseness of voice indicates spread of disease to the undersurface of vocal cords, infiltration of thyroarytenoid muscle or the involvement of recurrent laryngeal nerve at the cricoarytenoid joint. Hoarseness of voice is a late feature of subglottic growth.

# Diagnosis of Laryngeal Cancer

## 1. History

Symptomatology of glottic, subglottic and supraglottic lesions would vary and is described under appropriate heads. It is a dictum that *any patient in cancer age group having persistent or gradually increasing hoarseness of voice for 3 weeks must have laryngeal examination to exclude cancer.*

page 327

page 328

**Table 61-2. TNM classification of cancer larynx (American Joint Committee on Cancer, 2002)**

<b>Supraglottis</b>	
T <sub>1</sub>	Tumour limited to one subsite of supraglottis with normal vocal cord mobility
T <sub>2</sub>	Tumour invades mucosa of more than one adjacent subsite of supraglottis or glottis or region outside the supraglottis (e.g., mucosa of base of tongue, vallecula, medial wall of pyriform sinus) without fixation of the larynx
T <sub>3</sub>	Tumour limited to larynx with vocal cord fixation and/or invades any of the following: postcricoid area, pre-epiglottic tissues, paraglottic space and/or minor thyroid cartilage invasion
T <sub>4a</sub>	Tumour invades through the thyroid cartilage and/or invades tissues beyond the larynx (e.g., trachea, soft tissues of neck including deep extrinsic muscle of tongue, strap muscles, thyroid or oesophagus)
T <sub>4b</sub>	Tumour invades prevertebral space, encases carotid artery or invades mediastinal structures
<b>Glottis</b>	
T <sub>1</sub>	Tumour limited to vocal cord(s) (may involve anterior or posterior commissures) with normal mobility
T <sub>1a</sub>	Tumour limited to one vocal cord
T <sub>1b</sub>	Tumour involves both vocal cords
T <sub>2</sub>	Tumour extends to supraglottis and/or subglottis, and/or with impaired vocal cord mobility
T <sub>3</sub>	Tumour limited to the larynx with vocal cord fixation and/or invades paraglottic space and/or minor thyroid cartilage erosion
T <sub>4a</sub>	Tumour invades through thyroid cartilage and/or invades tissues beyond the larynx (e.g., trachea, soft tissues of neck including deep extrinsic muscles of the tongue, strap muscles, thyroid, or oesophagus)
T <sub>4b</sub>	Tumour invades prevertebral space, encases carotid artery or invades mediastinal structures
<b>Subglottis</b>	
T <sub>1</sub>	Tumour limited to the subglottis
T <sub>2</sub>	Tumour extends to vocal cord(s) with normal or impaired mobility
T <sub>3</sub>	Tumour limited to larynx with vocal cord fixation
T <sub>4a</sub>	Tumour invades cricoid or thyroid cartilage and/or invades tissues beyond the larynx (e.g., trachea, soft tissues of neck including deep extrinsic muscle of tongue, strap muscles, thyroid or oesophagus)
T <sub>4b</sub>	Tumour invades prevertebral space, encases carotid artery or invades mediastinal structures

Source: Greene FL, Page DL, Fleming ID, et al. (editors). American Joint Committee on Cancer Staging Manual, 6th edition, New York: Springer-Verlag, 2002.

<b>Regional lymph nodes (N)</b>	
N <sub>x</sub>	Regional lymph nodes cannot be assessed
N <sub>0</sub>	No regional lymph node metastasis
N <sub>1</sub>	Metastasis in a single ipsilateral lymph node, 3 cm or less in greatest dimension
N <sub>2</sub>	Metastasis in a single ipsilateral lymph node, more than 3 cm but not more than 6 cm in greatest dimension, or multiple ipsilateral lymph nodes, none more than 6 cm in greatest dimension, or bilateral or contralateral lymph nodes, none more than 6 cm in greatest dimension.
N <sub>2a</sub>	Metastasis in a single ipsilateral lymph node more than 3 cm but not more than 6 cm in greatest dimension
N <sub>2b</sub>	Metastasis in multiple ipsilateral lymph nodes, none more than 6 cm in greatest dimension
N <sub>2c</sub>	Metastasis in bilateral or contralateral lymph nodes, none more than 6 cm in greatest dimension
N <sub>3</sub>	Metastasis in a lymph node more than 6 cm in greatest dimension
<b>Distant metastasis (M)</b>	
M <sub>x</sub>	Distant metastasis cannot be assessed
M <sub>0</sub>	No distant metastasis
M <sub>1</sub>	Distant metastasis

Stage grouping			
0	T <sub>is</sub>	N <sub>0</sub>	M <sub>0</sub>
I	T <sub>1</sub>	N <sub>0</sub>	M <sub>0</sub>
II	T <sub>2</sub>	N <sub>0</sub>	M <sub>0</sub>
III	T <sub>3</sub>	N <sub>0</sub>	M <sub>0</sub>
	T <sub>1</sub>	N <sub>1</sub>	M <sub>0</sub>
	T <sub>2</sub>	N <sub>1</sub>	M <sub>0</sub>
	T <sub>3</sub>	N <sub>1</sub>	M <sub>0</sub>
IVA	T <sub>4a</sub>	N <sub>0</sub>	M <sub>0</sub>
	T <sub>4a</sub>	N <sub>1</sub>	M <sub>0</sub>
	T <sub>1</sub>	N <sub>2</sub>	M <sub>0</sub>
	T <sub>2</sub>	N <sub>2</sub>	M <sub>0</sub>
	T <sub>3</sub>	N <sub>2</sub>	M <sub>0</sub>
	T <sub>4a</sub>	N <sub>2</sub>	M <sub>0</sub>
IVB	T <sub>4b</sub>	Any N	M <sub>0</sub>
	Any T	N <sub>3</sub>	M <sub>0</sub>
IVC	Any T	Any N	M <sub>1</sub>
Histopathologic grade (G)			
Grade 1:	Well-differentiated		
Grade 2:	Moderately differentiated		
Grade 3:	Poorly differentiated		

## 2. Indirect laryngoscopy

- **(a) Appearance of lesion.** Appearance of lesion will vary with the site of origin.
  - (i) Lesions of suprahoid epiglottis are usually exophytic while those of infrahyoid epiglottis are ulcerative.
  - (ii) Lesion of vocal cord may appear as raised nodule, ulcer or thickening.
  - (iii) Lesion of anterior commissure may appear as granulation tissue.
  - (iv) Lesion of subglottic region appears as a raised submucosal nodule, mostly involving the anterior half.
- **(b) Vocal cord mobility.** Impairment or fixation of vocal cord indicates deeper infiltration into thyroarytenoid muscle, cricoarytenoid joint or invasion of recurrent laryngeal nerve, and is an important sign.
- **(c) Extent of disease.** Spread of disease to vallecula, base of tongue, pyriform fossa should be noticed.

## 3. Examination of neck

It is done to find (i) extralaryngeal spread of disease, and (ii) nodal metastasis. Growths of anterior commissure and subglottic region spread through cricothyroid membrane and may produce a midline swelling. They may also invade the thyroid cartilage and cause perichondritis when cartilage will be tender on palpation. Thyroid gland and strap muscles may also be invaded.

Search should be made for metastatic lymph nodes, their size and number; and also if they are mobile or fixed, unilateral, bilateral or contralateral.

## 4. Radiography

- **(a) X-ray chest** is essential for co-existent lung disease (e.g. tuberculosis), pulmonary metastasis or mediastinal nodes.
- **(b) Soft tissue lateral view neck.** Extent of lesions of epiglottis, aryepiglottic folds, arytenoids and involvement of pre-epiglottic space may be seen. Destruction of thyroid cartilage may be seen. This is now superseded by CT scan and MRI.
- **(c) Contrast laryngograms.** Radio-opaque dye, dionosil, is instilled into the larynx. Laryngograms outline the surface extent of tumours. This investigation has now been replaced by CT scan.
- **(d) CT scan.** It is a very useful investigation to find the extent of tumour, invasion of pre-epiglottic or paraepiglottic space, destruction of cartilage and lymph node involvement.

## 5. Direct laryngoscopy

It is done to see (a) the hidden areas of larynx and (b) extent of disease.

Hidden areas of the larynx include infrahyoid epiglottis, anterior commissure, subglottis and ventricle, which may not be clearly seen by mirror examination making direct laryngoscopy essential.

### **6. Microlaryngoscopy**

For small lesions of vocal cords, laryngoscopy is done under microscope to better visualise the lesion and take more accurate biopsy specimens without damaging the cord.

### **7. Supravital staining and biopsy**

Toluidine blue is applied to the laryngeal lesion and then washed with saline and examined under the operating microscope. Carcinoma-in-situ and superficial carcinomas take up the dye while leukoplakia does not. Thus, it helps to select the area for biopsy in a leukoplakic patch.

# Treatment of Laryngeal Cancer

It depends upon the site of lesion, extent of lesion, presence or absence of nodal and distant metastases. Treatment consists of:

- 1. Radiotherapy
- 2. Surgery, (a) conservation laryngeal surgery, (b) total laryngectomy
- 3. Combined therapy.

## 1. Radiotherapy

Curative radiotherapy is reserved for early lesions which neither impair cord mobility nor invade cartilage or cervical nodes. Cancer of the vocal cord without impairment of its mobility gives a 90% cure rate after irradiation and has the advantage of preservation of voice. Superficial exophytic lesions, especially of the tip of epiglottis, and aryepiglottic folds give 70-90% cure rate. Radiotherapy does not give good results in lesions with fixed cords, subglottic extension, cartilage invasion, and nodal metastases. These lesions require surgery.

## 2. Surgery

### (a) Conservation surgery

Earlier total laryngectomy was done for most of the laryngeal cancers and the patient was left with no voice and a permanent tracheostome. Lately, there has been a trend for conservation laryngeal surgery which can preserve voice and also avoid a permanent tracheal opening. However, few cases would be suitable for this type of surgery and they should be carefully selected. Conservation surgery includes:

- (i) Excision of vocal cord after splitting the larynx (cordectomy via laryngofissure),
- (ii) Excision of vocal cord and anterior commissure region (partial frontolateral laryngectomy),
- (iii) Excision of supraglottis, i.e. epiglottis, aryepiglottic folds, false cords and ventricle—a sort of transverse section of larynx above the vocal cords (partial horizontal laryngectomy).

page 329

page 330

### (b) Total laryngectomy

The entire larynx including the hyoid bone, pre-epiglottic space, strap muscles, and one or more rings of trachea are removed. Pharyngeal wall is repaired and lower tracheal stump sutured to the skin for breathing.

Laryngectomy may be combined with block dissection for nodal metastasis.

Total laryngectomy is indicated in the following conditions:

- T<sub>3</sub> lesions (i.e. with cord fixed)
- All T<sub>4</sub> lesions
- Invasion of thyroid or cricoid cartilage
- Bilateral arytenoid cartilage involvement
- Lesions of posterior commissure
- Failure after radiotherapy or conservation surgery
- Transglottic cancers, i.e. tumours involving supraglottis and glottis across the ventricle, causing fixation of the vocal cord.

It is contraindicated in patients with distant metastasis.

## 3. Combined therapy

Surgical ablation may be combined with pre- or post-operative radiation to decrease the incidence of recurrence. Pre-operative radiation may also render fixed nodes resectable.

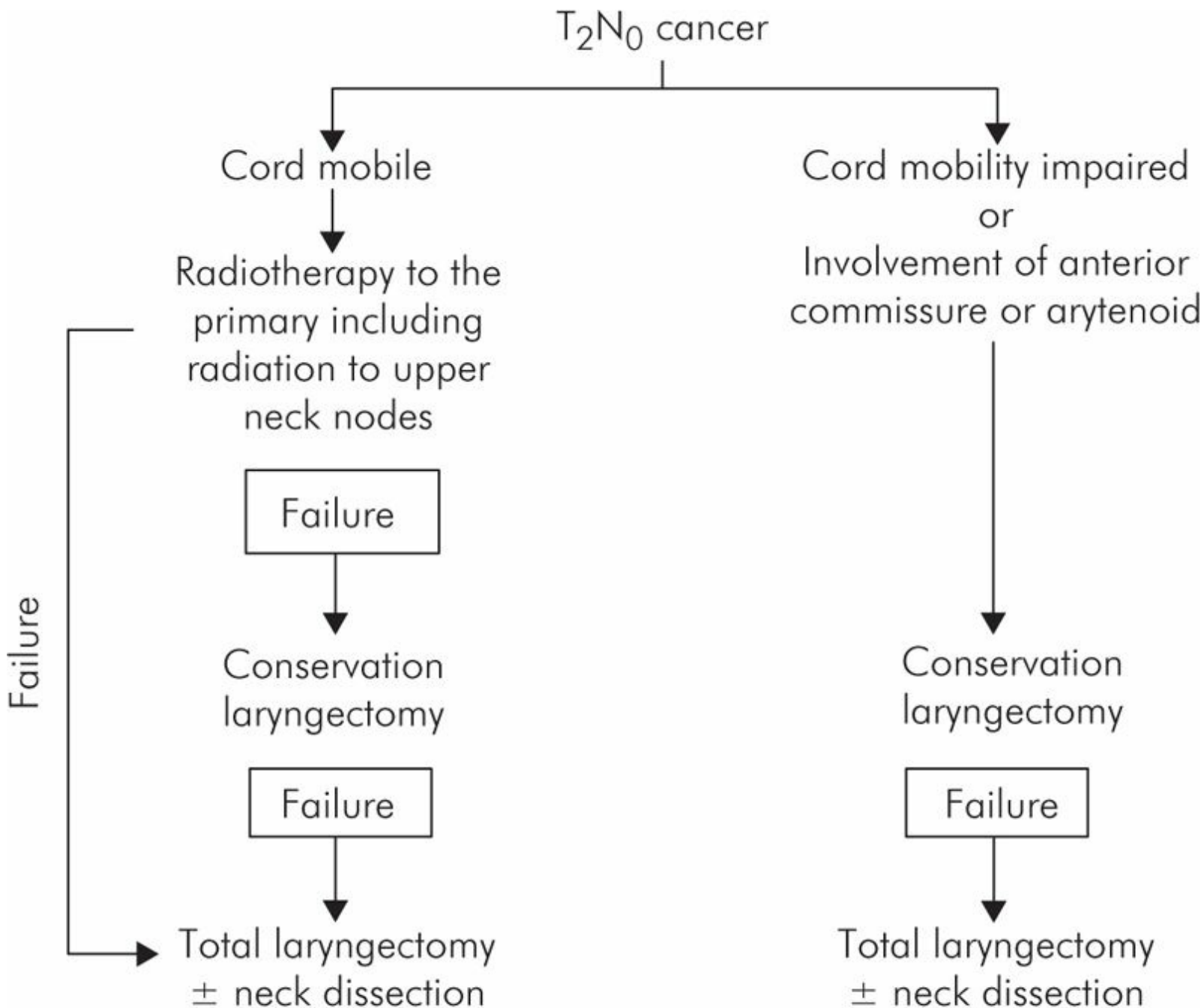
# Glottic Carcinoma

## ***Carcinoma-in-situ***

It is best treated by transoral endoscopic CO<sub>2</sub> laser. If laser is not available, stripping of vocal cord is done under microscope and tissue subjected to biopsy. If biopsy shows invasive carcinoma, give radiotherapy. If biopsy confirms only carcinoma in situ, treatment is regular follow-up.

## ***Invasive carcinoma***

- *T<sub>1</sub>-carcinoma*-Radiotherapy is the treatment of choice. If radiotherapy is refused or not available, excision of cord by endoscopic CO<sub>2</sub> laser or laryngofissure is performed.
- *T<sub>1</sub>-carcinoma with extension to anterior commissure*. Radiotherapy is the best choice. In the absence of this, frontolateral partial laryngectomy is done with regular follow-up. If it fails, total laryngectomy is performed.
- *T<sub>1</sub>-carcinoma with extension to arytenoid*. Treatment is same as above but surgery is preferred.
- *T<sub>2</sub>N<sub>0</sub>*-It implies tumour of the glottic region, i.e. vocal cord(s), anterior commissure and/or vocal process of the arytenoid with extension to supraglottic or subglottic regions but with no lymph node involvement. Treatment depends on two factors (see Fig. 61.3).
  1. Is mobility of vocal cord normal or impaired?
  2. Is there involvement of anterior commissure and/or arytenoid?



If cord is mobile and anterior commissure and arytenoid is not involved, radiotherapy gives good results. Such patients are kept under regular follow-up. If disease recurs, total laryngectomy is performed. Some surgeons will still consider partial vertical laryngectomy to preserve voice in such radiation-failed cases.

If anterior commissure and/or arytenoid is involved or cord mobility is impaired, radiotherapy is not preferred because of the possibility of developing perichondritis which would entail total laryngectomy. In such cases, some form of conservation surgery such as vertical hemilaryngectomy or frontolateral laryngectomy is done to preserve the voice. Such patients are also kept under regular follow-up and converted to total laryngectomy if disease recurs.

In N<sub>0</sub> neck, in T<sub>2</sub> carcinoma, chances of occult nodal metastasis are less than 25%, therefore prophylactic neck dissection is not done. However, if radiation is considered the mode of treatment, for the primary, upper neck nodes are included in the radiation field.

Cord mobility is important in determining the outcome of T<sub>2</sub> lesions. Normal cord mobility suggests growth is only limited to the surface. Impaired mobility indicates deeper invasion into intrinsic laryngeal muscles or paraglottic space and thus poor response to radiation. Invasion of paraglottic or subglottic space is also associated with undetected invasion of laryngeal cartilages and hence poor survival results. With radiation, cure rate of T<sub>2</sub> lesions, with normal cord mobility, is 86% and it drops to 63% if cord mobility is impaired.

page 330

page 331

T<sub>3</sub> and T<sub>4</sub> glottic carcinomas are best treated by total laryngectomy. It is combined with neck dissection if nodes are palpable. More advanced T<sub>4</sub> lesions are treated by combined therapy, i.e. surgery with post-operative radiotherapy or only palliative treatment.

### ***Subglottic cancer***

Early lesions T<sub>1</sub> and T<sub>2</sub> are treated by radiotherapy. T<sub>3</sub> and T<sub>4</sub> lesions require total laryngectomy and post-operative radiation. Radiation portal should also include superior mediastinum.

### ***Supraglottic cancer***


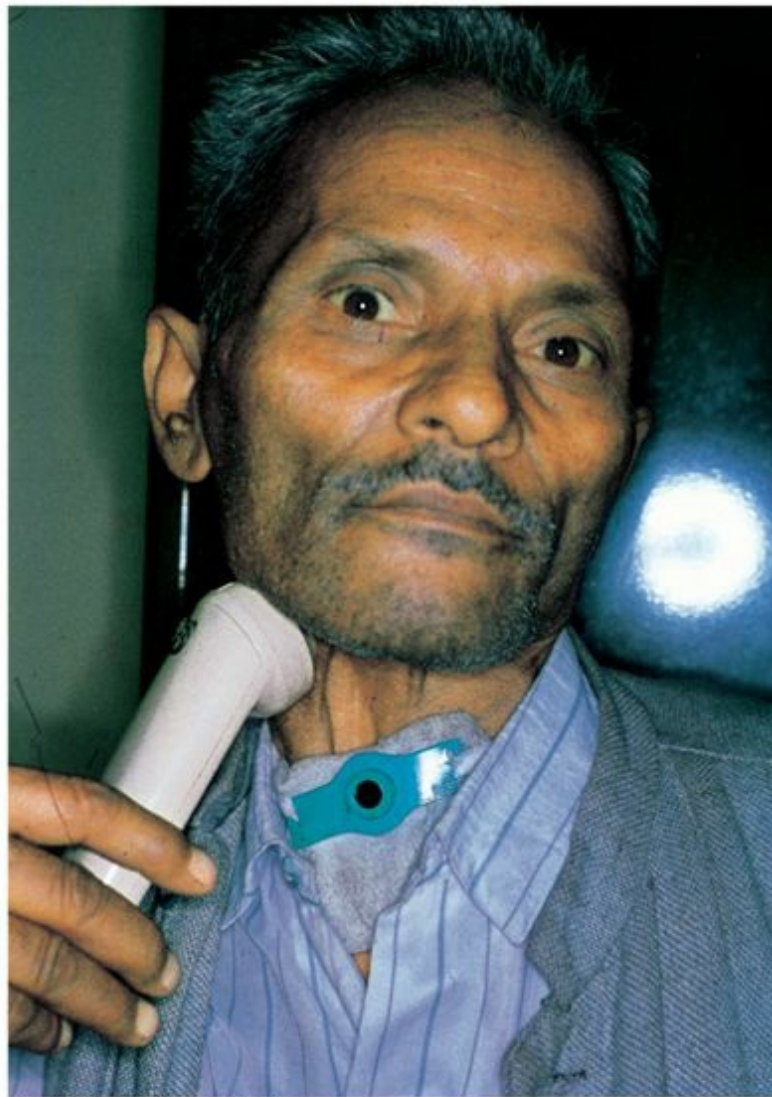
Following factors are considered in the treatment option:

- (i) Status of cervical lymph nodes
- (ii) Mobility of cord
- (iii) Age of the patient
- (iv) Status of lung functions
- (v) Cartilage invasion
- (vi) Subsite of supraglottis involved
- (vii) Status of pre-epiglottic space involvement

T<sub>1</sub> lesions respond well to radiation. They can also be excised with CO<sub>2</sub> laser.

T<sub>2</sub> lesions are treated by supraglottic laryngectomy with or without neck dissection if lung function is good. If lung function is poor, radiotherapy can be given to the primary and the nodes.

T<sub>3</sub> and T<sub>4</sub> lesions often require total laryngectomy with neck dissection and post-operative radiotherapy to neck.

**A****B**

Dhingra: Diseases of Ear Nose and Throat, 5th Edition  
Copyright © 2010 Elsevier. All rights reserved.

Figure 61.4 (A) Electrolarynx. (B) A laryngectomised patient using the electrolarynx to produce sound.

**Table 61-3. Methods of communication in laryngectomised patients**

- Written language (Pen and paper)
- Aphonic lip speech (By trapping air in buccal cavity, often combined with sign language)
- Oesophageal speech
- Electrolarynx
- Transoral pneumatic device
- Tracheo-oesophageal speech
  - Blom-Singer prosthesis
  - Panje prosthesis



# Vocal Rehabilitation After Total Laryngectomy

After laryngectomy, patient loses his speech completely. Various methods by which communication can be established are listed in Table 61.3.

## **1. Oesophageal speech**

In this, patient is taught to swallow air and hold it in the upper oesophagus and then slowly eject it from the oesophagus into the pharynx. Patient can speak 6-10 words before re-swallowing air. Voice is rough but loud and understandable.

## **2. Artificial larynx**

It is used in those who fail to learn oesophageal speech.

page 331

page 332

(a) *Electrolarynx*. It is a transistorised, battery operated portable device. Its vibrating disc is held against the soft tissues of the neck and a low pitched sound is produced in the hypopharynx which is further modulated into speech by the tongue, lips, teeth and palate (Fig. 61.4A,B).

(b) *Transoral pneumatic device*. Another type of artificial larynx is a transoral device. Here vibrations produced in a rubber diaphragm are carried by a plastic tube into the back of the oral cavity where sound is converted into speech by modulators. This is a pneumatic type of device and uses expired air from the tracheostome to vibrate the diaphragm.

## **3. Tracheo-oesophageal speech**

Here attempt is made to carry air from trachea to oesophagus or hypopharynx by the creation of skin-lined fistula or by placement of an artificial prosthesis. The vibrating column of air entering the pharynx is then modulated into speech. This technique has the disadvantage of food entering the trachea. These days prosthesis (Blom-Singer or Panje) are being used to shunt air from trachea to the oesophagus. They have inbuilt valves which work only in one direction thus preventing problems of aspiration.

## 62 Voice and Speech Disorders

### Hoarseness

Hoarseness is defined as roughness of voice resulting from variations of periodicity and/or intensity of consecutive sound waves.

For production of normal voice, vocal cords should:

- 1. Be able to approximate properly with each other.
- 2. Have a proper size and stiffness.
- 3. Have an ability to vibrate regularly in response to air column.

Any condition that interferes with the above functions causes hoarseness.

- (a) *Loss of approximation* may be seen in vocal cord paralysis or fixation or a tumour coming in between the vocal cords.
- (b) *Size of the cord* may increase in oedema of the cord or a tumour; there is a decrease in partial surgical excision or fibrosis.
- (c) *Stiffness* may decrease in paralysis, increase in spastic dysphonia or fibrosis.

Cords may not be able to vibrate properly in the presence of congestion, submucosal haemorrhages, nodule or a polyp.

### Aetiology

Hoarseness is a symptom and not a disease per se. The causes of hoarseness are summarised in Table 62.1.

### Investigations

Table 62-1. Causes of hoarseness

1. <i>Inflammations</i>	
Acute	Acute laryngitis usually following cold, influenza, exanthematous fever, laryngo-tracheo-bronchitis, diphtheria
Chronic	(i) <i>Specific</i> . Tuberculosis, syphilis, scleroma, fungal infections
	(ii) <i>Non-specific</i> . Chronic laryngitis, atrophic laryngitis
2. <i>Tumours</i>	
Benign	Papilloma (solitary and multiple), haemangioma, chondroma, fibroma, leukoplakia
Malignant	Carcinoma
Tumour-like masses	Vocal nodule, vocal polyp, angiofibroma, amyloid tumour, contact ulcer, cysts, laryngocele
3. <i>Trauma</i>	Submucosal haemorrhage, laryngeal trauma (blunt and sharp), foreign bodies, intubation
4. <i>Paralysis</i>	Paralysis of recurrent, superior laryngeal or both nerves
5. <i>Fixation of cords</i>	Arthritis or fixation of cricoarytenoid joints
6. <i>Congenital</i>	Laryngeal web, cyst, laryngocele
7. <i>Miscellaneous</i>	Dysphonia plica ventricularis, myxoedema, gout
8. <i>Functional</i>	Hysterical aphonia

page 333

page 334

- 1. History. Mode of onset and duration of illness, patient's occupation, habits and associated complaints are important and would often help to elucidate the cause. *Any hoarseness persisting for more than three weeks deserves examination of larynx. Malignancy should be excluded in patients above 40 years.*
- 2. Indirect laryngoscopy. Many of the local laryngeal causes can be diagnosed.
- 3. Examination of neck, chest, cardiovascular and neurological system would help to find cause for laryngeal paralysis.
- 4. Laboratory investigations and radiological examination should be done as per dictates of the cause suspected on clinical examination.
- 5. Direct laryngoscopy and microlaryngoscopy help in detailed examination, biopsy of the lesions and assessment of the mobility of cricoarytenoid joints.
- 6. Bronchoscopy and oesophagoscopy may be required in cases of paralytic lesions of the cord to exclude malignancy.

## Dysphonia Plica Ventricularis (Ventricular Dysphonia)

Here voice is produced by ventricular folds (false cords) which have taken over the function of true cords. Voice is rough, low-pitched and unpleasant. Ventricular voice may be secondary to impaired function of the true cord such as paralysis, fixation, surgical excision, or tumours. Ventricular bands in these situations try to compensate or assume phonatory function of true cords.

Functional type of ventricular dysphonia occurs in normal larynx. Here cause is psychogenic. In this type, voice begins normally but soon becomes rough when false cords usurp the function of true cords. Diagnosis is made on indirect laryngoscopy; the false cords are seen to approximate partially or completely and obscure the view of true cords on phonation. Ventricular dysphonia secondary to laryngeal disorders is difficult to treat but the functional type can be helped through voice therapy and psychological counselling.

## Functional Aphonia (Hysterical Aphonia)

It is a functional disorder mostly seen in emotionally labile females in the age group of 15-30. Aphonia is usually sudden and unaccompanied by other laryngeal symptoms. Patient communicates with whisper. On examination, vocal cords are seen in abducted position and fail to adduct on phonation; however adduction of vocal cords can be seen on coughing, indicating normal adductor function. Even though patient is aphonic, sound of cough is good. Treatment given is to reassure the patient of normal laryngeal function and psychotherapy.

## Puberphonia (Mutational Falsetto Voice)

Normally, childhood voice has a higher pitch. When the larynx matures at puberty, vocal cords lengthen, and the voice changes to one of lower pitch. This is a feature exclusive to males. Failure of this change leads to persistence of childhood high-pitched voice and is called puberphonia. It is seen in boys who are emotionally immature, feel insecure and show excessive fixation to their mother. Psychologically, they shun to assume male responsibilities though their physical and sexual development is normal. Treatment is training the body to produce low-pitched voice. Pressing the thyroid prominence in a backward and downward direction relaxes the overstretched cords and low tone voice can be produced (Gutzmann's pressure test). The patient pressing on his larynx learns to produce low tone voice and then trains himself to produce syllables, words and numbers. Prognosis is good.

# Phonasthenia

It is weakness of voice due to fatigue of phonatory muscles. Thyroarytenoid and interarytenoids or both may be affected. It is seen in abuse or misuse of voice or following laryngitis. Patient complains of easy-fatiguability of voice. Indirect laryngoscopy shows three characteristic findings:

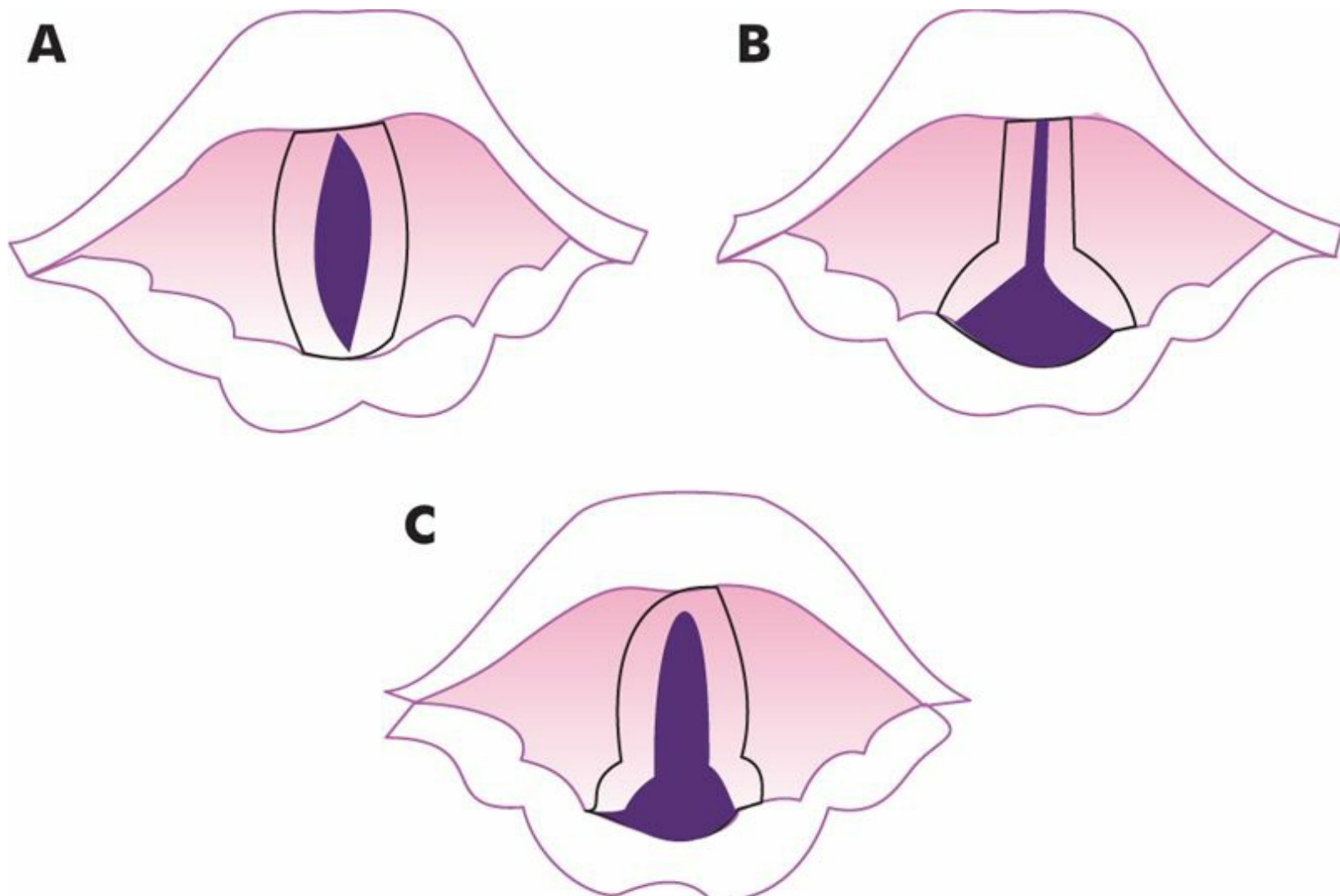
- **(i)** Elliptical space between the cords in weakness of thyroarytenoid.
- **(ii)** Triangular gap near the posterior commissure in weakness of interarytenoid.
- **(iii)** Key-hole appearance of glottis when both thyroarytenoid and interarytenoids are involved (Fig. 62.1).

Treatment is voice rest and vocal hygiene, emphasising on periods of voice rest after excessive use of voice.

## Hyponasality (Rhinolalia Clausa)

It is lack of nasal resonance for words which are resonated in the nasal cavity, e.g. m, n, ng.

It is due to blockage of the nose or nasopharynx. Important causes are listed in Table 62.2.



Dhingra: Diseases of Ear Nose and Throat, 5th Edition  
Copyright © 2010 Elsevier. All rights reserved.

Figure 62.1 Appearances of glottis in phonasthenia. (A) Weakness of thyroarytenoid, (B) Interarytenoid, (C) thyroarytenoid and interarytenoid.

Table 62-2. Causes of hyponasality and hypernasality

Hyponasality	Hypernasality
Common cold	Velopharyngeal insufficiency
Nasal allergy	Congenitally short soft palate
Nasal polypi	Submucous palate
Nasal growth	Large nasopharynx
Adenoids	Cleft of soft palate
Nasopharyngeal mass	Paralysis of soft palate
Familial speech pattern	Post-adenoidectomy
Habitual	Oronasal fistula
	Familial speech pattern
	Habitual speech pattern

## Hypernasality (Rhinolalia Aperta)

It is seen when certain words which have little nasal resonance are resonated through nose. The defect is in failure of the nasopharynx to cut off from oropharynx or abnormal communication between the oral and nasal cavities. The causes are listed in Table 62.2.



## Stuttering

It is a disorder of fluency of speech and consists of hesitation to start, repetitions, prolongations or blocks in the flow of speech. When well-established, a stutterer may develop secondary mannerisms such as facial grimacing, eye blink and abnormal head movements. Normally, most of the children have dysfluency of speech between 2-4 years. If too much attention is given or child reprimanded by parents and peers, this behaviour pattern may become fixed and child may develop into an adult stutterer. Stuttering can be prevented by proper education of the parents, not to overreact to child's dysfluency in early stages of speech development. Treatment of an established stutterer is speech therapy and psychotherapy to improve his image as a speaker and reduce his fear of dysfluency.

## 63 Tracheostomy and Other Procedures for Airway Management

### TRACHEOSTOMY

Tracheostomy is making an opening in the anterior wall of trachea and converting it into a stoma on the skin surface. Sometimes, the term *Tracheotomy* has been interchangeably used but the latter actually means opening the trachea, which is a step in the tracheostomy operation.

# Functions of Tracheostomy

- **1. Alternative pathway for breathing** This circumvents any obstruction in the upper airway from lips to the tracheostome.
- **2. Improves alveolar ventilation** In cases of respiratory insufficiency, alveolar ventilation is improved by:
  - (a) Decreasing the dead space by 30-50% (normal dead space is 150 ml).
  - (b) Reducing the resistance to airflow.
- **3. Protects the airways** By using cuffed tube, tracheobronchial tree is protected against aspiration of:
  - (a) Pharyngeal secretions, as in case of bulbar paralysis or coma.
  - (b) Blood, as in haemorrhage from pharynx, larynx or maxillofacial injuries. With tracheostomy, pharynx and larynx can also be packed to control bleeding.
- **4. Permits removal of tracheobronchial secretions** When patient is unable to cough as in coma, head injuries, respiratory paralysis; or when cough is painful, as in chest injuries or upper abdominal operations, the tracheobronchial airway can be kept clean of secretions by repeated suction through the tracheostomy, thus avoiding need for repeated bronchoscopy or intubation which is not only traumatic but requires expertise.
- **5. Intermittent positive pressure respiration (IPPR)** If IPPR is required beyond 72 hours, tracheostomy is superior to intubation.
- **6. To administer anaesthesia** In cases where endotracheal intubation is difficult or impossible as in laryngopharyngeal growths or trismus.

# Indications of Tracheostomy

There are three main indications (Table 63.1)

- **A.** Respiratory obstruction.
- **B.** Retained secretions.
- **C.** Respiratory insufficiency.

# Types of Tracheostomy

- Emergency tracheostomy
- Elective or tranquil tracheostomy
- Permanent tracheostomy
- Percutaneous dilatational tracheostomy
- Mini tracheostomy (cricothyroidotomy)

## 1. Emergency tracheostomy

It is employed when airway obstruction is complete or almost complete and there is an urgent need to establish the airway. Intubation or laryngotomy are either not possible or feasible in such cases.

## 2. Elective tracheostomy (syn. tranquil, orderly or routine tracheostomy)

This is a planned, unhurried procedure. Almost all operative surgical facilities are available, endotracheal tube can be put and local or general anaesthesia can be given. It is of two types:

- **(a) Therapeutic**, to relieve respiratory obstruction, remove tracheobronchial secretions or give assisted ventilation.
- **(b) Prophylactic**, to guard against anticipated respiratory obstruction or aspiration of blood or pharyngeal secretions such as in extensive surgery of tongue, floor of mouth, mandibular resection or laryngofissure.

page 336

page 337

Table 63-1. Indications for tracheostomy

<p><b>A. Respiratory obstruction</b></p> <ol style="list-style-type: none"><li>1. Infections<ul style="list-style-type: none"><li>◦ Acute laryngo-tracheo-bronchitis, acute epiglottitis, diphtheria</li><li>◦ Ludwig's angina, peritonsillar, retropharyngeal or parapharyngeal abscess, tongue abscess</li></ul></li><li>2. Trauma<ul style="list-style-type: none"><li>◦ External injury of larynx and trachea</li><li>◦ Trauma due to endoscopies, especially in infants and children</li><li>◦ Fractures of mandible or maxillofacial injuries</li></ul></li><li>3. Neoplasms<ul style="list-style-type: none"><li>◦ Benign and malignant neoplasms of larynx, pharynx, upper trachea, tongue and thyroid</li></ul></li><li>4. Foreign body larynx</li><li>5. Oedema larynx due to steam, irritant fumes or gases, allergy (angioneurotic or drug sensitivity), radiation</li><li>6. Bilateral abductor paralysis</li><li>7. Congenital anomalies<ul style="list-style-type: none"><li>◦ Laryngeal web, cysts, tracheo-oesophageal fistula</li><li>◦ Bilateral choanal atresia</li></ul></li></ol>
<p><b>B. Retained secretions</b></p> <ol style="list-style-type: none"><li>1. Inability to cough<ul style="list-style-type: none"><li>◦ Coma of any cause, e.g. head injuries, cerebrovascular accidents, narcotic overdose</li><li>◦ Paralysis of respiratory muscles, e.g. spinal injuries, polio, Guillain-Barre syndrome, myasthenia gravis</li><li>◦ Spasm of respiratory muscles, tetanus, eclampsia, strychnine poisoning</li></ul></li><li>2. Painful cough<ul style="list-style-type: none"><li>◦ Chest injuries, multiple rib fractures, pneumonia</li></ul></li><li>3. Aspiration of pharyngeal secretions<ul style="list-style-type: none"><li>◦ Bulbar polio, polyneuritis, bilateral laryngeal paralysis</li></ul></li></ol>
<ul style="list-style-type: none"><li>• <b>C. Respiratory insufficiency</b><ul style="list-style-type: none"><li>◦ Chronic lung conditions, viz. emphysema, chronic bronchitis, bronchiectasis, atelectasis</li><li>◦ Conditions listed in A and B</li></ul></li></ul>

Elective tracheostomy is often temporary and is closed when indication is over.

## 3. Permanent tracheostomy

This may be required for cases of bilateral abductor paralysis or laryngeal stenosis. In laryngectomy or laryngopharyngectomy, lower tracheal

stump is brought to surface and stitched to the skin.

Tracheostomy has also been divided into high, mid or low. A **high tracheostomy** is done above the level of thyroid isthmus (isthmus lies against II, III and IV tracheal rings). It violates the 1st ring of trachea. Tracheostomy at this site can cause perichondritis of the cricoid cartilage and subglottic stenosis and is always avoided. Only indication for high tracheostomy is carcinoma of larynx because in such cases, total larynx anyway would ultimately be removed and a fresh tracheostome made in a clean area lower down. A **mid tracheostomy** is the preferred one and is done through the II or III rings and would entail division of the thyroid isthmus or its retraction upwards or downwards to expose this part of trachea. A **low tracheostomy** is done below the level of isthmus. Trachea is deep at this level and close to several large vessels; also there are difficulties with tracheostomy tube which impinges on suprasternal notch.

# Technique

Whenever possible, endotracheal intubation should be done before tracheostomy. This is specially important in infants and children.

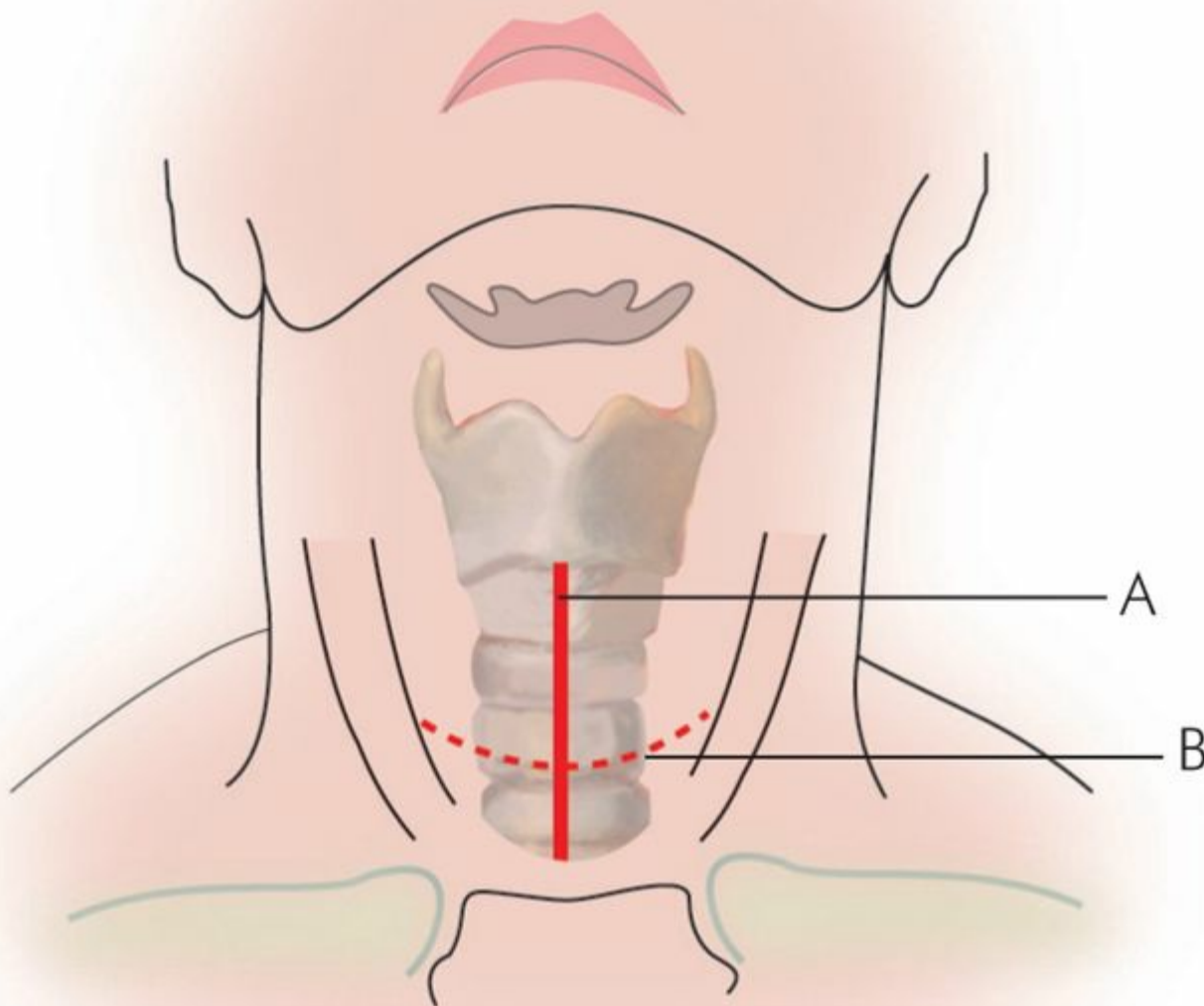
## ***Position***

Patient lies supine with a pillow under the shoulders so that neck is extended. This brings the trachea forward.

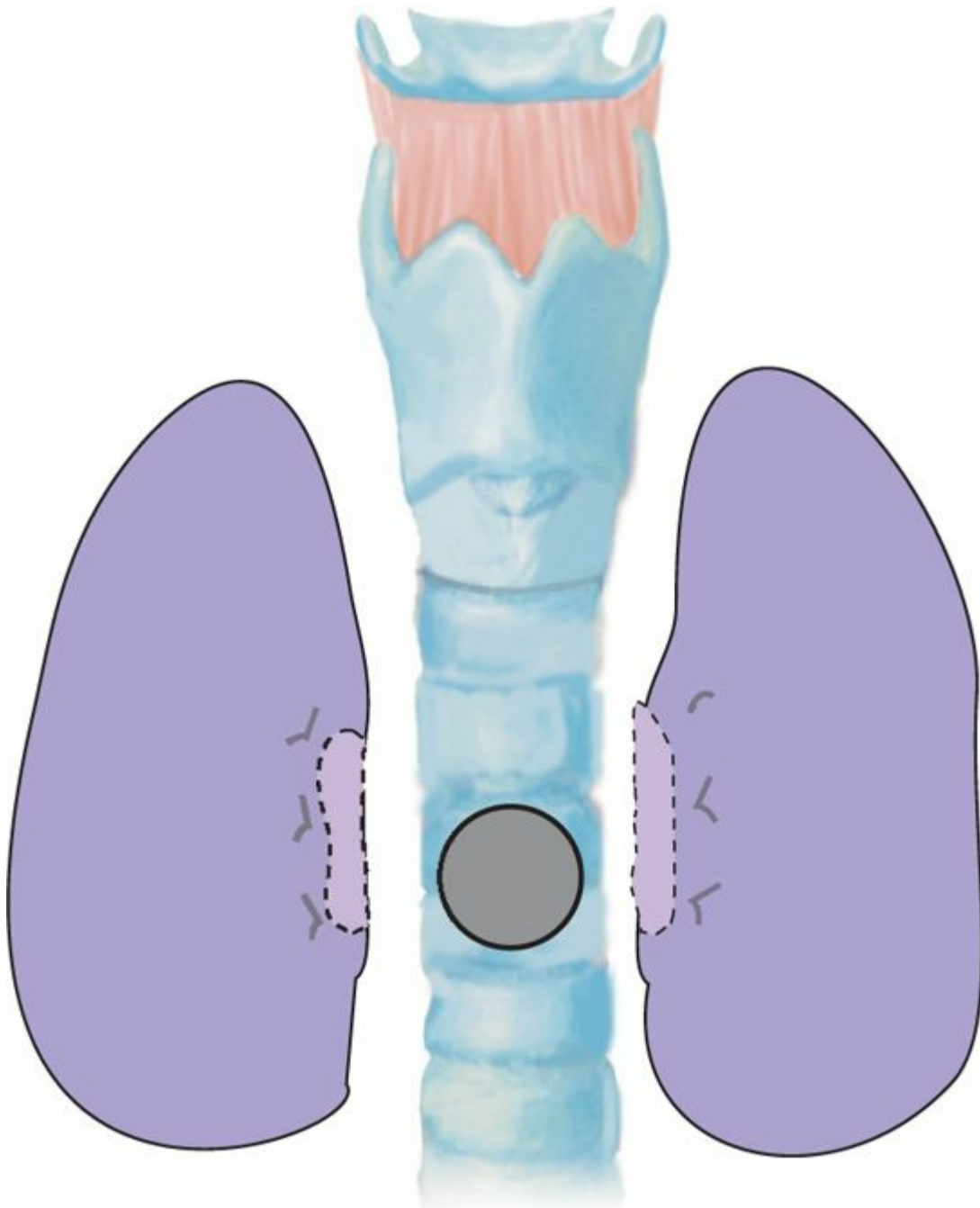
## ***Anaesthesia***

No anaesthesia is required in unconscious patients or when it is an emergency procedure. In conscious patients, 1-2% lignocaine with epinephrine is infiltrated in the line of incision and the area of dissection. Sometimes, general anaesthesia with intubation is used.

- 1. A vertical incision is made in the midline of neck, extending from cricoid cartilage to just above the sternal notch. This is the most favoured incision and can be used in emergency and elective procedures. It gives rapid access with minimum of bleeding and tissue dissection. A transverse incision, 5 cm long, made 2 fingers' breadth above the sternal notch can be used in elective procedures. It has the advantage of a cosmetically better scar (Fig. 63.1).
- 2. After incision, tissues are dissected in the midline. Dilated veins are either displaced or ligated.
- 3. Strap muscles are separated in the midline and retracted laterally.
- 4. Thyroid isthmus is displaced upwards or divided between the clamps, and suture-ligated.
- 5. A few drops of 4% lignocaine are injected into the trachea to suppress the cough when trachea is incised.
- 6. Trachea is fixed with a hook and opened with a vertical incision in the region of 3rd and 4th or 3rd and 2nd rings. This is then converted into a circular opening. The first tracheal ring is *never* divided as perichondritis of cricoid cartilage with stenosis can result (Fig. 63.2).
- 7. Tracheostomy tube of appropriate size is inserted and secured by tapes (see page 473 for different types and size of tracheostomy tubes).
- 8. Skin incision should not be sutured or packed tightly as it may lead to development of subcutaneous emphysema.
- 9. Gauze dressing is placed between the skin and flange of the tube around the stoma.







Dhingra: Diseases of Ear Nose and Throat, 5th Edition  
Copyright © 2010 Elsevier. All rights reserved.

Figure 63.2 Mid tracheostomy . Thyroid isthmus is divided and ligated.

# Tracheostomy in Infants and Children

Important conditions requiring tracheostomy in this age group are listed in Table 63.2.

**Table 63-2. Common indications of tracheostomy in infants and children**

Infants below 1 year (mostly congenital lesions)
<ul style="list-style-type: none"><li>• Subglottic haemangioma</li><li>• Subglottic stenosis</li><li>• Laryngeal cyst</li><li>• Glottic web</li><li>• Bilateral vocal cord paralysis</li></ul>
Children (mostly inflammatory or traumatic lesions)
<ul style="list-style-type: none"><li>• Acute laryngo-tracheo-bronchitis</li><li>• Epiglottitis</li><li>• Diphtheria</li><li>• Laryngeal oedema (chemical/thermal injury)</li><li>• External laryngeal trauma</li><li>• Prolonged intubation</li><li>• Juvenile laryngeal papillomatosis</li></ul>

Great care and caution is required when doing tracheostomy in infants and children lest it is attended with complications that are avoidable.

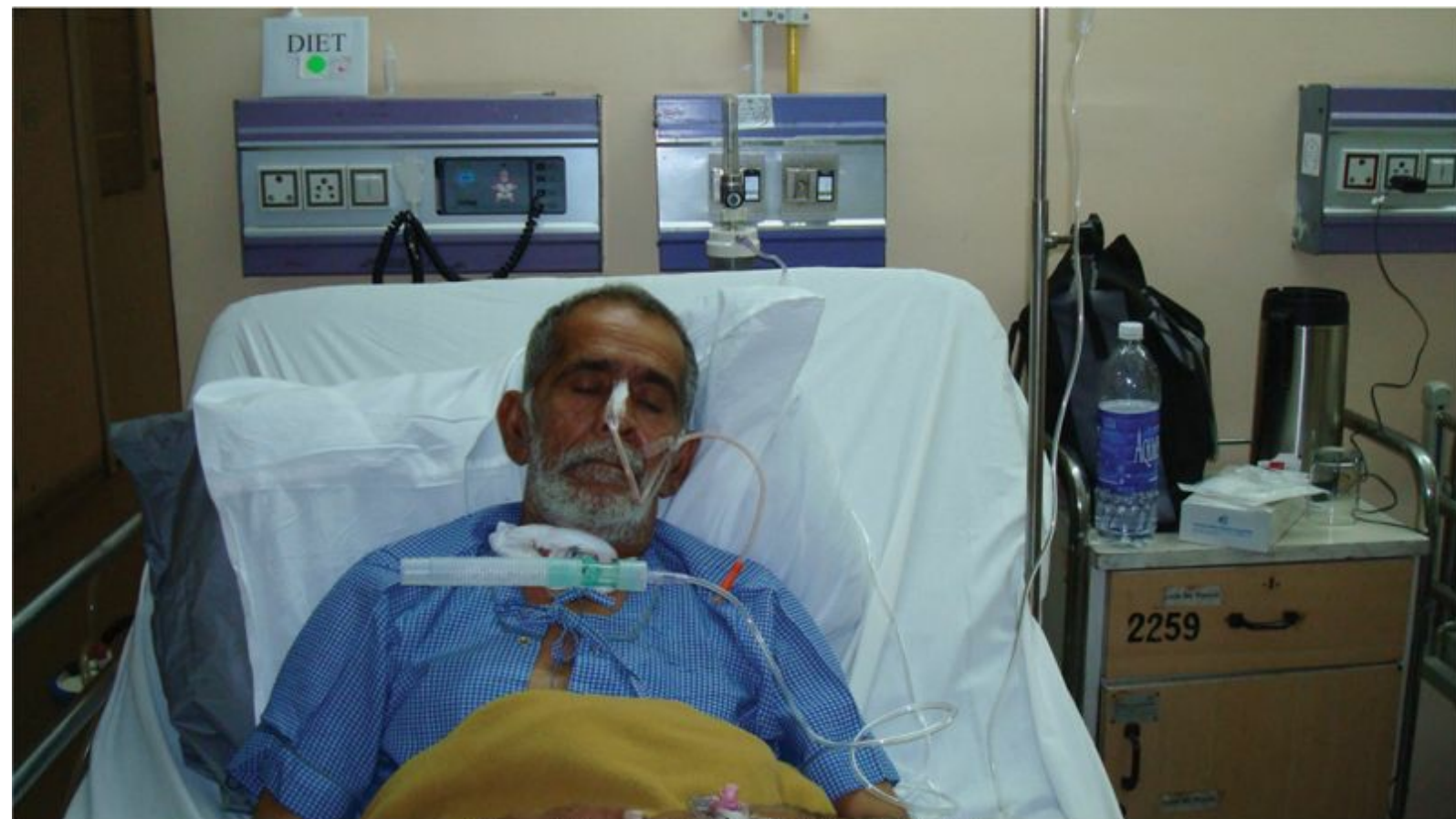- **1.** Trachea of infants and children is soft and compressible and its identification may become difficult and the surgeon may easily displace it and go deep or lateral to it injuring recurrent laryngeal nerve or even the carotid. It is always useful to have an endotracheal tube or a bronchoscope inserted into trachea before operation. Tracheostomy in infants and children is preferably done under general anaesthesia.
- **2.** During positioning, do not extend the neck too much as this pulls structures from chest into the neck and thus injury may occur to pleura, innominate vessels and thymus or the tracheostomy opening may be made too low near suprasternal notch.
- **3.** Before incising trachea, silk sutures are placed in the trachea, on either side of midline.
- **4.** Tracheal lumen is small, do not insert knife too deep; it will injure posterior tracheal wall or even oesophagus causing tracheo-oesophageal fistula.
- **5.** Trachea is simply incised, without excising a circular piece of tracheal wall.
- **6.** Avoid infolding of anterior tracheal wall when inserting the tracheostomy tube.
- **7.** Selection of tube is important. It should be of proper diameter, length and curvature. A long tube impinges on the carina or right bronchus. With high curvature, lower end of tube impinges on anterior tracheal wall while upper part compresses the tracheal rings or cricoid (see Appendix II, page 463).
- **8.** Use soft silastic or portex tube. Metallic tubes cause more trauma.
- **9.** Take a post-operative X-ray of the neck and chest to ascertain the position of the tracheostomy tube.

## Post-operative Care

- **1. Constant supervision.** After tracheostomy, constant supervision of the patient for bleeding, displacement or blocking of tube and removal of secretions is essential. A nurse or patient's relative should be in attendance. Patient is given a bell or a paper pad and a pencil to communicate.
- **2. Suction.** Depending on the amount of secretion, suction may be required every half an hour or so; use sterile catheters with a Y-connector to break suction force. Suction injuries to tracheal mucosa should be avoided. This is done by applying suction to the catheter only when withdrawing it (Fig. 63.3).
- **3. Prevention of crusting and tracheitis.** This is achieved by:
  - (a) Proper humidification, by use of humidifier, steam tent, ultrasonic nebulizer or keeping a boiling kettle in the room.
  - (b) If crusting occurs, a few drops of normal or hypotonic saline or Ringer's lactate are instilled into the trachea every 2-3 hours to loosen crusts. A mucolytic agent such as acetylcysteine solution, can be instilled to liquify tenacious secretions or to loosen the crusts.
- **4. Care of tracheostomy tube.** Inner cannula should be removed and cleaned as and when indicated for the first 3 days. Outer tube, unless blocked or displaced, should not be removed for 3-4 days to allow a track to be formed when tube placement will become easy. After 3-4 days, outer tube can be removed and cleaned every day.

If cuffed tube is used, it should be periodically deflated to prevent pressure necrosis or dilatation of trachea.

## Decannulation



Dhingra: Diseases of Ear Nose and Throat, 5th Edition  
Copyright © 2010 Elsevier. All rights reserved.

Figure 63.3 Tracheotomised patient of laryngeal cancer with suction-aid tracheostomy tube and receiving oxygen through a side port.

Tracheostomy tube should not be kept longer than necessary. Prolonged use of tube leads to tracheobronchial infections, tracheal ulceration, granulations, stenosis and unsightly scars.

To decannulate a patient, tracheostomy tube is plugged and the patient closely observed. If the patient can tolerate it for 24 hours, tube can be safely removed. In children, the above procedure is done using a smaller tube. After tube removal, wound is taped and patient again closely observed. Healing of the wound takes place within a few days or a week. Rarely a secondary closure of wound may be required.

Observe the following principles when decannulating an infant or a young child:

- **1.** Decannulate in the operation theatre where services of a trained nurse and an anaesthetist are available.
- **2.** Equipment for re-intubation should be available immediately. It consists of a good headlight, laryngoscope, proper-sized endotracheal

tubes and a tracheostomy tray.

- **3.** After decannulation, watch the child for several hours for respiratory distress, tachycardia and colour. Oxymetry is very useful to monitor oxygen saturation. It may require blood gas determinations. When attempts at decannulation are not successful, look for the cause. It may be:
  - (i) Persistence of the condition for which tracheostomy was done.
  - (ii) Obstructing granulations around the stoma or below it where tip of the tracheostomy tube had been impinging.
  - (iii) Tracheal oedema or subglottic stenosis.
  - (iv) Incurving of tracheal wall at the site of tracheostome.
  - (v) Tracheomalacia.
  - (vi) Psychological dependence on tracheostomy and inability to tolerate the resistance of the upper airways.

A case of difficult decannulation may require endoscopic examination of the larynx, trachea and bronchi preferably under magnification using telescopes or a flexible endoscope.

# Complications

## A. Immediate

page 339

page 340

(at the time of operation):

- 1. Haemorrhage.
- 2. Apnoea. This follows opening of trachea in a patient who had prolonged respiratory obstruction. This is due to sudden washing out of CO<sub>2</sub> which was acting as a respiratory stimulus. Treatment is to administer 5% CO<sub>2</sub> in oxygen or assisted ventilation.
- 3. Pneumothorax due to injury to apical pleura.
- 4. Injury to recurrent laryngeal nerves.
- 5. Aspiration of blood.
- 6. Injury to oesophagus. This can occur with tip of knife while incising the trachea and may result in tracheo-oesophageal fistula.

## B. Intermediate

(during first few hours or days):

- 1. Bleeding, reactionary or secondary.
- 2. Displacement of tube.
- 3. Blocking of tube.
- 4. Subcutaneous emphysema.
- 5. Tracheitis and tracheobronchitis with crusting in trachea.
- 6. Atelectasis and lung abscess.
- 7. Local wound infection and granulations.

## C. Late

(with prolonged use of tube for weeks and months):

- 1. Haemorrhage, due to erosion of major vessel.
- 2. Laryngeal stenosis, due to perichondritis of cricoid cartilage.
- 3. Tracheal stenosis, due to tracheal ulceration and infection.
- 4. Tracheo-oesophageal fistula, due to prolonged use of cuffed tube or erosion of trachea by the tip of tracheostomy tube.
- 5. Problems of decannulation. Seen commonly in infants and children.
- 6. Persistent tracheocutaneous fistula.
- 7. Problems of tracheostomy scar. Keloid or unsightly scar.
- 8. Corrosion of tracheostomy tube and aspiration of its fragments into the tracheobronchial tree.

# Procedures for Immediate Airway Management

When airway obstruction is so marked as to allow no time to do an orderly tracheostomy, following measures are taken:

## 1. *Jaw thrust*

Lifting the jaw forward and extending the neck improves the airway by displacing the soft tissues. Neck extension should be avoided in spinal injuries.

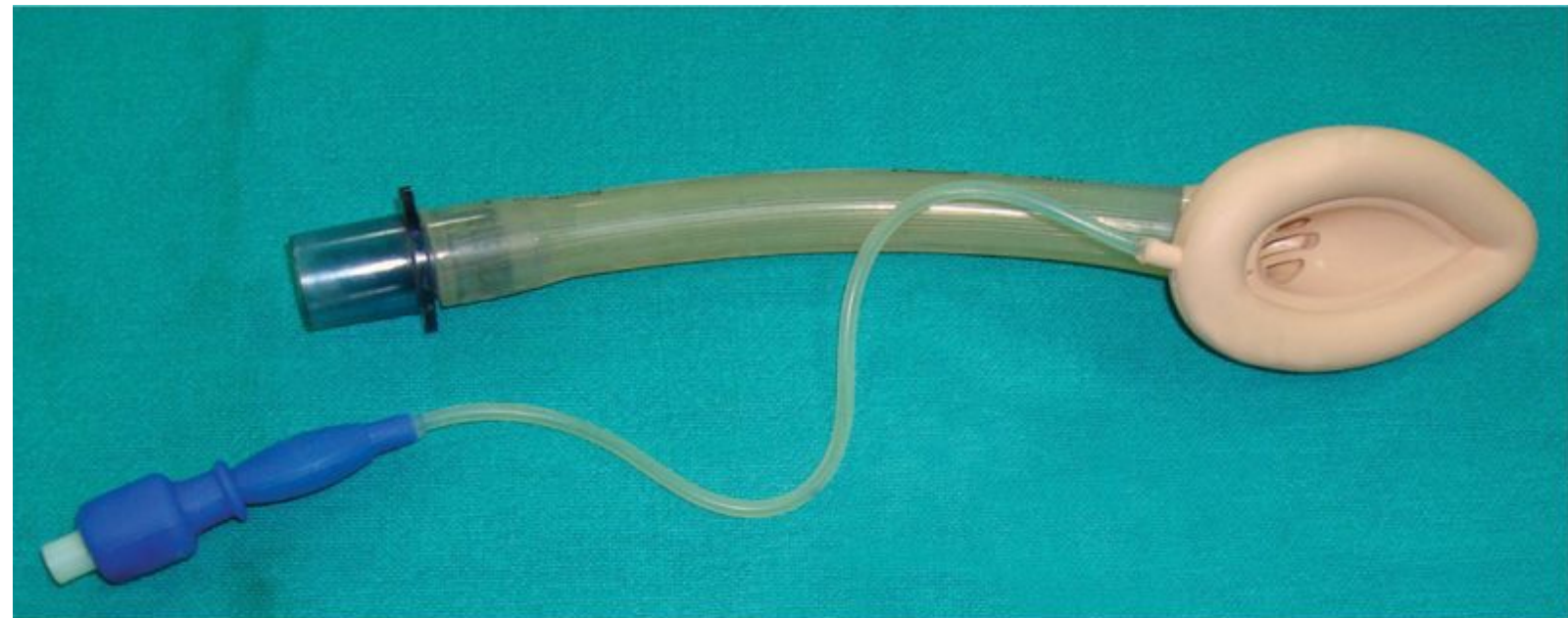## 2. *Oropharyngeal airway*

It displaces the tongue anteriorly and relieves soft tissue obstruction. Ventilation can be carried out by face mask placed snugly over the face and covering both nose and mouth. Ambu bag can be used for inflation of air or oxygen.

## 3. *Nasopharyngeal airway (trumpet)*

It is inserted *transnasally* into the posterior hypopharynx and relieves soft tissue obstruction caused by the tongue and pharynx. It is better tolerated than oropharyngeal airway in awake patients.

## 4. *Laryngeal mask airway*



Dhingra: Diseases of Ear Nose and Throat, 5th Edition  
Copyright © 2010 Elsevier. All rights reserved.

Figure 63.4 Laryngeal mask airway .

It is a device with a tube and a triangular distal end which fits over the laryngeal inlet (Fig. 63.4). Oxygen can be delivered directly into the trachea. Though most commonly used for non-emergent airway control, it can be used as an alternative if standard mask ventilation is inadequate and intubation unsuccessful (see Appendix II on Instruments).

## 5. *Transtacheal jet ventilation*

It is an invasive procedure. An intravenous catheter of 12 or 14 gauge with a syringe attached is inserted into the cricothyroid membrane and directed caudally. Once intraluminal placement is confirmed by aspiration, needle is withdrawn leaving the catheter in position and jet ventilation started. In thin individuals where trachea can be palpated, catheter can be inserted easily. Expiration of air should be insured otherwise pulmonary barotrauma with pneumothorax, pneumomediastinum and surgical emphysema can result.

## 6. *Endotracheal intubation*

This is the most rapid method. Larynx is visualised with a laryngoscope and endotracheal tube or a bronchoscope inserted. No anaesthesia is required. This helps to avoid a hurried tracheostomy in which complication rate is higher. After intubation, an orderly tracheostomy can be performed.

## 7. *Cricothyrotomy or laryngotomy or mini tracheostomy*

This is a procedure for opening the airway through the cricothyroid membrane. Patient's head and neck is extended, lower border of thyroid cartilage and cricoid ring are identified. Skin in this area is incised vertically and then cricothyroid membrane cut with a transverse incision. This space can be kept open with a small tracheostomy tube or by inserting the handle of knife and turning it at right angles if tube is not available. It is

essential to perform an orderly tracheostomy as soon as possible because perichondritis, subglottic oedema and laryngeal stenosis can follow prolonged laryngotomy.

"Mini tracheostomy is an emergency procedure to buy time to allow patient to be carried to operation theatre. Commercial emergency kits are also available for this. As an elective procedure it has been done to clear the bronchial secretions following thoracic surgery."

### **8. Emergency tracheostomy**

page 340

page 341

Technique of emergency tracheostomy is as follows: Patient's neck is extended, trachea identified and fixed between surgeon's left thumb and index finger. A vertical incision is made from lower border of thyroid to suprasternal notch cutting through skin and subcutaneous tissues. Lower border of cricoid cartilage is identified and a transverse incision made in pretracheal fascia. The thyroid isthmus dissected down to expose upper three tracheal rings. Vertical tracheal incision is made in 2nd and 3rd rings, opened with a haemostat and the tube inserted. Bleeding can be controlled by packing with gauze.

Emergency tracheostomy on a struggling patient with inadequate lighting, suction and instruments is fraught with many complications. If possible, an endotracheal tube should be put for a more orderly procedure to be carried out.

## **PERCUTANEOUS DILATATIONAL TRACHEOSTOMY**

This type of tracheostomy is done in ICU where patient is already intubated and being monitored. It is done under sedation. Neck is extended with a pad under the shoulders. Neck is prepared and draped and 1.5-2 cm incision is made 2 cm below the lower border of cricoid. Trachea is exposed by dissection and palpation. Thyroid isthmus is pushed down. Now a small caliber flexible bronchoscope, to which a camera has been attached, is passed through the endotracheal tube to monitor the passage of the needle, guide wire and dilator/s. It is important to enter the trachea in the midline and avoid any lateral entry. Entry into the trachea is made between second and third rings. After dilatation tracheostomy tube is inserted.

Advantages of the procedure include: (i) No need to transport the patient to operation theatre, (ii) avoiding OT expenses, (iii) avoiding ICU nosocomial infections to be carried to OT and earlier discharge of patient.

The procedure is avoided in patients who are obese, have a neck mass, difficult to intubate, difficult to extend the neck, larynx and trachea are not easily palpable or have uncorrectable coagulopathies.

Complication of the procedure include paratracheal entry of dilator or tracheostomy tube into the lumen, haemorrhage, damage to posterior tracheal wall and surgical emphysema.



## 64 Foreign Bodies of Air Passages

A foreign body aspirated into air passage can lodge in the *larynx*, *trachea*, or *bronchi*. Site of lodgement would depend on the size and nature of the foreign body.

A large foreign body, unable to pass through the glottis, will lodge in the supraglottic area while the smaller one will pass down through the larynx into the trachea or bronchi. Foreign bodies with sharp points, e.g. pins, needles, fish bones, etc. can stick anywhere in the larynx, or tracheobronchial tree.

## Aetiology

Children are more often affected; more than half of them are below 4 years. Accidents occur when they suddenly inspire during play or fight while having something in the mouth. In children, peanut is the most common vegetable foreign body; others include almond seed, peas, beans, gram or wheat seed, water melon seed, pieces of carrot or apple. Nonvegetable matters include plastic whistle, plastic toys, safety pins, nails, all-pin, twisted wires or ball bearings.

In adults, foreign bodies are aspirated during coma, deep sleep or alcoholic intoxication. Loose teeth or denture may be aspirated during anaesthesia.

## Nature of Foreign Bodies

- **(a) *Non-irritating type.*** Plastic, glass or metallic foreign bodies are relatively non-irritating and may remain symptomless for a long time.
- **(b) *Irritating type.*** Vegetable or foreign bodies like peanuts, beans, seeds, etc. set up a diffuse violent reaction leading to congestion and oedema of the tracheobronchial mucosa-a condition called "vegetal bronchitis". They also swell up with time causing airway obstruction and later suppuration in the lung.

# Clinical Features

Symptomatology of foreign body is divided into 3 stages:

## **1. Initial period of choking, gagging and wheezing**

This lasts for a short time. Foreign body may be coughed out or it may lodge in the larynx or further down in the tracheobronchial tree.

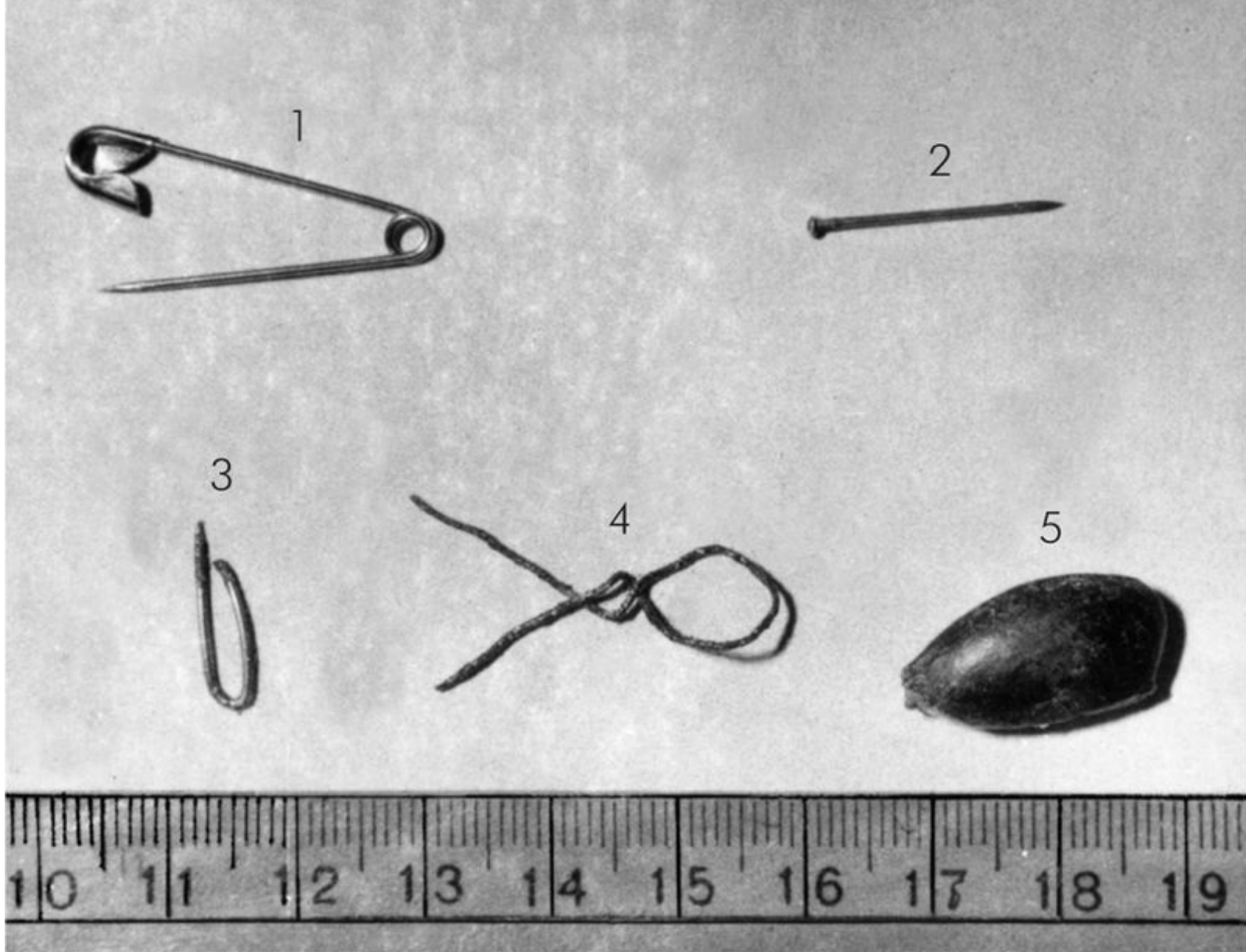
## **2. Symptomless interval**

The respiratory mucosa adapts to the presence of foreign body and initial symptoms disappear. Symptomless interval will vary with the size and nature of the foreign body.

## **3. Later symptoms**

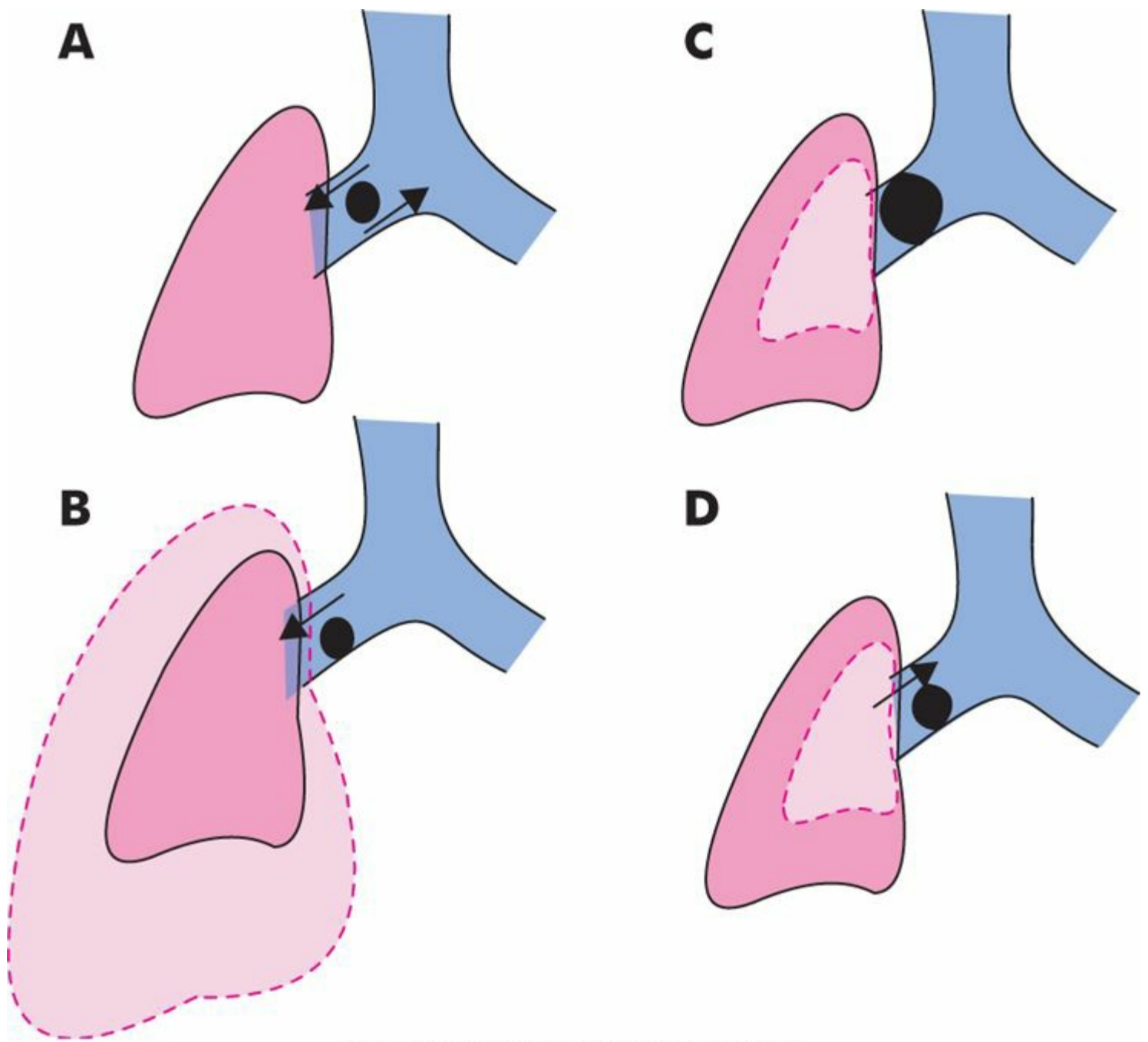
They are caused by obstruction to the airway, inflammation or trauma induced by the foreign body and would depend on the site of its lodgement.

- **(a) Laryngeal foreign body.** A large foreign body may totally obstruct the airway leading to sudden death unless resuscitative measures are taken urgently. A partially obstructive foreign body will cause discomfort or pain in the throat, hoarseness of voice, croupy cough, aphonia, dyspnoea, wheezing and haemoptysis. (Fig. 64.1).
- **(b) Tracheal foreign body.** A sharp foreign body will only produce cough and haemoptysis. A loose foreign body like seed may move up and down the trachea between the carina and the undersurface of vocal cords causing "audible slap" and "palpatory thud". Asthmatoïd wheeze may also be present. It is best heard at patient's open mouth.
- **(c) Bronchial foreign body.** Most foreign bodies enter the right bronchus because it is wider and more in line with the tracheal lumen. A foreign body may totally obstruct a lobar or segmental bronchus causing atelectasis or it may produce a check valve obstruction-allowing only ingress of air but, not egress, leading to obstructive emphysema. For pathogenesis and clinical picture of bronchial foreign body see Fig. 64.2.



Dhingra: Diseases of Ear Nose and Throat, 5th Edition  
Copyright © 2010 Elsevier. All rights reserved.

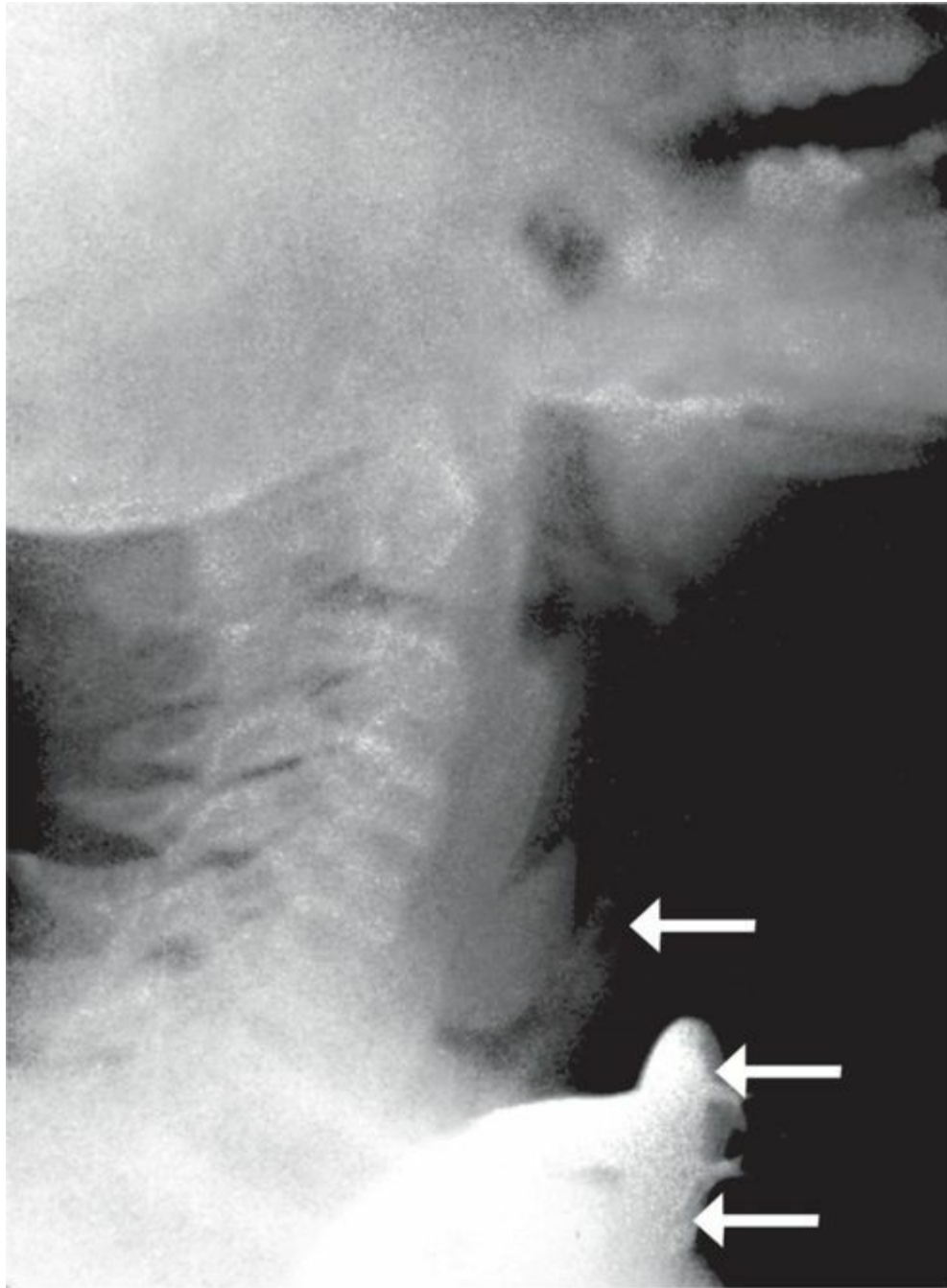
Figure 64.1 Laryngeal foreign bodies. (1) Safety pin, (2) An all pin, (3, 4) A twisted wire, (5) A fruit seed.



Dhingra: Diseases of Ear Nose and Throat, 5th Edition  
 Copyright © 2010 Elsevier. All rights reserved.

Figure 64.2 Types of bronchial obstruction by a foreign body. (A) Partial obstruction. Air can pass in and out, causing only wheeze. (B) One way obstruction. Air can go in (during inspiration) but not out, causing emphysema of lungs. (C) Total obstruction. Air can neither go in nor out, causing obstructive atelectasis. (D) One way obstruction (reverse of B). Air can only go out, causing atelectasis. Dark pink shows normal size of lung while lighter pink indicates effect of obstruction.

Emphysematous bulla may rupture causing spontaneous pneumothorax. A foreign body may also shift from one side to the other causing change in the physical signs. A retained foreign body in the lung may later give rise to pneumonitis, bronchiectasis or lung abscess.



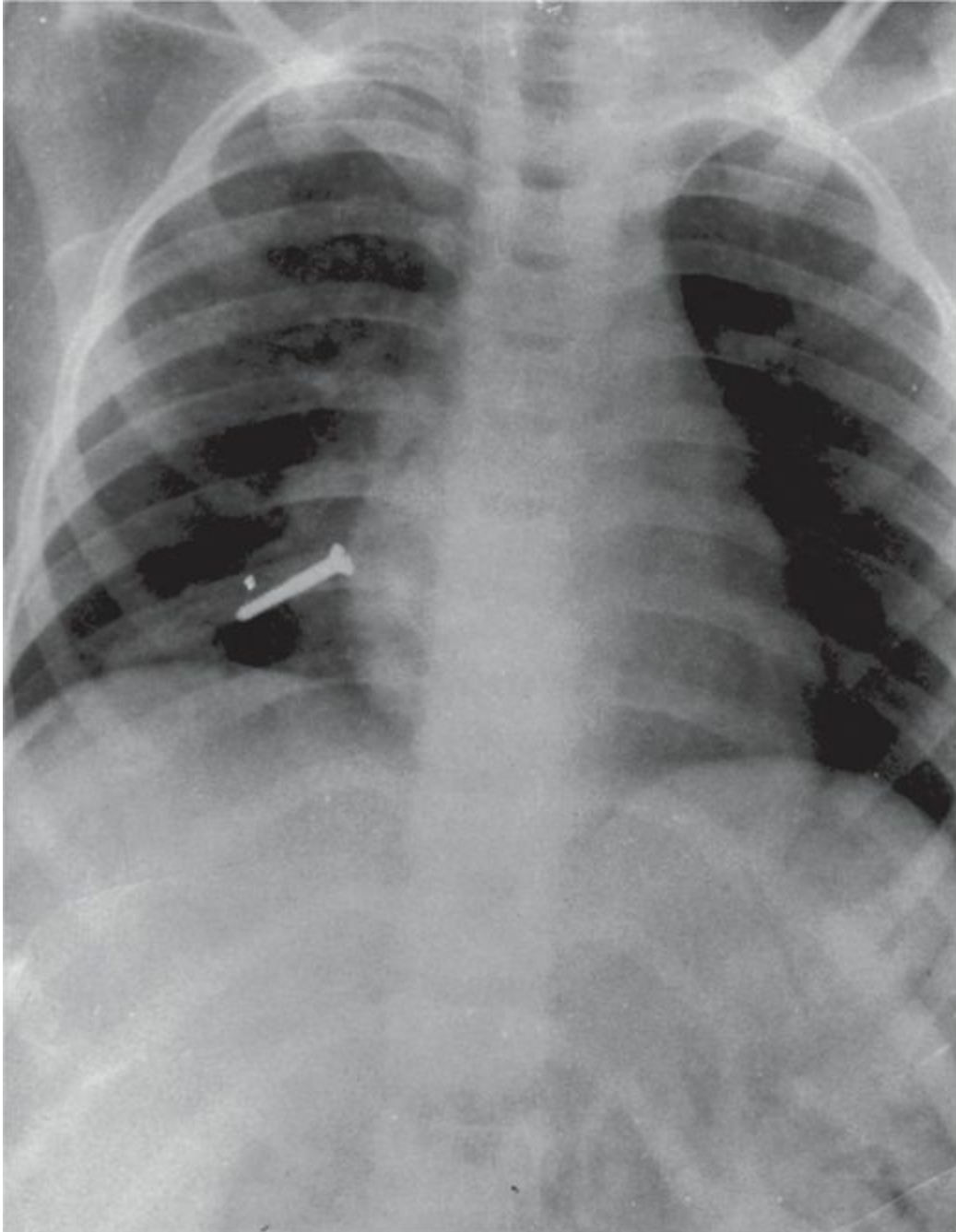
Dhingra: Diseases of Ear Nose and Throat, 5th Edition  
Copyright © 2010 Elsevier. All rights reserved.

Figure 64.3 A radiolucent fruit seed (Chiku) seen in subglottic region of larynx (arrow). Patient has a tracheostomy (double arrows).

It can be made by detailed history of the foreign body "ingestion", physical examination of the neck and chest. A history of sudden onset of coughing, wheezing and diminished entry of air into the lungs on auscultations forms a classical triad. Radiology is very helpful.

- **1.** Soft tissue posteroanterior and lateral view of the neck in its extended position. This can show radio-opaque and sometimes even the radiolucent foreign bodies in the larynx and trachea (Figs 64.3 to 64.5).
- **2.** Plain X-ray chest in posteroanterior and lateral views.
  - (a) It may show the radio-opaque foreign body-its size, shape and location.
  - (b) Lobar or segmental atelectasis (complete obstruction by foreign body).
  - (c) Unilateral hyperinflation of lobe or segment or entire lung (if ball valve obstruction). Mediastinal shift to opposite side is seen in hyperinflation. Fluoroscopy or X-rays taken during inspiration and expiration are helpful.
  - (d) Penumomediastinum or pneumothorax.
  - (e) A *normal X-ray chest*. In early cases within 24 hours or foreign body causing partial obstruction with full ingress and egress of air does not produce any sign.
  - (f) *Pneumonitis/bronchiectasis*. Prolonged stay of foreign body may cause atelectasis, pneumonitis or bronchiectasis.

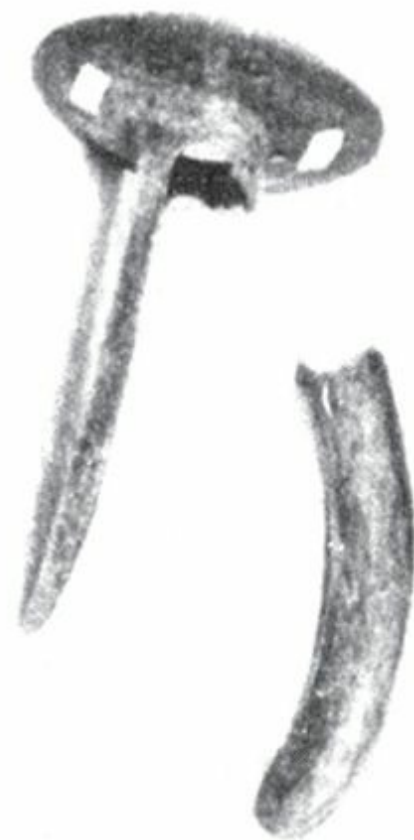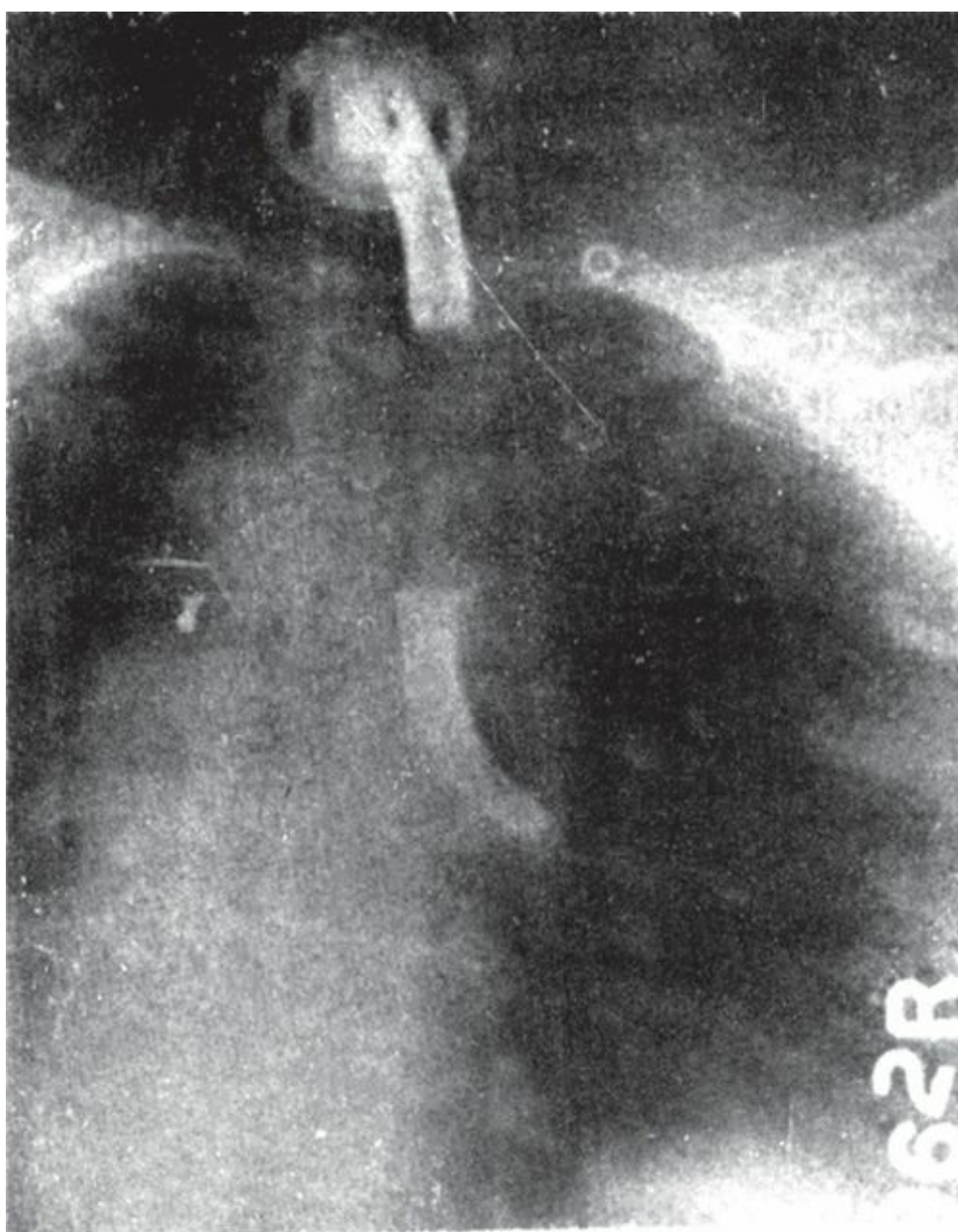
- 3. X-ray chest at the end of inspiration and expiration. Atelectasis and obstructive emphysema can be seen. They also give indirect evidence of radiolucent foreign bodies.
- 4. Fluoroscopy/videofluoroscopy. Evaluation during inspiration and expiration can be made.
- 5. CT chest.



Dhingra: Diseases of Ear Nose and Throat, 5th Edition  
Copyright © 2010 Elsevier. All rights reserved.

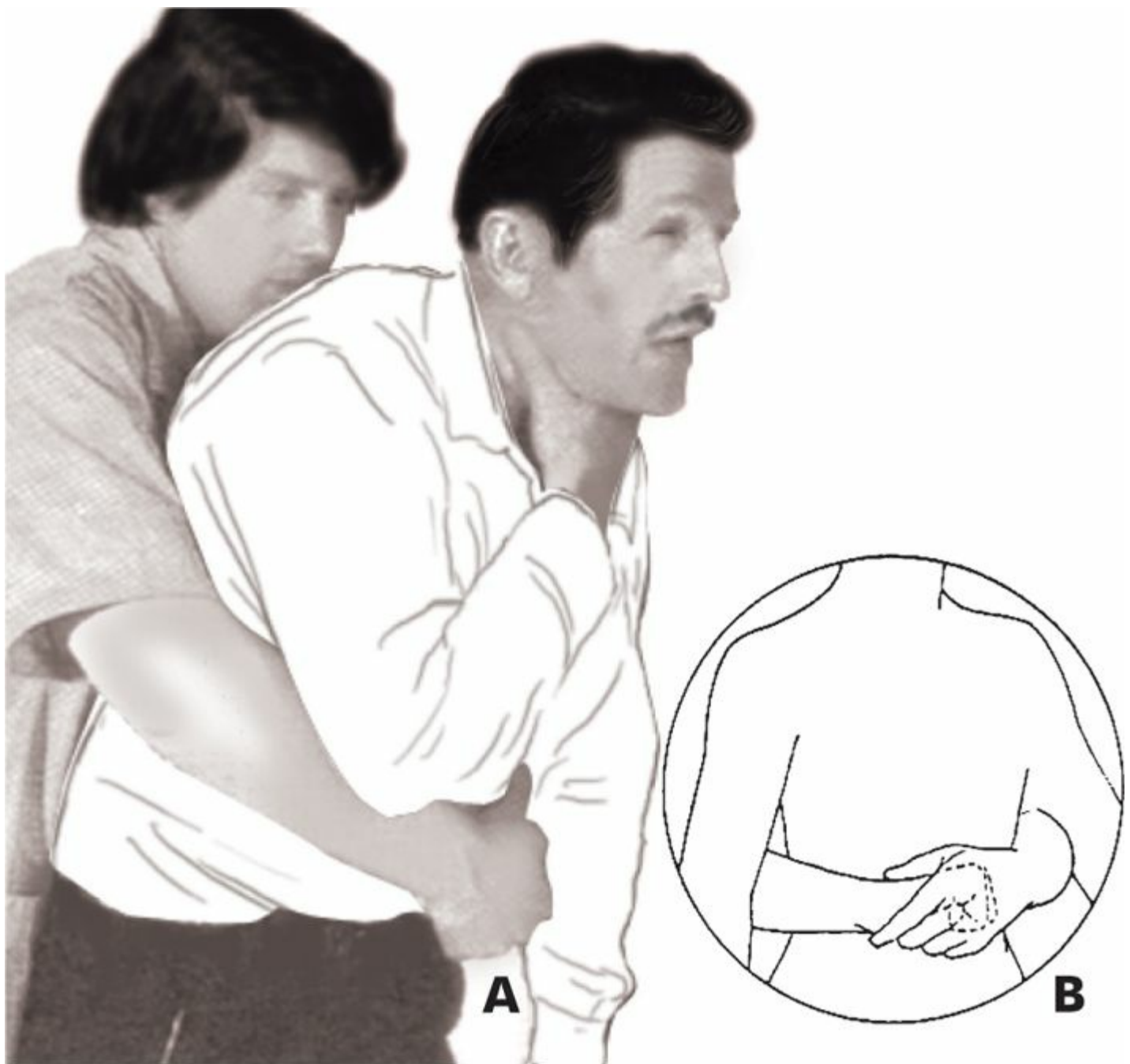Figure 64.4 P.A. view chest showing a nail in the right bronchus.





Dhingra: Diseases of Ear Nose and Throat, 5th Edition  
Copyright © 2010 Elsevier. All rights reserved.

Figure 64.5 P.A. view chest showing a broken piece of Fuller's tracheostomy tube in the left bronchus.



Dhingra: Diseases of Ear Nose and Throat, 5th Edition  
Copyright © 2010 Elsevier. All rights reserved.

Figure 64.6 Heimlich's manoeuvre. Sudden thrust directed upwards and backwards, below the epigastrium, squeezes the air from the lungs, sufficient to dislodge a foreign body.

A large bolus of food obstructed above the cords may make the patient totally aphonic, unable to cry for help. He may die of asphyxia unless immediate first aid measures are taken. The measures consist of pounding on the back, turning the patient upside down and following Heimlich manoeuvre. These measures should not be done if patient is only partially obstructed, for fear of causing total obstruction.

*Heimlich's manoeuvre.* Stand behind the person, and place your arms around his lower chest and give four abdominal thrusts. The residual air in the lungs may dislodge the foreign body providing some airway (Fig. 64.6).

Cricothyrotomy or emergency tracheostomy should be done if Heimlich's manoeuvre fails. Once acute respiratory emergency is over, foreign body can be removed by direct laryngoscopy or by laryngofissure, if found impacted.

### **Tracheal and bronchial foreign bodies**

can be removed by bronchoscopy with full preparation and under general anaesthesia. Emergency removal of these foreign bodies is not indicated unless there is airway obstruction or they are of the vegetable nature (e.g. seeds) and likely to swell up.

Methods to remove tracheobronchial foreign body:

- 1. Conventional rigid bronchoscopy.
- 2. Rigid bronchoscopy with telescopic aid.
- 3. Bronchoscopy with C-arm fluoroscopy.
- 4. Use of Dormia basket or Fogarty's balloon for rounded objects.
- 5. Tracheostomy first and then bronchoscopy through the tracheostome.
- 6. Thoracotomy and bronchotomy for peripheral foreign bodies.
- 7. Flexible fibre optic bronchoscopy in selected adult patients.

---

page 344

page 345

## **SECTION VI Diseases of Oesophagus**

---

page 345

page 346

# 65 Anatomy and Physiology of Oesophagus

## Applied Anatomy

It is a fibromuscular tube, about 25 cm long in an adult. It extends from the lower end of pharynx (C<sub>6</sub>) to the cardiac end of stomach (T<sub>11</sub>) (Fig. 65.1). It runs vertically but inclines to the left from its origin to thoracic inlet and again from T<sub>7</sub> to oesophageal opening in the diaphragm. It shows three normal constrictions and it is important to know their location at oesophagoscopy. They are:

- 1. At pharyngo-oesophageal junction (C<sub>6</sub>)-15 cm from the upper incisors.
- 2. At crossing of arch of aorta and left main bronchus (T<sub>4</sub>)-25 cm from upper incisors.
- 3. Where it pierces the diaphragm (T<sub>10</sub>)-40 cm from upper incisors.

Foreign bodies in the oesophagus can be held up at these constrictions.

The *wall* of oesophagus consists of four layers. From within outwards, they are:

- (a) *Mucosa*, which is lined by stratified squamous epithelium.
- (b) *Submucosa*, which connects mucosa to muscular layer.
- (c) *Muscular layer*, which has inner circular and outer longitudinal fibres. Circular fibres at the lower end are thickened to form a cardiac sphincter. The upper third of oesophagus has striated, the lower third smooth, and the middle third both striated and smooth muscle fibres (Fig. 65.2).
- (d) *Fibrous layer*, which forms loose covering of oesophagus.

## Nerve Supply

Parasympathetic fibres come from vagus nerves (X) and sympathetic fibres from the sympathetic trunk.

## Lymphatic Drainage

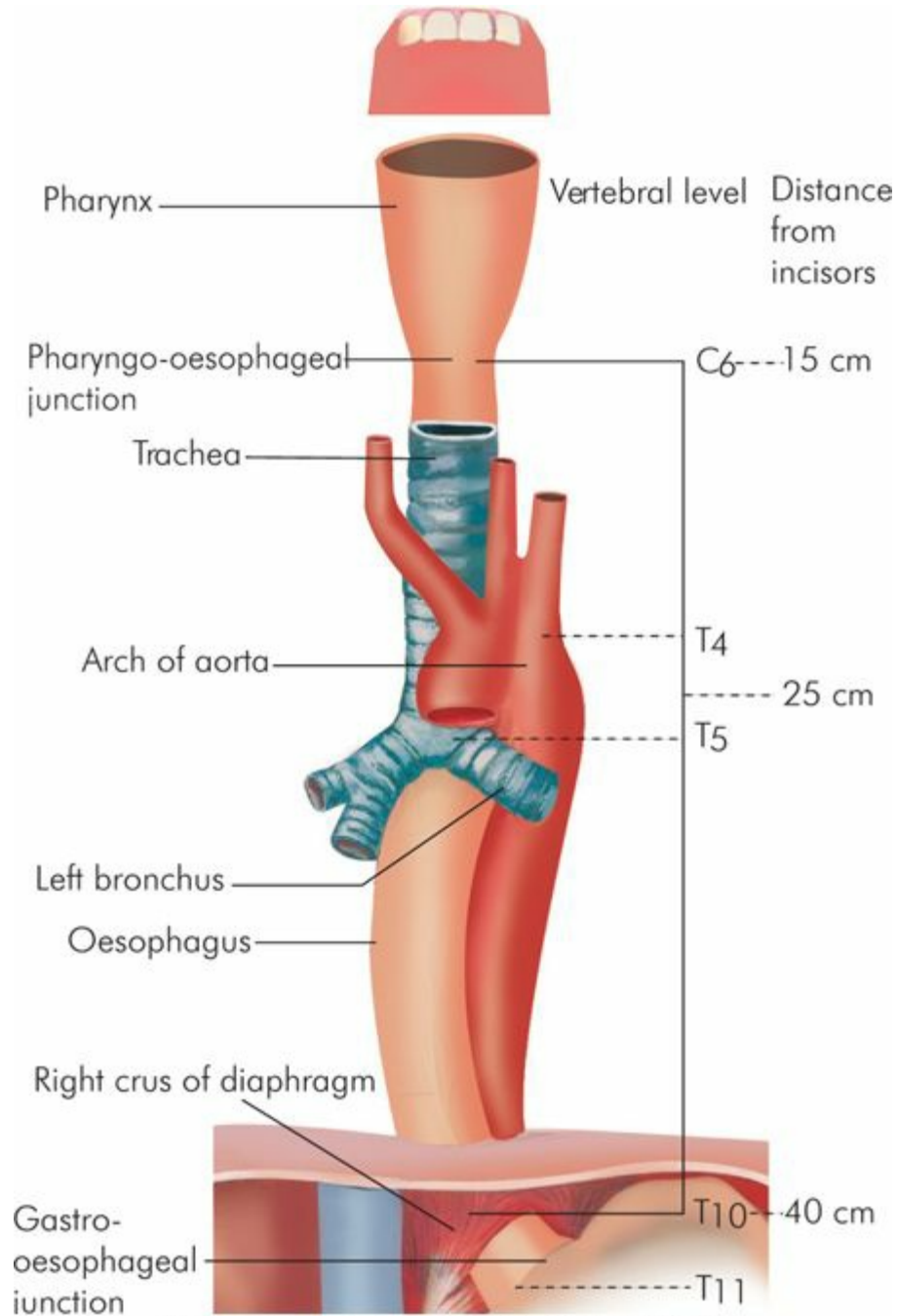
The cervical, thoracic and abdominal parts drain respectively into deep cervical, posterior mediastinal and gastric nodes.

# Applied Physiology

Manometric studies have shown two high pressure zones in oesophagus and they form the physiological sphincters.

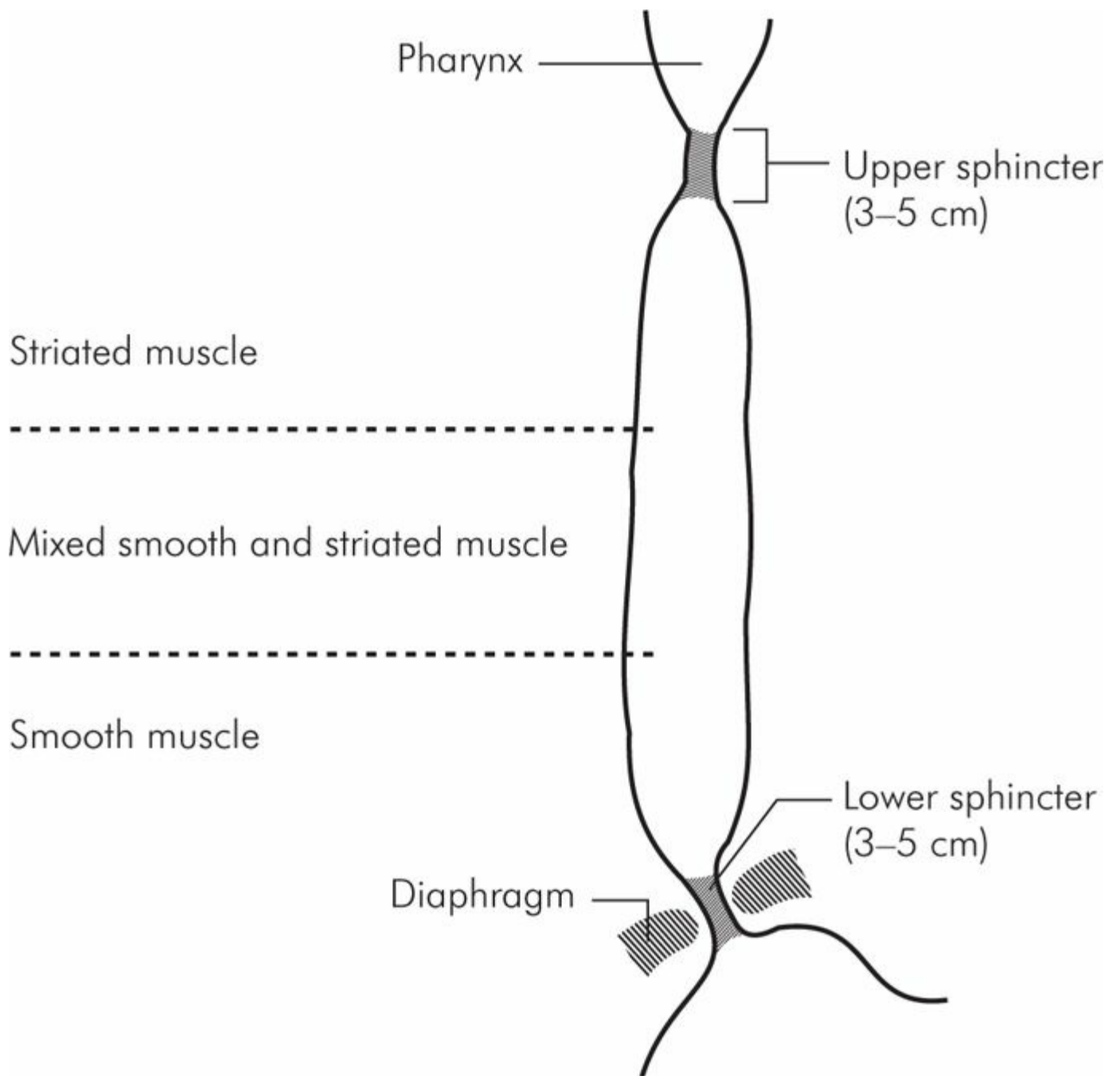
The *upper oesophageal sphincter* starts at the upper border of oesophagus and is about 3-5 cm in length and functions during the act of swallowing.

The *lower oesophageal sphincter* is situated at lower portion of oesophagus. It is also 3-5 cm in length and functions to prevent oesophageal reflux.



Dhingra: Diseases of Ear Nose and Throat, 5th Edition  
Copyright © 2010 Elsevier. All rights reserved.

Figure 65.1 Anatomy of oesophagus and levels of normal constrictions from the upper incisors.



Dhingra: Diseases of Ear Nose and Throat, 5th Edition  
 Copyright © 2010 Elsevier. All rights reserved.

Figure 65.2 Oesophagus and its sphincters.

Middle portion of oesophagus shows active peristalsis. The waves are weaker in the upper part, becoming gradually stronger towards the lower portion.

# Physiology of Swallowing

The act of swallowing is divided into three phases:

- **(a)** Oral or buccal
- **(b)** Pharyngeal
- **(c)** Oesophageal

## **(a) Oral or buccal phase**

The food which is placed in the mouth is chewed, lubricated with saliva, converted into a bolus and then propelled into the pharynx by elevation of the tongue against the palate.

## **(b) Pharyngeal phase**

It is initiated when the bolus of food comes into contact with pharyngeal mucosa. A series of reflex actions take place carrying the food past oro- and laryngopharynx into the oesophagus. The communications into nasopharynx, oral cavity and larynx are cut off.

- **(i)** Closure of nasopharynx: Soft palate contracts against the Passavant's ridge on the posterior pharyngeal wall and completely cuts off the nasopharynx from the oropharynx.
- **(ii)** Closure of oropharyngeal isthmus: The entry of food back into oral cavity is prevented by contraction of tongue against the palate and sphincteric action of palatoglossal muscles.
- **(iii)** Closure of larynx: Aspiration into the larynx is prevented by temporary cessation of respiration, closure of laryngeal inlet by contraction of aryepiglottic folds, closure of false and true cords, and rising of larynx under the base of tongue. The role of epiglottis in providing protection to larynx is not clear but it is seen to deflect backwards when food passes into the pyriform fossae.
- **(iv)** Contraction of pharyngeal muscles and relaxation of cricopharyngeus: Relaxation of cricopharyngeus muscles is so timed and synchronous that food passes from pharynx into the oesophagus during contraction of pharyngeal muscles.

## **(c) Oesophageal phase**

After food enters the oesophagus, the cricopharyngeal sphincter closes and the peristaltic movements of oesophagus take the bolus down the stomach. Gastro-oesophageal sphincter at the lower end of oesophagus relaxes well before peristaltic wave reaches and permits fluids to pass. Bolus of food is passed by contraction of peristaltic waves and then the sphincter closes.

Regurgitation of food back from stomach into oesophagus is prevented by (i) tone of gastro-oesophageal sphincter, (ii) negative intrathoracic pressure, (iii) pinch-cock effect of diaphragm, (iv) mucosal folds, (v) oesophagogastric angle, and (vi) slight positive intra-abdominal pressure.

## **66 Disorders of Oesophagus**

### **ACUTE OESOPHAGITIS**

It is acute inflammation of the oesophagus and can be due to (a) ingestion of hot liquids; (b) ingestion of caustic or corrosive agents; (c) laceration due to swallowed foreign body, or trauma of oesophagoscopy; (d) monilial infection of oesophagus from thrush in the oral cavity and (e) systemic disorder, like pemphigus.

Patient complains of dysphagia, retrosternal burning or haematemesis. Diagnosis can be made from history, X-ray studies and oesophagoscopy.



# PERFORATION OF OESOPHAGUS

## Aetiology

Perforation or the rupture of oesophagus results from:

- **(a) Instrumental trauma**, i.e. oesophagoscopy or dilatation of strictures with bougies. The common site of rupture in these cases is just above the upper sphincter; sometimes it is the lower oesophagus near the hiatus.
- **(b) Spontaneous rupture**. This usually follows vomiting and involves mostly the lower third oesophagus. Post-emetic rupture of all the layers of oesophagus is called Boerhaave's syndrome.

## Diagnosis

Early diagnosis is imperative, as mediastinitis, resulting from rupture, can rapidly prove fatal. All patients complaining of pain in the neck or interscapular region, following an oesophagoscopy, should be suspected of a perforation.

The *features of cervical oesophageal rupture* are pain, fever, difficulty to swallow and local tenderness, along with signs of surgical emphysema in the neck.

The *features of thoracic oesophageal rupture* are pain, referred to the interscapular region, fever 102-104°F (39-40°C), signs of shock, surgical emphysema in the neck, crunching sound over the heart (Hamman's sign, because of air in the mediastinum) and pneumothorax.

X-rays of the chest and neck are essential. They may reveal widening of the mediastinum and retrovisceral space, surgical emphysema, pneumothorax, pleural effusion or gas under the diaphragm.

## Treatment

All oral feeds are stopped immediately. Nutrition is maintained through i.v. route. Massive doses of antibiotics are given i.v. to combat infection.

Early perforations of cervical oesophagus can be managed by conservative measures; drainage is required only if suppuration develops. Retrovisceral space and/or upper mediastinum can be drained through the neck.

Rupture of thoracic oesophagus is more serious and conservative treatment rarely succeeds. If diagnosis is made early (within 6 hours), perforation is surgically repaired and pleural cavity drained. If diagnosis is delayed, repair is not possible; surgery is then restricted to drainage of the infected area.

# **CORROSIVE BURNS OF OESOPHAGUS**

## **Aetiology**

Acids, alkalies or other chemicals may be swallowed accidentally in children or taken with the purpose of suicide in adults.

Severity of oesophageal burns depends on the *nature of corrosive substance, its quantity and concentration* and the *duration of its contact* with the oesophageal wall. Alkalies are more destructive and penetrate deep into the layers of the oesophagus. With lye burns, entire oesophagus and stomach may slough off causing fatal mediastinitis and peritonitis.

Oesophageal burns run through three stages:

- **(i)** Stages of acute necrosis.
- **(ii)** Stage of granulations: Slough separates leaving granulating ulcer.
- **(iii)** Stage of stricture: Stricture formation begins at 2 weeks and continues for 2 months or longer.

## Evaluation of Patients

Evaluate the patient and determine the type of caustic ingested, signs and symptoms of shock, upper airway obstruction, mediastinitis, peritonitis, acid-base imbalance, and associated burns of face, lips and oral cavity. Take X-ray of the chest and soft tissue lateral view of neck.

# Management

- **(a)** Hospitalise the patient.
- **(b)** Treat shock and acid-base imbalance by i.v. fluids and electrolytes. Monitor urine output for renal failure.
- **(c)** Relieve pain.
- **(d)** Relieve airway obstruction. Tracheostomy may be required.
- **(e)** Neutralisation of the corrosive by appropriate weak acid or alkali, given by mouth, can be done but is effective only if done within first 6 hours.
- **(f)** Parenteral antibiotics should be started immediately and continued for 3-6 weeks depending on the degree of burns.
- **(g)** Pass a nasogastric tube. It is useful to feed the patient and to maintain oesophageal lumen.
- **(h)** Oesophagoscopy. Some advocate an early oesophagoscopy within 2 days to know if burns in the oesophagus have occurred and if so, their degree and extent so as to plan further treatment. Oesophagoscope is not passed beyond the first severe circumferential burn.
- **(i)** Steroids should be started within 48-96 hours and continued for 4-6 weeks to prevent stricture.
- **(j)** Follow the patient with oesophagogram and oesophagoscopy every two weeks, till healing is complete, for the development of any stricture.
- **(k)** If stricture develops it can be treated by:
  - (i) Oesophagoscopy and prograde dilatations, if permeable,
  - (ii) Gastrostomy and retrograde dilatation, if impermeable,
  - (iii) Oesophageal reconstruction or by-pass, if dilatations are impossible.
- **(l)** Patients of corrosive injuries of oesophagus may require life-long follow-up.

# BENIGN STRICTURES OF OESOPHAGUS

## Aetiology

The strictures usually occur when muscular coat of the oesophagus is damaged. The common causes are:

- **(a)** Burns due to corrosive substances or hot fluids.
- **(b)** Trauma to oesophageal wall due to impacted foreign bodies or instrumentation or external injuries.
- **(c)** Ulcerations due to reflux oesophagitis.
- **(d)** Ulcerations due to diphtheria, typhoid.
- **(e)** Sites of surgical anastomosis.
- **(f)** Congenital, usually in the lower third.



## Clinical Features and Diagnosis

Dysphagia, first to solids and then to liquids, is the common complaint. When obstruction is complete, regurgitation and cough may occur. Patient is malnourished.

Barium swallow establishes the diagnosis. Oesophagoscopy is required to exclude malignancy.

## Treatment

### **(a) Prograde dilatation with bougies**

It should be done under direct vision through oesophagoscope. Dilatations may be required frequently.

### **(b) Gastrostomy**

It helps to feed the patients and give rest to the inflamed area above the strictures. After a few days, when inflammation subsides, lumen may become visible and prograde dilatation can be restored. Patient can be given a thread to swallow, which is recovered from the stomach, and prograde or retrograde bouginage can be done.

### **(c) Surgery**

Excision of strictured segment and reconstruction of food passage using stomach, colon or jejunum.

It is displacement of stomach into the chest through oesophageal opening of the diaphragm. Most patients are elderly, past 40 years. This disorder is of two types:

- **(a) Sliding.** Stomach is pushed into the thorax, in line with the oesophagus. Reflux oesophagitis is common and may give rise to ulceration and stenosis. Haematemesis may occur. It is caused by raised intra-abdominal pressure.
- **(b) Paraoesophageal.** A part of the stomach along with its peritoneal covering passes up into the thorax by the side of oesophagus. The gastro-oesophageal junction still remains below the diaphragm and the angle between oesophagus and stomach is maintained. There is no reflux oesophagitis in this type of hernia. The main symptom is dyspnoea on exertion due to position of stomach in the thorax, and sometimes bleeding.

*Diagnosis* of both types of hiatus hernia can be made by barium swallow.

## Treatment

Mainly it is surgical; the hernia is reduced and diaphragmatic opening repaired. Early cases and those unfit for surgery may be treated conservatively to reduce reflux oesophagitis by measures such as (i) sleeping with head and chest raised; (ii) avoidance of smoking; (iii) use of drugs that reduce acidity (antacids and proton pump inhibitors); (iv) reduction of obesity; and (v) attention to the causes which raises intra-abdominal pressure.

## **PLUMMER-VINSON (PATTERSON BROWN-KELLY) SYNDROME**

Classical features of this syndrome include dysphagia, iron-deficiency anaemia, glossitis, angular stomatitis, koilonychia (spooning of nails) and achlorhydria. There is atrophy of the mucous membrane of the alimentary tract.

Predominantly, it affects females past 40 years. Barium swallow shows a web in the post-cricoid region and the same can be seen on oesophagoscopy. It is due to subepithelial fibrosis in this region.

About 10% of the cases with this syndrome will develop post-cricoid carcinoma. It also predisposes to the development of carcinoma in the tongue, buccal mucosa, pharynx, oesophagus and the stomach.

## Treatment

- **(i)** To correct anaemia by oral/parenteral iron. Serum levels of iron are more important than haemoglobin level. Associated B<sub>12</sub> and B<sub>6</sub> deficiency should also be corrected;
- **(ii)** dilatation of the webbed area by oesophageal bougies.

## **GLOBUS (HYSTERICUS) PHARYNGEUS**

It is a functional disorder where the patient complains of "lump" in the throat. There is no true dysphagia. In fact, feeling of lump is more marked between the meals rather than during a meal. Such a patient may have fear of cancer in the throat. Clinical examination of the pharynx, larynx and base of tongue is normal.

*Treatment* is reassurance to the patient when no cause has been found.

## MOTILITY DISORDERS OF OESOPHAGUS

They can be divided into:

- **(a)** Hypermotility disorder, e.g. cricopharyngeal spasm, diffuse oesophageal spasm, nut cracker oesophagus.
- **(b)** Hypomotility disorders, e.g. cardiac achalasia, gastro-oesophageal reflux, scleroderma, amyotrophic lateral sclerosis.

They may involve the upper sphincter, lower sphincter or the body of oesophagus.



## Cricopharyngeal Spasm

It is caused by failure of the upper oesophageal sphincter to relax properly. There is incoordination between relaxation of the upper oesophageal sphincter and simultaneous contraction of the pharynx. The common causes are cerebrovascular accidents, Parkinson's disease, bulbar polio, multiple sclerosis and muscular dystrophies.

## Diffuse Oesophageal Spasm

It is characterised by strong non-peristaltic contractions of the body of oesophagus while sphincteric relaxation is normal. The *symptoms* consist of dysphagia or odynophagia with substernal chest pain, simulating angina pectoris. Barium swallow may show segmented oesophageal spasms giving a *rosary bead* or a *cork-screw type* of oesophagus, though it may be normal in some. Manometry shows normal relaxation of the sphincter on swallowing. The *treatment* is dilatation of lower oesophagus. Severe cases may require myotomy of oesophagus from the arch of aorta to lower sphincter.

## Nut-cracker Oesophagus

These are strong, high amplitude oesophageal contractions but the contractions remain peristaltic (compare diffuse oesophageal spasm where contractions are non-peristaltic). It causes dysphagia and substernal pain.

## Cardiac Achalasia

It is characterised by the absence of peristalsis in the body of oesophagus and high resting pressure in lower oesophageal sphincter; the latter also does not relax during swallowing.

The *symptoms* of cardiac achalasia include dysphagia, which is more to liquids than solids (reverse of that seen in malignancy or strictures) and regurgitation of swallowed food particularly at night.

The *diagnosis* is made by: (a) radiography (barium swallow shows dilated oesophagus with narrowed *rat tail lower end*), sometimes also called bird-beak appearance; (b) manometric studies (low pressure in the body of oesophagus and high pressure at lower sphincter and failure of the sphincter to relax); (c) endoscopy (to exclude benign stricture or any development of carcinoma which is a common complication of this disorder).

The *treatment* of choice is the modified Heller's operation (myotomy of the narrowed lower portion of the oesophagus). Forceful pneumatic dilatation of the lower oesophagus can be done in those unfit for surgery.

# Gastro-oesophageal Reflux

It is due to decreased function of lower oesophageal sphincter thus permitting regurgitation of gastric contents into oesophagus. Other causes of gastro-oesophageal reflux are pregnancy, hiatus hernia, scleroderma, excessive use of tobacco and alcohol, and drugs that relax the smooth muscle (anticholinergic, beta-adrenergic drugs and calcium-channel blockers).

The *symptoms* of oesophageal reflux include substernal pain, heartburn, and regurgitation.

The *treatment* consists of:

- (a) Elevation of the head of bed at night.
- (b) Avoiding food at least 3 hours before bed time.
- (c) Antacids.
- (d) Drugs that increase tone of lower oesophageal sphincter, e.g. metoclopramide.
- (e) H<sub>2</sub> receptor antagonists, e.g. cimetidine and ranitidine.
- (f) Avoiding smoking, alcohol, caffeine, chocolates, mints and carbonated drinks.
- (g) Antireflux surgery, e.g. Nissen's fundoplication.

## Complications of Gastro-oesophageal Reflux

- I. Oesophagus
  - Oesophagitis, oesophageal mucosal erosion and haemorrhage
  - Benign oesophageal stricture
  - Barrett's oesophagus (normal squamous epithelium of oesophagus is replaced by columnar epithelium as a result of continuous inflammation). It is a precancerous condition
- II. Lung
  - Aspiration pneumonia
  - Asthma
  - Bronchiectasis
- III. Larynx
  - Posterior laryngitis causing vague pain in throat, hoarseness and repeated throat clearing
  - Pachydermia laryngis
  - Contact ulcers and granulomas
  - Posterior glottic stenosis
  - Paroxysmal laryngospasm
  - Carcinoma larynx
- IV. Ear
  - Otitis media with effusion
- V. Miscellaneous
  - Globus hystericus

## Scleroderma

It is a systemic collagen disorder *primarily neural*, but secondarily weakening the smooth muscles of the lower two-thirds of oesophagus and the lower oesophageal sphincter. Dysphagia may precede cutaneous lesions. Barium swallow shows absence of peristalsis in distal two-thirds of the oesophagus. Many of these patients have hiatus hernia, or reflux oesophagitis and may develop stricture in distal part of the oesophagus due to recurrent inflammation.

## Schatzki's Ring

It occurs at the junction of squamous and columnar epithelium at the lower end of oesophagus and has also been called *lower oesophageal ring*. Usually seen in patients above 50 years of age. Cause is unknown. Symptomatic patients complain of intermittent dysphagia and some may even present with bolus obstruction. It may be associated with hiatus hernia. Treatment is oesophageal dilatation.

# NEOPLASMS OF OESOPHAGUS

## Benign Neoplasms

Benign neoplasms are rare compared to malignant ones.

### ***Leiomyoma***

page 352

page 353

is the most common and accounts for two-thirds of all the benign neoplasms. It arises from the smooth muscle and grows in the wall of oesophagus. Dysphagia is produced when tumour exceeds the diameter of 5 cm. Barium swallow shows an ovoid filling defect. Endoscopy reveals a submucosal swelling. Biopsy should not be taken. Treatment is enucleation of the tumour by thoracotomy.

### ***Mucosal polyps, lipomas, fibromas and haemangiomas***

are other benign tumours. They are often pedunculated and present in the oesophageal lumen. Endoscopic removal is avoided because of the danger of oesophageal perforation. Treatment is surgical excision by oesophagotomy.



# Carcinoma Oesophagus

## Incidence

Incidence of oesophageal carcinoma is high in China, Japan, USSR and South Africa. In India, it constitutes 3.6% of all body cancers in the rich and 9.13% of those in the poor.

## Aetiology

Smoking and alcohol consumption are high risk factors and so are some particular dietary habits. In India, high incidence is associated with tobacco chewing and smoking.

About 5% of oesophageal cancers arise in the pre-existing pathological lesions, such as benign strictures, hiatus hernia, cardiac achalasia and diverticula. Plummer-Vinson syndrome is another predisposing factor.

## Pathology

Squamous cell carcinoma is the most common (93%). Adenocarcinoma (3%) is also seen, but in the lower oesophagus, and may be an upward extension of the gastric carcinoma. Other types are rare.

## Spread of Carcinoma

- **(a) Direct.** The lesion may fill the lumen and infiltrate the wall of oesophagus. It may also spread to the adjoining structures such as the trachea, left bronchus, aorta or pericardium. Involvement of the recurrent laryngeal nerves causes aspiration problems.
- **(b) Lymphatic.** Depending on the site involved, cervical, mediastinal or coeliac nodes may be involved. Cervical and thoracic lesions also spread to supraclavicular nodes. "Skip lesions" may also occur due to spread through the submucosal lymphatics.
- **(c) Blood borne.** Metastases may develop in the liver, lungs, bone and brain.

## Clinical Features

- **1. Early symptoms** include substernal discomfort and preference for soft or liquid food.
- **2. Progressive dysphagia and emaciation.** Dysphagia first to solids and then to liquids. Patient loses weight and becomes emaciated.
- **3. Pain.** Usually signifies extension of tumour beyond the walls of oesophagus. It is referred to the back.
- **4. Aspiration problem.** Spread of cancer may cause laryngeal paralysis or fistulae formation leading to cough, hoarseness of voice, aspiration pneumonia and mediastinitis.

## Diagnosis

- **1. Barium swallow** shows narrow and irregular oesophageal lumen, without proximal dilatation of the oesophagus.
- **2. Oesophagoscopy.** Useful to see the site of involvement, extent of the lesion, and to take biopsy. Flexible fibre optic oesophagoscopy obviates the need for general anaesthesia and gives a magnified view.
- **3. Bronchoscopy** helps to exclude extension of growth into the trachea and bronchi.
- **4. CT scan** is useful to assess the extent of disease and nodal metastases.

## Treatment

Surgery of upper two-thirds of oesophagus is difficult due to great vessels and involvement of mediastinal nodes. Radiotherapy is the treatment of choice.

Surgery is the preferred method of treatment for cancer of lower one third. The affected segment, with a wide margin of oesophagus proximally, and the fundus of stomach distally, can be excised with primary reconstruction of the food channel.

In advanced lesions, only palliation is possible. An alternative food channel can be provided by:

- **(i)** A by-pass operation.
- **(ii)** Oesophageal intubation with Celestin or Mousseau-Barbin or a similar tube.
- **(iii)** Permanent gastrostomy or a feeding jejunostomy.
- **(iv)** Laser surgery: Oesophageal growth is burnt with Nd: YAG laser to provide a food channel. Chemotherapy is used only as a palliative measure in the locally advanced or disseminated disease.

## Prognosis

Five-year survival is not more than 5-10%.

## 67 Dysphagia

*Dysphagia* is difficulty in swallowing. The term *odynophagia* is used when swallowing causes pain. The latter is more marked in ulcerative and inflammatory lesions of food passages-oral cavity, oropharynx and oesophagus.

# Aetiology

The cause of dysphagia may be *pre-oesophageal* (i.e. due to disturbance in the oral or pharyngeal phase of deglutition), or *oesophageal* (when disturbance is in oesophageal phase). This classification is clinically useful as most of the pre-oesophageal causes can be easily excluded by physical examination while oesophageal ones require investigation.

## Pre-oesophageal Causes

### (a) Oral phase

Normally, food must be masticated, lubricated with saliva, converted into a bolus by movements of tongue and then pushed into the pharynx by elevation of the tongue against the hard palate. Any disturbance in these events will cause dysphagia. Thus cause may be:

- **(i) Disturbance in mastication:** trismus, fractures of mandible, tumours of the upper or lower jaw, disorders of temporomandibular joints.
- **(ii) Disturbance in lubrication:** xerostomia following radiotherapy, Mikulicz disease.
- **(iii) Disturbance in mobility of tongue:** paralysis of tongue, painful ulcers, tumours of tongue, lingual abscess, total glossectomy.
- **(iv) Defects of palate:** cleft palate, oronasal fistula.
- **(v) Lesions of buccal cavity and floor of mouth:** stomatitis, ulcerative lesions, Ludwig's angina.

### (b) Pharyngeal phase

For a normal swallow, food should enter the pharynx and then be directed towards oesophageal opening. All unwanted communications into the nasopharynx, larynx, oral cavity should be closed. Disturbances in this phase can arise from:

- **(i) Obstructive lesions of pharynx,** e.g. tumours of tonsil, soft palate, pharynx, base of tongue, supraglottic larynx, or even obstructive hypertrophic tonsils.
- **(ii) Inflammatory conditions,** e.g. acute tonsillitis, peritonsillar abscess, retro or para-pharyngeal abscess, acute epiglottitis, oedema larynx.
- **(iii) Spasmodic conditions,** e.g. tetanus, rabies.
- **(iv) Paralytic conditions.** Paralysis of soft palate due to diphtheria, bulbar palsy, cerebrovascular accidents. They cause regurgitation into the nose.

Paralysis of larynx-lesions of vagus and bilateral superior laryngeal nerves cause aspiration of food into the larynx.

## Oesophageal Causes

The lesions may lie in the lumen, in the wall or outside the wall of oesophagus.

- **(a) Lumen.** Obstruction to lumen can occur in atresia, foreign body, strictures, benign or malignant tumours.
- **(b) Wall.** It can be acute or chronic oesophagitis, or motility disorders. The latter are:
  - (i) Hypomotility disorders, e.g. achalasia, scleroderma, amyotrophic lateral sclerosis.
  - (ii) Hypermotility disorders, e.g. cricopharyngeal spasm, diffuse oesophageal spasm.
- **(c) Outside the wall.** The lesions cause obstruction by pressing on the oesophagus from outside:
  - (i) Hypopharyngeal diverticulum (see page 290).
  - (ii) Hiatus hernia.
  - (iii) Cervical osteophytes.
  - (iv) Thyroid lesions, e.g. enlargement, tumours, Hashimoto's thyroiditis.
  - (v) Mediastinal lesions, e.g. tumours of mediastinum, lymph node enlargement, aortic aneurysm, cardiac enlargement.
  - (vi) Vascular rings (dysphagia lusoria).

# Investigations

## 1. History

A detailed history is of paramount importance. Ascertain, if dysphagia is of:

- (i) Sudden onset (foreign body or impaction of food on a preexisting stricture or malignancy, neurological disorders),
- (ii) Progressive (malignancy),
- (iii) Intermittent (spasms or spasmodic episodes over an organic lesion),
- (iv) More to liquids (paralytic lesions),
- (v) More to solids and progressing even to liquids (malignancy or stricture),
- (vi) Intolerance to acid food or fruit juices (ulcerative lesions).

Note any associated symptoms, e.g. regurgitation and heart burn (hiatus hernia); regurgitation of undigested food while lying down, with cough at night (hypopharyngeal diverticulum); aspiration into lungs (laryngeal paralysis); aspiration into the nose (palatal paralysis).

## 2. Clinical examination

Examination of oral cavity, oropharynx, and larynx and hypopharynx can exclude most of the pre-oesophageal causes of dysphagia. Examination of the neck, chest and nervous system, including cranial nerves should also be undertaken.

## 3. Blood examination

Haemogram is important in the diagnosis and treatment of Plummer-Vinson syndrome and to know the nutritional status of the patient.

## 4. Radiography

- (a) *X-ray chest*: To exclude cardiovascular, pulmonary and mediastinal diseases.
- (b) *Lateral view neck*: To exclude cervical osteophytes and any soft tissue lesions of post-cricoid or retropharyngeal space.
- (c) *Barium swallow*: It is useful in the diagnosis of malignancy, cardiac achalasia, strictures, diverticula, hiatus hernia or oesophageal spasms. Combined with fluoroscopic control or cineradiography, it can help in the diagnosis of motility disorders of oesophageal wall or sphincters.

## 5. Manometric and pH studies

A pressure transducer along with a pH electrode and an open-tipped catheter is introduced into the oesophagus to measure the pressures in the oesophagus and at its sphincters. Acid reflux into the oesophagus is measured by pH electrode. It also measures the effectiveness of oesophagus to clear the acid load after acid solution is put in the oesophagus. These studies help in motility disorders, gastro-oesophageal reflux and to find whether oesophageal spasms are spontaneous or acid-induced.

## 6. Oesophagoscopy

It gives direct examination of oesophageal mucosa and permits biopsy specimens. Flexible fibre-optic or rigid scopes can be used.

## 7. Other investigations

Bronchoscopy (for bronchial carcinoma), cardiac catheterisation (for vascular anomalies), thyroid scan (for malignant thyroid) may be required, depending on the case.

## 68 Foreign Bodies of Food Passage

An ingested foreign body (FB) may lodge in:

- 1. The tonsil.
- 2. The base of tongue/vallecula.
- 3. The pyriform fossa.
- 4. The oesophagus.

### ***Tonsil***

Usually, it is a sharp fish bone or a needle in one of the tonsillar crypts. It can be easily observed by oropharyngeal examination and removed.

### ***Base of tongue or vallecula***

Here again it is usually the fish bone or a needle. It can be observed by mirror examination. It can be removed as an office procedure by asking the patient to hold his own tongue while examiner holds a large laryngeal mirror in one hand and a curved forceps in the other.

### ***Pyriform fossa***

Fish bone, chicken bone, needle or a denture may lodge in the pyriform fossa. Small foreign bodies can be removed under local anaesthetic with a curved forceps as described above. Large impacted foreign bodies or those in children should be removed by endoscopy under general anaesthesia.

### ***Oesophagus***

Usual foreign bodies that get lodged in the oesophagus are a coin, piece of meat, chicken bone, denture, safety pin, or a marble.

## Aetiology

- **1. Age.** Children are more often affected. They have a tendency to put anything in the mouth. Playing while eating is another factor.
- **2. Loss of protective mechanism.** Use of upper denture prevents tactile sensation and a foreign body is swallowed undetected. Loss of consciousness, epileptic seizures, deep sleep or alcoholic intoxication are other factors.
- **3. Carelessness.** Poorly prepared food, improper mastication, hasty eating and drinking.
- **4. Narrowed oesophageal lumen.** Pieces of food may be held up in cases of oesophageal stricture or carcinoma. The first symptom of carcinoma oesophagus may be sudden obstruction from a foreign body such as a piece of meat, fruit or vegetable.
- **5. Psychotics.** Foreign body may be swallowed with an attempt to commit suicide.

## Site of Lodgement of Foreign Body

By far the commonest site is at or just below the cricopharyngeal sphincter. Flat objects like coins are held up at the sphincter while others are held in the upper oesophagus just below the sphincter due to poor peristalsis. Foreign bodies which pass the sphincter can be held up at the next narrowing at broncho-aortic constriction or at the cardiac end. Sharp or pointed objects lodge anywhere in the oesophagus.

# Clinical Features

## Symptoms

- 1. *History* of initial choking or gagging.
- 2. *Discomfort or pain* located just above the clavicle on the right or left of trachea. Discomfort increases on attempts to swallow. Local discomfort may point to the site of FB in cervical oesophagus but not so in lower oesophagus.
- 3. *Dysphagia*. Obstruction to swallowing may be partial or total. Partial obstruction becomes total with time due to oedema.
- 4. *Drizzling of saliva*. It is seen in cases of total obstruction. Saliva may be aspirated causing pneumonitis.
- 5. *Respiratory distress*. Impacted foreign body in the upper oesophagus compresses posterior wall of trachea causing respiratory obstruction especially in children. Laryngeal oedema can develop.
- 6. *Substernal or epigastric pain* may occur due to oesophageal spasm or incipient perforation.

---

page 356

page 357

## Signs

- 1. Tenderness in the lower part of neck on the right or left of trachea.
- 2. Pooling of secretions in the pyriform fossa on indirect laryngoscopy. They do not disappear on swallowing.
- 3. Sometimes a foreign body may be seen protruding from the oesophageal opening in the postcricoid region.



## Investigations

- **1. Plain X-rays.** Soft tissue lateral view of neck, posteroanterior, and lateral view of chest may show the presence and location of a radio-opaque foreign body (Fig. 68.1). Children should be X-rayed from nasopharynx to the rectum as multiple foreign bodies may have been ingested.
- **2. Fluoroscopy.** Radiolucent foreign bodies are not seen on plain X-rays. They can be diagnosed on fluoroscopy, when the patient is given a piece of cotton soaked in barium or barium filled capsule to swallow and its passage is observed through the oesophagus.

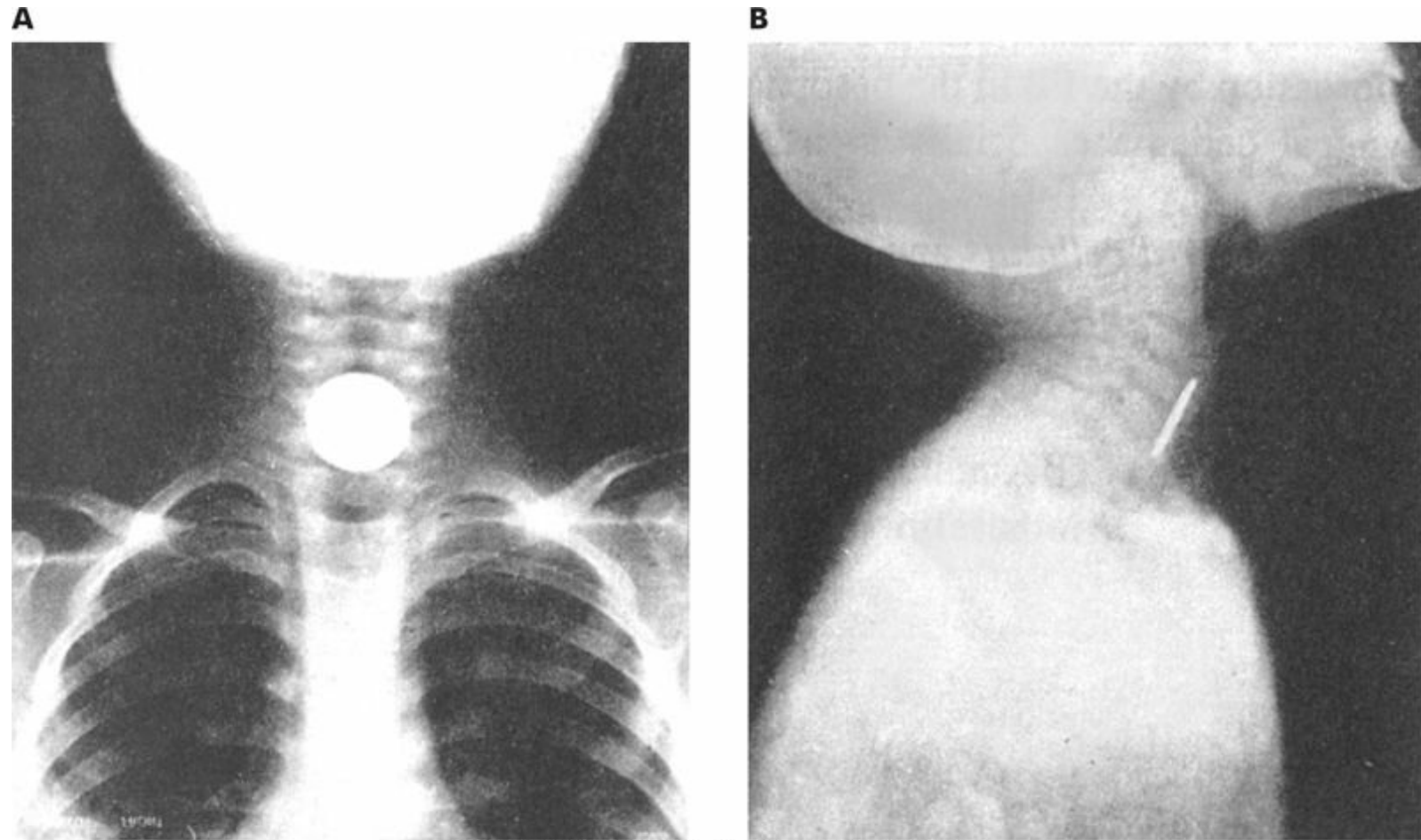
# Management

## 1. Oesophagoscopic removal

Most of the foreign bodies in oesophagus can be removed by oesophagoscopy under general anaesthesia.

## 2. Cervical oesophagotomy

Impacted foreign bodies or those with sharp hooks such as partial dentures located above thoracic inlet may require removal through an incision in the neck and opening of cervical oesophagus.



Dhingra: Diseases of Ear Nose and Throat, 5th Edition  
Copyright © 2010 Elsevier. All rights reserved.

Figure 68.1 Foreign body food passage. (A) P.A. view showing 50 paisa coin. (B) Lateral view of the same.

## 3. Transthoracic oesophagotomy

For impacted foreign bodies of thoracic oesophagus, chest is opened at the appropriate level.

A foreign body which has reached the stomach may pass through the rest of gastrointestinal tract without difficulty; stools should be carefully examined every day. Patient should take a normal diet, and no purgatives should be administered to hasten the passage. *Operative interference* may be required when:

- (i) Patient complains of pain and tenderness in abdomen.
- (ii) Foreign bodies are not showing any progress on serial X-rays taken at a few days interval.
- (iii) Foreign body is 5 cm or longer (e.g. hair pin) in a child below 2 years. It is unlikely to pass through the turns of the duodenum.
- (iv) Presence of pyloric stenosis.

## Complications of Oesophageal Foreign Body

- **1. Respiratory obstruction.** This is due to tracheal compression by the FB in the oesophagus, or laryngeal oedema especially in infants and children.
- **2. Perioesophageal cellulitis and abscess** in the neck.
- **3. Perforation.** Sharp objects may perforate the oesophageal wall, setting up mediastinitis, pericarditis or empyema. They may perforate the aorta and prove fatal.
- **4. Tracheo-oesophageal fistula.** Rare.
- **5. Ulceration and stricture.** Overlooked foreign bodies may cause slow ulceration and stricture.

---

page 357

page 358

page 358

page 359

## SECTION VII Recent Advances

---

page 359

page 360

## 69 Laser Surgery

LASER is an acronym for *Light Amplification by Stimulated Emission of Radiation*.

### ***Principle***

Normally, an atom is in a stable form, i.e. the electrons equal to the number of protons, are revolving around the nucleus in a fixed orbit. When given energy, electrons change their orbits away from the nucleus and the atoms are then called 'excited' but this excited state of atoms does not last long. The atoms soon release their absorbed energy automatically (spontaneous emission) and return to their original state. If photons are made to strike these excited atoms, the decay of the atoms is accelerated and both the incident and the absorbed photons are released (stimulated emission). This stimulated radiation is amplified with the help of mirrors. Thus, lasers are electromagnetic radiations with specific wave length depending upon the type of lasing medium such as argon, carbon dioxide or Nd:YAG.

# Types of Lasers

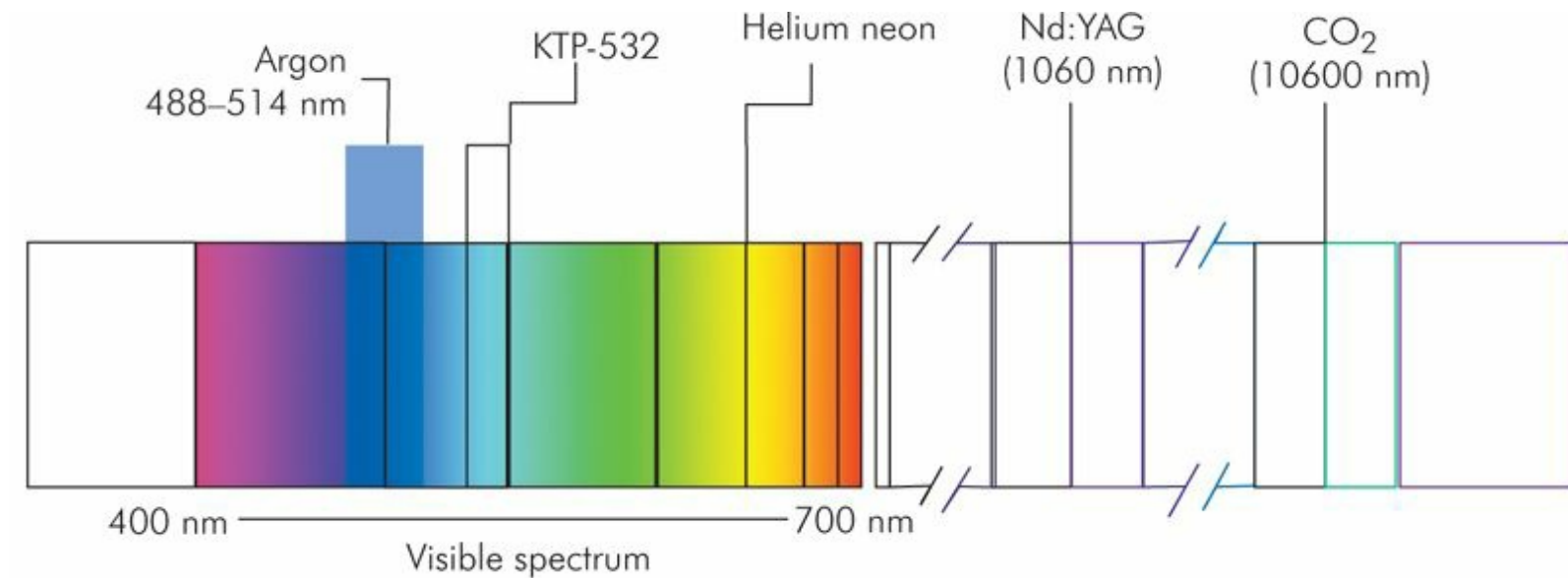
Four types of laser are generally used in surgery. They are:

- 1. Argon
- 2. KTP-532 (Potassium titanyl phosphate)
- 3. Nd:YAG (Neodymium-yttrium aluminium garnet)
- 4. CO<sub>2</sub>

The clinical applications of these lasers depend on their wave length and special absorptive powers of the tissues on which they are used. The function of the laser beams is three folds (i) to *vaporise*, (ii) to *cut* or (iii) to *coagulate the tissue*.

Argon and KTP-532 lasers fall in the visible spectrum (400-700 nm) and do not require a separate beam to focus them (Fig. 69.1). They are, therefore, ideal for middle ear surgery.

# Properties of Different Lasers and Their Surgical Use



Invisible spectrum

Invisible spectrum

Dhingra: Diseases of Ear Nose and Throat, 5th Edition  
Copyright © 2010 Elsevier. All rights reserved.

Figure 69.1 Argon and KTP-532 fall under visible zone of spectrum while Nd:YAG and CO<sub>2</sub> lasers are in invisible zone and require another visible source (He-Neon) to focus them.

page 361

page 362

- **1. Argon laser**, wave length 488-514 nm, blue in colour, passes through clear fluid but gets absorbed by pigmented tissues. It is mainly used for photocoagulation such as of port wine stain, haemangioma, telangiectasia. It is also used for retinal lesions and microsurgery of the ear (stapedotomy, lysis of middle ear adhesions, spot welding of tympanoplasty grafts).
- **2. KTP-532 laser**, wave function 532 nm, falls in visible spectrum (blue-green), and is selectively absorbed by pigment. It is used for microsurgery of the ear.
- **3. Nd:YAG laser**, wave length 1060 nm; invisible; can be transmitted by flexible endoscopes; has effective coagulative properties. It can be used with CO<sub>2</sub> laser in the treatment of tracheal and endobronchial tumours.
- **4. CO<sub>2</sub> laser**, wave length 10600 nm; invisible; requires aiming beam of helium-neon laser. It cannot pass through the flexible fibrescope. It is very effective to vaporise tissues and give a bloodless field. It is the most commonly used laser in ENT surgery.

## Uses of CO<sub>2</sub> Laser in ENT

- **(a) Nose**, e.g. papillomas, rhinophyma, telangiectasias, nasal polypi, choanal atresia, turbinectomy. It is very beneficial in patients with bleeding dyscrasias and coagulopathies.
- **(b) Oral cavity**, e.g. multiple areas of leukoplakia, erythroplakia, small superficial cancers, debulking of large, recurrent or inoperable tumours. Advantages are transoral approach, precision surgery, haemostasis and less post-operative oedema and pain.
- **(c) Oropharynx**, e.g. tonsillar and pharyngeal tumours. Laser tonsillectomy is done in those with coagulopathies or hypertension.
- **(d) Larynx**, e.g. papilloma larynx, laryngeal web, subglottic stenosis, capillary haemangioma. In adults, it has been used for vocal nodule, leukoplakia of cord, papilloma, polypoid degeneration of cord, endoscopic laser arytenoidectomy, malignant T<sub>1</sub> lesions of the vocal cord.
- **(e) Trachea and bronchi**, e.g. recurrent papillomatosis, tracheal stenosis, granulation tissue and bronchial adenoma, debulking of obstructive malignant lesions of trachea or bronchi.
- **(f) Plastic surgery**, e.g. benign and malignant tumours of skin, vaporisation of naevi and tattoos.
- **(g) Neuro-otology**, e.g. removal of acoustic neuromas.

## Safety Precautions in the Use of Laser

- **(a) Education of staff.** The surgeon, anaesthesiologist, nursing and operation theatre personnel should be educated in safety measures while using laser.
- **(b) Protection of eye.** Protective eye glasses, specific for the wave length of laser being used, should be worn by the personnel to prevent accidental burns to the cornea or retina. For Nd:YAG laser, wear green glasses with optical density of 6; for Argon laser use orange-yellow glasses.  
Patient's eyes should also be protected by a double layer of saline-moistened eye pads.
- **(c) Protection of other exposed areas.** All exposed parts of skin and mucous membranes of the patient, not in surgical field, should be protected by saline soaked towels, pads or sponges which are kept wet by moistening them periodically. Teeth should also be protected.
- **(d) Evacuation of smoke.** Two separate suctions, one for the blood and the other for smoke and steam which is produced by vaporisation of tissues, should be used.
- **(e) Anaesthetic gases and equipment.** Only non-inflammable gases like halothane or enflurane should be used. When using CO<sub>2</sub> laser, red rubber or silicone tube should be wrapped by reflective metallic foil. Cuff should be inflated with methylene-blue coloured saline and protected with saline soaked cottonoids.

The safest endotracheal tube to use with Nd:YAG laser is colourless or white polyvinyl or silicone tube that does not have any black or dark lettering or a lead lined marking along the side. Negligence in these precautions can cause endotracheal tube fires.

## Photodynamic Therapy

It is an upcoming newer modality of treating cancer of skin, larynx, nasopharynx, tumour of aerodigestive tract and endobronchial tumours. It is based on the principle of injecting a photosensitising agent which is taken up preferentially by the tumours cells and then exposing the site to specific wavelength of laser. Laser activates the photosensitising agent which brings about destruction of cancer cells but spares the normal tissues. Photodynamic therapy has also been used for recurrences after surgery, radiation or chemotherapy. Photosensitising agents used intravenously include haematoporphyrin derivative (for head and neck cancers) and photosan-3 (for endobronchial tumours). Topical sensitiser, delta aminolevulinic acid, has been used for skin cancers (basal cell carcinoma and Bowen's disease).

Laser often used is argon tunable dye laser with a wavelength of 630 nm. It also has the advantage of delivery through flexible fibres. Also, by changing the dye, lasers with different wavelengths can be produced. Patients receiving photodynamic therapy should avoid exposure to sunlight and use sun-protective clothing to avoid photosensitive skin reactions which may continue for several weeks.



## **RADIOFREQUENCY SURGERY IN ENT**

Radiowaves have been used surgically to reduce the volume of tissues. It has been used on inferior turbinates to relieve nasal obstruction; on soft palate to relieve primary snoring, upper airway resistance and sleep apnoea; and on the base of tongue to relieve sleep apnoea. It has also been used for the treatment of lingual thyroid.

The radiofrequency (RF) device generates electromagnetic waves of very high frequency between 350 kHz and 4 MHz. Usually 460 kHz is used. RF is delivered through various probes according to the site of ablation. The probe, inserted into the tissues, causes ionic agitation, heats up the tissues which result in protein coagulation and tissue necrosis but no charring. Later scar formation occurs in 3 weeks with reduction in size of tissue. Usually the temperature is controlled between 80 and 85°C. The essential parameters of radiofrequency are the power (in Watts), temperature (degrees of Celsius), resistance (in Ohms), treatment time (in seconds) and total energy delivered in joules (i.e. Watt × seconds) and can be controlled in the device.

Using different types of electrodes, radiofrequency has also been used to perform tonsillotomy, microlaryngeal surgery (to remove granulomas, papillomas, cysts), myringotomy, uvulopalatoplasty, correction of rhinophyma and cosmetic removal of skin lesions. Radiofrequency is used to cut and coagulate tissues with minimal lateral tissue damage and charring. It is minimally invasive technique, and surgery can be performed as an outdoor procedure. Complications are few. The procedures are cost effective.

## **HYPERBARIC OXYGEN THERAPY IN ENT**

The role of hyperbaric oxygen therapy (HBO<sub>2</sub>) in some disorders of ENT is well established and is being used in Europe, Japan and China. Disorders like sudden idiopathic sensorineural hearing loss, acoustic trauma, noise-induced hearing loss and tinnitus have been treated successfully by this modality. It has also been used to treat malignant otitis externa and mucormycosis of paranasal sinuses and skin flaps with compromised blood supply. During HBO<sub>2</sub> therapy, partial pressure of oxygen rises in the perilymph and endolymph, which then diffuses and supplies oxygen to sensory cells of the inner ear. During HBO<sub>2</sub> therapy pO<sub>2</sub> increases even up to 460% in labyrinthine fluids and is still 60% above normal after 1 hour of termination of therapy. HBO<sub>2</sub> also causes reduction of haematocrit and decrease in the blood viscosity and thus can have a rheologic effect improving diffusion of oxygen to cochlear and vestibular cells and other ischaemic cells.

## Procedure

Patient is placed in hyperbaric oxygen chamber where he/she inhales 100% oxygen for 1 hour at 2.4 atmospheric pressure. Patient can sit or lie down on the bed. Compression time for the chamber is 10 minutes while decompression is 15 minutes. This is in addition to 1 hour of oxygen inhalation under pressure. Patient receives one sitting per day (usually six per week) for a total of 10 to 20 sittings.

## Results

In sudden deafness, a recovery of 10-20 dB has been noticed in 32.6% of patients in two frequencies after 15 sittings. Tinnitus loudness was decreased by half (visual analogue scale) in 45% of patients. Late application of HBO<sub>2</sub> with delay more than 3 months reduces the beneficial outcome. In another randomised prospective trial of primary HBO<sub>2</sub> versus primary conservative treatment in Germany shows a better outcome in the HBO<sub>2</sub> group with recovery in 80% of patients. In still another trial using HBO<sub>2</sub> therapy where conservative treatment (including cortisone) had failed showed improvement in 30% of cases even after 3 months delay.

Tinnitus is reduced to 50% intensity in 70% of cases if treated within 3 months of onset; 30% may be totally cured of tinnitus.

Both in sudden deafness and tinnitus, results of treatment are better if the HBO<sub>2</sub> therapy is started earlier than in those started late after 3 months.

Hyperbaric oxygen therapy is also being used for several other conditions, such as:

- **I.** Non-healing ulcers and compromised skin grafts and flaps
- **II.** Gas gangrene
- **III.** Necrotising soft tissue infections of subcutaneous tissues, muscles and fascia
- **IV.** Burns
- **V.** Ocular ischaemic pathology
- **VI.** Carbon-monoxide poisoning or smoke inhalation
- **VII.** Air or gas embolism
- **VIII.** Non-healing wounds-diabetic or venous
- **IX.** Chronic osteomyelitis

## Cost of Treatment

Each sitting of therapy costs about Rs. 1800. However, special packages are also available for 5, 10, 20 applications.

## 70 Cryosurgery

Rapid freezing of tissues to temperatures of  $-30^{\circ}\text{C}$  and below and their slow thawing causes destruction. This fact has been used to treat various lesions of the head and neck including benign, premalignant and malignant neoplasms.

Agents used in freezing the tissue are used either by an open method (liquid nitrogen spray or carbon dioxide snow) or through a closed system such as a cryoprobe. A cryoprobe is based on Joule-Thomson effect, i.e. rapid expansion of compressed gas through a small hole produces cooling. Probes in current use produce a tip temperature of  $-70^{\circ}\text{C}$  or below and are available in different sizes and designs to suit the area of cryoapplication. Some probes also have thermocouples which can be inserted into the tissue to monitor the temperature. The clinically available closed systems employ liquid nitrogen, nitrous oxide or carbon dioxide.

# Mechanism of Tissue Destruction

Freezing causes cell death through several mechanisms:

## **1. Dehydration**

The pure water inside and outside the cell crystallises with consequent rise in the concentration of electrolytes. The pH of the medium also changes as the buffering substances crystallise out. Urea and dissolved gases also reach toxic concentrations and cause cell death.

## **2. Denaturation**

Cell membranes are made up of lipoproteins. Their denaturation makes cell membrane permeable to cations. Thawing of cells, now engorged with cations result, in cell lysis.

## **3. Thermal shock**

This arrests the respiratory function of cell.

## **4. Vascular stasis**

Both arterial and venous supply of blood is occluded leading to ischaemic infarct. Microthrombosis of capillaries is seen within a few hours of cryoapplication. It is because of this mechanism that cryosurgery is useful to treat vascular tumours, e.g. haemangioma, angiofibroma or glomus tumours.

## **5. Cryoimmunisation**

Autoantibodies, specific to the tissues frozen, have been seen experimentally. This is supposed to provide tissue specific immunity to subsequent challenges with the same tumour.

## Technique

Cryotherapy can be applied under local or light general anaesthesia. Sometimes, no anaesthesia is used as freezing itself causes numbness. The area to be frozen should be insulated. A suitable cryoprobe is applied into or upon the tissues and the latter frozen quickly for 3-8 minutes and then allowed to thaw slowly. The procedure is repeated once or twice. Area frozen should include a margin of normal tissue. A thermocouple can be implanted to ensure freezing at an adequate depth. After cryotherapy, the area is allowed to heal by secondary intention. The necrotic slough falls off in 3-6 weeks. Repeat cycles of cryotherapy may be required to achieve the desired result.



# Uses of Cryotherapy

## **1. Benign vascular tumours**

Cryotherapy has been found useful to treat haemangiomas involving skin, oral cavity or oropharynx. It has also been used as an adjunct to treat vascular tumours such as angiofibroma and glomus tumour.

## **2. Premalignant lesions**

Leukoplakia, involving the cheek, tongue, floor of mouth, has been effectively treated by cryotherapy. It is preferred to electrosurgery because of less scarring, better quality of regenerated epithelium, and no recurrence of lesion. It is also used to treat solar keratosis, a precancerous condition of skin.

## **3. Malignant lesions**

page 364

page 365

Skin cancers like Bowen's disease (intraepithelial carcinoma) and basal cell carcinoma have been treated successfully with a cure rate of 94-97%. Cryotherapy is particularly useful when tumour overlies the cartilage as the latter does not undergo necrosis with freezing. It is also useful for skin cancers which are multiple. Recurrent skin cancers or lesions which do not have well-defined margins should not be treated by this method.

Major role of cryotherapy has been in the palliation of advanced cancers or recurrent or residual tumours. In these cases, aim is to debulk the tumour mass to facilitate deglutition or respiration, to reduce tendency of tumours to bleed, and to relieve pain.

Role of curative cryotherapy in primary malignant lesion of the oral cavity and oropharynx is limited though some success is reported in early lesions (T1 N0) involving floor of mouth, tongue and palate. For this, cryotherapy should be used very selectively, in patients who are otherwise high risk groups and have a short expectancy of life due to other concurrent disease.

## **4. Other uses**

Cryotherapy has been applied to nasal turbinates to reduce their size and improve the airway. It has also been used in allergic rhinitis to control sneezing and rhinorrhoea. Cryodestruction of tonsils has been done in poor risk patients.

## Advantages of Cryotherapy

- 1. Useful in poor risk patients and can be applied without anaesthesia or under local anaesthesia.
- 2. Useful in patients with bleeding disorders or coagulopathies.
- 3. Can be used in multiple cancers, palliation of recurrent cancers where second course of radiation is not advisable.
- 4. Causes minimal post-treatment discomfort or pain.
- 5. Causes minimal scarring. Can be used at sites, notorious for keloid formation, e.g. presternal region.
- 6. It is an out-patient procedure.

## Disadvantages of Cryotherapy

- 1. No tissue is available for biopsy in case of small lesions.
- 2. Not possible to assess margins of tumour to know whether free of malignant cells.
- 3. No control on depth of freezing.
- 4. When used for skin lesions, cryotherapy causes depigmentation and loss of hair due to destruction of hair follicles.
- 5. Anaesthesia of the part is required when lesion is near the nerve, e.g. ulnar or digital.

With the advent of laser therapy, many of the indications for cryotherapy will be reduced; however, its lower cost will be an important factor in developing countries.

## 71 Radiotherapy in Head and Neck Cancer

Radiotherapy forms an important modality to treat head and neck malignancies. It may be used:

- **(a)** Alone, *to cure* early cancers and thus preserve the function of the organ, e.g. glottic cancer.
- **(b)** As an *adjuvant* to surgery or chemotherapy, to increase the survival rate in more advanced lesions.
- **(c)** As a *palliative measure*, in advanced lesions, to control local symptoms of pain, bleeding or obstruction to air and food channels, when total control of disease cannot be anticipated.

It has also been used in the treatment of certain *benign vascular lesions* where risks of surgery are great, e.g. angiofibroma or glomus tumour and also to control excessive scar formation in keloids.

# Types of Radiation

## 1. Photon beams

These are the most common forms of radiation, both X-rays and gamma rays fall in this category (Fig. 71.1). A photon is considered a "packet" of electromagnetic radiations. X-rays are produced by X-ray machines when high energy electrons bombard a metallic target. Gamma rays are emitted by radioactive sources, e.g. cobalt 60.

## 2. Electron beams

These are second most common forms of radiation. Their main characteristic is rapid dose build up and sharp dose fall off with very little scatter. They are used to boost up the radiation dose to the target area avoiding radiation to adjoining vital structures, e.g. spinal cord. They are produced by linear accelerator, betatron and microtron.

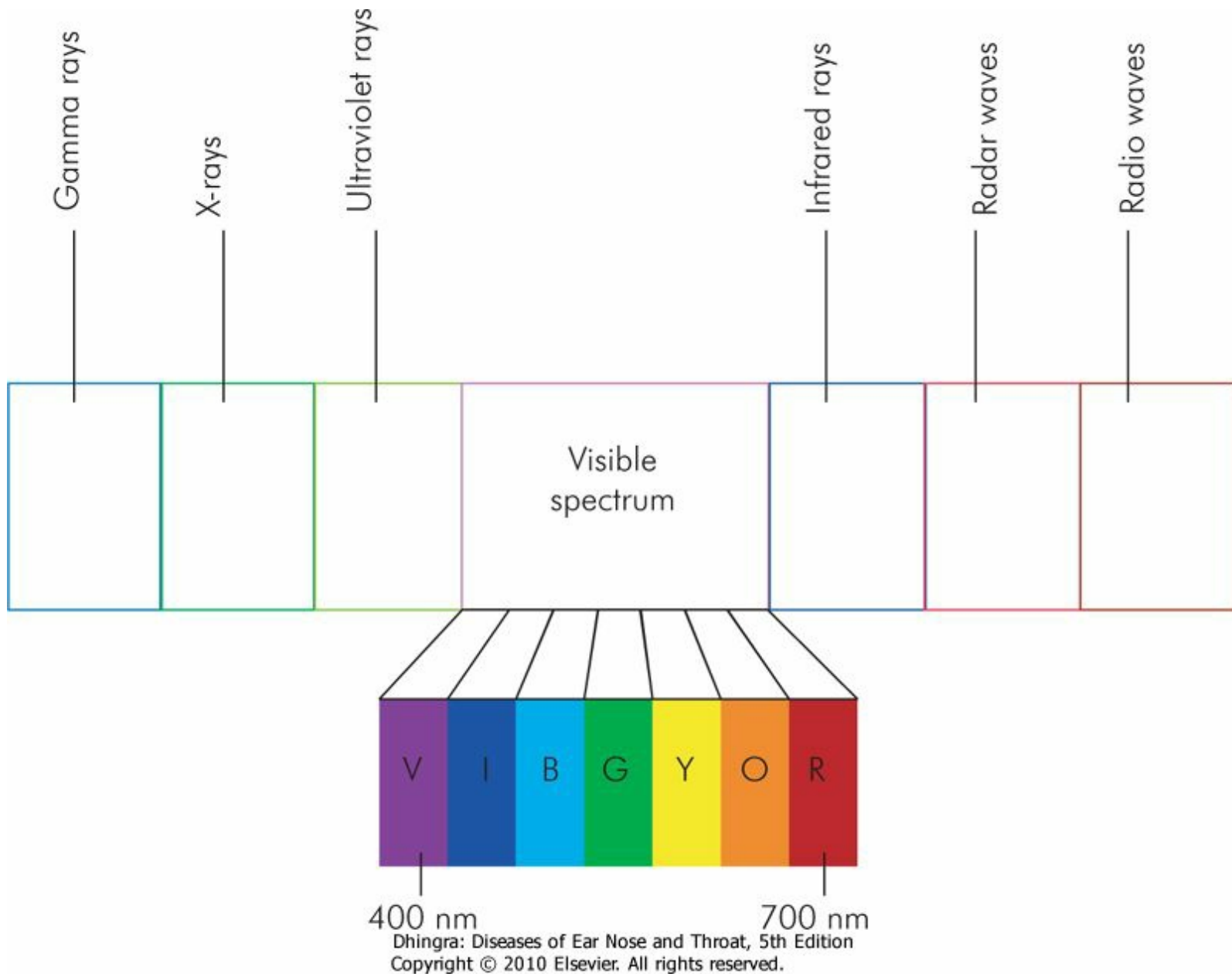


Figure 71.1 Electromagnetic spectrum.

## 3. Particle radiation

e.g. neutrons, protons or pions. They are still under investigation.

# Modes of Radiotherapy

## 1. External beam therapy or teletherapy

It uses photon or electron beams which are projected to the target area through the skin.

## 2. Brachytherapy

It uses radioactive material which are placed in close contact with the tumour tissue. The radioactive material is applied in the form of:

- **(i) Amould**
- **(ii) Interstitial implant.** Radioactive material in the form of needles, wires, ribbons or seeds, are inserted into the tumour tissue. Because of shorter half-life, they are sometimes permanently left in the tissues.
- **(iii) Intracavitary implant.** Here, radioactive material is placed in a hollow cavity next to the tumour, e.g. nasopharynx, maxillary antrum, for a specific period of minutes, hours or days.

Availability of after-loading techniques, development of safer radionuclides and computerised dosimetry have renewed the interest in brachytherapy which had been practically abandoned earlier due to hazards to radiation to the physician, nurses and other personnel.

*Advantages* of brachytherapy over external beam radiation are:

- **(a)** Greater dose can be delivered to the tumour and lesser to the surrounding normal tissues and thus better local control and fewer complications.
- **(b)** Radiation is delivered to the tumour continuously at a low dose. This is more effective than intermediate or high dose radiation in treatment of hypoxic or slowly proliferating tumours.

Brachytherapy may be used as the sole treatment of the tumour delivering a total of 70-80 Gy or it is combined with teletherapy delivering 40-50 Gy with teletherapy followed by 30-40 Gy with brachytherapy.

## 3. Intensity modulated radiation therapy (IMRT)

It is a recent development in delivery of radiotherapy and has been possible by (a) better delineation of target tissue by CT or MRI and (b) computer-controlled delivery of radiation. In this way maximum dose can be delivered to the tumour but saving important normal structures. It is a form of *conformal radiotherapy* because dose of radiation conforms to the amount of target tissue in three dimensions. In the maxillary antrum, IMRT helps to limit the dose to visual pathways, spinal cord and salivary glands. Similarly in the nasopharynx, salivary glands, skull bone and spinal cord can be protected by unnecessary irradiation thus avoiding complications.

## Sources of Radiation (Table 71.1)

Higher the energy of radiations, deeper do they penetrate. Earlier, X-ray machines produced energy in kilovolts (kV) and could be used for superficial tumours of the skin or lip. Now, machines can produce radiations of high energy in million volts (MV). They have greater penetrating power and can be used for deep-seated tumours sparing untoward effects on the skin and bone. The various sources used for radiation are:

### 1. Kilovoltage machines

They produce X-rays of 50-400 kV. They were the earliest machines used and can be divided into superficial 5-150 kV or orthovoltage 200-400 kV X-ray machines.

### 2. Cobalt 60 machine

It is the most commonly used source for head and neck cancer. It uses radioactive cobalt source which produces gamma rays of 1.17 and 1.33 MeV. The source has its natural decay time and needs replacement after every 5 years.

### 3. Linear accelerator, betatron or microtron

They are megavoltage machines which work on electricity and produce radiation of 4-25 MV. They can produce both photon or electron beams depending on whether an intervening metallic target is used in machine or not.

### 4. Radioactive material

Earlier, radium 226 was used in the form of needles but now its use has been replaced by safer radionuclides, e.g. Cesium 137 (in the form of pellets), Iridium 192 (in the form of wire), Gold 198 and Iodine 125 (in the form of seeds or grain).

### Unit of radiation

Earlier, rad (radiation absorbed dose) was the unit of radiation. Now it has been replaced by an international unit-Gray. One Gray (Gy) is equivalent to one joule of energy deposited per kilogram of material.

One Gy equals 100 rads or 100 centigrays (cGy).

Table 71.1 gives the energy range and type of radiation in different types of radiotherapy.

Table 71-1. Energy range, type of radiation in different types of radiotherapy

Types of therapy	Radiation	Voltage
Superficial therapy	X-rays	50-150 kV
Orthovoltage therapy	X-rays	200-400
Megavoltage therapy	X-rays	kV > 1MV
	γ-rays or electrons	
Low energy	X-rays electron beam	up to 6 MV
Medium energy	Same	6-15 MV
High energy	Same	>15 MV
Cobalt 60 therapy	γ-rays	1.17 or 1.33 MeV (fixed)

kV = Kilovolts, MeV = Million electron voltage, MV = Million volts

## Types of Radiotherapy (Table 71.2)

- **1. Curative radiotherapy.** Small cancerous lesions can be cured by radiotherapy alone. Surgery also gives equally good results in these cases but radiation has the advantage of preserving the function. The total dose of curative radiation in head and neck cancer ranges from 6500 to 7500 rads.
- **2. Palliative radiotherapy.** When cancer is too advanced, has distant metastases, or the condition of the patient is too poor to undergo surgery due to poor nutrition or other factors such as heart, lung, liver, or kidney disease, only palliative treatment is possible.
- **3. Combination therapy.** Radiotherapy can be combined with both surgery and chemotherapy.

### 1. Radiotherapy and Surgery

Radiotherapy can be given before or after surgery to achieve better control of disease. Each modality aims to overcome the deficiency of the other.

#### **Preoperative radiation**

##### *Advantages*

- (i) It reduces the tumour bulk making questionably respectable tumour to one that is definitely respectable.
- (ii) Oxygenation of tissues has not been tampered with and therefore the response to treatment is better.
- (iii) Lymphatics are blocked by radiation and thus dissemination of tumour cells during surgery is less.
- (iv) Eliminates microscopic spread beyond palpable tumour mass or occult metastasis to lymph nodes.

*Disadvantages.* Preoperative radiation reduces the vitality of tissues thereby delaying healing process. It also increases chances of flap necrosis, fistulae formation, carotid blow-outs in post-operative period.

#### **Postoperative radiation**

**Table 71-2. Types of radiotherapy**

1. Radiation alone  
Effective in early cases; preserves function
2. Combined surgery and radiation
  - Pre-operative radiation
  - Post-operative radiationUsed in advanced cases
3. Combined with chemotherapy  
Neoadjuvant chemoradiation
4. Palliative radiotherapy  
Massive cancers with distant metastases

##### *Advantages*

- (i) More effective, as bulk of tumour mass had been removed by surgery.
- (ii) Extent of tumour has been defined and radiation can be given to suspected areas of residual disease or areas of positive margins.
- (iii) Surgical resection is technically easier and postoperative healing better.
- (iv) There are few complication of flap necrosis and infection, if surgery is done in non-radiated tissues.

Generally, post-operative radiotherapy should be given to all cases of cancer when:

- (i) Margins or growth are reported too close or positive.
- (ii) When bone or cartilage is invaded.
- (iii) Lymph nodes show extracapsular invasion.
- (iv) Neck nodes are multiple or the size of a node is greater than 3 cm.

*Disadvantages.* After surgery, blood supply to the tissues interfered with, and the hypoxic cells will not respond well to radiation.

### 2. Radiotherapy and Chemotherapy

Chemotherapy can be used either before, during or after radiotherapy. When used *before* radiotherapy (induction chemotherapy), it reduces the bulk of tumour, while its vascularity is maintained or has been enhanced by decrease in size of the tumour. When used *concomitantly* with radiotherapy, chemotherapy acts as a radiosensitizer to improve the effect of radiation on the tumour cells. Methotrexate and bleomycin are both radiosensitizers. Concomitant chemotherapy and radiation has been used in head and neck cancers. Cells resistant to one modality may respond to the other. Chemotherapy shrinks the tumour decreasing its interstitial pressure and thus improving blood supply and oxygenation



where radiation can now work more effectively. Though chemoradiotherapy has been used in unresectable head and neck tumours, its role has been investigated in stage III or IV resectable tumours with added advantage of preservation of organ and its function, e.g. laryngeal or hypopharyngeal cancers. However, the side effects of concomitant radiation and chemotherapy are more. Chemotherapy can be used *after* radiation, but is less likely to penetrate the affected tissue due to poor blood supply.

The following points are considered when a patient is to receive radiotherapy:

- **1. Types of radiotherapy**, whether it is curative, palliative, or combination type of therapy.
- **2. Site of tumour and its lymphatic field** The primary tumour and its draining lymph nodes have to be included in the radiation field.
- **3. Extent of tumour** It can be found by clinical examination (palpation under anaesthesia is important), routine X-rays, CT scan or magnetic resonance imaging. Smaller the tumour bulk, better is the response to radiation. Field of radiation is planned according to the extent of tumour.
- **4. Histology of tumour** Tumours of lymphoid tissues are very sensitive and respond quickly. Anaplastic tumours and those of embryonal origin are also radiosensitive but recur early. Squamous carcinoma also responds well but slowly. Adenocarcinomas are less sensitive. Sarcomas and bone tumours also have low sensitivity.
- **5. Dose of radiation and fractionation** Generally, the curative dose is 6500-7500 cGy. Conventionally, it is delivered in fractions of 200 cGy per day for 5 days in a week (Mondays to Fridays) and thus it takes 6½ to 7½ weeks to complete the treatment.

**Table 71-3. Complications of radiotherapy**

Early	Late
<ol style="list-style-type: none"> <li>1. Radiation sickness (loss of appetite and nausea)</li> <li>2. Mucositis</li> <li>3. Dryness of mucous membranes</li> <li>4. Skin reactions (erythema, dry or wet desquamation)</li> <li>5. Laryngeal oedema</li> <li>6. <i>Candida</i> infections</li> <li>7. Haematopoietic suppression</li> <li>8. Acute transverse myelitis (rare)</li> </ol>	<ol style="list-style-type: none"> <li>1. Permanent xerostomia</li> <li>2. Skin changes (atrophy of skin, subcutaneous fibrosis)</li> <li>3. Decaying of teeth</li> <li>4. Osteoradionecrosis</li> <li>5. Trismus (fibrosis of TM joint and muscles)</li> <li>6. Transverse myelitis</li> <li>7. Radiation retinopathy and cataract</li> <li>8. Endocrinal deficit (thyroid, pituitary)</li> <li>9. Radiation induced malignancy (thyroid cancer, osteosarcoma of orbit)</li> </ol>

## Complications of Radiotherapy

Complications of radiotherapy depend on the site of radiation, total dose delivered and the daily fraction of radiation used. High total dose and larger daily fractions cause more complications.

Complications following radiation can be divided into early or late (Table 71.3).

# Care of Patient During Radiotherapy

## 1. Nutrition

This is particularly important in cancers of oral cavity and pharynx. Diet, rich in protein, vitamins and iron should be given. Nasogastric tube may be used where necessary. Blood transfusions may be required, if haemoglobin level is low.

## 2. Care of teeth

Any patient who is a candidate for irradiation particularly in the area of mandible should have dental evaluation and get all questionable teeth extracted before radiation. Wound must heal before radiation is started. Xerostomia adds to caries of teeth. Osteoradionecrosis of the mandible may follow extraction of teeth in an irradiated mandible.

## 3. Care of skin

Skin reactions are common with orthovoltage or electron beam therapy to skin but the modern megavoltage therapy has a skin-sparing effect. During radiotherapy, patient is advised in the care of irradiated skin. He should:

- (i) keep the area dry and avoid washing with soap and water.
- (ii) avoid exposure to sunlight.
- (iii) avoid wet shaving.
- (iv) not use adhesive plaster for dressings; it peels off the skin at the time of removal.
- (v) cover the area with soft cloth, like silk, which should provide free aeration of the skin, and
- (vi) not use abrasive dressing or clothing.

For moist desquamation, an antibiotic ointment is useful. Topical steroid creams can be used to relieve itching and pain.

## 4. Care of oral cavity

Mucositis and xerostomia are common complications. They also interfere with feeding. Patient should avoid alcohol, tobacco or highly spiced food to lessen further trauma. Irritating mouth washes which contain alcohol should not be used. Milk of magnesia can be applied to the area of mucositis to give protective coating. It also neutralises the acid pH and prevents caries of teeth. Pain and discomfort of mucositis can be relieved by use of lignocaine 10% to enable the patient to eat. Acute radiation mucositis usually persists 8-12 weeks after radiation.

## 5. Care against infection

Patients receiving radiotherapy are generally debilitated and easily develop *Candida* infection of the oral cavity and pharynx. It can be treated by topical application of nystatin or clotrimazole. Mycelia may lie protected beneath organic debris and may require antifungal systemic therapy.

## **72 Chemotherapy for Head and Neck Cancer**

Chemotherapy may be used alone or in combination with other modalities of treatment. Most of the head and neck malignancies are squamous cell cancers and the drugs found effective are methotrexate, cisplatin, bleomycin and 5-fluorouracil. Adriamycin has been used for certain non-squamous carcinomas (e.g. adenoid cystic carcinoma), and dacarbazine for melanomas. Lymphomas of the head and neck, both Hodgkin and non-Hodgkin types, are also treated by chemotherapy because of their multifocal origin and wide-spread involvement.

## Types of Chemotherapy

- **1. Palliative chemotherapy** Cytotoxic drugs, singly or in combination are used to treat advanced, recurrent or metastatic disease with an aim to relieve the symptoms and to prolong life in some of them.
- **2. Adjuvant chemotherapy** Here chemotherapy is used before, during or after treatment with other modalities.
  - When used before surgery or radiation, it is called *induction or anterior chemotherapy*. It helps to reduce tumour burden and micrometastases that can occur at the time of surgery or in the period before radiation.
  - When used simultaneously with radiotherapy, it acts as a radiosensitizer to cells which are otherwise radioresistant.
  - When used after surgery or radiation, it is called *posterior chemotherapy* and is aimed to cure micrometastases.

# Single Agent vs Multidrug Combination Therapy

Methotrexate, cisplatin, bleomycin and 5-fluorouracil have been used as single agents in various dosage forms.

**Table 72-1. Commonly used anticancer drugs and their side effects**

Drugs	Type of neoplasm	Conventional dose*	Side effects	Remarks
1. Methotrexate	Squamous cel cancer. Acute leukaemia lymphomas	40 mg/m <sup>2</sup> i.v. weekly, high dose can be given with leucovorin rescue	Bone marrow suppression mucositis of oral and G.I. mucosa. Maculopapular rash. Renal and hepatic toxicity	Excreted via urine. Hydration and alkalinisation of and urine before after drug administration reduces the risk of complications. Liver function tests before use
2. 5-Fluorouracil (5-Fu)	Squamous cell cancers. Non-squamous tumours of breast and G.I. tract	10-15 mg/kg i.v. daily. Not more than 1 g in single bolus for 4-5 days. Repeated at weekly intervals	Myelosuppression (Neutropenia thrombocytopenia at 1 to 2 weeks). Mucositis (nausea and vomiting, stomatitis and diarrhoea). Skin (alopecia, hyperpigmentation, maculopapular rash, hand-foot syndrome)	Not given in poorly nourished patients
3. Cyclophosphamide	Squamous cancer Lymphomas Leukaemia Neuroblastoma Multiple myeloma	60-120 mg/m <sup>2</sup> i.v daily × 5 days for 3 weeks	Haemorrhagic cystitis Nausea and vomiting Alopecia Neutropenia at 1-2 weeks with recovery at 2-3 weeks. Cessation of menses. Permanent infertility	Hydrate the patient well before and after drug administration. Avoid barbiturates during therapy
4. Dacarbazine	Melanoma Sarcomas	250 mg/m <sup>2</sup> × 5 days every 3 weeks	Severe nausea and vomiting Myelosuppression Flu-like symptoms (fever, malaise, myalgia) for several weeks Alopecia	
5. Bleomycin	Squamous cell cancer, Lymphoma	10-20 mg/m <sup>2</sup> once or twice weekly, i.m. or i.v.	Pneumonitis (dry cough and rales) and pulmonary fibrosis Fever and chills in first 24 h. (give antipyretics) Anaphylactic reaction Alopecia Erythema, hyperpigmentation Stomatitis	Weekly X-ray chest. Use with care in patients of pulmonary and renal disease. Do not exceed total dose of 400 units, as it causes. Pulmonary fibrosis. (1 unit = 1 mg)
6. Adriamycin (Doxorubicin)	Lymphoma Sarcomas Esthesioneuroblastomas. Salivary gland cancer Paediatric malignancy	60-90 mg/m <sup>2</sup> i.v. every 3 weeks. Cardiomyopathy if total dose exceeds (500 mg/m <sup>2</sup> )	Cardiotoxic Alopecia Stomatitis, nausea, vomiting and diarrhoea Neutropenia, thrombocytopenia which recovers by 3 weeks	Cardiotoxicity is seen in E.C.G. Urine may be red for 1-2 days
7. Actinomycin-D	Rhabdomyosarcoma	0.5 mg/m <sup>2</sup> i.v. × 5 days	Myelosuppression Nausea and vomiting Mucositis and diarrhoea Alopecia Maculopapular rash	Avoid extravasation into soft tissue at the time of injection
8. Vincristine (Oncovin)	Lymphoma Squamous cell cancer Rhabdomyosarcoma	1.5 mg/m <sup>2</sup> i.v. once or twice monthly. Single dose should not exceed 2 mg	Neurotoxic (sensory and motor neuropathy) Constipation (give stool softeners) Alopecia	Avoid extravasation into tissues
9. Cisplatin	Squamous cell cancer	80-120 mg/m <sup>2</sup> i.v. infusion every 3 weeks	G.I.T. (nausea, vomiting) Renal toxicity Haematologic (anaemia, neutropenia, thrombocytopenia) Neurologic (peripheral neuropathy) Ototoxicity (4-8 kHz)	Adequate prehydration Mannitol diuresis. Do not use drug if creatinine clearance is below 40 ml/min

\*Follow instructions given with drug literature. Most of the drugs are given according to surface area of the body which is calculated according to weight and height of a person.

They have also been used in combination with other drugs with the object to improve overall response rate and duration of response. A trend is emerging that combination of two or more drugs improves the response rate and definitely improves the quality of patient's life but it has failed to improve the duration of response.



# Drugs Used in Cancer Therapy

Commonly used anticancer drugs and their side effects are listed in Table 72.1.

## Pretreatment Work-up of the Patient

<b>1. History and clinical examination</b> (exclude kidney, heart and lung disease)	
<b>2. Haematological tests:</b>	
• Haemoglobin	(As a baseline, as many of the drugs are myelosuppressive)
• Total and differential count	
• Platelet count	
<b>3. Urine exam</b>	
<b>4. Biochemistry:</b>	
• Blood urea nitrogen	(Methotrexate and cisplatin are nephrotoxic)
• Creatinine	
• Liver function tests	
<b>5. Radiology:</b>	
X-ray chest (Bleomycin causes interstitial pulmonary fibrosis)	
CT scan or MRI where indicated	For extent of disease
Ultrasound of liver/spleen	
<b>6. Pulmonary function tests</b> (For Bleomycin)	
<b>7. E.C.G.</b> (For Adriamycin)	
<b>8. Audiogram</b> (Cisplatin causes high frequency hearing loss)	
<b>9. Nutritional status</b>	

Patient who is a candidate for cancer chemotherapy should be worked up in the following manner:

## Toxicity of Anticancer Drugs

Most of the drugs act on rapidly dividing cells and therefore include normal cells as those of hair follicles, gastrointestinal mucosa and bone marrow causing alopecia, stomatitis, nausea, vomiting, diarrhoea, anaemia, leukopenia and thrombocytopenia. Some drugs have selective action on kidney (methotrexate, cisplatin), nerves (vincristine and cisplatin), heart (adriamycin) and bladder (cyclophosphamide).

## 73 HIV Infection/AIDS and ENT Manifestations

Acquired immuno-deficiency is caused by retroviruses. Those infecting the human beings are of two types: (a) HIV Type I-which is the most common and very pathogenic and (b) HIV Type II-which is less common and less pathogenic. Once virus enters the body, it attacks T-lymphocytes and other cells which have CD4 surface marker. CD4 T-lymphocytes are normally associated with helper-inducer function of the immune system. With the fall in CD4 lymphocytes below  $500 \text{ cells/mm}^3$ , (normal  $600\text{-}1500 \text{ cells/mm}^3$ ) the immune system starts breaking down with the appearance of opportunistic infections and unusual malignancies when it is called AIDS. When CD4-cell count falls below  $200 \text{ cells/mm}^3$ , death occurs within 2-3 years.

# Modes of Transmission

HIV infection is transmitted through:

- **(a)** Sexual contact-homosexual or heterosexual.
- **(b)** Use of non-sterile needles, syringes or other skin-piercing instruments.
- **(c)** Blood and blood products.
- **(d)** Infected mother to infant-During birth, perinatally and via breast milk.

High risk groups include: (i) heterosexually promiscuous individuals (ii) homosexuals (iii) prostitutes and truck-drivers (iv) I.V. drug users (v) recipients of blood and blood products (haemophilics, thalassaemia patients and those undergoing dialysis and (vi) children born to HIV infected mothers.

Major hazard to health care workers is from blood and body fluids like amniotic, pleural, peritoneal or pericardial fluid.

Risk of acquiring infection from specimens of urine, stool, saliva, sputum, tears, sweat and vomitus is negligible.

## Epidemiology

The first case of AIDS was seen in India in the year 1986. Surveillance of HIV infection/AIDS cases was started in 1986. National AIDS Control Organisation (NACO) reports that of a total of 31,47,598 persons screened till July 1997, 66,315 were found seropositive (seropositivity of 21.07 per thousands).

States having high seropositivity rates per thousand persons are Manipur (169.62), Maharashtra (103.03), Nagaland (55.48), Punjab (43.68), and Daman and Diu (32.0). In Delhi, seropositivity rate is nearly 4 per thousand.

## AIDS Patients

Till 31st January 2003, 43,542 cases of AIDS have been reported to NACO. Table 73.1 gives the distribution of AIDS cases as reported to NACO. Maximum number of AIDS cases were detected in Tamil Nadu (18,276), followed by Maharashtra (10,797), Gujarat (2,141) and Andhra Pradesh (2,565).

Out of a total of 43,542, 84.24% were due to sexual relationship alone while nearly 3% were due to blood and blood products and 2.6% due to perinatal transmission.

After exposure, the disease runs through the following stages:

- **(a) Initial viraemia:** Primary infection with HIV, first causes viraemia which produces mild clinical disease like fever, headache, body aches and pains, macular skin rash and lymph nodes enlargement. This picture resembles infections like mononucleosis and subsides in 1-2 weeks. The virus is then taken up by lymphoid organs like lymph nodes, tonsils and adenoids. Initial plasma viraemia lasts for a few weeks and then no virus can be detected in plasma.
- **(b) Latent period:** This is the asymptomatic period and may last for a variable period, on an average 10 years. During this period no virus is detectable in plasma though it is replicating in the lymphoid tissue and CD4 T-helper cell number and function is deteriorating. Antibody test becomes positive in 2-4 months of infection.
- **(c) Advanced disease:** It starts after several years; The CD4 T-cell count falls below 200 cells/mm<sup>3</sup> and patient becomes susceptible to opportunistic infections. There are clinical signs and symptoms of AIDS and death may occur within 2 years.

Table 73-1. AIDS Cases in India (Reported to NACO)

S. no.	State/Union territory	AIDS cases	
		As on 31st July, 1997	As on 30th April, 2003
1.	Andhra Pradesh	27	2,565
2.	Assam	14	149
3.	Arunachal Pradesh	0	0
4.	Andaman & Nicobar Island	0	24
5.	Bihar	2	148
6.	Chandigarh (U.T.)		665
7.	Punjab	100	227
8.	Delhi	125	737
9.	Daman & Diu (U.T.)	1	1
10.	Dadra & Nagar Haveli	0	0
11.	Goa	12	139
13.	Gujarat	133	2,408
14.	Haryana	1	247
15.	Himachal Pradesh	9	106
16.	Karnataka	97	1,617
17.	Kerala	105	267
18.	Lakshadweep (U.T.)	0	0
19.	Madhya Pradesh	119	949
20.	Maharashtra	2,354	10,797
21.	Orissa	2	82
22.	Nagaland	4	298
23.	Manipur	276	1,238
24.	Mizoram	5	34
25.	Meghalaya	8	8
26.	Pondicherry	128	157
27.	Rajasthan	54	630
28.	Sikkim	1	6
29.	Tamil Nadu	1,080	18,276
30.	Tripura	0	5
31.	Uttar Pradesh	112	830
32.	West Bengal	57	930
	Total	4,828	43,542



# ENT Manifestations of AIDS

They are caused by opportunistic infections due to viruses, bacteria, fungi and protozoa and due to activation of the neoplastic process, e.g. Kaposi's sarcoma and non-Hodgkin's lymphoma. More than 50% of the patients with AIDS present with symptoms or signs in the head and neck region.

## **Ear**

- Otitis media
- Kaposi's sarcoma of pinna
- Sensorineural hearing loss (usually due to cytomegalovirus affecting inner ear or CN VIII)
- Facial paralysis (viral origin)

## **Nose**

- Sinusitis (due to both aerobic and anaerobic infections)
- Fungal sinusitis due to aspergillus or mucormycosis. It is rapidly invasive and extends intracranially

## **Oral cavity**

- Candida infection
- Angular cheilitis
- Recurrent aphthous ulcers
- Hairy leukoplakia (it is caused by E.B. virus and appears as white patches on the lateral border of tongue. Occurs early in HIV infection)
- Kaposi's sarcoma (can occur anywhere in the oral cavity but is most common in the palate)
- Non-Hodgkin's lymphoma

## **Parotid**

- Parotid cysts and parotitis

## **Oesophagus**

- Candida infection of oesophagus causing severe dysphagia

## **Neck**

- Cervical lymphadenopathy. It can be secondary infection, lymphoma, tuberculosis or carcinoma or Kaposi's sarcoma. FNAC or biopsy may be indicated.

Non-Hodgkin's lymphoma can occur in 10-30% of AIDS patients. It tends to be aggressive and occurs in late stages of disease when CD4 counts falls below  $200/\text{mm}^3$ . Both nodal and extranodal lymphomas may be seen. CNS lymphomas are also common in patients with AIDS.

## Kaposi's Sarcoma

It is a multicentric neoplasm which may involve skin, mucosa or viscera. There is excessive proliferation of spindle cells of vascular origin. It is non-invasive and respects the fascial planes. In the oral cavity, Kaposi's sarcoma is mostly seen in the palate, but may occur on the tongue or gingiva or the posterior wall of pharynx. It appears purplish in colour and may need to be differentiated from angioma or pyogenic granuloma. It can occur at any stage of HIV infection, even in those with normal CD4 counts. Size of the tumour may vary from a few mm to several centimetres. Diagnosis is based on biopsy which may show proliferation of spindle cells, endothelial cells, extravasation of red blood cells and haemosiderin laden macrophages. Treatment includes localised radiation, intralesional vinblastine or cryotherapy. Single agent systemic chemotherapy may be given in those with multiple lesions.

# Diagnosis of HIV Infection

- **1. ELISA test** (Enzyme-linked immunosorbent assay): It is a screening test with high sensitivity of 99.9%. When positive, it is confirmed by Western blot test.
- **2. Western blot test:** Confirmation test for HIV infection. The specificity of positive results by ELISA and Western blot reaches 100%.
- **3. Blood tests:** May indicate anaemia, leukopenia especially lymphopenia and thrombocytopenia in advanced disease.
- **4. CD4 T-cell count:** Normal count 600-1500/mm<sup>3</sup>. Falling counts indicate progression of disease. Count <200/mm<sup>3</sup> indicates risk of AIDS.  
CD4 lymphocyte percentage is more reliable than CD-4 count. Risk of progression to AIDS is high with count of ,20%.
- **5. β<sub>2</sub>-Microglobulin level:** It is indicative of macrophage-monocyte stimulation. Levels of this protein rise at seroconversion and continue to rise with progression of disease. This test is useful for prognosis.
- **6. P-24 antigen:** P-24 is core protein of the AIDS virus. Presence of this antigen indicates active HIV replication. Test is positive even prior to seroconversion.
- **7. PCR** (polymerase chain reaction): It is a quantitative test which measures viral load and thus correlates with progression of disease.

## HIV INFECTION AND HEALTH CARE WORKERS

Doctors, particularly the surgeons, nurses and laboratory staff handling the blood, blood-stained body fluids and other secretions may contract the disease as occupational hazard. They should follow the universal precautions (vide infra) considering that every sample they handle is potentially infected. The risk is due to:

- **1. Needle-stick injury.** Hollow needle (e.g. injection needle) is more dangerous than solid needle (e.g. suture needle). The risk is 1:250.
- **2. Cuts** with contaminated knife or other sharp instruments.
- **3. Exposure of open wound** to infected blood or body fluid. Entry of virus can also occur through an area of dermatitis.
- **4. Large mucous membrane exposure**, e.g. by splatter of blood, amniotic fluid, etc.
- **5. Exposure of skin** to infected blood and body fluids. Use of gloves and gown/coat is protective.

### Management of Needle-stick Injury

In case of needle-stick injury or cut, wash the area thoroughly with water and apply an antiseptic. ELISA test is done as soon as possible to establish negative baseline for worker's compensation. Test should be repeated at 6 weeks, 3 months and 6 months for any seroconversion. Zidovudine therapy for 6 weeks as soon as possible after exposure can be offered. It is shown to decrease the rate of seroconversion after needle-stick injury. However, the side effects of drug and also the fact that seroconversion can still occur in spite of drug therapy, should be borne in mind.

- Wash hands before and after patient or specimen contact.
- Handle the blood of all patients as potentially infectious.
- Wear gloves for potential contact with blood and body fluids.
- Place used syringes immediately in nearby impermeable container; DO NOT recap or manipulate needle in any way!
- Wear protective eyewear and mask if splatter with blood or body fluids is possible (e.g. bronchoscopy, oral surgery).
- Wear gowns when splash with blood or body fluids is anticipated.
- Handle all linen soiled with blood and/or body secretions as potentially infectious.
- Process all laboratory specimens as potentially infectious.
- Wear mask for TB and other respiratory organisms (HIV is not airborne).

## Antiretroviral Drugs

- **(a) Nucleoside analogues**
  - Zidovudine (AZT)
  - Didanosine (ddI)
  - Zalcitabine (ddC)
  - Stavudine (d4T)
  - Lamivudine (3TC) (reverse transcriptase inhibitor)
- **(b) Protease inhibitors**
  - Saquinavir
  - Ritonavir
  - Indinavir
- **(c) Combination of drugs**

---

page 376

page 377

## SECTION VIII Clinical Methods in ENT and Neck Masses

---

page 377

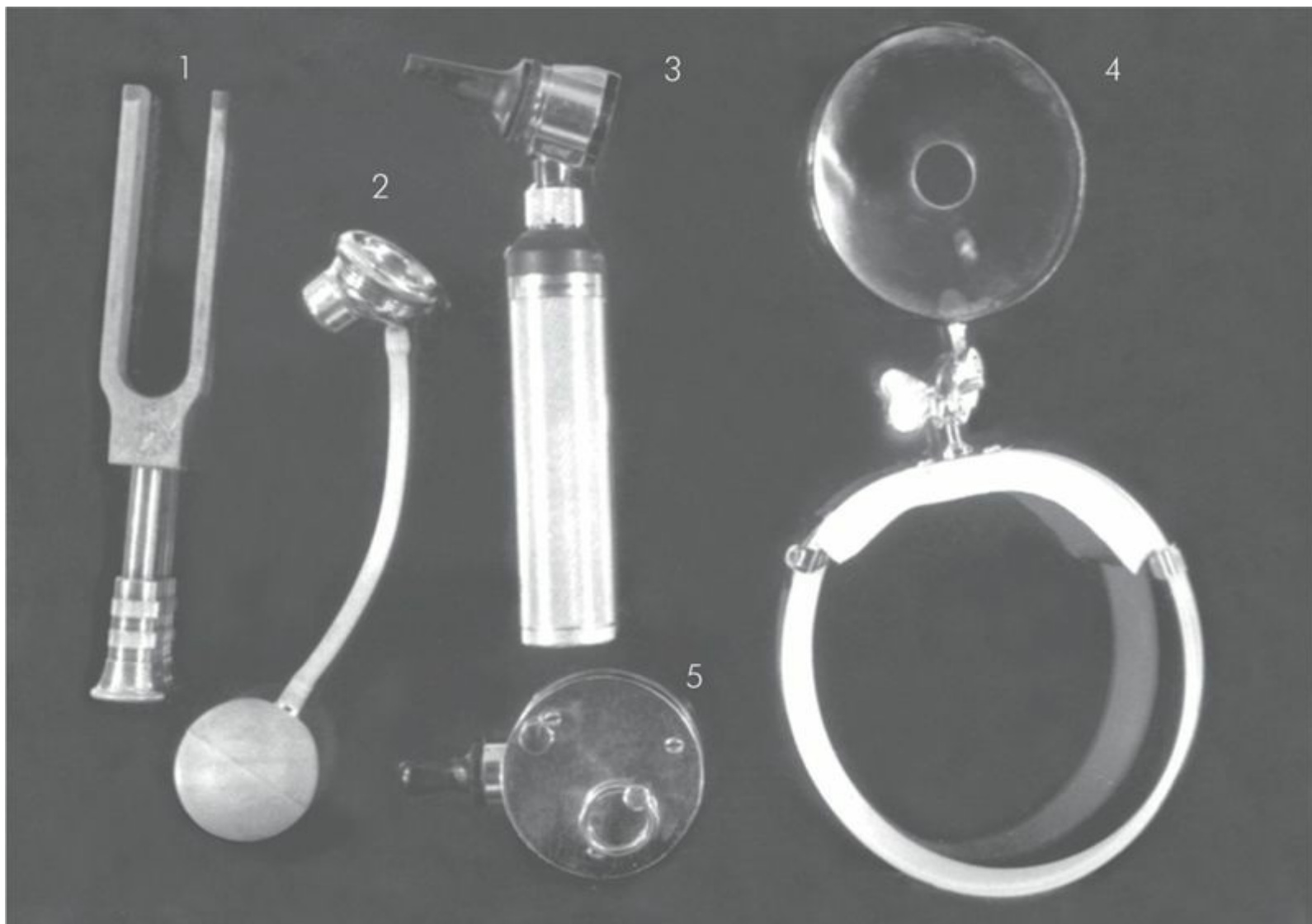
page 378

## **74 Clinical Methods in ENT**

### **EQUIPMENT, HISTORY TAKING AND GENERAL SETUP**

Evaluation of the patient with disease of ear, nose and throat requires skill in eliciting a meaningful history and masterly dexterity in the examination of darker cavities of the ear, nose, pharynx and larynx. A student is expected to learn this by regular practice in ENT clinics.





Dhingra: Diseases of Ear Nose and Throat, 5th Edition  
Copyright © 2010 Elsevier. All rights reserved.

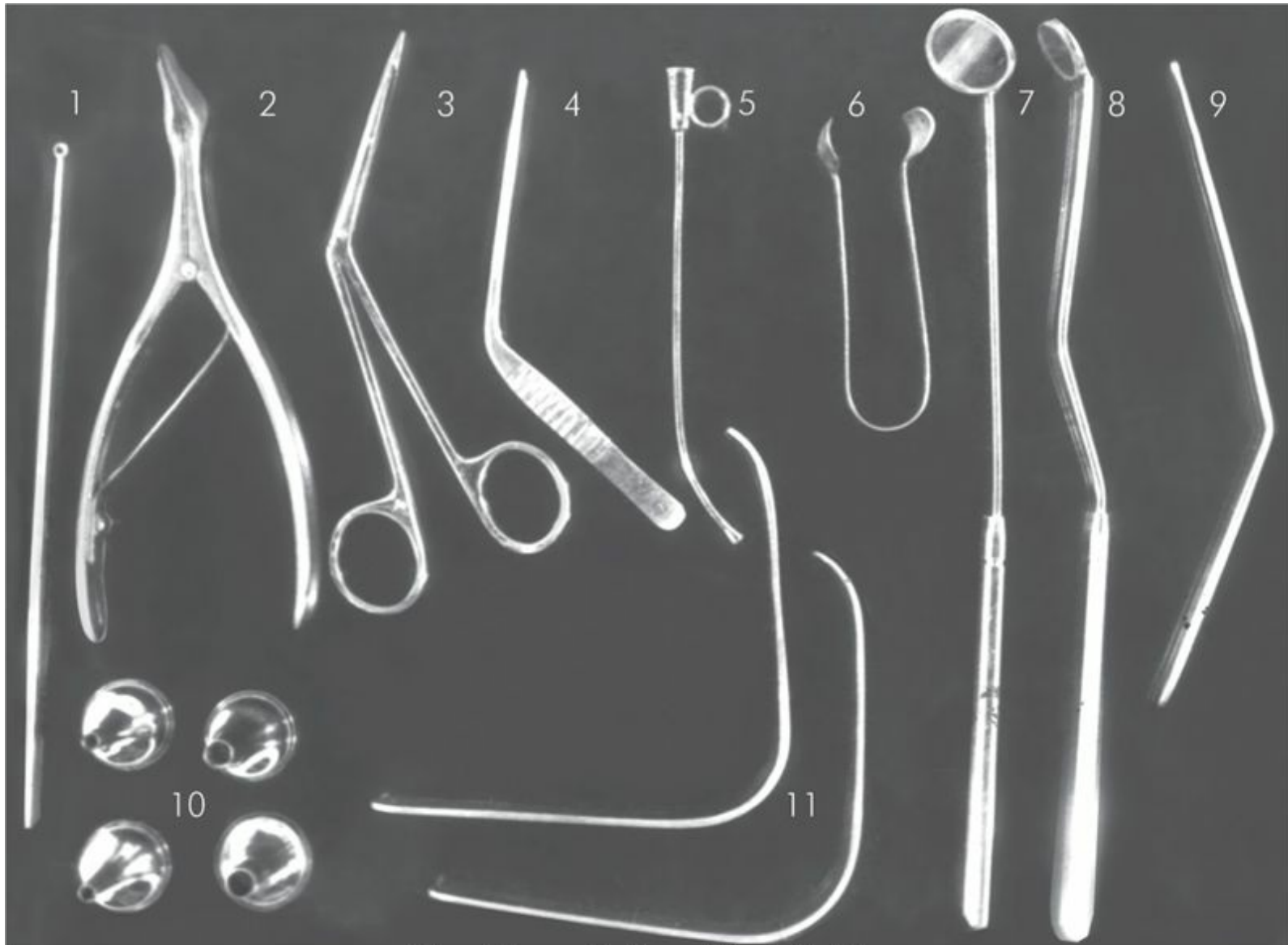
Figure 74.1A Left to right (1) Tuning fork, (2) Siegle's speculum, (3) Otoscope, (4) Head mirror, (5) Barany's noise box.

The requirements of equipment in a clinic may vary but the essential instruments for routine examination are listed here.

- **1. Bull's eye lamp.** It provides a powerful source of light. The lamp can be tilted, rotated, raised or lowered according to the needs.
- **2. Head mirror.** It is a concave mirror used to reflect light from the Bull's eye lamp onto the part being examined. It has a focal length of approximately 25 cm. The examiner sees through the hole in the centre of the mirror. Diameter of the mirror is 89 mm (3½") and that of the central hole is 19 mm (¾").
- **3. Tongue depressors.** Different sizes for children and adults should be available. It is used in the examination of oral cavity and oropharynx.
- **4. Nasal specula.** Two types are commonly used, namely the Thudicum and Vienna types. The size of the nasal speculum is selected according to the age of the patient and size of the nostril.
- **5. Laryngeal mirrors.** They are used to examine the larynx and laryngopharynx. Various sizes, from 6 to 30 mm diameter, are available. To prevent fogging, a mirror is always warmed over a spirit lamp or by dipping it in hot water and then tested on the back of hand before insertion into the mouth.
- **6. Postnasal mirror.** It is used to examine the nasopharynx and posterior part of nasal cavity. Like laryngeal mirror, it is also warmed and tested on the back of hand before use.
- **7. Ear specula.** Various sizes are available to suit different sizes of the ear canal. The largest speculum which can be conveniently inserted in the ear canal should be used.
- **8. Siegle's speculum.** Essential in examination of tympanic membrane; it gives magnified view of tympanic membrane and helps to test its mobility. It is also used to elicit the fistula sign.
- **9. Tuning forks.** Commonly used tuning fork has a frequency of 512 Hz. Forks of other frequencies, e.g. 256 and 1024 Hz should also be available.
- **10. Jobson-Horne's probe.** One end of the probe is used to form a cotton bud to clean the ear of discharge and the other end (with ring

curette) is used to remove the wax.

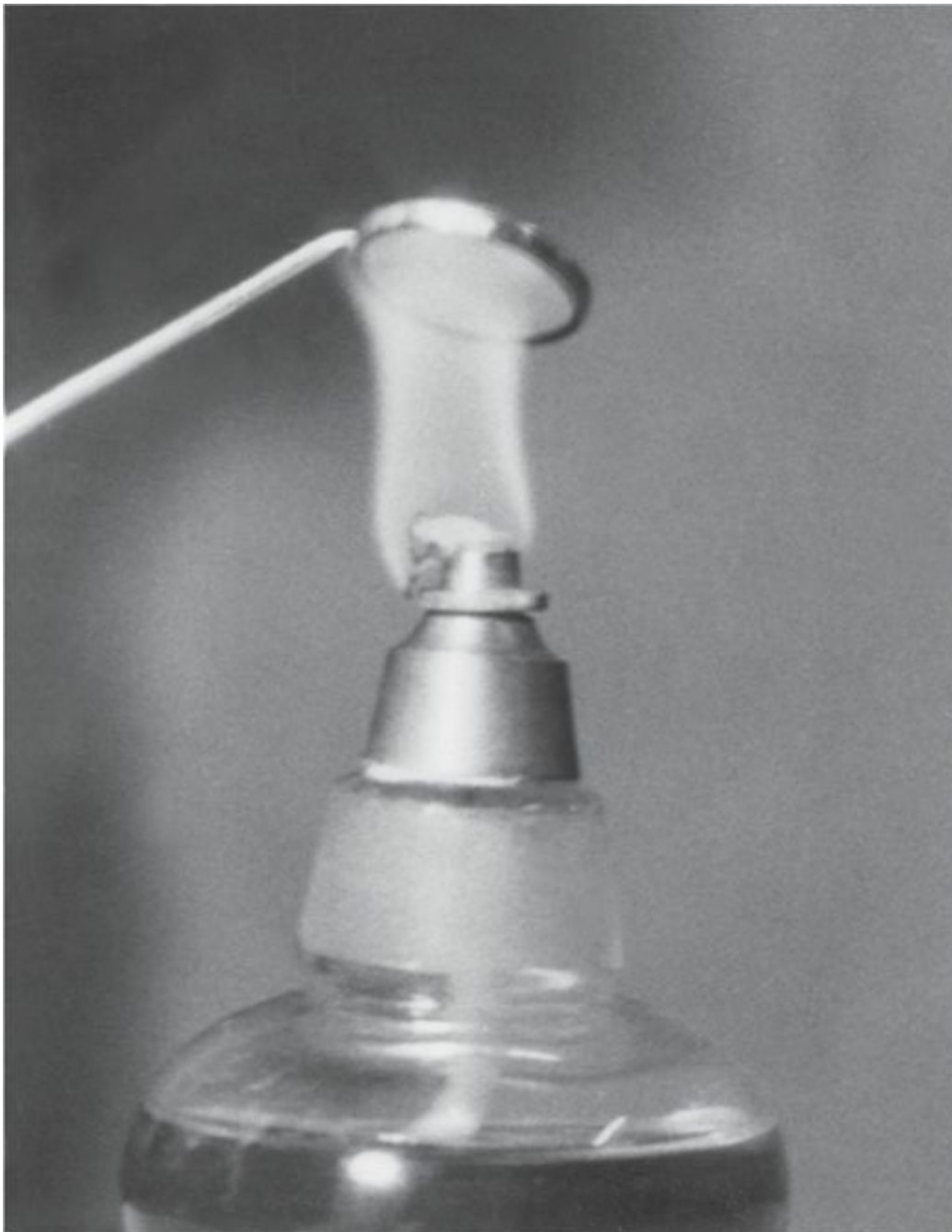
- **11. Blunt probe.** It is used for palpation in the nasal cavity or ear canal.
- **12. Tilley's or Hartman's forceps.** It is used in packing of ear canal or nasal cavity.
- **13. Eustachian catheter.** It is used to test patency of the eustachian tube and can also be used to remove foreign bodies from the nose. To test the patency of eustachian tube, the nose is first anaesthetised, the catheter is then passed along the floor of nose into the nasopharynx, turned medially and then slightly withdrawn till it engages on the posterior free border of the nasal septum. At this point, it is rotated 180° laterally to lie against the opening of eustachian tube. A bulb is attached and air insufflated. If the tube is patent, air enters the middle ear and can be detected by an auscultation tube which connects patient's ear to that of the examiner (see page 65).
- **14. Otoscope.** It is an electric or battery operated device with a magnifying glass. Sometimes it has an arrangement to attach a bulb to function as Siegle's speculum. It is useful for detailed examination of the ear. It is an essential instrument to examine the ear of an infant, a child or a bedridden patient.
- **15. Spirit lamp.** It is used to warm the laryngeal or post-nasal mirror (Fig. 74.2).
- **16. Gloves.** They are essential for intraoral palpation.
- **17. Spray.** It is used to apply local anaesthetic to abolish the gag reflex.
- **18. Suction apparatus.** To clear the ear or nose of discharge or blood for detailed examination.



Dhingra: Diseases of Ear Nose and Throat, 5th Edition  
Copyright © 2010 Elsevier. All rights reserved.

Figure 74.1B (1) Jobson-Horne probe, (2) Vienna nasal speculum, (3) Hartmann's packing forceps, (4) Wilde's packing forceps, (5) Eustachian tube catheter, (6) Thudicum nasal speculum, (7) Laryngeal mirror, (8) Post-nasal mirror, (9) Blunt probe, (10) Ear specula, (11) Lacks tongue depressor.

- **1. History of present illness.** A patient presents with certain presenting complaints. They are asked in detail, with particular reference to the duration of symptoms, their onset, progression, severity and other accompanying complaints. Inquiry should also be made of any systemic disease the patient may be suffering from, e.g. diabetes, hypertension, coronary artery disease, liver or kidney disease, or a bleeding disorder. Also find out about the treatment patient has taken or is still taking for the present ailment.
- **2. History of past illness.** It includes history of similar complaints in the past, treatment taken, history of any operation which the patient has undergone and allergy to any drug.
- **3. Personal history.** Inquire about the patient's profession and nature of job, personal habits (smoking, chewing pan or tobacco, use of alcohol) and food habits (excessive use of tea or coffee). It is also important to know about his activities, exercise, or sedentary habits.
- **4. Family history.** Some diseases have a genetic basis, e.g. otospongiosis, certain types of sensorineural hearing loss and autoimmune disorders while others are the result of close contact between different members of the family, e.g. tuberculosis, syphilis, pediculosis, scabies, etc.



Dhingra: Diseases of Ear Nose and Throat, 5th Edition  
Copyright © 2010 Elsevier. All rights reserved.

Figure 74.2 Warming a laryngeal mirror over a spirit lamp. Warm only the glass side of the mirror.

## General Setup and Position of Patient

The patient is examined in a semi-dark room. He is seated on a stool or chair opposite the examiner, and is made to sit erect leaning slightly forward towards the examiner. He should not slump in the seat. Bull's eye lamp is kept on the left at the level of his shoulder. The examiner uses a head mirror to reflect light from the Bull's eye lamp on to the area of examination.

A head mirror gives good illumination and permits freedom to use both hands for other activities. Some prefer to use a head light in place of Bull's eye lamp and a head mirror.

# I. EXAMINATION OF EAR

## Symptomatology

A patient with ear disease presents with one or more of the following complaints:

- 1. Hearing loss.
- 2. Tinnitus.
- 3. Dizziness or vertigo.
- 4. Ear discharge.
- 5. Earache.
- 6. Itching in the ear.
- 7. Deformity of the pinna.
- 8. Swelling around the ear.

The details of history of these symptoms particularly in reference to the *onset*, *duration*, *progression* and *severity* should be noted.

# Examination

It includes both physical and functional examination.

## A. Physical Examination

It includes examination of:

- 1. Pinna and the surrounding area.
- 2. External auditory canal:
  - (i) Without speculum
  - (ii) With speculum
- 3. Tympanic membrane.
- 4. Middle ear.
- 5. Mastoid.
- 6. Eustachian tube.
- 7. Facial nerve and other cranial nerves.

### 1. Pinna and the surrounding area

The pinna is examined by inspection and palpation. Both of its surfaces, the lateral and the medial, should be examined.

Look for *size* (microtia, macrotia); *shape* (abnormalities of contour, cauliflower ear); *position* (bat ear). Also look for *redness* (furuncle or abscess); *swelling* (haematoma, abscess); *vesicles in concha* and *retroauricular groove* (herpes zoster); *scars* (trauma or operation); *ulceration or neoplasm*.

page 381

page 382

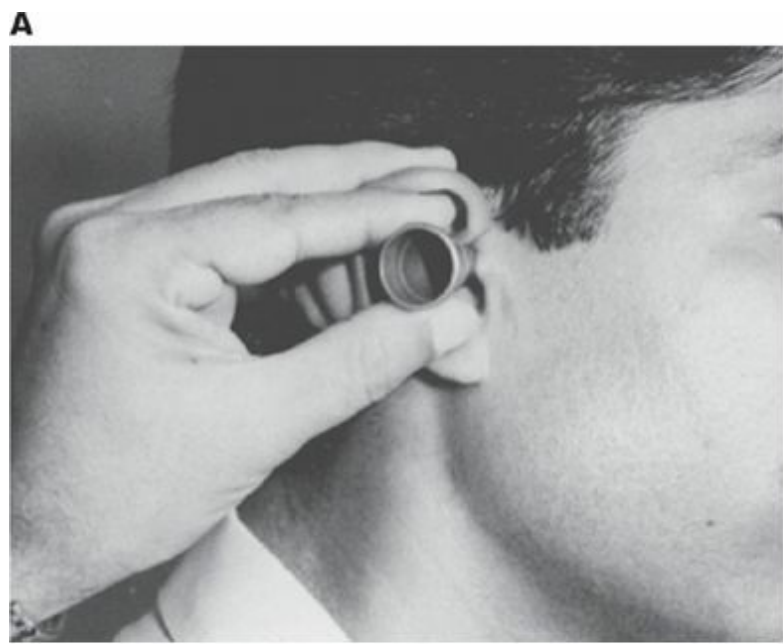
Also examine the area above, in front, below and behind the pinna and look for a *swelling* (mastoid or zygomatic abscess, neoplasm or lymph nodes); *sinus* (preauricular sinus); *fistula* (mastoid fistula) *scar* (endaural or postaural scar due to previous operation).

Palpation of pinna is essential to look for *raised temperature* (perichondritis or abscess); *thickness of tissues* (perichondritis); *fluctuation* (seroma or abscess) and *tenderness*. Movement of pinna is painful in furunculosis of the external canal.

### 2. Examination of external auditory canal

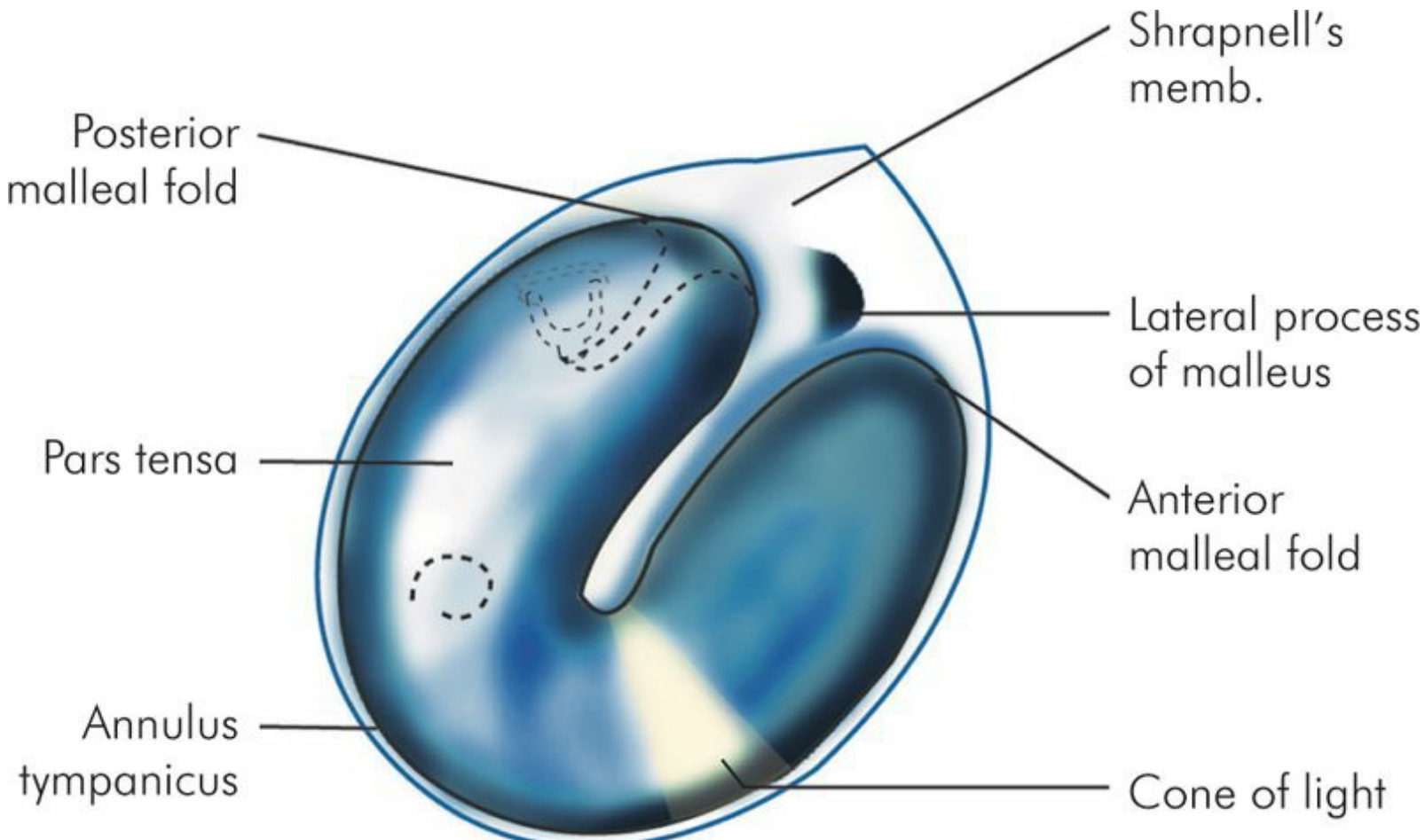
- **(a) Examination without a speculum.** This is an important part of the examination and precedes introduction of speculum. The pinna is pulled upwards and backwards while the tragus is pulled forwards to spread open the meatus. Look for the *size of meatus* (narrow or wide), *contents of lumen* (wax, debris, discharge or polyp) or *swelling of its wall* (furuncle, neoplasm).
- **(b) Examination with a speculum.** Once the size of the meatus is known, proper speculum is selected and introduced (Fig. 74.3). Use the largest speculum that can easily enter the canal. Look for wax, debris, discharge, polyp, granulations, exostosis, benign or malignant neoplasm, sagging of posterosuperior area (coalescent mastoiditis).

### 3. Examination of tympanic membrane



Dhingra: Diseases of Ear Nose and Throat, 5th Edition  
Copyright © 2010 Elsevier. All rights reserved.

Figure 74.3 Examination of ear with a speculum: (A) Right ear. (B) Left ear.



Dhingra: Diseases of Ear Nose and Throat, 5th Edition  
Copyright © 2010 Elsevier. All rights reserved.

Figure 74.4 Landmarks of a normal tympanic membrane (right side).

Normal tympanic membrane is pearly white in colour and semi-transparent, and obliquely set at the medial end of the meatus. It has two parts- pars tensa and pars flaccida, both of which should be carefully examined. Its various landmarks are shown in Fig. 74.4. A tympanic membrane is examined for:

- **(a) Colour.** Red and congested in acute otitis media, *bluish* in secretory otitis media or haemotympanum. A *chalky plaque* is seen in tympanosclerosis.
- **(b) Position.** Tympanic membrane may be retracting or bulging. General retraction is seen in tubal occlusion, retraction pockets are seen in attic or posterosuperior region and may collect epithelial flakes. Sometimes, tympanic membrane is very thin, deeply retracted and is fixed to promontory as in adhesive otitis media.  
Bulging tympanic membrane is seen in acute otitis media, haemotympanum or neoplasm of middle ear which has not yet perforated the drum.
- **(c) Surface of tympanic membrane.** It may show vesicles or bullae (herpes zoster or myringitis bullosa), a perforation (acute or chronic otitis media). A perforation may be central (in pars tensa) or attic (in pars flaccida) or marginal (at the periphery involving the annulus). A central perforation may be small, medium, subtotal or total.
- **(d) Mobility.** It is tested with a Siegle's speculum (Fig. 74.5). A normal tympanic membrane is mobile. Restricted mobility is seen in the presence of fluid or adhesions in the middle ear. An atrophic segment of tympanic membrane may be hypermobile.

#### 4. Examination of middle ear

Normally, middle ear cannot be examined directly. When tympanic membrane is semi-transparent, some structures can be seen through it. In the presence of a perforation, it is possible to know the condition of middle ear mucosa and any in-growth of squamous epithelium from the edges of the perforation.

#### 5. Examination of mastoid

Look for a *swelling* (abscess or enlarged nodes), *obliteration of retroauricular groove* (furuncle), *fistula* (burst abscess), *scar* (previous operation).

Normally, mastoid surface feels irregular on palpation. These irregularities are "ironed out" and surface feels smooth in periosteal inflammation as in subperiosteal abscess.

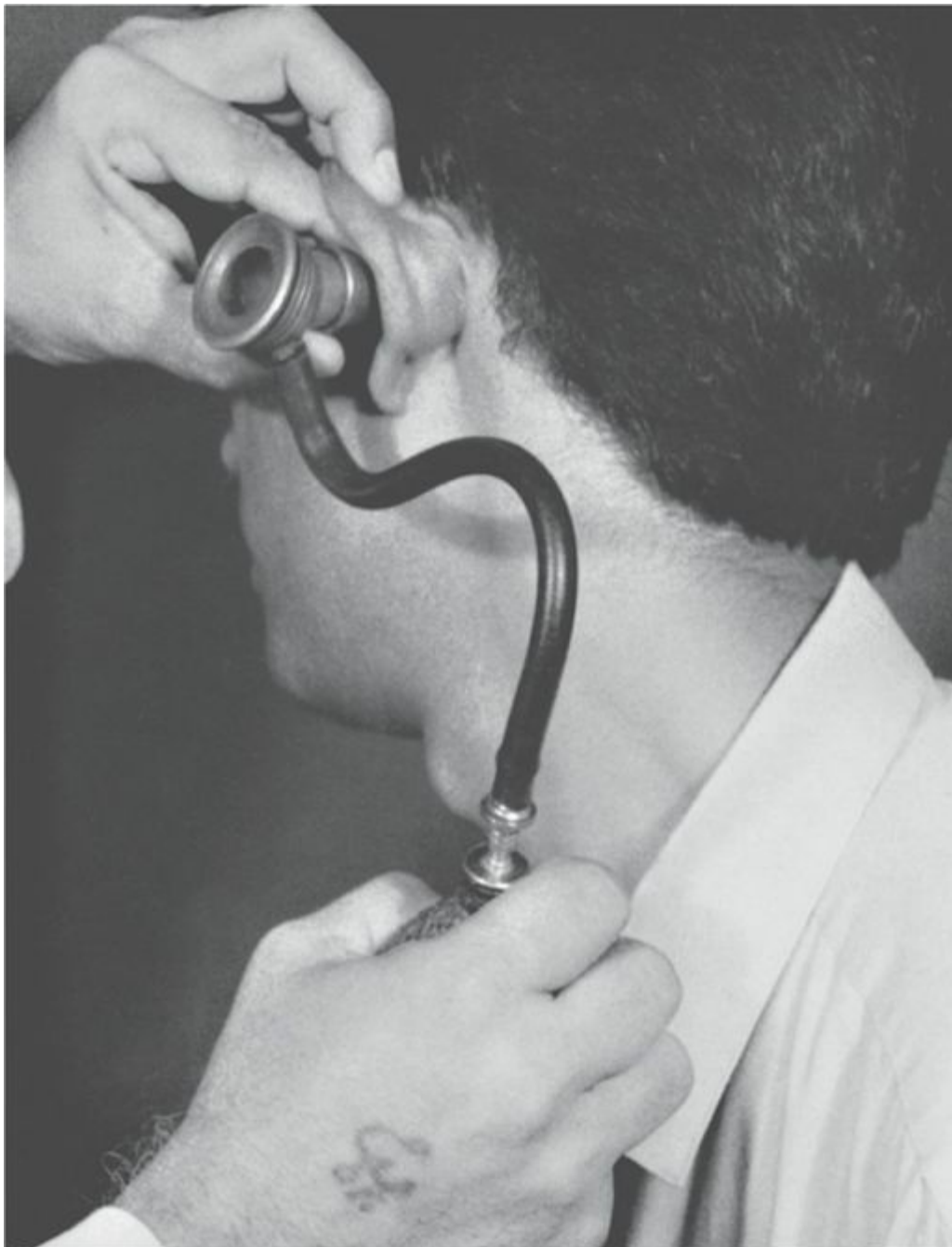
Tenderness of mastoid is seen in mastoiditis. It is elicited by pressure at three sites:

- **(a)** Over the antrum (just above and behind the meatus)
- **(b)** Over the tip
- **(c)** Over the part between the mastoid tip and mastoid antrum.

#### 6. Examination of eustachian tube

Tympanic orifice of eustachian tube can be seen in the anterior part of middle ear if there is perforation of tympanic membrane. Pharyngeal opening of tube can be seen by posterior rhinoscopy.





Dhingra: Diseases of Ear Nose and Throat, 5th Edition  
Copyright © 2010 Elsevier. All rights reserved.

Figure 74.5 Use of Siegle's speculum to see mobility of tympanic membrane.

Function of tube can be tested by Valsalva manoeuvre. In the presence of a perforation, air can be felt to escape from the ear when patient tries to blow with mouth and nose closed.

### **7. Examination of facial nerve**

Paralysis of facial nerve may co-exist with disease of the ear, e.g. acute or chronic suppurative otitis media, herpes zoster oticus, malignant otitis externa, tumours of external or middle ear and trauma. It is essential to test for facial nerve in every case of ear disease.

## **B. Functional Examination**

### **1. Auditory function**

- **(a)** Voice test
- **(b)** Tuning fork tests
  - Rinne test
  - Weber test
  - Schwabach test
  - Absolute bone conduction test.

## **2. Vestibular function**

- (a) Spontaneous nystagmus
- (b) Fistula test (page 47)
- (c) Positional tests (page 47).

## II. EXAMINATION OF NOSE AND PARANASAL SINUSES

### Symptomatology

A patient with disease of the nose and paranasal sinuses presents with one or more of the following complaints:

- **1.** Nasal obstruction.
- **2.** Nasal discharge.
- **3.** Post-nasal drip.
- **4.** Sneezing.
- **5.** Epistaxis.
- **6.** Headache or facial pain.
- **7.** Swelling or deformity.
- **8.** Disturbances of smell.
- **9.** Snoring.
- **10.** Change in voice (hyper- or hyponasality).

A detailed history of these symptoms with special regard to their onset, duration, progression, severity should be asked. They are discussed in the relevant sections of the book.

Nasal examination includes:

- 1. Examination of external nose.
- 2. Examination of vestibule.
- 3. Anterior rhinoscopy.
- 4. Posterior rhinoscopy.
- 5. Functional examination of nose.

### 1. External Nose

Examine the skin and osteocartilaginous framework of nose both by inspection and palpation.

*Skin* is examined for signs of *inflammation* (furuncle, septal abscess), *scars* (operation or trauma), *sinus* (congenital dermoid), *swelling* (dermoid or glioma) or a *neoplasm* (basal cell or squamous cell carcinoma).

*Osteocartilaginous framework* is examined for deformity, e.g. deviated or twisted nose, hump, depressed bridge, bifid or pointed tip, destruction of nose (trauma, syphilis, cancer).

Palpation of nose is done to find raised temperature, fixity of skin, thickening of soft tissues, tenderness, fluctuation or crepitation.

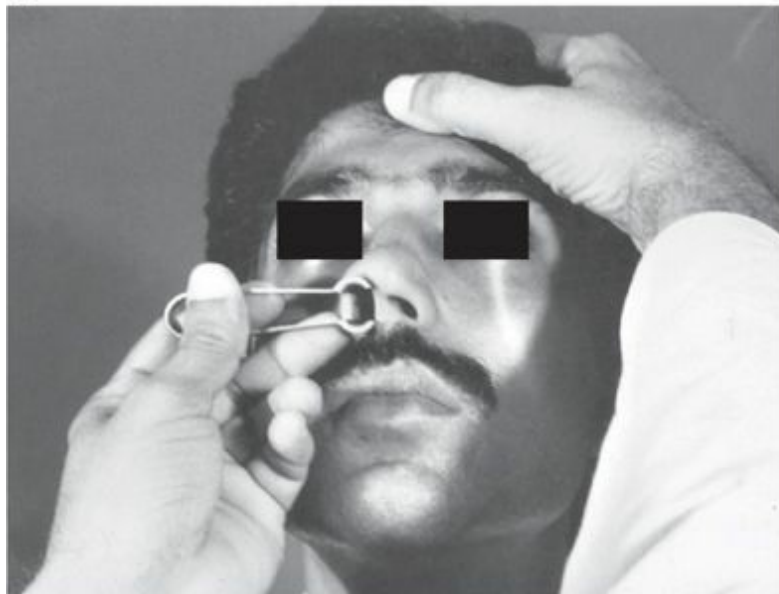
### 2. Vestibule

It is the anterior skin-lined part of nasal cavity having vibrissae and can be easily examined by tilting the tip of nose upwards. It is examined for a furuncle, a fissure (chronic rhinitis), crusting, dislocated caudal end of the septum, and tumours (cyst, papilloma or carcinoma).

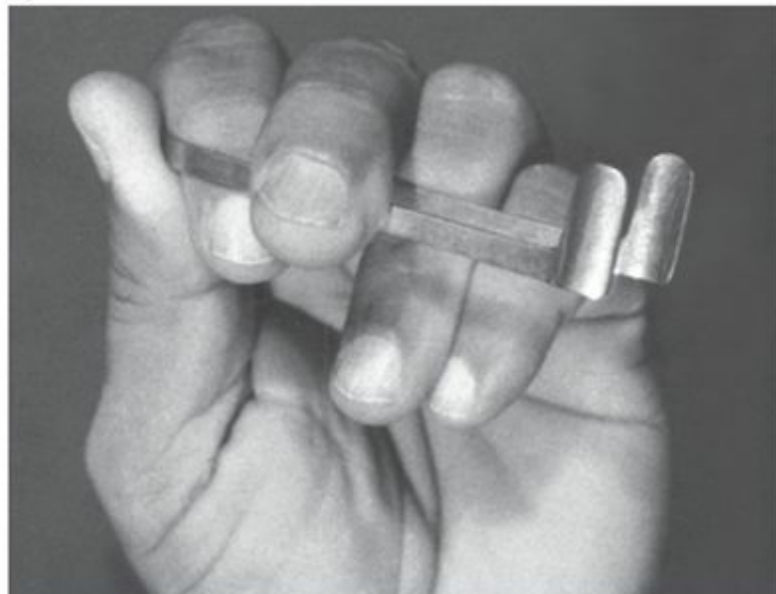
### 3. Anterior Rhinoscopy

#### Technique

**A**



**B**



Dhingra: Diseases of Ear Nose and Throat, 5th Edition  
Copyright © 2010 Elsevier. All rights reserved.

Figure 74.6 (A) Anterior rhinoscopy. (B) Technique of holding a Thudicum nasal speculum.

Patient is seated facing the examiner. A Thudicum or Vienna type of speculum is used to open the vestibule. The speculum is held in the left hand (by a right-handed person) (Fig. 74.6). It should be fully closed while introducing and partially open when removing from the nose to avoid catching the hair. Light is focussed at different sites in the nose to examine the nasal septum, roof, floor and the lateral wall. For this, patient's head may need to be tilted in different directions. Look for the following points:

- (i) *Nasal passage*. Narrow (septal deviation or hypertrophy of turbinates, growth), wide (atrophic rhinitis).
- (ii) *Septum*. Deviation or spur, ulcer, perforation, swelling (haematoma or abscess), growth (rhinosporidiosis, haemangioma).
- (iii) *Floor of nose*. Defect (cleft palate or fistula), swelling (dental cyst), neoplasm (haemangioma), or granulations (foreign body or osteitis).
- (iv) *Roof*. Usually not seen except in cases of atrophic rhinitis.

- **(v) Lateral wall.** Look at the turbinates and meatuses. Only the inferior and middle turbinates and their corresponding meatuses can be visualised. Examine the *colour of mucosa* (congested in inflammation and pale in allergy), *size of turbinates* (enlarged and swollen in hypertrophic rhinitis, small and rudimentary in atrophic rhinitis), *discharge* (discharge in the middle meatus indicates infection of maxillary, frontal or anterior ethmoidal sinuses), *mass* (polyp, rhinosporidiosis, carcinoma). A probe test should be done. It ascertains the site of attachment, consistency, mobility and sensitiveness of the mass. Attachment of the mass is found by passing the probe on all its surfaces. Bleeding during probing indicates vascular nature of the mass.

## 4. Posterior Rhinoscopy

### **Technique**

Patient sits facing the examiner, opens his mouth and breathes quietly from the mouth. The examiner depresses the tongue with a tongue depressor and introduces posterior rhinoscopic mirror which has been warmed and tested on the back of hand (Fig. 74.7). The mirror is held like a pen and carried behind the soft palate. Without touching it on the posterior third of tongue to avoid gag reflex, light from the head mirror is focussed on the rhinoscopic mirror which further illuminates the part to be examined. Patient's relaxation is important so that soft palate does not contract.

Structures normally seen on post-rhinoscopy are shown in Figure 74.8. Look for the following:

- **(i)** Choanal polyp or atresia.
- **(ii)** Hypertrophy of posterior ends of inferior turbinates.
- **(iii)** Discharge in the middle meatus. It is seen in infections of maxillary, frontal or ethmoidal sinuses. Discharge above the middle turbinate indicates infection of the posterior ethmoid or the sphenoid sinuses.

## 5. Functional Examination of Nose

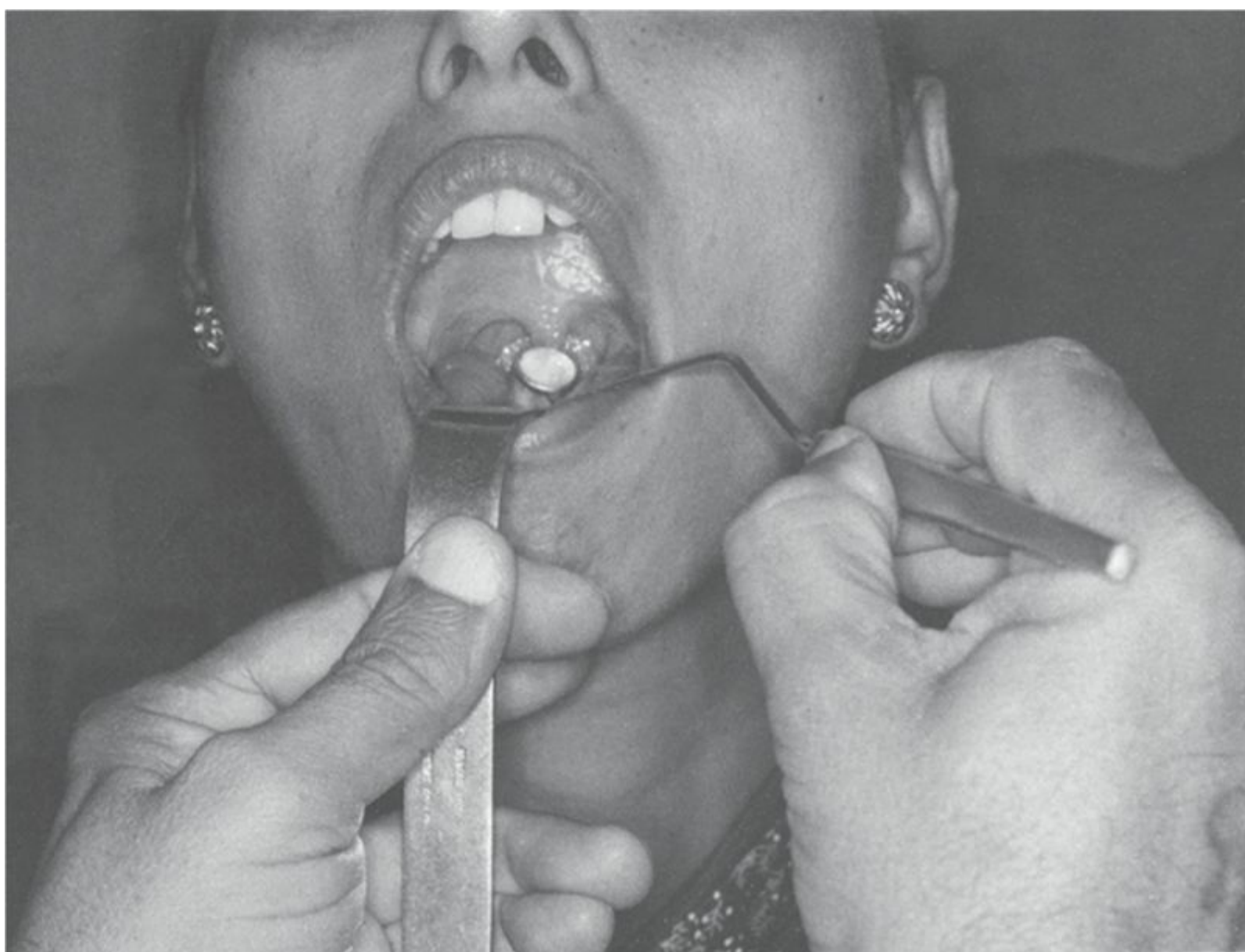
Test for patency of the nose and sense of smell.

### **Patency of nose**

(i) *Spatula test*: A clean cold tongue depressor is held below the nostrils to look for the area of mist formation, when patient exhales (Fig. 74.9), the two sides are compared.

(ii) *Cotton-wool test*: A fluff of cotton is held against each nostril and its movements are noticed when patient inhales or exhales.

### **Sense of smell**



Dhingra: Diseases of Ear Nose and Throat, 5th Edition  
Copyright © 2010 Elsevier. All rights reserved.

Figure 74.7 Technique of posterior rhinoscopy.

A simple test is to ask the patient to identify the smell of a solution or substance held before the nostril while keeping the eyes closed. Each nostril is tested separately. Common substances used are the clove oil, peppermint, coffee, and essence of rose. Ammonia stimulates the fibres of CN V and is not used to test the sense of smell.

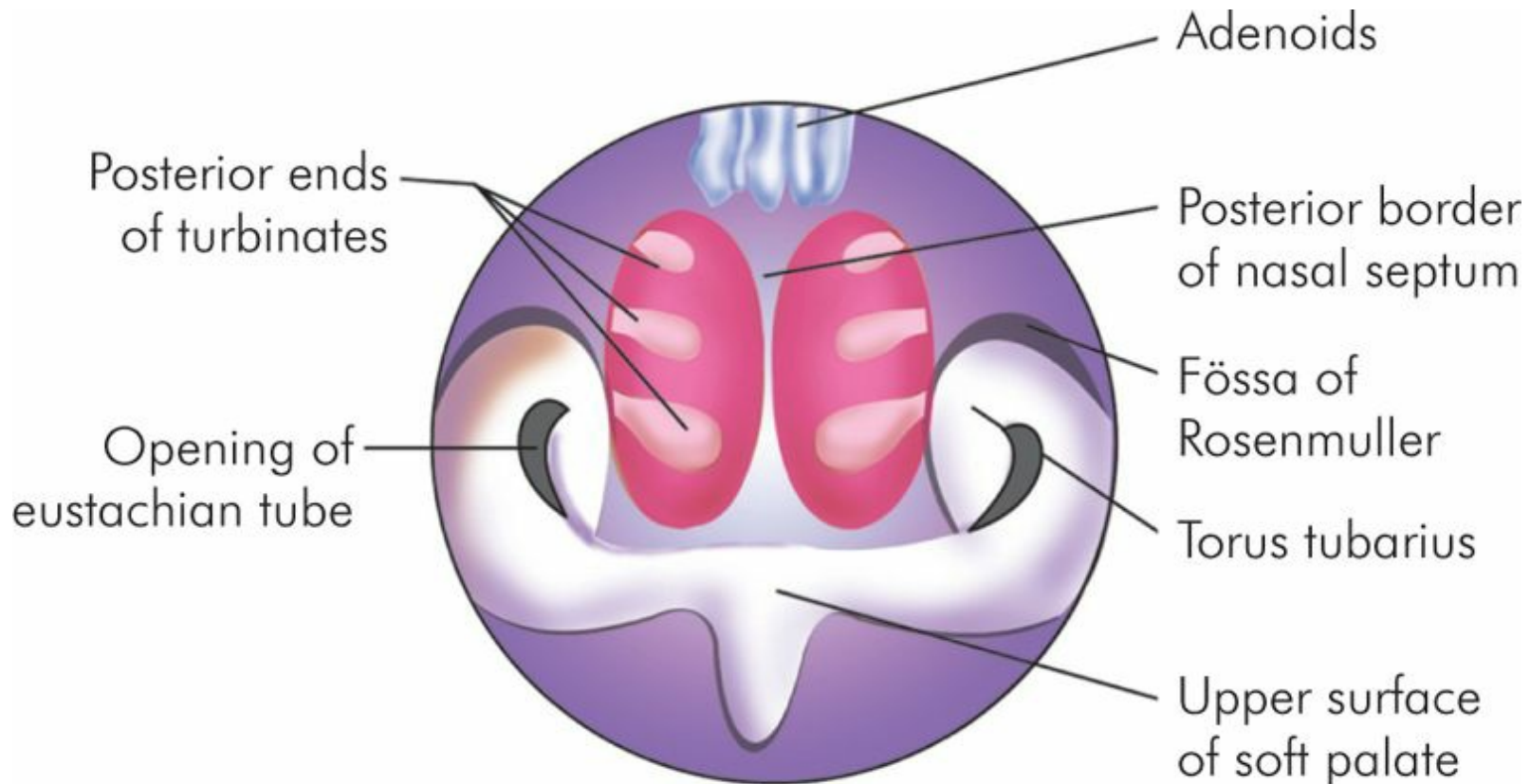
## B. Examination of Paranasal Sinuses

- 1. Maxillary sinus
- 2. Frontal sinus
- 3. Ethmoid sinuses
- 4. Sphenoid sinus

### 1. Maxillary Sinus

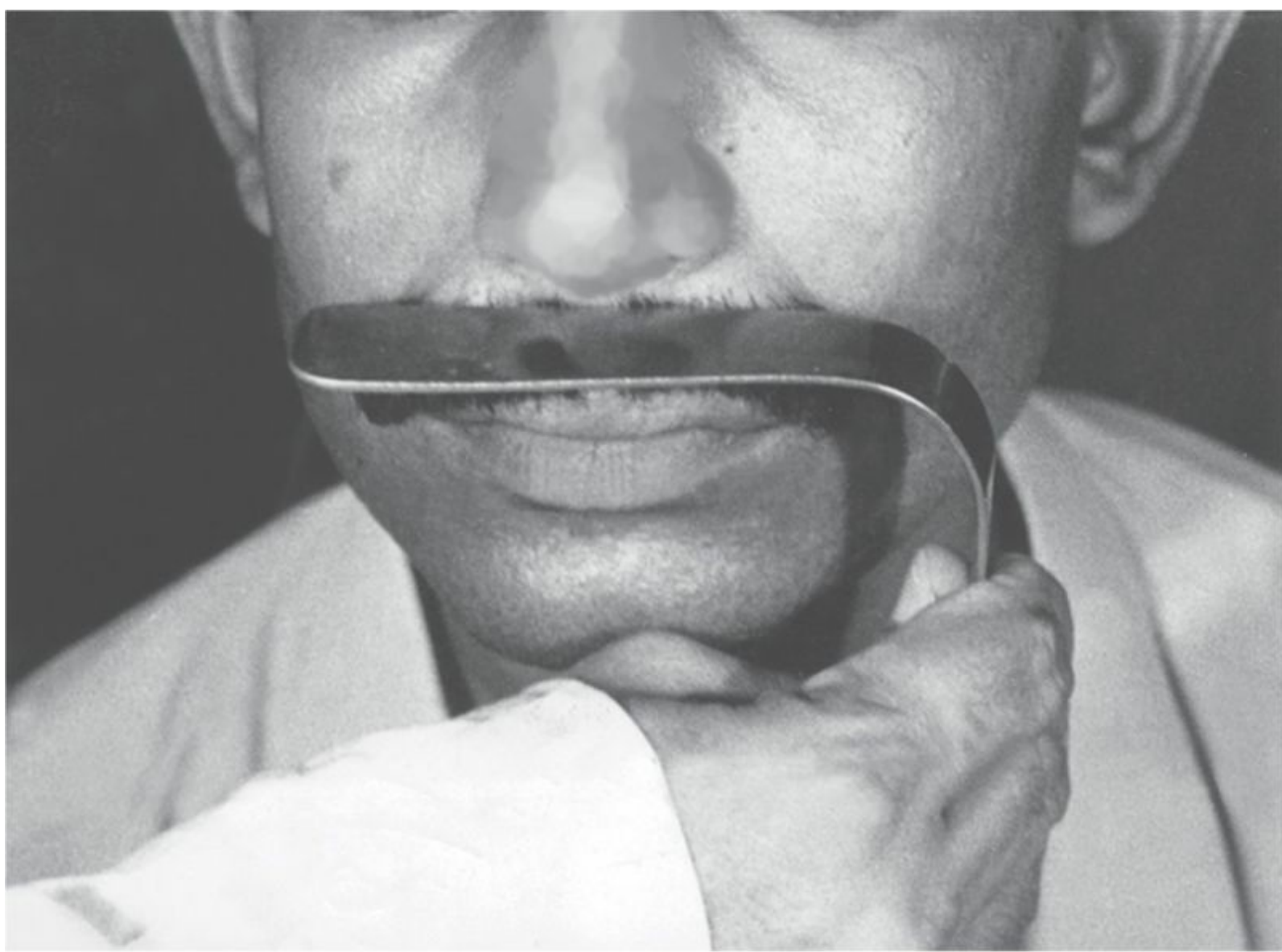
It is examined by inspection, palpation and trans-illumination.

Maxillary sinus has five walls and except for the posterior, all other walls can be examined directly.



Dhingra: Diseases of Ear Nose and Throat, 5th Edition  
Copyright © 2010 Elsevier. All rights reserved.

Figure 74.8 Structures seen on posterior rhinoscopy .



Dhingra: Diseases of Ear Nose and Throat, 5th Edition  
Copyright © 2010 Elsevier. All rights reserved.

Figure 74.9 Testing the patency of nose. Note the area of mist formation on the tongue depressor when patient exhales from nose.

page 385

page 386

Examine:

- (i) the soft tissues of cheek, lip, lower eye lid and the molar region,
- (ii) the orbit and its contents, and the vision,
- (iii) the vestibule of mouth by everting the lip,
- (iv) upper alveolus, teeth and palate,
- (v) the nose by anterior and posterior rhinoscopy,
- (vi) tenderness by pressure over the canine fossa (Fig. 74.10).

Transillumination of maxillary sinus is done by placing a specially made light source centrally in the mouth and closing the lips. Normally, a crescent of light in the inferior fornix and glow in the pupil, equally bright on both sides, can be seen. In the presence of pus, thickened mucosa or a neoplasm, the affected side does not transmit light. This test has limited value and has practically been abandoned in favour of X-rays.

## 2. Frontal Sinus

It is also examined by inspection, palpation and trans-illumination.

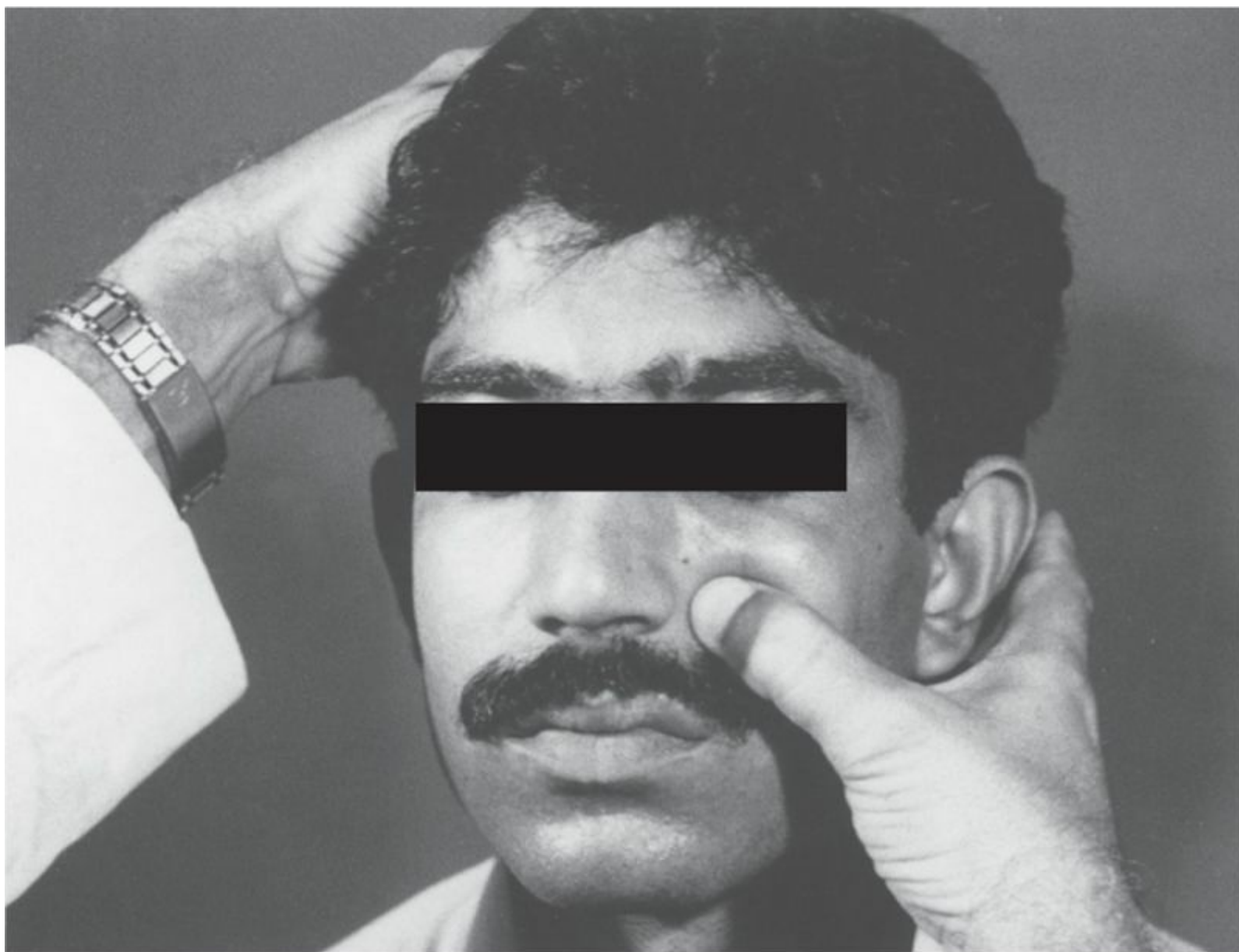
Frontal sinus has three walls, anterior, posterior and floor. Only the anterior wall and floor lend themselves to external examination.

### (a) External examination

For this, examine the forehead, root of nose, orbital margins, the orbit and its contents. Look for redness, swelling, fistula, proptosis, and displacement of the eye balls.



Tenderness of the frontal sinus can be elicited by pressure or percussion with a finger on its anterior wall above the medial part of eyebrow, or by pressing upwards on its floor above the medial canthus (Fig. 74.11).



Dhingra: Diseases of Ear Nose and Throat, 5th Edition  
Copyright © 2010 Elsevier. All rights reserved.

Figure 74.10 Testing for tenderness of maxillary sinus by pressure on the canine fossa.

### **(b) Examination of nose**

Nose should be examined by anterior as well as posterior rhinoscopy for evidence of discharge in the middle meatus and for any neoplasm.

Transillumination is done by placing a small light source in the superomedial angle of the orbit and observing the transmission of light from the anterior wall of the sinus. It is compared on both sides. Transillumination of frontal sinus is of limited value and has practically been abandoned in favour of X-rays.

## **3. Ethmoid Sinuses**

They are divided into two groups, the anterior and posterior. The former drains below the middle turbinate and the latter above it. They are examined by inspection and palpation.

### **(a) External examination**

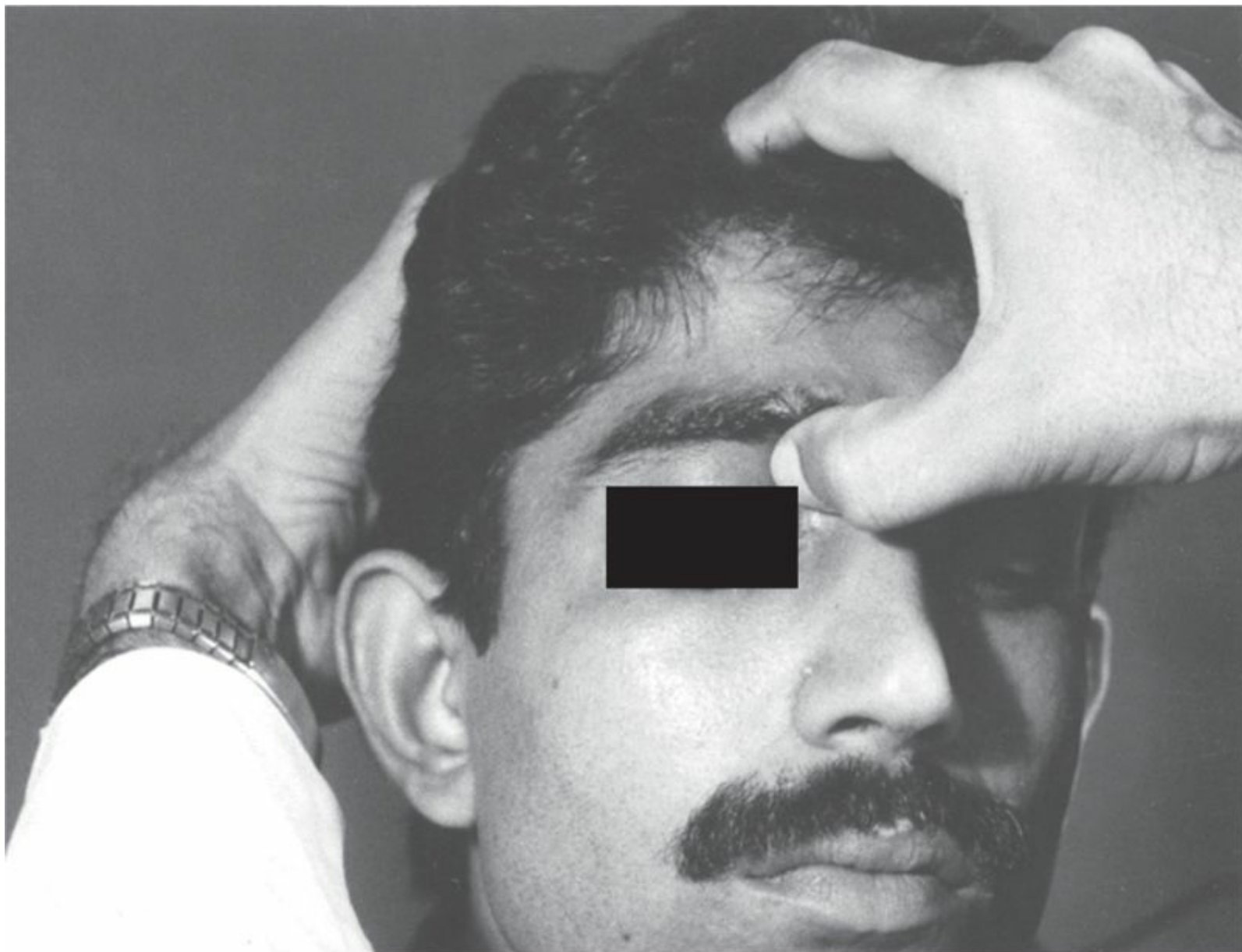
of ethmoid sinuses includes examination of orbit, upper and lower eye lids, root of nose, eye ball and vision.

Tenderness can be elicited only in the anterior ethmoid sinuses. This is done by gentle pressure applied on the medial wall of orbit just behind the root of nose. The area is tender in acute ethmoiditis.

**(b) Nasal examination**

Anterior rhinoscopy may reveal pus, polypi, or growth in the middle meatus (anterior group of ethmoid sinuses) or between the middle turbinate and the septum (posterior group of ethmoid sinuses). Probe test should be done to find the consistency, attachment and friability of the mass.

Posterior rhinoscopy may reveal pus or growth, below or above the middle turbinate.



Dhingra: Diseases of Ear Nose and Throat, 5th Edition  
Copyright © 2010 Elsevier. All rights reserved.

Figure 74.11 Testing for tenderness of frontal sinus.

#### **4. Sphenoid Sinus**

Sphenoid sinus lies deep and is not easy to examine directly. Sometimes, its anterior wall can be seen in atrophic rhinitis or in marked deviation of the septum to the opposite side.

**(a) Anterior rhinoscopy**

Sphenoid sinus opens in the sphenoethmoidal recess. Attention should therefore be paid to the findings in the olfactory fissure near the roof of nose. It may show discharge, crusts, polyp or growth. A probe can be used to palpate the mass.

**(b) Posterior rhinoscopy**

It may reveal pus in the nasopharynx or the choana, above the middle or superior turbinate. A growth or a polyp may also be seen.

### III. EXAMINATION OF NASOPHARYNX

#### Symptomatology

A patient with disease of nasopharynx presents with:

- 1. Nasal obstruction.
- 2. Post-nasal discharge.
- 3. Epistaxis.
- 4. Deafness (tubal block).
- 5. Cranial nerve palsies.
- 6. Enlargement of lymph nodes in the neck.

A detailed history of these symptoms regarding their onset, duration, progression and severity should be asked. (They have been discussed in the relevant sections.)

# Examination

Clinical examination of nasopharynx includes:

- 1. Anterior rhinoscopy.
- 2. Posterior rhinoscopy.
- 3. Other methods.
  - (a) Digital examination
  - (b) Endoscopy
  - (c) Retraction of soft palate with catheters and mirror examination
- 4. Cranial nerves.
- 5. Cervical lymph nodes.

## 1. Anterior Rhinoscopy

It is possible to see only a small part of the nasopharynx on anterior rhinoscopy. The view can be facilitated by decongestion of nasal and turbinal mucosa with vasoconstrictors.

## 2. Posterior Rhinoscopy

The technique is described on page 385. Structures to be examined are:

- (a) *Anterior wall*. Posterior border of nasal septum, choanae, posterior ends of turbinates and their meatuses.
- (b) *Lateral walls*. Torus tubarius, opening of eustachian tube, pharyngeal recess.
- (c) *Floor*. Upper surface of soft palate.
- (d) *Roof of posterior wall*.

Only a small part of nasopharynx can be seen in the mirror at one time. The examiner tilts the mirror in different directions to see all the walls of the nasopharynx, and then mentally reconstitutes the entire picture.

*Abnormal findings* in the nasopharynx include:

- (a) **Discharge** It may be seen below the middle turbinate (anterior group of sinuses) or above the middle turbinate (posterior group of sinuses).
- (b) **Crusting** Atrophic rhinitis or nasopharyngitis.
- (c) **Mass**
  - (i) Smooth pale mass-antrochoanal polyp
  - (ii) Pink lobulated mass-angiofibroma
  - (iii) Irregular bleeding mass-carcinoma
  - (iv) Smooth swelling in the roof-Thornwaldt's cyst or abscess
  - (v) Irregular mass with radiating folds-adenoids
  - (vi) Irregular mass filling the lower part of choana-mulberry hypertrophy of inferior turbinate.
- (d) **Bleeding** Due to posterior nasal or nasopharyngeal pathology.

## 3. Other Methods

### (a) Digital examination

It is a quick method to examine the nasopharynx by palpation but is uncomfortable for the patient. The examiner stands behind and to the right of the patient, invaginates patient's cheek with his left finger and inserts right index finger behind the soft palate into the nasopharynx. He first examines the posterior border of the nasal septum, then the choana, lateral wall and finally the posterior wall of nasopharynx. Adenoids, antrochoanal polyp and other masses in the nasopharynx can be examined. Avoid this examination if angiofibroma is suspected.

### (b) Endoscopy

A rigid nasal endoscope is passed through the nose after local anaesthesia and decongestion of nasal mucosa. It gives a bright and magnified view of the nasopharyngeal structures. Using endoscopes with different angles of view, it is possible to examine structures situated at an angle. Flexible nasopharyngoscope can also be used. It is also passed through the nose and gives a magnified view.

### (c) Retraction of soft palate with catheters and mirror examination

This method is reserved for difficult cases where view of nasopharynx is not obtained by other methods. It requires good local or general anaesthesia.

A soft rubber catheter is passed through each nostril and recovered from the oropharynx. Both ends of catheter are held together and clamped. In

this way, soft palate is retracted forwards. Now a mirror can be introduced and the nasopharynx examined.

#### **4. Examination of Cranial Nerves**

Malignancy of nasopharynx can involve any of the CN II to XII, more often CN IX, X and XI.

#### **5. Examination of Cervical Lymph Nodes**

It is not unusual for nasopharyngeal malignancy to present primarily as a lymph node mass in the neck. Lymph nodes commonly involved are upper internal jugular and those along the accessory nerve in the posterior triangle of the neck.

## **IV. EXAMINATION OF ORAL CAVITY**

Oral cavity extends from the lips to the level of anterior tonsillar pillars. Structures included in it are:

- 1. Lips.
- 2. Buccal mucosa.
- 3. Gums and teeth.
- 4. Hard palate.
- 5. Anterior two-thirds of tongue.
- 6. Floor of mouth.
- 7. Retromolar trigone.

# Symptomatology

A patient with disease of the oral cavity may present with one or more of the following complaints:

1. *Pain*. It may be localised to a particular site in the oral cavity, e.g. tooth, tongue, buccal mucosa, floor of mouth, etc. Sometimes, pain is referred to the ear from pathology in the oral cavity.
2. *Disturbance of salivation*. Xerostomia (dryness of mouth) can result from mouth breathing, irradiation or generalised disease of the salivary glands. Excessive salivation can result from ulcers of mouth and pharynx, poor orodental hygiene, ill-fitting denture, and iodide therapy.
3. *Disturbance of taste*. Sweet, sour and salt tastes are appreciated by taste buds on the anterior two-thirds of tongue. Patient may complain of unilateral or bilateral loss of taste, diminished or perverted taste. Lesions in these cases may be local on the tongue, e.g. heavily coated tongue, or injury to chorda tympani or the facial nerve.
4. *Trismus*. There are several causes of trismus but the important ones related to the oral cavity include ulcerative lesions, dental abscess, trauma to mandible or maxilla, and malignant lesions of tongue, buccal mucosa and retromolar trigone that have infiltrated deeply.
5. *Lesion or oral cavity*. Patient can easily see several parts of his oral cavity in the mirror and present with an abnormal growth, coating of tongue, a cleft (lip or palate) or a fistula (oroantral). It is not unusual for some patients of cancerphobia to fix their attention on the circumvallate papillae as cancer.

# Examination

Examine in seriatim the following structures:

## 1. Lips

Examine both the lips-the upper and lower, by inspection and palpation. Each lip has an outer (cutaneous), an inner (mucosal) surface and a vermilion border. Look for any swellings, vesicles, ulcers, crusts, scars, unilateral or bilateral clefts.

## 2. Buccal Mucosa

It can be examined by asking the patient to open the mouth and by retracting the cheek with a tongue depressor. Examine the mucosa of cheek and vestibule of mouth. Look for:

- (i) Change in colour
- (ii) Change in surface appearance, e.g. ulceration, vesicles or bullae (pemphigus), white stria (lichen planus), blanched appearance with submucosal scars (submucous fibrosis), leukoplakia, erythroplakia, pigmentation, atrophic change in mucosa, swelling or growth. Opening of parotid duct is seen opposite the upper 2nd molar tooth. It may be red and swollen with secretions flowing through it on massage of parotid gland (viral or suppurative parotitis).

## 3. Gums and Teeth

Examine the gums and teeth in both the upper and lower jaws. Outer surface of gums is examined by retracting the cheeks and lips and the inner surface by pushing the tongue away with a tongue depressor.

(i) Red and swollen gums	: Gingivitis
(ii) Ulcerated gums covered with a membrane	: Viral ulcers or Vincent's infections
(iii) Hyperplasia	: Pregnancy or dilantin therapy
(iv) Growths	: Benign or malignant neoplasms
(v) Loose teeth	: Maxillary or mandibular growth, periodontitis
(vi) Carious infected tooth or teeth	: Cause of maxillary sinusitis if upper, and Ludwig's angina, if lower
(vii) Malocclusion	: Fractures of mandible or of teeth maxilla, abnormalities of temporomandibular joint.

## 4. Hard Palate

Look for:

(i) Cleft palate	: Congenital
(ii) Oronasal fistula	: Trauma or syphilis
(iii) High-arched palate	: Mouth breathers
(iv) Bulge	: Tumours of palate, nose or antrum
(v) Bony growth in midline	: Torus palatinus
(vi) Mass or ulcer	: Cancer

## 5. Tongue

Only oral tongue (anterior two-thirds) is included in the oral cavity. First, examine the tongue in its natural position and then ask the patient to protrude it, move it to the right and left and then up. Examine the tip, dorsum, lateral borders and undersurface.

- (i) Large size: Macroglossia, haemangioma, lymphangioma, cretinism, oedema or abscess.
- (ii) Inability to protrude: Congenital ankyloglossia, cancer tongue or floor of mouth, painful ulcer, abscess.
- (iii) Deviation on protrusion: Paralysis CN XII on the side of deviation.
- (iv) Bald tongue: Iron-deficiency anaemia, median rhomboid glossitis (single patch in midline on the dorsum), geographical tongue.
- (v) Fissures: Congenital (Melkersson's syndrome), syphilitic. A single nonhealing fissure may be malignant.
- (vi) Ulcers: Aphthous traumatic (jagged tooth or denture), malignant, syphilitic or tubercular.
- (vii) White thick patch or plaque: Leukoplakia.
- (viii) Proliferative growth: Malignancy.

## 6. Floor of Mouth

Examine anterior part which lies under the tongue and two lateral gutters. Lateral gutters are better examined by two tongue depressors; one retracting the tongue, and the other, the cheek.



Opening of the submandibular duct is seen as a raised papilla on either side of the frenulum.

- **(i)** Short frenulum: Congenital ankyloglossia (i.e. tongue-tie).
- **(ii)** Scar: Trauma or corrosive burn.
- **(iii)** Ulcer: Trauma, erosion of submandibular duct stone, aphthous ulcer, malignancy.
- **(iv)** Swelling: Ranula, sublingual dermoid, calculus of submandibular duct, benign or malignant tumours, Ludwig's angina.

## **7. Retromolar Trigone**

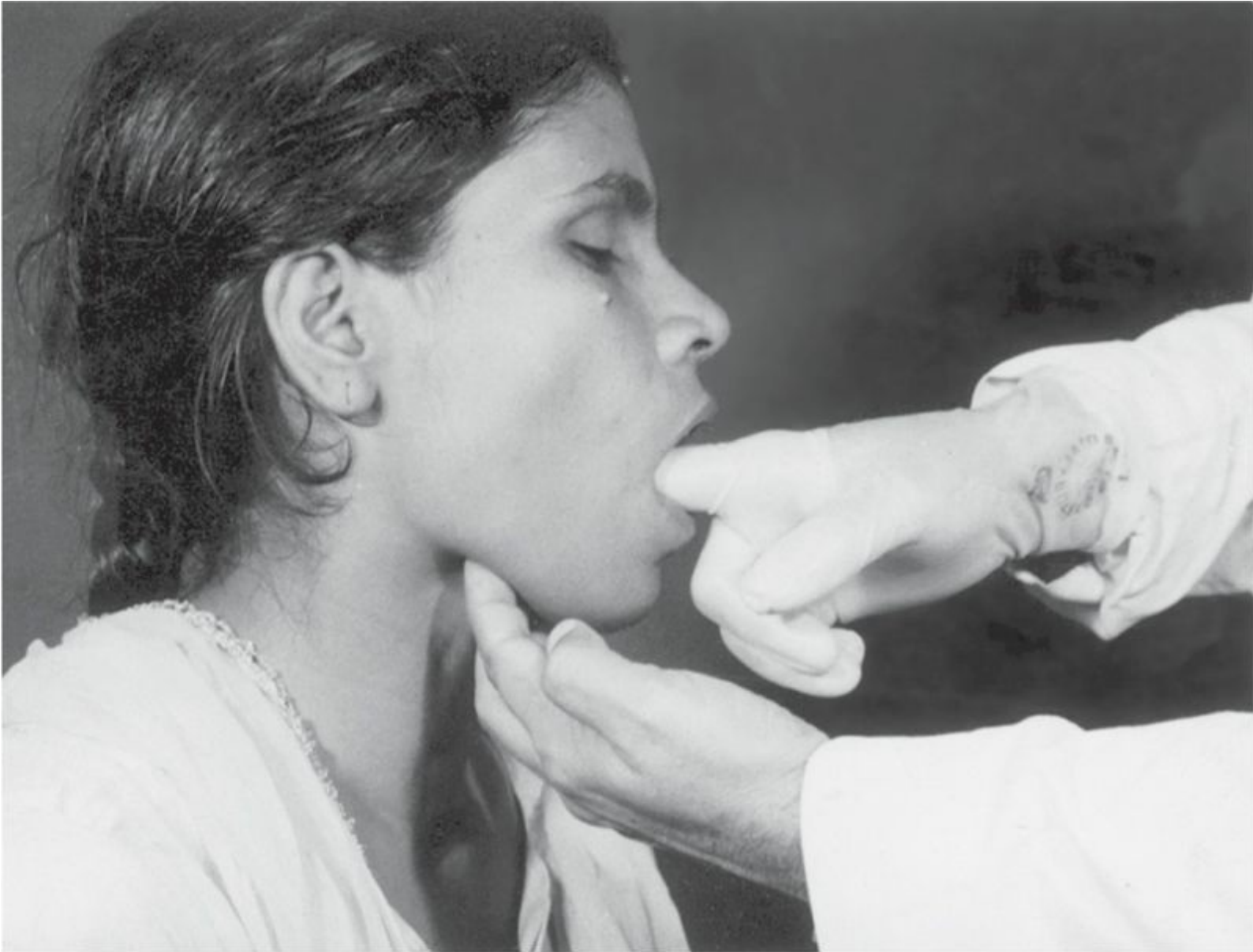Look for the inflammation due to impaction of last molar tooth or a malignant lesion of this area.

## Palpation

All lesions of the oral cavity, particularly of the tongue, floor of mouth, cheek, lip and palate, must be palpated. A swelling in the floor of mouth should be examined by bimanual palpation, to differentiate a swelling of submandibular (Fig. 74.12) salivary gland from that of submandibular lymph nodes.

## V. EXAMINATION OF OROPHARYNX

Oropharynx lies opposite the oral cavity. It starts at the level of anterior pillars and is bounded above by the junction of hard and soft palate and below by the V-shaped row of circumvallate papillae.



Dhingra: Diseases of Ear Nose and Throat, 5th Edition  
Copyright © 2010 Elsevier. All rights reserved.

Figure 74.12 Palpation of oral cavity .

Structures included in it are:

- 1. Tonsils and pillars
- 2. Soft palate
- 3. Base of tongue
- 4. Posterior pharyngeal wall

# Symptomatology

A disease of the oropharynx can disturb swallowing, phonation, respiration and hearing. A patient with disease of oropharynx presents with one or more of the following complaints:

- **1. Sore throat.** Acute or chronic tonsillitis, pharyngitis, ulcerative lesions of pharynx, etc.
- **2. Odynophagia** (painful swallowing). Ulcers, peritonsillar or retropharyngeal abscess, lingual tonsillitis, etc.
- **3. Dysphagia** (difficulty in swallowing). Tonsillar enlargements; parapharyngeal tumour; benign or malignant disease of tonsils, base of tongue or posterior pharyngeal wall; paralysis of soft palate; globus hystericus.
- **4. Change in voice.** Paralysis of palate causes hypernasality. Space-occupying lesions of the oropharynx cause muffled or hot-potato voice.
- **5. Earache.** Benign ulcers or malignant lesions of the base of tongue, tonsil, pillars and palate cause referred pain in the ipsilateral ear.
- **6. Snoring.** Large tonsils and other oropharyngeal lesions may obstruct respiration and cause snoring or sleep apnoea syndrome.
- **7. Halitosis** (bad smell from the mouth). In the oropharynx, cause may be infected tonsils, post-nasal discharge or malignancy.
- **8. Hearing loss.** A conductive hearing loss due to disturbance of eustachian tube function can result from enlarged tonsils (which interfere with movements of soft palate), cleft palate, submucous palate, palatal paralysis, recurrent pharyngitis or tonsillitis.
- **9. Abnormal appearance.** A patient may notice an abnormal finding while looking at his throat in the mirror and then consult the doctor. It is not unusual for patient to be concerned about hypertrophic circumvallate papillae and have fear of cancer.

# Examination

First, examine the oropharynx by asking the patient to open the mouth widely. Tongue depressor is used when this preliminary examination is unsatisfactory, or when it is required to displace the tongue to one side to examine tonsillo-lingual sulcus, or to press on the tonsils to look for the contents of tonsillar crypts. The base of tongue is examined by laryngeal mirror. Following structures of oropharynx are carefully examined.

## 1. Tonsils and Pillars

### (a) Tonsils

- (i) *Presence*: Look for presence or absence of tonsils.
- (ii) *Size*: Large and obstructive, small or embedded.
- (iii) *Symmetry*: Unilateral or bilateral enlargement.
- (iv) *Crypts*: White or yellow spots at the openings of crypts (follicular tonsillitis), white excrescences not easily wiped off (keratosis).
- (v) *Membrane*: Diphtheria, Vincent's angina, membranous tonsillitis, etc.
- (vi) *Ulcer*: Cancer, Vincent's angina, tuberculosis, ulcerating tonsillolith.
- (vii) *Mass*: Cystic (retention cyst), pedunculated or sessile solid mass (papilloma, fibroma), proliferative growth (cancer).
- (viii) *Bulge*: Peritonsillitis, parapharyngeal abscess, parapharyngeal tumour.

Pressure on the anterior pillar with the edge of tongue depressor may express cheesy material from the crypts (normal) or frank fluid pus (septic tonsil).

Palpation of the tonsil with a gloved finger is essential to know the consistency of the mass (hard in malignancy or tonsillolith), pulsation in tonsillar area (internal carotid artery aneurysm), palpation for an elongated styloid process.

### (b) Pillars

Uniform congestion of the pillars, tonsils and pharyngeal mucosa is seen in acute tonsillitis. Congestion of only the pillars may be a sign of chronic tonsillitis. Ulceration or proliferative growth may be an extension of malignancy from the tonsil base of tongue or the retromolar trigone.

## 2. Soft Palate

Look for redness (peritonsillitis), bulge or swelling. Normally, uvula is the midline. It becomes oedematous and displaced to the opposite side in peritonsillar abscess. Note movements of soft palate when the patient says "Aa". Deviation of the uvula and soft palate to the healthy side is a sign of vagal paralysis. This may be associated with paralysis of posterior pharyngeal wall which shows a "curtain effect" (the paralysed side moves like a sliding curtain to the healthy side).

A bifid uvula may be a sign of submucous cleft palate. In such cases, a notch can be palpated in the hard palate at its junction with soft palate in the midline.

## 3. Posterior Pharyngeal Wall

It can be seen directly. Look for lymphoid nodules (granular pharyngitis), purulent discharge trickling down the posterior pharyngeal wall (sinusitis), hypertrophy of lateral pharyngeal bands just behind the posterior pillars (chronic sinusitis), thin glazed mucosa and crusting (atrophic pharyngitis).

page 390

page 391

## 4. Base of Tongue and Valleculae

Posterior one-third of tongue forms the base of tongue and lies between the V-shaped row of circumvallate papillae and the valleculae. Valleculae are two shallow depressions which lie between the base of tongue and the epiglottis.

Base of tongue and valleculae are best examined by indirect laryngoscopy and finger palpation.

### (a) Indirect laryngoscopy

Look for the colour of mucosa (normal or congested); prominent veins, varicosities at the base of tongue or lingual thyroid, ulceration (malignancy, tuberculosis or syphilis), solid swelling (lingual tonsil, lingual thyroid, lymphoma, carcinoma base of tongue), cystic swelling (vallecular cyst, dermoid or thyroglossal cyst).

### (b) Palpation of base of tongue

It should never be omitted. Extent of tumour which infiltrates deeper into the tongue is better appreciated by palpation than by inspection. If the patient fails to relax sufficiently, palpation should be done under general anaesthesia. When palpating any structure in the oropharynx in a child, the examiner should invaginate the patient's cheek between his teeth with finger of the opposite hand to prevent biting on the examiner's finger.

## VI. EXAMINATION OF LARYNX AND LARYNGOPHARYNX

### Symptomatology

A patient with disease of the larynx presents with one or more of the following complaints:

- 1. *Disorders of voice*, e.g. hoarseness, aphonia, puberphonia or easy-fatiguability of voice.
- 2. *Respiratory obstruction*.
- 3. *Cough and expectoration*.
- 4. *Repeated clearing of throat* (chronic laryngitis, benign or malignant tumours of larynx).
- 5. *Pain in throat* (ulcerative lesions of larynx, perichondritis of laryngeal cartilages, arthritis of laryngeal joints).
- 6. *Dysphagia* (epiglottitis, aspiration of secretions due to laryngeal paralysis).
- 7. *Mass in the neck* (cervical nodes, direct extension of growth, laryngocele).

# Examination

Clinical examination of larynx includes:

- 1. External examination of larynx.
- 2. Indirect laryngoscopy.
- 3. Flexible or rigid fibre-optic endoscopy.
- 4. Assessment of voice.
- 5. Assessment of cervical lymph nodes.

## 1. External Examination of Larynx

Both inspection and palpation are employed.

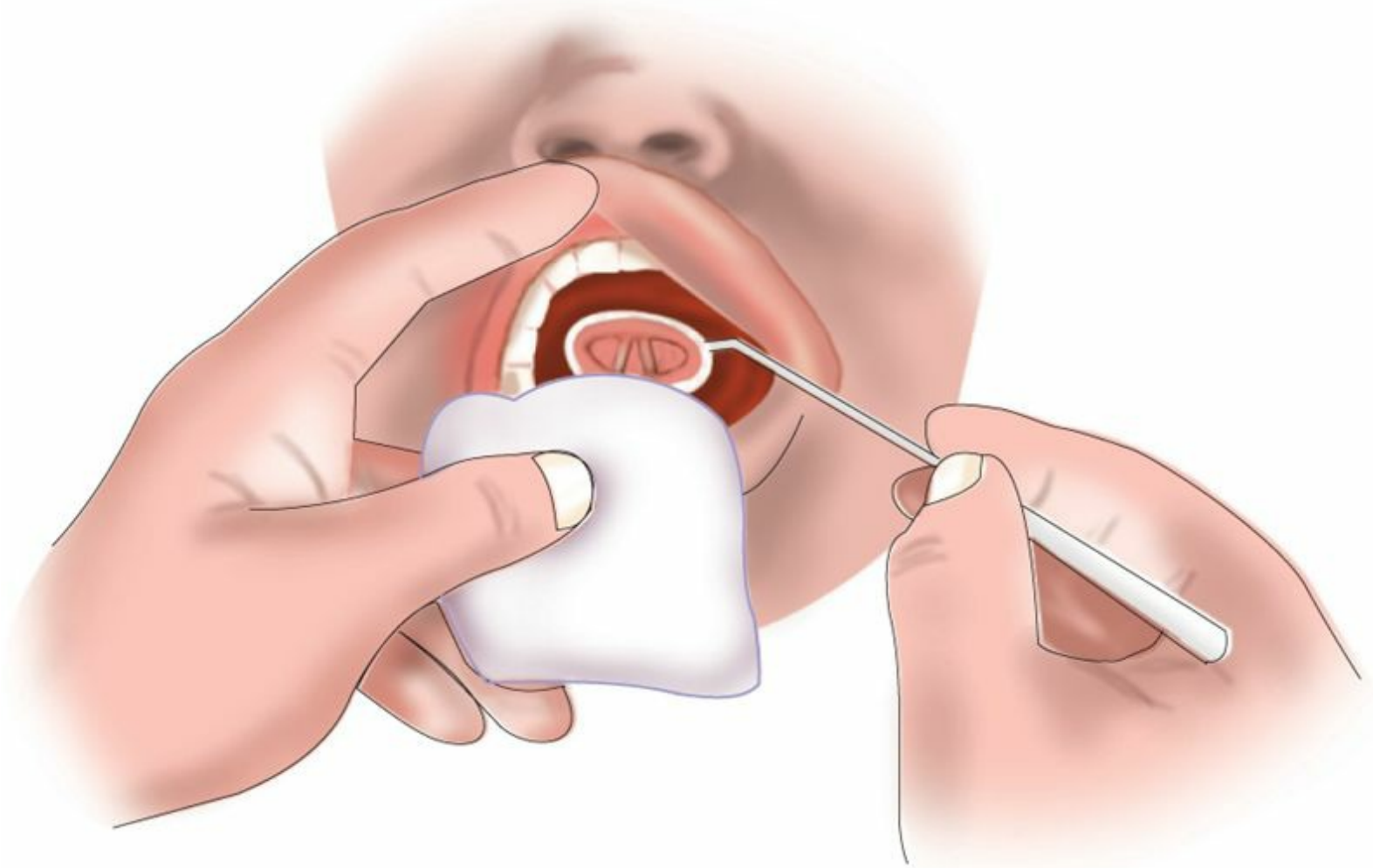
Look for:

- (i) *Redness of skin* (abscess, perichondritis)
- (ii) *Bulge or swelling* (extension of growth or enlarged lymph nodes)
- (iii) *Widening of larynx* (growth of pyriform fossa)
- (iv) *Surgical emphysema* (accidental or surgical trauma)
- (v) *Change in contour or displacement of laryngeal structures* (trauma or neoplasm). Palpate the hyoid bone, thyroid cartilage, thyroid notch, cricoid cartilage, and the tracheal rings.
- (vi) *Movements of larynx*. Normally, larynx moves with deglutition. It can also be moved from side to side producing a characteristic grating sound (laryngeal crepitus). Fixity of larynx indicates inflammation or infiltration of growth into the surrounding structures. Loss of laryngeal crepitus is due to postcricoid carcinoma.

## 2. Indirect Laryngoscopy

### **Technique**

Patient is seated opposite the examiner. He should sit erect with the head and chest leaning slightly towards the examiner. He is asked to protrude his tongue which is wrapped in gauze and held by the examiner between the thumb and middle finger. Index finger is used to keep the upper lip or moustache out of the way (Fig. 74.13). Gauze piece is used to get a firm grip of the tongue and to protect it against injury by the lower incisors.



Dhingra: Diseases of Ear Nose and Throat, 5th Edition  
Copyright © 2010 Elsevier. All rights reserved.

Figure 74.13 Indirect laryngoscopy.

page 391

page 392

Laryngeal mirror (size 4 to 6) which has been warmed and tested on the back of hand is introduced into the mouth and held firmly against the uvula and soft palate. Light is focussed on the laryngeal mirror and patient is asked to breathe quietly. To see movements of the cords, patient is asked to take deep inspiration (abduction of cords), say "Aa" (adduction of cords) and "Eee" (for adduction and tension). Movements of both the cords are compared.

#### **Structures seen on indirect laryngoscopy (Fig. 74.14)**

Indirect laryngoscopy permits examination of structures of the oropharynx, larynx and laryngopharynx.

**Larynx.** Epiglottis, aryepiglottic folds, arytenoids, cuneiform and corniculate cartilages, ventricular bands, ventricles, true cords, anterior commissure, posterior commissure, subglottis and rings of trachea.

**Laryngopharynx.** Both pyriform fossae, postcricoid region, posterior wall of laryngopharynx.

**Oropharynx.** Base of tongue, lingual tonsils, valleculae, medial and lateral glossoepiglottic folds.

### **3. Flexible or Rigid Fibre-optic Endoscopy**

#### **(a) Flexible endoscopy**

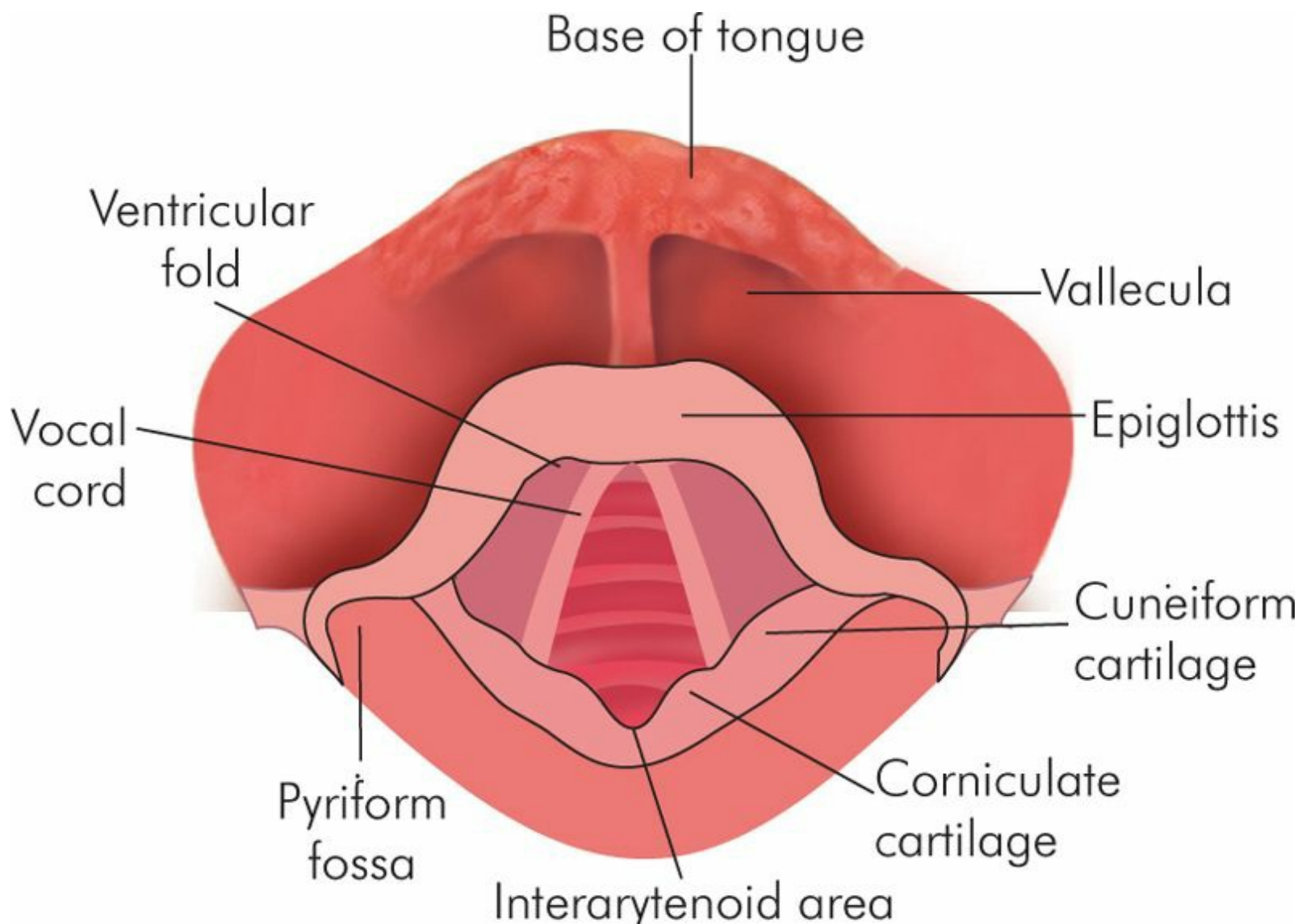
In difficult cases, where laryngeal examination cannot be performed with a mirror due to anatomical abnormalities or intolerance of mirror by the patient, a flexible rhinolaryngoscope can be used. It is passed through the nose under local anaesthesia and gives a good view of the larynx, laryngopharynx, subglottis and even upper trachea. It is an outdoor procedure.

#### **(b) Rigid endoscopy**

For this purpose, a rigid fibre-optic telescope is used. It gives a clear, wide-angle view of the larynx and laryngopharynx. It is also an outdoor



procedure.



Dhingra: Diseases of Ear Nose and Throat, 5th Edition  
Copyright © 2010 Elsevier. All rights reserved.

Figure 74.14 Structures seen on indirect laryngoscopy.

**Stroboscopy:** A stroboscope is a device which emits light in pulses, the frequency of which can be set by the examiner. If frequency of pulses is same as that of vocal cord movements, the latter appear stationary giving more time to study the cord. If frequency of pulses is more or less than that of vocal cord movements, the cords are seen in slow motion. Stroboscopes are synchronised with rigid or fibre-optic endoscopes and the vocal cord movements can be recorded on video (video stroboscopy). Stroboscopy has been found very useful in diagnosis of laryngeal paralysis, completeness of glottic closure during phonation, very small early laryngeal cancer, vocal cord scarring, laryngeal cyst versus polyp, and sulcus vocalis.

#### 4. Assessment of Voice

The examiner should make note of the quality of voice of the patient such as hoarse, rough, breathy, bitonal, dysphonic, whispered or feeble.

#### 5. Assessment of Cervical Lymph Nodes

No examination of the larynx and hypopharynx is complete without thorough search for cervical lymph nodes.

## VII. LYMPH NODES OF THE HEAD AND NECK

### Classification (Fig. 74.15)

#### 1. Upper horizontal chain of nodes

- (a) Submental
- (b) Submandibular
- (c) Parotid
- (d) Postauricular
- (e) Occipital
- (f) Facial

#### 2. Lateral cervical nodes

They include nodes, superficial and deep to sternocleidomastoid muscle and in the posterior triangle.

- (a) Superficial external jugular group
- (b) Deep group
  - (i) Internal jugular chain (upper, middle and lower groups)
  - (ii) Spinal accessory chain
  - (iii) Transverse cervical chain

#### 3. Anterior cervical nodes

- (a) Anterior jugular chain
- (b) Juxtavisceral chain
  - (i) Prelaryngeal
  - (ii) Pretracheal
  - (iii) Paratracheal

page 392

page 393

### 1. Nodes of Upper Horizontal Chain

#### (a) Submental nodes

They lie on the mylohyoid muscle in the submental triangle, 2 to 8 in number.

Afferents come from the chin, middle part of lower lip, anterior gums, anterior floor of mouth and tip of tongue.

Efferents go to submandibular nodes and internal jugular chain.

#### (b) Submandibular nodes

They lie in submandibular triangle in relation to submandibular gland and facial artery.

Afferents come from lateral part of the lower lip, upper lip, cheek, nasal vestibule and anterior part of nasal cavity, gums, teeth, medial canthus, soft palate, anterior pillar, anterior part of tongue, submandibular and sublingual salivary glands and floor of mouth. Efferents go to internal jugular chain.

#### (c) Parotid nodes

They lie in relation to the parotid salivary gland and are extraglandular and intraglandular. Preauricular and infraauricular nodes are part of the extraglandular group.

Afferents come from the scalp, pinna, external auditory canal, face, buccal mucosa.

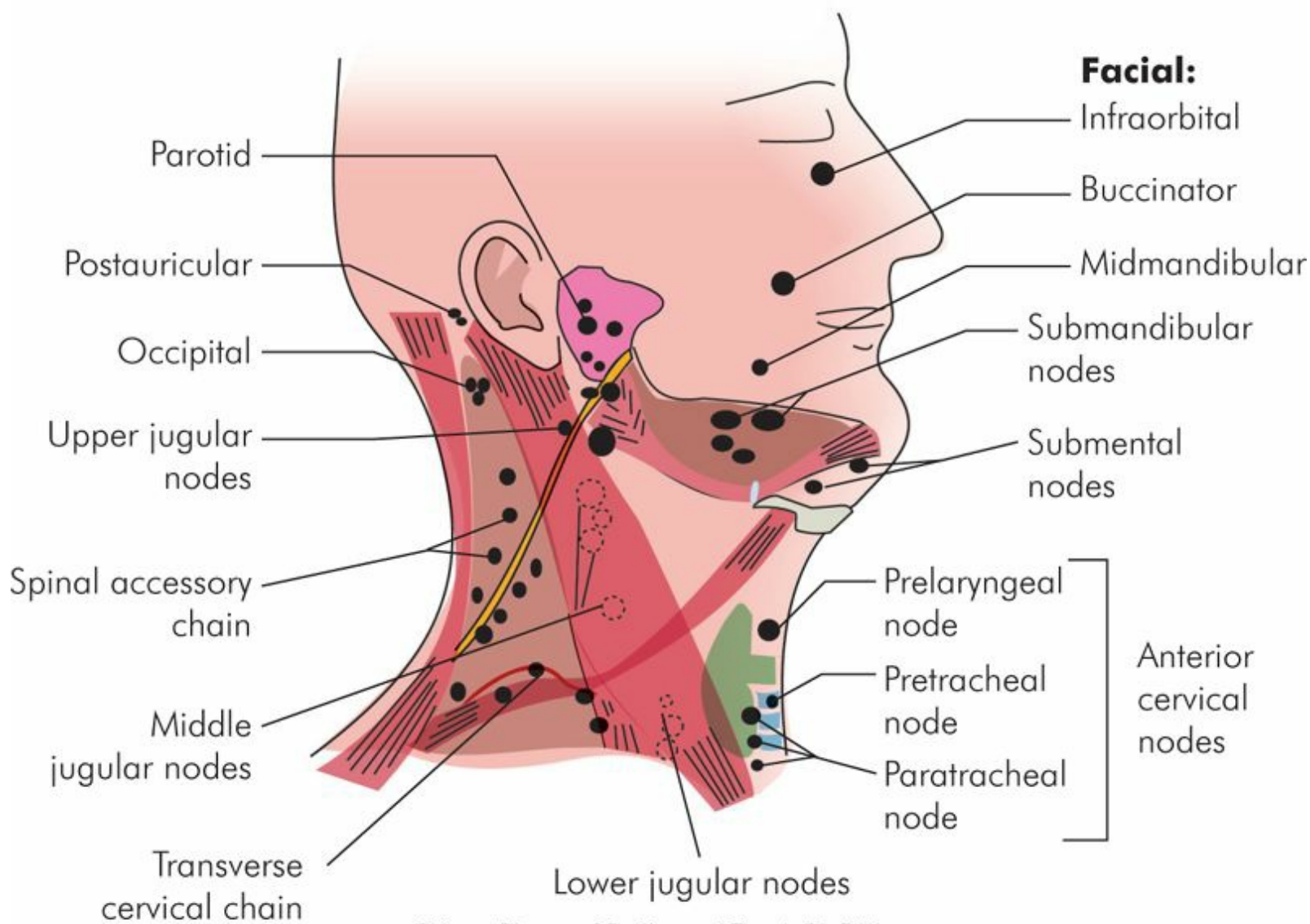
Efferents go to internal jugular or external jugular chain.

#### (d) Post auricular nodes (mastoid nodes)

They lie behind the pinna over the mastoid.

Afferents come from the scalp, posterior surface of pinna and skin of mastoid.

Efferents drain into infra-auricular nodes and into internal jugular chain.



Dhingra: Diseases of Ear Nose and Throat, 5th Edition  
Copyright © 2010 Elsevier. All rights reserved.

Figure 74.15 Lymph nodes of head and neck.

**(e) Occipital nodes**

They lie both superficial and deep to splenius capitus at the apex of the posterior triangle.

Afferents come from scalp, skin of upper neck. Efferents drain into upper accessory chain of nodes.

**(f) Facial nodes**

They lie along facial vessels and are grouped according to their location. They are midmandibular, buccinator, infraorbital and malar (near outer canthus) nodes.

Afferents come from upper and lower lids, nose, lips and cheek.

Efferents drain into submandibular nodes.

**2. Lateral Cervical Nodes**

They are divided into:

**(a) Superficial group**

It lies along external jugular vein and drains into internal jugular and transverse cervical nodes.

**(b) Deep group**

It consists of three chains, the internal jugular, spinal accessory and transverse cervical.

- **(i) Internal jugular chain.** Lymph nodes of internal jugular chain lie anterior, lateral and posterior to internal jugular vein and extend from the digastric muscle to the junction of internal jugular vein with the subclavian vein. They are arbitrarily divided into upper, middle and lower groups.  
Upper group (jugulodigastric node) drains oral cavity, oropharynx, nasopharynx, hypopharynx, larynx and parotid. Middle group drains hypopharynx, larynx, thyroid, oral cavity, oropharynx.  
Lower jugular group drains larynx, thyroid and cervical oesophagus.
- **(ii) Spinal accessory chain.** It lies along the spinal accessory nerve. Upper nodes of this chain coalesce with upper jugular nodes. Spinal accessory chain drains the scalp, skin of the neck, the nasopharynx, occipital and postauricular nodes.  
Efferents from this chain drain into transverse cervical chain.
- **(iii) Transverse cervical chain (supraclavicular nodes).** It lies horizontally, along the transverse cervical vessels, in the lower part of the posterior triangle. The medial nodes of the group are called *scalene nodes*. Afferents to those nodes come from the accessory chain and also infraclavicular structures, e.g. breast, lung, stomach, colon, ovary and testis.

### 3. Anterior Cervical Nodes

They lie between the two carotids and below the level of hyoid bone and consist of two chains:

#### (a) Anterior jugular chain

It lies along anterior jugular vein and drains the skin of anterior neck.

#### (b) Juxtavisceral chain

It consists of prelaryngeal, pretracheal, and paratracheal nodes.

Prelaryngeal node (Delphian node) lies on cricothyroid membrane and drains subglottic region of larynx and pyriform sinuses.

Pretracheal nodes lie in front of the trachea, deep to pretracheal fascia, and drain thyroid gland and the trachea. Efferents from these nodes go to paratracheal, lower internal jugular and anterior mediastinal nodes.

Paratracheal nodes (recurrent nerve chain) lie along recurrent laryngeal nerve and drain the thyroid lobes, subglottic larynx, trachea and cervical oesophagus.

### Lymph Nodes Not Clinically Palpable

#### (a) Retropharyngeal nodes

They lie behind the pharynx and are divided into lateral and medial groups. Lateral group lies at the level of atlas, close to the base of skull. Most superior node of the lateral group is called the *node of Rouviere*.

Medial group lies near the midline but at a lower level.

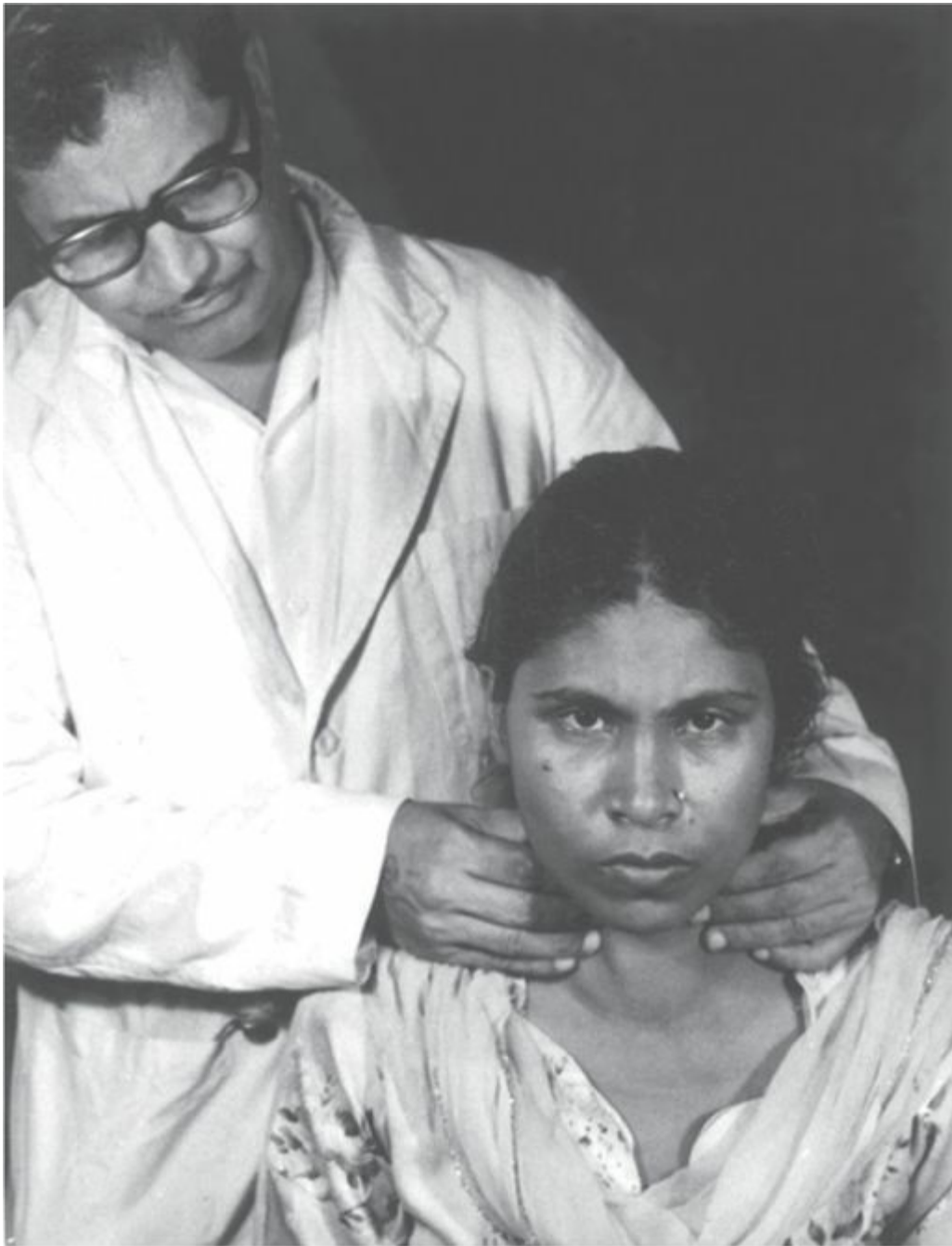Retropharyngeal nodes drain the nasal cavity, paranasal sinuses, hard and soft palate, nasopharynx, posterior wall of the pharynx and send efferents to the upper internal jugular group.

#### (b) Sublingual nodes

They lie deep along the lingual vessels and drain anterior part of the floor of mouth and ventral surface of tongue. Lymphatics from these nodes end in the submandibular or upper jugular nodes.

## Examination of Neck Nodes

Examination of neck nodes is important, particularly in head and neck malignancies and a systematic approach should be followed.



Dhingra: Diseases of Ear Nose and Throat, 5th Edition  
Copyright © 2010 Elsevier. All rights reserved.

Figure 74.16 Examination of neck nodes.

Neck nodes are better palpated while standing at the back of the patient. Neck is slightly flexed to achieve relaxation of muscles (Fig. 74.16). The nodes are examined in the following manner so that none is missed.

- **(a) Upper horizontal chain.** Examine submental, submandibular, parotid, facial, postauricular and occipital nodes.
- **(b) External jugular chain.** It lies superficial to sternomastoid.
- **(c) Internal jugular chain.** Examine the upper, middle and lower groups. Many of them lie deep to sternomastoid muscle which may need to be displaced posteriorly.
- **(d) Spinal accessory chain.**
- **(e) Transverse cervical chain.**
- **(f) Anterior jugular chain.**
- **(g) Juxtavisceral chain.** Prelaryngeal, pretracheal and paratracheal nodes.

When a node or nodes are palpable, look for the following points:

- (i) Location of nodes.
- (ii) Number of nodes.
- (iii) Size.
- (iv) Consistency. Metastatic nodes are hard; lymphoma nodes are firm and rubbery; hyperplastic nodes are soft. Nodes of metastatic melanoma are also soft.
- (v) Discrete or matted nodes.
- (vi) Tenderness. Inflammatory nodes are tender.
- (vii) Fixity to overlying skin or deeper structures. Mobility should be checked both in the vertical and horizontal planes.

# Classification of Neck Nodes According to Levels (see Table 74.1 and Fig. 74.17)

## Level I: Includes

- **IA** Submental nodes, which lie in the submental triangle, i.e. between right and left anterior bellies of digastric muscles and the hyoid bone.
- **IB** Submandibular nodes, lying between anterior and posterior bellies of digastric muscle and the body of mandible.

Levels are shown in

## Level II: Upper Jugular Nodes

They are located along the upper third of jugular vein, i.e. between the skull base above, and the level of hyoid bone (or bifurcation of carotid artery) below.

## Level III: Middle Jugular Nodes

They are located along the middle third jugular vein, from the level of hyoid bone above, to the level of upper border of cricoid cartilage (or where omohyoid muscle crosses the jugular vein) below.

## Level IV: Lower Jugular Nodes

They are located along the lower third of jugular vein; from upper border of cricoid cartilage to the clavicle.

Table 74-1. Division of neck nodes according to levels

Level I	Submental (IA)
	Submandibular (IB)
Level II	Upper jugular
Level III	Mid jugular
Level IV	Lower jugular
Level V	Posterior triangle group (Spinal accessory and transverse cervical chains)
Level VI	Prelaryngeal
	Pretracheal
	Paratracheal
Level VII	Nodes of upper mediastinum

## Level V: Posterior Cervical Group

They are located in the posterior triangle, i.e. between posterior border of sternocleidomastoid (anteriorly), anterior border of trapezius (posteriorly), and the clavicle below. They include lymph nodes of spinal accessory chain, transverse cervical nodes and supraclavicular nodes. Level V nodes are further subdivided into upper, middle and lower, corresponding to planes that define levels II, III and IV.

## Level VI: Anterior Compartment Nodes

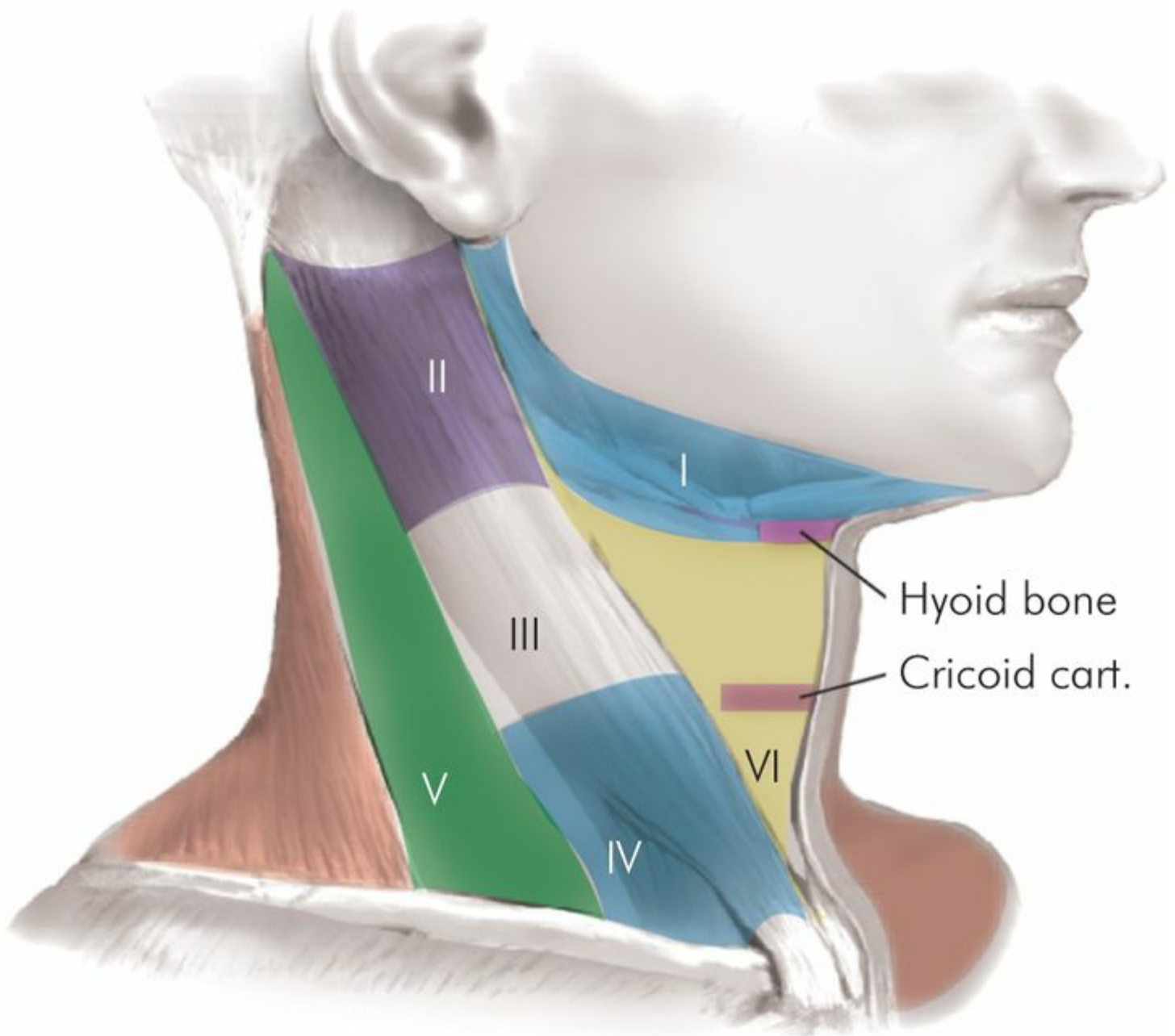
They are located between the medial borders of sternocleidomastoid muscles (or carotid sheaths) on each side, hyoid bone above and suprasternal notch below. They include prelaryngeal, pretracheal, paratracheal nodes.

## Level VII

They are located below the suprasternal notch and include nodes of the upper mediastinum.

Lymph nodes of supraclavicular zone or fossa (Ho's triangle) (Fig. 74.18). Supraclavicular zone is situated between (i) upper border of medial end of clavicle, (ii) upper border of lateral end of clavicle and (iii) point where neck meets the shoulder. Nodes in this triangle are important in carcinoma of the nasopharynx. Metastases in these nodes, irrespective of their size, would place them in N<sub>3</sub> category (AJCC, 1977). Nodes in this zone include lower part of levels IV and V.

## Other Groups

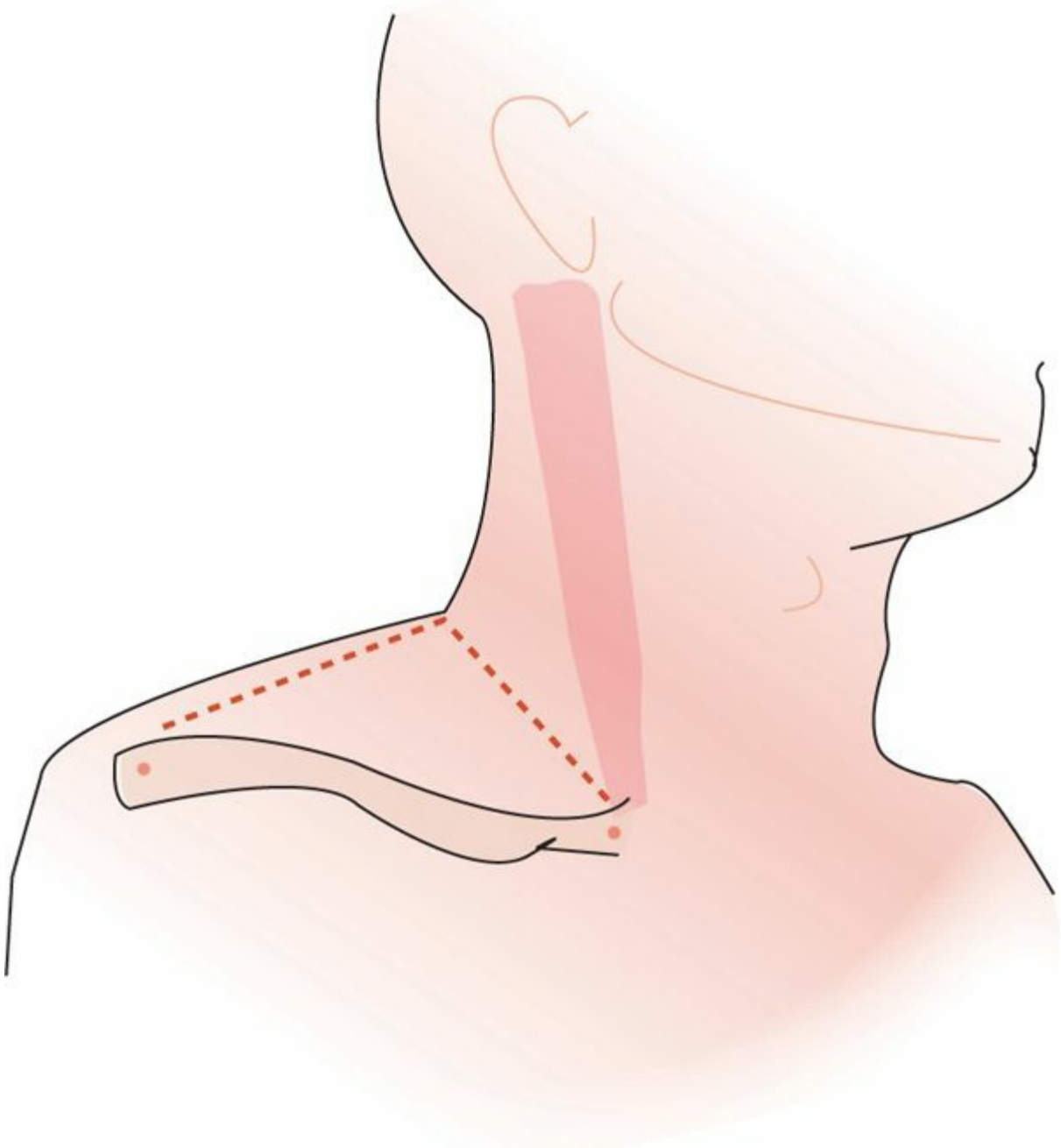


Dhingra: Diseases of Ear Nose and Throat, 5th Edition  
 Copyright © 2010 Elsevier. All rights reserved.

Figure 74.17 Classification of neck nodes according to levels.

- Retropharyngeal
- Facial
- Preauricular
- Postauricular (mastoid)
- Intraparotid
- Suboccipital





Dhingra: Diseases of Ear Nose and Throat, 5th Edition  
Copyright © 2010 Elsevier. All rights reserved.

Figure 74.18 Supraclavicular fossa (or Ho's triangle) is bounded by medial and lateral ends of clavicle and the point where neck meets the shoulder. Nodes in this zone include nodes of lower parts of levels IV and V.

## **NECK DISSECTION**

It is a procedure to remove lymph nodes and the surrounding fibrofatty tissues from the neck, to eradicate metastases to cervical lymph nodes from cancer of the aerodigestive tract.

# Classification of Neck Dissection

- **(i)** Radical neck dissection.
- **(ii)** Modified radical neck dissection.
  - Type I-Preserves CN XI
  - Type II-Preserves CN XI and internal jugular vein
  - Type III-Preserves CN XI, I.J.V. and sternocleidomastoid muscle.
- **(iii)** Selective neck dissection
  - (a) Supraomohyoid (or anterolateral) (removes level I to III)
  - (b) Lateral (removes nodes in level II to IV)
  - (c) Posterolateral (removes level II to V suboccipital and postauricular nodes)
  - (d) Anterior compartment (removes level VI nodes)
- **(iv)** Extended neck dissection.

## Radical Neck Dissection

In this procedure, all lymph nodes, extending from the mandible above to the clavicle below and from lateral border of sternomastoid, hyoid bone and contralateral anterior belly of digastric, medially, to the anterior border of trapezius posteriorly, are removed. The dissection specimen would include:

- **(a)** Lymph nodes of submental, submandibular, upper, middle and lower jugular, and lateral (posterior) triangle regions, i.e. level I to V along with its fibrofatty tissue.
- **(b)** Sternomastoid muscle.
- **(c)** Internal jugular vein.
- **(d)** Spinal accessory nerve.
- **(e)** Submandibular salivary gland.
- **(f)** Tail of the parotid.
- **(g)** Omohyoid muscle.

It saves following structures:

- **(i)** Carotid artery.
- **(ii)** Brachial plexus, phrenic nerve, vagus nerve, cervical sympathetic chain, marginal mandibular branch of facial, lingual and hypoglossal nerves.

Radical neck dissection does not remove nodes of postauricular, suboccipital, parotid (except those in the tail) facial, retropharyngeal and paratracheal regions.

Incision used in radical neck dissection (Fig. 74.19) will depend on the incision being used to remove the primary growth and whether patient received any radiation.

Commonly, the incisions used are:

- **(i)** Schobinger
- **(ii)** Mc Fee
- **(iii)** Hockey-stick
- **(iv)** Extensions from Gluck-Sorenson's incision, used for laryngectomy with neck dissection (Fig. 74.20).

## Contraindications

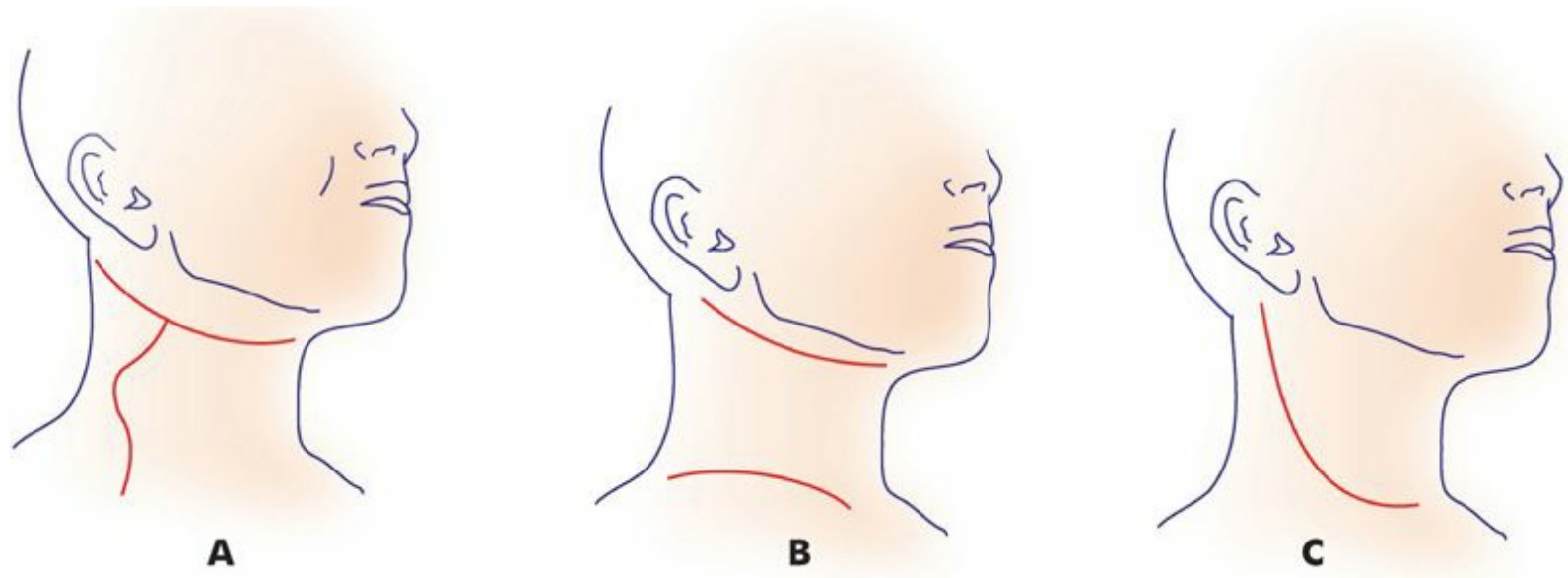
to radical neck dissection include:

- **(i)** Untreatable primary cancer.
- **(ii)** Distant metastases.
- **(iii)** Inoperable neck nodes when they are fixed to important structures.
- **(iv)** Medical illness which makes the patient unfit for major surgery.

## Modified Neck Dissection

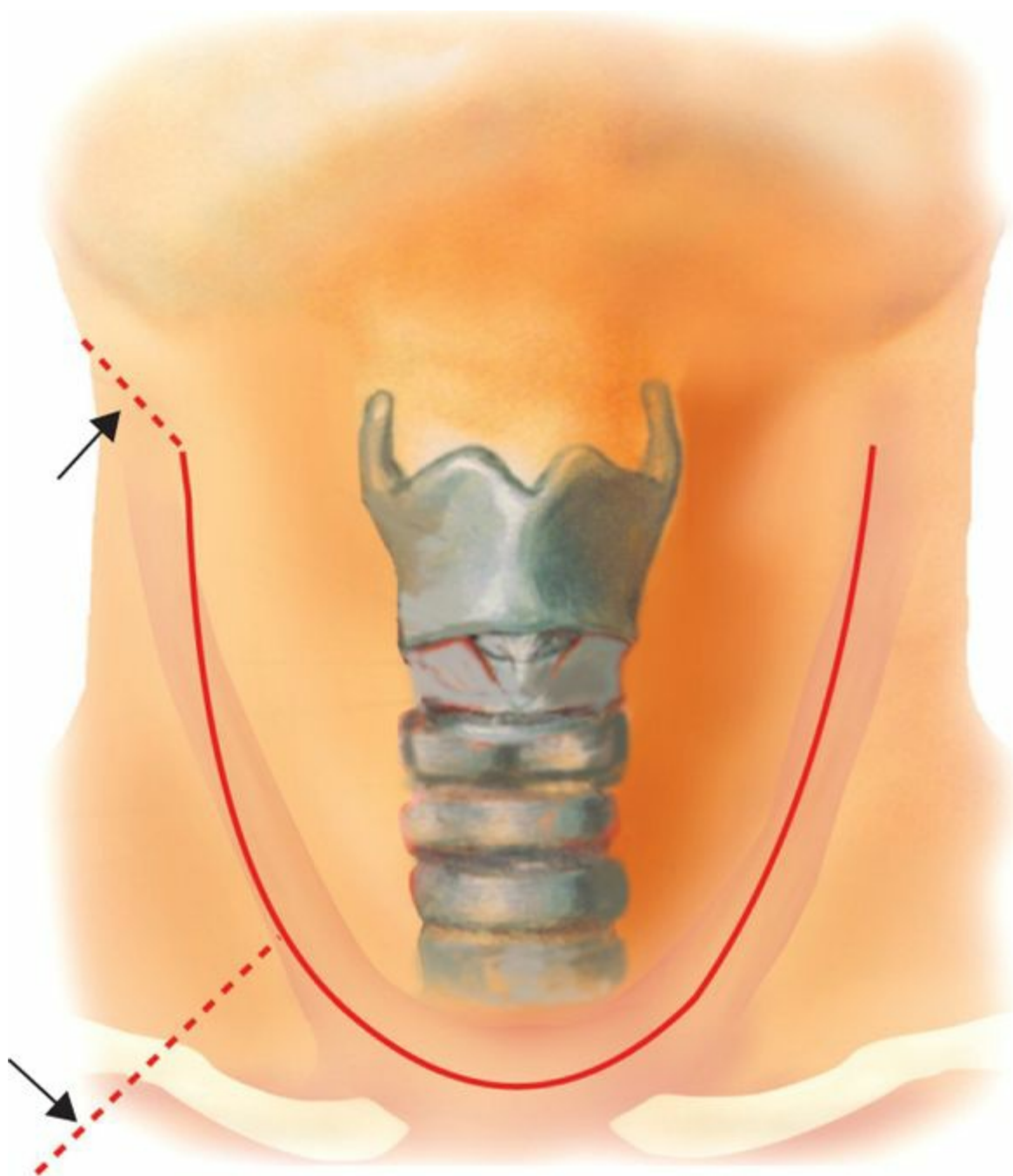
It is similar to radical neck dissection but with preservation of one or more of the following structures:

- **(i)** Spinal accessory nerve
- **(ii)** Internal jugular vein
- **(iii)** Sternocleidomastoid muscle.



Dhingra: Diseases of Ear Nose and Throat, 5th Edition  
Copyright © 2010 Elsevier. All rights reserved.

Figure 74.19 Incisions commonly used in radical neck dissection. (A) Schobinger, (B) Mc Fee, (C) Hockey-stick.



Dhingra: Diseases of Ear Nose and Throat, 5th Edition  
 Copyright © 2010 Elsevier. All rights reserved.

Figure 74.20 Gluck-Sorenson's incision used for laryngectomy. Dotted lines showing extensions of incisions for radical neck dissection.

### Selective Neck Dissection

It consists of preservation of one or more lymph node groups and all the three non-lymphatic structures, i.e. spinal accessory, sternocleidomastoid muscle and internal jugular vein.

#### ***Supraomohyoid***

Removes levels I to III (anterolateral), usually done in cancer of oral cavity.

#### ***Lateral***

Removes levels II to IV.

Used in cancer of pharynx, hypopharynx and larynx.

#### ***Posterolateral***

Removes levels II to V with postauricular and occipital nodes.

Used in cancer or melanoma of skin, located in posterior scalp or posterior upper neck behind the line passing through the tragus.

***Anterior compartment***

Removes nodes at level VI, i.e. pretracheal, paratracheal, prelaryngeal.

Used in differentiated thyroid cancer, subglottic, cervical tracheal or hypopharyngeal cancers.

**Extended Neck Dissection**

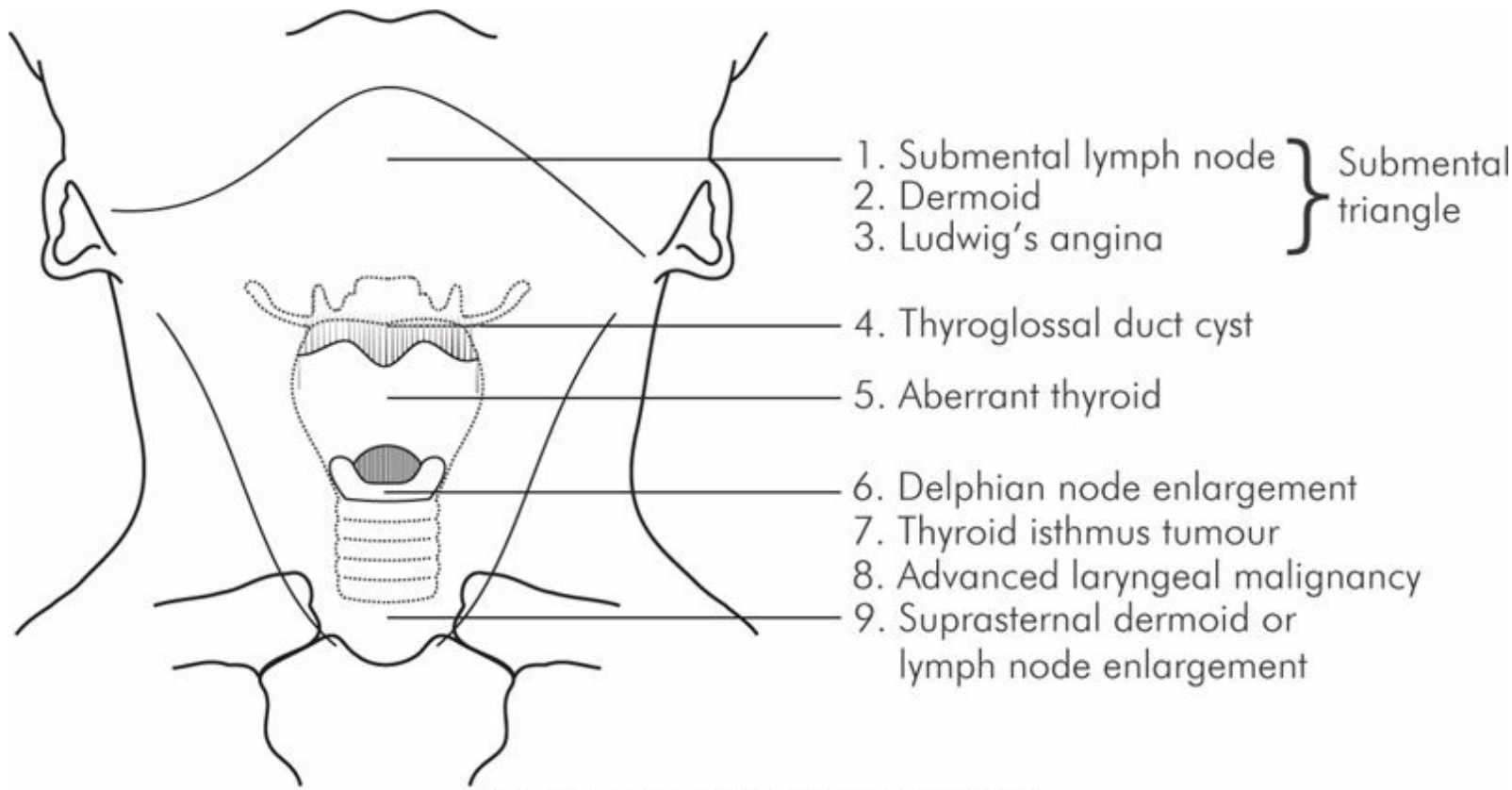
It consists of removal of structures as in radical neck dissection and further extended to include additional lymph node groups or non-lymphatic structures or both. Additional lymph node groups include retropharyngeal, parotid or level VI nodes, and non-lymphatic structures may include external carotid artery, hypoglossal nerve, parotid gland, mastoid tip, etc.

## 75 Neck Masses

Clinically neck masses can be divided into: (A) those in the midline (Fig. 75.1), and (B) those in the lateral aspect of neck (Fig. 75.2). The latter can be grouped according to triangles of neck. Only the clinically important ones are described in this chapter.

# Thyroglossal Duct Cyst

It presents as a cystic midline swelling, usually affecting young children but can occur at any age (Fig. 75.3). It is usually rounded with a diameter of 2-4 cm. It increases in size with upper respiratory tract infection. Sometime it presents as a draining sinus if it has burst due to infection or has been surgically drained. Because of the attachment of thyroglossal duct to foramen caecum at the base of tongue, it moves with tongue protrusion.



Dhingra: Diseases of Ear Nose and Throat, 5th Edition  
Copyright © 2010 Elsevier. All rights reserved.

Figure 75.1 Midline swellings of neck.

During development, thyroid anlage starts at foramen caecum, passes through base of tongue and then descends in front, behind or through the hyoid bone to form the thyroid gland. Thyroglossal cyst can occur anywhere in the course of thyroid duct (Fig. 75.4). It may contain the only functioning thyroid tissue in the body. Rarely carcinoma develops in the cyst.

## Treatment

is complete surgical excision, including with it the body of hyoid bone and core of tongue tissue around the tract in the suprahyoid tongue base to the foramen caecum (Sistrunk's operation). Simple excision of cyst without removal of its tract leads to recurrence.

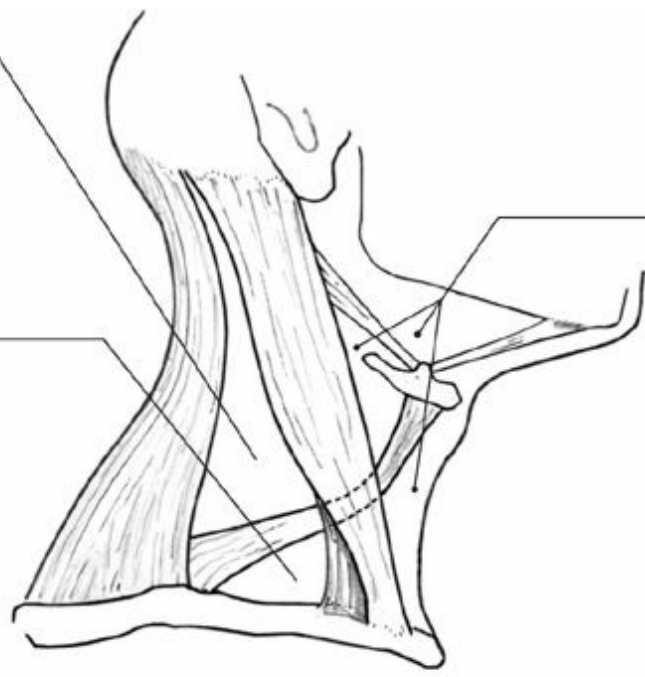


# Sublingual Dermoid Cyst

It presents as a midline submental swelling but does not move on protrusion of the tongue as it is not attached to foramen caecum. Sometimes it arises from the floor of mouth and needs differentiation from ranula. Treatment is surgical excision. A midline dermoid is also seen just above the suprasternal notch.

- Occipital triangle**
- Lymph nodes:
    - Inflammatory
    - Neoplastic
    - Metastatic

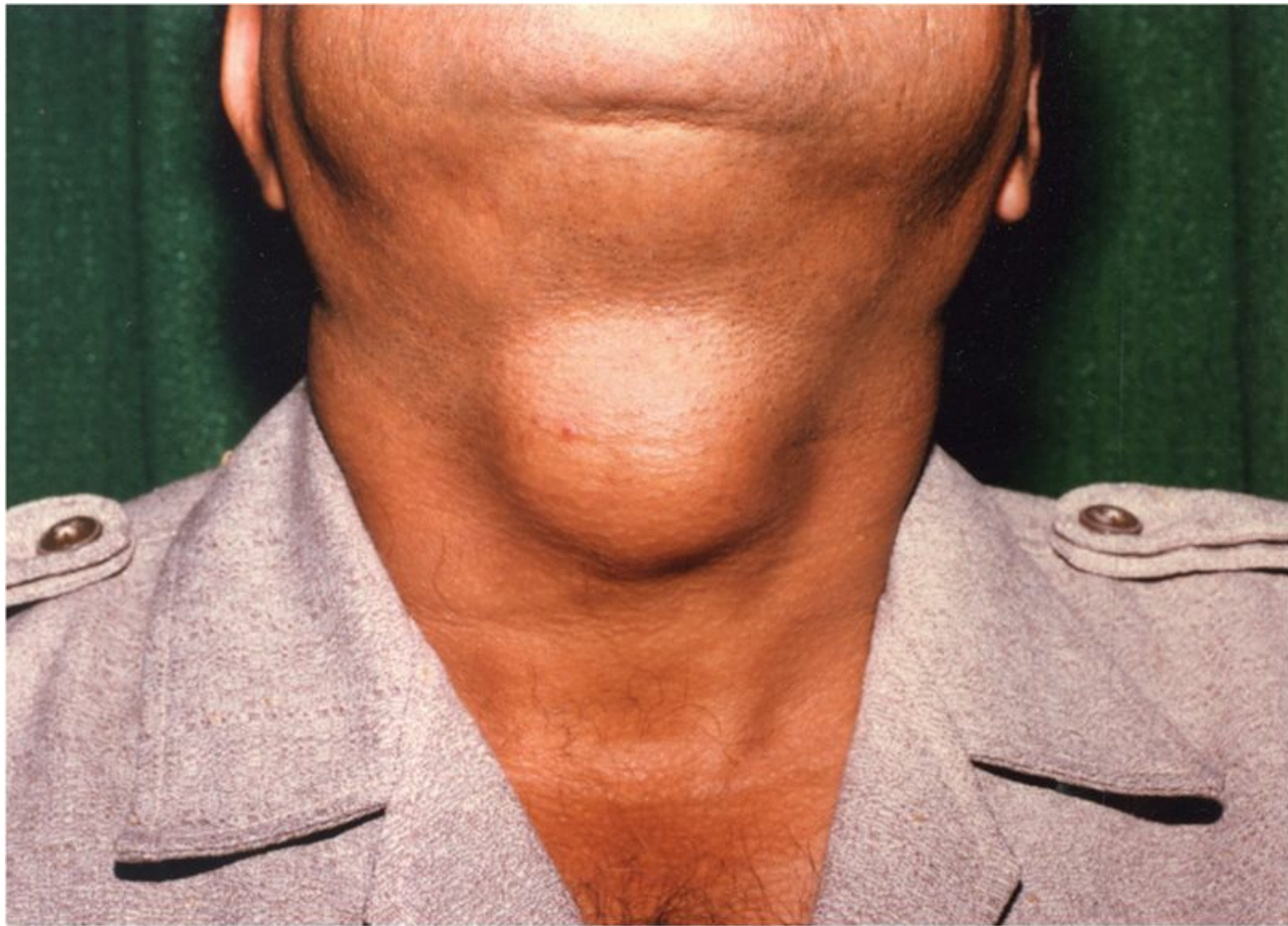
- Supraclavicular triangle**
- Metastatic nodes from infraclavicular primaries:
    - Breast
    - Lung
    - GI tract
    - Kidney
    - Ovary, testis
  - Cystic hygroma
  - Subclavian aneurysm
  - Cervical rib



- Anterior triangle**  
(Including its three subdivisions; digastric, carotid and muscular triangles)
- Submandibular sialadenitis or tumour
  - Submandibular lymph nodes:
    - Inflammatory
    - Neoplastic
    - Metastatic
  - Plunging ranula
  - Jugular lymph nodes
  - Branchial cyst
  - Swelling thyroid lobe
  - Carotid body tumour
  - Parotid (tail) swelling
  - Parapharyngeal tumour
  - Laryngocele
  - Pharyngeal pouch

Dhingra: Diseases of Ear Nose and Throat, 5th Edition  
Copyright © 2010 Elsevier. All rights reserved.

Figure 75.2 Lateral swellings of neck as seen in different triangles of neck.



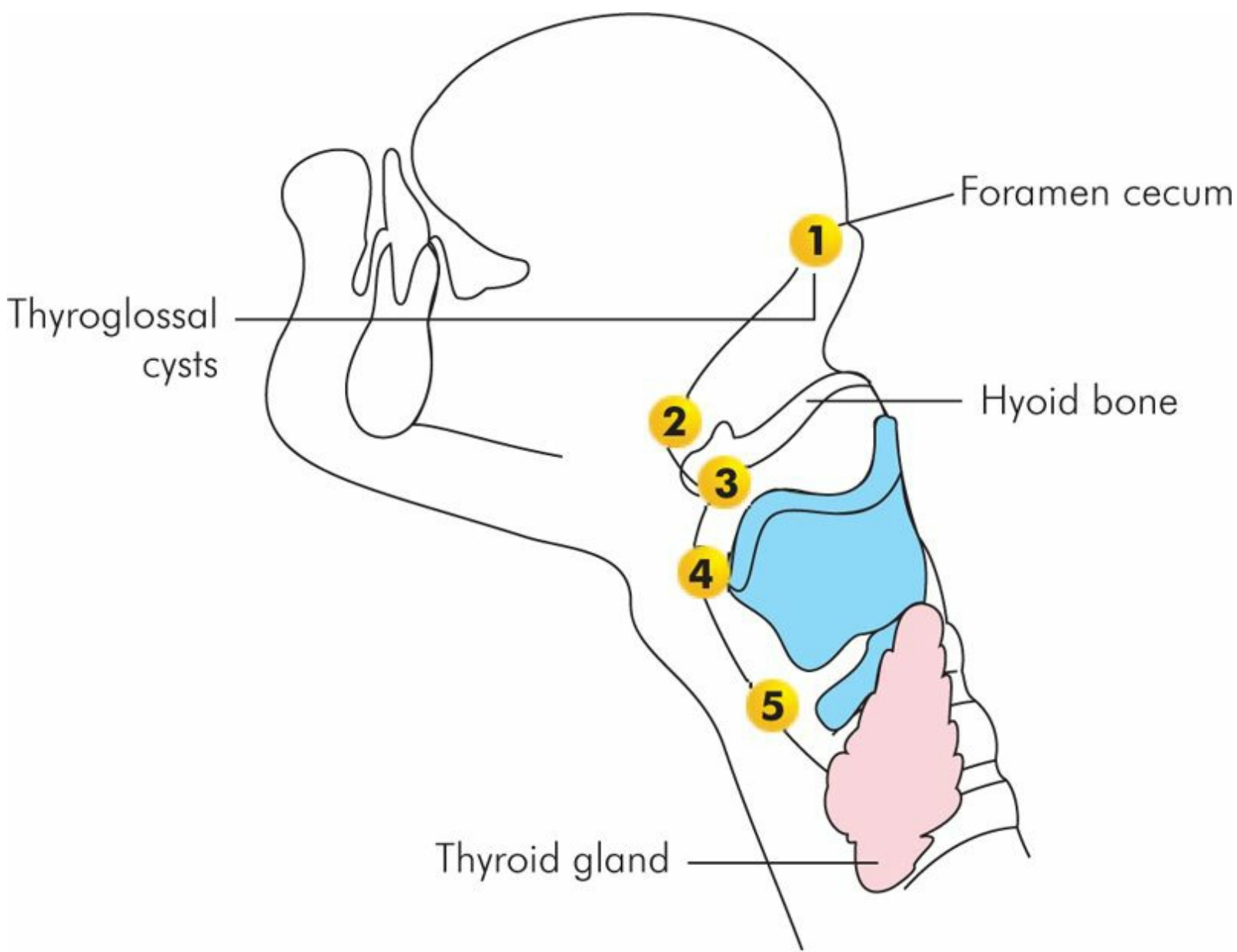
Dhingra: Diseases of Ear Nose and Throat, 5th Edition  
Copyright © 2010 Elsevier. All rights reserved.

Figure 75.3 Thyroglossal cyst.

## Submental Nodes

There are 2-8 nodes situated in the submental triangle between the platysma and mylohyoid muscle. They drain chin, middle part of lower lip, incisor region of gingiva, anterior floor of mouth and the tip of tongue.

When enlarged, the draining areas should be looked for infections or malignancy.



Dhingra: Diseases of Ear Nose and Throat, 5th Edition  
Copyright © 2010 Elsevier. All rights reserved.

Figure 75.4 Sites of thyroglossal duct cysts. 1. Base of tongue, 2. Suprahyoid, 3. Subhyoid (most common), 4. On the thyroid cartilage and 5. In front of cricoid.

## Prelaryngeal and Pretracheal Nodes

They belong to juxtavisceral chain of nodes and lie in front of the larynx and trachea. They drain the larynx and trachea, thyroid isthmus and anteromedial aspect of thyroid lobes. In case of enlargement of the above nodes, draining areas should be examined.

## Thymic Cyst

Thymus develops from the third pharyngeal pouch and then descends through the neck to the mediastinum. Thymic remnants may persist anywhere in its path from angle of the mandible to the midline of neck. Swelling is either cystic or solid. It can occur in children or adults and presents as a neck mass anterior and deep to middle third of sternocleidomastoid muscle. It is a very rare condition. Treatment is surgical excision. Sternotomy is required if it also extends into the mediastinum.

# Branchial Cyst

It is common in the second decade of life but can occur at any age with equal frequency in both sexes. Cyst presents as a swelling in the upper part of the neck anterior to sternocleidomastoid muscle. Mass is smooth, round, fluctuant, non-tender and non-transilluminant. A painful increase in size at the time of upper respiratory infection can occur. Anomalies of the second branchial arch are the most common. A branchial cyst may be associated with a sinus or a fistula. A second arch branchial sinus has an external opening at the junction of lower and middle of the anterior border of sternomastoid and may exude mucoid discharge. It may have an internal opening in the tonsillar fossa. When both internal and external openings are present, it is called a branchial fistula.

## ***Treatment***

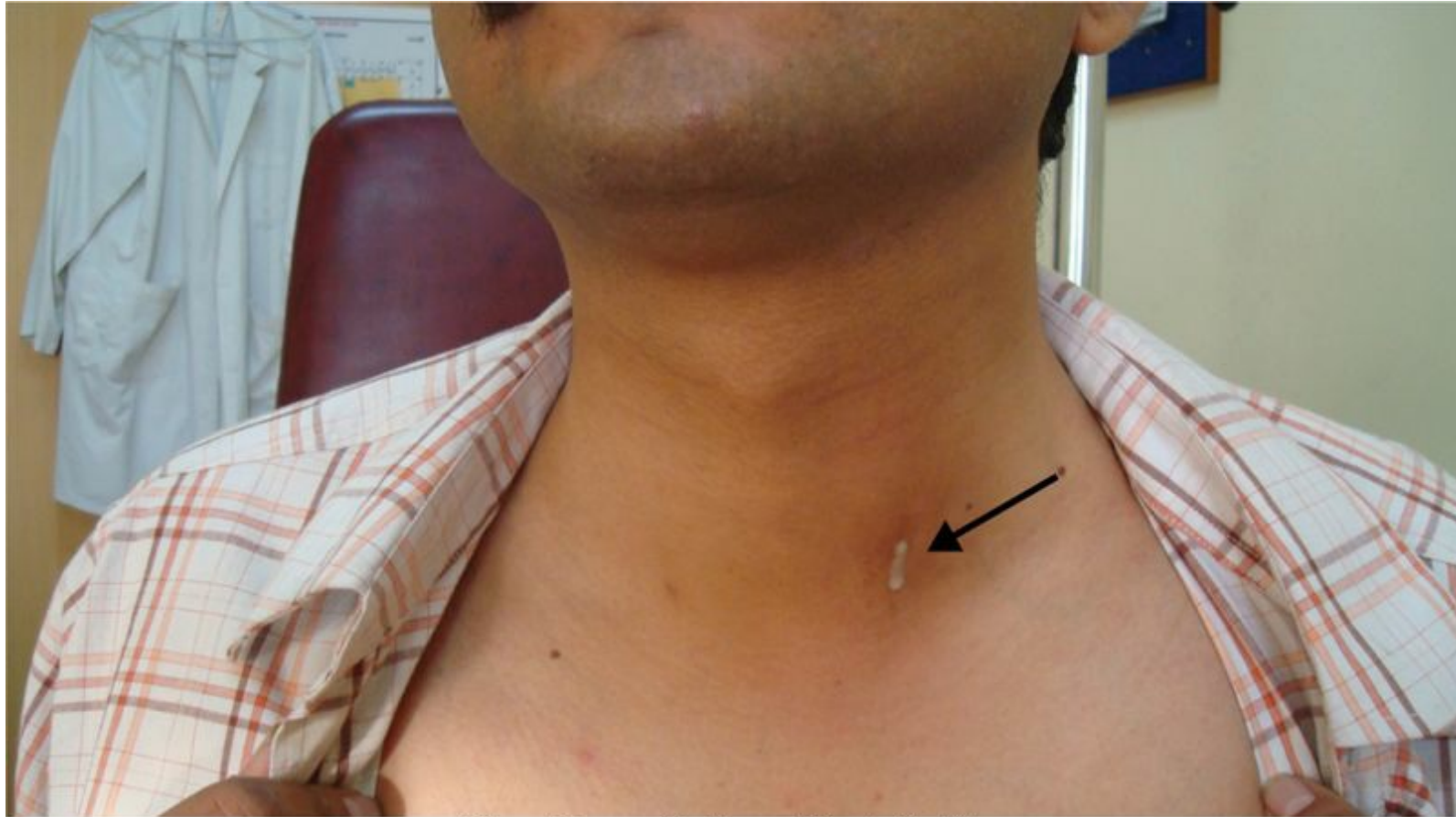of branchial cyst is surgical excision along with its tract, if present.

## Branchial Sinus or Fistula (Fig. 75.5)

A second arch fistula has a typical course, the knowledge of which can help in the total surgical extirpation of the tract. It has:

- (a) An external opening along the anterior border of sternocleidomastoid muscle.
- (b) A tract which ascends just deep to deep cervical fascia along the carotid artery.
- (c) The tract passes deep to second arch structures, i.e. external carotid artery, stylohyoid and posterior belly of digastric but superficial to third arch structure, i.e. internal carotid artery (the tract passes *between internal and external carotid arteries*). It also runs superficial to hypoglossal nerve.
- (d) Pierces the pharyngeal wall and ends in the tonsillar fossa.

Complete excision of the tract can be accomplished by step-ladder incisions.



Dhingra: Diseases of Ear Nose and Throat, 5th Edition  
Copyright © 2010 Elsevier. All rights reserved.

Figure 75.5 Left sided branchial sinus discharging pus.

Third branchial cleft sinus is uncommon. Its external opening is at the same place as second cleft sinus but internal opening is situated in pyriform sinus. Tract passes *behind both internal and external carotid vessels* but is superficial to vagus and hypoglossal nerves.

## Plunging Ranula

It is a pseudocyst caused by extravasation of mucus from obstruction to sublingual salivary gland. It presents as an isolated swelling in the submandibular area and is transilluminant. Sometimes plunging ranula coexists with a ranula in the floor of mouth. Treatment is total excision along with removal of sublingual gland.



# Carotid Body Tumour

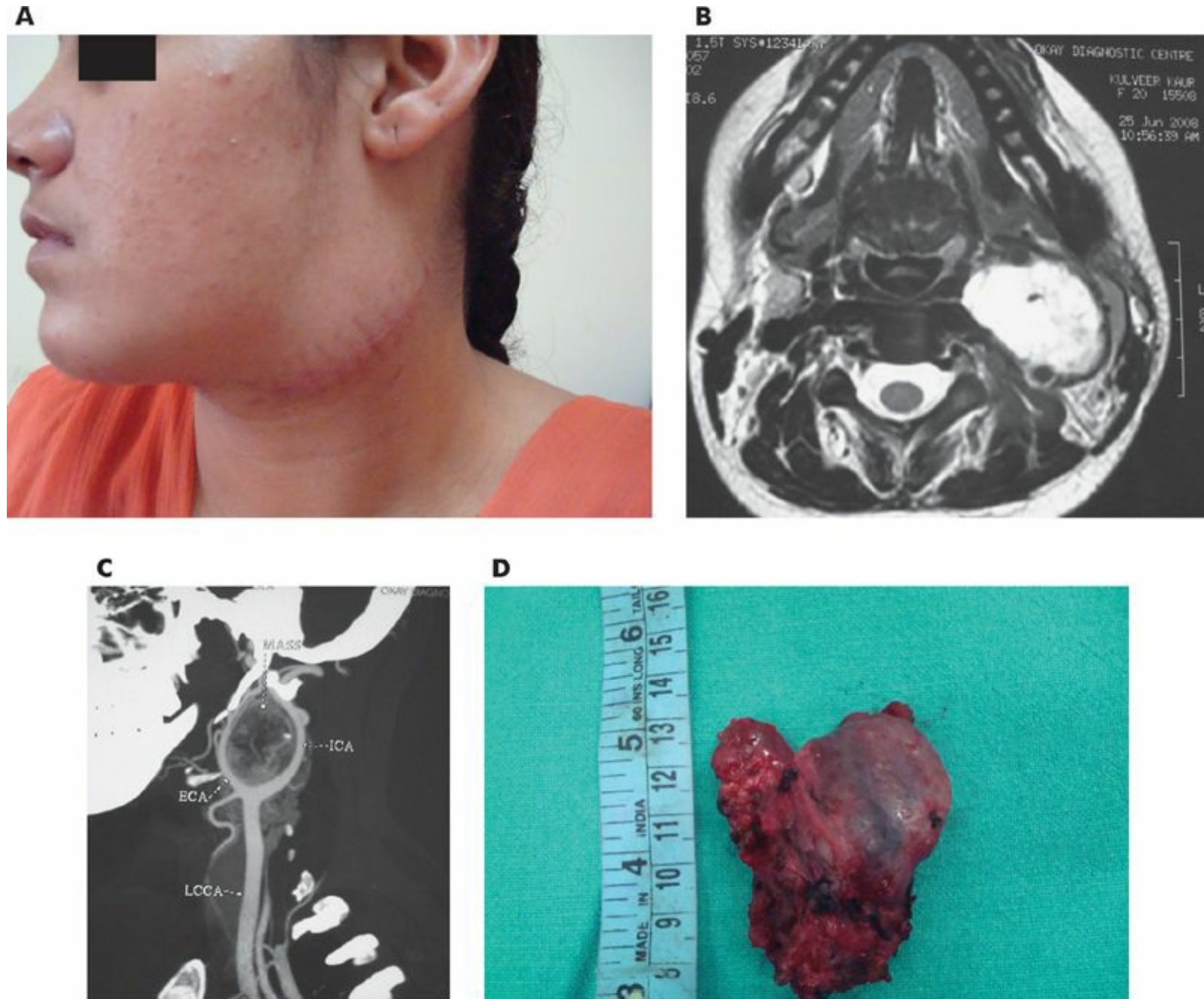
It arises from the chemoreceptor cells in the carotid body, hence also called chemodectoma. Mostly presents after 40 years. It is a very slow-growing tumour and the history of mass in the neck may extend into several years. It presents as a painless swelling which is pulsatile. Bruit can be heard with a stethoscope. It moves from side to side but not vertically. It may extend into the parapharyngeal space and present in the oropharynx (Fig. 75.6).

Contrast-enhanced CT and MRI with gadolinium are diagnostic and also show the extent of the tumour. MRI angiography shows splaying of internal and external carotid arteries (Lyre's sign). Some tumours are functional and secrete catecholamines. Hence serum catecholamines and urinary metanephrines and vanillylmandelic acid (VMA) should be estimated. Fine-needle aspiration cytology (FNAC) or biopsy should not be done because of the vascularity of tumour.

## Treatment

page 400

page 401



Dhingra: Diseases of Ear Nose and Throat, 5th Edition  
Copyright © 2010 Elsevier. All rights reserved.

Figure 75.6 (A) A 23-year-old female patient with carotid body tumour where surgery was earlier attempted. (B) MRI neck showing the tumour. (C) MRI angiography. Note splaying of the external carotid artery (ECA) and internal carotid artery (ICA). This is also called Lyre's sign. (D) Tumour after removal.

is surgical when the patient is younger than 50 years and surgically fit, or when the tumour extends into the oropharynx causing difficulty in speech, swallowing or breathing.

Radiotherapy is also effective and is used in older patients and those unfit for surgery or those who refuse surgery or have a metastatic disease.

## Parapharyngeal Tumours

These tumours present in the upper neck near the angle of mandible or retromandibular area.

They may also be seen intraorally displacing the tonsil, lateral pharyngeal wall and soft palate medially. Though majority of these tumours are of salivary gland origin (pleomorphic adenomas being the most common) others like schwannoma, neurofibroma, lipoma, haemangioma, paraganglioma or lymph node metastasis in parapharyngeal nodes are also seen. Diagnosis can be established by imaging techniques and FNAC.

# Cystic Hygroma

Also called *lymphangioma* or *cavernous lymphangioma*, it occurs most commonly in the posterior triangle of the neck. It arises from obstruction or sequestration of jugular lymph sac.

It may be seen in the neonate, early infancy or childhood. Ninety percent are seen before 2 years of age. When present at birth, they cause difficulty in labour.

Most commonly cystic hygroma is seen in the supraclavicular region and may extend to involve the whole of posterior triangle or extend into the axilla and mediastinum. Other common sites are axilla and groin. It may occur in the tongue and floor of mouth.

page 40

page 402

Cystic hygroma is soft, cystic, multilocular, partially compressible and brilliantly transilluminant. It may involve several tissue planes and neural and vascular structures. It may extend to involve laryngeal or pharyngeal structures to cause stridor, respiratory difficulty or feeding problems. When inflamed due to infection, it becomes painful and increases in size. Spontaneous regression is unpredictable.

## **Treatment**

is surgical excision with preservation of neural and vascular structures. Complete excision may not be possible in a single operation. Bipolar diathermy is useful. Rupture of cyst makes dissection difficult. Recurrence rate after surgical excision is only 5% if whole tumour is removed macroscopically but it is 50% if some part is left. Cystic hygroma causing respiratory distress may be aspirated or may require tracheostomy to relieve respiratory obstruction.

Injection of sclerosing agents is not favoured as it makes later dissection more difficult.

## Tubercular Lymph Nodes

Mass due to tubercular lymph nodes in the neck is very common in our country. Any lymph node group can be involved. It can occur in any age or sex. Involved lymph node may be single, multiple or matted due to periadenitis. Tubercular abscess may form when node/nodes caseate. It may become adherent to the skin and underlying structures or a draining tubercular sinus may develop (Figs 75.7 and 75.8).

Diagnosis is usually made by FNAC or lymph node biopsy which reveals a granulomatous lesion. Sometimes acid fast bacilli (AFB) can be demonstrated. AFB from the aspirated or biopsy material can be cultured and sensitivity established, to be prepared for multidrug resistant lesions.

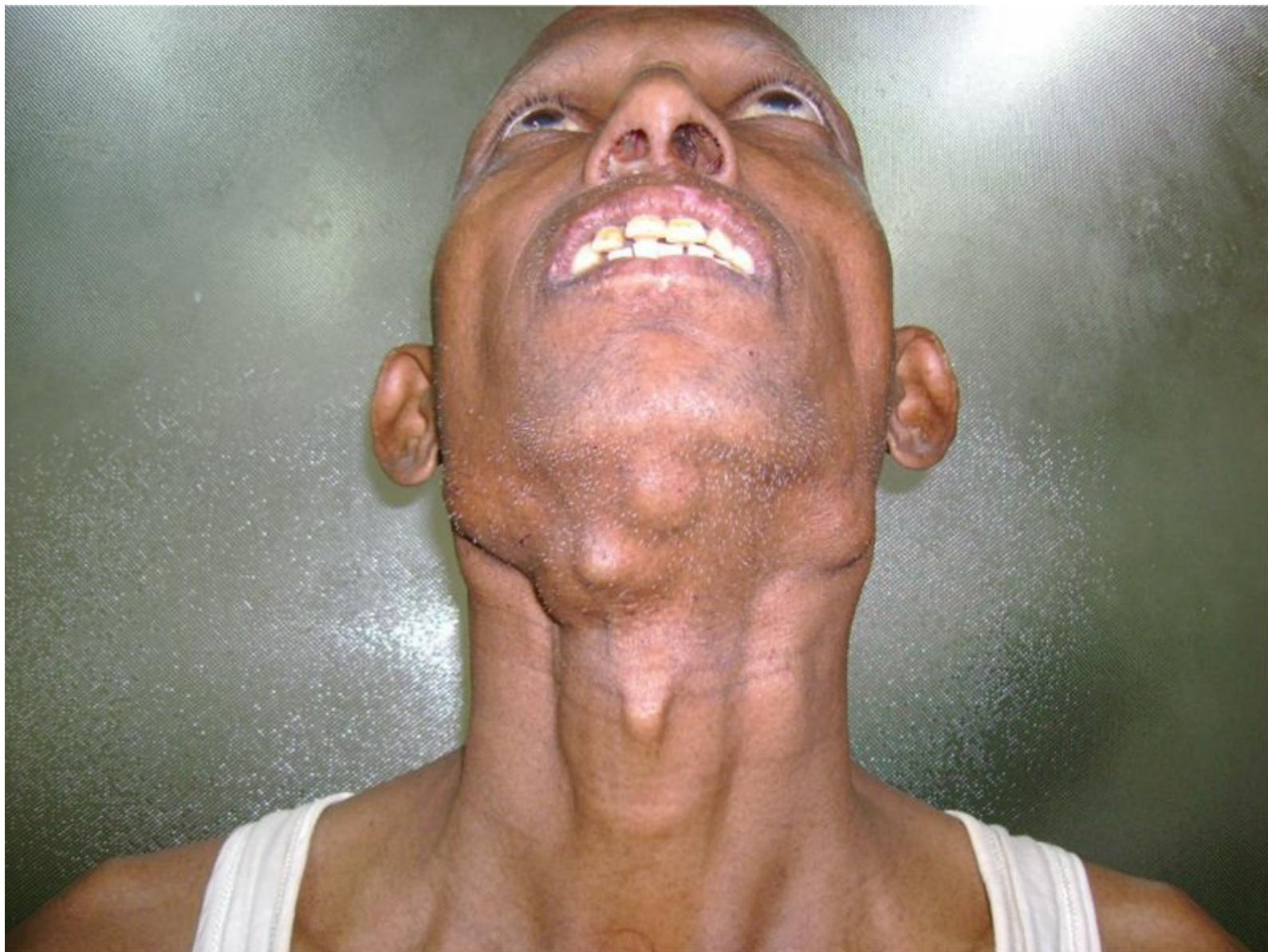
X-ray chest, skin test and work-up for other nodal group involvement should be done. Tuberculosis is also becoming more common due to AIDS.

### ***Treatment***

consists of initial 2 months course of four drugs (rifampicin, isoniazid, pyrazinamide and ethambutol) followed by 4 months course of rifampicin and isoniazid. Nodes may initially increase in size during treatment before they finally subside. Surgical excision of lymph node mass or abscess is occasionally required when drug treatment fails.

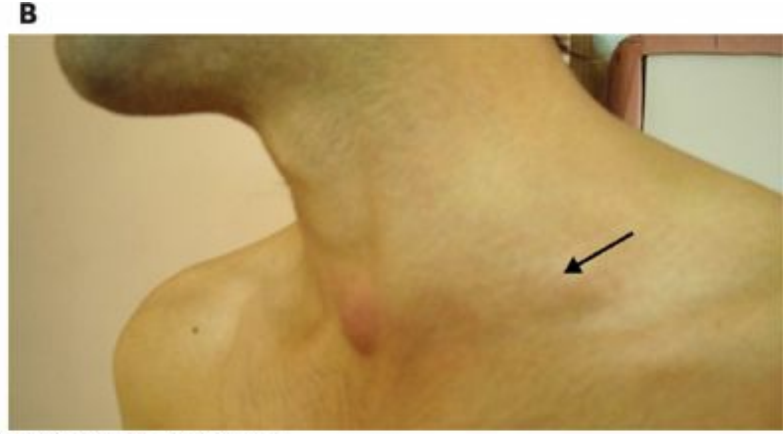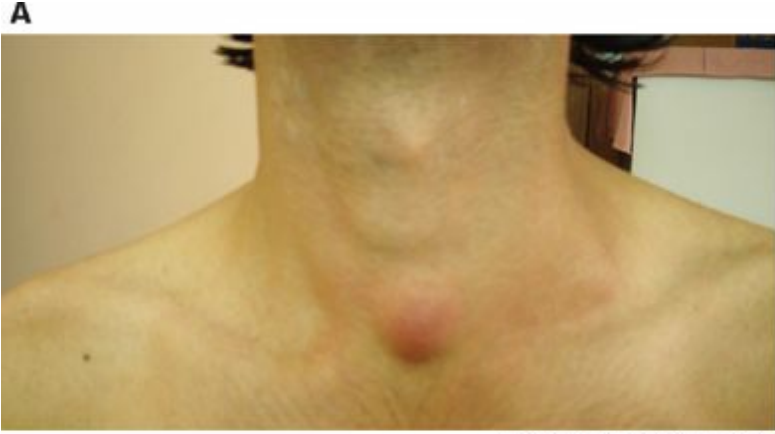## Metastatic Lymph Nodes

Any lymph node group can be involved depending on the site of primary malignancy. Upper cervical lymph nodes are commonly involved in malignancies of upper aerodigestive tract. Nasopharyngeal malignancies spread to accessory chain of nodes in the posterior triangle. In many cases primary malignant lesion is not discernible (occult primary), and in such cases the most common sites are tonsil, base of tongue, nasopharynx and pyriform sinus. Node/nodes in supraclavicular area should alert the surgeon to the possibility of an infraclavicular primary in the lung, breast, stomach, colon, kidney, ovary and testis.



Dhingra: Diseases of Ear Nose and Throat, 5th Edition  
Copyright © 2010 Elsevier. All rights reserved.

Figure 75.7 Multiple tubercular nodes in the neck.



Dhingra: Diseases of Ear Nose and Throat, 5th Edition  
Copyright © 2010 Elsevier. All rights reserved.

Figure 75.8 (A) Caseating tubercular suprasternal node forming abscess. (B) Tubercular nodes in supraclavicular area (same patient).

## Lymphomas

Both Hodgkin's and non-Hodgkin's lymphomas may present with cervical lymphadenopathy. Other lymphatic structures of the Waldeyer ring may also be involved and cause symptoms of dysphagia, serous otitis media or respiratory obstruction. In such cases other lymph nodes in the axilla, groin and abdomen should be examined in addition to spleen and liver enlargement.



## Cervical Rib

Occasionally an extra rib may arise from the 7th cervical vertebra and end anteriorly by attaching to the first rib. This rib may produce a bony hard lump in the supraclavicular region. Most often it is seen on the right but may be present on the left or is bilateral.

Subclavian artery and brachial plexus which normally pass between anterior and middle scalene muscles over the first rib have now to pass over the cervical rib (a vertebral space higher) and are thus compressed. It produces neurological or vascular symptoms. Patient may complain of tingling sensation or numbness along the upper side of forearm and hand due to compression of the lower part of brachial plexus. When subclavian artery is compressed, hand becomes cold and numb with intermittent claudication of upper limb. Due to arterial compression an aneurysm may develop with mural thrombus which may shoot emboli to the distal arterial system of the upper limb. Cervical rib, if asymptomatic, does not require treatment but symptomatic ones are excised by supraclavicular or transaxillary approach.

## Sternomastoid Tumour

Mostly seen in the newborns due to birth trauma. Fibrosis and later shortening of the sternocleidomastoid muscle causes torticollis. Face is turned to opposite side but the head is tilted on the ipsilateral shoulder. A mass can be palpated in the sternocleidomastoid muscle on physical examination. In long-standing cases, asymmetry of face and head can develop as a sequel.

### ***Treatment***

is passive exercises of the neck in early stages. Surgery is done when the condition is persistent and likely to causes facial hemihypoplasia. It consists of division of sternomastoid muscle.

---

page 403

page 404

page 404

page 405

## **SECTION IX Operative Surgery**

---

page 405

page 406

## **76 Myringotomy**

It is incision of the tympanic membrane with the purpose to drain suppurative or nonsuppurative effusion of the middle ear or to provide aeration in case of malfunctioning eustachian tube. Ventilation tube (grommet) may also be required in the latter case.

# Indications

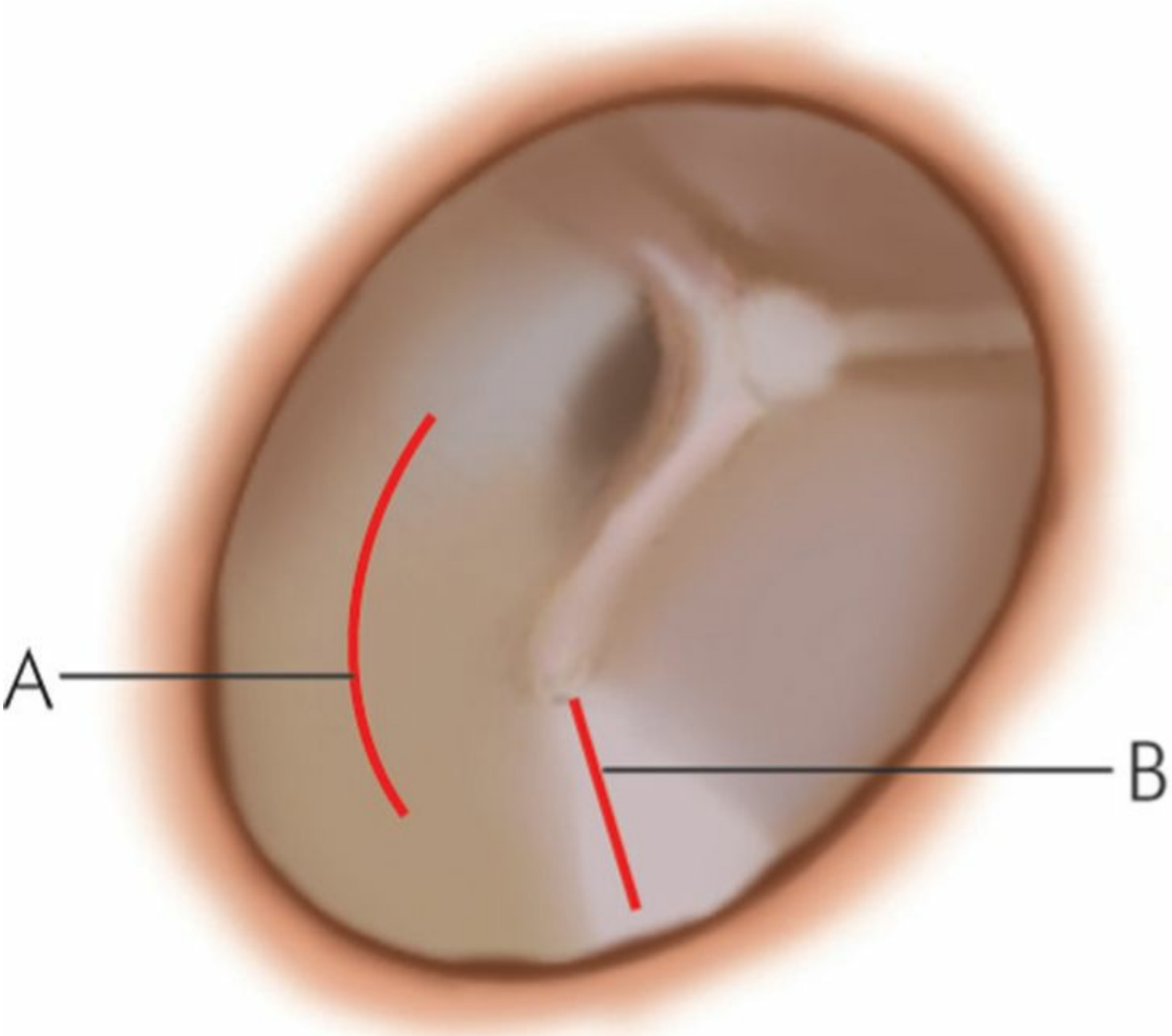
- **1. Acute suppurative otitis media**
  - (a) Severe earache with bulging tympanic membrane.
  - (b) Incomplete resolution with opaque drum and persistent conductive deafness.
  - (c) Complications of acute otitis media, e.g. facial paralysis, labyrinthitis or meningitis with bulging tympanic membrane.
- **2. Serous otitis media.**
- **3. Aero-otitis media** (to drain fluid and "unlock" the eustachian tube).
- **4. Atelectatic ear** (grommet is often inserted for long-term aeration).

## Contraindications

Suspected intratympanic glomus tumour. Myringotomy in these cases can cause profuse bleeding. Tympanotomy is preferred.

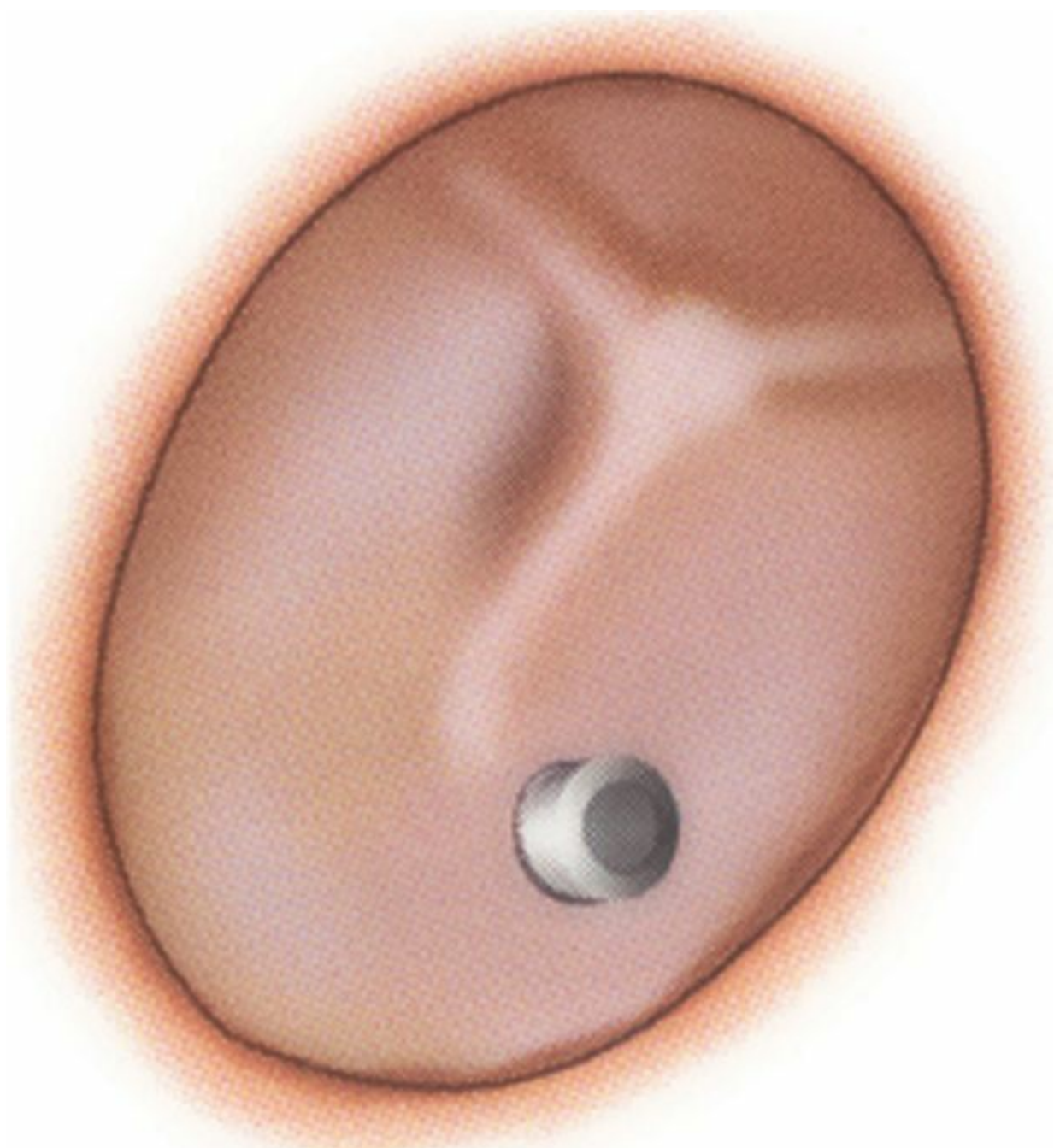
## Anaesthesia

In infants and children, always use general anaesthesia. For adults, general anaesthesia is used only when tympanic membrane is acutely inflamed. If there is no inflammation, myringotomy can be done under local anaesthesia or no anaesthesia at all.



Dhingra: Diseases of Ear Nose and Throat, 5th Edition  
Copyright © 2010 Elsevier. All rights reserved.

Figure 76.1 (A) Circumferential incision used in acute suppurative otitis media. (B) Radial incision used in serous otitis media.



Dhingra: Diseases of Ear Nose and Throat, 5th Edition  
Copyright © 2010 Elsevier. All rights reserved.

Figure 76.2 Grommet in tympanic membrane.

page 407

page 408

- 1. Ear canal is cleaned of wax and debris.
- 2. Operation is ideally performed under operating microscope using a sharp myringotome and a good suction apparatus.
- 3. In acute suppurative otitis media, a circumferential incision is made in the posteroinferior quadrant of tympanic membrane, midway between handle of malleus and tympanic annulus, avoiding injury to incudostapedial joint (Fig. 76.1A).
- 4. In serous otitis media, a small radial incision is given in the posteroinferior or anteroinferior quadrant and all the effusion sucked out (Fig. 76.1B).

When ventilation tube is to be inserted, incision should be just enough to admit the tube (Fig. 76.2).



## Pitfalls of Myringotomy

- **1.** When tympanic membrane is thick, incision may remain only in the superficial layers of drumhead without cutting through its entire thickness.
- **2.** Incision in the posterior meatal wall. This may happen when distinction between drum-head and posterior meatal wall is lost, when both are inflamed.

## Post-operative Care

Daily mopping of ear discharge will be required in cases of acute suppurative otitis media. In serous otitis media, just leave a wad of cotton wool for 24-48 hours.

Drum incisions usually heal rapidly. No water should be permitted to enter the ear canal for at least one week, and if a grommet has been inserted, entry of water is prevented so long as grommet is in position.

## Complications

- 1. Injury to incudostapedial joint or stapes.
- 2. Injury to jugular bulb with profuse bleeding, if jugular bulb is high and floor of the middle ear dehiscent.
- 3. Middle ear infection.

## **77 Mastoid Surgery**

### **TERMINOLOGY FOR OPERATIONS PERFORMED FOR CHRONIC EAR INFECTIONS**

#### **Myringoplasty**

It is an operation in which reconstructive procedure is limited to repair of tympanic membrane perforation.

## Tympanoplasty Without Mastoidectomy (tympanum = middle ear)

It is an operation to eradicate disease in the middle ear and to reconstruct the hearing mechanism without mastoid surgery, with or without tympanic membrane grafting. This means ossicular reconstruction only or ossicular reconstruction with myringoplasty.

## Tympanoplasty With Mastoidectomy

It is an operation to eradicate disease in both the mastoid and middle ear cavity, and to reconstruct the hearing mechanism with or without tympanic membrane grafting.

## Cortical Mastoidectomy (Simple Mastoidectomy or Schwartz Operation)

It is an exenteration of all *accessible* mastoid air cells preserving the posterior meatal wall.

## Modified Radical Mastoidectomy

It is an operation to eradicate disease of the attic and mastoid, both of which are exteriorised into the external auditory canal by removal of the posterior meatal and lateral attic walls. Tympanic membrane remnant, functioning ossicles and the reversible mucosa and function of the eustachian tube are preserved. These structures are necessary to reconstruct hearing mechanism at the time of surgery or in a 2nd stage operation.



## Radical Mastoidectomy

It is an operation to eradicate disease of the middle ear and mastoid in which mastoid, middle ear, attic and the antrum are exteriorised into the external ear by removal of posterior meatal wall. All remnants of tympanic membrane, malleus, incus (not the stapes) chorda tympani and the mucoperiosteal lining are removed, and the opening of eustachian tube closed by packing a piece of muscle or cartilage into the eustachian tube.

## Meatoplasty

Meatoplasty is an operation in which a crescent of conchal cartilage is excised to widen the meatus. It is invariably combined with all canal wall down procedures, i.e. modified radical and radical mastoidectomies for easy access to mastoid cavity for periodic inspection and cleaning. It is also done as an isolated procedure in a sagging auricle seen in older people. Sagging auricle obstructs the ear canal and causes hearing loss and retention of wax.

## Mastoid Obliteration

It is an operation to eradicate mastoid disease, when present, and to obliterate the mastoid cavity. Obliteration of mastoid cavity is done with pedicled temporalis muscle or musculofascial tissue raised as flaps.

# SURGICAL APPROACHES TO THE EAR AND INCISIONS

## 1. Endomeatal or transcanal approach

It is used to raise a tympanomeatal flap in order to expose the middle ear. *Rosen's incision* is the most commonly used for stapedectomy. It requires the meatus and canal to be wide enough to work. It consists of two parts; (a) a small vertical incision at 12 o'clock position near the annulus and (b) a curvilinear incision starting at 6 o'clock position to meet the 1st incision in the posterosuperior region of the canals, 5-7 mm away from the annulus (Fig. 77.1) Posterior meatal canal skin is raised in continuity with tympanic membrane, after dislocating the annulus from the sulcus. It gives a good view of the middle ear and ossicles. Stapes, if still covered by posterosuperior overhang of bony meatus, can be exposed by removing this part of the overhang. This incision is also used commonly for exploratory tympanotomy to find cause for conductive hearing loss, inlay myringoplasty or ossicular reconstruction.

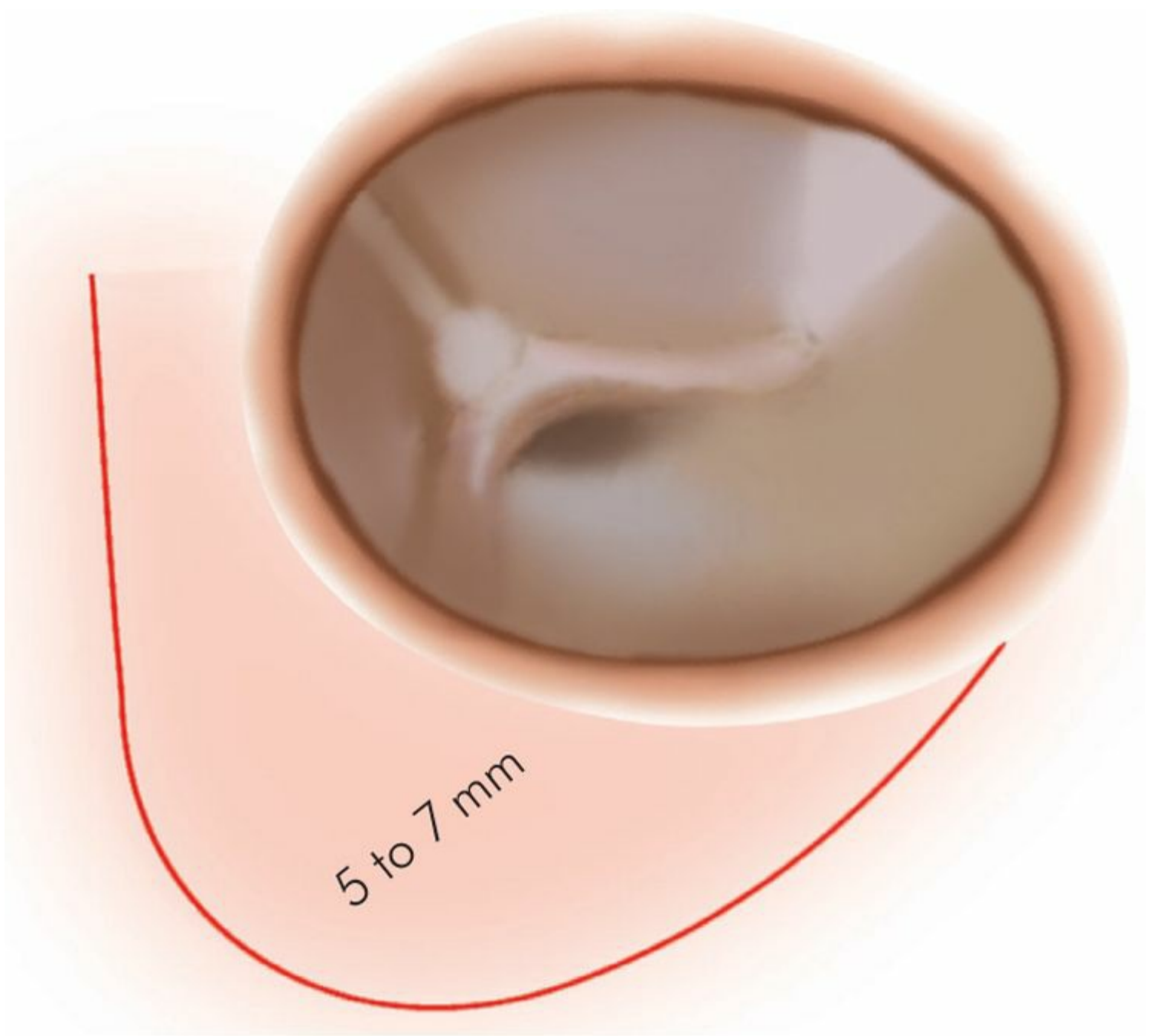
## 2. Endaural approach

It is used for:

- (a) Excision of osteomas or exostosis of ear canal.
- (b) Large tympanic membrane perforations.
- (c) Attic cholesteatomas with limited extension into the antrum.
- (d) Modified radical mastoidectomy where disease is limited to attic, antrum, and part of mastoid.

Endaural approach is made through Lempert's incision (Fig. 77.2). It consists of 2 parts:

Lempert I-It is semicircular incision, made from 12 o'clock to 6 o'clock position in the posterior meatal wall at the bony-cartilaginous junction.

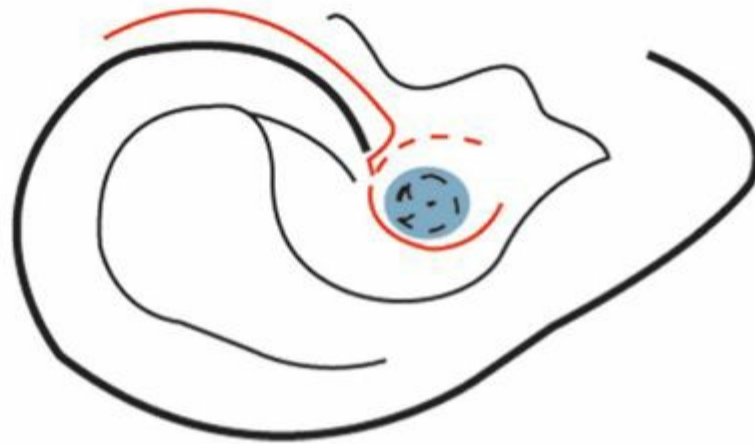


Dhingra: Diseases of Ear Nose and Throat, 5th Edition  
Copyright © 2010 Elsevier. All rights reserved.

Figure 77.1 Rosen's incision.

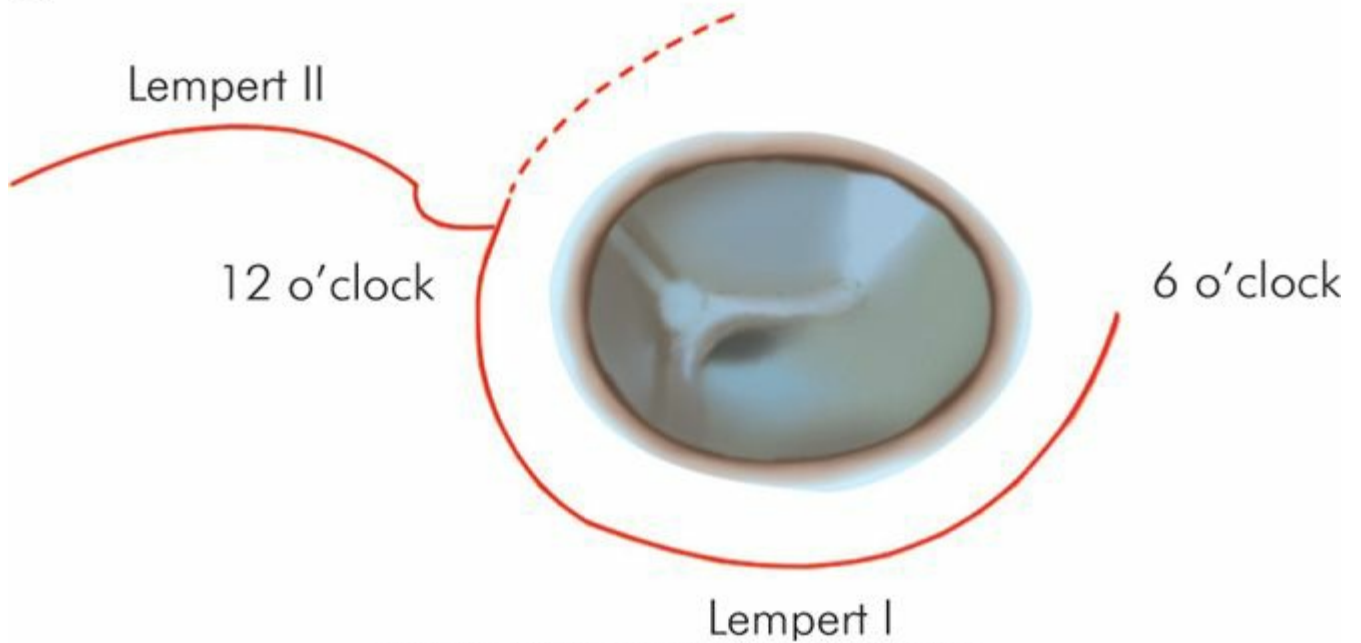
Lempert II-Starts from the 1st incision at 12 o'clock and then passes upwards in a curvilinear fashion between tragus and the crus of helix. It passes through the incisura terminalis and thus does not cut the cartilage. Both mastoid and external canal surgery can be done.

**A**



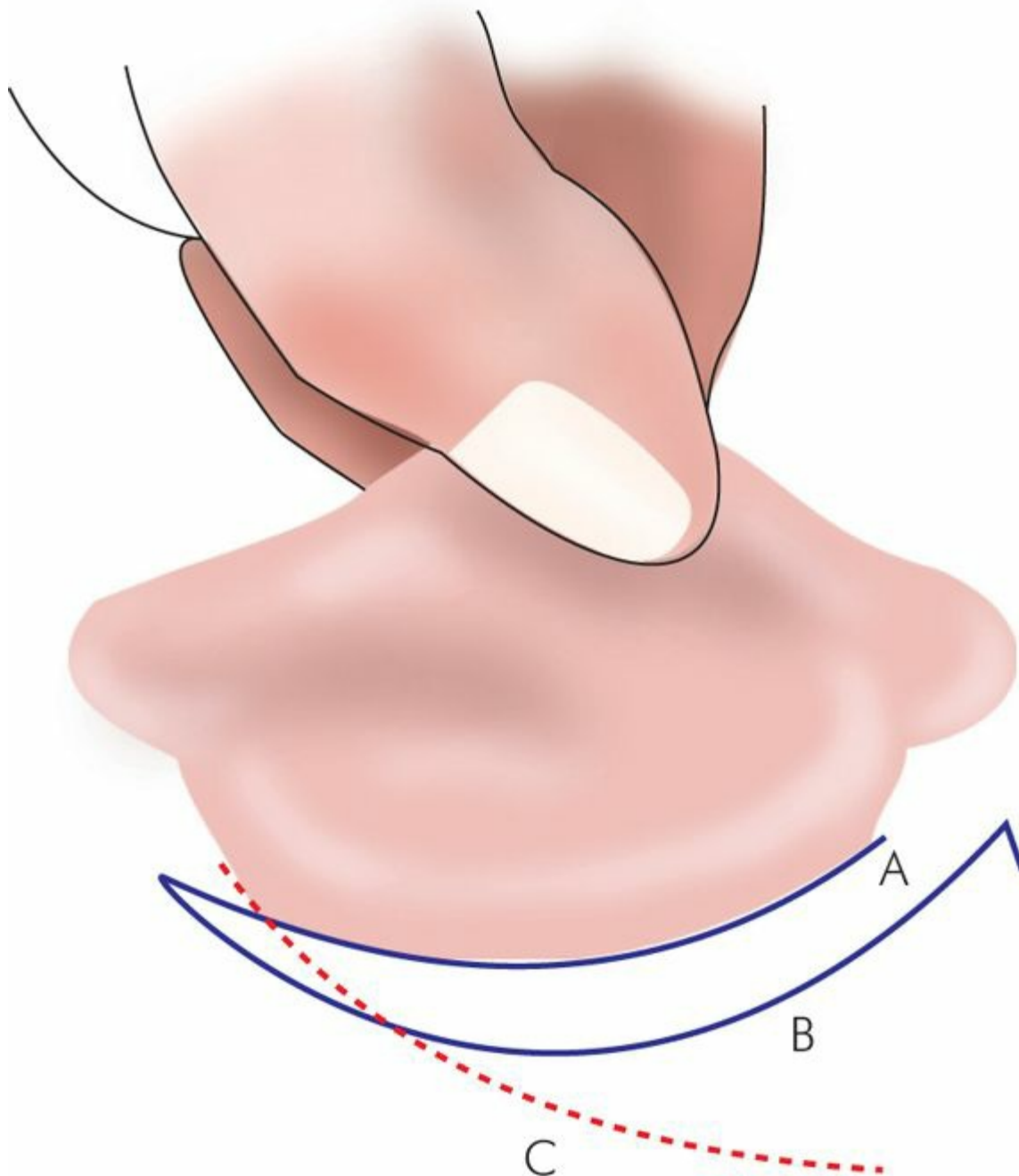
Lempert's endaural incision

**B**



Dhingra: Diseases of Ear Nose and Throat, 5th Edition  
Copyright © 2010 Elsevier. All rights reserved.

Figure 77.2 Endaural (Lempert's) incision. (A) Incision in the canal and incisura terminalis. (B) Magnified view of A. Note position of Lempert I and Lempert II incisions.



Dhingra: Diseases of Ear Nose and Throat, 5th Edition  
 Copyright © 2010 Elsevier. All rights reserved.

Figure 77.3 Types of postaural incisions (A) Sulcus incision. (B) Postaural incision in adults. (C) Postaural incision in infants.

### 3. Postaural (or Wilde's) incision (Fig. 77.3)

It starts at the highest attachment of the pinna, follows the curve of retroauricular groove, lying 1 cm behind it, and ends at the mastoid tip. In infants and children up to 2 years of age, the mastoid process is not developed and the facial nerve lies exposed near its exit, and the incision therefore is slanting posteriorly, avoiding lower part of the mastoid. Some surgeons prefer to make the postaural incision in the sulcus (retroauricular groove). Postaural incision is used for:

- (i) Cortical mastoidectomy.
- (ii) Modified radical and radical mastoidectomy.
- (iii) Tympanoplasty: when perforation extends anterior to handle of malleus.
- (iv) Exposure of CN VII in vertical segment.
- (v) Surgery of endolymphatic sac.

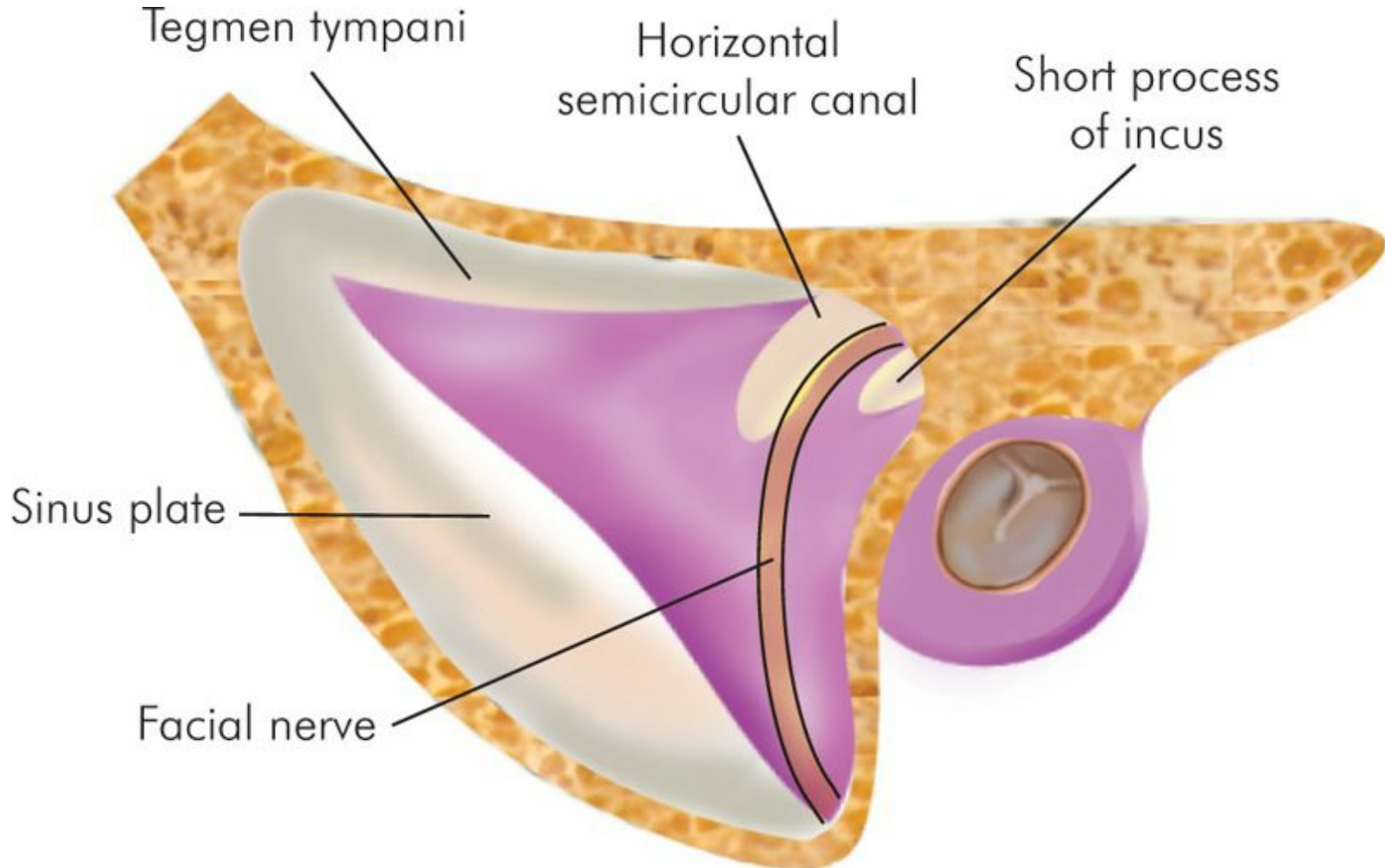
## CORTICAL MASTOIDECTOMY

Cortical mastoidectomy, known as *simple* or *complete* mastoidectomy or *Schwartz operation*, is complete exenteration of all accessible mastoid air cells and converting them into a single cavity. Posterior meatal wall is left intact (Fig. 77.4.) Middle ear structures are not disturbed.



## Indications

- 1. Acute coalescent mastoiditis.
- 2. Incompletely resolved acute otitis media with reservoir sign.
- 3. Masked mastoiditis.
- 4. As an initial step to perform:
  - (a) endolymphatic sac surgery
  - (b) decompression of facial nerve
  - (c) translabyrinthine or retro-labyrinthine procedures for acoustic neuroma.



Dhingra: Diseases of Ear Nose and Throat, 5th Edition  
Copyright © 2010 Elsevier. All rights reserved.

Figure 77.4 Cortical mastoidectomy . Posterior meatal wall is left intact.

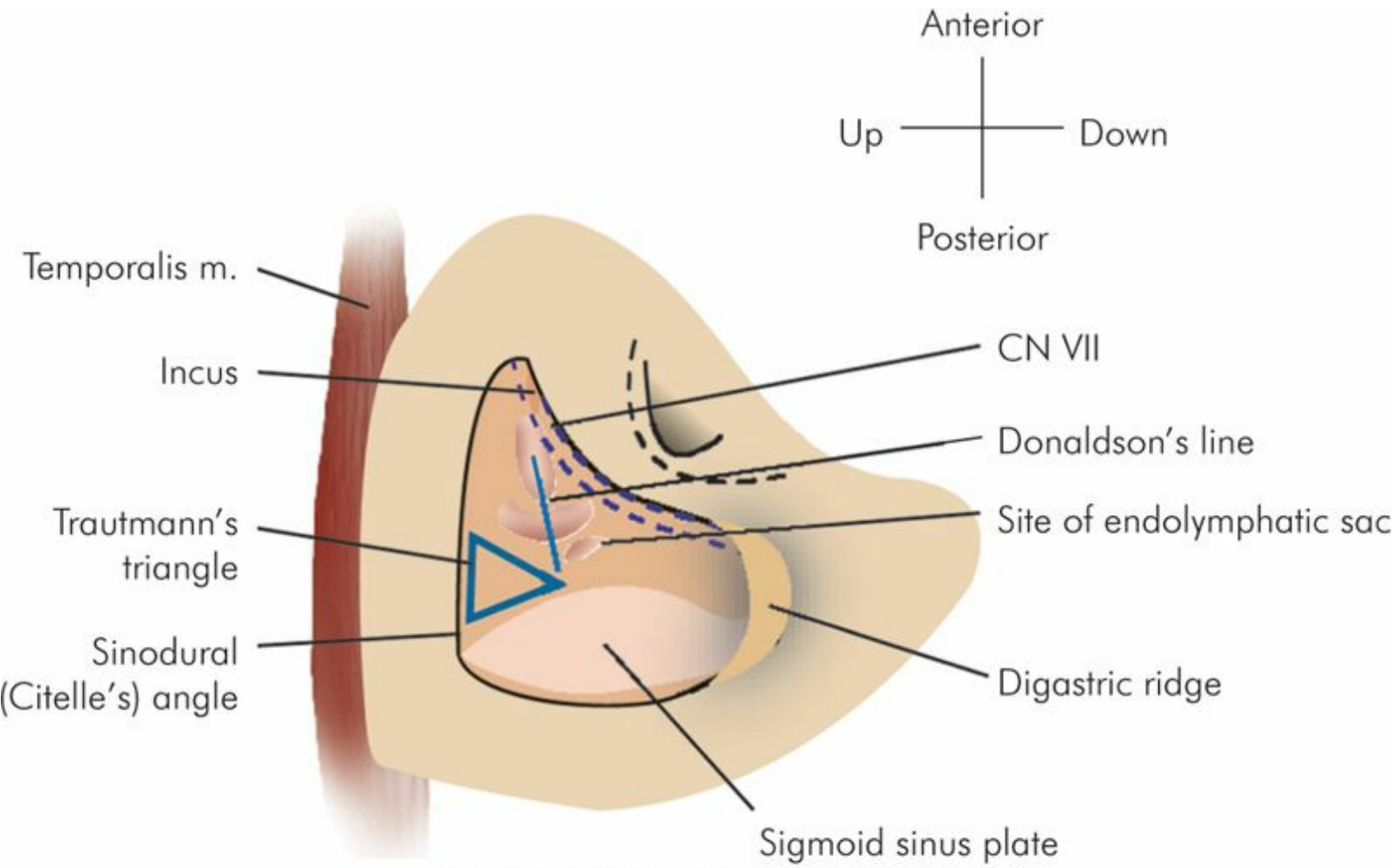
Figure 77.5 shows the various structures and landmarks seen after cortical mastoidectomy.

# Anaesthesia

General anaesthesia.

**Position**

Patient lies supine with face turned to one side and the ear to be operated upper-most.



Dhingra: Diseases of Ear Nose and Throat, 5th Edition  
Copyright © 2010 Elsevier. All rights reserved.

Figure 77.5 Various structures and landmarks seen after cortical mastoidectomy.

# Steps of Operation

## **1. Incision**

A curved postaural incision about 1 cm behind but parallel to the retroauricular sulcus, starting at the highest attachment of pinna to the mastoid tip (Fig. 77.3B).

In infants and children up to 2 years, the incision is short and more horizontal. This is to avoid cutting facial nerve which is superficial in the lower part of mastoid (Fig. 77.3C).

Incision cuts through soft tissues up to the periosteum. Temporalis muscle is not cut in the incision.

## **2. Exposure of lateral surface of mastoid and MacEwen's triangle**

Periosteum is incised in the line of first incision. A horizontal incision may be made along the lower border of temporalis muscle for more exposure.

Periosteum is scraped from the surface of mastoid and posterosuperior margin of osseous meatus. Tendinous fibres of sternomastoid are sharply cut and scraped down. A self-retaining mastoid retractor is applied.

## **3. Removal of mastoid cortex and exposure of antrum**

Mastoid cortex is removed with burr, or gouge and hammer. Mastoid antrum is exposed in the area of suprameatal triangle (MacEwen's triangle). In an adult, antrum lies 12-15 mm from the surface. Horizontal semicircular canal is identified.

## **4. Removal of mastoid air cells**

All accessible mastoid air cells are removed leaving behind the bony plate of tegmen tympani above, sinus plate behind and posterior meatal wall in front.

## **5. Removal of mastoid tip and finishing the cavity**

Lateral wall of the mastoid tip is removed, exposing muscle fibres of posterior belly of digastric. Zygomatic cells situated in the root of zygoma, retrosinus cells lying between sinus plate and cortex, behind the sinus, are removed. A finished cavity should have bevelled edges so that soft tissue can easily sit in and obliterate the cavity.

## **6. Closure of wound**

Mastoid cavity is thoroughly irrigated with saline to remove bone dust, and the wound is closed in two layers. A rubber drain may be left at the lower end of incision for 24-48 hours in case of infection or excessive bleeding. A meatal pack should be kept to avoid stenosis of ear canal. Mastoid dressing is applied.

## Post-operative Care

- **1.** Antibiotics started pre-operatively are continued post-operatively for at least one week. Culture swab taken from the mastoid, during operation, may dictate a change in the antibiotic.
- **2.** Drain, if put, is removed in 24-48 hours and sterile dressing done.
- **3.** Stitches are removed on the 6th day.

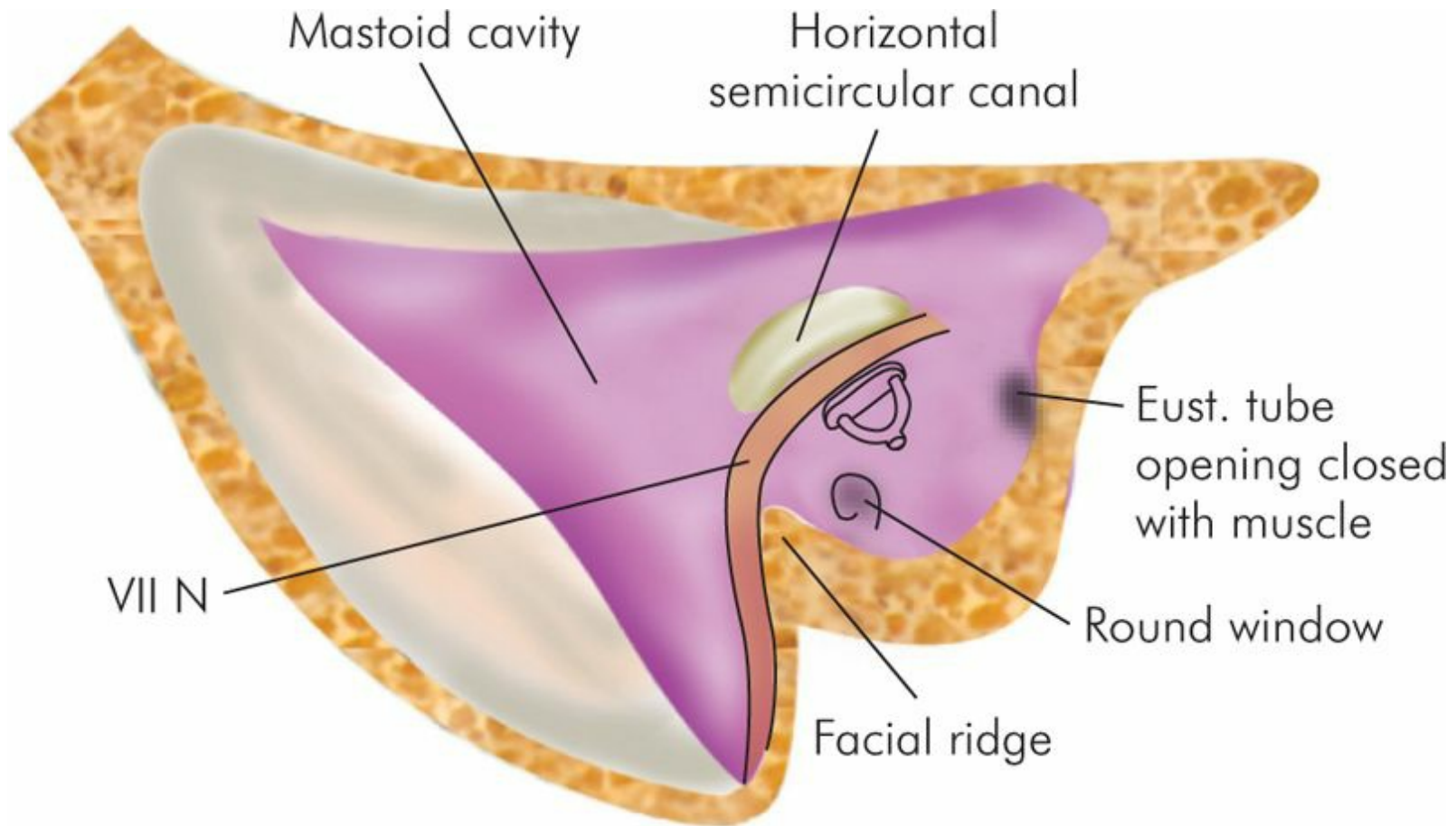
## Complications

- 1. Injury to facial nerve.
- 2. Dislocation of incus.
- 3. Injury to horizontal semicircular canal. Patient will have post-operative giddiness and nystagmus.
- 4. Injury to sigmoid sinus with profuse bleeding.
- 5. Injury to dura of middle cranial fossa.
- 6. Post-operative wound infection and wound break-down.

## **78 Radical Mastoidectomy**

Radical Mastoidectomy is a procedure to eradicate disease from the middle ear and mastoid without any attempt to reconstruct hearing. Posterior meatal wall is removed and the entire area of middle ear, attic, antrum and mastoid is converted into a single cavity. All remnants of tympanic membrane, ossicles (except stapes footplate) and mucoperiosteal lining are removed (Fig. 78.1). Eustachian tube is obliterated by a piece of muscle or cartilage. Aim of the operation is to permanently exteriorise the diseased area for inspection and cleaning. The radical mastoidectomy is infrequently required these days.

## Indications



Dhingra: Diseases of Ear Nose and Throat, 5th Edition  
Copyright © 2010 Elsevier. All rights reserved.

Figure 78.1 Radical mastoidectomy. The entire area of mastoid, middle ear, attic and antrum is exteriorised. Eustachian tube is obliterated and no attempt is made to reconstruct the hearing mechanism.

- 1. When all cholesteatoma cannot be safely removed, e.g. that invading eustachian tube, round window niche, perilyabyrinthine or hypotympanic cells.
- 2. If previous attempts to eradicate chronic inflammatory disease or cholesteatoma have failed.
- 3. As an approach to petrous apex.
- 4. Removal of glomus tumour.
- 5. Carcinoma middle ear. Radical mastoidectomy followed by radiotherapy is an alternative to en bloc removal of temporal bone in carcinoma middle ear.



# Anaesthesia

Mostly, general anaesthesia is given. Local anaesthesia can be used in selected cases.

# Position

Same as for cortical mastoidectomy.

# Steps of Operation

## **1. Incision**

Postaural (Fig. 78.2) or endaural (Fig. 78.3).

## **2. Retraction of soft tissues and exposure of mastoid area**

Mastoid area from posterior root of zygoma to behind the suprameatal triangle and from temporal line above to the lower part of mastoid tip below is exposed by elevating the periosteum and the wound retracted.

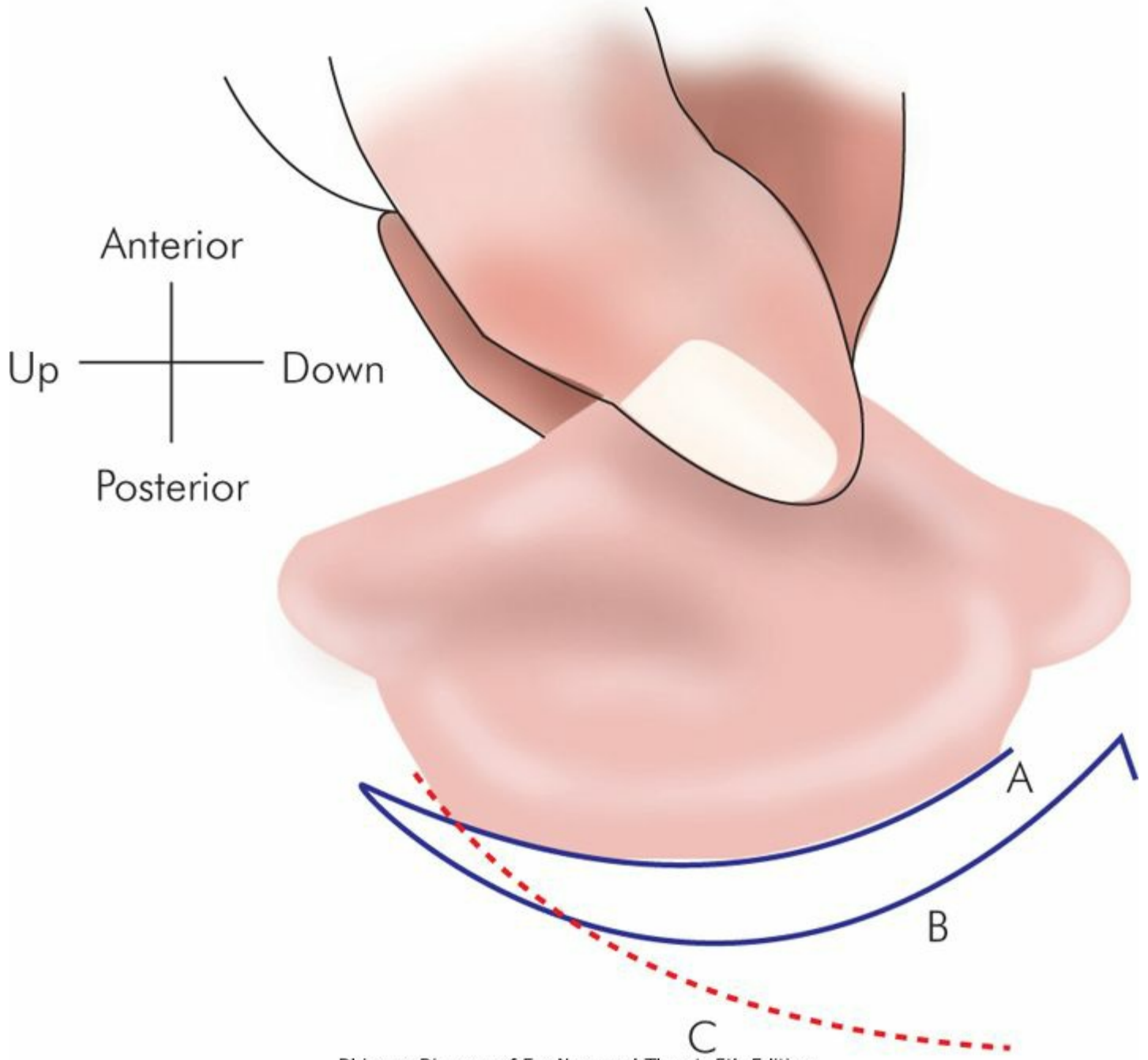
## **3. Removal of bone and exposure of attic and antrum**

With the help of burr, bone is removed from the area of suprameatal triangle, spine of Henle, root of zygoma to just above the anterior meatal wall, upper part of superior meatal wall is also removed. This will expose attic and antrum. Identify the tegmen antri and lateral semicircular canal.

## **4. Removal of the "bridge" and the buttresses**

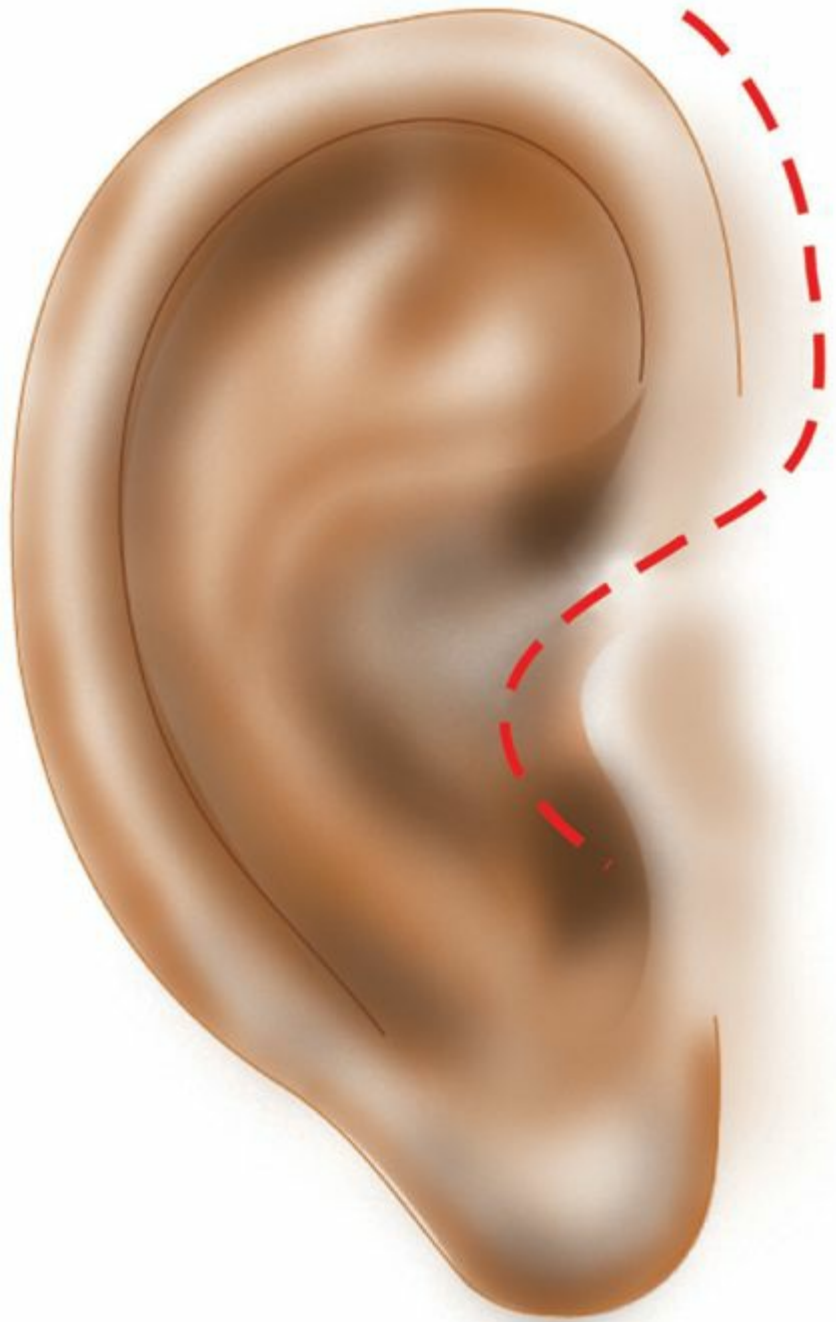
Deeper part of superior osseous meatal wall that bridges over the notch of Rivinus is removed.

Anterior spine of the notch (anterior buttress) and posterior spine of the notch (posterior buttress) are also removed. This removes the lateral attic wall. The incus and the malleus are also removed.



Dhingra: Diseases of Ear Nose and Throat, 5th Edition  
Copyright © 2010 Elsevier. All rights reserved.

Figure 78.2 Types of postaural incisions.



Dhingra: Diseases of Ear Nose and Throat, 5th Edition  
Copyright © 2010 Elsevier. All rights reserved.

Figure 78.3 Endaural incision.

#### **5. Lowering the facial ridge**

The deeper part of posterior meatal wall that overlies the vertical part of facial nerve is called facial ridge. It is removed as much as possible within the safety of VIIth nerve so that the mastoid cavity is freely accessible from the meatus.

#### **6. Toilet of middle ear**

Remnants of tympanic membrane with its annulus and sulcus tympanicus are removed. Middle ear mucoperiosteum along with any polyp or granulation tissue is removed. Malleus and incus are removed if not already done. Stapes is left intact. Eustachian tube opening is closed by curetting its mucosa and plugging the opening with tensor tympani muscle or piece of cartilage.

#### **7. Inspection of the cavity and irrigation**

It is necessary to ensure complete exteriorisation of the attic, antrum and middle ear and mastoid cavity into external auditory meatus. Any bony overhangs are removed and cavity smoothed with polishing burr. Finally, it is irrigated with saline to remove any blood or bone particles.

#### **8. Meatoplasty**

A flap, based laterally at the concha is raised from posterior and superior meatal wall and turned into the mastoid cavity to cover the area of the facial ridge. This helps in the epithelialisation of the mastoid cavity. A piece of conchal cartilage can be removed to enlarge the meatus and to

facilitate inspection and access to cavity.

### **9. Obliteration of the cavity**

If mastoid cavity is very large, it may be obliterated with temporalis muscle or other soft tissues, taking care that no vestige of disease (cholesteatoma) is buried underneath.

### **10. Closure of wound**

The cavity is packed with ribbon gauze, impregnated with an antibiotic/antiseptic and the wound is closed with interrupted sutures. Mastoid dressing is applied.

# Post-operative Care

## **1. Dressing**

First dressing is done on 3rd or 4th day. Replace the outer gauze and cotton and look for any signs of perichondritis or infection of meatal pack.

Second dressing is done on 6th or 7th day when stitches are removed and meatal pack is changed. Thereafter, change the pack at weekly intervals or leave the cavity unpacked with regular suction and cleaning till epithelialisation is complete.

## **2. Antibiotic**

A suitable antibiotic is given for about a week.

## **3. Cavity care**

Usually, cavity is fully epithelialised in 2-3 months. It should be periodically checked (every 4-6 months) in the first year and then annually for removal of any debris or infection. Any granulation tissue which delays epithelialisation is removed or cauterised.

## Complications

- 1. Facial paralysis.
- 2. Perichondritis of pinna.
- 3. Injury to dura or sigmoid sinus.
- 4. Labyrinthitis, if stapes gets dislocated.
- 5. Severe conductive deafness of 50 dB or more. This is due to removal of all ossicles and tympanic membrane.
- 6. Cavity problems. Twenty five percent of the cavities do not heal and continue to discharge, requiring regular after-care.



## **79 Modified Radical Mastoidectomy**

It is a modification of radical mastoidectomy where as much of the hearing mechanism as possible is preserved. The disease process which is often localised to the attic and antrum is removed and the whole area fully exteriorised into the meatus by removal of the posterior meatal and lateral attic wall (Fig. 79.1).

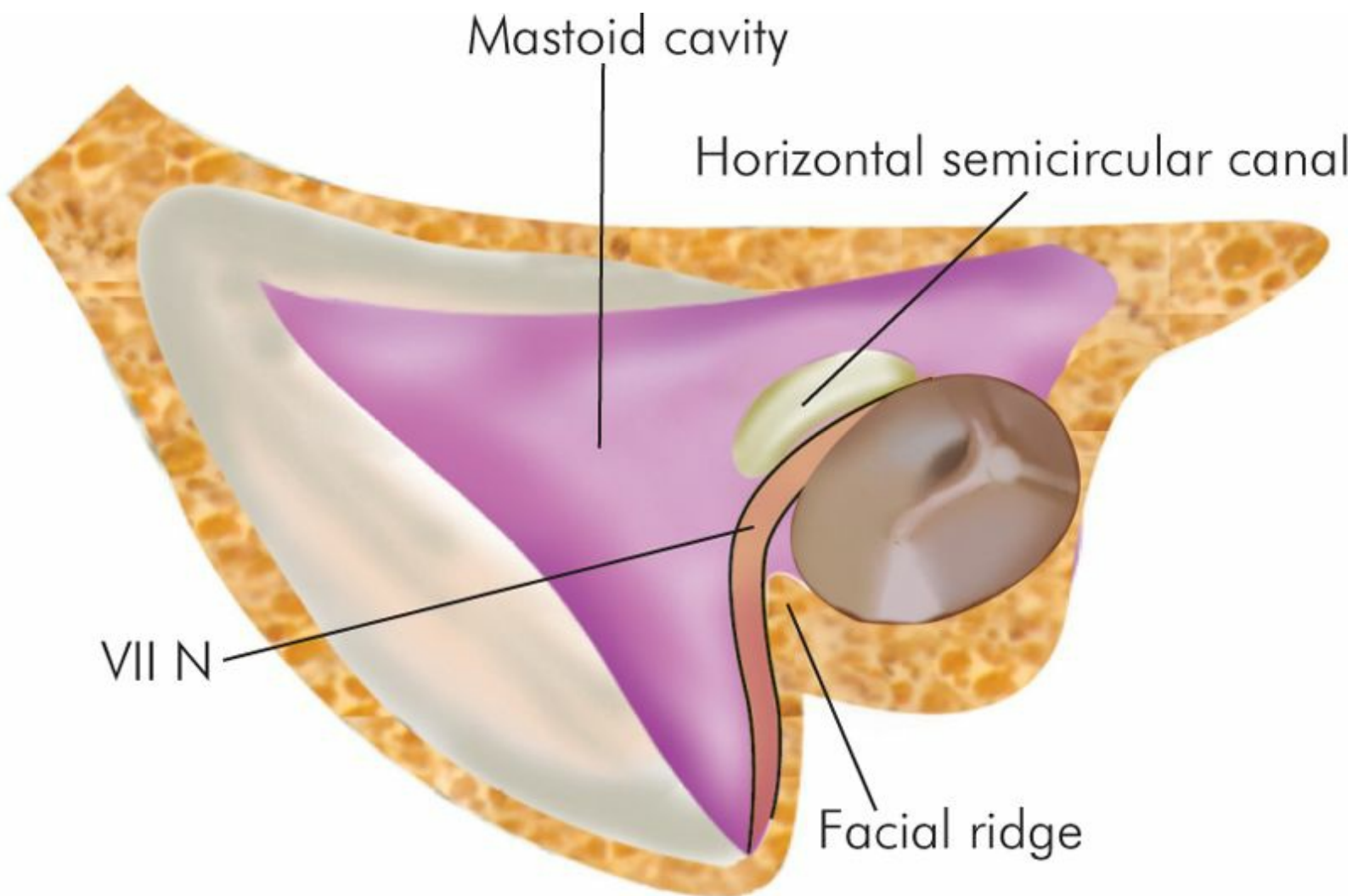
## Indications

- 1. Cholesteatoma confined to the attic and antrum.
- 2. Localised chronic otitis media.

Irreversibly damaged tissues are removed, preserving the rest to conserve or reconstruct hearing mechanism.

# Anaesthesia

Mostly general, local anaesthesia can be used in selected cases.



Dhingra: Diseases of Ear Nose and Throat, 5th Edition  
Copyright © 2010 Elsevier. All rights reserved.

Figure 79.1 Modified radical mastoidectomy . Posterior meatal wall is removed to exteriorise the diseased area into the meatus and the hearing mechanism reconstructed.

# Position

Same as for cortical mastoidectomy.

## Steps of Operation

- 1. Incision, postaural or endaural.
- 2. Retraction of soft tissues and exposure of mastoid area.
- 3. Removal of cortical bone and exposure of antrum and attic.  
Steps 2 and 3 are the same as in radical mastoidectomy.
- 4. Removal of diseased tissue. Cholesteatoma, granulations or unhealthy mucosa is removed. Incus and head of malleus often require removal, if cholesteatoma engulfs them or extends medial to them. They are preserved if possible. Lateral attic wall is removed to fully exteriorise the attic.
- 5. Facial ridge is lowered.
- 6. Mastoid cavity is smoothed with polishing burr, removing any overhangs and then irrigated with normal saline.
- 7. Reconstruction of hearing mechanism. Pars tensa of tympanic membrane and middle ear, if healthy, are left undisturbed. If disease extends into middle ear, only the irreversible tissues are removed. Reconstruction of tympanic membrane or ossicular chain, if damaged, can also be done (mastoidectomy with tympanoplasty operation).
- 8. Meatoplasty and closure of wound is same as in radical mastoidectomy.

# Post-operative Care and Complications

Same as in radical mastoidectomy.

## 80 Myringoplasty

Closure of perforation of pars tensa of the tympanic membrane is called *myringoplasty*. It has the advantage of:

- (i) restoring the hearing loss and in some cases the tinnitus.
- (ii) checking re-infection from external auditory canal and eustachian tube (nasopharyngeal infection ascends easily via eustachian tube in the presence of perforation than otherwise).
- (iii) checking aeroallergens reaching the exposed middle ear mucosa, leading to persistent ear discharge.

Myringoplasty can be combined with ossicular reconstruction when it is called *tympanoplasty*.

Physiologic principles for middle ear reconstruction are discussed on page 35.

## Contraindications

- **(i)** Active discharge from the middle ear.
- **(ii)** Nasal allergy. It should be brought under control before surgery.
- **(iii)** Otitis externa.
- **(iv)** Ingrowth of squamous epithelium into the middle ear. In such cases, excision of squamous epithelium from the middle ear or a tympanomastoidectomy may be required.
- **(v)** When the other ear is dead or not suitable for hearing aid rehabilitation.
- **(vi)** Children below 3 years.



# Anaesthesia

Local or general, the former is preferred.

## Position

Supine with face turned to one side; the ear to be operated is up.

*Graft materials used are:*

- **(i)** Temporalis fascia (most common),
- **(ii)** Perichondrium from the tragus,
- **(iii)** Tragal cartilage,
- **(iv)** Vein.

Incision for exposure of tympanic membrane depends on the size of the ear canal; it may be endomeatal, endaural or postaural.

# Technique

## Underlay Technique

### **1. Harvesting the graft**

of temporalis fascia; or perichondrium from the tragus.

### **2. Preparing the T.M. for grafting**

An incision is made along the edge of perforation and the ring of epithelium removed. Remove also a strip of mucosal layer from the inner side of perforation.

### **3. Inspecting the middle ear**

A stapes-type incision is made and the tympanomeatal flap raised to see the integrity and mobility of the ossicular chain and to ensure that no squamous epithelium has grown into the middle ear.

### **4. Placing the graft**

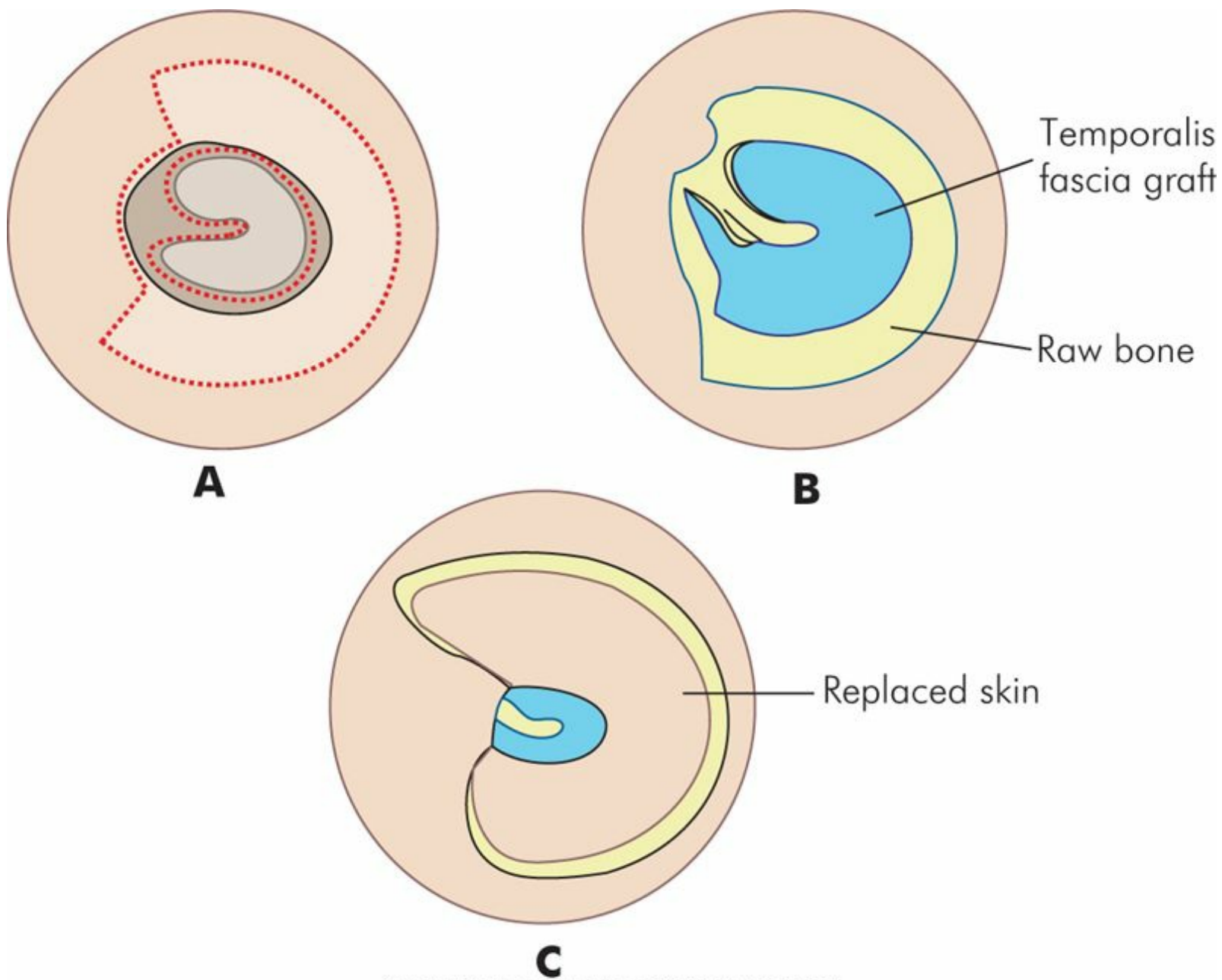
Middle ear is packed with gelfoam soaked with an antibiotic. A proper-sized graft is placed so that its edges extend under the margins of perforation all round and a small part also extends over the posterior canal wall. Tympanomeatal flap is replaced. An underlay technique has the advantage that the squamous epithelium is not buried in the middle ear.

## Overlay Technique

page 416

page 417

- **1.** Temporal fascia or perichondrial graft is harvested as above.
- **2.** Incision is made in the meatus as shown (Fig. 80.1) and meatal skin raised along with all epithelium from the outer surface of tympanic membrane remnant.
- **3.** Graft placed on the outer surface of T.M. A slit is made in the graft to tuck it under the handle of malleus.
- **4.** Meatal skin removed earlier is now replaced, covering the periphery of the graft. Ear canal packed with gelfoam and then with a small antibiotic pack.  
A modification of the overlay technique is to place the anterior edge of fascia graft under the annulus after removing the epithelium. This prevents blunting of anterior canal which is seen as a complication of overlay technique.
- **5.** Closure of endaural or postaural incision.
- **6.** Mastoid dressing.



Dhingra: Diseases of Ear Nose and Throat, 5th Edition  
 Copyright © 2010 Elsevier. All rights reserved.

Figure 80.1 Overlay technique. (A) Incision to raise medial meatal skin with tympanic membrane epithelium. (B) Placement of graft. (C) Replacement of skin.

## Post-operative Care

- 1. Stitches are removed after 5-6 days.
- 2. Ear pack is removed after 5-6 days without disturbing the gelfoam.
- 3. Patient is seen at 3 and 6 weeks after operation.
- 4. Complete epithelialisation of graft takes 6-8 weeks.

# Complications

## Underlay Technique

- 1. Middle ear becomes narrow.
- 2. Graft may get adherent to the promontory.
- 3. Anteriorly, graft may lose contact from the remnant of tympanic membrane leading to anterior perforation.

## Overlay Technique

- 1. *Blunting of the anterior sulcus.*
- 2. *Epithelial pearls.* They are epidermal cysts, when squamous epithelium is buried under the graft.
- 3. *Lateralisation of graft.* Graft loses contact from the malleus handle resulting in conductive loss. It is prevented by tucking the graft under the handle.

# Other Procedures for Closure of Tympanic Membrane Perforation

## **1. Splintage**

It is used in fresh traumatic perforations. The torn edges of the perforation are carefully everted under the microscope and splinted with absorbable gelfoam placed in the middle ear through the tear. Smaller tears can be splinted on the outer surface of the tympanic membrane with a piece of cigarette paper, gelfilm or silicon sheet.

## **2. Cautery-patching**

This is useful in small, long-standing central perforations where the margins, have become epithelialised and chronic. In this procedure, margins, of the perforation are cauterised with 50% trichloroacetic acid to remove the epithelialised edge (or freshened with a fine pick used for myringoplasty) and then supported with a cigarette paper moistened with 1% phenol in glycerine. This procedure can be repeated at two weeks interval. Instead of cigarette paper, other material such as steristrip, gelfilm or silicone sheets have also been used.

## **3. Fat-graft myringoplasty**

It is also used to close small perforations. After local anaesthesia, edges of perforation are freshened with 1 mm stapes hook. The inside of perforation is also scrapped. A small piece of fat harvested from the ear lobule is plugged into the perforation like an hour-glass. Over a time, the fat graft adheres and closes the perforation.

## **81 Proof Puncture (Syn. Antral Irrigation)**

This procedure involves puncturing the medial wall of maxillary sinus in the region of inferior meatus and irrigating the sinus.



## Indications

- 1. Chronic and subacute maxillary sinusitis with dual purpose of: (a) confirming the diagnosis and (b) washing out the pus.
- 2. To collect the specimen of the antral contents for culture and sensitivity, or cytological examination to exclude early malignancy.

## Contraindications

Acute maxillary sinusitis for fear of osteomyelitis.

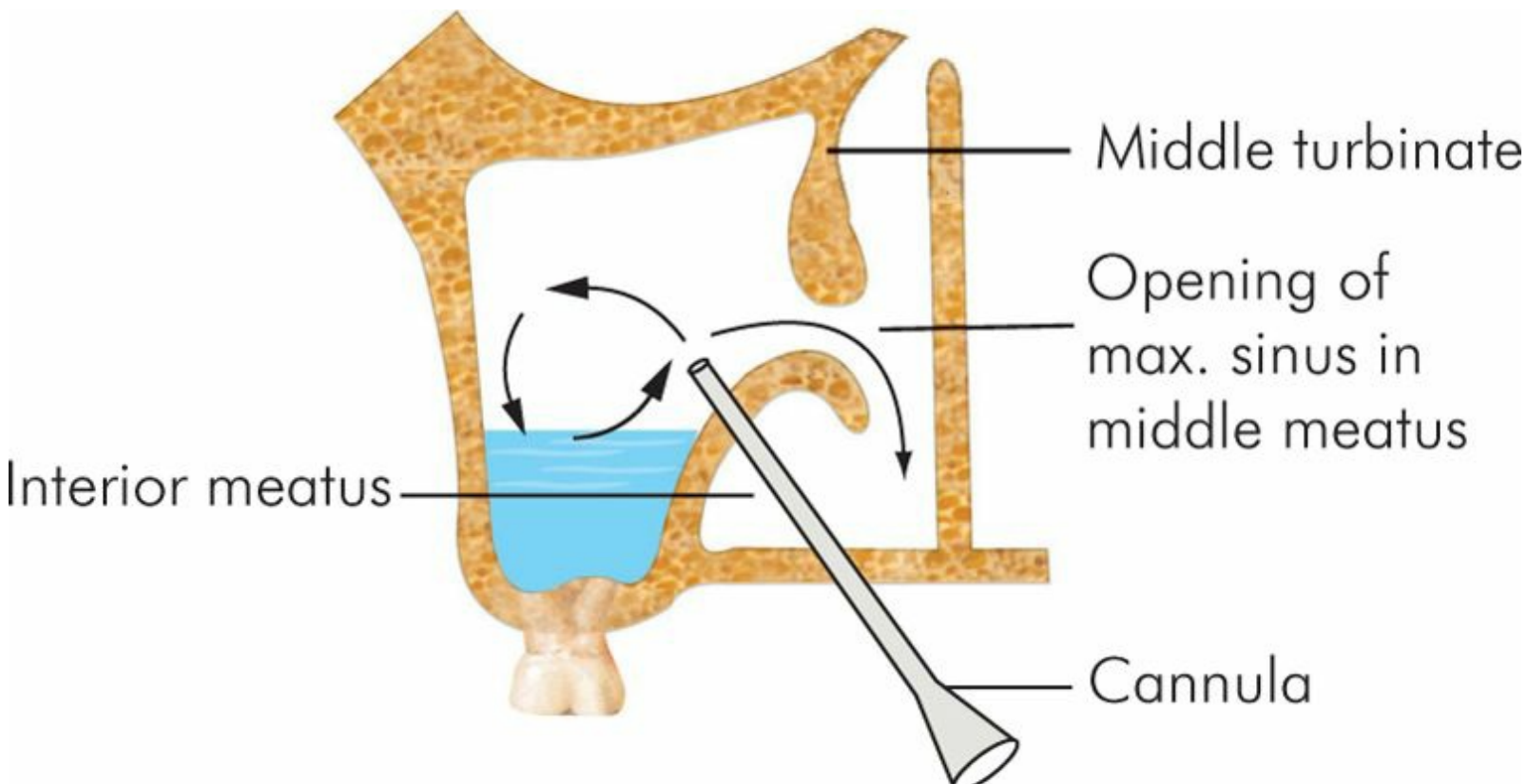
## Anaesthesia

In adults, local anaesthesia is preferred. A pack of 4% lignocaine with adrenaline is kept in inferior meatus for 10 to 15 minutes. In children, general anaesthesia is required. Area of middle meatus should be decongested to open the maxillary ostium for easy return of fluid.

## Position

Sitting position is preferred in all adults, when using local anaesthesia. When using general anaesthesia, patient is placed in tonsillectomy position.

# Technique



Dhingra: Diseases of Ear Nose and Throat, 5th Edition  
Copyright © 2010 Elsevier. All rights reserved.

Figure 81.1 Antral puncture.

The lateral wall of inferior meatus is punctured with Lichtwitz trocar and cannula at a point 1.5-2.0 cm from anterior end of inferior turbinate and near the attachment of concha with lateral wall. Here, the bone is very thin and can be easily pierced. Trocar and cannula are directed towards the homolateral ear. The nasoantral wall pierces with a "crack". Now remove the trocar and advance the cannula till it reaches the opposite antral wall and then withdraw a little. The antrum can now be irrigated with normal saline at 37°C with a 20 ml or Hagginson's syringe (Fig. 81.1). Syringing is continued till return is clear. After the puncture is over, cannula is removed and a pack kept in the inferior meatus to control bleeding.

## Diagnosis of Antral Pathology

- **1.** Thin amber-coloured fluid, flowing from cannula immediately on puncture and containing cholesterol crystals, indicates presence of antral cyst.
- **2.** Blobs of mucopus in washings indicate hyperplastic sinusitis.
- **3.** Presence of foul-smelling pus which easily mixes with irrigating fluid indicates suppuration. In such cases, antral wash may be repeated once or twice a week.

## Post-operative Care

- 1. Pack is removed after about an hour.
- 2. Antibiotics should be given for 5-6 days in cases of suppuration.
- 3. Nasal decongestant drops should be used to improve patency of the ostium.
- 4. Analgesics may be required for headache or post-operative pain.

## Complications

- **1. Swelling of cheek.** This is due to faulty technique. In this case, cannula lies in the soft tissues over the anterolateral wall of the maxilla and has failed to pierce the nasoantral wall.
- **2. Orbital injury and cellulites.** If trocar and cannula pierces the roof of antrum.
- **3. Puncture of the posterior antral wall.** This would cause swelling in posterior part of cheek.
- **4. Bleeding** due to injury to nasal mucosa.
- **5. Air embolism.** It is rare but may prove fatal. This complication can be prevented by avoiding insufflation of air into the antrum after lavage.

*Note:* This operation is now being performed less often. Most surgeons prefer to get a CT to find the middle meatal pathology causing obstruction to sinus ostium and deal with sinus disease and meatal pathology by functional endoscopic sinus surgery (FESS) at the same time.



## **82 Intranasal Inferior Meatal Antrostomy**

Intranasal Inferior Meatal Antrostomy is a process of making an opening in the nasoantral wall of the inferior meatus by intranasal route.

## Indications

Chronic purulent maxillary sinusitis.

## Contraindications

- **1.** Irreversible change in sinus mucosa, e.g. polypoidal hypertrophy.
- **2.** Presence of osteitis.
- **3.** Suspicion of malignancy.

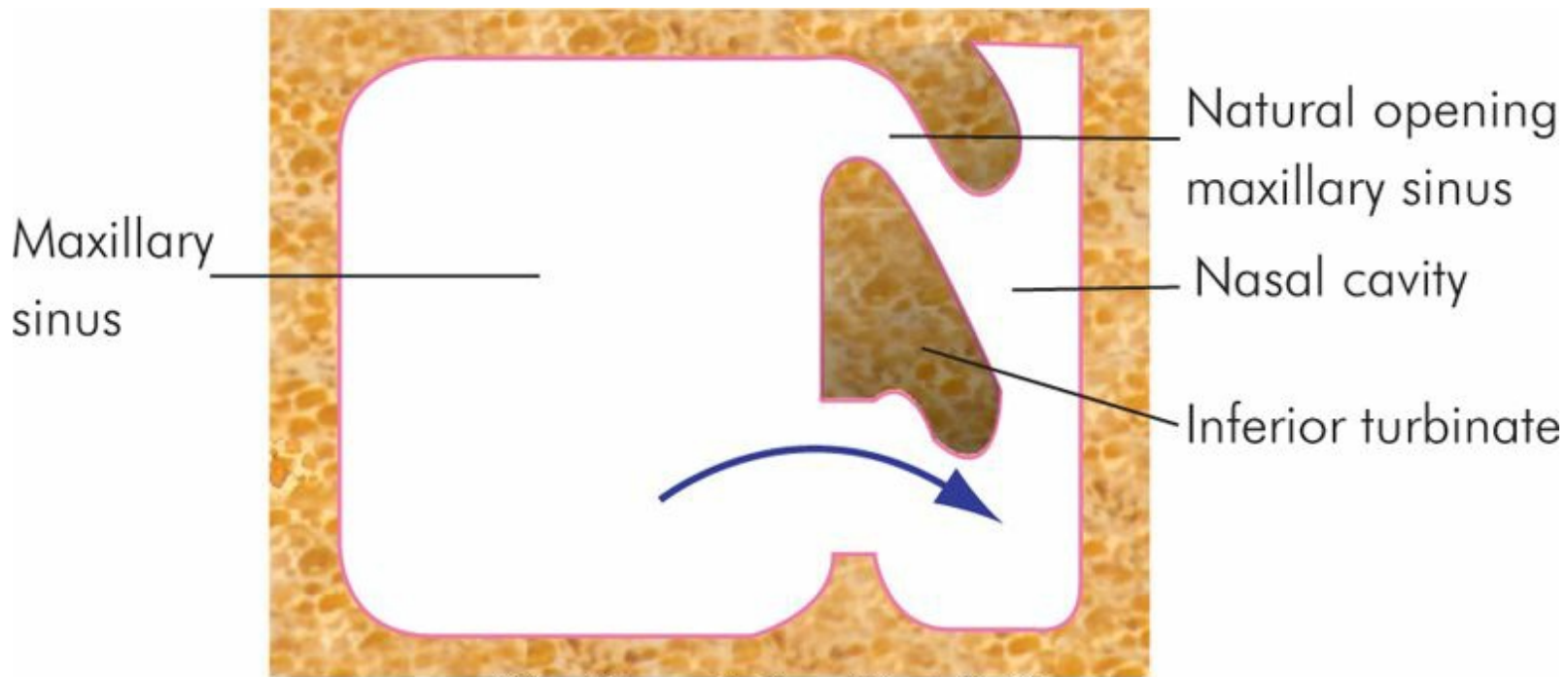
# Anaesthesia

Local or general anaesthesia.

## Position

Same as in submucous resection (SMR) operation (see Chapter 84).

## Technique



Dhingra: Diseases of Ear Nose and Throat, 5th Edition  
Copyright © 2010 Elsevier. All rights reserved.

Figure 82.1 Intranasal antrostomy in the inferior meatus.

Inferior turbinate is fractured medially and upwards with a large periosteal elevator. Nasoantral wall of inferior meatus is perforated with a curved haemostat and then this opening is enlarged, forwards with Kerrison's bone-forceps and backwards with Luc's or side-biting ring forceps. Opening should be 1.5 to 2 cm in diameter and as close to the floor of nose as possible (Fig. 82.1). Intrasinus pus/debris is removed by suction. Packing into the sinus and nose may be required if there is severe bleeding.

## Post-operative Care

Intranasal and nasal pack is removed in 24-48 hours.

# Complications

Few complications.

- 1. Post-operative bleeding.
- 2. Injury to nasolacrimal duct.

*Note:* These days, intranasal antrostomy is performed in the middle meatus. Middle meatal antrostomy is more physiological and is performed with nasal endoscopes and other surgical instruments used in functional endoscopic sinus surgery.



## 83 Caldwell-Luc Operation

Caldwell-Luc operation is a process of opening the maxillary antrum through canine fossa by sublabial approach and dealing with the pathology inside the antrum.

## Indications

- **1.** Chronic maxillary sinusitis with irreversible changes in the sinus mucosa.
- **2.** Removal of foreign bodies or root of a tooth.
- **3.** Dental cyst.
- **4.** Oroantral fistula.
- **5.** Suspected neoplasm in the antrum and its biopsy.
- **6.** Recurrent antrochoanal polyp.
- **7.** Fracture of maxilla or blow-out fractures of the orbit.
- **8.** As an approach to ethmoids (Horgan's transantral ethmoidectomy).
- **9.** Approach to pterygopalatine fossa for ligation of maxillary artery.
- **10.** Vidian neurectomy.

## Contraindications

Patient below 17 years of age.

# Anaesthesia

General anaesthesia with cuffed endotracheal tube and a pharyngeal pack. Can be done under local anaesthesia.

## Position

Reclining with head-end of the table raised. Patient lies supine with face turned slightly to the opposite side.

# Technique

## 1. Incision

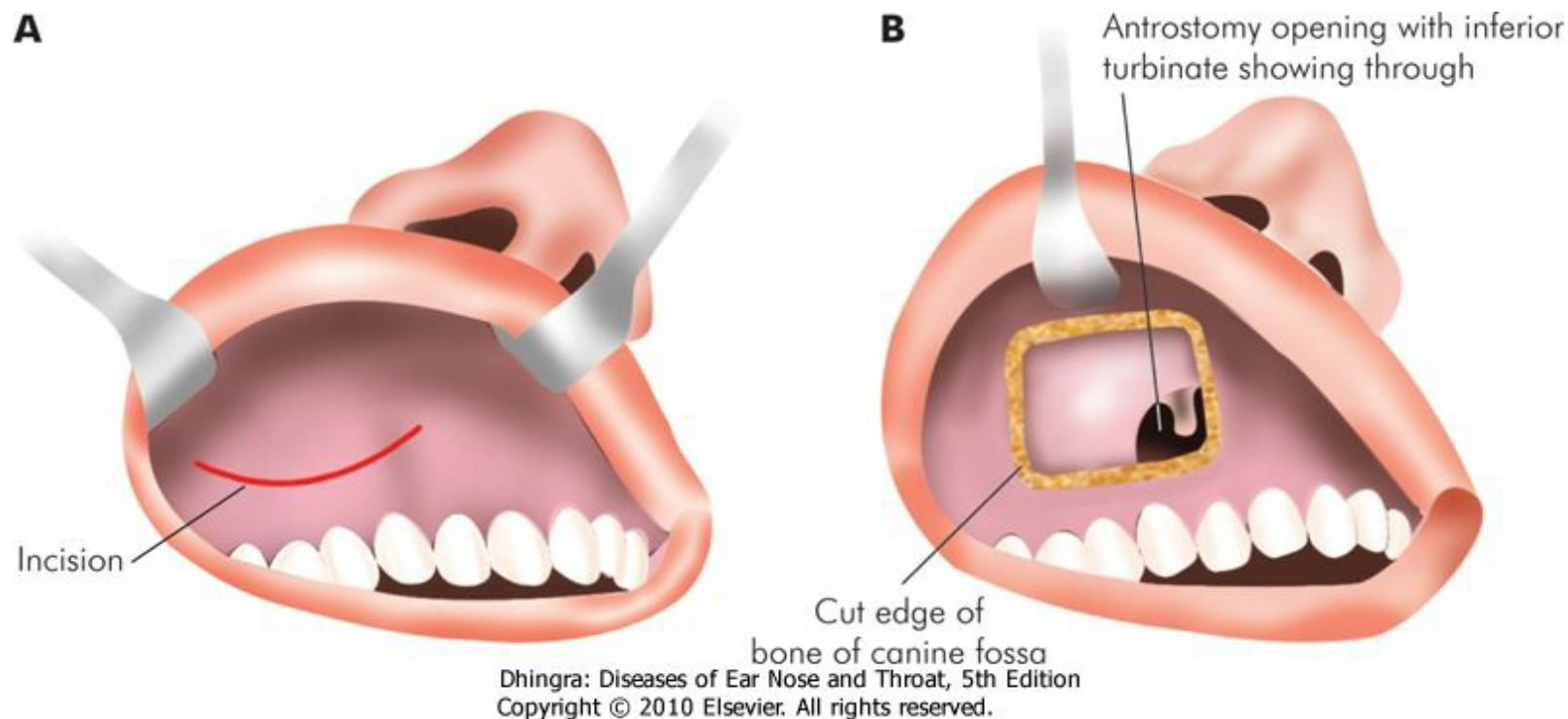


Figure 83.1 Caldwell-Luc operation. (A) Incision. (B) Inside view and position of antrostomy.

page 421

page 422

A horizontal incision with its ends upward is made below the gingivolabial sulcus, from lateral incisor to the 2nd molar (Fig. 83.1). It cuts through mucous membrane and periosteum.

## 2. Elevation of flap

The mucoperiosteal flap is raised from the canine fossa to the infraorbital nerve avoiding injury to the nerve.

## 3. Opening the antrum

Using cutting burr or gouge and hammer, a hole is made in the antrum. Opening is enlarged using Kerrison's punch.

## 4. Dealing with pathology

Once maxillary antrum has been opened, pathology is removed. Diseased antral mucosa can be removed with elevators, curettes and forceps. Cyst, benign tumour, foreign body or a polyp is removed.

## 5. Making nasoantral window

A curved haemostat is pushed into the antrum from the inferior meatus and then this opening is enlarged with Kerrison's and side-biting forceps to make a window, 1.5 cm in diameter.

## 6. Packing the antrum

Ribbon gauze, impregnated with liquid paraffin or Furacin™ (Furacin™ is 0.2% w/w nitrofurazone) ointment can be packed in the antrum and its end brought out from the nasoantral window into the nose. Intranasal packing is done if there is severe bleeding. Pack is also kept in the nose.

## 7. Closure of wound

Sublabial incision is closed with one or two catgut sutures.

## Post-operative Care

- 1. Ice packs over the cheek in the first 24 hours prevent oedema, haematoma and discomfort to the patient.
- 2. Packing in the sinus and nose can be removed in 24-48 hours.
- 3. Antibiotics are given for 5-7 days.
- 4. Patient should avoid blowing his nose for 2 weeks to avoid surgical emphysema.

# Complications

- 1. Post-operative bleeding. This can be controlled by nasal pack.
- 2. Anaesthesia of the cheek due to stretching of infraorbital nerve. It may last for a few weeks or months.
- 3. Anaesthesia of teeth.
- 4. Injury to nasolacrimal duct.
- 5. Sublabial fistula.
- 6. Osteomyelitis of maxilla (rare).

*Note:* Ever since the advent of endoscopic sinus surgery, indications for Caldwell-Luc operation have decreased. FESS can achieve all that can be done through Caldwell-Luc surgery.



## 84 Submucous Resection of Nasal Septum (SMR Operation)

### Indications

- 1. Deviated nasal septum (DNS) causing symptoms of nasal obstruction and recurrent headaches.
- 2. DNS causing obstruction to ventilation of paranasal sinuses and middle ear, resulting in recurrent sinusitis and otitis media.
- 3. Recurrent epistaxis from septal spur.
- 4. As a part of septorhinoplasty for cosmetic correction of external nasal deformities.
- 5. As a preliminary step in hypophysectomy (trans-septal trans-sphenoidal approach) or vidian neurectomy (trans-septal approach).

## Indications

- 1. Deviated nasal septum (DNS) causing symptoms of nasal obstruction and recurrent headaches.
- 2. DNS causing obstruction to ventilation of paranasal sinuses and middle ear, resulting in recurrent sinusitis and otitis media.
- 3. Recurrent epistaxis from septal spur.
- 4. As a part of septorhinoplasty for cosmetic correction of external nasal deformities.
- 5. As a preliminary step in hypophysectomy (trans-septal trans-sphenoidal approach) or vidian neurectomy (trans-septal approach).

## Contraindications

- 1. Patients below 17 years of age. In such cases, a conservative surgery (septoplasty) should be done.
- 2. Acute episode of respiratory infection.
- 3. Bleeding diathesis.
- 4. Untreated diabetes or hypertension.

# Anaesthesia

Local anaesthesia is preferred. General anaesthesia is used in children and apprehensive adults.

# Position

Reclining position with head-end of the table raised.

# Steps of Operation

## **1. Infiltration of nasal septum**

It is done in its subperichondrial planes with 2% xylocaine and 1:50,000 adrenaline.

## **2. Incision**

A curvilinear incision with forward convexity is made at the mucocutaneous junction on the left side of the septum. It cuts only through the mucosa and perichondrium.

## **3. Elevation of mucoperichondrial and periosteal flap**

Plane of dissection is important. It should be beneath the perichondrium and periosteum (Fig. 84.1A).

## **4. Incision of the cartilage**

Cartilage is incised just posterior to the first incision. Avoid cutting the opposite mucoperichondrium, otherwise, it will result in perforation.

## **5. Elevation of opposite mucoperichondrium and periosteum**

With the elevator passed through the cartilage incision, mucoperichondrial and periosteal flap is raised from the opposite side of the septum (Fig. 84.1B).

## **6. Removal of cartilage and bone**

Now working between the two flaps, cartilage and bone are removed. Cartilage can be removed with Ballenger swivel knife and bone with Luc's forceps. Bony spur or ridge can be removed with gouge and hammer. Preserve a strip of cartilage about 1 cm wide along the dorsal and caudal border of the septum to prevent collapse of the bridge of nose or retraction columella (Fig. 84.2).

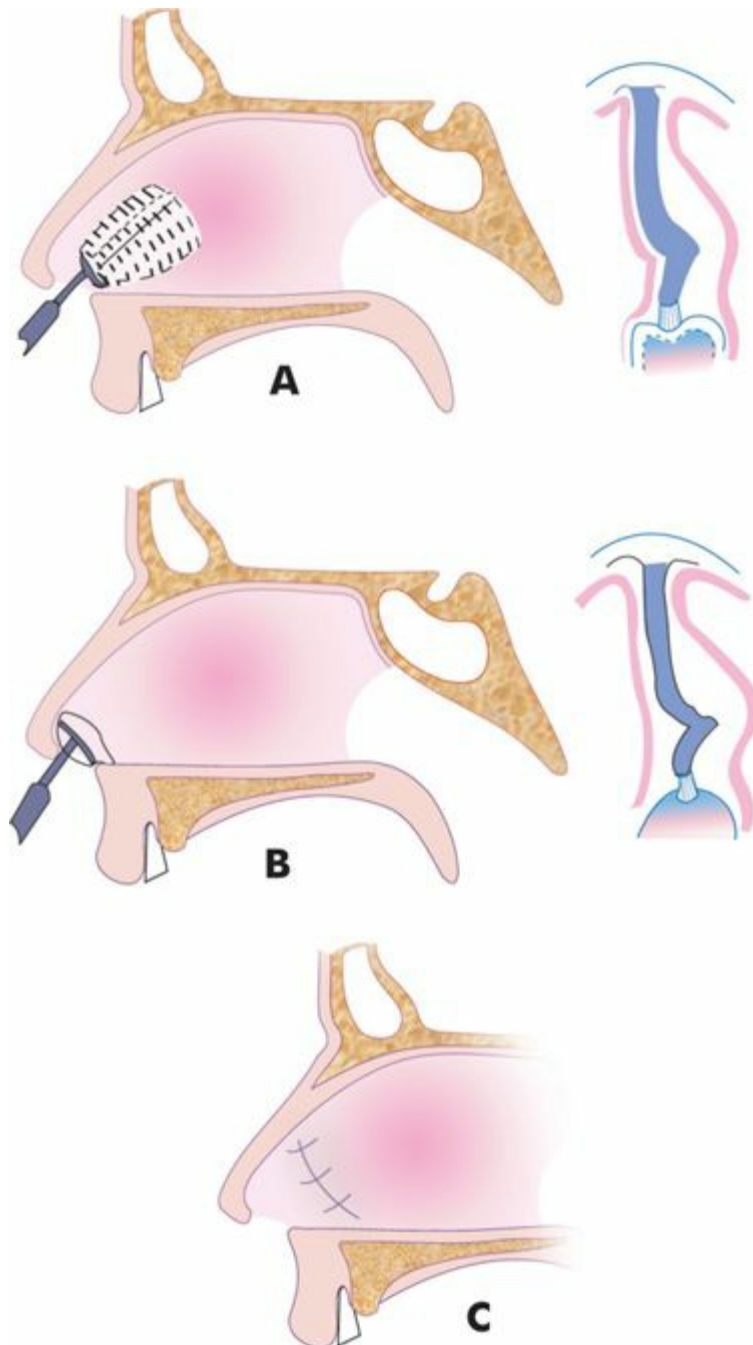
## **7. Stitching**

One or two catgut or silk stitches are applied in the initial mucoperichondrial incision.

## **8. Packing**

Ribbon gauze, smeared with an antibiotic ointment or liquid paraffin, is packed in each nasal cavity to prevent collection of blood between the flaps. Nasal dressing is applied.

- 1. Patient is placed in semi-sitting position to prevent oozing of blood. Outer nasal dressing is changed if soaked in blood.
- 2. A soft diet should be taken in the first two post-operative days to minimise active mastication which causes bleeding.
- 3. Pain, if any, should be controlled with analgesics.
- 4. Antibiotic cover is given for 5-6 days.
- 5. Nasal packs are gently removed after 24 hours and thereafter, decongestant nasal drops and steam inhalations are given daily for 5-6 days.
- 6. Silk stitch, if any, is removed on 5th or 6th day.
- 7. Patient should avoid trauma to the nose for several days.



Dhingra: Diseases of Ear Nose and Throat, 5th Edition  
 Copyright © 2010 Elsevier. All rights reserved.

Figure 84.1 Submucous resection of nasal septum: (A) Incision and elevation of flap on the left. (B) Elevation of flap on the right after incising the septal cartilage. (C) Closing the incision.

## Complications

- 1. *Bleeding*. It may require repacking, if severe.
- 2. *Septal haematoma*. Evacuate the haematoma and given intranasal packing on both sides of septum for equal pressure.
- 3. *Septal abscess*. This can follow infection of septal haematoma.
- 4. *Perforation*. When tears occur on opposing side of mucous membrane.
- 5. *Depression of bridge*. Usually occurs in supratip area due to too much removal of cartilage along the dorsal border.
- 6. *Retraction of columella*. Often seen when caudal strip of cartilage is not preserved.
- 7. *Persistence of deviation*. It usually occurs due to inadequate surgery and may require revision operation.
- 8. *Flapping of nasal septum*. Rarely seen, when too much of septal framework has been removed. Septum, which now consists of two mucoperichondrial flaps, moves to the right or left with respiration.
- 9. *Toxic shock syndrome*. It is rare after septal surgery. It can follow staphylococcal (sometimes streptococcal) infection and is characterised by nausea, vomiting, purulent secretions, hypotension and rash. It should be diagnosed early. It is treated by removal of packing, hydrating the patient, maintaining blood pressure and administering proper antibiotics.

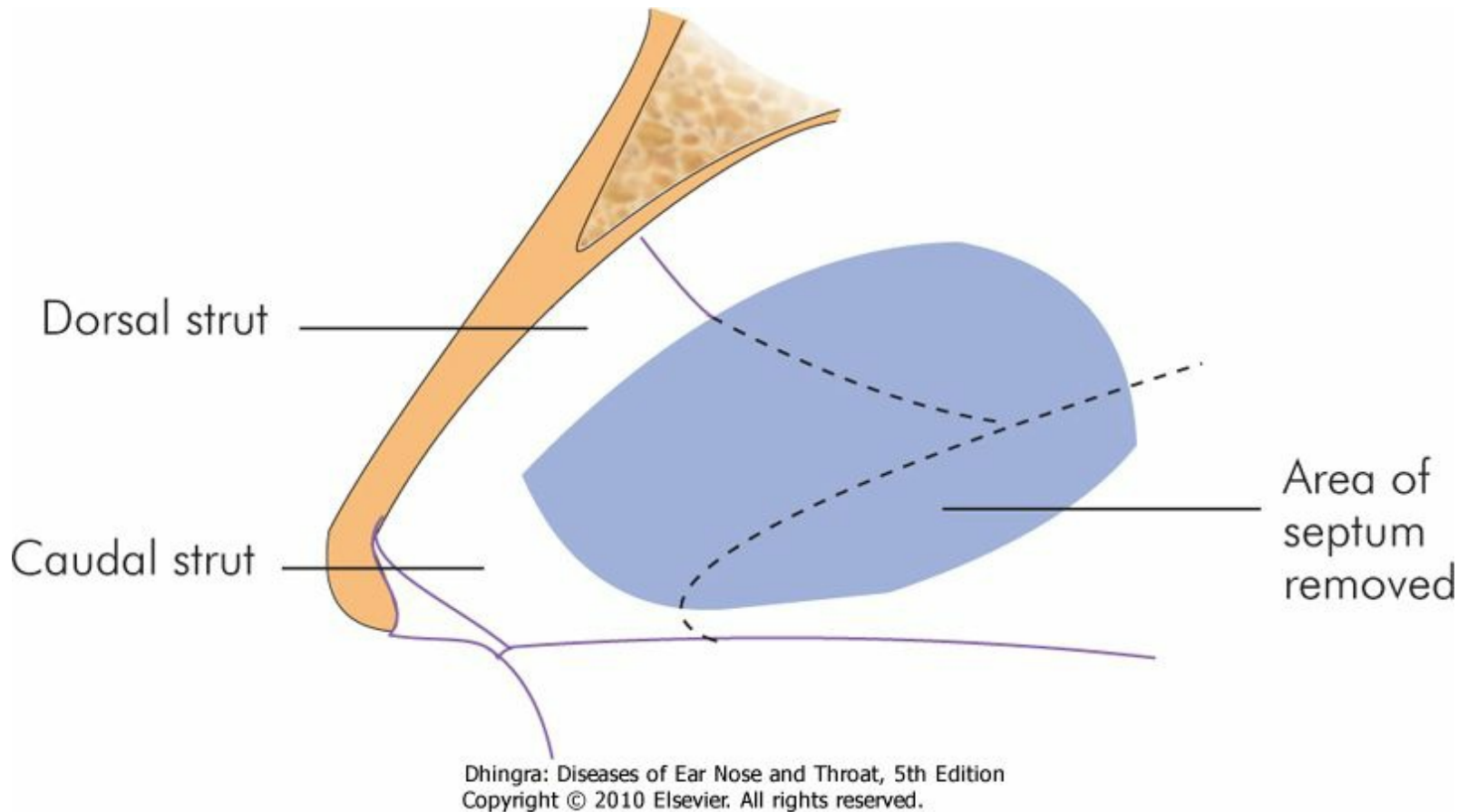


Figure 84.2 SMR operation. It is necessary to preserve dorsal and caudal struts of cartilage to avoid supratip depression or columellar recession respectively.



## **85 Septoplasty**

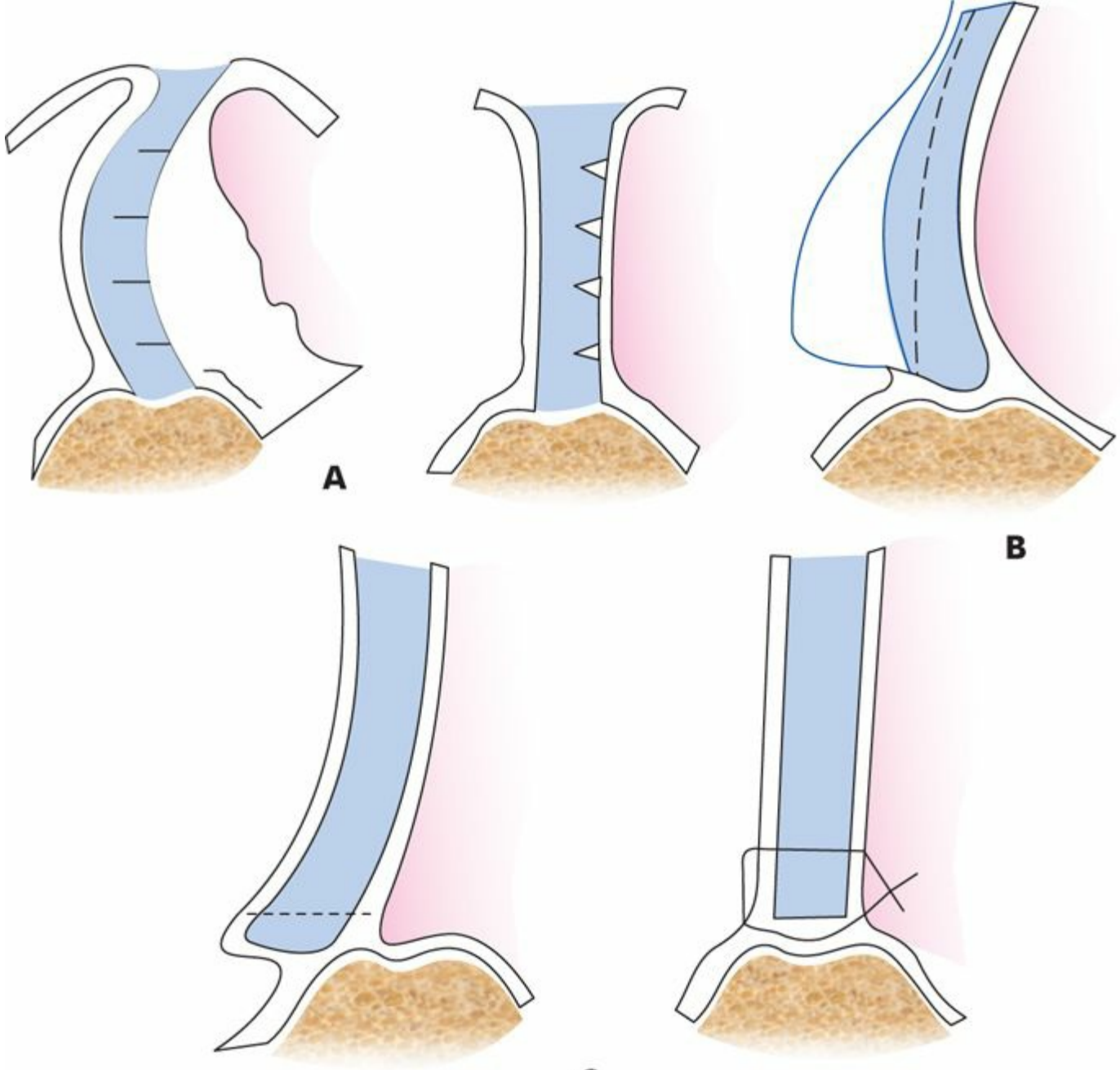
Septoplasty is a conservative approach to septal surgery; as much of the septal framework as possible is retained. Mucoperichondrial/periosteal flap is generally raised only on one side. This operation has almost replaced the SMR operation.

## Indications

- 1. Symptomatic deviated septum.
- 2. As a part of septorhinoplasty for cosmetic reasons.
- 3. As an approach to hypophysectomy.
- 4. Recurrent epistaxis due to septal spur.

# Contraindications

- 1. Acute nasal or sinus infection.
- 2. Untreated diabetes.
- 3. Hypertension.
- 4. Bleeding diathesis.



**C**  
Dhingra: Diseases of Ear Nose and Throat, 5th Edition  
Copyright © 2010 Elsevier. All rights reserved.

Figure 85.1 Septal cartilage is straightened by scoring the cartilage on the concave side to remove interlocked cartilage stresses (A), or by shaving the convex side of cartilage (B). Dislocated septal cartilage can be replaced in the maxillary groove or on the anterior nasal spine by excision of the cartilage along the floor of nose and fixing it with a suture (C).

# Anaesthesia

Local or general.

# Position

Same as for SMR operation.

# Technique

- - 
  - 
  -
- (i) Scoring on the concave side (Fig. 85.1).
  - (ii) Cross-hatching or morselizing.
  - (iii) Shaving.
  - (iv) Wedge excision.

Further manipulations like realignment of nasal spine, separation of septal cartilage from upper lateral cartilages, implantation of cartilage strip in the columella or the dorsum of nose may be required.

- **1.** Infiltrate the septum with 1% lignocaine with adrenaline, 1:100,000.
- **2.** In cases of deviated septum, make a slightly curvilinear incision, 2-3 mm above the caudal end of septal cartilage on the concave side (Killian's incision). In case of caudal dislocation, a transfixion or hemitransfixion (Freer's) incision is made.
- **3.** Raise mucoperichondrial/mucoperiosteal flap on one side only.
- **4.** Separate septal cartilage from the vomer and ethmoid plate and raise mucoperiosteal flap on the opposite side of septum.
- **5.** Remove maxillary crest to realign the septal cartilage.
- **6.** Correct the bony septum by removing the deformed parts. Deformed septal cartilage is corrected by various methods, such as:
- **7.** Trans-septal sutures are put to coapt mucoperichondrial flaps.
- **8.** Nasal pack.

# Post-operative Complications

Same as for SMR operation.

- 1. *Bleeding.*
- 2. *Septal haematoma and abscess.*
- 3. *Septal perforation.*
- 4. *Persistence of septal deviation, or external nasal deformity.*

## **86 Diagnostic Nasal Endoscopy**

Like anterior and posterior rhinoscopy, endoscopy of nose and nasopharynx helps in the diagnosis of diseases of nose, paranasal sinuses (PNS) and the nasopharynx. Because of the brighter illumination, magnification and angled view provided by the endoscopes, it is possible to examine all clefts and crevices of the nose and nasopharynx. It is an important part of examination of nose and nasopharynx.



## Indications

- 1. To diagnose any disease of the nose and PNS.
- 2. To diagnose source of bleeding in epistaxis.
- 3. To assess response to medical or surgical treatment of the nose and PNS disease.
- 4. To take a precise biopsy from nose and nasopharynx.

# Anaesthesia

Topical anaesthesia with 4% xylocaine and a vasoconstrictor (oxymetazoline), first as a nasal spray and then nasal packs.

## Position

Sitting or supine.

## Instruments

1. 4 mm 30° endoscope	
2.7 mm 30° endoscope	Required when nasal passages are narrow
2.7 mm 70° endoscope	
2. Freer's elevator or elevator with a suction channel	
3. Suction tips	
4. Biopsy forceps	
5. Antifog solution or Savlon™ to prevent fogging of the endoscopic lens.	

# Technique

After nasal packs are removed, endoscopy is performed by three passes:

## First Pass (Examination of nasopharynx and inferior meatus)

- 1. First obtain a general view of the nasal cavity. Look for any septal deviation or spurs and their size, mucous or purulent discharge in the nasal cavity and colour of the nasal mucous membrane.
- 2. Pass the endoscope along the floor of nose into the nasopharynx and examine: (i) opening of eustachian tube, (ii) walls of nasopharynx, (iii) upper surface of soft palate and uvula, and (iv) opening of eustachian tube of opposite side. To see these structures endoscope is rotated.
- 3. Withdraw the endoscope slightly and examine the margins of choana and posterior ends of turbinates.
- 4. Withdraw endoscope slowly and at the same time examine inferior meatus for opening of nasolacrimal duct and Hasner's valve. Slight pressure over the lacrimal sac may express a drop or two of lacrimal fluid through the nasolacrimal opening.

## Second Pass (Examination of the sphenoidal recess, superior meatus and openings of sphenoid sinus and posterior ethmoidal cells)

Endoscope is passed medial to middle turbinate to examine posterior part of middle turbinate, sphenoidal recess, superior turbinate and meatus, openings of posterior ethmoid cells (in the superior meatus) and opening of sphenoid sinus in the posterior wall of sphenoidal recess between the nasal septum and superior turbinate.

page 427

page 428

## Third Pass (Examination of the middle meatus in detail)

Endoscope is passed from the front into the middle meatus. Sometimes middle turbinate needs to be displaced medially or 2.7 mm 30° endoscope have to be used. Examine uncinat process, bulla ethmoidalis, hiatus semilunaris, sinus of the turbinate (cavity on lateral side of middle turbinate) and the frontal recess.

Sometimes middle meatus is better entered from behind where the space is wider than from the front and structures are seen from behind forward, e.g. basal lamina, bulla ethmoidalis, hiatus semilunaris, sinus of the turbinate and uncinat process and the frontal recess.

## Complications

Sometimes bleeding can occur due to suction or manipulation of instruments. It is usually mild and easily controlled by vasoconstrictor nasal drops.

## 87 Endoscopic Sinus Surgery

Endoscopic surgery has made a great contribution towards management of sinus disease. Indications for conventional operations like those of Caldwell-Luc, frontal sinus operations, external ethmoidectomy have greatly reduced. Endoscopic surgery is minimally invasive surgery and does not require skin incisions or removal of intervening bone to access the disease. In the sinuses, ventilation and drainage of the sinuses is established preserving the nasal and sinus mucosa and its function of mucociliary clearance. Advances in endoscopic surgery have been possible due to:

- 1. Development of better optics.
- 2. Improved brighter illumination.
- 3. Development of microsurgical instruments to work with the endoscopes and precise removal of tissue with sharp cuts without stripping the mucosa.
- 4. Concomitant developments in imaging techniques like CT and MRI to precisely define the area of pathology.
- 5. Introduction of powered instrumentation in the form of soft-tissue shavers also called micro-debriders (to remove nasal polyps, soft-tissue masses or mucosa) help reduce bleeding to a great extent while bone-cutting drills help endoscopic surgery of frontal sinus, lacrimal sac, etc. to remove bony obstruction.
- 6. The latest advancement has been the computer-assisted image-guided navigational surgery in difficult cases or revisional surgery when landmarks are not easy to identify.

## Indications

- 1. Chronic bacterial sinusitis unresponsive to adequate medical treatment.
- 2. Recurrent acute bacterial sinusitis.
- 3. Polypoid rhinosinusitis (diffuse nasal polyposis).
- 4. Fungal sinusitis with fungal ball or nasal polypi.
- 5. Antrochoanal polyp.
- 6. Mucocele of frontoethmoid or sphenoid sinus.
- 7. Control of epistaxis by endoscopic cauterization.
- 8. Removal of foreign body from the nose or sinus.
- 9. Endoscopic septoplasty.



## Advanced Nasal Endoscopic Techniques

- 1. Removal of benign tumours, e.g. inverted papillomas or angiofibromas.
- 2. Orbital abscess or cellulitis management.
- 3. Dacryocystorhinostomy.
- 4. Repair of CSF leak.
- 5. Pituitary surgery.
- 6. Optic nerve decompression.
- 7. Orbital decompression for Graves disease.
- 8. Control of posterior epistaxis (endoscopic clipping of sphenopalatine artery).
- 9. Choanal atresia.

## Contraindications

- 1. Inexperience and lack of proper instrumentation.
- 2. Disease inaccessible by endoscopic procedures, e.g. lateral frontal sinus disease and stenosis of internal opening of frontal sinus.
- 3. Osteomyelitis.
- 4. Threatened intracranial or intraorbital complication.

# Anaesthesia

General anaesthesia is preferred by most of the surgeons. Local anaesthesia with i.v. sedation can be used in adults when limited work is to be done.

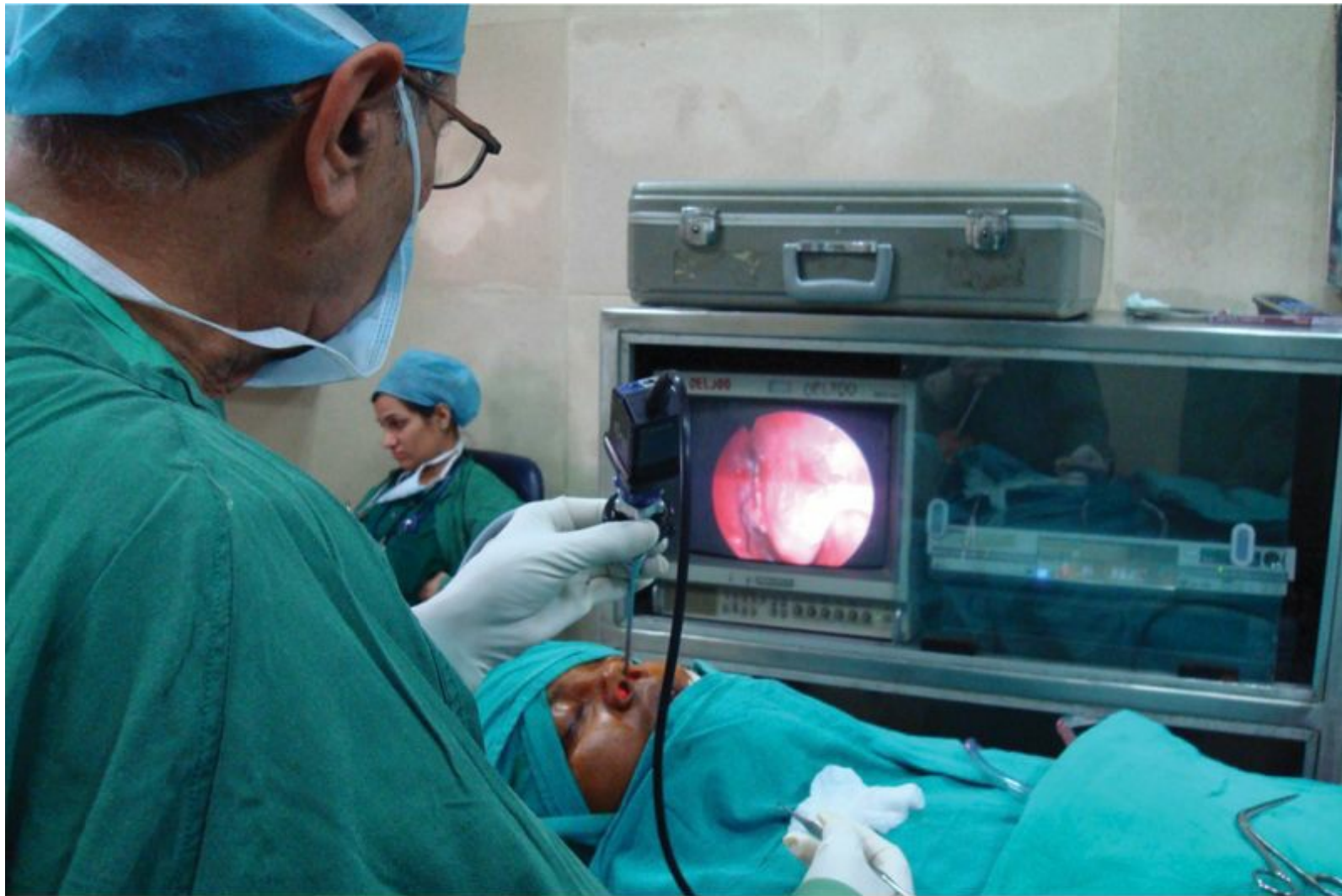## Position

Patient lies flat in supine position with head resting on a ring or head rest. Some also prefer to raise it by 15°.

## Techniques (Fig. 87.1)

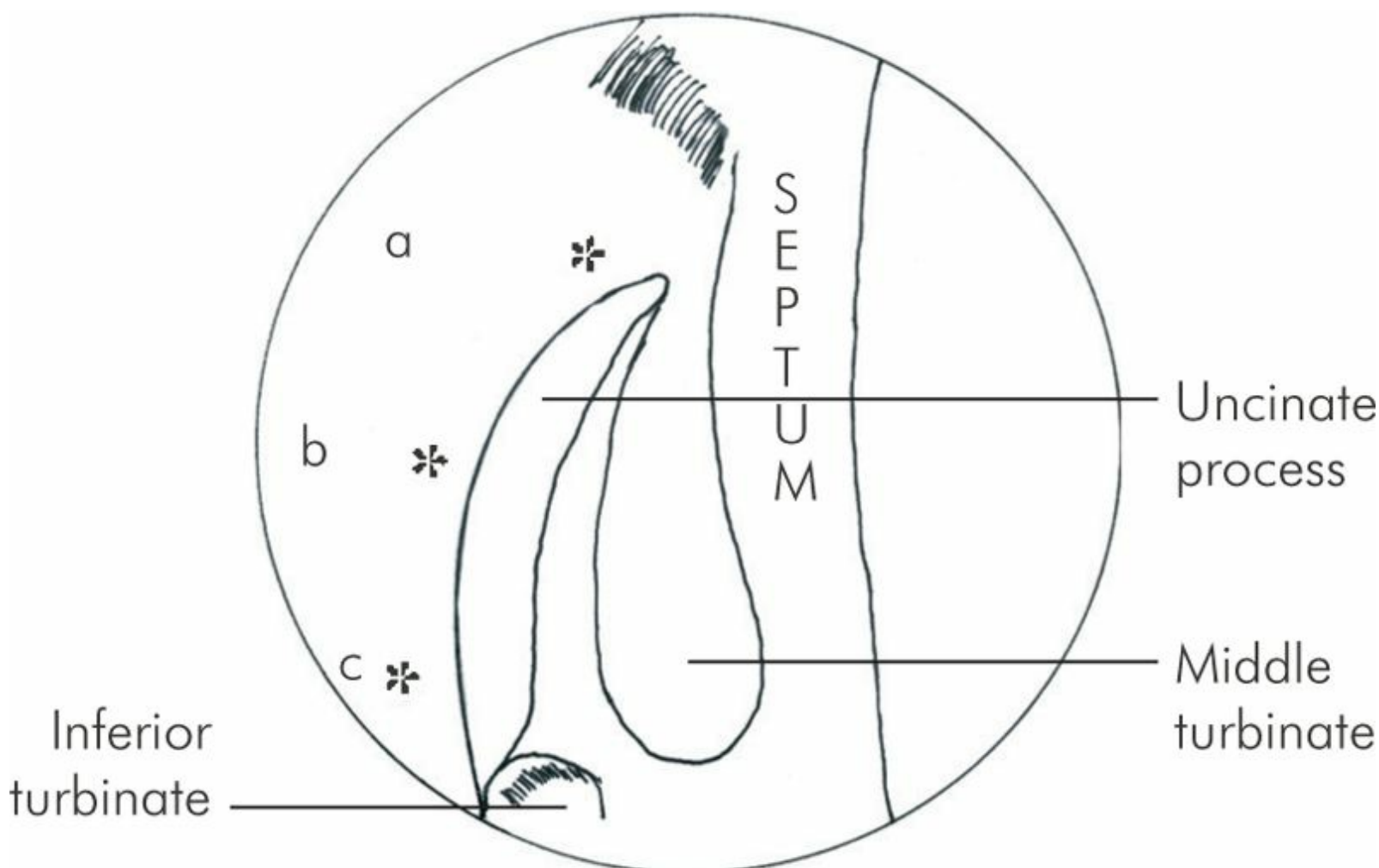
Two surgical techniques are followed:

- **(a)** Anterior to posterior (Stammberger's technique): In this technique surgery proceeds from uncinete process backward to sphenoid sinus. Advantage of this technique is to tailor the extent of surgery to the extent of disease.
- **(b)** Posterior to anterior (Wigand's technique): Surgery starts at the sphenoid sinus and proceeds anteriorly along the base of skull and medial orbital wall. This is mostly done in extensive polyposis or in revisional sinus surgery.



Dhingra: Diseases of Ear Nose and Throat, 5th Edition  
Copyright © 2010 Elsevier. All rights reserved.

Figure 87.1 Endoscopic surgery in progress. Endoscope and other surgical instruments are passed through the nose and surgery performed by looking at the monitor.



Dhingra: Diseases of Ear Nose and Throat, 5th Edition  
Copyright © 2010 Elsevier. All rights reserved.

Figure 87.2 Sites of injection (indicated by stars) just anterior to uncinat process on the lateral wall of right side of nose.

page 430

page 431

- 1. Remove the pledgets of cotton kept for nasal decongestion and topical anaesthesia.
- 2. Inspect the nose with 4 mm 0° endoscope or do complete nasal endoscopy if not already done.
- 3. Inject submucosally 1% lignocaine with 1:100,000 adrenaline under endoscopic control (Fig. 87.2):
  - (a) On the lateral wall, near the upper end of middle turbinate.
  - (b) On the lateral wall, just below the first injection.
  - (c) On the lateral wall, just above the inferior turbinate.
  - (d) In the middle turbinate, posterior aspect.
  - (e) Posterior aspect of nasal septum.
- 4. Replace cotton pledgets and repeat injections on the opposite side if bilateral FESS is to be done.

Medialise the middle turbinate and identify the uncinat process and bulla ethmoidalis. If middle turbinate is large, partial or total turbinectomy is performed. In case of concha bullosa, lateral lamella is removed. Definitive surgical steps include:

- 1. **Uncinectomy** Uncinate process is incised with sickle knife and removed with Blakesley forceps.
- 2. **Identification and enlargement of maxillary ostium** Maxillary ostium lies above the inferior turbinate and posterior to lower third of uncinat process. Once localised, it is enlarged anteriorly with a back-biting forceps or posteriorly with a through cut-straight forceps.
- 3. **Bullectomy** Bulla ethmoidalis is penetrated with curette or Blakesley forceps and removed. Avoid injury to medial orbital wall, skull base or anterior ethmoidal artery.
- 4. **Penetration of basal lamella and removal of posterior ethmoid cells** Basal lamella is the dividing thin bony septum between anterior and posterior ethmoid cells. It is penetrated in the lower and medial part with a small curette and then removed with Blakesley forceps. Posterior ethmoid cells are exenterated. Optic nerve is at risk if Onodi cell is present. Onodi cell is a posterior ethmoid cell which extends into the sphenoid bone lateral and superior to the sphenoid sinus.
- 5. **Clearance of frontal recess and frontal sinusotomy** If frontal sinus is clear on CT scan and patient also does not suffer from frontal headaches, nothing need to be done. In the event of frontal sinus disease, frontal recess is cleared and frontal sinus drainage established.

Opening of frontal sinus is situated lateral to attachment of middle turbinate, medial to medial orbital wall, anterior to anterior ethmoidal artery and posterior to agger nasi cell(s). Surgery in the area of frontal recess is challenging as any disrespect to the mucosa in this area would lead to stenosis of frontal sinus opening with mucocele formation or recurrent frontal sinusitis.

- **6. Sphenoidotomy** This step is done after clearance of posterior ethmoid cells or after frontal sinusotomy. It is omitted if sinus is healthy. In this procedure anterior wall of sphenoid sinus is removed, and pus and inspissated material from within the sinus removed. There are two ways to remove the anterior sinus wall:
  - (a) By entering the sphenoid sinus anterior and inferior to the ethmoid cavity created by the above steps.
  - (b) By enlarging the opening of sphenoid sinus with Blakesley forceps or J-curette. Sinus opening is identified after removal of the posterior-inferior portion of superior turbinate near the nasal septum and about 1.0 cm above the upper border of posterior choana.
- **7. Nasal packs** Finally the nasal packs are applied, if septal surgery has also been done with FESS or to stop any bleeding from the nasal cavity.



# Post-operative Care

It is individualised according to the extent of surgery done.

- **1. Removal of nasal packs** Nasal packs, if kept, are removed at the time of discharge 24 hours after the operation.
- **2. Antibiotics** An intraoperative intravenous antibiotic (amoxyclav, cephalosporin or quinolone) is administered and then continued for 7-10 days by oral route.
- **3. Antihistaminics** For allergic patients.
- **4. Analgesics** For relief of post-operative pain.
- **5. Nasal irrigations** Saline irrigations are started after 1 week post-operatively to remove blood clots, crusts and secretions and continued once or twice a day for 1 week.
- **6. Steroid nasal sprays** Required in cases of nasal allergy or those operated for nasal polyps.
- **7. Endoscopic toilet** Blood clots, crusts and debris are removed by suction and forceps from the ethmoid area lateral to middle turbinate. Any adhesion formation in the nose is divided with suction. Healthy mucosa should not be disturbed. Suction can be done from within the maxillary sinus with a curved cannula. Since the endoscopic clearance is a painful process, topical nasal anaesthetic with a decongestant is sprayed before the procedure.

**Table 87-1. Major and minor complications of endoscopic sinus surgery**

Major	Minor
<ol style="list-style-type: none"><li>1. Orbital haemorrhage</li><li>2. Loss of vision/blindness</li><li>3. Diplopia</li><li>4. CSF leak</li><li>5. Meningitis</li><li>6. Brain abscess</li><li>7. Massive haemorrhage requiring bloodtransfusion</li><li>8. Intracranial haemorrhage and direct brain trauma</li><li>9. Anosmia</li><li>10. Injury to internal carotid artery in sphenoid sinus</li><li>11. Injury to nasolacrimal duct and epiphora</li><li>12. Death</li></ol>	<ol style="list-style-type: none"><li>1. Periorbital ecchymosis</li><li>2. Periorbital emphysema</li><li>3. Post-operative epistaxis</li><li>4. Post-operative infection: rhinitis or sinusitis</li><li>5. Adhesions</li><li>6. Stenosis of maxillary or frontal sinus opening</li><li>7. Exacerbation of asthma</li><li>8. Hyposmia</li><li>9. Dental pain</li></ol>

Patient pays weekly visits for inspection of the cavity for 4 weeks and thereafter as required till mucosalisation of the cavity is complete.

## Complications

They are similar to conventional surgery of ethmoid complex and can be divided into major and minor. Mostly they involve orbit or skull base, or are of general nature (see Table 87.1). Many of the complications are preventable by careful surgical technique.

## 88 Direct Laryngoscopy

It is direct visualisation of larynx and hypopharynx.

# Indications

## A. Diagnostic

- 1. When indirect laryngoscopy is not possible as in infants and young children, and the symptomatology points to larynx and/or hypopharynx, e.g. hoarseness, dyspnoea, stridor and dysphagia.
- 2. When indirect laryngoscopy has not been successful, e.g. due to excessive gag reflex or overhanging epiglottis obscuring a part of the complete view of the larynx.
- 3. To examine hidden areas of:  
*Hypopharynx*: Base of tongue, valleculae and lower part of pyriform fossa.  
*Larynx*: Infrahyoid epiglottis, anterior commissure, ventricles and subglottic region.
- 4. To find the extent of growth and take a biopsy.

## B. Therapeutic

- 1. Removal of benign lesions of larynx, e.g. papilloma, fibroma, vocal nodule, polyp or cyst.
- 2. Removal of foreign bodies from larynx and hypopharynx.
- 3. Dilatation of laryngeal strictures.

## Contraindications

- 1. Diseases or injuries of cervical spine.
- 2. Moderate or marked respiratory obstruction unless the airway has been provided by tracheostomy.
- 3. Recent coronary occlusion or cardiac decompensation.

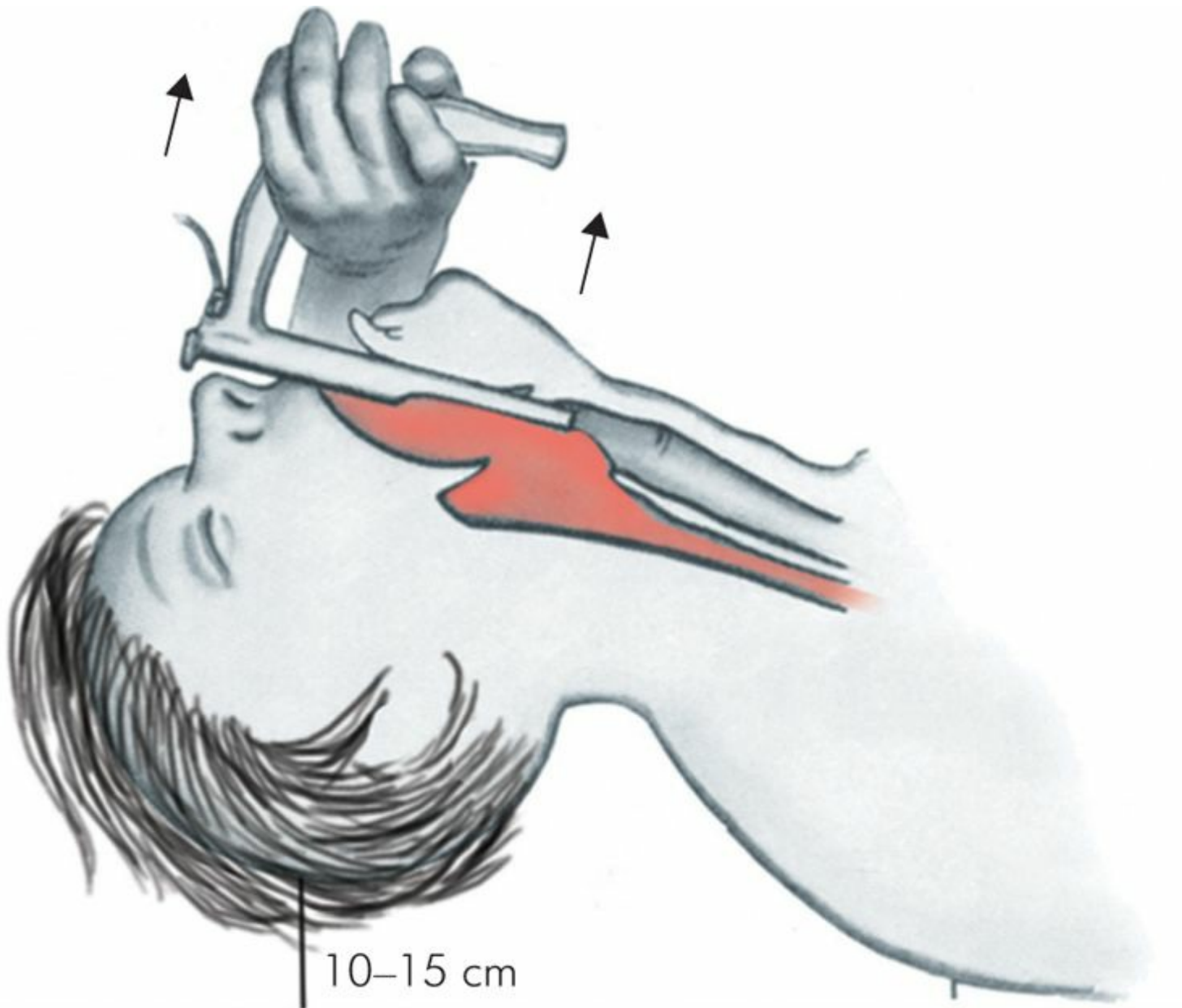
## Anaesthesia

General anaesthesia is preferred though this procedure can be performed under local anaesthesia. In infants and young children, no anaesthesia may be required if procedure is for diagnostic purpose.

## Position

Patient lies supine. Head is elevated by 10-15 cm by placing a pillow under the occiput or by raising head flap of the operation table. Neck is flexed on thorax and the head extended on atlanto-occipital joint (*Barking-dog position*).

- 1. A piece of gauze is placed on the upper teeth to protect them against trauma.
- 2. Laryngoscope is lubricated with a little autoclaved liquid paraffin or jelly.
- 3. Laryngoscope is held by the handle in the left hand. Right hand is used, to retract the lips and guide the laryngoscope and to handle suction and instruments.
- 4. Laryngoscope is introduced by one side of the tongue which is pushed to the opposite side till posterior third of tongue is reached. It is then moved to the midline and lifted forward to bring the epiglottis in view.
- 5. Laryngoscope is now advanced behind the epiglottis and lifted forward *without levering it on the upper teeth or jaw* (Fig. 88.1). This gives good view of the interior of the larynx.
- 6. If anterior commissure laryngoscope is being used, its tip can be advanced further between the ventricular bands to examine the ventricles and anterior commissure. It can be passed between the vocal cords to examine the subglottic region.
- 7. Following structures are examined serially: Base of tongue, right and left valleculae, epiglottis, (its tip, lingual and laryngeal surfaces), right and left pyriform sinuses, aryepiglottic folds, arytenoids, post-cricoid region, both false cords, anterior and posterior commissure, right and left ventricles, right and left vocal cords and subglottic area. Mobility of vocal cords should also be observed.



Dhingra: Diseases of Ear Nose and Throat, 5th Edition  
Copyright © 2010 Elsevier. All rights reserved.

Figure 88.1 Direct laryngoscopy.

A right-angled telescope can be used to see the undersurface of vocal cords and the walls of the subglottis. After the procedure is completed,



laryngoscope is withdrawn and lips and teeth examined for any injury.

## Post-operative Care

- **1.** Patient is kept in coma position to prevent aspiration of blood or secretions.
- **2.** Patient's respiration should be watched for any laryngeal spasm and cyanosis.
- **3.** Trauma to larynx, especially if repeated attempts at laryngoscopy have been made. It may lead to laryngeal oedema and respiratory distress.
- **4.** Bleeding may occur from the operative site. Patient may spit blood. Care should be taken to prevent aspiration.

## Complications

- 1. Injury to lips and tongue if they are nipped between the teeth and the laryngoscope.
- 2. Injury to teeth. They may get dislodged and fall into pharynx.
- 3. Bleeding.
- 4. Laryngeal oedema.

## 89 Bronchoscopy

Bronchoscopy is of two types:

- 1. Rigid.
- 2. Flexible fibre optic.

# RIGID BRONCHOSCOPY

## Indications

### A. Diagnostic

- 1. To find out the cause for wheezing, haemoptysis, or unexplained cough persisting for more than 4 weeks.
- 2. When X-ray chest shows:
  - (a) Atelectasis of a segment, lobe or entire lung
  - (b) Opacity localised to a segment or lobe of lung
  - (c) Obstructive emphysema-to exclude foreign body
  - (d) Hilar or mediastinal shadows
- 3. Vocal cord palsy.
- 4. Collection of bronchial secretions for culture and sensitivity tests, acid fast bacilli, fungus, malignant cells.

### B. Therapeutic

- 1. Removal of foreign bodies.
- 2. Removal of retained secretions or mucus plug in cases of head injuries, chest trauma, thoracic or abdominal surgery, or comatosed patients.

# Anaesthesia

General anaesthesia with no endotracheal tube or with only a small bore catheter is often preferred. It can also be done under topical surface anaesthesia.

# Position

Same as for direct laryngoscopy.

# Technique

There are two methods to introduce bronchoscope:

- **1. *Direct method.*** Here bronchoscope is introduced directly through the glottis.
- **2. *Through laryngoscope.*** Here glottis is first exposed with the help of a spatular type laryngoscope and then the bronchoscope is introduced through the laryngoscope into the trachea. Laryngoscope is then withdrawn. This method is useful in infants and young children, and in adults who have short neck and thick tongue.



## Details of Technique

1. A piece of gauze is placed on the upper teeth for their protection against injury.
2. Proper-sized bronchoscope is lubricated with a swab of autoclaved liquid paraffin or jelly. It is held by the shaft in surgeon's right hand in a pen-like fashion. Fingers of the left hand are used to retract the upper lip and guide the bronchoscope.
3. Now looking through the scope, tip of epiglottis is identified first and the scope passed behind it and the epiglottis lifted forward to expose the glottis. Now bronchoscope is rotated 90° clockwise so that its bevelled tip is in the axis of glottis to ease its entry into the trachea. Once trachea is entered, scope is rotated back to the original position.
4. Bronchoscope is gradually advanced and the entire tracheobronchial tree examined. Axis of bronchoscope should be made to correspond with axes of the trachea and bronchi. To achieve this, head and neck are flexed to the left when examining the right bronchial tree and vice versa.

Openings of all the segmental bronchi in both the lungs are examined seriatim.

5. Direct vision, right angled and retrograde telescopes can be used for magnification and detailed examination.

---

page 434

page 435

6. Biopsy of the lesion of suspicious area can be taken.
7. Secretions can be collected for exfoliative cytology, or bacteriologic examination.

## Post-operative Care

- 1. Keep the patient in humid atmosphere.
- 2. Watch for respiratory distress. This could be due to laryngeal spasm or subglottic oedema if the procedure had been unduly prolonged or the bronchoscope introduced repeatedly. Inspiratory stridor and suprasternal retraction will indicate need for tracheostomy.

## Complications

- 1. Injury to teeth and lips.
- 2. Haemorrhage from the biopsy site.
- 3. Hypoxia and cardiac arrest.
- 4. Laryngeal oedema.

## Precautions During Bronchoscopy

- 1. Select proper size of bronchoscope according to patient's age (see Table A1 in Appendix II).
- 2. Do not force bronchoscope through closed glottis.
- 3. Repeated removal and introduction of bronchoscope should be avoided.
- 4. Procedure should not be prolonged beyond 20 minutes in infants and children, otherwise it may cause subglottic oedema in post-operative period.

## **FLEXIBLE FIBRE OPTIC BRONCHOSCOPY**

These days, flexible fibre optic bronchoscopy has replaced rigid bronchoscopy for diagnostic procedures particularly in adults. It provides magnification and better illumination, and because of the smaller size of scope, permits examination of subsegmental bronchi. It is also easy to use in patients with neck or jaw abnormalities where rigid bronchoscopy may almost be impossible technically. This procedure can be performed under topical anaesthesia and is very useful for bedside examination of the critically ill patients. The suction/biopsy channel provided in the fibrescope helps to remove secretions, inspissated plugs of mucus or even small foreign bodies. Flexible bronchoscope can also be easily passed through endotracheal tube or the tracheostomy opening. However, it has limited utility in children because of the problems of ventilation.

## 90 Oesophagoscopy

Oesophagoscopy is of two types:

- **1.** Rigid oesophagoscopy.
- **2.** Flexible fibre-optic oesophagoscopy.

# RIGID OESOPHAGOSCOPY

## Indications

### A. Diagnostic

- 1. To investigate cause for dysphagia, e.g. cancer oesophagus, cardiac achalasia, strictures, oesophagitis, diverticula, etc.
- 2. To find cause for retrosternal burning, e.g. reflux oesophagitis or hiatus hernia.
- 3. To find cause for haematemesis, e.g. oesophageal varices.
- 4. Secondaries neck with unknown primary (as a part of panendoscopy).

### B. Therapeutic

- 1. Removal of a foreign body.
- 2. Dilatation in case of oesophageal strictures or cardiac achalasia.
- 3. Endoscopic removal of benign lesions, e.g. fibroma, papilloma, cysts, etc.
- 4. Insertion of Soutar's or Mousseau-Barbin tube in palliative treatment of oesophageal carcinoma.
- 5. Injection of oesophageal varices.

## Contraindications

- **1.** Trismus-makes the procedure technically difficult.
- **2.** Disease of cervical spine, e.g. cervical trauma, spondylosis, tuberculous spine, osteophytes, kyphosis. They make rigid oesophagoscopy technically difficult. Flexible fibre-optic oesophagoscopy is performed in these cases.
- **3.** Receding mandible.
- **4.** Aneurysm of aorta for fear of rupture and fatal haemorrhage.
- **5.** Advanced heart, liver or kidney disease may be a relative contraindication.



# Anaesthesia

General anaesthesia with oro-tracheal intubation, with tube in the left corner of the mouth. It can be performed under local anaesthesia in selected individuals.

## Position

Same as for direct laryngoscopy. Patient lies supine, head is elevated by 10-15 cm, neck flexed on chest, and head extended at atlanto-occipital joint. The purpose of this position is to attain the axes of mouth, pharynx and oesophagus in a straight line to pass the rigid tube easily. This position can be achieved with the help of an assistant or a special head rest.

# Technique

- **1.** A piece of gauze is placed over the upper teeth to protect teeth and lips.
- **2.** Oesophagoscope is lubricated with a swab of autoclaved liquid paraffin or jelly.
- **3.** The oesophagoscope is held by its proximal end in a pen-like fashion and introduced into the mouth by the right side of the tongue and then towards the middle of its dorsum.

page 436

page 437

Now there are 4 basic steps:

- **1. Identification of arytenoids.** Once oesophagoscope has been introduced to the back of tongue, it is advanced gently by the left thumb and index finger. Epiglottis is first seen, then the endotracheal tube and a little further down arytenoids can be identified.
- **2. Passing the cricopharyngeal sphincter.** Keeping the tip of oesophagoscope strictly in the midline, behind the larynx, it is lifted with movements of left thumb to open the hypopharynx. With slow but sustained pressure, the sphincter will open and then the tip of oesophagoscope can be guided easily into the oesophagus. Never apply force to open the sphincter. Sometimes, a fine bougie can be used to find the lumen. An additional dose of muscle relaxant may be required if sphincter does not open. Once oesophagus has been entered, it is easier to advance the scope, provided, oesophageal lumen is kept constantly in view.
- **3. Crossing the aortic arch and left bronchus.** In an adult, this natural narrowing lies about 25 cm from the incisors. Aortic pulsation can be seen. When crossing this area, head of the patient is slightly lowered so that oesophageal lumen is in line with that of the scope.
- **4. Passing the cardia.** Head and shoulders remain below the level of the table, head being slightly higher than the shoulders and moved slightly to the right. At this stage, the oesophagoscope points to the left anterior-superior iliac spine. Cardia is identified by its redder and more velvety or rugose mucosa.

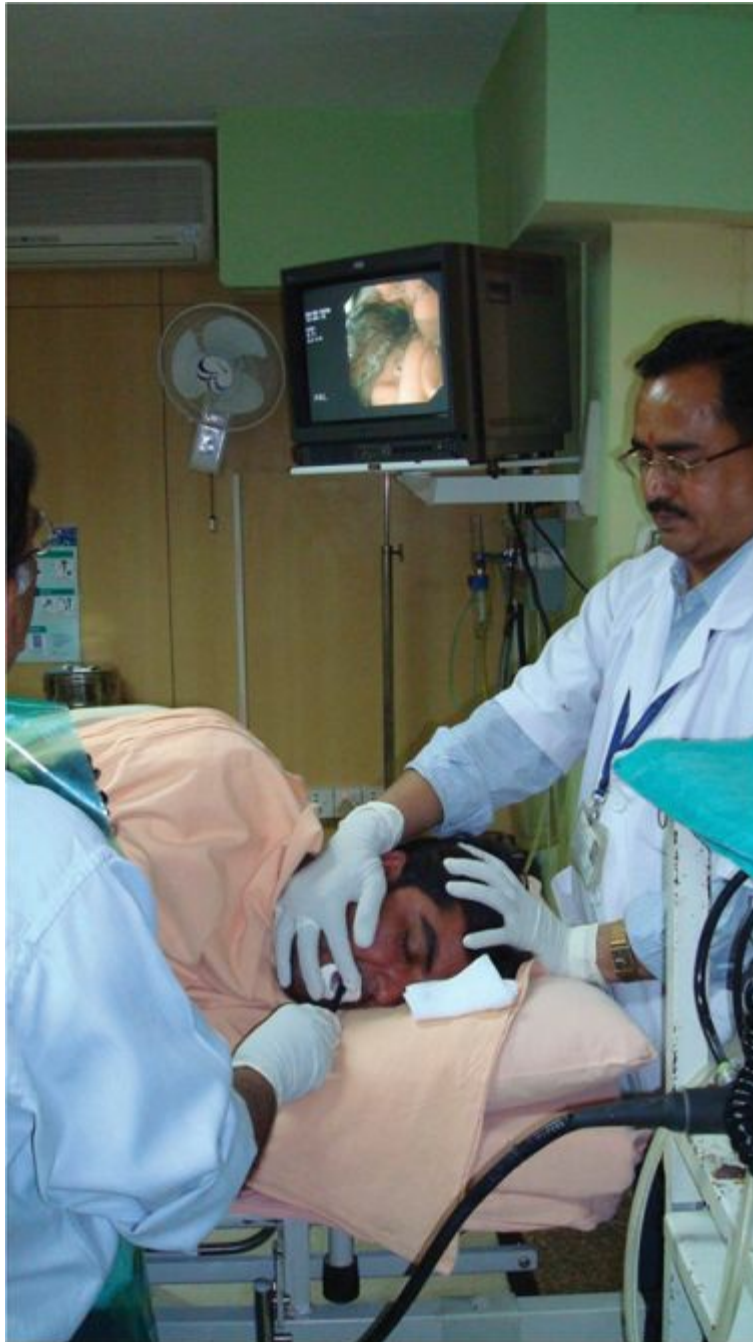*Never forget* to inspect the oesophageal wall again when the oesophagoscope is withdrawn.

## Post-operative Care

- **1.** Sips of plain water followed by usual diet may be given in an uneventful oesophagoscopy.
- **2.** Patient is watched for pain in the interscapular region, surgical emphysema of neck, and abrupt rise of temperature. They indicate oesophageal perforation.

## Complications

- 1. *Injury to lips and teeth.*
- 2. *Injury to arytenoids.*
- 3. *Injury to pharyngeal mucosa.* They are all the result of careless technique and can be avoided.
- 4. *Perforation of oesophagus.* Most often it occurs at the site of Killian's dehiscence (near cricopharyngeal sphincter) when undue force has been used to pass the oesophagoscope. Surgical emphysema develops within an hour or so and the patient complains of pain in the interscapular region. This may be complicated by abscess in retropharyngeal space or mediastinum.
- 5. *Compression of trachea.* Oesophagoscope may press on posterior tracheal wall, especially in children, causing obstruction to respiration and cyanosis. Treatment is immediate withdrawal of oesophagoscope.



Dhingra: Diseases of Ear Nose and Throat, 5th Edition  
Copyright © 2010 Elsevier. All rights reserved.

Figure 90.1 Flexible fibre optic oesophagoscopy.

## **FLEXIBLE FIBRE OPTIC OESOPHAGOSCOPY**

Its main advantage over the rigid oesophagoscopy is that it is an outpatient procedure, does not require general anaesthesia and can be used in patients with abnormalities of spine or jaw where rigid endoscopy is technically difficult. The oesophagus, stomach and duodenum can all be examined in one sitting. Good illumination and magnification provided by the fibrescope helps in the accurate diagnosis of the mucosal disease affecting these sites and permits taking of precision biopsies, removal of small foreign bodies or benign tumours, dilatation of webs or strictures and even injection of bleeding varices with sclerosing agents (Fig. 90.1). In cases of malignant disease, oesophageal stent can be placed as a palliative measure.

The procedure is performed under local anaesthesia with or without intravenous sedation. The patient lies in left lateral position and fibrescope is passed through a plastic mouth prop into the pharynx, post-cricoid area and oesophagus, insufflating air as the endoscope is advanced, to open the lumen of oesophagus. These days flexible fibre optic oesophagoscopy has practically replaced rigid oesophagoscopy except in some cases of foreign bodies.

# 91 Tonsillectomy

## Indications

They are divided into:

### A. Absolute

- **1. Recurrent infections of throat.** This is the most common indication. Recurrent infections are further defined as:
  - (a) Seven or more episodes in one year, or
  - (b) Five episodes per year for 2 years, or
  - (c) Three episodes per year for 3 years, or
  - (d) Two weeks or more of lost school or work in one year.
- **2. Peritonsillar abscess.** In children, tonsillectomy is done 4-6 weeks after abscess has been treated. In adults, second attack of peritonsillar abscess forms the absolute indication.
- **3. Tonsillitis causing febrile seizures.**
- **4. Hypertrophy of tonsils causing**
  - airway obstruction (sleep apnoea)
  - difficulty in deglutition
  - interference with speech.
- **5. Suspicion of malignancy.** A unilaterally enlarged tonsil may be a lymphoma in children and an epidermoid carcinoma in adults. An excisional biopsy is done.

### B. Relative

- **1.** Diphtheria carriers, who do not respond to antibiotics.
- **2.** Streptococcal carriers, who may be the source of infection to others.
- **3.** Chronic tonsillitis with bad taste or halitosis which is unresponsive to medical treatment.
- **4.** Recurrent streptococcal tonsillitis in a patient with valvular heart disease.

### C. As a Part of Another Operation

- **1.** Palatopharyngoplasty which is done for sleep apnoea syndrome.
- **2.** Glossopharyngeal neurectomy. Tonsil is removed first and then IX nerve is severed in the bed of tonsil.
- **3.** Removal of styloid process.

## Contraindications

- 1. Haemoglobin level less than 10 g%.
- 2. Presence of acute infection in upper respiratory tract, even acute tonsillitis. Bleeding is more in the presence of acute infection.
- 3. Children under 3 years of age. They are poor surgical risks.
- 4. Overt or submucous cleft palate.
- 5. Bleeding disorders, e.g. leukaemia, purpura, aplastic anaemia, haemophilia.
- 6. At the time of epidemic of polio.
- 7. Uncontrolled systemic disease, e.g. diabetes, cardiac disease, hypertension or asthma.
- 8. Tonsillectomy is avoided during the period of menses.



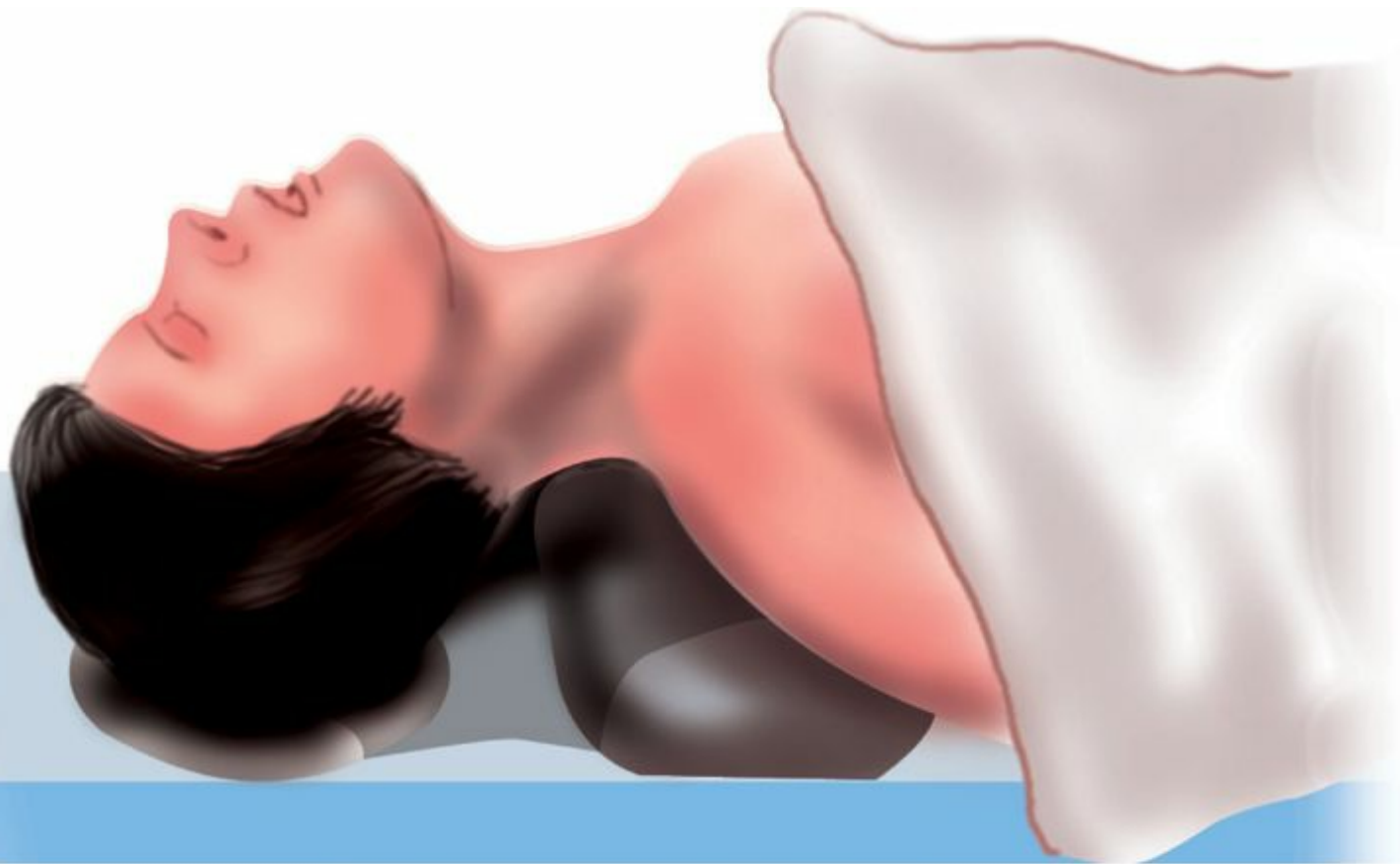
# Anaesthesia

Usually done under general anaesthesia with endotracheal intubation. In adults, it may be done under local anaesthesia.

## Position

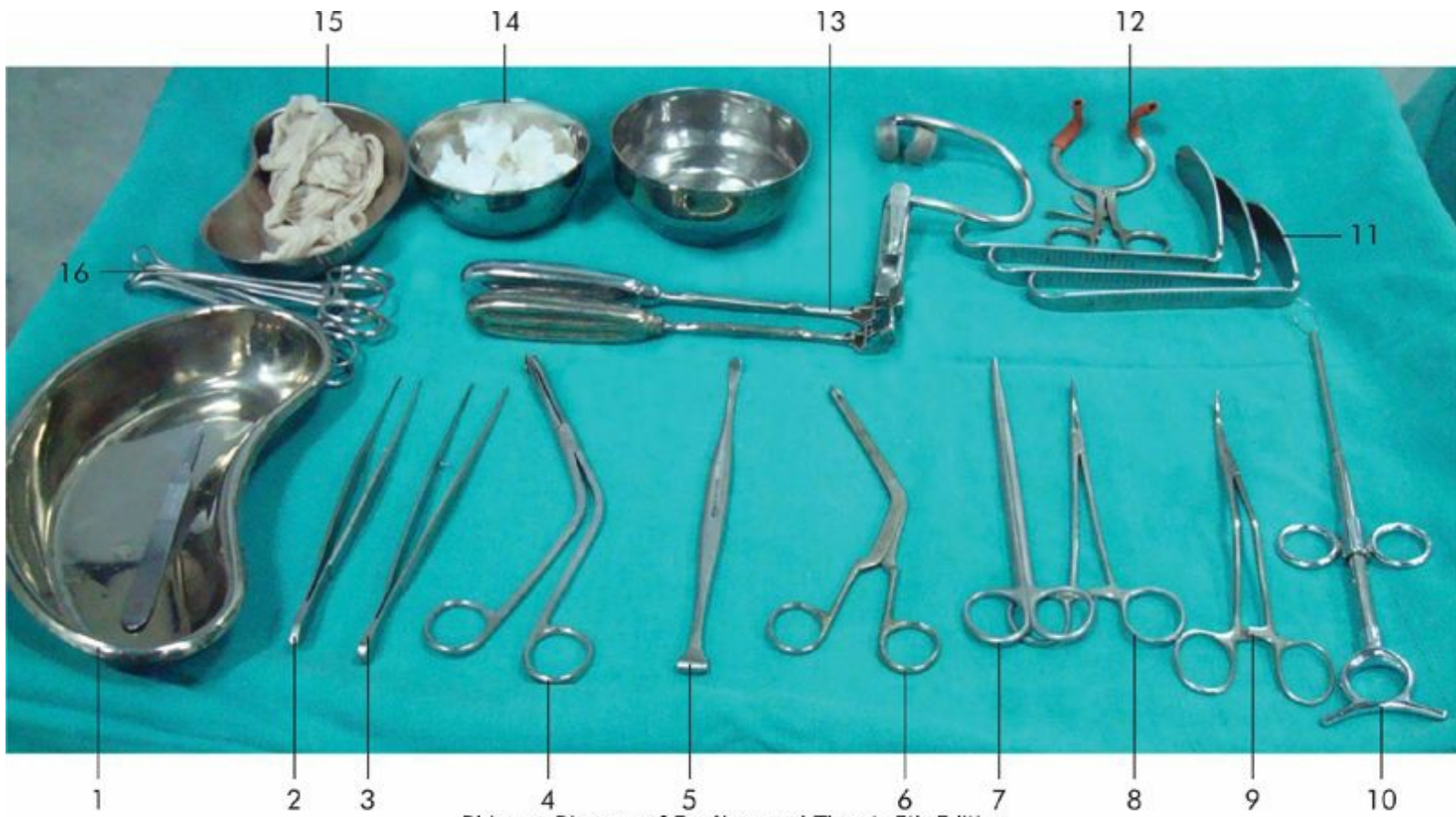Rose's position, i.e. patient lies supine with head extended by placing a pillow under the shoulders. A rubber ring is placed under the head to stabilise it (Fig. 91.1). Hyperextension should always be avoided.

- 1. Boyle-Davis mouth gag is introduced and opened. It is held in place by Draffin's bipods or a string over a pulley (Figs 91.2 and 91.3).
- 2. Tonsil is grasped with tonsil-holding forceps and pulled medially.
- 3. Incision is made in the mucous membrane where it reflects from the tonsil to anterior pillar. It may be extended along the upper pole to mucous membrane between the tonsil and posterior pillar.
- 4. A blunt curved scissor may be used to dissect the tonsil from the peritonsillar tissue and separate its upper pole.
- 5. Now the tonsil is held at its upper pole and traction applied downwards and medially. Dissection is continued with tonsillar dissector or scissors until lower pole is reached (Fig. 91.4).
- 6. Now wire loop of tonsillar snare is threaded over the tonsil on to its pedicle, tightened, and the pedicle cut and the tonsil removed.
- 7. A gauze sponge is placed in the fossa and pressure applied for a few minutes.
- 8. Bleeding points are tied with silk. Procedure is repeated on the other side.



Dhingra: Diseases of Ear Nose and Throat, 5th Edition  
Copyright © 2010 Elsevier. All rights reserved.

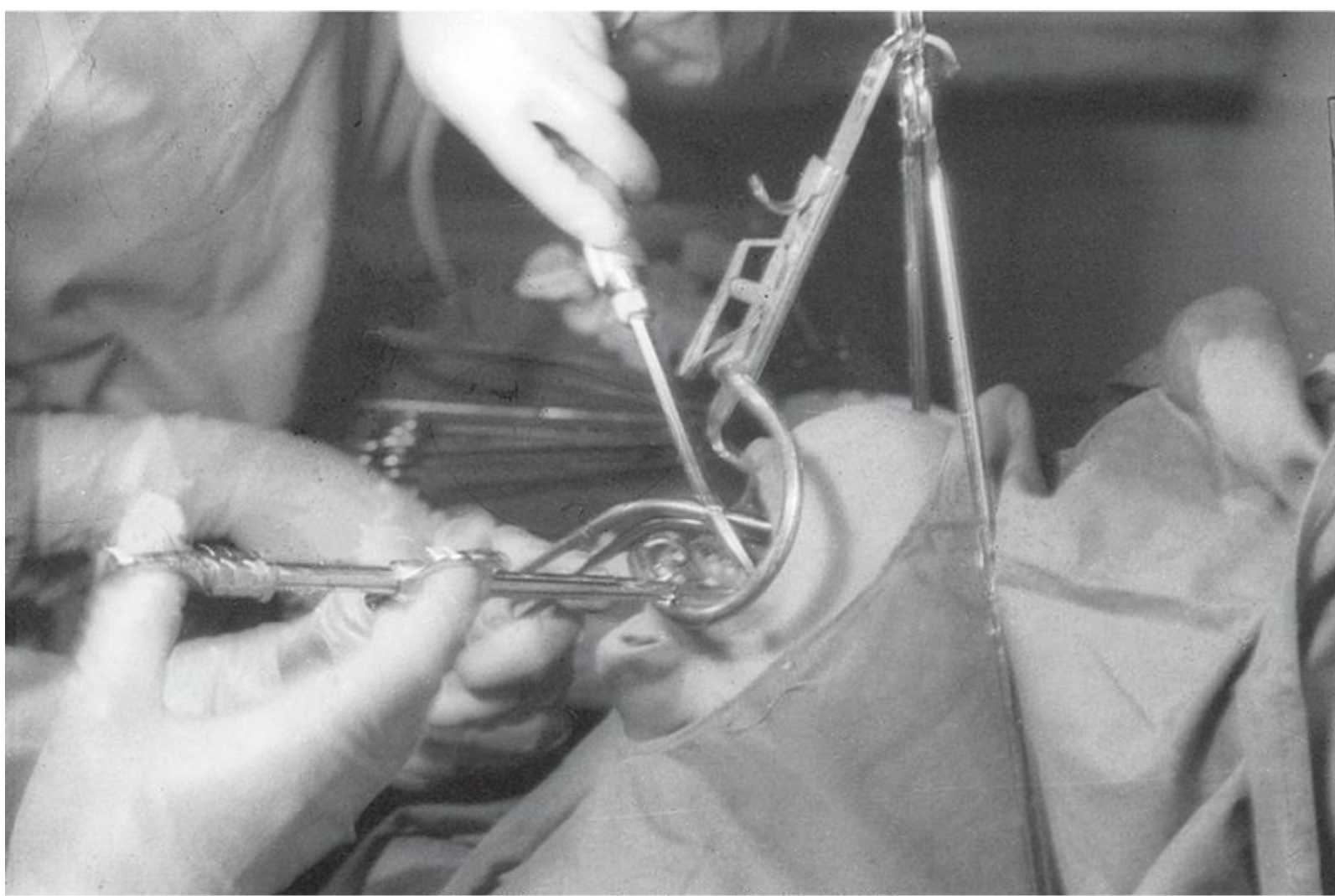
Figure 91.1 Rose's position for tonsillectomy. Neck is extended by a sand bag under the shoulders and the head is supported on a ring.



Dhingra: Diseases of Ear Nose and Throat, 5th Edition  
 Copyright © 2010 Elsevier. All rights reserved.

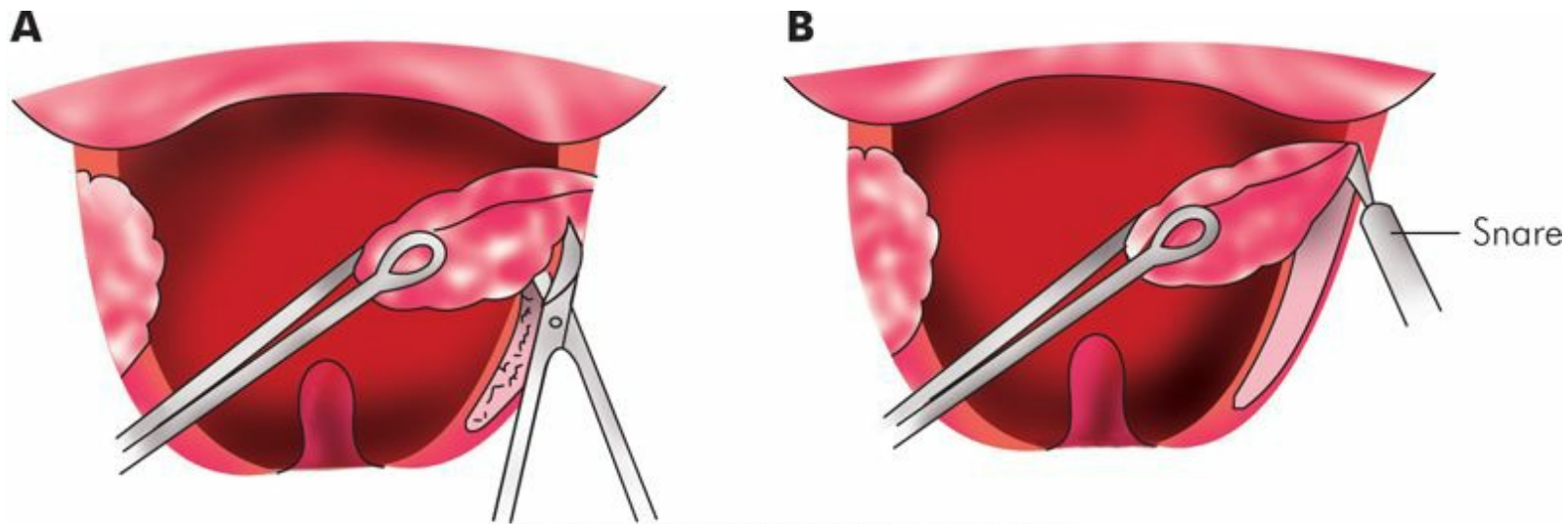
Figure 91.2 Set of instruments for tonsillectomy .

(1) Knife in kidney tray , (2) & (3) Toothed and non-toothed Waugh's forceps, (4) Tonsil holding forceps, (5) Tonsil dissector and anterior pillar retractor, (6) Luc's forceps, (7) Scissor, (8) Curved artery forceps, (9) Negus artery forceps, (10) Tonsillar snare, (11) Boyle Davis mouth gag with three sizes of tongue blades, (12) Doyen's mouth gag, (13) Adenoid curette, (14) Tonsil swabs, (15) Nasopharyngeal pack, (16) Towel clips.



Dhingra: Diseases of Ear Nose and Throat, 5th Edition  
Copyright © 2010 Elsevier. All rights reserved.

Figure 91.3 Tonsillectomy . Boyle-Davis mouth gag is supported on Draffin's bipods.



Dhingra: Diseases of Ear Nose and Throat, 5th Edition  
Copyright © 2010 Elsevier. All rights reserved.

Figure 91.4 (A) Tonsil being dissected from its bed. (B) The pedicle at the lower pole of tonsil being cut with a snare.

# Post-operative Care

## 1. Immediate general care

- (a) Keep the patient in coma position until fully recovered from anaesthesia.
- (b) Keep a watch on bleeding from the nose and mouth.
- (c) Keep check on vital signs, e.g. pulse, respiration and blood pressure.

## 2. Diet

When patient is fully recovered he is permitted to take liquids, e.g. cold milk or ice cream. Sucking of ice cubes gives relief from pain. Diet is gradually built from soft to solid food. They may take custard, jelly, soft boiled eggs or slice of bread soaked in milk on the 2nd day. Plenty of fluids should be encouraged.

## 3. Oral hygiene

Patient is given Condy's or salt water gargles 3-4 times a day. A mouth wash with plain water after every feed helps to keep the mouth clean.

## 4. Analgesics

Pain, locally in the throat and referred to ear, can be relieved by analgesics like paracetamol. An analgesic can be given half an hour before meals.

## 5. Antibiotics

A suitable antibiotic can be given orally or by injection for a week.

Patient is usually sent home 24 hours after operation unless there is some complication. Patient can resume his normal duties within 2 weeks.

Other methods for tonsillectomy (Table 91.1)

1. *Guillotine method*. Largely abandoned. It can be done only when tonsils are mobile and tonsil bed has not been scarred by repeated infections.
2. *Electrocautery*. Both unipolar and bipolar electrocautery has been used. It reduces blood loss but causes thermal injury to tissues.

Table 91-1. Techniques of tonsillectomy/tonsillotomy

Cold Methods	
I	Dissection and snare (most common)
II	Guillotine method
III	Intracapsular (capsule preserving) tonsillectomy with debrider
IV	Harmonic scalpel (ultrasound)
V	Plasma-mediated ablation technique
VI	Cryosurgical technique
Hot methods	
I	Electrocautery
II	Laser tonsillectomy or tonsillotomy (CO <sub>2</sub> or KTP)
III	Coblation tonsillectomy
IV	Radio frequency

3. *Laser tonsillectomy*. It is indicated in coagulation disorders. Both KTP-512 and CO<sub>2</sub> lasers have been used but the former is preferred. Technique is similar to one used in dissection method.

4. *Laser tonsillotomy*. Another method is laser tonsillotomy which aims to reduce the size of tonsils. It is indicated in patients who are unable to tolerate general anaesthesia. Tonsils are reduced by laser ablation up to anterior pillars by stage repeated applications.

5. *Intracapsular tonsillectomy*. With the use of powered instruments (debrider) tonsil is removed but its capsule is preserved in the hope to reduce post-operative pain.

6. *Harmonic scalpel*. It uses ultrasound to cut and coagulate tissues. It is a cold method with less tissue damage and post-operative pain compared to electrocautery technique.

7. *Plasma-mediated ablation technique*. In this ablation method, protons are energized to break molecular bonds between tissues. It is a cold method and does not cause thermal injury.

8. *Coblation tonsillectomy*.

---

page 440

page 441

9. *Cryosurgical technique*. Tonsil is frozen by application of cryoprobe and then allowed to thaw. Two applications, each of 3-4 minutes, are applied. Tonsillar tissue will undergo necrosis and later fall off leaving a granulating surface. Bleeding is less due to thrombosis of vessels caused by freezing.

# Complications

## A. Immediate

1. *Primary haemorrhage*. Occurs at the time of operation. It can be controlled by pressure, ligation or electrocoagulation of the bleeding vessels.
2. *Reactionary haemorrhage*. Occurs within a period of 24 hours and can be controlled by simple measures such as removal of the clot, application of pressure or vasoconstrictor. Presence of a clot prevents the clipping action of the superior constrictor muscle on the vessels which pass through it (compare post-partum uterine bleeding). If above measures fail, ligation or electrocoagulation of the bleeding vessels can be done under general anaesthesia.
3. *Injury to tonsillar pillars, uvula, soft palate*, tongue or superior constrictor muscle due to bad surgical technique.
4. *Injury to teeth*.
5. *Aspiration of blood*.
6. *Facial oedema*. Some patients get oedema of the face particularly of the eyelids.
7. *Surgical emphysema*. Rarely occurs due to injury to superior constrictor muscle.

## B. Delayed

1. *Secondary haemorrhage*. Usually seen between the 5th to 10th post-operative day. It is the result of sepsis and premature separation of the membrane. Usually, it is heralded by bloodstained sputum but may be profuse.

Simple measures like removal of clot, topical application of dilute adrenaline or hydrogen peroxide with pressure usually suffice. For profuse bleeding, general anaesthesia is given and bleeding vessel is electrocoagulated or ligated. Sometimes, approximation of pillars with mattress sutures may be required. Sometimes, external carotid ligation may also be required.

Transfusion of blood or plasma, depending on blood loss, is given. Systemic antibiotics are given for control of infection.

2. *Infection*. Infection of tonsillar fossa may lead to parapharyngeal abscess or otitis media.
3. *Lung complications*. Aspiration of blood, mucus or tissue fragments may cause atelectasis or lung abscess.
4. *Scarring in soft palate and pillars*.
5. *Tonsillar remnants*. Tonsil tags or tissue, left due to inadequate surgery, may get repeatedly infected.
6. *Hypertrophy of lingual tonsil*. This is a late complication and is compensatory to loss of palatine tonsils.

Sometimes, lymphoid tissue is left in the plica triangularis near the lower pole of tonsil, which later gets hypertrophied. Plica triangularis should, therefore be removed during tonsillectomy.



## **92 Adenoidectomy**

Adenoidectomy may be indicated alone or in combination with tonsillectomy. In the latter event, adenoids are removed first and the nasopharynx packed before starting tonsillectomy.

## Indications

- **1.** Adenoid hypertrophy causing snoring, mouth breathing, sleep apnoea syndrome or speech abnormalities, i.e. (rhinolalia clausa).
- **2.** Recurrent rhinosinusitis.
- **3.** Chronic secretory otitis media associated with adenoid hyperplasia.
- **4.** Recurrent ear discharge in benign CSOM associated with adenoiditis/adenoid hyperplasia.
- **5.** Dental malocclusion. Adenoidectomy does not correct dental abnormalities but will prevent its recurrence after orthodontic treatment.

## Contraindications

- **1.** Cleft palate or submucous palate. Removal of adenoids causes velopharyngeal insufficiency in such cases.
- **2.** Haemorrhagic diathesis.
- **3.** Acute infection of upper respiratory tract.

# Anaesthesia

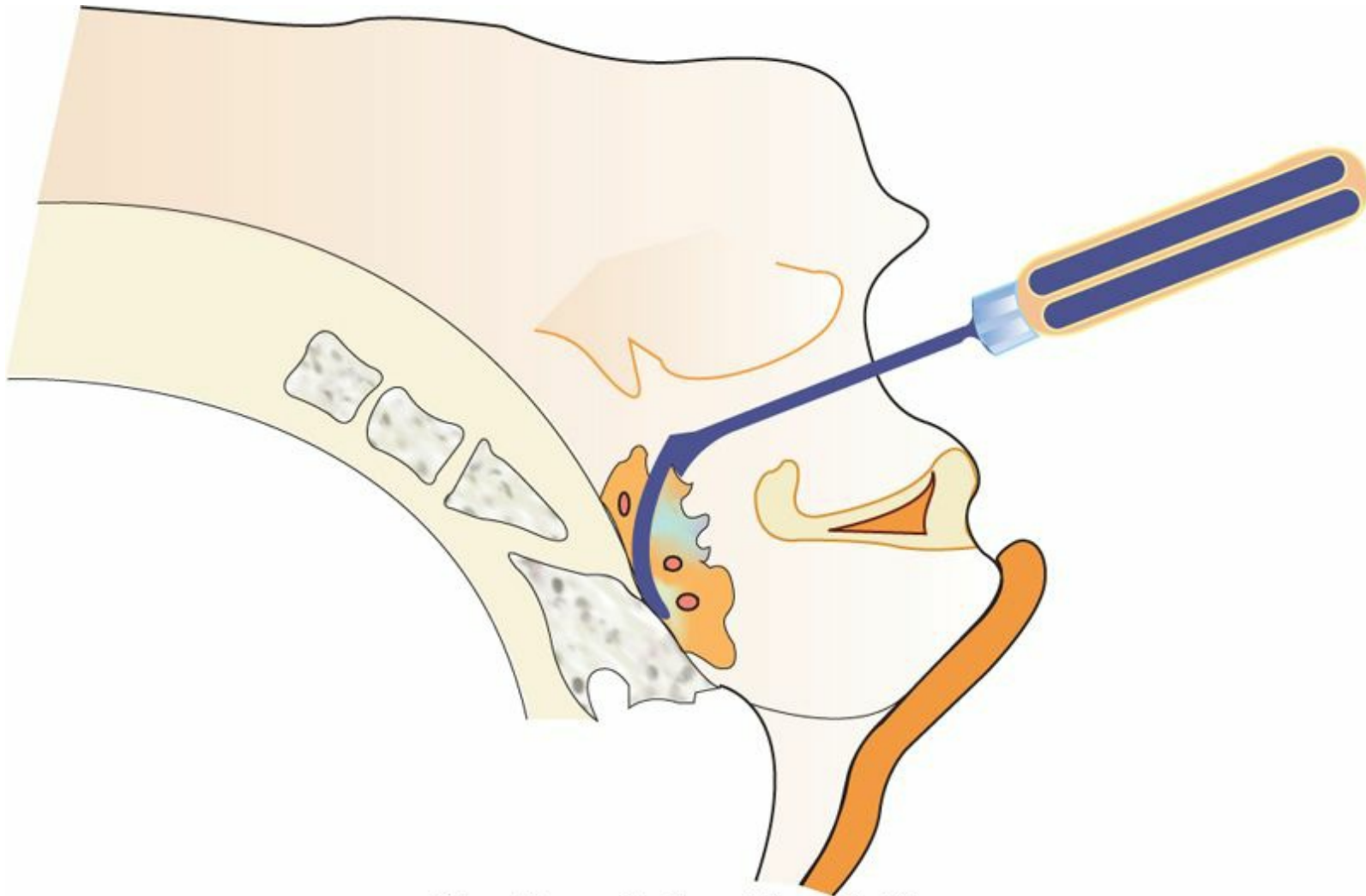
Always general, with oral endotracheal intubation.

## Position

Same as for tonsillectomy. Hyperextension of neck should always be avoided.

## Steps of Operation

- **1.** Boyle-Davis mouth-gag is inserted. Before actual removal of adenoids, nasopharynx should always be examined by retracting the soft palate with curved end of the tongue depressor and by digital palpation, to confirm the diagnosis, to assess the size of adenoids mass and to push the lateral adenoid masses towards the midline.
- **2.** Proper size of "adenoid curette with guard" is introduced into the nasopharynx till its free edge touches the posterior border of nasal septum and is then pressed backwards to engage the adenoids. At this level, head should be slightly flexed to avoid injury to the odontoid process.
- **3.** With gentle sweeping movement, adenoids are shaved off (Fig. 92.1). Lateral masses are similarly removed with smaller curettes; small tags of lymphoid tissue left behind are removed with punch forceps.
- **4.** Haemostasis is achieved by packing the area for sometime. Persistent bleeders are electrocoagulated under vision. If bleeding is still not controlled, a postnasal pack is left for 24 hours.



Dhingra: Diseases of Ear Nose and Throat, 5th Edition  
Copyright © 2010 Elsevier. All rights reserved.

Figure 92.1 Adenoidectomy.

# Endoscopic Adenoidectomy

These days adenoids can be removed more precisely by using a debrider under endoscopic control.

## Post-operative Care

Same as in tonsillectomy. There is no dysphagia and patient is up and about early.



## Complications

- **1. Haemorrhage**, usually seen in immediate post-operative period. Nose and mouth may be full of blood or the only indication may be vomitus of dark-coloured blood which the patient had been swallowing gradually in post-operative period. Rising pulse rate is another indicator. Treatment is same as for per-operative haemorrhage. Postnasal pack under general anaesthesia is often required.
- **2. Injury to eustachian tube opening.**
- **3. Injury to pharyngeal musculature and vertebrae.** This is due to hyperextension of neck and undue pressure of curette. Care should be taken when operating patients of Down's syndrome as 10-20% of them have atlanto-axial instability.
- **4. Griesel syndrome.** Patient complains of neck pain and develops torticollis. Mostly it is due to spasm of paraspinal muscles, but can be due to atlanto-axial dislocation requiring cervical collar and even traction.
- **5. Velopharyngeal insufficiency.** It is necessary to check for submucous cleft palate by inspection and palpation before removal of adenoids.
- **6. Nasopharyngeal stenosis** due to scarring.
- **7. Recurrence.** This is due to regrowth of adenoid tissue left behind.

# 93 Radiology in ENT

## TEMPORAL BONE

### 1. Law's view

It is lateral oblique view of mastoid.

Patient lies in such a way that sagittal plane of the skull is parallel to the film and X-ray beam is projected 15° cephalocaudal.

Structures seen are:

- (i) External auditory canal superimposed on internal auditory canal.
- (ii) Mastoid air cells.
- (iii) Tegmen.
- (iv) Lateral sinus plate.
- (v) Temporomandibular joint.

"Key area" of the mastoid, i.e. attic, aditus and antrum are not well seen.

### 2. Schuller's view

Similar to Law's view but cephalocaudal beam makes an angle of 30° to the sagittal.

Structures seen are:

- (i) External canal superimposed on internal canal
- (ii) Mastoid air cells
- (iii) Tegmen
- (iv) Lateral sinus plate
- (v) Condyle of mandible
- (vi) Sino-dural angle
- (vii) Antrum and upper part of attic (i.e. key area).

This view is taken to see the extent of pneumatisation, destruction of intercellular septa (as in mastoiditis), location of sinus plate and tegmen, cholesteatoma and longitudinal fracture of petrous pyramid.

### 3. Stenver's view

This view is taken in such a way that long axis of the petrous bone lies parallel to the film.

Structures seen are:

- (i) Entire petrous pyramid
- (ii) Arcuate eminence
- (iii) Internal auditory meatus
- (iv) Labyrinth with its vestibule
- (v) Cochlea
- (vi) Mastoid antrum.

### 4. Towne's view

It is anteroposterior view with 30° tilt from above and in front. It shows both petrous pyramids which can be compared.

Structures seen are:

- (i) Arcuate eminence and superior semicircular canal.
- (ii) Mastoid antrum.
- (iii) Internal auditory canal.
- (iv) Tympanic cavity.
- (v) Cochlea.
- (vi) External auditory canal.

This view is usually taken for acoustic neuroma, and apical petrositis.

### 5. Transorbital view

This view is taken with occiput on the film with orbitomeatal line at right angles to the film. X-ray beam passes through the orbit.

Structures seen are:

- **(i)** Internal auditory canal.
- **(ii)** Cochlea.
- **(iii)** Labyrinth.
- **(iv)** Entire petrous pyramid projected through the orbit.

Since both petrous pyramids are seen, structures on one side can be compared with the those of the opposite side.

This view is usually done for acoustic neuroma and petrous pyramid.

#### **6. Submentovertical view**

This view is taken with vertex near the film and X-ray beam projected at right angles to the film from the submental area.

---

page 444

page 445

Structures seen are:

- **(i)** External auditory canal.
- **(ii)** Middle ear cleft, i.e. mastoid cells, middle ear and eustachian tube.
- **(iii)** Internal auditory canal.
- **(iv)** Sphenoid sinus.
- **(v)** Foramen ovale and spinosum.
- **(vi)** Carotid canal.

# PARANASAL SINUSES

## **1. Waters' view (Occipitomenal view or nose-chin position)**

It is taken in such a way that nose and chin of the patient touch the film while X-ray beam is projected from behind. Waters' view with open mouth is preferred as it also shows sphenoid sinus. In this view, petrous bones are projected below the maxillary antra.

Structures seen are:

- (i) Maxillary sinuses (seen best).
- (ii) Frontal sinuses.
- (iii) Sphenoid sinus (if the film is taken with open mouth).
- (iv) Zygoma.
- (v) Zygomatic arch.
- (vi) Nasal bone.
- (vii) Frontal process of maxilla.
- (viii) Superior orbital fissure.
- (ix) Infratemporal fossa.

## **2. Caldwell view (Occipitofrontal view or nose-forehead position)**

The view is taken with nose and forehead touching the film and X-ray beam is projected 15-20° caudally.

Structures seen are:

- (i) Frontal sinuses (seen best).
- (ii) Ethmoid sinuses.
- (iii) Maxillary sinuses.
- (iv) Frontal process of zygoma and zygomatic process of frontal bone.
- (v) Superior margin of orbit and lamina papyracea.
- (vi) Superior orbital fissure.
- (vii) Foramen rotundum (inferolateral to superior orbital fissure).

## **3. Lateral view**

Lateral side of the skull lies against the film and X-ray beam is projected perpendicular from the other side.

Structures seen are:

- (i) Anterior and posterior extent of sphenoid, frontal and maxillary sinuses.
- (ii) Sella turcica.
- (iii) Ethmoid sinuses.
- (iv) Alveolar process.
- (v) Condyle and neck of mandible.

## **4. Submentovertical (Basal) view**

This view is taken as described earlier.

Structures seen are:

- (i) Sphenoid, posterior ethmoid and maxillary sinuses (seen best in that order).
- (ii) Zygoma.
- (iii) Zygomatic arch.
- (iv) Mandible along with coronoid and condyloid processes.

Right and left oblique views

They are taken to see the posterior ethmoid sinuses and the optic foramen of the corresponding side.

# X-RAYS FOR NASAL FRACTURES

## **1. Lateral view of nasal bones**

Both right and left lateral views should be taken. Fracture line and depression or elevation of the fractured segment is seen. Lower part of nasal bones is thin, and fractured more frequently. *Groove for ethmoidal nerve and vessels can be seen running downwards and forwards and may look like fracture line.*

## **2. Occlusal view of nasal bone**

In this the X-ray film is held between the teeth, and central beam is projected perpendicular to the film. Both sides of the nasal pyramid are seen. Fracture line and lateral displacement of the nasal pyramid is seen clearly.

## **3. Waters' view**

It gives end-on view of nasal arch. Fractures of right and left nasal bones and their lateral displacement can be seen.

# NECK, LARYNX AND PHARYNX

## ***Lateral view of neck***

It is an extremely useful view in ENT. In a normal person, it shows:

- **(i)** Outline of base of tongue.
- **(ii)** Vallecula.
- **(iii)** Hyoid bone.
- **(iv)** Epiglottis and aryepiglottic folds.
- **(v)** Arytenoids.
- **(vi)** False and true cords with ventricle in between them.
- **(vii)** Thyroid and cricoid cartilages.
- **(viii)** Subglottic space and trachea.
- **(ix)** Prevertebral soft tissues.
- **(x)** Cervical spine.
- **(xi)** Pretracheal soft tissues and thyroid.

page 445

page 446

This view helps in the diagnosis of:

- **(i)** Foreign bodies of larynx, pharynx and upper oesophagus and to differentiate a foreign body of the airway from that of the food passage.
- **(ii)** Acute epiglottitis (Thumb sign).
- **(iii)** Retropharyngeal abscess.
- **(iv)** Position of tracheostomy tube, T-tube or laryngeal stent.
- **(v)** Laryngeal stenosis.
- **(vi)** Fractures of larynx and hyoid bone and their displacement.
- **(vii)** Compression of trachea by thyroid or retropharyngeal masses.
- **(viii)** Caries of cervical spine, associated with retropharyngeal abscess or osteophytes in cervical vertebrae or injuries of spine.

## ***Anteroposterior view of neck***

This view is useful to differentiate a foreign body of larynx from that of oesophagus. It is also done to see any compression or displacement of trachea by lateral neck masses, e.g. thyroid tumours or enlargement.

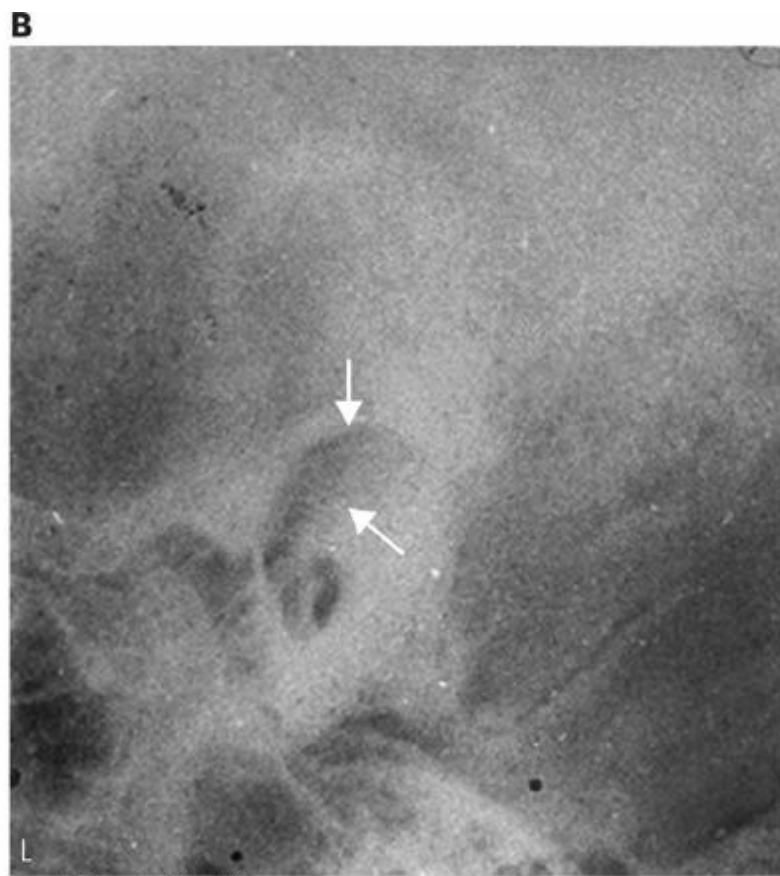
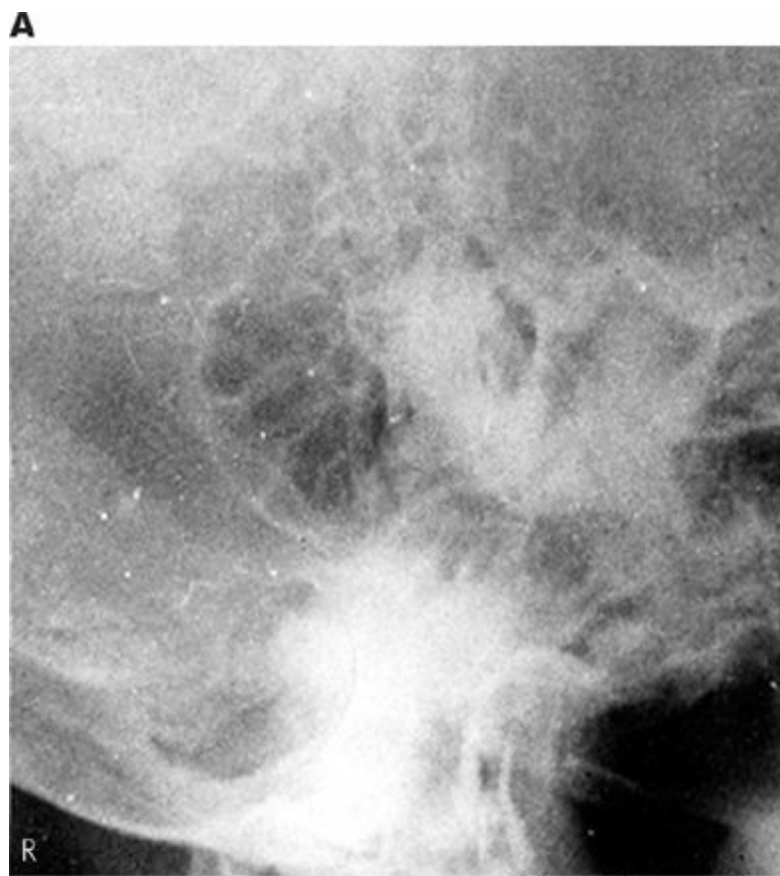
## ***Soft tissue lateral view of nasopharynx***

This is usually taken to assess soft tissue masses in the nasopharynx e.g., adenoids, antrochoanal polyp or angiofibroma.

The structures seen are:

- **(i)** Nasal cavity. A foreign body in the nose can be seen. Interruption of air column from nose to nasopharynx may indicate a tumour or choanal atresia.
- **(ii)** Soft palate.
- **(iii)** Roof and posterior wall of nasopharynx. Adenoid mass may be seen arising from posterosuperior wall of nasopharynx and compromising the airway.

Antrochoanal polyp may also show a soft tissue density, but usually a column of air is seen between the mass and posterior wall of nasopharynx. This column of air differentiates antrochoanal polyp from other nasopharyngeal masses arising from posterosuperior wall of nasopharynx e.g. angiofibroma.

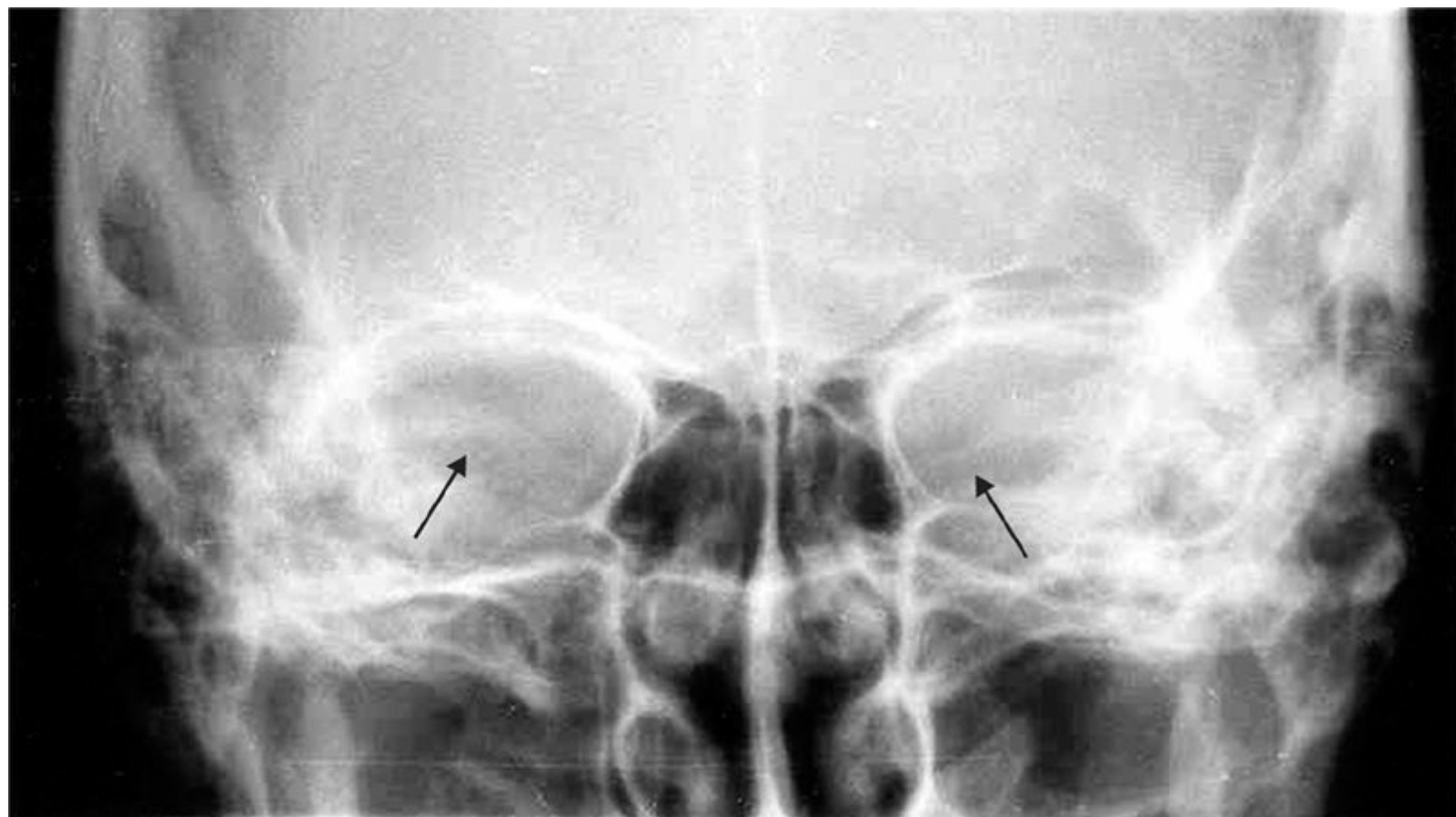


Dhingra: Diseases of Ear Nose and Throat, 5th Edition  
Copyright © 2010 Elsevier. All rights reserved.

Law's view of mastoid. (A) Note normal structures and pneumatisation on the right. (B) On the left side mastoid is sclerotic with destruction (arrows) of the "key area" due to cholesteatoma.

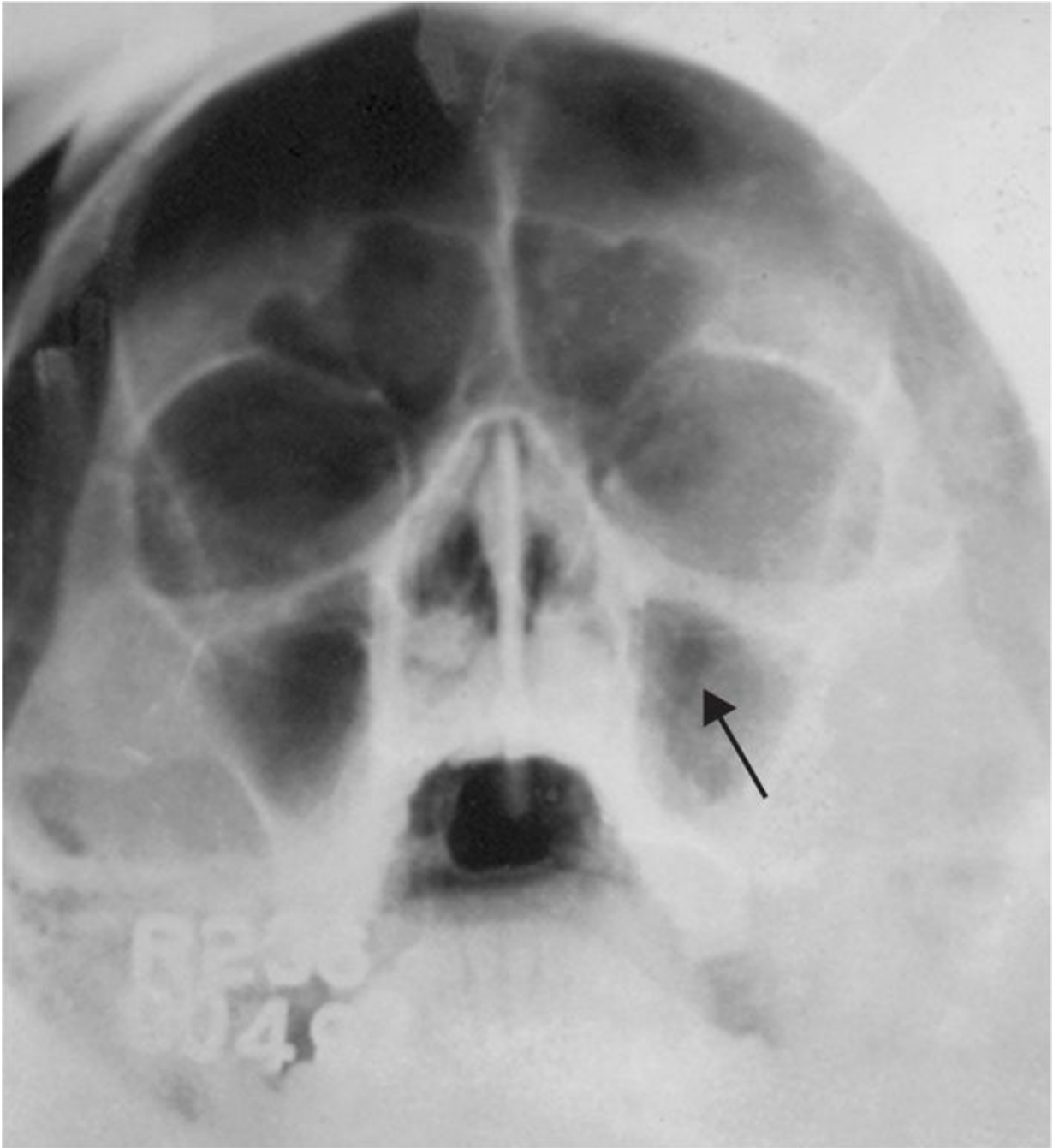
page 446

page 447



Dhingra: Diseases of Ear Nose and Throat, 5th Edition  
Copyright © 2010 Elsevier. All rights reserved.

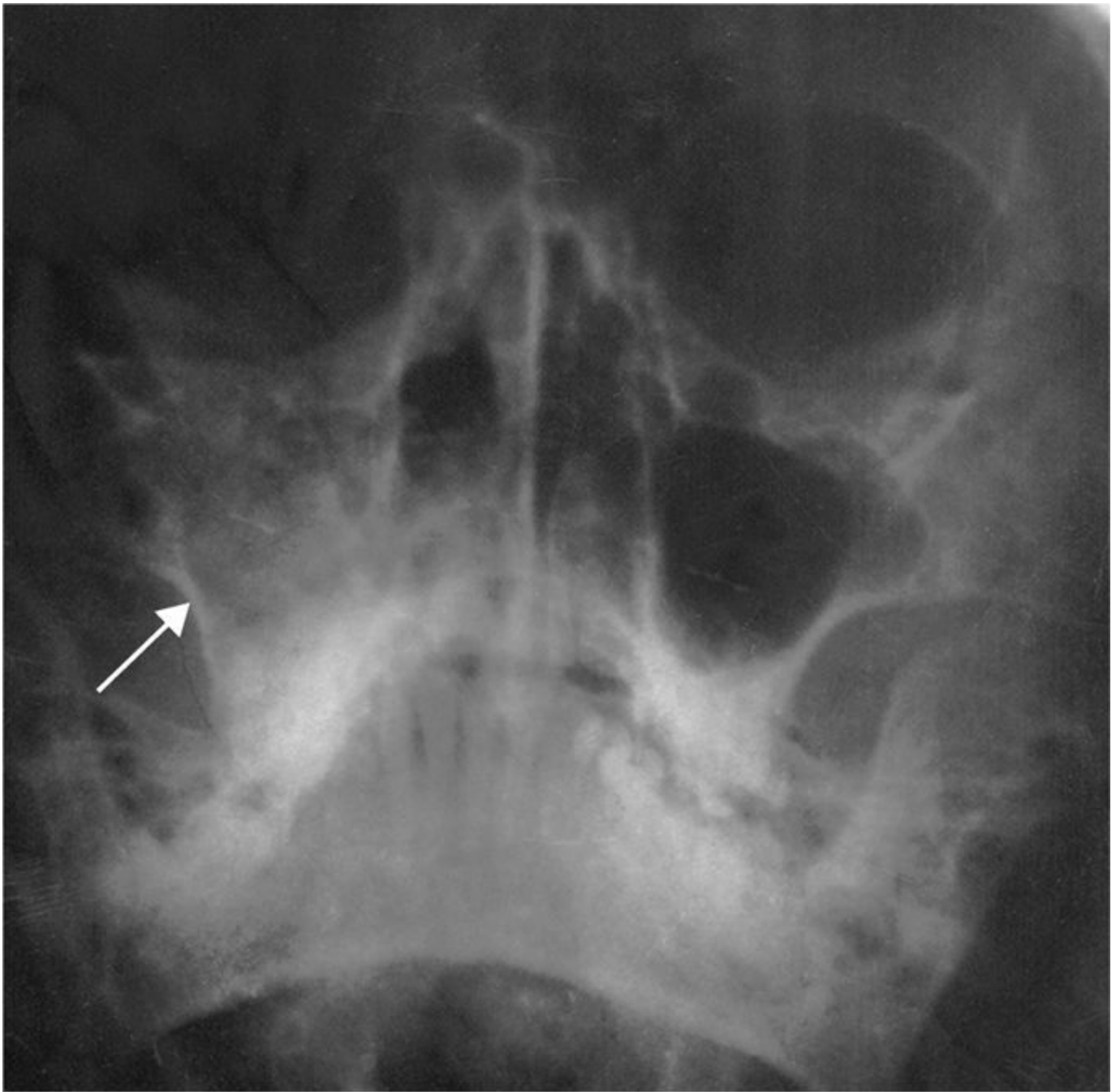
Transorbital view. Note both petrous pyramids are projected through the orbits. Internal auditory meatus and labyrinths are seen on both sides. Internal auditory canals of both sides are normal in shape and dimensions (arrows).



Dhingra: Diseases of Ear Nose and Throat, 5th Edition  
Copyright © 2010 Elsevier. All rights reserved.

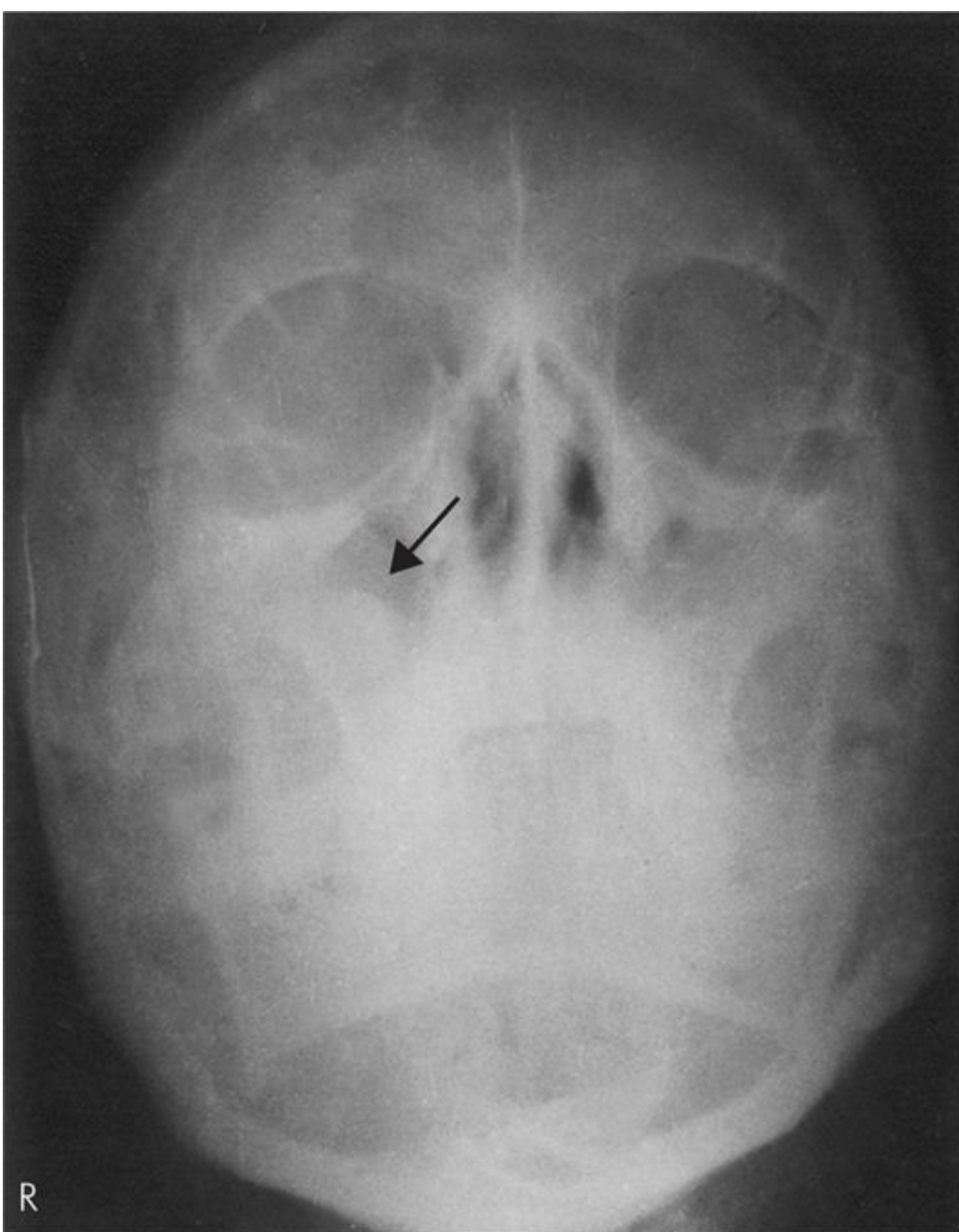
Waters' view with open mouth. Note haziness of left maxillary sinus due to mucosal hypertrophy (arrow). Other sinuses appear normal.





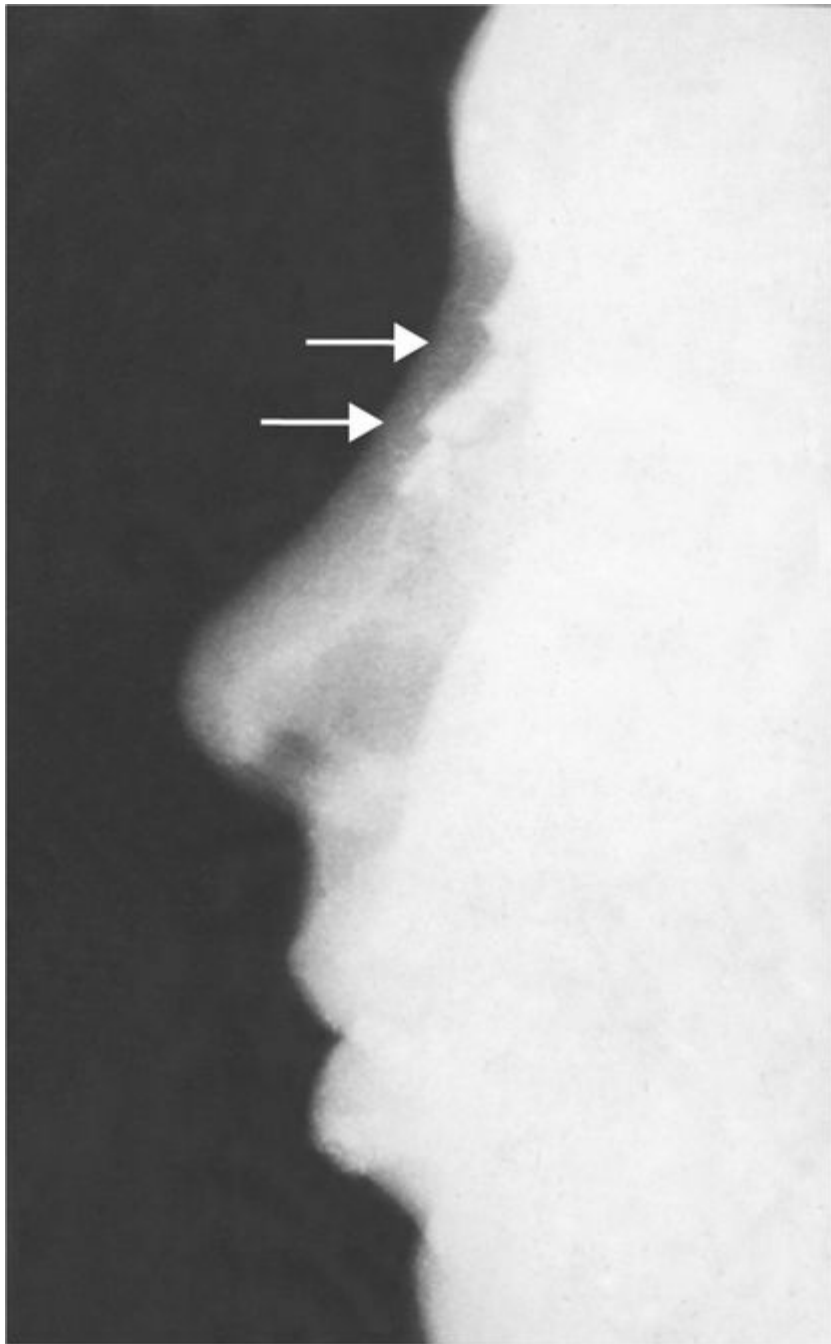
Dhingra: Diseases of Ear Nose and Throat, 5th Edition  
Copyright © 2010 Elsevier. All rights reserved.

Waters' view. Note opacity in right maxillary sinus due to sinusitis (arrow).



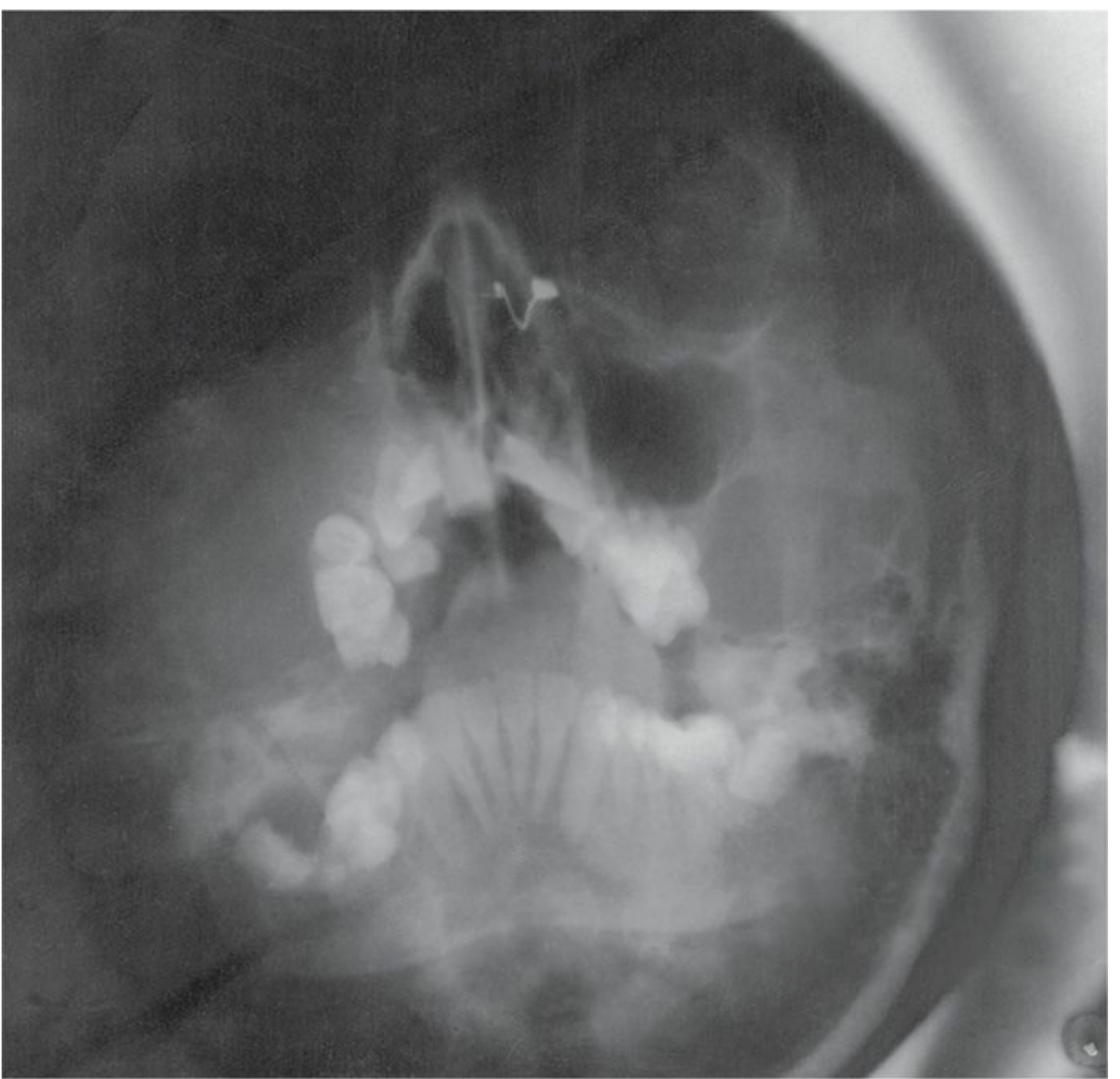
Dhingra: Diseases of Ear Nose and Throat, 5th Edition  
Copyright © 2010 Elsevier. All rights reserved.

Waters' view showing a globular cyst in the right (arrow) and mucosal hypertrophy in the left maxillary sinus.



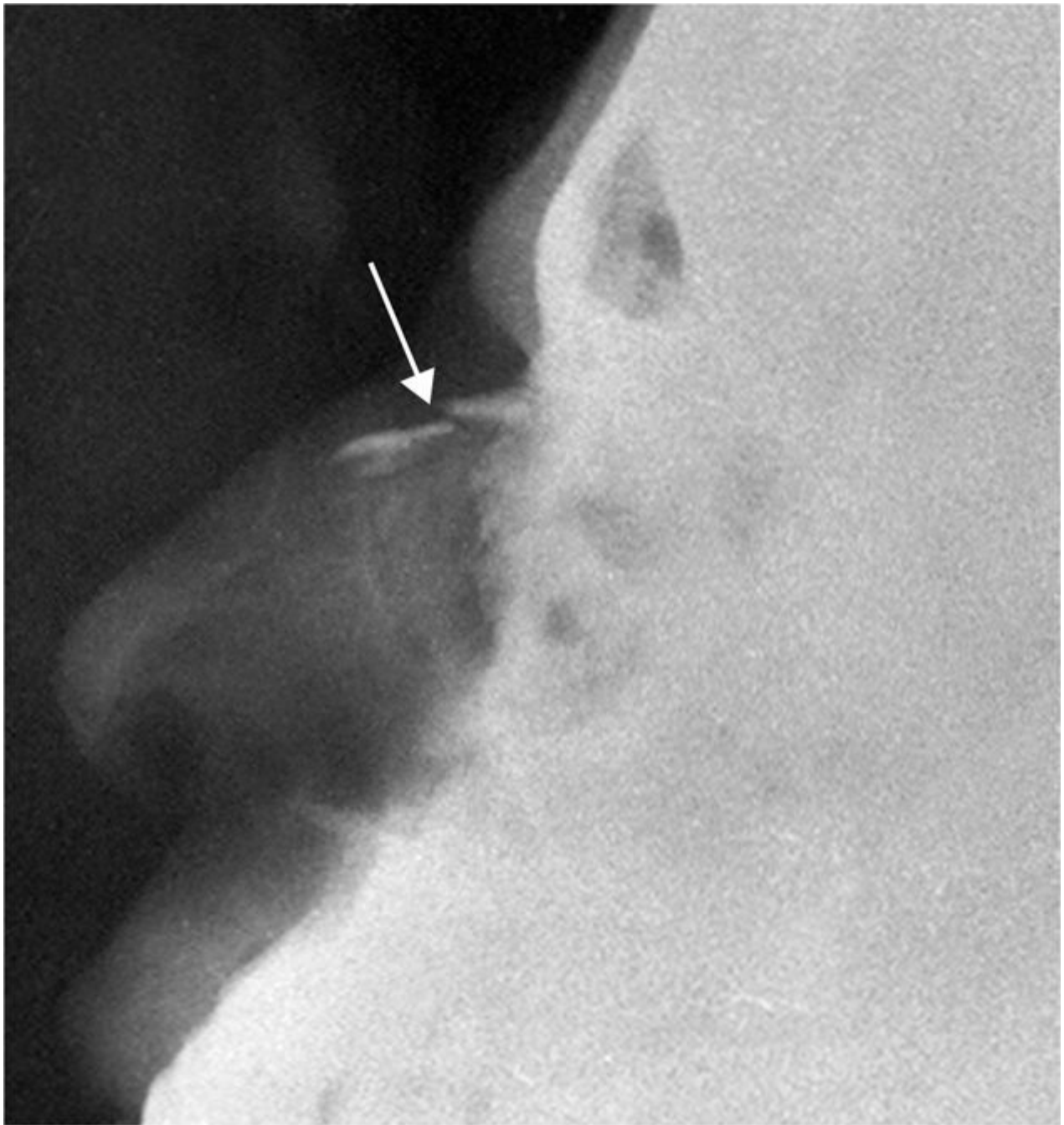
Dhingra: Diseases of Ear Nose and Throat, 5th Edition  
Copyright © 2010 Elsevier. All rights reserved.

Lateral view of nasal bones showing fracture.



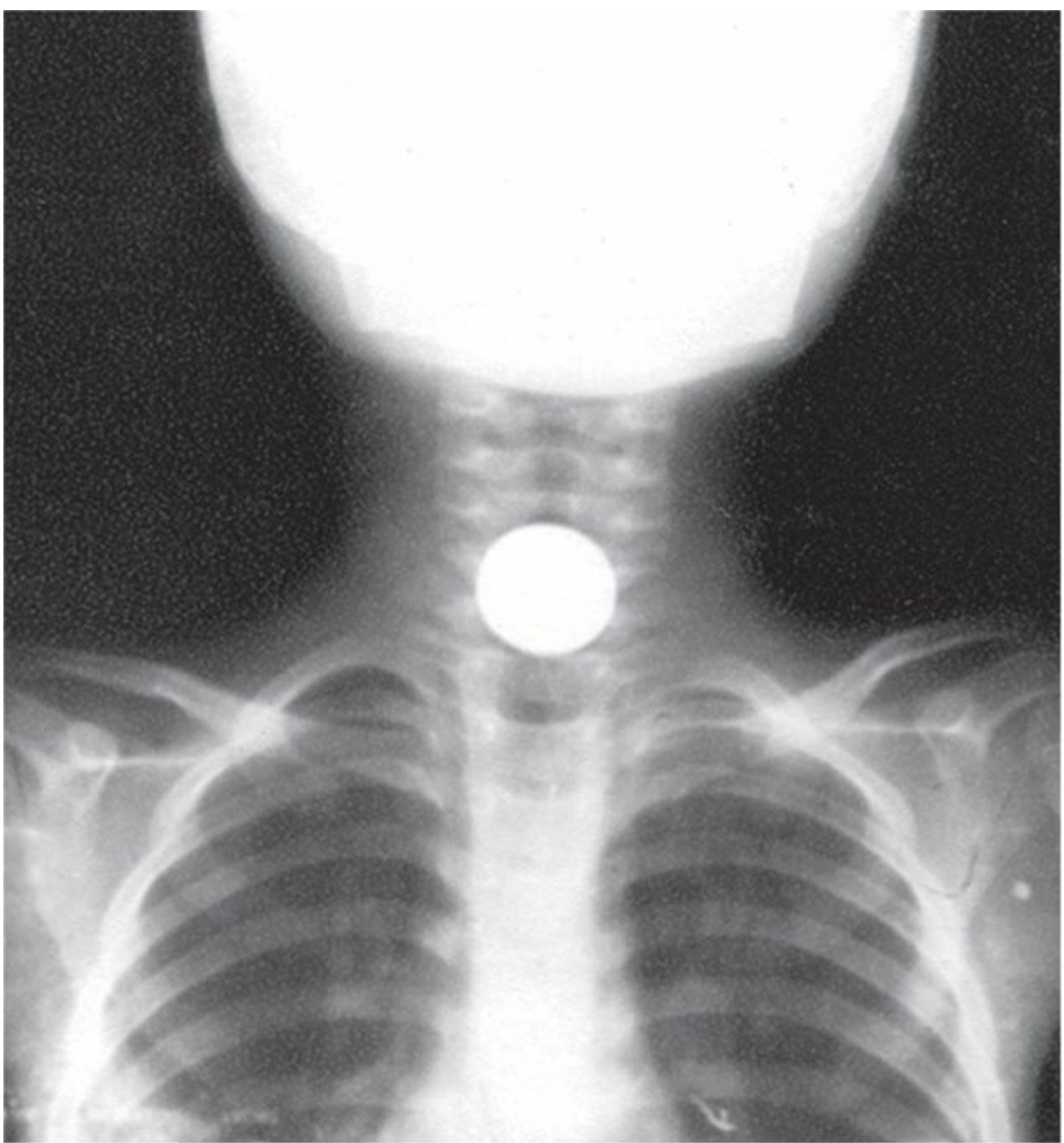
Dhingra: Diseases of Ear Nose and Throat, 5th Edition  
Copyright © 2010 Elsevier. All rights reserved.

Waters' view showing carcinoma right maxillary sinus. Note: (i) Soft tissue expansion. (ii) Bony destruction of walls of maxillary sinus.



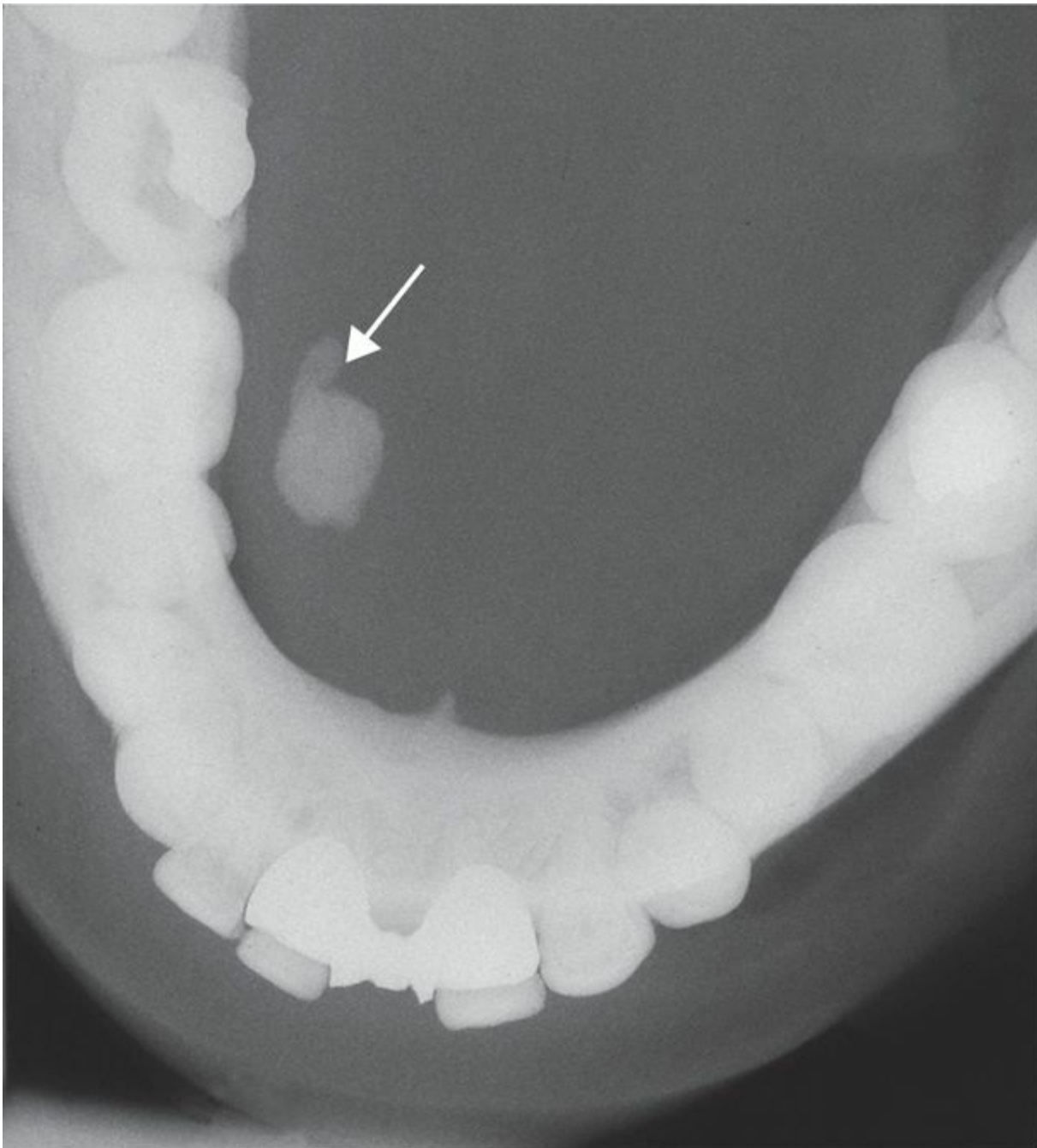
Dhingra: Diseases of Ear Nose and Throat, 5th Edition  
Copyright © 2010 Elsevier. All rights reserved.

Lateral view-nasal bones. Note fracture of nasal bone (arrow).



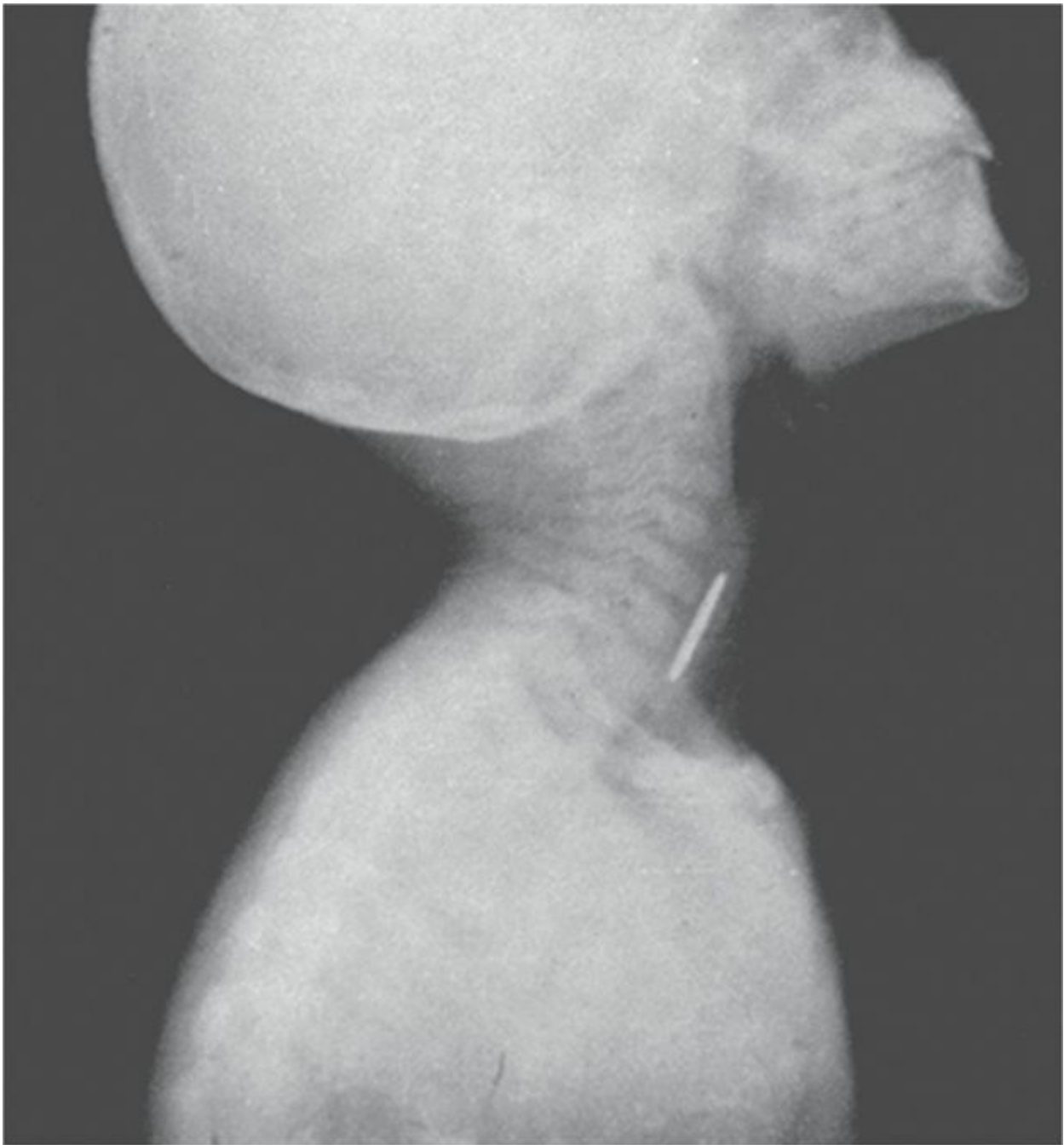
Dhingra: Diseases of Ear Nose and Throat, 5th Edition  
Copyright © 2010 Elsevier. All rights reserved.

P.A. view. A radio-opaque foreign body (coin) in the oesophagus at the level of thoracic inlet.



Dhingra: Diseases of Ear Nose and Throat, 5th Edition  
Copyright © 2010 Elsevier. All rights reserved.

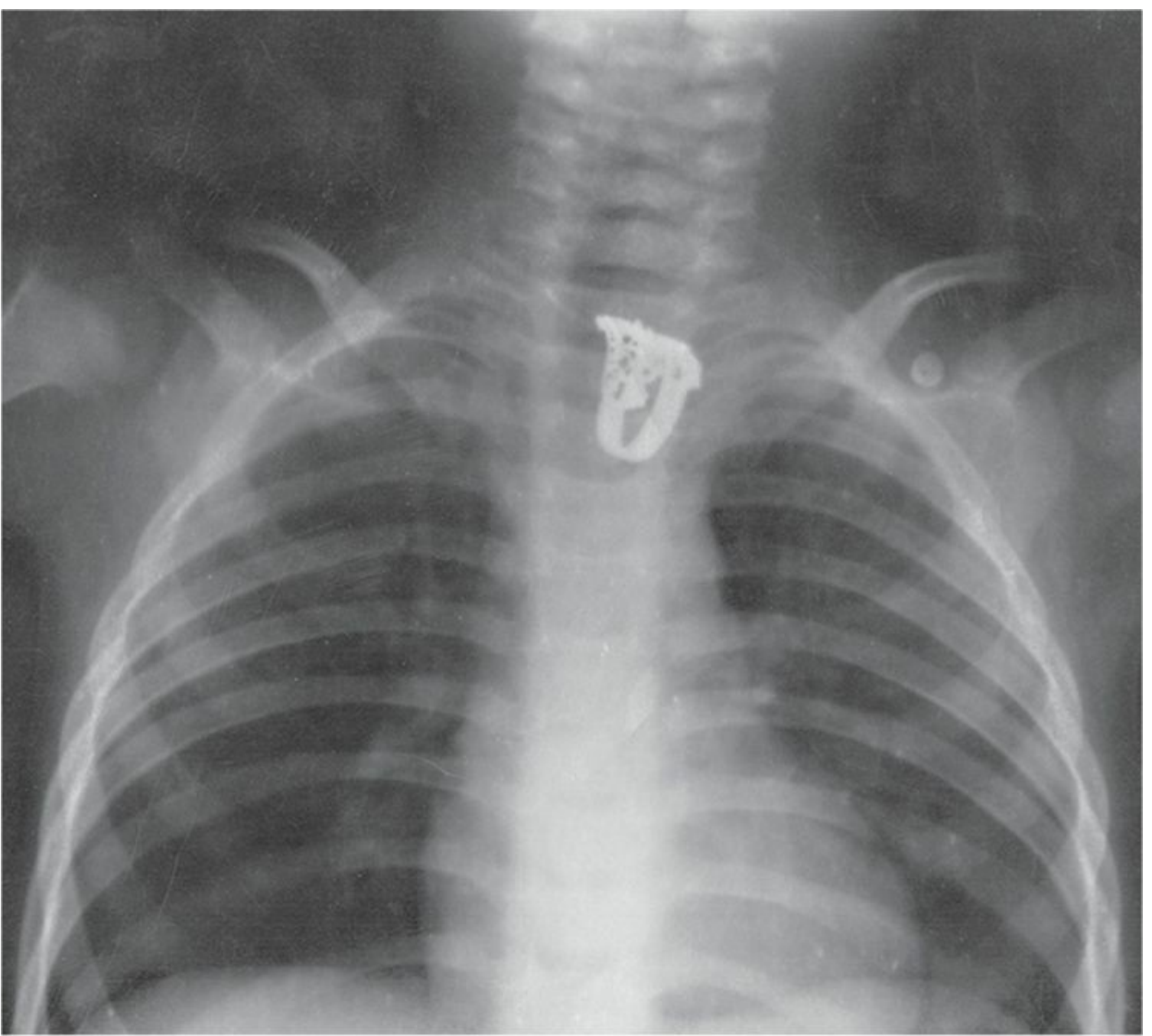
Occlusal view showing a stone in right submandibular duct.



Dhingra: Diseases of Ear Nose and Throat, 5th Edition  
Copyright © 2010 Elsevier. All rights reserved.

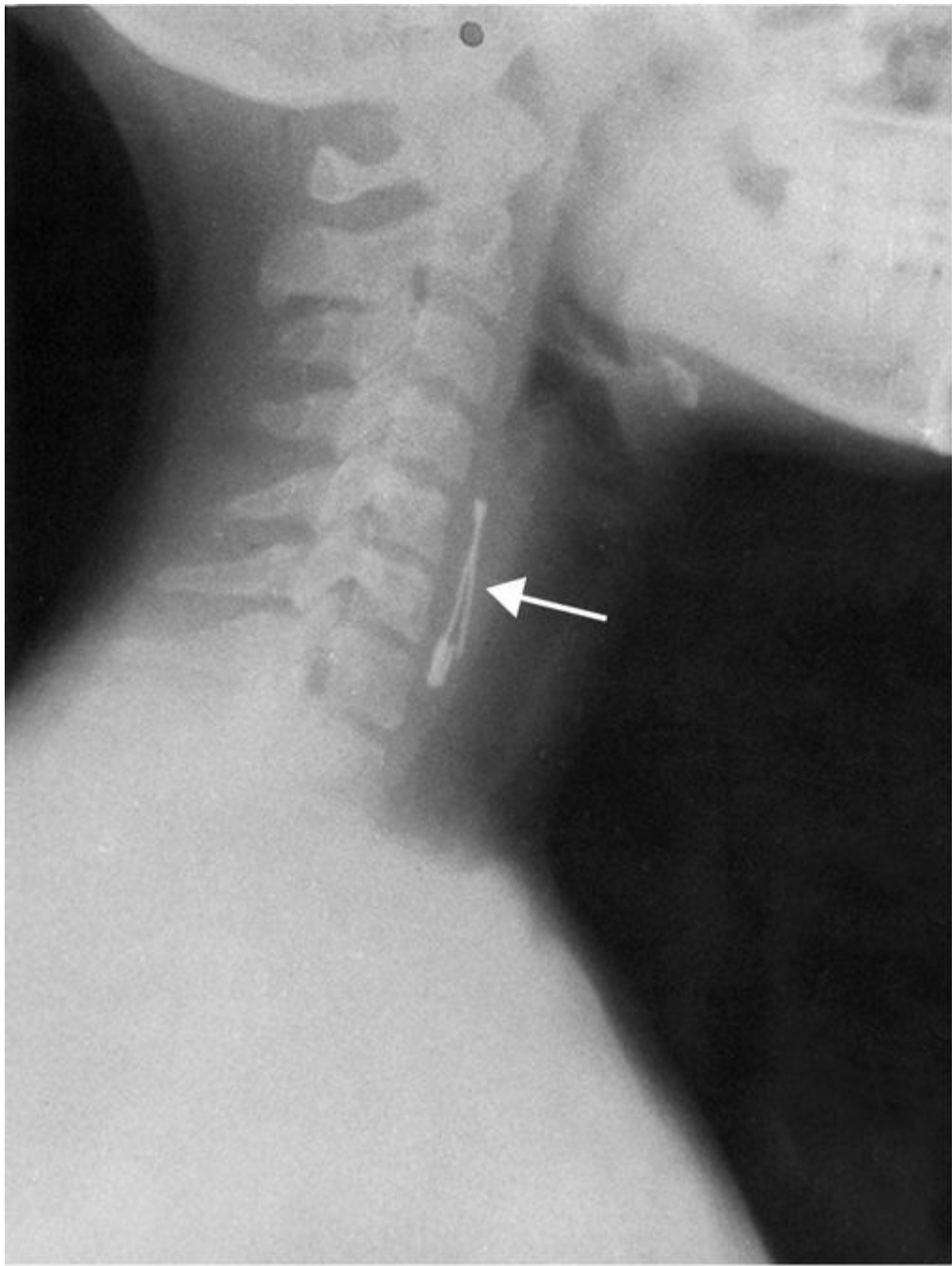
Lateral view neck showing a foreign body (coin) in oesophagus. Note the end-on position of coin in this position.





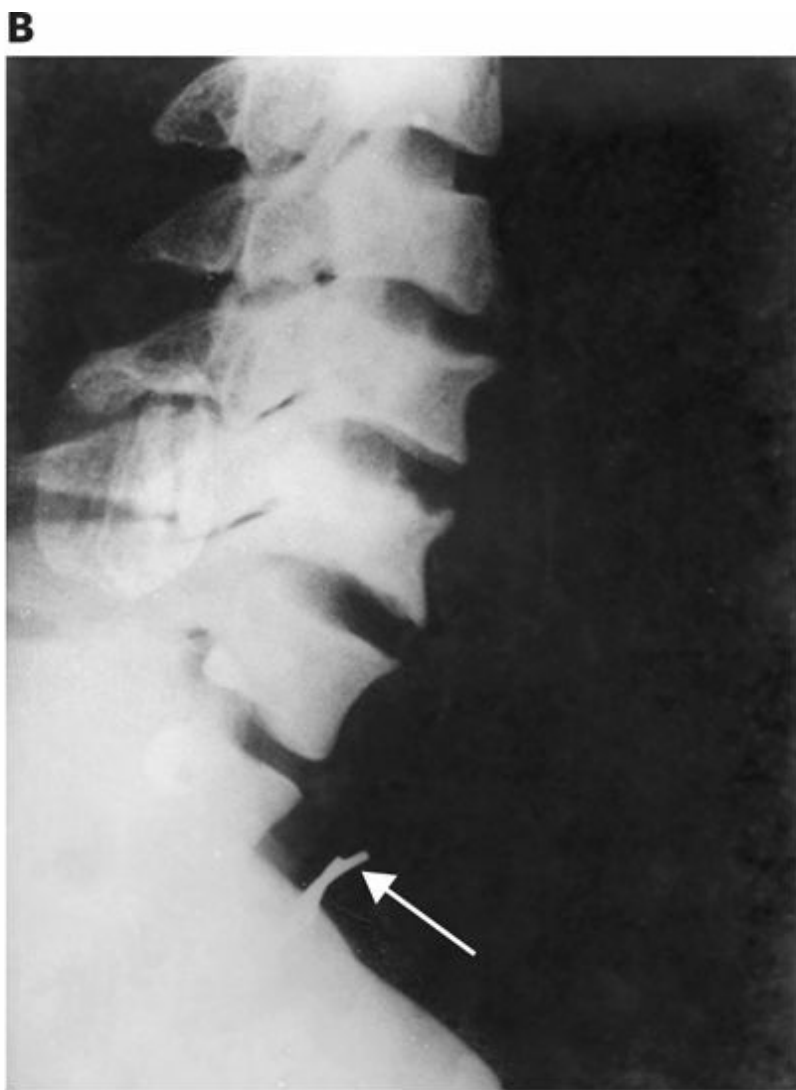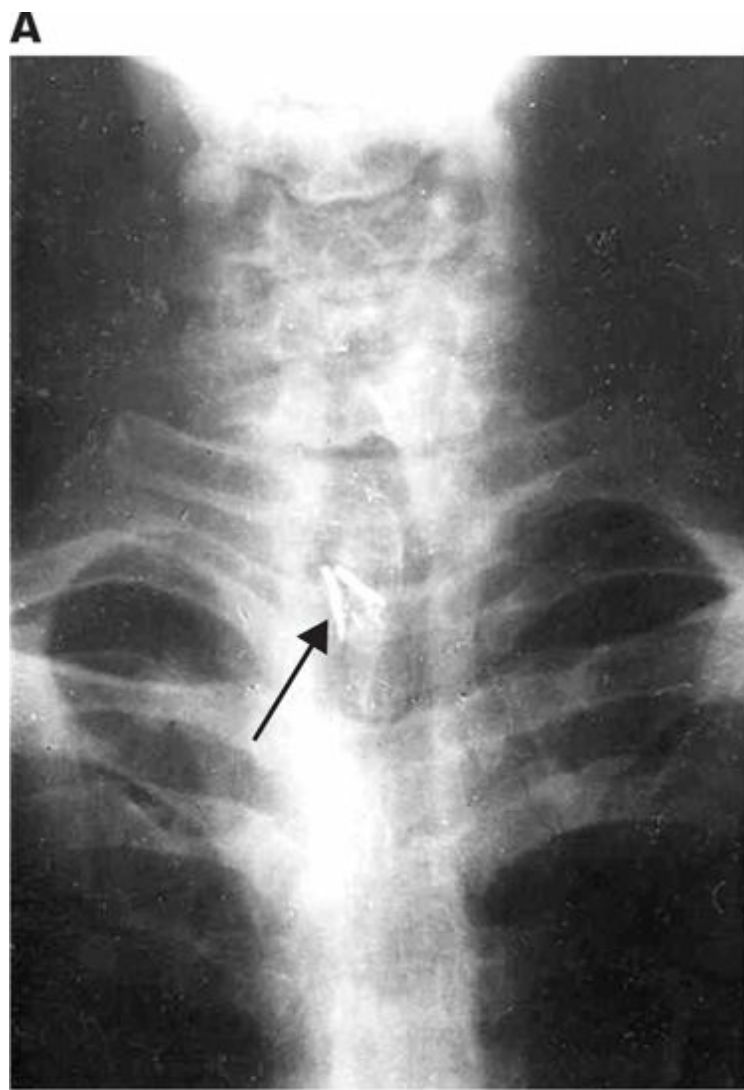
Dhingra: Diseases of Ear Nose and Throat, 5th Edition  
Copyright © 2010 Elsevier. All rights reserved.

P.A. view-neck and chest showing a ring at the level of thoracic inlet.



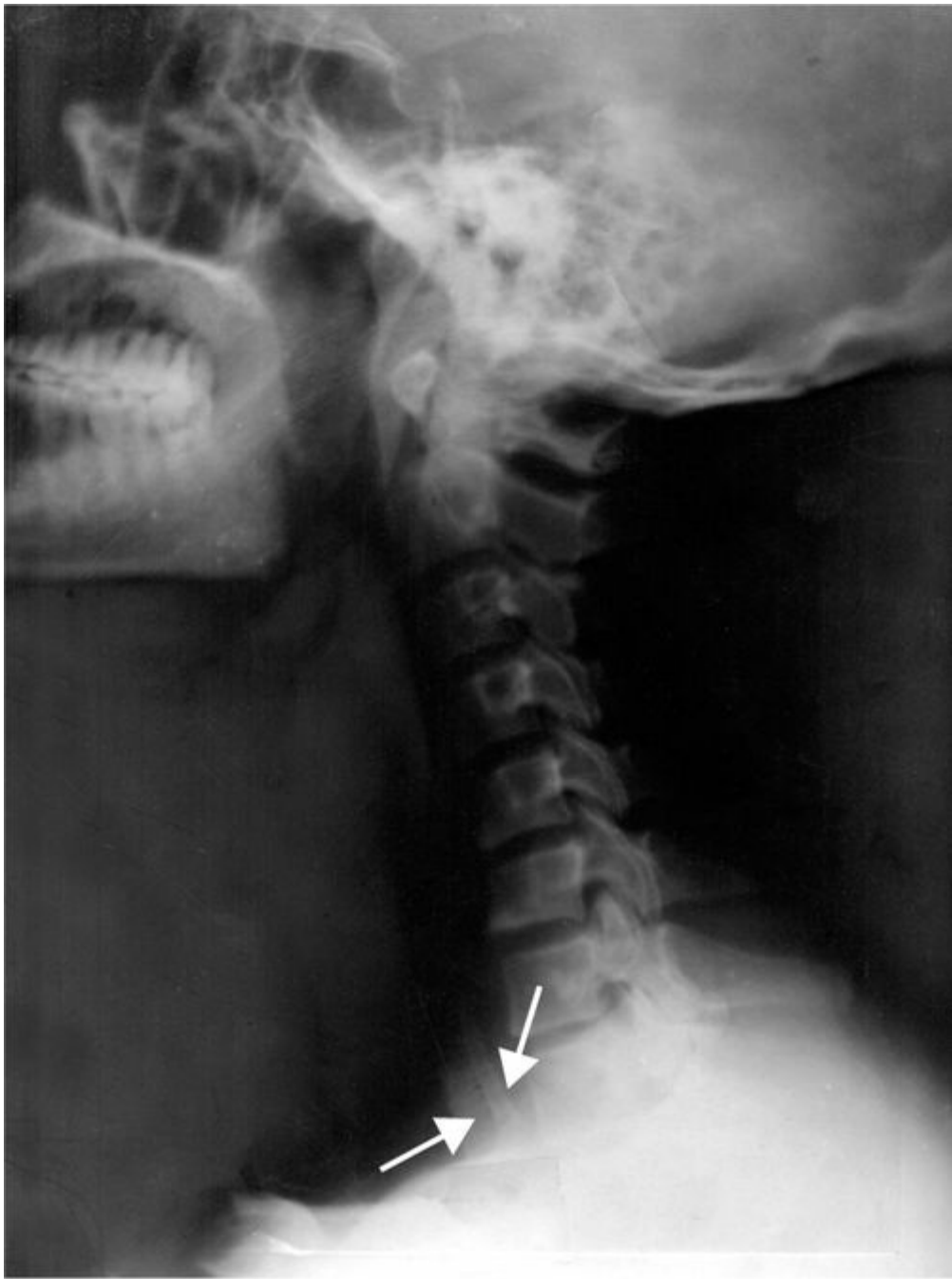Dhingra: Diseases of Ear Nose and Throat, 5th Edition  
Copyright © 2010 Elsevier. All rights reserved.

Open safety pin in the oesophagus. Note its point is directed downwards.



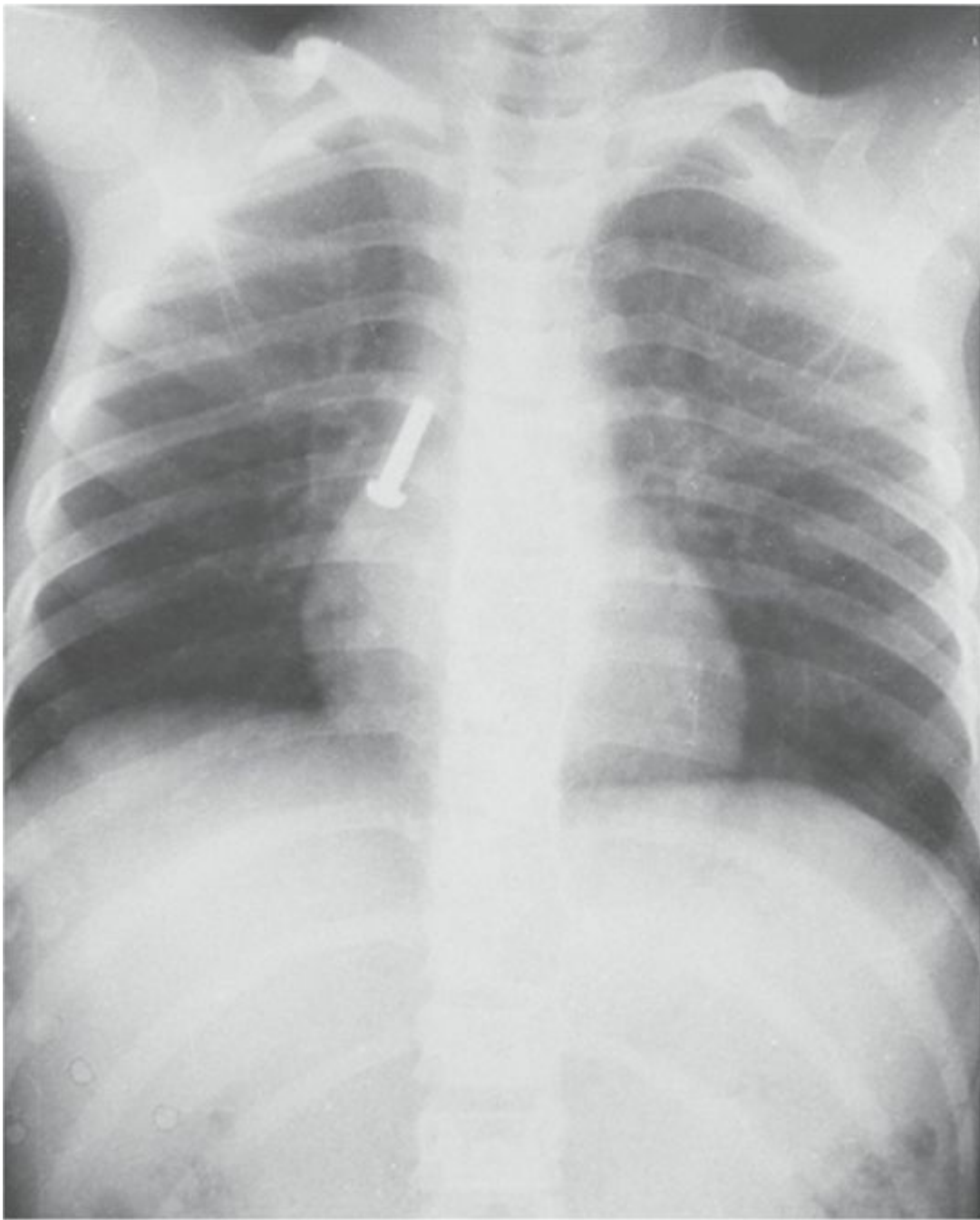
Dhingra: Diseases of Ear Nose and Throat, 5th Edition  
Copyright © 2010 Elsevier. All rights reserved.

(A) P.A. view-neck and chest with denture at the level of thoracic inlet. Denture is radiolucent but two metallic hooks are visible (arrow). (B) Lateral view-neck of the same patient showing metallic hooks at thoracic inlet (arrow).



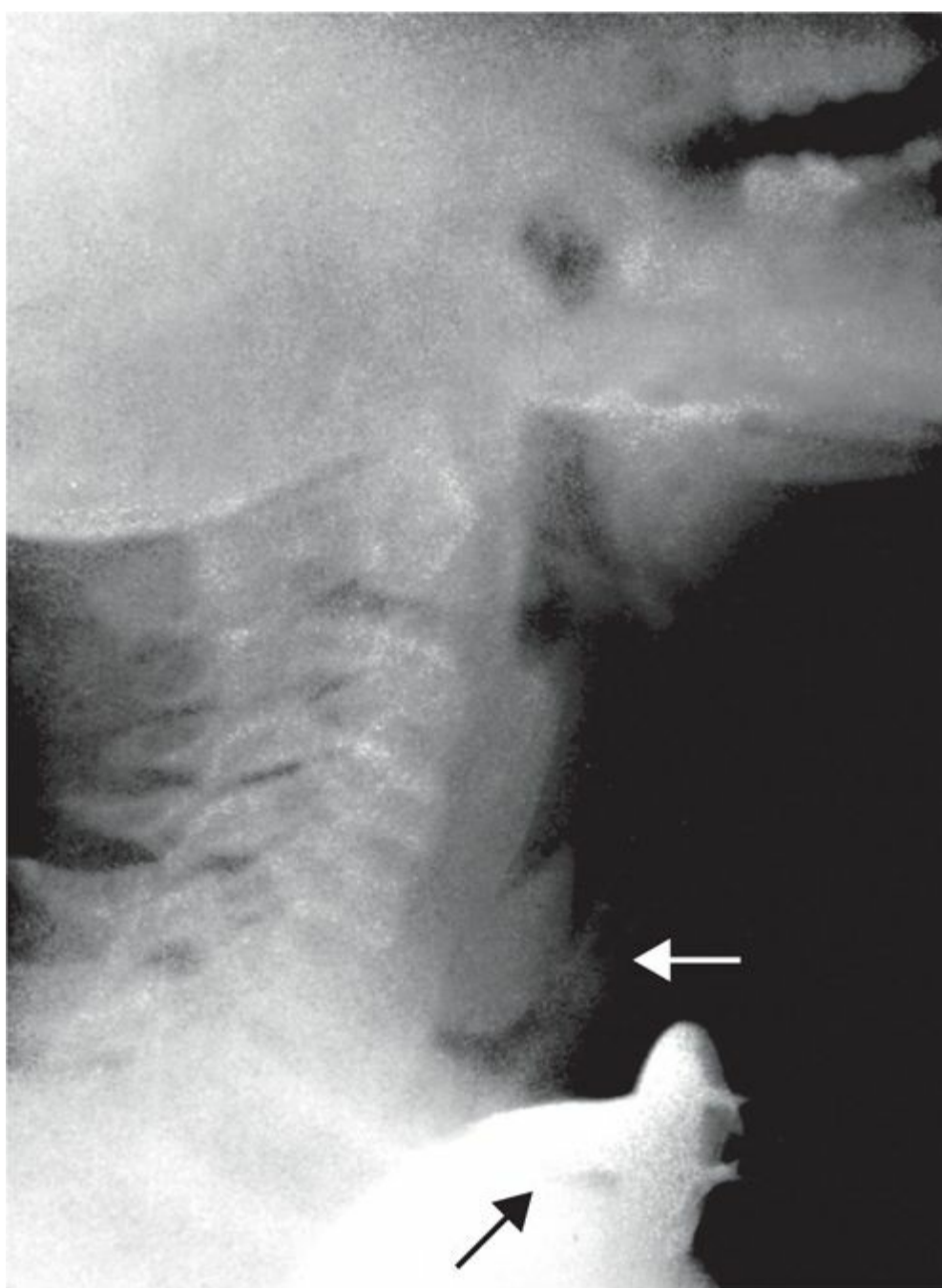
Dhingra: Diseases of Ear Nose and Throat, 5th Edition  
Copyright © 2010 Elsevier. All rights reserved.

X-ray lateral view neck showing a chicken bone in the oesophagus opposite C7 and C8 (arrows).



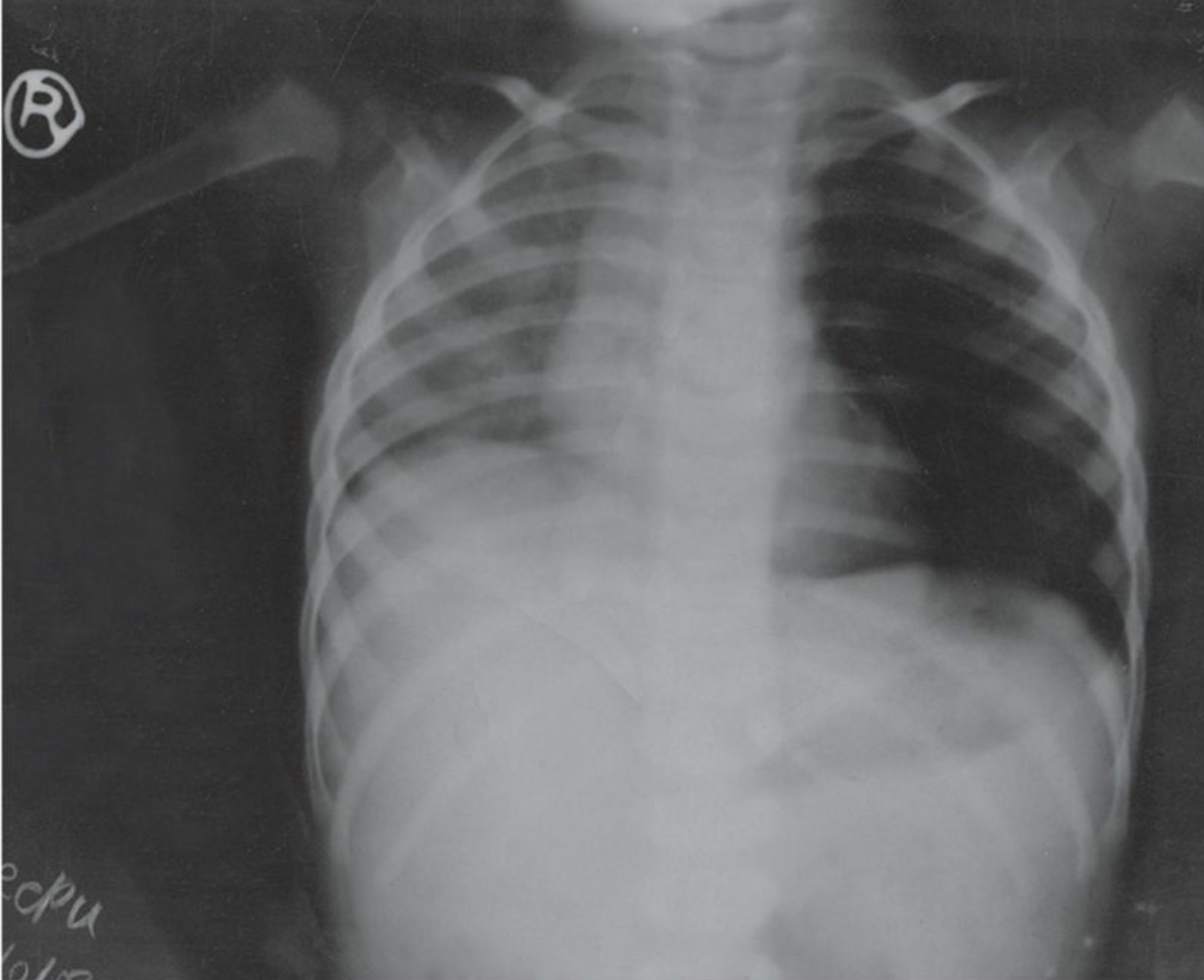
Dhingra: Diseases of Ear Nose and Throat, 5th Edition  
Copyright © 2010 Elsevier. All rights reserved.

P.A. view chest. A radio-opaque foreign body (nail) in the right bronchus.



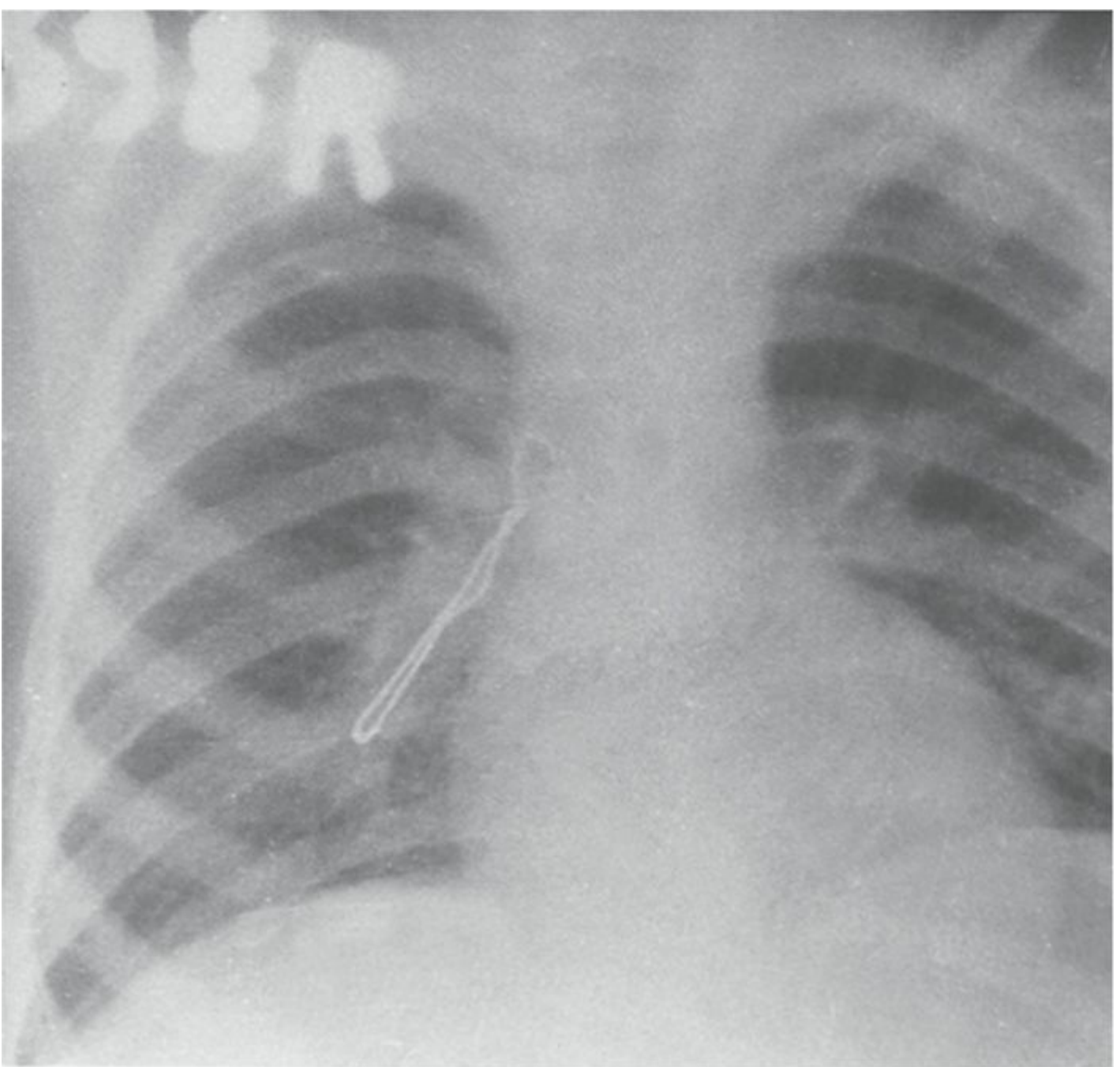
Dhingra: Diseases of Ear Nose and Throat, 5th Edition  
Copyright © 2010 Elsevier. All rights reserved.

Soft tissue lateral view neck showing a fruit seed (Chiku) in the subglottic region of larynx (arrow). Note: The patient needed tracheostomy (black arrow) to relieve obstruction.



Dhingra: Diseases of Ear Nose and Throat, 5th Edition  
Copyright © 2010 Elsevier. All rights reserved.

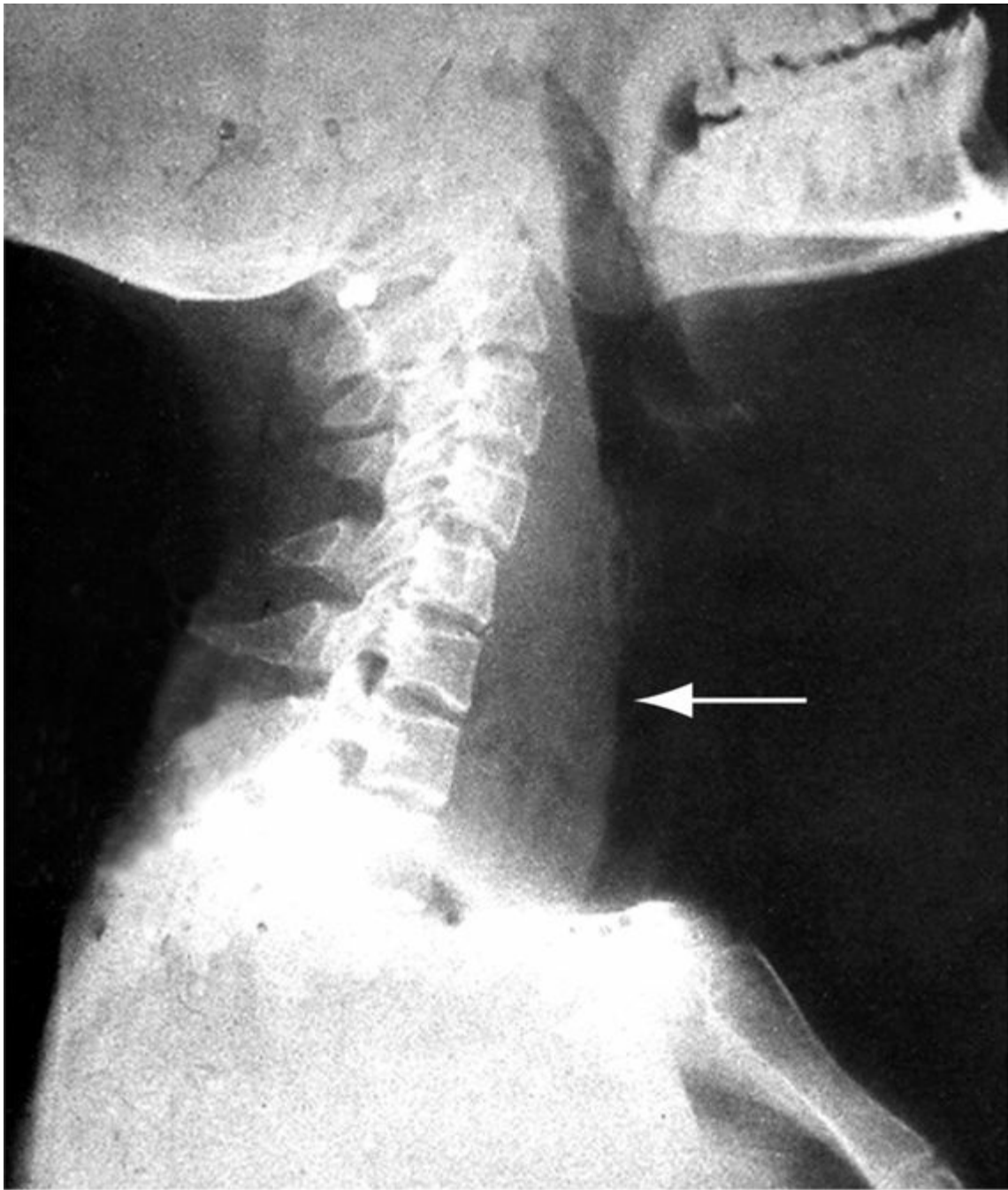
P.A. chest in a child with a radiolucent foreign body (a peanut) in right bronchus. Note: (i) Collapse of right lung and shift of mediastinum to the same side. (ii) Raised dome of diaphragm on the right. (iii) Emphysema left lung.



Dhingra: Diseases of Ear Nose and Throat, 5th Edition  
Copyright © 2010 Elsevier. All rights reserved.

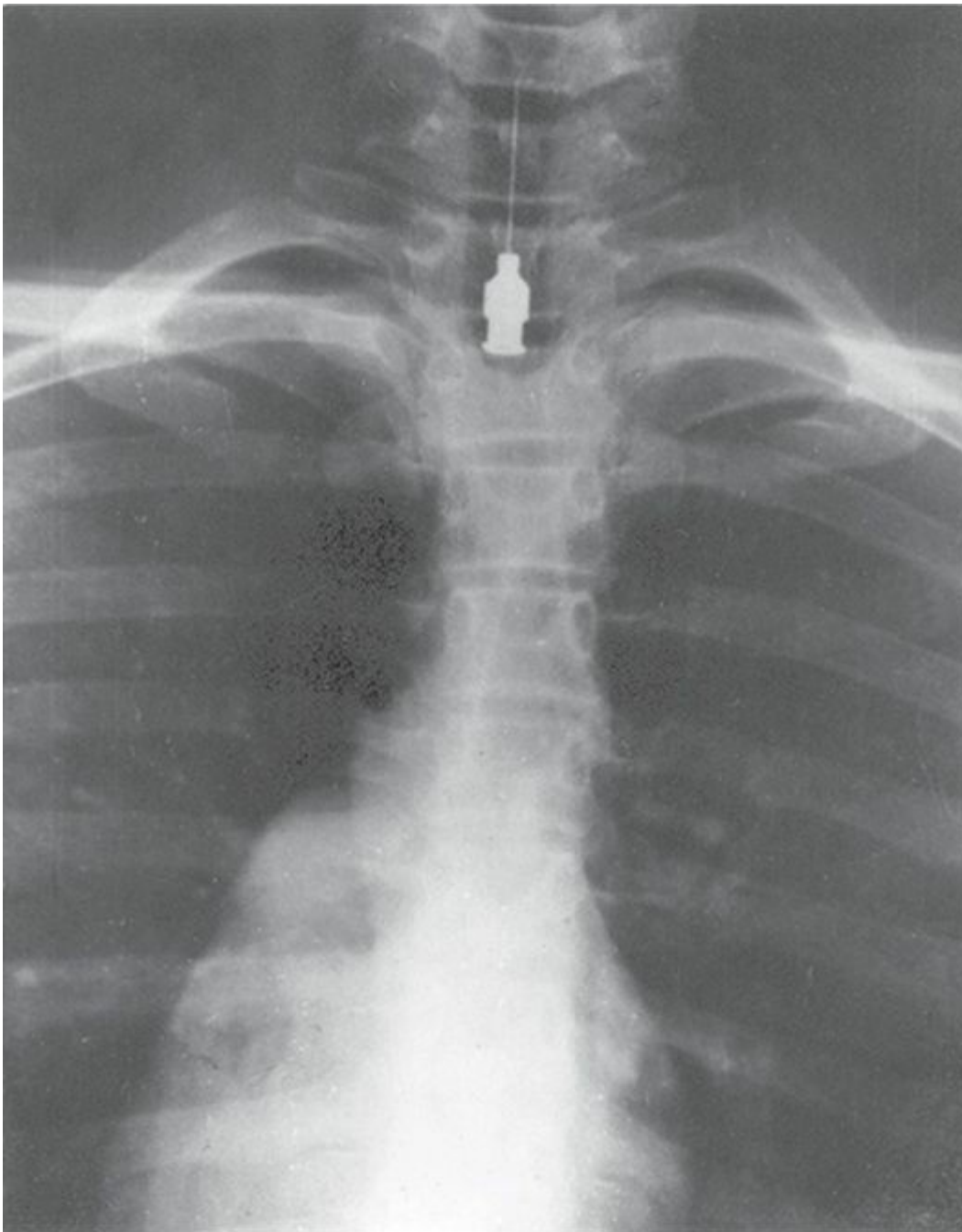
P.A. view chest showing a hair pin in the right bronchus.





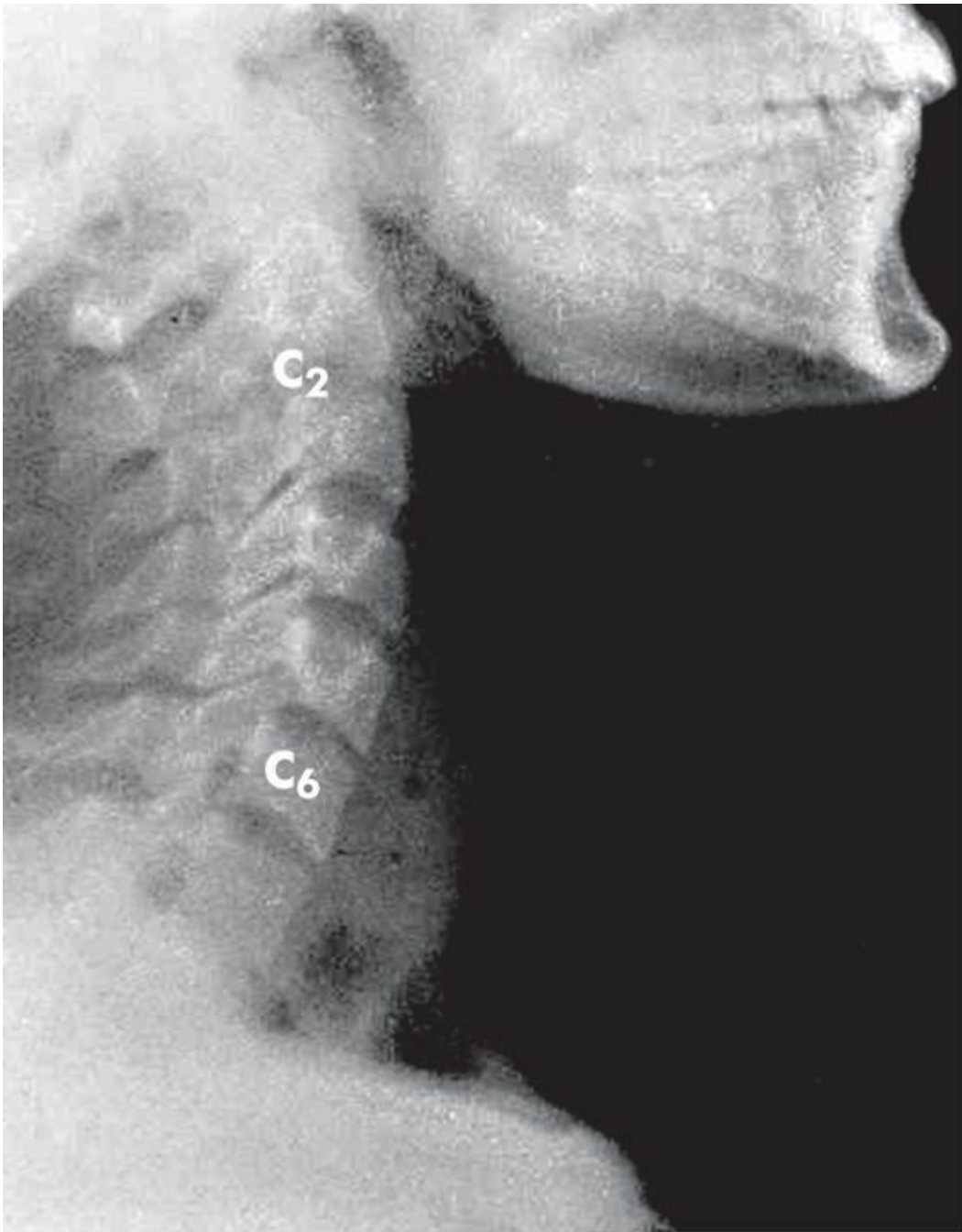
Dhingra: Diseases of Ear Nose and Throat, 5th Edition  
Copyright © 2010 Elsevier. All rights reserved.

Soft tissue lateral view neck showing retro-pharyngeal and retro-oesophageal abscess due to a fish bone in a 25-years-old female. Note: (i) Increased prevertebral soft tissue shadow (maximum against C7). (ii) Compression of trachea compromising the airway. (iii) Straightening of cervical spine. (iv) Vertebral bodies and intervertebral spaces are normal.



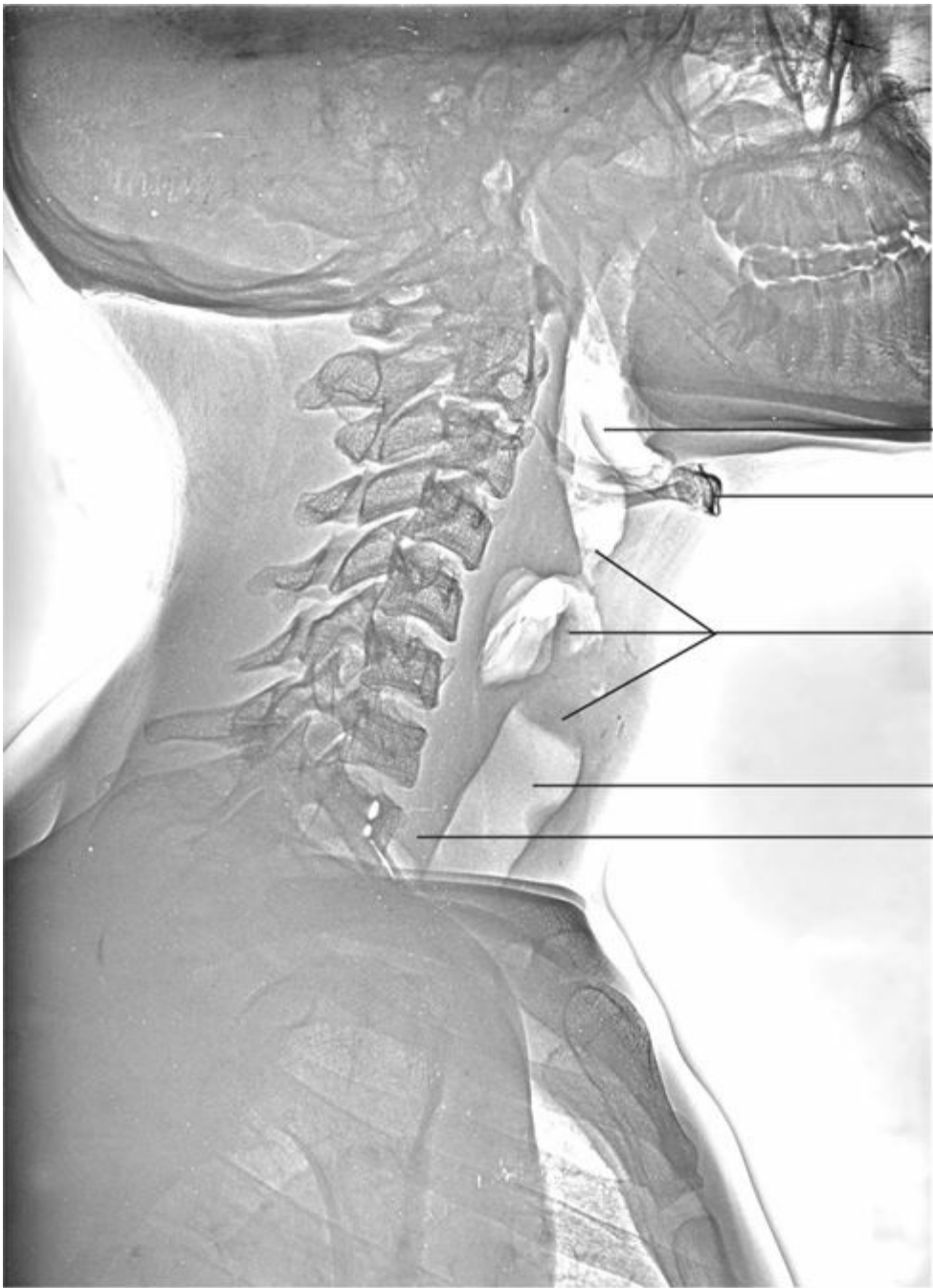
Dhingra: Diseases of Ear Nose and Throat, 5th Edition  
Copyright © 2010 Elsevier. All rights reserved.

Hypodermic injection needle in the trachea in an adult. Sudden gasp due to a pat on the back from an unnoticed friend when he was busy pricking his teeth.



Dhingra: Diseases of Ear Nose and Throat, 5th Edition  
Copyright © 2010 Elsevier. All rights reserved.

Radiograph (lateral view neck) showing retropharyngeal abscess. Note increase in width of prevertebral soft tissues opposite C<sub>6</sub> and also gas shadow due to gas-producing organisms. To diagnose retropharyngeal abscess, the prevertebral soft tissue shadow should exceed width of body of C<sub>2</sub> (or should be more than 7 mm) in both children and adults opposite C<sub>2</sub>. Opposite C<sub>6</sub>, the soft tissue shadow should exceed 14 mm in children less than 15 years and 22 mm in adults.



Epiglottis

Hyoid bone

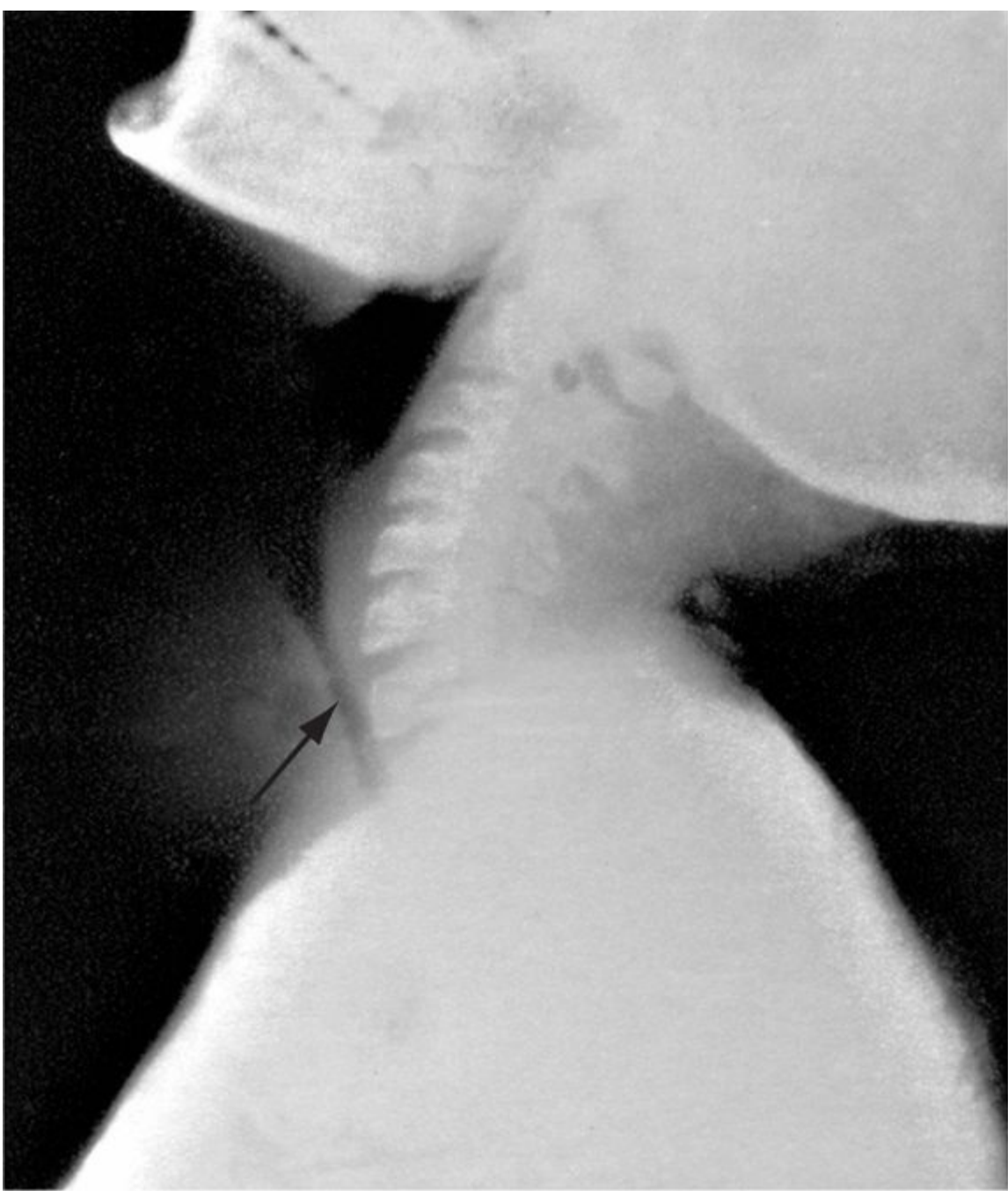Laryngeal  
stenosis

Trachea

Prevertebral  
shadow

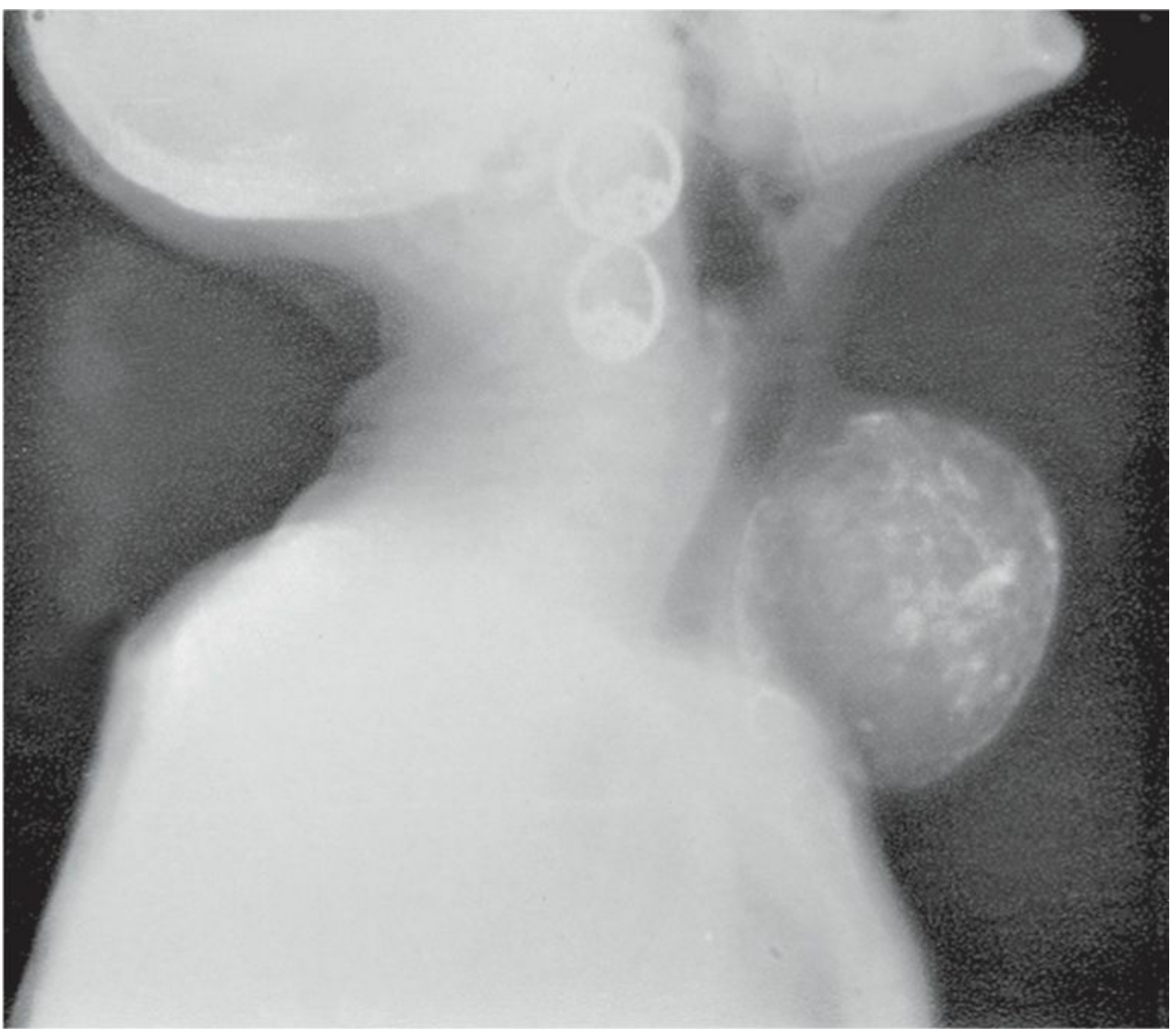
Dhingra: Diseases of Ear Nose and Throat, 5th Edition  
Copyright © 2010 Elsevier. All rights reserved.

Xeroradiograph (lateral view neck). Note laryngeal stenosis involving supraglottic, glottic and subglottic regions.



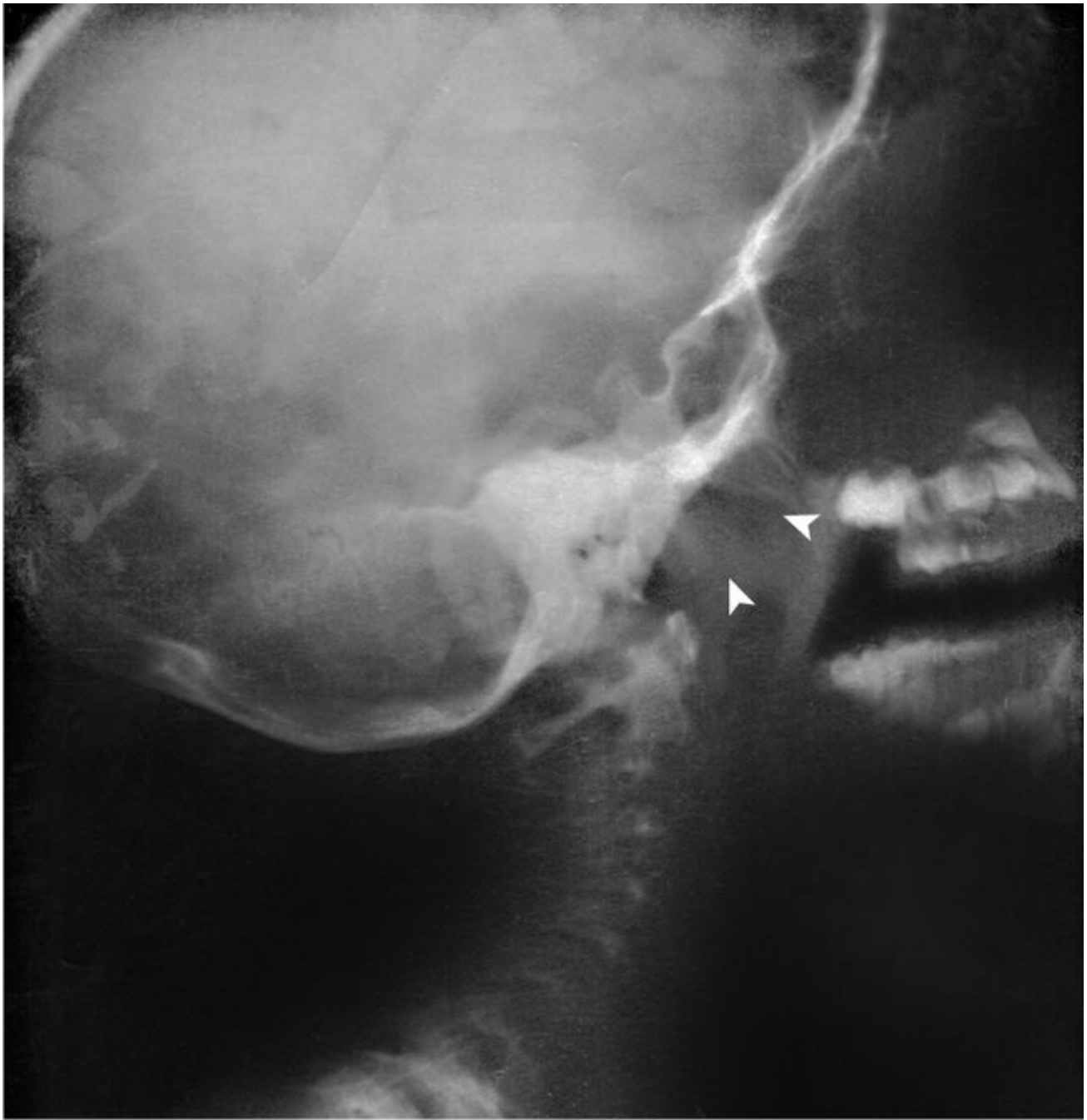Dhingra: Diseases of Ear Nose and Throat, 5th Edition  
Copyright © 2010 Elsevier. All rights reserved.

Soft tissue radiograph (lateral neck) showing tracheal compression due to thyroid mass.



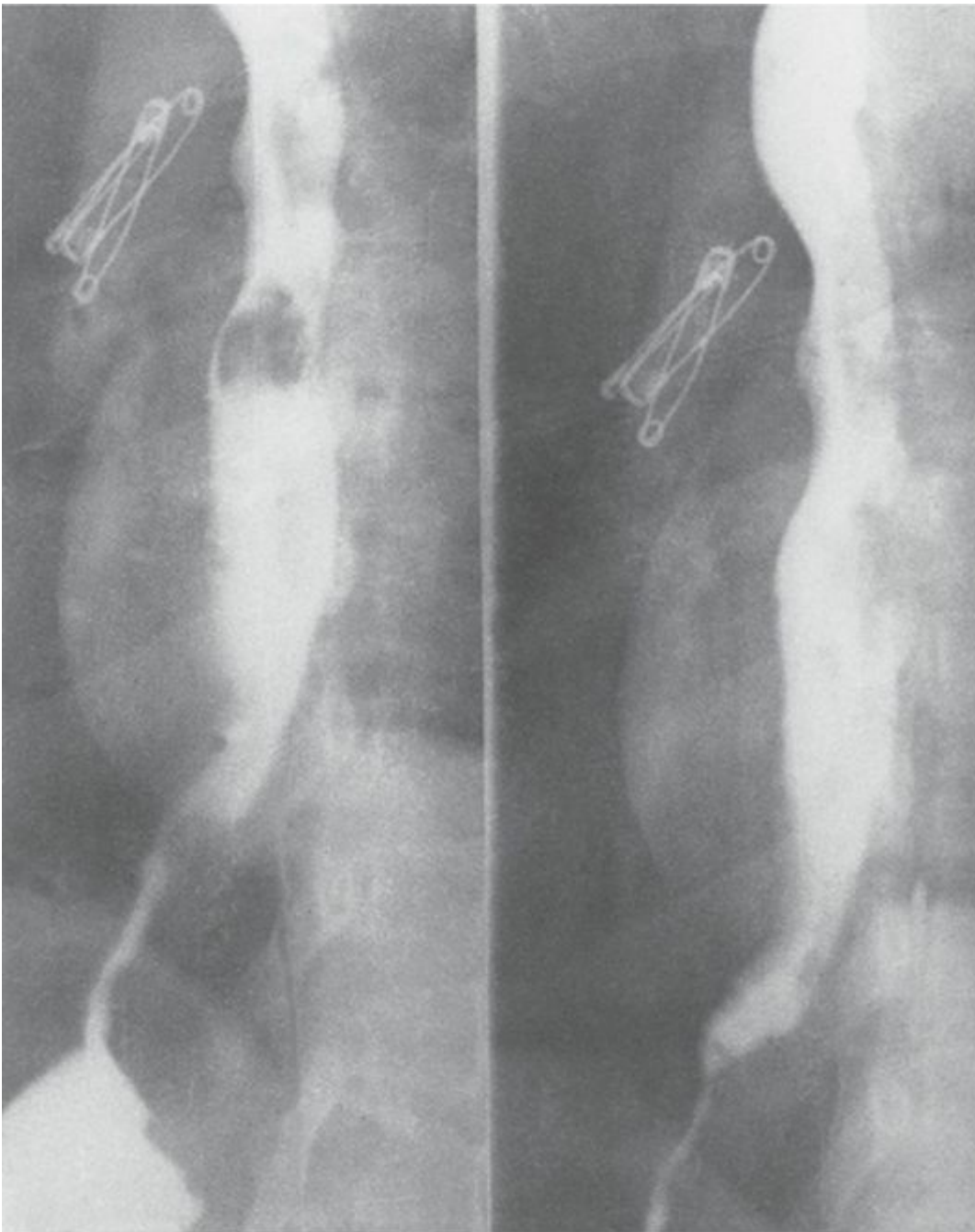
Dhingra: Diseases of Ear Nose and Throat, 5th Edition  
Copyright © 2010 Elsevier. All rights reserved.

Lateral view neck showing calcification in the thyroid gland.



Dhingra: Diseases of Ear Nose and Throat, 5th Edition  
Copyright © 2010 Elsevier. All rights reserved.

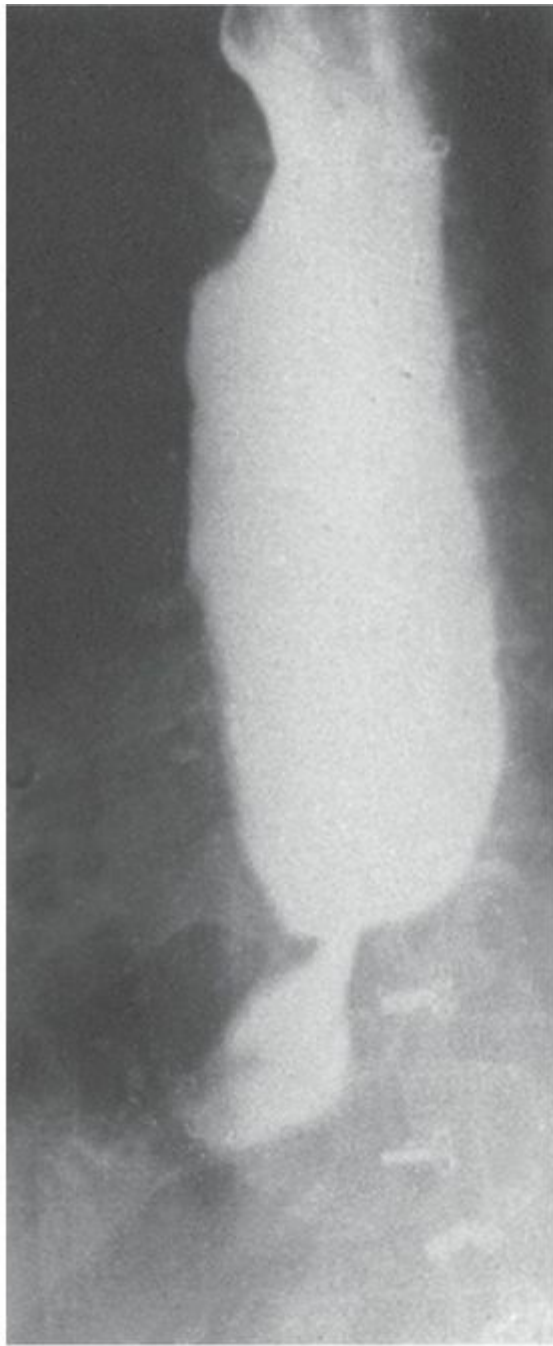Soft tissue lateral view-nasopharynx. Note a large adenoid mass almost completely obstructing the nasopharyngeal airway (arrowheads).



Dhingra: Diseases of Ear Nose and Throat, 5th Edition  
Copyright © 2010 Elsevier. All rights reserved.

Barium swallow in a patient with dysphagia. Note irregular narrowing of lower oesophagus due to carcinoma.





Dhingra: Diseases of Ear Nose and Throat, 5th Edition  
Copyright © 2010 Elsevier. All rights reserved.

Cardiac achalasia (Megaesophagus). There is a failure of lower oesophageal sphincter to relax with dilatation of oesophagus due to stasis of food. Achalasia is due to degeneration of ganglion cells of Auerbach's plexus.

---

page 454

page 455

page 455

page 456

page 456

page 457

\* Note: For details and better understanding, the reader is advised to refer the relevant section of the book.

---

page 457

page 458

page 458

page 459

page 459

page 460

page 460

page 461

page 461

page 462

- 
- 
- 

- (i) Conductive hearing loss (due to eustachian tube obstruction).
- (ii) Ipsilateral immobility of soft palate.
- (iii) Neuralgic pain in the distribution of V<sub>3</sub>.

Trismus and preauricular fullness may be associated with the above.

page 462  
page 463  
page 463  
page 464  
page 464  
page 465  
page 465  
page 466  
page 466  
page 467  
page 467  
page 468  
page 468  
page 469  
page 469  
page 470  
page 470  
page 471  
page 471  
page 472  
page 472  
page 473  
page 473  
page 474  
page 474  
page 475